Published by the American Medical Association

March 1977

16.8.77

COK-H05053-8-P024906

archives of Dermatology

Reviewers for 1976 . . . 283

Chemosurgery for Melanoma . . . 285

Treatment of Psoriasis . . . 292

Griseofulvin Absorption . . . 302

Giant Basal Cell Carcinoma . . . 316

Human Scabies . . . 320

Volume 113 Number 3

Complete Contents . . . 258

Eruptions Due to Oral Contraceptives . . . 333

Immunology of Leprosy . . . 345

Radiotherapy and Thyroid Cancer . . . 362

AMA AMERICAN MEDICAL ASSOCIATION

LIBRARY

Reservoir of moisture

Each bath with Alpha Keri® Therapeutic Bath Oil is a reservoir of moisture for dry skin. The addition of Alpha Keri in the bath helps skin store moisture for days. And feel soft, smooth, and supple in minutes. (Between baths, a single application of Keri® Lotion instantly restores moisture to dry skin for hours.)

Alpha Keri®
Therapeutic Bath Oil

helps skin keep in touch with moisture

See PDR for complete product information.

WESTWOOD PHARMACEUTICALS INC.
Buffalo, New York 14213
In Canada, Belleville, Ontario K8N 5E9

© 1976, W. P. Inc.

For effective and individualized control of acne....

Prescribe the only benzoyl peroxide acne medication available in cover-up lotions....

LOROXIDE® Acne Lotion and LOROXIDE-HC® Lotion

(benzoyl peroxide 5.5%, chlorhydroxyquinoline ¼%) (benzoyl peroxide 5.5%, chlorhydroxyquinoline ¼%, hydrocortisone ½%)

- Contains the proved synergistic bactericidal combination of benzoyl peroxide and chlorhydroxyquinoline (300% greater antibacterial activity[1]) — which topically reduces C. Acnes *within* comedones[2]
- LOROXIDE-HC® effectively treats papular, pustular and cystic acne[3] — a favorable response has been reported in 75% of patients in as short a period as two weeks[4]
- Ideal therapy providing "all day," penetrating antimicrobial activity with controlled drying and desquamation — at school, work or play.
- No sun-sensitizing properties — no need to restrict your patient's outdoor activities or eliminate the known benefits of natural UV exposure.
- *The only* adjustable tint-intensity benzoyl peroxide lotions available.
- Replaces and helps to prevent abuse with over-the-counter cosmetics.
- For *day-long control* of all grades of acne vulgaris.
- Lesion-masking base helps to eliminate the..."natural but distorted feelings that other people perceive him as 'acne with a person attached rather than as a person who happens to have acne.'"

REFERENCES: 1. Kuflik, E. G.: *Benzoyl Peroxide Gel in Acne Therapy,* Derm. Digest May, 1976, Pgs. 44-45. 2. Frank, L. and Petrou, P.: *Active Oxygen Plus Chlorhydroxyquinoline in Acne and Pyodermas,* Cutis, 3:3, Pg. 256-260, March, 1967. 3. Lubowe, I.: *Adolescent Skin Problems,* Cutis, Vol. 17, Pg. 369-374, February, 1976. 4. Frank, L.: *Active Oxygen in Acne Therapy,* Cutis 1:306, 1965. 5. Reisner, R.: *The Rational Therapy of Acne,* Cutis, Vol. 17, Pgs. 527-530, March, 1976.

Plus "Instant Social Confidence"

Dermik Color Blender™

EXCLUSIVE!

Dermik

Dermik Laboratories, Inc.
Fort Washington, Pa. U.S.A. 19034

OROXIDE® Acne Lotion and LOROXIDE-HC® Lotion

DESCRIPTION: Loroxide Acne Lotion contains (as dispensed) benzoyl peroxide 5.5%, and chlorhydroxyquinoline 0.25%; incorporated in a water washable lotion consisting of purified water, propylene glycol, hydroxyethylcellulose, caramel color, cholesterol-sterol, cetyl alcohol, propylene glycol stearate, polysorbate 20, lanolin alcohol, propylparaben, decyl oleate, purcelline oil syn., antioxidants, vegetable oil, methylparaben, tetrasodium EDTA, buffers, cyclohexanediamine tetraacetic acid, calcium phosphate, silicone emulsion, silica, kaolin, talc and titanium dioxide, with "Dermik Color Blender™" supplied separately.

Loroxide-HC Lotion contains (as dispensed) hydrocortisone 0.5%, benzoyl peroxide 5.5% and chlorhydroxyquinoline 0.25% incorporated in a lotion identical to Loroxide Lotion (see above).

Actions: Provides keratolytic, peeling and drying action.

Indications: An aid in the treatment of acne and oily skin.

Contraindications: This product is contraindicated for use by patients having known hypersensitivity to hydrocortisone, benzoyl peroxide, chlorhydroxyquinoline or any other component of this preparation. Topical steroids are contraindicated in viral diseases of the skin, such as varicella and vaccinia.

Warning — Usage in Pregnancy: Although topical steroids have not been reported to have an adverse effect on the fetus, the safety of their use during pregnancy has not been absolutely established. Therefore, they should not be used extensively, or in large amounts or for prolonged periods of time on pregnant patients.

Precautions: For external use only. Keep away from eyes. If irritation develops, the product should be discontinued and appropriate therapy instituted. In the presence of an infection, the use of appropriate antifungal or antibacterial agents should be instituted. If a favorable response does not occur promptly, the corticosteroid should be discontinued until the infection has been adequately controlled. If extensive areas are treated, or if the occlusive technique is used, the possibility exists of increased systemic absorption of the corticosteroid and suitable precautions should be taken.

Do not add any other medicaments or substances to this lotion unless specifically directed by physician to do so. Patients should be observed carefully for possible local irritation or sensitization during long-term topical therapy. Apply with caution on neck and/or other sensitive areas. There may be a slight, transitory stinging or burning sensation on initial application which invariably disappears on continued use. Ultraviolet and cold quartz light should be employed in lesser amounts, as this lotion is keratolytic and drying. Harsh, abrasive cleansers should not be used simultaneously with this lotion. Colored or dyed garments may be bleached by the oxidizing action of benzoyl peroxide. Chlorhydroxyquinoline may cause temporary light-yellowish skin staining in rare cases. Keep out of the reach of children.

Adverse Reactions: The following local adverse reactions have been reported with topical corticosteroids: burning sensations, itching, irritation, dryness, folliculitis, secondary infection, skin atrophy, striae, hypertrichosis, acneiform eruptions, and hypopigmentation. The sensitizing potential of benzoyl peroxide and chlorhydroxyquinoline are low, but they can, on occasion, produce allergic reaction. Occurrence of excessive redness or peeling indicates that the amount and frequency of application should be reduced.

Directions: Shake well before using. Apply a small quantity to affected areas with light massaging 1 to 3 times daily, or in accordance with the physician's directions.

(Important information directed to the Pharmacist: At time of dispensing, add contents of vial* to the bottle. Shake well and/or stir with a glass rod to insure a uniform dispersion. Place expiration date of three (3) months on bottle label.)

*"Benzie-Pak" vials contain a mixture of benzoyl peroxide 35% and calcium phosphate 65%.

Net weight of each vial is 3.8 grams.

How Supplied: Bottles, 25 Gm.

Caution: Federal law prohibits dispensing without prescription.

Archives of DERMATOLOGY

Copyright © 1977 by the AMERICAN MEDICAL ASSOCIATION

VOL 113, NO. 3 MARCH 1977

EDITORIAL

Reviewers for 1976
John H. Epstein, MD; Kimie Fukuyama, MD, Denny L. Tuffanelli, MD, San Francisco 283

ORIGINAL CONTRIBUTIONS

Chemosurgery for Melanoma
Frederic E. Mohs, MD, Madison, Wis 285

Topical Methoxsalen and Blacklight in the Treatment of Psoriasis
John W. Petrozzi, MD; Kays M. Kaidbey, MD; Albert M. Kligman, MD, PhD, Philadelphia 292

Shortage of Full-Time Faculty in Dermatology
Clayton E. Wheeler, Jr, MD; Robert A. Briggaman, MD; Ivor Caro, MB, BCh, FF Derm, Chapel Hill, NC 297

Gastrointestinal Absorption of Griseofulvin From Corn Oil-in-Water Emulsions
Theodore R. Bates, PhD; Henry J. Pieniaszek, Jr; Joel A. L. Sequeira; James E. Rasmussen, MD, Buffalo, NY 302

Superficial Mycoses
Nardo Zaias, MD, Francisco Battistini, MD, Miami Beach, Fla 307

Serum IgE in Dermatitis and Dermatosis
Sean O'Loughlin, MD; Jose L. Diaz-Perez, MD; Gerald J. Gleich, MD; R. K. Winkelmann, MD, PhD, Rochester, Minn 309

Giant Basal Cell Carcinoma
Mary C. Curry, MD; Hamilton Montgomery, MD; Richard K. Winkelmann, MD, PhD, Rochester, Minn 316

Pathologic Findings in Human Scabies
Nilda Fernandez, MD; Antonio Torres, MD; A. Bernard Ackerman, MD, New York 320

CASE REPORTS

Bullous Disease of Childhood
Edward Shmunes, MD, Columbia, SC, Suyu Shu, PhD, Buffalo 325

Pseudofolliculitis Capitis
Maj James D. Smith, MC, USA, Lt Col Richard B. Odom, MC, USA, Presidio of San Francisco, Calif 328

(Continued on page 260)

EDITORIAL BOARD

Chief Editor
John H. Epstein, MD
450 Sutter Street
San Francisco 94108

Assistant Chief Editor
Kimie Fukuyama, MD
San Francisco

Assistant Chief Editor
Denny L. Tuffanelli, MD
San Francisco

Donald C. Abele, MD
Augusta, Ga.

Harry L. Arnold, Jr, MD
Honolulu

Walter C. Lobitz, Jr, MD
Portland, Ore

Frederick D. Malkinson, MD
Chicago

Sigfrid A. Muller, MD
Rochester, Minn

W. Mitchell Sams, Jr, MD
Denver

John S. Strauss, MD
Boston

Morris Waisman, MD
Tampa, Fla

Gerald D. Weinstein, MD
Miami


OPTIMAL PENETRATION
a completely dissolved hydrocortisone for optimal cutaneous penetration with a rapid release vehicle for maximum hydrocortisone effectiveness
nutracort® Gel
(1.0% Hydrocortisone Gel)
SCRIPTION: Nutracort* Gel 1.0% provides 1.0% drocortisone in a non-aqueous clear gel base ntaining propylene glycol, alcohol 22% (w/w), droxypropyl cellulose, and citric acid. NTRAINDICATIONS. In viral diseases of the skin h as varicella and vaccinia and in patients with a ory of hypersensitivity to any component. Not for thalmic use. Topical steroids should not be used n circulation is markedly impaired. PRECAUTIONS: itation develops, discontinue and institute opriate therapy. In presence of infection, use of opriate antifungal or antibacterial agents should be tuted. If a favorable response is not obtained mptly, discontinue until the infection has been equately controlled. Suitable precautions should be en against increased systemic absorption which may r if extensive areas are treated or if the occlusive ue is used. Should not be used extensively, amounts, or for prolonged periods in pregnancy.
Owen
nutracort® Gel
(1.0% HYDROCORTISONE GEL)
60 GRAMS
ADVERSE REACTIONS: Burning sensation, itching, irritation, dryness, folliculitis, secondary infection, skin atrophy, striae, hypertrichosis, acneform eruption and hypopigmentation have been reported with or without occlusive dressings. DOSAGE: Apply to affected areas 3 to 4 times daily. HOW SUPPLIED: Nutracort* Gel (1.0% hydrocortisone gel) is available in a 60 gram tube. Nutracort* Lotion is available in 0.25%, 0.5% and 1.0% strengths, 2 oz. and 4 oz. bottles Nutracort* Cream available in 0.25%, 0.5% and 1.0% strengths, 2 oz. and 4 oz. jars. Nutracort* Cream 1.0% also available in 1 lb. jars.
Owen Owen Laboratories
Dallas, Texas 75234
Division of Alcon Laboratories, Inc.

CONTENTS—Continued

Multicentric Reticulohistiocytosis
David R. Taylor, MD, Fresno, Calif 330

Eruptions Due to Oral Contraceptives
Ralph J. Coskey, MD, FACP, Detroit 333

REM Syndrome (Reticular Erythematous Mucinosis)
Kalman Keczkes, MB, ChB, MRCP,
Prakash Jadhav, MB, ChB, Hull, England 335

Mucocutaneous Lymph Node Syndrome
Lt Col Richard B. Odom, MC, USA,
Capt Eric G. Olson, MC, USA, Presidio of San Francisco, Calif 339

REVIEW ARTICLES

Current Concepts in the Immunology of Leprosy
Thomas H. Rea, MD, Norman E. Levan, MD, Los Angeles 345

Gamma Benzene Hexachloride Toxicity
Lawrence M. Solomon, MD; Lester Fahrner; Dennis P. West, MS, Chicago 353

AAD TASK FORCE REPORT

Dermatologic Radiotherapy and Thyroid Cancer
Herbert Goldschmidt, MD, Bala-Cynwyd, Pa 362

REGULAR DEPARTMENTS

News and Notes 369

Letters to the Editor 374

An Unusual Variant of Darier Disease James F. Dolezal, MD, Iowa City . . . **Discoid Lupus Erythematosus and the Variant Form of Hereditary Angioedema** Denny L. Tuffanelli, MD, San Francisco . . . **Furosemide-Induced Cutaneous Necrotizing Vasculitis** William M. Hendricks, MD, Richard S. Ader, MD, Cleveland . . . **Nomenclature of Antibiotics** Harry L. Parlette, MD, Pensacola, Fla . . . **Side Effects of Bounce** Charles Sheard, MD, Stamford, Conn; Donald E. Hazelrigg, MD, Isaac R. Hargett, MD, Evansville, Ind; Donald H. Huldin, MD, Lansing, Mich; James E. Weaver, PhD, Cincinnati . . . **Sunlight and Pityriasis Rosea** Howard P. Baden, MD, Jack Provan, MD, Boston . . . **Topical Therapy for Onychomycosis** Fillmore K. Bagatell, MD, Phoenix . . . **Systemic Scleroderma in Mother and Daughter** Soichiro Sasaki, MD, PhD, Hiroko Yoshino, MD, Hyogo, Japan . . . **Doxorubicin and Unusual Skin Manifestations** Ivan P. Law, MD, Fort Bragg, NC . . . **Primary Inoculation With *Mycobacterium marinum*** Ronald R. Chappler, MD; Axel W. Hoke, MD; Kenneth A. Borchardt, PhD, San Francisco

Society Transactions 384

Index to Advertisers 394

Instructions for Authors 264

SUBSCRIPTION RATES: The yearly rate of the ARCHIVES OF DERMATOLOGY is as follows: United States and US Possessions, one year, $18; two years, $28; all other countries, one year, $28; two years, $38. Special yearly price to residents, interns and medical students in the United States and US Possessions, $9.

THE ARCHIVES OF DERMATOLOGY is published monthly by the American Medical Association, 535 N Dearborn St, Chicago, IL 60610, and is an official publication of the Association. Second-class postage paid at Chicago and at additional mailing office.



Selsun®
(SELENIUM SULFIDE LOTION, U.S.P.) ℞

Brief Summary

Contains:
Selenium sulfide, 2½%, w/v; bentonite; lauric diethanolamide; ethylene glycol monostearate; titanium dioxide; amphoteric—2; sodium lauryl sulfate; sodium phosphate (monobasic); glyceryl monoricinoleate; citric acid; captan; perfume; and water.

Indications:
For the treatment of dandruff and seborrheic dermatitis of the scalp.

Contraindications:
Should not be used by patients allergic to any of its components.

Warnings:
Safety for use on infants has not been established.

Precautions:
Cutaneous sensitization of the scalp or adjacent areas has been reported; if sensitivity reaction should occur, discontinue use. Chemical conjunctivitis may result if product enters the eyes. Do not use when acute inflammation or exudation is present as an increase in absorption may occur.

Adverse Reactions:
As with other shampoos, oiliness or dryness of the hair and scalp may occur following use; there have been occasional reports of an increase in the amount of normal hair loss. Hair discoloration may occur; can be avoided or minimized by thorough rinsing.

ABBOTT

703318

Announcing Selsun.
What?
New Selsun®

(SELENIUM SULFIDE LOTION, U.S.P.)



Archives of Dermatology

James H. Sammons, MD
Executive Vice-President

Thomas F. Hannon
Group Vice-President,
Publishing Operations

William R. Barclay, MD
Group Vice-President,
Scientific Publications

Norman D. Richey
Director, Publication
Production Division

John T. Baker
Director, Marketing Division

Helen R. Mazur
Acting Fulfillment Manager

John T. Baker, General Sales Manager; **Robert Corcoran,** Eastern Sales Manager; **Fred Bauman, Richard M. Johnson,** Eastern Sales Representatives; **William J. Healy,** Midwest Sales Representative; **Thomas J. Carroll,** West Coast/Northern Sales Representative

PUBLICATION STAFF

Offices: 535 N Dearborn St
Chicago, IL 60610

William R. Barclay, MD, Director
Scientific Publications Division

Robert W. Mayo, Executive Editor

Marlene M. Hinsch, Production Manager

Editorial Processing Manager: Diana A. Morgan

Copy Editing: Rosanne Schulenberg (Supervisor), Rae Usinger

Proofreading: Lorraine L. Kruse (Supervisor), Helen Grzeskiewicz, Elizabeth Petrikenas, Patricia Simmers, Dorothy Troy, Dorothy Waier

Production Supervisors: Julia Bero (Layout), Thomas J. Handrigan (Illustrations), Marlene M. Hinsch (Editorial), James P. Bagniewski (Advertising)

Art and Senior Production Assistants: Betty Frigerio, Shirley Latronica, Deborah Orent, Donna Pender, Nancy Keyes, Susan Routhier, JoAnne Weiskopf

Production Assistants: Karen Branham, E. Linda Eisenberg, Anna Goins, Lucille Kuznicki

Manuscript Records: Mary Paino

Indexing: Phyllis H. McLaren (Supervisor), Jane P. Mauldin, Helen F. Topel

Please address communications concerning accepted or published communications to: AMA Specialty Journals, 535 N Dearborn St, Chicago, IL 60610.

Conditions for Acceptance of Color Illustrations

Illustrations in full color are accepted for publication in ARCHIVES OF DERMATOLOGY if the editor believes that color will add significantly to the published manuscript.

When color illustrations are accepted, the American Medical Association will pay part of the expense of reproduction and printing, the remainder to be borne by the author or the institution with which he is affiliated. After deducting AMA's contribution, the author's share is $275 for up to six square finished illustrations. Additional illustrations and special effects, such as outlining, opaquing, or surprinting, will be billed to the author at cost.

Color transparencies must be submitted for evaluation. Do not send color prints unless accompanied by original transparencies. If transparencies are mounted in frames or glass, the material should be carefully packed in gauze and sent with the manuscript in a separate container or between two pieces of pressboard.

Advertising and Subscription Information

ADVERTISING OFFICES: 535 N Dearborn St, Chicago, IL 60610, Area Code 312, 751-6000; and 122 E 42nd St, New York, NY 10017, Area Code 212-867-6640.

ADVERTISING PRINCIPLES: Each advertisement in this issue has been reviewed and complies with the principles governing advertising in AMA scientific publications. A copy of these principles is available on request.

CHANGE OF ADDRESS: Please notify the publisher at least six weeks in advance, including both old and new address, and a mailing label taken from the most recent copy. Include your new zip code number.

announcing BETADINE® microbicidal bath concentrate

to disinfect bath water before and during use

Effectiveness of disinfection demonstrated in test studies

Cultures of bath water were taken at specified intervals in 36 cases* before and during the immersion of a test subject. Bath water was recultured after adding BETADINE Microbicidal Bath Concentrate, and after the removal of the test subject.

Little contamination of bath water was seen prior to subject's immersion. High degree of contamination of bath water occurred one minute after subject's immersion (without use of BETADINE Microbicidal Bath Concentrate) regardless of the condition of the subject. No contamination of bath water could be seen in virtually all cases two minutes after the addition of BETADINE Microbicidal Bath Concentrate, while the subject remained in the tub and after subject's removal.

Test subjects in these studies presented various diagnoses, including psoriasis, neurodermatitis, bullous pemphigoid, stasis ulcers, contact dermatitis, burns, decubitus ulcers, diabetic gangrene, osteoarthritis, and

Wide area of use

BETADINE Microbicidal Bath Concentrate may be particularly useful in the disinfection of bath water whenever bathtub use is desired, as in hospitals, where persons suffering from bacterial and mycotic skin infections could contaminate the water. It can be used to help prevent contamination of bath water used by persons who are debilitated either through age, disease, or both, and who (due to their condition) are most often recommended baths rather than showers. It may be used to disinfect bath water before and during bathing of persons to avoid bacterial contamination of water in the bath.

*Data on file, Medical Department, The Purdue Frederick Company.

Purdue Frederick

Instructions for Authors

Send manuscripts by first-class mail to the Chief Editor, John H. Epstein, MD, 450 Sutter St, San Francisco, CA 94108. Manuscripts are received with the understanding that they are not under simultaneous consideration by another publication. Accepted manuscripts become the permanent property of the ARCHIVES and may not be published elsewhere without permission from the publisher (AMA).

Author Responsibility.—All accepted manuscripts are subject to copy editing. The author will receive an edited typescript rather than galley proofs for approval. The author is responsible for all statements in his work, including changes made by the copy editor.

Designate one author as correspondent and provide his address and telephone number. Order reprints at the time the typescript is returned after editorial processing. Specify address to which requests for reprints should be sent.

Manuscript Preparation.—Submit an original typescript and two high-quality copies of the entire manuscript. All copy (including references, legends, and tables) must be typed double-spaced on 22 × 28-cm (8½ × 11-inch), heavy-duty white bond paper. Ample margins should be provided.

Refer to patients by number (or, in anecdotal reports, by fictitious given names). Real names or initials should not be used in the text, tables, or illustrations.

Titles.—Titles should be short, specific, and clear. They should not exceed 42 characters per line, including punctuation and spaces, and be limited to two lines, if possible.

Style of Writing.—The style of writing should conform to acceptable English usage and syntax. Slang, medical jargon, obscure abbreviations, and abbreviated phrasing are to be avoided.

Informed Consent.—Manuscripts reporting the results of experimental investigations of human subjects must include a statement to the effect that informed consent was obtained after the nature of the procedure(s) had been fully explained.

Abstract.—Provide an abstract (135-word maximum) of the article, including statements of the problem, method of study, results, and conclusions. The abstract replaces the summary.

References.—List references in consecutive numerical order (not alphabetically). Once a reference is cited, all subsequent citations should be to the original number. All references must be cited in the text or tables. Unpublished data and personal communications should not be listed as references. References to journal articles should include (1) author, (2) title, (3) journal name (as abbreviated in *Index Medicus*), (4) volume number, (5) inclusive page numbers, and (6) year, in that order. References to books should include (1) author(s), (2) chapter title (if any), (3) editor (if any), (4) title of book, (5) city of publication, (6) publisher, and (7) year. Volume and edition numbers, specific pages, and name of translator should be included when appropriate. The author is responsible for the accuracy and completeness of the references and for their correct text citation.

Metrication.—All measurements must be in metric units. English units may also be given parenthetically if the measurements were originally done in English units.

Illustrations.—Use only those illustrations that clarify and augment the text. Submit illustrations in duplicate, unmounted and untrimmed. Do not send original artwork. Send high-contrast glossy prints (not photocopies). Figure number, name of senior author, and arrow indicating "top" should be typed on a gummed label and affixed to the back of each illustration. All lettering must be legible after reduction to column size. Artwork submitted for publication may be relettered to achieve uniformity of lettering style throughout the journal. Magnification and stain should be provided when pertinent. Illustrations should preferably be in a proportion of 12.5 × 18 cm (5 × 7 inches).

An experienced medical illustrator should be employed whenever possible for the preparation of all artwork. Template lettering or preset type is preferred to hand-lettered labels. If halftone artwork with labels is submitted, affix type and leaders to a clear acetate overlay registered to the base drawing. Labels and leaders should be applied directly to the drawing board surface if the artwork consists only of line ink technique.

Illustrations in full color are accepted for publication if the editors believe that color will add significantly to the published manuscript. The ARCHIVES will pay part of the expense of reproduction and printing color illustrations, the remainder to be borne by the author or his sponsor. After deducting the ARCHIVES contribution, the author's share is $275.00 for up to six square-finished illustrations that can be arranged on a one-page layout. Any additional illustrations or special effects will be billed to the author at cost. Positive color transparencies (35 mm preferred) must be submitted for an evaluation. Do not send color prints unless accompanied by original transparencies. All transparencies should be carefully packed and sent with the manuscript.

Legends.—Legends should be typed double-spaced, beginning on a separate sheet of paper. Length should be limited to a maximum of 40 words.

Photographic Consents.—A letter of consent must accompany all photographs of patients in which a possibility of identification exists. It is not sufficient to cover the eyes to mask identity.

Acknowledgments.—Illustrations from other publications must be acknowledged. Include the following when applicable: author(s), title of article, title of journal or book, volume number, page(s), month, and year. The publisher's permission to reprint should be submitted to the ARCHIVES after the manuscript has been formally accepted.

Statistical Review.—Manuscripts containing statistical evaluations should include the name and affiliation of the statistical reviewer.

Tables.—Each table should be typed double-spaced, including all headings, on a separate sheet of 22 × 28-cm (8½ × 11-inch) paper. Do not use larger size paper. If a table must be continued, use a second sheet and repeat all heads and stubs. Each table must have a title.

Inflammatory manifestations of psoriasis and atopic dermatitis...

Effectiveness demonstrated in only 8 days*

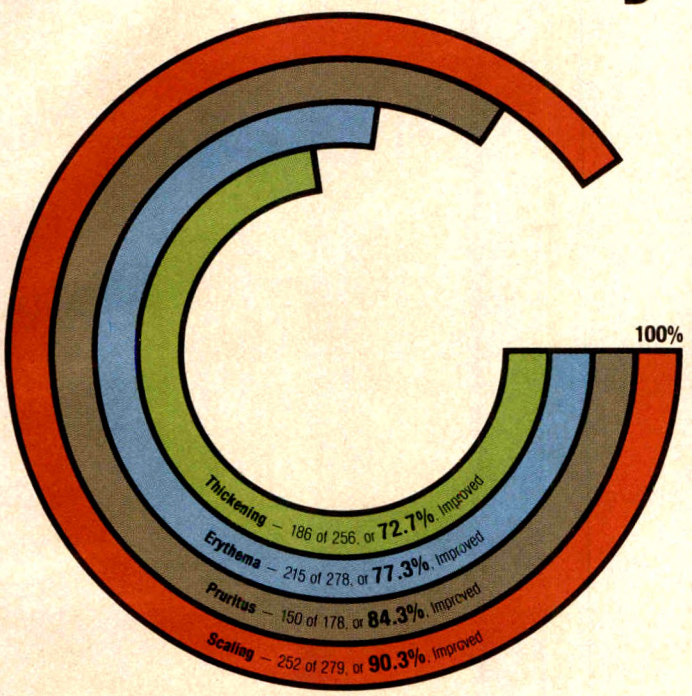

Psoriasis

In a study of 279 psoriatic patients

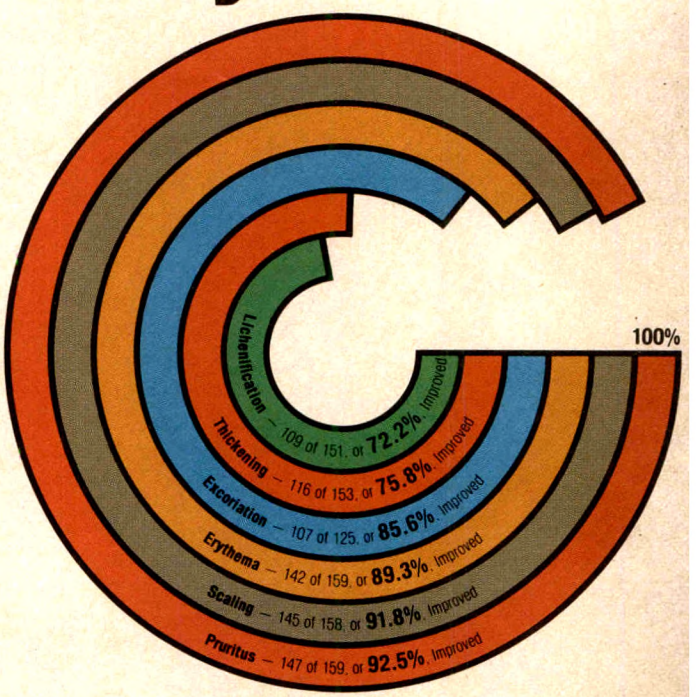

Atopic Dermatitis

In a study of 162 atopic dermatitis patients

Cordran® (Flurandrenolide)

Description: Cordran® (flurandrenolide, Dista) is a potent corticosteroid intended for topical use. **Actions:** Cordran is primarily effective because of its anti-inflammatory, antipruritic, and vasoconstrictive actions. **Indications:** For relief of the inflammatory manifestations of corticosteroid-responsive dermatoses. **Contraindications:** Topical corticosteroids are contraindicated in vaccinia and varicella and in patients with a history of hypersensitivity to any of their components. **Precautions:** If irritation develops, the product should be discontinued and appropriate therapy instituted. In the presence of an infection, an appropriate antifungal or antibacterial agent should be used. If a favorable response does not occur promptly, the corticosteroid should be discontinued until the infection has been adequately controlled. If extensive areas are treated or if the occlusive technique is used, there is a possibility of increased systemic absorption of the corticosteroid, and suitable precautions should be taken. Although topical corticosteroids have not been reported to have an adverse effect on pregnancy, the safety of their use on pregnant women has not been absolutely established. Therefore, they should not be used extensively, in large amounts, or for prolonged periods of time on pregnant patients. These products are not for ophthalmic use. **Adverse Reactions:** The following local adverse reactions have been reported with topical corticosteroid formulations: acneform eruptions, burning, dryness, folliculitis, hypertrichosis, hypopigmentation, irritation, itching. The following may occur more frequently with occlusive dressings: maceration of the skin, miliaria, secondary infection, skin atrophy, striae. **Administration and Dosage:** For moist lesions, a small quantity of the cream or lotion should be rubbed gently into the affected areas two or three times a day. For dry, scaly lesions, the ointment is applied as a thin film to affected areas two or three times daily. [111875]

Cream, Ointment, and Lotion Cordran®, 0.05%
flurandrenolide

Cream and Ointment Cordran, 0.025%

*Data on file at Dista Products Company.

DISTA
Dista Products Company
Division of Eli Lilly and Company
Indianapolis, Indiana 46206

700136
Additional information available to the profession on request.

Cream
Cordran®
Flurandrenolide

Efficacy is its strength

Ways to help allergy patients avoid "a bad day at the office"

Your allergy patients who are offic workers may spend a quarter of thei adult life in a hostile environment - from an allergen standpoint. Here ar suggestions that might, with the hel of an understanding employer, lesse the allergic burden.

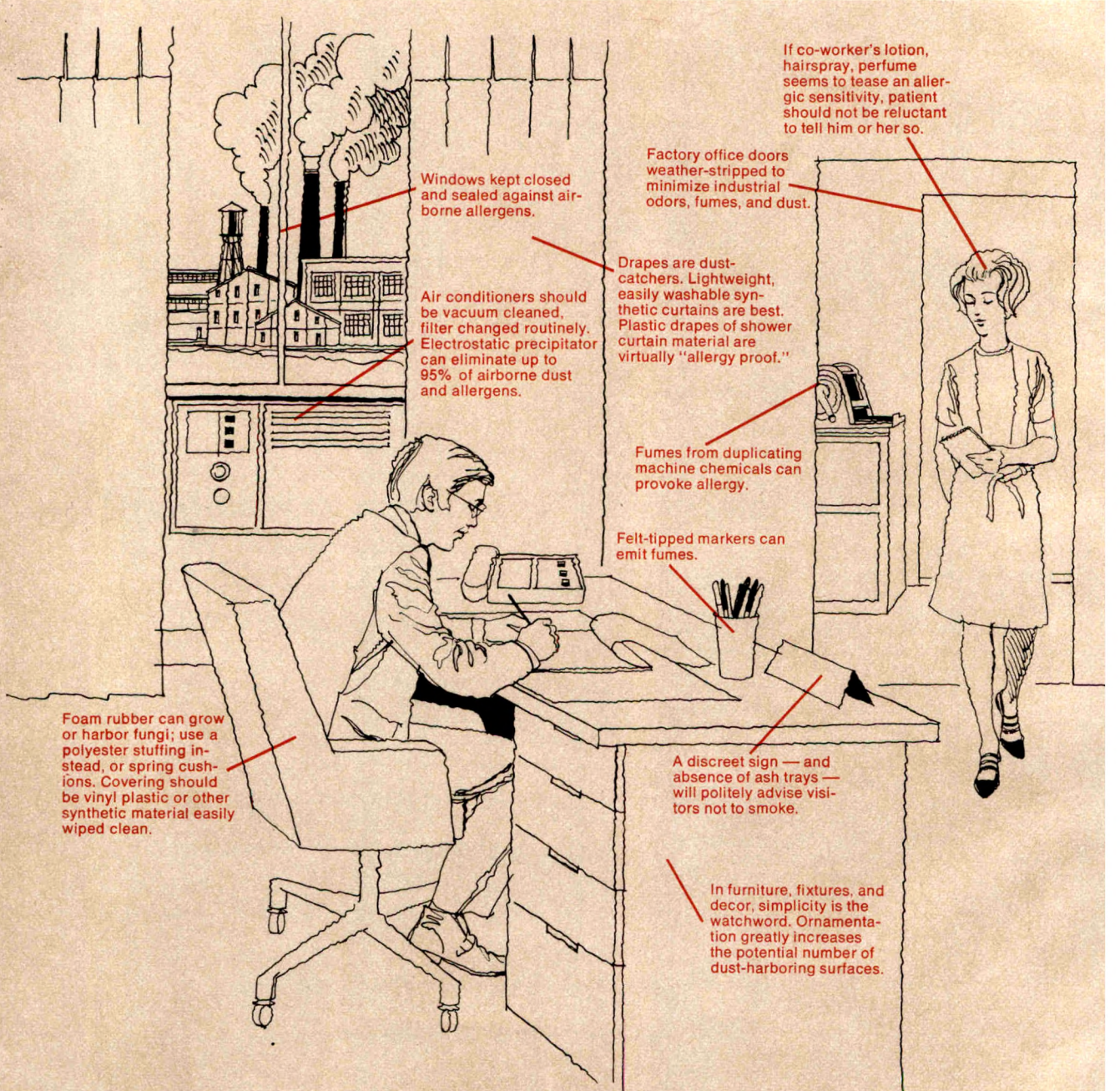

All measures to minimize exposure can be helpful. Still, allergic symptoms may occur and an antihistamine will be needed to bring these reactions under control. Dimetane Extentabs keep working for 10-12 hours, are economical, and are likely to produce good results in stubborn as well as routine cases, usually without drowsiness or overstimulation.

DIMETANE Extentabs®

(BROMPHENIRAMINE MALEATE,NF 8 mg. and 12 mg.)

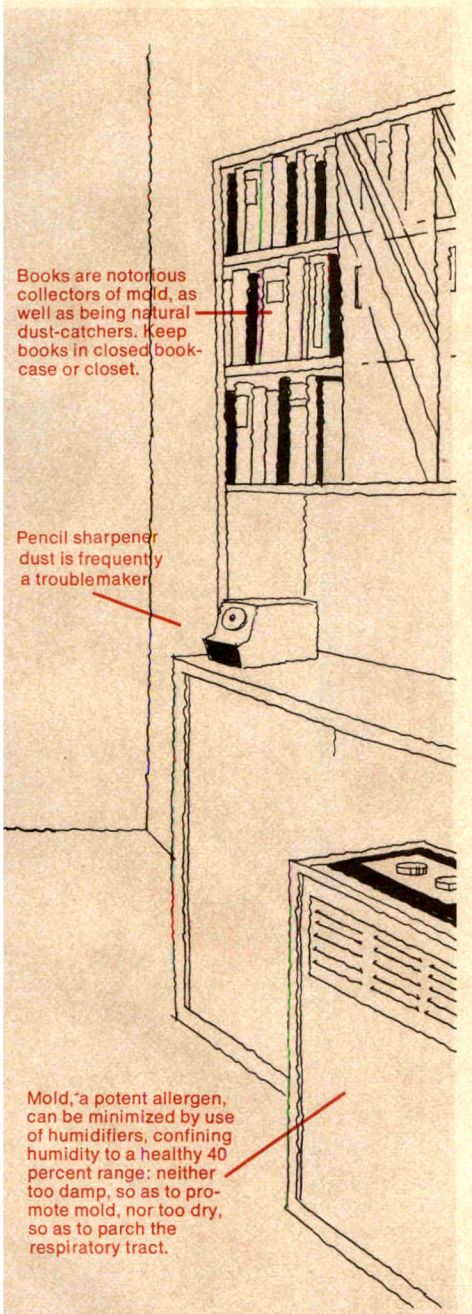

Indications: Perennial and seasonal allergic rhinitis; vasomotor rhinitis; allergic conjunctivitis due to inhalant allergens and foods; mild, uncomplicated allergic skin manifestations of urticaria and angioedema; amelioration of allergic reactions to blood or plasma; dermatographism; as therapy for anaphylactic reactions *adjunctive* to epinephrine and other standard measures after the acute manifestations have been controlled. **Contraindications:** *Use in Newborn or Premature Infants.* This drug should **not** be used in newborn or premature infants. *Use in Nursing Mothers.* Because of the higher risk of antihistamines for infants generally and for newborns and prematures in particular, antihistamine therapy is contraindicated in nursing mothers. *Use in Lower Respiratory Disease.* Antihistamines should NOT be used to treat lower respiratory tract symptoms including asthma. Antihistamines are also contraindicated in the following conditions: hypersensitivity to brompheniramine maleate and other antihistamines of similar chemical structure; monoamine oxidase inhibitor therapy (see Drug Interaction section). **Warnings:** Antihistamines should be used with considerable caution in patients with: narrow angle glaucoma; stenosing peptic ulcer; pyloroduodenal obstruction; symptomatic prostatic hypertrophy; bladder neck obstruction. *Use in Children.* In infants and children, especially, antihistamines in **overdosage** may cause hallucinations, convulsions, or death. As in adults, antihistamines may diminish mental alertness in children. In the young child, particularly, they may produce excitation. *Use in Pregnancy.* Experience with this drug in pregnant women is inadequate to determine whether there exists a potential for harm to the developing fetus. *Use with CNS Depressants.* Dimetane has additive effects with alcohol and other CNS depressants (hypnotics, sedatives, tranquilizers, etc.). *Use in Activities Requiring Mental Alertness.* Patients should be warned about engaging in activities requiring mental alertness, such as driving a car or operating appliances, machinery, etc. *Use in the Elderly (approximately 60 years or older).* Antihistamines are more likely to cause dizziness, sedation, and hypotension in elderly patients. **Precautions:** As with other antihistamines, Dimetane has an atropine-like action and, therefore, should be used with caution in patients with: history of bronchial asthma; increased intraocular pressure; hyperthyroidism; cardiovascular disease; hypertension. **Drug Interactions:** MAO inhibitors prolong and intensify the anticholinergic (drying) effects of antihistamines. **Adverse Reactions:** The most frequent adverse reactions are italicized: *General:* Urticaria, drug rash, anaphylactic shock, photosensitivity, excessive perspiration, chills, dryness of mouth, nose, and throat. *Cardiovascular System:* Hypotension, headache, palpitations, tachycardia, extrasystoles. *Hematologic System:* Hemolytic anemia, thrombocytopenia, agranulocytosis. *Nervous System: Sedation, sleepiness, dizziness, disturbed coordination,* fatigue, confusion, restlessness, excitation, nervousness, tremor, irritability, insomnia, euphoria, paresthesias, blurred vision, diplopia, vertigo, tinnitus, acute labyrinthitis, hysteria, neuritis, convulsions. *G.I. System: Epigastric distress,* anorexia, nausea, vomiting, diarrhea, constipation. *G.U. System:* Urinary frequency, difficult urination, urinary retention, early menses. *Respiratory System: Thickening of bronchial secretions,* tightness of chest and wheezing, nasal stuffiness. **Overdosage:** Antihistamine overdosage reactions may vary from central nervous system depression to stimulation. Stimulation is particularly likely in children. Atropine-like signs and symptoms – dry mouth; fixed, dilated pupils; flushing; and gastrointestinal symptoms may also occur. *If vomiting has not occurred spontaneously,* the patient should be induced to vomit. This is best done by having him drink a glass of water or milk after which he should be made to gag. Precautions against aspiration must be taken, especially in infants and children. *If vomiting is unsuccessful,* gastric lavage is indicated within 3 hours after ingestion and even later if large amounts of milk or cream were given beforehand. Isotonic and ½ isotonic saline is the lavage solution of choice. *Saline cathartics,* as milk of magnesia, by osmosis draw water into the bowel and therefore, are valuable for their action in rapid dilution of bowel content. *Stimulants* should **not** be used. Vasopressors may be used to treat hypotension. **Dosage and Administration:** DOSAGE SHOULD BE INDIVIDUALIZED ACCORDING TO THE NEEDS AND THE RESPONSE OF THE PATIENTS. *Adults:* One to two 4 mg tablets three or four times a day. One Extentab (8 or 12 mg) every eight to twelve hours or twice daily. Two to four teaspoonfuls of elixir three or four times a day. *Children over six.* One 4 mg tablet three or four times a day. One Extentab (8 or 12 mg) every twelve hours. One or two teaspoonfuls of elixir three or four times a day. *Children under six.* 0.5 mg of brompheniramine maleate per kg of body weight per 24 hours, or 15 mg per M^2 per 24 hours, divided into 3-4 doses.

A·H·ROBINS A. H. ROBINS COMPANY RICHMOND, VA 23220

PSORIASIS
The Capricious Dermatosis

LIDEX® (fluocinonide) 0.05%
A Stabilizing Influence

Psoriasis. Mere mention of the word ca
make an afflicted patient cringe. And,
because of the capricious, unpredictab
nature of the disease, the patient rarely
knows where or when it will recur.

Obviously, the goal is control. And,
though varied treatment modalities are
available today, none offers universal

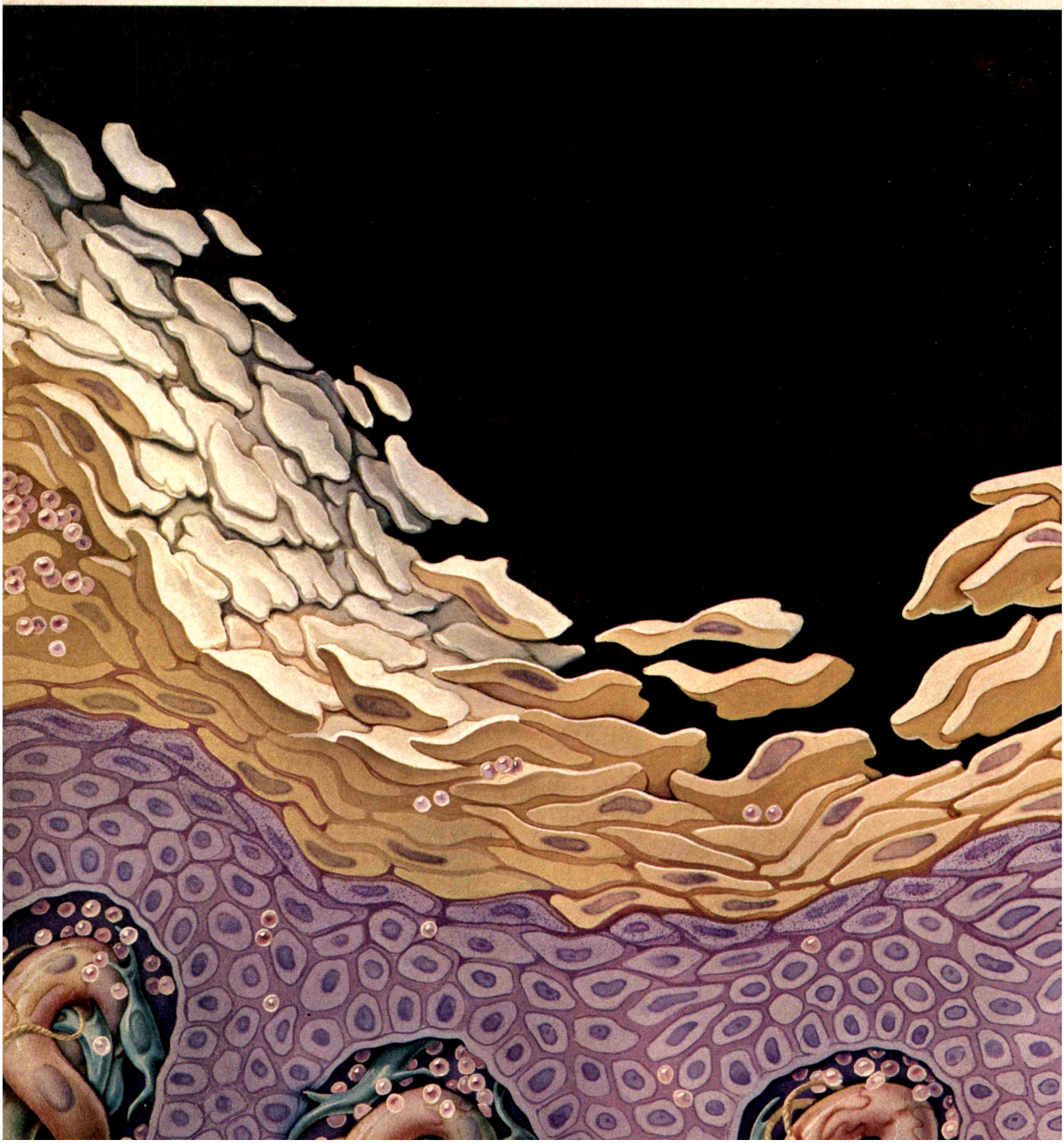

efficacy for all patients, all of the time.

Yet, very often a highly effective topical steroid, like Lidex, (fluocinonide) can help stabilize psoriasis.

Lidex. A highly effective topical steroid with anti-inflammatory, vasoconstrictive, antipruritic actions.

100% dissolved for optimal penetration, important in stages that exhibit thickened, scaly lesions.

Totally free of preservatives.

Available in cream, ointment, and Topsyn® (fluocinonide) gel.

SYNTEX

SYNTEX LABORATORIES, INC.
PALO ALTO, CALIFORNIA 94304

Artist's rendition of psoria

(See following page

LIDEX® (fluocinonide)
0.05% Cream and Ointment

TOPSYN® (fluocinonide)
0.05% Gel

Summary of prescribing information

Description
LIDEX cream 0.05%, LIDEX ointment 0.05% and TOPSYN gel 0.05% contain the active compound fluocinonide. Fluocinonide, which is the 21-acetate ester of fluocinolone acetonide, has the chemical formula 6α, 9α, -difluoro-11β, 16α, 17α, 21-tetrahydroxypregna-1,4-diene-3, 20-dione, cyclic 16, 17-acetal with acetone 21-acetate. LIDEX cream contains fluocinonide in FAPG® cream, a specially formulated cream base consisting of stearyl alcohol, polyethylene glycol 6000, propylene glycol, 1, 2, 6-hexanetriol and citric acid. This white cream vehicle is greaseless, non-staining, anhydrous and completely water miscible. The base provides emollient and hydrophilic properties. In this formulation, the active ingredient is totally in solution.

LIDEX ointment contains fluocinonide in a specially formulated ointment base consisting of Amerchol CAB (mixture of sterols and higher alcohols), white petrolatum, propylene carbonate and propylene glycol. It provides the occlusive and emollient effects desirable in an ointment. In this formulation the active ingredient is totally in solution.

TOPSYN gel contains fluocinonide in a specially formulated gel base consisting of propylene glycol, propyl gallate, disodium edetate, and Carbopol 940 (carboxypolymethylene) with NaOH and/or HCL added to adjust the pH. This clear, colorless, thixotropic vehicle is greaseless, non-staining and completely water miscible. In this formulation, the active ingredient is totally in solution.

Indications
LIDEX cream and ointment and TOPSYN gel are intended for the relief of inflammatory manifestations of corticosteroid responsive dermatoses.

Contraindications
Topical steroids are contraindicated in vaccinia and varicella. Topical steroids are contraindicated in those patients with a history of hypersensitivity to any of the components of the preparation.

Precautions
If irritation develops, the cream, ointment or gel should be discontinued and appropriate therapy instituted. In the presence of an infection the use of an appropriate antifungal or antibacterial agent should be instituted.

If a favorable response does not occur promptly, the corticosteroid cream, ointment or gel should be discontinued until the infection has been adequately controlled.

If extensive areas are treated, the possibility exists of increased systemic absorption and suitable precautions should be taken.

Although topical steroids have not been reported to have an adverse effect on pregnancy, the safety of their use in pregnant females has not absolutely been established. Therefore, they should not be used extensively on pregnant patients, in large amounts or for prolonged periods of time.

LIDEX® (fluocinonide) cream and ointment and TOPSYN® (fluocinonide) gel are not for opthalmic use.

Adverse reactions
The following local adverse reactions have been reported with topical corticosteroids:

burning	folliculitis
itching	acneform eruptions
irritation	hypopigmentation
dryness	striae
secondary infection	skin atrophy

Dosage and administration
A small amount should be gently massaged into the affected area three or four times daily, as needed.

How supplied
LIDEX 0.05% Cream—15 g 30 g and 60 g tubes.
LIDEX 0.05% Ointment—15 g 30 g and 60 g tubes.
TOPSYN Gel 0.05% 15 g and 60 g tubes.

SYNTEX
SYNTEX LABORATORIES, INC.
PALO ALTO, CALIFORNIA 94304

Laboratory Services
(On Hair and Other Organic Materials*)

1. Amino Acid Analysis
2. Mechanical Optical Properties
3. Scanning Electron Microscopy
4. Trace Metal Analysis

Lead	Zinc
Arsenic	Copper
Cadmium	Magnesium
Mercury	and many more

5. Transmission Electron Microscopy
6. plus many other capabilities and their...

... **Medical** importance are described in the new **Laboratory Handbook.**

Yours for the asking from

**including blood and urine*

P.S.
Call Toll Free
(800) 423-3062
In California
Call Collect
(213) 781-4934

REMEDCO
ANALYTICAL LABORATORY
HEW Lic. #04-1156
14721 Califa Street, Van Nuys, CA 91411

NEW



U.V. PHOTOTHERAPY RADIOMETER for PHOTOCHEMOTHERAPY of PSORIASIS

Features:
- Direct readout in milliwatts/cm².
- Spectral response to match the photosensitization of skin.
- Sensitivity from 0.3 to 100 milliwatts/cm², full scale.
- Wide field of view to match the cosine receiving function of human skin.
- Small, rugged and battery operated for full portability and safety.
- L.E.D. battery status indicator lamp.
- Silicon photodiode detector for maximum stability..

Write Dept. A

international light INC
Specialists in Light Measurement
DEXTER INDUSTRIAL GREEN
NEWBURYPORT, MA. 01950 617 465-5923

Schering

When it's all you want, it's all they get.

pure and simple

Chlor-Trimeton® 12mg.

brand of
chlorpheniramine maleate, USP

brand of
Repetabs® Tablets, repeat-action tablets

Available on prescription only.

Also available:
Chlor-Trimeton®
8 mg. Repetabs®
Injection 100 mg./ml.
and 10 mg./ml.

Copyright © 1977, Schering Corporation. All rights reserved.

SWW-9340

wash it. dry it. peel it.

Fostex,® the flexible therapeutic acne wash that degreases, dries, and peels. Easily integrated with all topical or systemic therapy for acne Grades I, II, and III. Convenient and economical Fostex Liquid and Cream are also effective anti-seborrheic shampoos for oily scalps associated with acne. Available as Fostex Cream in 4½ oz. jars, Fostex Cake in 3¾ oz. bars, and Fostex Liquid in 5 oz. plastic bottles.

Fostril,® the flesh-tinted drying and peeling lotion that conceals as it heals. Adaptable to Grades I, II, or III acne, Fostril is available in 1 oz. plastic tubes.

Transact,® the transparent medicated acne gel. A thin film of Transact will dry the oiliest of skin and is ideal for acne on chest, shoulders, and back. Greaseless, nonstaining, with a fresh clean fragrance. In 1 oz. plastic tubes.

WESTWOOD
PHARMACEUTICALS INC.
Buffalo, New York 14213
In Canada, Belleville, Ontario K8N 1E2

...safe for your patients to use, ...effective and less traumatic than cryosurgery or curettage[1]

Pet remedies for warts are almost as common as warts themselves. However, one specific formulation has again clinically proven its value.

R. B. Rees reported, *"My favorite wart remedy is . . . equal parts of salicylic acid and lactic acid in four parts of flexible collodion (Duofilm)".*[2]

Bunney and associates find the Duofilm formula, used at home, at least as effective as, and less traumatic than, cryotherapy and curettage.[1]

Arndt[3], in a double-blind controlled study of patients with multiple warts, confirmed Bunney's findings.

Duofilm is safe and simple to use. Special patient instruction pads and supplies of Duofilm for your treatment table are available on request.

Duofilm®

(Salicylic Acid, USP, 16.7% and Lactic Acid, USP, 16.7% in Flexible Collodion, USP)

for warts

Composition: Salicylic Acid, USP, 16.7% and Lactic Acid, USP, 16.7% in Flexible Collodion, USP.

Indications: DUOFILM is indicated as a keratolytic agent for the removal of benign epithelial tumors such as common warts.

Dosage and Administration: Prior to the application of DUOFILM, soak the affected area in hot water for at least five minutes. Dry thoroughly with a clean towel.

Apply DUOFILM directly to the wart using the plastic applicator. Each drop should be permitted to dry before re-application of the liquid. Care should be taken to see that DUOFILM is not applied to the surrounding skin. A Band-Aid® or similar bandage should then be applied lightly.

Treatment should take place once daily and continue as directed by physician.

Contraindications: Diabetics or patients with impaired blood circulation should not use DUOFILM. Do not use on moles, birthmarks or unusual warts with hair growing from them.

Precautions: For external use only.

DUOFILM is highly flammable and should be kept away from fire or flame. Keep bottle tightly capped when not in use. Store at controlled room temperature.

If spilled on mucous membranes or in eyes, flush with water, remove precipitated collodion, and flush with water for an additional 15 minutes.

Keep this and all medication out of the reach of children.

How Supplied: DUOFILM is available in ½ oz. bottles with plastic applicators.

Caution: Federal law prohibits dispensing without a prescription.

1. Bunney, M.H.; Nolan, M.W.; Williams, D.A.: An assessment of methods of treating viral warts by comparative treatment trials based on a standard design. *Brit. J. Derm.* **94,** 667, 1976.

2. Rees, R.B.: Post-graduate course in Dermatology, sponsored by Cleveland Clinic and U. of Cal., San Fran., Nov. 5-10, 1976, Maui, Hawaii.

3. Arndt, K.A.: Double-blind study of salicylic and lactic acid lotion in treating warts. Study on file at Stiefel Research Institute.

STIEFEL
Logical Dermatologicals since 1847

Stiefel Laboratories, Inc.,
Oak Hill, N.Y. 12460
Stiefel Laboratories (Canada) Ltd.,
St. Laurent, Quebec, Canada H4R 1E1

9-1085

new LactiCare® Lotion

A genuine breakthrough in the management of dry skin.

More physiologic: LactiCare's unique formula restores humectants which occur naturally in normal healthy skin.

Prolonged protection that won't easily wash away: Unlike most humectants which easily may be rinsed away, lactic acid is adsorbed onto the cells of the stratum corneum and remains there to improve their water-retention ability, even after extended immersion in water.

Better moisture-binding ability: Both of the major humectants in LactiCare have been shown superior to the most commonly-used hygroscopic agents in their ability to absorb moisture and supply it to the stratum corneum.[1]

Greater economy: LactiCare is a highly concentrated lotion with a pleasant, thick creamy consistency. It should be used sparingly and less often than ordinary lotions. Even all-over body use costs only pennies a day.

Formula Lactic Acid USP 5.0%
Na-PCA 2.5%
in an oil-in-water lotion base containing: purified water, mineral oil, isopropyl palmitate, coceth-6, sodium hydroxide, glyceryl stearate, myristyl lactate, cetyl alcohol, carbomer-940, imidazolidinyl urea, fragrance, dehydroacetic acid.

Please see LactiCare file card for full prescribing information.

STIEFEL
Logical Dermatologicals since 1847

Stiefel Laboratories, Inc.,
Oak Hill, N.Y. 12460
Stiefel Laboratories (Canada) Ltd.,
St. Laurent, Quebec, Canada H4R 1E1

Obviously, efficacy is foremost in your mind when you recommend a therapeutic shampoo. And efficacy, coupled with cosmetic acceptability, usually guarantees a successful therapeutic course.

That's why Head & Shoulders is so highly regarded in the treatment of dandruff.

Clinically effective

For years, Head & Shoulders has proved effective in the treatment of dandruff—whether for initial therapy or long-term control. And now, research shows that Head & Shoulders is effective in the treatment of seborrheic dermatitis.*

Cosmetically pleasing

Head & Shoulders lathers well, has a pleasant odor and appearance, and need not be left on the scalp for an extended period of time. Also, it leaves hair clean, manageable, and attractive.

Head & Shoulders®

You'll like it for its therapeutic benefits. Your patients will like it for its cosmetic appeal.

*Orentreich, N.: A clinical evaluation of two shampoos in the treatment of seborrheic dermatitis, J. Soc. Cosmet. Chem. 23:189 (March 3) 1972.

IN SKIN INFECTIONS, WHERE CLEANLINESS REQUIRES MORE THAN SOAP

BETADINE® Skin Cleanser

Degerms as it cleanses

Patients can use BETADINE Skin Cleanser to degerm and cleanse face, hands and body, gently and thoroughly—particularly when it is essential to prevent autoinoculation of new sites, as may be the case in infected acne pimple

BETADINE Skin Cleanser, with its rich, golden lather, provides these advantages:

- Prompt, broad-spectrum microbicidal action—kills both gram-positive and gram-negative bacteria (including antibiotic-resistant strains), fungi, viruses, protozoa and yeasts.
- Maintains microbicidal activity in the presence of blood, pus and serum.
- Virtually nonirritating to skin and mucosa.*
- Nonstaining to skin and natural fabrics.

Supplied: 4 fl. oz. plastic bottles.

*In the rare instance of local irritation or sensitivity, discontinue use by the individual.

Purdue Frederick © COPYRIGHT 1976, THE PURDUE FREDERICK COMPANY

NORWALK, CONN. 06856 A8196 172076

P 24,906

Get down to the level of normal skin.

Remove hyperkeratotic build up safely and effectively.



Keralyt® Gel is clear, and easy to apply. Keralyt Gel's mechanism of action is believed to be its ability to dissolve the intracellular material that binds the cells of the stratum corneum, thus aiding the simple, safe removal of excessive hyperkeratotic skin.

Keralyt's keratolytic action is an important preliminary to other topical agents. After the hyperkeratotic barrier is removed, tar, steroids, and other therapy can function with less impediment.

Keralyt® GEL

6% salicylic acid in a gel containing propylene glycol (60%), ethyl alcohol (19.4%), hydroxypropyl cellulose and water.
Please see full prescribing information.

©1977, W.P. Inc.

Available only on your prescription.

Keralyt® GEL

NDC-0072-6500-01

Rx CAUTION: FEDERAL LAW PROHIBITS DISPENSING WITHOUT PRESCRIPTION.

CONTENTS: 6% salicylic acid in a gel containing propylene glycol (60%), ethyl alcohol (19.4%), hydroxypropyl cellulose and water.

ACTION AND USES:
For Dermatological Use: Keralyt is a topical aid in the removal of excessive keratin in hyperkeratotic skin disorders, including the various ichthyoses (vulgaris, sex-linked and lamellar), keratosis palmaris and plantaris, keratosis pilaris, pityriasis rubra pilaris, psoriasis (including body, scalp, and palms and soles). Keralyt has been reported as helpful as adjunctive therapy for fungal infections.

For Podiatric Use: Keralyt is a topical aid in the removal of excessive keratin in dorsal and plantar hyperkeratotic lesions. Keralyt has been reported as helpful as adjunctive therapy for verruca plantaris.

DIRECTIONS FOR USE: The preferable method of use is to apply thoroughly to the affected area and place under occlusion at night. The skin should be hydrated for at least five minutes prior to application. The medication is washed off in the morning, and if excessive drying and/or irritation is observed, a bland cream or lotion may be applied. Once clearing is apparent, the occasional use of Keralyt will usually maintain the remission. In those areas where occlusion is difficult or impossible, application may be made more frequently, and hydration by wet packs or baths prior to application apparently enhances the effect. Unless hands are being treated, rinse hands thoroughly following application.

CONTRAINDICATIONS: Not to be used in patients known to be sensitive to any ingredient of Keralyt.

PRECAUTIONS: In view of the salicylic acid content, use in children under 12 years of age should be limited to no more than one tube (1 oz.) in 24 hours. Avoid contact with eyes and mucous membranes. For external use only. Keep this and all medications out of reach of children.

HOW SUPPLIED: Plastic tubes 1 oz. (24.8 gm.)

WESTWOOD PHARMACEUTICALS INC.
Buffalo, New York 14213

Look closely at these patients. Their dermatologist had them on a KOMEX®/KOMED® regimen.

Step 1 KOMEX®

"...toward keeping the skin meticulously clean...to decrease the usually concomitant oiliness."[1]

Cleanses thoroughly yet gently.

The detergent cleansing effect of Komex acne cleanser is uniquely enhanced with mild dissolving sodium borate particles (Scrubules) for effective yet gentle cleansing of the skin. Komex removes surface debris. Clears comedones. Cleans clogged pores. Unplugs hair follicles. And removes oils.

Mild abradancy won't damage skin.

"A frequently overlooked source of excessive friction is the practice of vigorous scrubbing in an attempt to wash acne away. The use of brushes and other scrubbing techniques can induce significant inflammatory lesions...Elimination of sources of excessive friction lead to rapid improvement[2]

The patented Komex Scrubules enable doctor and patient to control particle dissolution from 0-60 seconds, depending on water dilution. Acne patients can't overabrade with Komex. A significant exclusive.

Conditions the skin.

In fact, the skin *conditioning* effect of Komex acne soap is truly phenomenal. You can detect some of it in the patient photos. But it really must be seen—and felt.

Step 2 KOMED®

"...to peeling of the skin so that the follicular orifices are kept open."[1]

Employs a non-comedogenic form of sulfur.

Komed Lotion works beautifully with Komex.
"The sovereign remedy in the topical management of acne vulgaris is sulfur."[3]
"Sulfur...still the most effective remedy...In addition ...salicylic acid and other peeling chemicals are used in cosmetically elegant lotions..."[4]
The exclusive Komed formulation keeps skin dry and desquamating with salicylic acid and *non-comedogenic* sodium thiosulfate.

"Suspensions and creams containing elemental sulphur were shown to be capable of inducing comedones in the rabbit ear and on human backs."[5]

Has "excellent patient appeal."

"All of the patients liked the fact that (Komed) dries quickly to an invisible film...the female patients found that the lotion did not interfere with the use of non-oily cosmetics. Male patients also appreciated the lack of a masking effect, the absence of staining properties, and the fact that the lotions blend with natural skin tone."[6]

Barnes-Hind Pharmaceuticals, Inc.
895 Kifer Road, Sunnyvale, California 94086

KOMEX®/KOMED® Classical topical therapy. Still the effective treatment for mild acne.

1. Domonkos AN: Andrews' diseases of the skin. 6:257, Saunders: Philadelphia, 1971
2. Leyden JJ: Antibiotic resistant acne. Cutis 17:593, 1976
3. Frank L: Active oxygen in acne therapy. Cutis 1:306, 1965
4. Domonkos AN: Andrews' diseases of the skin. 6:257-258, Saunders: Philadelphia, 1971
5. Mills OH Jr, Kligman AM: Is sulphur helpful or harmful in acne vulgaris? Br J Derm 86:620, 1972
6. Sewell JW Jr: Therapeutic and cosmetic advantages of a nonpigmented acne lotion. Cutis 1:475-476, 1965

Aristocort
Triamcinolone
Acetonide
Ointment
0.1%
R
Aristocort
Triamcinolone
Acetonide
Cream 0.025%
LP
Aristocort
Triamcinolone
Acetonide
Cream 0.1%
R
Aristocort
Triamcinolone
Acetonide
Cream 0.5%
HP
Aristocort
Triamcinolone
Acetonide
Ointment 0.1%
R
Aristocort
Triamcinolone
Acetonide
Ointment 0.5%
HP
Aristocort
Triamcinolone
Acetonide
Cream 0.1%
R
Aristocort
Triamcinolone
Acetonide
Cream 0.5%
HP
Aristocort
Triamcinolone
Acetonide
Cream 0.1%
R
1/2 lb.
Aristocort
Triamcinolone
Acetonide
Cream 0.5%
HP
1/2 lb.
Aristogel



Our Town

where there's always the right topical form and strength for every clinical need ...the home of

Aristocort®

Triamcinolone Acetonide

There are alternatives...but no substitutes!

A standard for effectiveness in fluorinated topicals.

The first triamcinolone preparation to remove common sensitizers—contains no parabens, phenol preservatives, lanolin.

One of the most economical topical steroids available—in forms, strengths and sizes for every problem.

In cosmetically-pleasing forms that have become traditional patient favorites.

Indications: For relief of inflammatory manifestations of corticosteroid responsive dermatoses.

Contraindications: Viral skin diseases, such as varicella and vaccinia hypersensitivity to any component (not for ophthalmic use); when circulation is markedly impaired.

Warnings: Safety of use in pregnancy has not been absolutely established. Do not use extensively, in large amounts, or for prolonged periods of time in pregnant patients.

Precautions: If irritation develops, discontinue use and institute appropriate therapy. In infections, use appropriate antifungal or antibacterial agents; if a favorable response does not occur promptly, discontinue the corticosteroid until the infection is adequately controlled. If extensive areas are treated or the occlusive technique is used, increased systemic absorption of the corticosteroid may occur; take suitable precautions.

Adverse Reactions: (local) Burning sensations, itching, irritation, dryness, folliculitis, secondary infection, skin atrophy, striae, hypertrichosis, acneform eruption and hypopigmentation.

Supplied: *Cream 0.5%*—Per Gm.: triamcinolone acetonide 5 mg., sorbic acid 0.1% and potassium sorbate 0.1% as preservatives; *Cream 0.1%*—Per Gm.: triamcinolone acetonide 1 mg., sorbic acid 0.1% and potassium sorbate 0.1% as preservatives; *Cream 0.025%*—Per Gm.: triamcinolone acetonide 0.25 mg., sorbic acid 0.1% and potassium sorbate 0.1% as preservatives; all potencies are in a water base of mono and diglycerides, squalane, polysorbate 80 USP, polysorbate 60, spermaceti USP, stearyl alcohol USP, Tenox II, and sorbitol solution USP. *Ointment 0.5%*—Per Gm.: triamcinolone acetonide 5 mg.; inactive ingredient: white petrolatum; *Ointment 0.1%*—Per Gm.: triamcinolone acetonide 1 mg.; inactive ingredient: white petrolatum. *ARISTOGEL® Gel 0.1%*—Per Gm.: triamcinolone acetonide 1 mg., 1.8% benzyl alcohol as preservative; inactive ingredients in a water base: polysorbate 80 USP, polyoxyethylene (20) cetyl ether, glycerin USP, and citric acid USP. 775-4

Lederle

Lederle Laboratories
A Division of American Cyanamid Company, Pearl River, New York 10965

PreSun®

5% PABA GEL/LOTION

Provides superior sunscreen protection.

WESTWOOD
PHARMACEUTICALS INC.
Buffalo, New York 14213

©1976 W.P. Inc.

Reviewers for 1976

The editors of the ARCHIVES would like to take this opportunity to thank, on behalf of themselves and the readership, the large number of dedicated individuals who have reviewed articles for the journal in 1976. As you may or may not know, every submitted paper is examined by at least two referees, as well as by the editors. Though this procedure may delay publication, it is essential for the maintenance of accuracy and quality of material published.

The following is a compilation of the names of these reviewers who have so generously given their time and expertise on behalf of the ARCHIVES. If any name is misspelled or not included, we apologize in advance. Please let us know and we will include the information as a correction in a future issue.

JOHN H. EPSTEIN, MD
KIMIE FUKUYAMA, MD
DENNY L. TUFFANELLI, MD

Donald C. Abele
A. Bernard Ackerman
John L. Aeling
Ralph W. Alexander
Alfred M. Allen
Richard J. Allison, Jr
Jules Altman
Razà Aly
Robert B. Amon
Dennis B. Amos
Philip C. Anderson
Prapand Apisarnthanarax
Kenneth A. Arndt
Harry L. Arnold
Faye D. Arundell
Howard P. Baden
William B. Baker
Phillip W. Banda
Vincent P. Barranco
Bruce J. Bart
Robert S. Bart
Samuel F. Bean
James H. Bennett
Eugene S. Bereston
Wilma Fowler Bergfeld
Ernst H. Beutner
David R. Bickers
Robert T. Binford
Alan N. Binnick
Donald J. Birmingham
Martin Black
Harvey Blank
Irvin H. Blank
M. Scott Blois
Irwin M. Braverman
Robert A. Briggaman
Martin Brotman
Algie Curry Brown
Martin H. Brownstein
Marian M. Brubaker
Louis A. Brunsting, Sr
Kenneth H. Burdick
Kelmar M. Burge, Jr
Thomas K. Burnham
Thomas Butterworth
Jean-Claude Bystryn
Thomas E. Carson
D. Martin Carter
Ronald R. Chappler
William H. Chew
Herbert B. Christianson
Edward C. Clark
James E. Cleaver
William E. Clendenning
Harvey J. Cohen
Marcus A. Conant
Victor S. Constantine
Rudi H. Cormane
Alvin J. Cox, Jr
William R. Crain
David L. Cram
J. N. Crawford
Derek J. Cripps
Mark V. Dahl
Steve A. Davis
D. Joseph Demis
Thomas E. Drake
David J. Drutz
Howard V. Dubin
Edmund L. Dubois
William H. Eaglstein
Arthur Z. Eisen
Peter M. Elias
Edward A. Emmett
Ana M. Eng
Marvin L. Engel
Ernst Epstein
Ervin H. Epstein, Jr
Ervin H. Epstein, Sr
William L. Epstein
Nancy B. Esterly
Mark Allen Everett
Eugene M. Farber
Albert Farbman
Paul Fasal
Raymond Fay
David S. Feingold
Michael J. Fellner
Bertram F. Felsher
Robert M. Fine
Alexander A. Fisher
Raul Fleischmajer
P. Donald Forbes
Irwin M. Freedberg
Robert G. Freeman
David F. Fretzin
Phillip Frost
James E. Fulton, Jr
Nancy L. Furey
Kenneth H. Fye
Gerald A. Gellin
William C. Gentry, Jr
James N. Gilliam
Richard G. Glogau
Detlef K. Goette
Herbert Goldschmidt
Lowell Alan Goldsmith
Loren E. Golitz
Robert W. Goltz
James W. Good
Richard S. Goodman
Bernard I. Gordon
Bernard Gottlieb
William M. Gould
Richard Graham
Joseph H. Greenberg
David A. Grekin
Michael A. Gromet
Lloyd W. Gross
Inta A. Grots
Ralph W. Grover
Victor C. Hackney
Terry P. Hadley
Carlyn J. Halde
Kenneth M. Halprin
George W. Hambrick, Jr
Edwin M. Hamlin, Jr
Jon M. Hanifin
Virgil Hanson
Mustafa T. Haqqani
Leonard C. Harber
E. Richard Harrell
David R. Harris
Ken Hashimoto
Richard J. Havel
Harley A. Haynes
Elson B. Helwig
William J. Hennessy
Les G. Hilger
Paul Hirsch

Axel W. Hoke
W. Mage Honeycutt
Winthrope R. Hubler
Peter B. Hukill
Harry J. Hurley
Allan K. Izumi
Alvin H. Jacobs
Kent F. Jacobs
Paul H. Jacobs
Gail T. Jacoby
G. Thomas Jansen
Michael T. Jarratt
Otis F. Jillson
Marie-Louise Johnson
Waine C. Johnson
Henry W. Jolly, Jr
Frank J. Jonelis
Henry E. Jones
William P. Jordan
Robert E. Jordon
Guinter Kahn
Marvin A. Karasek
Stephen I. Katz
Donald M. Kay
Robert E. Kellum
John A. Kenney, Jr
Robert R. Kierland
Frederick A. J. Kingery
Sidney N. Klaus
Albert M. Kligman
John M. Knox
Alfred W. Kopf
Lawrence S. Krain
Gerald G. Krueger
David Lagunoff
Madeleine Landry
Montague Lane
Walter G. Larsen
Paul Lazar
Gerald S. Lazarus
Ullin W. Leavell, Jr
John A. H. Lee
Norman E. Levan
Jay A. Levy
S. William Levy
Barton L. Lewis
Charles W. Lewis
Henry M. Lewis
James J. Leyden
Clarence S. Livingood
Reed Lockwood
Allan L. Lorinez
Edmund D. Lowney
Herbert Z. Lund
Marvin A. Lutzner
Peter J. Lynch
Lisa Mahoney
Howard I. Maibach
John C. Maize
Frederick D. Malkinson
William Margaretten
Richard R. Marples
Francis N. Marzulli
Charles J. McDonald
James McGinley
John D. McGrae, Jr
Joseph S. McGuire, Jr
Amir H. Mehregan
Kenneth L. Melmon
Herbert Mescon
Ronald P. Messner
Beno Michel
Eugene W. Monroe
Samuel L. Moschella
Sigfrid A. Muller
Douglas N. Naversen
Kenneth H. Neldner
Lee T. Nesbitt, Jr
Victor D. Newcomer
Walter R. Nickel
Arthur L. Norins
Richard B. Odom
Milton R. Okun
Milton Orkin
Richard K. Park
Frank Parker
John A. Parrish
Frances Pascher
David Paslin
Franklin Pass
Madhu A. Pathak
Roger W. Pearson
Samuel M. Peck
Neal S. Penneys
Harold O. Perry
Lawrence D. Petz
Hermann Pinkus
Sheldon R. Pinnel
J. Lewis Pipkin
Peter E. Pochi
Maureen B. Poh-Fitzpatrick
Vera H. Price
Thomas T. Provost
Michel Prunieras
Stephen D. Prystowsky
Walter C. Quevedo
Steven F. Rabens
David L. Ramsay
James E. Rasmussen
Robert C. Rau
Thomas H. Rea
William B. Reed
Rees B. Rees
John R. T. Reeves
Victor Richards
Daniel F. Richfield
Sidney Riegelman
John W. Rippon
Perry Robins
Gerald P. Rodnan
Henry H. Roenigk, Jr
Nick Rogentine
Roy S. Rogers III
E. William Rosenberg
Stanley Rosenthal
Jane M. Rosenzweig
Harry L. Roth
Earl J. Rudner
Andrew H. Rudolph
Wayne Rundles
Arkadi M. Rywlin
Henry F. Safrit
Richard W. Sagebiel
Martin H. Samitz
W. Mitchell Sams, Jr
Philip E. Sartwell
Perry L. Scholnick
William F. Schorr
Donald S. Schuster
Robert B. Scoggins
Larry E. Seitz
Gordon Sharp
John M. Shaw
Lawrence E. Shulman
Jerome L. Shupack
Robert C. Siegel
Sol Silverman, Jr
Jay Smith
Wayne E. Smith
Lawrence M. Solomon
Nicholas A. Soter
William H. Spencer
Lynn E. Spitler
James J. Stagnone
Willard D. Steck
Otto C. Stegmaier
Samuel J. Stegman
Bernard Stone
Stephen P. Stone
Frances J. Storrs
Richard B. Stoughton
John S. Strauss
Raymond R. Suskind
George Szabo
Frederick J. Szymanski
Lewis Tanenbaum
David Taplin
James S. Taylor
William B. Taylor
William Thayer
E. George Thorne
John P. Tindall
Victor M. Torres
Frances A. Torrey
F. Charles Tring
Theodore A. Tromovitch
Stephen B. Tucker
Kathleen B. Unger
Hideo Uno
Frederick Urbach
John P. Utz
Rodney J. Valentine
Theodore VanRavenswaay
Eugene J. Van Scott
John J. Voorhees
Margaret Waisman
Morris Waisman
Peyton E. Weary
William Weems
David L. Weinberg
Gerald D. Weinstein
William L. Weston
Clayton E. Wheeler, Jr
Laurens P. White
Isaac Willis
Richard K. Winkelmann
John E. Wolf, Jr
Klaus Wolff
Margaret Gray Wood
Theodore E. Woodward
Robert C. Wright
Kirk D. Wuepper
James B. Wyngarden
Herschel S. Zackheim
Nardo Zaias
Alvin S. Zelickson
Murray C. Zimmerman

Chemosurgery for Melanoma

Frederic E. Mohs, MD

• **Microscopically controlled excision of melanoma by the chemosurgical method ensures complete eradication of any unsuspected outgrowths from the clinically observed tumor mass. The method differs from the chemosurgical techniques used for excision of cutaneous carcinomas in the following two respects: the tissues always are chemically fixed in situ before any incisions are made in order to minimize the chance of dissemination, and an extra margin of tissues is removed after reaching a microscopically melanoma-free plane in order to encompass possible outlying melanomatous satellites in the peritumoral lymphatics. In a series of 103 consecutive cases of melanomas of the nodular, superficial spreading, and lentigo maligna types, there were 86 determinate cases with a five-year cure rate of 50%. This is a high rate for a series in which 69% were nodular melanomas and 64% invaded to subcutaneous tissues (Clark's level 5).**

(*Arch Dermatol* 113:285-291, 1977)

In common with basal and squamous cell carcinoma of the skin, cutaneous melanoma often sends out unpredictable ramifications for some distance beyond the clinically apparent borders of the neoplasm. The eradication of these silent outgrowths is ensured by the microscopical control afforded by the chemosurgical method. However, because of the strong tendency for melanoma to invade vascular walls and hence to metastasize frequently, the chemosurgical technique differs from that used for carcinomas in two ways.[1,2]

First, in the treatment of melanoma, the tissues are always subjected to chemical fixation in situ before any incisions are made. Never is the main mass initially excised surgically prior to the layer-by-layer chemosurgical excision of the melanoma, nor is the "fresh tissue" chemosurgical technique used whereby the layers are excised without prior fixation in situ. The purpose of the in situ fixation is to minimize the chance of dislodging melanoma tissue that often dangles precariously in the lumens of the vessels. Using a sharp scalpel, the layers of fixed tissue are gently excised with care to avoid cutting into the underlying unfixed tissues.

The second way in which the chemosurgical excision of melanoma differs from that of carcinomas is that after a microscopically melanoma-free plane has been reached, an extra margin of tissues is removed. The reason for chemosurgically excising the extra margin is that melanoma, in contrast to carcinoma, fairly frequently deposits malignant cells in the peritumoral lymphatics to form satellites that may be too small to be seen at the time of the excision. Determination of the width of the extra margin is made by microscopically examining the melanoma; if it is highly anaplastic, invades vessel walls, causes extravasation, and invades deeply into the reticular dermis or beyond, the extra margin may be 3 cm or more, whereas if the microscopical features indicate a less highly malignant neoplasm, the extra margin may be 1 cm, or even less if some important facial structure is being encountered.

TECHNIQUE

To illustrate the steps of the chemosurgical technique, a case of melanoma arising in an area of melanosis on the temple is described (Fig 1).

First, dichloroacetic acid is applied to the surface until the skin whitens, indicating penetration of the keratin layer that is a barrier to zinc chloride. The zinc chloride fixative paste then is applied (Fig 1, top right). This is covered with a thin layer of

Accepted for publication June 2, 1976.

From the Department of Surgery, University of Wisconsin Medical Center, Madison, Wis.

Read before the American Academy of Dermatology, San Francisco, Dec 11, 1975.

Reprint requests to Chemosurgery Clinic, University Hospitals, Madison, WI 53706 (Dr Mohs).

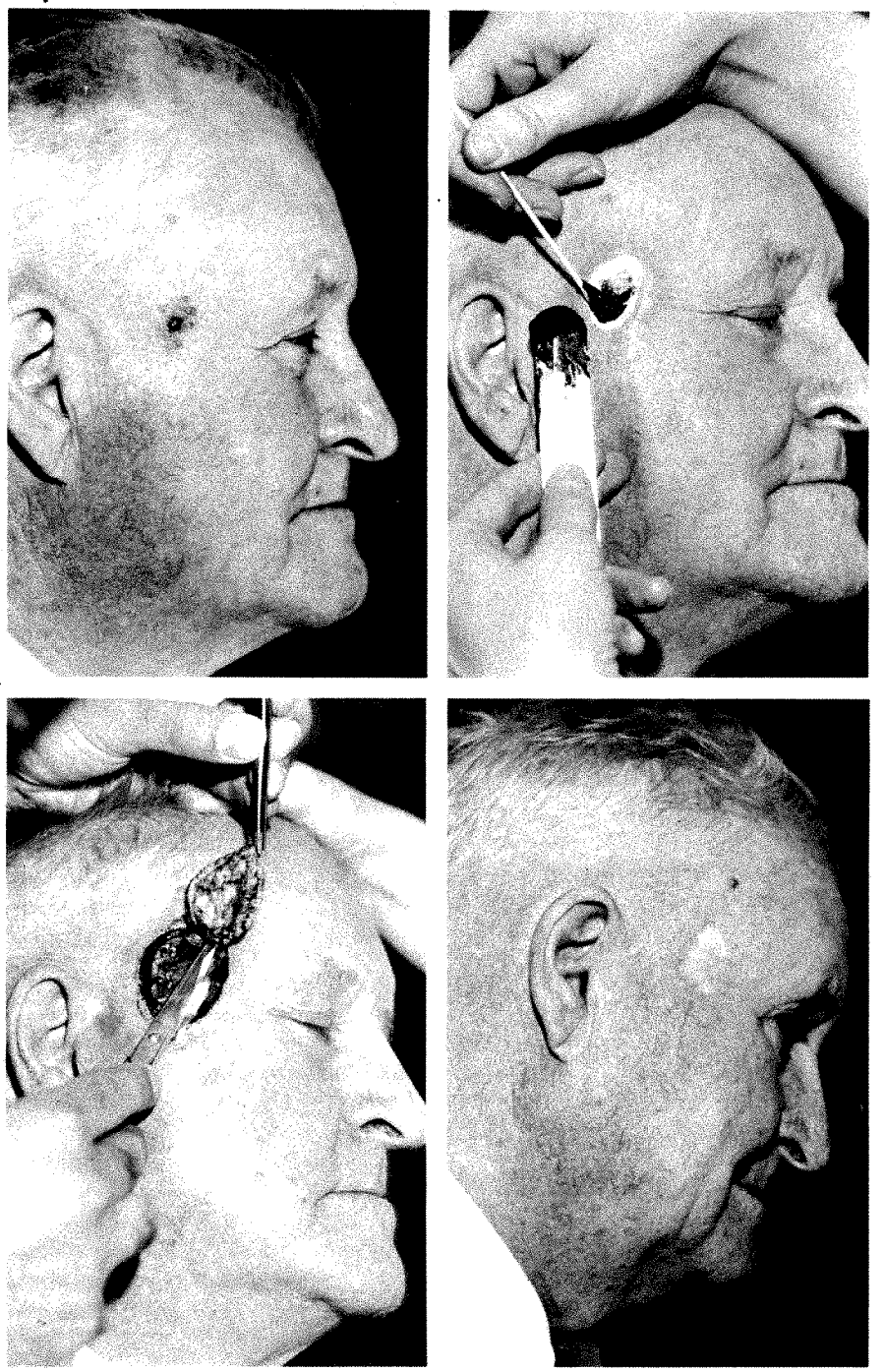

Fig 1.—Top left, Nodular melanoma of six months' duration in area of melanosis of three years' duration invasive to level 3. Top right, Application of zinc chloride paste for fixation in situ. Whitening of skin was from dichloroacetic acid that had been applied to render keratin layer permeable to zinc chloride. Bottom left, Removal of final layer of fixed tissue after eight days. Bottom right, Healed lesion after one year.

cotton that, in turn, is covered with an overlapping, petrolatum-spread, cotton dressing to provide occlusion.

After 24 hours, a layer of tissue that has been fixed in situ is excised. The incisions are made through fixed tissue with care to avoid cutting into the underlying unfixed tissue. If the melanoma is pigmented it is readily seen grossly at this stage because the black neoplastic tissue contrasts sharply with the white color of the fixed normal tissues. The fixative is reapplied and another layer is excised on the next day. If there is no grossly visible melanoma, the entire area is examined microscopically. This is accomplished by dividing the excised layer into specimens of convenient size, and having frozen sections cut through the undersurface of each of the flat pieces of tissue. The site of origin of each specimen is marked on the lesion with merbromin. Even if no melanoma is found by thorough scanning of the sections, another application of the fixative is made to provide an extra margin for the purpose of eliminating any possible melanomatous satellites in the surrounding skin lymphatics. In this case, the melanoma did not appear highly malignant because it had barely impinged on the reticular dermis (level 3 of Clark[3]), was only moderately anaplastic, and showed no evidence of invasion of vessel walls. Therefore, a 1 cm extra margin was considered adequate. After eight days, the final layer of fixed tissue had demarcated and was removed by snipping adherent strands (Fig 1, bottom left). The lesion, which was not closed or covered with a graft, healed with a smooth, whitish scar (Fig 1, bottom right).

The patient declined prophylactic dissection of the regional nodes but agreed to report for follow-up every two months. Two years later, a small nodule appeared in the lower parotid region. A superficial parotidectomy and a cervical dissection revealed four small metastatic parotid nodes but the 22 cervical nodes contained no melanoma. Although there was no recurrence of the primary tumor or evidence of metastasis in the parotid or cervical nodes, the patient died of internal malignancy five years after removal of the primary melanoma. Multiple metastatic nodules in the lungs and liver were presumed to be melanoma, but in the absence of an autopsy, the possibility of another primary malignancy was not ruled out.

THREE TYPES OF MELANOMA

Nodular melanoma, superficial spreading melanoma, and lentigo maligna melanoma all are treated chemosurgically in essentially the same way. However, because the biologic behavior differs for the three types,[3] they are considered separately.

Nodular Melanoma

Nodular melanoma grows vertically from the onset that is in contrast to the other types of melanoma that characteristically spread peripherally in the superficial layers of the skin for a considerable time before the vertical growth phase sets in. Partly because

Fig 2.—Left, Amelanotic melanoma, invasive to level 5. Center, Granulations after chemosurgical excision that included a clinically unpredicted extension into upper eyelid. Right. Healed lesion. No recurrence after five years.

Fig 3.—Top left, Nodular melanoma of the heel, invasive to level 5. Top right, Fixed tissue when a microscopically melanoma-free level was reached. Bottom left, Granulations after separation of fixed tissue. Bottom right, Healed lesion with stabile weight-bearing scar. No recurrence of primary melanoma after five years when palpable inguinal nodes necessitated a groin dissection.

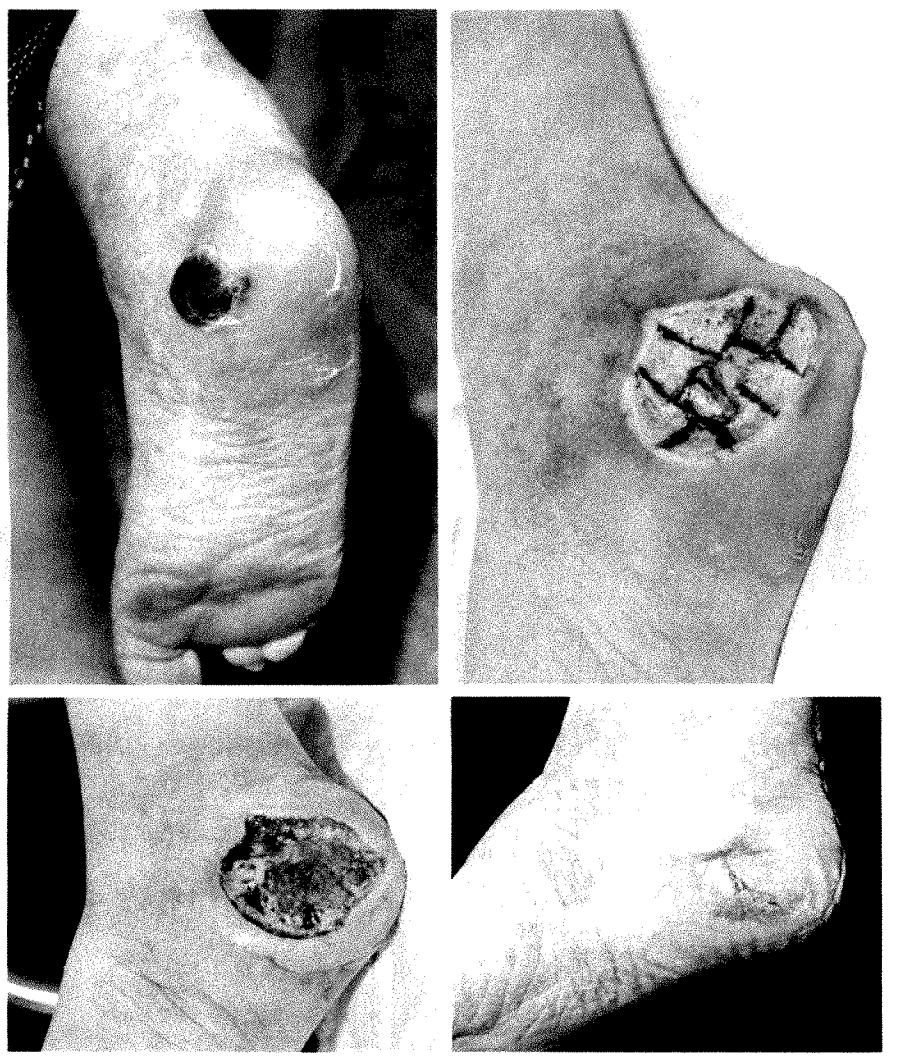

the prognosis depends on the depth of the vertical growth phase, nodular melanomas tend to have a poorer prognosis than the other types. Even when the melanoma only has spread to the extent that it impinges on the reticular dermis (level 3 of Clark), as in the case illustrated in Fig 1, there can be metastases to the regional nodes. Therefore, recognition of the danger of metastatic spread from nodular melanoma is particularly important.

One of the advantages of chemosurgery in the treatment of melanoma is that when the primary neoplasm is close to an important structure, such as the eye, the excision can be more conservative than would be safe with traditional surgical techniques. Thus, an amelanotic nodular melanoma invasive to level 5 was successfully removed from the medial canthal area despite the presence of an unexpected extension of the neoplasm into the upper eyelid (Fig 2). A very wide surgical excision might have entailed enucleation of the orbit and removal of part of the nose while a less radical surgical excision could have missed the silent outgrowth in the upper lid.

Chemosurgery has certain technical advantages in the treatment of melanomas in other areas. For example, melanoma of the sole of the foot can be reliably removed, and when the wound heals by second intention, the scar is stable and comfortable to walk on (Fig 3). The patient shown in Fig 3 declined a prophylactic groin dissection because of her age of 83. However, five years later, she permitted a therapeutic inguinal dissection

because palpable nodes had appeared. Several of the lower nodes were found to contain melanoma, but the upper ones did not. Eight months later she died of a stroke without evidence of recurrence in the primary or secondary sites.

Superficial Spreading Melanoma

Although superficial spreading melanoma often spreads peripherally for many months without danger of metastasis, it becomes increasingly more likely to metastasize when the vertical growth phase sets in. Chemosurgical excision of these lesions ensures removal of both the peripheral superficial component and the vertically-growing component (Fig 4).

Lentigo Maligna Melanoma

Lentigo maligna, or Hutchinson freckle, appears on exposed skin of elderly people and can spread slowly for many years without metastasizing, but it gains the ability to metastasize with the appearance of the vertical growth phase. Chemosurgery

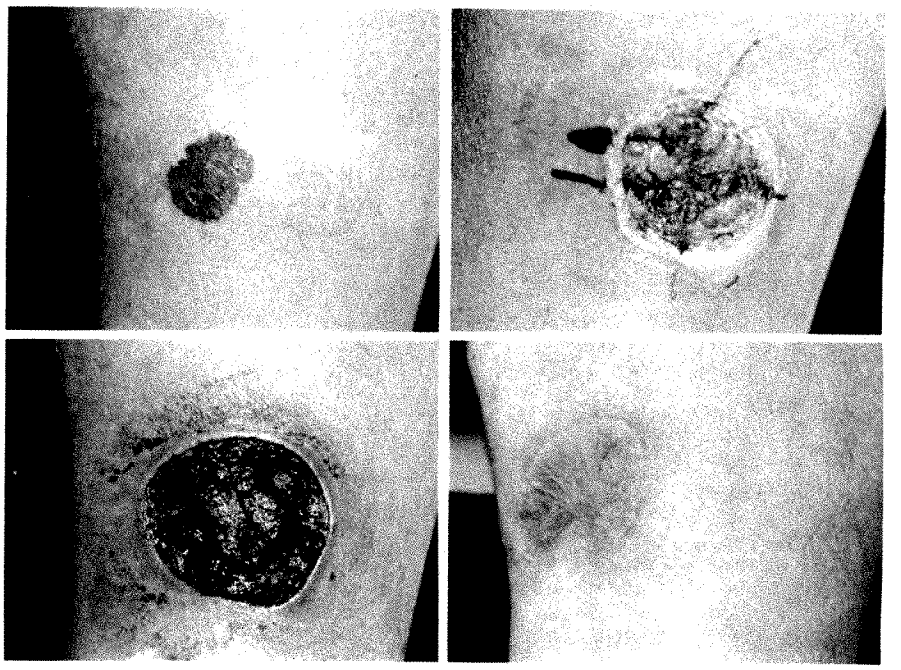

Fig 4.—Top left, Superficial spreading melanoma of the calf of the leg, invasive into reticular dermis (level 4). Top right, Fixed tissue on lesion when a microscopically melanoma-free plane was reached. Bottom left, Granulations after separation of fixed tissue. Bottom right, Healed lesion. No recurrence or metastasis after ten years.

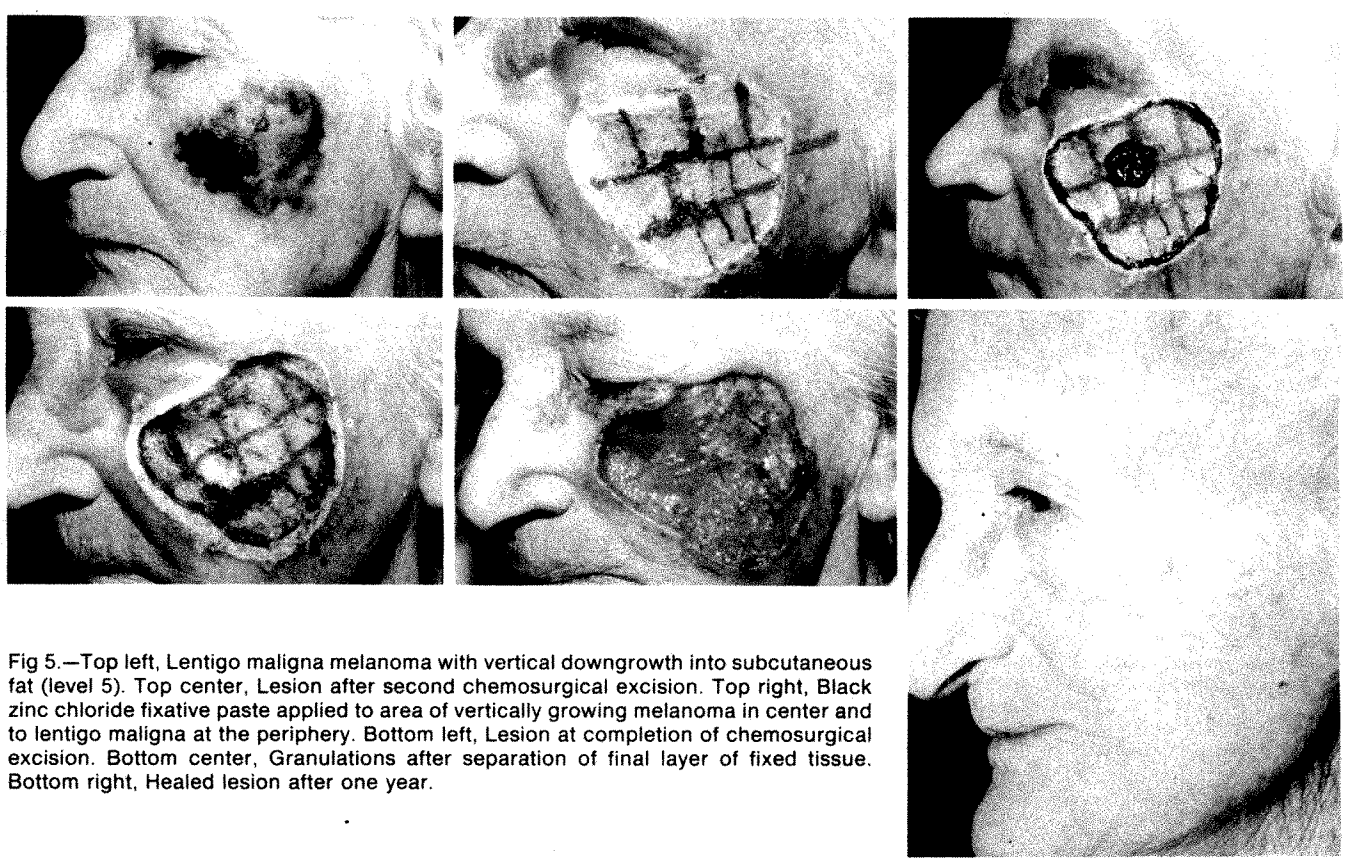

Fig 5.—Top left, Lentigo maligna melanoma with vertical downgrowth into subcutaneous fat (level 5). Top center, Lesion after second chemosurgical excision. Top right, Black zinc chloride fixative paste applied to area of vertically growing melanoma in center and to lentigo maligna at the periphery. Bottom left, Lesion at completion of chemosurgical excision. Bottom center, Granulations after separation of final layer of fixed tissue. Bottom right, Healed lesion after one year.

Fig 6.—Left, Lentigo maligna melanoma invasive only to papillary dermis (level 2). Center, Granulations after separation of fixed tissue. Right, Healed lesion after one year.

Table 1.—Five-Year End Results for the Three Types of Melanoma*

Type of Melanoma	No. of Cases	Determinate Cases		
		Total	Successful	Rate of Cure, %
Nodular	70	59	26	44.0
Superficial spreading	19	16	10	62.5
Lentigo maligna	14	11	7	63.6
Total	**103**	**86**	**43**	**50.0**

*A consecutive series of microscopically proved melanomas, early to advanced, previously treated or recurrent, with or without metastasis, treated chemosurgically during a period of 31 years. Indeterminate cases are those of patients who were without evidence of melanoma when they either died or were lost from observation before completion of the 5-year follow-up.

Table 2.—Effect of Depth of Dermal Invasion on Therapeutic Results Compared With Other Series

Level (Clark)	Chemosurgery, Determinate Cases			Clark et al,[2] Determinate Cases		
	No.	Incidence, %	Cure Rate, %	No.	Incidence, %	Cure Rate, %
2	4	5	100	29	18	90
3	13	15	92	58	36	57
4	14	16	64	59	36	41
5	55	64	33	16	10	19
All	86		50	162		53

not only permits precise location and sure removal of the vertically-growing melanoma, but it also enables accurate removal of the peripheral lentigo maligna portion that often spreads farther than indicated by the grossly visible pigmentation (Fig 5). The lesions are permitted to heal by second intention; no grafts or flaps are used.

With education to impress on everyone the importance of early recognition and treatment of melanomas, the goal of removing these neoplasms while still in the safe level 2 stage is occasionally reached (Fig 6).

RESULTS

Meaningful evaluation of the five-year results of the chemosurgical treatment of melanoma requires separate classification of the data under the three types of melanoma (Table 1) and under the five levels of dermal invasion (Table 2).

As shown in Table 1, there were 103 cases of melanoma of which 86 were determinate. Of the 86 determinate cases, 43 were successfully treated giving a five-year cure rate of 50% for all three types of melanoma. As expected, the cure rate for nodular melanoma (44%) was less than that for superficial spreading melanoma (62.5%), or for lentigo maligna melanoma (63.6%). To be noted is the unusually high incidence of nodular melanoma (59/86 or 69%); this probably is because the more serious malignancies tend to be referred to a university medical center. In evaluating the statistics, the adverse effect of the high proportion of nodular melanomas has to be considered.

As shown in Table 2, the rate of cure of melanomas of all types is strongly influenced by the depth of dermal invasion. The cure rates for lesions invasive to the various levels were: 100% for level 2, 92% for level 3, 64% for level 4, and 33% for level 5. This is a pattern similar to the series of surgically treated melanomas reported by Clark et al,[3] but it will be noticed that the cure rates achieved with chemosurgery are higher for each individual level of invasion. However, the rate of cure for the combined total of lesions at all levels was 50% for the chemosurgery series as compared with 53% in Clark's series. This seeming discrepancy is readily accounted for by noting the much higher incidence of the deeper lesions in the chemosurgery series. For example, in the chemosurgery column the incidence of level 5 lesions was 64% as compared with only 10% in the surgery column. The higher cure rate in Clark's combined group reflects the earlier diagnosis of melanoma that has resulted in recent years from education of both the public and the profession regarding the importance of early recognition and treatment of growing pigmented lesions. When the present series of chemosurgically-treated melanomas was instituted in 1937, almost all of the neoplasms had invaded to level 5, but in recent years there has been definite trend toward earlier diagnosis with consequent higher rates of cure.

When the proportion of nodular melanomas and the levels of invasion, as well as the thickness, diameter, and degree of malignancy are considered, the five-year therapeutic results achieved with chemosurgery compare favorably with conventional surgery.

In the present series of 103 cases of melanoma, there were only three recurrences in the primary site (3%).

One was in an eyelid where a recurrent melanoma in an area of melanosis in the conjunctiva was being treated when the patient died of coronary occlusion. The second recurrent melanoma appeared in the center of a chemosurgical scar on the lower leg four years after chemosurgical excision of a nodular melanoma; the recurrent focus was re-excised chemosurgically, and there was no further recurrence after 15 years. The third recurrent lesion was a superficial spreading melanoma under a fingernail; the recurrence appeared proximal to the nail which had been chemosurgically excised nine months previously. Following chemosurgical re-excision, there was no further recurrence after 18 years.

COMMENT

Advantages of Chemosurgery

Advantages of chemosurgery in the treatment of cutaneous melanoma are as follows: (1) reliability, (2) flexibility, (3) conservatism, (4) low operative risk, (5) good healing, and (6) extension of operability to some patients with advanced melanoma in difficult sites where other treatment would not be feasible. Because these advantageous features form the basis of the rationale of chemosurgery in the treatment of cutaneous melanoma, they are elaborated on herewith.

1. Reliability is evidenced not only by the overall five-year cure rate of 50%, but also by the rate of recurrence in the primary site of only 3%. These statistics are the more impressive when it is considered that 69% of the neoplasms were of the most dangerous type, nodular melanoma, and that 64% of the melanomas had invaded to the subcutaneous tissues (level 5). What are the reasons for this exceptionally high degree of reliability? First, the microscopically controlled excisions ensure removal of the silent outgrowths as well as the main mass of the primary melanoma. Second, the removal of an extra margin of tissue after reaching a microscopically melanoma-free plane enhances the likelihood of encompassing any possible satellites in the peritumoral lymphatics. Third, if a clinically-undetected satellite is transected during chemosurgical excision, the neoplasm remains localized and on the surface where it can be detected early and excised chemosurgically. It is not seeded in the wound as it could be with cold knife surgery during undermining to permit primary closure or during covering of the wound with a graft or flap. Fourth, chemical fixation in situ has no tendency to increase metastasis from malignant tumors as has been shown by animal experiments[4] and by long clinical experience with the chemosurgical method.[5] This is in contrast with electrosurgical methods that produce tissue gases that may propel viable melanomatous cells through the blood vessels or lymphatics.[6] Moreover, chemosurgery avoids the danger of dislodging melanoma cells by a "milking" action such as might occur with any but the most gentle handling of the tissues during surgical excision.

2. Flexibility is achieved by the chemosurgical technique because the first excised layer safely provides adequate tissue for microscopic examination to determine how radical the subsequent excisions should be. If the frozen sections show that the lesion is not melanoma, the subsequent excisions may be appropriately conservative. Among nonmelanomatous lesions that can resemble melanoma are pigmented basal cell carcinoma, pigmented nevi of the junctional, compound, intradermal or blue varieties, histiocytoma, senile lentigo, lentigo maligna, pigmented seborrheic or solar keratoses, basosquamous cell acanthoma, hemangioma, and granuloma pyogenicum. Of course, most of these conditions are readily diagnosed clinically, and it is only rarely that their appearance resembles melanoma, but when it does, chemosurgery provides a safe means of obtaining a definite diagnosis. If the frozen sections of the first excised layer show melanoma, the assessment of the degree of malignancy permits a relatively accurate determination of the proper width of the extra margin that should be removed after reaching a microscopically melanoma-free plane. If the malignancy is observed to be moderate, a 1 cm margin may be adequate, whereas if the malignancy is high, 3 cm or more may be required. The microscopically determined degree of malignancy also aids in deciding whether or not a prophylactic dissection of regional nodes is indicated.

3. Conservatism is an advantage of chemosurgery that is particularly important in treating facial cancers where important structures, such as the eyes or facial nerve, may be endangered. Because the microscopical control ensures removal of the unpredictable ramifications, the removal of the extra margin is only for eliminating possible satellites and hence is somewhat flexible. If satellite deposits should appear at the periphery following removal of an unusually narrow extra margin, these foci have not been disturbed and still are amenable to chemosurgical excision.

4. Low operative risk results from the lack of need for a general anesthetic and the lack of complications from the breakdown of wounds or from infection. Moreover, the greater degree of conservatism, that often is safely feasible, adds to the safety of the procedure. Because most patients remain ambulatory during treatment, the danger of pulmonary complications is obviated.

5. Good healing following chemosurgical excision of melanomas often produces quite good cosmetic results even though most lesions are permitted to heal by second intention. If a defect requiring repair is produced, the well-vascularized tissues following chemosurgery provide a good base for the reconstruction that usually is delayed for at least a year.

6. Extension of operability to patients with extensive melanomas in difficult sites where surgical excision might not be feasible is an advantage. Even though the likelihood of distant metastases from extensive melanomas may dim the prospects for complete cure, the palliative value of removing the primary melanoma often is appreciable.

Management of Regional Nodes

A detailed discussion of the relative merits of prophylactic versus therapeutic dissection of regional nodes is not in the scope of this paper. To date,

there have been no well-controlled, prospective series comparing the results of prophylactic dissection with the results of very close observation of the nodes followed by therapeutic dissection as soon as the nodes become barely palpable. In the absence of such a study, each case has to be evaluated individually regarding the management of the nodes. In the early years of this series, E. R. Schmidt, MD, and I had experiences that caused us to wonder whether therapeutic dissections might not be preferable to prophylactic dissections. For example, a prophylactic groin dissection was done following chemosurgical removal of a nodular, level 5 melanoma of the lower leg. No metastatic nodes were found, but six months later, a therapeutic dissection was required because a metastasis appeared in the pubic region, medial to the usual scope of a groin dissection. Fortunately, the outcome was successful and the patient lived for 30 years without recurrence. Another patient was not so fortunate; a prophylactic neck dissection was carried out after removal of a small nodular, level 4 melanoma of the cheek; no metastatic nodes were found, but seven months later, a node appeared posterior to the scope of the usual neck dissection. A therapeutic dissection was done, but this did not prevent further cervical and finally internal metastases. The question arose: would it not have been preferable to have omitted the prophylactic dissections and to have closely observed these patients and then performed therapeutic dissections that would have encompassed the metastatic nodes beyond the edges of the usual dissection sites?

Until sufficient data are available to permit definite conclusions, it seems best to recommend prophylactic dissections if the primary melanoma has invaded the reticular dermis (level 4) or subcutaneous tissue (level 5), and if the neoplasm is located where there is a well-defined lymphatic drainage pattern. However, there often is a question as to whether a large number of patients should be subjected to unnecessary dissections to provide a somewhat questionable advantage to a relatively few individuals.

Whether or not a prophylactic dissection is done, very close observation must be insisted on. If the patient doesn't return, he should be sent a follow-up letter or called by telephone. If necessary, the help of relatives and the family physician should be enlisted to ensure close follow-up.

Because melanoma is an extremely variable disease, an optimistic attitude should be maintained as long as there is any chance of eradicating the neoplasm. Chemosurgery is an important addition to our armamentarium for the management of primary melanomatous lesions, but the propensity of melanoma to metastasize will constitute a serious problem until earlier diagnosis and treatment is achieved. The best hope of controlling the disease is education of laymen as well as physicians regarding both the early signs of melanoma and the importance of avoiding delay.

References

1. Mohs FE: *Chemosurgery in Cancer, Gangrene and Infections.* Springfield, Ill, Charles C Thomas Publisher, 1956.
2. Mohs FE: Chemosurgical treatment of melanoma: A microscopically controlled method of excision. *Arch Dermatol* 62:269-279, 1950.
3. Clark WH, Lynn F, Bernardino EA, et al: The histogenesis and biologic behavior of primary human malignant melanomas of the skin. *Cancer Res* 29:705-727, 1969.
4. Mohs FE, Guyer MF: Pre-excisional fixation of tissues in the treatment of cancer in rats. *Cancer Res* 1:49-51, 1941.
5. Mohs FE: Chemosurgery for skin cancer: Fixed tissue and fresh tissue techniques. *Arch Dermatol* 112:211-215, 1976.
6. Amadon PD: Electrocoagulation of melanoma and its dangers. *Surg Gynecol Obstet* 56:943-946, 1933.
7. Mihm MC, Fitzpatrick TB, Lane Brown MM, et al: Early detection of primary cutaneous malignant melanoma. *N Engl J Med* 289:989-996, 1973.

Topical Methoxsalen and Blacklight in the Treatment of Psoriasis

John W. Petrozzi, MD; Kays M. Kaidbey, MD; Albert M. Kligman, MD, PhD

• Thirty patients with recalcitrant psoriasis were treated with topical methoxsalen and blacklight (UVA). A 1% concentration either in an acetone, alcohol, propylene glycol vehicle, or hydrophilic ointment, USP, applied two hours before light exposure was highly effective. Twelve patients were completely cleared and nine were markedly improved in three to five weeks. Plaque-type and guttate psoriasis responded best while exfoliative psoriasis benefitted less. Maintenance of a phototoxic reaction in the lesion was necessary for total resolution. Topical methoxsalen and blacklight is feasible for outpatient treatment of plaque-type psoriasis of limited extent.

(*Arch Dermatol* 113:292-296, 1977)

The beneficial effects of sunlight in psoriasis have been recognized for centuries.[1] Heliotherapy remains a prominent form of treatment in many countries. By utilizing crude coal tar and ultraviolet light (UVA) from a hot quartz lamp, Goeckerman succeeded in clearing psoriasis more consistently and rapidly than was possible with sunlight alone.[2,3] Truly resistant cases to this regimen are few, and remissions may be long-lasting.[4] The action spectrum of tar resides in the long UVA region, with peak activity at about 360 nm.[5] Blacklights are a ready source of UVA. However the efficaciousness of the Goeckerman regimen is offset by the messiness and offensive qualities of coal tar. In addition, the role of UVA is still controversial in view of the comparatively large amounts of UVA emitted by the light sources generally used in this regimen.

Recently, investigators have become interested in another, cleaner photosensitizer whose mode of action is understood at the molecular level, namely methoxsalen. In the presence of the drug, irradiation with UVA inhibits the synthesis of DNA by epidermal keratinocytes.[6-8] A stable covalent bond is formed between the pyrimidine bases of nucleic acid and psoralens. In addition, interstrand cross links may be formed between psoralens and two pyrimidine bases of opposite strands of the DNA double helix. Since psoriasis is a hyperproliferative disorder, inhibition of cell multiplication by various means usually brings about regression of lesions.

As early as 1962, a preliminary verbal communication described promising results with topical methoxsalen phototherapy.[9] Strangely, further studies were delayed for ten years. Willis and Harris[10] were unable to achieve clearing of psoriatic plaques with topical methoxsalen and blacklight.[10] Walter et al[8,11] were only moderately successful. More recent studies will be described later.

Our object is to show that topical methoxsalen (8-MOP) appropriately employed with blacklight is a highly effective way of clearing psoriatic lesions.

MATERIAL AND METHODS

Patients

Twenty-nine male subjects and one female subject with longstanding psoriasis were treated. They ranged in age from 13 to 65 years. Twenty-five had chronic, stable, extensive plaque-type psoriasis; three had exfoliative psoriasis involving about 75% of the body surface. Two, including the 13-year-old female subject, had guttate psoriasis. All had been previously treated with topical corticosteroid preparations and were no longer responding adequately. Fifteen were hospitalized. The remaining 15 were outpatients.

Light Source

We used the following two UVA set ups: (*a*) For irradiation of localized plaques, a bank of five parallel 20 W fluorescent blacklights, 2 cm apart, in an aluminum reflecting housing was used (F20-T-12, Sylvania). The bank utilized five preheat

Accepted for publication June 18, 1976.

From the Department of Dermatology, School of Medicine, University of Pennsylvania, and the Dermatology Section of the Veterans Administration Hospital, Philadelphia.

Reprint requests to Department of Dermatology, Philadelphia Veterans Administration Hospital, University and Woodland Aves, Philadelphia, PA 19104 (Dr Petrozzi).

transformers with starters. The lamp-skin distance was 13 cm to compensate for the comparatively low irradiance of the lamps. The bank used for the first 14 patients in the study utilized a less efficient ballast and emitted a lower amount of UVA energy. (*b*) For total body irradiation of extensive psoriasis, a Zimmerman cabinet was used (internal dimensions 85 cm × 70 cm). Initially (first 14 patients), this was equipped with eight UVA bulbs, two in each corner; later we increased to 28 fluorescent rapid-start blacklight tubes (General Electric F40 BL), distributed so as to encircle the patient (six bulbs on the three sides, two bulbs in each of the four corners, and two bulbs on the door). The box was lined with aluminum reflectors.

Treatment

Initially we utilized a 1% concentration of methoxsalen in hydrophilic ointment, USP. Subsequently, we evaluated a proprietary form of methoxsalen (Oxsoralen), 1% solution in an acetone, alcohol, propylene, glycol vehicle. The medications were applied liberally with cotton-tipped applicators, two hours before irradiation. The first two exposure times, three days apart, were three minutes with the bank of blacklights and five minutes in the Zimmerman box. The first 14 patients received starting exposure times of five minutes from the bank and eight minutes from the Zimmerman box since these sources emitted lower UVA energy than the modified Zimmerman box and the more efficient ballasts in the UVA bank. Because psoralen phototoxicity peaks at about 72 hours, this interval allowed time to perceive the patient's reaction and to plan dosage accordingly. Very little reaction was visible within the plaques themselves; erythema developed in the surrounding skin despite attempts to confine medication to the lesions. In fact, the phototoxic reaction in perilesional skin guided dosage increments. After the first week, patients were treated either daily (five times weekly) or three times a week. In general, the exposure could be increased by two minutes every second or third treatment after the first week. In this way, a mild to moderate phototoxic response was maintained. The dose could be more rapidly increased in blacks and patients who tanned readily while fair-skinned patients required a more gradual increase. Treatment could usually be completed with a maximum exposure of about 25 minutes with the UVA bank and 35 minutes in the cabinet. We did not realize until afterwards that the ultraviolet meter used to measure irradiance gave excessively high readings; hence we record the dose in minutes rather than joules.

Therapeutic Response of Patients*

Patient No.	Age, yr	Sites Treated	Light Source	Therapeutic Response	No. of Treatments
1	62	Trunk and extremities	Box	1+	5
2	57	Lower extremities	Bank	3+	21
3	38	Trunk	Bank	4+	21
4	36	Trunk and extremities	Box	4+	28
5	61	Trunk	Bank	4+	21
6	45	Upper extremities	Bank	4+	12†
7	32	Generalized exfoliative	Box	2+	21
8	56	Generalized exfoliative	Box	2+	28
9	60	Lower extremities	Bank	4+	21
10	13	Generalized guttate	Box	3+	14
11	62	Generalized exfoliative	Box	2+	12†
12	59	Trunk	Box	3+	28
13	23	Trunk and extremities	Box	4+	28
14	53	Trunk	Box	4+	15
15	47	Trunk and extremities	Box	4+	15†
16	50	Trunk and extremities	Box	2+	15†
17	44	Trunk and extremities	Box	3+	15†
18	54	Trunk and extremities	Box	3+	15†
19	38	Extremities	Box	2+	15†
20	45	Extremities	Bank	4+	20
21	64	Trunk	Bank	4+	15
22	60	Extremities	Bank	3+	20
23	37	Trunk and extremities	Box	3+	12
24	58	Extremities	Bank	2+	17†
25	47	Elbows	Bank	3+	19
26	59	Elbows	Bank	1+	20
27	52	Knees	Bank	2+	16†
28	57	Knees	Bank	3+	23
29	50	Elbows and arms	Bank	4+	12†
30	61	Thighs	Bank	4+	10

*Patients 1 through 14 received exposures from lower UVA energy sources.
†Treated three times a week on alternate days.

In patients with very thick plaques, two nightly occlusive applications of 15% salicylic acid in a propylene glycol:ethanol solution (85%:15%) were used before phototherapy to remove scales. Unfortunately, the number of plaques receiving these applications were not tabulated and compared with those not receiving salicylic acid applications. This data therefore could not be clearly presented.

Clearing of the lesions was graded as follows: 1+, diminished scaling; 2+, decreased erythema and infiltration; 3+, minimal infiltration; and 4+, complete clearing. The treatment period ranged from three to five weeks.

Control plaques were treated in each patient with the vehicle and UVA irradiation. The use of UVA alone and the vehicles alone were abandoned after it was shown to be completely ineffective in the first six patients.

RESULTS

Therapeutic Response

Twelve of 30 patients cleared completely after 12 to 28 treatments (Table). Eleven of these had plaque-type and one had guttate psoriasis. Nine others were markedly improved, and nine showed a partial response (2+ to 1+) (Fig 1 through 4). Three of the latter patients had generalized exfoliative psoriasis. It was our clinical impression that lesions over the trunk generally responded more promptly than those over the extremities, though the number of patients was too small to be definitive. Since patients treated three times per week received five to nine less treatments over the study period, we cannot compare the results of the two treatment regimens. It is possible that while taking longer, treating three times per week may be equally or more effective. Patients who did not achieve a greater than +2 response by five weeks were deemed to be resistant. We found that several more weeks of intensive treatment failed to bring about clearing. Control plaques

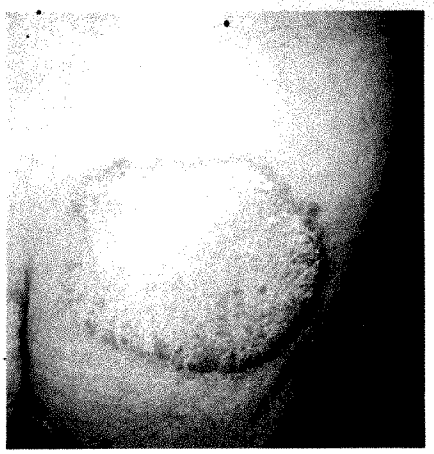

Fig 1.—Patient 5 before treatment.

Fig 2.—Patient 5 after 21 treatments with 1% methoxsalen in hydrophilic ointment.

Fig 3.—Patient 13 before treatment.

Fig 4.—Patient 13 after 28 treatments with 1% methoxsalen solution.

never cleared and generally did not change, even slightly. Therefore, they have been excluded from the tabulation of the grades of response. Responses to the higher energy UVA sources did not appreciably increase the effectiveness of the treatment. It did, however, decrease the duration of treatments in patients who tanned quickly and required longer exposures. We did not tabulate the number of psoriatic plaques that received and did not receive salicylic acid, but it is our clinical impression that thick plaques respond better when pretreated with salicylic acid.

Adverse Reactions

Pruritus.—This occurred in eight patients usually after three to four treatments and was associated with marked perilesional erythema. Pruritus usually persisted throughout treatment though it could be somewhat diminished by giving antihistamines. One patient (No. 1) discontinued therapy after five treatments because of stubborn severe pruritus.

Hyperpigmentation.—This was conspicuous in all white patients. The cleared sites were intensely pigmented, providing an impressive record of the distributions of lesions. In most cases, the hyperpigmentation that also involved a small area of surrounding skin disappeared in about two months. In three cases, the pigmentation was evident for four months and in two others, it lasted for six months.

Koebner Reaction.—Two patients who showed severe phototoxic reactions after six to ten exposures developed a Koebner reaction in the perilesional skin at the site of the phototoxic reaction after four to seven days. Nonetheless these new lesions also responded while treatment was continued with lower doses.

Blistering.—Three patients treated with the bank developed small blisters at the margins of psoriatic plaques, one after the first exposure, another after the third, and the last one after the 13th exposure. Treatment of these plaques was discontinued for a week and then reinstituted at lower doses with no difficulty. All three later achieved complete clearing.

Follow-Up Observation

Seventeen patients could be followed for one year without further treatment.

Eight who were completely cleared stayed in remission for two to ten months. Six of these were clear for an average of 2½ months, one for 6 months, and one for 10 months.

All nine incompletely cleared patients relapsed to pretreatment levels in three to five weeks.

Special Studies

Interval.—In a previous study,[12] it was determined that UVA exposures two hours after the ingestion of methoxsalen was the optimum time interval for production of a phototoxic reaction. We carried out a similar study with 1% methoxsalen cream on the normal skin of the back in four patients 30 minutes, 1, 2, 4, 6, and 24 hours after open application. Irradiation was with the UVA bank, 5 cm from the skin for two minutes. The reactions were examined 72 hours after exposure.

Results.—At one half and one hour, reaction varied from 1+ to 3+. Peak reactions (+4) developed at two hours in all four patients. The response had begun to diminish after three hours (+2, +3), clearly so after four and six hours (+1 to +2). No reaction occurred after 24 hours in any patient. (Grading: +1 erythema, +2 erythema with edema, +3 marked erythema and edema, +4 vesiculation, 72 hours after exposure).

Concentration.—In the same four

patients, occluded and unoccluded applications (0.2 mg from a tuberculin syringe) of 0.1% and 1% methoxsalen in hydrophilic ointment were compared after irradiation at 5 cm for two minutes with the UVA bank two hours after application. The agents were rubbed in vigorously with a cotton-swab, and when occluded, a plastic wrap was taped over the site. Readings were made 72 hours after exposures.

Results.—With occlusion, 0.1% methoxsalen was only slightly less phototoxic than 1% as judged by the same grading system as above. Three patients differed by one grade, that is, +2 vs +3 and +3 vs +4. One patient went from +1 to +3 with the 1% methoxsalen. Without occlusion, 0.1% methoxsalen produced no reaction in one patient, +1 reaction in two patients, and +2 reaction in one patient. This compared to +2 reaction in two and +3 reaction in two patients using 1% methoxsalen.

Comparison of Solution with Cream on Psoriatic Lesions.—In symmetrical plaques of five patients, 1% methoxsalen in the liquid vehicle was compared to hydrophilic ointment. Each plaque was treated five times weekly for three weeks and irradiated with the UV-A bank two hours after open application.

Results.—The solution was equal to the hydrophilic ointment in only one patient who cleared completely at the same rate with both preparations. In the other four, the hydrophilic ointment caused clearing in two, with marked improvement in the other two. The solution gave moderate improvement in two and only slight improvement in the remaining two. The rate of clearing was slower with the solution. This was particularly evident in thick plaques.

COMMENT

The combination of 1% methoxsalen followed in two hours by individually adjusted doses of UVA sufficient to produce a phototoxic reaction was highly efficacious in recalcitrant plaque-type psoriasis. We selected the concentration and the interval between application and irradiation after having evaluated these variables on normal persons. Our results with topical phototherapy are more impressive than those of previous workers. Willis and Harris[10] found no benefit with 0.1% methoxsalen irradiated after 30 to 45 minutes for 15 minutes with three sunlamps and three blacklight bulbs placed 17.5 to 22 cm from the skin. In our view, they failed because the concentration of methoxsalen was too low, the interval was too short, and the dosage of UVA was too small (too few lamps at too great a distance).

Walter and Voorhees[11] were more successful. Two of eight patients cleared, and eight of 11 improved. They used trioxsalen in an ethanol: propylene glycol solution, in concentrations up to 0.25%, irradiating two hours later with four blacklight bulbs for as long as 20 minutes, three times weekly. Topically, trioxsalen is as phototoxic as methoxsalen.[13] Again, a higher concentration would probably have improved their results.

Weber[14] used 0.15% methoxsalen in isopropyl alcohol followed in one hour by 8 to 12 minute exposures to 30 high-intensity blacklight bulbs in a cylindrical chamber. He achieved total clearing in 34 and great improvement in 24 of 74 patients. The higher quantity of irradiation from 30 UVA bulbs apparently offset the low concentration. Weber's patients received treatment for five days a week for two weeks with a week interval before re-exposures for another two weeks.

The beneficial results obtained by Tronnier and Schule[15] in seven psoriatics are surprising to say the least. They irradiated every three to four days with a bank of five blue-black UVA bulbs at 50 cm for 8 to 20 minutes, ten minutes after application of 0.15% methoxsalen. We could not clear psoriatic plaques in two patients treated in a similar manner (unpublished data).

Recently, Parrish et al[16] have utilized oral methoxsalen (up to 50 mg) followed in two hours by exposures in a chamber housing 48 newly developed, high energy UVA fluorescent bulbs. Their results were dramatic; 21 of 21 psoriatics achieved complete resolution. They used the term "photochemotherapy" for this treatment; their claims are being amply confirmed by ourselves and many others. Treatment was given on alternate days. Remission occurred after 12 to 20 exposures. For widespread psoriasis, oral administration of methoxsalen is certainly the method of choice. It eliminates the burden of applying medication to every plaque and is not attended by unsightly hyperpigmentation at cleared sites. On the other hand, topical methoxsalen might be advantageous when there are only a few lesions. Moreover, in special locations such as the palms and soles, topical therapy might be more practical. Topical methoxsalen may be a useful adjunct to oral phototherapy for treating very thick lesions or stubborn plaques in special locations. We are currently evaluating this "touch-up" approach. We would emphasize that extensive psoriasis requires oral phototherapy.

We have lately treated a good many more psoriatic patients with topical phototherapy. Our current views may be summarized as follows:

1. Thick keratotic plaques should be descaled prior to the start of treatment. Salicylic acid under occlusion for two to three nights is the best drug for this purpose. We used 15% salicylic acid in a propylene glycol:ethanol base, but a proprietary preparation of 6% salicylic acid in propylene glycol can be employed. It is our clinical impression that without prior sal acid treatment to thick plaques, the response to therapy is less effective. Non-keratotic plaques do not require sal acid treatment.

2. The optimal interval between application and irradiation is two hours.

3. We prefer 1% methoxsalen in hydrophilic ointment. Patients must be cautious against sloppy applications. The agent must be restricted to the psoriatic lesions to minimize the risk of blistering. The exposures must be long enough to create a visible phototoxic reaction in the surrounding skin. The times will increase as therapy proceeds but must be adjusted to each individual according to skin type. Useful information can be obtained by inquiring about ease of sunburning and difficulty in tanning. With a bank of five blacklights (Syl-

vania BL F20T12) 13 cm away, the maximum exposure in most instances will rarely exceed 25 minutes and is usually 15 to 20 minutes. However, some patients may build up a tremendous tolerance and withstand 30 to 40 minutes.

4. Daily irradiation brings about more rapid clearing than on alternate days, most likely in our experience because it resulted in a greater number of treatments given in the study period. It is possible that alternate day treatment may be effective. Caution is advised in the first week until the patients' responses are known. The first dose is given on Monday and the second on Thursday since phototoxicity to methoxsalen reaches a peak in 48 to 72 hours. We now start with three minutes from our UVA bank in fair-skinned subjects who sunburn easily and tan poorly. Exposures can be more rapidly advanced in those who tan rapidly. In thick palmar plantar psoriasis, exposures may begin at 15 minutes and have to be increased to 45 minutes daily. It should not be casually assumed that all blacklights are equivalent either in intensity or spectral quality. We can vouchsafe only for the lamps we used (Sylvania BL F20T12 and General Electric F40 BL).

Finally, there is the question of photocarcinogenicity. Tumors on the ears of albino mice were produced in 53% of the animals treated with topical 0.1% methoxsalen in ethanol and irradiated with UVA five days a week for 127 days.[17] Using the same animal model, similar tumors were produced in 100% of mice treated with 3% crude coal tar and UVA irradiation. Recently, the carcinogenic effect of topical methoxsalen was demonstrated in hairless mice irradiated with the xenon arc solar simulator two hours a day, five days a week for 40 weeks.[18]

It is anybody's speculation whether oral or topical methoxsalen phototherapy will produce cancers in humans with the exposures required to keep psoriasis in remission. It is a fact that despite the known carcinogenicity of coal tar, instances of tumor induction in humans treated over decades by the Goeckerman regimen are exceedingly rare and of these, none are indisputable. The same can be said for centuries of use of plant psoralens in countries where solar insulation is very high. We think the risks are slight in relation to the torments of the disease.

Recently, a novel approach to the photochemotherapy of psoralen has been offered by Fischer and Juhlin.[19] They utilized a 15 minute bath with trioxsalen (0.5 mg/liter) and irradiated immediately after the bath with 8 dysprosium gas discharge lamps. This light source emits a low dose of UVB as well as high intensity UVA. Seventeen of 18 psoriatic patients were cleared within six weeks.

Margaret McQuiggan rendered technical assistance in the treatment of these patients.

Nonproprietary Name and Trademarks of Drug

Methoxsalen—*8-MOP; Oxsoralen.*

References

1. Alderson JE: Heliotherapy in psoriasis. *Arch Dermatol Syphilol* 8:79-80, 1923.
2. Goeckerman WH: The treatment of psoriasis. *Northwest Med* 24:229-231, 1925.
3. Goeckerman WH: Treatment of psoriasis. *Arch Dermatol Syphilol* 24:446-450, 1923.
4. Perry HO, Soderstrom CW, Schulze RW: The Goeckerman treatment of psoriasis. *Arch Dermatol* 98:178-182, 1968.
5. Everett MA, Miller JV: Coal tar and ultraviolet light: II. Cummulative effects. *Arch Dermatol* 84:937-940, 1961.
6. Epstein JH, Fukuyama K: Effects of 8-methoxypsoralen (8-MOP) induced phototoxic effects on mammalian epidermal macromolecular synthesis in vivo. *Photochem Photobiol* 21:325-330, 1975.
7. Baden HP, Parrington JM, Delhandty JDA, et al: DNA synthesis in normal and xeroderma pigmentosum fibroblasts following treatment with 8-methoxypsoralen and long wave ultraviolet light. *Biochem Biophys Acta* 261:247-248, 1972.
8. Walter JE, Voorhees JJ, Kelsey WH, et al: Psoralen plus blacklight inhibits epidermal DNA synthesis. *Arch Dermatol* 107:861-865, 1973.
9. Allyn B: Studies on phototoxicity in man and laboratory animals. Read before the 21st annual meeting of the American Academy of Dermatology, Chicago, December 1962.
10. Willis I, Harris DR: Resistant psoriasis: Combined methoxsalen-anthralin therapy. *Arch Dermatol* 107:358-362, 1973.
11. Walter JF, Voorhees JJ: Psoriasis improved by psoralens plus blacklight. *Acta Derm Venereol (Stockh)* 53:469-472, 1973.
12. Kligman A, Goldstein FP: Oral dosage in methoxsalen phototoxicity. *Arch Dermatol* 107:548-550, 1973.
13. Pathak MA, Fellman JH, Kaufman KD: The effect of structural alterations on the erythemal activity of furocoumarins: Psoralens. *J Invest Dermatol* 35:165-183, 1960.
14. Weber G: Combined 8-methoxypsoralen and blacklight therapy of psoriasis. *Br J Dermatol* 90:317-323, 1974.
15. Tronnier H, Schule D: Zur dermatologischen therapie von dermatosen mit langwelligem UV nach photosensibilisierung der huat mit Methoxsalen erste ergebnisse bei der psoriasis vulgaris. *Z Haut Geschlechtskr* 48:385-393, 1973.
16. Parrish JH, Fitzpatrick T, Tanenbaum L, et al: Photochemotherapy of psoriasis with oral methoxsalen and longwave ultraviolet light. *N Engl J Med* 291:3-7, 1974.
17. Urbach F: Modification of ultraviolet carcinogenesis by photoactive agents. *J Invest Dermatol* 32:373-378, 1959.
18. Forbes PD, Urbach F: Experimental modification of photocarcinogenesis: III. Simulation of exposures to sunlight and fluorescent whitening agents. *Food Cosmet Toxicol* 13:343-345, 1975.
19. Fischer T, Juhlin L: Photochemotherapy of psoriasis with trioxsalen baths and dysprosium lamps. *Arch Dermatol,* to be published.

Shortage of Full-Time Faculty in Dermatology

Clayton E. Wheeler, Jr, MD; Robert A. Briggaman, MD; Ivor Caro, ME, BCh, FF Derm

• A persistent shortage of full-time faculty exists in dermatology. Despite the addition of 124 new full-time faculty since 1971 through 1972, 136 training programs in 1974 through 1975 were actively seeking 88 new full-time faculty and believed they needed 243. With a net gain of 30 new faculty a year, it will take 2.93 years to add 88 new faculty that are being actively sought and 5.16 years to add 155 more that are urgently needed. During this eight years, demand for new faculty will increase, so that figures of need may remain essentially unchanged in 1982 through 1983 as between 1971 through 1972 and 1974 through 1975. Expertise that was most needed was in immunology, electron microscopy, histopathology, microbiology, and biochemistry; many accept faculty in any area or with no special training. Measures should be taken to attract and retain more dermatologists in full-time academic positions.

***(Arch Dermatol* 113:297-301, 1977)**

In our report in 1973,[1] we called attention to the existence of a severe shortage of full-time faculty in 1971 through 1972. Since then we have conducted two surveys, one in 1972 through 1973 and one in 1974 through 1975, to determine whether the number of full-time faculty in dermatology has increased and whether a shortage still exists. In this communication, we compare the results of the 1971 through 1972 survey with the results of the 1972 through 1973 and 1974 through 1975 surveys. Although there has been an increase of 124 persons in the total number of full-time faculty since 1971 through 1972, the demand for new faculty has increased, so that the degree of shortage remains about the same as it was in 1971 through 1972.

MATERIALS AND METHODS

In our 1971 through 1972 survey, a five-page questionnaire was sent to all active or potential training units in dermatology in the United States and Puerto Rico, which was a total of 133 training units. A less extensive, two-page questionnaire was sent to the same units in 1972 through 1973, except that category D, which consisted of three unclassified units, was omitted. In 1974 through 1975, the two-page questionnaire was sent to all of the actual or potential training units in dermatology, which at that time numbered 136. Questions in the shorter, two-page questionnaire were taken from the original five-page questionnaire; hence, the questions that were pertinent to this study were the same for the three periods of survey and should produce comparable data for these periods. All training units either returned completed questionnaires or were called by telephone. We therefore obtained information from all of the units.

For purposes of our surveys and this report, the training units were divided into three categories. Category A included training programs in medical schools in which there were approved dermatology residencies; category B included training programs in medical schools in which there were no approved dermatology residencies; and category C included approved dermatology residency programs outside medical schools. In the 1971 through 1972 and 1972 through 1973 periods, there were 67 units in category A, 44 units in category B, and 19 units in category C. In 1972 through 1973, five programs in category B were well along in developing residency programs, and in 1974 through 1975, these were shifted to category A, since their programs were then approved. Since new medical schools were activated, new schools were added to category B in the 1974 through 1975 survey. There were also some rearrangements in category C; one of these programs was transferred to category A, one was phased out, and two new ones were added. In 1974 through 1975, there were 74 units in category A, 43 units in category B, and 19 units in category C.

A full-time faculty member was defined as one who spends about half of his time in teaching, research, or administration, regardless of the source of his income. He might spend the other half of his time in various combinations of teaching, research, patient care, or administration. He might derive his income from school salary, from a practice within the geographic confines of the school, from a private office outside

Accepted for publication June 29, 1976.

From the Department of Dermatology, University of North Carolina School of Medicine, Chapel Hill.

Reprint requests to North Carolina Memorial Hospital, Chapel Hill, NC 27514 (Dr Wheeler).

of the school, or from combinations of these. The major requirement was that he spend half of the total working hours in teaching, research, or administration. We recognize that this definition includes fully salaried faculty, geographic full-time faculty deriving income from practice within the confines of the institution, and functionally geographic full-time faculty deriving all or most of their income from practice outside of the confines of the institution. This definition differs from that used by most schools and by the American Medical Association, but we can see no real difference in "faculty function" between a fully salaried member who spends half of his time seeing private patients in the institution to generate funds for his own salary and departmental activities, a geographic full-time member who does about the same, and a "part-time" faculty member who generates all of his personal income from practice outside of the institution, yet works half-time at teaching, research, or administration at the institution.

Table 1.—Number of Full-Time Faculty in Dermatology

Type of Unit*	1971-1972† No. of Units	1971-1972† No. of Faculty	1971-1972† Faculty per Unit	1972-1973† No. of Units	1972-1973† No. of Faculty	1972-1973† Faculty per Unit	1974-1975 No. of Units	1974-1975 No. of Faculty	1974-1975 Faculty per Unit
A	67	256	3.82	67	307	4.58	74§	360	4.86
B	44	12	0.27	44	24‡	0.55	43‖	14	0.33
C	19	52	2.74	19	63	3.32	19	70	3.68
Total	**130**	**320**	2.46	**130**	**394**	3.03	**136**	**444**	3.26

*A indicates training programs in medical schools with approved dermatology residencies; B, training programs in medical schools without approved dermatology residencies; C, approved dermatology residency programs outside medical schools.

†Indicates questionnaire sent to same programs in 1971 through 1972 and 1972 through 1973.

‡Higher figure includes five units with developing residency programs. These units were moved in 1974 through 1975 to type A units with approved residency programs.

§Seventy-two schools with 74 residency programs.

‖Forty-two schools with 43 programs.

Table 2.—Distribution of Training Units According to Number of Full-Time Faculty per Unit

Type of Unit*	Number of Full-Time Faculty Members per Unit: 0	1	2	3	4	5	6	7	8	9	>9†	‡
130 Training Units in 1971-1972												
A	3	13	15	8	7	6	5	4	0	0	5	1
B	34	8	2	0	0	0	0	0	0	0	0	0
C	0	4	4	5	2	2	0	1	0	0	0	1
Total	**37**	**25**	**21**	**13**	**9**	**8**	**5**	**5**	**0**	**0**	**5**	**2**
136 Training Units in 1974-1975												
A	1	7	12	16	14	5	8	3	0	2	6	...
B	29	13	1	0	0	0	0	0	0	0	0	...
C	0	2	4	5	3	2	1	0	1	1	0	...
Total	**30**	**22**	**17**	**21**	**17**	**7**	**9**	**3**	**1**	**3**	**6**	...

*For explanation of symbols, see Table 1.

†For 130 training units in 1971 through 1972, there is one each at 10, 14, 15, 17, and 18; for 136 training units in 1974 through 1975, there is one each at 12, 16, 17, 20, 21, and 23.

‡Not clear how many full-time members per unit.

RESULTS

Number of Full-Time Faculty in Dermatology in 1971 Through 1972, 1972 Through 1973, and 1974 Through 1975

The number of full-time faculty in the three survey periods is presented in Table 1, which shows the number of dermatologic units, the total number of faculty, and the number of faculty per unit in each of our three categories. During the four-year period, the average number of full-time faculty in category A increased from approximately four to approximately five per training unit. The number increased from approximately three to approximately four in category C. The number remained essentially unchanged in category B. Overall, the average number of full-time faculty increased from 2.5 to 3.25 per training unit.

According to our survey, the total full-time faculty increased from 320 in 1971 through 1972 to 444 in 1974 through 1975, an increase of 124 positions, or 38.7%. By another definition of full-time faculty, the AMA lists filled budgeted full-time positions in dermatology as follows: 192 positions in 1971 through 1972,[2] 232 in 1972 through 1973;[3] 246 in 1973 through 1974,[4] 262 in 1974 through 1975.[5] This is an increase from 1971 through 1972 to 1974 through 1975 of 70 positions, or 36.5%. By either method, it appears that there has been an increase of 36% to 38% in full-time faculty in dermatology during the four-year period.

Distribution of Full-Time Faculty Among the Training Units

Table 2 shows the distribution of full-time faculty among the training units in the three categories for the 130 programs in 1971 through 1972 and the 136 programs in 1974 through 1975.

Although the average number of faculty per training unit in category A increased from about four in 1971 through 1972 to about five in 1974 through 1975 (Table 1), Table 2 shows that there were two faculty per unit most often in 1971 through 1972, and there were three faculty per unit most often in 1974 through 1975. Obviously, figures for the average faculty per unit were skewed by the few programs with large members of faculty; there were five programs with over ten faculty in 1971 through 1972 and six with over 12 in 1974 through 1975. Despite an increase in average faculty per unit from 2.74 to 3.68 in category C, the most frequently reported number of faculty per unit in the two survey periods was three. Perhaps the most noteworthy item in Table 2 was the large number of training units without full-time faculty, ie, 37 in 1971 through 1972 and 30 in 1974 through 1975. As anticipated, these were chiefly in category B, which includes schools without residency training programs.

Number of New Full-Time Faculty Being Actively Sought in 1974 Through 1975

The number of new full-time faculty members being actively sought in 1974 through 1975 in comparison with

1971 through 1972 and 1972 through 1973 is presented in Table 3. According to respondents to the questionnaires (chiefs of programs in dermatology, chairman of medicine departments, and deans), funds to pay these faculty members were either at hand or there were excellent possibilities of obtaining the money if suitable faculty could be found. In all three survey periods, essentially all of the respondents indicated that it would be difficult to find these faculty members. According to our data, 88 new faculty members were being actively sought by 61 training units in 1974 through 1975 in comparison with 99 and 95 faculty members in 61 training units in 1972 through 1973 and 1971 through 1972, respectively. Although 61 training programs were actively seeking faculty in each of the three survey periods, the same programs were not seeking new faculty each year; it is only coincidence that the number of programs seeking faculty was 61 in each period. The number of faculty being actively sought in the three categories of training units was similar in the three survey periods, despite the total gain of 124 full-time faculty in the period from 1971 through 1972 to 1974 through 1975, as shown in Table 1.

It is likely that some units were not actively seeking faculty, but hired new faculty when exceptional persons appeared. For instance, in 1971 through 1972, the five larger programs stated that they were not actively seeking new faculty. Yet by 1974 through 1975 each of these five programs had added at least two new members, which is one more member per program than the overall average increase. Therefore, there is reason to believe that there is more real seeking for new faculty than has been expressed by the programs.

Number of New Full-Time Faculty Believed Needed in 1974 Through 1975

Those in charge of developing the dermatologic units were asked to state the number of new full-time faculty that they would be seeking if they had adequate funds (Table 4). They were urged not to inflate the number and to list only those who were really needed. The 136 units indicated that they needed 243 new faculty in 1974 through 1975. This compared with the need expressed by the 130 units for 221 in 1972 through 1973 and 264 in 1971 through 1972.

Type of Training Being Sought in New Full-Time Faculty

The types of training being sought in new faculty members by those in charge of developing dermatologic units, whether new or well established, are listed as follows:

Discipline	Times Requested
Immunology	169
Electron microscopy	99
Patient care	80
Histopathology	76
Microbiology	61
Anything faculty desires	55
Research, undifferentiated	38
Biochemistry	34
Teaching	27
Pediatric dermatology	11
Pharmacology	10
Surgery	10
Geriatric dermatology	9
Genetics	9
Oncology	8
Virology	5
Photobiology	5
Physiology	4
Molecular biology	4
Radiation	3
Mycology	3
Biophysics	3
Rehabilitation	2
Administration	2
Tissue culture	2
Cell biology	2
Contact dermatitis	2
Community dermatology	1
Syphilology	1
Industrial dermatology	1
Metabolism	1
Radioautography	1
Allergy	1
Pigmentation	1
Train paramedics	1
Endocrinology	1
Cytogenesis	1
Teenage dermatology	1
Train technicians	1
Teach in family practice	1
Histochemistry	1

Some of these areas could be combined, but we list them to indicate the diversity of the disciplines being sought in new faculty members. Obviously, training programs usually listed a number of areas that might be acceptable for a given new faculty person, since the number of acceptable disciplines far exceeds the number of new faculty being actively sought. This table is a composite of disciplines sought as shown by the three surveys.

COMMENT

The degree of shortage of full-time faculty in dermatology appears to be as great in 1974 through 1975 as it was in 1971 through 1972, despite the addition of 124 new faculty members in the four-year span. Obviously the demand for faculty has exceeded the supply to produce the chronic shortage. This increasing demand for new full-time faculty is related to several factors. New medical schools are being activated with a corresponding need to provide new dermatology faculty. Existing medical schools with no full-time faculty are beginning to appreciate the need for full-time faculty. A major factor is that existing dermatology teaching units, both in and outside of medical schools, are expanding to meet the greatly increased demands placed on them. These demands include the following: more teaching of medical students due to the greatly increased number of students (freshman enrollment has increased from 12,361 to 14,963, and total enrollment has increased from 43,650 to 54,074 from 1971 through 1972 to 1974 through 1975) and changing techniques of teaching these students; more teaching of nondermatologic residents, especially family medicine, medicine, and pediatrics, which is due to their increased numbers and their increasing appreciation of the need for dermatologic knowledge; more teaching of dermatology residents; more teaching of nondermatologist- and dermatologist-practicing physicians (partly as a result of continuing education requirements); greater involvement in patient care; more complicated research; more administrative duties in schools and hospitals; more involvement of dermatology in organized medicine at a national level. New activities are being added, such as

Table 3.—Number of New Full-Time Faculty Being Activity Sought*

Type of Unit*	1971-1972 No. of Units	1971-1972 No. Seeking Faculty	1971-1972 No. Faculty Sought	1972-1973 No. of Units	1972-1973 No. Seeking Faculty	1972-1973 No. Faculty Sought	1974-1975 No. of Units	1974-1975 No. Seeking Faculty	1974-1975 No. Faculty Sought
A	67	38	58	67	35	59	74	40	54
B	44	16	27	44	21	32	43	15	27
C	19	7	10	19	5	8	19	6	7
Total	**130**	**61**	**95**	**130**	**61**	**99**	**136**	**61**	**88**

*For explanation of symbols, see Table 1.

Table 4.—Number of New Full-Time Faculty Believed Needed*

Type of Unit*	1971-1972 No. of Units	1971-1972 No. Needing Faculty	1971-1972 No. Faculty Needed	1972-1973 No. of Units	1972-1973 No. Needing Faculty	1972-1973 No. Faculty Needed	1974-1975 No. of Units	1974-1975 No. Needing Faculty	1974-1975 No. Faculty Needed
A	67	66	152	67	56	139	74	66	149
B	44	37	87	44	35	63	43	30	71
C	19	14	25	19	11	19	19	15	23
Total	**130**	**117**	**264**	**130**	**102**	**221**	**136**	**111**	**243**

*For explanation of symbols, see Table 1.

training of allied health professionals, assistance in self-evaluation programs, and continuing education for practicing physicians. All indications are that the demand for new full-time faculty will increase, probably at a rapid rate.

One shortage area stands out above all others, namely, the complete absence of full-time faculty in 30 medical schools (29 without dermatology residency training programs and one with a dermatology residency training program). Three of these schools are two-year basic science schools, and two are in early phases of development, where a full-time dermatologist might not be essential; but the remainder are operational, and many have been in operation a long time. Although there may be notable exceptions in these schools, teaching of dermatology to medical students and primary care residents (pediatrics, medicine, family medicine, obstetrics, etc,) and continuing dermatologic education of primary care physicians is for the most part inadequately done; dermatological research is usually nonexistent; and there is little participation of dermatologists in the administrative affairs of the school or of the associated hospitals. Since dermatologic disease constitutes a significant portion, possibly 10% to 15% of the practice of primary care physicians, and since there is increasing emphasis on the training and continuing education of primary care physicians, it seems essential that dermatology be adequately taught in all medical schools. Some of the schools that place the greatest emphasis on training primary care physicians appear to be the weakest in terms of dermatology faculty and curriculum, which is paradoxical. It continues to be a real challenge to the specialty of dermatology to ensure that dermatology is adequately taught in all medical schools, but especially in those without full-time faculty, which we previously defined.

What is the possibility of relieving the shortage of full-time faculty in dermatology if our current rate of addition of 30 new faculty members per year to the total pool continues? At this rate it will take 2.93 years to acquire the 88 faculty that is currently being actively sought, and another 5.16 years to acquire the additional 155 that is considered needed. Unless the rate of training and recruiting new faculty is increased or the rate of loss is decreased, or both, there will remain a shortage of faculty for eight years or until 1982 through 1983, assuming that there is no further growth and expansion of faculty beyond the need perceived for 1974 through 1975. However, as discussed previously, the demand for new faculty will in all likelihood increase over the next eight years, so that we suspect that figures of need for faculty in 1983 will look like they do for 1974 through 1975. Even if the faculty being actively sought and the additional faculty considered needed can be recruited, the size of dermatologic faculties will still be small, ie, an average of five faculty members per unit, a figure that appears to be well below the critical mass to accomplish what these units should be doing. At least, in these days of concern about training too many specialists, dermatologic faculty appears to be one group in which there appears to be little danger of creating a surplus in the forseeable future.

For reasons presented in this communication, measures should be taken to increase the number of full-time faculty in dermatology. Further study should be done to determine if the shortage is due to too few academic dermatologists being trained or too many leaving academic dermatology after being trained, or a combination of these two. Efforts should be made to accept persons into training who have firm commitments to academic dermatology. Measures should be taken to make academic dermatology more attractive and more competitive with full-time practice and practice with part-time teaching.

One of the reasons for preparing this report in 1973 and again at this time was to inform prospective full-time academicians that many job opportunities exist. A registry or job clearinghouse has been established through the joint efforts of the American Academy of Dermatology (AAD) and the Association of Professors of Dermatology with the purpose of getting the job hunter and the job opportunity together. This joint effort has supported a booth at the annual AAD meeting for the past two years and has conducted questionnaire surveys to identify residents who are interested in academic positions. Potential academicians might contact the AAD office or Mark A. Everett,

MD, at the University of Oklahoma School of Medicine, who represents the Association of Professors of Dermatology in this effort. In addition to contacting this registry, we suggest that any would-be academician send a letter of inquiry and a curriculum vita to those units in which he might have an interest. The names and addresses of dermatologic training units may be obtained from the *1975-76 AAMC Directory of American Medical Education*,[6] the AMA *Directory of Approved Internships and Residencies 1974-75*,[7] and the secretary of the Association of Professors of Dermatology.

Another reason to prepare this report was to point out that program directors are looking for some area of expertise in new faculty members that they are trying to recruit. The would-be academician would do well to identify and pursue a special area early in his training so as to enhance his job opportunities later. The particular area of expertise is less important than that the prospective faculty member has such an area. However, having acquired no special area of expertise should not deter a dedicated, prospective full-time faculty member from searching for a position. At the present time immunology, electron microscopy, histopathology, microbiology, and biochemistry are the most popular special areas (Table 5). It is encouraging to note that patient care, any special area that the prospective faculty member desires, undifferentiated research, including clinical investigation and teaching, occupy equally high positions on the list.

The final reason to prepare this report in 1973 and again in 1976 was to point out that the shortage of full-time faculty constitutes an urgent problem that should be of primary concern to all dermatologists. As we wrote in 1973, the fountainhead of our specialty consists of the training of new dermatologists and of the acquisition of new knowledge of the skin and its diseases. These activities take place primarily, though not exclusively, in our schools and hospitals. Full-time faculty, as defined by us in previously, is required for dermatology to hold and enhance its position in schools and hospitals. It is in schools and hospitals that decisions are made concerning the position of dermatology in the curriculum; the amount of money, space, and equipment for teaching, research, and administration; and the amount of dermatology clinic and bed space for teaching purposes. It is also in schools and hospitals that practical decisions are made concerning which disease is to be cared for by what type of physician, ie, what the purview is of a given specialty. If the position of dermatology is lost in schools and hospitals, few dermatologists will be trained, and little research will be done. If the position of dermatology is lost in schools and hospitals, the specialty will lose its identity, and pressures will eventually arise to eliminate or restrict the specialty. If the position in schools and hospitals is lost, the specialty will wither and die, no matter how many patients are being seen in the offices of the dermatologists who have already been trained. The shortage of full-time faculty and maintenance of full-time faculty should therefore be a concern of all dermatologists, whether they are academically inclined or exclusively interested in private practice.

References

1. Wheeler CE Jr, Briggaman RA, Lynch PJ, et al: Shortage of full-time faculty in dermatology. *Arch Dermatol* 107:529-532, 1973.
2. Medical education in the United States 1971-1972. *JAMA* 222:961-1048, 1972.
3. Medical education in the United States 1972-1973. *JAMA* 226:893-989, 1973.
4. Medical education in the United States 1973-1974. *JAMA* 231 (suppl):1-139, 1975.
5. Medical education in the United States 1974-1975. *JAMA* 234:1325-1432, 1975.
6. Wilson VL (ed): *1975-1976 AAMC Directory of Medical Education*. Washington, DC, Association of American Medical Colleges, 1975.
7. *Directory of Approved Residencies 1974-75*. Chicago, American Medical Association, 1975.

Gastrointestinal Absorption of Griseofulvin From Corn Oil-in-Water Emulsions

Effect of Amount of Corn Oil Ingested in Man

Theodore R. Bates, PhD; Henry J. Pieniaszek, Jr; Joel A. L. Sequeira; James E. Rasmussen, MD

• The effect of the amount of emulsified corn oil ingested on the gastrointestinal absorption of griseofulvin in man was assessed after oral administration of 5, 10, 15, or 30 gm doses of a corn oil (40% w/w)-in-water emulsion dosage form, each containing 250 mg of microsize griseofulvin. For comparison, griseofulvin absorption from two-125 mg commercial tablets of ultramicrosize drug dispersed in polyethylene glycol 6,000 was also determined. Griseofulvin was almost completely absorbed from the microsize drug emulsions and ultramicrosize drug tablets, whereas 50% of an oral dose is absorbed from commercial microsize griseofulvin tablets. Only 4 gm of emulsified corn oil (as a 10-gm dose of emulsion) is required to maximize the uniformity and extent of griseofulvin absorption. The emulsion dosage form is uniquely suited for pediatric use.

(*Arch Dermatol* 113:302-306, 1977)

Griseofulvin, a systemic antifungal antibiotic with limited aqueous solubility (15 mg/liter at 37 C), is slowly and incompletely absorbed in man after oral administration of microsize drug as an aqueous suspension[1,2] or as commercial tablet dosage forms.[2-4] The average amount absorbed from these dosage forms is approximately 50% of the dose. These poor absorption characteristics are thought to account for the lack of clinical response of some patients treated with conventional dosage forms of microsize griseofulvin.[5-7]

Crounse[6] demonstrated that in man, oral administration of microsize griseofulvin (1 gm dose) with a high fat meal (bacon, eggs, cream, and butter)[5] results in increased gastrointestinal absorption of this antibiotic as reflected by increased four and eight hour serum concentrations. The lack of information on the actual lipid content of the meal (assumed to be considerably more than 60 gm) precludes proper utilization of this finding by clinicians since the degree of potentiation of griseofulvin absorption is a function of the amount of coingested dietary fat.[5,6] This approach to enhancing the absorption of microsize griseofulvin is also limited by patient compliance and the necessity of maintaining patients on high lipid diets for extended periods of time.

Previous studies in this laboratory[2] indicated that oral administration of microsize griseofulvin (500 mg dose) dispersed in a corn oil-in-water emulsion dosage form vehicle can result in a twofold enhancement in the amount of griseofulvin absorbed in man as compared to administration of the antibiotic in an aqueous suspension vehicle or in commercial tablet dosage forms. Twelve grams of corn oil, in an emulsified form, was used to produce this maximal increase in griseofulvin absorption. It would be highly desirable if the amount of emulsified corn oil coingested with griseofulvin could be further reduced.

The present bioavailability study was designed to assess the effect of the amount of emulsified corn oil ingested with a 250 mg oral dose of microsize griseofulvin on drug absorption and to compare the oral absorption of the microsize griseofulvin corn oil-in-water emulsion with that of commercial ultramicrosize griseofulvin tablets (Gris-PEG). The latter formulation, which contains ultramicrosize griseofulvin dispersed in polyethylene glycol (PEG) 6,000, has also been reported to be twice as available as commercial tablets of microsize griseofulvin.[8,9]

SUBJECTS AND METHODS

Dosage Forms

Ultramicrosize griseofulvin tablets *125*

Table 1.—Treatment Schedule

Subject No. (Age, yr; Weight, kg)	Treatments for Week No. 1	2	3	4
1 (23; 73)	A	B	C	D
2 (25; 87)	B	C	D	A
3 (24; 84)	C	D	A	B
4 (24; 70)	D	A	B	C

Accepted for publication June 21, 1976.

From the Department of Pharmaceutics, School of Pharmacy (Dr Bates and Mr Pieniaszek and Sequeira), and the Department of Dermatology, School of Medicine (Dr Rasmussen), State University of New York at Buffalo.

Reprint requests to Department of Pharmaceutics, State University of New York at Buffalo, Buffalo, NY 14214 (Dr Bates).

Table 2.—Mean Urinary pH as a Function of Time After a 250 mg Oral Dose of Griseofulvin in Tablet and Emulsion Dosage Forms

Collection Interval, hr	Mean Urinary pH (n = 4) ± SEM*					
	Ultramicrosize Griseofulvin, 2 Tablets	Corn Oil-in-Water Emulsion, 30 gm	Corn Oil-in-Water Emulsion, 15 gm	Corn Oil-in-Water Emulsion, 10 gm	Corn Oil-in-Water Emulsion, 5 gm	Level of Significance†
0-2	5.89 ± 0.41	5.78 ± 0.19	5.41 ± 0.13	6.11 ± 0.30	5.99 ± 0.31	NS‡
2-4	5.96 ± 0.40	6.14 ± 0.34	5.39 ± 0.17	6.49 ± 0.44	6.45 ± 0.39	NS
4-6	5.94 ± 0.28	5.85 ± 0.23	5.49 ± 0.20	6.33 ± 0.29	6.02 ± 0.34	NS
6-8	5.78 ± 0.18	5.83 ± 0.15	5.72 ± 0.23	6.15 ± 0.44	5.64 ± 0.11	NS
8-12	6.29 ± 0.39	5.76 ± 0.24	5.90 ± 0.24	5.78 ± 0.31	5.75 ± 0.28	NS
12-24	5.79 ± 0.31	5.50 ± 0.09	5.63 ± 0.08	5.64 ± 0.13	5.74 ± 0.22	NS
24-48	5.89 ± 0.15	5.74 ± 0.16	5.95 ± 0.23	5.97 ± 0.11	6.23 ± 0.20	NS
48-72	5.66 ± 0.12	5.94 ± 0.25	5.91 ± 0.13	5.89 ± 0.10	6.36 ± 0.10	NS ($P > .05$)
72-96	6.01 ± 0.15	5.93 ± 0.17	6.03 ± 0.17	6.19 ± 0.09	6.28 ± 0.03	NS

*SEM indicates standard error of the mean.
†Analysis of variance.
‡NS indicates not significant ($P > .01$).

Table 3.—Mean Cumulative Urinary Excretion of Total 6-Desmethylgriseofulvin as a Function of Time After a 250-mg Oral Dose of Griseofulvin in Tablet and Emulsion Dosage Forms

Time, hr	Mean Cumulative Excretion of Total 6-Desmethylgriseofulvin, mg (n = 4) ± SEM*				
	Ultramicrosize Griseofulvin, 2 Tablets	Corn Oil-in-Water Emulsion, 30 gm	Corn Oil-in-Water Emulsion, 15 gm	Corn Oil-in-Water Emulsion, 10 gm	Level of Significance†
2	15.30 ± 5.58	15.58 ± 5.20	13.46 ± 2.32	12.31 ± 0.694	NS‡
4	34.02 ± 11.1	38.57 ± 9.61	35.58 ± 3.71	33.22 ± 1.18	NS
6	48.74 ± 13.6	56.31 ± 11.8	51.83 ± 5.93	48.06 ± 2.00	NS
8	60.37 ± 15.5	69.71 ± 13.3	64.18 ± 7.65	59.27 ± 2.28	NS
12	82.88 ± 17.8	90.70 ± 15.1	84.40 ± 10.3	75.65 ± 5.16	NS
24	129.5 ± 18.7	133.5 ± 14.7	130.8 ± 13.6	115.6 ± 7.55	NS
48	170.6 ± 15.0	175.5 ± 9.31	176.6 ± 11.5	160.6 ± 8.57	NS
72	181.4 ± 14.3	186.1 ± 7.37	192.5 ± 12.4	173.6 ± 9.13	NS
96	183.6 ± 14.5	198.2 ± 7.99	196.7 ± 13.0	176.6 ± 8.56	NS

*SEM indicates standard error of the mean.
†Based on treatment mean square from the analysis of variance for crossover (latin square) design.
‡NS indicates not significant ($P > .1$).

Table 4.—Maximum Excretion Rate of Total 6-Desmethylgriseofulvin After Oral Administration of a 250 mg Dose of Griseofulvin in Tablet and Emulsion Dosage Forms

Subject	Maximum Excretion Rate of Total 6-Desmethylgriseofulvin, mg/hr			
	Ultramicrosize Griseofulvin, 2 Tablets	Corn Oil-in-Water Emulsion, 30 gm	Corn Oil-in-Water Emulsion, 15 gm	Corn Oil-in-Water Emulsion, 10 gm
1	15.5 (3)*	17.3 (3)	12.6 (3)	9.68 (3)
2	14.3 (1)	10.9 (3)	10.6 (3)	9.58 (3)
3	6.89 (5)	11.2 (3)	6.75 (3)	9.86 (3)
4	4.92 (7)	6.51 (3)	14.3 (3)	12.7 (3)
Mean	10.4	11.5	11.1	10.5
SEM†	2.6	2.2	1.6	0.75
CV (%)‡	50.7	38.6	29.4	14.4
Statistical Significance—Analysis of Variance for Crossover (Latin Square) Design Differences among four dosage forms: NS§ ($P > .1$) F‖ = 0.0918; df = 3,6				

*Time of occurrence of maximum excretion rate (hr) in parentheses.
†SEM indicates standard error of the mean.
‡CV (%), coefficient of variation (percent).
§NS, not significant.
‖Critical F value for 3 and 6 df at the 10% level is 3.29.

mg, were purchased on the open market.

Corn oil-in-water emulsions, containing 250 mg of dispersed microsize griseofulvin per 5, 10, 15, and 30 gm of emulsion, were prepared as described previously.[10] These amounts of corn oil-in-water emulsion correspond to 2, 4, 6, and 12 gm of emulsified corn oil, respectively.

Prior to use, all dosage forms were assayed in triplicate for drug content by the spectrophotometric method described earlier.[10]

Absorption Studies

A four-way crossover study (latin square design) was performed on four healthy, nonobese, male volunteers between the ages of 23 and 25 years and weighing between 70 and 87 kg. Informed consent was obtained after the nature of the procedures had been fully explained. The criteria for subject selection included a routine physical examination, urinalysis,

UNIVERSITY OF MEDICINE LIBRARY

and blood chemistries. The subjects were instructed not to consume any drugs or alcoholic beverages for seven days prior to, and for four days following griseofulvin administration.

In each phase of the crossover study, a single 250 mg oral dose of griseofulvin was administered at 8 AM to each subject after an overnight fast (at least eight hours) as two-125 mg ultramicrosize griseofulvin tablets with 100 ml of water (treatment A), as 30 gm of corn oil-in-water emulsion with 70 ml of water (treatment B), as 15 gm of corn oil-in-water emulsion with 85 ml of water (treatment C), and as 10 gm of corn oil-in-water emulsion with 90 ml of water (treatment D). The treatments were administered according to the schedule shown in Table 1 and were separated by a one-week "wash-out" period. At the end of the fourth treatment week, the same four subjects ingested a 250 mg dose of microsize griseofulvin as 5 gm of corn oil-in-water emulsion with 95 ml of water.

Urine was collected from each subject immediately prior to drug administration (time zero) and at 2, 4, 6, 8, 12, 48, 72, and 96 hours after drug administration. The pH and volume of each specimen was recorded, and an aliquot was stored in the frozen state until assayed in duplicate for 6-desmethylgriseofulvin content. No food was permitted until four hours after drug administration.

Free 6-desmethylgriseofulvin in the urine was determined by a double extraction, differential spectrophotometric method.[11] Total 6-desmethylgriseofulvin (free and the glucuronide conjugate) was assayed by the same procedure after incubating an aliquot of the urine specimens with 500 units of β-glucuronidase (bacterial-type II, Sigma Chemical Co, St. Louis) for two hours at pH 6.8 and 37 C.[2]

RESULTS

It is well established that the rate and extent of absorption (bioavailability) of griseofulvin in man can be determined from urinary excretion data for the major metabolite 6-desmethylgriseofulvin and its glucuronide conjugate.[1,2,4,9,12,13]

No statistical difference (analysis of variance) in urine pH was found to exist among the five study conditions at any collection period examined (Table 2). Thus, differences noted in the amounts of total 6-desmethylgriseofulvin excreted in the urine accurately reflect differences in the bioavailability of griseofulvin.

The cumulative amounts of total 6-desmethylgriseofulvin excreted in the urine as a function of time after oral administration of the ultramicrosize griseofulvin tablets and 10, 15, and 30 gm of corn oil in-water emulsions are listed in Table 3. Excretion of total 6-desmethylgriseofulvin was completed within 72 hours after administration of griseofulvin under each of the four study conditions, indicating that 96 hours was more than adequate to assess the bioavailability of griseofulvin.

Total 6-desmethylgriseofulvin excretion rate profiles, which reflect the time course of griseofulvin concentrations in the plasma,[1,4] were quite similar after administration of the ultramicrosize griseofulvin tablets and 10, 20, and 30 gm of the corn oil-in-water emulsion formulations (Figure). No substantial differences existed among the four formulations

Table 5.—Bioavailability of Griseofulvin After Oral Administration of a 250 mg Dose of the Antibiotic in Tablet and Emulsion Dosage Forms

	Cumulative Amount of Total 6-Desmethylgriseofulvin Excreted in 96 Hours (Percent of Dose)			
Subject	Ultramicrosize Griseofulvin, 2 Tablets	Corn Oil-in-Water Emulsion, 30 gm	Corn Oil-in-Water Emulsion, 15 gm	Corn Oil-in-Water Emulsion, 10 gm
1	82.48	81.68	82.12	75.28
2	80.04	70.84	68.24	64.68
3	56.72	78.64	72.68	64.84
4	74.48	86.00	91.68	77.72
Mean	73.43	79.29	78.68	70.63
SEM*	5.82	3.20	5.21	3.43
CV (%)†	15.8	8.06	13.2	9.70
Statistical Significance—Analysis of Variance for Crossover (Latin Square) Design Differences among four dosage forms: NS‡ ($P > .1$) F§ = 1.355; df = 3,6				

*SEM indicates standard error of the mean.
†CV (%), coefficient of variation (percent).
‡NS, not significant.
§Critical F value for 3 and 6 df at the 10% level is 3.29.

Table 6.—Fraction of Total 6-Desmethylgriseofulvin Ultimately Excreted in Urine as Free 6-Desmethylgriseofulvin After a 250-mg Oral Dose of Griseofulvin in Tablet and Emulsion Dosage Forms

Subject	Ultramicrosize Griseofulvin, 2 Tablets	Corn Oil-in-Water Emulsion, 30 gm	Corn Oil-in-Water Emulsion, 15 gm	Corn Oil-in-Water Emulsion, 10 gm	Corn Oil-in-Water Emulsion, 5 gm
1	0.60	0.61	0.55	0.55	0.58
2	0.51	0.51	0.50	0.49	0.60
3	0.71	0.71	0.68	0.71	0.67
4	0.54	0.46	0.53	0.63	0.66
Mean	0.59	0.57	0.57	0.60	0.63
SEM*	0.04	0.06	0.04	0.05	0.02
CV (%)†	15	19	14	16	7.1
Statistical Significance—Analysis of Variance Differences among five dosage forms: NS‡ ($P > .1$) F§ = 0.315; df = 4, 15					

*SEM indicates standard error of the mean.
†CV (%), coefficient of variation (percent).
‡NS, not significant.
§Critical F value for 4 and 15 df at the 10% level is 2.36.

with respect to the mean maximum excretion rate of total 6-desmethylgriseofulvin (Table 4), suggesting that comparable maximum body levels of griseofulvin were attained after their administration. The maximum excretion rate of total 6-desmethylgriseofulvin consistently occurred three hours after administration of either 10, 20, or 30 gm of corn oil-in-water emulsion whereas, the time of occurrence of the maximum excretion rate varied from one to seven hours after administration of the ultramicrosize griseofulvin tablets (Table 4).

The cumulative amounts of total 6-desmethylgriseofulvin ultimately excreted in the urine for each subject after each formulation, expressed as percent of the oral dose of griseofulvin, are listed in Table 5. Statistical analysis of these data indicated no significant differences among the ultramicrosize griseofulvin tablets, and the 10, 20, and 30 gm corn oil-in-water emulsion formulations. Free and conjugated 6-desmethylgriseofulvin together account for approximately 84% (mean of five subjects) of all of the urinary metabolites of griseofulvin in man.[1] A comparison of this average maximum value with the average 96-hour excretion values reported in Table 5 suggests that almost all of the 250 mg oral dose was absorbed from the commercial ultramicrosize griseofulvin tablets and the microsize griseofulvin corn oil-in-water emulsions. The bioavailability of griseofulvin from these formulations is approximately *twice* that found from microsize griseofulvin tablets currently in clinical use.[2-7] In addition, the administration of corn oil caused no statistically significant change in the fraction of total 6-desmethylgriseofulvin ultimately excreted in the urine as free 6-desmethylgriseofulvin (Table 6). The mean fractions calculated for the corn oil-in-water emulsion formulations and the ultramicrosize griseofulvin tablet (Table 6) were comparable to literature values.[1-4]

COMMENT

The improved absorption of griseofulvin after administration of the ultramicrosize griseofulvin tablets or

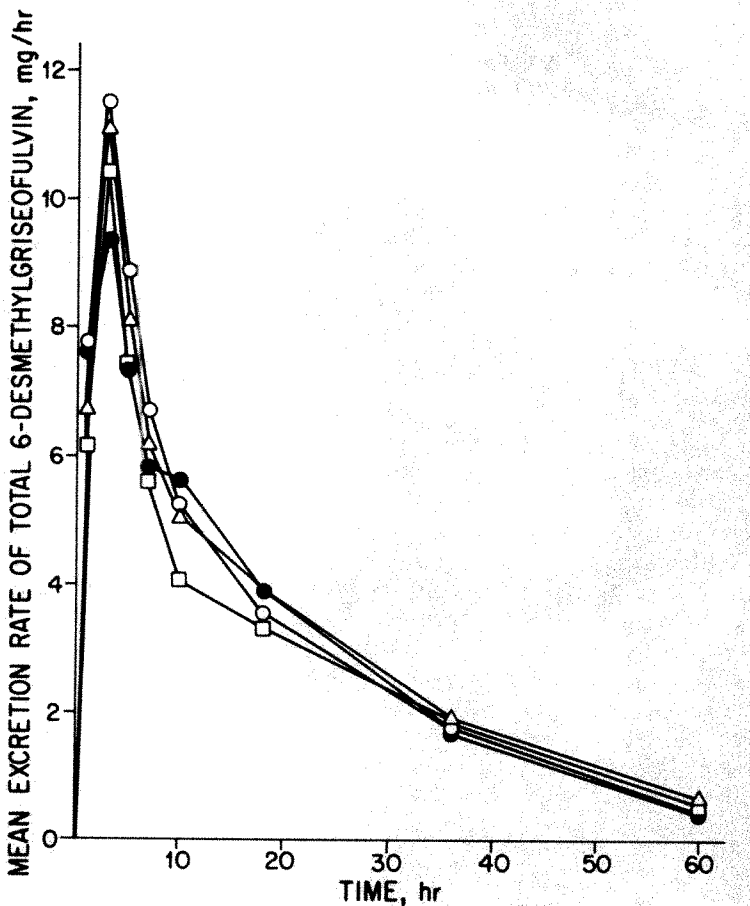

Excretion rate of total 6-desmethylgriseofulvin as a function of time after a 250 mg oral dose of griseofulvin as ultramicrosize griseofulvin tablets (closed circles), as a corn oil-in-water emulsion, 30 gm (open circles), as a corn oil-in-water emulsion, 15 gm (triangles), and as a corn oil-in-water emulsion, 10 gm (squares). Each point represents mean of four fasting subjects.

Table 7.—Maximum Excretion Rate and Cumulative Urinary Excretion of Total 6-Desmethylgriseofulvin (6-DMG) After Oral Administration of a 250-mg Dose of Griseofulvin as 5 gm of Corn Oil-in-Water Emulsion

Subject	Maximum Excretion Rate of Total 6-DMG, mg/hr	Cumulative Amount of Total 6-DMG Excreted in Urine in 96 hr, % of Dose
1	12.2 (3)*	69.20
2	5.41 (3)	48.00
3	7.78 (3)	63.67
4	10.2 (3)	76.93
Mean	8.89	64.45
SEM†	1.5	6.12
CV (%)‡	31.4	19.0

*Time of occurrence of maximum excretion rate (hr) in parentheses.
†SEM indicates standard error of the mean.
‡CV (%), coefficient of variation (percent).

the corn oil-in-water emulsions is produced by different mechanisms. In the case of the tablet formulation, the increased absorption is thought to be due to the presence of ultramicrosize griseofulvin particles (as a dispersion in the water soluble carrier, polyethylene glycol 6,000) which, because of their greater surface area, dissolve at rates appreciably more rapid than those of the microsize griseofulvin particles contained in conventional tablets.[1,8,9] The particle size fraction of griseofulvin (microsize) in the corn oil emulsion formulation is the same as that used in commercial tablets. Hence, the enhanced absorption of griseofulvin from the corn oil-in-water emulsion is probably due to the ability of emulsified lipid (corn oil) to inhibit gastrointestinal motility and to stimulate gallbladder evacuation.[2] Bates and Sequeira[2] have proposed that the inhibitory effect of emulsified corn oil on gastric emptying results in a slow transfer of undissolved griseofulvin into the small intestine. The smaller amounts of drug present in the proximal intestine at any particular time after oral administration of the corn oil emulsion, coupled with the inhibitory effect of lipid and/or the fatty acids liberated during its digestion on intestinal motility, allows the drug more time to dissolve in the region of the small intestine where absorption is believed to be optimal. The presence of emulsified corn oil and/or its digestion products (oleic and linoleic acids) in the intestine also stimulates the evacuation of bile from the gallbladder, which increases the dissolution rate of this poorly soluble antibiotic.[2]

Dose-response relationships have been demonstrated for the effects of ingested lipid or long chain fatty acid on gastrointestinal motility[14,15] and gallbladder evacuation[16] in man. A similar relationship may exist between the amount of corn oil ingested and the bioavailability of griseofulvin at emulsion doses of less than 10 gm. In fact, as noted in Table 5, all subjects absorbed slightly less of the 250 mg dose of antibiotic when it was administered with 4 gm of emulsified corn oil as 10 gm of corn oil-in-water emulsion than when either 6 gm (15 gm of corn oil-in-water emulsion) or 12 gm (30 gm of corn oil-in-water emulsion) of emulsified lipid was ingested with the antibiotic.

This observation prompted an additional absorption study in which the same four subjects received a 250 mg dose of microsize griseofulvin as 5 gm of corn oil-in-water emulsion, an amount equivalent to 2 gm of emulsified corn oil. The results of this experiment are summarized in Table 7. Paired *t*-tests reveal that no significant differences in either the maximum excretion rate of total 6-desmethylgriseofulvin or in its time of occurrence exist between the 5 gm dose of corn oil-in-water emulsion and either the 10, 15, or 30 gm dose of corn oil-in-water emulsion (Tables 4 and 7). However, the bioavailability of microsize griseofulvin was significantly lower after administration of 5 gm of corn oil-in-water emulsion than after administration of either 15 gm ($P < .01$) or 30 gm ($P < .02$) of corn oil-in-water emulsion (Tables 5 and 7). Even though the absorption of griseofulvin from 5 gm of corn oil-in-water emulsion was not optimal, the absorption-enhancing effect of emulsified corn oil was still evident. The bioavailability of griseofulvin was reduced, on the average, by less than 20% when ingested with only 2 gm of emulsified corn oil (Tables 5 and 7).

The results of this investigation indicate that the bioavailability of griseofulvin can be maximally enhanced upon its administration to man with as little as 4 gm of emulsified, unsaturated lipid in the form of a corn oil-in-water emulsion formulation. Also, unlike the solid dosage forms (tablets and capsules) of griseofulvin currently in clinical use, the emulsion dosage form affords the greatest uniformity in drug absorption, is uniquely suited for pediatric use, and allows for facile dosage adjustments.

This investigation was supported in part by a grant-in-aid from Westwood Pharmaceuticals, Inc, Buffalo, NY.

Nonproprietary Name and Trademarks of Drug

Griseofulvin—*Fulvicin, Fulvicin V/F, Grifulvin, Grifulvin V, Grisactin, Grisowen, Gris-PEG.*

References

1. Lin CC, Magat J, Chang R, et al: Absorption, metabolism and excretion of ^{14}C-griseofulvin in man. *J Pharmacol Exp Ther* 187:415-422, 1973.
2. Bates TR, Sequeira JA: Bioavailability of micronized griseofulvin from corn oil-in-water emulsion, aqueous suspension, and commercial tablet dosage forms in humans. *J Pharm Sci* 64:793-797, 1975.
3. Rowland M, Riegelman S, Epstein WL: Absorption kinetics of griseofulvin in man. *J Pharm Sci* 57:984-989, 1968.
4. Chiou WL, Riegelman S: Absorption characteristics of solid dispersed and micronized griseofulvin in man. *J Pharm Sci* 60:1376-1380, 1971.
5. Crounse RG: Human pharmacology of griseofulvin: The effect of fat intake on gastrointestinal absorption. *J Invest Dermatol* 37:529-533, 1961.
6. Crounse RG: Effective use of griseofulvin. *Arch Dermatol* 87:176-178, 1963.
7. Kraml M, Dubuc J, Dvornik D: Gastrointestinal absorption of griseofulvin. *Arch Dermatol* 87:179-182, 1963.
8. Barrett WE, Bianchine JR: The bioavailability of ultramicrosize griseofulvin (Gris-PEG) tablets in man. *Curr Ther Res* 18:501-509, 1975.
9. Barrett WE, Hanigan JJ: The bioavailability of griseofulvin-PEG ultramicrosize (Gris-PEG) tablets in man under steady state conditions. *Curr Ther Res* 18:491-500, 1975.
10. Carrigan PJ, Bates TR: Biopharmaceutics of drugs administered in lipid-containing dosage forms: I. GI absorption of griseofulvin from an oil-in-water emulsion in the rat. *J Pharm Sci* 62:1476-1479, 1973.
11. Rowland M, Riegelman S: Determination of 6-desmethylgriseofulvin in urine. *J Pharm Sci* 62:2030-2032, 1973.
12. Kabasakalian P, Katz M, Rosenkrantz B, et al: Parameters affecting absorption of griseofulvin in a human subject using urinary metabolite excretion data. *J Pharm Sci* 59:595-600, 1970.
13. Riegelman S, Rowland M, Epstein WL: Griseofulvin-phenobarbital interaction in man. *JAMA* 213:426-431, 1970.
14. Card WI: A comparison of the inhibitory action of different fats and fatty acids introduced into the duodenum on gastric contractions. *Am J Dig Dis* 8:47-53, 1941.
15. Hunt JN, Knox MT: A relation between the chain length of fatty acids and the slowing of gastric emptying. *J Physiol* 194:327-336, 1968.
16. Ivy AC: Physiology of the gall bladder. *Physiol Rev* 14:1-102, 1934.

Superficial Mycoses

Treatment With a New, Broad-Spectrum Antifungal Agent: 1% Clotrimazole Solution

Nardo Zaias, MD, Francisco Battistini, MD

• A 1% clotrimazole solution was used as an antifungal for Tinea versicolor, Cutaneous Candidiasis and Dermatophytosis. All studies were double-blind and controlled, active vs vehicle. The final evaluation was made at a two-week follow-up after the treatment was stopped, which for most of the clinical conditions studied, was 28 days. The 1% clotrimazole solution was found to be effective with no local irritation noted.

(*Arch Dermatol* 113:307-308, 1977)

In 1958,[1] Gentles introduced griseofulvin as an antifungal agent that produced systemic effects. Many investigators followed Gentles obvious hint, and after 18 years of human use experience, griseofulvin is still the best and safest antidermatophytic agent producing systemic effects. The unique antifungal specificity demonstrated by griseofulvin against dermatophytic fungi in 1958, a breakthrough for the time, is now in 1976, its Achilles' heel. From 1962 to 1963, thiabendazole, a substituted benzimidazole, enjoyed the unique characteristic of being both safe and a superb antidermatophytic agent applied topically; it was, however, never used as such until 1974.[2] The era of the substituted imidazole led to the realization that one drug could be effective against various types of fungi and yeasts. The intent of this study is to present data on clotrimazole, a new, broad-spectrum antimycotic agent.[3]

TINEA VERSICOLOR

Protocol

Patients were enrolled in this study if their direct microscopic examinations revealed the typical spores and hyphae of Pityrosporum furfur. Either strip-tape, or microscopic slide method was used. The patients were treated twice daily for only 14 days. At end of treatment, they were again examined clinically and microscopically for traces of the fungus. The last follow-up examination was done 14 days after medication was stopped.

Results

The Table presents the data from a double-blind study on the efficacy after 14 days treatment and after 14 days follow-up posttreatment. Clotrimazole was 86% effective vs 52% vehicle effectiveness.

CUTANEOUS CANDIDIASIS

Cutaneous candidiasis is an opportunistic infection on the surface of the skin. Its source, the gastrointestinal tract, supplies the protagonist in quantities that are dispersed over the body surface. In the intertrigenous area of the skin, the yeast thrives, yet

Patients Clinically and Mycologically Cured at End of 14-Day Posttreatment Follow-up*

	1% Clotrimazole Lotion	Polyethylene Glycol 400 Vehicle
Tinea versicolor (68 patients)	30/35, 86%	17/33, 52%
Cutaneous candidiasis due to *C albicans* (99 patients)	49/56, 88%	14/43, 33%
Tinea cruris or corporis (73 patients)	33/34, 97%	6/39, 15%
Tinea pedis (33 patients)	12/16, 75%	7/17, 35%

*Double-blind studies.

Fig 1.—Cutaneous candidiasis of the penis.

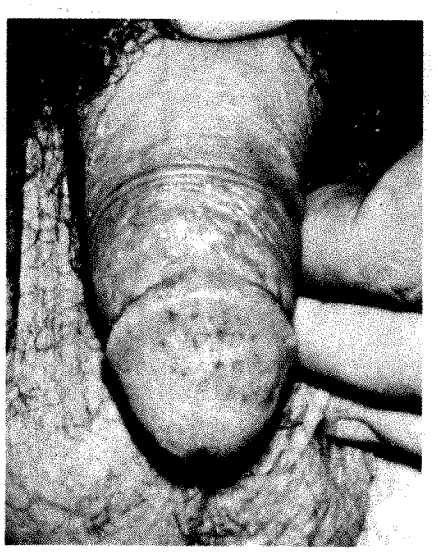

Fig 2.—Patient after two-week posttreatment follow-up. Treatment four weeks.

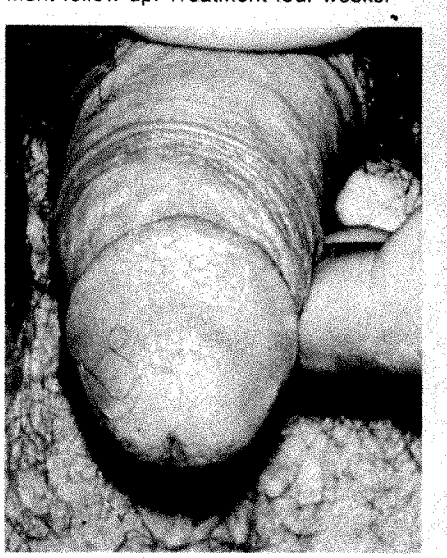

Accepted for publication May 19, 1976.

From the Department of Dermatology, Mount Sinai Medical Center, Miami (Dr Zaias) and the Department of Dermatology, Universidad de Oriente, Ciudad Bolivar, Venezuela (Dr Battistini).

Reprint requests to Suite 402—Abbey Bldg, 960 Arthur Godfrey Rd, Miami Beach, FL 33140 (Dr Zaias).

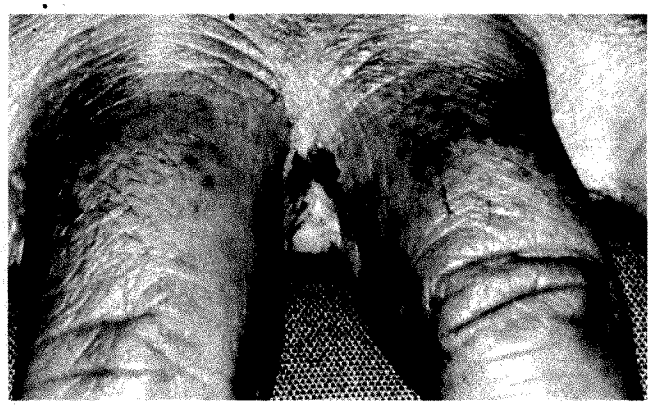

Fig 3.—Cutaneous candidiasis.

Fig 4.—Patient after two-week posttreatment follow-up. Treatment four weeks.

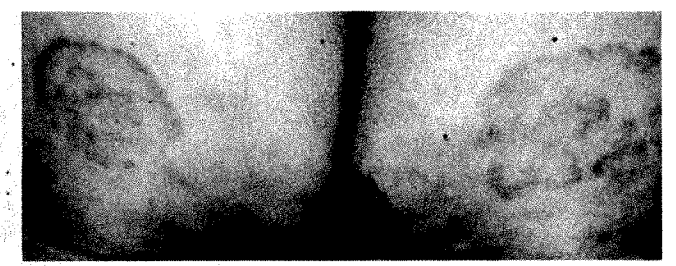

Fig 5.—Tinea corporis by Trichophyton rubrum.

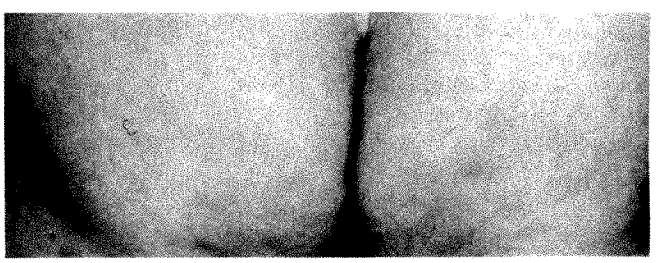

Fig 6.—Patient after two-week posttreatment follow-up. Treatment four weeks.

normally is kept under control by the antimicrobial environment, as well as host factors. When the delicate balance is upset, the organism thrives and replicates in great numbers, and the clinical lesions result.

Protocol

Patients with clinical candidiasis were enrolled in this study. Pretreatment cultures and direct microscopic confirmation of candidiasis (Gram smear or KOH preparation) were performed. Only patients with germ tube producers *(Candida albicans)* were entered into this study. The patients were treated for 28 days and again examined and cultured. After 14 days following the cessation of treatment, the patients were again examined clinically and mycologically.

Results

The Table shows the results of the double-blind study of 1% clotrimazole vs placebo vehicle. Clotrimazole lotion has effectively cured (Fig 1 through 4), clinically and mycologically, 88% of patients treated as compared to 33% cured in the placebo group.

TINEA CORPORIS—TINEA CRURIS DERMATOPHYTOSIS

Protocol

Patients suspected of having tinea corporis or tinea cruris, clinically, were entered in the study after demonstration of a hyphal element by direct microscopy. To remain in the study, cultures had to be positive for a dermatophyte. Patients were treated for 28 days at the end of treatment period, and were examined again clinically and mycologically (Fig 5 and 6). Final clinical and mycological examination was done at 14 days posttreatment.

Results

The Table shows clotrimazole to be 97% effective vs 15% cure in vehicle group.

TINEA PEDIS

Protocol

Patients suspected of having tinea pedis were studied. A pretreatment clinical, mycological culture and direct microscopic examination were performed prior to inclusion into the study. Patients were treated for 28 days and again clinically and mycologically studied. The final clinical and mycologic study was done 14 days after cessation of treatment.

Results

The Table shows the 75% of patients using 1% clotrimazole were determined as cured clinically and mycologically 14 days after treatment was stopped, as compared to 35% cured by vehicle.

This investigation was done in cooperation with "the treatment of superficial mycoses cooperative study group": Humberto Bogaert, MD, Antonio Coiscu, MD, and Rosa Rojas, MD, Santo Domingo, Dominican Republic; Fabio Londono, MD, Bogota, Colombia; Guillermo Ortiz, MD, San Juan, Puerto Rico; and Alvaro Vivas, MD, and Jorge Zavala, MD, Merida, Yucatan, Mexico.

Nonproprietary Name and Trademark of Drug

Clotrimazole—*Lotrimin.*

References

1. Gentles JC: Experimental ringworm in guinea pigs: Oral treatment with griseofulvin. *Nature* 182:476, 1958.
2. Battistini F, Zaias N, Rebell G: Clinical antifungal activity of thiabendazole. *Arch Dermatol* 109:695-699, 1974.
3. Plempel M, Bartmann K, Buchel KH, et al: Antimycotic properties of clotrimazole. *Postgrad Med J* 50(suppl 1):11-12, 1974.

Serum IgE in Dermatitis and Dermatosis

An Analysis of 497 Cases

Sean O'Loughlin, MD; Jose L. Diaz-Perez, MD; Gerald J. Gleich, MD; R. K. Winkelmann, MD, PhD

• Serum IgE values from 497 patients with various forms of dermatitis, dermatosis, and tinea pedis were analyzed statistically and compared with values from 95 normal controls. The median and geometric mean values were significantly elevated (except in acne without atopy, lichen planus, and tinea pedis), even after exclusion of patients with a history of atopy or of cutaneous reaction to food or drugs. Serum IgE levels and atopic dermatitis have a close correlation. A modest positive correlation ($p \cong .05$) appeared between the log serum IgE level and peripheral blood absolute eosinophil count in 80 cases of atopic dermatitis. A unique group of adult nonatopic patients had acquired generalized dermatitis and markedly elevated serum IgE levels (> 12,000 ng/ml). Our results suggest that, in most common dermatologic disorders, elevated serum IgE is a secondary phenomenon rather than a primary causative factor.

(*Arch Dermatol* 113:309-315, 1977)

The discovery of IgE[1-4] and the development of radioimmunoassay techniques for IgE estimation[5-7] were major stimuli to the investigation of allergic diseases. Although serum IgE concentrations are low in normal health, they are high in atopic dermatitis,[8-14] asthma and allergic rhinitis,[7,15-18] and parasitic disorders.[19-21] Serum IgE levels in dermatologic conditions other than atopic dermatitis usually have been reported as normal,[8,10,12,13,22,23] but many of these reports were based on very few cases.

We have analyzed serum IgE levels in 497 Mayo Clinic patients who had various forms of dermatitis, common dermatoses, or tinea pedis. The results indicate that serum IgE is frequently elevated in dermatologic diseases.

Accepted for publication July 29, 1976.

From the Mayo Clinic and Mayo Foundation, Rochester, Minn.

Reprint requests to Section of Publications, Mayo Clinic, 200 First St SW, Rochester, MN 55901 (Dr O'Loughlin).

MATERIAL AND METHODS

Subjects

The controls were 95 normal nonatopic subjects. The 497 dermatology patients were divided into three clinical groups: dermatitis, dermatosis—both with nosologic subdivisions—and tinea pedis (Tables 1 and 2).

All diagnoses were made by experienced dermatologists at the Mayo Clinic.

Dermatitis

Atopic Dermatitis.—These patients had classic pruritic, acute and chronic, lichenified dermatitis that involved particularly the flexural areas. Most of the patients had had infantile eczema or gave a family history of atopic disease. Many had other markers of atopy such as previous or current allergic respiratory disease.

Neurodermatitis.—This localized or generalized, pruritic, lichenified dermatitis reaction occurred, usually in mid or late life, without current or previous atopy. The patients responded negatively to intradermal allergic and methacholine (Mecholyl) skin tests. Patch testing, performed in 31 cases, gave negative results. Ten patients were distinctive clinically in that they had marked prurigo nodularis lesions— intensely pruritic, hard, globular nodules of a chronic nature, often symmetrically distributed and widely spaced, and occurring particularly on the limbs.

Contact Dermatitis.—In these patients, a delayed hypersensitivity reaction caused dermatitis after exposure to contact allergens or compounds to which they had become sensitized. The diagnosis was confirmed by patch tests. All patients were tested with a standard test tray as recommended by the International Contact Dermatitis Committee. In addition, 40 patients had patch tests using a vehicle tray, and 12 patients had further specific antigen tests. A positive patch test produced erythema and papules that were usually mildly pruritic, developed often within 24 hours after application, and were present consistently at 48 hours. Significant positive reactions to patch-test agents occurred in all patients (and individual patients often showed a positive reaction to more than one allergen): 1.0% aqueous potassium chromate, 11 patients; 1.0% ethylenediamine, 10; 1:1,500 phenylmercuric acetate, 9; 1.0% aqueous nickel nitrate, 9; 1.0% sodium lauryl sulfate, 6; 1.0% paraphenylenediamine, 6; 2.5% aqueous formalin, 6; various detergents, 5; rubber mix, 5; 1.0% aqueous glutaraldehyde, 4; hydrocarbon series, 4; parabens, 3; medications, 3; 0.1% aqueous mercury chloride, 3; 1.0% alcohol benzocaine, 3; 25% potassium iodide in petroleum, 3; 30% turpentine in oil, 3; hair shampoo, 2; polyethylene glycol, 2; 5% aqueous copper sulfate, 2; 1:1,000 thimerosol, 2; 10% propylene glycol, 1; 5% Bismark brown, 1; 0.5% aqueous sodium arsenate, 1; and cinnamon, 1.

Nonspecific Dermatitis.—This subgroup included the following disorders (Table 1) in which no evidence of contact, atopic, or fungal factors could be established.

1. Nummular dermatitis was manifested by chronic, recurrent, pruritic, coin-shaped plaques of closely set papulovesicles on an erythematous base. They occurred particularly on the trunk and limbs.

2. Eczematoid dermatitis was defined as a nonspecific, poorly demarcated, erythematous area of exudation and crusting of variable degree, which occurred without preferential localization.

3. Exfoliative dermatitis was defined as a universal, chronic inflammation with widespread exfoliation. The cause in these cases was unknown.

4. Stasis dermatitis was defined as eczema of dependent limbs associated with venous insufficiency but uncomplicated by contact dermatitis from local therapy or infection.

5. Infectious eczematoid dermatitis was defined as superficial inflammation caused by staphylococci, streptococci, or both. It sometimes originated from foci of infection in an ulcer or sinus tract.

Table 1.—Serum IgE in Patients With Various Dermatologic Diseases: Dermatitis

Classification	No. Subjects	M/F Ratio	Age, yr	Serum IgE, ng/ml Range	Median	Geometric Mean	CI*	P†
Normal controls	95	64/31	7-62	1-2,667	80	74	56-100	
Dermatitis								
Atopic dermatitis	123	55/68	9/12-70	3-156,500	2,346	2,265	1,567-3,275	<.0001
Neurodermatitis								
Localized	9	5/4	25-46	10-115,000	230	1,012	95-10,732	<.0001
Generalized	23	14/9	10-73	26-38,983	1,374	2,071	829-5,176	<.0001
Without food or drug reaction	19	10/9	23-73	26-38,983	932	1,197	475-3,018	<.0001
Prurigo nodularis	10	6/4	27-63	26-5,814	315	467	127-1,718	<.0002
Contact dermatitis	52	22/30	9-85	16-35,700	328	423	276-649	<.0001
Without food or drug reaction	48			16-20,420	312	336	229-493	<.0001
Nonspecific dermatitis	55	33/22	7/12-77	7-22,940	256	317	196-512	<.0001
Without food or drug reaction	53			7-22,940	252	288	180-465	<.0001
Nummular dermatitis	14	9/5	7/12-77	14-2,074	75	112	50-251	NS‡
Without food or drug reaction	13				68	90	44-186	NS
Eczematoid dermatitis	18	8/10	9-72	7-11,651	246	362	142-926	<.005
Without food or drug reaction	17				217	303	142-649	<.001
Exfoliative dermatitis	11	7/4	25-77	151-22,940	520	803	310-2,041	<.0001
Stasis dermatitis	7	2/5	50-77	252-2,322	210	885	509-1,541	<.0001
Infectious eczematoid dermatitis	3	2/1	26-39	120-412	210			
Asteatotic dermatitis	2	2/0	60-72	10-166	84		10-166	
Dyshidrotic dermatitis	19	11/8	10-53	18-21,271	224	370	168-816	<.0001
Without atopy	16	9/7	10-53	18-21,271	218	239	113-506	<.005

*CI indicates 95% confidence interval of geometric mean.
†For differences from control group.
‡NS indicates not significant.

Table 2.—Serum IgE in Patients With Various Dermatologic Diseases: Dermatosis and Tinea Pedis

Classification	No. Subjects	M/F Ratio	Age, yr	Serum IgE, ng/ml Range	Median	Geometric Mean	CI*	P†
Normal controls	95	64/31	7-62	1-2,667	80	74	56-100	
Dermatosis								
Psoriasis	80	48/32	13-79	1-24,335	220	219	153-314	<.0001
Without atopy	75	46/29	13-79	1-2,132	164	175	128-239	<.0001
With arthropathy	5	3/2	23-65	94-2,180	798	539	186-1,567	<.005
With pustules	5	2/3	29-61	74-552	87	126	60-266	NS‡
Urticaria	47	20/27	9-81	6-22,362	315	334	217-514	<.0001
Without atopy	44			16-2,298	294	317	221-458	<.0001
Acne vulgaris	13	9/4	20-51	16-4,906	133	181	75-435	<.05
Without atopy	11			16-850	125	109	57-208	NS
Alopecia areata	50	27/23	5-58	12-5,669	310	297	192-462	<.0001
Without atopy	41				194	196	129-299	<.0005
Pityriasis rubra pilaris	6	6/0	52-78	155-1,787	428	509	253-1,024	<.005
Lichen planus	5	2/3	26-62	26-239	91	81	40-165	NS
Tinea pedis	15	8/7	17-56	8-991	91	128	61-272	NS

*CI indicates 95% confidence interval of geometric mean.
†For differences from control group.
‡NS indicates not significant.

6. Asteatotic dermatitis was manifested by dry, scaling, cracked, and fissured skin involving the limbs particularly. It was seen more commonly in the elderly and was most prominent during the winter months.

Dyshidrotic Dermatitis.—This was an acute, recurrent, or chronic vesicular eruption on the palms, soles, or digits. Fungal and contact allergenic features were absent.

Dermatoses

In view of their classic clinical presentation, the following common dermatoses do not require individual definition: psoriasis, urticaria, acne vulgaris, alopecia areata, pityriasis rubra pilaris, and lichen planus (Table 2).

Tinea Pedis

This was defined as a severe, chronic and recurring, symptomatic dermatophytic infection of the foot, proved by KOH examination and culture. The patients were not atopic and had no other dermatologic disease. Culture revealed that 11 patients had *Trychophyton rubrum;* 3, *Trychophyton mentagrophytes;* and 1, *Epidermophyton floccosum.*

Measurement of IgE

Serum IgE protein was measured by double antibody radioimmunoassay. Previous studies with this method in our normal subjects revealed a range from 1 to 2,700 ng/ml and a median of 80 ng/ml. The 94% confidence interval of serum IgE values was 6 to 780 ng/ml.[7] Although the control sera were not examined concurrently with the test sera, we recently have tested sera from 30 healthy blood donors

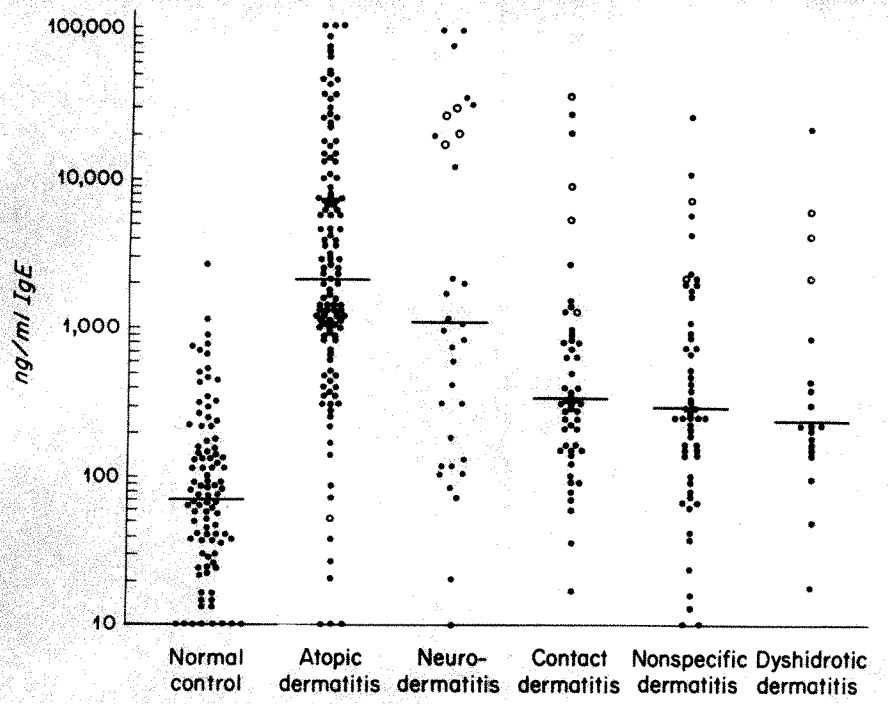

Fig 1.—IgE in dermatitis. In neurodermatitis, contact dermatitis, and nonspecific dermatitis, open circles represent patients with a history of cutaneous reaction to food or drugs. In other groups, open circles represent a history of atopy. A crossbar indicates the geometric mean of each group after excluding both types of patients.

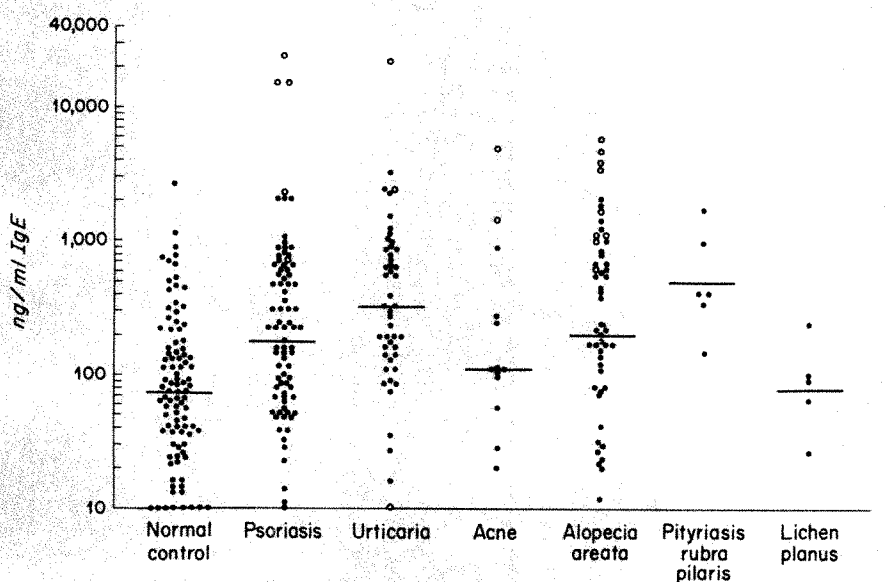

Fig 2.—IgE in common dermatoses. Open circles represent patients with a history of atopy. A crossbar indicates geometric mean of each group after exclusion of these patients.

and obtained an arithmetic mean of 114 ng/ml, a median of 58 ng/ml, and a 95% confidence interval of 12 to 699 ng/ml. These results are remarkably similar to those reported in 1971[7]: arithmetic mean 179 ng/ml, median 80 ng/ml, and 94% confidence interval 6 to 780 ng/ml. These results encourage belief that the assay has not changed since its introduction and that the use of the original controls is appropriate here. In this study, serum IgE levels are expressed in nanograms per milliliter. Data from the literature reported as International Units (IU) are converted to weight (1 IU = 2.35 ng)[24,25] for comparison purposes.

Stool examination for ova and parasites was performed in 80% of the cases with moderate or markedly elevated serum IgE concentrations.

Statistical Analysis

The median, the geometric mean, and the 95% confidence interval for the geometric mean (CI) of serum IgE levels were estimated for each subgroup. To correct for the skewed distribution of serum IgE values in each subgroup, we used a log transformation of serum IgE values. Employing Student's *t*-test (two-tailed), we compared each subgroup and the tinea pedis group with the normal control group investigated previously by Gleich et al.[7] In addition, where appropriate, we excluded all patients who had a history of atopic diathesis and again compared each subgroup with the control group. (Atopic patients were those who previously or currently had atopic dermatitis, allergic rhinitis, or allergic asthma.) Also, in certain dermatitis subgroups—neurodermatitis, contact dermatitis, and nonspecific dermatitis—the cases with histories suggesting cutaneous manifestations of immediate hypersensitivity reaction to foods or drugs were excluded from a second analysis of the subgroups (Table 1 and 2). Although suggestive of atopy, this type of reaction was not considered sufficient to classify any of these subgroups as atopic dermatitis.

The relationship between serum IgE concentrations and peripheral eosinophil count was assessed in 80 cases of atopic dermatitis.

GENERAL FINDINGS

The serum IgE concentration of each member of each group or subgroup and each control subject is plotted in Fig 1 through 3.

Table 1 and 2 present clinical, laboratory, and statistical data from the control group, from each dermatitis and dermatosis subgroup, and from the tinea pedis group.

Figure 4 shows the percentage of patients in each subgroup with serum IgE levels exceeding the upper limit of normal IgE (780 ng/ml).

The median and geometric mean levels for serum IgE are significantly elevated in all categories except nonatopic acne, lichen planus, and tinea pedis. This elevation remained after patients with a history of atopy or of cutaneous reaction to food or drugs were excluded. The P value ($< .05$) in the acne group is not conclusive but significant.

The results of stool examination for ova and parasites were negative in all patients tested. As reported previously, the prevalence of intestinal para-

sites is low among allergic patients at this institution.[26]

COMMENT

Dermatitis

Atopic.—Serum IgE concentrations greater than 10,000 ng/ml were present in 30% of these cases. One patient with severe active allergic asthma had a concentration of 55 ng/ml (signified by unfilled circle in Fig 1). Figure 5 shows a modest positive correlation ($p \cong .05$) between the log serum IgE level and peripheral blood absolute eosinophil count in 80 cases of atopic dermatitis (correlation coefficient = 0.22).

The geometric mean level of 2,865 ng/ml from our series may be compared to 2,733, 1,159, 2,768, and 2,270 reported from other large series.[8-11] Our median level of 2,346 ng/ml is slightly less than 2,639 ng/ml found earlier in 58 patients at this institution.[14] Our results also are comparable to those reported in the German literature.[12,13]

Concentrations greater than 1,000 ng/ml were measured in 76% of our cases and in 82% of cases reported by Juhlin et al.[8] A history of either allergic asthma of hay fever, or both, was recorded in 37% of their cases. Serum IgE levels within the normal limit were obtained in 24% of our cases, contrasting with the 62.5% in a series of "pure" atopic dermatitis cases from which patients with concurrent allergic diseases and those receiving hyposensitization or systemic corticosteroid therapy were excluded.[11] Stone et al[14] have confirmed a relationship between extent of atopic dermatitis and serum IgE levels.

The absence of excessive IgE in some patients with atopic dermatitis might be explained by the finding of non-IgE, reaginic antibodies in some experimental animals.[27] The IgE reaginic antibody in allergic asthma[28] and "short-term, anaphylactoid, IgG antibodies" in food allergy[29] exist in humans, and naturally occurring anti-IgE antibodies[30] or other undetected antibodies may exist as well.

Neurodermatitis.—Of the 32 cases, 11 had serum IgE levels exceeding 10,000 ng/ml. Among these 11, the median was 35,736 (Table 3). The highest levels were seen in three patients with chronic acral dermatitis who have been described previously by Winkelmann and Gleich.[31] They were unique in that the acral involvement was the predominant feature, and may constitute a distinct group. We have included the three cases in the neurodermatitis group because the manifestations and characteristics of the two conditions are similar in many respects. At the present time we are inclined to regard these patients as a subset of those with neurodermatitis. Supporting this view is Cormane's[32] independent recognition of a form of acral dermatitis having a high percentage of circulating lymphocytes bearing IgE.

The other patients with levels exceeding 10,000 ng/ml all had severe generalized dermatitis but without acral predominance, and none had spontaneous or induced evidence of atopy (Table 3). This latter group points to the existence of a separate nonatopic form of dermatitis that has high levels of serum IgE and a chronic course. We believe this is a significant clinical observation emphasizing that stimuli other than the usual atopic stimuli can be related to IgE levels.

The relationship of serum IgE levels to prurigo lesions is uncertain. There was a significant elevation of the median level of serum IgE. The presence of prurigo was not specifically related to serum IgE levels, however, since six of the ten patients had serum IgE values less than 500 ng/ml. Analysis of the ten cases failed to show a relationship between serum IgE levels and extent of lesions, duration of lesions, age of patient, or peripheral eosinophil count.

There has been scant reference in the literature to serum IgE levels in neurodermatitis or prurigo. Two cases of prurigo simplex has serum values of 774 and 2,081 ng/ml[13]; one case of prurigo nodularis had a serum value of 445 ng/ml.[8] In a case of generalized prurigo nodularis, the concentration was 5,404 ng/ml.[10] The range of our cases was 26 to 5,814 ng/ml.

Contact Dermatitis.—Published reports give geometric mean levels of 202 ng/ml and 909 ng/ml in contact dermatitis.[8,10] Ours was 336 ng/ml. Elsewhere, normal levels were found in 6 cases[12]; a mean of 540 ng/ml was found in ten cases that was compared with a mean of 163 ng/ml in 100 normal subjects.[13]

Our data suggest that elevated

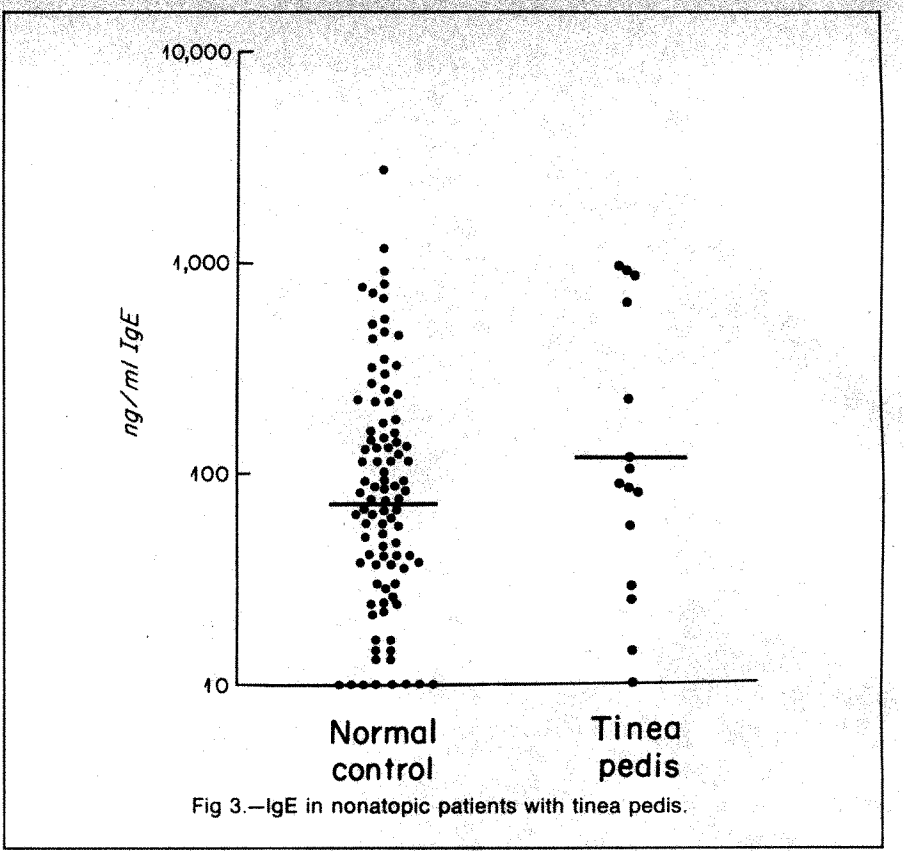

Fig 3.—IgE in nonatopic patients with tinea pedis.

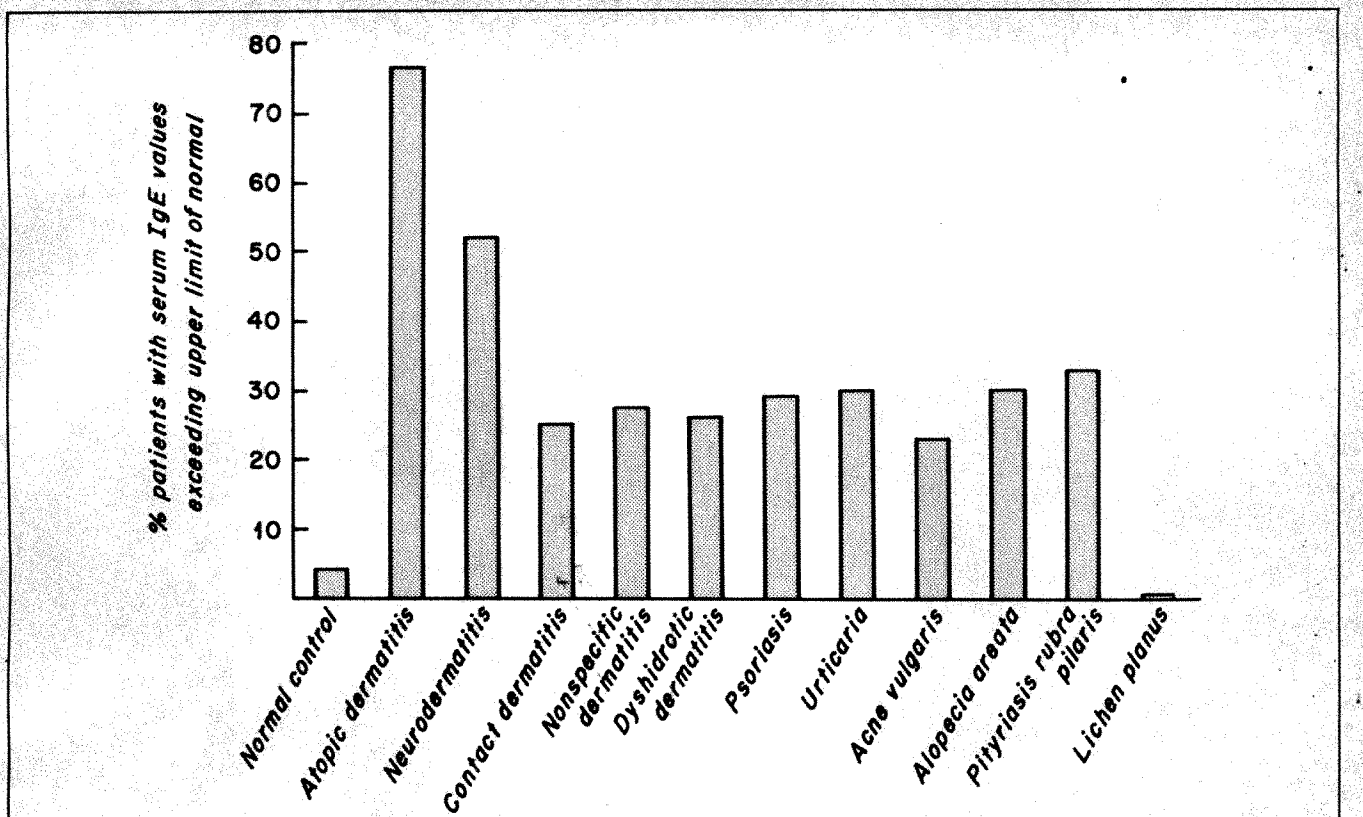

Fig 4.—Percentage of patients with serum IgE values that exceeded upper limit of normal.

serum IgE levels may occur in patients who have severe contact dermatitis and that serum IgE remains a factor to be evaluated, not necessarily for its role in the etiology but for its significance in the chronicity of the disease.

Nonspecific Dermatitis.—In *nummular* dermatitis, no relationship was readily apparent between serum IgE levels and age, duration of dermatitis, or extent of cutaneous involvement.

Our findings support the statement by Krueger et al[22] that normal IgE levels are present in patients with nummular eczema. They studied 26 patients, including five children less than 15 years of age, who had moderate to severe chronic involvement with nummular dermatitis. The children had levels within the normal range for their age. Among the values for the 21 adults, 4 were greater than the normal upper limit of 500 ng/ml, and 2 of those greater than 1,000 ng/ml. They found significantly lower IgE levels in the group with nummular dermatitis than in a group with atopic dermatitis. In their opinion, the difference in IgE elevation established the two conditions as separate entities.

Normal serum IgE values have been reported from four cases of nummular dermatitis[12] and also from two cases wherein atopic dermatitis had resolved 49 and 22 years prior to the onset of nummular dermatitis.[23] Gurevitch et al[10] found an elevated geometric mean serum value of 2,218 ng/ml in three patients with nummular dermatitis; however, all of them were thought to have atopy.

Gurevitch et al[10] described 15 cases that they called eczematoid dermatitis, in which atypical eruptions occurred in adults who had no personal or family history of any atopic disorder. This group included two patients with generalized exfoliative dermatitis, one patient with generalized prurigo nodularis, and one patient with papulosquamous facial eruption. The remainder had eczematoid eruptions of varying extent. Six of the 15 patients had serum IgE levels greater than 2,350 ng/ml. The geometric mean serum IgE level was 1,348 ng/ml in the total group. In their study, the geometric mean serum IgE level of pooled sera from 51 nonatopic patients was 644 ng/ml. They did not consider the mean serum IgE level of 1,348 ng/ml to be significantly elevated. They concluded that an elevated serum IgE level may provide a helpful clue to the presence of atopy in unusual, adult-onset, eczematous disorders. In contrast, our data suggest that serum IgE is often elevated in cutaneous disease and therefore cannot be used alone to identify an individual patient with atopy. Analysis of sex, age, duration, and extent of cutaneous involvement failed to reveal any readily apparent relationship of these factors to serum IgE levels.

Dyshidrotic Dermatitis.—Our data suggest that elevated serum IgE levels occur in dyshidrotic dermatitis patients who have no evidence of atopy. The patient with the highest serum IgE level, 21,271 ng/ml, had no personal or family history for atopic disease. In these 19 cases there was no readily apparent correlation between serum IgE levels and age, sex, duration of disease, or extent of disease (ie, hands, feet, or both).

Gurevitch et al[10] discussed eight patients with a dyshidrotic eruption whose geometric mean serum IgE value was 570 ng/ml. All the patients

had a personal or family history of atopy, but none had current or past cutaneous manifestations of atopy other than the vesicular eruption of the palms, soles, or both. They found that two of the eight patients had serum IgE levels greater than 4,700 ng/ml; an additional patient had a level greater than 2,350 ng/ml. Only one of these three patients had a history of hay fever or asthma, a 14-year-old girl who had asthma and a dyshidrotic eczema of the hand for one month. These authors concluded that all eight cases could be considered as variants of atopic dermatitis with limited skin manifestations. Two other cases of dyshidrotic dermatitis were reported as having normal serum IgE levels,[12] and an additional case had a level of 1,548 ng/ml.[13] Our results suggest that dyshidrotic dermatitis is unrelated to atopic dermatitis, since the median and geometric mean levels from our 16 nonatopic patients were much lower than the levels from the atopic dermatitis group.

Dermatosis

Psoriasis.—Corresponding to the geometric mean level of 175 ng/ml in our 75 nonatopic patients are the geometric means 362 and 846 ng/ml reported in the literature.[9,10] Six reported cases had levels ranging from 61 to 410 ng/ml. The elevation of the mean serum IgE level in a group of 32 patients was not considered statistically significant[12]; and the mean level of 838 in a group of 51 patients was compared with 394 ng/ml in normal controls.[13]

Among the nonatopic patients, five with psoriatic arthropathy had significant elevation of IgE concentration and five with pustular psoriasis did not (Table 2).

Urticaria.—The three patients with an atopic background had IgE concentrations of 22,362 ng/ml (hay fever), 2,321 ng/ml (asthma), and 6.1 ng/ml (hay fever). Among 36 patients with chronic recurrent urticaria, 3 had dermatographia in extreme degree; their IgE values were 33, 596, and 615 ng/ml. The cause of the chronic urticaria in these 36 cases was uncertain, although penicillin was suspected in 3 cases. The urticaria had acute onset and brief duration in five cases. Three of them were related to penicillin ingestion (715, 1,194, and 3,231 ng/ml) and two were attributed to infection of the upper respiratory tract (100 and 3,231 ng/ml). Four patients had chronic recurring angioedema involving the facial and laryngeal tissue (16, 74, 145, and 561 ng/ml). One patient, who had cold urticaria of an acquired nonfamilial type and also a history of hay fever, had a serum IgE level of 22,362 ng/ml. One nonatopic patient with delayed pressure urticaria had a level of 2,484 ng/ml.

The geometric mean IgE concentration was 317 in our 44 urticaria patients without atopic diathesis and 172 ng/ml in 34 cases reported by Juhlin et al,[8] of which 17 were acute and 17 were chronic. In our group, seven of the 44 had levels greater than 1,000 and 12 others had levels greater than 500 ng/ml, but none of our patients with marked dermatographia or angioedema had significantly elevated serum IgE levels.

In 37 patients with urticaria described by Wüthrich et al,[12] the mean serum IgE was not significantly elevated; but when a definite antigen could be incriminated, the IgE concentration tended to be higher. The 12 patients described by Graul et al[13] had a mean of 507 ng/ml, that was compared with a mean of 163 ng/ml in 100 normal controls. Four other cases reported had normal levels.[23] As an overall group, our urticaria patients had a significantly elevated median serum IgE level; however, the pa-

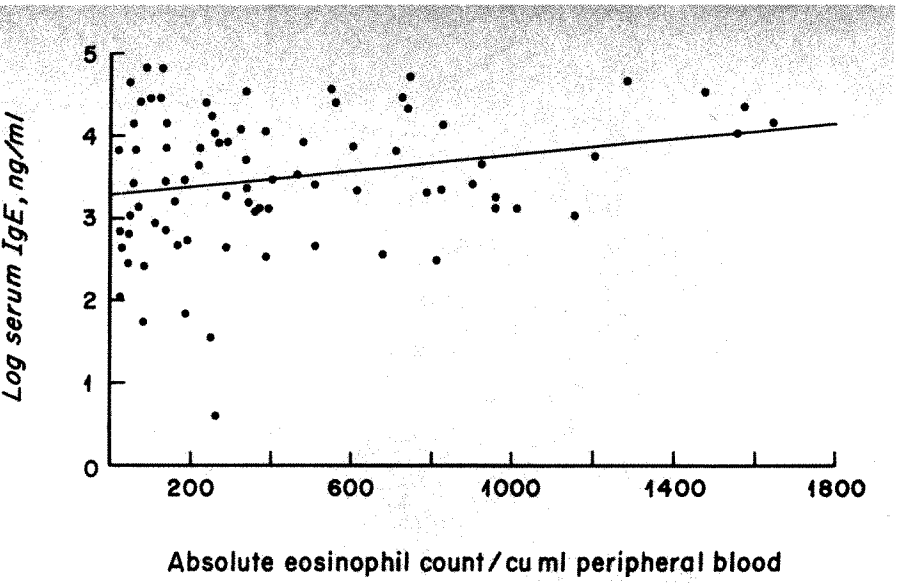

Fig 5.—Relationship of peripheral eosinophil count to serum IgE concentration in atopic dermatitis.

Table 3.—Analysis of Neurodermatitis Patients With Serum IgE > 10,000 ng/ml

Sex	Age	Duration, yr	Extent	Eosinophils, %	Leukocytes, /cu mm	History of drug Reaction	Patch Testing	Serum IgE, ng/ml
M	42	6	Diffuse	15.5	7,000	0	0	12,004
F	60	15	Diffuse	6.5	5,100	PCN* urticaria	0	21,066
F	57	1	Diffuse	4.0	5,300	0	0	25,814
F	53	5	Diffuse	3.0	5,100	PCN urticaria	0	28,482
F	10	3	Diffuse	6.5	5,700	PCN urticaria	0	32,158
F	72	1	Diffuse	1.5	7,400	PCN urticaria	Detergent (+)	35,736
F	66	10	Diffuse	5.5	4,400	0	0	38,043
F	49	12	Diffuse	25.0	16,500	0	Not done	38,983
M	41	20	Acral	32.0	33,800	0	0	70,000
F	46	7	Acral	9.5	5,500	0	0	99,000
M	39	2½	Acral	14.0	10,900	0	0	115,000

*PCN indicates penicillin.

tients with chronic urticaria, including those with marked simple dermatographia or chronic angioedema, did not have markedly elevated serum IgE levels. We agree with Warin and Champion[33] that these disorders are not closely associated with atopic disorders, as defined by the serum IgE level.

Acne Vulgaris.—Our 11 patients with acne vulgaris but no atopic background had a geometric mean serum IgE level of 109 ng/ml; and 56 cases reported by others also had a normal mean.[8,10,13] Seven of our patients had severe conglobata acne, and one of these had a significantly elevated level (4,906 ng/ml), which presumably was related to his atopic status.

Gurevitch et al[10] reported a geometric mean serum level of 768 ng/ml in 52 acne patients. But the 19 with an atopic background had a mean of 1,208, and the 33 without it had a mean of 592 ng/ml. As we found in comparing our atopic and nonatopic acne patients, this was a significant difference. In contrast, however, our nonatopic patients had levels that were not significantly elevated above the normal range. Signs of or a history of atopy were present in four of their six cases with levels greater than 2,350 ng/ml. They postulated, therefore, that elevated IgE levels may reflect atop even in the absence of obvious allergic diseases or, alternatively, that elevated IgE levels in some cases may be unrelated to atopy.

Alopecia Areata.—The significantly elevated levels in nonatopic patients contrast noticeably with the six normal levels reported by others.[8,12,13] The nine patients with alopecia totalis whose history was negative for atopy had a median serum IgE level of 155 ng/ml.

Pityriasis Rubra Pilaris.—Despite the small size of the sample, the median and geometric mean levels were significantly elevated, appreciably more so than in the psoriatic group.

Lichen Planus.—In this small group, the serum IgE levels were not significantly elevated. Two patients described by others had normal serum IgE levels.[10,12]

Tinea Pedis.—Jones et al[34] have stated that atopic individuals who have either allergic rhinitis or bronchial asthma, or who have a history of these conditions, have an increased tendency to develop this chronic dermatophytosis. Our 15 patients with tinea pedis had serum IgE levels that did not differ significantly from those of normal controls.

CONCLUSION

Our data clearly indicate a strong correlation between elevated serum IgE levels and atopic dermatitis. The cases of acquired generalized dermatitis that had very high serum IgE levels may represent a new entity in adult, nonatopic individuals. The major finding in this study, however, is that serum IgE levels are significantly elevated in the majority of the common dermatitides and dermatoses. This relationship persists even after the exclusion of atopic individuals from the study groups. Cutaneous reactions of many types may cause a significant elevation of serum IgE. Our data suggest that, in the majority of the common dermatitides and dermatoses, elevated levels of serum IgE are a secondary phenomenon rather than a primary causative factor.

This investigation was supported in part by Research Grant AI-11483 from the National Institutes of Health.

Peter C. O'Brien, PhD, and Jeanine E. Ransom performed the statistical analyses.

References

1. Ishizaka K, Ishizaka T, Hornbrook MM: Physico-chemical properties of human reaginic antibody: IV. Presence of a unique immunoglobulin as a carrier of reaginic activity. *J Immunol* 97:75-85, 1966.

2. Ishizaka K: Human reaginic antibodies. *Annu Rev Med* 21:187-200, 1970.

3. Johansson SGO, Bennich H: Immunological studies of an atypical (myeloma) immunoglobulin. *Immunology* 13:381-394, 1967.

4. Johansson SGO, Bennich H, Wide L: A new class of immunoglobulin in human serum. *Immunology* 14:265-272, 1968.

5. Rowe DS: Radioactive single radical diffusion: A method for increasing the sensitivity of immunochemical quantification of protein in agar gel. *Bull WHO* 40:613-616, 1969.

6. Polmar SH, Waldmann TA, Terry WD: IgE in immunodeficiency. *Am J Pathol* 69:499-513, 1972.

7. Gleich GJ, Averbeck AK, Swedlund HA: Measurement of IgE in normal and allergic serum by radioimmunoassay. *J Lab Clin Med* 77:690-698, 1971.

8. Juhlin L, Johansson SGO, Bennich H, et al: Immunoglobulin E in dermatoses: Levels in atopic dermatitis and urticaria. *Arch Dermatol* 100:12-16, 1969.

9. Ogawa M, Berger PA, McIntyre OR, et al: IgE in atopic dermatitis. *Arch Dermatol* 103:575-580, 1971.

10. Gurevitch AW, Heiner DC, Reisner RM: IgE in atopic dermatitis and other common dermatoses. *Arch Dermatol* 107:712-715, 1973.

11. Clendenning WE, Clack WE, Ogawa M, et al: Serum IgE studies in atopic dermatitis. *J Invest Dermatol* 61:233-236, 1973.

12. Wüthrich B, Kopper E, Virchow C: IgE-Bestimmung bei Neurodermatis und anderen Dermatosen. *Hautarzt* 24:381-386, 1973.

13. Graul EH, Borelli S, Müller H, et al: Immunoglobulin E-Bestimmung bei Dermatosen. *Hautarzt* 24:235-240, 1973.

14. Stone SP, Muller SA, Gleich GJ: IgE levels in atopic dermatitis. *Arch Dermatol* 108:806-811, 1973.

15. Johansson SGO: Raised levels of a new immunoglobulin class (IgND) in asthma. *Lancet* 2:951-953, 1967.

16. Berg T, Johansson SGO: IgE concentrations in children with atopic diseases: A clinical study. *Int Arch Allergy Appl Immunol* 36:219-232, 1969.

17. Rowe DS, Wood CBS: The measurement of serum immunoglobulin E levels in healthy adults and children and in children with allergic asthma. *Int Arch Allergy Appl Immunol* 39:1-5, 1970.

18. Virchow Chr, Möller E, Debelic M: IgE-serumspiegel-bestimmungen bei chronisch-obstruktiven Atemwegsleiden. *Pneumonologie* 145:428-440, 1971.

19. Hogarth-Scott RS, Johansson SGO, Bennich H: Antibodies to toxocara in the sera of visceral larva migrans patients: The significance of raised levels of IgE. *Clin Exp Immunol* 5:619-625, 1969.

20. Rosenberg EB, Whalen GE, Bennich H, et al: Increased circulating IgE in a new parasitic disease—human intestinal capillariasis. *N Engl J Med* 283:1148-1149, 1970.

21. Rosenberg EB, Polmar SH, Whalen GE: Increased circulating IgE in trichinosis. *Ann Intern Med* 75:575-578, 1971.

22. Krueger GG, Kahn G, Weston WL, et al: IgE levels in nummular eczema and ichthyosis. *Arch Dermatol* 107:56-58, 1973.

23. Johansson SGO, Juhlin L: Immunoglobulin E in "healed" atopic dermatitis and after treatment with corticosteroids and azathioprine. *Br J Dermatol* 82:10-18, 1970.

24. Yunginger JW, Gleich GJ: Measurement of ragweed antigen E by double antibody radioimmunoassay. *J Allergy Clin Immunol* 50:326-337, 1972.

25. Bazaral M, Hamburger RN: Standardization and stability of immunoglobulin E (IgE). *J Allergy Clin Immunol* 149:189-191, 1972.

26. Van Dellen RG, Thompson JH Jr: Absence of intestinal parasites in asthma. *N Engl J Med* 285:146-148, 1971.

27. Bloch KJ: Immunoglobulin heterogeneity and anaphylactic sensitization, in Austen KF, Becker EL (eds): *Biochemistry of the Acute Allergic Reactions*. Philadelphia, FA Davis Co, 1968, p 45.

28. Bryant DH, Burns MW, Lazarus L: New type of allergic asthma due to IgG "reaginic" antibody. *Br Med J* 4:589-592, 1973.

29. Parish WE: Short-term anaphylactic IgG antibodies in human sera. *Lancet* 2:591, 1970.

30. Williams RC Jr, Griffiths RW, Emmons JD, et al: Naturally occurring human antiglobulins with specificity for γE. *J Clin Invest* 51:955-963, 1972.

31. Winkelmann RK, Gleich GJ: Chronic acral dermatitis: association with extreme elevations of IgE. *JAMA* 225:378-381, 1973.

32. Cormane RH: B and T cells in dermatitis. *Mayo Clin Proc* 49:531-536, 1974.

33. Warin RP, Champion RH: Urticaria. *Major Probl Dermatol* 1:1-173, 1974.

34. Jones HE, Reinhardt JH, Rinaldi MG: Immunologic susceptibility to chronic dermatophytosis. *Arch Dermatol* 110:213-220, 1974.

Giant Basal Cell Carcinoma

Mary C. Curry, MD; Hamilton Montgomery, MD; Richard K. Winkelmann, MD, PhD

• **Whereas basal cell carcinoma usually is a slow-growing tumor of the head and neck region, we have observed, over a 20-year period, three large, unique basal cell tumors of the back that were distinctive and presented clinical and histologic problems in diagnosis. They commonly formed exophytic, vegetative, flesh-colored to red, sessile plaques up to 20 cm in diameter. Ulceration was the principal feature of a fourth tumor, which destroyed the skin of the entire lumbar area and invaded the muscle. Regional-node metastases from this tumor showed basal cell carcinoma. Histologically, all the primary lesions were adenoid basal cell carcinomas with mucinous stroma. Histochemistry in two cases demonstrated minimal respiratory enzymes and no special esterolytic or lysosomal enzymes. Surgery was curative in three of these cases of rare, giant variant of basal cell carcinoma of the skin.**

(*Arch Dermatol* 113:316-319, 1977)

Basal cell carcinoma is one of the tumors most frequently seen by dermatologists, and many histologic and clinical variants have been noted. Recently, we have compiled four cases of giant basal cell carcinoma of the back, seen in the course of 20 years.

REPORT OF CASES

CASE 1.—A 72-year-old man came to the department of dermatology for removal of a tumor that had been on the lower part of his back for at least ten years (Fig 1, top). When first noticed, the lesion had been about the size of a dime, and it had grown slowly. In the last year, it had begun to weep foul-smelling fluid and to bleed with minimal trauma. The lesion produced no other symptoms, and the patient was in good general health.

Examination revealed a plate-shaped (12 × 8 × 2 cm) friable, weeping tumor of the right lumbar area. There were telangiectasias at the base of the lesion, but the surrounding epithelium was intact.

Other physical, radiologic, and laboratory findings were normal, except for mild iron-deficiency anemia.

The lesion was completely excised to the fascia, and a split-thickness graft was applied.

CASE 2.—A 67-year-old man came to the department of dermatology for removal of a large tumor that had been on his back for 25 years. The lesion had grown slowly, but in recent years, it had begun to bleed easily. The patient had been in good health and had sought no medical advice.

Examination revealed a fungating, friable sessile tumor (8 × 12 × 12 cm) in the midlumbar area. The epidermis to the base of the lesion was intact. The surrounding subcutaneous tissue was indurated, but there were no visible satellite lesions.

Physical, radiologic, and laboratory examinations revealed no other abnormalities except for iron-deficiency anemia.

The lesion was completely excised to the fascia, and a pedicle graft was applied. Two years later the patient was treated for a small recurrence in the flap. Subsequent follow-up examinations gave negative findings.

CASE 3.—A 72-year-old woman came to the department of dermatology for definitive medical advice concerning a tumor present on her back for 20 years (Fig 1, center). The lesion had grown slowly at first; but in the last several years, it had begun to grow more rapidly, to bleed easily, and to weep serous fluid, though otherwise it was asymptomatic. One physician had told her it was cancerous; another had said it was not. The patient was in good general health.

Examination revealed an erythematous, friable, fungating tumor, 15 × 12 × 2 cm, which appeared to burrow laterally under the skin. The epidermis was intact to the base of the tumor. No satellite lesions were apparent.

Other physical, radiologic, and laboratory examinations disclosed no abnormalities except iron-deficiency anemia.

The lesion was excised completely to the fascia, and a split-thickness graft was applied. There was no recurrence at one-year follow-up.

CASE 4.—A 43-year-old woman came to the Mayo Clinic because of a mole on her back that had been present 20 years. Seven years before her visit, it had begun to grow at an accelerated rate, to ulcerate, and to bleed. Surgical removal had been suggested at that time, but the patient had refused. The lesion had continued to enlarge and to weep foul-smelling, purulent material; and the patient had begun to isolate herself from family and friends. She had been amenorrheic for the past year and had lost 7 kg.

Physical examination revealed a necrotic, purulent ulcer, 26 × 28 cm, on the midback at the L2-4 level (Fig 1, bottom), seeming to penetrate into the deep fascia overlying the vertebrae. The lesion had a discrete, sclerotic, slightly elevated margin. Within the ulcer were scattered dark-purple indurated nodules. There were hyperplastic nodes (1 cm) in the right inguinal and right axillary regions. Mucous membranes were pale.

A chest roentgenogram revealed cardiomegaly but no evidence of pulmonary lesions. The hemoglobin was 4.2 g/100 ml and the hematocrit, 15.3%. Iron studies showed iron-deficiency anemia. The cardiomegaly and hematologic abnormalities resolved after a 7-unit transfusion.

Radiologic studies of the bones showed no metastasis. Liver function was normal, although a liver-spleen scan showed hepatomegaly without focal defects in uptake.

Serum thyroxine, creatinine, and electrolyte values were normal. Serum protein electrophoresis revealed decreased albumin. Delayed hypersensitivity skin tests were positive for mumps only (5-mm induration).

Cultures of the ulcer grew numerous anaerobic and aerobic organisms, including *Escherichia coli*, corynebacteria, β-hemolytic streptococci of group D, *Bacteroides fragilis*, *B melaninogenicus*, and *Staphylococcus epidermidis*. No acid-fast organisms or fungi grew out. Cultures of the blood for aerobic, anaerobic, and acid-fast bacteria and fungi were negative.

Biopsies of the ulcer margins (both upper and lower) and the central nodules, and of the right axillary and right inguinal hypertrophic lymph nodes were done.

Dressings wet with potassium permanganate were applied to the ulcer. Because it was not resectable, 2,100 rads of radiation were directed to it in divided doses. The patient was dismissed with a prescription for 50 mg methotrexate, administered intramuscularly every week.

At follow-up in October 1973, metastasis to the left ribs was noted, and x-ray treatment was given.

In March 1974, metastasis to the right axillary node was verified as basal cell

Accepted for publication July 27, 1976.

From the Department of Dermatology, Mayo Clinic and Mayo Foundation, Rochester, Minn.

Reprint requests to Section of Publications, Mayo Clinic, 200 First St SW, Rochester, MN 55901 (Dr Curry).

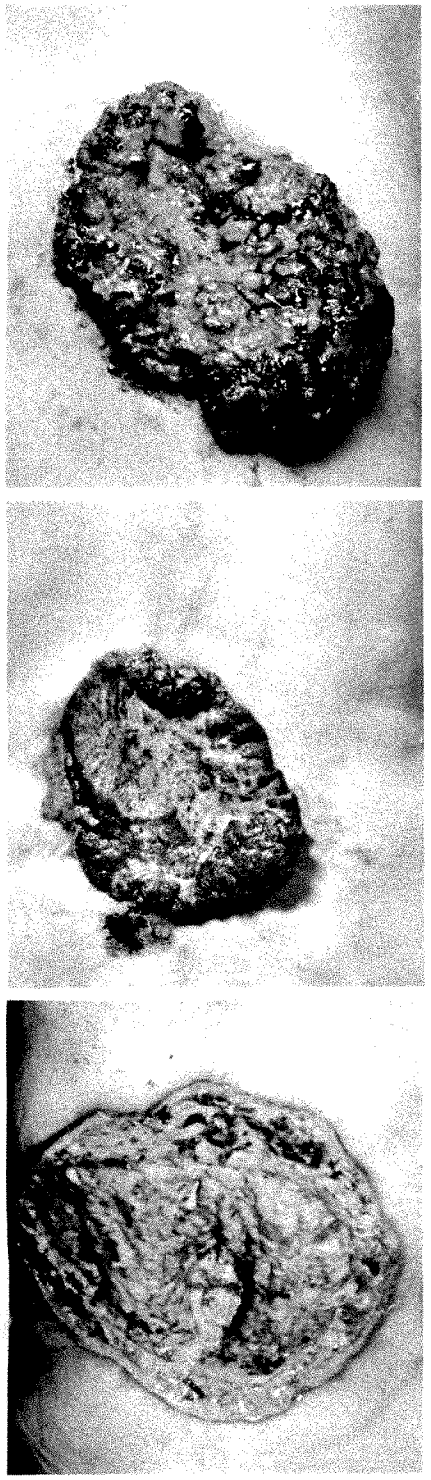

Fig 1.—Giant basal cell carcinoma. Top, Typical appearance and location; verrucoid character (case 1). Center, Close similarity to case 1 (case 3). Bottom, Giant rodent ulcer, with penetrating character (case 4).

carcinoma by excision biopsy findings.

The ulcer itself seemed to be slowly healing. In June 1974, there was a 2-cm margin of healing around it, and biopsy of the margin showed fibrosis.

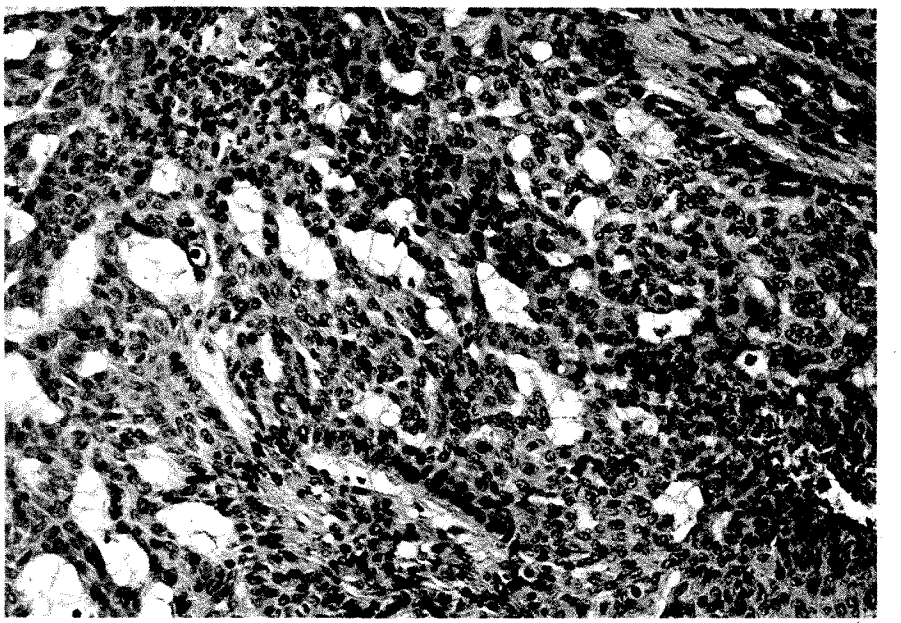

Fig 2.—Case 1. Basaloid character of tumor cells with peripheral palisades of cells and well-developed vascular stroma (hematoxylin-eosin, original magnification ×170).

Fig 3.—Case 2. Characteristic cystic-mucinous degeneration extending to periphery of tumor (hematoxylin-eosin, original magnification ×70).

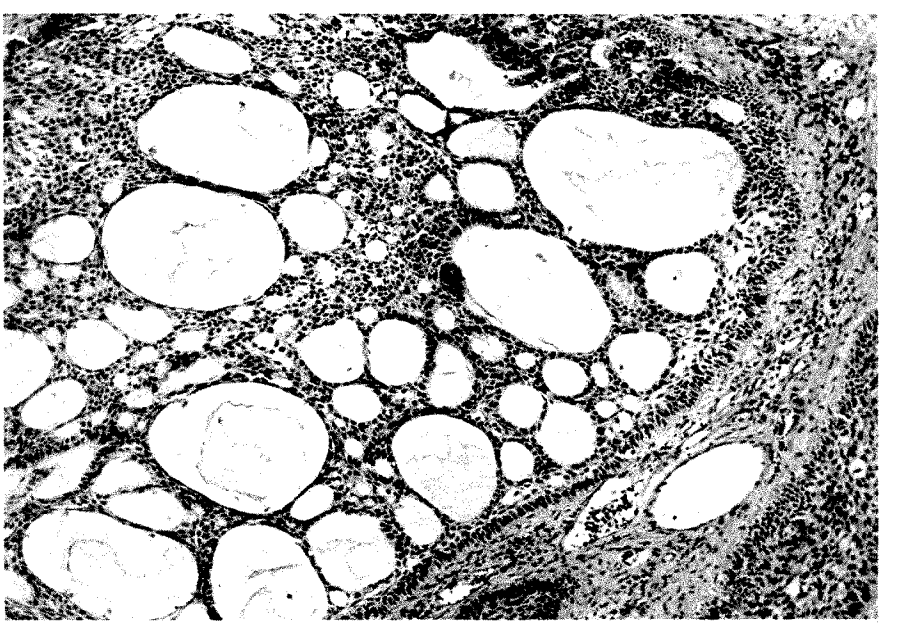

In January 1975, the tumor was noted to have progressed. Pulmonary metastasis was suspected. Administration of methotrexate was replaced by a cyclic program of prednisone (Deltasone) and cyclophosphamide (Cytoxan), each given at the rate of 50 mg daily on the same five days during one week per month. The patient has continued to do poorly and presently is bedridden.

LABORATORY INVESTIGATION
Histochemical Methods

Tissue from all four tumors and the metastatic lymph nodes in case 4 were stained with hematoxylin-eosin, PAS, and elastin-Giemsa.

Wedges of tissue from cases 1 and 4 were frozen immediately in liquid nitrogen. Sections were cut with a cryostat and tested for the following enzymes: acid phosphatase, alkaline phosphatase, adenosine triphosphatase, indoxyl esterase, nonspecific esterase, cholinesterase, leucine aminopeptidase, succinic dehydrogenase, nicotinamide adenine nucleotide dehydrogenase, and glycogen phosphorylase.[1]

Microscopic Observations

The histologic features of the first three tumors are identical. The tumors consist of strongly basophilic oval or slightly elongated cells with scant cytoplasm. The nuclei are hyperchromatic. There are five to ten mitoses per high-power field. These cells are arranged haphazardly in compact strands, sheets, or islands bounded by a single layer of palisaded cells (Fig 2). The larger islands have areas of cystic degeneration, some of which are so extensive as to give a Swiss cheese appearance to the tumor (Fig 3). At the periphery of the lesion, these tumor masses can be seen to be coming directly off the basal cell layer. The tumors extend down to the level of the middermis (Fig 4). The fibrous stroma contains a well-developed vascular network.

The histologic features of the fourth case are more consistent with morpheiform basal cell carcinoma. Small sheets and strands of oval basophilic cells are sandwiched in a dense fibrous stroma scattered throughout the dermis and into the subcutaneous tissue (Fig 5). The tumor can be seen to attach to the basal-cell layer of the epidermis. Larger islands of cells do show cystic degeneration. There are 10 to 20 mitoses per high-power field in this tumor.

Metastases in the inguinal lymph nodes show an identical pattern of small islands of immature basaloid cells sandwiched in dense fibrous stroma that occupies and destroys the major part of the nodes (Fig 6). There is no evidence of maturation or differentiation toward squamous cells.

Histochemical studies of tumors from subjects 1 and 4 gave results consistent with basal cell carcinoma. There was mild generalized activity of the respiratory enzymes, as is usual in basal cell carcinoma. There was no acid phosphatase activity. Alkaline phosphatase, adenosine triphosphatase, and leucine aminopeptidase activity characterized the vascular stroma and was associated with the endothelial cells of the vessels and vascular stroma.

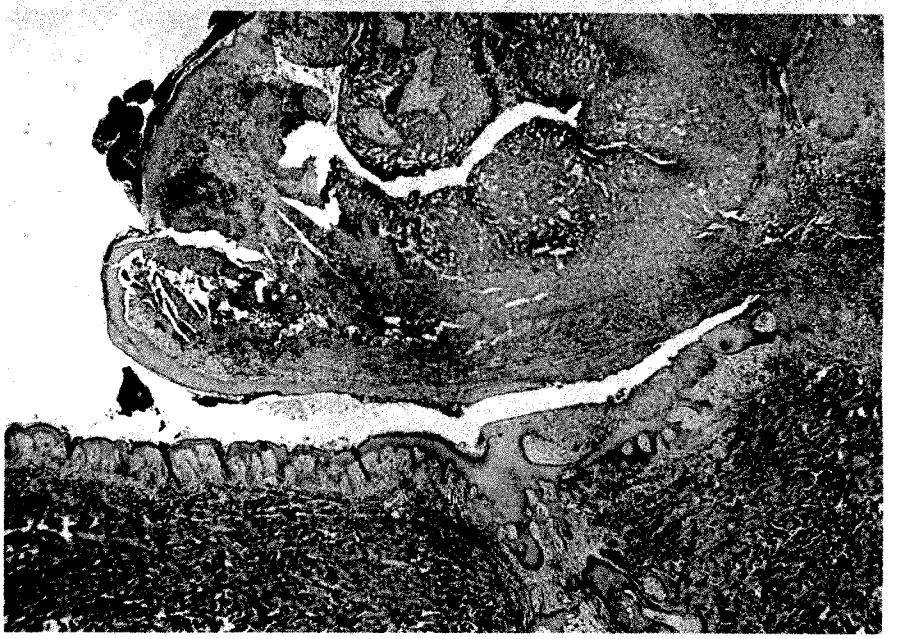

Fig 4.—Case 1. Tumor grows directly off basal area and remains exophytic (hematoxylin-eosin, original magnification ×20).

Fig 5.—Case 4. Rodent ulcer has almost morpheiform character at edges (hematoxylin-eosin, original magnification ×70).



COMMENT

Basal cell carcinoma is the most common skin cancer in the white population. It is most frequent on the head and neck and is often multiple. Ultraviolet light, exposure x-ray, exposure arsenic ingestion and genetic factors are important in its etiology; but in most cases no cause can be found. It is generally a cancer of the middle to later years.

One may classify basal cell tumors by clinical morphological findings. Nodular basal cell carcinomas are firm and are raised from the surrounding skin. They may or may not be ulcerated or hyperkeratotic. Superficial basal cell carcinomas, however, are flat, eczematous, and hyperkeratotic. They may have a well-demarcated, papular, pearly border. Many are pigmented. Fibrous basal cell carcinomas include the morpheiform basal cell carcinoma and the fibroepithelioma of Pinkus. These are very firm plaques or papules that often are mistaken for scars or benign fibrous growths.

Further classification of basal cell carcinoma may be made on the basis

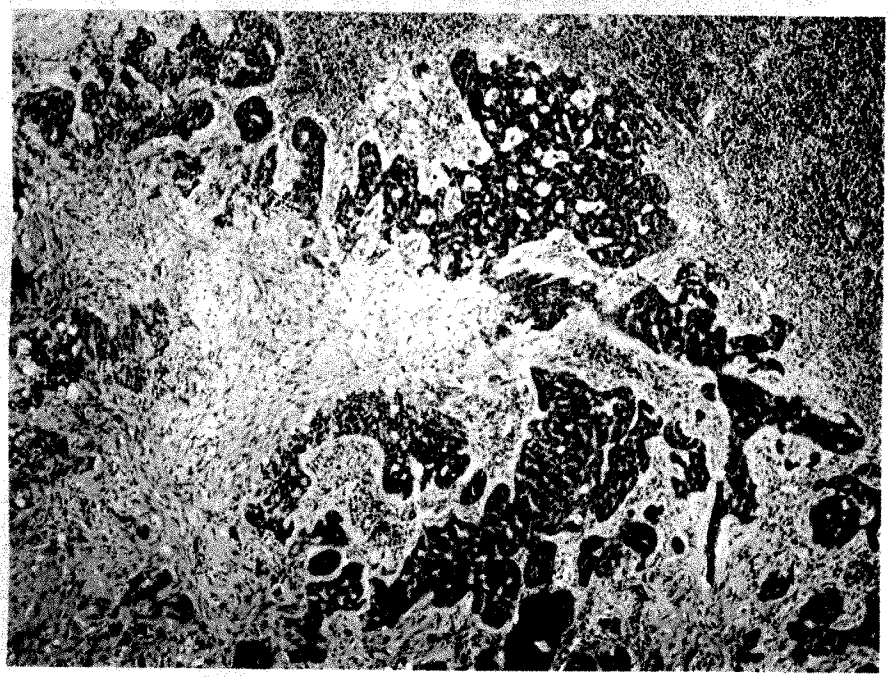

Fig 6.—Case 4. In lymph node, basal cell carcinoma similar to primary carcinoma (hematoxylin-eosin, original magnification ×64).

of histopathological findings. Solid tumors are masses of basal cells with minimal connective-tissue stroma. Cystic tumors show regional cystic degeneration. Mucinous tumors contain much mucin and myxoid elements in the stroma. Keratotic lesions afford some minimal evidence of differentiation, usually toward pilar structures. Bowenoid lesions show clear-cut malignant changes and cellular pleomorphism. Any form of basal cell carcinoma may manifest some tendency toward pilar, eccrine, apocrine, or sebaceous differentiation.

Large basal cell carcinoma occurs, but quite uncommonly. Three types of basal cell carcinoma are recognized as follows: (1) superficial, (2) rodent ulcer, and (3) vegetative. Some of these are associated with ingestion of arsenicals. Arsenic-induced tumors present a distinct clinical appearance of multiple superficial spreading lesions, mostly on the trunk. These may be asymptomatic and may become very large before the patient seeks any attention. Occasionally, nodules or internal malignancy develops.

More dramatic are those basal cell carcinomas that metastasize or are so invasive locally as to destroy vital structures. These are rare—fewer than 100 cases have been reported.[2,3] Eighty-five percent of them occur on the head and neck. They are slow-growing, but relentless and recalcitrant to radical surgery and irradiation. The "ulcus terebrans" variety may involve most of the scalp and invade, through bone, into the leptomeninges.[4-7] Lesions on the face may invade through the orbit, sinuses, or large vessels of the neck. Much less common are large invasive lesions of the back and extremities. All are ulcerative and penetrate deeply.

Metastasis occurs most frequently in regional lymph nodes, and next most often in the lungs. Such developments from tumors of the head and neck may be related to implantation. The frequencies of liver and bone metastasis are almost equal.

The lesion in case 4 is a giant rodent ulcer. It was an isolated, long-standing tumor, ulcerative and invasive from onset. The patient had no history of arsenic ingestion. At the time she sought medical treatment, the lesion was inoperable and metastasis to regional lymph nodes had occurred. During the course of observation, bony metastases were observed. On the patient's last visit, pulmonary metastasis was suspected. The tumor has been resistant to irradiation and chemotherapy, though some improvement occurred with methotrexate.

Cases 1, 2, and 3 are unique, and we could find no similar tumors in the English literature. Duperrat's vegetative basal cell carcinoma[8] and Degos' forme bourgeonnate et vegetante[9] may be similar lesions. Petres and Hagedorn[10] included a similar-appearing tumor in their discussion of surgical management of large epitheliomas but did not mention its histologic type. Characteristically, the lesions described in the literature have been exophytic and verrucous. They are contained within the dermis. Recurrences after excision have been at the periphery, not under the flaps or grafts. Except for mild stable iron-deficiency anemia, these tumors have not affected the health of the host. The inflammatory response to them is not greater than for any other basal cell carcinoma. Our cases indicate that these lesions are isolated and not associated with other skin or visceral malignancy. The patients have no history of arsenical therapy. All do come from small, rural Midwestern communities. The distinct biologic nature of these tumors may be related to the characteristics of the tumor stroma,[11] as in fibroepithelioma; but the lesions do not show such a relation clearly. These rare tumors need to be recognized and treated early.

References

1. Castro C, Winkelmann RK: Spiradenoma: Histochemical and electron microscopic study. *Arch Dermatol* 109:40-48, 1974.

2. Costanza ME, Dayal Y, Binder S, et al: Metastatic basal cell carcinoma: Review, report of a case, and chemotherapy. *Cancer* 34:230-235, 1974.

3. Wermuth BM, Fajardo LF: Metastatic basal cell carcinoma: A review. *Arch Pathol* 90:458-462, 1970.

4. Midana A, Visetti M, Leigheb G: Deux cas d'épithéliomas baso-cellulaire du cuir chevelu avec envahissement ostéo-méningé, abstracted. *Bull Soc Fr Dermatol Syphiligr* 80:282-283, 1973.

5. Rizovsky R, Bourlond A, Mairesse M, et al: Epithelioma basocellulaire etendu de la nuque. *Arch Belg Dermatol Syphiligr* 30:263-268, 1974.

6. Weidner F, Stolte M: Multizentrisches metatypisches Kopfhautbasaliom (Typ Ulcus terebrans) mit Perforationen der Schädelkalotte. *Hautarzt* 25:68-72, 1974.

7. Wenig K: Discussion. *Hautarzt* 19:483-484, 1968.

8. Duperrat B: *Précis de Dermatologie*. Paris, Masson & Cie, 1959.

9. Degos R: *Dermatologie*. Paris, Flammarion, 1953, p 848.

10. Petres J, Hagedorn M: Zur operativen Therapie ausgedehnter Hauttumoren des Stammes. *Hautarzt* 25:566-569, 1974.

11. Van Scott EJ, Reinertson RP: The modulating influence of stromal environment on epithelial cells studied in human autotransplants. *J Invest Dermatol* 36:109-117, 1961.

Pathologic Findings in Human Scabies

Nilda Fernandez, MD; Antonio Torres, MD; A. Bernard Ackerman, MD

• **The histologic findings in the papular, vesicular, nodular, and Norwegian variants of scabies have in common a superficial and deep perivascular mixed inflammatory cell infiltrate of lymphocytes, histiocytes, and numerous eosinophils. A spongiotic vesicle occurs in the papulovesicular type, a dense cellular infiltrate in the nodular type, and a hyperkeratotic psoriasiform dermatitis in the Norwegian type. Eggs, larvae, and adult mites are abundant in the cornified layer of Norwegian scabies, are practically never found in biopsy specimens from lesions of nodular scabies, and are discovered only episodically in papulovesicular lesions.**
(*Arch Dermatol* 113:320-324, 1977)

Within the past few years there has been an explosion of cases of scabies in the United States.[1] Because the mite, *Sarcoptes scabiei*, evokes a variety of cutaneous lesions (macules, papules, vesicles, pustules, bullae, nodules, and scaling plaques) in different body sites, scabies can be confused with many other skin diseases. Biopsy specimens from cases of scabies sent to our pathology laboratory are rarely accompanied by notation of the clinical impression of scabies, but rather by diagnoses of dermatitis herpetiformis,[2] drug eruption, or insect-bite reaction. Pathologists often misread the histologic changes of scabies as those of drug eruptions, erythema multiforme, and even malignant lymphoma.[3] The present study was undertaken to alert dermatologists and pathologists to the pathologic changes of scabies.

Accepted for publication Nov 24, 1975.
From the Departments of Dermatology and Pathology, New York University School of Medicine. Drs Fernandez and Torres are now at the Dermatologic Institute, Santo Domingo, Dominican Republic.
Reprints not available.

MATERIALS AND METHODS

The material for this study came from biopsy specimens submitted to the Dermatopathology Laboratory of the New York University School of Medicine during the 22 months between July 1973 and May 1975. There were 26 cases of papulovesicular scabies, ten cases of nodular scabies and three cases of Norwegian scabies. For the diagnosis of the papulovesicular and Norwegian types of scabies, we required finding a mite or its eggs in the cornified layer; for the nodular type, other criteria obtained, namely, characteristic clinical lesions in a patient with scabies proven by positive scrapings from other papular or vesicular lesions. All specimens were processed in the routine fashion and were stained with hematoxylin-eosin. In most instances, step sections were made through the entire specimen.

RESULTS

The papulovesicular type of scabies, the most common manifestation of the infestation in human skin, typically showed a superficial and deep perivascular mixed inflammatory-cell infiltrate of lymphocytes, histiocytes, and numerous eosinophils (Fig 1). The eosinophils particularly were scattered among collagen bundles at all levels of the dermis. Occasionally, the inflammatory-cell infiltrate was found to extend into the subcutaneous fat. The overlying epidermis often showed a focus of spongiosis or spongiotic vesiculation, above which was a scale-crust composed of parakeratotic cells and homogenous eosinophilic material (serum) (Fig 2). Within this scale-crust it was possible to see the mite, egg shells, eggs with visible larvae, or feces. The papillary dermis was usually edematous. If the lesion had been excoriated, neutrophils could be found within the scale-crust and within the papillary dermis, where there were also extravasated erythrocytes. An uncommon finding was vasculitis, especially involving the blood vessels of the deep venular plexus. Here, inflammatory cells were present within the vessel wall, where there also was fibrillary eosinophilic material (fibrinoid). Infrequently, a mite could be found lodging within the cornified zone of a follicular infundibulum (Fig 3).

The papules of papulovesicular scabies are dome-shaped, pinkish-red, and range in size from pin point to 5 mm. Because of the intense pruritus, the papules are often eroded and covered by yellowish or hemorrhagic crusts, which are evidence of excoriations (Fig 4). The vesicles of papulovesicular scabies are tense and slightly elevated, being 2 to 3 mm in diameter.

We found, as others have,[4-6] that the burrows of scabies are formed principally within the cornified layer (Fig 5). Orthokeratotic and some parakeratotic cells constituted the roof of the burrow and most of the floor, but in some foci the head of the mite

extended into the spinous zone, where there often was spongiosis. The epidermis beneath the burrow was usually hyperplastic. The inflammatory-cell changes within the dermis beneath burrows were the same as in other lesions of papulovesicular scabies.

The burrow is a fine, curved, slightly elevated track 3 to 15 mm long. A small papule or papulovesicle at one end of the burrow marks the site of the mite within the cornified layer.

Nodular scabies showed dense inflammatory-cell infiltrates of lymphocytes, histiocytes, plasma cells, eosinophils, and atypical mononuclear cells (some in mitosis) arranged predominantly around thickened blood vessels throughout the dermis and sometimes around blood vessels in subcutaneous fat (Fig 6). Inflammatory cells were also present among the collagen bundles. The papillary dermis was usually thickened by coarse collagen fibers associated with increased numbers of plump, stellate, and multinucleated fibroblasts. Frequently, vasculitis with fibrinoid and inflammatory cells was present within dermal blood vessel walls. Sometimes thrombi occluded the lumina of these vessels. Extravasated erythrocytes were found in the connective tissue around such blood vessels. The overlying epidermis was usually hyperplastic and hyperkeratotic. Mites, their eggs, or excreta were rarely found in the cornified layer of nodular lesions of scabies.

Nodular lesions of scabies are firm, elevated, round or oval, and vary from bright red at the outset to brownish-red and eventually to dark brown (Fig 7). Nodular lesions of scabies may persist for months and even years.[7-10]

Norwegian scabies was characterized by massive orthokeratosis and parakeratosis within and between which great numbers of mites resided (Fig 8). The mites could be seen in all stages of development: adult, larval, and egg (some containing visible larvae). Adult mites are considerably larger than larval ones. Fecal material was strewn throughout the cornified layer appearing as lumps of brown granular material. In addition, homogeneous eosinophilic material (serum) and RBCs were also seen within the cornified layer. The remainder of the epidermis was substantially psoriasiform and usually hypergranular. Foci of spongiosis, spongiform pustules, and neutrophilic abscesses (Fig 9) were seen within the spinous zone. These changes were usually found in close proximity to the mite or its eggs. Mitotic figures were usually increased in the basal and spinous zones. The papillary dermis was thickened by vertically streaked collagen oriented perpendicular to the surface of the specimen and parallel to the rete ridges, and there was an increased number of dilated, somewhat thick-walled capillaries. A superficial and deep perivascular lymphohistiocytic infiltrate with numerous plasma cells, eosinophils, and neutrophils sur-

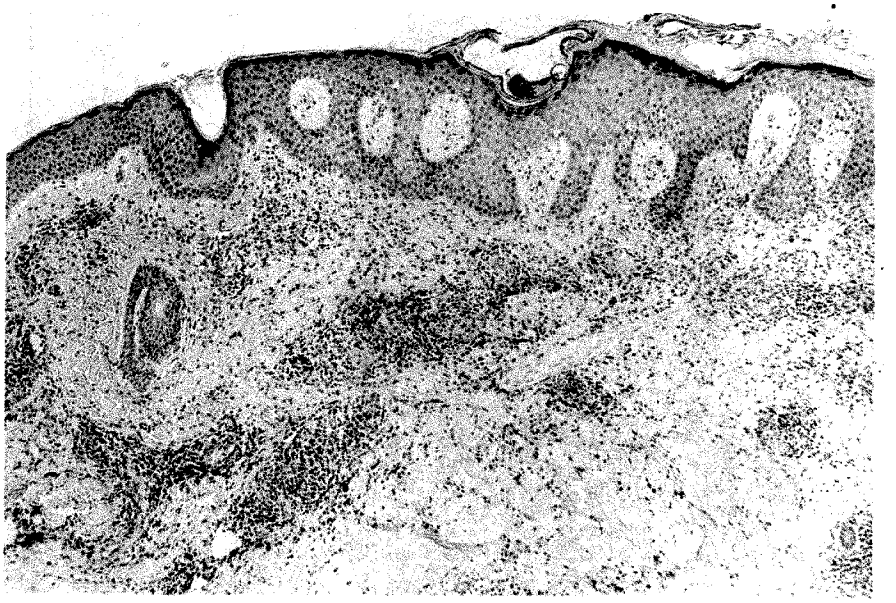

Fig 1.—Inflammatory-cell infiltrate in papular lesions of scabies consists of lymphocytes, histiocytes, and eosinophils arranged around blood vessels of both superficial and deep plexuses and scattered between collagen bundles. Note larva-containing egg in cornified layer (hematoxylin-eosin, original magnification ×90).

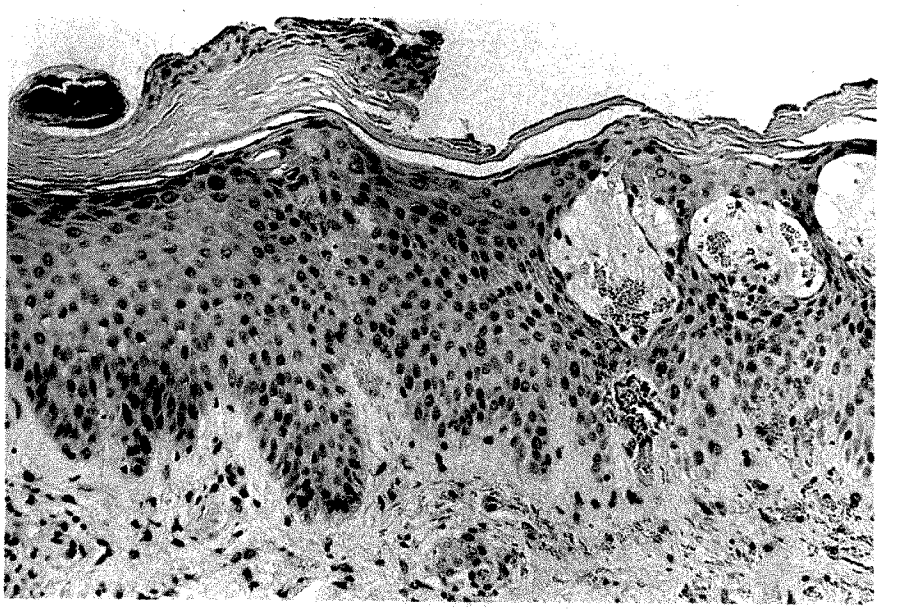

Fig 2.—Vesicular lesions of scabies result from spongiotic vesicles. Egg is present within cornified layer on left (hematoxylin-eosin, original magnification ×240).

Fig 3.—Mite of scabies nestled within a follicular infundibulum (hematoxylin-eosin, original magnification ×340).

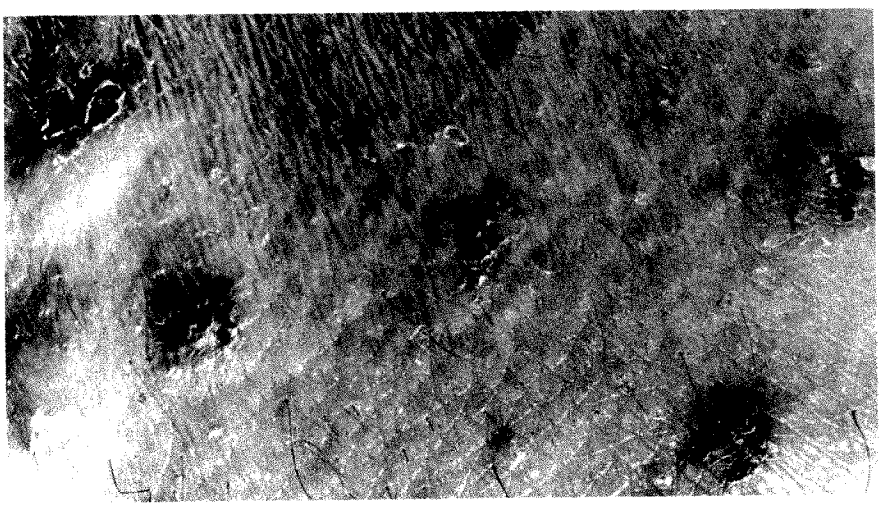

Fig 4.—Papular and vesicular lesions of scabies, some eroded and covered by scale-crusts secondary to excoriations.

Fig 5.—Scabietic burrow within cornified layer contains eggs and feces (hematoxylin-eosin, original magnification ×460).

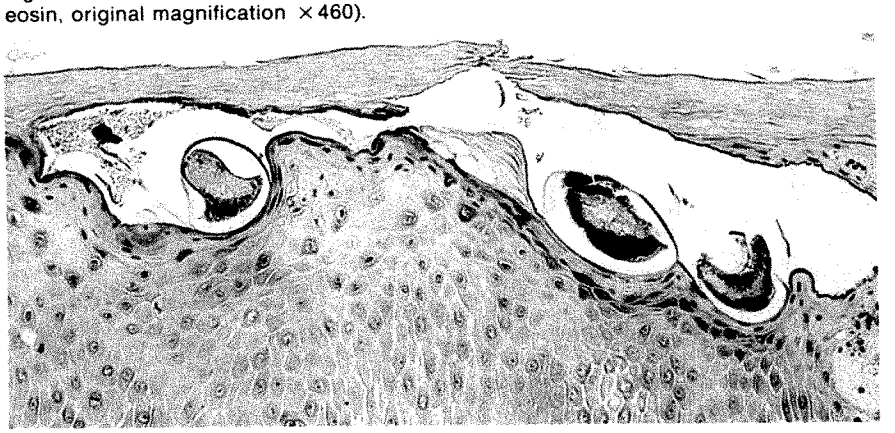

Fig 6.—Nodular lesions of scabies showing predominantly perivascular dense inflammatory-cell infiltrate composed of lymphocytes, histiocytes, plasma cells, and eosinophils. Cells extend among collagen bundles and sometimes into subcutaneous fat (hematoxylin-eosin, original magnification ×50).

Fig 7.—Nodular lesions of scabies on genital skin.

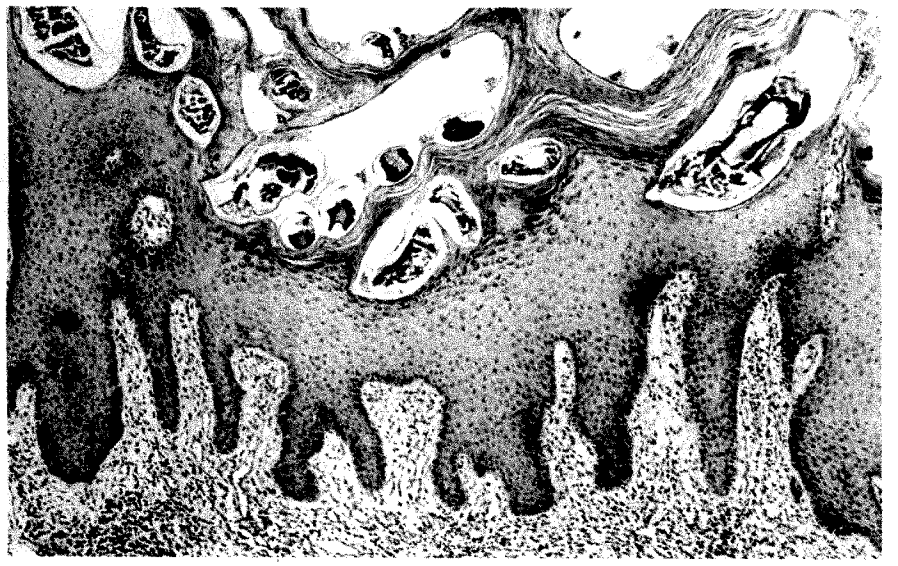

Fig 8.—Norwegian scabies, showing myriad mites, eggs, and fecal deposits throughout substantially thickened cornified layer that surmounts a psoriasiform dermatitis (hematoxylin-eosin, original magnification ×160).

Fig 9.—Intraepidermal pustules are contiguous to mites or their eggs. Norwegian scabies (hematoxylin-eosin, original magnification ×240).

Fig 10.—Widespread scaly plaques dotted by pustules and hemorrhagic crusts in typical lesions of Norwegian scabies.

rounded the blood vessels at all levels of the dermis, but especially the upper half. Norwegian scabies, also named "crusted scabies," is characterized by thick, scaly, crusted, whitish-yellow plaques (Fig 10).[11-17]

COMMENT

With the rising incidence of scabies, dermatologists and pathologists have been confronted with diagnostic problems regarding the gross and microscopical features of the disease. Clinically, scabies can mimic a variety of other conditions, most notably dermatitis herpetiformis.[2] Histologically, papulovesicular scabies has been misinterpreted as drug eruptions or erythema multiforme[18] and nodular scabies as malignant lymphoma.[3]

The histologic concomitants of the papulovesicular lesions of scabies are a superficial and deep perivascular lymphohistiocytic infiltrate with eosinophils, the cells also being scattered among collagen bundles at all levels of the dermis, but especially the upper half, and sometimes extending into the subcutaneous fat. The papillary dermis is usually edematous. Focal intracellular and intercellular edema may eventuate in an intraepidermal vesicle. Vasculitis occurs in some instances. These histologic changes of papulovesicular lesions of scabies are indistinguishable from those of other arthropod-bite reactions, such as mosquitoes and bed bugs. The larva of creeping eruption induces histologic changes that cannot be differentiated from those produced by the mite in papulovesicular scabies and other acute arthropod reactions.

The histologic findings in papulovesicular scabies are not comparable to those of any drug eruption nor should they be confused with erythema multiforme. There are many different cutaneous histologic expressions of reactions to drugs such as urticarial, fixed, and bullous, but none of them produces the dermal and epidermal changes that are seen in papulovesicular scabies. Unlike the histologic appearance of papulovesicular scabies, erythema multiforme consists of an inflammatory-cell infiltrate of lymphocytes and histiocytes that involves the vessels of the superficial plexus only. There are practically no eosinophils or neutrophils in the infiltrate of erythema multiforme. In addition, the

epidermal changes of erythema multiforme, consisting initially of individual necrotic keratinocytes and eventually of confluent epidermal necrosis, are entirely different from the usual epidermal changes of scabies.[19]

When the dermal changes common to papulovesicular scabies, other arthropod-bite reactions, and creeping eruption are noted, the next step should be to search the cornified layer for an adult mite, its larvae, eggs, or feces. If these are not found, more sections should be made through the specimen in an attempt to find them. Unfortunately, even in a patient with scabies proven by scraping, it may not be possible to find the mite in every random biopsy specimen.

Nodular scabies (persistent nodules in scabies) is characterized by a dense superficial and deep perivascular, predominantly lymphohistiocytic infiltrate with numerous plasma cells and eosinophils. These cells are also scattered among collagen bundles. The papillary dermis is thickened by coarse collagen fibers associated with stellate and multinucleate fibroblasts. Vascular changes may be present in the form of thickened blood-vessel walls with plump endothelial cells, and there may even be vasculitis. The mite and its parts are rarely seen in the cornified layer of nodular scabies. This is not to be taken to mean that they were not originally present, but that because of the long-standing nature of these nodular lesions, the mite has been either eliminated by therapy or by scratching. The histologic features of nodular scabies favor an inflammatory, rather than neoplastic, process: the infiltrate is always more dense in the upper rather than the lower portion of the dermis, the infiltrate is mixed, the blood vessels are increased in number, and their walls are altered by thickening and sometimes by vasculitis. There are two types of malignant lymphoma with mixed-inflammatory infiltrates, namely, Hodgkin disease and mycosis fungoides. Unlike Hodgkin disease, nodular scabies does not have Reed-Sternberg cells, and unlike mycosis fungoides, atypical mononuclear cells are not present within the epidermis. The histologic differential diagnosis of nodular scabies includes long-standing granulomatous reactions to arthropod bites.

The histologic signs of papillary dermal thickening by vertically streaked coarse collagen fibers associated with numerous stellate and multinucleate fibroblasts are evidence of active fibroplasia in a lesion that has been chronically rubbed (lichen simplex chronicus, prurigo nodularis).[20] Rubbing is surely one contributing factor to the development of nodular lesions in scabies. Another factor is the special skin of the genital region that seems to respond to the mite with a more vigorous inflammatory reaction and subsequent nodule formation, rather than by papules and vesicles.

Norwegian scabies is characterized by psoriasiform dermatitis that involves the blood vessels of both plexuses and consists of perivascular mixed inflammatory-cell infiltrate of lymphocytes, histiocytes, neutrophils, plasma cells, and eosinophils. The papillary dermis is thickened by a vertically streaked collagen, another sign of long-standing rubbing. The most dramatic change involves the cornified layer, which the mites abound within. Layered in tiers throughout the cornified layer are adult mites, larvae, eggs containing larvae, egg shells, and nuggets of feces. In addition, serum and extravasated erythrocytes are frequently present within this cornified layer. Beneath the cornified layer, there are frequently spongiotic and pustular foci. In sum, the histologic changes of Norwegian scabies are unique, not to be confused with any other psoriasiform dermatitis.

Because of its extraordinarily varied clinical and histologic characteristics, syphilis has often been termed the great imitator. The same can be said for scabies.

William George, MD, contributed two cases of Norwegian scabies, and Roger Stewart, MD, submitted five cases of nodular scabies.

References

1. Orkin M: Today's scabies. *JAMA*. 233:882-885, 1975.
2. Ackerman AB, Stewart R, Stillman M: Scabies masquerading as dermatitis herpetiformis. *JAMA* 233:53-54, 1975.
3. Thomson J, Cochrane T, Cochran R, et al: Histology simulating reticulosis in persistent nodular scabies. *Br J Dermatol* 90:421-429, 1974.
4. Heilesen B: Studies on acarus scabiei and scabies. *Acta Derm Venereol* 26(suppl 14): 1946.
5. Mellanby K: *Scabies*. Middlesex, England, EW Clasey Ltd, 1972.
6. Unna PG: The histopathology of the diseases of the skin. Edinburgh, WF Clay, 1896.
7. Ayres S Jr, Anderson NP: Persistent nodules in scabies: Histologic observations and treatment. *Arch Dermatol Syphilol* 25:485-493, 1932.
8. Berge T, Krook G: Persistent nodules in scabies. *Acta Derm Venereol* 47:20-24, 1967.
9. Cremer G: Large papules in scabies, abstracted. *Year Book of Dermatology*, Chicago, Year Book Medical Publishers, 1948, pp 357-359.
10. Grant PW, Keczkes K: Persistent nodules in scabies. *Arch Dermatol* 89:239-242, 1964.
11. Burks JW, Jung R, George WM: Norwegian scabies. *Arch Dermatol* 74:131-140, 1956.
12. Calnan CD: Crusted scabies. *Br J Dermatol* 62:71, 1950.
13. George WM: Norwegian scabies. *Arch Dermatol* 78:320-324, 1958.
14. Haydon JR, Caplan RM: Epidemic scabies. *Arch Dermatol* 103:168-173, 1971.
15. Rook A, Wilkinson DS, Ebling FJ: *Textbook of Dermatology*, ed 2. London, Blackwell Scientific Publications, 1972, vol 1, pp 869-874.
16. Wells GG: Norwegian scabies. *Br Med J* 2:18, 1952.
17. Wishart J: Norwegian scabies: A Christchurch epidemic. *Aust J Dermatol* 13:127, 1972.
18. Hejazi N, Mehregan AH: Scabies: Histological study of inflammatory lesions. *Arch Dermatol* 111:37-39, 1975.
19. Ackerman AB, Penneys NS, Clark WH Jr: Erythema multiforme exudativum: Distinctive pathological process. *Br J Dermatol* 84:554-566, 1971.
20. Reed RJ, Ackerman AB: Pathology of the adventitial dermis. *Hum Pathol* 4:207-217, 1973.

Bullous Disease of Childhood

Report of a Case Demonstrating Antibasal Cell Antibody

Edward Shmunes, MD, Suyu Shu, PhD

• This report describes a child with protracted bullous disease responsive only to high doses of steroids, who on immunofluorescent testing, consistently displays antibasal cell antibody. The child had been treated with penicillin a week prior to the development of the bullous disease. The etiologic possibility of this drug history in the evolution of the bullous disease is raised, with particular respect to recent reports of similar circulating antibody in drug reactions.

(*Arch Dermatol* 113:325-327, 1977)

Childhood bullous diseases have given rise to nosologic confusion due to their varying response to sulfones and sulfapyridine, usually negative results from immunofluorescent studies, and histologic patterns no more characteristic than subepidermal bulla formation.[1] Jordon et al[2] suggested the name "benign chronic bullous dermatosis of childhood" as perhaps a more fitting designation than either bullous pemphigoid of childhood or bullous dermatitis herpetiformis of childhood, when this constellation of clinical and laboratory tests occurred in a child with bullous disease.[2] A shortened form "bullous disease of childhood" has persisted and appeared in society transactions.[3] In 1974, Bean and Jordon[4] included this entity along with bullous pemphigoid, dermatitis herpetiformis, and pemphigus, labeling this group "chronic nonhereditary blistering disease in children." The following case report describes a child with protracted bullous disease responsive only to high doses of steroids, who on immunofluorescent testing, consistently displays antibasal cell antibodies.

Accepted for publication Jan 23, 1976.

From the Columbia Skin Clinic, Columbia, SC (Dr Shmunes), and the Department of Microbiology, State University of New York at Buffalo (Dr Shu).

Read before the Section on Dermatology at the 124th annual convention of the American Medical Association, Atlantic City, NJ, June 14, 1975.

Reprints not available.

REPORT OF A CASE

A 5-year-old boy developed a generalized bullous dermatitis one week following a penicillin injection in July 1973. The penicillin had been given by another physician because of a severe purulent dermatitis of his legs characterized by boils that had been spreading rapidly over a seven-day span. The child had previously been in good health.

Physical findings at the time of hospital admission revealed the patient to be febrile, uncomfortable, and covered with tense bullae over the arms, legs, trunk, face, and scalp. The lower left leg was covered with a confluent purulent crust, which at its periphery showed many tiny, tense bullae. The satelliting phenomenon was evident around resolving older lesions and in other areas as well. Mucosal surfaces were spared (Fig 1).

Results of the following laboratory studies were within normal limits: sickle cell preparation, the VDRL test for syphilis, antistreptolysin titer, blood culture, urinalysis, hemoglobin, glucose 6-phosphate dehydrogenase, hematocrit, and stool examinations for ova and parasites. The WBC count was elevated at 11,000/cu mm and showed 71 neutrophils, 20 lymphocytes, 4 monocytes, and 5 eosinophils on differential cell count. Serum protein electrophoresis showed slightly elevated α_2 and γ-globulin fractions. Bacteriological culture from a purulent lesion on the leg produced mixed growth of a coagulase positive *Staphylococcus*, *Enterococcus*, and *Proteus vulgaris*. Viral cultures of blister fluid failed to produce isolates in three host systems.

A biopsy specimen of an early bullous lesion from the back revealed a subepidermal vesicle showing a mixture of many neutrophils, eosinophils, and lymphocytes. The underlying dermis showed prominent perivascular infiltrate around capillaries and veins.

Course

The patient failed to respond to tub baths and systemic antibiotics. His condition was finally controlled and he was discharged on a regimen of 40 mg of prednisone daily.

Attempts to taper prednisone dosages slowly, 5 mg weekly, were met with flares of bullae, particularly on the legs at ranges at or below 30 mg daily. Attempts to slowly switch to alternate day therapy were also met with similar flares. During periods of

good control, he was placed on separate trials of dapsone, 50 mg daily, and sulfapyridine, 1 gm daily, with new efforts made to reduce prednisone dosage. Neither sulfapyridine nor dapsone at the dosages given altered his need for prednisone and during the first year, levels of 50 mg daily were necessary to achieve control. Poor social conditions resulted in suprainfection with β-hemolytic streptococci on two occasions, necessitating prophylactic penicillin therapy.

Oral administration of erythromycin was used initially, but oral administration of penicillin was given by another physician with control of the secondary infection without a resultant flare in the bullous disease. By July of 1974, the child was able to be tapered down to 10 mg of prednisone daily and in June of 1975, prednisone was discontinued without exacerbation.

Fig 1.—Older bullous lesion with satelliting.

Immunofluorescence Studies

A serum specimen was submitted for indirect immunofluorescence during the initial hospitalization. This was repeated along with direct immunofluorescent studies from both involved and uninvolved skin five months later. The direct immunofluorescent testing included testing for specific deposits of IgG, IgA, IgM, and C4.

Results

The initial indirect immunofluorescent with patient's serum on monkey esophagus sections revealed only a trace of basal cell antibody. On repeat examination five months later and while receiving 50 mg of prednisone daily, the child had a basal cell antibody titer of 1:20. This pattern of staining is shown in Fig 2. There was no basement membrane or intercellular fluorescence as in cases of bullous pemphigoid and pemphigus. Direct immunofluorescent studies of both involved and uninvolved skin failed to reveal any fluorescent patterns.

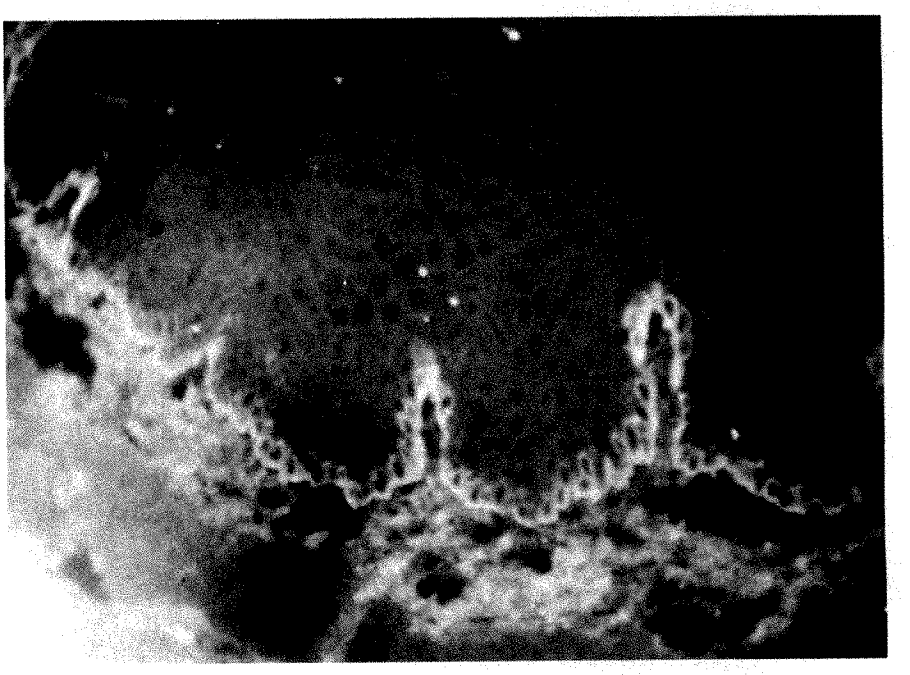

Fig 2.—Antibasal cell fluorescence pattern in patient's serum.

COMMENT

Immunoglobulin deposits in and/or on basal cells of skin have been reported on direct immunofluorescent study in drug related eruptions. Stein et al[5] reported basal cell immunofluorescence in drug induced toxic epidermal necrolysis in two patients due to penicillin and chloropromazine, respectively. Shelley et al[6] demonstrated intercellular fluorescence in the basal cell layer and the two to three adjacent suprabasilar cell layers in a patient with a bullous fixed drug eruption due to phenolphthalein. In both reports no circulating antibasal cell antibody could be detected by indirect immunofluorescence. It is possible that the direct immunofluorescence observation may represent deposits of immunoglobulin in this area secondary to the drug reaction process rather than antibody to the basal cell layer. The failure to detect circulating antibody in these instances is noteworthy.

Fellner and Prutkin[7] reported indirect immunofluorescent studies demonstrating circulating epithelial intercellular antibodies in two patients with morbilliform eruptions due to penicillin. More recently, van Joost[8] described that in 35 cases of drug reaction examined, 7 had circulating antibodies reactive with basal cells of skin of both human and guinea pig with the exception of 1 that did not react with human skin. Direct immunofluorescence tests performed on skin biopsies in four cases revealed in vivo bound immunoglobulins and complement in and/or on basal cells in the erythematous area only in one case

that had the highest titer of demonstrable antibasal cell antibody in the circulation.

In 1974, van Joost et al[9] also reported a case of a well documented drug induced skin reaction caused by phenylbutazone characterized by erythematous papules and nodules with some bulla formation. The duration of the reaction after stoppage of the offending drug was five weeks. The indirect immunofluorescent technique showed circulating IgG class antibodies reactive with the cytoplasm and membrane of basal cells of three different stratified epithelial substrates including guinea pig lip, monkey esophagus, and normal human skin. They also reported the circulating basal cell antibodies were able to fix complement in vitro. Direct immunofluorescent technique of lesions in their patient showed IgG deposits in and around vessel walls and some areas of the basal cell layer.[9]

In a few patients with bullous pemphigoid or pemphigus, immunofluorescent studies reveal both basal cell and basement membrane zone antibodies or intercellular antibodies, and sometimes the former interfere with the detection of the disease antibody (T. Chlorzelski, oral communication, 1975). In these cases, direct immunofluorescent studies are corroborative.

Bean et al[10] were the first to demonstrate that some children with bullous disease have circulating antibodies to the basement membrane, supporting the concept that some of these children represent a juvenile counterpart to adult bullous pemphigoid. This has been subsequently confirmed in other selected cases, though the majority of these children with a virtually identical histopathological picture fail to give positive immunofluorescent reaction.

Jablonska et al[11] demonstrated that a small portion (two of eight patients studied) may show deposits of IgA in the papillae around the lesions on direct immunofluorescence. On the eight children studied, the two with deposits of IgA were the only two children with papular lesions only, as opposed to bullous and papular lesions. Only one of the children was responsive to sulfapyridine or sulphones.[11] Thus, another small fraction of clinical bullous disease of childhood may correspond fully to the adult form of dermatitis herpetiformis.

In our patient, the indirect immunofluorescent studies were consistently positive, even on moderately high doses of steroids. The patient's clinical course has been protracted and he has been responsive to steroids only.

The demonstration of circulating antibasal cell antibody in our patient's sera, directed against monkey esophagus, is puzzling. We were unable to demonstrate auto-reactivity, or reaction with the basal cells of monkey skin. Under fluorescent microscope, the antibody appeared to be directed against cytoplasm of basal cells rather than against cell surface or intercellular area.

Though demonstration of such interior antigens has been considered questionably significant, it may bear diagnostic value in the future. The report of van Joost[8] of similar antibody in drug reactions is particularly interesting in that our patient had a history of an intramuscular dose of penicillin one week before his eruption.

With the newer information on basal cell antibodies in drug reactions, one might be tempted to classify this case report as a drug reaction. The clinical course over a two-year period as well as the clinical presentation is similar to those cases described as bullous disease of childhood. Were it not for the positive indirect immunofluorescence directed against an interior antigen that is little understood, it would remain lumped within that group. It would appear more fitting clinically to classify this case report as bullous disease of childhood.

Judging from available information, the basal cell antibodies are at least not disease specific. Their role in the process of pathogenic changes is still not clear. Clinical correlation, particularly within the group of bullous diseases of children, appears to warrant further investigation.

References

1. Kim R, Windelmann RK: Dermatitis herpetiformis in children: Relationship to bullous pemphigoid. *Arch Dermatol* 83:895-902, 1961.
2. Jordon RE, Bean SF, Trifthauser CT, et al: Childhood bullous dermatitis herpetiformis. *Arch Dermatol* 101:629-634, 1970.
3. Griesemer RD: Bullous disease of childhood. *Arch Dermatol* 104:454, 1971.
4. Bean SF, Jordon RE: Chronic nonhereditary blistering disease in childhood. *Arch Dermatol* 110:941-944, 1974.
5. Stein KM, Schlappner OLA, Heaton CL, et al: Demonstration of basal cell immunofluorescence in drug induced toxic epidermal necrolysis. *Br J Dermatol* 86:246-252, 1972.
6. Shelley WB, Schlappner OLA, Heiss HB: Demonstration of intercellular immunofluorescence and epidermal hysteresis in bullous fixed drug eruption due to phenolphthalein. *Br J Dermatol* 86:118-125, 1972.
7. Fellner JJ, Prutkin L: Morbilliform eruption caused by penicillin. *J Invest Dermatol* 55:390-395, 1970.
8. van Joost T: The incidence of circulating antibodies reactive with basal cells of skin in drug reactions. *Acta DermVenereol* 54:183-188, 1974.
9. van Joost T, Ashgar SS, Cormane RH: Skin reactions caused by phenylbutazone. *Arch Dermatol* 110:929-933, 1974.
10. Bean SF, Good RA, Windhorst DB: Bullous pemphigoid in an 11-year-old boy. *Arch Dermatol* 102:205-208, 1970.
11. Jablonska S, Chlorzelski T, Beautner EH, et al: Juvenile dermatitis herpetiformis in the light of immunofluorescent studies. *Br J Dermatol* 85:307-313, 1971.

Pseudofolliculitis Capitis

Maj James D. Smith, MC, USA, Lt Col Richard B. Odom, MC, USA

• Pseudofolliculitis of the bearded area is a common dermatoses among black men. Acne keloidalis probably represents this same condition, but is located in the nape area. Pseudofolliculitis of the pubic area (pseudofolliculitis pubis) has been reported. We wish to report pseudofolliculitis including the entire scalp and to add the term *pseudofolliculitis capitis* for this heretofore unreported entity.

(*Arch Dermatol* 113:328-329, 1977)

Pseudofolliculitis barbae is a well recognized entity that most often occurs in the bearded area of black men who regularly shave their faces, necks, and submental areas.[1] Alexander[2] reported this same condition in a woman with familial facial hirsutism. He also reports its occurrence in the pubic area (pseudofolliculitis pubis) of a woman who shaved the area of involvement for cosmetic reasons. Acne keloidalis most likely represents this same condition on the nape of the neck.[3] Strauss and Kligman[4] reported the basic etiological factor to be a curved ingrown hair eliciting a foreign body response.

We recently have observed severe pseudofolliculitis of the scalp of four brothers and propose the term *pseudofolliculitis capitis* for this heretofore unreported condition.

REPORT OF CASES

Four black brothers, 10, 9, 8, and 6 years old, had "scalp problems" when they came to the pediatric dermatology clinic of our hospital. Two weeks prior to their clinic visit their father had shaved the entire scalp of each individual using a straight razor with shampoo as a lathering agent. There was no apparent irritation from this process until approximately one week later when the two older patients complained of tender scalps.

There was no history of scalp disease prior to or at the time the scalps were shaved. The father shaved their scalps because he felt they were not caring for their longer hair styles properly. Each had previously used the same shampoo repeatedly without apparent ill effects. None of the involved individuals had ever had their scalps shaved previously. There was no history of pseudofolliculitis barbae in the father.

The scalps of the older two individuals were edematous and slightly boggy, with myriads of erythematous papules covering the entire scalp. Each papule had a short hair embedded in its center. The hairs were coarse, tightly coiled, and in many locations both ends of the hair were anchored into the skin, thus producing a loop effect (Fig 1). A 27-gauge needle could be slipped under these loops and with minimal leverage the end from the inflammatory papule would spring free. Each had fine

Fig 1.—Scalp showing myriads of papules with ingrown hairs. Every hair is intraepidermal yet very shallow, thus, remaining visible through epidermis.

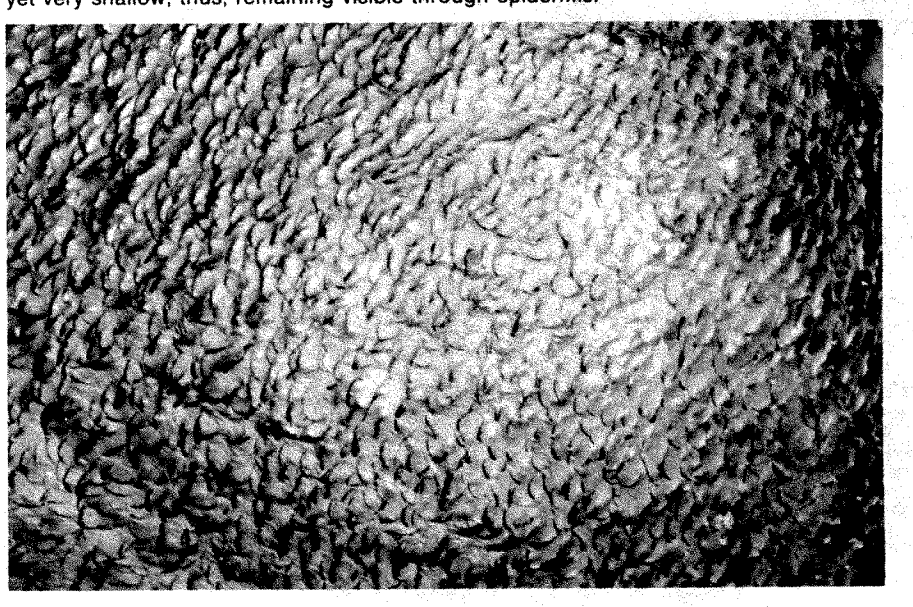

Accepted for publication Jan 16, 1976.

From the Department of Medicine, Dermatology Service, Letterman Army Medical Center, Presidio of San Francisco.

The opinions or assertions contained herein are the private views of the authors and are not to be construed as official or as reflecting the views of the Department of the Army or the Department of Defense.

Reprint requests to Technical Publications Editor, Letterman Army Medical Center, Presidio of San Francisco, CA 94129.



Fig 2.—Occiput area displaying fine superficial desquamation.

sheets of desquamated epidermis peeling from the occiput areas (Fig 2). A few discrete pustules were present as well as occasional small crusted areas. These two children had enlarged posterior cervical lymph nodes that were slightly tender to palpation. The two younger siblings had similar involvement localized to the occiput-nape area, but lacked lymphadenopathy.

A Wood's light examination showed no fluorescence. Results of potassium hydroxide preparations, fungal cultures, and bacterial cultures were normal.

The mother of the children was counselled regarding the pathogenesis of the problem. In view of the lymphadenopathy and crusting, each of the older patients was started on a regimen of erythromycin orally at a dosage of 250 mg three times daily. This was discontinued two days later when the bacterial cultures revealed only *Staphylococcus epidermidis*. Topical betamethasome valerate cream, 0.1%, was initiated with three daily applications. Tap water compresses were applied three times daily.

Approximately one week later the scalp of each boy was nontender. Within three weeks the individual hairs no longer penetrated the epidermis. None of the involved areas formed keloids. At three months follow-up each scalp appeared normal.

COMMENT

The pathogenesis, clinical course, and treatment of pseudofolliculitis have been amply elucidated in previous publications.[1-6] Unusual variants, such as pseudofolliculitis pubis,[2] have been documented. Certainly, black men, women, and children shave their scalps. In recent past years shaving the scalp was recommended as an integral step in the therapeutic regimen of tinea capitis. Despite these practices, it appears that pseudofolliculitis of this anatomical area has not been reported.

Several factors may have played a role in precipitating this event in the four brothers. The use of a straight razor to obtain a close shave was most likely an initiating factor. Razor shaving renders the cut end of the hair sharply pointed and facilitates reentry of the free end into the skin, thus, evoking a foreign body reaction that presents clinically as an inflammatory papule or pustule. The use of a shampoo as a lathering agent in all probability precipitated an irritant dermatitis as evidenced by the crusting and peeling scalp surface.

The fact that the patients were related certainly supports a genetic factor, as Alexander[2] proposed. We support the concept that pseudofolliculitis barbae is a genetic condition in that certain people inherit the characteristic of having curved hair follicles that produce curly and kinky hairs. These persons are thus predisposed to pili incarnati (ingrowing hairs). We have observed pseudofolliculitis barbae of a milder nature in white persons; thus, probably no race is excluded by this disease. Close shaving of the nape of these predisposed individuals initiates acne keloidalis nuchae. It seems quite reasonable that these same individuals would develop this process in the scalp, or for that matter, any site occupied by terminal hairs of a kinky, coarse character.

Pseudofolliculitis capitis is not common apparently, but the severity of the reaction in our patients warrants both medical and public awareness of its existence. One must agree with Alexander[2] that pseudofolliculitis knows no sexual or anatomical boundaries. We would add that pseudofolliculitis also respects no age limitations.

References

1. Munro DD: Disorders affecting the skin appendages, in Fitzpatrick TB, Arndt KA, Clark WH, et al, (eds): *Dermatology in General Medicine*. New York, McGraw-Hill Book Co, 1971, pp 329-330.
2. Alexander AM: Pseudofolliculitis diathesis. *Arch Dermatol* 109:729-730, 1974.
3. Mc Donald CJ: Dermatological problems in black skin, *Progress in Dermatology*. 1973, vol 7, No. 4, pp 15-20.
4. Strauss JS, Kligman AM: Pseudofolliculitis of the beard. *Arch Dermatol* 74:533-542, 1956.
5. Kenny JA: Management of dermatoses peculiar to Negroes. *Arch Dermatol* 91:126-129, 1965.
6. Craig GE: Shaving, its relationship to diseases of the bearded area of the face. *Arch Dermatol* 71:11-13, 1955.

Multicentric Reticulohistiocytosis

David R. Taylor, MD

• **Multicentric reticulohistiocytosis is a rare disorder of the skin and joints that possesses distinctive histologic findings. A case is reported from shortly after its onset to a stage of resolution 4½ years later.**

(*Arch Dermatol* 113:330-332, 1977)

Multicentric reticulohistiocytosis (MR) is rare and histologically unique disorder that was initially studied by Caro and Senear in 1932.[1] They described a patient with multiple cutaneous tumors and labeled the biopsy findings reticulohistiocytic granuloma. Their further studies disclosed that the cells that comprised the tumors were reticuloendothelial in origin, since they took up injected colloidal iron. Because the lesion resembled a granuloma, it was not believed to be neoplastic.[1] The first adequately described example of the systemic form of this disease was made in 1937 by Weber and Freudenthal.[2]

Allen's study of 8,000 cutaneous tumors during World War II attests to the rarity of the disorder, since only two cases of patients were reported with histologic examples of multinucleated giant cells. He referred to these tumors as reticulohistiocytomas.[3]

In 1954, Goltz and Laymon used the term "multicentric reticulohistiocytosis" to differentiate those patients who have the full-blown syndrome of cutaneous tumors and a definite arthritis from those who do not have arthritis and have only solitary or few cutaneous lesions.[4]

Since the 1950s, a limited number of case histories have been reported. On the basis of strict diagnostic criteria, Barrow and Holubar were able to identify only 33 cases in the world literature that could qualify as examples of MR.[5] Only patients with arthritis and biopsy-confirmed, characteristic cutaneous nodules fulfilled their diagnostic requirements. The disorder is little known to rheumatologists and orthopedists, although it is listed in the *Nomenclature and Classification of Rheumatic Disease*.[6] Most reports have been in the dermatologic literature.[7-9]

Accepted for publication Feb 20, 1976.

Dr Taylor is in private practice in Fresno, Calif.

Reprint requests to 1237 R St, Fresno, CA 93721 (Dr Taylor).

REPORT OF A CASE

A 40-year-old woman was in good health until April 1971, when she developed a diffuse, small nodular eruption of the face, upper aspect of the trunk, and upper extremities. Shortly thereafter she experienced arthritis of her finger joints, wrists, elbows, and knees. The cutaneous eruption was extremely pruritic, and her joints were hot, swollen, and painful. There had been no weight loss or fever at the time of her initial complaint. Her pruritus was increased when she was exposed to sunlight. There was no history of previous skin disease or recent drug intake.

On initial examination, the patient was found to have myriads of closely set, light brown, firm, small nodules involving the frontal hairline area, the upper aspect of the forehead, and the external ears. The V-shaped area of the sternum was solid with small, 0.2-to 0.5-cm nodules that produced a cobblestone effect (Fig 1). The upper portion of the back near the neck, the nuchal zone, and the occipital area also were involved. The forearms showed scattered, slightly larger lesions, and a few nodules were observed on the dorsa and sides of the fingers, with an isolated lesion involving the paronychial areas. The outer third of her eyebrows were sparse. The finger joints were painful, red, and swollen, especially the distal interphalangeal joints. The wrists, elbows, ankle joints, and knees showed inflammation of varying degree. The knee and ankle joints were the source of her greatest discomfort: however, she remained ambulatory.

A specimen for biopsy was removed, and a dermal histopathologist's interpretation was that the findings were inconclusive, but that sarcoidosis could be considered. The tissues were then submitted to another histopathologist, and he thought that the diagnosis of a zirconium granuloma should be entertained.

There was little change in her condition until May 1972, when her joint distress and cutaneous lesions became more pronounced. A second biopsy specimen from a lesion on the elbow was suggestive of giant cell reticulohistiocytoma. The slide was then sent to another dermohistopathologist, whose findings were as follows:

This specimen shows an essentially normal epidermis. The chief change is in the rather circumscribed, but not encapsulated accumulation of multinucleated giant cells having a large amount of ground glass cytoplasm. A few smaller histiocytes and lymphocytic inflammatory cells are interspersed between the giant cells. The changes are those of reticulohistiocytoma, or multicentric reticulohistiocytosis (Fig 2).

In June 1972 her knee became extremely painful and swollen and prevented her from walking. She was hospitalized, and the results of the physical examination were as follows: temperature, 38.3 C; pulse rate, 90 beats per minute; blood pressure, 140/70 mm Hg. The dermatologic findings showed pinkish, pearly nodules involving the mucosa of the lower lip and the right corner of the mouth. The nodular eruption was observed on the head, neck, upper part of the trunk, upper extremities, and the external auditory meati.

Marked limitation of the motion of the fingers, wrists, shoulders, knees, and ankles was noted. These joints were swollen, tender, and hot; the most notable swelling was observed on the left knee. A chest film was normal. X-ray films of her hands showed soft-tissue swelling and demineralization. A rheumatoid latex fixation test and a fluorescent antinuclear antibody test were negative. Results of a complete blood cell count and uric acid study were within normal limits. Blood chemistry determinations were normal, except for a serum cholesterol level of 280 mg/100 ml. The left knee was aspirated of a thick, cloudy fluid that contained a protein level of 4.2 gm/100 ml and 44,500 polymorphonuclear leukocytes. Cultures of the aspirated fluid were negative. Results of urinalysis were normal. The ESR was 34 mm/hr, and a VDRL test for syphilis was negative. Serum electrophoresis revealed a normal pattern, and the liver scan was normal. X-ray films of the left knee showed no abnormalities, except for the suggestion of fluid in the suprapatellar space.

The patient was treated with salicylates, diazepam, and 80 mg of prednisone every other day. Her condition improved rapidly, except for the cutaneous lesions, and she was discharged in an afebrile and ambulatory state after six days of hospitalization. The patient, on her own, discontinued the prednisone treatment because of vomiting. She continuously complained of severe

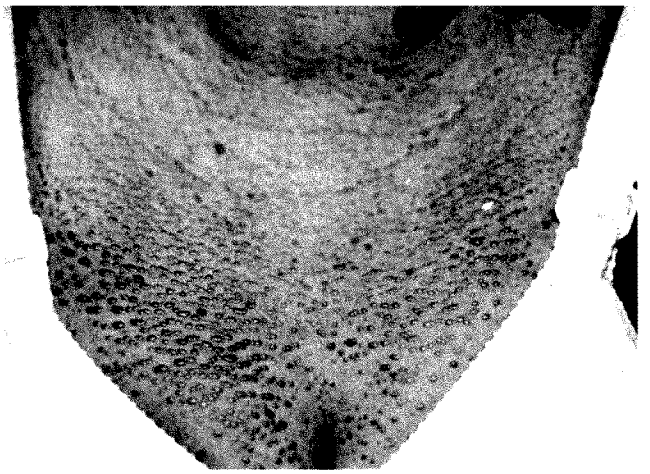

Fig 1.—Neck and V-shaped area of sternum showing numerous closely set, firm nodules in a cobblestone-like pattern.

Fig 2.—Same area as in Fig 1 showing marked clearing of eruption four years after onset.

Fig 3.—Biopsy specimen removed from lesion on elbow showing typical ground-glass-like eosinophilic cytoplasm with varying number of nuclei. Process is unencapsulated (hematoxylin-eosin, original magnification ×100).

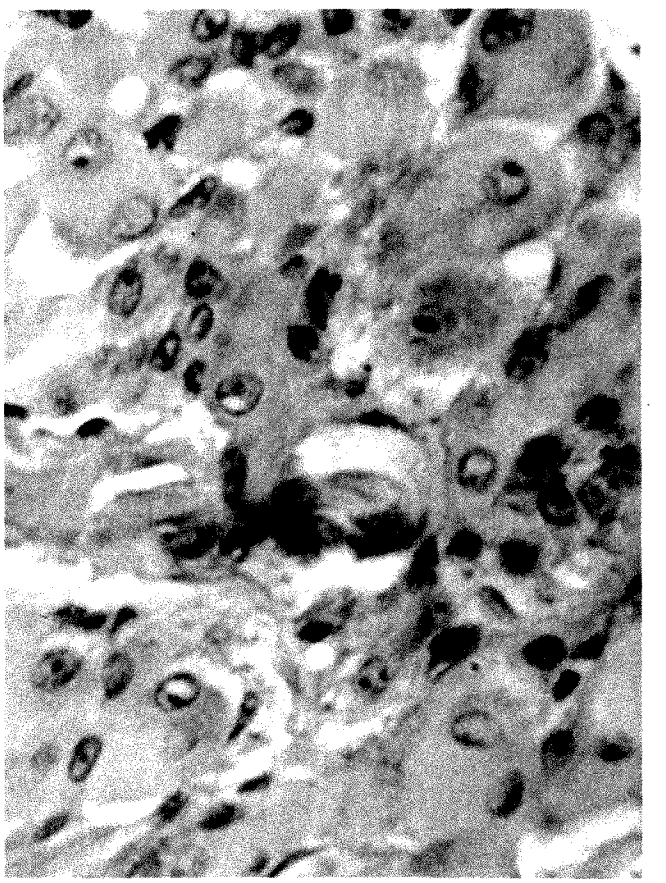

Fig 4.—Skin biopsy specimen showing large histiocytes and histiocytic giant cells with fine granular cytoplasm, vesicular nuclei, and prominent nucleoli (hematoxylin-eosin, original magnification ×400).

pruritus of her skin lesions and was given chlorpheniramine malleate orally, which gave her some relief.

One month later she sustained a myocardial infarction of the inferior wall and was hospitalized for seven days. After an uneventful recovery, she again was given prednisone to relieve her marked pruritus, along with oral chlorpheniramine. Because of increased joint distress and a flare of her cutaneous manifestations, the dosage of prednisone was increased to 40 mg per day. Following a family altercation, she took approximately 100 tablets of prednisone, but had no untoward effect as reported by her internist. The prednisone was then prescribed in smaller amounts, and an alternate-day schedule was stressed. The joint involvement gradually lessened; however, the cutaneous activity and her pruritic distress were more persistent. The joint distress was confined to mild swelling of her right ankle and was not incapacitating. In March 1974, xanthelasma palpebrarum was observed on the lids of both eyes, and a normal blood cholesterol level was determined. The xanthelasma disappeared without treatment. A second-strength purified protein derivative test was negative.

Her last examination in September 1975 disclosed no new nodules, and only a few lesions appropriate for biopsy were ob-

served on the nuchal zone. These lesions were in a state of resolution. A specimen from one was subjected to electron microscopy, and the findings were suggestive of a focal granulomatous inflammation and mild fibrosis consistent with a resolving MR. No dense bodies were seen in the tumor cells as was reported by Hashimoto and Pritzker,[9] but the specimen was from a resolving lesion.

COMMENT

The strikingly distinctive features of MR's histopathologic pattern are the presence of aggregates of histiocytic giant cells and histiocytes that can be found in the skin, synovia, and mucosa. Characteristic cellular infiltrations have even been reported in bone. The histiocytic multinucleated giant cells can be as large as 100 μ, and multiple nuclei, up to 20, can be observed. What sets the giant cells and the individual histiocytes off is the presence of a finely granular eosinophilic cytoplasm that has a ground-glass appearance. Giant cells in MR are of a foreign-body type, with the nuclei arranged in the cytoplasm haphazardly. However, peripheral alignment or central aggregation can occur. The nodular infiltrate can occupy the entire dermis and is unencapsulated. The mononuclear histiocytes constitute the other typical cellular component. They are usually oval or round, but can be irregular in size and shape. The cytoplasm is also eosinophilic and finely granular. Other cell types are lymphocytes, eosinophils, plasma cells, RBC, and fibroblasts. In younger lesions lymphocytes can form dense infiltrates. Fibroplasia may be the mode of regression because spindle cells are seen. The connective tissue stroma is pushed aside by the cellular masses, and the stroma becomes well vascularized. The epidermis is not directly invaded, but flattening and effacement of the rete ridges is noted. Histochemical studies indicate that the MR giant cells and histiocytes contain a PAS-reactive material, neutral fat, phospholipids, and iron. The PAS-positive substance, according to some investigators, may represent a mucoprotein or a glycoprotein.[5]

The clinical features of MR are visually impressive. Few or literally hundreds of small (2 to 10 mm wide) nodules may involve the head, neck, upper aspect of the trunk, and upper extremities. Typically, the fingers show nodules on the dorsal surfaces especially in the paronychial areas. The ears, bridge of the nose, and scalp are also frequent sites of distribution. The nodules range from flesh color to yellow and reddish brown. They can be pruritic (33%).[5] Mucosal surfaces have been involved in over half of the patients. Xanthelasma was reported to occur in one fourth of the patients studied by Orkin et al.[8] A leonine facies resulting from facial and paranasal nodulation can be seen in MR and could serve to confuse the disorder clinically with leprosy.

A symmetrical polyarthritis that was insidious in onset preceded the nodular eruption in nearly two thirds of the cases. Since women are affected more commonly than are men (3:1), the typical clinical picture is that of a middle-aged woman complaining of rheumatoid joint symptoms.[5] Large joints such as the knees, hips, and shoulders, as well as smaller joints, participate in the process. A clinically distinguishing feature of MR is destruction of the distal interphalangeal joints.[5] When this happens, along with destruction of other interphalangeal joints, a severely deformed hand results. Such a hand has short stubby fingers that amazingly can be stretched to their normal length. This clinical oddity has been referred to as the "accordion," or "concertina" hand.[5] One fifth of the patients have been reported to get a mutilating arthritis of the hands.[8] In four such cases, the latex, fixation tests were negative. The arthritis can be variable in its behavior, with some cases persisting, while others disappear. It does mimic rheumatoid arthritis. The cutaneous eruption cleared in one fourth of a series of patients, while it progressed in an equal percentage of patients.[8] The remainder either showed improvement or remained static. Weight loss was observed in some patients, and a small percentage became febrile. The ESR was moderately elevated, and 33% had an elevation of the serum cholesterol level.[5] Electrophoresis of serum proteins gave normal results, as did immunophoresis. Sternal marrow studies have been normal. Reactions to mumps, tuberculin, and *Candida* skin-test antigens revealed an intact delayed-hypersensitivity.[8]

If the skin is not carefully examined, MR can be easily confused with rheumatoid arthritis. The case presented demonstrates the classic findings of a serologically negative symmetric polyarthritis associated with a papulonodular eruption that is histologically distinctive. The patient also manifested the frequently associated findings of mucous membrane lesions and xanthelasma palpebrarum. The patient's cutaneous eruption, save for a few resolving scalp lesions and her joint disorder, have disappeared after it had been present for 4½ years. This is in contrast to Barrows and Holubar's report that their average patient maintained the dermatoarthritis for eight years.[5] Although the eruption has cleared, she still complains of pruritus of the previously involved sites.

It is difficult to evaluate the worth of the steroid therapy in this patient, although my impression is that it did not influence the basic pathological process. The patient is firm in her opinion that it did relieve the intense pruritus, which remained a constant complaint throughout the period of observation. Since the origin of MR remains obscure and since the majority of patients show self-resolution, the therapeutic management should be a conservative one, directed toward symptomatic relief. There is no satisfactory treatment for MR.

John D. Krafchuck, MD, and Robert W. Glotz, MD, rendered the histopathologic diagnosis.

References

1. Caro MR, Senear FE: Reticulohistiocytoma of the skin. *Arch Dermatol Syphilol* 65:701-713, 1952.

2. Weber PF, Freudenthal W: Nodular nondiabetic cutaneous xanthomatosis with hypercholesterolemia and atypical histologic features. *Proc Roy Soc Med* 30:522-526, 1937.

3. Allen AC: Survey of pathologic studies of cutaneous disease during World War II. *Arch Dermatol Syphilol* 57:19-56, 1948.

4. Goltz RW, Laymon CW: Multicentric reticulohistiocytoses of the skin and synovia. *Arch Dermatol Syphilol* 69:717-731, 1954.

5. Barrow MV, Holubar K: Multicentric reticulohistiocytosis: A review of 33 patients. *Medicine* 48:287-305, 1969.

6. Primer on rheumatic Diseases. *JAMA* 190:127, 425, 509, 741, 1964.

7. Holubar K, Mach K: Histiocytosis gigantocellularis: Ein beitrag zur klinik und histologie. *Hautarzt* 17:440-445, 1966.

8. Orkin M, Goltz RW, Good RA, et al: A study of multicentric reticulohistiocytosis. *Arch Dermatol* 89:640-654, 1964.

9. Hashimoto K, Pritzker MS: Electron microscopic study of reticulohistiocytoma: An unusual case of congenital, self-healing reticulohistiocytosis. *Arch Dermatol* 107:263-270, 1973.

Eruptions Due to Oral Contraceptives

Ralph J. Coskey, MD, FACP

• Three patients developed eruptions attributable to oral contraceptives. The eruptions of two of the patients resolved when the women discontinued the use of oral contraceptives. The third patient changed the type of oral contraceptive she was taking, and the eruption subsequently subsided.

(*Arch Dermatol* 113:333-334, 1977)

In 1971 I reported the cases of two women who developed an eruption secondary to the ingestion of oral contraceptives.[1] One of these patients had a papular eruption on the legs that histologically was compatible with toxic dermatitis or lymphocytic vasculitis. The other patient had a pigmented, lichenified, ecchymotic eruption on the forearms that on biopsy also showed toxic dermatitis or lymphocytic vasculitis. Both patients' eruptions resolved when the medication was discontinued. In this communication, I will describe three other women who developed dermatoses in the last three years that were attributable to the ingestion of oral contraceptives.

REPORT OF CASES

CASE 1.—A 40-year-old woman was seen on March 23, 1973 because of an erythematous, edematous, plaque-like, pruritic eruption of 13 months' duration that involved her forearms and left breast. She had been taking birth control tablets that contained 1 mg of ethynodiol diacetate and 0.1 mg of mestranol (Ovulen 21) for eight years. The eruption would always appear during the second week that she was taking the medication and would disappear at about the time she took the last tablet.

A diagnosis of a fixed drug eruption was made, and a biopsy specimen was obtained. Microscopical examination showed no important epidermal changes (Fig 1). The corium showed mild edema and a perivascular inflammatory cell infiltrate in a coat-sleeve-like fashion. The infiltrate consisted of mostly lymphocytes.

The patient discontinued the birth control medication for one menstrual cycle, during which time the eruption did not appear. However, she restarted the medication, and the dermatosis reappeared monthly until she discontinued the birth control medication after she had a tubal ligation in October 1973. The eruption disappeared, and it has not recurred since.

CASE 2.—A 20-year-old woman was seen on June 7, 1973 for a persistent, pruritic, lichenified, plaque-like eruption on the anterior aspects of her legs of two months' duration. She was taking an anovulatory agent that contained 1 mg of ethynodiol diacetate and 50 μg of ethinyl estradiol (Demulen 28). A diagnosis of a drug eruption was made, and a biopsy specimen was obtained. Microscopical examination of the tissue showed slight thickening of the epidermis, with hypergranulosis and hyperkeratosis (Fig 2). There were occasional small foci of minimal spongiosis and exocytosis, which lead to spotty parakeratosis. The corium showed a minimal perivascular infiltrate that consisted mainly of lymphocytes, a few histiocytes, eosinophils, and macrophages that contained melanin pigment granules. The findings were characteristic of lichen simplex chronicus or possibly a lichenoid form of drug eruption.

The eruption did not respond to topical application of 0.025% triamcinolone acetonide cream (Kenalog) or fluocinonide cream (Lidex). The patient discontinued the anovulatory agent in November 1974, and the eruption resolved in eight days. She was given an oral contraceptive agent that contained 1 mg of norethindrone and 0.08 mg of mestranol (Ortho-Novum 1/80) in December and has had no recurrence for the last nine months.

CASE 3.—A 20-year old woman was seen on Jan 10, 1975 because of an unremitting nummular pruritic dermatitic eruption on her neck, forearms, legs, and feet of two months' duration. Some of the lesions appeared to be infiltrated. She was taking an anovulatory agent that contained 0.5 mg of norgestrel and 0.05 mg of ethinyl estradiol (Ovral).

The eruption did not respond to treatment with 0.025% triamcinolone acetonide cream. Microscopical examination of a biopsy specimen taken on Jan 17, 1975 showed only a few small foci of mild spongiotic edema and some erosion of the lower border of the rete ridges by lymphocytes, leading to some loss of pigment into macrophages in the corium (Fig 3). The corium showed diffuse edema and a moderately heavy coat-sleeve-like perivascular inflammatory cell infiltrate that consisted largely of lymphocytes.

The patient discontinued the birth control medication on Jan 24, 1975, and continued to apply the triamcinolone acetonide cream. She was last seen on Jan 31, 1975, and the eruption had resolved.

COMMENT

There have been many cutaneous side effects reported secondary to the birth control medications. Chloasma probably is the most common.[2] If the medication is stopped, the pigmentation may or may not resolve.

Acne may improve after a woman takes an estrogen-dominant[3] oral contraceptive for three or four cycles, with an associated decrease in sebum production.[4] After the medication is taken for 12 months, a small percentage of women may develop an increase in sebaceous gland activity back to normal levels, with a corresponding flare in their acne.[4] When the medication is stopped, they may

Accepted for publication Feb 25, 1976.

From the Department of Dermatology, Wayne State University School of Medicine, Detroit.

Reprint requests to 23133 Orchard Lake Rd, Farmington, MI 48024 (Dr Coskey).

Fig 1.—Coat-sleeve-like perivascular lymphocytic infiltrate in corium (case 1) (hematoxylin-eosin, original magnification ×225).

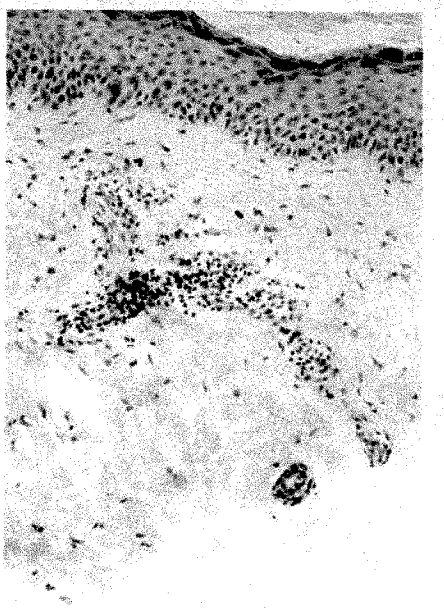

Fig 2.—Slight thickening of epidermis with perivascular infiltrate consisting primarily of lymphocytes (case 2) (hematoxylin-eosin, original magnification ×225).

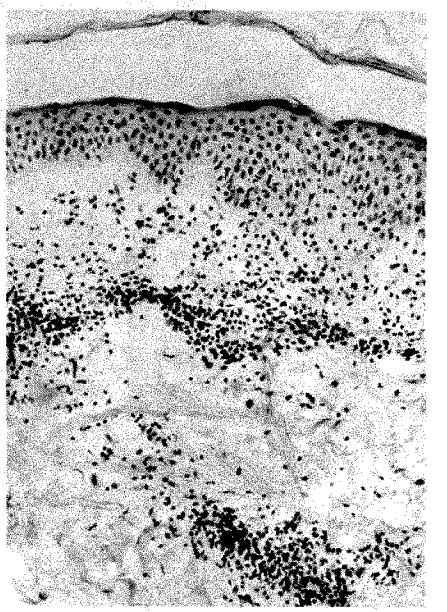

Fig 3.—Few foci of spongiotic edema and erosion of lower border of epidermal rete ridges by lymphocytes. Corium shows diffuse edema and coat-sleeve-like perivascular lymphocytic infiltrate (case 3) (hematoxylin-eosin, original magnification ×225).

also develop a flare of their acne due to increased sebaceous gland activity.[5]

Oral contraceptives also have been reported to cause the following cutaneous side effects: angioneurotic edema,[6] monilial vulvovaginitis,[7] photosensitivity,[8] herpes gestationis,[9] jaundice,[10] erythema multiforme,[11] hirsutism,[12] alopecia,[13] aggravation of porphyria variegata,[14] and porphyria cutanea tarda.[15-17] In addition, erythema nodosum,[18] acquired port-wine-colored marks,[19] purpura, and aggravation of hereditary hemorrhagic telangiectasia,[20] as well as telangiectasia and spider angiomas[21] have been reported.

The three cases I have described were compatible clinically with a fixed drug reaction, lichen simplex chronicus, and nummular eczema. Histologically, all three women showed changes that were compatible with a drug eruption. When the patients discontinued taking oral contraceptives, the eruptions disappeared within seven or eight days, which makes it very likely that the eruptions were due to the oral contraceptives. However, it is impossible to say if the estrogen, progestagen, or even the filler or dye in the tablet caused the dermatoses.

Amir Mehregan, MD, interpreted the histologic sections.

References

1. Coskey RJ: Cutaneous side effects of oral contraceptives. *Mich Med* 70:199-200, 1971.
2. Resnik S: Melasma induced by oral contraceptive drugs. *JAMA* 199:95-99, 1967.
3. Barranco VP, Jones DD: Effect of oral contraceptives on acne. *South Med J* 67:703-706, 1974.
4. Strauss JS, Pochi PE: Systemic estrogen therapy of acne. *Prog Dermatol* 2:7-10, 1967.
5. Kligman AM: Pimples following the pill. *Arch Dermatol* 105:298, 1972.
6. Wolf RJ: Angioneurotic edema from oral contraceptives. *JAMA* 201:982, 1967.
7. Catterall RD: *Candida albicans* and the contraceptive pill. *Lancet* 2:830-831, 1966.
8. Erickson LR, Peterka ES: Sunlight sensitivity from oral contraceptives. *JAMA* 203:980-981, 1968.
9. Morgan JK: Herpes gestationis influenced by oral contraceptives. *Br J Dermatol* 80:456-458, 1968.
10. Larsson-Cohn V, Steraram V: Jaundice during treatment with oral contraceptive agents. *JAMA* 193:422-426, 1965.
11. Savel H, Madison JF, Meeker I: Cutaneous eruptions and in vitro lymphocyte hypersensitivity. *Arch Dermatol* 101:187-190, 1970.
12. Estrogens, progestagens, oral contraceptives and ovulatory agents, in *AMA Drug Evaluations*, ed 2, Acton, Mass, Publishing Sciences Group Inc, 1973, p 422.
13. Cormia FE: Alopecia from oral contraceptives. *JAMA* 201:635-637, 1967.
14. Dean G: Oral contraceptives in porphyria variegata. *S Afr Med J* 39:278-280, 1965.
15. Roenigk HH Jr, Gottlob ME: Estrogen-induced porphyria cutanea tarda. *Arch Dermatol* 102:260-266, 1970.
16. Gajdos A, Gajdos-Torok M: Porphyria cutanea tarda revealed by administration of estrogens. *Nouv Presse Med J* 2:1131-1133, 1973.
17. Gilchrest B, Pathak MA, Parrish JA: Porphyria cutanea tarda in young women. *Arch Dermatol* 111:263-264, 1975.
18. Baden HP, Holcomb FD: Erythema nodosum from oral contraceptives. *Arch Dermatol* 98:634-635, 1968.
19. Goldman L: Oral contraceptives and vascular anomalies. *Lancet* 2:103-104, 1970.
20. Rowley PT, Kurnick J, Cheville R: Hereditary hemorrhagic telangiectasia aggravated by oral contraceptives. *Lancet* 1:474-475, 1970.
21. Jelinek JE: Cutaneous side effects of oral contraceptives. *Arch Dermatol* 101:181-186, 1970.

REM Syndrome (Reticular Erythematous Mucinosis)

Report of a Further Case or Variant of It

Kalman Keczkes, MB, ChB, MRCP, Prakash Jadhav, MB, ChB

• A 50-year-old woman had cervical lymphadenopathy, swollen and waxy-looking gums, and a diamond-shaped, reticular erythematous eruption on her back of eight years' duration. Histologic examination of the gingival tissue and skin showed round-cell infiltration around the small blood vessels and in the upper part of the dermis, and an extensive eosinophilic amorphous deposit throughout the dermis that stained with Alcian blue. The clinical and histologic features, although not identical, resembled those reported by Lischka and Orthenberger (1972)[1] and later by Steigleder et al (1974).[2,3]

(*Arch Dermatol* 113:335-338, 1977)

Lischka and Orthenberger[1] presented three cases, one male patient and two female patients, at a meeting of the Cologne Dermatological Society in 1972 with an unusual sheet-like, or net-like eruption on the chest and back. In each case, the histologic findings showed round-cell infiltration around the blood vessels and mucopolysaccharides being deposited in the corium. They believed these cases represented a new entity and called it "round-cell erythematosis." Steigleder et al[2,3] reported five patients (including the three patients of Lischka and Orthenberger) in more detail later. All had a net-like, erythematous eruption on the chest and/or back with slight infiltration and mild itching. Mucous membranes, genitalia, and internal organs were not involved. Histologic examination of the involved skin showed a nonspecific round-cell infiltration around the blood vessels and diffuse deposits of substance in the dermis that stained with Alcian blue. Extensive clinical and laboratory investigations failed to show any other abnormality. They believed that these cases represent a new entity and suggested the name REM syndrome (reticular erythematous mucinosis). We report a patient with similar clinical and histologic features, but with involvement of the gums and a fluctuating nonspecific cervical lymphadenopathy.

Accepted for publication Feb 19, 1976.

From the Department of Dermatology, Hull Royal Infirmary, Hull, England.

Reprint requests to Department of Dermatology, Hull Royal Infirmary, Hull, HU3 2JZ, England (Dr Keczkes).

REPORT OF A CASE

A 42-year-old woman was seen at the Dermatological Out-Patient Clinic at Hull Royal Infirmary in July 1967 with red eruptions on her chest and back, which she first noticed in April 1967. The eruptions were mildly pruritic. Cervical lymphadenopathy had been present since November 1966. Her previous health was good, and she denied receiving any drugs. There was no history of photosensitivity. On examination, she had a diamond-shaped, reticular, slightly palpable, erythematous area on her back (Fig 1 and 2) and similar but less obvious lesions on the anterior part of her chest wall. She had firm, rubbery, enlarged lymph glands on both sides of her neck and one in the left axilla. She was edentulous, and her gums appeared to be swollen and waxy (Fig 3). Apart from these findings, results of the physical examination were within normal limits.

INVESTIGATIONS

Histologic studies were performed in August 1967. A skin biopsy specimen from her back showed that the epidermis was normal. The dermis looked swollen, and collagen bundles were fragmented. The skin appendages were surrounded by a moderately dense lymphocytic infiltrate. Increased amounts of hyaluronic acid were present in the dermis that stained with Alcian blue. Staining with methyl violet was negative for amyloid.

A biopsy specimen from her right upper gum showed that the epithelium was normal but that the collagen bundles were fragmented in the dermis. Staining with Alcian blue showed that hyaluronic acid was being abundantly deposited throughout the dermis. A biopsy specimen from a lymph gland from the left posterior triangle of her neck was taken. There were nonspecific inflammatory changes with prominent lymphoid

Fig 1.—Diamond-shaped, reticular, slightly palpable, erythematous area on back.

Fig 2.—Close-up view of lesions on back showing reticular pattern.



follicles, a little sinus catarrh, some hyperplasia of medullary cells, and a little fibrosis.

In November 1975 another biopsy specimen of skin was taken from her back. The epidermis showed patchy atrophy with follicular hyperkeratosis. The collagen bundles of the upper part of the dermis appeared separated, and there was a low-grade perifolliculitis with patchy lymphocytic, histiocytic infiltration and some new blood vessel formation (Fig 4). In one pilosebaceous follicle, there was an area of degeneration in the upper part of the follicle.

Histochemical Findings

On staining with Alcian blue, granular and filamentous deposits of Alcian blue-positive material were found in the spaces between the separated collagen bundles of the upper part of the dermis (Fig 5). Pretreatment of the sections with testicular hyaluronidase (strength, approximately 750 National Formulary units/mg) resulted in this material becoming unstainable with Alcian blue. The area of degeneration in the hair follicle also stained strongly with Alcian blue, confirming that this was follicular mucinosis. The material in the dermis did not stain with mucicarmine of Gomori hexamine silver, and there was no evidence of amyloid or abnormal lipids.

Immunofluorescence studies were carried out. The full range of direct immunofluorescence tests performed (polyvalent, IgA, IgG, IgM conju-

Fig 3.—Swollen, waxy-looking gums.

gates) on the skin biopsy specimen gave negative results in every case. In particular, only evidence of autofluorescence of dermal collagen was found, with no pathologic significance, as judged by control specimens processed at the same time.

Laboratory Investigations

Laboratory studies disclosed the following values: hemoglobin, 14.8 gm/100 ml; WBC count, 5.0/cu mm; film, differential WBC count, and platelet counts, within normal limits; ESR (Westergren), 4 mm/hr; blood glucose, 80 mg/100 ml (fasting); BUN, 21 mg/100 ml; serum electrolytes, normal; serum albumin, 4.3 gm/100 ml; serum globulin, 1.9 gm/100 ml; electrophoresis of serum proteins, normal; serum calcium, 9.6 mg/100 ml; serum inorganic phosphorus, 2.7 mg/100 ml; serum alkaline phosphatase, 8 King-Armstrong units/100 ml; SGOT, 4 units/ml; SGPT, 12 units/ml; serum bilirubin, 0.2 mg/100 ml; serum creatinine, 1.2 mg/100 ml; creatinine clearance, 66 ml/min; serum protein-bound iodine, 7.6 μg/100 ml. A midstream specimen of urine did not contain protein; cells, casts, and culture for bacteria were negative. Ultracentrifugal examination of patient's serum did not show abnormal proteins. Serum immunoelectrophoresis studies disclosed the following values: IgA, 50 IU/ml; IgG, 64 IU/ml; IGM, 103 IU/ml.

The chemical screening test for erythropoietic protoporphyria was negative. Fecal porphyrins: coproporphyrins, 12 μg/gm dry weight; and protoporphyrins, 19 μg/gm dry weight; urinary porphyrins: coproporphyrins, 10 μg/24 hr; and uroporphyrins, 48 μg/24 hr. Results of the antinuclear antibody test and of the Paul Bunnell screening test were negative. A culture from a throat swab showed profuse growth of *Streptococcus viridans*. Laboratory studies disclosed an anti-streptolysin O titer of 100 Todd units. Virus antibody titers were within normal limits against the following: influenza A, B, C; parainfluenza I and III; adenovirus; *Rickettsia burnetii;* psittacosis; *Mycoplasma pneumoniae;* respiratory syncytial; mumps S and V; herpes simplex; and measles viruses. A chest roentgenogram and a barium meal and follow-through showed no abnormalities. Results of a laryngoscopy also showed no abnormalities.

PROGRESS

During the past seven years, the patient remained under periodic observation. Various topical corticosteroids were administered, but none had any effect on her skin. The skin and gum lesions remained essentially the same, and mild itching periodically affected her back. Lymphadenopathy intermittently was present. During the past two years, she frequently complained of lassitude.

After Steigleder et al[3] and Montgomery and Underwood[4] reported some success using chloroquine phosphate in their cases of REM syndrome, our patient was discharged on a regimen of 200 mg of hydroxychloroquine sulfate twice daily on Nov 12, 1974. Ten days later, she developed an itching, extensive morbilliform, erythematous eruption all over her body, limbs, and face, which was suggestive of a drug reaction to the hydroxychloroquine. Treatment was stopped immediately, and the morbilliform, erythematous lesions gradually cleared in two weeks. The original lesions remained unchanged.

COMMENT

Cutaneous mucinosis includes those conditions in which a mucinous material, mostly acid mucopolysaccharides, accumulate in the dermis. The first condition that was recognized to belong to this group was generalized myxedema secondary to hypothyroidism. Later, pretibial myxedema, following treated hyperthyroidism, was added. Further studies showed conditions in which deposits of mucin were present in the skin over large areas in the absence of endocrinopathy, and the term lichen myxedematosus, or papular mucinosis, was applied to these.

It soon became apparent that deposits of mucin in lichen myxedematosus, or papular mucinosis, may take up different morphologic forms. In 1953, Montgomery and Underwood[4] clas-

Fig 4.—Histologic findings showing follicular hyperkeratosis separation of collagen bundles of upper dermis and patchy lymphocytic and histiocytic infiltration and some new blood vessel formation (hematoxylin-eosin, original magnification ×80).

Fig 5.—Histologic findings showing granular and filamentous deposits in spaces between separated collagen bundles of upper dermis (Alcian blue, original magnification ×400).

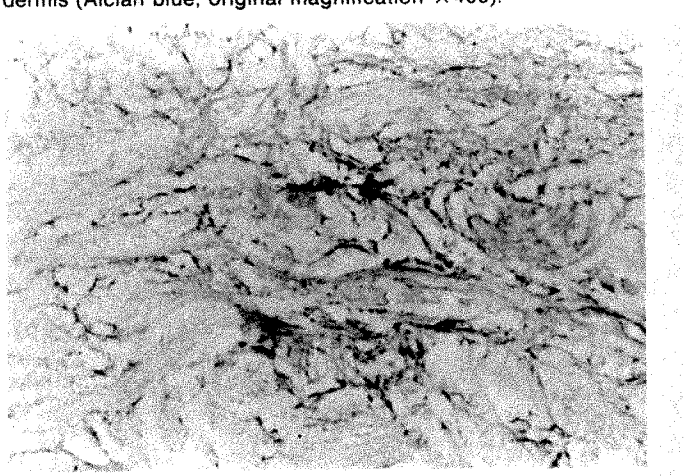

sified them into the following four groups: (1) generalized lichenoid papular, (2) discrete papular, (3) localized or generalized lichenoid plaques, and (4) urticarial and nodular type.

Perry et al (1960)[5] described a plaque-like form of cutaneous mucinosis in three patients who had persistent erythematous plaques on the anterior and posterior aspects of the thorax. The lesions were composed of closely net erythematous, somewhat urticarial papules that persisted for up to eight years. They were mildly pruritic, and exposure to sunshine aggravated them. Histologic sections stained with Mayer mucicarmine showed a bright-pink, heavy deposit beneath the epidermis that was patchily distributed throughout the upper part of the corium. The deposits stained with Alcian blue metachromatically and also stained with PAS. Treatment of unstained sections with hyaluronidase, prior to subsequent staining with toluidine blue, eradicated the deposits.

McCarthy et al (1964)[6] found abnormal serum globulins in a case of papular mucinosis, which have been classified as 7S immunoglobulins. These findings with the demonstrated presence of the long-acting thyroid stimulator,[7,8] also an immunoglobulin of the 7S class, in pretibial myxedema, suggest a role for immunoglobulins in the pathogenesis of altered mucopolysaccharide metabolism in the skin.

Lischka and Orthenberger (1972)[1] and Steigleder et al (1974)[2,3] described another form of mucinosis with new morphologic manifestations. Only the skin was involved, and extensive investigations failed to show underlying disease. Although their cases were similar to the case reported by Perry et al (1960),[5] clinical and histochemical differences justify their separation from existing forms of mucinosis.

Howsden et al (1975)[9] described a 70-year-old woman with a papular type of lichen myxedematosus. The authors demonstrated the presence of a yellow-green immunofluorescence between autofluorescent elastic fibers in skin biopsy specimens incubated with fluorescence-labeled goat anti-human IgG. No abnormal protein was detected in the patient's blood. Treatment with cyclophosphamide and prednisolone reduced itching after one month of treatment, when administration of prednisolone was discontinued. Three months later, the skin was less indurated, and after one year of treatment with cyclophosphamide, the skin became completely normal. Skin biopsy specimens that were taken at this time showed diminution in the number of fibroblasts and mucin.

Our case seems to represent yet another variant of mucinosis. The morphologic features and histochemical findings in our patient are similar to those described by Lischka and Orthenberger[1] and Steigleder et al.[2,3] In our patient, however, the gums were also affected, and an evanescent, nonspecific lymphadenopathy affecting the cervical and left axillary lymph glands was also present. The importance of this remains unclear. Immunofluorescence studies gave negative results in our patient. Since previous investigators did not do immunofluorescence studies in their patients, we cannot compare our findings. The skin lesions of the patients of Perry et al[5] and Steigleder et al[2,3] appeared to be aggravated by exposure to sunshine, which was not the case with our patient.

We are not certain whether our case is a true case of REM syndrome. We also wonder whether the cases of Perry et al,[5] Steigleder et al,[2,3] and of ourselves are separate entities. We would be inclined to believe that the various forms of papular, plaque-like, and reticular mucinosis are part of a whole spectrum of conditions in which mucopolysaccharides are deposited in the dermis. In some of these cases, immunoglobulins are also present in the serum and in the dermis. These findings, along with the fact that mucinous deposits are found around the blood vessels in internal organs at necropsy,[10] suggest that these conditions may constitute a generalized disorder of mucopolysaccharides.

P. Bury, MD, was consultant pathologist for the first histologic report. Professor J.A. Milne, FRCP, MRCPath, performed the second skin biopsy in November 1975 and provided the histochemical reports and photomicrographs. M. Sephton provided secretarial help.

References

1. Lischka G, Orthenberger D: "Rundzellerythematosis" ein neues Krankheitsbild? *Z Haut Geschlechtskr* 47:995-999, 1972.

2. Steigleder GK, Gartmann H, Linker U: REM-Syndrom, Retikuläre erythematöse Mucinosis (Rundzellerythematosis). *Z Haut Geschlechtskr* 49:235-238, 1974.

3. Steigleder GK, Gartmann H, Linker U: REM Syndrome: Reticular erythematous mucinosis (round-cell erythematosis), a new entity? *Br J Dermatol* 91:191-199, 1974.

4. Montgomery H, Underwood LJ: Lichen myxedematosus (differentiation from cutaneous myxedemas or mucoid states). *J Invest Dermatol* 20:213-236, 1953.

5. Perry HO, Kierland RR, Montgomery H: Plaque-like form of cutaneous mucinosis. *Arch Dermatol* 82:980-985, 1960.

6. McCarthy JT, Osserman E, Lombardo PC, et al: An abnormal serum globulin in lichen myxedematosus. *Arch Dermatol* 89:446-450, 1964.

7. Kriss JP, Pleshakov V, Chien JR: Isolation and identification of the long-acting thyroid stimulator and its relation to hyper-thyroidism and circumscribed pretibial myxoedema. *J Clin Endocrinol Metab* 24:1005-1028, 1964.

8. Pimstone BL, Hoffberg R, Black E: Parallel assays of thyrotropin, long-acting thyroid stimulating and exophthalmos-producing substance in endocrine exophthalmos and pretibial myxedema. *J Clin Endocrinol Metab* 24:976-982, 1964.

9. Howsden SM, Herndon JH, Jr, Freeman RG: Lichen myxedematosus: A dermal infiltrative disorder responsive to cyclophosphamide therapy. *Arch Dermatol* 111:1325-1330, 1975.

10. McCuistion CH, Schoch EP, Jr: Autopsy findings in lichen myxedematosus. *Arch Dermatol* 259-262, 1956.

Mucocutaneous Lymph Node Syndrome

Lt Col Richard B. Odom, MC, USA, Capt Eric G. Olson, MC, USA

• In 1967, Kawasaki reported an acute, febrile, mucocutaneous condition accompanied by swelling of cervical lymph nodes that afflicted infants and young children in Japan. He called the entity mucocutaneous lymph node syndrome. In 1974, the condition was reported in Hawaii, and several cases have been reported subsequently from the continental Unites States and other countries. One percent to two% of patients had died suddenly of cardiac failure. Rickettsia-like bodies have been demonstrated from skin and lymph node biopsy specimens, and the pathologic features suggest a relationship to infantile periarteritis nodosa.

(*Arch Dermatol* 113:339-340, 1977)

In early 1961, Kawasaki began noting a disease in infants and young children in Japan that manifested as an acute, febrile, mucocutaneous condition accompanied by swelling of cervical lymph nodes. He[1] reported 50 cases in 1967 under the title mucocutaneous lymph node syndrome (MLNS). More than 6,000 cases from Japan have been recorded through 1973.[2] In 1974, Melish et al[3] reported the cases of nine patients from Hawaii with a similar syndrome, and several cases of MLNS have been reported subsequently from the continental United States.[4-9] Cases indistinguishable from MLNS have been observed in Canada,[10,11] Greece,[12] and Korea.[13]

The MLNS can be misdiagnosed as scarlet fever, the Stevens-Johnson syndrome, infantile periarteritis nodosa, systemic juvenile rheumatoid arthritis,[14] or other acute febrile exanthems. The importance of the condition is related to the fact that a small percentage (1% to 2%) of patients affected develop sudden cardiac failure that usually results in death from myocardial infarction with coronary artery thrombosis and aneurysm.[15]

A patient with MLNS was seen in our clinic. In view of the dramatic mucocutaneous findings and major potential systemic complications associated with this condition, we wish to report this case, briefly review the literature, and alert dermatologists to enable recognition and accurate diagnosis of this new, intriguing, and possibly increasing disease in the United States.

REPORT OF A CASE

An eight-year-old boy developed fever, sore tongue, diarrhea, cough, and generalized rash three days before visiting the pediatric clinic. He had a generalized erythematous, maculopapular rash that involved predominantly the trunk and the intertriginous areas. Conjunctivitis and mild periorbital swelling were noted. The papillae of the tongue were erythematous and hypertrophic (strawberry tongue). The pharynx was normal. A mild, nonproductive cough was noted. Throat culture grew *Staphylococcus aureus*. Previous history disclosed episodes of seasonal allergic rhinitis and eczema of cheeks. Maternal history disclosed allergic rhinitis. Diphenhydramine and 1% hydrocortisone cream were prescribed.

The day following the clinic visit, the hands and feet became erythematous and edematous, and the lips were noted to be dry and fissured. Two days later, desquamation of the hands and feet were noted to begin at the base of the fingernails and toenails.

On the sixth day after the initial visit, the patient was referred to the dermatology clinic. Physical findings included a temperature of 37.6 C; large, tender, right anterior cervical lymphadenopathy; mild periorbital swelling; dryness and fissuring of the lips; hypertrophied papillae of the tongue; a fine desquamation of the trunk; and marked desquamation of the distal portion of the fingers, toes, and plantar surfaces of the feet (Fig 1 and 2). Examination four weeks later revealed transverse depressions of all fingernails and toenails (Beau lines).

Results of the following laboratory studies were normal: antistreptolysin O titers

Fig 1.—Dry, fissured exfoliation of lips and marked desquamation of distal aspect of fingers.

Accepted for publication Nov 30, 1976.

From the Dermatology Service, Department of Medicine, Letterman Army Medical Center, Presidio of San Francisco.

The opinions or assertions contained herein are the private views of the authors and are not to be construed as official or as reflecting the views of the Department of the Army or the Department of Defense.

Reprint requests to Technical Publications Editor, Letterman Army Medical Center, Presidio of San Francisco, CA 94129

Fig 2.—Marked desquamation of distal aspect of fingers, toes, and plantar surfaces of feet.

and streptozyme determinations (immediately and at one month); C reactive protein; complete blood cell count; serum protein electrophoresis; serologic studies for viruses and rickettsiae; and febrile agglutinins. (All determinations were made from serum samples collected one month following the acute illness.)

Approximately three weeks after the onset of symptoms, the cutaneous, mucosal, and lymph node abnormalities had resolved. However, fatigue persisted for two more weeks. Subsequently, the patient's health has been excellent and without sequelae, except for the obvious Beau lines of all nails.

COMMENT

The principal features of MLNS are as follows: (1) fever ranging from 38.0 to 40.0 C, which lasts from one to two weeks or more and is not affected by antibiotic therapy; (2) bilateral conjunctival congestion; (3) diffuse reddening of the lips, which become dry, fissured, and eroded; diffuse erythema and prominent papillae of the tongue strikingly similar to the "strawberry tongue" of scarlet fever; diffusely erythematous oropharyngeal mucosa; (4) acute nonpurulent enlargement of the cervical lymph nodes; (5) initial erythema of the palms and soles with indurative edema (sclerodermoid) followed in the convalescent stage by a striking desquamation beginning in the junction of the nails and skin on the tips of the fingers and toes; (6) polymorphous exanthem of the torso described as generalized scarlatiniform erythroderma, maculopapular morbilliform eruption, or erythema multiforme in configuration; and (7) age of onset usually below 5 years.

Other important findings include (1) carditis, especially myocarditis and pericarditis; (2) diarrhea; (3) arthralgia or arthritis; (4) urethritis; (5) aseptic meningitis; (6) focal encephalopathy; and (7) mild jaundice.

Laboratory abnormalities include leukocytosis with shift to the left, increased ESR, proteinuria and pyuria, slight decrease in erythrocyte and hemoglobin levels, positive C reactive protein, increased α_2-globulin, thrombocytosis in second or third week of illness, mild elevations of serum transaminase level and abnormal results of cardiac studies. Rickettsia-like bodies have been found by electron microscopy inside cytoplasmic vacuoles of macrophages and inside the vascular lumen in biopsy specimens of the skin and lymph nodes from patients with MLNS.[16]

Normal studies include antistreptolysin O titers and bacterial cultures of blood, urine, stool, lymph nodes, and CSF. Viral cultures and serologic studies have been negative. *Chlamydia* antibodies, leptospiral agglutinins, febrile agglutinins, and rickettsial antibody titers have been unrevealing. Titers for antinuclear antibodies and rheumatoid factor have been negative.

Etiological speculations are as follows: (1) a hyperimmune response to any of a variety of different infections; (2) a viral syndrome; (3) an allergic or toxic response to pollutants, drugs, or unidentified toxic agents; and (4) a rickettsial disease.

The disease has failed to respond to treatment with various antibiotics, including penicillin. Steroids appear to have an antifebrile effect on the disease, but do not appear to influence the course or duration.

References

1. Kawasaki T: MCLS: Clinical observation on 50 cases. *Jap J Allerg* 16:178, 1967.
2. Kawasaki T, Kosaki F, Okawa S, et al: A new infantile acute febrile mucocutaneous lymph node syndrome (MLNS) prevailing in Japan. *Pediatrics* 54:271-276, 1974.
3. Melish ME, Hicks PM, Larson EO: Mucocutaneous lymph node syndrome (MCLS) in the US, abstracted. *Pediatr Res* 8:427, 1974.
4. Nix WL, Clark E, Montgomery JR, et al: A case of the mucocutaneous lymph node syndrome in the continental United States, abstracted. *Clin Res* 23:70, 1975.
5. Goldsmith RW, Gribetz D, Strauss L: Mucocutaneous lymph node syndrome (MLNS) in the continental United States. *Pediatrics* 57:431-435, 1976.
6. John TJ, DeBenedetti CD, Zee ML: Mucocutaneous lymph node syndrome in Arizona. *Am J Dis Child* 130:613-614, 1976.
7. Bernhardt IB: Mucocutaneous lymph node syndrome with encephalopathy in the continental United States. *West J Med* 125:230-233, 1976.
8. Lauer BA, Bruhn FW, Todd JK, et al: Mucocutaneous lymph node syndrome in Denver. *Am J Dis Child* 130:610-612, 1976.
9. Brown JS, Billmeier GJ, Cox F, et al: Mucocutaneous lymph node syndrome in the continental United States. *J Pediatr* 88:81-83, 1976.
10. Russell AS, Zaragoza AJ, Shea R: Mucocutaneous lymph node syndrome in Canada. *Can Med Assoc J* 112:1210-1211, 1975.
11. Radford DJ, Sondheimer HM, Williams GJ, et al: Mucocutaneous lymph node syndrome with coronary artery aneurysm. *Am J Dis Child* 130:596-598, 1976.
12. Valaes T: Mucocutaneous lymph node syndrome (MLNS) in Athens, Greece. *Pediatrics* 55:295, 1975.
13. Kim J, Yeo Y, Lee DB: Mucocutaneous lymph node syndrome: Clinical observations of eight cases. *Korea New Med J* 16:1157, 1973.
14. Melish ME, Hicks RM, Larson EJ: Mucocutaneous lymph node syndrome in the United States. *Am J Dis Child* 130:599-607, 1976.
15. Kato H, Koike S, Yamamoto M, et al: Coronary aneurysms in infants and young children with acute febrile mucocutaneous lymph node syndrome. *J Pediatr* 86:892-898, 1975.
16. Hamashima Y, Kishi K, Tasaka K: Rickettsia-like bodies in infantile acute febrile mucocutaneous lymph node syndrome. *Lancet* 2:42, 1973.

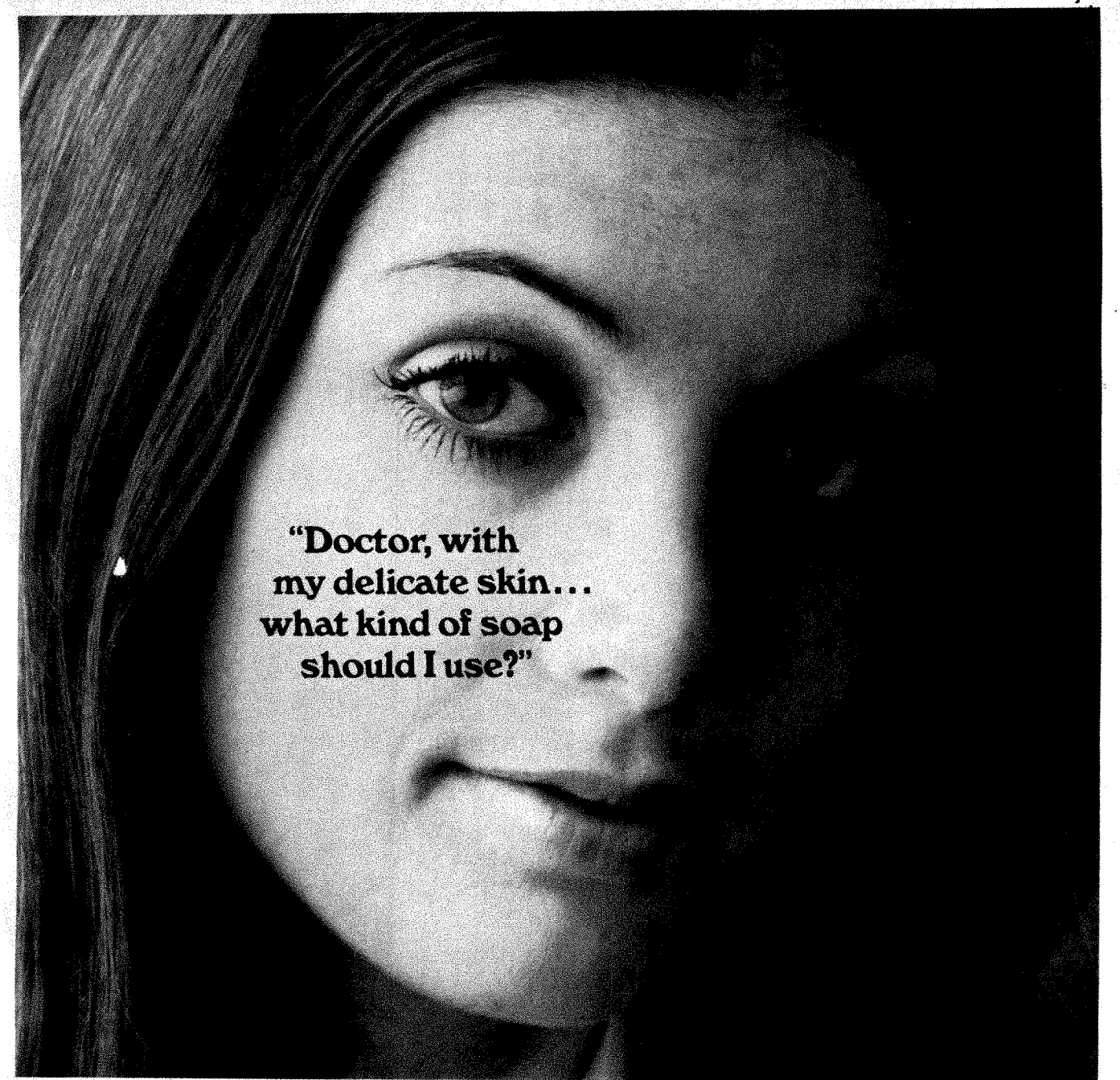

Pure mild Ivory is one of the safest possible soaps you can recommend for delicate skin. More doctors recommend Ivory than any other soap.

It makes sense. Ivory's absence of many extra ingredients helps minimize chances of irritation.

Thirty-eight years of laboratory testing—including patch tests and arm immersion experiments—confirm that Ivory is one of the mildest, least irritating soaps you can recommend.

And 89 years of safe consumer use support this clinical experience.

Ivory may safely be used as an adjunct to treatment of scabies, seborrhea and impetigo.

antifungal
antipruritic
antibacterial
anti-
inflammatory
TAXI

Clear choice

When dermatoses become infected with bacteria or fungi, plain topical steroids are generally not the recommended therapeutic choice.

A clear choice, however, is Vioform®-Hydrocortisone. With its unique four-way action, it supplies the kind of comprehensive treatment many common dermatoses* require.

*This drug has been evaluated as possibly effective for these indications. See brief prescribing information.

Vioform®-Hydrocortisone
(iodochlorhydroxyquin and hydrocortisone)

INDICATIONS
Based on a review of this drug by the National Academy of Sciences-National Research Council and/or other information, FDA has classified the indications as follows:
"Possibly" effective: Contact or atopic dermatitis; impetiginized eczema; nummular eczema; infantile eczema; endogenous chronic infectious dermatitis; stasis dermatitis; pyoderma; nuchal eczema and chronic eczematoid otitis externa; acne urticata; localized or disseminated neurodermatitis; lichen simplex chronicus; anogenital pruritus (vulvae, scroti, ani); folliculitis; bacterial dermatoses; mycotic dermatoses such as tinea (capitis, cruris, corporis, pedis); moniliasis; intertrigo. Final classification of the less-than-effective indications requires further investigation.

CONTRAINDICATIONS
Hypersensitivity to Vioform-Hydrocortisone, or any of its ingredients or related compounds; lesions of the eye; tuberculosis of the skin; most viral skin lesions (including herpes simplex, vaccinia, and varicella).

WARNINGS
This product is not for ophthalmic use.
In the presence of systemic infections, appropriate systemic antibiotics should be used.

Usage in Pregnancy
Although topical steroids have not been reported to have an adverse effect on pregnancy, the safety of their use in pregnant females has not been established. Therefore, they should not be used extensively on pregnant patients in large amounts or for prolonged periods of time.

PRECAUTIONS
May prove irritating to sensitized skin in rare cases. If this occurs, discontinue therapy. May stain.
If used under occlusive dressings or for a prolonged period, watch for signs of pituitary-adrenal axis suppression.
May interfere with thyroid function tests. Wait at least one month after discontinuance of therapy before performing these tests. The ferric chloride test for phenylketonuria (PKU) can yield a false-positive result if Vioform is present in the diaper or urine.
Prolonged use may result in overgrowth of nonsusceptible organisms requiring appropriate therapy.

ADVERSE REACTIONS
Few reports include: Hypersensitivity, local burning, irritation, pruritus. Discontinue if untoward reaction occurs. Rarely, topical corticosteroids may cause striae at site of application when used for long periods in intertriginous areas.

DOSAGE
Apply a thin layer to affected areas 3 or 4 times daily.

HOW SUPPLIED
Cream, 3% iodochlorhydroxyquin and 1% hydrocortisone in a water-washable base containing stearyl alcohol, cetyl alcohol, stearic acid, petrolatum, sodium lauryl sulfate, and glycerin in water; tubes of 5 and 20 Gm. *Ointment*, 3% iodochlorhydroxyquin and 1% hydrocortisone in a petrolatum base; tubes of 20 Gm. *Lotion*, 3% iodochlorhydroxyquin and 1% hydrocortisone in a water-washable base containing stearic acid, cetyl alcohol, lanolin, propylene glycol, sorbitan trioleate, polysorbate 60, triethanolamine, methylparaben, propylparaben, and perfume Flora in water; plastic squeeze bottles of 15 ml. *Mild Cream*, 3% iodochlorhydroxyquin and 0.5% hydrocortisone in a water-washable base containing stearyl alcohol, cetyl alcohol, stearic acid, petrolatum, sodium lauryl sulfate, and glycerin in water; tubes of ½ and 1 ounce. *Mild Ointment*, 3% iodochlorhydroxyquin and 0.5% hydrocortisone in a petrolatum base; tubes of 1 ounce.

Consult complete product literature before prescribing.

CIBA Pharmaceutical Company
Division of CIBA-GEIGY Corporation
Summit, New Jersey 07901

2/6867 17

Vioform®-Hydrocortisone
(iodochlorhydroxyquin and hydrocortisone)

The most widely prescribed form... 20-Gm Cream

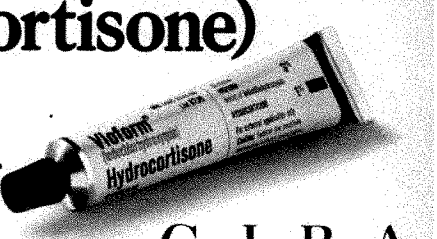

CIBA

we named it what it is



and then we tarred it!

*TM

neutral pH
no preservatives

616 ALLEN AVE.,
GLENDALE, CA
91201

PERSON & COVEY INC.

Current Concepts in the Immunology of Leprosy

Thomas H. Rea, MD, Norman E. Levan, MD

This review is intended to acquaint the nonleprologist with current immunologic concepts of leprosy and with the data that support these concepts. For further reading, the reviews by Rees,[1] Wager,[2] Turk and Bryceson,[3] Bullock,[4] Skinsnes,[5] Convit and Ulrich,[6] and a memoranda sponsored by the World Health Organization[7] are recommended.

CLASSIFICATION

Rabello's polar concept of leprosy[8,9] and the studies of Ridley and co-workers,[10-12] which were based on clinical and histological observations, have been pivotal in the formation of current ideas concerning immunologic mechanisms in the pathogenesis of leprosy. Ridley and co-workers[10-12] have provided nomenclature, in the form of a system of diagnostic classification, that is fundamental to most current immunological investigations.

For those readers who are not conversant with the classification of leprosy, two analogies may be helpful. Leprosy is likened to a salami that can be taken as a whole or sliced, either thickly or thinly. When thickly sliced into two pieces, one is tuberculoid leprosy and the other is lepromatous leprosy. For most purposes such thick pieces are awkward, ie, many cases are difficult to class as either tuberculoid or lepromatous and so the salami is sliced into three less-thick pieces: tuberculoid, borderline, and lepromatous leprosy. Ridley and co-workers recognized that even thinner slices were possible histologically and clinically and were desirable when studying patients immunologically; hence their classifications as described below. In the second analogy, cells of the macrophage series are regarded as good but not very bright soldiers. In polar lepromatous leprosy, the soldier-histiocyte phagocytizes *Mycobacterium leprae* and provides a milieu for its growth. If ordered to do something against *M leprae*, it is effective. When a macrophage receives orders from an antigen-specific T-lymphocyte, like a good soldier it promptly obeys and transforms itself into a bacteriolytic epithelioid cell. To mix the metaphors, polar lepromatous leprosy is that extreme end of the salami in which the histiocyte receives no instructions from antigen-specific T-lymphocytes. Each of the other slices represents clinical and histologic constellations that originate in differing degrees of instructions provided by antigen-specific T-lymphocytes. A summary of the clinical and histological features in each of the stages of the Ridley-Jopling five-membered classification, with emphasis on those traits interpretable as reflecting the influence (or absence thereof) of specific T-lymphocytes, is found in the Table.

As an elaboration of the polar concept, Ridley and Jopling[10,11] first proposed a five-membered system of classification. They retained the traditional tuberculoid pole (TT), lepromatous pole (LL), and borderline group (BB), but added two intermediary categories: borderline with tuberculoid features (BT) and borderline with lepromatous features (BL)—TT, BT, BB, BL, and LL comprise a spectrum in continuity.

They reasoned that each stage in the spectrum was determined by and the result of host responses to antigens of *M leprae;* ie, patients with BL have more immunity against *M leprae* than do patients with LL, but less than patients with BB. To confirm this hypothesis, they measured the rate of disappearance of acid-fast bacilli (AFB)[10] in tissue specimens from sulfone-treated patients, with the assumption that sulfone therapy caused the death of organisms equally rapidly but that variation in destruction of organisms by macrophages was influenced primarily by immune responses. (This latter assumption has been partially verified by Drutz et al,[13] who found that blood monocyte-derived macrophages from leprosy patients are normal in vitro, and by Convit et al,[14] who found that nonspecifically, immunologically activated macrophages in lepromatous patients are highly bacteriolytic for *M leprae*.) The rate of disappearance of AFB was found to be significantly greater in patients with BB than in patients with BL and greater in patients with BL than in patients with LL, thus providing indirect support for their hypothesis.

In studying patients in Malaya, Ridley and Waters[12] later separated from the Ridley-Jopling LL category a sixth group that lay between true polar lepromatous and BL; this subpolar category they named leproma indefinite (LI). Patients with LI were found to clear AFB more rapidly than patients with LL.

An analogous tuberculoid indefinite (TI) group that lay between TT and

Accepted for publication Aug 25, 1976.

From the Section of Dermatology, Department of Internal Medicine, University of Southern California School of Medicine, Los Angeles (Dr Rea), and the Department of Dermatology, Los Angeles County-University of Southern California Medical Center, Los Angeles (Dr Levan).

Reprint requests to Section of Dermatology, Department of Internal Medicine, University of Southern California School of Medicine, 2025 Zonal Ave, Los Angeles, CA 90033 (Dr Rea).

Clinical and Histologic Features of Ridley-Jopling Classification of Leprosy

Clinical and Histologic Features	Polar Tuberculoid (TT)	Borderline With Tuberculoid Features (BT)	Borderline (BB)	Borderline With Lepromatous Features (BL)	Polar Lepromatous (LL)
Skin lesions	Few in number; sharply defined, active border with clearing center; asymmetrical	Smaller, more numerous than lesions of TT	Annular lesions with sharply defined inner margins and ill-defined peripheral margins	Annular lesions of BB type mixed with nodular lesions of LL type	Ill-defined nodules and/or generalized diffuse infiltration; symmetrical; leonine facies and eyebrow alopecia
Nerve lesions	Skin lesions anesthesia early; nerve trunk palsies	As in TT	As in TT	Mixed TT and LL	Skin lesions, no anesthesia early; no nerve trunk palsies; symmetrical acral, distal anesthesia.
Organisms	Rare—less than 1 per 100 oil-emersion fields	Rare to 1 per 10 oil-emersion fields, More in nerve bundles	1 to 10 per oil-emersion field	10 to 100 per oil-emersion field	10 to 1,000 per oil-emersion field
Monocytic Derivatives					
Histiocytes	Absent	Absent	Absent	Present without foamy change	Present with foamy change
Epithelioid cells	Present	Present	Present	Present	Absent
Langerhan giant cells	Present	Present	Absent	Absent	Absent
Lymphocytes	Present; dense peripheral infiltration about granuloma; infiltration into epidermis	Present; peripheral infiltration about granuloma, no epidermal infiltration	Variable; diffuse and focal (nerve) distribution	Scant; focal areas of infiltration, especially perineural cuffs	Scant; diffuse in distribution
Lepromin skin test	Usually positive	Variable	Negative	Negative	Negative

BT was defined,[15] which completed a seven-membered spectrum—TT, TI, BT, BB, BL, LI, and LL in continuity. In actual practice, some investigators use the five-membered system and others use the seven. Unless otherwise specified, the Ridley system refers to the seven-membered system in the rest of this review.

The Ridley system is useful primarily because it is the most precise method of establishing patient comparability among the diverse ethnic and geographic groups that are studied. The Ridley system has proved to be clinically useful also: TT and LL patients are stable, whereas TI through LI patients are apt to spontaneously change clinical or histologic features; clinical lesions of tuberculoid and borderline type and nerve trunk palsies are signs of cell-mediated immunity against antigens of *M leprae*.

The Ridley system is not without its difficulties. A troublesome problem is the immunologic validity of the distinction between LI and LL, ie, do LI patients have more cell-mediated immunity against *M leprae* than do LL patients? (Has the salami been sliced too thinly to be meaningful?)

In a study of the rates of disappearance of bacilli with treatment, Russell et al[16] grouped together responses of LL patients and a subpolar group designated by them as BL/LL, which presumably is similar to LI. It is reasonable to infer that they found no meaningful difference in the rate of disappearance of organisms between polar and subpolar patients, thus lending no support to an LL-LI distinction as judged by this criterion. Myrvang et al[17] studied *M leprae*-induced lymphocyte transformation and migration-inhibition factor production and found that lymphocytes from patients with LI did not respond in a greatly different manner than those from patients with LL, which suggests that the distinction between LL and LI may be spurious immunologically. We have found that many of our Mexican patients are histologically classifiable as LI but have clinical features of LL. Thus, we believe that the histologic distinction between LL and LI is without importance, at least as applied to these particular patients.[18,19]

Superimposable on various segments of the granulomatous spectrum of leprosy are a variety of reactional states, including at least three types.

Erythema nodosum leprosum (ENL)[18] is characterized clinically by crops of tender skin and subcutaneous nodules that typically arise in grossly uninvolved tissue. Histologically ENL is characterized by a neutrophilic and lymphocytic inflammatory infiltrate that is superimposed on the previously subclinical lepromatous granuloma. Erythema nodosum leprosum is often seen after the onset of chemotherapy, but its occurrence in the absence of chemotherapy is not unusual. Erythema nodosum leprosum is most common in LL patients, but is seen with progressively less frequency in patients with LI and BL.[11,12]

The Lucio phenomenon,[20] which is observed most commonly but not exclusively in patients from Mexico, is characterized clinically by crops of irregular, stellate infarctions of the skin in individuals with pure diffuse leprosy, ie, without nodular lesions and with alopecia of the eyebrows. The Lucio phenomenon is characterized histologically by severe vasculitis of the dermal vessels. Systematic study of the Lucio phenomenon according to the Ridley system has not been made, but in our experience these patients are clinically classifiable as LL.[19] Usually the Lucio phenomenon is observed prior to chemotherapy.

A third (or perhaps a third and fourth) type of reaction has no entirely satisfactory or universally accepted terminology. Ridley[21] has proposed the terms "downgrading" and "reversal reactions," which obligatorily imply a decreasing or increasing amount of immunity directed against *M leprae;* reversal reaction will be used in this review (synonyms, acute phase and reactional tuberculoid state).

These reactions are characterized clinically by an increase in tissue reaction in skin lesions already grossly evident and the abrupt onset of nerve trunk palsies, and histologically by the granuloma of leprosy with edema but without vasculitis or acute inflammatory infiltrate. This type of reaction does not occur in patients with LL (except after the use of transfer factor),[22,23] but is seen throughout the rest of the leprosy spectrum, either in the presence or in the absence of chemotherapy.

LEPROMIN REACTIVITY

Lepromin,[1] the skin-test antigen widely used in studies of leprosy, has no diagnostic value. The antigen, which is derived from autoclaved lepromatous tissue, contains dead *M leprae*. Because lepromin is particulate, devoid of heat-labile determinants, contaminated with host-tissue antigens, and scarce, it is less than ideal.

Three types of positive responses to intradermal lepromin have been described. A delayed 21-day (or longer) response with histologic characteristics of a tuberculoid granuloma, the Mitsuda reaction,[1] is particularly well elicited by the Mitsuda or integral type of lepromin; it has not been reproducibly passively transferred with whole lymphocytes[24,25] or transfer factor.[22,26] A delayed 48-hour response with the histologic characteristics of a tuberculin reaction, the Fernandez reaction,[1] is particularly well elicited by the Dharmendra type of lepromin and has been irregularly conferred on LL patients with previously negative reactions with whole lymphocytes[24,25] or transfer factor.[22,23,26] An immediate reaction, the Medina reaction, has been inconsistently observed in patients with the Lucio phenomenon and is of no further importance in this review.[20,27] For clarity, "lepromin responsivity" will subsequently refer to both Mitsuda and Fernandez responsivity.

Patients with TT and TI are lepromin-positive; BB through LL patients are lepromin-negative; and BT patients are either lepromin-negative or lepromin-positive. Thus, lepromin responsivity is of some prognostic value.[11] In BB through LL patients, lepromin unresponsiveness is not invariable: Guinto[28] reports no Fernandez responsiveness at 10 mm or more of induration and a 1% rate of Mitsuda responsiveness at the 5 mm or more of induration; Mukerjee and Kundu[29] found Mitsuda reactivity in one of 15 "frank lepromatous" patients; Leiker[30] found no Mitsuda reactivity at 3 mm or more induration in 54 patients with diffuse lepromatous leprosy, but weak Mitsuda reactivity at 3 to 5 mm of induration was present in seven of 53 (13%) "nondiffuse" lepromatous patients; Talwar et al[31] reported Fernandez responsiveness in one of two patients who were histologically classed as LL; Convit et al[32] reported Fernandez reactivity at 10 mm or more of induration in 4% to 8% of lepromatous patients and Mitsuda reactivity at 3 mm or more of induration in 10% to 34%, with the least involved showing the greatest reactivity. These positive reactions are usually weak and may represent responses to host-tissue elements contaminating the lepromin(s) used. Uncertainty may be anticipated until a pure antigen is available. Conversely, in TT through TI patients, lepromin responsiveness is not invariable; Guinto[28] reported Fernandez responsiveness in 39% and Mitsuda responsiveness in 94% of tuberculoid patients.

Lepromin responsiveness, especially of the Mitsuda type, is the rule in normal adults,[1] which makes lepromin responsivity of no diagnostic value. In a large population in an endemic area, Guinto et al[33] found that the rate of Mitsuda responsiveness increased with age. Mitsuda reactivity was found in 17% of those 4 years old or less, but was found in 95% of those 20 years old or more. Also, these investigators found that the rates of Mitsuda responsivity were similar in individuals from households with lepromatous leprosy, with nonlepromatous leprosy, or without leprosy.[34] In normal adult individuals with leprosarium exposure, Convit et al[32] found a 37% rate of Fernandez responsivity (10 mm) and a 96% rate of Mitsuda responsivity (3 mm). In a nonendemic area (New York), Rotberg et al[35] reported a 19% rate of Fernandez responsivity and an 86% rate of Mitsuda responsivity among 64 healthy controls. Similarly, in a study of 73 adults not exposed to leprosy, Shepard and Saitz[36] found a 22% rate of Fernandez responsivity (10 mm) and a 100% rate of Mitsuda responsivity (3 mm). Waters[37] found a 2% rate of Fernandez responsivity (10 mm) and 43% rate of Mitsuda responsivity (5 mm) in 65 tuberculin-negative residents of England who had not been exposed to leprosy.

There is no definite answer to the question of whether lepromin responsivity arises from cross-reactivity with tuberculin sensitivity. Rotberg et al[35] argued that it probably does and cite cross-reactivity (but do not prove its existence) to explain Fernandez reactions in New Yorkers; Waters' data support this view.[37] Shepard and Saitz[36] reasoned with substantial evidence that cross-reactivity with tuberculin does not explain the Fernandez reactivity they observed. Doull et al[38,39] and Guinto et al[40] concluded that Mitsuda responsiveness cannot be explained by prior exposure to either *M leprae* or other mycobacteria.

Does BCG vaccination influence lepromin responsiveness? In patients with lepromatous leprosy, BCG vaccination will produce a transient Mitsuda responsiveness in one half of the individuals so treated, but this neither alters Fernandez nonresponsiveness nor alters the patient's clinical condition.[41] In patients with tuberculoid disease, BCG vaccination does not increase lepromin responsiveness.[41] In tuberculin-negative normal children, BCG vaccination will accelerate conversion to lepromin positivity, as does lepromin testing.[38]

The mechanism of lepromin responsiveness is not known. Some observations support the hypothesis that lepromin responsivity is a cell-mediated immune reaction: (1) Fernandez reactivity can be transferred passively with the use of whole lymphocytes[24] or transfer factor;[22] (2) the histologic characteristics of the Fernandez reaction are similar to those of a tuberculin reaction[1]; (3) the high rate of Mitsuda responsivity in tuberculin-negative individuals who have not been exposed to leprosy can be explained by the eliciting dose becoming the sensitizing dose[1]; and (4) (weakest of these arguments) Fernandez reactivity in patients who have not been exposed to leprosy is a matter of cross-reactivity.[35]

Other observations support the hypothesis that lepromin responsivity is not cell-mediated immunity, but is a

phenomena of unknown mechanism: (1) Mitsuda reactivity has not been convincingly passively transferred[22,24-26]; (2) cross-reactivity is not an adequate explanation for Fernandez responsivity in unexposed, tuberculin-negative individuals[36]; (3) the rate of conversion to Mitsuda positivity is greater than that of conversion to tuberculin positivity and cannot be explained by exposure to leprosy[38-40] and is difficult to explain by lepromin testing[38]; (4) results of lepromin-induced lymphocyte transformation studies are usually negative in unexposed adults,[42] but such individuals are usually Mitsuda-positive.

That the mechanism of lepromin unresponsiveness is unknown is evident. In infants, "immaturity" is an easy explanation, but begs the basic question. In adults with LL to BB disease, it is uncertain whether disease develops because of unresponsiveness or if unresponsiveness is a consequence of disease development. Dharmendra and Chattergee's[43] follow-up of lepromin-negative individuals in an endemic area with a high incidence of lepromatous leprosy in previously lepromin-negative subjects suggests that lepromin negativity and susceptibility to lepromatous leprosy may be closely related phenomena (or that the initial study identified patients in the incubation period of the disease.)

An understanding of lepromin unresponsiveness, the most widely reported abnormality characterizing BB to LL patients, may be central to an understanding of the pathogenesis of lepromatous disease.

CELL-MEDIATED IMMUNITY AGAINST *M LEPRAE*

Current concepts of the role of cell-mediated immunity in the pathogenesis of leprosy have their origin in the polar concept of leprosy[8] and their recent elaboration in the clinical and histologic studies of Ridley and coworkers.[10-12] Cell-mediated immunity against antigens of *M leprae* is believed to determine the following: (1) resistance or susceptibility to infection; (2) the clinical expression of the disease when infection occurs, ie, the niche occupied by the patient on the Ridley scale TT to LL is determined by the degree of cell-mediated immunity toward antigens of *M leprae;* and (3) reversal type of reactions.

From the Armauer Hansen Research Institute, Ethiopia, direct evidence in support of these ideas has been found with the use of the technique of lepromin (antigen)-induced lymphocyte transformation. Godal and Negassi[42] studied lymphocyte responses of previously exposed or unexposed health care personnel; the finding of unresponsiveness in unexposed individuals and a response rate of up to 80% in those with over one year of exposure support the concept of a common subclinical infection with control and subsequent protection being mediated by cell-mediated immunity. Myrvang et al[17] studied lymphocyte responses of patients throughout the Ridley scale, TT to LL; they found progressively decreasing responsivity as one "descended" from TT toward LL and virtually no responsivity at all among LI and LL patients. This finding supports the concept that a patient's Ridley classification (particularly using the five-membered system) is quantitatively related to the degree of cell-mediated immunity directed against antigens of *M leprae*. Godal et al,[44] Samuel et al,[45] and Barnetson et al[46] studied lymphocyte response of patients before, during, and after reactions of the reversal type; they found a definite increase in lymphocyte responsivity to lepromin during the reaction and a decrease during the postreaction phase. The administration of transfer factor to lepromatous (LL) patients is associated with the development of a "reversal" reaction,[22,23] which is further, albeit indirect evidence that such reactions are mediated by cell-mediated immunity.

CELL-MEDIATED IMMUNITY AGAINST ANTIGENS OTHER THAN *M LEPRAE*

Generalized impairment of cell-mediated immune responses, ie, responses to antigens other than those of *M leprae*, has been reported in lepromatous patients (BL to LL) in diverse ethnic groups and from several geographic areas. Methods of study have included intradermal skin tests,[19,28,31,32,47-56] epicutaneous allergic sensitization to a haptene,[19,32,50-53,55-57] allograft rejection,[58] antigen-[17,59-62] or mitogen-induced[19,31,34,39,60,62-69] lymphocyte transformation, and measurement of peripheral[19,70-73] blood T-lymphocytes and lymphokine production in vitro.[31,52]

This generalized impairment of cell-mediated immunity is a phenomenon separable from that of lepromin unresponsiveness. Within populations with a generalized impairment of cell-mediated immunity are some individuals who show no evidence of this impairment[32,57]; some entire populations display no generalized impairment but are, as expected, unresponsive to lepromin.[19,32,68] When the generalized impairment is present, it may diminish with antileprosy chemotherapy,[51,67] but lepromin unresponsiveness persists.[1,29]

The generalized impairment of cell-mediated immunity thus does not appear to be the cause of lepromin unresponsiveness, a predisposing cause of leprosy, or a necessary sequellae of leprosy.

The mechanisms of the generalized impairment of cell-mediated immunity are unknown. In other infectious diseases, an antigen-excess state may be responsible for the development of anergy[74]; in leprosy no direct evidence bears on this point, but it is suggested indirectly by young age and evidently early state of the disease in populations without a generalized impairment of cell-mediated immunity.[19,32,68] Abnormalities in the circulation or percolation patterns of T-lymphocytes has been proposed: Turk and Waters[55,57] noted replacement of paracortical area of lymph nodes by granuloma and suggested that inability to respond normally to dinitrochlorobenzene might be secondary to this. Bullock et al[75] demonstrated changes in splenic lymphocyte populations during *M lepraemurium* infections in mice. Rook[76] demonstrated peripheral decrease in and splenic sequestration of phytohemagglutinin (PHA)-responsive lymphocytes in mice with experimentally produced *M ulcerans* infection. Nelson et al[65] found PHA responsiveness to segregate according to racial groups and suggested that genetic factors may be involved. Clinically inapparent, but histologically evident, diffuse lepromatous infiltration of the skin conceivably could influence epicutaneous haptene sensitization.[77] Other conceivably relevant

mechanisms that have not been studied include nutritional status and the presence of coincidental infections, particularly malaria and intestinal parasitosis.

At present, whether the observed generalized impairment of cell-mediated immunity adversely affects the health of lepromatous patients is open to question. Observations of associated illnesses are difficult to interpret and may be attributable to variables other than leprosy, eg, the high incidence of tuberculosis among some lepromatous groups[78] is apt to be related to a local factor, since Fernandez, in his study of Argentinians, concluded that leprosy and tuberculosis were mutually exclusive diseases.[47] Some reports do suggest that an additional burden does exist in lepromatous patients, including a high incidence of adverse vaccinia reactions,[79] a high incidence of basal cell carcinomas,[80] and a high incidence of lymphoma.[81] These reports are isolated, and other studies where evidence has been sought for a specific vulnerability that arises as a result of impaired cell-mediated immunity, such as immunosurveillance against cancer, no abnormality has been found.[82]

General cell-mediated immune responsivity has not been as extensively studied in tuberculoid patients. In some investigations a generalized impairment has been found, but of less severity than in lepromatous patients.[31,53,63,65,66] In others no generalized impairment has been identified.[31,47,52,62,67]

ANTIBODY-MEDIATED IMMUNITY

Quantitative determinations of serum immunoglobulin levels have demonstrated that lepromatous patients are apt to be hypergammaglobulinemic.[83,84] Quantitative studies of classes of immunoglobulin have shown divergent results, which may be attributable to reactional states, genetic factors, associated diseases, treatment, and disease extent. In lepromatous patients, serum IgG, IgA, and IgM levels have been variously and variably elevated. Lim and Fusaro[85] found substantial elevations of serum IgG and IgM levels; Bonomo and Dammacco,[86] Bullock et al,[87] and Sagher et al[88] found elevations of serum IgG, IgA, and IgM levels; Sheagren et al[89] found elevations of serum IgG and IgA levels; Saha and Mittal[89] found elevations of serum IgM and IgA levels; Malaviya et al[90] found an elevation of serum IgA level only ($P < .02$). The serum IgE level may be normal or even diminished, but is still not thoroughly studied.[91,92] Lim and Fusaro[85] found a significant elevation of IgA in tuberculoid patients, but this finding has not been confirmed by others. Peripheral blood B-lymphocyte levels have been found to be elevated,[70,73,93] normal,[19] or decreased[72] in lepromatous patients.

Lepromatous patients as a group may respond to a specific immunogen with substantially higher antibody titers than do controls: Buck and Hasenclever[19] found higher serum agglutination titers to *Candida albicans* in lepromatous patients than in tuberculoid patients or normals. De Almeida et al[94] found that in response to typhoid vaccination, 60 lepromatous patients produced higher titers of agglutinins to H antigen than did 60 military recruits.

Antimycobacterial antibodies, precipitins,[95-98] agglutinins,[99] and immunofluorescins,[100] are found in the sera of lepromatous patients. These antibodies react with antigens from various mycobacterial species. The lack of a pure antigen makes it impossible to know with certainty if any of the demonstrable antibodies are specific for antigens of *M leprae*. Claims of specificity usually rest on one or more assumptions; for example, (1) the complete removal of antibodies against all but *M leprae*-specific determinants occurs with absorption by material from other mycobacteria; (2) host-tissue antigens that obligatorily contaminate preparations of *M leprae* have no influence on the demonstrated antigen-antibody reactions; (3) antibodies cross-reacting with *M lepraemurium* are induced by specific *M leprae* antigens.

Immune complexes are demonstrable in the sera of lepromatous patients. Cryoglobulins were found[95,101] and proved to be of the mixed type[102,103]; these may have rheumatoid factor activity[102,103] and may contain IgA, Clq, C3, and C4, as well as IgG and IgM.[103] Further serologic evidence for the existence circulating immune complexes includes the presence of a Clq precipitin,[104-106] of a platelet agglutinin,[107] and of a factor that gives a positive Raji cell test.[103]

Less well established is the function of immune complexes in the pathogenesis of clinical phenomena. Wemambu et al[108] and Waters and associates[109] found IgG, IgM, and C3 in the vessel walls of ENL lesions; Fields and Abel[110] and Londono et al[111] found C3 but no immunoglobulin. Quismorio et al[103] found IgG, IgM, and C3 in vessel walls of Lucio phenomenon lesions. In patients with ENL, Drutz and Gutman[112] found a high incidence of glomerulonephritis, which is consistent with immune complex injury.

The questions raised by the existence of immune complexes extend beyond their possible role in the pathogenesis of ENL and Lucio phenomenon. What is the antigen in the Clq precipitable complex? What is the antigenic specificity of the IgG in the cryoglobulin? Could immune complexes have a role in the pathogenesis of LL?

A wide variety of circulating autoantibodies have been described in BL to LL patients[86,89,90,101,102,113-118]; these include antinuclear, antithyroid, and antisperm antibodies and rheumatoid factor. Studies vary in prevalence rates and in specificities found; in our own series, patients did not differ from controls.[19] The differences observed might be attributable to genetic factors, duration of disease, and methods used, but the mechanism of autoantibody production and importance remains obscure. Suggested mechanisms include defective suppressor T cells[96] and cross-reactivity with *M leprae*.[118]

A narrower range of tissue-fixed putative autoantibodies has been reported.[110,119,120] A "band" of IgM at the basement membrane of the epidermis has been observed in one third of LI to LL patients. Complement is not fixed, and the presence of the band is independent of gross involvement of the site with leprosy or the duration of treatment. Similar IgM deposits have been observed on the collagen fibrils of the papillary dermis by Quismorio et al.[120] These antibodies are of unknown importance. Perhaps they cross-react with *M leprae* or are secondary to lepromatous infiltration, but probably are unrelated to identifiable circulating autoantibodies.

Syphilitic reagin directed against cardiolipin antigen is found in the sera of about one third of BL to LL patients and is established as "false-positive" by testing for specific antitreponemal antibodies.[101] Matthews and Trautman[101] found cardiolipin reactivity in the sera disappeared with cryoprotein extraction. Bonomo and Dammacco[86] found cardiolipin reactivity restricted to the 19S fraction in some patients. Abe[121] demonstrated in a phospholipid similar to cardiolipin-lecithin in a lepromatous nodule, which suggests that antibody directed against *M leprae* may be producing the reaction.

IMMUNOTHERAPY

The most ambitious attempt to achieve some control of leprosy by immunologic means has been the use of BCG vaccination. The initial controlled study from Uganda indicated that a reduction in the incidence tuberculoid leprosy in children occurred as a result of BCG vaccination.[122] An ongoing controlled study by WHO is currently in progress in Burma; to date the incidence of leprosy is similar in vaccinated individuals and in controls.[123]

Several exploratory studies of transfer factor[22,23,26] or lymphocyte transfer[24,25,56] therapy have been reported in the treatment of LL patients. All studies have been short-term, but the results have been encouraging. Fernandez reactivity has been irregularly and transiently conferred.[22,25] (Mendes et al[56] reported transfer of Mitsuda reactivity; because the histologic characteristics of these reactions were only briefly described and because the finding has evidently not been reproduced, it is best to regard Mitsuda reactivity as nontransferrable pending further study.) Bacilli have disappeared from tissue at a more rapid rate than seen with chemotherapy.[23] Reversal reactions easily controlled by prednisone have occurred.[22,23] Long-term trials are in progress.

Lim et al[124] reported improvement in lepromatous patients associated with the administration of deliberately mismatched leukocytes. To our knowledge, confirmatory studies have not been reported.

Meyers et al[125] found that levamisole did not alter either Mitsuda or Fernandez reactivity in patients with either positive or negative responses. Nelson et al[126] found that levamisole augmented responsivity to *C albicans* antigen and dinitrofluorobenzene, but not responsivity to tuberculin in borderline and lepromatous patients.

In LL patients, BCG vaccination locally results in bacteriolysis of *M leprae*, which presumably represents a nonspecific effect of activation of macrophages by a specific, immunologic mechanism.[14] At present there is no evidence that nonspecific activation is of any potential therapeutic importance.

PERSPECTIVES

Several points of view have been constructed to explain the pathogenesis of LL.

Polar lepromatous leprosy can be viewed as an example of specific immunologic unresponsiveness (tolerance) toward antigens of *M leprae*.[61] Several models of such specific unresponsiveness are known to exist in animals. Clonal deletion,[127] which is a mechanism of unresponsiveness toward self-antigens, is attractive because it is consistent with the large amounts of *M leprae* that do accumulate. Specific inhibition by antibody or immune complexes[128] is consistent with available data, particularly the high incidence of immune complexes. Specific inhibition by "suppressor" T cells[129,130] is conceivable, but lacks supporting or negating evidence.

Rotberg has postulated a "natural" or N-factor to explain the pathogenesis of LL, and his argument was sympathetically summarized by Newell.[131] Briefly, responsiveness to lepromin and resistance to LL is conferred by an N-factor that is absent at birth but appears with maturation (as walking). The N-factor has three virtues: (1) it is consistent with lepromin reactivity in the absence of exposure or tuberculin reactivity; (2) it is consistent with Dharmendra's epidemiologic findings; (3) it is consistent with the seemingly paradoxical, always low incidence of LL but extremely variable incidence of TT through BB.

The N-factor hypothesis can be partially restated immunologically as the failure or dysfunction of an immune-response gene. The immune-response gene hypothesis[132] holds that immune responses or the lack thereof are under direct genetic control at a hypothetical immune-response locus, close to the HL-A second or B locus and the mixed leukocyte-culture locus. However, seven studies of HL-A antigens have demonstrated no consistent relationship between leprosy and HL-A antigen distribution, and thus provide no support for the immune-response gene hypothesis.[133-139]

Susceptibility to leprosy has been implicitly attributed to immunologic inexperience and is part of the rationale for the use of BCG vaccination, ie, the BCG experience will increase host resistance.

Lim et al[71] postulated that susceptibility to LL can be explained by transient immunoincompetence of the host at the time of initial exposure. Godal et al[42] argued that the predisposition to LL seen in LL families might result from tolerogenic exposure to *M leprae*, ie, prolonged ingestion of organisms. To argue by analogy with experimentally produced leishmaniasis[140] where access to lymphatic vessels by inoculum may be critical in determining whether cure or dissemination results, the potential importance of transient local factors in the pathogenesis of leprosy must be considered.

The immunologic unresponsiveness towards antigens of *M leprae* has been speculatively attributed to metabolic factors unrelated to host immunologic incompetence[5,51]; in such a scheme, an enzymatic failure in a macrophage leads to failure to form immunogen or the formation of a tolerogen. There is no evidence either for or against this idea.

References

1. Rees RJW: The significance of the lepromin reaction in man. *Prog Allerg* 8:224-258, 1964.
2. Wager O: Immunological aspects of leprosy with special reference to autoimmune diseases. *Bull WHO* 41:793-804, 1969.
3. Turk JL, Bryceson ADM: Immunological phenomena in leprosy and related diseases. *Adv Immunol* 13:209-266, 1971.
4. Bullock WE: Leprosy, in Samter M (ed): *Immunological Diseases*. Boston, Little, Brown & Co, 1971, pp 630-643.
5. Skinsnes OK: Immuno-pathology of leprosy: The century in review. *Int J Lepr* 41:329-360, 1973.
6. Convit J, Ulrich M: Recent advances in the immunology of leprosy. *Int J Dermatol* 15:157-170, 1976.
7. Abe M, Allison AC, Bechelli LM, et al:

Immunological problems in leprosy research. *Bull WHO* 48:345-354, 483-494, 1973.

8. Rabello FE, Azulay RD: Immunological principles as a guide to a new leprosy concept: A lifelong study. *Int J Dermatol* 14:770-773, 1975.

9. Arnold HL: Polar concept in leprosy. *Int J Lepr* 42:459-460, 1974.

10. Ridley DS, Jopling WH: A classification of leprosy for research purposes. *Lepr Rev* 33:119-128, 1962.

11. Ridley DS, Jopling WH: Classification of leprosy according to immunity: A five-group system. *Int J Lepr* 34:255-273, 1966.

12. Ridley DS, Waters MFR: Significance of variations within the lepromatous group. *Lepr Rev* 40:143-152, 1969.

13. Drutz DJ, Cline MJ, Levy L: Leukocyte antimicrobial function in patients with leprosy. *J Clin Invest* 53:380-386, 1974.

14. Convit J, Pinardi ME, Ochoa GR, et al: Elimination of *Mycobacterium Leprae* subsequent to local in vivo activation of macrophages in lepromatous leprosy by other mycobacteria. *Clin Exp Immunol* 17:261-265, 1974.

15. Ridley DS: Review of the five-group system for the classification of leprosy according to immunity. *Int J Lepr* 40:102-103, 1972.

16. Russell DA, Shepard CC, McRae DH, et al: Acedapsone (DADDS) treatment of leprosy patients in the Karimui of Papua, New Guinea. *Am J Trop Med Hyg* 24:485-495, 1975.

17. Myrvang B, Godal T, Ridley DS, et al: Immune responsiveness to *Mycobacterium leprae* and other mycobacterial antigens throughout the clinical and histopathological spectrum of leprosy. *Clin Exp Immunol* 14:541-553, 1973.

18. Rea TH, Levan NE: Erythema nodosum leprosum in a general hospital. *Arch Dermatol* 111:1575-1580, 1975.

19. Rea TH, Quismorio FP, Harding B, et al: Immunologic responses in patients with lepromatous leprosy. *Arch Dermatol* 112:791-800, 1976.

20. Latapi F, Zamora AC: The "spotted" leprosy of Lucio (La lepra "manchada" de Lucio). *Int J Lepr* 16:421-437, 1948.

21. Ridley DS: Reactions in leprosy. *Lepr Rev* 40:77-81, 1969.

22. Bullock WE, Fields JP, Brandriss MW: An evaluation of transfer factor as immunotherapy for patients with lepromatous leprosy. *N Engl J Med* 287:1053-1059, 1972.

23. Jacobson RR, Hastings RC, Morales MJ, et al: The treatment of leprosy with transfer factor. *Int J Lepr* 42:507-508, 1974.

24. Paradisi ER, de Bonaparte YP, Morganfield MC: Response in two groups of anergic patients to the transfer of leukocytes from sensitive donors. *N Engl J Med* 280:859-861, 1969.

25. Antia NH, Khanolkar SR: Transfer of cell-mediated immunity in leprosy by transfer of lymph node cells. *Int J Lepr* 42:28-32, 1974.

26. Silva C, Lima AO, Andrade LMC, et al: Attempts to convert lepromatous into tuberculoid-type leprosy with blood lymphocyte extracts from sensitized donors. *Clin Exp Immunol* 15:87-92, 1973.

27. Moschella SL: The lepra reaction with necrotizing skin lesions. *Arch Dermatol* 95:565-575, 1967.

28. Guinto RS: Biology of the mycobacterioses: Skin tests in leprosy. *Ann NY Acad Sci* 154:149-156, 1968.

29. Mukerjee N, Kundu S: The late lepromin reaction in subsided lepromatous cases. *Int J Lepr* 29:14-19, 1961.

30. Leiker DL: Studies on the lepromin test: IV. influence of leprosy on the reactions to lepromin tuberculin and the "875 bacillus" suspension. *Int J Lepr* 29:496-501, 1961.

31. Talwar GP, Krishnan AD, Mehra VL, et al: Evaluation of cell-mediated immune responses in untreated cases of leprosy. *Clin Exp Immunol* 12:195-203, 1972.

32. Convit J, Pinardi ME, Rojas FA: Some considerations regarding the immunology of leprosy. *Int J Lepr* 39:556-564, 1971.

33. Guinto RS, Doull JA, Mabalay EB: A note on the lepromin reaction in males and females of the general population of Cordova, Mactan Island, Cebu, Philippines. *Int J Lepr* 23:131-134, 1955.

34. Guinto RS, Doull JA, Mabalay EB: The Mitsuda reaction in persons with and without household exposure to leprosy. *Int J Lepr* 23:135-138, 1955.

35. Rotberg A, Bechelli LM, Keil H: The Mitsuda reaction in a non-leprous area. *Int J Lepr* 18:209-220, 1950.

36. Shepard CC, Saitz EW: Lepromin and tuberculin reactivity in adults not exposed to leprosy. *J Immunol* 99:637-642, 1967.

37. Waters MFR: Significance of the lepromin test in tuberculin-negative volunteers permanently resident in a leprosy-free area. *Int J Lepr* 41:563, 1973.

38. Doull JA, Guinto RS, Mabalay MC: Effect of BCG vaccination, lepromin testing and natural causes in inducing reactivity to lepromin and to tuberculin. *Int J Lepr* 25:13-33, 1957.

39. Doull JA, Guinto RS, Mabalay MC: The origin of natural reactivity to lepromin. *Int J Lepr* 27:31-42, 1959.

40. Guinto RS, Mabalay MC, Doull JA: Cutaneous responses to lepromin and to other mycobacterial antigens. *Int J Lepr* 30:152-165, 1962.

41. Schujman S: Subsequent evolution of the induced Mitsuda reaction in clinically and bacteriologically negative lepromatous cases. *Int J Lepr* 24:51-56, 1956.

42. Godal T, Negassi K: Subclinical infection in leprosy. *Br Med J* 3:557-559, 1973.

43. Dharmendra, Chatterjee KR: Prognostic value of the lepromin test in contacts of leprosy cases. *Leprosy in India* 27:149-158, 1955 (reprinted in *Int J Lepr* 24:315-318, 1956).

44. Godal T, Myrvang B, Samuel DR, et al: Mechanism of "reactions" in borderline tuberculoid (BT) leprosy: A preliminary report. *Acta Path Microbiol Scand A* 236(suppl):45-53, 1973.

45. Samuel DR, Godal T, Myrvang B, et al: Mechanism of "reactions" in borderline tuberculoid (BT) leprosy. *Int J Lepr* 41:539, 1973.

46. Barnetson R StC, Bjune G, Pearson JMH, et al: Cell-mediated and humoral immunity in "reversal reactions." *Int J Lepr* 44:267-274, 1976.

47. Fernandez JMM: Leprosy and tuberculosis. *Arch Dermatol* 75:101-106, 1957.

48. Guinto RS, Mabalay MC: A note on the tuberculin reaction in leprosy. *Int J Lepr* 30:278-283, 1962.

49. Buck AA, Hasenclever HF: The influence of leprosy on delayed-type skin reactions and serum agglutination titers to *Candida albicans*. *Am J Hyg* 77:305-316, 1963.

50. Waldorf DS, Sheagren JN, Trautman JR, et al: Impaired delayed hypersensitivity in patients with lepromatous leprosy. *Lancet* 2:773-776, 1966.

51. Bullock WE: Studies of immune mechanisms in leprosy: I. Depression of delayed allergic responses to skin test antigens. *N Engl J Med* 278:298-304, 1968.

52. Katz SI, De Betz BH, Zaias N: Production of macrophage inhibitory factor by patients with leprosy. *Arch Dermatol* 103:358-361, 1971.

53. Saha K, Mittal MM: A study of cell-mediated immunity in leprosy: Changing trends in the immunological spectrum of the disease. *Clin Exp Immunol* 8:901-909, 1971.

54. Salazar-Mallen M, Zamora AC, Montes JM, et al: Estudios sobre la inmunidad de la lepra. *Alergia* 18:185-191, 1971.

55. Turk JL, Waters MFR: Immunological significance of changes in lymph nodes across the leprosy spectrum. *Clin Exp Immunol* 8:363-376, 1971.

56. Mendes E, Raphael A, Mota NGS: Cell-mediated immunity in leprosy and transfer of delayed hypersensitivity reactions *J Allerg Clin Immunol* 53:223-229, 1974.

57. Turk JL, Waters MFR: Cell-mediated immunity in patients with leprosy. *Lancet* 2:243-246, 1969.

58. Han SH, Weiser RS, Kau ST: Prolonged survival of skin allografts in leprosy patients. *Int J Lepr* 39:1-6, 1971.

59. Sheagren JN, Block JB, Trautman JR, et al: Immunologic reactivity in patients with leprosy. *Ann Intern Med* 70:295-302, 1969.

60. Bullock WE, Fasal P: Studies of immune mechanisms in leprosy: III. The role of cellular and humoral factors in impairment of the in vitro immune response. *J Immunol* 106:888-899, 1971.

61. Godal T, Myklestad B, Samuel DR, et al: Characterization of the cellular immune defect in lepromatous leprosy: A specific lack of circulating *Mycobacterium leprae*-reacting lymphocytes. *Clin Exp Immunol* 9:821-831, 1971.

62. Han SH, Weiser RS, Lin YC: Transformation of leprous lymphocytes by leprolin, tuberculin and phytohemagglutinin. *Int J Lepr* 39:789-795, 1971.

63. Dierks RE, Shepard CC: Effect of phytohemagglutinin and various mycobacterial antigens on lymphocyte cultures from leprosy patients. *Proc Soc Exp Biol Med* 127:391-395, 1968.

64. Paradisi ER, de Bonaparte YP, Morganfield MC: Blasts in lepromatous leprosy. *Lancet* 1:308-309, 1968.

65. Nelson DS, Nelson M, Thurston JM, et al: Phytohemagglutinin-induced lymphocyte transformation in leprosy. *Clin Exp Immunol* 9:33-43, 1971.

66. Wong PC, Chan-Teoh CH, Wu S, et al: Transformation of lymphocytes by phytohemagglutinin in leprosy sera. *Int J Lepr* 39:7-13, 1971.

67. Mehra VL, Talwar GP, Balakrishnan K, et al: Influence of chemotherapy and serum factors on the mitogenic responses of peripheral leukocytes of leprosy patients to phytohemagglutinin. *Clin Exp Immunol* 12:205-213, 1972.

68. Ulrich M, de Salas B, Convit J: Lymphocyte transformation with phytomitogens in leprosy. *Int J Lepr* 40:4-9, 1972.

69. Balina LM, Fliess EL, Bachmann A, et al: Similar alterations of lymphoblastic dedifferentiation in lepromatous patients and their healthy lepromin-negative consanguinious offspring. *Int J Lepr* 41:7-13, 1973.

70. Dwyer JM, Bullock WE, Fields JP: Disturbance of the blood T:B lymphocyte ratio in lepromatous leprosy: Clinical and immunologic correlations. *N Engl J Med* 288:1036-1039, 1973.

71. Lim SD, Kiszkiss DF, Jacobson RR, et al: Thymus-dependent lymphocytes of peripheral blood in leprosy patients. *Infect Immun* 9:394-399, 1974.

72. Mendes NF, Kipersztych S, Mota GS: T and B lymphocytes in patients with lepromatous leprosy. *Clin Exp Immunol* 16:23-30, 1974.

73. Nath I, Curtis J, Bhutani LK, et al: Reduction of a subpopulation of T lymphocytes in lepromatous leprosy. *Clin Exp Immunol* 18:81-87, 1974.

74. Kantor FS: Infection, anergy and cell-mediated immunity. *N Engl J Med* 292:629-634, 1975.

75. Bullock WE, Evans PD, Wyatt CR: Depletion of lymphocyte subpopulations in the spleen by murine leprosy. *Int J Lepr* 42:509, 1974.

76. Rook GAW: The immunological consequences of antigen overload in experimental mycobacterial infections of mice. *Clin Exp Immunol* 19:167-177, 1975.

77. Rea TH, Gottlieb B, Levan NE: Apparently normal skin in lepromatous leprosy. *Arch Dermatol* 111:1571-1574, 1975.

78. Gray HH, Bancroft H: Tuberculosis at the United States Public Health Service, Carville, Louisiana. *Int J Lepr* 20:467-478, 1952.

79. Saha K, Mittal MM: Consequences of smallpox vaccination in leprosy patients. *Infect Immun* 8:301-308, 1973.

80. Michalany J: Malignant tumors of the skin among leprosy patients. *Int J Lepr* 34:274-286, 1966.

81. Rodriguez E, de Bonaparte YP, Morganfield MC et al: Malignant lymphomas in leprosy patients: A clinical and histologic study. *Int J Lepr* 36:203-212, 1968.

82. Oleinick A: Altered immunity and cancer risk: a review of the problem and analysis of the cancer mortality experience of leprosy patients. *J Nat Cancer Inst* 43:775-781, 1969.

83. Ishihara S: Studies on serum protein in leprosy. First and second reports. *La Lepro* 19:3-11, 1950.

84. Hoxter G, Batista L, Vellini LL. Estudios electrofroeticos nas diversas formas clinicas da lepra. *Rev Bras Leprol* 19:27-40, 1951.

85. Lim SD, Fusaro RM: Leprosy. IV. The quantitation of immunoglobulins (IgG, IgM and IgA) in leprosy sera. *Int J Lepr* 36:144-153, 1968.

86. Bonomo L, Dammacco F: Protein changes and immunity in some chronic infectious diseases, in Chini V, Bonomo L, Sirtori C (eds): *Proceedings of the International Symposium on Gammopathies, Infectious Cancer and Immunity.* Milan, Italy, Carlo Erba Foundation, 1968, pp 12-24.

87. Bullock WE, Ho MF, Chen MJ: Studies of immune mechanisms in leprosy: II. Quantitative relationships of IgG, IgA and IgM immunoglobulins. *J Lab Clin Med* 75:863-870, 1970.

88. Sagher F, Sheskin J, Zlotnick A, et al: Complement and immunoglobulin determinations in leprosy and lepra reaction. *Int J Lepr* 39:541-553, 1971.

89. Saha K, Mittal MM: Immunologic aspects of lepromatous leprosy with special reference to the study of antibodies. *Int J Lepr* 40:260-264, 1972.

90. Malaviya AN, Pasricha A, Paricha JS, et al: Significance of serologic abnormalities in lepromatous leprosy. *Int J Lepr* 40:361-365, 1972.

91. Grabosz JAJ, Derblom H, Godal T: IgE serum levels in leprosy. *Acta Path Microbiol Scand B* 81:806-807, 1973.

92. Hamburger RN, Fernandez-Cruz E, Arnaiz A, et al: The relationship of the P-K titre to the serum IgE level in patients with leprosy. *Clin Exp Immunol* 17:253-260, 1974.

93. Gajl-Peczalska KJ, Lim SD, Jacobson RR, et al: B lymphocytes in lepromatous leprosy. *N Engl J Med* 288:1033-1035, 1973.

94. De Almeida JO, Brandao H, de Lima EG: Enhanced serologic response of lepromatous patients to antityphoid vaccination. *Int J Lepr* 32:292-296, 1964.

95. Ulrich M, Pinardi ME, Convit J: A study of antibody response in leprosy. *Int J Lepr* 37:22-27, 1969.

96. Abe M: Studies on the antigenic specificity of *Mycobacterium leprae:* I. Demonstration of soluble antigens in leprosy nodules by immunodiffusion. *Int J Lepr* 38:113-125, 1970.

97. Navalkar RG: Immunologic studies on leprosy: I. Demonstration of antibodies in sera of leprosy patients using mycobacterial antigens. *Jap J Exp Med* 40:467-472, 1970.

98. Axelsen NH, Barboe M, Closs O, et al: BCG antibody profiles in tuberculoid and lepromatous leprosy. *Infect Immun* 9:952-958, 1974.

99. Levine M: Hemagglutination of tuberculin sensitized sheep cells in Hansen's disease (leprosy). *Proc Soc Exp Med Biol* 76:171-173, 1951.

100. Matsuo E, Skinsnes OK: Specific direct fluorescent antibody identification of Mycobacterium leprae. *Int J Lepr* 43:204-209, 1975.

101. Matthews LJ, Trautman JR: Clinical and serological profiles in leprosy. *Lancet* 2:915-918, 1965.

102. Bonomo L, Dammacco F: Immune complex cryoglobulinemia in lepromatous leprosy: A pathogenetic approach to some clinical features of leprosy. *Clin Exp Immunol* 9:175-181, 1971.

103. Quismorio FP, Rea TH, Levan NE, et al: Immunopathologic studies in Lucio's phenomenon. *Clin Res* 24:97A, 1976.

104. Moran CJ, Ryder G, Turk JL, et al: Evidence for circulating immune complexes in lepromatous leprosy. *Lancet* 2:572-573, 1972.

105. Rojas-Espinosa O, Mendez-Navarrete I, Estrada-Parra S: Presence of Clq-reactive immune complexes in patients with leprosy. *Clin Exp Immunol* 12:215-223, 1972.

106. Gelber RH, Drutz DJ, Epstein WV: Clinical correlates of Clq-precipitating substances in the sera of patients with leprosy. *Am J Trop Med Hyg* 23:471-475, 1974.

107. Wager O, De Almeida JO, Godal T, et al: Platelet aggregation and cryoglobulin IgM in the study of circulating complexes in leprosy. *Int J Lepr* 41:554, 1973.

108. Wemambu SNC, Turk JL, Waters MFR, et al: Erythema nodosum leprosum: A clinical manifestation of the Arthus phenomenon. *Lancet* 2:933-935, 1969.

109. Waters MFR, Turk JL, Wemambu SNC: Mechanisms of reactions in leprosy. *Int J Lepr* 39:417-428, 1971.

110. Fields JP, Abel EA: Immunofluorescent abnormalities in leprosy patients. *Arch Dermatol* 111:1164-1165, 1975.

111. Londono F, Pararroyo ME, de Rueda MMD, et al: Erythema nodosum leprosum. *Arch Dermatol,* to be published.

112. Drutz DJ, Gutman RA: Renal manifestations of leprosy: Glomerulonephritis, a complication of erythema nodosum leprosum. *Am J Trop Med Hyg* 22:496-502, 1973.

113. Cathcart ES, Williams RC, Ross H, et al: The relationship of the latex fixation test to the clinical and serologic manifestations of leprosy. *Am J Med* 31:758-765, 1961.

114. Bonomo L, Tursi A, Trimigliozzi G, et al: LE cells and antinuclear factors. *Br Med J* 2:689-690, 1965.

115. Abe M, Chinone S, Hirako T: Rheumatoid-factor-like substance and antistreptolysin O antibody in leprosy serum. *Int J Lepr* 35:336-344, 1967.

116. Petchclai B, Chuthanondh R, Rungruong S, et al: Autoantibodies in leprosy among Thai patients. *Lancet* 1:1481-1482, 1973.

117. Wright DJM: Autoantibodies in leprosy. *Lancet* 2:40, 1973.

118. Wall JR, Wright DJM: Antibodies against testicular germinal cells in lepromatous leprosy. *Clin Exp Immunol* 17:51-59, 1974.

119. Bullock WE, Callerame ML, Panner BJ: Immunohistologic alteration of skin and ultrastructural changes of glomerular basement membrane. *Am J Trop Med Hyg* 23:78-83, 1974.

120. Quismorio FP, Rea TH, Levan NE, et al: Immunoglobulin deposits in lepromatous leprosy skin. *Arch Dermatol* 111:331-334, 1975.

121. Abe M: Serological relationship of leprosy, tuberculosis and syphilis: II. In vitro antigenicity of the lipid recovered from leprous nodule. *La Lepro* 26-28:59-65, 1960.

122. Brown JAK: Studies of BCG vaccination against leprosy in Uganda. *Ann NY Acad Sci* 154:237-243, 1968.

123. Bechelli LM, Garbajosa PG, Gyi MM, et al: BCG vaccination of children against leprosy: Seven-year findings of the controlled WHO trial in Burma. *Bull WHO* 48:323-334, 1973.

124. Lim SD, Fusaro R, Good RA: Leprosy: VI. The treatment of leprosy patients with intravenous infusions of leukocytes from normal persons. *Clin Immunol Immunopathol* 1:122-139, 1972.

125. Meyers WM, Kvernes S, Staple EM: Failure of levamisole to alter the lepromin reaction. *Am J Trop Med Hyg* 24:857-859, 1975.

126. Nelson KE, Pagels GA, Batt MD, et al: Studies of levamisole in lepromatous leprosy. *Clin Res* 24:350A, 1976.

127. Nossal GJV, Pike BL: Unifying concepts in tolerance induction for various T and B cell sub-populations, in Katz DH, Benacerraf B (eds): *Immunologic Tolerance.* New York, Academic Press Inc, 1974, pp 351-371.

128. Diener E: Is there a unifying concept for diverse models of tolerance induction?, in Katz DH, Benacerraf B (eds): *Immunologic Tolerance.* New York, Academic Press Inc, 1974, pp 543-561.

129. Clamen HN, Phanuphak P, Moorhead JW: Tolerance to contact sensitivity—a role for suppressor T cells?, in Katz DH, Benacerraf B (eds): *Immunologic Tolerance.* New York, Academic Press Inc, 1974, pp 123-128.

130. Zinkernagel R, Doherty P: Indications of active suppression in mouse carriers of lymphocytic choriomeningitis virus, in Katz DH, Benacerraf B (eds): *Immunologic Tolerance.* New York, Academic Press Inc, 1974, pp 403-412.

131. Newell KW: An epidemiologist's view of leprosy. *Bull WHO* 34:827-857, 1966.

132. McDevitt HO, Bodmer WF: HL-A, immune-response genes and disease. *Lancet* 1:1269-1275, 1974.

133. Escobar-Gutierrez A, Gorodezky C, Salazar-Mallen M: Distribution of some of the HL-A system lymphocyte antigens in Mexicans. *Vox Sang* 25:151-155, 1973.

134. Thorsby E, Godal T, Myrvang B: HL-A antigens and susceptibility to diseases: II. Leprosy. *Tissue Antigens* 3:373-377, 1973.

135. Kriesler M, Arnaiz A, Perez B, et al: HL-A antigens in leprosy. *Tissue Antigens* 4:197-201, 1974.

136. Reis AP, Maia F, Reis VF, et al: HL-A antigens in leprosy. *Lancet* 2:1384, 1974.

137. Dasgupta A, Mehra NK, Ghei SK, et al: Histocompatibility antigens in leprosy. *Tissue Antigens* 5:85-87, 1975.

138. Smith GS, Walford RL, Shepard CC, et al: Histocompatibility antigens in leprosy. *Vox Sang* 28:42-49, 1975.

139. Rea TH, Levan NE, Terasaki P: Histocompatibility antigen in patients with leprosy. *J Infect Dis,* to be published.

140. Kadivar DMH, Soulsby EJL: Model for disseminated cutaneous leishmaniasis. *Science* 190:1198-1200, 1975.

Gamma Benzene Hexachloride Toxicity

A Review

Lawrence M. Solomon, MD; Lester Fahrner; Dennis P. West, MS

Scabies has once again become a major health problem. Currently, the most frequently used antiscabetic substance is a lotion containing 1% of the pesticide, gamma benzene hexachloride (lindane). Because of its widespread use in humans and because of some anecdotal communications suggesting that toxic reactions may have been observed in children treated for scabies with gamma benzene hexachloride, we felt it would be of interest to review toxicity of the substance and examine the indications and methods currently recommended for its use.

Gamma benzene hexachloride is the γ isomer of 1,2,3,4,5,6-hexachlorocyclohexane (HCCH). It is the chlorine analogue of muco-inositol.[1] It is a nonaromatic compound whose physical properties are given in the Figure.

Gamma benzene hexachloride is present in several products sold under a number of trade names. Although gamma benzene hexachloride was probably first synthesized by Michael Faraday in 1825, the pure alpha, beta, gamma, and delta isomers were not prepared until 1943 by J. C. Smart. Since that time, three other isomers have been found. The use of hexachlorocyclohexane as an insecticide was first investigated in 1942. The gamma isomer alone proved to be an effective insecticide, useful against a wide spectrum of insects and mites.[2] Since then, gamma benzene hexachloride has found numerous public health and agricultural applications.[3,4]

TOXICITY STUDIES

The acute toxicity of gamma benzene hexachloride administered by various routes has been determined in a number of warm-blooded species. The oral lethal dose for 50% survival of a group (LD_{50}) for mouse, rat, guinea pig, rabbit, dog, and sparrow ranged from 60 to 230 mg/kg of body weight. Gamma benzene hexachloride administered via subcutaneous injection in rat, guinea pig, and rabbit had an LD_{50} of from 50 to 100 mg/kg of body weight. Intraperitoneal injection resulted in an LD_{50} of 35 to 85 mg/kg of body weight in the rat, and intravenous injection had an LD_{100} of 6 mg/kg of body weight in rabbits. The LD_{50} values from cutaneous applications in the mouse, rat, guinea pig, and rabbit range from 300 to 500 mg/kg of body weight.[5] In rabbits, LD_{50} dropped from 4,000 mg/kg of body weight when gamma benzene hexachloride was applied in dry form to 50 mg/kg body weight when it was applied in an unspecified solvent,[6] indicating that the vehicle plays an important role in percutaneous penetration. Lipid vehicles increase absorption. Gamma benzene hexachloride is considered moderately toxic when compared to other insecticides. Death results often from neurotoxic effects and usually follows muscle spasms and epileptiform convulsions.[3,7,8] Necropsy of animals and humans partially poisoned by it demonstrates fatty infiltration and enlargement of the liver, pulmonary edema, numerous small brain hemorrhages, and necrosis of the wall of the small vessels.[3]

The varied responses of experimental animals subjected to gamma benzene hexachloride toxicity have been compiled in Tables 1 and 2.

The physiologic impact of exposure to gamma benzene hexachloride is in part a function of the route of administration, the dosage,[11] and the health and nutrition[42] of the animal[22] to whom it is administered. Since it is a chlorinated hydrocarbon, it is processed by the liver, primarily stored in depot fat and secondarily in other lipophilic tissues.[17,18] It is cleared from the body more readily than many other chlorinated insecticides,[17] and male rats clear the compound faster than females,[43] which may offer a

Accepted for publication Sept 13, 1976.

From the Department of Dermatology, Abraham Lincoln School, College of Medicine (Dr Solomon and Mr Fahrner), and the Department of Pharmacy Practice, College of Pharmacy (Mr West), University of Illinois, Chicago.

Reprint requests to Department of Dermatology, PO Box 6998, Chicago, IL 60680 (Dr Solomon).

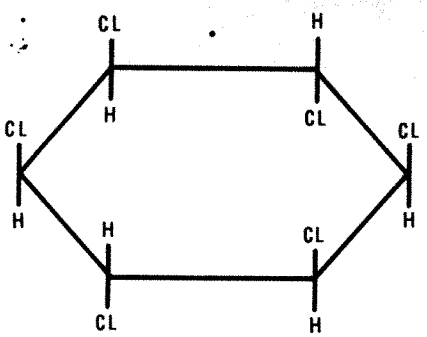

Chemical properties of gamma benzene hexachloride. Molecular weight, 290.84 white crystalline powder. Melting point, 112.5 C H_2O in solution (nonpolar solvent solution).

partial explanation of the greater susceptibility of the latter to toxicity.[35] In brain tissue, there is a clear preference for gamma benzene hexachloride storage in the white matter to the extent that is has been used as an experimental convulsant.[29]

Young animals appear to be particularly susceptible to gamma benzene hexachloride toxicity[44] and appear to store the substance more readily and for a longer time in the adipose tissue. Differences in animal sensitivity to gamma benzene hexachloride may be due to differences in rates of absorption, excretion rate, liver cell function, differential fatty distribution, and undefined species and individual response factors.

USES OF GAMMA BENZENE HEXACHLORIDE IN VETERINARY MEDICINE

Gamma benzene hexachloride is used as a spray, dip, or dust in veterinary medicine against ectoparasites and as a general insecticide. Its use is contraindicated in emaciated, very young, or lactating animals.[45] It has been applied against mange, lice, ticks, and fleas, as a dusting powder (0.5% to 1%), which is thoroughly brushed off after ten minutes as a spray, and most commonly as a dip in concentrations of .02% to .06%. Considerable mortality of cattle has been reported from accidental ingestion[46] or improper dipping of the animals.[21,23,47,48] As a result, precautions are clearly printed on the labels of the pharmaceuticals destined for veterinary use.

Table 1.—Disposition of Gamma Benzene Hexachloride in Experimental Animals

Route of Entry	Absorption	Local Effects	Storage
Respiratory system	Yes	Tracheitis; chemical pneumonitis	Unknown
GI tract	Absorption varies with vehicle,[10,11] simultaneous use of chlorophenols,[12,20] exercise[12-18]	Possibly gastritis and enteritis	Found in fat, kidney, brain, blood, liver, adrenals, muscle, spleen, and milk of lactating animals
Skin	Varies with particle size, exposure period, vehicle,[40] hair length of animal's coat[8,19,21,25,39]	Dermatitis; hyperkeratosis, abscess formation	Subcutaneous fat[22]

Table 2.—Toxic Effects of Gamma Benzene Hexachloride in Experimental Animals

Tissue	Toxic Symptoms	Reference Nos.
Bone marrow	Depression of hematopoiesis	24
	Porphyria*	25
Peripheral nervous system	Degeneration of neurons	26
	Sympathetic ganglionic blocking agent	27
	Lower excitability of retina	28
CNS	Seizures	7, 8
	Concentration in white matter	29, 30
	Raises threshold to seizures induced by other agents	31, 32
	Learning impairment	33
Genitals	Testicular atrophy and hypertrophy	34
Kidneys	Fatty degeneration, necrosis and compromise of function. Fat deposits in proximal convoluted tubule	7, 35, 36
Liver	Benign hepatomas	3, 37, 38
	Fatty degeneration of liver with compromise of function	5, 21, 24, 26, 35, 36, 40
Immune system	Decreased IgG response to antigen	41

*Not to be confused with hexachlorobenzene-induced porphyria.

HUMAN USE

In 1948, Wooldridge[49] successfully treated human scabies with 1% gamma benzene hexachloride cream. With recrudescence of scabetic dermatitis in recent years, this treatment is now widely used and appears to be effective.[49-52] Gamma benzene hexachloride has also been effectively used topically against pediculosis.[50,53] Although the treatment remains effective, there may be an increasing number of treatment failures.[52]

When gamma benzene hexachloride was given orally as an emulsion against oxyuriasis,[54] four of the 15 subjects treated experienced toxic symptoms, and the treatment was not considered acceptable. The reported symptoms of human gamma benzene hexachloride toxicity are as follows: nausea, vomiting, convulsions, respiratory failure with cyanosis, and sometimes death.[54-57] Recommended treatment for acute poisoning includes saline gastric lavage, emesis, oxygen therapy, calcium thiosulfate (or gluconate) injections, and phenobarbital.[9,48,53,55,57-59] Necropsy studies on patients who have had fatal reactions to gamma benzene hexachloride have detected fatty infiltration of the liver, degeneration of cardiac muscle, and necrosis of the vessels of the lungs, kidneys, and brain.

Chronic gamma benzene hexachloride exposure may occur by absorption through the skin or lungs, or gastrointestinal tract and may cause blood dyscrasias and hematopoietic depression.[9,59-72] Some of the observed effects of the hematologic system may have occurred by an immunologic mechanism,[73] since gamma benzene hexachloride was found to block the blas-

togenic effect of phytohemagglutinin on cultured human lymphocytes.[74] It was postulated that the block may result from inhibition of phosphatidylinositol formation. Inhibition of phosphatidylinositol formation by gamma benzene hexachloride was also seen in some neural preparations of experimental animals.[8,27,75] The structural similarilty of muco-inositol to phosphatidylinositol may play a central role in understanding gamma benzene hexachloride toxicity.

In a study of workers chronically exposed to gamma benzene hexachloride, a correlation was made[76] between amounts of exposure (via air and skin contact) and gamma benzene hexachloride levels in the blood. The length of exposure did not correlate positively with the blood level, and tissue levels were not studied. Examination of the formed elements of the blood in the subjects studied was not consistent with the notion of simple toxic suppression of hematopoiesis, although idiosyncratic disease responses or rare hypersensitivity could not be ruled out.[76-78] A study of pesticide worker in Hungary[79] demonstrated strong correlation between blood gamma benzene hexachloride levels above 0.02 ppm and EEG abnormalities in 15 of 17 subjects. Chronic exposure to gamma benzene in humans has also resulted in depressed liver function,[80,81] altered menses,[82] and cardiac arrhythmias.[83]

The first suggestion that major toxicity and death could be caused by exposure of the skin to gamma benzene hexachloride was reported in 1953.[58] Seventy-nine persons were affected by a 40% mixture of gamma benzene hexachloride isomers applied to the household environment, including bed covers, clothes, as well as the subjects' body surfaces. Initial symptoms were lassitude, headache, vertigo, and myalgia, followed by intestinal colic, diarrhea, and stomatitis. Finally, CNS symptoms were seen: mental confusion, blindness, dysarthria, and convulsions. One patient died following degeneration of the liver and kidneys.

In another incident a farmer had the following progression of symptoms after contact with gamma benzene hexachloride and chlorophenothane (DDT): burning and peeling of the skin, nausea, submandibularis gland abscess, mental slowness, extrasystoles, panmyelophthisis, and death. All parenchymal organs studied had been infiltrated with fat.[71]

After applying gamma benzene hexachloride in acetone to intact human skin (forearm) at least 9.3% of the substance was found by Feldmann and Maibach[84] to be absorbed and excreted in the urine during the following five days. The scrotal skin posed virtually no barrier to penetration of gamma benzene hexachloride and other pesticides.[85] Wolfe believed cutaneous penetration to be the most important route in poisoning of pesticide formulators and sprayers.[86] Topical contact with gamma benzene hexachloride was followed by urticaria,[3,87] eczema,[50,88] and in one case report, gamma benzene hexachloride mixed with chlorophenothane was followed by alopecia.[83] The cause and effect relationship between these last symptoms and gamma benzene hexachloride has not been established.

COMMENT

Although there is not total agreement about every aspect of gamma benzene hexachloride toxicity it is reasonably clear that the reported toxic effects of accidental poisoning in animals and humans bears a striking similarity to the rare anecdotal communications of complications in humans being treated for scabies with gamma benzene hexachloride lotion (headache, nausea, transient seizures). The recommendations for treatment of scabies with gamma benzene hexachloride includes its use after a hot soapy bath and a single application for 24 hours. However, the *minimum* requisite time of application resulting in a reasonable cure rate is not known. In 1948, Wooldridge[49] reported 95% of his patients were mite-free with the regimen recommended above, and the same regimen seems to have been advocated and used ever since by most practitioners treating scabies.

Although some aspects of the percutaneous absorption of gamma benzene hexachloride have been studied,[84,85] it is fallacious to assume that such data reflect its percutaneous penetrability in patients whose epidermal barrier has been damaged by chronic excoriation. The biological effects of equal doses of medications such as gamma benzene hexachloride may be greater in infants than in adults, but there are no pediatric dosage guidelines available. In fact, premature infants absorb greater amounts percutaneously. Certain areas of the body, such as the scrotum, appear to offer virtually no barrier to absorption. We have no clear evidence concerning the effects of gamma benzene hexachloride on embryonic tissue, particularly those of the human. Finally, the long-term effects of exposure are not well-known.

Considering the present data, and until more information becomes available about the specific treatment needs of scabies, the following observations and suggestions may have some merit.

1. Gamma benzene hexachloride should not be applied after a hot soapy bath. It seems unreasonable to increase percutaneous absorption of the substance when the organism to be attacked is in the epidermis. It should probably be applied on dry, cool skin. If a cleansing bath is to be taken, the skin should first be permitted to dry and cool. Cannon and McCrae[39] found the application to be quite effective without bathing.

2. Since we do not know how long we must apply gamma benzene hexachloride to effect a cure, the presently used regimen of application for 24 hours may be unnecessarily long if shorter contact time may be effective.

3. A concentration weaker than 1% may suffice, particularly for badly excoriated skin.

4. Commercially available 1% concentrations of gamma benzene hexachloride dosage forms should be used with extreme caution, if at all, in pregnant women, very small infants, and people with massively excoriated skin.

5. Recently, a gamma benzene hexachloride spray for the home environment has been marketed. There seems to be no demonstrated urgent need for such a spray. The spray itself may

pose unknown environmental hazards.

6. The use of gamma benzene hexachloride shampoo for pediculosis is probably relatively safe if the contact time is brief.

7. There are other available treatments for scabies, such as crotamiton and benzyl benzoate and sulfur, and these should be reconsidered when the patients are very young, pregnant, or badly excoriated.

8. Retreatment of patients with gamma benzene hexachloride should not take place before eight days and then only if active organisms can be demonstrated.

Finally, gamma benzene hexachloride is an effective agent against a major human health problem. Its potential for toxic effects should be recognized and since it remains unknown, the minimum appropriate dose needed to effect a cure needs to be determined.

Nonproprietary Names and Trademarks of Drugs

Gamma benzene hexachloride—*Gamiso, Gexane, Kwell.*
Crotamiton—*Eurax Cream.*

References

1. Hornstein I: Nomenclature and structure of 1,2,3,4,5,6-hexachlorocyclohexane. *Science* 121: 206-207, 1955.
2. Slade RE: The γ isomer of hexachlorocyclohexane. *Chem Ind* 64:314-319, 1945.
3. Hayes W: *Clinical Handbook on Ecomonic Poisons*, publication 476. US Government Printing Office, 1963.
4. Todd RG (ed): *Extra Pharmacopeia, Martindale*, ed 25. London, The Pharmaceutical Press, 1967, pp 525 and 528.
5. Von Oettingen WF: *The Halogenated Hydrocarbons: Their Toxicity and Potential Dangers*, PHS publication 44. US Department of HEW, US Government Printing Office, 1955, pp 272-275.
6. Lehman AJ: The toxicology of the newer agricultural chemicals. *Bull Assoc Food Drug Office* 12:82-89, 1948.
7. Cameron GR, Burgess F, cited by Von Oettingen WF: *The Halogenated Hydrocarbons: Their Toxicity and Potential Dangers*, PHS publication 44. US Department of HEW, US Government Printing Office, 1955, pp 272-275.
8. St Omer V: Investigation into mechanisms responsible for seizures induced by chlorinated hydrocarbon pesticides. *J Neurochem* 18:365-374, 1971.
9. Conley BE: Toxic effects of technical benzene hexachloride and its principle isomers. *JAMA* 147:571-574, 1951.
10. Albro PW, Thomas R: Intestinal absorption of hexachlorobenzene and hexachlorocyclohexane isomers in rats. *Bull Environ Contam Toxicol* 12:289-294, 1974.
11. Coper H, Herken H, Clempau J: Zur pharmakologie und toxikologie chlorierter cyclohexane. *Naunyn Schmiedebergs Arch Pharmacol* 212:463-471, 1951.
12. Freal JJ, Chadwick RW: Metabolism of hexachlorocyclohexane to chlorophenols and effect of isomer pretreatment on lindane metabolism in rat. *J Agric Food Chem* 21:424-472, 1973.
13. Koransky W, Portig J, Munch G: Resorption, verteilung und ausscheidung von α und γ hexachlorocyclohexan. *Naunyn Schmiedebergs Arch Pharmacol* 244:564-575, 1963.
14. Koransky W, Portig J, Vohland HW, et al: Die Elimination von α und γ hexachlorocyclohexan und ihre beeinflussung durch enzyme den lebermtkrosonen. *Naunyn-Schmiedebergs Arch Pharmacol* 247:49-60, 1964.
15. Chadwick RW, Cranmer MF, Peoples AJ: Comparative Stimulation of γ HCH metabolism by pretreatment of rats with γ HCH, DDT, and DDT+ γ HCH. *Toxicol Appl Pharmacol* 18:685-695, 1971.
16. Clausen J, Konat G: Enzymic and behavioral changes induced in mice fed polychlorinated biocides followed by starvation. *Experientia* 28:402-403, 1972.
17. Laug EP: Tissue distribution of atoxicant following oral ingestion of the gamma isomer of benzene hexachloride in rats. *J Pharmacol Exp Ther* 93:277-281, 1948.
18. Davidow B, Frawley JP: Tissue distribution, accumulation and elimination of the isomers of benzene hexachloride. *Proc Soc Exp Biol Med* 76:780-783, 1951.
19. Dikshith TSS, Chandra P, Datta KK: Effect of lindane of the skin of albino rats. *Experientia* 29:684-685, 1973.
20. Dikshith TSS, Datta KK, Chandra P: Interaction of lindane and diazinon on the skin of rats. *Exp Pathol (Jena)* 9:219-224, 1974.
21. Ray AC, Norris JD, Reagor JC: Benzene hexachloride poisoning in cattle. *JAVMA* 166:1180-1182, 1975.
22. Davey RJ, Johnson LA: Tissue residues, blood chemistry, and physiological response of lindane-treated swine. *J Anim Sci* 38:318-324, 1974.
23. Ely RE, Underwood PC, Moore LA, et al: Observations on lindane poisoning in dairy animals. *JAVMA* 123:448-449, 1953.
24. Barke A, cited by Von Oettingen WF: *The Halogenated Hydrocarbons: Their Toxicity and Potential Dangers*, PHS publication 44. US Department of HEW, US Government Printing Office, 1955, pp 272-275.
25. Simon N, Siklosi C: Experimentelles porphyrie-modell mit hexachlor-cyklohexan. *Z Hautkr* 49:497-504, 1974.
26. Dallemayne MJ, Gerebtzoff MA, Phillipot E: Surcharge lipidique de l'organisme dans l'intoxication chronique du chien par le γ Hexachlorocyclohexane. *Experientia* 6:274, 1950.
27. White GL, Larrabee MG: Phosphoinositides and other phospholipids in sympathetic garglia and nerve trunks of rats. *J Neurochem* 20:783-798, 1973.
28. Schway F, Kaschowitz H: Das flimmer-electroretinopramm des frosches unter der einwirkung von hexachlorocyclohexan. *Acta Biol Med Germ* 21:205-212, 1968.
29. Litterst CL, Miller E: Distribution of lindane in brains of control and phenobarbital pretreated dogs at the onset of lindane-induced convulsions. *Bull Environ Contam Toxicol* 13:619-624, 1975.
30. Koransky W, Ullberg S: Distribution in the brain of ^{14}C-benzenehexachloride: Autoradiographic study. *Biochem Pharmacol* 13:1537-1538, 1974.
31. Herken H, Klempau I, cited by Von Oettingen WF: *The Halogenated Hydrocarcons: Their Toxicity and Potential Dangers*, PHS publication 44. US Department of HEW, US Government Printing Office, 1955, pp 272-275.
32. Herken H, Kewitz H, Klempau I: Wirkungsverluste von krampfgiften durch hexachlorocyclohexan. *Naunyn Schmiedebergs Arch Exper Path Pharmacol* 215:217-230, 1950.
33. Desi I: Neurotoxicological effect of small quantities of lindane. *Int Arch Arbeitsmed* 33:153-162, 1974.
34. Dikshith TSS, Datta KK: Effect of intratesticular injection of lindane and endrin on the testes of rats. *Acta Pharmacol Toxicol (Kbh)* 31: 1-10, 1972.
35. Fitzburgh OG, Nelson AA, Holland OL: Comparison of the chronic toxicity of alpha, beta, and gamma isomers of benzene hexachloride. *J Pharmacol Exp Ther* 8:291-292, 1949.
36. Dallemagne J, Gerebtzoff MA, Phillipot E: Fat deposits in the kidney in chronic intoxication of the dog by hexachlorocyclohexane. *Science* 112:148, 1950.
37. Herbst M, Weisse I, Koellmer H: A contribution to the question of the possible hepatocarcinogenic effects of lindane. *Toxicology* 4:91-96, 1975.
38. Goto M, Hattori M, Miyagawa T, cited by Herbst M, Weisse I, Koellmer H: A contribution to the question of the possible hepatocarcinogenic effects of lindane. *Toxicology* 4:91-96, 1975.
39. Cannon AB, McCrae ME: Treatment of scabies. *JAMA* 138:557-560, 1948.
40. Grzycki S, Zarebska A: Histoenzymatic studies on the liver cell after the administration of gamma benzene hexachloride. *Z Mikrosk Anat Forsch* 87:470-476, 1973.
41. Wassermann M, Wassermann D, Kedan F, et al: Effects of dieldrin and gamma BAC on serum proteins and PBI. *Bull Environ Contam Toxicol* 8:177-185, 1972.
42. Boyd EM, Chen CP: Lindane toxicity and lindane deficient diet. *Arch Environ Health* 17:156-163, 1968.
43. Frawley JP, Fitzhugh DG: Rate of disappearance of isomers of benzene hexachloride from fat deposits in rats. *Fed Proc* 8:242-243, 1949.
44. Radeleff RD, Bushland RC: Acute toxicity of chlorinated insecticide applied to livestock. *J Econ Entomol* 43:358-364, 1950.
45. Siegmund OH (ed): *The Merck Veterinary Manual*, ed 4. Rahway NJ, The Merck Co, 1973.
46. McFarland PS, McCracken RM, O'Hare MB, et al: Benzene hexachloride poisoning in cattle. *Vet Rec* 93:369-371, 1973.
47. Radeleff RD, Bushland RC, cited by Dikshith TSS, Datta KK, Chandra P: Interaction of lindane and diazinon on the skin of rats. *Exp Pathol (Jena)* 9:219-224, 1974.
48. Heiberg OM, Wright HN: Benzene hexachloride poisoning. *Arch Indust Health* 11:457-458, 1955.
49. Wooldridge WE: The gamma isomer of hexachlorocyclohexane in the treatment of scabies. *J Invest Dermatol* 10:363-366, 1948.
50. Spühler H: Die behandlung der scabies und der pediculosen mit gamma-hexachlorcyclohexan. *Schweiz Med Wochenschr* 84:701-704, 1954.
51. James BHE: Gamma benzene hexachloride as a scabicide. *Br Med J* 1:178-179, 1972.
52. Hurwitz S: Scabies in babies. *Am J Dis Child* 126:226-228, 1973.
53. Huff BJ (ed): *Physicians Desk Reference*, ed 30. Oradell NJ, Medical Economics Co, 1976, pp 1241-1242.
54. Graeve K, Herrnring G: Toxische wirkung des gamma hexachlorocyclohexan bei seiner anwendung als anthelminticum am menschen.

Klin Wochenschr 28:622-623, 1950.

55. Stur O, Zweymüller E: Diagnose und therapie der akuten γ hexachlorocyclohexanvergiftung bei kleinkindern. *Dtsch Med Wochenschr* 86:1474-1476, 1961.

56. McNamara BGP: Benzene hexachloride poisoning. *Br Med J* 3:585, 1970.

57. Starr HG, Clifford NJ: Acute lindane intoxication. *Arch Environ Health* 25:374-375, 1972.

58. Kay RWW, Kuder GG, Sessler WA, et al, cited by McNamara BGP: Benzene hexachloride poisoning. *Br Med J* 3:585, 1970.

59. Danopoulos E, Melissinos K, Katsas G: Serious poisoning by hexachlorocyclohexane. *Arch Industr Hyg Chicago* 8:582-587, 1953.

60. Best WR: Drug associated blood dyscrasias. *JAMA* 185:286-290, 1963.

61. Sanchez-Medal L, Costanedo JP, Garci-Rojas F: Insecticides and aplastic anemia. *N Engl J Med* 269:1365-1367, 1963.

62. Hoshizaki H, Niki Y, Tajima H, et al: A case of leukemia following exposure to insecticides. *Acta Haematol Jap* 32:672-677, 1969.

63. Friberg L, Martensson K, Katsas G: Case of panmyelophithisis after exposure to chlorophenothane and benzene hexachloride. *Arch Industr Hyg Chicago* 8:166-164, 1953.

64. Loge JP: Aplastic anemia following exposure to benzene hexachloride (lindane). *JAMA* 193:110-114, 1965.

65. West I: Lindane and hematologic reactions. *Arch Environ Health* 15:97-101, 1967.

66. Stieglitz R, Stobbe H, Schutzmann W: Knochenmarkschäden nach beruflicher einwirkung des insectizids gamma-hexachlorocyclohexan (lindane). *Acta Haematol Basel* 38:337-350, 1967.

67. Jedlicka VL, Hermanska Z, Smida I, et al: Paramyeloblastic leukemia appearing simultaneously in two blood cousins after simultaneous contact with gammexane (hexachlorocyclohexane). *Acta Med Scand* 161:447-451, 1958.

68. Albahary C, Pulrisay J, Guerin, cited by West I: Lindane and hematologic actions. *Arch Environ Health* 15:97-101, 1967.

69. Mendeloff AL, Smith DE: Exposure to insecticides bone marrow failure, gastrointestinal bleeding, and uncontrollable infections. *Am J Med* 19:274-284, 1955.

70. Scott JL, Cartwright GE, Wintrobe MM: Acquired aplastic anemia: Analysis of 39 cases and review of pertinent literature. *Medicine* 38:119-172, 1959.

71. Bauer E, Reisner G: Ein Fall von Panmyelophthise mach versprühung eines hexachlorocyclohexan-haltigen spritzmittels in Österreich. *Monatsschr Ohrenheilkd und Laryngorhinol* 104:492-495, 1970.

72. Woodliff HJ, Conner PM, Scopa J: Aplastic anemia associated with insecticides. *Med J Aust* 1:628-629, 1966.

73. Steiglitz R, Stobbe R, Schultzmann W, et al: Zum pathomechanismus von panmyelophthisen durch das insektizid lindan. *Folia Haematol (Leipz)* 91:293-301, 1969.

74. Fisher DB, Mueller GC: Gamma-hexachlorocyclohexane inhibits the initiation of lymphocyte growth by phytohemagglutinin. *Biochem Pharmacol* 20:2,515-2,518, 1971.

75. Hokin MR, Brown DF: Inhibition by γ hexachlorocyclohexane of acetylocholine stimulated phosphatidylinositol synthesis in cerebral cortex slices and of phosphatidic acid-inositol transferase in cerebral cortex particulate fractions. *J Neurochem* 16:475-483, 1969.

76. Milby TH, Samuels AJ, Ottoboni F: Human exposure to lindane: Blood lindane levels as a function of exposure. *J Occup Med* 10:584-587, 1968.

77. Samuels AJ, Milby TH: Human exposure to lindane: Comparison of an exposed and unexposed population. *J Occup Med* 13:147-151, 1971.

78. Milby TH, Samuels AJ: Human exposure to lindane: Comparison of an exposed and unexposed population. *J Occup Med* 13:256-258, 1971.

79. Czegledi-Janko G, Avar P: Occupational exposure to lindane: Clinical and laboratory findings. *Br J Ind Med* 27:283-286, 1970.

80. Abdel-Koder MM, Emara AM, Kamel G, et al: Chemico-pathological changes in the liver of industrial workers chronically exposed to cotton dust. *J Egypt Med Assoc* 54:489-501, 1971.

81. Schuttmann W: Chronische lebererkrankungen nach beruflichen einwirkung von DDT un HCH. *Int Arch Gewerbepath Gewerbehyg* 24:193-210, 1968.

82. Ilina VI, Blekherman NA: Some data on the specific functions of the female organism in women working with hexachlorocyclohexane. *Pediatr Akush Ginekol* 1:46-49, 1974.

83. Haustein UF: Chlorkohlenwasserstoffhaltiges pestizid als ursache einer toxischen alopecie. *Z Haut Geschlechtskr* 43:105-108, 1968.

84. Feldmann RJ, Maibach HI: Percutaneous penetration of some pesticides and herbicides in man. *Toxicol Appl Pharmacol* 28:126-132, 1974.

85. Maibach HI, Feldmann RJ, Milly TH, et al: Regional variation in percutaneous penetration in man. *Arch Environ Health* 23:208-211, 1971.

86. Wolfe HR: Protection of workers from exposure to pesticides. *Pest Control* 40:17-42, 1972.

87. Conley BE: Health problems in vaporizing and fumigating devices for insecticides. *JAMA* 152:1,232-1,234, 1953.

88. Baumgartner O: Uberempfindlichkeit auf hexachlorocyclohexane. *Schweiz Med Wochenschr* 83:1043-1094, 1953.

PROBABLY WON'T CARRY FACE CLOTHS...
BUT THEY MIGHT CARRY

THERAPADS PLUS®

TO COMPLEMENT ANY ACNE REGIMEN

☐ CONVENIENT CLEANSING— ANYTIME, ANYWHERE

Therapads Plus provide effective cleansing and drying actions to remove excess surface oiliness... cleanse deeply, thoroughly, and antiseptically. Therapads Plus are pleasantly scented and saturated with a colorless solution of 70% ethyl alcohol, 1.5% salicylic acid, and 0.1% sodium alkyl aryl polyether sulfonate.

☐ HELP CONTROL OILY SKIN, BLACKHEADS, ACNE

Used 2 or 3 times a day—such as midmorning, midafternoon and bedtime—Therapads Plus help keep skin clean, and free from oil between soap and-water washings; also help dry existing blemishes.

Therapads Plus—available in boxes of 30 foil-wrapped pads. Therapads (regular)—available in jars of 40 and 100.



FULLER LABORATORIES, INC.
SUBSIDIARY OF
PARKE, DAVIS & COMPANY
EDEN PRAIRIE, MN 55343

PARKE-DAVIS

PARKE, DAVIS & COMPANY
Detroit, MI 48232

FD-JA 2130-1-C (12-76)

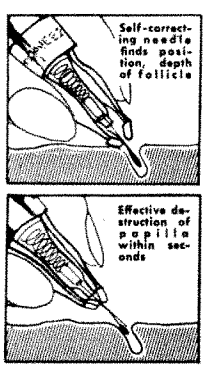

Perma Tweez®

ELECTROLYSIS FOR PERMANENT HAIR REMOVAL

Clinical study (copy on request) proves safety and efficacy of laity self-use electrolysis. Study shows chin and even axilla can be self-treated effectively through use of mirror. This permanent hair remover features the only patented self-correcting needle in existence. Battery operated instrument sterilizes itself when current flows. No-puncture safety feature also helps prevent infection.

Thousands of units sold to physicians for such varied application as removal of inverted eyelashes to cosmetic use.

PERMA TWEEZ & ATTACHMENT $22.45

☐ Invoice after 30 days

☐ Check enclosed

30 DAY FREE TRIAL EXAMINATION

(MAY BE RETURNED WITH NO OBLIGATION)

GENERAL MEDICAL CO., Dept. D-83
1935 Armacost Ave
West Los Angeles, CA 90025

DR _____
STREET _____
C/S _____ ZIP _____

Now, a dry skin lotion formulated to meet the exacting requirements of atopics

Carmol® Ten Lotion The Dry Skin Lotion with the Light Touch.
Carmol Ten Lotion relieves the itching and rough feel of dry skin; restores and retains the normal softness of skin.

Contains 10% Urea for its moisturizing action and cosmetic effect.
Lipid free, non-occlusive: contains no petrolatum, no mineral oil.
Hypoallergenic: contains no lanolin, parabens or other sensitizing preservatives.
Carmol Ten is available in pharmacies in 6 fluid ounce bottles.
Samples on request.

Ingram Pharmaceutical Company, San Francisco 94111 © IPC. 1976

The seven most important reasons to prescribe a topical antifungal. Right at your fingertips.

1 It is effective against the most prevalent fungal pathogens. MicaTin brand miconazole nitrate 2% offers exceptional effectiveness against the most difficult-to-treat pathogen—*Trichophyton rubrum*, and is equally effective against *Trichophyton mentagrophytes, Epidermophyton floccosum, Candida albicans* and *Malassezia furfur.*

2 It clears the most common fungal infections. MicaTin provides outstanding clinical and mycological efficacy in tinea pedis,* tinea corporis* and tinea cruris* as well as candidiasis and tinea versicolor.

3 It relieves symptoms quickly. Within 72 hours for the majority of patients. Within 1 to 2 weeks for virtually all patients.

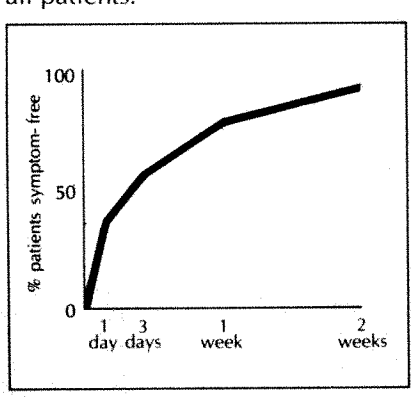

4 It demonstrates effectiveness in extensive studies. Clinical studies† demonstrate the outstanding success rate of MicaTin in the treatment of tinea pedis, tinea corporis and tinea cruris, when used with the recommended dosage of twice daily for one month. At the end of therapy, 88—94% of the patients were clinically clear.

The clinical studies of patients with candidiasis and tinea versicolor are equally impressive. Nine out of ten patients with candidiasis or tinea versicolor were clinically and mycologically clear within two weeks—the recommended duration of treatment.

Pathogen	Infection	Conversion KOH	Culture	Clinical Clearance or Improvement
Trichophyton rubrum	Tinea pedis	82%	86%	88%
Trichophyton mentagrophytes / *Epidermophyton floccosum*	Tinea corporis / Tinea cruris	93%	90%	94%
Candida albicans	Candidiasis†	92%	86%	88%
Malassezia furfur	Tinea versicolor	89%	—	92%

5 Its low relapse rate promises an outstanding chance of cure. To prove how effective MicaTin really is in keeping fungal infections clear, we evaluated these same patients one month later (median).† Of the 121 patients who were clear of tinea pedis, tinea corporis and tinea cruris at the end of treatment *and* were available for follow-up, 92% showed no clinical or mycological recurrence of the original infection.

And of the 34 patients cleared of cutaneous candidiasis *and* available for follow-up, 91% were still clear two weeks later (median).

6 It has a low incidence of side effects. Reports of "burning" sensation, irritation and maceration with MicaTin have been few and isolated. Naturally, it should not be used in patients with known hypersensitivity to any of its ingredients.

7 It is economically priced. The retail price of MicaTin is usually lower than that of other prescription antifungals.

Introducing new
MicaTin Lotion
brand miconazole nitrate 2%
12 ml. and 30 ml. bottles

MicaTin cream
brand miconazole nitrate 2%
new 85 g. (3 oz.) tube
and familiar 1 oz. and 15 g. sizes

Description: MicaTin brand miconazole nitrate cream 2% and lotion 2% each contain miconazole nitrate‡ 2%, formulated into a water miscible base consisting of pegoxol 7 stearate, peglicol 5 oleate, mineral oil, benzoic acid, and butylated hydroxyanisole.

Actions: Miconazole nitrate is a synthetic antifungal agent which inhibits the growth of the common dermatophytes, *Trichophyton rubrum, Trichophyton mentagrophytes,* and *Epidermophyton floccosum,* the yeast-like fungus, *Candida albicans,* and the organism responsible for tinea versicolor *(Malassezia furfur).*

Indications: For topical application in the treatment of tinea pedis (athlete's foot), tinea cruris, and tinea corporis caused by *Trichophyton rubrum, Trichophyton mentagrophytes,* and *Epidermophyton floccosum,* in the treatment of cutaneous candidiasis (moniliasis), and in the treatment of tinea versicolor.

Contraindications: MicaTin has no known contraindications.

Precautions: If a reaction suggesting sensitivity or chemical irritation should occur, use of the medication should be discontinued.

For external use only. Avoid introduction of MicaTin brand miconazole nitrate cream 2% and lotion 2% into the eyes.

Adverse Reactions: There have been isolated reports of irritation, burning, and maceration associated with application of MicaTin.

Dosage and Administration: Sufficient MicaTin cream should be applied to cover affected areas twice daily (morning and evening) in patients with tinea pedis, tinea cruris, tinea corporis, and cutaneous candidiasis and once daily in patients with tinea versicolor. It is preferable to use MicaTin lotion in intertriginous areas; if the cream is used, it should be applied sparingly and smoothed in well to avoid maceration effects.

Early relief of pruritus (first week) and early clinical improvement (one to two weeks) have been seen in treatment of infections caused by common dermatophytes. Even though clinical improvement may be seen fairly soon after treatment is begun, *Candida* infections should be treated for two weeks and dermatophyte infections for one month in order to reduce the possibility of recurrence. If a patient shows no clinical improvement after a month of treatment, the diagnosis should be redetermined. Patients with tinea versicolor usually exhibit clinical and mycological clearing after two weeks of treatment.

How Supplied: MicaTin brand cream 2% containing miconazole nitrate at 2% strength is supplied in 1 oz., 15 g., and 3 oz. tubes. MicaTin brand lotion 2% containing miconazole nitrate at 2% strength is supplied in polyethylene squeeze bottles in quantities of 12 and 30 ml.

*When infecting organisms are *Trichophyton rubrum, Trichophyton mentagrophytes* and *Epidermophyton floccosum.*

†Data for tinea pedis is based on 4 weeks' therapy in 138 patients; for tinea cruris and tinea corporis—4 weeks' therapy in 50 patients; for tinea versicolor—2 weeks' therapy in 38 patients; for candidiasis—2 weeks' therapy in 23 patients and 4 weeks' therapy in 20 patients. (There was no significant difference in effectiveness between the two candidiasis groups.) Data on file, Dermatological Division, Johnson & Johnson.

‡Chemical name: 1-[2,4-dichloro-β-[(2,4-dichlorobenzyl) oxy] phenethyl] imidazole mononitrate.

An ethical specific from the Dermatological Division of

Johnson & Johnson

New Brunswick, New Jersey 08903

MicaTin Cream/Lotion

BRAND miconazole nitrate 2%

It all adds up to confidence.

AAD Task Force Report

Dermatologic Radiotherapy and Thyroid Cancer

Herbert Goldschmidt, MD

The increased risk of thyroid cancer in patients who received therapeutic doses of x-radiation to the head, neck, and upper part of the thorax for various nonmalignant conditions during infancy and childhood is well recognized. Recent publicity through articles in local newspapers and journals and announcements via radio and television has alarmed many patients who are aware of such irradiation. The Task Force on Ionizing Radiation of the National Program for Dermatology has been contacted by many colleagues requesting advice on the proper procedure to follow with patients who were treated in the past for benign skin conditions. Published recommendations by various specialists are contradictory, particularly concerning the benefits and risks of radioactive diagnostic procedures and the need for recall of irradiated patients. Recent statements by the National Cancer Institute and the American Thyroid Association, Inc, have helped considerably to clarify this situation.

Accepted for publication June 29, 1976.

From the Task Force on Ionizing Radiation of the National Program for Dermatology.

Reprint requests to Suite 620, One Bala-Cynwyd Plaza, Bala-Cynwyd, PA 19004 (Dr Goldschmidt).

The following recommendations are partially excerpted from the summary of a workshop, "Late Effects of Irradiation of the Head and Neck in Infancy and Childhood,"[1] held at the National Cancer Institute (NCI) in Bethesda, Md, in September 1975, which was attended by leading representatives of various medical specialties. The report from the workshop is the most authoritative statement on this matter and supersedes other recommendations. Similar recommendations were endorsed by the American Thyroid Association, Inc.[2]

Thyroid Cancer

Thyroid cancer is a relatively rare disease; it occurs twice as frequently in females as in males. The incidence increases with age. It is estimated that it will account for approximately 1,150 deaths in the United States in 1976 and that 8,100 new cases will be diagnosed. The age-adjusted rate of thyroid cancer in the United States in 1969-1971 was 3.7/100,000.[3] Autopsies of patients dying with no known thyroid disease have revealed small foci of cells that appear malignant in up to 5.7% of the glands.[3] The true incidence of thyroid cancer in *irradiated* individuals is therefore difficult to assess. There is no doubt, however, that the incidence of thyroid cancer is significantly increased in some patients 5 to 35 years after they received radiation therapy for various benign conditions during infancy and childhood, particularly for enlargement of the thymus, hypertrophy of tonsils and adenoids, cervical adenitis, mastoiditis, sinusitis, tinea capitis, hemangiomas, and keloids of the head and neck. The participants in the workshop agreed that only a small percentage of irradiated individuals develop thyroid tumors. Most of the tumors found have been benign, and most of those that are malignant have been well-differentiated papillary or follicular neoplasms or both, which grow slowly, metastasize relatively late, and are curable by surgery while still localized. (A relatively high incidence was found in a well-publicized study from Michael Reese Hospital in Chicago,[4,5] where 27% of 1,056 irradiated individuals recalled showed various thyroid abnormalities; thyroid carcinomas were found in 33% of 60 of the affected patients on surgical exploration.)

Thyroid Cancer and Dermatologic X-Ray Therapy

1. **Radiotherapy of Various Skin Conditions.**—The great majority of pub-

lished reports of thyroid abnormalities refer to radiation treatments of nondermatologic problems during infancy. Radiotherapy for dermatologic conditions is mentioned as a possible causative factor of such abnormalities in only a small number of patients.[4,6,7] Two large studies indicate an increased risk of thyroid nodules or thyroid cancer or both in children treated for tinea capitis with very penetrating radiation qualities.[8,9] Indiscriminate radiotherapy of hemangiomas and other benign skin diseases of the neck region during infancy and early childhood is clearly associated with an increased risk to the thyroid gland. Most of these indications are obsolete now and require no further discussion. Patients who were treated for these conditions in the past should be followed up as described below. The only remaining indication for radiotherapy in young age groups is the treatment of selected cases of acne[10]; other indications must be exceedingly rare.

2. **Radiotherapy of Acne *Without* Radiation Protection.**—Dermatologists have been using radiation protection measures for several decades. During radiotherapy of acne, cones are employed by most dermatologists to reduce scatter radiation to the thyroid and other body regions; a lead shield over the thyroid area serves to further reduce unnecessary exposure.

A different situation exists in patients who were treated without the benefits of cones or thyroid shields or both, particularly when the neck area was deliberately or inadvertently exposed to full therapeutic doses. Because of the increased risk of thyroid abnormality, these patients should be examined every two years. This also applies when accurate records of radiation exposure are not available.

3. **Radiotherapy of Acne With Radiation Protection.**—Is radiotherapy of acne associated with an increased risk to the thyroid gland when modern radiation protection measures are used and relatively superficial radiation qualities are applied? The Task Force on Ionizing Radiation believes that presently available statistical data[4,6,7] are insufficient to substantiate a causative relationship and suggests further in-depth studies to clarify this problem. Since no other equally effective form of treatment was available, radiotherapy was given to a large number of dermatological patients until 1950; the occurrence of thyroid cancer in a very limited number of these irradiated patients could therefore be coincidental. It is also conceivable that the biological effects of small fractionated weekly doses of ionizing radiation reaching more mature thyroid tissue are significantly less hazardous than those observed following radiotherapy with one or two high doses directly to the thyroid region during infancy and early childhood. Few dermatologists treated acne with x-radiation before the age of 16 to 18 years when the thyroid is considered to be fully developed and less radiosensitive.[1] Even more important is the fact that the majority of dermatologists have used cones to reduce scatter radiation even before 1950. The effectiveness of cones in dermatologic x-ray therapy has been demonstrated by thermoluminescence dosimetry.[11] Many dermatologists also have applied lead shields routinely to the thyroid region for additional protection. Compared to diagnostic roentgenographic methods, the dose reaching the thyroid is extremely small when proper radiation protection measures are used.[11]

Identification of Patients

Although the participants in the NCI workshop agreed that it would be desirable to recall for examination every patient who received radiation therapy, they concluded that, for the most part, this would be logistically impossible. It is estimated that there are over 1 million individuals in the United States who have been irradiated for benign conditions in the head and neck areas[12]; in many instances radiation records are no longer available or patients have moved and are difficult or impossible to locate. The NCI group felt that recall efforts should be encouraged but that a low-keyed public education program would be more appropriate. This program should educate the public about the problem, stressing the need for medical examination, the low incidence of cancer, and the high probability of cure.

Diagnostic Measures

The main recommendation of the NCI consultants was that all individuals with a history of head or neck irradiation should be examined periodically (at least every two years) indefinitely.

Most patients with radiation-related thyroid tumors are asymptomatic. Inspection and palpation of the thyroid gland are the two most important measures of the clinical evaluation. The presence of a palpable nodule is the most conclusive evidence of a thyroid abnormality. Only a small percentage of palpable tumors show malignant changes. Most tumors grow very slowly and metastases are rare and usually occur late. Laboratory studies are less important than clinical findings. The majority of workshop participants concluded that a thyroid scan is *not mandatory,* if palpation of the gland by an experienced examiner reveals no abnormalities. In the absence of palpable abnormalities, careful re-examination is recommended at least every two years.

When the palpation of the thyroid reveals one or more firm, discrete nodules, the majority of consultants believed that these should be removed surgically. They agreed that radioisotope scans contribute little useful information and that most discrete nodules should be removed without consideration of a scan. (Some specialists disagree with this view and recommend thyroid imaging procedures on all patients with a history of irradiation, whether or not palpable nodules are present. The new technetium Tc 99m scintigram is far safer [estimated dose to the adult thyroid: 0.1 rad][13,14] than the older and still widely used radioactive imaging procedure with ^{131}I, which delivers a relatively high radiation dose [100-200 rads]).

Current Use of Dermatologic Radiotherapy for Benign Conditions

Ionizing radiation has been used in the treatment of benign diseases by

many medical specialties. The growing awareness of potential side effects has led to the recognition that in most instances radiotherapy should be limited to diseases where other forms of treatment have failed or are expected to fail. The advisability of continuing radiotherapy for certain benign diseases by various medical specialties, and the potential risks of ionizing radiation therapy are presently being investigated by a committee of the National Academy of Sciences/National Research Council, which includes radiotherapists, radiobiologists, radiophysicists, epidemiologists, geneticists, thyroid specialists, pediatricians, thyroid surgeons, ophthalmologists, and dermatologists. The Task Force on Ionizing Radiation is planning to issue guidelines for dermatologic radiotherapy, based on the recommendations of this committee. These guidelines will summarize modern indications and techniques and describe appropriate radiation protection measures. Until then radiotherapy for benign skin conditions should be given only with proper radiation protection (cones; eye, thyroid, and gonad shielding). The least penetrating, effective radiation qualities (eg, grenz rays) should be preferred and doses should be limited to the smallest effective individual and total dose.

References

1. The National Cancer Institute: Information for physicians on irradiation-related thyroid cancer. *CA* 26:150, 1976.
2. McConahey MW, Hayles AB: Radiation and thyroid neoplasia. *Ann Intern Med* 84:749, 1976.
3. Sampson RJ, Woolner LB, Bahn RC, et al: Occult thyroid carcinoma in Olmsted County, Minnesota: Prevalence at autopsy compared with that in Hiroshima and Nagasaki, Japan. *Cancer* 34:2072-2076, 1974.
4. Refetoff S, Harrison J, Karanfilski BT, et al: Continuing occurrence of thyroid carcinoma after irradiation to the neck in infancy and childhood. *N Engl J Med* 292:171-175, 1975.
5. Favus JJ, Schneider AB, Stachura ME, et al: Thyroid malignancy occurring as a late consequence of head and neck irradiation: Evaluation of 1,056 patients. *N Engl J Med* 294:1019, 1976.
6. DeGroot L, Paloyan E: Thyroid carcinoma and radiation: A Chicago endemic. *JAMA* 225:487, 1973.
7. Albright EC, Allday RW: Thyroid carcinoma after radiation therapy for adolescent acne vulgaris. *JAMA* 199:280, 1967.
8. Modan B, Baldatz D, Mart H, et al: Radiation induced head and neck tumors. *Lancet* 1:277, 1974.
9. Albert RE, Omran AR: Follow-up study of patients treated by x-ray epilation for tinea capitis. *Arch Environ Health* 17:899, 1968.
10. Goldschmidt H: Ionizing radiation therapy in dermatology: Current use in the United States and Canada. *Arch Dermatol* 111:1511, 1975.
11. Petratos MA, Grisewood EN, Wingate C: Measurement of scattered radiation to body areas during radiotherapy of basal cell epitheliomas. *Dermatol Int* 8:10, 1969.
12. Frohman LA: Irradiation and thyroid carcinoma: Legacy and controversy. *J Chronic Dis*, to be published.
13. Arnold J, Pinsky S, Ryo UY, et al: 99m Tc Pertechnetate thyroid scintography in patients pre-disposed to thyroid neoplasms by prior radiotherapy to the head and neck. *Radiology* 115:653, 1975.
14. Weber PM, Jasko IA, Dos Remodios LV: Thyroid scintophotography in 1,000 patients: Rational use of ^{99m}Tc and ^{131}I compounds. *J Nucl Med* 12:673-677, 1971.

Desquam-X®

5 or 10% Benzoyl Peroxide 6% Polyoxyethylene Lauryl Ether

the topical side of C. acnes control

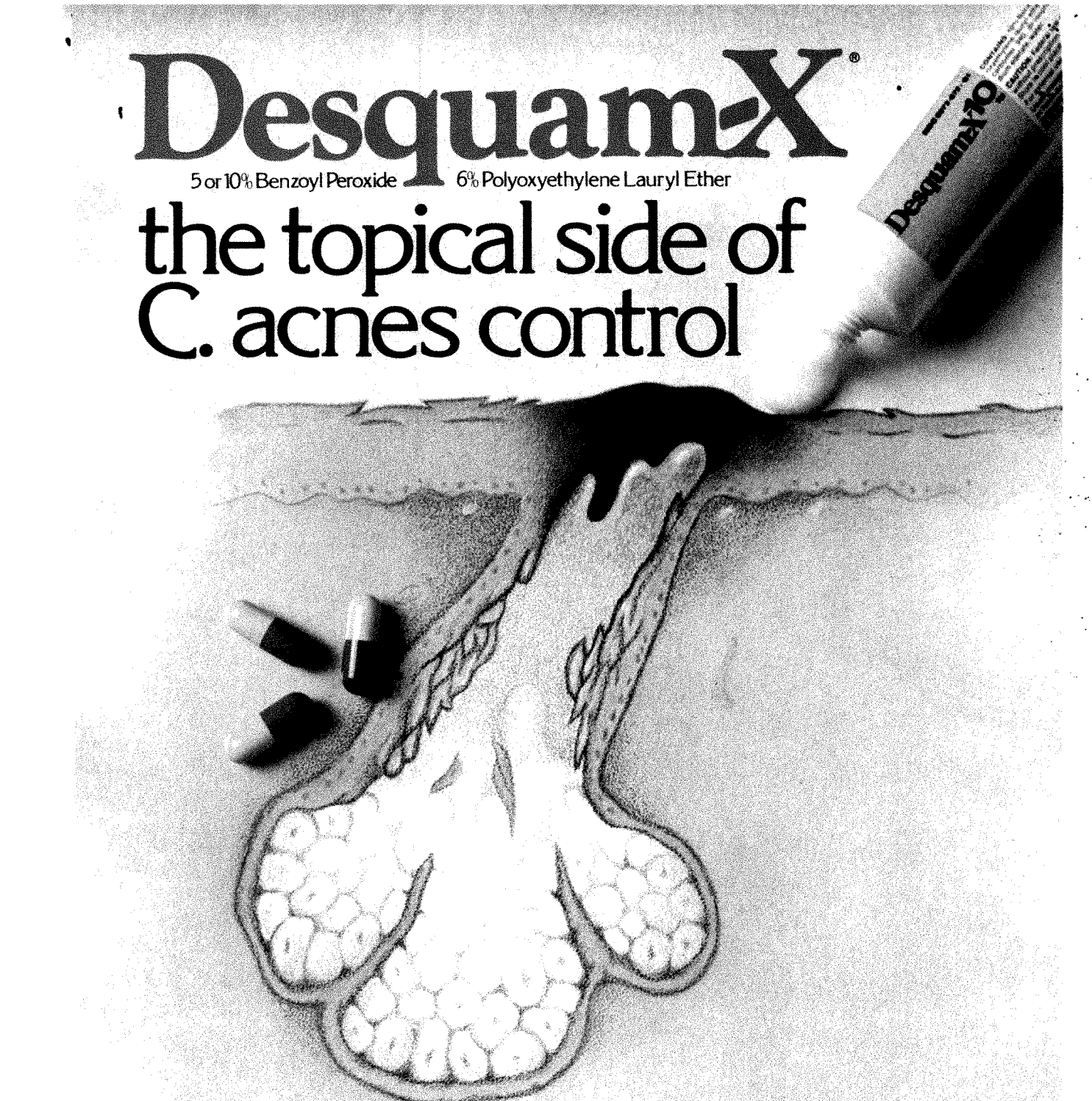

Desquam-X5®

Desquam-X10®

CONTENTS: Desquam-X 5 contains 5% Benzoyl Peroxide, 6% polyoxyethylene lauryl ether, 37% ethyl alcohol, carbomer 940, di-isopropanolamine, disodium edetate and water.

Desquam-X 10 contains 10% Benzoyl Peroxide, 6% polyoxyethylene lauryl ether, 37% ethyl alcohol, carbomer 940, di-isopropanolamine, disodium edetate and water.

INDICATION: A topical aid for the control of acne vulgaris.

ACTION: Provides the desirable drying and desquamation needed in the topical treatment of acne. Desquam-X has been demonstrated to have anti-bacterial effects, especially against Corynebacterium acnes.

DIRECTION FOR USE: After washing as instructed, rub Desquam-X into affected areas twice daily. In fair-skinned individuals or under excessively dry atmospheric conditions it is suggested that therapy be initiated with one application daily. The desired degree of drying and peeling can be obtained by modification of the dosage schedule.

CONTRAINDICATIONS: Not to be used in patients known to be sensitive to any ingredient of Desquam-X.

PRECAUTIONS: Avoid contact with eyes and mucous membranes. For external use only. Keep this and all medication out of the reach of children.

NOTE: May bleach colored fabrics.

HOW SUPPLIED: Plastic tubes 1.5 oz. (42.5 gm.)

CAUTION: Federal law prohibits dispensing without prescription.

WESTWOOD
PHARMACEUTICALS INC.
Buffalo, New York 14213
In Canada, Belleville, Ontario K8N1E2

©1975 W. P. Inc.

AVEENO®
Colloidal Oatmeal
bath for sensitive skin

When you treat inflammatory diseases, such as wet dermatitis (including allergic, atopic and contact), intertrigo or wet pruritus, a colloidal oatmeal bath may prove valuable, adjunctive therapy.

Soak Away The Discomfort With AVEENO COLLOIDAL OATMEAL.

- **Cleans naturally**—a soap-free way to absorb dirt and excess oil.
- **Comforts gently**—soothingly soaks hard-to-reach and widespread problem areas.
- **Long-lasting protection**—colloidal oatmeal film continues to protect after bathing.
- **Helps restore normal skin pH.**

Available in 1 lb. and 4 lbs. boxes.

Cooper Laboratories, Inc., Wayne, N.J. 07470 Cooper

CUT THE GRISEOFULVIN DOSE IN HALF

Gris-PEG®
(griseofulvin ultramicrosize)
Tablets 125 mg

For fungal infections sensitive to griseofulvin

- Only half the dose required*
- Absorption nearly complete without fatty meals
- Once-a-day or b.i.d. dosage
- Reduced cost for patients

*250 mg of Gris-PEG® provides plasma levels equivalent to those obtained with 500 mg microsize griseofulvin. This improved absorption permits the oral intake of half as much griseofulvin but there is no evidence, at this time, that this confers any clinical difference in regard to safety or efficacy.



Dorsey LABORATORIES
Division of Sandoz Inc.
LINCOLN, NEBRASKA 68501

Please see other side for full prescribing information

Gris-PEG®
(griseofulvin ultramicrosize) Tablets 125 mg
The ½ dose griseofulvin.

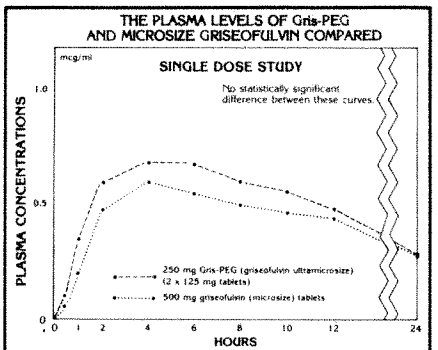

Based on a single dose double-blind bioavailability study conducted in 24 human volunteers comparing the average griseofulvin (microsize) and Gris-PEG plasma levels. There is no significant difference between peak plasma levels, times to peak, and areas under the curve. Gas chromatographic assay.

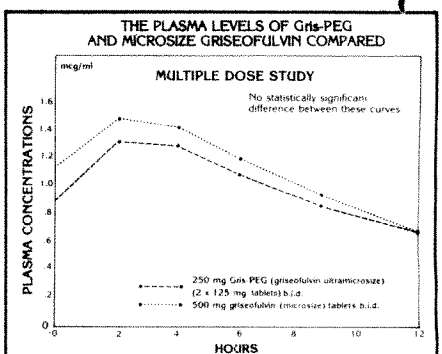

Based on a double-blind multiple dose steady state crossover bioavailability study conducted in 17 human volunteers comparing the average griseofulvin (microsize) and Gris-PEG plasma levels obtained on days 9, 11 and 13. There is no significant difference between times to peak, peak plasma levels, and areas under the curve. Gas chromatographic assay.

DESCRIPTION

Griseofulvin is an antibiotic derived from a species of *Penicillium*.

Gris-PEG is an ultramicrocrystalline solid-state dispersion of griseofulvin in polyethylene glycol 6000.

Gris-PEG tablets differ from griseofulvin (microsize) tablets USP in that each tablet contains 125 mg of ultramicrosize griseofulvin biologically equivalent to 250 mg of microsize griseofulvin.

ACTION

Microbiology: Griseofulvin is fungistatic with *in vitro* activity against various species of *Microsporum, Epidermophyton* and *Trichophyton*. It has no effect on bacteria or other genera of fungi.

Human Pharmacology: The peak plasma level found in fasting adults given 0.25 g of Gris-PEG occurs at about four hours and ranges between 0.37 to 1.6 mcg/ml.

Comparable studies with microsize griseofulvin indicated that the peak plasma level found in fasting adults given 0.5 g occurs at about four hours and ranges between 0.44 to 1.2 mcg/ml.

Thus, the efficiency of gastrointestinal absorption of the ultramicrocrystalline formulation of Gris-PEG is approximately twice that of conventional microsized griseofulvin. This factor permits the oral intake of half as much griseofulvin per tablet but there is no evidence, at this time, that this confers any significant clinical differences in regard to safety and efficacy.

Griseofulvin is deposited in the keratin precursor cells and has a greater affinity for diseased tissue. The drug is tightly bound to the new keratin which becomes highly resistant to fungal invasions.

INDICATIONS

Gris-PEG (griseofulvin ultramicrosize) is indicated for the treatment of the following ringworm infections.

Tinea corporis (ringworm of the body)
Tinea pedis (athlete's foot)
Tinea cruris (ringworm of the thigh)
Tinea barbae (barber's itch)
Tinea capitis (ringworm of the scalp)
Tinea unguium (onychomycosis; ringworm of the nails)

when caused by one or more of the following genera of fungi:

Trichophyton rubrum
Trichophyton tonsurans
Trichophyton mentagrophytes
Trichophyton interdigitalis
Trichophyton verrucosum
Trichophyton megnini
Trichophyton gallinae
Trichophyton crateriform
Trichophyton sulphureum
Trichophyton schoenleini
Microsporum audouini
Microsporum canis
Microsporum gypseum
Epidermophyton floccosum

NOTE: Prior to therapy, the type of fungi responsible for the infection should be identified.

The use of the drug is not justified in minor or trivial infections which will respond to topical agents alone.

Griseofulvin is *not* effective in the following:

Bacterial infections
Candidiasis (Moniliasis)
Histoplasmosis
Actinomycosis
Sporotrichosis
Chromoblastomycosis
Coccidioidomycosis
North American Blastomycosis
Cryptococcosis (Torulosis)
Tinea versicolor
Nocardiosis

CONTRAINDICATIONS

This drug is contraindicated in patients with porphyria, hepatocellular failure, and in individuals with a history of sensitivity to griseofulvin.

WARNINGS

Prophylactic Usage: Safety and Efficacy of Griseofulvin for Prophylaxis of Fungal Infections Has Not Been Established.

Animal Toxicology: Chronic feeding of griseofulvin, at levels ranging from 0.5-2.5% of the diet, resulted in the development of liver tumors in several strains of mice, particularly in males. Smaller particle sizes result in an enhanced effect. Lower oral dosage levels have not been tested. Subcutaneous administration of relatively small doses of griseofulvin, once a week, during the first three weeks of life has also been reported to induce hepatomata in mice. Although studies in other animal species have not yielded evidence of tumorigenicity, these studies were not of adequate design to form a basis for conclusions in this regard.

In subacute toxicity studies, orally administered griseofulvin produced hepatocellular necrosis in mice, but this has not been seen in other species. Disturbances in porphyrin metabolism have been reported in griseofulvin treated laboratory animals. Griseofulvin has been reported to have a colchicine-like effect on mitosis and cocarcinogenicity with methylcholanthrene in cutaneous tumor induction in laboratory animals.

Usage in Pregnancy: The safety of this drug during pregnancy has not been established.

Animal Reproduction Studies: It has been reported in the literature that griseofulvin was found to be embryotoxic and teratogenic on oral administration to pregnant rats. Pups with abnormalities have been reported in the litters of a few bitches treated with griseofulvin. Additional animal reproduction studies are in progress.

Suppression of spermatogenesis has been reported to occur in rats, but investigation in man failed to confirm this.

PRECAUTIONS

Patients on prolonged therapy with any potent medication should be under close observation. Periodic monitoring of organ system function, including renal, hepatic and hematopoietic, should be done.

Since griseofulvin is derived from species of *Penicillium*, the possibility of cross sensitivity with penicillin exists; however, known penicillin-sensitive patients have been treated without difficulty.

Since a photosensitivity reaction is occasionally associated with griseofulvin therapy, patients should be warned to avoid exposure to intense natural or artificial sunlight. Should a photosensitivity reaction occur, lupus erythematosus may be aggravated.

Griseofulvin decreases the activity of warfarin-type anticoagulants so that patients receiving these drugs concomitantly may require dosage adjustment of the anticoagulant during and after griseofulvin therapy.

Barbiturates usually depress griseofulvin activity and concomitant administration may require a dosage adjustment of the antifungal agent.

ADVERSE REACTIONS

When adverse reactions occur, they are most commonly of the hypersensitivity type such as skin rashes, urticaria, and rarely, angioneurotic edema, and may necessitate withdrawal of therapy and appropriate countermeasures. Paresthesias of the hands and feet have been reported rarely after extended therapy. Other side effects reported occasionally are oral thrush, nausea, vomiting, epigastric distress, diarrhea, headache, fatigue, dizziness, insomnia, mental confusion and impairment of performance of routine activities.

Proteinuria and leukopenia have been reported rarely. Administration of the drug should be discontinued if granulocytopenia occurs.

When rare, serious reactions occur with griseofulvin, they are usually associated with high dosages, long periods of therapy, or both.

DOSAGE AND ADMINISTRATION

Accurate diagnosis of the infecting organism is essential. Identification should be made either by direct microscopic examination of a mounting of infected tissue in a solution of potassium hydroxide or by culture on an appropriate medium.

Medication must be continued until the infecting organism is completely eradicated as indicated by appropriate clinical or laboratory examination. Representative treatment periods are—*tinea capitis*, 4 to 6 weeks; *tinea corporis*, 2 to 4 weeks; *tinea pedis*, 4 to 8 weeks; *tinea unguium*—depending on rate of growth—fingernails, at least 4 months; toenails, at least 6 months.

General measures in regard to hygiene should be observed to control sources of infection or reinfection. Concomitant use of appropriate topical agents is usually required particularly in treatment of *tinea pedis*. In some forms of athlete's foot, yeasts and bacteria may be involved as well as fungi. Griseofulvin will not eradicate the bacterial or monilial infection.

An oral dose of 250 mg of Gris-PEG (griseofulvin ultramicrosize) is biologically equivalent to 500 mg of griseofulvin (microsized), USP (see ACTION Human Pharmacology).

Adults: A daily dose of 250 mg will give a satisfactory response in most patients with *tinea corporis, tinea cruris* and *tinea capitis*. One 125 mg tablet twice per day or two 125 mg tablets once per day is the usual dosage. For those fungal infections more difficult to eradicate such as *tinea pedis* and *tinea unguium*, a divided daily dose of 500 mg is recommended. In all cases, the dosage should be individualized.

Children: Approximately 5 mg per kilogram (2.5 mg per pound) of body weight per day is an effective dose for most children. On this basis, the following dosage schedule for children is suggested:

Children weighing over 25 kilograms (approximately 50 pounds)—125 mg to 250 mg daily.

Children weighing 15-25 kilograms (approximately 30-50 pounds)—62.5 mg to 125 mg daily.

Children 2 years of age and younger—dosage has not been established.

Dosage should be individualized, as is done for adults. Clinical experience with griseofulvin in children with *tinea capitis* indicates that a single daily dose is effective. Clinical relapse will occur if the medication is not continued until the infecting organism is eradicated.

HOW SUPPLIED

Gris-PEG (griseofulvin ultramicrosize) Tablets (white) differ from griseofulvin (microsize) tablets (USP) in that each tablet contains 125 mg of ultramicrosize griseofulvin biologically equivalent to 250 mg of microsized griseofulvin. Two 125 mg tablets of Gris-PEG are biologically equivalent to 500 mg of microsized griseofulvin. In bottles of 100 and 500 scored, film-coated tablets.

Dorsey LABORATORIES
Division of Sandoz, Inc. • LINCOLN, NEBRASKA 68501

O--YB

News and Notes

Institute in Immunologic Diagnosis.—An "Advanced Institute in Methods of Immunological Diagnosis," conducted under the auspices of the World Health Organization Collaborating Laboratory for the Serology of Autoimmune Diseases at Wayne State University School of Medicine, will be held June 15-24, 1977 at the Cranbrook Educational Community in Bloomfield Hills, Mich. The course will present an up-to-date survey of current immunological methods applicable to the diagnosis of human immunological diseases. Category 1 credit for postgraduate medical education has been approved. Deadline for receiving applications is April 15. Further information can be obtained by writing to Noel R. Rose, MD, PhD, Department of Immunology and Microbiology, Wayne State University School of Medicine, 540 East Canfield, Detroit, MI 48201.

The University of California, San Francisco-Cleveland Clinic Seminar in Maui.—The second annual University of California, San Francisco-Cleveland Clinic Seminar will be held at the Hotel Intercontinental in Maui from Jan 20 to 25, 1978. The program will stress advances in dermatologic sciences most relevant to patient care. For information about registration, please write the Department of Dermatology at either the Cleveland Clinic, 9500 Euclid Ave, Cleveland, OH 44106 or the University of California, San Francisco 94143.

Advanced Seminars in Dermatology.—The annual Advanced Seminars in Dermatology will be held in Monterey, Calif, from Wednesday through Sunday Sept 14 through 18, 1977. In addition to the faculty of the University of California Medical School, San Francisco, there will be guest speakers. A partial list includes Drs Thomas Fitzpatrick, Henry Roenigk, and E. Krull. For information please write the Skin Disease Research Foundation, c/o Charlotte Sandoval, PO Box 27534, San Francisco, CA 94127.

Eastern Regional Meeting of the Society for Investigative Dermatology.—The next eastern regional meeting of the Society for Investigative Dermatology, Inc, will be held on Sunday morning, May 8, 1977 at the Waldorf-Astoria Hotel, New York City. Address all inquiries to Alan R. Shalita, MD, Downstate Medical Center, Division of Dermatology, 450 Clarkson Ave, Brooklyn, NY 11203.

Clinical Teaching Slides.—The American Academy of Dermatology and the Institute for Dermatologic Communication and Education have prepared another collection of clinical teaching slides. The fourth set of 50 slides, a broad collection of *Skin Tumors*, is now available. The fee for the slides is $35 (Illinois residents add 5% sales tax; outside the United States and Canada, add $6). The first three sets of 50 slides, *Pediatric Dermatoses*, *Some Common Dermatoses*, and *Cutaneous Manifestations of Systemic Disease*, are available at the same price. Interested parties can obtain these sets directly from the American Academy of Dermatology, PO Box 552, Evanston, IL 60204. Your check or money order must accompany your order.

Samitz Lectorship.—The Department of Dermatology of the University of Pennsylvania School of Medicine announces the second M. H. Samitz Lectureship. Herman N. Eisen, MD, professor of immunology, Cancer Research Center, Massachusetts Institute of Technology, will present "Specificity of Cell-Mediated Immune Reactions" Friday, April 22, 1977 at 4 o'clock in the Medical Alumni Hall of the Hospital of the University of Pennsylvania. There will be a reception following the lecture.

Atlantic Dermatological Conference.—The next meeting of the Atlantic Dermatological Conference will be held at the Waldorf-Astoria Hotel, New York City, Friday and Saturday, May 6 and 7, 1977. Address all inquiries to Peter Lombardo, MD, 120 E 64th St, New York, NY 10021.

Scleroderma Research Award for 1977.—The Monterey Bay Scleroderma Foundation announces its first $1,000 annual Award for Scleroderma Research for 1977. The establishment of an award carries with it the hope that it will act as an incentive to study this chronic disabling disease.

The award is designed for the individual or group whose investigative work in this field has been outstanding. Names of applicants for the award, together with supporting data should be submitted for consideration by Dec 1, 1977. Results of the research must have been presented at a scientific medical meeting or published in a recognized medical journal.

The award recipient will be determined by a committee of five men. If,

in the committees' opinion, none of the applications reflects outstanding research, no award will be given for that year. Address all communications to Denny L. Tuffanelli, MD, Department of Dermatology, University of California, School of Medicine, San Francisco, CA 94143.

Symposium.—"Diagnosis of Inflammatory Skin Diseases: Histologic, Electron Microscopic, and Immunologic Aspects," directed by Dr A. Bernard Ackerman and sponsored by the Departments of Dermatology and Pathology of the New York University Medical Center, will be conducted from 9:00 AM, Thursday, Oct 13, to 12:00 PM, Saturday, Oct 15, 1977, at the New York University Medical Center.

This symposium deals with the diagnosis of inflammatory diseases of the skin by light microscopy, electron microscopy, and immunology. Special attention will be given to those diseases that are better recognized and understood by means of electron microscopy and immunologic study. Also, the function of inflammatory cells in diseases of the skin will be emphasized.

Each general subject will be moderated by a histopathologist who will call on electron microscopists and immunologists for further elucidation of appropriate topics. The format will be brief presentations of particular subjects by particular members of the faculty, followed by discussion first by the entire faculty, and then by the audience with the faculty responding.

The faculty is as follows: histology: Drs A. Bernard Ackerman, John Headington, John Maize, Arkadi Rywlin; electron microscopy: Drs Michael Heaphy, Elaine Waldo, Helmut Wolff; immunology: Drs Frank Austen, Rudolf Baer, Gunter Burg, Jean-Claude Bystryn, Stephen Katz, H. Sherwood Lawrence, William Meigel, Thomas Provost, Dorothy Zucker-Franklin.

Further details may be obtained from the Office of the Associate Dean, New York University Postgraduate Medical School, 550 First Ave, New York, NY 10016.

CORRECTIONS

In the article "Corticosteroid-Induced Cutaneous Atrophy and Telangiectasia," which appeared in the August issue of the ARCHIVES (112:1115-1117, 1976), **Fig 1** (p 1116) **was reversed.** The larger animal (control) should have been on the far left instead of the right.

Typesetting Error.—In the article "Chronic Bullous Dermatosis of Childhood," published in the January issue of the ARCHIVES (113:42-46, 1977), the introductory paragraph of the article should have been set as the last paragraph of the abstract.

DESCRIPTION

Synalar® (fluocinolone acetonide) has th
6α, 9α-difluoro-16α-hydroxyprednisolone-

Synalar® Solution 0.01%—contains 0.01% f
acetonide in propylene glycol with citric

Synalar® Ointment 0.025%—contains 0.0
acetonide in white petrolatum.

Synalar-HP® Cream—contains 0.2% fluoc
in a water-washable aqueous base of st
alcohol, mineral oil, propylene glycol, so
stearate, polyoxyethylene sorbitan monc
citric acid, with methylparaben and prop
preservatives.

Synemol™ (fluocinolone acetonide) has t
6α, 9α-difluoro-16α-hydroxyprednisolone-

The vehicle is a water-washable aqueou
stearyl alcohol, cetyl alcohol, mineral oil,
sorbitan monostearate, polyoxyethylene
stearate and citric acid.

INDICATIONS

For relief of the inflammatory manifestatic
steroid-responsive dermatoses.

CONTRAINDICATIONS

Topical steroids are contraindicated in v
varicella.

Topical steroids are contraindicated in th
history of hypersensitivity to any of the cor
preparation.

Synalar-HP Cream should not be used or
years of age.

PRECAUTIONS

If irritation develops, the product should b
appropriate therapy instituted.

In the presence of an infection the use of
antifungal or antibacterial agent should
favorable response does not occur prom
steroid should be discontinued until the ir
adequately controlled.

If extensive areas are treated or if the occ
used, the possibility exists of increased sy
of the corticosteroid and suitable precau
taken.

Although topical steroids have not been r
adverse effect on pregnancy, the safety
pregnant females has not absolutely be
Therefore, they should not be used extens
patients, in large amounts, or for prolong

Topical steroids are not for ophthalmic us

Synalar-HP Cream should not be used for
and the quantity per day should not exce
formulated material.

ADVERSE REACTIONS

The following local adverse reactions ha
with topicalcorticosteroids: burning, itchir
dryness, folliculitis, hypertrichosis, acnefor
hypopigmentation.

Synalar Cream and Ointment, Synemol C

The following may occur more frequently
dressings than without such therapy: mac
secondary infection, skin atrophy, striae, r

HOW SUPPLIED

Synalar® (fluocinolone acetonide)
Cream 0.025%—15, 60 g tubes; 120, 425 g
Cream 0.01%—15, 45, 60 g tubes; 120, 425
Ointment 0.025%—15, 60 g tubes; 425 g j
Solution 0.01%—20, 60 cc plastic squeeze
Synalar-HP® (fluocinolone acetonide) 0.2
tubes.
Synemol™ (fluocinolone acetonide)
Cream 0.025%—15, 60 g tubes.

These preparations are available on pres

SYNTEX
SYNTEX LABORATORIES, INC.
PALO ALTO, CALIFORNIA 94304

INFLAMMATION OF
CONTACT DERMATITIS

SOLVED

SYNALAR®
TOPICALS
FLUOCINOLONE ACETONIDE

Treat Sensitive, Irritated, Stubborn, Pustular Acne **Gently!**

Soft as a Fleecy Cloud.

SULFACET-HC®

Sodium Sulfacetamide 10%, Hydrocortisone Alcohol ½%, Sulfur Colloid 5%.

Drying without Irritation.

SULFACET-HC*— unsurpassed anti-microbial and anti-seborrheic acne lotion.

DESCRIPTION (As Dispensed)

Hydrocortisone	0.5%W/V
Sodium Sulfacetamide	10.0%W/V
Sulfur Colloid	5.0%W/V

in a water-washable lotion containing purified water, zinc oxide, talcum, propylene glycol, titanium dioxide, natural clays, fatty acid amide, iron oxides, ethoxylated esters, natural and synthetic gums, organic salts, sodium chloride and bisulfite, sequestrant, butyl and methyl parabens and 2-Bromo-2-nitropropan-1,3-diol.

ACTIONS — Keratolytic, peeling, drying and antiseborrheic action.

INDICATIONS — Acne vulgaris, acne rosacea and seborrheic dermatitis.

CONTRAINDICATIONS — Topical steroids are contraindicated in viral diseases of the skin such as varicella and vaccinia. Topical steroids are contraindicated in those patients with a history of hypersensitivity to any of the components of the preparation. This preparation is not for ophthalmic use. Topical steroids should not be used when circulation is markedly impaired or in patients with kidney disease or those who have previously exhibited sensitivity to sulfonamides.

WARNINGS — USAGE IN PREGNANCY: Although topical steroids have not been reported to have an adverse effect on the fetus, the safety of their use in pregnant females has not been absolutely established. Therefore, they should not be used extensively on pregnant patients or in large amounts or for prolonged periods of time.

PRECAUTIONS — For External Use Only. Keep Away From Eyes. Sensitivity to sulfacetamide may occur. Caution and careful supervision should be observed when prescribing these drugs for patients who may be prone to hypersensitivity to topical sulfonamides, particularly if areas of denuded or abraded skin are involved. If irritation develops, the product should be discontinued and appropriate therapy instituted. In the presence of an infection, the use of the appropriate antifungal or antibacterial agents should be instituted. If a favorable response does not occur promptly, the corticosteroid should be discontinued until the infection has been adequately controlled. If extensive areas are treated or if the occlusive technique is used, the possibility exists of increased systemic absorption of the corticosteroid and suitable precautions should be taken.

ADVERSE REACTIONS — The following local adverse reactions have been reported with topical corticosteroids, either with or without occlusive dressings: burning sensations, itching, irritation, dryness, folliculitis, secondary infection, skin atrophy, striae, hypertrichosis, acneform eruption and hypopigmentation. Hypersensitivity to the sulfonamides indicated by previous toxic reaction such as agranulocytosis, acute hemolytic anemia, purpura hemorrhagica, drug fever, jaundice or contact dermatitis.

DOSAGE AND ADMINISTRATION — Apply a small quantity to the affected areas two to three times daily. The skin should be thoroughly cleansed and applications blended in with light massaging. Consult physician for advice on diet and other factors in control of acne.

HOW SUPPLIED — Lotion, bottles, 1 oz. and 2 oz. as dispensed.

CAUTION — Federal law prohibits dispensing without prescription.

Dermik WHERE RESEARCH AND ECONOMY COME FIRST! Fort Washington, Pa. 19034

Ideal for dry skin care.

For dry skin care on a day-to-day basis, consider the soothing, softening, nondetergent cleansing properties of Alpha Keri Soap.

- Excellent cleansing properties eliminate harshness and irritation
- Contains Alpha Keri® therapeutic bath oil to soothe and soften skin
- Rich lather and delicate scent create outstanding patient acceptance

Alpha Keri® soap

The soothing, smoothing detergent-free cleanser

WESTWOOD
PHARMACEUTICALS INC.
Buffalo, New York 14213

In Canada, Belleville, Ontario K8N5E9

©1976, W.P. Inc.

An Unusual Variant of Darier Disease

Fig 1.

Fig 2.

Fig 3.

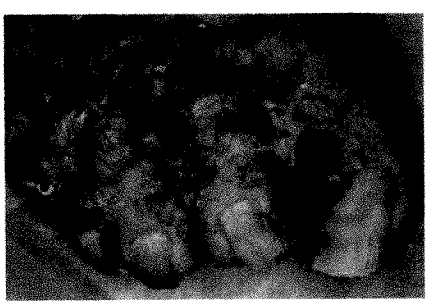

Fig 4.

To the Editor.—The article by Peck et al (112:495, 1976), reporting the cornifying variant of Darier disease was most interesting. The variant is not unique in the usual meaning of the word, for the authors refer to a second similar case found in the literature.

We have been following a patient with a cornifying variant of Darier disease for over ten years.

Report of a Case.—A 35-year-old man came to the dermatology clinic because of painful, malodorous vegetations on the lower legs. Lesions typical of the disease, both clinically and histologically, were present on his trunk, arms, and legs. His secondary infection cleared with tetracycline and acetic acid compresses. He was then lost to follow-up for 11 years, when he again returned because of painful, malodorous legs. Verrucous cornifying growths were present on the sides of the lower part of his legs (Fig 1 and 2), and the dorsum of his feet (Fig 3) and toes (Fig 4). Most of these areas were tender, malodorous, and a purulent discharge was present. Typical hyperkeratotic papules were present on the thorax, arms, and legs.

This is apparently the third reported case of this unusual variant of Darier disease.

JAMES F. DOLEZAL, MD
Iowa City

Discoid Lupus Erythematosus and the Variant Form of Hereditary Angioedema

To the Editor.—There are a number of reports in the literature of patients who, in association with connective tissue disease, have deficiencies of one or another component of the complement system. Recently Kohler et al[1] reported identical male twins with longstanding discoid lupus erythematosus (LE) and hereditary angioedema with C1 inhibitor (C1 INH) deficiency and a marked secondary decrease in C4.

Two genetic forms of hereditary angioedema have been described, the common and variant forms.[2] About 85% of patients have the common form. Immunochemical and functional concentrations of C1 INH in these patients range from undetectable to about 50% of normal. The remaining 15% of patients have the variant form of the disease; that is, normal or increased levels of an antigenically identical, but functionally deficient protein.[3] We recently have had the opportunity to study a patient with classical discoid LE and the variant form of hereditary angioedema.

Report of a Case.—The patient, a 49-year-old woman, had urticaria since childhood, associated with swelling of the hands, difficulty in swallowing, and stomach pains. She had been studied at the University of Cincinnati and a diagnosis of hereditary angioneurotic edema was made by Virginia Donaldson, MD. Her maternal grandmother and son also had hereditary angioneurotic edema.

Her main concern when I saw her was the cosmetic problem of scarring alopecia. She had extensive cutaneous lupus involving her face, scalp, and hands, which had not responded to therapy. She had no clinical evidence of systemic lupus.

Complement studies revealed total hemolytic complement at 17 CH_{50} units (normal, 25-42), C3 by immunodiffusion 120 (normal, 70-160), serum C4 assay 80,000 (normal, 242,000 to 1 million). Biopsy of an involved skin lesion showed granular deposition of IgG in the dermal epidermal zone. A biopsy specimen of uninvolved skin showed no abnormalities. Studies for C1 INH were done by Neal R. Cooper, MD, at the Scripps Clinic. Her sera contained normal levels of C1 INH protein. She had very low levels of C1 INH activity and a diagnosis of the variant form of hereditary angioedema was made. Her antinuclear antibody gave a positive reaction by a 1 to 160 speckled pattern. Anti-DNA and anti-ENA were not present.

Comment.—The occurrence of discoid LE and hereditary angioedema in

a patient with C1 INH and C4 deficiency seems significant. Demonstration of IgG at the dermal epidermal junction in the cutaneous lesions and the presence of apparently normal levels of C1 INH protein but very low levels of C1 INH activity were of added interest.

DENNY L. TUFFANELLI, MD
San Francisco

1. Kohler PF, Percy J, Campion WM, et al: Hereditary angioedema and "familial" lupus erythematosus in identical twin boys. *Am J Med* 56:406-411, 1974.

2. Rosen FS, Charache P, Pensky J, et al: Hereditary angioneurotic edema: Two genetic variants. *Science* 148:957-958, 1965.

3. Frank MM, Gelfand JA, Atkinson JP: Hereditary angioedema: The clinical syndrome and its management. *Ann Intern Med* 84:580-593, 1976.

Furosemide-Induced Cutaneous Necrotizing Vasculitis

To the Editor.—We would like to report a case of cutaneous necrotizing vasculitis that was presumably induced by an allergic reaction to furosemide.

Report of a Case.—A 72-year-old white man with a past history of an anterior myocardial infarction, congestive heart failure, pacemaker insertion, mild renal insufficiency, and duodenal ulcer was referred to University Hospitals from a nursing home with a four-day history of purpuric skin lesions and blood-tinged sputum. His medications at the time of admission included daily doses of furosemide (40 mg) for at least the past five months and digoxin (0.25 mg).

On admission, physical examination revealed bibasilar pulmonary rales, a liver palpable 8 cm below the right costal margin, edema of both legs (3+), and a functioning cardiac pacemaker. The patient was responsive, but demented, with positive grasp and snout reflexes. The left pupil was nonreactive with vertical nystagmus noted on horizontal gaze. Bruits were appreciated over his left carotid artery and bilaterally over his femoral arteries. Examination of the skin revealed several, clear, bullous skin lesions on a hemorrhagic base located over the legs and ankles with multiple petechial lesions distributed over the legs, arms, palms, soles, trunk, and buccal mucosa (Fig 1).

Laboratory studies included a hematocrit reading of 35%; WBC count, 6,000/cu mm, with 87% polymorphonuclear leukocytes, 3% band cells, 7% lymphocytes, and 3% monocytes; platelets, 185,000/cu mm; total protein, 5.9 gm/100 ml; albumin, 2.5 gm/100 ml; and the chest x-ray film showed severe cardiomegaly. The clotting studies, Coombs test, tests for fibrin split products and antinuclear factor, lupus erythematosus preparation, and cultures of

Fig 1.—Bullous lesions on a hemorrhagic base located on the lower leg.

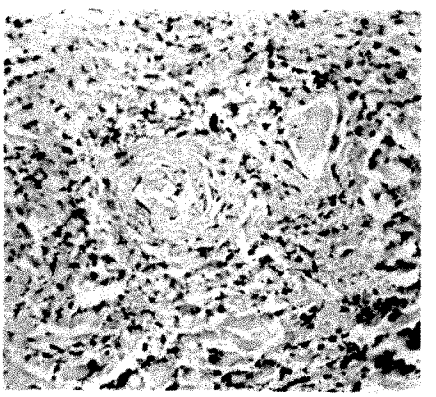

Fig 2.—Leukocytoclastic vasculitis with involvement of the deep dermal blood vessels (hematoxylin-eosin, ×250).

the blood, urine, sputum, cerebrospinal fluid, and skin were all normal. A skin biopsy specimen demonstrated a leukocytoclastic vasculitis with involvement of the blood vessels in the lower dermis (Fig 2). Direct immunofluorescence of the skin showed positive fluorescence of the blood vessels with anti-IgG, anti-IgA, anti-IgM, and anti-complement.

On the suspicion of systemic necrotizing vasculitis secondary to an allergic drug reaction, furosemide therapy was discontinued, and treatment with hydrocortisone (80 mg intravenously every six hours), ethacrynic acid (50 mg daily), and penicillin (2.5 million units every six hours) was started. The next day the patient appeared better, with resolution of some of the skin lesions. On the third day of hospitalization, however, he suffered a massive right cerebral infarction with left hemiparesis. Intravenous administration of dexamethasone was started, but the patient never regained consciousness and died five days later.

At autopsy, severe arteriosclerotic cardiovascular disease was found, with a recent right cerebral hemispheric infarction secondary to an embolus in the right middle cerebral artery. Examination of the vasculature of the kidneys and brain failed to show any signs of vasculitis.

Comment.—Necrotizing vasculitis has been associated with allergic drug reactions, collagen vascular disease, malignancy, cryoglobulinemia, macroglobulinemia, and infection. In light of the essentially negative findings of the laboratory evaluation of this patient, one must suspect an allergic drug reaction as the cause of his hemorrhagic, bullous eruption.

Hemorrhagic bullae on the lower extremities have been reported previously in a 65-year-old man taking digoxin, erythromycin, and furosemide.[1] The skin biopsy specimen in that case was interpreted as showing erythema multiforme. Bullous pemphigoid has also been reported after furosemide therapy.[2] We could find no reports, however, of a leukocytoclastic vasculitis following treatment with furosemide. Sulfonamides, on the other hand, have been reported to produce a sensitivity vasculitis,[3] and even a periarteritis nodosa-like picture. Since furosemide is a sulfonamide, it is postulated that furosemide was the inciting agent in this case of cutaneous necrotizing vasculitis.

WILLIAM M. HENDRICKS, MD
RICHARD S. ADER, MD
Cleveland

1. Ebringer A, Adam WR, Parkin JD: Bullous haemorrhagic eruption associated with Frusemide. *Med J Aust* 1:768-771, 1969.

2. Fellner MJ, Katz JM: Occurrence of bullous pemphigoid after furosemide therapy. *Arch. Dermatol* 112:75-77, 1976.

3. Kutscher AH, Lane SL, Segall R: The clinical toxicity of antibiotics and sulfonamides: A comparative review of the literature based on 104,672 cases treated systemically. *J Allergy* 25:135-150, 1954.

Nomenclature of Antibiotics

To the Editor.—In reference to the recent article by Pablo and Fulton (111:734-735, 1975), it should be pointed out that chlortetracycline hydrochloride is marketed as Aureomycin (Lederle), while Achromycin (Lederle) is a brand name for tetracycline hydrochloride.[1] This raises the question as to whether the authors inadvertently studied the same antibiotic twice or simply confused their nomenclature.

HARRY L. PARLETTE, MD
Pensacola, Fla

1. Goodman LS, Gilman A (eds): *The Pharmacologic Basis of Therapeutics*, ed 4. New York, Macmillan Co, 1970, p 1258.

In the letters to the editor that follow, reactions apparently induced by the fabric softener, Bounce, are noted. Initial letters from Donald H. Huldin, MD, received in November 1975 and Jerome Z. Litt, MD, in February 1976 were not accepted due to my misjudgment. Subsequently, Dr Litt published his account (Cutis 18:134, 1976). *Though the exact relationships and mechanisms involved in these responses are not clear, the time sequences reported strongly suggest specific associations. Because Bounce and perhaps other similar agents may be responsible for adverse reactions, we believed that this information should be made available to the readers of the* ARCHIVES. *We have asked James E. Weaver, PhD, to present the manufacturer's point of view in response to these reports.*—ED.

Side Effects of Bounce

To the Editor.—Up to now I have seen four cases of an acute contact dermatitis that appear to have been caused by Bounce, a fabric softener used in the drier. Two patients who wore T-shirts developed their rash in the underarm area, and two patients who wore jockey shorts developed their rash on the anterior abdomen.

Onset coincided with the first-time use of this product, and clearing occurred rapidly with its discontinuance and with treatment with 1% hydrocortisone cream. A careful history eliminated other causes. In one instance, the Bounce was used to impart a pleasant odor to the garments by placing it between the layers of clothing in a drawer.

This is another product with side effects.

CHARLES SHEARD, MD
Stamford, Conn

To the Editor.—About one year ago, complimentary samples of Bounce, a new fabric softener, were sent to physicians in this area. The product consists of sheets of nonwoven rayon impregnated with a perfume and two softening agents, dialkyldimethylammonium methyl sulfate and a fatty acid ester of a polyhydric alcohol.[1] The sheets are added to the clothes drier, and the warmth and tumbling action is said to release the ingredients. Four patients have been seen with symptoms that we believe were exacerbated by this new fabric softener.

Report of Cases.—A 2-year, 10-month-old boy was seen for a dermatitis of several weeks' duration that had been unresponsive to penicillin. The patient had a chronic recurrent nasal congestion, and there was a family history of allergy. The mother, a physician's wife, had recently used the new product. A severe erythematous scaly dermatitis on the flexors and small erythematous papules on the trunk were noted. The dermatitis cleared on treatment with systemic steroids, and the patients skin has remained clear with no further exposure to the product.

A 9-month-old girl was hospitalized for a facial dermatitis and respiratory distress of coughing, wheezing, and congestion. The patient had been in excellent health, except for one episode of bronchitis one month prior to admission. The mother, who has asthma and allergies, had recently used the fabric softener in the clothes drier but stopped it the day before admission. The dermatitis consisted of small erythematous papules and diffuse erythema on both cheeks. Complete blood cell count and temperature were normal, and chest roentgenograms showed inflammatory changes. The child's symptoms cleared while she was hospitalized, and she was discharged and seen three months later with no further difficulty since discontinuing use of the product.

A 4-month-old boy was hospitalized for treatment of respiratory distress with coughing, choking, and tachypnea. The infant had recently been exposed to viral respiratory infection, and there was a family history of respiratory allergy. Chest roentgenograms showed a right perihilar infiltrate consistent with bronchial pneumonia. Nasal pharyngeal culture grew no pathogenic organisms, and a WBC count and differential were normal. No dermatitis was present. Treatment consisted of amoxicillin and a mist tent, and seven days later the infant was discharged; he was still wheezing slightly, but he was otherwise asymptomatic and comfortable. Three weeks later, the infant was still wheezing, but results of a repeat chest roentgenogram were normal. Inspiratory wheezing in an infant who looked well was the only finding. The mother suspected the fabric softener was responsible and discontinued using it. Within a few days the wheezing stopped and has never recurred.

A 21-year-old woman was seen for a dermatitis of four months' duration. Although a family history of allergies was noted, the patient was in excellent health. Her mother had recently begun to use the fabric softener. A mild erythematous papular dermatitis on the anterior part of the thighs, antecubitals, and upper part of the back was noted. She received topical steroids, and her skin has remained clear since discontinuing use of the product.

Comment.—Dermatologic testing carried out by the manufacturer has shown no toxicity.[1] However, the literature reports four patients with bronchial asthma after exposure to the fabric softener.[2,3] Others have noted an increasing incidence of a generalized pruritis and dermatitis.[4] Many families may be exposed to this new fabric softener, and physicians should be alerted.

DONALD E. HAZELRIGG, MD
ISAAC R. HARGETT, MD
Evansville, Ind

1. Weaver JE: Dermatologic testing of household laundry products: A novel fabric softener. *Int J Dermatol* 15:297-300, 1976.
2. Mauceri RA, Rosan JR: Possible asthmatic reaction to the fabric softener. *N Engl J Med* 294:907, 1976.
3. Oster MW: More on Bounce and asthmatic symptoms. *N Engl J Med* 294:1297, 1976.
4. Litt JZ. Letter to the editor. *Cutis* 18:134, 1976.

To the Editor.—The Midwest has recently been used as a marketing area for a new antistatic laundry agent labeled Bounce. Many physicians received this free sample through the mail, along with a flier that described its nontoxic, benign nature in reference to dermatologic complaints. Many of the homes in the Midwest have also received complementary samples of this agent.

We have noted five contact dermatitis cases that we believe are directly related to this preparation being used in the care of the clothing. These are characterized by papular and pseudovesicular eruptions over the covered parts of the body. I was also impressed with the erythema that certain patients demonstrated in association with the primary lesions. These eruptions usually began roughly ten days after the institution of the chemical into the wash-care program.

On two occasions we have specifically attributed the precipitation of extrinsic asthma in patients that have been symptom-free for many years. This came to my attention because one of the asthmatic patients is the daughter of my nurse, who made the observation simultaneously with the appearance of these unusual dermatoses in our clinial practice.

DONALD H. HULDIN, MD
Lansing, Mich

In Reply.—We appreciate the opportunity to place added perspective on the Letters to the Editor in this issue that refer to our Bounce fabric softener. We discussed the cases cited

in these letters with the physicians involved and have urged their participation in follow-up diagnostic patch or cautious reuse testing to determine whether there indeed exists a cause and effect relationship.

Bounce was heavily advertised during its marketing introduction, and free samples were distributed to a large percentage of US households. It has been our repeated experience that during such market introduction of any new product, some consumers and physicians will associate its use with personal problems that develop due to other causes. However, diagnoses from personal histories alone become much more difficult, because a high percentage of patients seen during this introductory period will report the new product as the only new item they have used.

Dr Hazelrigg stated in a telephone conversation that patch testing would be appropriate in the investigation of the dermatitides that he reported. However, he declined our suggestion that he test these patients, at our expense, to confirm his anecdotal observations. He also declined our encouragements to obtain diagnostic follow-up on the respiratory problems to which he referred.

Dr Sheard informed us that he has seen no problems that he attributes to the Bounce chemical ingredients. He believes that his patients have instead experienced a "mechanical" irritation from small pieces of fiber from the nonwoven rayon sheet that was used as the substrate for the fabric-softening agents. His patients were unavailable for controlled reuse testing that he agreed would be appropriate to determine if their dermatitides were actually related to this fabric softener. Dr Sheard, himself, experienced such a dermatitis. He has since reused Bounce with no recurrence of it. We have microscopically examined fabrics softened with Bounce in our laboratory, as well as softened clothing that a few consumers thought had caused their skin problems. No fibers from the rayon sheet were found.

Dr Huldin has also been contacted. He declined to consider any testing.

Since Procter & Gamble began selling Bounce four years ago, more than 40 million households have safely used over 2 billion sheets of it. Comments from consumers on the subject of its skin mildness have been consistent with those received for other safe products that we have marketed over the years. This is not at all surprising, since the ingredients in Bounce have been used safely for years in liquid fabric softeners or cosmetics.

Despite our confidence in Bounce's safety, we have followed up on every consumer complaint received. Whenever the consumers consented, we obtained the cooperation of local, independent physicians—primarily determatologists and allergists—in examining them and, when appropriate, in conducting patch tests with product ingredients and softened fabrics or prick tests with ingredients. The tests were performed at our expense to ensure the maximum cooperation of these patients. In none of the more than 350 completed, medically supervised tests has Bounce been shown to be the cause of dermatitides, respiratory distress, or other of the consumers' problems.

Examinations by local, independent dermatologists of about 90 additional consumers with active dermatitides showed a wide variety of actual causes. These include common topical and systemic bacterial or viral infections, scabies, jewelry allergy, and poison ivy. In about 100 other cases, consumers who had originally questioned Bounce's safety agreed to reuse it and are now using the product regularly without adverse effects.

The diagnostic testing experience with Bounce is consistent with extensive safety testing that was conducted earlier under well-defined, monitored protocols. Over 2,000 persons, including infants, participated in studies designed to assess skin safety. This testing consisted of patch tests for skin irritation, repeat insult patch tests for skin allergy, diagnostic testing for allergy among factory and laboratory workers who have had prolonged, intimate contact with the product and its ingredients, as well as clinical wear-testing of clothing and diapers that were softened with Bounce. Results from these tests demonstrate that Bounce is safe for consumer use. An independent panel of leading dermatologists who reviewed the safety data also concluded that Bounce was unlikely to cause dermatoses.

The net of the above remarks is that extensive safety testing and follow-up of consumer complaints have demonstrated that Bounce is a safe product for consumer use. We recognize that no testing program, however extensive, can anticipate the individual responsiveness of each of the 220 million persons in the United States. Nevertheless, diagnostic and laboratory testing experience indicates that even persons with atopic allergies have not responded unusually to this product.

We have voluntarily disclosed all of our safety information and consumer complaint files to the Bureau of Biomedical Science of the Consumer Product Safety Commission. They, too, have concluded, after careful study of all pertinent safety data, that Bounce is a nonhazardous consumer product.

It is appropriate to express appreciation to the vast majority of physicians who have responded to our request for assistance in obtaining definitive follow-up of problems that had been thought to be related to Bounce. Without their interest and cooperation, we would have been unable to conduct the thorough diagnostic program referred to previously. We continue to be interested in working with physicians who have patients who are candidates for diagnostic follow-up. Additional information and patch test materials for Bounce may be obtained by writing or telephoning me, collect, at area code (513) 977-3332.

JAMES E. WEAVER, PhD
Procter & Gamble Company
Cincinnati

Sunlight and Pityriasis Rosea

To the Editor.—Pityriasis rosea is a common self-limiting disease that affects children and young adults. Topical therapy has not been effective in promoting healing of the lesions or reducing the pruritus.[1] Ultraviolet light has been mentioned as helpful, but there is only one study substantiating such claims,[2] and the authors did not evaluate the effect on pruritus. This report describes one patient in whom lesions developed during the summer, when she had prolonged exposure to sunlight, and three others in whom the onset was in the fall when they were tanned but no longer exposed to sunlight. There was marked sparing of the tanned skin only in the patient who was exposed to the sun during the time the lesions were developing, suggesting a direct beneficial effect of light.

Report of Cases.—A 30-year-old woman complained of a nonpruritic eruption that had been spreading for several days. A single, asymptomatic, red, scaling lesion had been noted several weeks previously on the trunk. The patient had been in good health and denied taking any drugs. Findings of physical examination were unremarkable except for slightly elevated, round and oval, erythematous plaques, with a peripheral collarette of scale present primarily in the nontanned areas of the trunk. Complete blood cell count, urinalysis, Hinton test, and skin scrapings showed no abnormalities.

A 19-year-old woman, a 22-year-old woman, and a 30-year-old man all acquired the typical erythematous plaques of pityriasis rosea in the fall, when they were considerably tanned but no longer exposed to sunlight. There was no significant sparing of the tanned skin. Complete blood cell counts, urinalysis, Hinton test, and skin scrapings showed no abnormalities.

Comment.—The distribution of pityriasis rosea with the trunk being predominantly involved and the face and extremities spared might suggest that light has an ameliorating affect on the process. However, the scalp, palms, and soles, which are protected from the biological effects of light rarely show any lesions. If ultraviolet does suppress the disease, it appears that this happens only when the skin is exposed during the active phase. We have noted that in patients in whom pityriasis rosea develops in the fall, when they are no longer sunbathing but still retain their summer tan show no sparing of the sun-exposed skin of the trunk.

The mechanism by which ultraviolet light exerts its favorable effect is complex and may involve changes in the blood vessels, cells of the dermis, and the epidermis. Considering the renewed interest in ultraviolet light treatment[3] and the availability of improved light sources, further carefully controlled studies of pityriasis rosea using this form of therapy may be warranted.

HOWARD P. BADEN, MD
JACK PROVAN, MD
Boston

1. Harman RRM, Nagington J, Rook A: Virus infections, in Rook A, Wilkinson DS, Ebling FJG (eds): *Textbook of Dermatology*, ed 2. Oxford, England, Blackwell Scientific Publications, 1972, pp 601-604.

2. Merchant M, Hammond R: Controlled study of ultraviolet light for pityriasis rosea. *Cutis* 4:548-549, 1974.

3. Parrish JA, Fitzpatrick TB, Tanenbaum L, et al: Photochemotherapy of psoriasis with oral methoxsalen and longwave ultraviolet light. *N Engl J Med* 291:1207-1222, 1974.

Topical Therapy for Onychomycosis

To the Editor.—Chronic onychomycosis generally has required oral antifungal agents for therapy. The introduction of flucytosine for the treatment of systemic and topical fungal diseases has prompted the use of another fluorinated pyrimidine, fluorouracil (5FU), in the treatment of onychomycosis. Fluorouracil, in addition to being effective in the treatment of actinic keratoses, has also been shown to be effective for psoriasis of the nails (110:735, 1974).

Briefly, patients were entered into a double-blind study of a solution containing 1% fluorouracil in propylene glycol vs placebo solution (propylene glycol) with proved onychomycosis (as made evident by potassium hydroxide preparation and culture on Sabouraud agar). Three-week intervals were allowed between visits. Photographs were taken of the affected nails in addition to the laboratory tests. At the end of 12 weeks of therapy, a decision was made as to whether the patient had been receiving the "active" medication or the "placebo" medication as measured by the clinical response and laboratory results. If the patient was believed to be receiving "placebo" medication, then he/she was transferred to a single-blind phase of "active" medication, ie, the investigator knew the contents of the medication, but the patient did not.

In the ongoing study, 16 patients have completed 24 weeks of therapy and the code has been broken. The results have been as follows:

Nine patients initially received the "active" medication. In five, the condition cleared or markedly improved. One patient failed to respond to therapy even after being transferred at 12 weeks. Three patients were transferred at 12 weeks and began to respond to treatments late in the observation period.

Eight patients initially received placebo medication. Two showed clearing or marked improvement. Five patients were transferred at 12 weeks and improved on active therapy. One patient initially received placebo but was lost to follow-up after being transferred to active medication at 12 weeks.

Propylene glycol in high concentrations is a known antifungal agent; therefore, one might expect some success with the placebo alone. This did occur in two of eight patients. Five of eight patients responded to treatment with the active medication. The three patients originally receiving active drug began to respond late in the treatment period following transfer to second-phase active medication and presumably required a greater length of time to respond.

Topical therapy for onychomycosis achieving a 70% to 80% success rate would be an advance, since it is now difficult to achieve this rate with orally given antifungal agents. The study is still in progress, but I wish to share this information if it will aid any patient with onychomycosis who is unable to use oral antifungal agents for a medically valid reason.

FILLMORE K. BAGATELL, MD
Phoenix

Systemic Scleroderma in Mother and Daughter

To the Editor.—Systemic scleroderma still remains an uncommon disease of unknown cause, and the familial occurrence is very rare. We have seen two patients, a mother and a daughter in a family, with findings of systemic scleroderma.

Report of Cases.—CASE 1.—June 1975, a 45-year-old woman was admitted to the Hospital of the Hyogo College of Medicine with the chief complaint of hardening of her upper extremities. Fifteen years prior to admission, Raynaud phenomen of both hands and feet developed. She gradually noticed cutaneous hardness of her hands, forearms and feet, and then the shortness of her fingers and limitation of motion of her hands and fingers were recognized. Recently, she noticed slight retardation of the lips and loss of the ability to smile.

Laboratory Studies.—The erythrocyte sedimentation rate (ESR) was 103 mm/hr. The WBC count was 3,900/cu mm; the RBC count, 3.07×10^6/cu mm; the hematocrit reading, 25.0%; the hemoglobin concentration, 8.0 gm/100 ml; and the thrombocyte count, 4.3×10^4/cu mm. The serum globulin level was 7.4 gm/100 ml with an increased γ-globulin level. The immunoglobulin (IgG, IgA, and IgM) values were 3,600 mg/100 ml, 506 mg/100 ml, and 96 mg/100 ml, respectively. C-reactive protein was +1 positive, as was rheumatoid factor. The serum iron and copper values were 25 and 37 μg/100 ml, respectively. Normal data were obtained from urinalysis, serum electrolyte determination, lupus erythematosus (LE) test, anti-streptolysin O titer, and tests for liver and renal function. The serum antinuclear factor reaction and the test for syphilis were negative. A roentgenogram of the chest showed a bilateral

interstitial reticular pattern. A roentgenographic study of the upper part of the gastrointestinal tract showed the esophagus to be slightly atonic and dilated. The results of both the pulmonary function test and the ECG were in the normal range. The histocompatibility antigen (HL-A) typing examination showed A 9 and BW 40. The result of the chromosomal examination was normal.

The skin biopsy specimen from the forearm revealed a flattened epidermis, a collagenized, thickened dermis with minimal atrophy of the adnexa, homogenization, and hyaline changes. Masson stain showed an increased amount of collagen.

CASE 2.—A 27-year-old woman was examined at the Hospital of the Hyogo College of Medicine in June 1975. She was the eldest of the two daughters of patient 1. Consanguinity was not known in the family. It was believed that an onset of feeling of coldness of her both hands occurred when she was 14 years old. Since then, an increasing Raynaud phenomen of her hands and feet developed, along with progressive shiny stiffness of her hands and forearms and limitation of motion of small joints of hands and feet.

Laboratory Studies.—The following laboratory studies yielded normal values: urinalysis, complete blood cell count, serum electrolytes, C-reactive protein, rheumatoid factor, serum antinuclear factor, LE test, antistreptolysin O titer, and the VDRL test for syphilis. The ESR was 33 mm/hr. The serum globulin level was 8.1 gm/100 ml, with an increased γ-globulin level. The immunoglobulin (IgG, IgA, and IgM) determinations revealed 3,600 mg/100 ml, 506 mg/100 ml, and 548 mg/100 ml, respectively. Normal results were obtained from the ECG, tests for liver and renal function, pulmonary function, a roentgenogram of the chest, and a roentgenographic study of the upper part of the gastrointestinal tract. HL-A typing examination showed A 9, 10, and BW 40. No abnormalities were seen in the chromosomal analysis.

The skin biopsy specimen from the dorsum of the hand showed thickening and swelling of dermal collagen bundles. Masson stain showed an increased amount of collagen.

Comment.—Despite of the rarity of familial scleroderma, several cases of both systemic and localized scleroderma have been described.[1-5] Evidence such as a high level of antinuclear factor in the first-degree relatives[6] and significant results of HL-A typing,[7] suggest that genetic factors play a part in the etiology of systemic scleroderma. Burch and Rowell[8] proposed that the cause of systemic scleroderma was characterized by a single inherited dominant allele on the X-chromosome. However, the female predominance was not found in cases of the Brandywine isolate.[9] Though Emerit et al[10] found chromosomal abnormalities in lymphocyte mitoses of patients with scleroderma, our two cases were normal. The fact that there are several publications of familial scleroderma including these two cases, may encourage further search from the view of genetic predisposition to the disease.

SOICHIRO SASAKI, MD, PHD
HIROKO YOSHINO, MD
Hyogo, Japan

Read in part before the 75th general meeting of the Japanese Dermatological Association, Fukuoka, Japan, April 2, 1976.

1. Burge KM, Perry HO, Stickler GB: "Familial" scleroderma. *Arch Dermatol* 99:681-687, 1969.

2. Camus JP, Emerit I, Reinert P, et al: Sclérodermie familiale avec syndrome de Sjögren et anomalies lyphocytaires et chromosomiques. *Ann Med Interne* 121:149-161, 1970.

3. Wuthrich RC, Roenigk HH Jr, Steck WD: Localized scleroderma. *Arch Dermatol* 111:98-100, 1975.

4. Orobona MI, Alnano O: Progressive systemic sclerosis (or visceral scleroderma): Review of literature and report of cases. *Acta Med Scand*, suppl 333, 1958, pp 1-170.

5. Rees RB, Bennett J: Localized scleroderma in father and daughter. *Arch Dermatol* 68:360, 1953.

6. Fennell RH Jr, Maclachlan MJ, Rodnan GP: The occurrence of antinuclear factors in the sera of relatives of patients with systemic rheumatic diseases. *Arthritis Rheum* 5:296, 1962.

7. Fujiwara N, Kano H, Yoshino H, et al, read before the 27th Meeting of the West-Japan Dermatological Society, Kurashiki, October 1975.

8. Burch PR, Rowell NR: Aetiological aspects of chronic discoid and systemic lupus erythematosus, systemic sclerosis and Hashimoto's thyroiditis: Some immunological implication. *Lancet* 2:507-513, 1963.

9. Greger RE: Familial progressive systemic scleroderma. *Arch Dermatol* 111:81-85, 1975.

10. Emerit I, cited by Wuthrich RC, Roenigk HH Jr, Steck WD: Localized scleroderma. *Arch Dermatol* 111:98-100, 1975.

Doxorubicin and Unusual Skin Manifestations

To the Editor.—Doxorubicin hydrochloride (Adriamycin), an anthracycline antibiotic that has a broad spectrum of antitumor activity, has been widely used as a single agent or in combination with other drugs.[1] The major toxic side effects have been nausea, vomiting, mucosal ulcerations, alopecia, hematopoietic depression, and cardiomyopathy. I would like to report two unusual melanotic cutaneous reactions related to doxorubicin therapy.

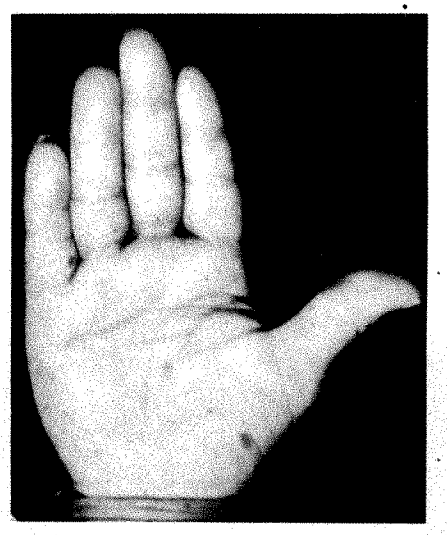

Fig 1.—Black hyperpigmentation on palm.

Fig 2.—Black hyperpigmentation on nails and nailbeds.

Report of Cases.—CASE 1.—A 55-year-old black woman was referred for chemotherapy for metastatic breast carcinoma. In November 1973, she underwent radical mastectomy for carcinoma of the left breast, with an uneventful recovery. In May 1974, an epidural metastasis developed, with compression of the spinal cord at the T-4 and T-5 levels. Laminectomy was performed and she was subsequently treated with cyclophosphamide (Cytoxan), methotrexate, vincristine sulfate, fluorouracil, and prednisone.[2] After further progression, with an appearance of new lesions in the spine, doxorubicin therapy was started. She was treated with a relatively low dose of 20 to 30 mg/sq m every three to four weeks. After a fifth course, or a total of 200 mg of doxorubicin, she noticed the black hyperpigmented changes in the palms, soles, nails and nail beds (Fig 1 and 2). However, the metastatic lesions responded to doxorubicin, and she received a total dose of 850 mg (400 mg/sq m). Subsequently, therapy was changed to vinblastine sulfate (Velban) and thiotepa. The skin changes improved when doxorubicin therapy was discontinued.

CASE 2.—A 51-year-old black woman was seen on Aug 27, 1975, for chemotherapy for

metastatic breast cancer. In 1951, the patient had had a hysterectomy and oophorectomy for uterine leiomyoma. In January 1975, she underwent left radical mastectomy for carcinoma of the breast. In August 1975, multiple pulmonary metastases developed and responded to cyclophosphamide, 100 mg/sq m orally from day 1 to 14; methotrexate, 40 mg/sq m intravenously on days 1 and 8; and fluorouracil, 500 mg/sq m intravenously on days 1 and 8 of the 28-day cycle. On Jan 21, 1976, a new lesion was observed in the left lung and doxorubicin therapy was started. After a second dose of doxorubicin, a total of 150 mg, she noticed hyperpigmented changes in the palms, dermal creases, and nail beds.

Comment.—The hypermelanotic pigmentary reaction as in these two patients had been recognized in children[3]; however, it has rarely been reported in adults.[4] Although the pathogenesis of this cutaneous manifestation is obscure, it appears to have a special predilection for the black race. There was no apparent correlation with the total dose administered and the development of the skin hyperpigmentation.

IVAN P. LAW, MD
Fort Bragg, NC

1. Adriamycin: New drug seminar. *Cancer Chem Rep* 6:383-389, 1975.
2. Carter SK: Single and combination nonhormonal chemotherapy in breast cancer. *Cancer* 30:1543-1555, 1972.
3. Pratt CB, Shanks EC: Hyperpigmentation of nails from doxorubicin. *JAMA* 228:460, 1974.
4. Rothberg H, Place CH, Shteir O: Adriamycin (NSC 123127) toxicity: Unusual melanotic reaction. *Cancer Chem Rep* 58:749-751, 1974.

Primary Inoculation With *Mycobacterium marinum*

To the Editor.—Nontuberculous mycobacterioses are becoming more frequently recognized as etiological agents in cutaneous disease.[1-4] Recently we had the opportunity to observe the course of a cutaneous *Mycobacterium marinum* infection in an accidentally inoculated laboratory worker.

Report of a Case.—Late in the evening of Dec 31, 1973, while attempting to inject the tail vein of a mouse, a 21-year-old male research laboratory worker accidentally inoculated his left thumb with a needle on a syringe containing a viable suspension of a 4-week-old culture of *M marinum* W46 that was grown on Dubos Oleic Albumin medium. The culture was centrifuged, and the bacteria was resuspended in Hanks balanced salt solution, without adjuvant, to give approximately 3.7×10^6 colony forming units/ml. The site was cleansed with an antiseptic detergent containing hexachlorophene (pHisoHex), but no further therapy was initiated. Ten days later the area was erythematous and mildly tender. On Jan 15, 1974, a 1-mm pale-yellow papule surrounded by a 2-mm rim of erythema was observed. Smears of pus that were tested for acid-fast bacilli were positive. Cultures of the same material on Middlebrook 7H10 and Lowenstein-Jensen media that were incubated for two weeks at 32 C grew *M marinum*.

Susceptibility tests indicated the following: sensitive to streptomycin sulfate at 10.0 μg/ml; ethionamide, 5.0 μg/ml; kanamycin sulfate, 5.0 μg/ml; viomycin sulfate, 5.0 μg/ml; ethambutol, 5.0 μg/ml, rifampin, 1.0 μg/ml. Resistance was confirmed to isoniazid and PAS. One tuberculin unit of purified protein derivative that was injected intradermally resulted in 10 mm of induration within 48 hours. Roentgenograms of the thumb and chest were normal. The patient declined having a biopsy because he feared dissemination. Also, he did not wish local or systemic therapy because of potential adverse effects and anticipated spontaneous resolution.

By Feb 12, the lesion had increased in size to 6×8 mm and had become hyperkeratotic. Two weeks later two satellite lesions, which were 2×2 mm, were noted proximal to the nodule. By the end of July these satellite nodules had disappeared, and the lesion was showing resolution. Complete resolution with only a fine scar was noted 15 months after the initial inoculation. There has been no recurrence during the past two years.

RONALD R. CHAPPLER, MD
AXEL W. HOKE, MD
KENNETH A. BORCHARDT, PHD
San Francisco

Lawrence Wayne, PhD, obtained the culture of *M marinum*.

1. Jolly HW, Seabury JH: Infections with *Mycobacterium marinum*. *Arch Dermatol* 106:32-36, 1972.
2. Zeligman I: *Mycobacterium marinum* granuloma: A disease acquired in the tributaries of Chesapeake Bay. *Arch Dermatol* 106:26-31, 1972.
3. Philpott JA, Jr, Woodburne AR, Philpott OS, et al: Swimming pool granuloma: A study of 290 cases. *Arch Dermatol* 88:158-162, 1963.
4. Adams RM, Remington JS, Steinbert J, et al: Tropical fish aquariums: A source of *Mycobacterium marinum* infections resembling sporotrichosis. *JAMA* 211:457-461, 1970.

HALOG® CREAM (Halcinonide Cream 0.1%)

Each gram of Halog Cream (Halcinonide Cream 0.1%) contains 1 mg. halcinonide (0.1%) in a cream base.

INDICATIONS: This product is intended for topical application for adjunctive therapy and symptomatic relief of inflammatory manifestations of acute and chronic corticosteroid responsive dermatoses.

CONTRAINDICATIONS: Topical steroids are contraindicated in vaccinia, varicella, and in those patients with a history of hypersensitivity to any of the components of the preparation. This preparation is not for ophthalmic use.

PRECAUTIONS: *General*—If local infection exists, suitable concomitant antimicrobial or antifungal therapy should be administered. If a favorable response does not occur promptly, application of the corticosteroid should be discontinued until the infection is adequately controlled. Although systemic side effects associated with absorption of topical corticosteroid preparations are rare, their possible occurrence must be kept in mind when these preparations are used over large areas or for an extended period of time. If irritation or sensitization develops, the preparation should be discontinued and appropriate therapy instituted. Although topical steroids have not been reported to have an adverse effect on pregnancy, the safety of their use during pregnancy has not been absolutely established; therefore, they should not be used extensively on pregnant patients, in large amounts, or for prolonged periods of time.

Occlusive Dressing Technique—The use of occlusive dressing increases the percutaneous absorption of corticosteroids; their extensive use increases the possibility of systemic effects. For patients with extensive lesions it may be preferable to use a sequential approach, occluding one portion of the body at a time. The patient should be kept under close observation if treated with the occlusive technique over large areas and over a considerable period of time. Occasionally, a patient who has been on prolonged therapy, especially occlusive therapy, may develop symptoms of steroid withdrawal when the medication is stopped. Thermal homeostasis may be impaired if large areas of the body are covered. Use of the occlusive dressing should be discontinued if elevation of the body temperature occurs. Occasionally, a patient may develop a sensitivity reaction to a particular occlusive dressing material or adhesive and a substitute material may be necessary. If infection develops, discontinue the use of the occlusive dressing and institute appropriate antimicrobial therapy.

ADVERSE REACTIONS: The following local adverse reactions have been reported with topical corticosteroids: burning, itching, irritation, striae, skin atrophy, secondary infection, dryness, folliculitis, hypertrichosis, acneform eruptions, and hypopigmentation. The following may occur more frequently with occlusive dressings: maceration of the skin, secondary infection, skin atrophy, striae, and miliaria. Contact sensitivity to a particular dressing material or adhesive may occur occasionally (see PRECAUTIONS).

For full prescribing information, consult package insert.

HOW SUPPLIED: In tubes of 15 and 60 g. and in jars of 240 g. (8 oz.).

SQUIBB® The Priceless Ingredient of every product is the honor and integrity of its maker. ™

© 1976 E.R. Squibb & Sons, Inc. 357-504

"Major improvement" in 5 days

Contact Dermatitis

Condition due to excessive use of 5-FU. Patient presented with intense pruritus, severe pain. Facial involvement sharply demarcated and acutely eczematous, erythematous and swollen—extending up into infra-orbital regions, but sparing eyelids and eyebrows.

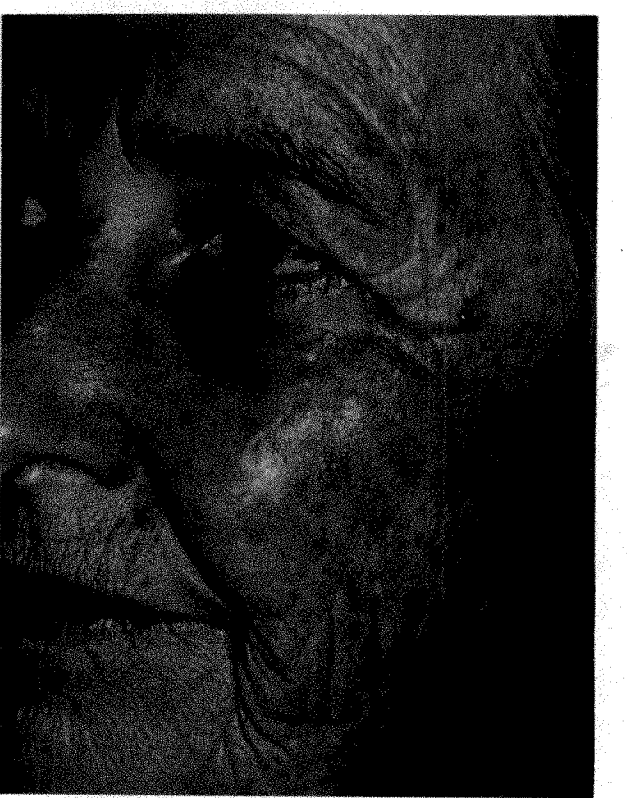

After 5 days

Halog 0.1% cream applied twice daily. Pruritus and pain relieved within 48 hours. Examination on day 5 of therapy revealed major improvement with only mild, residual erythema still present. Total resolution of all lesions nine days later, at which time therapy was discontinued.

Case history on file at Squibb Institute for Medical Research.

after Halog® Cream b.i.d

Halcinonide Cream 0.1%

See adjacent **SQUIBB®** column for brief summary.

Dermatophilus Infection in Animals and Man

Edited by
D. H. LLOYD and K. C. SELLERS

This book is the proceedings of a symposium on Dermatophilus infection held at the University of Ibadan, Nigeria, which brought together research workers interested in the disease from various parts of the world, and provided a forum for discussion of the many controversial aspects of the subject.

The book includes chapters on the prevalence and epidemiology of Dermatophilus infection in tropical, subtropical and temperate regions of the world. There are sections on the pathology, bacteriology and immunology of the disease, its economic effects and methods for its prevention and control—in particular the use of a recently developed method of prophylactic vaccination is described. A chapter is specifically devoted to a review of the disease in man and other primates, and the final section of the book deals with controversy over the classification of *Dermatophilus congolensis* and the nomenclature of different clinical forms of Dermatophilus infection.

CONTENTS: The Epidemiology of Dermatophilus Infection: The Disease in Africa; The Disease in Europe and the Middle East; The Disease in America; The Disease in Primates; The Analysis of Epidemiological Information. The Site of Infection by *Dermatophilus congolensis*: The Pathology of Dermatophilus Infection. The Bacteriology of *Dermatophilus congolensis*. The Immunology of Dermatophilus Infection. The Treatment and Control of Dermatophilus Infection. The Economic Consequences of Dermatophilus Infection. Nomenclature in Dermatophilus Infection: A Discussion.

1976, 332 pp., $17.25/£7.00
ISBN: 0-12-453750-2

Send payment with order and save postage plus 50¢ handling charge.
Prices subject to change without notice.

ACADEMIC PRESS, INC.
A Subsidiary of
Harcourt Brace Jovanovich, Publishers
111 FIFTH AVENUE, N.Y., N.Y. 10003
24-28 OVAL ROAD, LONDON NW1 7DX

Please send me____copies of Lloyd/Sellers: *Dermatophilus Infection in Animals and Man*
Check enclosed____ Bill me____

NAME____
ADDRESS____
CITY/STATE/ZIP____

New York residents please add sales tax.
Direct all orders to Mr. Paul Negri, Media Dept. *ArchD/3/77*

The Department of Dermatology Stanford University School of Medicine

is seeking a replacement for a faculty position at the Assistant or Associate Professor level in Dermatopathology. Applicants should have Board Certification in Pathology or Dermatopathology and experience in skin biology and dermatopathology to meet the requirements of the position which involves teaching, research and dermatodiagnostic pathology. Stanford University is an equal opportunity employer and welcomes nominations of women and minority group members and applications from them.

Applicants should send their curriculum vitae to Eugene M. Farber, M.D., Professor and Chairman, Department of Dermatology, Stanford University School of Medicine, Stanford, Calif. 94305



computers and medicine

the publication that tells you how physicians have put computers to work -- in practical, valuable ways

This bi-monthly publication reports on ways computer potential has been harnessed and used clinically and administratively in private practice, clinics, hospitals, and medical societies.

It describes medical-computer systems in use now, those still in the developmental and experimental stages, and tells you whom to contact for more details.

Let COMPUTERS AND MEDICINE start bringing you ideas. Order a subscription now! $5 for 1 yr.; $8 for 2 yrs. (U.S. and U.S. Possessions only). Send a check or money order to Subscriber Services. AMA, 535 N. Dearborn St., Chicago, Ill. 60610.

FULVICIN-U/F® Tablets brand of griseofulvin (microsize) tablets, U.S.P.
CLINICAL CONSIDERATIONS—
INDICATIONS Griseofulvin is indicated for the treatment of ringworm infections of the skin, hair, and nails, namely: *Tinea corporis, Tinea pedis, Tinea cruris, Tinea barbae, Tinea capitis, Tinea unguium* (onychomycosis) when caused by one or more of the following genera of fungi: *Trichophyton rubrum, Trichophyton tonsurans, Trichophyton mentagrophytes, Trichophyton interdigitalis, Trichophyton verrucosum, Trichophyton megnini, Trichophyton gallinae, Trichophyton crateriform, Trichophyton sulphureum, Trichophyton schoenleini, Microsporum audouini, Microsporum canis, Microsporum gypseum, Epidermophyton floccosum.*
NOTE: Prior to therapy, the type of fungi responsible for the infection should be identified.
The use of this drug is not justified in minor or trivial infections which will respond to topical agents alone.
Griseofulvin is *not* effective in the following: Bacterial infections, Candidiasis (Moniliasis), Histoplasmosis, Actinomycosis, Sporotrichosis, Chromoblastomycosis, Coccidioidomycosis, North American Blastomycosis, Cryptococcosis (Torulosis), *Tinea versicolor*, Nocardiosis.
CONTRAINDICATIONS This drug is contraindicated in patients with porphyria, hepatocellular failure, and in individuals with a history of sensitivity to griseofulvin.
WARNINGS **Prophylactic usage:** Safety and efficacy of griseofulvin for prophylaxis of fungal infections have not been established.
Animal toxicology: Chronic feeding of griseofulvin, at levels ranging from 0.5-2.5% of the diet, resulted in the development of liver tumors in several strains of mice, particularly in males. Smaller particle sizes result in an enhanced effect. Lower oral dosage levels have not been tested. Subcutaneous administration of relatively small doses of griseofulvin, once a week, during the first three weeks of life has also been reported to induce hepatomata in mice. Although studies in other animal species have not yielded evidence of tumorogenicity, these studies were not of adequate design to form a basis for conclusions in this regard.
In subacute toxicity studies, orally administered griseofulvin produced hepatocellular necrosis in mice, but this has not been seen in other species. Disturbances in porphyrin metabolism have been reported in griseofulvin-treated laboratory animals. Griseofulvin has been reported to have a colchicine-like effect on mitosis and cocarcinogenicity with methylcholanthrene in cutaneous tumor induction in laboratory animals.
Usage in pregnancy: The safety of this drug during pregnancy has not been established.
Animal reproduction studies: It has been reported in the literature that griseofulvin was found to be embryotoxic and teratogenic on oral administration to pregnant rats. Pups with abnormalities have been reported in the litters of a few bitches treated with griseofulvin. Additional animal reproduction studies are in progress.
Suppression of spermatogenesis has been reported to occur in rats, but investigation in man failed to confirm this.
PRECAUTIONS Patients on prolonged therapy with any potent medication should be under close observation. Periodic monitoring of organ system functions, including renal, hepatic, and hematopoietic, should be done.
Since griseofulvin is derived from species of *Penicillium*, the possibility of cross sensitivity with penicillin exists; however, known penicillin-sensitive patients have been treated without difficulty.
Since a photosensitivity reaction is occasionally associated with griseofulvin therapy, patients should be warned to avoid exposure to intense natural or artificial sunlight. Should a photosensitivity reaction occur, lupus erythematosus may be aggravated.
Griseofulvin decreases the activity of warfarin-type anticoagulants so that patients receiving these drugs concomitantly may require dosage adjustment of the anticoagulant during and after griseofulvin therapy.
Barbiturates usually depress griseofulvin activity and concomitant administration may require a dosage adjustment of the antifungal agent.
ADVERSE REACTIONS When adverse reactions occur, they are most commonly of the hypersensitivity type, such as skin rashes, urticaria, and rarely, angioneurotic edema, and may necessitate withdrawal of therapy and appropriate counter-measures. Paresthesias of the hands and feet have been reported rarely after extended therapy. Other side effects reported occasionally are oral thrush, nausea, vomiting, epigastric distress, diarrhea, headache, fatigue, dizziness, insomnia, mental confusion, and impairment of performance of routine activities.
Proteinuria and leukopenia have been reported rarely. Administration of the drug should be discontinued if graulocytopenia occurs.
When rare, serious reactions occur with griseofulvin, they are usually associated with high dosages, long periods of therapy, or both.
AVAILABLE in 125 mg., 250 mg., and 500 mg. scored tablets.
010 AUGUST 1973
For more complete details, consult package insert or Schering literature available from your Schering Representative or Professional Services Department, Schering Corporation, Kenilworth, New Jersey 07033.

SUSTAINED THERAPEUTIC PLASMA LEVELS WITH ONLY ONE TABLET A DAY

Schering

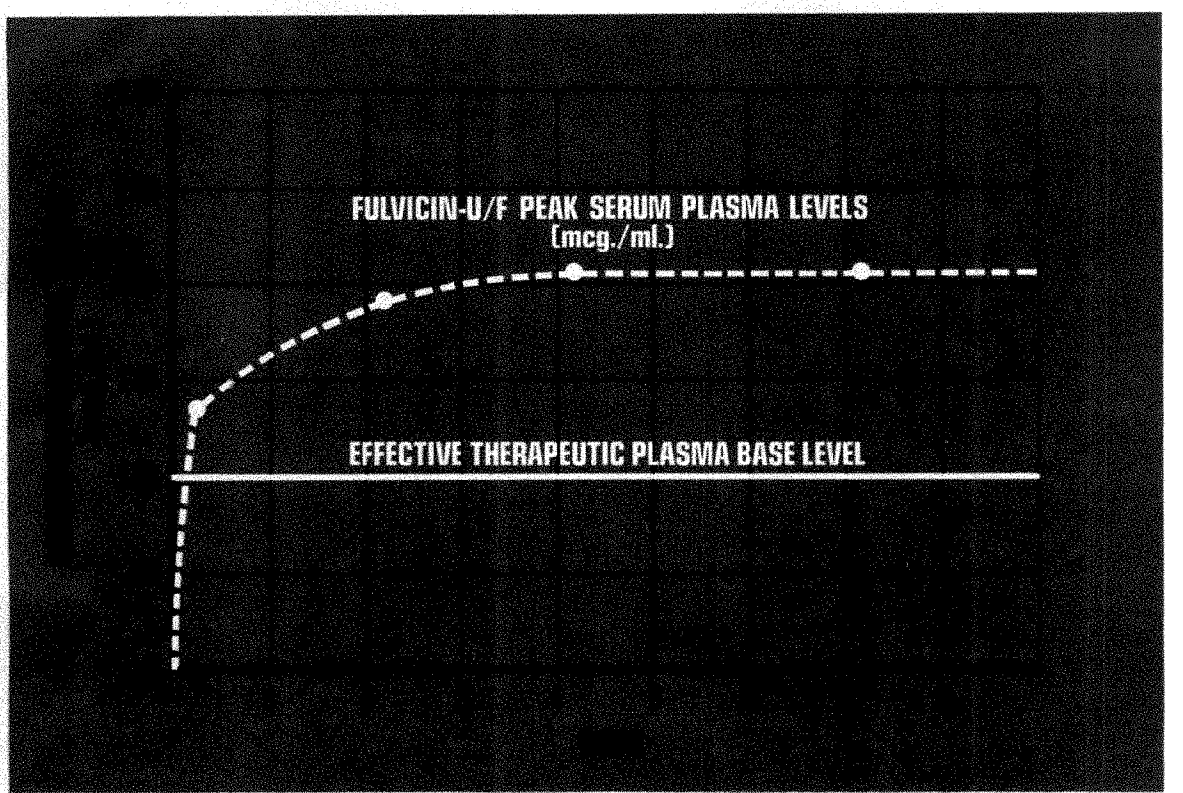

Adapted from Symchowicz, S., and Katchen, B.: J. Pharm. Sci. 57:1383, 1968.

The above graph depicts average peak serum plasma levels of FULVICIN-U/F following once-daily dosage of one FULVICIN-U/F 500 mg. tablet given before breakfast to six normal subjects for a seven-day period.

Hours of fungistatic action at ringworm sites

The above graph on plasma levels of FULVICIN-U/F 500 mg. in once-daily dosage indicates that this dosage is adequate to keep the antibiotic available for antifungal action in the keratin precursor cells where fungi have invaded. With the growth checked by the fungistatic action, the fungi are cast off as the keratin grows out and sloughs off. Healthy tissue replaces infected keratin of skin, hair, and nails.

Clinical efficacy, safety, and convenience

The Ultra-Fine form of FULVICIN®—in clinical use for over 15 years—possesses two vital keys to success in long-term ringworm therapy: product familiarity, and the confidence that comes after years of effective and safe therapy. For your patient: dosage simplicity. The easy-to-remember, once-a-day routine that helps avoid dosage delinquency and the possibility of therapeutic setbacks when therapeutic plasma levels are not maintained.

FULVICIN-U/F® 500mg.
brand of
griseofulvin [microsize] tablets, U.S.P.

JUST ONCE a DAY

See Clinical Considerations on opposite page.

COPYRIGHT © 1975, SCHERING CORPORATION, ALL RIGHTS RESERVED.

SLS-534

Society Transactions

The Society Proceedings are edited by Dr Morris Waisman, 806 First Federal Bldg, 220 Madison St, Tampa, FL 33602. Transactions and photographs should be sent, in duplicate, directly to him.

THE LOS ANGELES DERMATOLOGICAL SOCIETY
May 14, 1975

Marian M. Brubaker, MD, Recorder

Prurigo Nodularis, Presenting as a Pseudotumor. Presented by DON E. SUTER, MD, ALFRED TROSOW, MD.

A 48-year-old man was seen initially in April 1975 with a 2.5-cm firm tumor of the right temple that had an oozing surface and that had been present for three weeks. There were no cervical nodes. He has a history of recurrent, long-term pruritic eruptions of his arms and trunk attended with scratching. There is a 20-year history of ulcer symptoms, for which he takes antacids. He bathes frequently and has used various antibacterial soaps.

Results of a complete blood cell count, VDRL test for syphilis, and urinalysis and chest film were all normal. Biopsy specimens were taken from the left temple lesion and from a lesion on the left side of the chest. These specimens were examined by Dr Elson B. Helwig of the Armed Forces Institute of Pathology and were diagnosed as chronic dermatitis. Because of the marked acanthosis, the diagnosis of prurigo nodularis was suggested by one member of the staff.

Treatment has consisted of 0.1% betamethasone (Valisone) cream, which cleared most of the trunk and arm lesions, but made little change in the temple lesion.

Discussion

DR LEO INDIANER: I could only interpret the slide as pseudoepitheliomatous hyperplasia. This is not my concept of prurigo nodularis. It would be nice to postulate that this is caused by neurodermatitis and that it is a pseudotumor. It is a tumor only clinically; it still may be a tumor histologically if other areas are examined.

DR SAMUEL AYRES JR: I cannot go along with the diagnosis of prurigo nodularis. The patient said he had had an itchy eruption from the age of 4 to 18, but for the ensuing 30 years, he had no skin trouble until two months ago. Now he has this single lesion. I do not see how you can connect this with prurigo nodularis. I do not know what the lesion is. It looks like some type of granuloma. A suberythema dose of x-ray therapy might be of some benefit.

DR LAWRENCE NELSON: Occasionally, we see this solitary-type lesion in patients in mental institutions. They will chew an arm and get a similar lesion, but with hair growing in the site.

DR LYON ROWE: Clinically, prurigo nodularis should be single or multiple hard keratotic nodules that the patient manipulates. Also, the microscopic sections have been described as having fragmented nerve fibers imbedded in the lesions. Thus, neither clinically nor histopathologically does this case fit prurigo nodularis.

DR SUTER: Dr Trosow disagrees with prurigo nodularis. I do not. A patient with prurigo nodularis picks at his skin chronically, as this man does. He had 15 or 20 lesions on his trunk when we saw him three weeks ago. They have markedly subsided, but they are still palpable. He scratches. My impression when I first saw him was that he had a metastatic or primary carcinoma on his temple. I think that this is a localized hypertrophic neurodermatitis or something similar, and that this is what prurigo nodularis is. It remains to be proved whether or not the histopathologic features are as exact for this disease as now stated.

Lepromatous Leprosy. Presented by RONALD REISNER, MD, SUSAN PHELPS, MD.

The patient is a 21-year-old woman (eight months pregnant) from Guadalajara, Mexico, who has been living in California for the past three years. She visits Mexico each year. During the last seven months, she has noted a pruritic macular scaling eruption on her extremities. In the last three months, she has developed tender nodules on her extremities, with some numbness of her toes. There are no other systemic complaints. She denies that any other family member has had a similar eruption.

On examination, there is a purplish reticulated pattern on her extremities, with scattered and slightly tender nodules primarily on the legs, with a few lesions on the forearms. The ulnar nerves are slightly palpable. There is no loss of eyebrows.

A complete blood cell count was done. The hemoglobin value was 11.3 gm/100 ml; the hematocrit reading was 34.7%; and the WBC count was 6,400/cu mm, with a normal differential cell count. The platelets were adequate, and the ESR was 38 mm/hr. Results of blood chemistry studies with an automated analysis system and blood creatinine level were normal. The VDRL test for syphilis was negative. The biopsy diagnosis was leprosy, with a positive Fite stain.

Discussion

DR CARL KORN: This is a case of lepromatous leprosy of the diffuse form that shows evidence of nodular formation. The focus here is on an immediate therapeutic decision: the form of therapy to choose and whether treatment should be instituted immediately in leprosy newly diagnosed in a woman eight months pregnant, or be delayed until after delivery. The objectives include control of the disease in the patient and reduction of the risk of transmission to others. The unusual features of this case concern the possibility of fetal transmission and the fact that the patient was in a reactional state when first examined, having erythema nodosum leprosum (ENL).

The standard therapeutic agent in leprosy remains the sulfones. Their effect is slow, as measured by both the clinical course and by the available methods for determining their bacteriostatic action. These methods include the bacteriologic index and the morphologic index, which have been extrapolated to apply to transmissibility of the disease; but their relevance is highly inferential. There is much that is certain regarding transmission of the disease. Intrauterine transmission is not known to occur. Household exposure of young children and others can result in infection. The Kluth study in Texas several years ago showed 4% of the offspring living with parents who had active lepromatous leprosy developing the disease.

Our experience has been that leprosy is not transmitted across the placental barrier. Also, transmission to contactants of treated cases is rare. In southern California, leprosy is essentially an imported disease. In view of this, there is no reason to institute therapy to protect the fetus.

One might consider the possibility that the earlier treatment is begun in the mother, the less the risk of postpartum transmission to the infant. However, the slow effect of the sulfones indicates there would be no harm in delaying sulfone therapy a month now, and there may be advantages to this short delay. Since the patient is in a reactional state of ENL, and evidence is that this can occur in the absence of or prior to any sulfone therapy, it may be potentiated by sulfones. With the advent of thalidomide, this has not been a problem when the drug can be used in lepromatous leprosy. However, can we use thalidomide during pregnancy? Our evidence concerning embryopathy is that it occurs with the administration of the drug early in pregnancy. Nevertheless, I would advise erring on the side of caution; it would be difficult to defend thalidomide's use should a malformed fetus be delivered.

Other factors we may consider in this patient have to do with isolation, childhood leprosy, and sulfone-induced anemia. It is no longer standard practice to isolate patients, even those with lepromatous leprosy. It certainly is not the practice to separate a mother and her child. With regard to childhood leprosy, many children possibly have a limited form of the disease and heal spontaneously. Finally, an almost constant side effect of sulfone therapy is a shortened RBC half-life and resultant anemia. Fortunately this anemia is generally mild, limited to a 2.0- to 4.0-gm drop in the hemoglobin level; but, this may be important in pregnancy. In summation, I would withhold sulfone therapy in this pregnant woman until after delivery of her baby.

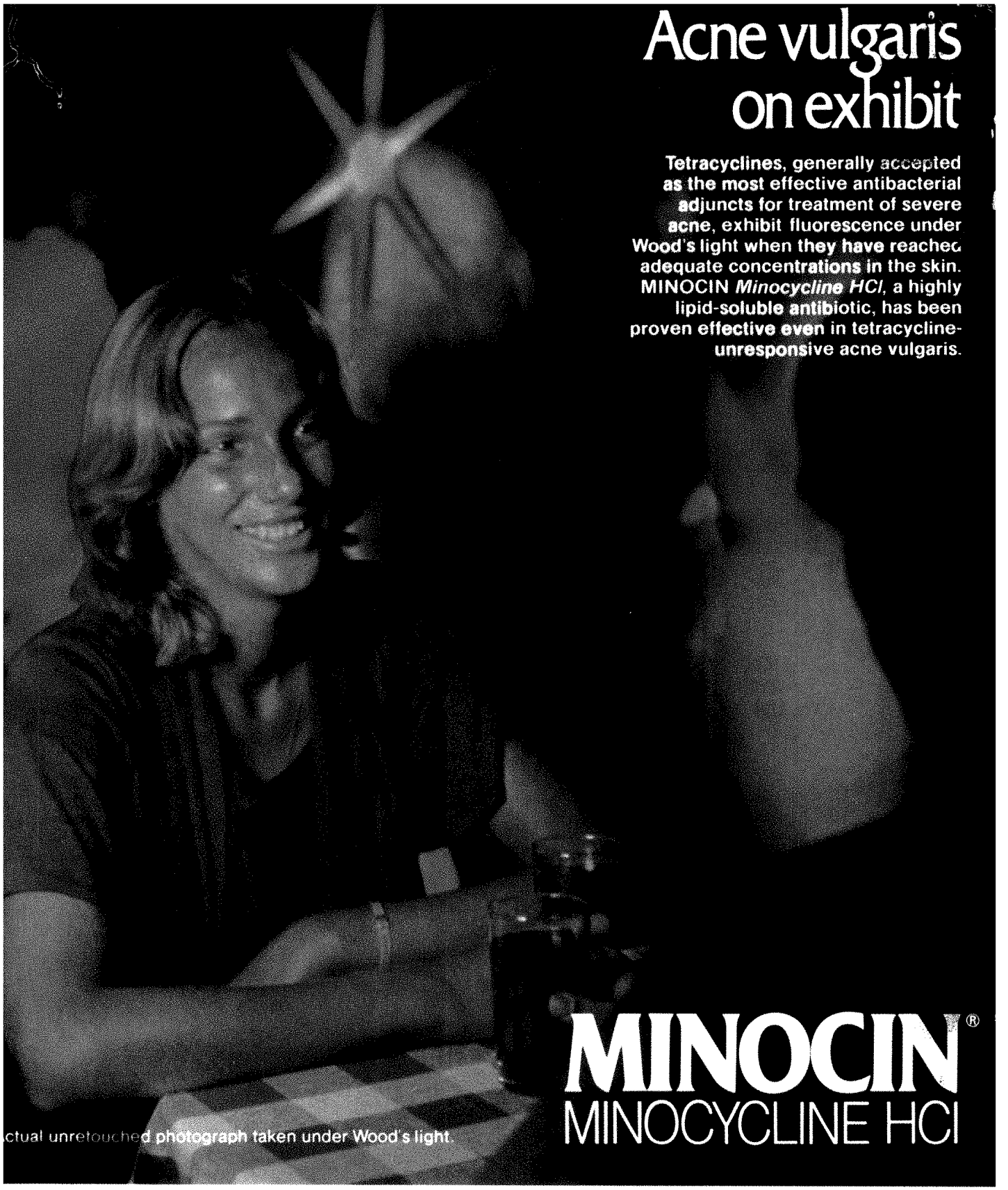

INOCIN Minocycline HCl
ral and Intravenous Brief Summary
ontraindications: Hypersensitivity to any tetracycline.
arnings: Intravenous use, particularly in pregnancy, in daily oses exceeding 2 grams has been associated with deaths rough liver failure. When need for intensive treatment outeighs potential dangers, perform renal and liver function tests efore and during therapy; also follow serum concentrations. In nal impairment, usual doses may lead to excessive accumulaon and liver toxicity. Under such conditions, use lower total oses, and, in prolonged therapy, determine serum levels. This azard is of particular importance in I.V. use in pregnant or ostpartum patients with pyelonephritis. In such cases, the blood vel should not exceed 15 mcgm/ml, and liver function tests ould be made at frequent intervals. Do not prescribe other

cyclines during tooth development (last half of pregnancy, infancy and childhood to the age of 8 years) may cause permanent discoloration of the teeth (yellow-gray-brown). This is more common during long-term use but has been observed following repeated short-term courses. Enamel hypoplasia has also been reported. Tetracyclines, therefore, should not be used in this age group unless other drugs are not likely to be effective or are contraindicated. Photosensitivity manifested by an exaggerated sunburn reaction has been observed in some individuals taking tetracyclines. Advise patients apt to be exposed to direct sunlight or ultraviolet light that such reaction can occur, and discontinue treatment at first evidence of skin erythema. Studies to date indicate that photosensitivity is rarely reported with MINOCIN *Minocycline HCl*. In patients with significantly impaired renal function, the antianabolic action of tetracycline may cause an

acidosis. CNS side effects (lightheadedness, dizziness, vertigo) have been reported, may disappear during therapy, and always disappear rapidly when drug is discontinued. Caution patients who experience these symptoms about driving vehicles or using hazardous machinery while taking this drug. **Pregnancy:** In animal studies, tetracyclines cross the placenta, are found in fetal tissues, and can have toxic effects on the developing fetus (often related to retardation of skeletal development). Embryotoxicity has been noted in animals treated early in pregnancy. **Newborns, infants and children:** All tetracyclines form a stable calcium complex in any bone-forming tissue. Prematures, given oral doses of 25 mg /kg every 6 hours, demonstrated a decrease in fibula growth rate, reversible when drug was discontinued. Tetracyclines are present in the milk of lactating women who are taking a drug in this class.

Staph infection: Skin deeper

When the patient is penicillin-hypersensitive, when bacteriologic testing shows *Staph. aureus* to be resistant or the infection has proved unresponsive, MINOCIN *Minocycline HCl* may be an effective alternative.* Clinical studies have demonstrated satisfactory response in 156 of 173 simple or mixed skin and soft tissue infections due to staphylococci.

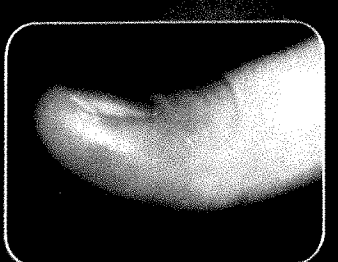

Actual patient photograph after 7 days of MINOCIN.

MINOCIN®
MINOCYCLINE HCl

CAPSULES 50 mg and 100 mg
SYRUP 50 mg/5 cc
INTRAVENOUS 100 mg/vial

100 or 200 mg initially, 50 mg *q.i.d.* or 200 mg initially, 100 mg *b.i.d.*

*Tetracyclines are not the drugs of choice in the treatment of any type of staphylococcal infection. MINOCIN is indicated for treatment of *Staphylococcus aureus* skin and soft tissue infections only when bacteriologic tests indicate appropriate susceptibility to the drug.

MINOCIN Minocycline HCl
Oral and Intravenous Brief Summary (continued)
organisms, including fungi. If superinfection occurs, institute appropriate therapy. In venereal diseases when coexistent syphilis is suspected, darkfield examination should be done before treatment is started and blood serology repeated monthly for at least four months. Patients on anticoagulant therapy may require downward adjustment of such dosage. Test for organ system dysfunction (*e.g.*, renal, hepatic and hemopoietic) in long-term use. Treat all group A beta-hemolytic streptococcal infections for at least 10 days. Avoid giving tetracycline in conjunction with penicillin.
Adverse Reactions: GI: (with both oral and parenteral use) anorexia, nausea, vomiting, diarrhea, glossitis, dysphagia, enterocolitis, inflammatory lesions (with monilial overgrowth) in anogenital dermatitis (uncommon). Photosensitivity is discussed above ("Warnings"). **Renal toxicity:** rise in BUN, dose-related (see "Warnings"). **Hypersensitivity reactions:** urticaria, angioneurotic edema, anaphylaxis, anaphylactoid purpura, pericarditis, exacerbation of systemic lupus erythematosus. In young infants, bulging fontanels have been reported following full therapeutic dosage, disappearing rapidly when drug was discontinued. **Blood:** hemolytic anemia, thrombocytopenia, neutropenia, eosinophilia. **CNS:** (see "Warnings"). When given in high doses, tetracyclines may produce brown-black microscopic discoloration of thyroid glands; no abnormalities of thyroid function studies are known to occur. **NOTE: Concomitant therapy:** Antacids containing aluminum, calcium, or magnesium impair absorption; do not give to patients taking oral minocycline. Studies to date indicate that absorption of MINOCIN *Minocycline HCl* is not notably influenced by foods and dairy products.

CNS side effects including lightheadedness, dizziness, or vertigo have been reported with MINOCIN. Patients who experience these symptoms should be cautioned about driving vehicles or using hazardous machinery while on minocycline therapy.

Lederle

LEDERLE LABORATORIES
A Division of American Cyanamid Compa

what's best for the care of dry, or premature aging or wrinkled skin... DUE TO EPIDERMAL DEHYDRATION?

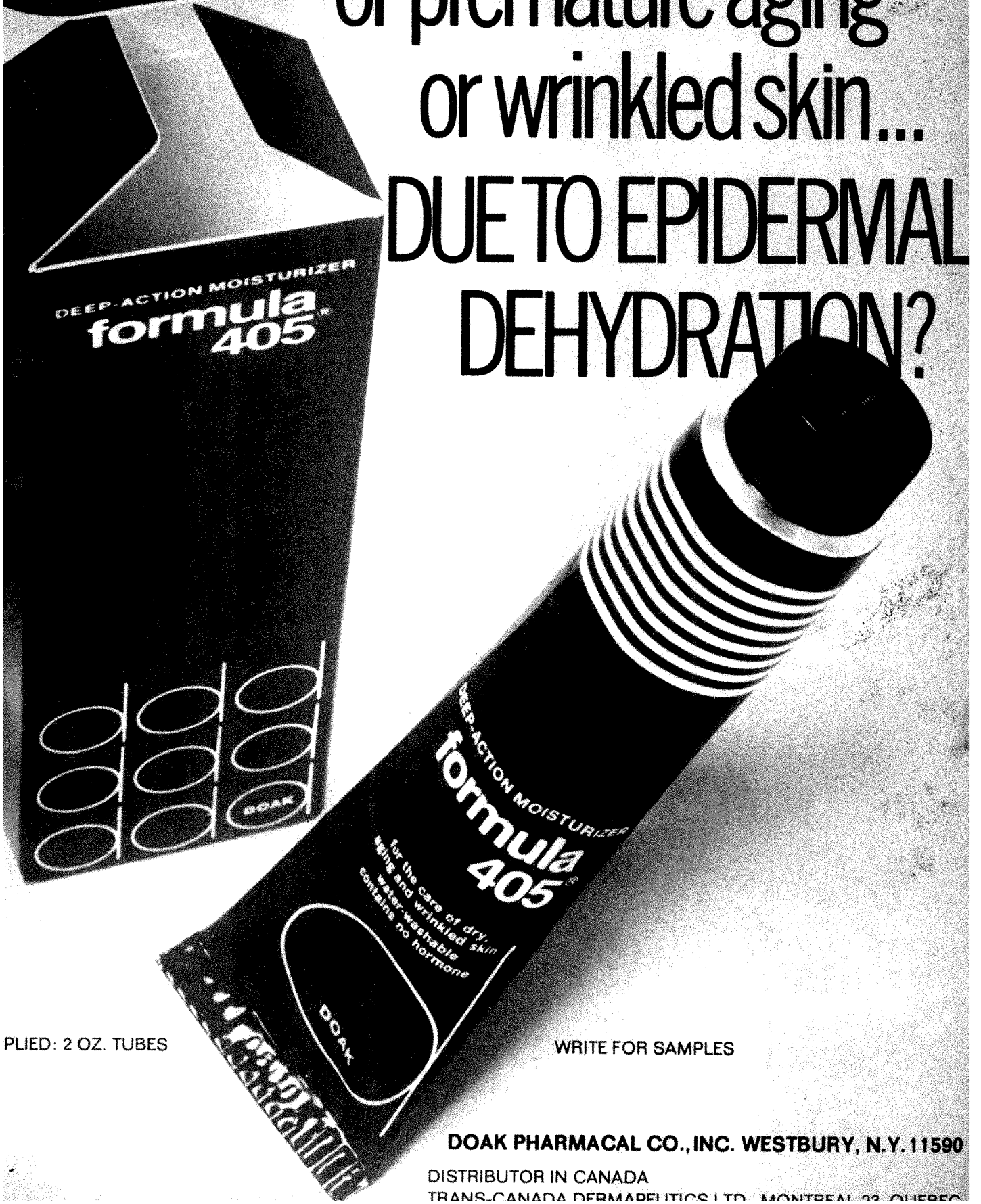

PLIED: 2 OZ. TUBES

WRITE FOR SAMPLES

DOAK PHARMACAL CO., INC. WESTBURY, N.Y. 11590

DISTRIBUTOR IN CANADA

TRANS-CANADA DERMAPEUTICS LTD., MONTREAL 23, QUEBEC

aggravating

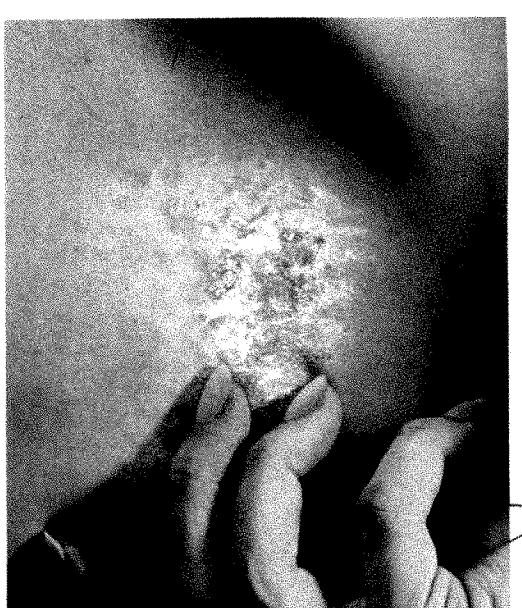

...allergic dermatoses

with strong emotional overlay

Atarax®

(hydroxyzine hydrochloride)

TABLETS: 10 mg, 25 mg, and 50 mg

- rapid antianxiety action
- demonstrated antihistaminic activity

Contraindications: Hypersensitivity to hydroxyzine. Hydroxyzine, when administered to the pregnant mouse, rat, and rabbit, induced fetal abnormalities in the rat at doses substantially above the human therapeutic range. Clinical data in human beings are inadequate to establish safety in early pregnancy. Until such data are available, hydroxyzine is contraindicated in early pregnancy.

Precautions: Hydroxyzine may potentiate the action of central nervous system depressants such as meperidine and barbiturates. In conjunctive use, dosage for these drugs should be reduced. Because drowsiness may occur, patients should be cautioned against driving a car or operating dangerous machinery.

Adverse Reactions: Drowsiness may occur; if so, it is usually transitory and may disappear in a few days of continued therapy or upon dosage reduction. Dryness of the mouth may occur with higher doses. Involuntary motor activity, including rare instances of tremor and convulsions, has been reported, usually with higher than recommended dosage.

Supply: Tablets, containing 10 mg, 25 mg, or 50 mg hydroxyzine hydrochloride, 100's and 500's; Tablets, containing 100 mg, 100's; Syrup, containing 10 mg per teaspoonful (5 ml) and ethyl alcohol 0.5% v/v, pint bottles.

Before prescribing or administering, see package circular.

ROERIG Pfizer

A division of Pfizer Pharmaceuticals
New York, New York 10017

ROCHE

Roche Laboratories announces an additional therapeutic application for Efudex® 5% Cream fluorouracil/Roche

now indicated for superficial basal cell carcinoma

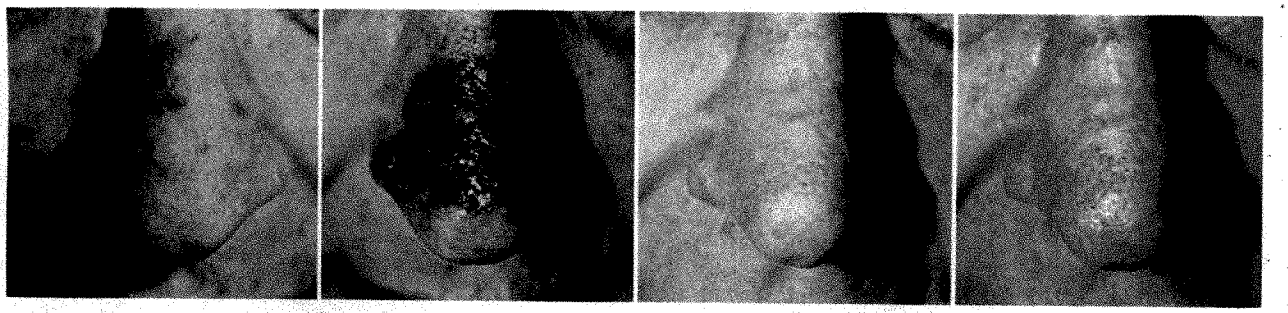

8/8/69
Before treatment a superficial, scaly, slightly excoriated lesion was present. Biopsy revealed the lesion to be a superficial basal cell carcinoma.

9/25/69
After 7 weeks of treatment with Efudex (fluorouracil) 5% Cream, lesion site is clearly delineated, markedly erythematous; surrounding skin shows no reaction to medication. Treatment terminated.

12/10/70
Follow-up approximately 14 months after treatment; healing has occurred with minimal scarring.

4/18/74
Patient has been followed continuously since treatment. **No evidence of recurrence.**

Efudex (fluorouracil) 5% Cream is recommended as an effective topical alternative to surgery for multiple lesions and difficult treatment sites.

A proven cytotoxic agent that exerts a marked effect on cells that grow more rapidly.

Cosmetically gratifying results, with minimal or no scarring. No systemic toxicity. Normal tissue rarely affected. Convenient, economical b.i.d. application.

Prolonged exposure to ultraviolet light may accelerate reaction to medication. If an occlusive dressing is used, there may be an increase in the incidence of inflammatory reactions in the adjacent normal skin.

An exclusive Roche formulation

Efudex® 5% Cream

fluorouracil/Roche

Before prescribing, please consult complete product information, a summary of which follows:
Indications: Multiple actinic or solar keratoses; superficial basal cell carcinomas when conventional methods are impractical (5% strength only).
Contraindications: If occlusive dressing is used, may increase inflammatory reactions in adjacent normal skin. Avoid prolonged exposure to ultraviolet rays. Safe use in pregnancy not established.
Precautions: If applied with fingers, wash hands immediately. Apply with care near eyes, nose and mouth. Solar keratoses failing to respond should be biopsied; perform follow-up biopsies in superficial basal cell carcinoma.
Adverse Reactions: Local—pain, pruritus, hyperpigmentation and burning at application site most frequent; also dermatitis, scarring, soreness, tenderness, suppuration, scaling and swelling. Also reported—insomnia, stomatitis, irritability, medicinal taste, photosensitivity, lacrimation, telangiectasia, leukocytosis, thrombocytopenia, toxic granulation and eosinophilia.
Dosage and Administration: *Actinic or solar keratosis*—apply sufficient quantity to cover lesions, twice daily. Usual length of therapy is 2 to 4 weeks. *Superficial basal cell carcinomas*—apply sufficient quantity **(only 5% strength recommended)** to cover lesions, twice daily. Continue treatment for at least 3 to 6 weeks, but possibly as long as 10 to 12.
How Supplied: Solution, 10-ml drop dispensers containing 2% or 5% fluorouracil on a weight/weight basis. Cream, 25-Gm tubes containing 5% fluorouracil in a vanishing cream base.

ROCHE

Roche Laboratories
Division of Hoffmann-La Roche Inc.
Nutley, New Jersey 07110

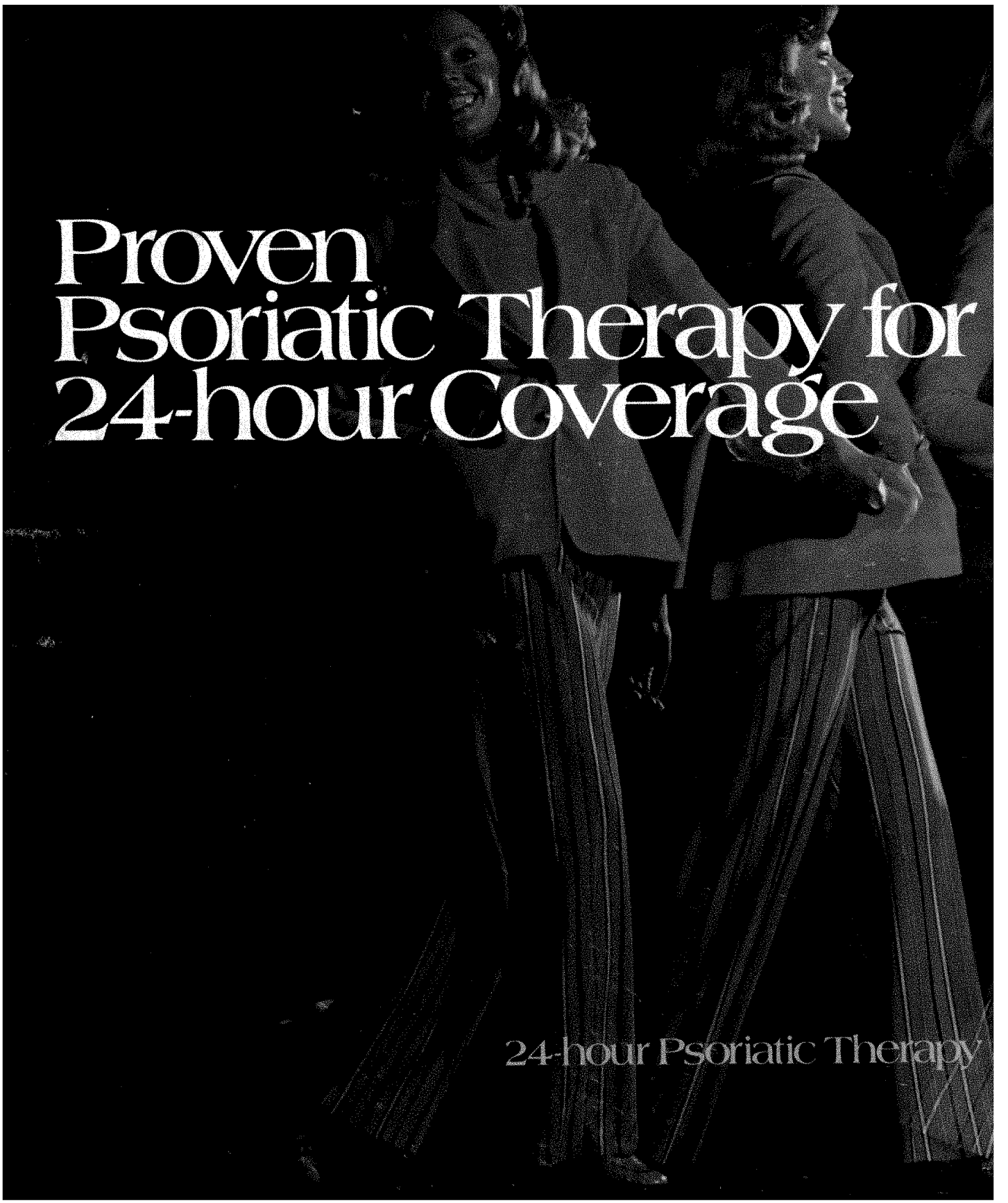
Proven
Psoriatic Therapy for
24-hour Coverage
24-hour Psoriatic Therapy

estar™

Therapeutic Tar Gel

Tar odor won't betray **estar** therapy. Proven **estar** Therapeutic Tar Gel is equivalent to 5% crude coal tar in everything but odor. No sticky, greasy residue to remain on the skin . . . proven therapy to control the formation of psoriatic scales and reduce itching with antipruritic action so that scratching is less likely.

The gel base enables the patient to apply **estar** evenly and smoothly. Tar therapy that doesn't smell like it . . . **estar** Therapeutic Tar Gel.

Balnetar®

Water-dispersible Emollient Tar

Change ordinary water into a psoriatic treatment for patients who bathe before bedtime. **Balnetar** can work through the night to provide keratoplastic, antieczematous, and antipruritic action. It lubricates and moisturizes the skin to relieve and help prevent excessive dryness while it softens and aids in the removal of scales and crusts. One to three capfuls of **Balnetar** added to a tub of warm water can extend the effect of **estar** Therapeutic Tar Gel to twenty-four hour tar therapy. The active ingredient in **Balnetar** treats the skin without staining it or the porcelain of the tub.

Sebutone®

Therapeutic Tar Shampoo

When psoriasis finds its way to the scalp, **Sebutone** can penetrate, soften, and remove scales, crusts, and excess oil with its chemically and biologically standarized tar. Microfine particles of tar remain on the scalp for up to three days (as shown with Wood's light) providing prolonged residual action. The fresh, clean fragrance and excellent cleansing properties of **Sebutone** make no other shampoo necessary when treating scalp psoriasis or any stubborn case of seborrhea or dandruff.

ith estar/Balnetar/Sebutone

Please see product information on next page.

©1977 W.P. Inc.

WESTWOO
PHARMACEUTICALS IN
Buffalo, New York 142
In Canada, Belleville, Ontario K8N 1

estar™

Therapeutic Tar Gel

Composition: Westwood® Tar (biologically equivalent to 5% Coal Tar USP) in hydro-alcoholic gel (29% alcohol).

Actions and Uses: A therapeutic aid in the treatment of psoriasis and other tar responsive dermatoses such as eczema (atopic dermatitis, lichen simplex chronicus, nummular eczema) and seborrheic dermatitis. **estar** is suitable for use in a modified Goeckerman regimen, either in the hospital or on an outpatient basis; it also can be used in follow-up treatment to help maintain remissions.

Contraindications: estar should not be applied to acutely inflamed skin or used by individuals who are known to be sensitive to coal tar.

Dosage and Administration:

Psoriasis:
The patient should massage **estar** into affected areas, once or twice per day or as directed by physician. Rub in well, allow the gel to remain for five minutes, and then remove excess by patting with tissues.

Chronic atopic dermatitis, Lichen simplex chronicus, Nummular eczema, and Seborrheic dermatitis:

One or two applications per day, as described above, are suggested. If dryness occurs, an emollient may be applied one hour after **estar.**

Caution: AFTER USING, PROTECT TREATED AREAS FROM SUNLIGHT UNLESS DIRECTED BY PHYSICIAN. DO NOT USE ON HIGHLY INFLAMED OR BROKEN SKIN. If used on the scalp, temporary discoloration of blond, bleached or tinted hair may occur. If undue irritation develops or increases, discontinue use and consult physician. AVOID CONTACT WITH EYES. In case of contact, flush eyes with water.

Slight staining of clothing may occur. Standard laundry procedures will usually remove stains.

For complete prescribing information, see PDR.

SUPPLIED: 3 oz. plastic tube.

Balnetar®

Water-dispersible Emollient Tar

CONTAINS: WESTWOOD® TAR (Equivalent to 2.5% crude coal tar U.S.P.) mineral oil, and lanolin oil.

Balnetar is an important adjunct in the management of a wide range of dermatoses, including:

Atopic dermatitis
Psoriasis
Chronic eczematoid dermatitis
Eczematoid dermatitis
Seborrheic dermatitis

Suggested for use in modified Goeckerman regimen.

Directions:
Balnetar should always be used with water—either added to water or rubbed into wet skin.

Bath: Add 1 to 3 capfuls to a tub of warm water. Do not use soap. Soak for 10 to 20 minutes. Pat dry. Frequency depends on nature and severity of condition.

Direct Application: Pat off excess with tissue or old towel to help minimize staining of clothing or linens.

Scalp Application: Mix 2 to 3 capfuls with ¼ cup of water. Rub into scalp with fingertips. Apply once a day, preferably before bedtime. A therapeutic shampoo may be used the following morning.

Contraindication: Not indicated when acute inflammation is present.

CAUTION: If irritation persists, discontinue use and consult physician. In rare instances, temporary discoloration of blond, bleached, or tinted hair may occur. In rare cases, Balnetar may cause allergic irritations attributable to coal tar. Keep out of the reach of children. AVOID CONTACT WITH EYES.

PRECAUTION: After use of Balnetar, avoid exposure to sunlight unless otherwise directed by physician. GUARD AGAINST SLIPPING IN BATHTUB. TO AVOID STAINING, DO NOT USE IN FIBER GLASS BATHTUBS.

SUPPLIED: 8 fl. oz. plastic bottles.

Sebutone®

Therapeutic Tar Shampoo

CONTAINS: WESTWOOD® TAR (equivalent to 0.5% Coal Tar U.S.P.) sulfur 2% and salicylic acid 2% in SEBULYTIC® brand of unique penetrating surface-active combination of soapless cleaners and wetting agents.

CAUTION: If undue skin irritation develops or increases, discontinue use and consult physician. In rare instances, temporary discoloration of blond, bleached, or tinted hair may occur. For external use only. Keep out of the reach of children. AVOID CONTACT WITH EYES. IN CASE OF CONTACT, FLUSH EYES WITH WATER.

SUPPLIED: 4 and 8 oz. bottles and Sebutone Cream in 4 oz. tubes.

WESTWOOD
PHARMACEUTICALS INC.
Buffalo, New York 14213
In Canada, Belleville, Ontario K8N 1E2

INDEX TO ADVERTISERS

A

Abbott Laboratories 260-261
Academic Press 382

B

Barnes-Hind Pharmaceuticals ..... 278-279, 3rd Cover

C

Ciba Pharmaceuticals 342-343
Cooper Laboratories, Inc. 366

D

Dermik Laboratories 257, 372
Dista Products Company 265
Doak Pharmacal Company 387
Dorsey Laboratories 367-368

G

General Medical Company 358

I

Ingram Pharmaceutical Company 359
International Light Inc. 270

J

Johnson & Johnson 360-361

L

Lederle Laboratories, Division of
American Cyanamid Company 280-281, 385-386

O

Owen Laboratories, Inc. 259

P

Parke-Davis & Company 358
Person & Covey, Inc. 344
Procter & Gamble Company 275, 341
Purdue Frederick Company 263, 276

R

Remedco Analytical Laboratory 270
Robins, A.H., Company 266-267
Roche Laboratories, Division of
Hoffmann-LaRoche, Inc. 390-391
Roerig, J.B., Company
Division of Pfizer, Inc. 388-389

S

Schering Corporation 271, 382-383
Squibb, E.R., & Sons, Inc. 380-381
Stanford University
School of Medicine 382
Stiefel Laboratories, Inc. 273-274
Syntex Laboratories, Inc. 268-270, 370-371

W

Westwood Pharmaceuticals, Inc. ..... 2nd Cover,
272, 277, 282, 365, 373, 392-394, 4th Cover

While every precaution is taken to insure accuracy, we cannot guarantee against the possibility of an occasional change or omission in the preparation of this index.

Four indications for Komed® HC Acne Lotion

Komed HC reduces inflammation as it keeps skin dry and desquamating with non-comedogenic sodium thiosulfate[1]

1.

When you wish to alternate severe acne medication with acne medication that will reduce erythema and irritation



3.

When you determine that initial use of severe acne medication is not indicated

2.

When severe acne medication has been effective and you want to maintain acne control with minimal irritation



4.

When reducing the inflammation associated with acne vulgaris is an important consideration



Besides its ability to reduce inflammation, patients appreciate the invisibility of Komed HC. It dries rapidly to a transparent film to be worn unseen or used as the base for makeup.

Contraindications Contraindicated for herpes simplex, chickenpox, smallpox, tuberculous ulcers and fungal infections.
Warning Although there have been no reports of topical stercids having adverse effects on pregnant patients, the safety of their use has not been established. Therefore, they should not be used extensively, in large amounts, or for prolonged periods of time during pregnancy.
For acne conditions not requiring the anti-inflammatory effects of hydrocortisone, KOMED lotion or KOMED MILD lotion are recommended.
Precautions If signs of irritation or sensitivity develop, discontinue use. If infections due to bacteria or fungi appear during therapy, appropriate measures should be taken. The anti-inflammatory action of hydrocortisone may mask the presence of infection. Do not use on or about the eyes.
Caution U S. Federal law prohibits dispensing without a prescription.

[1]Mills OH Jr, Kligman AM "Is Sulphur helpful or harmful in acne vulgaris?" Br J Derm 86:620, 1972

"Suspensions and creams containing elemental sulphur were shown to be capable of inducing comedones in the rabbit ear and on human backs."

Komed® HC

(hydrocortisone acetate 0.5%, sodium thiosulfate 8%, salicylic acid 2%)

Barnes Hind Pharmaceuticals, Inc.
895 Kifer Road
Sunnyvale, California 94086

When treating tar-responsive dermatoses...

You'll have to tell your patients it's tar.

NEW estar™
Therapeutic
Tar Gel

The odor won't.

For full product information, see PDR.

WESTWOOD
PHARMACEUTICALS INC.
Buffalo, New York 14213

©1976, W.P. Inc.

15.7.77

Published by the American Medical Association

April 1977

archives of Dermatology

Progesterone Dermatitis . . . 426

Acantholytic Dermatosis . . . 431

Skin Carcinoma After Renal Transplantation . . . 436

Acne Fulminans . . . 444

Hidradenitis Suppurativa . . . 450

Therapy of Mycosis Fungoides . . . 454

Granuloma Annulare . . . 463

Volume 113 Number 4

Complete Contents . . . 396

Phenytoin-Induced Pseudolymphoma . . . 477

Hidrotic Ectodermal Dysplasia . . . 481

Treatment of Port-Wine Stains . . . 504

UNIVERSITY OF MEDICINE LIBRARY

AMA AMERICAN MEDICAL ASSOCIATION

Reservoir of moisture

ach bath with Alpha Keri® Therapeutic Bath Oil is a reservoir of moisture for dry skin. ne addition of Alpha Keri in the bath helps skin store moisture for days. And feel soft, nooth, and supple in minutes. (Between baths, a single application of Keri® Lotion stantly restores moisture to dry skin for hours.)

Alpha Keri®

Therapeutic Bath Oil

helps skin keep in touch with moisture

ee PDR for complete oduct information.

WESTWOOD
HARMACEUTICALS INC.
Buffalo, New York 14213

Four indications for Komed® HC Acne Lotion

Komed HC reduces inflammation as it keeps skin dry and desquamating with non-comedogenic sodium thiosulfate[1]

1.

When you wish to alternate severe acne medication with acne medication that will reduce erythema and irritation



3.

When you determine that initial use of severe acne medication is not indicated

2.

When severe acne medication has been effective and you want to maintain acne control with minimal irritation





4.

When reducing the inflammation associated with acne vulgaris is an important consideration



Besides its ability to reduce inflammation, patients appreciate the invisibility of Komed HC. It dries rapidly to a transparent film to be worn unseen or used as the base for makeup.

Contraindications Contraindicated for herpes simplex, chickenpox, smallpox, tuberculous ulcers and fungal infections.
Warning Although there have been no reports of topical steroids having adverse effects on pregnant patients, the safety of their use has not been established. Therefore, they should not be used extensively, in large amounts, or for prolonged periods of time during pregnancy.
For acne conditions not requiring the anti-inflammatory effects of hydrocortisone, KOMED lotion or KOMED MILD lotion are recommended.
Precautions If signs of irritation or sensitivity develop, discontinue use. If infections due to bacteria or fungi appear during therapy, appropriate measures should be taken. The anti-inflammatory action of hydrocortisone may mask the presence of infection. Do not use on or about the eyes.
Caution U.S. Federal law prohibits dispensing without a prescription.

[1]Mills OH Jr, Kligman AM "Is Sulphur helpful or harmful in acne vulgaris?" Br J Derm 86:620, 1972

"Suspensions and creams containing elemental sulphur were shown to be capable of inducing comedones in the rabbit ear and on human backs."

Komed® HC

(hydrocortisone acetate 0.5%, sodium thiosulfate 8%, salicylic acid 2%)

Barnes Hind Pharmaceuticals, Inc.
895 Kifer Road
Sunnyvale, California 94086

Archives of DERMATOLOGY

Copyright © 1977 by the AMERICAN MEDICAL ASSOCIATION

VOL 113, NO. 4 **APRIL 1977**

EDITORIAL

Should Vitiligo Be Induced in Patients After Resection of Primary Melanoma?
Aaron B. Lerner, MD, James J. Nordlund, MD, New Haven, Conn **421**

ORIGINAL CONTRIBUTIONS

Zinc Correction of Defective Chemotaxis in Acrodermatitis Enteropathica
William L. Weston, MD; J. Clark Huff, MD; James R. Humbert, MD; K. Michael Hambidge, MD; Kenneth H. Neldner, MD; Philip A. Walravens, MD, Denver **422**

Autoimmune Progesterone Dermatitis
Roland Hart, MD, Stanford, Calif **426**

Transient Acantholytic Dermatosis
Marc Chalet, MD, New York; Ralph Grover, MD, East Meadow, NY; A. Bernard Ackerman, MD, New York **431**

Incidence of Skin Carcinoma After Renal Transplantation
Eugene O. Hoxtell, MD; Jack S. Mandel, MPH; Samuel S. Murray; Leonard M. Schuman, MD, MS; Robert W. Goltz, MD, Minneapolis **436**

Curettage-Electrodesiccation Treatment of Basal Cell Carcinomas
Alfred W. Kopf, MD; Robert S. Bart, MD; David Schrager; Mark Lazar; George L. Popkin, MD, New York **439**

Acne Fulminans
Herbert Goldschmidt, MD; James J. Leyden, MD; Kenneth H. Stein, MD, Philadelphia **444**

Host-Defense Mechanisms in Hidradenitis Suppurativa
Vera C. Dvorak, MD; Richard K. Root, MD; Rob Roy MacGregor, MD, Philadelphia **450**

Topical Chemotherapy and Immunotherapy of Mycosis Fungoides
Eric C. Vonderheid, MD; Eugene J. Van Scott, MD; Waine C. Johnson, MD; David A. Grekin, MD; Sucha O. Asbell, MD, Philadelphia **454**

Vasculitis in Granuloma Annulare
Mark V. Dahl, MD; Susanne Ullman, MD; Robert W. Goltz, MD, Minneapolis .. **463**

CASE REPORTS

Thrombocythemia as a Cause of Erythermalgia
Keith G. Redding, MD, Marshfield, Wis **468**

Hidrotic Ectodermal Dysplasia With Diffuse Eccrine Poromatosis
Ralph D. Wilkinson, MD, FRCP(C); Paula Schopflocher, MD, FRCP(C); Maria Rozenfeld, MD, FRCP(C), Montreal **472**

Phenytoin-Induced Pseudolymphoma Syndrome
Maj Ernest N. Charlesworth, MC, USAF, San Antonio, Tex **477**

Hidrotic Ectodermal Dysplasia
Krishna Rajagopalan, MB, MRCP, DDM, Kuala Lumpur, Malaysia, Chong Hai Tay, MB, FRCP, Republic of Singapore **481**

(Continued on page 398)

EDITORIAL BOARD

Chief Editor
John H. Epstein, MD
450 Sutter Street
San Francisco 94108

Assistant Chief Editor
Kimie Fukuyama, MD
San Francisco

Assistant Chief Editor
Denny L. Tuffanelli, MD
San Francisco

Donald C. Abele, MD
Augusta, Ga.

Harry L. Arnold, Jr, MD
Honolulu

Walter C. Lobitz, Jr, MD
Portland, Ore

Frederick D. Malkinson, MD
Chicago

Sigfrid A. Muller, MD
Rochester, Minn

W. Mitchell Sams, Jr, MD
Denver

John S. Strauss, MD
Boston

Morris Waisman, MD
Tampa, Fla

Gerald D. Weinstein, MD
Miami

The cosmetically acceptable infection fighter

NEOSPORIN®G Cream

(polymyxin B-neomycin-gramicidin)

Each gram contains Aerosporin® brand Polymyxin B Sulfate 10,000 units; neomycin sulfate 5 mg (equivalent to 3.5 mg neomycin base); gramicidin 0.25 mg. Inactive ingredients: liquid petrolatum, white petrolatum, purified water, propylene glycol, polyoxyethylene polyoxypropylene compound, emulsifying wax, and 0.25% methylparaben as preservative.

NEOSPORIN®G Cream
(polymyxin B-neomycin-gramicidin)

When topical infection invades hairy areas, facial skin or intertriginous areas, Neosporin®-G Cream provides broad antibacterial coverage. It contains three antibiotics that combat virtually all pathogenic bacteria found topically.*

These antibiotics are seldom used systemically, so the patient is spared the possibility of sensitization to those antibiotics which might later be required systemically.

Smooth vanishing cream base leaves no greasy residue on skin, no stains on fabric.

Wellcome / **Burroughs Wellcome Co.**
Research Triangle Park
North Carolina 27709

*INDICATIONS: Based on a review of this drug by the National Academy of Sciences—National Research Council and/or other information, FDA has classified the indications as follows:

"Possibly" effective: For topical administration for the treatment of the listed localized infections or for suppressive therapy in such conditions: · primary pyodermas (impetigo, ecthyma, sycosis vulgaris, paronychia) · secondary infected dermatoses (eczema, herpes, and seborrheic dermatitis) · traumatic lesions (inflamed or suppurating as a result of bacterial infection).

Final classification of the less-than-effective indications requires further investigation.

CONTRAINDICATIONS: Not for use in the eyes or in the external ear canal if the eardrum is perforated. This product is contraindicated in those individuals who have shown hypersensitivity to any of its components.

WARNING: Because of the potential hazard of nephrotoxicity and ototoxicity due to neomycin, care should be exercised when using this product in treating extensive burns, trophic ulceration and other extensive conditions where absorption of neomycin is possible. In burns where more than 20 percent of the body surface is affected, especially if the patient has impaired renal function or is receiving other aminoglycoside antibiotics concurrently, not more than one application a day is recommended.

When using neomycin-containing products to control secondary infection in the chronic dermatoses, such as chronic otitis externa or stasis dermatitis, it should be borne in mind that the skin in these conditions is more liable than is normal skin to become sensitized to many substances, including neomycin. The manifestation of sensitization to neomycin is usually a low grade reddening with swelling, dry scaling and itching; it may be manifest simply as failure to heal. During long-term use of neomycin-containing products, periodic examination for such signs is advisable and the patient should be told to discontinue the product if they are observed. These symptoms regress quickly on withdrawing the medication. Neomycin-containing applications should be avoided for that patient thereafter.

PRECAUTIONS: As with other antibacterial preparations, prolonged use may result in overgrowth of nonsusceptible organisms, including fungi. Appropriate measures should be taken if this occurs.

ADVERSE REACTIONS: Neomycin is a not uncommon cutaneous sensitizer. Articles in the current literature indicate an increase in the prevalence of persons allergic to neomycin. Ototoxicity and nephrotoxicity have been reported (see Warning section).

HOW SUPPLIED: Tube of 15 g.

Complete literature available on request from Professional Services Dept. PML.

CONTENTS—Continued

Unilateral Nevoid Telangiectasia
Jonathan K. Wilkin, MD, Memphis 486

Secondary Syphilis Presenting as a Pruritic Dermatosis
Gary W. Cole, MD; Robert B. Amon, MD; Paul S. Russell, MD, Portland, Ore .. 489

Giant Melanosomes in Multiple Lentigines Syndrome
Larry W. Weiss, MD, PhD, Alvin S. Zelickson, MD, Minneapolis 491

Depressed Immune Function in Epidermodysplasia Verruciformis
Steven E. Prawer, MD; Franklin Pass, MD; James C. Vance, MD; Leonard J. Greenberg, PhD; Edmond J. Yunis, MD; Alvin S. Zelickson, MD, Minneapolis 495

Eruptive Vellus Hair Cysts
Nancy B. Esterly, MD; David F. Fretzin, MD, Chicago; Hermann Pinkus, MD, Detroit 500

Laser Treatment of Extensive Mixed Cavernous and Port-Wine Stains
Leon Goldman, MD, Ronald Dreffer, Cincinnati 504

REGULAR DEPARTMENTS

Society Transactions 511

Letters to the Editor 518

Cutaneous Polyarteritis Nodosa Liza Antony, MD, Gurdip S. Sidhu, MD, New York . . . **Nonathletic Calcaneal Petechiae** Thomas S. Saunders, MD, Portland, Ore . . . **Lichen Planus and Xanthoma** David Weedon, MB, FRCPA, Ivan Robertson, MB, Brisbane, Australia . . . **Tinea Versicolor** William E. McDaniel, MD, Lexington, Ky . . . **Onycholysis Through Phototoxicity** Manfred S. Rothstein, MD, Durham, NC . . . **An Aqueous Solution?** Harry L. Arnold, Jr, MD, Honolulu . . . **Dermatolipidectomy of Elephantiasis Nostras Verrucosa of the Panniculus** Paul R. Gross, MD; R. Barrett Noone, MD; William D. Jones III, MD, Philadelphia . . . **Report on Levamisole Hydrochloride for Warts** Joseph D. Sutton, MD, Suffern, NY . . . **"The First Report of . . ."** David A. Voron, MD, Arcadia, Calif . . . **Chondrodermatitis Nodularis** Arnold I. Lester, MD, Cincinnati . . . **Penetration of Topical Steroid Preparations** J. A. Carruthers; R. C. D. Staughton; P. J. August, London . . . **Demonstration of Herpes Virus by Electron Microscopy in the Crust of a Healing Lesion of Eczema Herpeticum** Maria Medenica, MD, Thomas Steinberg, MD, Chicago . . . **Allergic Reactions to Chocolate** Claude A. Frazier, MD, Asheville, NC . . . **Viral Hepatitis Type B** Edward M. Moss, MD, Fresno, Calif . . . **Pro and Con of Continuing Education** William E. Laur, MD; Randal E. Posey, MD; Jack D. Waller, MD, Amarillo, Tex

Books 529

News and Notes 532

Index to Advertisers 544

Instructions for Authors ..... see March 1977, p 264

SUBSCRIPTION RATES: The yearly rate of the ARCHIVES OF DERMATOLOGY is as follows: United States and US Possessions, one year, $18; two years, $28; all other countries, one year, $28; two years, $38. Special yearly price to residents, interns and medical students in the United States and US Possessions, $9.

THE ARCHIVES OF DERMATOLOGY is published monthly by the American Medical Association, 535 N Dearborn St, Chicago, IL 60610, and is an official publication of the Association. Second-class postage paid at Chicago and at additional mailing office.

UNIVERSITY OF MEDICINE LIBRARY C. U.

Selsun®
(SELENIUM SULFIDE LOTION, U.S.P.) ℞

Brief Summary

Contains:
Selenium sulfide, 2½%, w/v; bentonite; lauric diethanolamide; ethylene glycol monostearate; titanium dioxide; amphoteric—2; sodium lauryl sulfate; sodium phosphate (monobasic); glyceryl monoricinoleate; citric acid; captan; perfume; and water.

Indications:
For the treatment of dandruff and seborrheic dermatitis of the scalp.

Contraindications:
Should not be used by patients allergic to any of its components.

Warnings:
Safety for use on infants has not been established.

Precautions:
Cutaneous sensitization of the scalp or adjacent areas has been reported; if sensitivity reactions should occur, discontinue use. Chemical conjunctivitis may result if product enters the eyes. Do not use when acute inflammation or exudation is present as an increase in absorption may occur.

Adverse Reactions:
As with other shampoos, oiliness or dryness of the hair and scalp may occur following use; there have been occasional reports of an increase in the amount of normal hair loss. Hair discoloration may occur; can be avoided or minimized by thorough rinsing.

ABBOTT

7033184

Announcing Selsun.

What?

New Selsun®

(SELENIUM SULFIDE LOTION, U.S.P.)



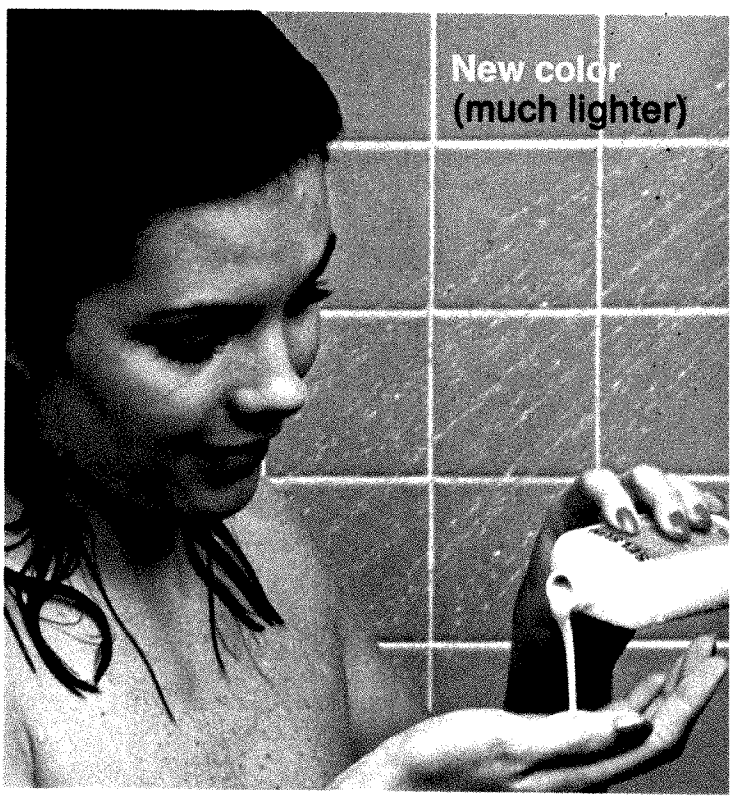

Please see opposite page for Brief Summary.

Archives of Dermatology

James H. Sammons, MD
Executive Vice-President

Thomas F. Hannon
Group Vice-President,
Publishing Operations

William R. Barclay, MD
Group Vice-President,
Scientific Publications

Norman D. Richey
Director, Publication
Production Division

John T. Baker
Director, Marketing Division

Helen R. Mazur
Acting Fulfillment Manager

John T. Baker, General Sales Manager; **Robert Corcoran,** Eastern Sales Manager; **Fred Bauman, Richard M. Johnson,** Eastern Sales Representatives; **William J. Healy,** Midwest Sales Representative; **Thomas J. Carroll,** West Coast/Northern Sales Representative

PUBLICATION STAFF

Offices: 535 N Dearborn St
Chicago, IL 60610

William R. Barclay, MD, Director
Scientific Publications Division

Robert W. Mayo, Executive Editor

Marlene M. Hinsch, Production Manager

Editorial Processing Manager: Diana A. Morgan

Copy Editing: Rosanne Schulenberg (Supervisor), Rae Usinger

Proofreading: Lorraine L. Kruse (Supervisor), Helen Grzeskiewicz, Elizabeth Petrikenas, Patricia Simmers, Dorothy Troy, Dorothy Waier

Production Supervisors: Julia Bero (Layout), Thomas J. Handrigan (Illustrations), Marlene M. Hinsch (Editorial), James P. Bagniewski (Advertising)

Art and Senior Production Assistants: Betty Frigerio, Shirley Latronica, Deborah Orent, Donna Pender, Nancy Keyes, Susan Routhier, JoAnne Weiskopf

Production Assistants: Karen Branham, E. Linda Eisenberg, Anna Goins, Lucille Kuznicki

Manuscript Records: Mary Paino

Indexing: Phyllis H. McLaren (Supervisor), Jane P. Mauldin, Helen F. Topel

Please address communications concerning accepted or published communications to: AMA Specialty Journals, 535 N Dearborn St, Chicago, IL 60610.

Conditions for Acceptance of Color Illustrations

Illustrations in full color are accepted for publication in ARCHIVES OF DERMATOLOGY if the editor believes that color will add significantly to the published manuscript.

When color illustrations are accepted, the American Medical Association will pay part of the expense of reproduction and printing, the remainder to be borne by the author or the institution with which he is affiliated. After deducting AMA's contribution, the author's share is $275 for up to six square finished illustrations. Additional illustrations and special effects, such as outlining, opaquing, or surprinting, will be billed to the author at cost.

Color transparencies must be submitted for evaluation. Do not send color prints unless accompanied by original transparencies. If transparencies are mounted in frames or glass, the material should be carefully packed in gauze and sent with the manuscript in a separate container or between two pieces of pressboard.

Advertising and Subscription Information

ADVERTISING OFFICES: 535 N Dearborn St, Chicago, IL 60610, Area Code 312, 751-6000; and 122 E 42nd St, New York, NY 10017, Area Code 212-867-6640.

ADVERTISING PRINCIPLES: Each advertisement in this issue has been reviewed and complies with the principles governing advertising in AMA scientific publications. A copy of these principles is available on request.

CHANGE OF ADDRESS: Please notify the publisher at least six weeks in advance, including both old and new address, and a mailing label taken from the most recent copy. Include your new zip code number.

Get down to the level of normal skin.

Remove hyperkeratotic build up safely and effectively.

Keralyt® Gel is clear, and easy to apply. Keralyt Gel's mechanism of action is believed to be its ability to dissolve the intracellular material that binds the cells of the stratum corneum, thus aiding the simple, safe removal of excessive hyperkeratotic skin.

Keralyt's keratolytic action is an important preliminary to other topical agents. After the hyperkeratotic barrier is removed, tar, steroids, and other therapy can function with less impediment.

Keralyt® GEL

6% salicylic acid in a gel containing propylene glycol (60%), ethyl alcohol (19.4%), hydroxypropyl cellulose and water.
Please see full prescribing information.

©1977, W.P. Inc.

Available only on your prescription.

Keralyt® GEL

NDC-0072-6500-01

Rx CAUTION: FEDERAL LAW PROHIBITS DISPENSING WITHOUT PRESCRIPTION.

CONTENTS: 6% salicylic acid in a gel containing propylene glycol (60%), ethyl alcohol (19.4%), hydroxypropyl cellulose and water.

ACTION AND USES:
For Dermatological Use: Keralyt is a topical aid in the removal of excessive keratin in hyperkeratotic skin disorders, including the various ichthyoses (vulgaris, sex-linked and lamellar), keratosis palmaris and plantaris, keratosis pilaris, pityriasis rubra pilaris, psoriasis (including body, scalp, and palms and soles). Keralyt has been reported as helpful as adjunctive therapy for fungal infections.

For Podiatric Use: Keralyt is a topical aid in the removal of excessive keratin in dorsal and plantar hyperkeratotic lesions. Keralyt has been reported as helpful as adjunctive therapy for verruca plantaris.

DIRECTIONS FOR USE: The preferable method of use is to apply thoroughly to the affected area and place under occlusion at night. The skin should be hydrated for at least five minutes prior to application. The medication is washed off in the morning, and if excessive drying and/or irritation is observed, a bland cream or lotion may be applied. Once clearing is apparent, the occasional use of Keralyt will usually maintain the remission. In those areas where occlusion is difficult or impossible, application may be made more frequently, and hydration by wet packs or baths prior to application apparently enhances the effect. Unless hands are being treated, rinse hands thoroughly following application.

CONTRAINDICATIONS: Not to be used in patients known to be sensitive to any ingredient of Keralyt.

PRECAUTIONS: In view of the salicylic acid content, use in children under 12 years of age should be limited to no more than one tube (1 oz.) in 24 hours. Avoid contact with eyes and mucous membranes. For external use only. Keep this and all medications out of reach of children.

HOW SUPPLIED: Plastic tubes 1 oz. (24.8 gm.)

WESTWOOD PHARMACEUTICALS INC.
Buffalo, New York 14213

a new potency to provide a different set of benefits

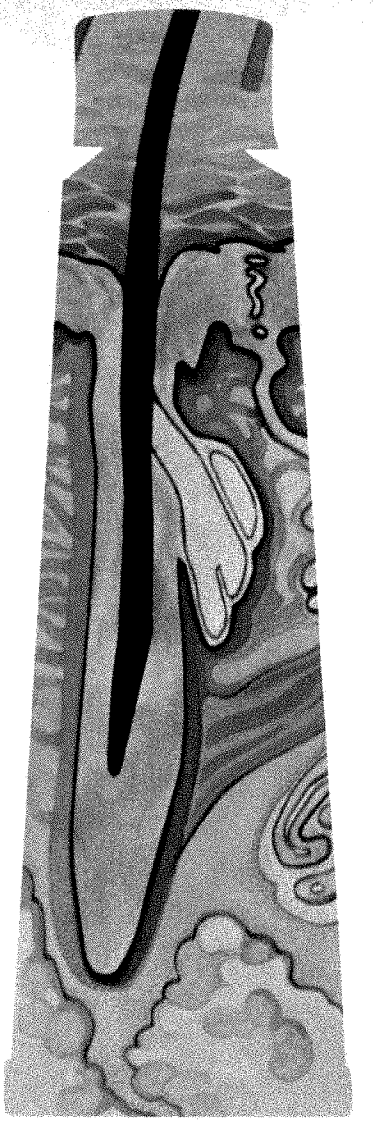

a strength to consider... for treating large skin areas and for use with occlusive dressings

More to it

INDICATIONS: For relief of inflammatory manifestations of corticosteroid-responsive dermatoses.
CONTRAINDICATIONS: Viral skin diseases, such as varicella and vaccinia; hypersensitivity to any component (not for ophthalmic use); when circulation is markedly impaired.
WARNINGS: Safety of use in pregnancy has not been absolutely established. Do not use extensively, in large amounts, or for prolonged periods of time in pregnant patients.
PRECAUTIONS: If irritation develops, discontinue use and institute appropriate therapy. In infections, use appropriate antifungal or antibacterial agents; if a favorable response does not occur promptly, discontinue the corticosteroid until the infection is adequately controlled. If extensive areas are treated or the occlusive technique is used, increased systemic absorption of the corticosteroid may occur; take suitable precautions. *ARISTOCORT A Spray Lotion only:* Take care when using periorbitally, or in the scrotal, vulvar or perineal areas due to a fairly high incidence of burning sensation.
ADVERSE REACTIONS: (local) Burning sensations, itching, irritation, dryness, folliculitis, secondary infection, skin atrophy, striae, hypertrichosis, acneform eruption and hypopigmentation.
SUPPLIED: *Cream 0.5%* — Per Gm.: triamcinolone acetonide 5 mg., sorbic acid 0.1% and potassium sorbate 0.1% as preservatives; *Cream 0.1%* — Per Gm.: triamcinolone acetonide 1 mg., sorbic acid 0.1% and potassium sorbate 0.1% as preservatives; *Cream 0.025%* — Per Gm.: triamcinolone acetonide 0.25 mg., sorbic acid 0.1% and potassium sorbate 0.1% as preservatives; all potencies are in a water base of mono and diglycerides, squalane, polysorbate 80 USP, polysorbate 60, synthetic spermaceti NF, stearyl alcohol USP, Tenox II, and sorbitol solution USP. *Ointment 0.5%* — Per Gm.: triamcinolone acetonide 5 mg.; inactive ingredient: white petrolatum; *Ointment 0.1%* — Per Gm.: triamcinolone acetonide 1 mg.; inactive ingredient: white petrolatum. *ARISTOGEL® Gel 0.1%* — Per Gm.: triamcinolone acetonide 1 mg., 1.8% benzyl alcohol as preservative; inactive ingredients in a water base: polysorbate 80 USP, polyoxyethylene (20) cetyl ether, glycerin USP, and citric acid USP.
ARISTOCORT A CREAM: Each gram of ARISTOCORT A contains 0.25 mg. (0.025%), 1 mg. (0.1%), or 5 mg. (0.5%) of the highly active steroid, Triamcinolone Acetonide (a derivative of triamcinolone) in AQUATAIN, a specially formulated base composed of emulsified wax NF, isopropyl palmitate, glycerin USP, sorbitol solution USP, lactic acid, 2% benzyl alcohol and purified water. AQUATAIN is non-staining, water-washable, paraben-free, spermaceti-free and has a light texture and consistency.
ARISTOCORT A OINTMENT: Each gram of ARISTOCORT A Ointment contains 1 mg. (0.1%) or 5 mg. (0.5%) of the highly active steroid, Triamcinolone Acetonide (a derivative of triamcinolone) in a specially formulated base composed of emulsifying wax NF, white petrolatum, and propylene glycol. In addition, the 0.1% Ointment contains Tenox II and lactic acid.
ARISTOCORT A SPRAY LOTION: Each 15 Gm. pressurized aluminum can contains 2.94 Gm. of a concentrate supplying a minimum of 17 mg. of ARISTOCORT A triamcinolone acetonide; inactive ingredients: alcohol 18.1% and isopropyl myristate; propellants: dichlorodifluoromethane and cryofluorane.

Lederle LEDERLE LABORATORIES,
A Division of American Cyanamid Company,
Pearl River, New York 10965

837-6

AQUATAIN™ Hydrophilic Base... to help overcome problem dryness and keep treatment areas soft and smooth during the healing process.

more economical therapy ... for maintenance of chronic conditions and for widespread lesions

a preferred potency... for starter therapy in many patient types.

than less steroid

Quarter Strength

Aristocort® A

Triamcinolone Acetonide

with AQUATAIN™ Hydrophilic Base

0.025% Cream

Laboratory Services

(On Hair and Other Organic Materials*)

1. Amino Acid Analysis
2. Mechanical Optical Properties
3. Scanning Electron Microscopy
4. Trace Metal Analysis

Lead	Zinc
Arsenic	Copper
Cadmium	Magnesium
Mercury	and many more

5. Transmission Electron Microscopy
6. plus many other capabilities and their...

... **Medical** importance are described in the new **Laboratory Handbook.**

Yours for the asking from

**including blood and urine*

P.S.
Call Toll Free
(800) 423-3062
In California
Call Collect
(213) 781-4934

REMEDCO
ANALYTICAL LABORATORY
HEW Lic. #04-1156
14721 Califa Street, Van Nuys, CA 91411



U.V. PHOTOTHERAPY RADIOMETER for PHOTOCHEMOTHERAPY of PSORIASIS

Features:

- Direct readout in milliwatts/cm².
- Spectral response to match the photosensitization of skin.
- Sensitivity from 0.3 to 100 milliwatts/cm², full scale.
- Wide field of view to match the cosine receiving function of human skin.
- Small, rugged and battery operated for full portability and safety.
- L.E.D. battery status indicator lamp.
- Silicon photodiode detector for maximum stability..

Write Dept. A

international light INC.
Specialists in Light Measurement
DEXTER INDUSTRIAL GREEN
NEWBURYPORT, MA. 01950 617 465 5923

Vanoxide® Acne Lotion and Loroxide® Acne Lotion

Description: Vanoxide Acne Lotion contains (as dispensed) benzoyl peroxide 5% and chlorhydroxyquinoline 0.25%, incorporated in a water washable lotion.

Loroxide Acne Lotion contains (as dispensed) benzoyl peroxide 5.5%, and chlorhydroxyquinoline 0.25%, incorporated in a water washable lotion, with "Dermik Color Blender" supplied separately.

How Supplied: Vanoxide—Bottles, 25 and 50 grams; Loroxide—Bottles, 25 grams

Vanoxide-HC® and Loroxide-HC® Lotions

Description: Vanoxide-HC Lotion contains (as dispensed) hydrocortisone 0.5%, benzoyl peroxide 5.0% and chlorhydroxyquinoline 0.25%, incorporated in a water washable lotion containing purified water, propylene glycol, hydroxyethylcellulose, FD&C color, cholesterol-sterol, cetyl alcohol, propylene glycol stearate, polysorbate 20, lanolin alcohol, propylparaben, decyl oleate, purcelline oil syn., antioxidants, vegetable oil, methylparaben, tetrasodium EDTA, buffers, cyclohexanediamine tetraacetic acid, calcium phosphate, silicone emulsion, and silica.

Loroxide-HC Lotion contains (as dispensed) hydrocortisone 0.5%, benzoyl peroxide 5.5% and chlorhydroxyquinoline 0.25%, incorporated in a water washable lotion containing purified water, propylene glycol, hydroxyethylcellulose, caramel color, cholesterol-sterol, cetyl alcohol, propylene glycol stearate, polysorbate 20, lanolin alcohol, propylparaben, decyl oleate, purcelline oil syn., antioxidants, vegetable oil, methylparaben, tetrasodium EDTA, pH buffers, cyclohexanediamine tetraacetic acid, calcium phosphate, silicone emulsion, silica, kaolin, talc and titanium dioxide, with "Dermik Color Blender" supplied separately.

Actions: Provides keratolytic, peeling and drying action.

Indications: An aid in the treatment of acne and oily skin.

Contraindications: Contraindicated for patients having known hypersensitivity to hydrocortisone, benzoyl peroxide, chlorhydroxyquinoline or any other component of this preparation. Topical steroids are contraindicated in viral diseases of the skin, such as varicella and vaccinia.

Warning—Usage in Pregnancy: Safety of use of topical steroids during pregnancy has not been absolutely established. Therefore, they should not be used extensively, or in large amounts or for prolonged periods of time on pregnant patients.

Precautions: For external use only. Keep away from eyes. Discontinue use if irritation develops. Use of appropriate antifungal or antibacterial agents should be instituted in presence of infection. If a favorable response does not occur promptly, the corticosteroid should be discontinued until the infection has been adequately controlled. If extensive areas are treated, or if the occlusive technique is used, the possibility exists of increased systemic absorption of the corticosteroid and suitable precautions should be taken. Observe patients carefully for possible local irritation or sensitization during long-term topical therapy. Apply with caution on neck and/or other sensitive areas. There may be a slight, transitory stinging or burning sensation on initial application which invariably disappears on continued use. Ultraviolet and cold quartz light should be employed in lesser amounts, as this lotion is keratolytic and drying. Harsh, abrasive cleansers should not be used simultaneously with this lotion. Colored or dyed garments may be bleached by the oxidizing action of benzoyl peroxide. Chlorhydroxyquinoline may cause temporary light-yellowish skin staining in rare cases. Keep out of the reach of children.

Adverse Reactions: Local adverse reactions reported with topical corticosteroids: burning sensations, itching, irritation, dryness, folliculitis, secondary infection, skin atrophy, striae, hypertrichosis, acneiform eruptions, and hypopigmentation. The sensitizing potential of benzoyl peroxide and chlorhydroxyquinoline are low; but they can produce allergic reaction. Reduce amount and frequency of application if excessive redness or peeling occurs.

How Supplied: Bottles, 25 grams.

Caution: Federal law prohibits dispensing without prescription.

5-Benzagel® and 10-Benzagel® Acne Gels

Description: 5% or 10% benzoyl peroxide, 6% polyoxyethylene lauryl ether and 40% alcohol in an astringent gel containing colloidal magnesium aluminum silicate, hydroxypropyl methylcellulose, citric acid, fragrance, and purified water.

Action: Provides drying, desquamative and antiseptic activity.

Indication: An aid in the treatment of acne.

Dosage and Administration: Wash affected areas prior to application. Apply once or more daily or as directed by physician.

Contraindications: Should not be used by patients having known sensitivity to either benzoyl peroxide or polyoxyethylene lauryl ether.

Precautions: For External Use Only. Not for ophthalmic use. Keep away from eyes and mucosae. Very fair individuals should begin with a single application at bedtime allowing overnight medication. May bleach colored fabrics. Keep this and all other medications out of the reach of children.

Caution: Federal law prohibits dispensing without prescription.

How Supplied: Plastic tubes, 1½ oz. and 3 oz.

Dermik

DERMIK LABORATORIES, INC.
Fort Washington, Pa., U.S.A. 19034

Now!...a full family of products for intensive acne care from

Dermik

originator and leader in Benzoyl Peroxide Acne Therapy at practical patient cost

...for Benzoyl Peroxide Acne Therapy with superior, penetrating, antibacterial action...

INVISIBLE

- Vanoxide® and Vanoxide-HC® are indicated for severe, recalcitrant, oily acne.

FLESH-TINTED

- Loroxide® and Loroxide-HC® are the only tinted benzoyl peroxide products available, and they can be used as a daily make-up. These products provide the same formulation and therapeutic benefits as Vanoxide and Vanoxide-HC.
- Chlorhydroxyquinoline—benzoyl peroxide lotions provide substantially greater action than benzoyl peroxide alone. It is topical acne medication with proven ability to reduce C. acnes within the pilosebaceous structures.

For Benzoyl Peroxide Therapy in acne where maximal drying effect is desired...

- 5 Benzagel® and 10 Benzagel® contain 5% or 10% benzoyl peroxide, 6% polyoxyethylene lauryl ether and 40% alcohol in an astringent, colloidal magnesium aluminum silicate gel vehicle.
- This combination provides superior drying action and achieves dramatic improvement in comedone and papular stages of acne ... WITHOUT EXCESSIVE ERYTHEMA OR IRRITATION.

The seven most important reasons to prescribe a topical antifungal. Right at your fingertips.

1 It is effective against the most prevalent fungal pathogens. MicaTin brand miconazole nitrate 2% offers exceptional effectiveness against the most difficult-to-treat pathogen—*Trichophyton rubrum*, and is equally effective against *Trichophyton mentagrophytes, Epidermophyton floccosum, Candida albicans* and *Malassezia furfur.*

2 It clears the most common fungal infections. MicaTin provides outstanding clinical and mycological efficacy in tinea pedis,* tinea corporis* and tinea cruris* as well as candidiasis and tinea versicolor.

3 It relieves symptoms quickly. Within 72 hours for the majority of patients. Within 1 to 2 weeks for virtually all patients.

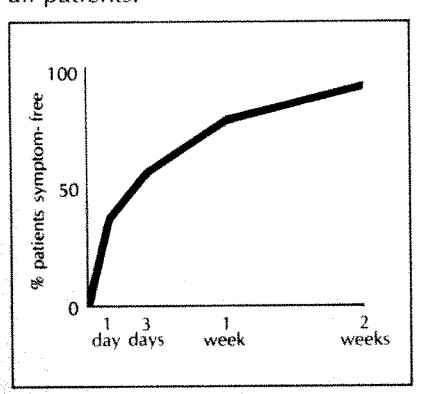

4 It demonstrates effectiveness in extensive studies. Clinical studies† demonstrate the outstanding success rate of MicaTin in the treatment of tinea pedis, tinea corporis and tinea cruris, when used with the recommended dosage of twice daily for one month. At the end of therapy, 88—94% of the patients were clinically clear.

The clinical studies of patients with candidiasis and tinea versicolor are equally impressive. Nine out of ten patients with candidiasis or tinea versicolor were clinically and mycologically clear within two weeks—the recommended duration of treatment.

Pathogen	Infection	Conversion KOH	Culture	Clinical Clearance or Improvement
Trichophyton rubrum	Tinea pedis	82%	86%	88%
Trichophyton mentagrophytes / *Epidermophyton floccosum*	Tinea corporis / Tinea cruris	93%	90%	94%
Candida albicans	Candidiasis†	92%	86%	88%
Malassezia furfur	Tinea versicolor	89%	—	92%

5 Its low relapse rate promises an outstanding chance of cure. To prove how effective MicaTin really is in keeping fungal infections clear, we evaluated these same patients one month later (median).† Of the 121 patients who were clear of tinea pedis, tinea corporis and tinea cruris at the end of treatment *and* were available for follow-up, 92% showed no clinical or mycological recurrence of the original infection.

And of the 34 patients cleared of cutaneous candidiasis *and* available for follow-up, 91% were still clear two weeks later (median).

6 It has a low incidence of side effects. Reports of "burning" sensation, irritation and maceration with MicaTin have been few and isolated. Naturally, it should not be used in patients with known hypersensitivity to any of its ingredients.

7 It is economically priced. The retail price of MicaTin is usually lower than that of other prescription antifungals.

Introducing new
MicaTin Lotion
brand miconazole nitrate 2%
12 ml. and 30 ml. bottles
MicaTin cream
brand miconazole nitrate 2%
new 85 g. (3 oz.) tube
and familiar 1 oz. and 15 g. sizes

Description: MicaTin brand miconazole nitrate cream 2% and lotion 2% each contain miconazole nitrate‡ 2%, formulated into a water miscible base consisting of pegoxol 7 stearate, peglicol 5 oleate, mineral oil, benzoic acid, and butylated hydroxyanisole.

Actions: Miconazole nitrate is a synthetic antifungal agent which inhibits the growth of the common dermatophytes, *Trichophyton rubrum, Trichophyton mentagrophytes,* and *Epidermophyton floccosum,* the yeast-like fungus, *Candida albicans,* and the organism responsible for tinea versicolor (*Malassezia furfur*).

Indications: For topical application in the treatment of tinea pedis (athlete's foot), tinea cruris, and tinea corporis caused by *Trichophyton rubrum, Trichophyton mentagrophytes,* and *Epidermophyton floccosum,* in the treatment of cutaneous candidiasis (moniliasis), and in the treatment of tinea versicolor.

Contraindications: MicaTin has no known contraindications.

Precautions: If a reaction suggesting sensitivity or chemical irritation should occur, use of the medication should be discontinued.

For external use only. Avoid introduction of MicaTin brand miconazole nitrate cream 2% and lotion 2% into the eyes.

Adverse Reactions: There have been isolated reports of irritation, burning, and maceration associated with application of MicaTin.

Dosage and Administration: Sufficient MicaTin cream should be applied to cover affected areas twice daily (morning and evening) in patients with tinea pedis, tinea cruris, tinea corporis, and cutaneous candidiasis and once daily in patients with tinea versicolor. It is preferable to use MicaTin lotion in intertriginous areas; if the cream is used, it should be applied sparingly and smoothed in well to avoid maceration effects.

Early relief of pruritus (first week) and early clinical improvement (one to two weeks) have been seen in treatment of infections caused by common dermatophytes. Even though clinical improvement may be seen fairly soon after treatment is begun, *Candida* infections should be treated for two weeks and dermatophyte infections for one month in order to reduce the possibility of recurrence. If a patient shows no clinical improvement after a month of treatment, the diagnosis should be redetermined. Patients with tinea versicolor usually exhibit clinical and mycological clearing after two weeks of treatment.

How Supplied: MicaTin brand cream 2% containing miconazole nitrate at 2% strength is supplied in 1 oz., 15 g., and 3 oz. tubes. MicaTin brand lotion 2% containing miconazole nitrate at 2% strength is supplied in polyethylene squeeze bottles in quantities of 12 and 30 ml.

*When infecting organisms are *Trichophyton rubrum, Trichophyton mentagrophytes* and *Epidermophyton floccosum.*

†Data for tinea pedis is based on 4 weeks' therapy in 138 patients; for tinea cruris and tinea corporis—4 weeks' therapy in 50 patients; for tinea versicolor—2 weeks' therapy in 38 patients; for candidiasis—2 weeks' therapy in 23 patients and 4 weeks' therapy in 20 patients. (There was no significant difference in effectiveness between the two candidiasis groups.) Data on file, Dermatological Division, Johnson & Johnson.

‡Chemical name: 1-[2,4-dichloro-β-{(2,4-dichlorobenzyl) oxy} phenethyl] imidazole mononitrate.

An ethical specific from the Dermatological Division of

Johnson & Johnson

New Brunswick, New Jersey 08903

© Johnson & Johnson 1977

Cream/
Lotion

MicaTin

BRAND

miconazole nitrate 2%

It all adds up to confidence.

what's best for the care of dry, or premature aging or wrinkled skin... DUE TO EPIDERMAL DEHYDRATION?

UPPLIED: 2 OZ. TUBES

WRITE FOR SAMPLES

DOAK PHARMACAL CO., INC. WESTBURY, N.Y. 115

DISTRIBUTOR IN CANADA

TRANS-CANADA DERMAPEUTICS LTD. MONTREAL 23, QUEBE

wash it. dry it. peel it.

Fostex,® the flexible therapeutic acne wash that degreases, dries, and peels. Easily integrated with all topical or systemic therapy for acne Grades I, II, and III. Convenient and economical Fostex Liquid and Cream are also effective anti-seborrheic shampoos for oily scalps associated with acne. Available as Fostex Cream in 4½ oz. jars, Fostex Cake in 3¾ oz. bars, and Fostex Liquid in 5 oz. plastic bottles.

Fostril,® the flesh-tinted drying and peeling lotion that conceals as it heals. Adaptable to Grades I, II, or III acne, Fostril is available in 1 oz. plastic tubes.

Transact,® the transparent medicated acne gel. A thin film of Transact will dry the oiliest of skin and is ideal for acne on chest, shoulders, and back. Greaseless, nonstaining, with a fresh clean fragrance. In 1 oz. plastic tubes.

WESTWOOD
PHARMACEUTICALS INC
Buffalo, New York 14213
In Canada, Belleville, Ontario K8N 1E2

Pleasingly Superior

DHS* TAR SHAMPOO

pleasant tar scent

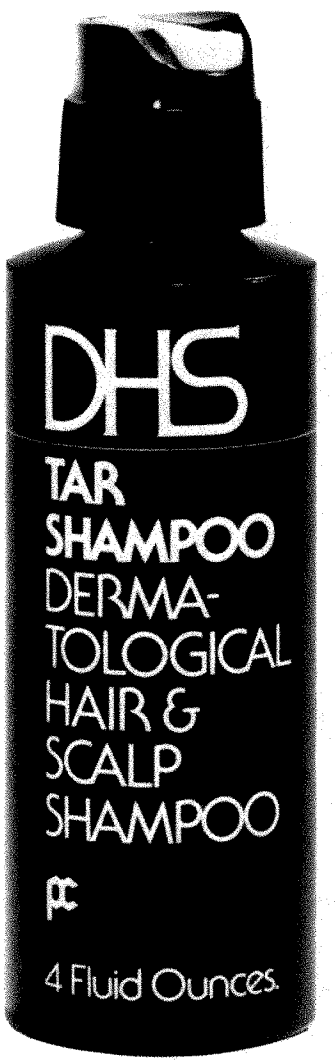

no lingering tar odor

Special cleansing agents of DHS* Shampoo combine with tar to remove excess oil and scales in seborrhea (dandruff) and psoriasis of the scalp.

Write for information and samples.

Available in Canada.

PERSŌN & COVEY INC.
616 ALLEN AVENUE
GLENDALE, CA 91201

*TM

CUT THE GRISEOFULVIN DOSE IN HALF

Gris-PEG®
(griseofulvin ultramicrosize)
Tablets 125 mg

For fungal infections sensitive to griseofulvin

- Only half the dose required*
- Absorption nearly complete without fatty meals
- Once-a-day or b.i.d. dosage
- Reduced cost for patients

*250 mg of Gris-PEG® provides plasma levels equivalent to those obtained with 500 mg microsize griseofulvin. This improved absorption permits the oral intake of half as much griseofulvin but there is no evidence, at this time, that this confers any clinical difference in regard to safety or efficacy.



Dorsey LABORATORIES
Division of Sandoz, Inc.
LINCOLN, NEBRASKA 68501

Please see other side for full prescribing information.

Gris-PEG®
(griseofulvin ultramicrosize) Tablets 125 mg
The ½ dose griseofulvin.

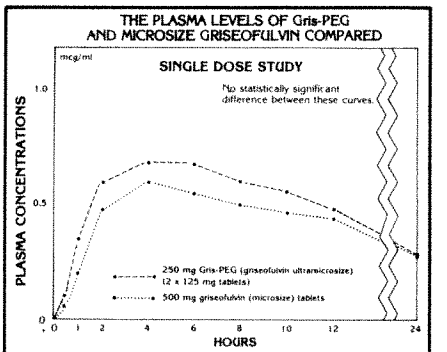

Based on a single dose double-blind bioavailability study conducted in 24 human volunteers comparing the average griseofulvin (microsize) and Gris-PEG plasma levels. There is no significant difference between peak plasma levels, times to peak, and areas under the curve. Gas chromatographic assay.

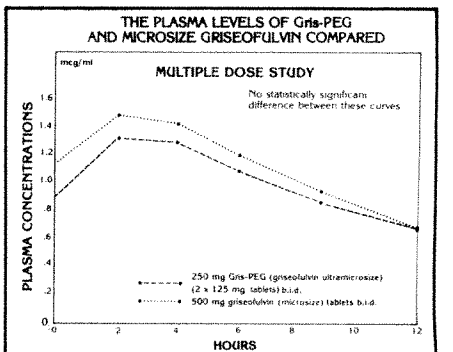

Based on a double-blind multiple dose steady state crossover bioavailability study conducted in 17 human volunteers comparing the average griseofulvin (microsize) and Gris-PEG plasma levels obtained on days 9, 11 and 13. There is no significant difference between times to peak, peak plasma levels, and areas under the curve. Gas chromatographic assay.

DESCRIPTION

Griseofulvin is an antibiotic derived from a species of *Penicillium*.

Gris-PEG is an ultramicrocrystalline solid-state dispersion of griseofulvin in polyethylene glycol 6000.

Gris-PEG tablets differ from griseofulvin (microsize) tablets USP in that each tablet contains 125 mg of ultramicrosize griseofulvin biologically equivalent to 250 mg of microsize griseofulvin.

ACTION

Microbiology: Griseofulvin is fungistatic with *in vitro* activity against various species of *Microsporum, Epidermophyton* and *Trichophyton*. It has no effect on bacteria or other genera of fungi.

Human Pharmacology: The peak plasma level found in fasting adults given 0.25 g of Gris-PEG occurs at about four hours and ranges between 0.37 to 1.6 mcg/ml.

Comparable studies with microsize griseofulvin indicated that the peak plasma level found in fasting adults given 0.5 g occurs at about four hours and ranges between 0.44 to 1.2 mcg/ml.

Thus, the efficiency of gastrointestinal absorption of the ultramicrocrystalline formulation of Gris-PEG is approximately twice that of conventional microsized griseofulvin. This factor permits the oral intake of half as much griseofulvin per tablet but there is no evidence, at this time, that this confers any significant clinical differences in regard to safety and efficacy.

Griseofulvin is deposited in the keratin precursor cells and has a greater affinity for diseased tissue. The drug is tightly bound to the new keratin which becomes highly resistant to fungal invasions.

INDICATIONS

Gris-PEG (griseofulvin ultramicrosize) is indicated for the treatment of the following ringworm infections.

Tinea corporis (ringworm of the body)
Tinea pedis (athlete's foot)
Tinea cruris (ringworm of the thigh)
Tinea barbae (barber's itch)
Tinea capitis (ringworm of the scalp)
Tinea unguium (onychomycosis; ringworm of the nails)

when caused by one or more of the following genera of fungi:

Trichophyton rubrum
Trichophyton tonsurans
Trichophyton mentagrophytes
Trichophyton interdigitalis
Trichophyton verrucosum
Trichophyton megnini
Trichophyton gallinae
Trichophyton crateriform
Trichophyton sulphureum
Trichophyton schoenleini
Microsporum audouini
Microsporum canis
Microsporum gypseum
Epidermophyton floccosum

NOTE: Prior to therapy, the type of fungi responsible for the infection should be identified.

The use of the drug is not justified in minor or trivial infections which will respond to topical agents alone.

Griseofulvin is *not* effective in the following:

Bacterial infections
Candidiasis (Moniliasis)
Histoplasmosis
Actinomycosis
Sporotrichosis
Chromoblastomycosis
Coccidioidomycosis
North American Blastomycosis
Cryptococcosis (Torulosis)
Tinea versicolor
Nocardiosis

CONTRAINDICATIONS

This drug is contraindicated in patients with porphyria, hepatocellular failure, and in individuals with a history of sensitivity to griseofulvin.

WARNINGS

Prophylactic Usage: Safety and Efficacy of Griseofulvin for Prophylaxis of Fungal Infections Has Not Been Established.

Animal Toxicology: Chronic feeding of griseofulvin, at levels ranging from 0.5-2.5% of the diet, resulted in the development of liver tumors in several strains of mice, particularly in males. Smaller particle sizes result in an enhanced effect. Lower oral dosage levels have not been tested. Subcutaneous administration of relatively small doses of griseofulvin, once a week, during the first three weeks of life has also been reported to induce hepatomata in mice. Although studies in other animal species have not yielded evidence of tumorigenicity, these studies were not of adequate design to form a basis for conclusions in this regard.

In subacute toxicity studies, orally administered griseofulvin produced hepatocellular necrosis in mice, but this has not been seen in other species. Disturbances in porphyrin metabolism have been reported in griseofulvin treated laboratory animals. Griseofulvin has been reported to have a colchicine-like effect on mitosis and cocarcinogenicity with methylcholanthrene in cutaneous tumor induction in laboratory animals.

Usage in Pregnancy: The safety of this drug during pregnancy has not been established.

Animal Reproduction Studies: It has been reported in the literature that griseofulvin was found to be embryotoxic and teratogenic on oral administration to pregnant rats. Pups with abnormalities have been reported in the litters of a few bitches treated with griseofulvin. Additional animal reproduction studies are in progress.

Suppression of spermatogenesis has been reported to occur in rats, but investigation in man failed to confirm this.

PRECAUTIONS

Patients on prolonged therapy with any potent medication should be under close observation. Periodic monitoring of organ system function, including renal, hepatic and hematopoietic, should be done.

Since griseofulvin is derived from species of *Penicillium*, the possibility of cross sensitivity with penicillin exists; however, known penicillin-sensitive patients have been treated without difficulty.

Since a photosensitivity reaction is occasionally associated with griseofulvin therapy, patients should be warned to avoid exposure to intense natural or artificial sunlight. Should a photosensitivity reaction occur, lupus erythematosus may be aggravated.

Griseofulvin decreases the activity of warfarin-type anticoagulants so that patients receiving these drugs concomitantly may require dosage adjustment of the anticoagulant during and after griseofulvin therapy.

Barbiturates usually depress griseofulvin activity and concomitant administration may require a dosage adjustment of the antifungal agent.

ADVERSE REACTIONS

When adverse reactions occur, they are most commonly of the hypersensitivity type such as skin rashes, urticaria, and rarely, angioneurotic edema, and may necessitate withdrawal of therapy and appropriate countermeasures. Paresthesias of the hands and feet have been reported rarely after extended therapy. Other side effects reported occasionally are oral thrush, nausea, vomiting, epigastric distress, diarrhea, headache, fatigue, dizziness, insomnia, mental confusion and impairment of performance of routine activities.

Proteinuria and leukopenia have been reported rarely. Administration of the drug should be discontinued if granulocytopenia occurs.

When rare, serious reactions occur with griseofulvin, they are usually associated with high dosages, long periods of therapy, or both.

DOSAGE AND ADMINISTRATION

Accurate diagnosis of the infecting organism is essential. Identification should be made either by direct microscopic examination of a mounting of infected tissue in a solution of potassium hydroxide or by culture on an appropriate medium.

Medication must be continued until the infecting organism is completely eradicated as indicated by appropriate clinical or laboratory examination. Representative treatment periods are – *tinea capitis*, 4 to 6 weeks; *tinea corporis*, 2 to 4 weeks; *tinea pedis*, 4 to 8 weeks; *tinea unguium* – depending on rate of growth – fingernails, at least 4 months; toenails, at least 6 months.

General measures in regard to hygiene should be observed to control sources of infection or reinfection. Concomitant use of appropriate topical agents is usually required particularly in treatment of *tinea pedis*. In some forms of athlete's foot, yeasts and bacteria may be involved as well as fungi. Griseofulvin will not eradicate the bacterial or monilial infection.

An oral dose of 250 mg of Gris-PEG (griseofulvin ultramicrosize) is biologically equivalent to 500 mg of griseofulvin (microsized). USP (see ACTION Human Pharmacology).

Adults: A daily dose of 250 mg will give a satisfactory response in most patients with *tinea corporis, tinea cruris* and *tinea capitis*. One 125 mg tablet twice per day or two 125 mg tablets once per day is the usual dosage. For those fungal infections more difficult to eradicate such as *tinea pedis* and *tinea unguium*, a divided daily dose of 500 mg is recommended. In all cases, the dosage should be individualized.

Children: Approximately 5 mg per kilogram (2.5 mg per pound) of body weight per day is an effective dose for most children. On this basis, the following dosage schedule for children is suggested:

Children weighing over 25 kilograms (approximately 50 pounds) – 125 mg to 250 mg daily.

Children weighing 15-25 kilograms (approximately 30-50 pounds) – 62.5 mg to 125 mg daily.

Children 2 years of age and younger – dosage has not been established.

Dosage should be individualized, as is done for adults. Clinical experience with griseofulvin in children with *tinea capitis* indicates that a single daily dose is effective. Clinical relapse will occur if the medication is not continued until the infecting organism is eradicated.

HOW SUPPLIED

Gris-PEG (griseofulvin ultramicrosize) Tablets (white) differ from griseofulvin (microsize) tablets (USP) in that each tablet contains 125 mg of ultramicrosize griseofulvin biologically equivalent to 250 mg of microsized griseofulvin. Two 125 mg tablets of Gris-PEG are biologically equivalent to 500 mg of microsized griseofulvin. In bottles of 100 and 500 scored, film-coated tablets.

Dorsey LABORATORIES
Division of Sandoz, Inc. • LINCOLN, NEBRASKA 68501

O- -YB

ECLIPSE®

(3% glyceryl PABA and 3% octyl dimethyl PABA)

For your patients

who can't-or won't-stay out of the sun.

For some, it's occupation. For others, the social desirability of a tan. Whatever the reason, many of your patients may be spending more time in the sun than you'd like.

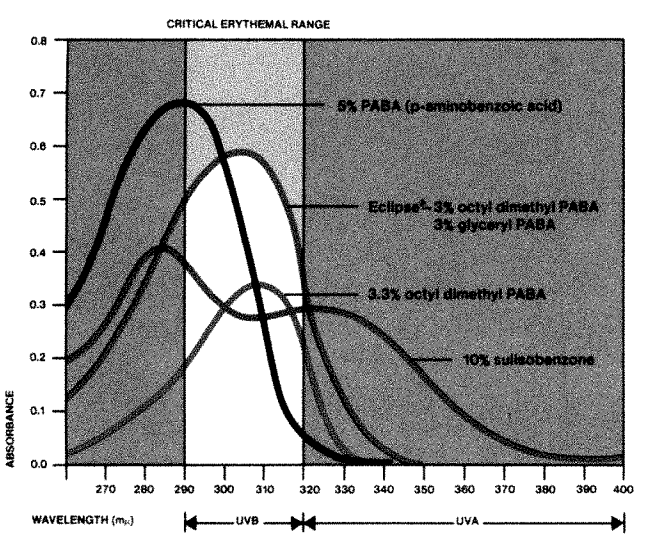

Unique Eclipse formulation combines two PABA derivatives for maximum UVB absorption.

They need Eclipse—a highly effective sunscreen that works immediately upon application, resists wash-off, and contains our exclusive Aquacare® base to help relieve sun and wind-dried skin.

Can other sunscreens do all that? Take a minute to read the labels: we're confident you'll recommend Eclipse.

- Absorbs more than 99% of erythemogenic solar UVB.
- Spreads smoothly and predictably for even protection.
- Permits slow tanning.
- Resists wash-off; protects after swimming or sweating.
- Formulated in Aquacare® to relieve sun and wind-dried skin.



Herbert Laboratories
Dermatology Division of
Allergan Pharmaceuticals
Irvine, CA 92713 U.S.A.

Ways to help allergy patients avoid "a bad day at the office"

Your allergy patients who are office workers may spend a quarter of their adult life in a hostile environment — from an allergen standpoint. Here are suggestions that might, with the help of an understanding employer, lessen the allergic burden.

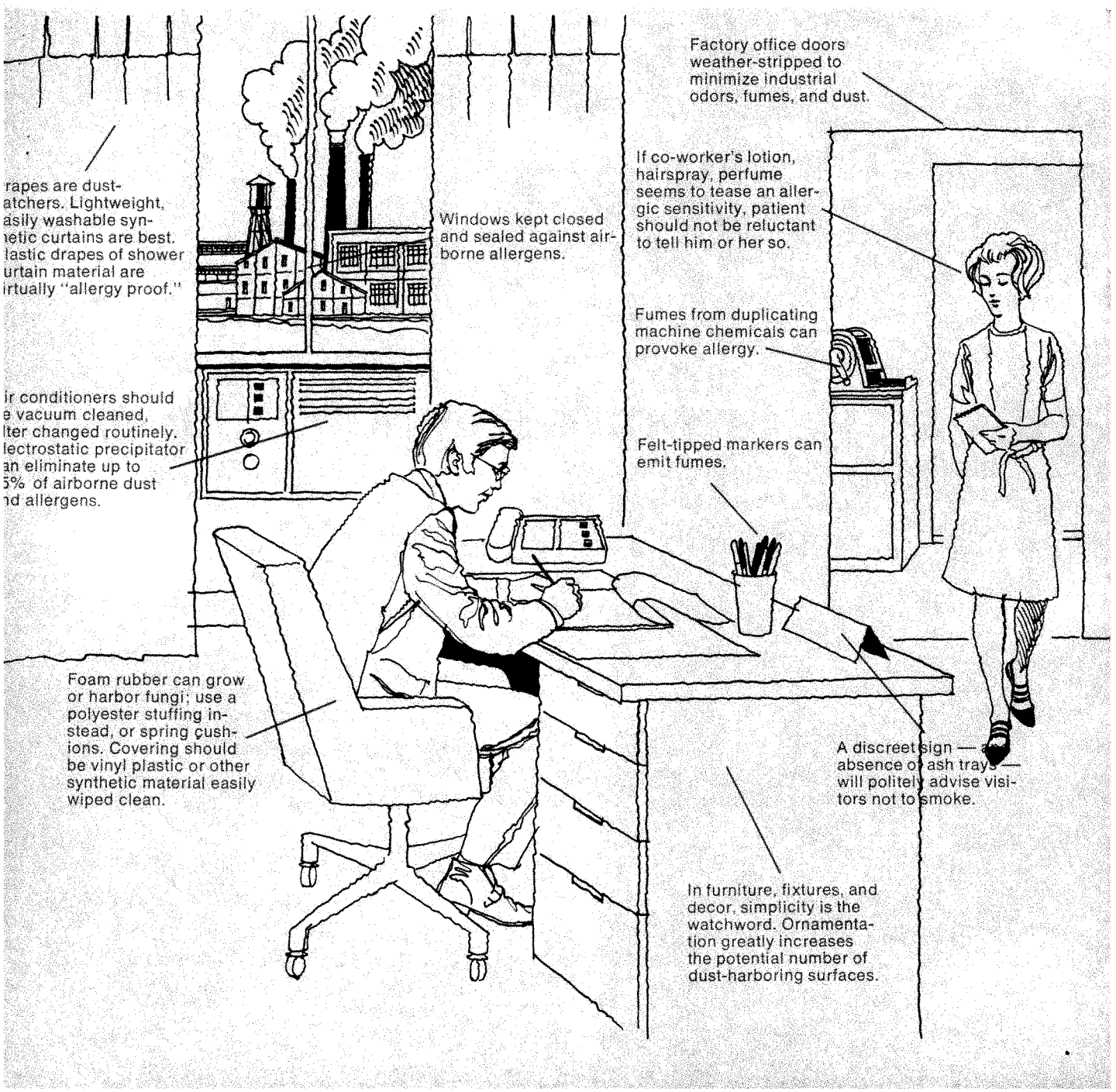

All measures to minimize exposure can be helpful. Still, allergic symptoms may occur and an antihistamine will be needed to bring these reactions under control. Dimetane Extentabs keep working for 10-12 hours, are economical, and are likely to produce good results in stubborn as well as routine cases, usually without drowsiness or overstimulation.

DIMETANE Extentabs®

(BROMPHENIRAMINE MALEATE, NF 8 mg. and 12 mg.)

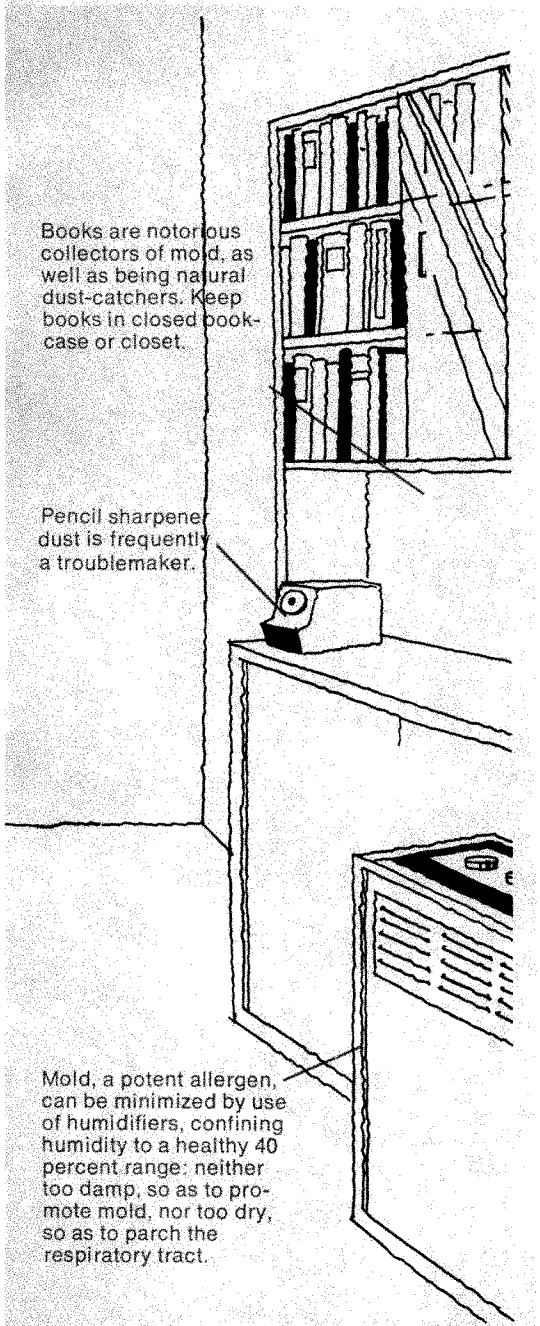

Indications: Perennial and seasonal allergic rhinitis; vasomotor rhinitis; allergic conjunctivitis due to inhalant allergens and foods; mild, uncomplicated allergic skin manifestations of urticaria and angioedema; amelioration of allergic reactions to blood or plasma; dermatographism; as therapy for anaphylactic reactions *adjunctive* to epinephrine and other standard measures after the acute manifestations have been controlled. **Contraindications:** *Use in Newborn or Premature Infants.* This drug should **not** be used in newborn or premature infants. *Use in Nursing Mothers.* Because of the higher risk of antihistamines for infants generally and for newborns and prematures in particular, antihistamine therapy is contraindicated in nursing mothers. *Use in Lower Respiratory Disease.* Antihistamines should NOT be used to treat lower respiratory tract symptoms including asthma. Antihistamines are also contraindicated in the following conditions: hypersensitivity to brompheniramine maleate and other antihistamines of similar chemical structure; monoamine oxidase inhibitor therapy (see Drug Interaction section). **Warnings:** Antihistamines should be used with considerable caution in patients with: narrow angle glaucoma; stenosing peptic ulcer; pyloroduodenal obstruction; symptomatic prostatic hypertrophy; bladder neck obstruction. *Use in Children.* In infants and children, especially, antihistamines in **overdosage** may cause hallucinations, convulsions, or death. As in adults, antihistamines may diminish mental alertness in children. In the young child, particularly, they may produce excitation. *Use in Pregnancy.* Experience with this drug in pregnant women is inadequate to determine whether there exists a potential for harm to the developing fetus. *Use with CNS Depressants.* Dimetane has additive effects with alcohol and other CNS depressants (hypnotics, sedatives, tranquilizers, etc.). *Use in Activities Requiring Mental Alertness.* Patients should be warned about engaging in activities requiring mental alertness, such as driving a car or operating appliances, machinery, etc. *Use in the Elderly (approximately 60 years or older).* Antihistamines are more likely to cause dizziness, sedation, and hypotension in elderly patients. **Precautions:** As with other antihistamines, Dimetane has an atropine-like action and, therefore, should be used with caution in patients with: history of bronchial asthma; increased intraocular pressure; hyperthyroidism; cardiovascular disease; hypertension. **Drug Interactions:** MAO inhibitors prolong and intensify the anticholinergic (drying) effects of antihistamines. **Adverse Reactions:** The most frequent adverse reactions are italicized: *General:* Urticaria, drug rash, anaphylactic shock, photosensitivity, excessive perspiration, chills, dryness of mouth, nose, and throat. *Cardiovascular System:* Hypotension, headache, palpitations, tachycardia, extrasystoles. *Hematologic System:* Hemolytic anemia, thrombocytopenia, agranulocytosis. *Nervous System: Sedation, sleepiness, dizziness, disturbed coordination,* fatigue, confusion, restlessness, excitation, nervousness, tremor, irritability, insomnia, euphoria, paresthesias, blurred vision, diplopia, vertigo, tinnitus, acute labyrinthitis, hysteria, neuritis, convulsions. *G.I. System: Epigastric distress,* anorexia, nausea, vomiting, diarrhea, constipation. *G.U. System:* Urinary frequency, difficult urination, urinary retention, early menses. *Respiratory System: Thickening of bronchial secretions,* tightness of chest and wheezing, nasal stuffiness. **Overdosage:** Antihistamine overdosage reactions may vary from central nervous system depression to stimulation. Stimulation is particularly likely in children. Atropine-like signs and symptoms – dry mouth; fixed, dilated pupils; flushing; and gastrointestinal symptoms may also occur. *If vomiting has not occurred spontaneously,* the patient should be induced to vomit. This is best done by having him drink a glass of water or milk after which he should be made to gag. Precautions against aspiration must be taken, especially in infants and children. *If vomiting is unsuccessful,* gastric lavage is indicated within 3 hours after ingestion and even later if large amounts of milk or cream were given beforehand. Isotonic and ½ isotonic saline is the lavage solution of choice. *Saline cathartics,* as milk of magnesia, by osmosis draw water into the bowel and therefore, are valuable for their action in rapid dilution of bowel content. *Stimulants* should **not** be used. Vasopressors may be used to treat hypotension. **Dosage and Administration:** DOSAGE SHOULD BE INDIVIDUALIZED ACCORDING TO THE NEEDS AND THE RESPONSE OF THE PATIENTS. *Adults:* One to two 4 mg tablets three or four times a day. One Extentab (8 or 12 mg) every eight to twelve hours or twice daily. Two to four teaspoonfuls of elixir three or four times a day. *Children over six.* One 4 mg tablet three or four times a day. One Extentab (8 or 12 mg) every twelve hours. One or two teaspoonfuls of elixir three or four times a day. *Children under six.* 0.5 mg of brompheniramine maleate per kg of body weight per 24 hours, or 15 mg per M^2 per 24 hours, divided into 3-4 doses.

A·H·ROBINS

A. H. ROBINS COMPANY RICHMOND, VA 23220

J 015A 1800

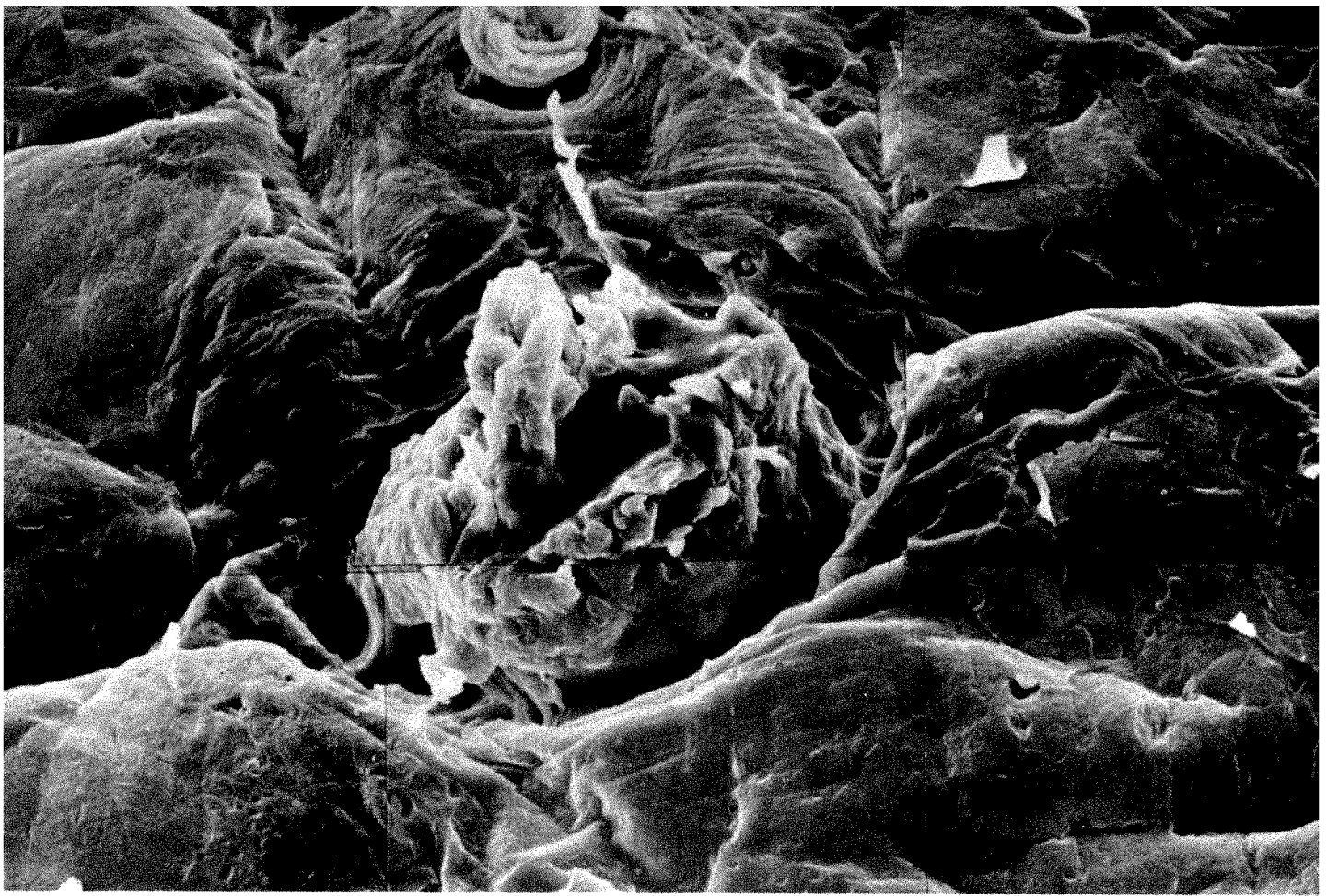

BEFORE TREATMENT: Comedo plugged with keratinous debris. Directly above is a smaller comedo, and in the lower left hand corner a vellus hair is apparent. Note absence of sharp lines of demarcation between layers of cells.*

Pernox® Begins to Improve an Acne Lesion in 2 Days

Rapid resolution of an acne lesion is graphically demonstrated with Scanning Electron Microscopy.

We formulated Pernox® Abradant Scrub to make it effective yet gentle enough for acne skin.

Patients respond to Pernox rapidly, often noticing improvement after the first wash. Pernox Scrub/Lotion is a unique combination of therapeutic agents to emulsify oil and desquamate affected areas. Both forms of Pernox offer significant patient benefits.

Pernox® Lotion offers less desquamation and additional flexibility for your therapeutic acne regimen.

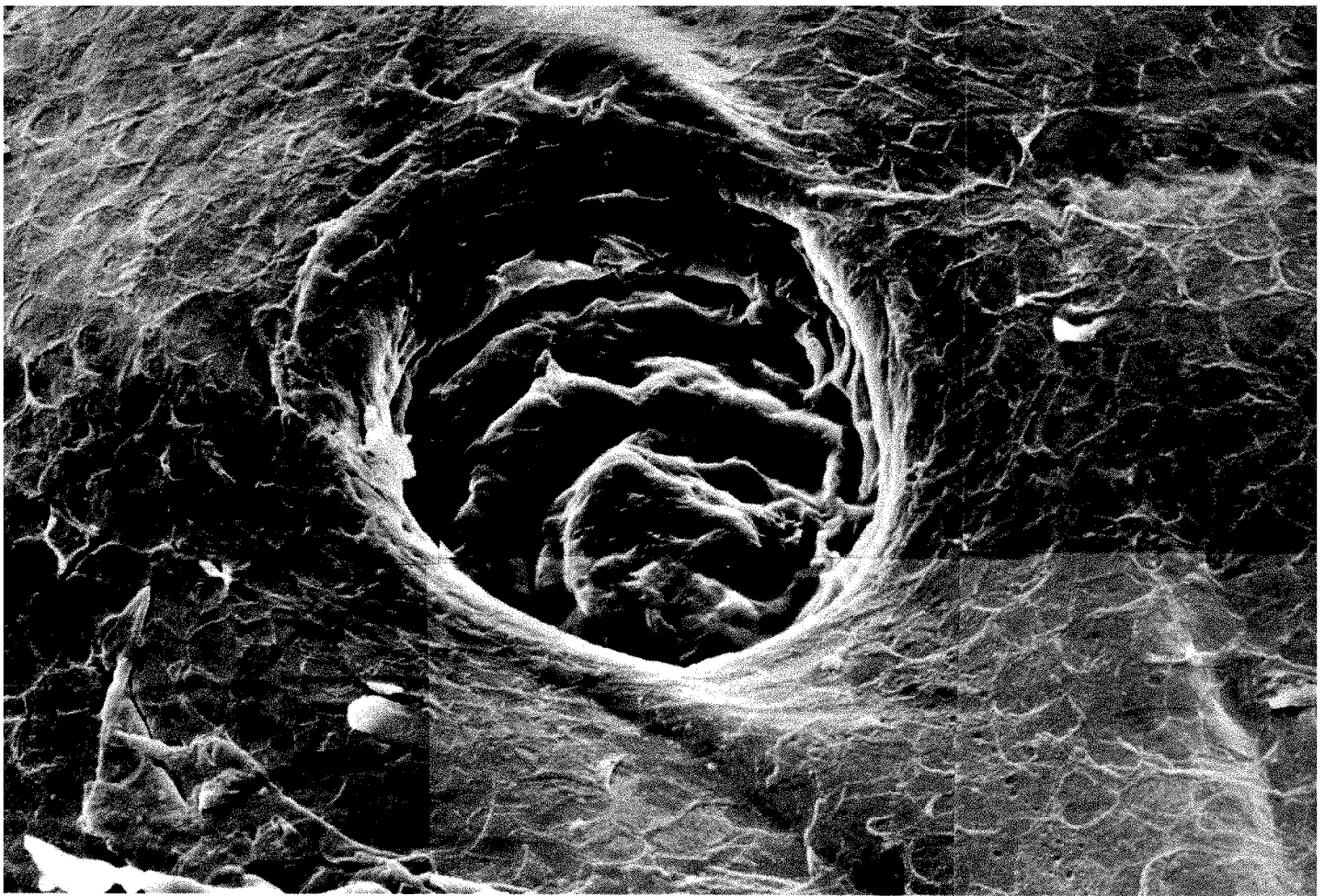

AFTER 2 DAYS: Depth of orifice indicates removal of plug in both large central and smaller top comedo. Surface desquamation and excellent hexagonal demarcations of individual epithelial cells are apparent.*

Pernox . . . an acne regimen formulated to give you an alternative to your present acne therapy or to be used adjunctively with other topical modalities for acne. Washing varies from patient to patient. You determine the regimen by frequency of washing and the amount of water used during the wash.

INDICATIONS: Acne vulgaris, oily skin, comedones.
CONTAINS: Gentle abradant microfine granules of polyethylene, 2% sulfur, 1.5% salicylic acid in SEBULYTIC® brand of unique penetrating surface-active combination of soapless cleansers and wetting agents.
CONTRAINDICATIONS: Not indicated when acute inflammation is present or in nodular or cystic acne.
ADMINISTRATION AND DOSAGE: After wetting the skin, PERNOX is applied with the fingertips and massaged into the skin for about one-half to one minute. The skin is then thoroughly rinsed. Used one to two times daily, or as directed.
CAUTION: If undue skin irritation develops or increases, adjust usage schedule or discontinue use. If necessary, anti-inflammatory measures may be used after discontinuance. For external use only. Contact with eyes should be avoided. In case of contact, flush eyes thoroughly with water.

*These photographs were part of a study in which participants cleansed twice daily with Pernox® Scrub.

The Abradant Of Choice

PERNOX®

Scrub/Lotion

Lathering Abradant
Cleanser for Acne

Scrub: 2 oz. and 4 oz. tubes, regular or lemon-scented
Lotion: 6 oz., lemon-scented

WESTWOOD
PHARMACEUTICALS INC.
Buffalo, New York 14213

©1977, W. P. Inc.

AVEENO®
Colloidal Oatmeal
bath for sensitive skin

When you treat inflammatory diseases, such as wet dermatitis (including allergic, atopic and contact), intertrigo or wet pruritus, a colloidal oatmeal bath may prove valuable, adjunctive therapy.

Soak Away The Discomfort With AVEENO COLLOIDAL OATMEAL.

- **Cleans naturally**—a soap-free way to absorb dirt and excess oil.
- **Comforts gently**—soothingly soaks hard-to-reach and widespread problem areas.
- **Long-lasting protection**—colloidal oatmeal film continues to protect after bathing.
- **Helps restore normal skin pH.**

Available in 1 lb. and 4 lbs. boxes.

Cooper Laboratories, Inc., Wayne, N.J. 07470 Cooper

Schering

When it's all you want, it's all they get.

pure and simple

Chlor-Trimeton® 12mg.

brand of
chlorpheniramine maleate, USP

brand of
Repetabs® Tablets, repeat-action tablets

Available on prescription only.

Also available:
Chlor-Trimeton®
8 mg. Repetabs®
Injection 100 mg./ml.
and 10 mg./ml.

Copyright © 1977, Schering Corporation. All rights reserved.

SWW-9340

PreSun

5% PABA GEL/LOTION

Provides superior sunscreen protection.

WESTWOOD
PHARMACEUTICALS INC.
Buffalo, New York 14213

© 1976, W.P. Inc.

Editorial

Should Vitiligo Be Induced in Patients After Resection of Primary Melanoma?

The incidence of vitiligo is particularly high in patients who have melanomas. Indeed, one has the impression that the frequency of vitiligo increases with a prolongation of the interval between the excision of a primary melanoma and the appearance of metastatic lesions. This statement implies that vitiligo presages for the host either a prolonged remission free from the melanoma or a vigorous resistance and survival longer than expected for those without vitiligo even after metastases are found. Occasionally, patients develop vitiligo many years after the original surgical excision of a melanoma. In these patients metastases may accompany the developing leukoderma. However, the association does not negate the general principle that patients with vitiligo associated with melanomas live longer and handle their melanoma better than those with melanomas without loss of skin color.

Observations on pigs, horses, and human beings suggest that induction of vitiligo early in the course of the illness could prolong the life expectancy of the patient. The Sinclair minipig is born with benign and malignant nevocellular nevi. The animals develop total vitiligo as their tumors regress. Arabian and Lipizzaner horses are brown at birth. They develop perirectal melanomas that enlarge slowly. Their skin and hair become progressively white as the tumor grows. Based on these observations, it appears that the melanomas may precede the vitiligo. In any event horses handle their melanomas far more effectively than do human beings. Observations on man indicate that spontaneous vitiligo without BCG or vaccinia comes as a late response and that factors that cause vitiligo also retard the growth of the melanoma. One patient with vitiligo developed a melanoma. The tumor was resected and the patient may be cured because it is 19 years since the time of surgery. Another patient had extensive spread of melanoma throughout his leg and amputation was performed. After the surgery, a few cutaneous metastases grew on the stump. Those lesions were excised. The patient developed vitiligo, and he remains without recurrence for more than two years. Another patient had total vitiligo and a melanoma of many years duration before the tumor began to spread. Without the vitiligo he might have followed a more rapid downhill course.

A study should be carried out in patients whose primary melanomas are classified by depth histologically and according to the lymphocytic response. Such patients should then be treated with phenolic or catecholic compounds to produce depigmentation. Control subjects could be used, but some of the patients with melanomas could serve as their own controls because not everybody in whom one attempts to produce depigmentation will actually get vitiligo. For those patients who already have advanced disease it is important to determine the locations of their metastases and to remove as many of them as possible by surgery, x-ray, or chemotherapy. We have for a long time considered the possibility of using factors in the serum or lymphocytes from patients with vitiligo but without melanomas for the destruction of malignant melanocytes in patients with melanomas. Patients should be given serum or lymphocytes from other patients who have extensive vitiligo, but who do not have melanomas.

Can the production of depigmentation make a patient with a melanoma worse? The conditions of many patients follow a downhill course as soon as vitiligo occurs. We believe that in those situations, the host resistance has been maximum but to no avail, because it came too late. That is, the stimulus needed to get a useful immunologic response is so great that it comes only when the malignancy is far advanced. But if vitiligo could be induced early, the patient will probably have a better chance for survival.

AARON B. LERNER, MD
JAMES J. NORDLUND, MD
New Haven, Conn

Zinc Correction of Defective Chemotaxis in Acrodermatitis Enteropathica

William L. Weston, MD; J. Clark Huff, MD; James R. Humbert, MD; K. Michael Hambidge, MD; Kenneth H. Neldner, MD; Philip A. Walravens, MD

• Three patients with acrodermatitis enteropathica (AE), a disorder of zinc metabolism, demonstrated a zinc-responsive defect in chemotaxis of neutrophils and monocytes. Monocyte chemotaxis was depressed during a controlled period of zinc deficiency and increased to normal values after administration of oral zinc sulfate supplements that was sufficient to restore normal plasma zinc levels. In the only patient in whom neutrophils were also studied, a similar defect in chemotaxis of neutrophils was corrected by administration of zinc sulfate supplements. Preincubation of defective cells in vitro with zinc sulfate increased chemotaxis in an almost linear dose-response relationship. These findings suggest an important role for zinc in neutrophil and monocyte chemotaxis and demonstrate a correctable immune defect in AE.

(*Arch Dermatol* 113:422-425, 1977)

Acrodermatitis enteropathica (AE), a rare autosomal recessive disorder, is characterized by onset before age 1; failure to thrive; diarrhea; alopecia; a vesiculobullous eruption around the mouth, anus, hands, and feet; photophobia; glossitis; stomatitis; and susceptibility to *Candida albicans, Pseudomonas,* and other infections. For 30 years the disorder has been treated empirically with halogenated hydroxyquinoline derivatives and human breast milk. Moynahan[1,2] has recently demonstrated that the manifestations of AE are reversible by treatment with oral zinc salt supplements. Neldner and Hambidge[3] carefully reported zinc deficiency and biochemical evidence of response to zinc.[3] Most authors accept zinc deficiency as an important biochemical marker of this disease and consider AE an inherited disorder of zinc metabolism.[3-5]

Immune deficiency has been suspected in such patients because of their frequent secondary infections with *C albicans* and their ultimate death from sepsis.[6-12] One infant who died of AE was reported to have had dysgammaglobulinemia and at autopsy had a small thymus, no tonsils or Peyer patches, and no germinal centers nor IgG staining of lymph nodes.[6] This generalized lymphoid depletion was interpreted as representing both T- and B-lymphocyte deficiency. An additional child had no demonstrable thymus at autopsy.[11] Calves of the Danish black pied cattle breed also have a disease similar to AE that is characterized by severe hypoplasia of the lymphoid system and that may be reversible with zinc supplements.[13] Immunologic investigations to date in AE have been limited to the lymphocyte system.

In three patients with AE, we investigated another aspect of immunity, monocyte function. We report our findings in these three patients during a carefully monitored period of zinc deficiency and after plasma zinc levels were restored to normal by oral zinc sulfate therapy.

SUBJECTS AND METHODS

Patients

The first patient (1), a 23-year-old woman who had been treated with diiodohydroxyquin, was reported in an earlier study.[3,14] The second patient (2), a 31-month-old boy, developed typical cutaneous findings and failure to thrive at 6 weeks of age and was diagnosed as having AE at 3 months of age. He could not be treated with diiodohydroxyquin because of diarrhea and vomiting, and was treated successfully with human breast milk that was provided through a nationwide campaign. The third patient (3), a 12-year-old girl, developed diarrhea at the age of 3 months and was diagnosed as having AE at the age of 4 months. Response to diiodohydroxyquin was temporarily helpful, but due to visual disturbances, this therapy was discontinued at the age of 3 years, and she received no subsequent treatment. She demonstrated hyperkeratotic plaques around her mouth, perineum, elbows, knees, antecubital and popliteal fossae,

Accepted for publication June 29, 1976.

From the Departments of Dermatology (Drs Weston, Huff, and Neldner), Pediatrics (Drs Humbert, Hambidge, and Walravens), and Biophysics and Genetics (Dr Humbert), University of Colorado Medical Center, Denver.

Reprints not available.

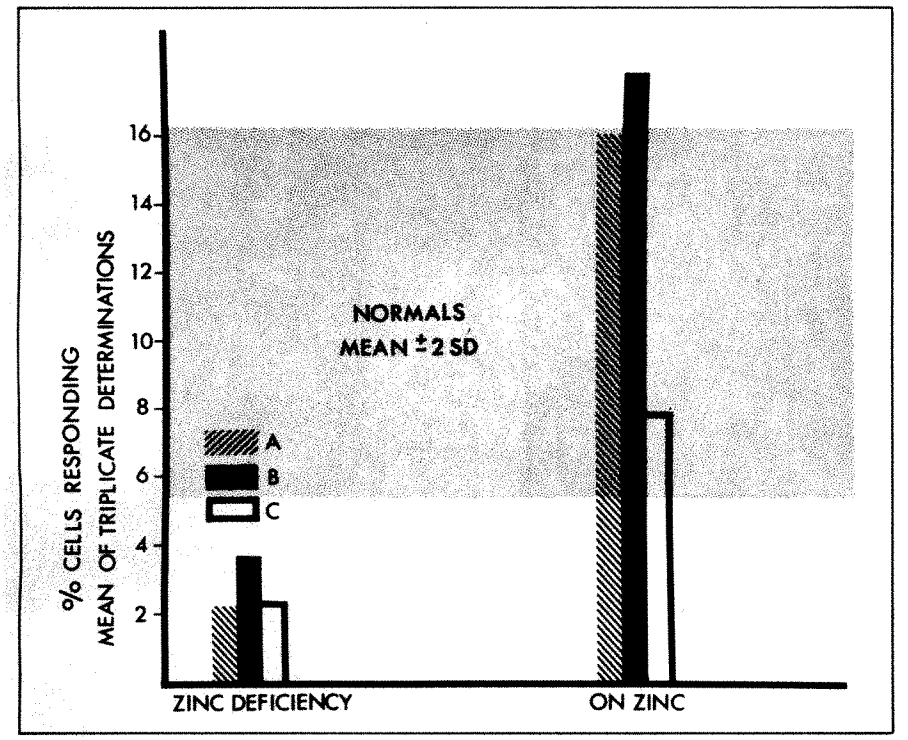

Fig 1.—Mean chemotaxis of monocytes during two phases: (1) zinc deficiency with mild symptoms of acrodermatitis enteropathica (AE) and (2) after symptoms and AE were corrected and plasma zinc levels returned to normal.

Table 1.—Monocyte Chemotaxis and Plasma Zinc Levels

Patient*	Zinc Deficient	Oral Supplemental Zinc
Patient 1		
Chemotactic cells, %	2.88 $P < .01$	16.10 P = NS
Plasma zinc, μg/100 ml	10.00 $P < .001$	72.00 P = NS
Patient 2		
Chemotactic cells, %	4.20 $P < .05$	18.02 P = NS
Plasma zinc, μg/100 ml	47.00 $P < .001$	80.00 P = NS
Patient 3		
Chemotactic cells, %	3.32 $P = .01$	8.25 P = NS
Plasma zinc, μg/100 ml	30.00 $P < .001$	135.00 P = NS

*P values compare results in patients 1, 2, and 3 to mean of 30 normal controls that were: plasma zinc (mean ± SE) 88.3 ± 2.5, and monocyte chemotaxis 11.6 ± 0.6.

palms, and soles, as well as alopecia and substantial photophobia. Two older siblings had died at the ages of 6 months and 16 months with similar symptoms and signs that were suggestive of AE.

Protocol

All three patients were admitted to the Pediatric Clinical Research Unit at Colorado General Hospital. Patients 1 and 2 were withdrawn from their previous therapies and were allowed to become symptomatic with minimal dermatitis, as well as affective symptoms of depression or irritability. The three patients were studied during two clinical phases: (1) while receiving no therapy and zinc deficient, and (2) after zinc sulfate therapy had restored their plasma zinc levels to normal. Patients were given oral zinc sulfate at 4 to 9 mg/kg of body weight daily (1 to 2 mg/kg of body weight daily of elemental Zn^{++}) and were assayed for phagocyte function at 21, 4, and 9 days, respectively, after receiving oral zinc, when plasma zinc levels were restored to normal.

Laboratory Investigations

Plasma zinc levels and leukocyte studies were performed between 8:00 AM and 9:00 AM after an overnight fast. Blood was collected by peripheral venipuncture. Zinc specimens were collected in 1.5-ml polypropylene tubes that had been washed in hydrochloric acid and that contained 10 μg of heparin free of detectable zinc. Plasma samples were ashed in the oxygen plasma of a low-temperature asher prior to zinc analyses. Dissolved ash samples were analyzed spectrochemically with a silver-argon, dc-arc, and 1.5-meter direct-reading spectrometer.[15]

Quantitative monocyte studies were performed on human monocytes, as described previously.[16] Monocytes isolated from Ficoll-sodium diatrizoate gradients were suspended in a zinc-free tissue culture medium, Rosewell Park Memorial Institute (RPMI)-1640, without added serum. The mononuclear cell mixture was adjusted to 0.25×10^6 phagocytic mononuclear cells (monocytes) per chemotaxis chamber. The cells of patient 3 during the zinc deficiency stage were preincubated for 30 minutes in zinc sulfate dissolved in RPMI-1640 to make final zinc concentrations of 0.01, 0.1, and 1.0 μg/ml and then were tested for chemotaxis.[15] Similar concentrations of gluconate calcium and cupric sulfate were also investigated.

Chemotaxis was measured by the method described previously[16] with the use of microchemotaxis plastic chambers that were separated into two compartments by a sandwich of two permeable membrane filters (Millipore). An 8.0-μ filter was placed on top, and a 0.45-μ filter was placed below, which permitted counting of any cells that passed completely through the upper filter and did not adhere to its lower surface. A standard chemotactic attractant used in this assay was a 10% solution of pooled AB-negative human serum in RPMI-1640 tissue culture media activated with *Escherichia coli* lipopolysaccharide endotoxin type 0111:B4 at 200 μg/ml for 30 minutes at 37 C. This amount of endotoxin has been found to be the most effective quantity in activating the C3a and C5a components of the complement system.[16] Aliquots of 0.5 ml of endotoxin-activated serum were stored and frozen at −70 C. Attractants were added to the lower chamber, and .25 ml of a concentration of 1×10^6 monocytes per milliliter (250,000 monocytes) was added to the upper compartment. All assays were performed in triplicate. Chambers were incubated at 37 C with 5% carbon dioxide and 100% humidity for five hours. After incubation, the filters were removed, and they were fixed in absolute methanol and were rinsed in distilled water. Filters were stained with hematoxylin and bluing agents and then they were dehydrated in a standard fashion and were cleared with xylene. After they were mounted on a slide and were allowed to dry overnight, the filters were examined at a magnification of 430. Ten fields were counted. The cells on the upper surface of the 8.0-μ filter (cells that did not migrate) were compared with those migrating through the filter (including those within the filter) plus those that passed through the 8.0-μ filter and were entrapped on the surface of the 0.45-μ filter. The results were expressed as the percentage of total cells migrating by the following formula: $N = 100 \times T_1/T_2$,

where T_1 equals the total number of cells migrating, and T_2 equals the total number of cells migrating and not migrating.

Only monocyte functions were examined in patients 1 and 2. During the study of patient 3, chemotaxis of neutrophils was performed by a modified Boyden chamber technique[17] simultaneously with monocyte functions. Eosinophils were not studied. All assays were performed in triplicate, with phagocytes from healthy donors examined the same day.

Bacterial phagocytosis and bactericidal assays, phagocytosis of oil red O-containing paraffin oil particles, and phagocytosis-induced nitro blue tetrazolium (NBT) reduction were performed as described previously[16] on monocytes from the phases of zinc deficiency.

Neutrophil migration in vivo was evaluated by a new method involving plastic chambers over tape-stripped epidermis with 50% autologous serum as the chemotactant.[18] Samples were counted at 24 hours and were recorded as neutrophils per square centimeter of skin at 24 hours. Neutrophil migration was compared with that of 30 healthy young adult controls. All data were evaluated by the χ^2 method.

RESULTS

All three patients demonstrated defective monocyte chemotaxis when they were not receiving therapy (Fig 1, Table 1). Simultaneous plasma zinc levels for patients 1, 2, and 3 were 10, 47, and 30 μg/100 ml, respectively, which were well below the normal range of 68 to 112 μg/100 ml. The defective chemotaxis was corrected to normal or elevated levels (patient 2) after oral zinc sulfate supplements had increased plasma zinc values to the normal range (Fig 1).

In patient 3, assays of neutrophil chemotaxis paralleled those of monocyte chemotaxis (Table 2). Addition of zinc sulfate in vitro improved chemotaxis of both monocytes and neutrophils (Fig 2). At 0.01 μg/ml of zinc, neutrophils were more responsive than monocytes. Addition of cupric sulfate and calcium sulfate in similar concentrations had no significant effect on chemotaxis. Assays of other monocyte functions (bacterial phagocytosis, bacterial killing, phagocytosis of oil red O-containing paraffin oil particles, and phagocytosis-induced NBT reduction) were normal during zinc deficiency (Table 3). In vivo quantitative neutrophil migration into tape-stripped skin sites was normal in both the zinc-deficient and zinc-treated state at 24 hours (2.3×10^5 vs control of 1.4×10^6 leukocytes per sq cm of skin at 24 hours).

Dietary treatment with zinc sulfate reversed the symptoms and signs in all three patients. Decreased irrita-

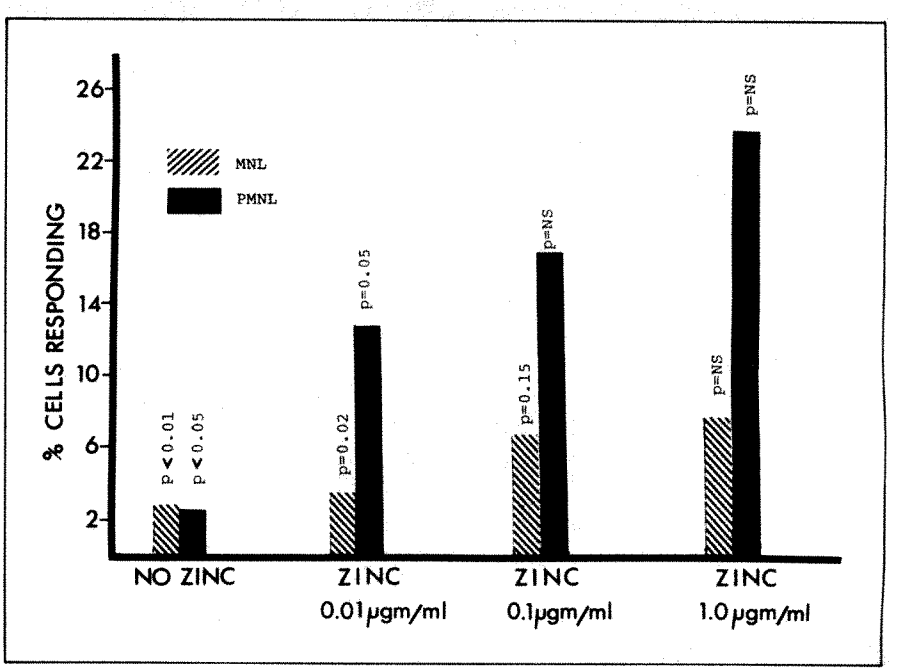

Fig 2.—Mean chemotaxis of monocytes (MNL) and neutrophils (PMNL) from 3 patients with acrodermatitis enteropathica during clinical zinc deficiency. *P* values compare mean chemotaxis with that of 30 healthy controls. NS indicates not significant.

Table 2.—Monocyte and Neutrophil Chemotaxis and Plasma Zinc Levels in Patient 3

Date	Plasma Zinc, μg/100 ml	Monocyte Chemotaxis, % Chemotactic Cells	Neutrophil Chemotaxis, % Chemotactic Cells†
8/20/75	30.5	2.76	3.2
8/26/75*	30.0	3.32	3.1
9/10/75	135.5	8.25	8.7
11/3/75	115.0	11.90	8.0
11/7/75	159.5	14.10	ND
Controls Mean ± SE	88.7 ± 1.8	11.6 ± 0.6	5.6 ± 0.3

*Patient received 100 mg of oral zinc sulfate twice a day that was begun Aug 26, 1975.
†ND indicates not done.

Table 3.—Normal Monocyte Functions During Zinc Deficiency

	Patient 1	Patient 2	Patient 3	Controls (N = 23)*
Bacterial phagocytosis (% extracellular bacteria surviving)	35	43	19	19.96 ± 14.24
Bacterial killing (% intracellular bacteria surviving)	1	0	3	0.61 ± 1.0
Oil red O phagocytosis (micrograms ingested per 10^7 cells)	25	16	2	18.78 ± 20.34
Phagocytosis-stimulated nitro blue tetrazolium reduction (micrograms of formazan per 10^7 cells)	119	132	327	247.6 ± 178

*Mean ± 2.

bility and personality improvement were the first changes that were noted; most cutaneous manifestations cleared within two weeks.

COMMENT

Investigation of the monocyte system in these three patients showed suppressed cellular chemotaxis of monocytes during zinc deficiency, while other in vitro assays of monocyte functions (phagocytosis and bactericidal activity) were unaffected. Furthermore, in patient 3 defective chemotaxis of both neutrophils and monocytes was observed. Despite abnormal chemotaxis in vitro in our patients, neutrophil migration as measured by skin chambers in vivo was normal at 24 hours, suggesting that these two parameters of neutrophil movement depend on different determinants. Furthermore, examining the neutrophil migration at 24 hours may not uncover defects in the early stages of chemotaxis. The physiologic significance of defective in vitro chemotaxis in patients with AE is not known, but the rapid accumulation of neutrophils and monocytes at tissue sites is a crucial early event in host defenses to invading microorganisms.[17] Patients with AE do suffer from frequent and persistent infections, and this defect in chemotaxis may contribute to this susceptibility.

In addition, the defect in chemotaxis in the zinc deficiency of patients with AE was correctable by adding small amounts of zinc to defective neutrophils and monocytes in vitro. This finding demonstrated the need to study AE neutrophils and monocytes in zinc-free medium. Normal neutrophils and monocytes did not demonstrate improved chemotaxis with the addition of zinc sulfate, nor did cupric sulfate or gluconate calcium salts improve faulty chemotaxis in patient 3.

Immunity in patients with AE has been infrequently studied in the past.[6-11] The two autopsy studies to date showed diminished thymic tissue and generalized lymphoid depletion. However, in both cases, prolonged malnourishment, diarrhea, and failure to thrive may account for lymphoid changes occurring as a terminal event rather than preceding signs of AE. The Danish cattle breed with zinc deficiency and with signs and symptoms of AE often die at the age of 4 to 5 months with generalized lymphoid depletion. Their extreme state of malnutrition may result in this depleted lymphoid system as in the two children who were the subjects of the autopsy reports.[3] No requirements for zinc in human immune function have been described.

Evidence that zinc affects phagocytic cells has been observed in mice that were treated with low doses of zinc, which resulted in increased viability of their peritoneal macrophages when exposed to toxic doses of silica. Both low-dose and high-dose zinc treatment resulted in impaired phagocytosis of *Staphylococcus aureus* by mouse macrophages.[19] Furthermore, zinc also may serve as a cofactor to aid the spreading of mouse macrophages on glass surfaces.[19] These animal studies suggest that zinc expresses activity on phagocyte membranes.

Identification of a correctable immune defect in AE during zinc deficiency broadens our understanding of this disease. Furthermore, it suggests that zinc may play a crucial role in monocyte and neutrophil chemotaxis.

This study was supported by a grant from the National Live Stock and Meat Board; by grant RO1-AM-1243 from the National Institute of Arthritis, Metabolic and Digestive Disease; and by grant RR-69 from the General Clinical Research Centers program of the Division of Research Resources, National Institutes of Health.

Selma Targovnik, MD, and Archie McIntosh, MD, referred patients 2 and 3.

W. Mitchell Sams, Jr, MD, gave advice and criticism.

The authors thank Roberta Dustin, Steven K. Hecht, and Donna A. Chadwick for their expert technical assistance.

Microchemotaxis chambers were modified from a design originated by Dr Hans Uli Keller, Geneva.

References

1. Moynahan EJ: Zinc deficiency in acrodermatitis enteropathica: Multiple dietary intolerance treated with synthetic diet. *Proc R Soc Med* 66:327-329, 1973.

2. Moynahan EJ: Acrodermatitis enteropathica: A lethal inherited human zinc deficiency disorder. *Lancet* 2:399-400, 1974.

3. Neldner KH, Hambidge KM: Zinc therapy of acrodermatitis enteropathica. *N Engl J Med* 292:879-882, 1975.

4. Michaëlsson G: Zinc therapy in acrodermatitis enteropathica. *Acta Derm Venereol* 54:377-381, 1974.

5. Thyresson N: Acrodermatitis enteropathica. *Acta Derm Venereol* 54:383-385, 1974.

6. Julius R, Schulkind M, Sprinkle T, et al: Acrodermatitis enteropathica with immune deficiency. *J Pediatr* 83:1007-1011, 1973.

7. Hodgson-Jones IS: Acrodermatitis enteropathica. *Br J Dermatol* 67:222-224, 1955.

8. Bloom D: Acrodermatitis enteropathica: Another inborn error of metabolism? *NY State J Med* 60:3609-3616, 1960.

9. Wells BT, Winkelmann RK: Acrodermatitis enteropathica: Report of 6 cases. *Arch Dermatol* 84:40-52, 1961.

10. Margileth AM: Acrodermatitis enteropathica. *Am J Dis Child* 105:285-291, 1963.

11. Rodin AE, Goldman AS: Autopsy findings in acrodermatitis enteropathica. *Am J Clin Pathol* 51:315-322, 1969.

12. Tompkins RR, Livingood CS: Acrodermatitis enteropathica persisting into adulthood. *Arch Dermatol* 99:190-195, 1969.

13. Kirchner H, Rühl H: Zinc deficiency. *Lancet* 1:1317, 1973.

14. Neldner KH, Hagler L, Wise WR, et al: Acrodermatitis enteropathica: A clinical and biochemical survey. *Arch Dermatol* 110:711-721, 1974.

15. Hambidge KM: Use of a static argon atmosphere in emission spectrochemical determination of chromium in biological materials. *Anal Chem* 43:103-107, 1971.

16. Weston WL, Dustin RD, Hecht SK: Quantitative assays of human monocyte-macrophage function. *J Immunol Methods* 8:213-222, 1975.

17. Keller HU, Hess MW, Cottier H: Physiology of chemotaxis and random motility. *Semin Hematol* 12:47-57, 1975.

18. Mass MF, Dean PB, Weston WL, et al: Leukocyte migration *in vivo*: A new method of study. *J Lab Clin Med* 86:1040-1046, 1975.

19. Karl L, Chvapil M, Zurowski DF: Effect of zinc on the viability and phagocytic capacity of peritoneal macrophages. *Proc Soc Exp Biol Med* 142:1123-1127, 1973.

Autoimmune Progesterone Dermatitis

Roland Hart, MD

• **Seven patients had autoimmune progesterone dermatitis. The morphological findings illustrate the polymorphous nature of the disease in which urticaria, erythema multiforme, and dyshidrosiform lesions were seen. Recurrence of the eruption five to ten days prior to the menses with spontaneous resolution following the menses was present in all cases. Intradermal skin testing to progesterone was done to confirm the diagnosis. Six of the seven patients had a history of use of artificial progestational hormones prior to the beginning of their eruption. It is postulated that the artificial progesterones may have been the trigger for the development of their autosensitivity. Treatment with conjugated estrogens resulted in remission of the disease in five of the seven cases reported.**

(*Arch Dermatol* 113:426-430, 1977)

To date there have been seven cases reported in the literature of skin diseases caused by progesterone that seemed to represent an autoimmune disease. Two of the cases reported were urticarial and five were nonurticarial. Only one case was reported in a pregnant woman.

The concept of an autosensitivity to one's own progesterone could be considered analogous to other autoimmune diseases such as lupus erythematosus and pemphigus in which there are circulating antibodies directed against autologous tissues.

Seven patients are reported herein with progesterone dermatitis, five of which were successfully treated with anovulatory drugs. In addition, a review of the literature and of normal female progesterone function is presented, and an hypothesis is offered as a possible etiology of this disease.

REPORT OF CASES

CASE 1.—This 29-year-old college English teacher came to the Dermatology Clinic on Dec 3, 1973, with a six-month history of a markedly pruritic vesicular eruption on the palms and soles. The eruption on the soles prevented her from standing or walking without severe pain. She had been treated previously with tolnaftate (Tinactin), a mixture of nystatin, neomycin sulfate, and triamcinolone (Mycolog), hydrocortisone, and 0.1% triamcinalone (Kenalog) creams, all of which reduced the pruritus, but the eruption continued to recur.

At the time of her initial examination in the clinic, she was taking no drugs other than an occasional aspirin. She had taken birth control pills previously, but none since the eruption began. She had no known sensitivities. Her family history was negative for skin disease.

On initial physical examination there were vesicles and pustules on the palms and soles (Fig 1 and 2) and an erythematous, macular, and papular eruption on the arms and legs. A KOH preparation and fungal cultures were negative.

Initially, she was given an emulsion ointment (Cetaphil) as a replacement for soap and water baths, 0.1% triamcinolone cream, and Burrows soaks to the feet.

Additional history on the next visit revealed that, since the beginning, her eruption had been flaring cyclically just prior to her menses and clearing with or without treatment as the menses began. However, each flare was worse than the previous one.

On this visit, intradermal skin tests to progesterone and *Candida* were administered. One of the nurses in the clinic also received progesterone skin tests to serve as

Accepted for publication May 25, 1976.

From the Department of Dermatology, Stanford University Medical Center, Stanford, Calif.

Read before National Medical Association Meeting, Miami, Aug 10, 1975.

Reprint requests to Department of Dermatology, R-132, Stanford University Medical Center, Stanford, CA 94305 (Dr Hart).

Fig 1.—Vesicular eruption on feet.

Fig 2.—Vesicular eruption on hands.

Fig 3.—Positive progesterone skin tests.

Fig 4.—Erythema multiforme on hands.

Fig 5.—Urticarial at site of progesterone test at 20 minutes. No reaction at site of saline injection.

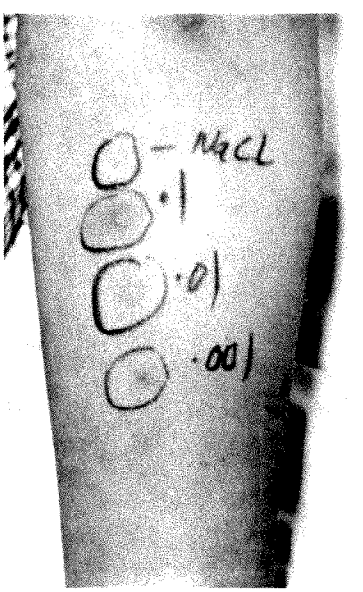

a control. After 48 hours, the patient's progesterone tests showed 6 mm induration and 2 cm of erythema and was interpreted as positive (Fig 3). The nurse's control tests were negative.

In December 1973, conjugated estrogens (Premarin), 1.25 mg/day, was begun for a 21-day cycle, and she was referred to gynecology for breast and pelvic exams.

The January 1974 follow-up showed no vesiculation, no weeping, and no oozing throughout the entire cycle.

However, in April 1974, a few vesicles developed and the conjugated estrogens were increased.

In June 1974, she was completely clear and was switched to norethynodrel (Enovid E). During the next two cycles, she flared, the norethynodrel therapy was discontinued, and regimens of conjugated estrogens, 1.25 mg/day, were begun, and she again cleared.

In June 1975, the conjugated estrogens were reduced to 0.625 mg/day and when she was last seen in December 1975, she was still free of skin lesions.

Case 2.—This 25-year-old housewife presented in July 1973 with a seven-year history of a bullous eruption on the mouth, chest, back, and arms. Historically, the eruption began five days prior to the menses with resolution following the menstrual flow. Her eruption was initially felt to be related to birth control pills she was taking and they were stopped; however, her eruption continued to recur cyclically. Skin biopsy results were consistent with bullous erythema multiforme.

Past medical history revealed she had a

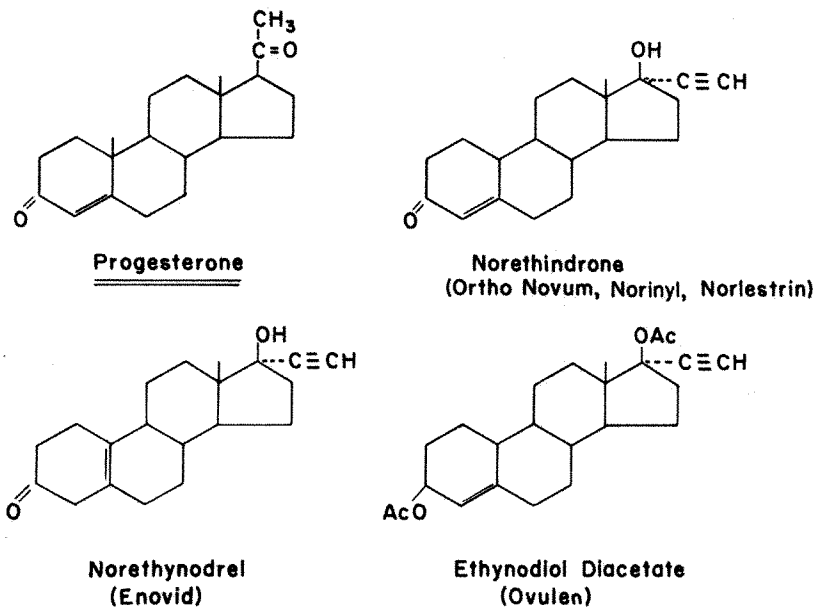

Fig 6.—Comparison of progesterone with synthetic progestins.

unilateral oophorectomy because of an ovarian cyst.

Initial examination revealed multiple vesicles on an erythematous base on the upper back, face, and arms. No oral lesions were observed.

Skin tests to progesterone were administered intradermally and were positive at 48 hours.

Regimens of conjugated estrogens were started. Follow-up one month later showed her to have had a completely lesion-free cycle. In September, she was switched to norethynodrel, and during the next cycle, she again developed bullous lesions prior to the menses. The conjugated estrogen therapy was again initiated and she has remained free of lesions since.

CASE 3.—This 40-year-old typist presented in March 1974 with a three-year history of a bullous eruption on the extremities and mouth. The eruption occurred cyclically and appeared seven to ten days prior to the menses and resolved following the menses. There was no history of any drug ingestion, herpes, or recurrent strep infection. She had a proven allergy to penicillin and a history of hay fever.

Past history revealed a previous Papanicolaou smear showing low estrogen effect.

Examination revealed erythematous target-like vesicles on both hands (Fig 4), wrists, knees, and shins. There was an erosive lesion on the left buccal mucosa. Skin biopsy results were consistent with bullous erythema multiforme.

She was admitted to the hospital for workup of erythema multiforme. The workup results were normal except for intradermal skin tests to progesterone that showed 1.5 cm erythema and 7 mm induration. Conjugated estrogen therapy, 1.25 mg/day, was begun.

In May 1974, follow-up revealed no eruption. Subsequently she married, moved, and was lost to follow-up.

CASE 4.—This 30-year-old woman came to Redwood City Kaiser Dermatology Clinic in October 1972 with a seven-year history of a chronic, symmetrical dermatitis of the feet and a few vesicles on the hands. She was initially treated with systemic steroids. Patch tests to the 14 most common sensitizers listed by the North American Patch Test Group were applied and revealed 1+ to formalin, 1+ to neomycin, and 4+ to ethylenediamine. Betamethasone valerate (Valisone) ointment was then prescribed but gave no relief.

Intralesional triamcinolone diacetate (Aristocort) injections were subsequently given around the tenth day of August, September, October, November, December, January, and February without significant results. A KOH preparation and fungal cultures were negative in May 1974, and a skin biopsy taken at that time revealed hypertrophic lichen simplex chronicus.

On June 4, 1974, a history of occurrence of the eruption just prior to each menses was obtained. In July 1974, progesterone, 25 mg intramuscularly, was given as a provocative test, and severe pruritus with vesiculation occurred on the feet.

Consequently, therapy with ethinyl estradiol (Estinyl), 0.02 mg daily, was begun with resolution of her problem for two cycles. However, she was unable to continue estrogen therapy because of endometriosis. Oophorectomy is being contemplated.

CASE 5.—A 48-year-old woman had a one-year history of chronic urticaria, angioneurotic edema, and laryngeal spasm necessitating self injections of epinephrine (Adrenalin). She was treated on several occasions with hydroxyzine pamoate (Vistaril), desensitization injections, corticosteroids, adrenocorticotropic hormone, strict elimination diets, and oral and vaginal nystatin (Mycostatin) without much improvement.

She gave a history of her urticaria initially occurring in cyclical patterns ten days prior to the end of each month, but by the time of her presentation in the clinic, the urticaria was almost constant with exacerbation of laryngeal spasm occurring at the end of each monthly cycle.

Past medical history revealed recurrent aphthous stomatitis, chronic allergic rhinitis, hypothyroidism, total abdominal hysterectomy, nephrolithiasis, pityriasis rosea, and lumbar disc disease with laminectomy and fusion.

Medications at the time included thyroid USP, propranolol hydrochloride (Inderal), hydroxyzine, tripelennamine (Pyribenzamine), and epinephrine as needed.

Physical examination revealed small 5 to 6 mm urticarial lesions and a dermographism response.

She was admitted to the hospital and subsequent laboratory test results, including those from chemistry screening battery II, lupus erythematosus preparation, urinalysis, porphyrins, fluorescent antinuclear antibody, complete blood cell count, antinuclear antibody, stool guaiac, ova and parasites, and challenge to salicylates, were negative. Abdominal x-ray film revealed residual pantopaque from her myelogram and splenic calcifications from old granulomatous disease. Chest x-ray film revealed old calcifications of the right hilar nodes. Follicle stimulating hormone levels were 7.0, and basal body temperature ranged from 36 C (96.8 F) to 36.1 C (97 F) with an increase to 37.2 C (99 F) for three days. These latter two studies suggested she was not postmenopausal and was ovulating. Intradermal skin tests to progesterone produced noticeable urticaria after 20 minutes (Fig 5) and positive

delayed hypersensitivity at 48 hours. Intermediate purified protein derivative, cocci, and *Candida* test results were negative; mumps was positive. Saline control was negative at 20 minutes and negative at 48 hours. A nurse-assistant control was negative for progesterone.

On discharge, she was placed on regimens of bromodiphenhydramine hydrochloride (Ambodry), chlorpheniramine maleate (Teldrin), and hydroxyzine. Her urticaria continued, as did her laryngeal edema, requiring epinephrine and systemic steroids.

In October 1974, therapy with conjugated estrogens was started, and one week later, fewer urticaria were observed.

In November, some urticaria were still present and the regimen of conjugated estrogens was increased. Because of another episode of laryngeal spasm, the dosage had to be increased once more to alternating doses of 2.50 and 1.25 mg/day. This produced clearing of her urticaria. She was seen again in January 1975, and was free of urticaria, but had edema of the lower extremities so her dosage was decreased. One week later, she was free of urticaria and had decreased fluid retention.

When last seen in November 1975, she had been free of urticaria for six months and on no antihistamines.

Case 6.—This 34-year-old woman had a four-month history of urticaria that occurred prior to her menses. Historically, she received an injection of medroxyprogesterone acetate (Depo-Provera) in August 1972 and another in November 1972. She developed an eruption diagnosed as pityriasis rosea in January 1973. She received a third injection in February, following which she developed definite urticaria. In March, April, May, and June, she had cyclical urticaria with no relief from antihistamines and subsequently was placed on prednisone, 10 mg daily each month, when the urticaria began through her menses. She was lost to follow-up for 1½ years. A phone conversation with this patient in September 1975 revealed that her urticaria had continued cyclically for 18 months and then resolved. She is still menstruating, but it is unknown whether she continues to ovulate.

Case 7.—This 29-year-old woman developed generalized erythema multiforme in February 1972, after taking norgestrel (Ovral) for one month. This eruption continued to occur monthly approximately 10 to 14 days prior to the menses even though the norgestrel had been discontinued. On two occasions, she was diagnosed as having Stevens-Johnson syndrome and required treatment with systemic steroids. Over the last two years, she has had several emergency room visits in which she was given systemic steroids for relief of erythema multiforme.

Physical examination on Sept 3, 1975, revealed target lesions on the hands, elbows, and back and vesicles on the buccal mucosa.

On administration of progesterone skin tests intradermally in September 1975, urticaria were noted around the progesterone and mumps injection sites in 15 minutes but not around a saline control site or *Candida*. At 48 hours, there was 6 mm duration and 8 mm erythema at the progesterone sites, and these were interpreted as positive. The mumps were also positive. Skin biopsy was consistent with erythema multiforme. Direct immunofluorescence was negative. Indirect immunofluorescence using human and rat corpus luteum was positive at 1:5 and 1:10 dilutions.

Treatment with conjugated estrogens, 1.25 mg/day was begun at the time of submission of this paper.

BRIEF REVIEW OF THE LITERATURE

In 1951, Guy et al[1] reported a case of a 28-year-old woman with a history of generalized urticaria of six years' duration that occurred premenstrually each month.

In 1964, Shelley et al[2] reported a 27-year-old woman with a vesicular eruption of five years' duration who had regular premenstrual exacerbation that could be elicited by giving progesterone and progesterone compounds. In addition, basophil degranulation was found to be marked and was followed by basopenia. They were able to suppress her eruption with estinyl estradiol. Attempts at desensitization to progesterone failed. She underwent oophorectomy and remained free of disease.

Tromovitch and Heggli,[3] in 1967 reported a case of progesterone urticaria in a 20-year-old woman and successfully treated her with conjugated estrogens, 1.875 mg/day. Of interest in this case was that challenge with 20 mg intramuscularly injected progesterone gave an immediate reaction that had to be controlled with epinephrine and steroids.

Jones and Gordon,[4] in 1969, reported a case involving a 17-year-old with pruritus and erythematous, eczematous papules that flared premenstrually. They were able to demonstrate in vitro indirect basophil degranulation.

Farah and Shbaklu,[5] in 1971, described two patients with premenstrual urticaria and were able to demonstrate positive skin tests to progesterone, passive cutaneous transfer, and positive indirect immunofluorescence of IgG antibodies to the luteinizing cells of the corpus luteum.

Bierman, in 1973,[6] presented a 25-year-old woman with papules, pustules, hyperpigmentation, and erosions on the arms, legs and buttocks, and spontaneous abortions of each of her two pregnancies. She demonstrated positive skin tests to progesterone; however, skin immunofluorescence was negative. She was successfully treated with conjugated estrogens.

Meltzer,[7,8] in a report to the Southern Medical Association in 1961, presented several patients with endocrine hypersensitivity. Interestingly, two of his cases appeared to have been exogenously sensitized to progesterone. He suggested that exogenous as well as endogenous hormones may stimulate antibody formation.

REVIEW OF PROGESTERONE FUNCTION

Progesterone is the principal hormone of the corpus luteum and is derived from cholesterol. In addition to the two-carbon side chain at position 17, progesterone possesses a ketone function at carbon 20 and the Δ^4 three keto grouping in ring A. Its chief source is the corpus luteum, but it is also found in small amounts in the serum of the ovarian, placental, adrenal, and peripheral veins.[9] Pregnanediol is its major known metabolite. The liver is the major site of conversion of progesterone.

Forbes[10] has demonstrated progestational activity in the blood of ovulating woman reaching a maximum between the 20th and 21st day of the cycle. Assays of corpus luteum shows first measurable progesterone on the 14th day. Johansson,[11] from Sweden, has perfected a simplified method of assaying plasma progesterone uti-

lizing petroleum ether extraction followed by competitive protein binding analysis.

Radioimmunoassay studies in humans by Yussman[12] show a dramatic rise in progesterone or total progestin 24 to 48 hours prior to ovulation. These studies suggest "that this rise is not dependent upon ovulation alone but is also a product of the still unruptured but developing follicle or perhaps, of other atretic follicles."

Progesterone's main function is to prepare the uterus for implantation of the ovum. It also affects the cervical mucous secretion, is responsible for the acinar and lobular development of the breast, and causes increased body temperature.

The synthetic progesterones are made by adding or modifying side chains (Fig 6). Most are derived from 19-nortestosterone, 17α hydroxyprogesterone, or acetoxyprogestin.

All seven patients presented are similar in that, their eruptions began seven to ten days prior to the menses. In addition, their eruptions tended to clear spontaneously following the menstrual flow. In each case, estrogen therapy suppressed the disease. All skin testing was done intradermally, using aqueous progesterone suspension 100 mg/ml. This was diluted with normal saline to 0.1 mg/ml, 0.01 mg/ml, and 0.001 mg/ml. In each case mumps and *Candida* intradermal skin tests were administered as a control. One of the clinic nurses served as an additional control.

In case 4, provocative testing was done, using 25 mg progesterone suspension intramuscularly.

Historically, six of our patients were noted to have taken exogenous progesterones at some time prior to the beginning of their eruption. The oral contraceptives are similar in structure but dissimilar enough to possibly induce antibody formation in susceptible individuals. It seems that artificial progestins may have been the trigger for the disease in six of our patients.

In case 1 and 2, it is noted that both patients flared when given norethynodrel. This seems to further suggest that there was cross reactivity between artificial progesterone and endogenous progesterone.

The following outlines our series of patients and their use of prior hormones:

	Prior Use of Hormones
Case 1	Yes, norethindrone (Norinyl)
Case 2	Yes, brand unknown
Case 3	No?
Case 4	Yes, brand unknown
Case 5	Yes, brand unknown
Case 6	Yes, medroxyprogesterone acetate
Case 7	Yes, norgestrel

The positive indirect immunofluorescence indicates the presence of circulation antibodies against the cells of the corpus luteum. The fluorescence is seen within the cytoplasm of the luteinizing cells. It is believed this is where the production and/or secretion of progesterone takes place.

The hormonal and immunological functions of the body are complex. The increasing use of synthetic drugs may be adding a new dimension to the etiology of hormonal disturbances and may be mediated by the induction of immunological reactions with cutaneous manifestations in susceptible patients, as we see in drug induced lupus erythematosus for example.

In patients with a cyclical eruption related to the menses, this entity should be strongly considered.

Alvin J. Cox, MD, Denny Tuffanelli, MD, and Betty Russell assisted with the immunofluorescence.

References

1. Guy WH, Jacob FM, Guy WB: Sex hormone sensitization (corpus luteum). *Arch Dermatol* 63:377, 1951.

2. Shelley WB, Purcel R, Spount S: Autoimmune progesterone dermatitis: Cure by oophorectomy. *JAMA* 190:35-38, 1964.

3. Tromovitch TA, Heggli WF: Autoimmune progesterone urticaria. *Calif Med* 106:211-212, 1967.

4. Jones WN, Gordon VH: Autoimmune progesterone eczema: An endogenous progesterone hypersensitivity. *Arch Dermatol* 99:57-59, 1969.

5. Farah FS, Shbaklu Z: Autoimmune progesterone urticaria. *J Allergy Clin Immunol* 48:257-261, 1971.

6. Bierman SM: Autoimmune progesterone dermatitis of pregnancy. *Arch Dermatol* 107:896-901, 1973.

7. Meltzer L: Hypersensitivity to gonadal hormones. *South Med J* 56:538-542, 1963.

8. Meltzer L: Endocrine hypersensitivity. *Ann Allergy* 9:753-759, 1951.

9. Novak ER, Jones GS, Jones HW Jr: Physiology of menstruation and pregnancy—progesterone, in *Novak's Textbook of Gynecology*, ed 7. Baltimore, Williams & Wilkins Co, pp 32-47.

10. Forbes TR: Systemic plasma progesterone levels during the human menstrual cycle. *Am J Obstet Gynecol* 60:180, 1950.

11. Johansson E: A simplified procedure for the assay of progesterone: Steroid assay by protein binding, in *Karolinska Symposia on Research Methods in Reproductive Endocrinology*, 2nd symposium, March 23-25, 1970, Geneva, World Health Organization, pp 188-199.

12. Yussman M: Serum levels of follicle-stimulating hormone, luteinizing hormone, and plasma progestins correlated with human ovulation. *Fertil Steril* 21:119-125, 1970.

Transient Acantholytic Dermatosis

A Reevaluation

Marc Chalet, MD; Ralph Grover, MD; A. Bernard Ackerman, MD

• **Transient acantholytic dermatosis is a self-limited, primary acantholytic disease that occurs predominantly in persons over 50 years old. The primary lesions, discrete papules and papulovesicles, are distributed mainly on the chest, back, and thighs and may be intensely pruritic. The disease lasts less than three months in the majority of patients, but occasionally may go on for two or three years.**

Four distinct histologic patterns are present in the biopsy specimens, namely, Darier-like in which there is focal acantholysis and dyskeratosis overlying suprabasilar clefts; pemphigus vulgaris-like, in which there are a few acantholytic cells above discrete suprabasal clefts having a mostly intact overlying epidermis; Hailey-Hailey-like, in which there are numerous acantholytic cells overlying suprabasilar clefts; and, finally, spongiotic, in which a few acantholytic cells are present within, or contiguous with, spongiotic foci. Some cases show a predominance of one pattern, but more frequently two or more of these patterns can be found in a single biopsy specimen.

(*Arch Dermatol* 113:431-435, 1977)

Transient acantholytic dermatosis (TAD) was described in 1970.[1] In the original and subsequent[2] reports, the disease was characterized as pruritic and self-limited. The lesions were papules and/or papulovesicles and were predominantly distributed on the chest, back, and thighs of older persons. Results of histologic and electron microscopical examination showed either acantholysis that mimicked Hailey-Hailey disease,[3] or acantholysis and dyskeratosis that resembled Darier disease.[4] Ackerman has proposed the term "focal acantholytic dyskeratosis"[5] as an appropriate label for this latter general category of histologic change.

Transient acantholytic dermatosis has apparently become increasingly well recognized, as judged by our experience in private practice and by the patients sent to the dermatopathology laboratory of the New York University Medical Center. On the basis of our increased experience, we believe that some features of the original clinical description should be amended, and the histologic features should be described in more detail.

Accepted for publication June 28, 1976.

From the Departments of Dermatology (Drs Chalet and Ackerman) and Pathology (Dr Ackerman), New York University School of Medicine, New York, and the Nassau County Medical Center, East Meadow, NY (Dr Grover).

Reprints not available.

PATIENTS AND METHODS

For the clinical aspects of the study, 54 patients with TAD seen by one of us (R. W. G.) were reviewed. The clinical diagnosis was supported in each patient either by histologic[2,3] or cytologic[3,4] examination, or both. When a Tzanck smear showed acantholytic cells from a lesion of a patient with the clinical features of TAD, the diagnosis was deemed to be confirmed.

For the histologic portion of the study, we reviewed 40 cases of clinically diagnosed TAD. Of these, 19 came from the files of the dermatopathology laboratory of New York University Medical Center, and

Fig 1.—Discrete papulovesicular lesions on "V" of chest in elderly man.

Fig 2.—Closer view of lesions in Fig 1 showing edematous and crusted papules.

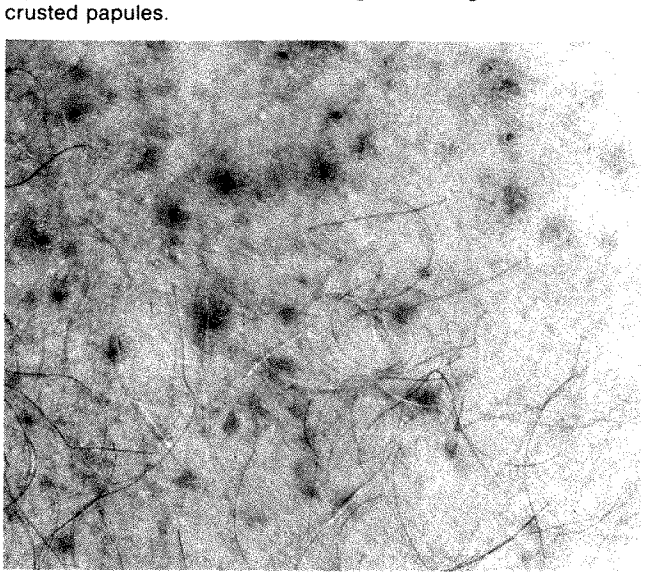

the rest were from the group used in the clinical study noted in the previous paragraph. Step sections were cut through the specimen in every case.

RESULTS
Clinical Features

The general characteristics previously reported[1,2] were confirmed. All of the patients, save one, were over age 40. The one exception was three months short of being 40 years old when his disease began. The course of the disease usually was relatively brief. In two of three patients it lasted from two weeks to three months, but it continued for a year or more in four instances. In one of these patients, the disease lasted for two years. Another patient (from the group of patients in the New York University records) still had his disease at the end of three years and has been reported elsewhere.[6]

The lesions of TAD occur primarily in four areas: about the clavicles, the lower anterior aspect of the rib cage, the upper portion of the chest (Fig 1), the back, and the lumbar area. The disease may begin in any of these areas and may remain limited to a few discrete papules or papulovesicles (Fig 2). When the eruption is more extensive, several or all of the areas may be involved, as may be the deltoids and the lateral aspects of the neck and thighs. Lesions affect the scalp infrequently and have not been seen to involve mucous membranes, palms, or soles.

The individual lesions of TAD vary from edematous papules or papulovesicles to keratotic and/or papules. The keratotic papules resemble those of Darier disease. Contrary to the impression given by the photographs in the original report,[1] the lesions are usually sparse and remain discrete. Confluence is infrequent. Because pruritus is common and is often severe, many papules may be excoriated.

The clinical characteristics of TAD are often subtle, and diagnosis requires a high index of suspicion. Transient acantholytic dermatosis may be mistaken for acne, seborrheic dermatitis, miliara rubra or folliculitis. In the more intensely pruritic patients, TAD may be confused with scabies

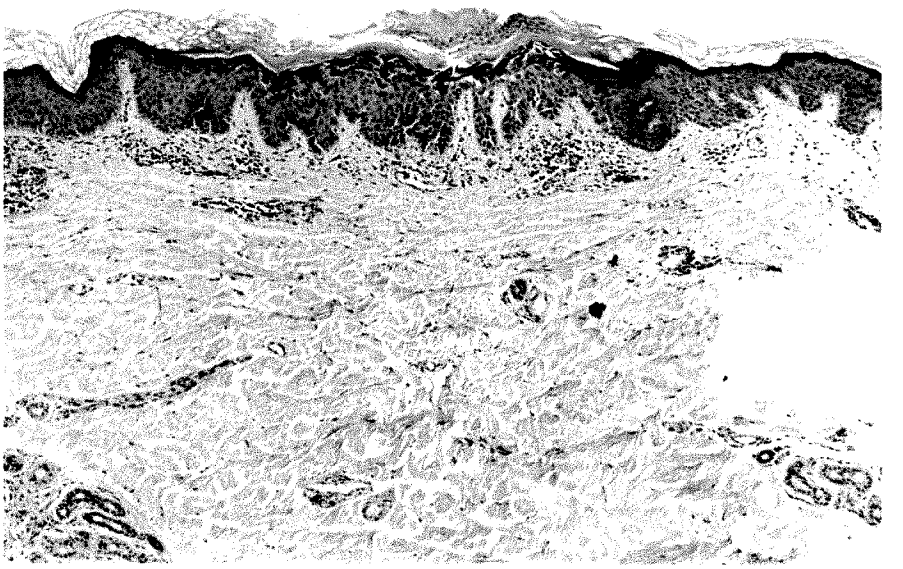

Fig 3.—Well-circumscribed focus of Darier-like changes in patient with transient acantholytic dermatosis (hematoxylin-eosin, original magnification ×16).

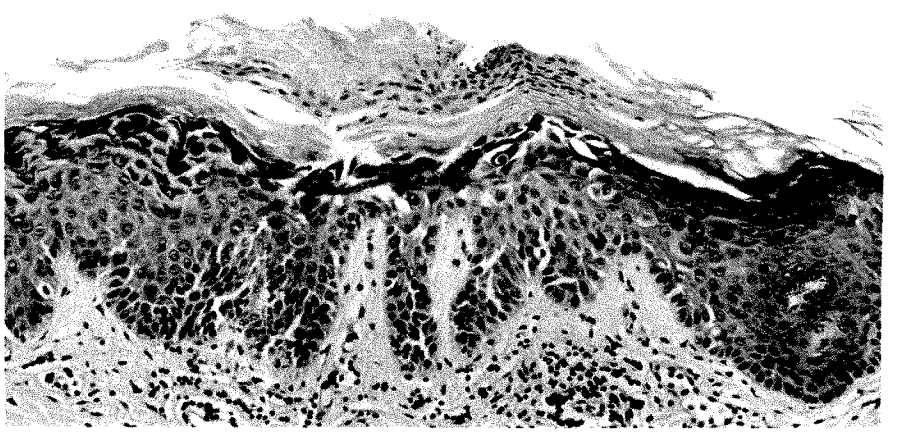

Fig 4.—View at higher power of changes shown in Fig 3 showing suprabasilar clefts and acantholytic, dyskeratotic cells in granular and spinous layers. Alternating vertical orthokeratosis and parakeratosis here seen is unusual in Darier disease (hematoxylin-eosin, original magnification ×40).

Fig 5.—Well-circumscribed foci of pemphigus vulgaris-like changes in patient with transient acantholytic dermatosis (hematoxylin-eosin, original magnification ×28).

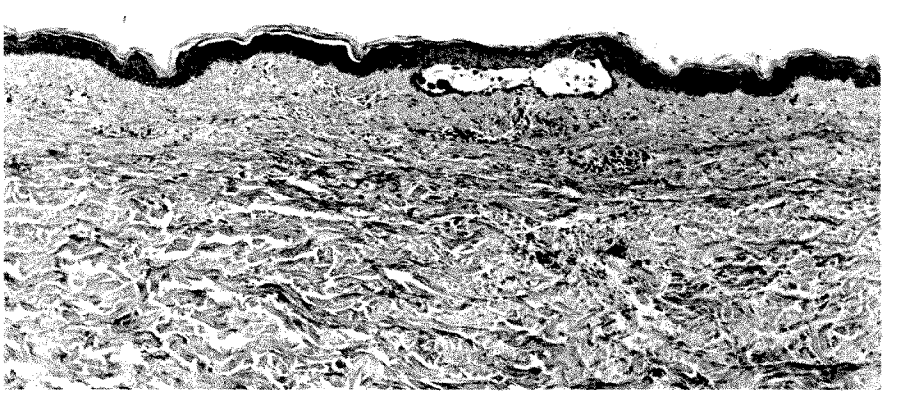

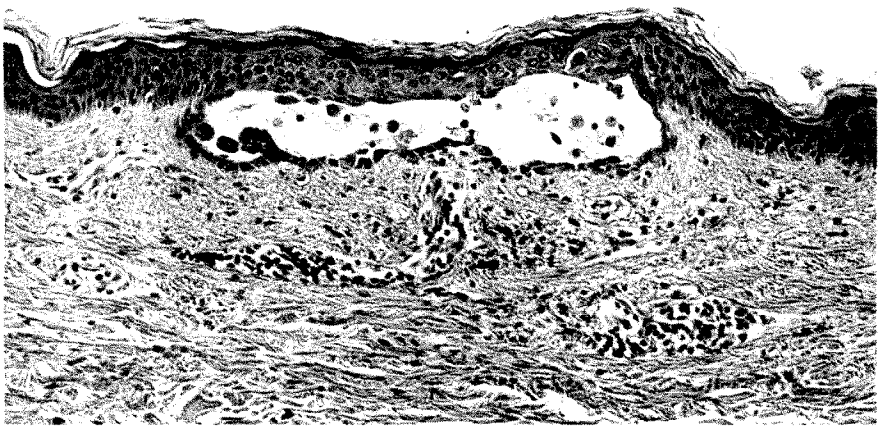

Fig 6.—View at higher power of changes in Fig 5 showing suprabasilar clefts and acantholytic cells beneath otherwise intact epidermis (hematoxylin-eosin, original magnification ×44).

Fig 7.—View at scanning power showing well-circumscribed foci of Hailey-Hailey-like changes in patient with transient acantholytic dermatosis (hematoxylin-eosin, original magnification ×40).

and dermatitis herpetiformis.

Eleven of the patients with TAD had been exposed to excessive natural sunlight during the month prior to the onset of their disease, usually during winter vacations in Florida. In only three did the disease start in the summer months.

TAD was associated with asteatotic dermatitis in six patients, and with psoriasis in eight others. In the latter group, three patients had eruptive psoriasis which had been triggered either by injudicious ultraviolet therapy or by an irritative reaction to anthralin.

Histologic Features

Four histologic patterns were seen within the epidermis. Two or more of these patterns might be found in the same specimen. The first of these histologic changes was a focal, acantholytic dyskeratosis resembling Darier disease (Fig 3 and 4). Above suprabasal clefts there were acantholytic and dyskeratotic cells at all levels of the epidermis, as well as parakeratosis. In some instances, the cornified layer had a normal basket-weave configuration. These Darier-like changes were seen by themselves in eight of the cases, and in association with other histologic patterns in five cases.

Fig 8.—View at higher power of changes in Fig 7 showing suprabasilar clefts and acantholytic cells at all levels of epidermis (hematoxylin-eosin, original magnification ×160).

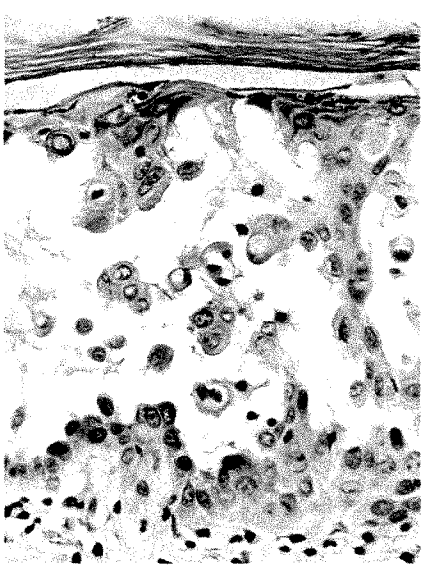

Fig 9.—Focal changes that resemble those of superficial pemphigus (foliaceous and erythematosus) in patient with transient acantholytic dermatosis (hematoxylin-eosin, original magnification ×40).

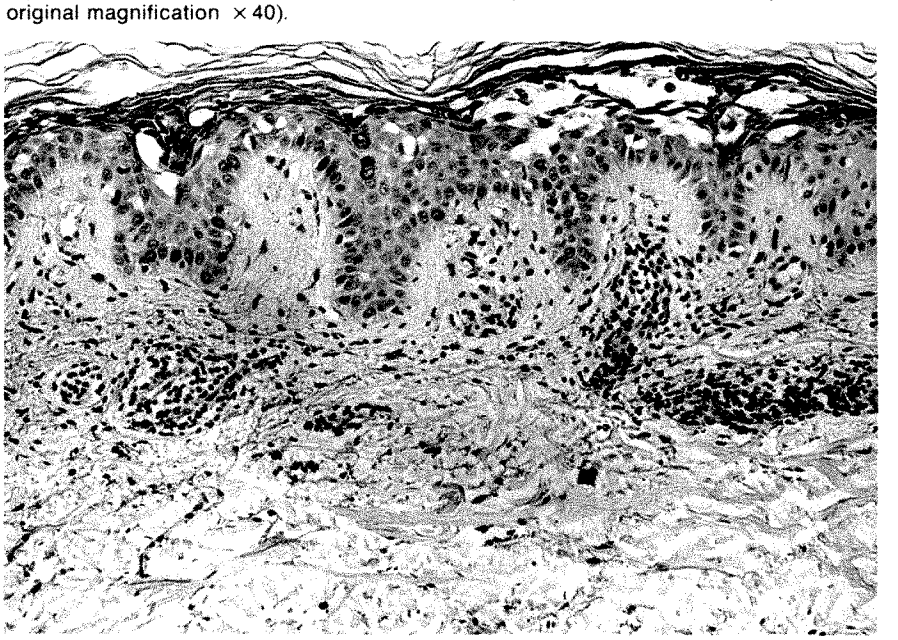

A second histologic pattern was similar to that of pemphigus vulgaris (Fig 5 and 6). There were focal suprabasal clefts, but little overlying acantholysis and no associated dyskeratosis. This pemphigus vulgaris-like change was an isolated finding in 11 cases and was seen in combination with other histologic changes in 12 cases.

A third histologic pattern resembled Hailey-Hailey disease (Fig 7 and 8). In addition to suprabasal clefts, there was abundant acantholysis through the overlying spinous layer. This pattern was found alone in only two cases, but was seen in combination with other histologic changes in three cases. Occasionally, acantholysis was seen only in the upper portion of the epidermis, thus resembling pemphigus foliaceous (Fig 9 and 10). These changes occurred in two of our cases and have also been reported elsewhere.

The fourth histologic pattern was basically spongiotic. Acantholytic cells were present within the spongiotic foci (Fig 11 and 12). Often there was slight intracellular edema in addition to the spongiosis and acantholysis. This spongiotic-acantholytic pattern was seen alone in only two cases, but was the pattern most frequently seen in combination with the other histologic patterns. In nine instances, the spongiotic-acantholytic changes were contiguous to pemphigus vulgaris-like changes. In three cases they were juxtaposed to Darier-like changes. Other combinations of the histologic patterns of TAD are summarized in the Table.

The changes within the dermis were less varied than those within the epidermis. In all cases there was a lymphohistiocytic infiltrate about the vessels of the superficial plexus. In eight of the cases, eosinophils were present within the infiltrate and were associated with spongiosis in all but one case. The changes in the dermis are summarized in the Table.

COMMENT

Transient acantholytic dermatosis is a common disease.[1] One should be alert to the possibility of the diagnosis in patients who are over 40 years old

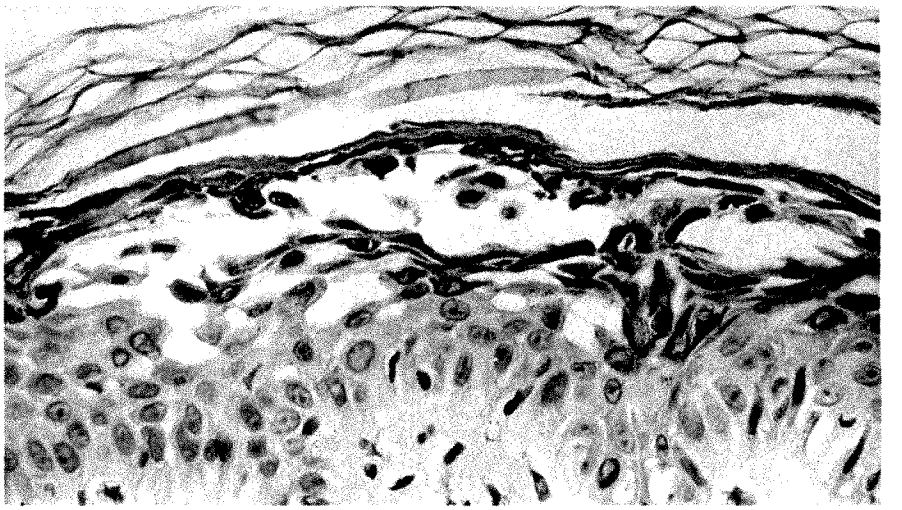

Fig 10.—View at higher power of changes in Fig 9 showing acantholytic cells in upper portion of epidermis (hematoxylin-eosin, original magnification ×100).

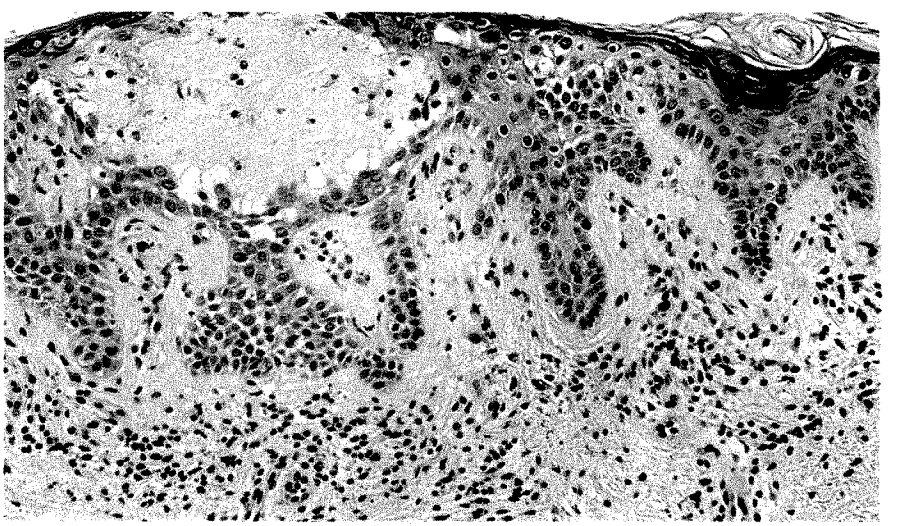

Fig 11.—Discrete focus of spongiosis and acantholysis in patient with transient acantholytic dermatosis (hematoxylin-eosin, original magnification ×40).

Fig 12.—View at higher power of Fig 11 showing acantholytic cells within spongiotic vesicle (hematoxylin-eosin, original magnification ×160).

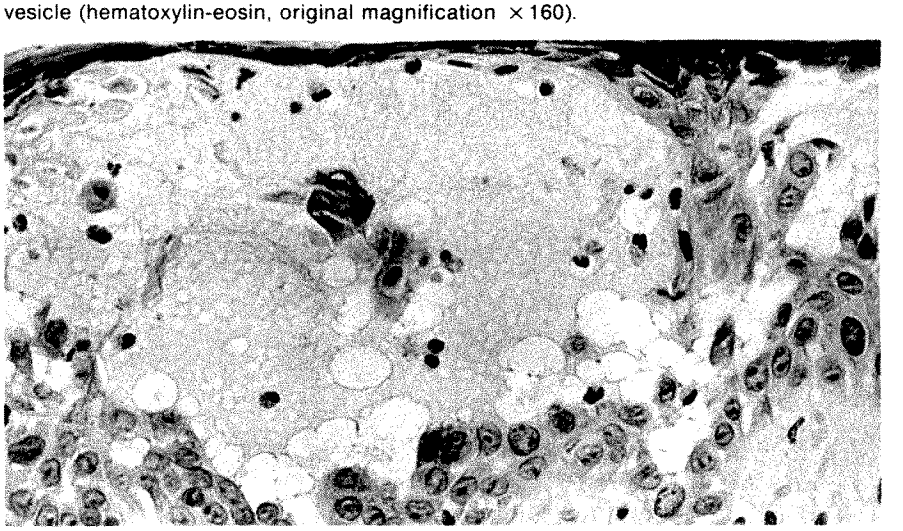

Analysis of Patients With Transient Acantholytic Dermatosis by Histologic Pattern

No. of Patients With Pattern	Histologic Pattern*			Sex		Age	
	Epidermal	Dermal: LH	Dermal: LH + E	M	F	< 60	> 60
11	PV	11	0	7	4	5	6
8	D	8	0	7	1	4	4
2	HH	2	0	2	0	1	1
2	Sp-Ac	0	2	2	0	0	2
9	PV-Sp-Ac	6	3	7	2	4	5
3	D-Sp-Ac	2	1	2	1	2	1
2	PV-HH-Sp-Ac	2	0	1	1	0	2
1	PV-D-Sp-Ac	1	0	1	0	1	0
1	D-HH-Sp-Ac	0	1	1	0	0	1
1	FAD-Intraepidermal pustule	0	1	1	0	0	1
Total 40		32	8	...	...	...	...

*D indicates Darier-like pattern; PV, pemphigus vulgaris-like pattern; HH, Hailey-Hailey-like pattern; Sp-Ac, spongiotic acantholytic pattern; LH, lymphohistiocytic infiltrate; E, eosinophils.

who have pruritic papular or papulovesicular lesions of the trunk, especially if the pruritus is out of proportion to the apparent clinical disease.

The inordinate persistence of the disease in some patients has cast some shadow on the propriety of characterizing it as "transient." This is especially true of the patient reported by Simon et al,[6] and the group of patients presented by Heaphy et al[8] under the term "benign papular acantholytic dermatosis" but which appears in our opinion, to be TAD. Since the majority of patients with TAD have a brief course and since the patient with persistent disease is the exception rather than the rule, we believe that the allusion to transience is still valid, especially when the disease is compared with the essentially life-long genodermatoses with which it is apt to be confused histologically.

From the pathologist's viewpoint, TAD has diverse histologic patterns with the unifying feature of acantholysis. Acantholysis can appear at any level of the epidermis and can be accompanied by dyskeratosis. Our study indicates that at least four identifiable patterns may be found in transient acantholytic dermatosis: Darier-like, pemphigus vulgaris-like, Hailey-Hailey-like, and spongiotic-acantholytic. These patterns may occur singly or in combination. The variability of the acantholytic phenomenon as expressed in TAD is witnessed in other acantholytic processes, such as pemphigus vulgaris. A single biopsy specimen from a patient with indubitable pemphigus vulgaris may show, in addition to the typical histologic findings of that disease, features of pemphigus foliaceus and Hailey-Hailey disease.

Some cases of TAD are indistinguishable histologically from Darier disease. When the cornified layer has a normal basket-weave pattern or slight parakeratosis rather than prominent focal vertical parakeratosis, or when there is associated spongiosis, the diagnosis is more likely to be TAD rather than Darier disease.

In those forms of TAD that resemble pemphigus vulgaris or Hailey-Hailey disease, a critical point of distinction is the focal nature of the lesion of TAD. In pemphigus vulgaris and Hailey-Hailey disease, the acantholytic change usually occupies the entire breadth of the specimen, whereas the acantholytic changes in TAD are highly circumscribed. This change, of course, is consonant with the clinical pattern of the former two diseases in which a substantial blister is the primary lesion, in contradistinction to the discrete papules and papulovesicles of TAD.

Another clue to the diagnosis of TAD is the association of acantholysis with spongiosis. In our experience, TAD is the only disease in which this association can be noted by light microscopy.

References

1. Grover RW: Transient acantholytic dermatosis. *Arch Dermatol* 101:426-434, 1970.
2. Grover RW: Transient acantholytic dermatosis. Proceedings of the 14th International Congress, Padua-Venice, 1972. Amsterdam, Excerpta Medica, 1974.
3. Grover RW: Transient acantholytic dermatosis: Electron microscope study. *Arch Dermatol* 104:26-37, 1971.
4. Grover RW, Duffy JL: Transient acantholytic dermatosis: Electron microscopic study of the Darier type. *J Cutaneous Pathol* 2:111-127, 1975.
5. Ackerman AB: Focal acantholytic dyskeratosis. *Arch Dermatol* 106:702-706, 1972.
6. Simon R, Bloom D, Ackerman AB: Persistent acantholytic dermatosis: A variant of transient acantholytic dermatosis (Grover disease). *Arch Dermatol* 112:1429-1431, 1976.
7. Waisman M, Stewart JJ, Walker AE: Bullous transient acantholytic dermatosis. *Arch Dermatol* 112:1440-1441, 1976.
8. Heaphy MR, Tucker SB, Winkelmann RK: Benign papular acantholytic dermatosis. *Arch Dermatol* 112:814-821, 1976.

Incidence of Skin Carcinoma After Renal Transplantation

Eugene O. Hoxtell, MD; Jack S. Mandel, MPH;
Samuel S. Murray; Leonard M. Schuman, MD, MS; Robert W. Goltz, MD

• The development of de novo malignant neoplasms after renal transplantation continues to be of importance. The incidence of skin cancer in the renal transplant population at the University of Minnesota Hospital is compared with that expected on the basis of rates from the special nonmelanoma part of the Third National Cancer Survey. Overall, the risk of skin cancer in the renal transplant population was 7.1 times that expected. This excess was due primarily to squamous cell carcinomas, which were 36.4 times as frequent as expected.

(*Arch Dermatol* 113:436-438, 1977)

More than 16,000 patients undergoing kidney transplants have now been registered with the American College of Surgeons/National Institutes of Health Renal Transplant Registry. Of these recipients, 6,781 are still alive with a functioning graft. The development of de novo malignant neoplasms after renal transplantation continues to be of importance.[1] Two types of neoplasms account for most of the malignancies: lymphomas and epidermoid carcinomas. By comparison with cancer registry data, the risk of a renal transplant recipient developing a lymphoma has been calculated to be 35 times that of the normal population.[2] For reticulum cell sarcoma, the incidence was 350 times greater than the normal population.[2] Skin and lip cancers occurred up to four times more often than expected.[2] In the study by Hoover and Fraumeni, the patients that underwent renal transplants were reported to the Human Renal Transplant Registry (American College of Surgeons) from throughout the country. To compute expected values of skin cancers, data from the nonmelanotic skin cancer survey conducted as part of the Third National Cancer Survey (TNCS) were used.[3] Since only four areas of the country were included in the TNCS, it was necessary to compute a range of expected values, using first a low-incidence area of the survey and then a high-incidence area.

This skin cancer survey, which is the most comprehensive to date, was carried out from Sept 1, 1971, to Feb 29, 1972, in four of the nine areas participating in the TNCS. The five-county Minneapolis-St Paul Standard Metropolitan Statistical Area (SMSA) with a population of 1,813,647 (1,763,769 Caucasians) was one of the areas included in this skin cancer survey. Since most patients with skin cancer are seen and treated in physicians' offices and usually are not hospitalized, the ascertainment of cases was accomplished through surveillance of physicians' offices.

This study compares the incidence of nonmelanotic skin cancer in the renal transplant population at the University of Minnesota with that expected on the basis of rates from

Accepted for publication Oct 6, 1976.

From the Department of Dermatology (Drs Hoxtell and Goltz) and the Division of Epidemiology, School of Public Health (Messrs Mandel and Murray and Dr Schuman), University of Minnesota Medical School, Minneapolis.

Reprint requests to Department of Dermatology, Box 98 Mayo, University of Minnesota Hospitals, Minneapolis, MN 55455 (Dr Hoxtell).

Observed and Expected Numbers of Cutaneous Tumors, Risk Ratios, and 95% Confidence Intervals (CI) for Men and Women Undergoing Renal Transplants

	Men			Women			Total		
Carcinoma	Observed	Expected	Risk Ratio and 95% CI	Observed	Expected	Risk Ratio and 95% CI	Observed	Expected	Risk Ratio and 95% CI
Squamous cell	4	0.08	50.0* (13.6-127.9)	0	0.03	0.0	**4**	0.11	36.4* (9.9-93.1)
Basal cell	0	0.56	0.0	3	0.32	9.4* (1.9-27.5)	**3**	0.88	3.4 (0.7-9.9)
Total	**4**	**0.64**	6.3* (1.7-16.1)	**3**	**0.35**	8.6† (1.8-25.2)	**7**	**0.99**	7.1* (2.9-14.6)

*$P < .01$.
†$P < .05$.

the Minneapolis-St Paul component of the nonmelanotic skin cancer survey. It avoids one of the problems experienced by previous studies, namely, the use of inappropriate skin cancer rates to compute expected values for comparison with patients that undergo renal transplants.[2-4]

SUBJECTS AND METHODS

The study population consisted of all patients who had a renal transplant between Jan 1, 1968, and Dec 31, 1974, at the University of Minnesota. All newly diagnosed cutaneous tumors that occurred through September 1975 were ascertained from the renal transplantation registry. Records of each of these patients were examined, and, when possible, the patient was seen and examined.

For analysis, the patients that underwent renal transplants were divided into ten-year age groups separated by sex. The number of person-years of risk was computed. The expected number of skin cancers was obtained by applying the age-sex-specific incidence rates from the special survey of nonmelanotic skin cancers in the Minneapolis-St Paul SMSA.

The expected numbers of skin cancers were summed, and the totals compared with the observed numbers by means of risk ratios (observed/expected). A significance test was applied by comparing the observed number with its expectation under the Poisson assumption.[5]

RESULTS

Seven cases of skin cancer were diagnosed during the study period among the 495 patients that underwent renal transplants. Four of seven (57%) cases were squamous cell carcinomas, whereas in the TNCS data, only 14% of the skin cancers were of this cell type.

Overall, the risk of skin cancer was 7.1 times that expected for both men and women (Table). This excess was due primarily to the squamous cell carcinomas, which were 36.4 times that expected. The risk ratio for basal cell carcinomas was statistically significant ($P < .01$) only for women. We have no explanation for this difference. It is likely that it is secondary to the small number of cases available for study.

The mean age of the seven patients with cutaneous carcinomas was 48 years (range, 35 to 64 years). The mean time from transplantation to diagnosis of first cutaneous carcinoma was 43.4 months (range, 18 to 66 months).

Four of the seven patients had more than one cutaneous carcinoma diagnosed. The seven patients had a total of 17 cutaneous carcinomas: thus, the mean number of carcinomas was 2.43 per patient. In the TNCS, the mean number of lesions was 1.09 carcinomas per patient. Data on the baseline population are not available to do a detailed age- and sex-adjusted comparison of the occurrence of multiple carcinomas. All of the multiple carcinomas were squamous cell carcinomas located on sun-exposed areas of the body. One patient had six squamous cell carcinomas of the head and neck area during an 18 month period. Two other patients had three squamous cell carcinomas each; these also were on sun-exposed areas.

This study confirms the previously reported finding of an increased risk of skin cancer among patients undergoing renal transplants. Rates used to compute expected values can be considered more appropriate than those used in previous studies. In our study, most of the patients that underwent renal transplants were residents of the Minneapolis-St Paul SMSA and the skin cancer survey component of the TNCS was conducted around the midpoint of the study period. Therefore, use of these data to compute expected values avoids some of the potential problems encountered in previous studies.

The relatively small number of observed skin cancers must be considered in interpreting the results. Likewise, the fact that the renal transplant recipients are a closely followed up population must be considered. Nevertheless, the substantial increase in incidence of cutaneous malignant neoplasms observed in this renal transplant population is compatible with previous studies. This finding is also compatible with the increase of malignant neoplasms noted among patients with naturally occurring impairment of immunity, particularly in those with deficiencies of cell-mediated immunity.[6-9] Malignant neoplasms also have been observed in patients not undergoing renal transplants who have received immunosuppressive agents for other therapeutic purposes.[10-13] Included in these groups are several patients with cutaneous carcinomas.

The theory of immunologic surveillance was predicted by Paul Ehrlich in 1908, when he stated, "in the enormously complicated course of fetal and post-fetal development aberrant cells become unusually common. Fortunately in the majority of people they remain completely latent thanks to the organisms' positive mechanisms."[14] Tumor-specific antigens and both humoral and cell-mediated

immunity have been demonstrated in several human neoplasms.[15] Experimental animal studies have also showed that the interference with development of immunologic competency by thymectomy facilitates the development of neoplasms induced by both chemical carcinogens[16] and of neoplasms induced by oncogenic viruses.[17] It has been suggested that in addition to the immunosuppressive agents administered to renal transplant recipients, a further anergy induced by antigen load, namely, the grafted organ, may be of importance.[18]

A number of published reports have discussed de novo cutaneous malignant neoplasms occurring in renal transplant recipients.[13,19-24] From these reports and the present study, a number of conclusions can be drawn. The cutaneous malignant neoplasms occur primarily on sun-exposed areas. The incidence appears to be higher in areas of greater sun exposure. The risk appears to increase with time from transplantation. Multiple carcinomas in the same patient are common, and squamous cell carcinomas outnumber basal cell carcinomas.

Studies leading to this publication were supported in part by funds from Public Health Service training grant T01 AM 05560.

References

1. The 12th report of the Human Renal Transplant Registry, Advisory Committee to the Renal Transplant Registry. *JAMA* 233:787-796, 1975.

2. Hoover R, Fraumeni JF: Risk of cancer in renal-transplant recipients. *Lancet* 2:55-57, 1973.

3. Scotto J, Kopf AW, Urbach F: Non-melanoma skin cancer among Caucasians in four areas of the United States. *Cancer* 34:1333-1338, 1974.

4. Matas AJ, Simmons RL, Kjellstrand CM, et al: Increased incidence of malignancy during chronic renal failure. *Lancet* 1:833-840, 1975.

5. Bailar JC, Ederer F: Significance factors for the ratio of a Poisson variable to its expectation. *Biometrics* 20:639-643, 1964.

6. Miller DG: The association of immune disease and malignant lymphoma. *Ann Intern Med* 66:507-521, 1967.

7. Waldmann TA, Strober W, Blaese RM: Immunodeficiency disease and malignancy: Various immunologic deficiencies of man and the role of immune processes in the control of malignant disease. *Ann Intern Med* 77:605-628, 1972.

8. Gatti RA, Good RA: Occurrence of malignancy in immunodeficiency disease: A literature review. *Cancer* 28:89-98, 1971.

9. Cammarata RJ, Rodnan GP, Jensen WN: Systemic rheumatic disease and malignant lymphoma. *Arch Intern Med* 111:330-337, 1963.

10. Craig SR, Rosenberg EW: Methotrexate-induced carcinoma? *Arch Dermatol* 103:505-506, 1971.

11. Harris CC: Malignancy during methotrexate and steroid therapy for psoriasis. *Arch Dermatol* 103:501-504, 1971.

12. Klein MD, Pereira FA, Kantor I: Kaposi's sarcoma complicating systemic lupus erythematosus treated with immunosuppression. *Arch Dermatol* 110:602-607, 1974.

13. Marshall V: Premalignant and malignant skin tumors in immunosuppressed patients. *Transplantation* 17:272-275, 1974.

14. Ehrlich P, quoted by Schwartz RS: Current concepts: Another look at immunologic surveillance. *N Engl J Med* 293:181-184, 1975.

15. Hellstrom I, Hellstrom KE, Sjogren HO, et al: Demonstration of cell-mediated immunity to human neoplasms of various histologic types. *Int J Cancer* 7:1-16, 1971.

16. Miller JFAP, Grant GA, Roe FJC: Pathology-effect of thymectomy on the induction of skin tumors by 3 4-Benzopyrene. *Nature* 199:920-922, 1963.

17. Law LW: Immunologic responsiveness and the induction of experimental neoplasms. *Cancer Res* 26:1121-1132, 1966.

18. Kantor FS: Infection, anergy and cell-mediated immunity. *N Engl J Med* 292:629-634, 1975.

19. Koranda FC, Dehmel EM, Kahn G, et al: Cutaneous complications in immunosuppressed renal homograft recipients. *JAMA* 229:419-424, 1974.

20. Penn I, Starzl TE: Malignant tumors arising de novo in immunosuppressed organ transplant recipients. *Transplantation* 14:407-417, 1972.

21. Penn I, Starzl TE: A summary of the status of de novo cancer in transplant recipients. *Transplant Proc* 4:719-732, 1972.

22. Walder BK, Robertson MR, Jeremy D: Skin cancer and immunosuppression. *Lancet* 2:1282-1283, 1971.

23. Berger HM, Goldman R, Bunick HC, et al: Epidermoid carcinoma after renal transplantation. *Arch Intern Med* 128:609-612, 1971.

24. Westburg SP, Stone OJ: Multiple cutaneous squamous cell carcinomas during immunosuppressive therapy. *Arch Dermatol* 107:893-895, 1973.

Curettage-Electrodesiccation Treatment of Basal Cell Carcinomas

Alfred W. Kopf, MD; Robert S. Bart, MD; David Schrager; Mark Lazar; George L. Popkin, MD

• Cure rates after treatment of basal cell carcinomas with curettage-electrodesiccation were compared among three groups: group A, 597 lesions treated in the Skin and Cancer Unit in 1958 to 1962; group B, 91 lesions treated in the Skin and Cancer Unit in 1970; and group C, 210 lesions treated in private practice in 1962 to 1973. The following were the five-year cumulative recurrence rates: group A, 18.8%; group B, 9.6%; and group C, 5.7%. In all three groups, there were high recurrence rates for tumors treated on the nose, paranasal areas, and forehead.

Few complications occurred after curettage-electrodesiccation with the exception of hypertrophic scars. The cosmetic results following curettage-electrodesiccation improved with time.

Curettage-electrodesiccation, when performed by experienced physicians, is a very useful modality for the treatment of basal cell carcinomas, with cure rates of over 90%, satisfactory cosmetic results, and few significant complications.

***(Arch Dermatol* 113:439-443, 1977)**

The procedure of curettage-electrodesiccation is the most frequently used method for the treatment of basal cell carcinomas in the Skin and Cancer Unit. Of the 3,033 consecutive, histologically-proved, coded lesions of this type first seen from 1955 to 1967, 51.6% were treated by curettage-electrodesiccation; 25.7% were treated by x-radiation, 17.3% by excision, and 5.4% by other methods.

Some authors have stressed the importance of experience in the technique of curettage-electrodesiccation.[1,2] The present study is a comparison of the results achieved with curettage-electrodesiccation of 688 histologically-verified basal cell carcinomas treated in our clinic with the results in 210 lesions treated in private practice.

Accepted for publication July 26, 1976.

From the Department of Dermatology, New York University School of Medicine, and the Oncology Section, Skin and Cancer Unit, New York University Medical Center, New York.

Reprints not available.

MATERIALS AND METHODS

A total of 898 histologically proved basal cell carcinomas treated by curettage-electrodesiccation in the Skin and Cancer Unit and in the private practices of two of the authors were reviewed. There were three groups of lesions as follows: group A, 597 lesions (in 477 patients) coded and treated in the clinic during 1958 to 1962; group B, 91 lesions (in 69 patients) coded and treated in the clinic in 1970; and group C, 210 tumors (in 92 patients) combined from the active files of the private practices of two of the authors (AWK and RSB) treated during 1962 to 1973.

Table 1 shows the number of lesions per patient in each of the three groups. Table 2 summarizes the anatomic locations (head and neck versus trunk and extremities) of the lesions.

Groups A, B, and C were compared for cumulative recurrence rates using a modification of the life-table method of Cutler and Ederer.[3] The value of this method lies in its ability to utilize follow-up information on patients who have been observed for varying lengths of time. When the data were insufficient to employ this method, a raw recurrence rate was determined by dividing the number of recurrences by the total number of lesions treated in that category or subgroup. For raw recurrence rates, all recurrences were included, regardless of when they were discovered. Thus, a recurrence found 15 years after curettage-electrodesiccation would be included in raw recurrence rates but not in the cumulative recurrence rates that were calculated to only five years. Therefore, in group A, 108 recurrences are reflected in calculations of raw recurrence rates, and only 93 in the five-year cumulative recurrence rate (Table 3). Raw recurrence rates were determined for various anatomic sites and lesion sizes. The results of retreating recurrences with various modalities were analyzed.

RESULTS

Comparison Between Clinic and Private Patient Groups

Table 1 shows that in this study there was a much lower percentage of lesions from clinic patients with multiple basal cell carcinomas (group A, 34.2%; group B, 27.5%) as compared to the percentage of lesions from private patients with multiple basal cell carcinomas (group C, 77.1%). Furthermore, as shown in Table 2, there was a substantially lower percentage of treated lesions on the trunk and extremities in the clinic patients (group A, 17%; group B, 33%) than in the private patients (group C, 48%).

Recurrences

Table 3 shows the cumulative recurrence rates for the clinic groups for the first five years of follow-up. The five-year cumulative recurrence rate for group A was 18.8% and that for group B was 9.6%. Table 3 also shows the five-year cumulative recurrence rate for the private-practice group which was 5.7%.

Table 4 compares the raw recurrence rates of tumors grouped according to their largest diameters. There is a general trend toward increasing recurrence rates with in-

Table 1.—Number of Histologically Verified Basal Cell Carcinomas per Patient in Clinic and Private Patient Groups

Lesions	Group A (Clinic: 1958-1962) No. of Patients	Group A (Clinic: 1958-1962) Total Lesions	Group B (Clinic: 1970) No. of Patients	Group B (Clinic: 1970) Total Lesions	Group C (Private Practices) No. of Patients	Group C (Private Practices) Total Lesions
1	393	393	50	50	48	48
2	61	122	16	32	23	46
3	16	48	3	9	8	24
4	4	16			3	12
5	0	0			0	0
6	3	18			3	18
7					3	21
8					2	16
9					1	9
10 or more					1	16
Totals	**477**	**597**	**69**	**91**	**92**	**210**

Table 2.—Anatomic Distribution of the Basal Cell Carcinomas in the Three Groups

Location of Carcinomas	Group A (Clinic: 1958-1962)	Group B (Clinic: 1970)	Group C (Private Practices)
Head and neck	495 (83%)	61 (67%)	109 (52%)
Trunk and extremities	102 (17%)	30 (33%)	101 (48%)
Total	**597 (100%)**	**91 (100%)**	**210 (100%)**

creasing tumor diameters; however, there were no recurrences in the private practice group for lesions over 20 mm in diameter.

Table 5 shows the raw recurrence rates for lesions on the forehead, cheek, nasal-paranasal, and trunk extremity areas as compared to all other areas. In all three groups, recurrence rates were high on the forehead (group A, 20.5%; group B, 18.2%; group C, 12.5%), and low on the trunk and extremities (group A, 8.8%; group B, 3.3%; group C, 2.0%). On the other anatomic sites, the recurrence rates varied widely among the three groups.

Retreatment of Recurrences

Table 6 outlines how the recurrences in group A (clinic, 1958 to 1962) were retreated and the results at final examination. These data can be summarized as follows:

1. Out of 597 lesions, there were 108 recurrences (18.1% raw rate).
2. Of the 57 lesions where curettage-electrodesiccation was the meth-

Table 3.—Cumulative Recurrence Rates for Groups A Through C

Years of Exposure Risk After Treatment	No. of Lesions At Start of Period* (a)	Lost in Year (b)	Years of Exposure to Risk of Those Lost to Follow-up (c)†	Total Years of Exposure to Risk in This Period (d) = (a)—(c)	Recurrences in Year (e)	Annual Recurrence Rate (f) = (e) ÷ (d)	Rate of No Recurrence (g) = 1—(f)	Cumulative Rate of No Recurrence (h)‡	Cumulative Rate of Recurrence (i) = 1—(h)
Group A (clinic: 1958-1962)									
0-0.99	597	74	37	560	45	.0804	.9196	.9196	.0804
1-1.99	478	38	19	459	17	.0370	.9830	.8850	.1144
2-2.99	423	36	18	405	14	.0346	.9654	.8550	.1450
3-3.99	373	46	23	350	12	.0343	.9657	.8257	.1743
4-4.99	315	23	11.5	303.5	5	.0165	.9835	.8121	.1879§
Group B (clinic: 1970)									
0-0.99	91	7	3.5	87.5	6	.0686	.9314	.9314	.0686
1-1.99	78	6	3.0	75.0	0	.0000	1.000	.9314	.0686
2-2.99	72	10	5.0	67.0	0	.0000	1.000	.9314	.0686
3-3.99	62	12	6.0	56.0	0	.000	1.000	.9314	.0686
4-4.99	50	32	16.0	34.0	1	.0294	.9706	.9040	.0960§
Group C (private practices)									
0-0.00	210	23	11.5	198.5	2	.0101	.9899	.9899	.0101
1-1.99	185	27	13.5	171.5	3	.0175	.9825	.9726	.0274
2-2.99	155	38	19.0	136.0	2	.0147	.9853	.9583	.0417
3-3.99	115	40	20.0	95.0	0	.0000	1.000	.9583	.0417
4-4.99	75	24	12.0	63.0	1	.0159	.9841	.9431	.0569§

*Number of lesions at start of previous year less those lost (b) and less those which recurred (e) in previous year.
†Total years of exposure of those lost in period computed to the fraction of the year followed.
‡Rate of no recurrence (g) times cumulative rate of no recurrence in the previous year (h).
§Standard error = ±0.0179 (group 1); ±0.0376 (group 2); and ±0.0214 (group 3).[3]

od of retreatment, 28 (49%) recurred at least once more.

3. Of the 20 lesions where surgical excision was the method of retreatment, four (20%) recurred at least once more.

4. Of the 18 lesions where x-ray therapy was the method of retreatment, two (11%) recurred at least once more.

5. Of the five lesions where chemosurgery was the method of retreatment, no second recurrences were observed.

6. The overall incidence of second recurrences was 34.0% (35 out of 103 lesions).

7. Of the 28 second recurrences following curettage-electrodesiccation, 21 were eventually cured and 7 had tumor at the time of last examination.

8. Of the four second recurrences following excision, two were eventually cured, and two had tumor at the time of last examination.

9. Of the two second recurrences following x-ray treatment, one was eventually cured and the other had tumor at the time of last examination.

10. The overall eventual cure rate (no recurrence at last observation) of the 103 recurrent basal cell carcinomas was 89.3%.

Of the 597 lesions that were followed after definitive treatment of the original tumor, or of their recurrences, only 16 (including the 5 lost to follow-up) had tumor present at the last examination. Thus, at last observation, 97.3% of the lesions showed no evidence of recurrence.

Table 4.—Recurrences by Size

Largest Diameter (mm)	Lesions	Total Lesions, %	Recurrences	Recurrence Rates, %
Group A (clinic: 1958-1962)				
1 to 5	150	25.1	24	16.0
6 to 10	261	43.7	40	15.3
11 to 15	94	15.7	24	25.5
16 to 20	45	7.5	8	17.8
Over 20	47	7.9	12	25.5
Totals	**597**	**100.0**	**108**	**18.1**
Group B (clinic: 1970)				
1 to 5	15	16.5	1	6.7
6 to 10	32	35.2	1	3.1
11 to 15	25	27.5	2	8.0
16 to 20	10	11.0	1	10.0
Over 20	9	9.9	2	22.2
Totals	**91**	**100.0**	**7**	**7.7**
Group C (private practices)				
1 to 5	69	32.9	4	5.8
6 to 10	105	50.0	2	1.9
11 to 15	24	11.4	1	4.2
16 to 20	7	3.3	1	14.3
Over 20	5	2.4	0	0.0
Totals	**210**	**100.0**	**8**	**3.8**

Table 5.—Recurrences by Site

Sites	Lesions	Total Lesions, %	Recurrences	Recurrence Rates, %
Group A (clinic: 1958-1962)				
Forehead	88	14.7	18	20.5
Cheek	124	20.8	28	22.5
Nose & paranasal	186	31.2	41	22.0
Trunk & extremities	102	17.1	9	8.8
All other	97	16.2	12	12.4
Totals	**597**	**100.0**	**108**	**18.1**
Group B (clinic: 1970)				
Forehead	11	12.1	2	18.2
Cheek	13	14.3	1	7.7
Nose & paranasal	14	15.4	1	7.1
Trunk & extremities	30	33.0	1	3.3
All other	23	25.3	2	8.7
Totals	**91**	**100.0**	**7**	**7.7**
Group C (private practices)				
Forehead	32	15.2	4	12.5
Cheek	45	21.4	0	0.0
Nose & paranasal	32	15.2	2	6.25
Trunk & extremities	101	48.1	2	2.0
All other	0	0	0	0
Totals	**210**	**100.0**	**8**	**3.8**

Cosmetic Results After Treatment of Nonrecurrent Lesions in Group A

The cosmetic appearance of the treated site is evaluated at the time of each return visit to the clinic and designated as excellent, good, fair, or poor. When the treated area cannot be easily distinguished from the surrounding untreated skin, the result is considered "excellent." A "poor" result is an unsightly alteration of the skin. "Fair" and "good" refer to results that are intermediate between these extremes. The cosmetic results used for analysis were the ones recorded at the time of last examination. Table 7 reveals that cosmetic results tend to improve with time. Excellent or good cosmetic results were observed in 47% of the lesions within the 1st year of treatments, in 78% in the 3rd year after treatment, and in 83% in the 10th to 15th years.

Sequelae and Complications in Group A

The wound produced by the curettage-electrodesiccation procedure heals by secondary intention and results in scarring of varying degree. The commonest complication following curettage-electrodesiccation is a thickened scar, which occurred in 98 of the 597 treatment sites (Table 8). The distinction between hypertrophic scar and keloid is a matter of clinical judgment. In a true keloid, the exuberant scarring spreads beyond the area treated and usually persists indefi-

Table 6.—Results in Group A (Clinic: 1958-1962; 597 Lesions) of Retreatment of the 103 Recurrent Basal Cell Carcinomas*

Retreatment Modality	Result of First Retreatment		Final Result of 35 Second Recurrences	
	No Recurrence	Rerecurrence	Tumor Absent at Last Examination	Tumor Present at Last Examination
C & D 57	29 (51%)	28 (49%)	21	7
Excision 20	16 (80%)	4 (20%)	2	2
X-ray 18	16 (89%)	2 (11%)	1	1
Mohs' surgery 5	5 (100%)	0 (0%)	0	0
Other treatments 3	2 (66.6%)	1 (33.3%)	0	1
Total 103	**68 (66.0%)**	**35 (34.0%)**	**24 (68.6%)**	**11 (31.4%)**

*Excludes the five patients that did not return for retreatment.

Table 7.—Cosmetic Results vs Length of Follow-up Group A (Clinic: 1958-1962)*

Years of Follow-up	No. Lesions	Cosmetic Results, %				
		Excellent	Good	Fair	Poor	Not Stated
0-0.99	70	13	34	9	1	43
1-1.99	28	25	46	14	4	11
2-2.99	33	33	39	9	3	15
3-3.99	40	18	60	13	8	3
4-4.99	23	22	65	4	0	4
5-5.99	30	27	60	3	0	10
6-6.99	42	10	60	17	0	14
7-7.99	27	22	56	11	0	11
8-8.99	26	15	69	15	0	0
9-9.99	20	20	60	5	0	15
10-14.99	106	16	67	8	0	8
15+	11	9	27	18	0	45
Total Study	**456**	**18**	**55**	**10**	**2**	**15**

*Excludes 108 patients who had recurrences and 33 patients who did not return for evaluation of cosmetic results.

nitely whereas hypertrophic scars are confined to the treated area and often involute spontaneously in a year or so.

Other complications were much less frequent and included hypopigmentation, atrophy, and persistent erythema.

COMMENT

One is struck by the very high five-year recurrence rate (18.8%) of basal cell carcinomas treated by curettage-electrodesiccation in group A (clinic: 1958 to 1962) compared to that (5.7%) seen in group C (private practice). The recurrence rate in group B (clinic: 1970) was intermediate (9.6%). Previously published series have reported recurrence rates ranging from a high of 12.3%[1] to a low of 2.5%[5] with the technique of curettage-electrodesiccation (see Table 9).

There are several plausible explanations for the marked difference in the recurrence rates between group A (clinic patients) and group C (private patients). The first is the selection of lesions. In the oncology section of the clinic, physicians code only one or a few lesions if the patient has numerous basal cell carcinomas. Therefore, the less impressive lesions may not enter into the statistics, and the bias is toward inclusion of the more difficult-to-cure tumors. In comparison, group C included all basal cell carcinomas in the active files of the two private practices.

Another possible factor contribut-

Table 8.—Complications (Excluding Recurrences)—Group A*

Type of Complication	No. of Lesions	Percent of Lesions
Hypertrophic scars	91	15.2
Keloids (probable)	7	1.1
Hypopigmentation	2	0.3
Depigmentation	1	0.2
Atrophic scar	1	0.2
Erythema	1	0.2
Total	**103**	**17.3**

*Clinic: 1958-1962; total 597 basal cell carcinomas.

Table 9.—Previous Reports of Recurrence Rates of Basal Cell Carcinomas Treated by Curettage-Electrodesiccation

Author	No. of Lesions	Duration of Follow-up, yr	Recurrence Rates, %
Sweet[4]	597	5	12.3
Knox et al[5]	2cm-282	5	2.5
	2cm- 83	5	0.0
Crissey[8]	1400	5	7.4
Jackson[1]	X 127*	?	5.5
	Y 71*	?	2.8
Shanoff[15]	618	?	4.0
Williamson & Jackson[2]	287	3	7.7
Our series:			
Group A (clinic: 1958-1962)	597	5	18.8
Group B (clinic: 1970)	91	5	9.6
Group C (private patients)	210	5	5.7

*"X" and "Y" refer to two attending physicians who treated patients with curettage-electrodesiccation by slightly different techniques.

ing to the higher recurrence rates in the clinic groups is the lesser experience of the physicians in training. Jackson[1] and Williamson and Jackson[2] reported that the recurrence rates of lesions treated by residents were significantly lowered as a result of greater supervision, approaching the lower recurrence rates achieved by the attendings. In the late 1960s, after preliminary data showed a high recurrence rate in our clinic, steps were taken to improve the supervision and training of resident physicians doing the curettage-electrodesiccation procedures. Analogous to the experience of Jackson, the recurrence rate was significantly lowered in group B (ie, lesions treated in 1970) in comparison group A (ie, lesions treated in the clinic in years 1958 to 1962).

An additional explanation for the higher recurrence rate in the clinic groups is the higher percentage of head and neck lesions compared to the private practice group. Undoubtedly, there is a natural tendency to give greater consideration to cosmetic results when treating lesions on the face and therefore to be less vigorous in the treatment procedure.

The improvement of cosmetic results with time following curettage-electrodesiccation is in accord with previous studies[1,4,6-11] and is in contrast to the deterioration in cosmetic results which was seen in our study on the treatment of basal cell carcinomas with x-rays.[12] Following curettage-electrodesiccation, excellent to good cosmetic results were observed in 47% of lesions during the 1st year of follow-up; in 78% in the 3rd year; and 83% in the 10th to 15th years. In contrast, the figures for our series of 500 x-ray-treated basal cell carcinomas were 73.6% in the 1st year; 67% in the 3rd and 4th years, and 48.6% in the 9th to 13th years. These differences are primarily due to the progressive radiodermatitis resulting from cancericidal doses of x-rays.

Hypertrophic scars were the most common complication of curettage-electrodesiccation treatment of basal cell carcinomas. Fortunately, they usually involuted spontaneously. In contrast, hypertrophic scars were very rare after x-ray treatment. Papule or nodule formations, verrucous lesions, and ulcers, the most common complications after x-ray therapy, were not seen in our patients who had been treated by curettage-electrodesiccation.

The pattern of second recurrences of basal cell carcinomas originally treated by curettage-electrodesiccation is similar to that reported by Menn et al,[13] but shows generally lower rates of second recurrences. The pattern is the same in that in descending order of magnitude the treatments showing the highest second recurrence rates of lesions originally treated by curettage-electrodesiccation are as follows: curettage-electrodesiccation, surgical excision, x-ray treatment, and Mohs' surgery. Menn et al[13] observed an overall second recurrence rate of 49.2% (31 of 63 lesions following retreatment), whereas the present study indicates the somewhat lower rate of 34.0% (35 of our 103 lesions). Our results once again indicate that recurrent lesions must be treated more aggressively than previously untreated lesions. It also suggests that Mohs' surgery is probably the treatment of choice for recurrent lesions. According to a communication in March 1976, Mohs achieved a 96.8% five-year cure-rate treating 1,387 consecutive recurrent basal cell carcinomas with chemosurgery. In a series of 214 recurrent basal cell carcinomas treated in the Chemosurgery Section of the Skin and Cancer Unit, the three-year cure rate was 96.3%.[14]

The cumulative recurrence rates (9.6% and 18.8%) reported here for clinic lesions are greater than the rate (7.9%) reported for our series of 500 basal cell carcinomas treated in our clinic by a standardized x-ray method.[12] It should be emphasized, however, that highly experienced personnel were directly involved in the therapy of all the basal cell carcinomas treated with x-rays. Although the general principles of curettage-electrodesiccation are well established, there is considerable variation in technique and no one "standardized" method is followed by all practitioners. This is in marked contrast to our study on x-ray therapy of basal cell carcinomas where a uniform "standardized" method of treatment was employed.[12]

Future studies should attempt to identify those elements of the curettage-electrodesiccation technique that result in the highest cure rates, fewest complications, and best cosmetic results. Possibly, a more standardized technique of curettage-electrodesiccation for the treatment of basal cell carcinomas of the skin could be defined and taught in graduate training programs.

References

1. Jackson R: The treatment of basal-cell carcinomas. Cutis. 5:1,231-1,234, 1969.
2. Williamson GS, Jackson R: Treatment of basal-cell carcinoma by electrodesiccation and curettage. *Can Med Assoc J* 86:855-862, 1962.
3. Cutler SJ, Ederer F: Maximum utilization of the life table method in analyzing survival. *J Chronic Dis* 8:699-712, 1958.
4. Sweet RD: The treatment of basal-cell carcinoma by curettage. *Br J Dermatol* 75:137-148, 1963.
5. Knox JM, Freeman RG, Duncan WC, et al: Treatment of skin cancer. *South Med J* 60:241-246, 1967.
6. Belisario JC: An appraisal of therapeutic methods for skin carcinomas by scalpel or electrosurgery, ionizing radiations, electrochemosurgery and local chemotherapy. *Acta Derm Venereol* 44(suppl 56):1-34, 1964.
7. Chambers RG: Selection of definitive therapy in cancer of the head and neck. *Md State Med J* 23:50-4, 1974.
8. Crissey JT: Curettage and electrodesiccation as a method of treatment for epitheliomas of the skin. *J Surg Oncol* 3:287-291, 1971.
9. Epstein N: Curettage and electrodesiccation, in: *Skin Surgery*, ed 3. Springfield, Ill, Charles C Thomas Publisher, 1970, pp 261-267.
10. Ferrara RJ: The private dermatologist and skin cancer: Clinical study of 226 epitheliomas derived from five dermatologic practices. *Arch Dermatol* 81:225, 1960.
11. Tromovitch TA: Skin cancer: Treatment by curettage and desiccation. *Calif Med* 103:107-108, 1965.
12. Bart RS, Kopf AW, Petratos MA: X-ray therapy of skin cancer: Evaluation of a "standardized" method for treating basal cell epitheliomas, in *Proceedings of the American Cancer Society*. Philadelphia, JB Lippincott, 1970, pp 559-570.
13. Menn H, Robins P, Kopf AW, et al: The recurrent basal cell epithelioma: A study of 100 cases of recurrent, retreated basal cell epithelioma. *Arch Dermatol* 103:628-631, 1971.
14. Robins P, Albom MJ: Mohs' surgery: Fresh tissue technique. *J Derm Surg* 1:37-41, 1975.
15. Shanoff LB, Spira M, Hardy SB: Basal-cell carcinoma: A statistical approach to rational management. *Plast Reconstr Surg* 39:619-624, 1967.

Acne Fulminans

Investigation of Acute Febrile Ulcerative Acne

Herbert Goldschmidt, MD; James J. Leyden, MD; Kenneth H. Stein, MD

• Eight cases of acne fulminans (acute febrile ulcerative acne) are compared with 13 previously reported cases. This rare disorder of male teenage patients is characterized by the sudden appearance of highly inflammatory, tender, ulcerative and crusted lesions on the back, chest, and face: it is one of the most scarring acute dermatologic disorders of young patients. At the onset of the disease, all patients showed febrile temperatures and marked leukocytosis; other systemic symptoms occurred with varying frequency. Polyarthralgia was noted in half of our series.

Investigations of potential trigger mechanisms (eg, septisemia due to *Corynebacterium acnes*, immunologic defects, altered polymorphonuclear leukocyte function, Shwartzman phenomenon) did not yield any clues regarding the pathogenesis of this disease. Clinical and laboratory findings suggest that acne fulminans is not directly related to acne conglobata.

(*Arch Dermatol* 113:444-449, 1977)

Eight new cases of acne fulminans (acute febrile ulcerative acne) are compared with 13 previously reported cases. This rare disorder of male teenage patients is characterized by the sudden appearance of highly inflammatory, tender, ulcerative, and crusted lesions on back, chest and face; it is one of the most scarring acute dermatologic disorders of young patients. At the onset of the disease, all patients showed febrile temperatures and marked leukocytosis; other systemic symptoms occurred with varying frequency. Polyarthralgia was noted in one half of our series.

Accepted for publication July 29, 1976.

From the Department of Dermatology, University of Pennsylvania Medical School, Philadelphia.

Reprints not available.

Investigations of potential trigger mechanisms (eg, septicemia due to *Corynebacterium acnes*, immunologic defects, altered polymorphonuclear leukocyte function, Shwartzman phenomenon) did not yield any clues regarding the etiology and pathogenesis of this disease. Clinical, histological, and laboratory findings suggest that acne fulminans is not directly related to acne conglobata.

REPORT OF CASES

Eight patients with acne fulminans were observed in the private office of one of us (H.G.) and at the Hospital of the University of Pennsylvania. A summary of pertinent findings is presented in Table 1 (cases 14 to 21). Due to space limitations only one characteristic case can be described in detail.

CASE 14.—This 13-year-old boy gave a history of severe acne of six months' duration. The eruption started with suddenly developing multiple pustular lesions on his shoulders that spread to involve his face, back, and chest. For the six weeks prior to admission, progression of the eruption continued and the lesions became markedly tender. Febrile episodes up to 38.3C (101F), weight loss of 5.4 kg, back pain, and extreme malaise were additional symptoms. A trial of tetracycline, 1 gm daily for four weeks, in addition to intensive topical treatment were without effect on the lesions. He had no past history of gastrointestinal symptoms or of recurrent infections. An older sister had comedonal acne as a teenager that has subsequently resolved. The patient has a history of seborrheic dermatitis and hayfever in the spring.

Physical Examination.—On admission the physical examination revealed a young man in some distress. Temperature was 37.8C (100F); pulse rate, 100 beats per minute; blood pressure, 110/70 mm Hg. Tender and crusted ulcerated lesions covered with hemorrhagic exudate were distributed on his back (Fig 1), anterior part of the chest, shoulders, and the proximal portions of his upper extremities (Fig 2). Multiple discrete pustular lesions on an erythematous base involved the same areas. Few comedones were seen and the face was relatively spared. Early atrophic scars were seen on back and chest.

The patient showed progressive resolution of his active lesions and marked symptomatic improvement within five days on a regimen of cephalexin monohydrate (Keflex) 1 gm daily, and prednisone, 40 mg daily. Supplemental therapy consisted of Burow's compresses every two hours to the involved areas. Milk, milk products, and iodides were restricted in his diet. At the time of discharge two weeks later there were no active lesions. The prednisone was tapered off slowly over the next four weeks.

Laboratory Data.—The hemoglobin level was 15 gm/100 ml, hematocrit reading was 47%, and the red cell count was 5.4×10^6. Platelets were adequate. The white count was 18,000 with 75% neutrophils, 20% lymphocytes, and 5% monocytes. Results of blood glucose, blood urea nitrogen, serum electrolytes, urinalysis, T-4 uptake, rapid plasma reagin card test, and electrocardiogram were normal. The sedimentation rate was 43 mm/hr (Wintrobe). Chest x-ray films, barium enema, and upper gastrointestinal series were normal.

Intradermal antigenic skin tests to *Streptococcus faecalis*, *S pyogenes*, *S nonhemolyticus*, *Staphylococcus aureus*, *Micrococcus*, *Proteus vulgaris*, *pseudomonas*, oidiomycin, trichophytin, and intermediate purified protein derivative (PPD) were negative. The mumps intradermal skin test was positive. Serum protein electrophoresis revealed a small increase in the α_1-globulin, an increase in the α_2-globulin fraction to 1.21 gm (normal, 0.34 to 0.7), and an increase in the β-globulin to 1.14 gm (normal, 0.52 to 0.94). Immunoelectrophoresis showed that all immunoglobulin bands were smooth and without distortion. There was no evidence of a paraprotein. Quantitative immunoglobulin surveys revealed normal levels of IgG, IgA, and IgM. A lumbosacral film revealed spondylolisthesis of

Table 1.—Summary of 21 Cases of Acne Fulmmans*

Case No.	Author(s)	Age at Onset, yr	Arthralgia	Temperature, C (F)	WBC	Bacteriology
1	Burns & Colville[1]	16	Yes	39.4 (103)	12,800	*St aureus*, diphtheroids
2	Windom et al[2]	15	Yes	38.3 (101)	13,300	ID†
3	Moschella[4]	15	Yes	38.7 (101.8)	17,000	*St aureus*
4	Kelly & Burns[5]	18	Yes	38.5 (101.5)	12,800	*St aureus, C acnes*
5	Kelly & Burns[5]	14	Yes	37.7-38.9 (100-102)	21,000	*St aureus*
6	Kelly & Burns[5]	14	Yes	38.7 (101.8)	19,900	*Streptococcus, Coli*
7	Ström et al[6]	16	Yes	38.9 (102)	23,200	*St albus*
8	Ström et al[6]	15	No	38.9 (102)	33,000	*St albus*
9	Ström et al[6]	18	No	ID†	25,500	ID†
10	Ström et al[6]	16	Yes	ID†	18,200	ID†
11	Ström et al[6]	18	No	ID†	10,100	ID†
12	Ström et al[6]	19	Yes	ID†	12,000	ID†
13	Ström et al[6]	15	No	ID†	16,900	ID†
14	Goldschmidt et al	13	Yes	38.3 (101)	18,000	*C acnes*
15	Goldschmidt et al	16	Yes	38.3(101)	13,000	*C acnes*
16	Goldschmidt et al	17	Yes	37.8 (100)	17,400	*C acnes*, micrococci, diphtheroids
17	Goldschmidt et al	16	No	37.8 (100)	18,000	*C acnes*, micrococci
18	Goldschmidt et al	15	No	38.3 (101)	14,000	No growth
19	Goldschmidt et al	19	No	38.3 (101)	12,000	*C acnes*, micrococci *Proteus*
20	Goldschmidt et al	19	No	38.3 (101)	16,000	*C acnes*, micrococci
21	Goldschmidt et al	18	Yes	38.3 (101)	10,000	*C acnes*

*All the subjects were male.
†ID indicates insufficient data.

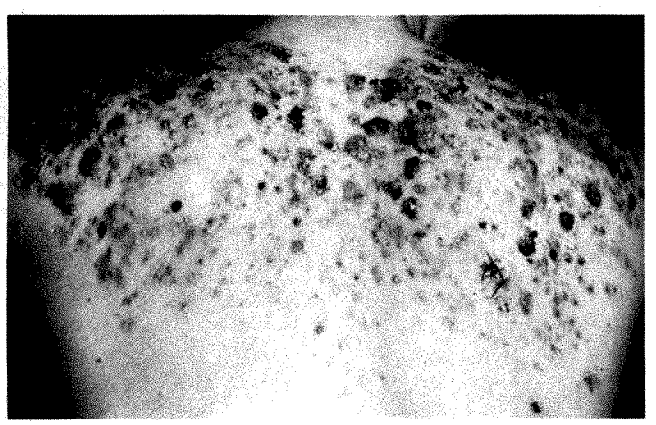

Fig 1.—Case 14. Numerous pustular and ulcerative lesions covered with hemorrhagic crusts.

Fig 2.—Same patient. Similar lesions on upper part of chest. Note characteristic sparing of neck area.

the L-4 and L-5 vertebral level.

Assays of neutrophil mobilization, phagocytic and chemotactic activity, and random mobility of the neutrophils showed no abnormality.

Cultures of pustular lesions revealed micrococci and *C acnes*. Blood cultures were negative. Several biopsies were taken that revealed severe inflammatory changes.

REVIEW AND SUMMARY OF PUBLISHED CASES

A review of the world literature revealed 13 published cases of acne fulminans.[1-3] The essential data are presented in Table 1 that also includes our own eight cases. All patients were white male teenagers, the majority with a history of only mild preceding acne vulgaris. Their ages at the onset of the disease ranged from 13 to 19 years (with a median age of 16); few patients continued into their 20s. All patients had acute sudden onset of severe painful ulcerative cutaneous lesions and systemic symptoms. Thirteen of 21 patients had arthralgia of varying degree; 8 had no joint symptoms. All patients had elevated temperatures, ranging from 101 to 103° with a median temperature of 101.5. The WBC was markedly elevated from 10,000 to 33,000 with a median elevation of 16,000 leukocytes. The sedimentation rate was raised from 37 to 145/hr with a median elevation of 84/hr. All other symptoms varied considerably.

COMMENT

Clinical Findings

The clinical findings of the presented eight new cases correspond

Fig 3.—Case 18. Widespread large ulcerative lesions with hemorrhagic crusts, early pustular lesions, and scarring.

Fig 4.—Case 18. Same patient three months later. Lesions have healed with marked atrophic and hypertrophic erythematous scars.

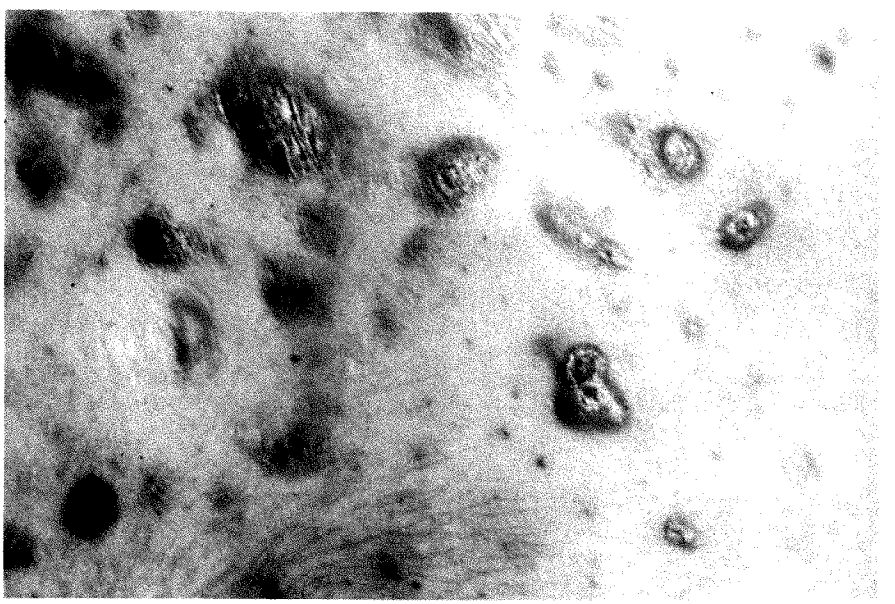

Fig 5.—Case 17. Close-up view of sternal region showing numerous small pustular lesions with inflammatory halos, nodules, early erythematous ulcers, and atrophic scarring.

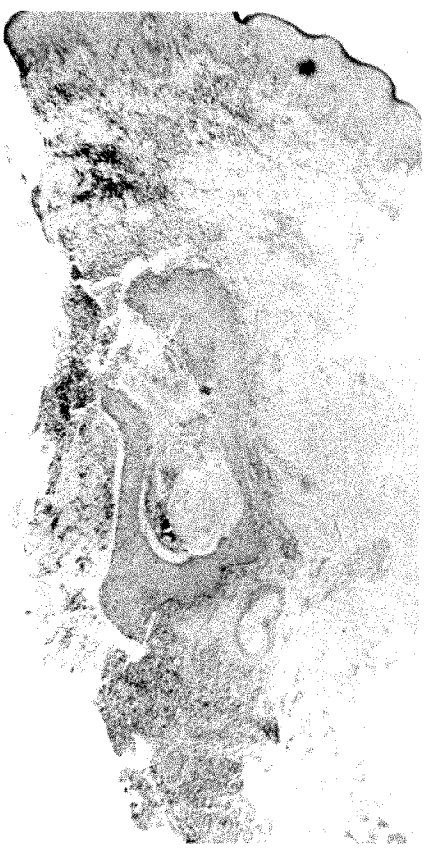

Fig 6.—Pustule showing ruptured follicular wall, intrafollicular accumulation of keratinous material, and intense infiltrate composed mostly of polymorphonuclear neutrophils.

closely to the previously published cases.[1-6] Our eight patients were young men (13 to 19 years old) who had only mild to moderate acne of the facial (and back) area for one to two years prior to the onset of the widespread acute eruption. The predilection areas were the shoulders, upper part of the back, and upper part of the chest (Fig 1-4); characteristically, the anterior and lateral neck region (including a 5 to 10 cm semicircular area of adjacent skin) and the lateral trunk below and including the axillary region were completely clear in most patients (Fig 2). The facial area was either not involved or showed only mild to moderate acne lesions.

In very early stages, small 2 to 3 mm pustules on an erythematous base could be discerned as primary lesions (Fig 5). They rapidly developed into large 1 to 5 cm sized, discrete or confluent dark, oval or round, slightly raised erythematous lesions with a thin friable surface layer that could be easily removed by moderate tangential pressure revealing a gelatinous reddish-yellow ulceration. Many of these ulcerative lesions were covered with thick hemorrhagic crusts. Nodular or cystic lesions were seen only rarely. The number and size of comedones was also inconspicuous; large polyporous (double or triple) come-

Fig 7.—Ulcerative lesion showing denuded epidermis, intense infiltrate of polymophonuclear neutrophils, and occasional remnants of follicular epithelium and sebaceous glands.

Fig 8.—Later fluctuant, nodular lesion with regenerated, acanthotic epidermis, persistent dense inflammatory infiltrate, dermal edema, and numerous dilated vessels.

dones were not observed. Both the small and large lesions were extremely tender causing the patient to walk or stand with his neck bent and his shoulders drooping. This characteristic gait and posture often gave a diagnostic clue even at a distance.

Systemic symptoms were present in all eight patients, particularly fever, chills, and malaise during the acute stage. Polyarthralgia was reported in varying degrees by four of our patients; the remaining four denied joint pain. Weight loss (often more than 4.5 kg in two to three months) occurred in the majority of our patients.

Laboratory Findings

All patients had a leukocytosis of more than 12,000 with polymorphonuclear leukocytes. Where done, the ESR was elevated more than 40 mm/hr. Anemia was not a consistent finding.

The results of multiple cultures taken from early and late lesions and from the nasal mucosa were inconclusive. The *C acnes* and micrococci were frequently demonstrated in varying numbers, and *St aureus* was found only in rare instances. *Proteus* was cultured from only one of three lesions of one patient. A particular bacteriological pattern could not be established. Repeated special blood cultures were also started in three patients but failed to reveal any evidence of septicemia due to aerobic or anaerobic microorganisms (eg, due to *C acnes*). Results of various other routine laboratory studies were also normal. In particular, we were unable to find any indication for an immunological defect. Intradermal skin tests with bacterial and other antigens showed normal responses. Results of serum protein electrophoresis were either normal or showed a small increase in α_1-globulin, α_2-globulin, and M globulin. Immunoelectrophoresis showed that all bands were smooth and without distortion. Quantitative immunoglobulin surveys revealed normal levels of IgG, IgA, and IgM. Assays of neutrophil mobilization, phagocytosis, chemotaxis, and random mobility of neutrophiles were normal. Skin tests with a suspension of the patient's comedones (heat-killed and control) were done in one patient and did not show any difference in reaction in a dilution of 1:100.

Histology

Since previous reports lack detailed data on microscopic findings, various stages of acne fulminans were examined histologically.

Early Pustular Lesions.—The early pustular lesions showed an intense infiltrate consisting of polymorphonuclear cells and some histiocytes with invasion and destruction of the follicular wall (Fig 6). Some follicles showed some distension with accumulated keratinized cells (microcomedone formation) but others did not reveal any tendency for comedone formation. The polymophonuclear infiltrate often extended down to the panniculus (Fig 6). Clinically such lesions showed an intense erythema surrounding the pustule.

Ulcerative and Nodular Lesions.—Many lesions showed a thick hemorrhagic crust; the epidermis showed extensive necrosis or was entirely missing. In the dermis there was an intense, deep infiltrate comprised of polymorphonuclear neutrophiles, histiocytes, and lymphocytes (Fig 7 and 8). Follicular structures were absent except for occasional follicular remnants. Several lesions showed extensive edema and vascular hyperplasia deep in the dermis (Fig 7). In all cases the infiltrate was predominantly perivascular; occasional invasion of blood vessel walls was seen but nuclear dust, fibrinoid material, or endothelial changes were not noted. A late lesion showed a regenerated acanthotic epidermis with the dermis containing a dense mixed cellular infiltrate, vascular hyperplasia, and numerous stellate fibroblastic cells.

Normal Skin.—Biopsies of normal skin areas of the back of three patients showed no abnormalities.

Summary of Microscopic Findings

The histologic findings could be interpreted as a markedly exaggerated fulminant follicular reaction developing into an extensive, spreading, liquefying necrosis engulfing neighboring follicles in its path. (In contrast, in mild to moderate acne vulgaris ruptured microcomedones result only in relatively small and limited perifollicular abscesses.) No evidence of vasculitis or other changes

Table 2.—Differential Diagnosis of Acne Fulminans*

	Acne Vulgaris	Acne Conglobata	Tropical Acne	Acne Fulminans
Cutaneous Signs				
Sex	M, F	M, (F)	M, (F)	M
Age	12-25	14-40	20-40	13-20
Distribution	Face, back (chest)	Back, chest face	Back, chest gluteal	Shoulders, back chest, (neck and face often free)
Primary comedones (open/closed)	+ − + + +	+ − + + +	+	+ − + +
Polyporous comedones (double or triple)	+	+ + − + + +	+	+
Nodules and cysts	+ +	+ + +	+ +	(+)
Ulcerative lesions with hemorrhagic crusts	−	+	+	+ + +
Scarring	+ − + +	+ + +	+ + +	+ + +
Tenderness	+	+ − + +	+ + − + + +	+ + +
Systemic Signs and Symptoms				
Fever [> 37.8 C (100 F)]	−	(+)	(+)	+ + +
Leukocytosis (> 12,000)	−	(+)	(+)	+ + +
Polyarthralgia	−	(+)	−	+ − + +
Response to Therapy				
Systemic tetracycline	+ + +	+ +	+ − + + (without climatic change)	+
Systemic steroids	+ − + +	+ − + +	− (without climatic change)	+ +

*Explanation: − = Not seen; + = rare; + + = common; + + + = very common.

suggestive of an immune or Shwartzman type reaction were detected. The paucity of clinically visible comedones could be explained by the fulminant course of this disease that does not allow for sufficient time to develop visible comedones from subclinical microcomedones.

Therapeutic Results

Most of our patients gave a history of unsatisfactory responses to routine acne treatments, often extending over six to eight months prior to the initiation of intensive and proper therapy.

The majority of these patients responded dramatically to a combination of systemic steroids (eg, prednisone 30 mg daily in gradually decreasing dosage) with systemic antibiotics over a period of six to eight weeks. Tetracycline (500 mg, three times a day), demeclocycline hydrochloride (Declomycin) (300 mg, twice a day), clindamycin (Cleocin) (150 mg, three times a day), and cephalexin monohydrate (500 mg, three times a day) were ineffective without concomitant systemic steroid therapy but seemed to be helpful as supportive antibacterial treatment. Because of the severity of symptoms no attempt was made in this series of patients to determine if treatment with corticosteroids without antibiotics could be equally effective.

In contrast to other reported cases only three of our eight cases showed a tendency to chronicity and repeated exacerbations after six months with proper therapy (including corticosteroids). The other five of eight patients were free of symptoms; only the preexisting mild or moderate involvement with acne vulgaris continued to a certain degree after the acute eruption had cleared up. The therapeutic efficacy of sulfone therapy could not be properly evaluated because of our limited number of cases. Dapsone (Avlosulfon) (100 to 200 mg daily) was used in two patients but had to be discontinued in one patient because of possibly related side effects. In the early stages of our investigation (when we were unaware of the need for higher doses of systemic steroids) two patients with severe scarring lesions were recalcitrant to all systemic regimens (including antibiotics and 10 to 15 mg of prednisone) or topical therapy (including sulfurated lime solution [Vleminckx solution] and various steroid and antibiotic creams). They were eventually treated with cautious dermatologic radiotherapy, using a half-value layer of 0.9 mm Al with a half-value depth of 12 mm of skin, with weekly doses of 80 R up to a total of 720 R to the upper part of the back and chest with careful shielding on noninvolved areas, eyes, thyroid, and gonads. Response to ionizing radiation in these two patients was extremely satisfactory and even three years after radioactive therapy, recurrences have not been observed. Only one of the eight patients is still under treatment for recurrent febrile flares more than two years after his original sudden outbreak.

ETIOLOGY AND PATHOGENESIS

The pathogenesis of this rare and devastating skin condition is still a mystery. Various potential trigger mechanisms were investigated without success. The systemic findings of fever, leukocytosis, increased sedimentation rate, anemia, malaise, and weight loss are suggestive of a septicemia (eg, due to *C acnes*), but repeated careful blood cultures remained negative. Bacteriologic examination showed no unusual flora, with *C acnes* and micrococci prevailing. An immunological deficiency or a generalized hypersensitivity state were also suspected but no specific clues could be found in qualitative or quantitative immunoglobulin assays, skin tests, biopsies, and other studies. It is known that some patients with severe acne conglobata show depressed delayed sensitivity reactions but this could be explained on a nonspecific response to severe inflammatory disease.[7] Extensive assays of neutrophil function were also completely negative. Neutrophil mobilization, phagocytic and chemotactic reactions, and random mobility of neutrophils were normal.

Some authors have suspected a reaction similar to a Shwartzman phenomenon but no evidence could be found for this theory either.

NOSOLOGY

The lack of an internationally accepted scheme for classifying acne and acneiform eruptions has been a primary source of confusion and controversy. This is particularly true for the nosological relations between acne vulgaris with nodular and cystic lesions, acne conglobata, and tropical acne. The mounting number of case reports on acne fulminans further adds to this confusion.

The new classification by Plewig and Kligman[7] seems best suited to clarify this situation. The authors differentiate three main types of acne vulgaris, comedonal acne, papulopustular acne, and acne conglobata. Acute febrile ulcerative acne is mentioned as another variety of acne vulgaris (and not as a subspecies of acne conglobata). When we discussed these patients with Dr Kligman several years ago, he proposed to replace this cumbersome term with "acne fulminans" (from L. fulmen, n. = lightning) that emphasizes the characteristic sudden onset and severity of this disease and avoids reference to acne conglobata that takes a different course and can be distinguished by its different symptomatology and prognosis. This new term has now been adopted in Plewig and Kligman's classification. The shorter term has the added advantage that it does not prejudice further investigations by including in its title symptoms that are completely variable (eg, polyarthralgia) or variable in degree (eg, leukemoid reaction).

DIFFERENTIAL DIAGNOSIS

Table 2 compares acne vulgaris, acne conglobata, tropical acne, and acne fulminans, four potentially scarring varieties of acne involving chest and back, with or without involvement of the facial region.

The clinical and laboratory findings of *acne fulminans* are described above. This rare, severely scarring disease is, in our opinion, a unique and distinct disease that is not directly related to any of the other three diseases. It differs from all other disorders by its sudden, violent onset and the presence of fever and leukocytosis, often also polyarthralgia, malaise, anemia, weight loss, and other systemic findings. Additional unique features are the characteristic ulcerative and crusted lesions that are often equisitely tender. Back and chest are usually more severely involved than the facial area; the neck area is often spared out in a peculiar fashion.

In contrast to acne conglobata, large noninflamed secondary cysts and polyporous (double or triple) comedones are absent. The age distribution (13 to 20 years) most closely resembles acne vulgaris. All published cases have been male patients (a 14-year-old girl was described by Ström et al[6] but was not included in Table 1 because distinctive ulcerative lesions were missing).

Tropical acne[8-10] may resemble acne fulminans closely but its distribution pattern is often different (buttocks, axillae). Various types of severe inflammatory acne lesions are usually present and ulcerative lesions are rare. Tropical acne can easily be ruled out in nontropical climates. Acne fulminans also differs from other diseases by its lack of response to antibiotic therapy and its favorable response to systemic corticosteroids. Presumably, the untreated patient eventually improves when the disease has "burned out" since the marked scarring is unsuitable for further inflammatory flares.

This investigation was supported by the Wende Fund and the Kline Fund.

Herbert B. Allen, MD; Chalmers E. Cornelius, MD; Walter B. Shelley, MD; and Maurice Thew, MD, permitted inclusion of their patients in this study.

Edward Glifort prepared the photographs.

Leukocyte function was investigated in the laboratory of Michael E. Miller, MD.

Nonproprietary Names and Trademarks of Drugs

Cephalexin monohydrate—*Keflex, Keforal.*
Clindamycin—*Cleocin.*

References

1. Burns RE, Colville JM: Acne conglobata with septicemia (?). *Arch Dermatol* 79:361, 1959.
2. Windom RW, Sanford JP, Ziff M: Acne conglobata and arthritis. *Arthritis Rheum* 4:632, 1961.
3. Thyresson N: Acne conglobata and septicemia. Transactions of the Swedish Dermatological Society 1961. *Acta Derm Venereol* 43:498, 1963.
4. Moschella SL: Report of a case of acne conglobata and arthritis. *Bull Assoc Milit Dermatol* 13:15, 1964.
5. Kelly P, Burns RE: Acute febrile ulcerative conglobate acne with polyarthralgia. *Arch Dermatol* 104:182, 1971.
6. Ström S, Thyresson N, Boström H: Acute febrile ulcerative conglobate acne with leukemoid reaction. *Acta Derm Venereol* (Stockh) 53:306-312, 1973.
7. Plewig G, Kligman AM: *Acne.* Berlin-New York, Springer-Verlag, 1975.
8. Strauss JS: Diseases of sebaceous glands, in Fitzpatrick TB, Arndt KA, Clark WH, et al (eds): *Dermatology in General Medicine.* New York, McGraw-Hill, 1971, p 369.
9. Sulzberger MB, Addenbrooke EF, Joyce FJ, et al: Tropical acne. *US Naval Med Bull* 46:1178, 1946.
10. Novy FG Jr: A severe form of acne developing in the tropics. *Arch Dermatol* 60:206, 1949.

Host-Defense Mechanisms in Hidradenitis Suppurativa

Vera C. Dvorak, MD; Richard K. Root, MD; Rob Roy MacGregor, MD

• **Host-defense mechanisms were studied in seven patients with active hidradenitis suppurativa (HS). Granulocyte phagocytic function was measured by ingestion of *Staphylococcus aureus* labeled with radioactive carbon 14 and intracellular killing was determined by bactericidal pour plate method. Chemotaxis was measured by radioactive counting of sodium chromate Cr 51 granulocytes migrating in modified Boyden chambers. Granulocyte adherence was estimated in vitro by filtering blood samples through nylon fiber columns. Cell-mediated immunity was measured by intradermal delayed hypersensitivity responses to *Candida*, mumps, streptokinase/streptodornase, and purified protein derivative antigens. No abnormality was demonstrated in any granulocyte or cell-mediated immune function tests. Moreover, all patients had normal immunoglobulin levels and elevated total hemolytic complement. Therefore, we conclude that HS is a localized chronic infection of apocrine glands without a generalized defect in host defense.**

(*Arch Dermatol* 113:450-453, 1977)

Hidradenitis suppurativa (HS) is a chronic suppurative process involving the apocrine glands; the onset is usually after puberty. Early lesions resemble furuncles but progress into subcutaneous abscesses that fistulate and develop intercommunicating sinus tracts, resulting in irregular hypertrophic scars. According to the pathologic findings, HS has been divided into acute (AHS) and chronic (CHS) forms; AHS lacks sinus tracts and hypertrophic scarring. *Staphylococcus aureus* is the most frequent organism found in AHS, while CHS has infection secondary to Gram-negative organisms as frequently as it has with *S aureus*.[1]

Infection is probably a secondary pathogenic event of HS and not its cause. This disease has been produced experimentally by the application of adhesive tape to the axilla.[2] Sequential changes in the apocrine glands included keratinous obstruction of the apocrine ducts, dilatation of the ducts, and severe inflammatory changes in the occluded glands as bacteria trapped beneath the obstructing plug induced a granulocytic exudate. Thus, HS can be defined as a bacterial infection of an obstructed apocrine gland.

Treatment with antibiotics alone usually is successful in AHS, while CHS almost always requires surgical therapy.[3] Pathogenesis is uncertain but some factors appear more frequently in the history of patients with HS than in the general population. These include a family history of the disease, poor hygiene, excessively oily skin secretions, obesity, diabetes mellitus, pilonidal cysts, and acne.[1,2,4] Defects in host-defense mechanisms have been suspected but not systematically investigated in patients with HS. To resolve this question we studied cellular, humoral, and granulocyte defenses in seven patients with HS.

POPULATION AND METHODS

Seven patients were included in the study; three men with a mean age of 31 years and four women with a mean age of 43 years. All patients had characteristic lesions of CHS and all had had at least one surgical drainage procedure in the past. At the time of study all patients had suppurating lesions, two requiring surgery (patients 1 and 6). All were examined on only one occasion except patient 6 who was

Accepted for publication Aug 3, 1976.

From the Infectious Disease Section, Department of Medicine, University of Pennsylvania School of Medicine, Philadelphia. Dr Root is now with the Infectious Disease Section, Yale University, New Haven, Conn. Dr Dvorak is a fellow in Infectious Disease, University of Pennsylvania School of Medicine.

Reprint requests to Infectious Disease Section, 552 Johnson Pavillion, University of Pennsylvania School of Medicine, Philadelphia, PA 19174 (Dr MacGregor).

examined again three weeks after surgery. None had received antibiotics, corticosteroid therapy, or other medication within ten days of the study.

Controls for the investigation consisted of normal laboratory personnel. On the day of the study leukocytes were separated from patients' and controls' heparinized blood samples by sedimentation with 3% dextran in normal saline solution, followed by hypotonic lysis of RBCs.[5] The leukocytes were concentrated by centrifugation at 80 g for seven minutes and washed twice in modified Hank solution. The total granulocyte content of this mixed leukocyte population was counted and the cells were suspended in Hank balanced salt solution to a final granulocyte concentration of 5×10^6/ml.

Table 1.—Patients' Characteristics*

Patient	Age, yr	Sex	HS Distribution	Duration of HS, yr	Underlying Illness
1	26	M	Generalized	7	Pilonidal cyst two yr prior to onset of HS; psoriasis, 3 yr prior
2	39	F	Generalized	15	Mild obesity; recurrent thrombophlebitis; positive family history for HS
3	30	M	Generalized	10	Four pilonidal cysts prior to onset of HS; acne
4	32	F	Axilla	17	Obesity; adult onset of diabetes mellitus; hypercholesterolemia; pilonidal cyst two yr after onset of HS
5	48	F	Axilla	8	Obesity
6	27	M	Generalized	10	Down syndrome
7	33	F	Generalized	5	Obesity, alcoholism; abnormal glucose tolerance test; positive famly history for HS (sister of patient 2)

*Hidradenitis suppurativa indicated by HS.

Granulocyte Function Studies

Phagocytosis was studied by using *S aureus* 502A labeled with radioactive carbon C 14 as the particle.[6] Bacteria-to-cell ratio was 500:1. The mixture of patient or control leukocytes, labeled bacteria, and autologous serum was incubated at 37 C without aggitation. At successive intervals, ingestion of bacteria was stopped by addition of cold 0.01M sodium flouride. Noningested bacteria were separated from the leukocytes by low-speed centrifugation. Cell pellets were dried overnight and digested with 0.2N sodium hydroxide at 56 C for three hours. The lysate was brought to neutral pH and 1-ml portions were counted in a liquid scintillation counter. The percent uptake of radioactive-labeled bacteria by granulocytes was determined at 8 and 20 minutes of incubation.

Bactericidal ability of granulocytes was determined by a modification of a method developed in this laboratory.[6] A 1:10 ratio of *S aureus* 502A and granulocytes were tumbled in 1 ml of 10% autologous serum and Hank balanced salt solution at 37 C. At 20 minutes, lysostaphin was added to all tubes to kill extracellular bacteria. The incubation was continued and either 10-μl or 100-μl Eppendorf micropippets were used to sample each tube at 20, 30, and 60 minutes. Each sample was placed in 10 ml of distilled water for ten minutes to lyse the granulocytes and 10-μl and 100-μl samples then were mixed into trypticase soy agar pour plates and incubated at 37 C for quantitation of viable bacteria. A cell-free control was plated at 0 and 60 minutes to assure that only cell-associated killing of bacteria was taking place. Bactericidal activity is defined as the percent of ingested bacteria (those present at 20 minutes, after lysostaphin addition to kill extracellular bacteria) that have been killed by 30 and 60 minutes of incubation.

Chemotaxis was measured by a radioactive counting technique in modified Boyden chambers.[7] Chemotactic factor was generated from human serum by activation with endotoxin. *Escherichia coli* 0127:B8 lipopolysaccharide B endotoxin was prepared in normal saline solution at 300 μg/ml and stored at −70 C. For chemotactic factor generation, 0.1 ml of endotoxin solution was mixed with 0.1 ml of the test serum and 0.8 ml of barbital (Veronal) gelatin buffer. This was incubated for 60 minutes at 37 C, after which residual complement was inactivated by heating at 56 C for 30 minutes.[7] Normal chemotaxis was defined as that amount seen when normal control cells were stimulated by the chemotactic factor generated from their own serum. The chemotactic factor generated from patient serum was compared to that from normal serum by the relative chemotactic response of normal cells to each. Chemotaxis of patient and normal cells was measured to those factors from both normal and patient sera.

Granulocyte adherence was estimated in vitro by filtering heparinized whole blood through nylon fiber columns and measuring the number of granulocytes remaining in the column.[8] The 80-mg columns were used for men and 70-mg columns for women.

Cell-Mediated Immune Studies

Delayed hypersensitivity to *Candida*, mumps, streptokinase/streptodornase, and purified protein derivative antigens was tested by measuring the millimeters of induration 48 hours following intracutaneous injection of 0.1 ml of the antigen into the volar surface of the forearm. Induration of more than 5 mm in diameter was considered a positive reaction. Each patient received all four antigens, two to each forearm.

Humoral Immune Studies

Quantitative immunoglobulin levels were measured by radial diffusion on agar plates. Total hemolytic complement was measured by the technique of Kabat and Mayer.[9]

RESULTS

Five patients had chronic, generalized HS and two chronic, localized HS (Table 1). Three patients had a history of pilonidal cysts, which had preceded the onset of HS in two. All women were moderately obese. One had an abnormal glucose tolerance test result and one was overtly diabetic. One patient had Down syndrome and one had active psoriasis. Two of the study subjects were sisters (patients 2 and 7); the daughter of one sister gave a history of bilateral axillary furunculosis on two occasions.

The rates of phagocytosis of *S aureus* 502A after 20 minutes of incubation were not substantially different between the patients and controls (Table 2).

The bactericidal results are expressed in two ways: (1) by a calculation of intracellular killing at 30 and 60 minutes as the percent of bacteria killed after phagocytosis (Table 2) and (2) as the number of bacteria surviving at 20, 30, and 60 minutes of incubation (Table 3). By the first analysis, 96.5% to 99.5% of ingested bacteria were killed at 60 minutes of incuba-

Table 2.—Host-Defense Function Tests

Patient	Phagocytosis* Patient/Control	Bactericidal Activity, %† Patient/Control 30 min	Bactericidal Activity, %† Patient/Control 60 min	Granulocyte‡ Adherence, %	Immunoglobulins, mg/dl§	Complement, U‖	Positive Delayed Hypersensitivity Reactions, mm¶
1	41.5/37.3	81/90	96.5/98.8	92.7	Normal by immunoelectrophoresis	Not done	Mumps, 10 SK/SD, 10
2	34.8/32.9	92.7/94.1	98.7/99.8	83.9	Normal	238	*Candida*, 20 Mumps, 10 SK/SD, 10
3	30.4/26.1	88.4/89	98.3/98.2	77.8	IgG, 1,125 IgA, 145 IgM, 140	208	Mumps, 12 *Candida*, 8
4	32.6/34.3	76.3/79.3	99.2/99.5	61.8	IgG, 1,400 IgA, 120 IgM, 278	>250	*Candida*, 5 SK/SD, 40
5	19.9/26.1	85.3/89	97.5/98.2	63.7	Normal	204	Mumps, 8
6	26.2/28.8	88.4/91	97.7/98	91.2	IgG, 1,675 IgA, 520 IgM, 83	>250	*Candida*, 5 SK/SD, 8
7	45/32.9	90.5/94.1	98/99.8	86.3	Normal	250	*Candida*, 5 SK/SD, 10

*Percent uptake of *Staphylococcus aureus* at 20 minutes of incubation.
†Percent intracellular-killed bacteria 30 and 60 minutes after phagocytosis.
‡Normal values: 76% ± 12% for men; 70.8% ± 4.3% for women.
§Normal levels: IgG, 620 to 1,420 mg/dl; IgA, 60 to 340 mg/dl; IgM, 50 to 280 mg/dl.
‖Normal level, 150 ± 20 U.
¶ Streptokinase/streptodornase indicated by SK/SD.

Table 3.—Phagocytic and Bactericidal Mean Values of Patients and Controls

Test	Patients (7) Mean ± SE	Controls (7) Mean ± SE
Phagocytosis, %*	32.9 ± 3.2	31.2 ± 1.6
Bactericidal†		
Zero time	$2.2 \times 10^7 \pm 0.44$	$2.3 \times 10^7 \pm 0.5$
After 20 min incubation	$1.5 \times 10^7 \pm 0.3$	$1.4 \times 10^7 \pm 0.3$
After 30 min	$1.5 \times 10^6 \pm 0.26$	$1.38 \times 10^6 \pm 0.23$
After 60 min	$1.2 \times 10^5 \pm 0.5$	$1.3 \times 10^5 \pm 0.5$

*Percent uptake of *Staphylococcus aureus* at 20 minutes' incubation.
†Number of bacteria surviving per milliliter.

Table 4.—Chemotaxis

Granulocyte Source	Serum Source	Chemotaxis, Mean Counts ± SE* Stimulated by CF	Chemotaxis, Mean Counts ± SE* Unstimulated
Controls	Controls	7441.4 ± 2761.6	399 ± 98
Controls	Patients	9341.6 ± 4112.6	. . .
Patients	Controls	7290 ± 2380.6	. . .
Patients	Patients	8244.5 ± 3477.8	405 ± 78

*Measured as counts per minute. Chemotactic factor indicated by CF.

tion in control and patient groups. The second method also showed no difference between controls and patients. Mean granulocyte adherence for women was 73.9% ± 6.1% compared to 70.8% ± 4.3% for normals. The mean value for male patients was 87.2% ± 4.7% vs 76% ± 12.0% for normals (Table 2). All patients produced chemotactic factor that stimulated their own and control granulocytes equally (Table 4), and patient cells showed chemotaxis equal to that of control cells. While the chemotactic factor from the patients produced a greater mean chemotactic response in both normal and patient cells than that from normal controls, the differences were not statistically significant ($P > .1$, Student t test). There was no correlation between chemotactic response and the extent or chronicity of the disease. All of the patients had delayed hypersensitivity reaction to at least one test antigen (Table 2). There was no correlation between the extent of the disease and the size of the induration. All patients had active lesions at the time of study. One patient had mildly elevated IgG and IgA antibody levels and all patients had elevated total hemolytic complement levels.

Two additional patients were studied in 1969 by one of us (RKR). Patient 8 was a 48-year-old man with generalized HS and a history of acne for 30 years. The patient had normal cell-mediated and humoral immunity, as tested by purified protein derivative skin test and immunoglobulin levels. In vivo migration of WBCs to an inflammatory stimulus was evaluated by the Rebuck skin window test,[16] and was normal. Phagocytic values were comparable to those of the control. In the bactericidal assay, *S aureus*, *S albus*, and *E coli* were used as particles; no difference in killing activity was found between the

patient and control for any of these organisms. Patient 9 was a 28-year-old man with HS involving axillae and groins. There was no significant past medical history. No defect in phagocytosis or bacterial killing by granulocytes was found.

COMMENT

A chronic and recurrent infection of the apocrine glands, HS is manifested by draining abscesses. The lack of infections in other sites and good response to surgical excision of apocrine-bearing tissue suggest well-functioning cellular and humoral immune mechanisms in patients with HS; in contrast, patients with primary defects in host immune mechanisms,[6,11] or with underlying diseases resulting in such defects,[12] usually have infections involving multiple sites such as the skin, upper and lower respiratory tracts, and other organs.

Granulocyte response to inflammation involves adherence of granulocytes to endothelium near the stimulus followed by diapedesis into the extravascular space and cell movement in the direction of chemotactic gradients. Phagocytosis and bacterial killing are the last steps in granulocyte response to inflammatory stimuli induced by bacterial infection. Defects occurring in any of these steps can compromise the host's defense against infection.

Chemotaxis, phagocytosis, and intracellular killing of ingested bacteria were normal in all of the patient samples studied. Granulocyte adherence was increased in two patients (1 and 6) and was probably in response to a highly active inflammation. Augmented granulocyte adherence has been described in patients with active inflammation, mediated by a heat-labile plasma factor[13]; on the other hand, anti-inflammatory drugs (aspirin, corticosteroids) inhibit granulocyte adherence.[8] Both patients subsequently required surgical procedures for control of their disease. Total hemolytic complement level was increased in all patients. Complement concentration has been found to increase greatly in inflammatory conditions, as one of the biologic phenomena associated with tissue damage. Elevated complement levels are also found in noninflammatory processes such as myocardial infarction, neoplasms, and thyrotoxicosis.[14] The magnitude of the complement elevation does not appear to correlate with the outcome of the underlying process.

Immunoglobulin levels, as determined by radial diffusion, were normal in all but one of our patients. This patient (patient 6) with Down syndrome had elevated IgG and IgA levels. Patients with Down syndrome and other chromosomal abnormalities have been described as having elevated IgG, IgA, and total γ-globulin levels with mean values 150% of those seen in normal adults, whereas IgM was decreased to a mean of 62% of normal.[15] Elevated levels could not be correlated with a history of infections.

We conclude that HS is a localized chronic infection due not to a generalized defect in host defense but rather to local factors leading to obstruction of the apocrine glands. Once initiated, the process of inflammation perpetuates itself with further impairment of the glandular drainage. Early in the disease, broad spectrum antibiotics and elimination of the local factors might reverse the process, but in the chronic phase, surgery remains the only curative mode of therapy. Patients treated with radical surgery to remove all involved apocrine glands have no in-site recurrence and no apparent predisposition for infection elsewhere.[3]

This investigation was supported in part by grant AA 00332 from the National Institute for Alcohol Abuse and Alcoholism.

References

1. Steiner K, Grayson LD: Hidradenitis suppurativa of the adult and its management. *Arch Dermatol* 71:205-211, 1955.

2. Shelley WB, Cahn MM: The pathogenesis of hidradenitis suppurativa in man. *Arch Dermatol* 72:562-565, 1955.

3. Masson JK: Surgical treatment for hidradenitis suppurativa. *Surg Clin North Am* 49:1043-1052, 1969.

4. Brunsting HA: Hidradenitis suppurativa: Abscess of the apocrine sweat gland. *Arch Dermatol Syphilos* 39:108-120, 1939.

5. Fallon HJ, Frei E, Davidson JD, et al: Leukocyte preparations from human blood: Evaluation of their morphologic and metabolic state, *J Lab Clin Med* 59:779-791, 1962.

6. Root RK, Rosenthal AS, Balestra DJ: Abnormal bactericidal, metabolic and lysosomal functions of Chediak-Higashi syndrome leukocytes. *J Clin Invest* 51:649-665, 1972.

7. Gallin JI, Clark RA, Kimball HR: An improved in vitro assay employing ^{51}Cr labeled granulocytes. *J Immunol* 110:233-240, 1973.

8. MacGregor RR, Spagnuolo PJ, Lentnek AL: Inhibition of granulocyte adherence by ethanol, prednisone, and aspirin, measured with a new assay system. *N Engl J Med* 291:642-646, 1974.

9. Kabat EA, Mayer MM: *Experimental Immunochemistry*, ed 2. Springfield, Ill, Charles C Thomas Publisher, 1967.

10. Rebuck JW, Smith RW, Margulis RR: The modification of leukocytic function in human windows by ACTH. *Gastroenterology* 19:644-657, 1951.

11. Mickenberg ID, Root RK, Wolff SM: Leukocytic function in hypogammaglobulinemia. *J Clin Invest* 49:1528-1538, 1970.

12. Bagdale JD, Root RK, Bulger RJ: Impaired leukocyte function in patients with poorly controlled diabetes. *Diabetes* 23:9-15, 1974.

13. Lentnek AL, Schreiber AD, MacGregor RR: The induction of augmented granulocyte adherence by inflammation. *J Clin Invest* 57:1098-1103, 1976.

14. Fischel EE: Serum complement as an indication of the presence and degree of inflammatory reaction in various diseases. *J Clin Invest* 32:568, 1953.

15. Stiehm ER, Fudenberg HH: Serum levels of immune globulins in health and disease: A survey. *Pediatrics* 37:715-727, 1966.

Topical Chemotherapy and Immunotherapy of Mycosis Fungoides

Intermediate-Term Results

Eric C. Vonderheid, MD; Eugene J. Van Scott, MD;
Waine C. Johnson, MD; David A. Grekin, MD; Sucha O. Asbell, MD

• A group of 220 patients with mycosis fungoides (MF) and other lymphomatous diseases was treated with sustained topical applications of dilute aqueous solutions of mechlorethamine hydrochloride for intervals ranging in excess of seven years. Response to treatment, immunologic responsiveness, and subsequent course and survival were inversely related to magnitude of disease at time of starting treatment. Relapses were common, and in most instances were related to failure of maintenance of topical therapy rather than to drug resistance. In selected patients topical therapy with an analog of mechlorethamine (nor-mechlorethamine) and with topical immunogenic agents provided additional improvement.
(*Arch Dermatol* 113:454-462, 1977)

Mycosis fungoides (MF), a progressive cutaneous malignant lymphoma that eventually involves lymph nodes and other internal organs, has remained a lethal disease in a substantial proportion of patients. In an earlier publication[1] we reported that whole body topical applications of dilute aqueous solutions of mechlorethamine hydrochloride were effective treatment of early MF, with 56% maintained in a disease free state at the end of therapy periods of up to four years.

We presented data on the abolition and prevention of delayed hypersensitivity to mechlorethamine, a frequent occurrence with topical mechlorethamine therapy. It was found that cutaneous delayed hypersensitivity to mechlorethamine could be abolished or diminished by giving daily intravenous infusions of small doses of mechlorethamine. We also reported that contact sensitization could be prevented by initial induction of specific immunologic tolerance to mechlorethamine by means of giving small weekly intravenous injections of mechlorethamine three to five weeks prior to initiating topical mechlorethamine therapy. In 12 patients so pretreated, no instance of a delayed hypersensitivity occurred, in comparison to a frequency of 38% in the control group of 56 patients.

A follow-up evaluation of our results with topical mechlorethamine therapy, now covering an additional three years, seems appropriate. We include additional data on immunologic reactivity in MF, the therapeutic effect of delayed hypersensitivity reactions imposed on extensive areas of the body, topical therapy with an mechlorethamine analog (nor-nitrogen mustard), and a reevaluation of the subject of induction of immunologic tolerance to mechlorethamine.

DIAGNOSTIC CLASSIFICATION AND STAGING

Clinical data of 192 patients with MF and 28 patients with various other lymphomatous dermatoses evaluated during the interval from Sept 1, 1968, to Sept 1, 1975, are presented in Table 1. Diagnostic criteria for each grouping were based on conventional clinical and pathologic features.[2-4] (The biopsy specimens were reviewed by one of us [W.C.J.] to assure consistent histopathologic interpretation.) The MF patients were further subclassified into three types according to the predominant clinical features of cutaneous disease when first observed by us: infiltrative plaque-tumors (classical Alibert MF); poikilodermatous lesions with or without infiltration; and diffuse erythroderma (including those otherwise identified as having the Sezary syndrome). The clinical staging system previously used (Table 2) has been followed with the slight modification in connection with patients having erythrodermic disease. Since lymphadenopathy (stage 4) was consistently present in these patients, the cases were subdivided according to percentages of easily detectable circulating atypical mononuclear cells.

TREATMENT

The use of topical and intralesional mechlorethamine, procedures to induce immunologic tolerance prior to its use, and desensitization of allergic patients have been described in detail in the earlier report.[1] Briefly, for topical therapy with mechlorethamine, 10 mg of mechlorethamine powder are dissolved in 1½ to 2 ounces of water; a teaspoon of glycerin or vegetable oil may be added for patients with xerotic skin. The patient is instructed to apply the freshly prepared solution daily over the *entire* cutaneous surface, but relatively sparingly in the intertriginous zones. The dose and frequency of applications are adjusted according to any encountered irritation and response to therapy. In the event of slow responding disease, drug applications may be increased to two or three times daily, governed only by degrees of irritation that may arise. Topical painting usually has been preceeded by a series of small intravenous injections of mechlorethamine for the

Accepted for publication July 29, 1976.
From the Skin and Cancer Hospital, Department of Dermatology, Temple University School of Medicine (Drs Vonderheid; Van Scott; Johnson; and Grekin), and the Department of Radiation Therapy and Nuclear Medicine, Hahnemann Medical College and Hospital of Philadelphia (Dr Asbell), Philadelphia.
Reprint requests to Skin and Cancer Hospital, 3322 N Broad St, Philadelphia, PA 19140 (Dr Van Scott).

Table 1.—Diagnostic Classification, Age, Sex, and Racial Distribution of 220 Patients With MF and Other Related Conditions

Diagnosis	No.	Median Age*	Sex		Racial Background	
			M	F	W	B
Mycosis fungoides Poikilodermic	23	52	20	3	22	1
Infiltrative	135	61	83	52	127	8
Erythrodermic	34	65	24	10	32	2
Other cutaneous lymphomas	9	53	7	2	9	0
Parapsoriasis en plaque†	2	51	2	0	2	0
Lymphomatoid papulosis	5	52	1	4	5	0
Actinic reticuloid	1	52	1	0	0	1
Uncertain†	11	49	4	7	9	2
Total	**220**		**142**	**78**	**206**	**14**

*Age on entry into study.
†Atypical cells identified histopathologically.

Table 2.—Clinical Staging of Mycosis Fungoides

Stage	Clinical Characteristics of Skin Lesions	Axillary, Inguinal, or Cervical Lymphadenopathy	Internal Lesions
0	0 or hyperpigmentation	0	0
1	Erythematous patches or minimally infiltrated plaques	0	0
2	Moderately infiltrated papules or plaques usually associated with erythematous patches	0	0
3	Tumor or nodule formation; usually associated with papules, plaques, or erythematous patches	0	0
4	Any of above	+	0
5	Any of above	+	+

purpose of inducing immunologic tolerance. For this, 200 μg of mechlorethamine was given as single rapid intravenous injections once weekly for a total of five injections; topical therapy was started at the end of the third or fourth week of injections. Other tolerogenic procedures, however, were also explored in smaller numbers of patients.

Tumors were frequently injected with a drug mixture prepared as follows: 100 μg of mechlorethamine hydrochloride, 1 ml of 2% triamcinolone acetonide suspension (to counteract inflammation due to mechlorethamine) and 1 ml of 1% lidocaine (to relieve pain following injection). Lesions were infiltrated at multiple sites, with 0.05 to 0.1 ml at each site.

In a few patients allergic to mechlorethamine, nor-mechlorethamine, an analog previously demonstrated to have antimitotic properties[5] was applied in a manner similar to that used for mechlorethamine by diluting 5 ml of 5% nor-mechlorethamine in absolute alcohol with 45 ml of water.

Systemic chemotherapy was provided in addition to topical therapy for patients with initial or later evidence of systemic disease (ie, stages 4 or 5) and for patients with rapidly progressive, unresponsive, or otherwise problematic intracutaneous disease. Various drugs were used, including mechlorethamine as a single agent or in combination with vincristine sulfate, procarbazine, and/or prednisone (MOPP); cyclophosphamide; or methotrexate. The dosage schedule used for intravenous mechlorethamine was what we have termed "slow dose," a schedule in which 2 mg of mechlorethamine is given daily for a usual total dose of 0.4 mg/kg.[6]

Topical immunotherapy was explored on selected patients, in which either mechlorethamine or dinitrochlorobenzene was used as the antigenic agent. Mechlorethamine was utilized usually in cases where spontaneous sensitization to mechlorethamine had occurred during the course of topical therapy; dinitrochlorobenzene was used in other cases, in which the procedure for induction of delayed hypersensitivity to dinitrochlorobenzene was as customarily used.[7] At the time of immunotherapy the patient's degree of sensitivity was determined by means of titrated patch testing to the appropriate antigen. In patients undergoing mechlorethamine immunotherapy 10, 1, and 0.1 μg of freshly prepared mechlorethamine, in 0.1 ml aqueous solution, were applied to 15 sq cm (3 × 5 cm) areas of clinically normal skin, distributed evenly over the test area, allowed to dry, and left uncovered. In patients undergoing dinitrochlorobenzene immunotherapy a similar titration using 250, 25, and 2.5 μg of dinitrochlorobenzene dissolved in equal parts of acetone and water were applied to 15 sq cm sites. The threshold of reactivity and the desired degree of reaction was determined by observing the test sites over the next 48 hours and the reaction graded as follows: no reaction, 0; erythema only, +1; erythema and edema, +2; erythema and vesiculation, +3; bulla formation and/or denudation, +4. Further titrations to smaller quantities were done as needed in a few cases where exquisite sensitivity existed to either antigen. Immunotherapy consisted of one or more applications of the antigen to most of the body surface areas in amounts gauged to provoke a distinctly discernible delayed hypersensitivity reaction (+2). In some patients, applications to discernible diseased areas only, generally to provoke a +3 reaction, were done. The resulting dermatitis was symptomatically treated with bland topical creams or wet dressings with or without antihistaminic drugs to relieve pruritus for approximately one week after the reaction appeared.

RESPONSES TO TOPICAL MECHLORETHAMINE

Table 3 summarizes the current status of 166 MF patients followed for a minimum period of six months treated with topical mechlorethamine and, if necessary, with other modes of therapy. A prognostic correlation is found between the initial magnitude of disease, as connoted by the clinical stage, and the current status. About half of patients with typical infiltrative MF apparently limited to the skin (stages 1 to 3) are currently free of detectable disease.

A similar prognostic correlation is found in erythrodermic patients when the percentage of circulating Sezary cells is used as an index of severity of disease. Patients with high percentages of circulating Sezary cells in general responded less well to therapy

Table 3.—Status of 166 MF Patients Treated With Topical Mechlorethamine With or Without Subsequent Additional Therapy

Initial Classification and Stage	No. Treated	Median Time Followed up, mo	No. to Achieve Complete Remission (%)	Current Status*						
				Disease Free	(%)	Partial Improvement	No Change	Worse	Dead†	(%)
Poikiloderma group										
1 and 2	18	56	17 (94)	12	(67)	...	6	0	0	(0)
Infiltrative group										
1	20	18	18 (90)	14	(70)	...	5	1	0	(0)
2	52	34	42 (81)	24	(46)‡	11	11	3	3	(6)
3	17	45	12 (71)	7	(41)	5	0	1	5	(2)
4	23	14	11 (48)	2	(19)	8§	4	1	7	(3)
5	5	15	1 (20)	0	(0)	1	0	...	4	(8)
Erythroderma group										
No Sezary cells	9	48	5 (56)	5	(56)	0	2	0	2	(2)
Sezary cells (1%-10%)	7	30	4 (57)	2	(29)‖	3¶	1	1	0	(0)
Sezary cells (> 10%)	15	28	4 (27)	1	(7)	3	3	1	7	(4)

*As determined by comparison of initial to current stage.
†Includes only deaths related to advanced MF or its treatment. Includes ten deaths probably unrelated to MF: ‡Myocardial infarction (two), cerebrovascular accident, pneumonia, pancreatic carcinoma, esophageal carcinoma. §Myocardial infarction, cerebrovascular accident, carcinoma of colon. ‖Carcinoma of lung scar. ¶Bronchoalveolar carcinoma of lung.

Table 4.—Status of 72 MF Patients Treated With Topical Mechlorethamine Only

Initial Classification and Stage	No. Treated	Median Time Followed, mo	No. to Achieve Complete Remission (%)	Current Status*					
				Disease Free	(%)	Partial Improvement	No Change	Worse	Dead
Poikiloderma group									
1 and 2	14	53	13 (93)	10	(71)	...	4	0	0
Infiltrative group									
1	17	15	16 (94)	14	(82)	...	3	0	0
2	36	25	31 (86)	21	(84)†	6	8	1	0
3	2	77	2 (100)	1	(50)	1	0	0	0
4	1	9	0 (0)	0	(0)	0	1	0	0
Erythrodermic group									
No Sezary cells	2	48	2 (100)	2	(100)	0	0	0	0
Sezary cells (1%-10%)	0	...	...	...	...	...	...	...	...
Sezary cells (> 10%)	0	...	...	...	...	...	...	...	...

*As determined by comparison of initial to current stage.
†Includes six deaths probably unrelated to MF (myocardial infarction [two], cerebrovascular accident, pneumonia, pancreatic carcinoma, esophageal carcinoma).

than patients with low numbers of cells.

Table 4 presents data on those patients maintained on a regimen of topical mechlorethamine only. Topical mechlorethamine was found to be effective as a sole therapeutic agent in most patients with early disease, whereas patients with more advanced disease required additional forms of therapy, ie, systemic chemotherapy.

Data on the remaining 21 patients with miscellaneous lymphomatous diseases, are summarized in Table 5. Although the numbers are small, the therapeutic improvements in most patients have been less than those achieved in MF.

MAINTENANCE THERAPY WITH TOPICAL MECHLORETHAMINE

The therapeutic objectives in our patients have been (1) to induce a complete clinical remission, and (2) thereafter maintain the remission for sustained intervals. Table 6 presents data on the course of patients who achieved a complete remission. Any detectable clinical sign of renewed activity of disease, ie, visible dermatitis, was considered to be an indication of relapse, even in the absence of specific histopathologic confirmation. Of the 114 MF patients in whom a complete remission was achieved, in only 41 (36%) was the remission completely sustained. In 14 patients complete remissions have lasted for more than three years.

Survival curves of patients with MF as determined by an actuarial method[8] are presented in Fig 1 and 2. The numbers at each point denote the number of patients alive at the beginning of each time interval. Patients dying of causes probably unrelated to MF are recorded as being alive during the year of their death.

The major clinical problems encountered with topical mechlorethamine therapy were irritation, allergic sensitization, and therapeutic unresponsiveness. Mild irritation was commonly observed in intertriginous zones

Table 5.—Status of 21 Patients With Miscellaneous Lymphomatous Disease Treated With Topical Mechlorethamine With or Without Additional Therapy

Initial Classification	No. Treated	Median Time Followed, mo	Current Status*						
			Disease Free	(%)	Partial Improvement	No Change	Worse	Dead	(%)
Other cutaneous lymphomas	9	21	2	(22)	1	2	1	3	(33)
Parapsoriasis en plaque	1	31	0	(0)	0	1	0	0	(0)
Lymphomatoid papulosis	4	28	1	(25)	1	2	0	0	(0)
Actinic reticuloid	1	32	0	(0)	1†	0	0	0	(0)
Uncertain diagnosis	6	27	1	(17)	0	5	0	0	(0)

*As determined by comparison of initial to current stage.
†Loss of abnormal skin infiltration; persistance of photosensitivity.

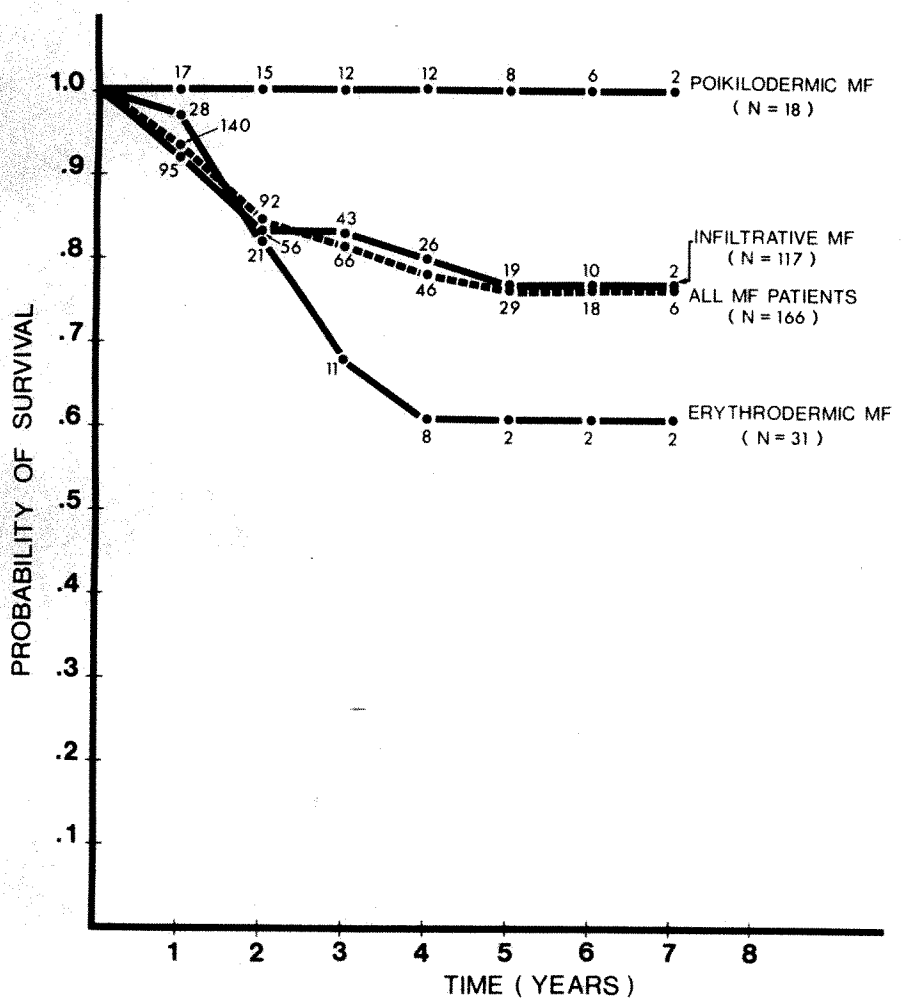

Fig 1.—Actuarial survival curves for MF patients according to clinical appearance.

and at lesion sites. Irritation required diminution of dose or frequency of applications in 11% of poikilodermic patients, 7% of patients with infiltrative lesions, and 23% of erythrodermic patients. Relative drug resistance, as judged by unusually slow or minimal resolution of lesions occurred in 6% of poikilodermic, 23% of infiltrative, and 29% of erythrodermic patients. Allergic sensitization of the delayed type, when occurring, usually was clinically apparent within 14 to 28 days after initial topical exposure to drug.

Recurrence of clinical disease following complete remission, occurring in many patients (Table 6), had variable causes. These included interruption of topical therapy because of irritation or allergic sensitization, patient noncompliance with prescribed procedures, acquired drug resistance, and new evidence of internal disease. Acquired unresponsiveness to therapy was fairly common in advanced stages of infiltrative MF and Sezary syndrome but also in 20% of patients with infiltrative MF, stages 1 and 2.

CORRELATION OF IMMUNOLOGIC RESPONSIVENESS WITH TYPE AND EXTENT OF DISEASE

Table 7 presents data on delayed hypersensitivity to dinitrochlorobenzene and mechlorethamine. Patients presenting with poikilodermic MF appear to have a normal immunologic responsiveness to dinitrochlorobenzene as compared to reported normal controls,[9,10] whereas those with other clinical forms seem to have a somewhat depressed responsiveness. These results augment those of an earlier report[11] that indicated a near normal responsiveness to dinitrochlorobenzene in patients with MF limited to the skin, a study that otherwise did not take into account stages of disease.

A comparison of dinitrochlorobenzene and mechlorethamine reactivity suggests that dinitrochlorobenzene is a more potent antigen than mechlorethamine. In support of this interpretation is the observation that few patients not sensitizable to dinitrochlorobenzene became sensitized to mechlorethamine, and that immunologic reactivity to mechlorethamine seemed relatively more suppressed with advanced disease. However, a definite conclusion on this cannot be established because the conditions for application of each are distinctly different; ie, dinitrochlorobenzene is applied in irritant quantities to a

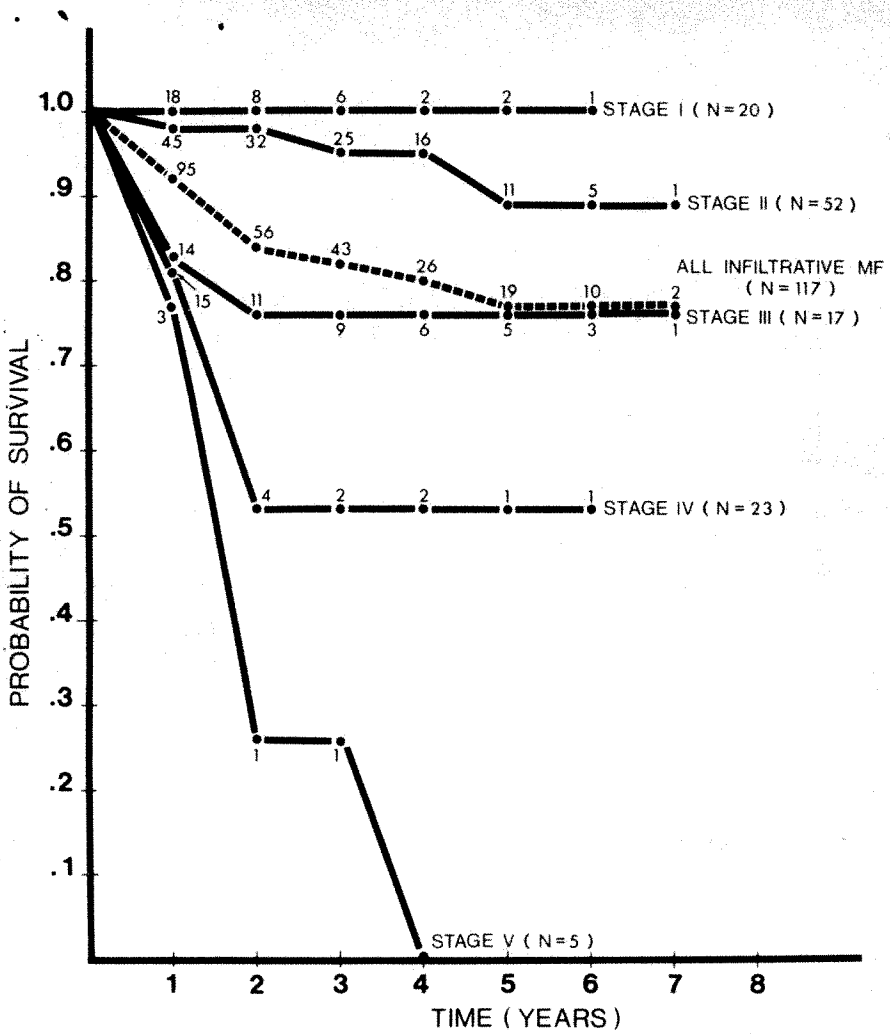

Fig 2.—Actuarial survival curves for infiltrative MF patients in different clinical stages.

small area of the skin, whereas mechlorethamine is applied in subirritant doses to the entire skin surface.

PROGNOSTIC SIGNIFICANCE OF INTACT IMMUNOREACTIVITY

In general, patients who were dinitrochlorobenzene-sensitive achieved clinical remission sooner (four months) than patients who were not sensitive (six months), although both groups eventually achieved remission in equal frequency. A slightly decreased frequency of MF-related deaths was observed at a given clinical stage in dinitrochlorobenzene-sensitive patients compared to the dinitrochlorobenzene-nonsensitive group (Table 8), but this difference may not be statistically significant. Furthermore, we have observed ten patients who eventually lost their ability to react to dinitrochlorobenzene, and this loss was associated with systemic dissemination of disease. These observations support the general factor in host defense to MF as with other forms of cancer.

INDUCTION OF SPECIFIC IMMUNOLOGIC TOLERANCE TO TOPICAL MECHLORETHAMINE

Initial observations presented in a previous report[1] suggested that the frequency of delayed hypersensitivity to mechlorethamine could be diminished by small preliminary injections of mechlorethamine intravenously. Since the present review of accumulated data indicates that immunologic responsiveness to mechlorethamine varies considerably with different clinical presentations and stages, reassessment of this subject seems necessary to assure exclusion of bias on the basis of patient selection.

Table 9 presents a summary of results with two tolerogenic schedules according to clinical classification. The patients presented in this table excluded all who had received any previous therapy. However, a selection bias may still exist within these groups, ie, schedule A contains proportionately more patients at stage 1 and fewer at stage 2 than the control group, a difference probably favoring greater inherent immunoreactivity within the schedule A group. Schedule B, which differs from schedule A only by the addition of oral mechlorethamine to the regimen, appears to have induced tolerance more successfully. The statistical significance of these differences however remains uncertain, and no further conclusions can be drawn by us at this time.

DESENSITIZATION TO MECHLORETHAMINE

As previously reported,[1] small doses of intravenous mechlorethamine administered daily may achieve states of desensitization to enable resumption of topical therapy. The procedure unfortunately requires one or more hospitalizations of one to four weeks' duration and has potential risks. Therefore other therapeutic options, eg, immunotherapy or nor-mechlorethamine, have been preferred by us recently.

We have observed 60 instances of delayed contact hypersensitivity to mechlorethamine, 16 of which were related to prior topical therapy initiated by other physicians. Thirty-one patients were hospitalized for the intravenous desensitization procedures. In seven cases, the procedure was discontinued abruptly because of the development of linear dermatitis overlying the vein of the infusion, a complication generally necessitating lower doses and extended hospitalization periods. In ten patients, desensitization was achieved with one hospitalization, permitting resumption of topical therapy without further difficulty. In 12 patients hyposensitization was achieved, as assessed by serial patch testing. Neither desensitization nor hyposensitization was reached in two patients. The likelihood of successful desensitization seemed better

Table 6.—Follow-up Course of Patients to Date

Initial Classification and Stage	Total No.	No. to Achieve Complete Remission	(%)	Median Months	Time in to Remission (Range)	Subsequent Course: Sustained Remissions: No. of Patients	(%)	Median Duration (mo)	Relapses: No. of Patients	(%)
Mycosis fungoides										
Poikilodermic										
1 and 2	18	17	(94)	5	(1-37)	9	(53)	45+	8	(47)
Infiltrative										
1	20	18	(90)	4	(1-23)	12	(67)	14+	6	(33)
2	52	42	(81)	4	(1-19)	14	(33)	12+	28	(67)
3	17	12	(71)	7	(1-32)	1	(8)	3+	11	(92)
4	23	11	(48)	5	(1-28)	1	(9)	21+	10	(91)
5	5	1	(20)	4	...	0	(0)	...	1	(100)
Erythrodermic:										
No Sezary cells	9	5	(56)	7	(1-12)	2	(40)	49+	3	(60)
Sezary cells (1%-10%)	7	4	(57)	7	(3-10)	2	(50)	17+	2	(50)
Sezary cells (> 10%)	15	4	(27)	7	(6-13)	0	(0)	...	4	(100)
Totals	**166**	**114**				**41**			**73**	
Other cutaneous lymphomas	9	7	(78)	9	(2-15)	1	(14)	32+	6	(86)
Lymphomatoid papulosis	4	2	(50)	2	(2-6)	1	(25)	26+	3	(75)

Table 7.—Frequency of Delayed Hypersensitivity to Dinitrochlorobenzene and Mechlorethamine*

Assessment	Dinitrochlorobenzene: No. Tested	No. Allergic	(%)	Mechlorethamine: No. Treated	No. Allergic	(%)	Dinitrochlorobenzene Mechlorethamine: No. Tested	No. Allergic	(%)
Mycosis fungoides									
Poikilodermic									
1 and 2	15	14	(93)	8	6	(75)	16	15	(94)
Infiltrative									
1	16	12	(75)	6	4	(67)	18	14	(78)
2	45	36	(80)	19	7	(37)	52	43	(83)
3	16	12	(75)	4	1	(25)	16	12	(75)
4	11	7	(64)	7	1	(14)	13	7	(54)
5†	...	...	...	...	...	...	...	...	...
Erythrodermic									
No Sezary cells	7	5	(71)	1	1	(100)	7	5	(71)
Sezary cells (1%-10%)	3	2	(67)	...	...	...	3	2	(67)
Sezary cells (> 10%)	8	2	(25)	4	0	(0)	9	2	(22)
Other cutaneous lymphomas	6	5	(83)	...	...	...	6	5	(83)
Lymphomatoid papulosis	3	2	(67)	1	0	(0)	4	2	(50)
Actinic reticuloid	1	0	(0)	...	...	...	1	0	(0)
Uncertain diagnosis	3	2	(67)	...	...	...	3	2	(67)

*Excludes patients who received prior or concurrent administration of drugs known to suppress allergenicity. Patients who received small doses of drugs for "induction of tolerance" to mechlorethamine are also excluded from the mechlorethamine column only.
†Three patients in stage 5 tested for dinitrochlorobenzene were nonreactive: all had received some prior chemotherapy.

Table 8.—Correlation of Response to Topical Mechlorethamine and Initial Dinitrochlorobenzene Reactivity in Infiltrative MF

Stage	Dinitrochlorobenzene Status	No. Treated	No. to Achieve Complete Remission	(%)	Current Status*: Disease Free	(%)	Partial Improvement	No Change	Worse	Dead†	(%)
2	+	35	29	(83)	14	(40)	10	8	3	0	(0)
	−	9	8	(89)	5	(56)	0	2	0	2	(22)
3	+	12	9	(75)	5	(42)	4	0	1	2	(17)
	−	4	3	(75)	2	(50)	1	0	0	1	(25)
4	+	7	4	(57)	1	(14)	1	2	0	3	(43)
	−	6	3	(50)	1	(17)	1	1	0	3	(50)

*As determined by comparison of initial to current stage.
†Deaths related to MF or its treatment.

Table 9.—Frequency of Delayed Hypersensitivity Reactions to Topical Mechlorethamine With and Without Induction of Tolerance With Intravenous Mechlorethamine

Clinical Assessment	No Induction			Schedule A*			Schedule B†		
	No. of Patients	Allergic	(%)	No. of Patients	Allergic	(%)	No. of Patients	Allergic	(%)
Mycosis fungoides Poikilodermic 1 and 2	8	6	(75)	7	2	(29)	2	0	(0)
Infiltrative 1	6	4	(67)	13	5	(38)	2	0	(0)
2	19	7	(37)	9	4	(44)	4	0	(0)
3	4	1	(25)	4	1	(25)	2	1	(50)
Total	**37**	**18**	(49)	**33**	**12**	(36)	**10**	**1**	(10)

*Two hundred micrograms of mechlorethamine IV once weekly for five injections; topical mechlorethamine started at third or fourth week.
†Same as above + daily oral mechlorethamine, 6 μg three times a day for one to three weeks.

Table 10.—Course of MF Following Unintentional Delayed Hypersensitivity Reaction to Topical Mechlorethamine

Initial Assessment	No. Observed	Degree of Improvement		
		None	Partial	Complete
Mycosis fungoides Poikilodermic 1 and 2	8	6	2	0
Infiltrative 1	5	1	1	3
2	15	4	4	7
3	5	2	0	3
Erythrodermic No Sezary cells	3	1	0	2
Sezary cells (1%-10%)	1	1	0	0
Sezary cells (> 10%)	2	2	0	0
Total	**39**	**17**	**7**	**15**

with patients manifesting lesser degrees of reactivity to mechlorethamine on the onset. Complete desensitization of the hyposensitized group was eventually achieved in four cases after a second attempt and in three additional cases after several attempts. Thus 17 of 24 patients (71%) have been able to resume sustained applications of topical mechlorethamine following one or more desensitization courses of intravenous mechlorethamine.

INFLUENCE OF UNINTENTIONAL DELAYED HYPERSENSITIVITY REACTIONS TO MECHLORETHAMINE ON SUBSEQUENT COURSE OF DISEASE

Spontaneous development of an unintentional delayed hypersensitivity reaction during topical mechlorethamine therapy appears to have a beneficial effect on the short-term course of MF (Table 10). Of 39 patients with active MF at the time of the spontaneous delayed hypersensitivity reaction, which necessitated discontinuation of the drug, 15 (38%) were subsequently noted to lose all evidence of their disease, without additional therapy except for the brief administration of a topical or systemic corticosteroid preparation for the allergic reaction. At the time of the reaction most of these patients had improved partially from the influence of the preceding mechlorethamine therapy such that a lesser degree of disease involvement was present. Of interest, the median time to achieve a complete remission in these patients was about two months, and the duration of remission seemed to be inversely correlated to the clinical stage at the time of the delayed hypersensitivity reaction.

Patients with infiltrative MF seemed particularly likely to benefit from a delayed hypersensitivity reaction. One patient, however, converted from infiltrative MF to the Sezary syndrome following the delayed hypersensitivity reaction.

OBSERVATIONS ON INTENTIONALLY INDUCED DELAYED HYPERSENSITIVITY REACTIONS (IMMUNOTHERAPY)

Based on the foregoing and on previous observations that delayed hypersensitivity reactions have beneficial effects on individual lesions,[12] intentional topical immunotherapy using mechlorethamine or dinitrochlorobenzene as antigens was given to 19 patients with MF (Table 11). Complete clearing of clinically detectable disease followed immunotherapy in eight (42%) patients.

In the first few months following a single course of immunotherapy, a moderate decrease in the magnitude of lesion infiltration was observed in most patients. The benefits were more difficult to assess in poikilodermic MF, and in one patient with erythrodermic MF the disease transiently seemed to worsen. Thus, the majority of our patients required more than one course of immunotherapy to achieve complete remission.

The duration of remissions have ranged from 2 months to beyond 22 months without any further treatment. Application of dinitrochlorobenzene or mechlorethamine solutions either to the whole body or to lesions alone produced complete clinical remission. Although the numbers are small, the duration of remission seems to be somewhat longer following whole body applications.

The complications of immunotherapy were excessive pruritus and occasional secondary skin infections. Of interest, several patients became less sensitive to mechlorethamine after

Table 11.—Effect of Intentionally Induced Topical Delayed Hypersensitivity Reactions on MF

Initial Assessment	No. Treated	Degree of Improvement		
		None	Partial	Complete
Mycosis fungoides				
Poikilodermic				
1 and 2	3	1	0	2
Infiltrative				
1	1	0	1	0
2	9	1	4	4
3	5	0	3	2
Erythrodermic				
Sezary cells (1%-10%)	1	1	0	0
Total	**19**	**3**	**8**	**8**

repeated courses of topical mechlorethamine immunotherapy.

TOPICAL THERAPY WITH NOR-NITROGEN MUSTARD (PRELIMINARY OBSERVATIONS)

Nor-nitrogen mustard (nor-mechlorethamine) was utilized as topical treatment for 3 patients with poikilodermic MF, 34 patients with infiltrative MF, and in 7 patients with erythrodermic variants. The indications for its use included contact hypersensitivity to mechlorethamine (24 patients); as a primary drug when mechlorethamine was precluded by irritation or resistance (9 patients); and as a primary drug for an initial four-week interval, ie, a period selected for induction of tolerance to mechlorethamine (11 patients).

Delayed hypersensitivity reactions to nor-mechlorethamine developed in 11 patients. In ten patients already allergic to mechlorethamine, the reaction to nor-mechlorethamine developed on first exposure, indicating a 42% frequency of an immunologic cross reactivity between these compounds. One additional patient who never applied mechlorethamine developed delayed hypersensitivity to nor-mechlorethamine indicating the potential of primary sensitization to this drug.

Of 33 patients who received nor-mechlorethamine uncomplicated by delayed hypersensitivity, 17 patients improved to a measurable degree during its use, with complete eradication of lesions in 5 patients. The responsiveness to nor-mechlorethamine seemed somewhat less than with usual doses of topical mechlorethamine. It is concluded that nor-mechlorethamine can be effectively used in the topical treatment of early-stage MF, and that higher topical dosages for longer intervals may be required to improve treatment results.

FREQUENCY OF VARIOUS EPITHELIAL AND INTERNAL NEOPLASMS IN PATIENTS RECEIVING A TOPICAL NITROGEN MUSTARD

Since systemically administered mechlorethamine is carcinogenic in animals,[13] an important consideration is whether topical mechlorethamine, when applied over long periods of time, will increase the incidence of epithelial or other neoplasms. To investigate this possibility, the duration of topical mechlorethamine usage in our patients was compared to the observed numbers of epithelial and internal neoplasms. Patients having received prior therapy known to be carcinogenic, ie, arsenic or whole body radiation, or those giving a history of a prior epithelial neoplasms were excluded from the analysis.

Of 140 patients who received topical mechlorethamine for a three-year interval or less, 6 (4%) instances of an epithelial neoplastic growth (2 actinic keratoses, 2 squamous cell carcinomas, 1 Bowens disease, and 1 basal cell carcinoma) were confirmed by biopsy. Of 26 patients treated in excess of three years, 7 (27%) patients developed at least one type of epithelial neoplasm and, in 4 patients, the lesions were of several types. The single lesions included two instances of actinic keratoses and of Bowens disease; the lesions on the other four patients include both actinic keratoses and squamous cell carcinomas. All were noted to develop in the sun-exposed areas of white-skinned persons. There have been no examples of malignant melanoma. Thus, an increased frequency of actinic keratoses and squamous cell carcinomas may be emerging in our patients, perhaps by augmenting precarcinogenic solar damage. These conclusions are based on a small number of patients observed over a relatively short time interval, and may or may not be valid.

Six patients have developed internal neoplasms. The tumor types included carcinomas of the esophagus, pancreas, and colon; bronchoalveolar carcinoma; adenomatous carcinoma of the lung (two cases); and a pituitary tumor of unknown type. Four of these patients had received systemic alkylating agents or other potential carcinogens in the past. There appears to be little evidence at this time to implicate topical mechlorethamine as a cause of internal cancer.

COMMENT

Historically, both radiation and mechlorethamine have been recognized as effective therapeutic modalities for MF.[14] Recently, better utilization of each has produced sustained remissions to the point that "cure" is now considered possible. Important to both are early and adequate treatment, while the disease remains localized to the skin.

With radiation therapy, whole body treatment without serious internal side effects is now possible with high energy electrons. In 1971, Fuks and Bagshaw[15] reported that aggressive administration of whole body electron beam therapy could produce long remissions and probable cures of MF limited to the skin. Of 132 patients treated, 14 (11%) achieved sustained remission for intervals ranging from 3 to 14 years and may be considered cured on the basis of actuarial survival data.[16] No remissions beyond one year occurred when tumors were present in the skin. The treatment has the advantage of not requiring maintenance therapy but is limited to special centers and in some patients may cause cutaneous side effects such as

dermatitis and atrophy. A direct comparison with our results is not possible since the clinical classifications are somewhat different.

In 1973, Van Scott and Kalmanson[1] showed that complete remissions of MF could be achieved if dilute solutions of mechlorethamine were regularly applied to the entire cutaneous surface.[1] It is now apparent that recurrences of MF will often develop if the treatment is not adequately delivered. Fourteen patients have remained completely free of disease from three to seven years after remission, and further experience with topical mechlorethamine is needed to determine whether cure is actually achieved. The ideal maintenance regimen for the patient in complete remission, ie, dose, frequency, and duration of topical mechlorethamine therapy, has not been established at this time. In practice we currently continue whole body topical therapy once daily for six months after complete remission has been reached, and thereafter at lesser frequencies for a period of at least three years following complete remission.

Our exploratory experience to date with immunotherapy indicates this form of treatment might consistently induce clinical remissions. Histologic changes followed delayed hypersensitivity reactions imposed on lesions of MF have shown rises in lymphocyte proportions with decreases in atypical hyperchromatic "MF" cells.[17]

Our poor results in maintaining complete remissions in patients with tumors (ie, stage 3) suggest that extracutaneous involvement may go undetected in many instances. Indeed recent information from staging laparotomies indicates that the tumor stage is often associated with ultrastructurally detectable disease in the lymph nodes and other internal organs.[18] Furthermore, we have observed that the cellular composition of tumors at advanced stages provides substantial prognostic value; that is, tumors composed of a predominance of atypical histiocytoid cells generally respond poorly to mechlorethamine treatment while tumors with a predominance of lymphocytoid cells have a good response (unpublished observations).

In conclusion, treatment of MF today can be optimistic, with long remissions now possible from adequate whole-body therapy of early disease. Our experience using topical mechlorethamine for its chemotherapeutic properties, which are apparently separable from its immunogenic properties, indicates that recurrences may occur when maintenance applications are too infrequently applied. Therefore sustained intensive applications of mechlorethamine at a dose and frequency to maintain a disease-free state for a minimum period of three years are recommended. It seems probable that immunotherapy will further augment the benefits of either topical mechlorethamine or electron beam therapy.

This investigation was supported in part by grant 5 P01 CA11536 and 5 M01 RR 349 from the National Institutes of Health.

Dorothy Rose, Susan Corbett, and the staff of the Clinical Research Center, Temple University Hospital, gave assistance with our patients.

Nonproprietary Names and Trademarks of Drugs

Mechlorethamine hydrochloride–*Mustargen Hydrochloride.*
Vincristine Sulfate–*Oncovin.*

References

1. Van Scott EJ, Kalmanson JD: Complete remissions of mycosis fungoides lymphoma induced by topical nitrogen mustard (HN2): Control of delayed hypersensitivity to HN2 and by induction of specific immunologic tolerance. *Cancer* 32:18-30, 1973.

2. Van Scott EJ, Haynes HA: Cutaneous lymphomas, in Fitzpatrick TB, Arndt KA, Clark WH Jr, et al (eds): *Dermatology in General Medicine.* New York, McGraw Hill, 1971, pp 556-573.

3. Macaulay WL: Lymphomatoid papulosis: A continuing self-healing eruption, clinically benign-histologically malignant. *Arch Dermatol* 97:23-30, 1968.

4. Ive FA, Magnus IA, Warin RP, et al: "Actinic Reticuloid": A chronic dermatosis associated with severe photosensitivity and the histological resemblance to lymphoma. *Br J Dermatol* 81:469-485, 1969.

5. Van Scott EJ, Yu RJ: Antimitotic, antigenic and structural relationships of nitrogen mustard and its homologues. *J Invest Dermatol* 62:378-383, 1974.

6. Van Scott EJ, Grekin DA, Kalmanson JD, et al: Frequent low doses of intravenous mechlorethamine for late-stage mycosis fungoides lymphoma. *Cancer* 36:1613-1618, 1975.

7. Catalona WJ, Taylor PT, Rabson AS, et al: A method for dinitrobenzene contact sensitization–a clinicopathologic study. *N Engl J Med* 286:399-402, 1972.

8. Berkson J, Gage RP: Calculation of survival rates for cancer. *Proc Staff Meeting Mayo Clin* 25:270-286, 1950.

9. Catalona WJ, Taylor PT, Chretien PB: Quantitative dinitrochlorobenzene contact sensitization in a normal population. *Clin Exp Immunol* 12:325-333, 1972.

10. Waldorf DS, Willkens RF, Decker JL: Impaired delayed hypersensitivity in an aging population: Association with antinuclear reactivity and rheumatoid fever. *JAMA* 203:831-834, 1968.

11. Blaylock WB, Clendenning WE, Carbone PP, et al: Normal immunologic reactivity in patients with the lymphoma mycosis fungoides. *Cancer* 19:233-236, 1966.

12. Ratner AC, Waldorf DS, Van Scott EJ: Alterations of lesions of mycosis fungoides lymphoma by direct imposition of delayed hypersensitivity reactions. *Cancer* 21:83-88, 1968.

13. Heston WE: Carcinogenic action of the mustards. *J Natl Cancer Inst* 11:415-423, 1950.

14. Bluefarb SM: *Cutaneous Manifestations of the Malignant Lymphomas.* Springfield, Ill, Charles C Thomas Publisher, 1959, pp 5-215.

15. Fuks A, Bagshaw MA: Total-skin electron treatment of mycosis fungoides. *Radiology* 100:145-150, 1971.

16. Fuks A, Bagshaw MA, Farber EM: Prognostic signs and the management of the mycosis fungoides. *Cancer* 32:1385-1395, 1973.

17. Waldord DS, Ratner AC, Van Scott EJ: Cells in lesions of mycosis fungoides lymphoma following therapy. *Cancer* 21:264-269, 1968.

18. Variakojis D, Rosas-Uribe A, Rappaport H: Mycosis fungoides: Pathologic findings in staging laparotomies. *Cancer* 33:1589-1600, 1974.

Vasculitis in Granuloma Annulare

Histopathology and Direct Immunofluorescence

Mark V. Dahl, MD; Susanne Ullman, MD; Robert W. Goltz, MD

• Biopsy specimens from patients with granuloma annulare were studied by conventional light and immunofluorescence microscopy. In six of 20 patients, IgM was present in blood vessels of involved skin, and C3 was present in blood vessels in ten of 20 patients. In addition, IgM, C3, or fibrinogen were observed at the dermal-epidermal junction of eight patients. Necrobiotic areas contained fibrinogen. A retrospective histopathologic study of 38 biopsy specimens from other patients with granuloma annulare showed blood vessels with vessel wall necrosis, fibrinoid change, thickening, or occlusion in most specimens. Nuclear dust and extravasation of RBCs were also noted. These findings suggest that an immunoglobulin-mediated vasculitis may be involved in the pathogenesis of granuloma annulare.

(*Arch Dermatol* 113:463-467, 1977)

Granuloma annulare is characterized by necrobiotic granulomas surrounded by a palisade of histiocytic cells.[1-4] The pathophysiologic events leading to formation of a necrobiotic granuloma are unknown. Biopsy specimens from lesions of granuloma annulare frequently show blood vessel thickening.[5] This suggests that occlusion or other events relating to blood vessels may be at least partially responsible for the necrobiosis. In order to examine this possibility, we studied vascular changes in biopsies from patients with granuloma annulare by light and immunofluorescence microscopy.[6]

Accepted for publication Aug 3, 1976.

From the Department of Dermatology, University of Minnesota School of Medicine (Drs Goltz and Dahl), and the Division of Oral Pathology, University of Minnesota School of Dentistry (Dr Ullman), University of Minnesota Medical Center, Minneapolis.

Reprint requests to Department of Dermatology, University of Minnesota Hospitals, Minneapolis, MN 55455 (Dr Dahl).

PLAN OF STUDY

The study consists of two parts. Retrospectively, histopathologic sections from 38 patients with unequivocal granuloma were studied for the presence of pathologic alterations of blood vessels. Prospectively, frozen tissue sections from 20 other patients with granuloma annulare were studied for the presence of immunoglobulins, complement, and fibrinogen.

CLINICAL DATA

Biopsy specimens in which granuloma annulare had been considered in the histopathologic diagnosis were reviewed without prior identification. Only those specimens judged diagnostic of granuloma annulare by histopathologic criteria[1] were retained for further study. Of these, the prebiopsy clinical diagnosis was granuloma annulare in 38 patients, and the histopathologic part of this study was confined to biopsy specimens from these 38 patients.

Biopsies for direct immunofluorescence were performed on 20 other patients. All had a papular eruption compatible with granuloma annulare. The diagnosis was confirmed by biopsy specimens from all patients. Clinical data are summarized in Table 1.

METHODS

Histopathological Findings

Histopathologic sections stained with hematoxylin and eosin were examined for each of the following features: (1) swelling of endothelial cells; (2) thickening of blood vessel walls; (3) fibrinoid change of vessel walls, (4) necrosis of vessel walls; (5) occlusion of vessel lumina; (6) karyorrhexis (nuclear dust) in perivascular tissues; and (7) extravasation of RBCs. The presence of any of these features in any part of the biopsy specimens was recorded.

Immunofluorescence

Specimens were processed for direct immunofluorescence as previously described.[7] Briefly, 4-8 μ cryostat-cut sections were air dried for 15 minutes, washed in pH 7.2 phosphate-buffered saline for 15 minutes, and incubated 30 minutes with an appropriate dilution of antihuman IgG, IgA, IgM, C3, or fibrinogen labeled with fluorescein.

Blocking experiments with appropriate unconjugated antisera to IgG, IgA, IgM, C3, and fibrinogen were performed on adjacent cryostat-cut sections from each biopsy specimen. Prior to incubation with conjugate labeled with fluorescein, these sections were incubated three hours with unconjugated antisera and washed for 30 minutes with pH 7.2 phosphate-buffered saline. Occasionally, blocking incubations were continued for 12 hours.

Rabbit IgG, labeled with fluorescein-isothiocyanate, specific for human γ, μ, and α chains, complement C3, and fibrinogen was used (Dako, Copenhagen). The specificity of the antisera was controlled by crossed immunoelectrophoresis, and the

Table 1.—Immunofluorescence in Involved Skin of Individual Patients With Granuloma Annulare*

Patient No./ Age/Sex	Biopsy Site	Duration, yr	Blood Vessels	Dermal-Epidermal Junction	Necrobiotic Area
1/51/F	Thumb	0.1	IgM	C3	—
2/32/F	Arm	0.5	—	—	Fibr
3/28/F	Hand	9	IgM, C3	IgM, C3	Fibr
4/16/F	Knee	0.2	IgM, C3	IgM	Fibr
5/04/F	Arm	0.1	IgM, C3	IgM	ND
6/71/M	Shoulder	2	—	—	Fibr
7/13/F	Hand	1	—	—	ND
8/36/F	Leg	4	IgM, C3, Fibr	IgM	Fibr
9/30/F	Elbow	6	C3, Fibr	—	Fibr
10/27/M	Hand	2	C3, Fibr	C3, Fibr	Fibr
11/22/F	Elbow	4	—	—	—
12/19/F	Foot	1	—	—	—
13/65/M	Elbow	3	—	—	Fibr
14/25/F	Elbow	1	—	—	—
15/49/F	Shoulder	2	C3	—	Fibr
16/51/F	Neck	1	C3	—	Fibr
17/09/M	Knee	2	IgM, C3	IgM	Fibr
18/21/F	Finger	3	C3, Fibr	C3	Fibr
19/25/F	Elbow	18	—	—	Fibr
20/45/F	Elbow	3	—	—	Fibr
Totals			**IgM 6 C3 10 Fibr 4**	**IgM 5 C3 4 Fibr 1**	**Fibr 14 Neg 4 ND 2**

*Fibr indicates fibrinogen; ND, not done; and—, absent.

conjugated antisera against γ, μ, and α chains were tested on myeloma bone marrow cells. The antibody titer of all conjugates was 100. The titer denotes the number of micrograms of antigen that must be added to 1 ml of antibody to obtain a supernatant containing neither antigen nor antibody,[8] ie, if the titer is 100, 1 ml conjugate absorbs 100 mg pure antigen. The total protein concentration of the conjugates was 1.8 mg/ml. The fluorescein:protein ratios of all conjugates was 0.63 ± 0.03, estimated as the extinction ratio E 495 nm/E 278 nm. This corresponds to a molar F:P ratio of 2.3.[9] The working dilutions of the conjugates were as follows: anti-IgG 1:20, anti-IgM 1:10, anti-IgA 1:10,

Fig 1.—Left, Vasculitis in granuloma annulare. Three affected vessels are seen in midfield (arrow). They adjoin a typical necrobiotic focus of granuloma annulare, seen at the middle right (hematoxylin-eosin, original magnification ×100). Right, Higher magnification of left. Fibrinoid deposits and necrotizing changes in these vessels indicate the presence of significant vasculitic disease (hematoxylin-eosin, original magnification ×250).

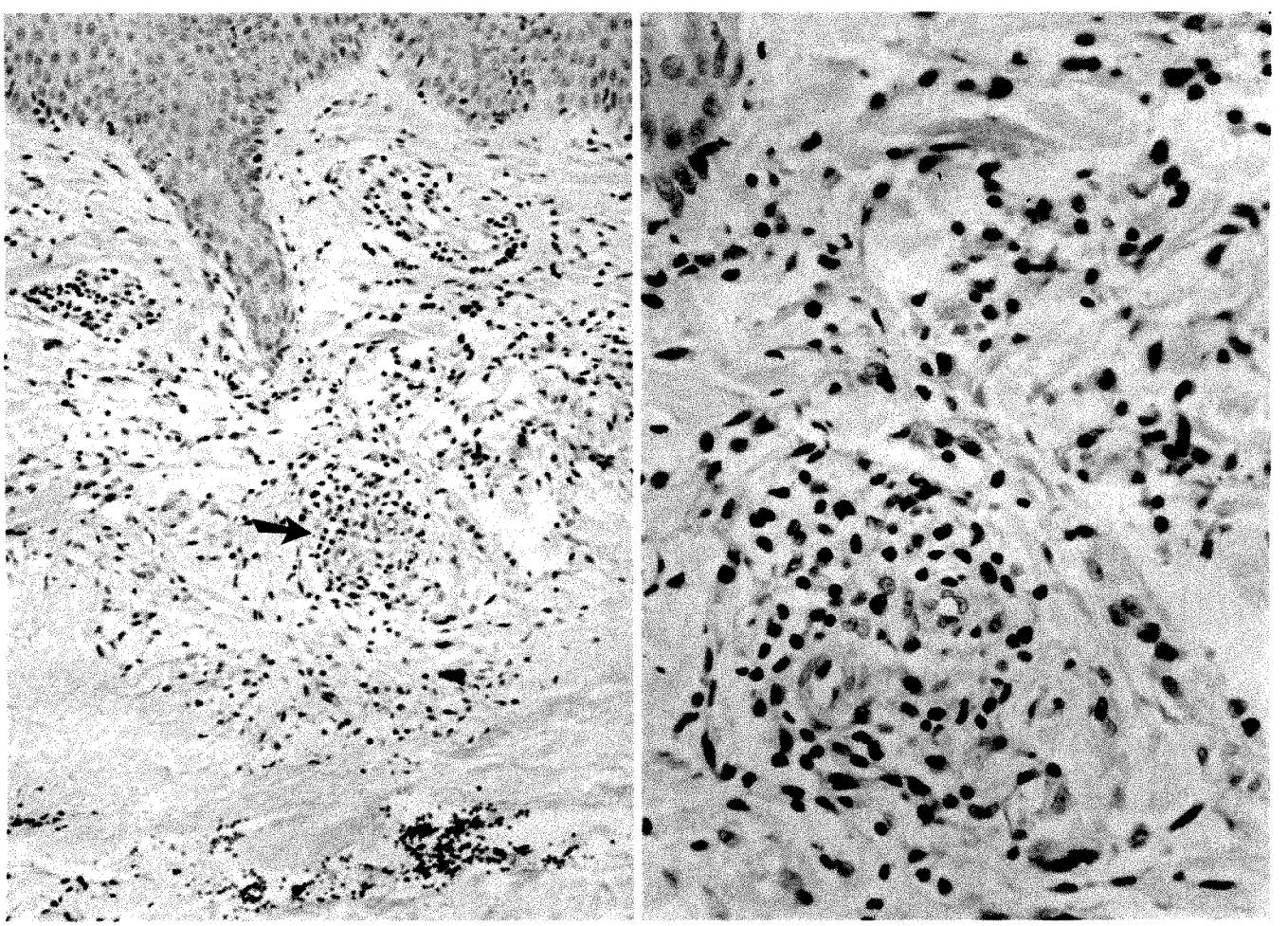

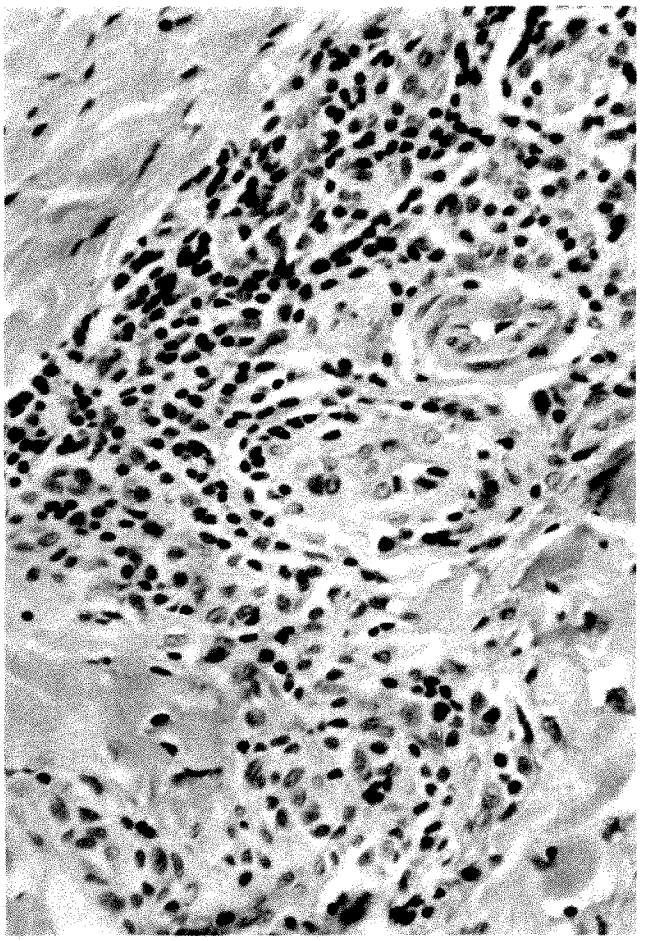

Fig 2.—Endothelial swelling and thrombus formation in several involved blood vessels (hematoxylin-eosin, original magnification ×250).

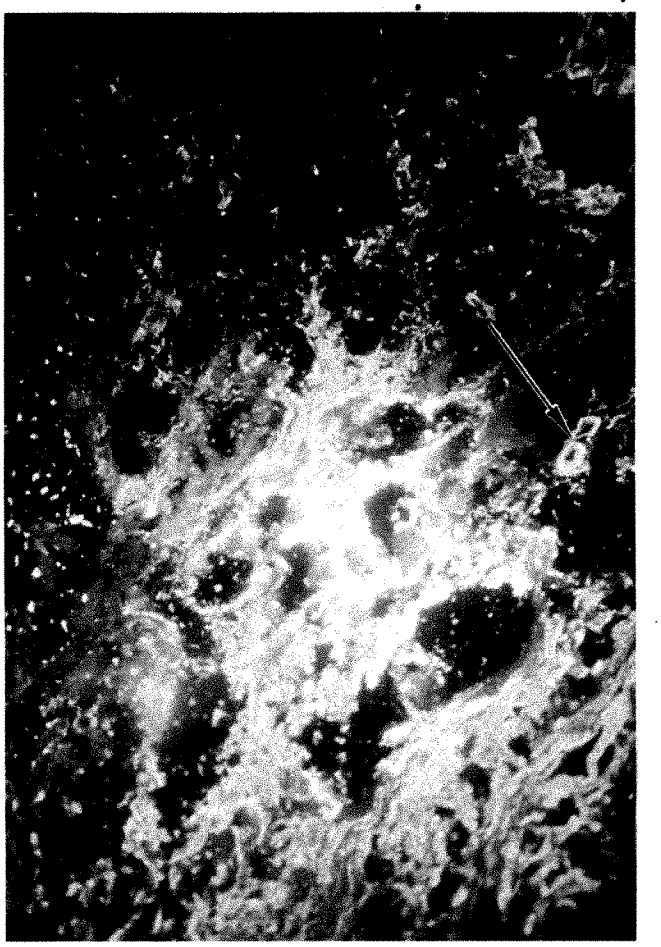

Fig 3.—Fibrinogen is present throughout entire area of necrobiosis as demonstrated by fluorescence microscopy. Fibrinogen is also present in blood vessel walls (arrow) (antihuman fibrinogen, original magnification ×192).

Table 2.—Vascular Changes in Granuloma Annulare

Criteria	Present Total
Endothelial swelling	33/38
Vessel wall thickening	33/38
Necrosis of vessel walls	32/38
Occlusion of vascular lumina	32/38
Fibrinoid changes	29/38
Nuclear dust	13/38
Extravasation of RBCs	10/38

anti-C3 1:10, and anti-fibrinogen 1:20.

Analogous unlabeled rabbit antisera were used for blocking experiments. The antibody titers of these antisera were as follows: anti-IgG 600, anti-IgM 400, anti-IgA 400, anti-C3 400, anti-fibrinogen 300. The total protein concentration of each antisera was 7 to 8 mg/ml. Blocking experiments were performed with undiluted antisera.

Sections were examined for the presence of fluorescence with a Leitz fluorescence microscope equipped for transmitted light illumination, using an Osram HBO 200 lamp, an interference filter with a red contrast band (Optic Laboratory, Copenhagen), a dark-field condensor, and a 2-mm OG 515 nm matched glass barrier filter.

Adjacent frozen tissue sections were stained with hematoxylin and eosin and examined by light microscopy. This step was undertaken to confirm that a necrobiotic granuloma was present in the biopsy specimen processed for direct immunofluorescence.

Biopsies of clinically uninvolved skin from the upper outer arm or buttock were obtained from seven patients (patients 4, 9, 10, 13, 14, 18, and 20) and processed for direct immunofluorescence and light microscopy in an analogous fashion.

Serum Studies

Values for antinuclear antibody, rheumatoid factor, total hemolytic complement (CH50), and fasting blood sugars were determined in seven patients whose biopsies contained IgM or C3. Hepatitis associated antigen and cryoglobulins were also determined in two of these patients.

RESULTS

Histopathology

Results are summarized in Table 2. Vascular changes were observed in 35 of 38 sections. Swelling of vascular endothelial cells, thickening of blood vessel walls, occlusion of vascular lumina, fibrinoid change, and necrosis of blood vessel walls were observed in 33, 33, 32, 29, and 32 biopsy sections, respectively (Fig 1). Fibrinoid change and necrosis were particularly notable in or near areas of necrobiosis, but it

Table 3.—Summary of Immunofluorescence in Involved Skin of Granuloma Annulare in 20 Patients

Location	C3	IgG	IgM	IgA	Absent
Blood vessels	10	0	6	0	9
Dermal-epidermal junction	4	0	5	0	12

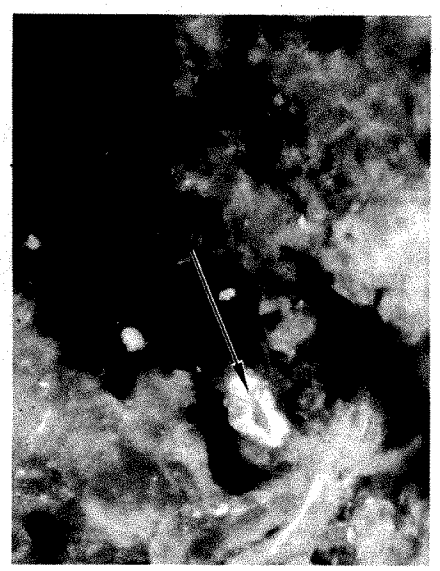

Fig 4.—Blood vessel of granuloma annulare (arrow) (patient 10) demonstrating deposition of C3 (antihuman C3, original magnification ×192).

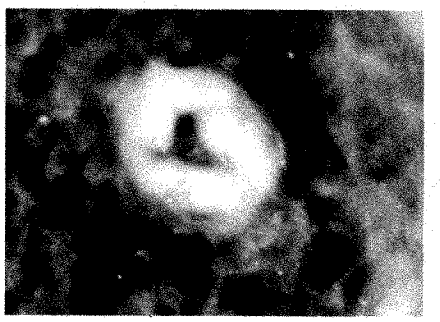

Fig 5.—The C3 in blood vessel of involved skin from patient 3 (antihuman C3, original magnification ×192).

was often difficult to be certain that the necrobiotic material in these areas was of vascular origin, since it sometimes merged imperceptably with the necrobiotic collagen of the granuloma itself.

Occlusion of one or more blood vessels was noted in 32 specimens, but most blood vessels were not occluded (Fig 2). In some specimens, occlusion and necrosis of a blood vessel was so advanced that the blood vessel itself was no longer defineable, but its presence was indicated by a collection of inflammatory cells similar to those surrounding necrobiotic vessels elsewhere.

A large collection of inflammatory cells usually surrounded blood vessels undergoing necrosis, and there was frequently extravasation of RBCs and production of nuclear dust. Inflammatory cells were predominantly lymphocytes or histiocytes although neutrophils were occasionally noted. Smaller numbers of inflammatory cells surrounded less severely involved vessels. Extravasation of RBCs was noted in 10 biopsy specimens; nuclear dust in 13.

Immunofluorescence

Results are summarized in Tables 1, 3, and 4. Deposits of fibrinogen were seen in the necrobiotic areas (Fig 3). This pathological finding was present in 13 of 18 biopsy specimens and correlated well with the presence of necrobiosis noted by light microscopic examination of adjacent hematoxylin and eosin stained sections (Table 2). Deposits of fibrinogen were so massive that blocking procedures had to be maintained for 12 hours before staining became negative or unquestionably weaker.

Complement C3 was demonstrated in blood vessel walls in 10 of 20 biopsy specimens of involved skin (Fig 4 and 5). Immunoglobulin M was present in six specimens. Fibrinogen was present in blood vessels of four of 18 biopsy specimens, but the intense fibrinogen staining of the necrobiotic granuloma itself may have masked fibrinogen in other vessels.

Deposits of IgM were noted at the dermal-epidermal junction of five biopsies (Fig 6). These deposits were granular and appeared similar to deposits commonly seen in biopsy specimens from patients with lupus erythematosus. All biopsy specimens

Table 4.—Summary of Fibrinogen in Involved Skin of Granuloma Annulare in 18 Patients

Location	Fibrinogen	Absent
Blood vessels	4	14
Dermal-epidermal junction	1	17
Necrobiotic zone	13	5

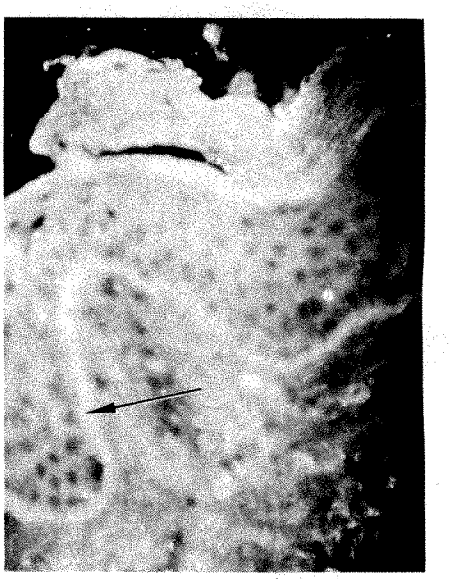

Fig 6.—The IgM at dermal-epidermal junction (arrow) of involved skin from patient 17 (antihuman IgM, original magnification ×192).

with deposits of IgM at the dermal-epidermal junction also had deposits of IgM in dermal blood vessels. Fibrinogen and C3 were also occasionally observed at the dermal-epidermal junction.

Immunoglobulin G and IgA were not detected in any biopsy specimen.

In all specimens, appropriate blocking experiments abolished or greatly reduced specific staining when compared to unblocked sections.

Serum Studies

Values for fasting blood sugar, total hemolytic complement, antinuclear antibody, and rheumatoid factor were normal or absent in all seven patients tested. Hepatitis-associated antigen and cryoglobulins were absent from sera of two patients.

COMMENT

These studies confirm our earlier

observations of immunoglobulins and complement in involved skin of granuloma annulare.[6]

The similarity of histopathologic vessel changes in lesions of granuloma annulare and in the Arthus reaction of experimental animals suggests that an immune-mediated, type 3 reaction might induce the vascular damage and subsequent necrobiosis.[10-15] In support of this hypothesis, IgM, complement, and fibrinogen are present in blood vessels in areas of granuloma annulare. Furthermore, granulomas can be produced in animals by subcutaneous injection of immune complexes formed in antigen-antibody equivalence, or antibody excess.[16]

There are, however, some differences between granuloma annulare and a typical type III immune vasculitis such as anaphylactoid purpura or the Arthus reaction. Lesions of granuloma annulare remain for weeks, months, or years, while lesions of allergic vasculitis disappear within days. In granuloma annulare, the infiltrate around blood vessels is composed predominantly of mononuclear cells rather than neutrophils, again suggesting a less acute process. Similarly, deposition of immunoglobulins and complement in blood vessels can be demonstrated even when lesions have persisted for months or years, whereas immunoglobulins can be demonstrated in blood vessels only during the first 24 hours after induction of the Arthus reaction.[11] These differences suggest that the immune reaction that may induce lesions of granuloma annulare is a chronic, ongoing one, perhaps produced by an immune reaction involving antibody and local tissue antigen.

Fibrinogen is present throughout the entire area of necrobiosis suggesting that this protein composes at least a portion of the necrobiotic material within the granuloma. It provides ready identification of the necrobiotic areas by immunofluorescence microscopy. In some patients, it is easier to recognize fibrinogen in necrobiosis stained with antihuman fibrinogen labeled with fluorescein, than it is to recognize necrotic material stained with hematoxylin and eosin.

Immunoglobulin M and C3 were present at the dermal-epidermal junction of some patients. Here these appeared similar to bands of immunoglobulins and C3 observed in skin of patients with lupus erythematosus,[17] porphyria,[18] leprosy,[19] graft versus host reaction,[20] dermatitis herpetiformis,[21] facial granuloma,[22] and occasionally other dermatoses. Similar deposits are also observed in allergic vasculitis such as anaphylactoid purpura,[23,24] and urticarial vasculitis.[25] Their significance is unknown but may be important. These deposits may represent collections of immune complexes formed in vessels, dermis, or other tissues that have lodged against the epidermal basement membrane. The analogous deposits seen at the dermal-epidermal junction of patients with lupus erythematosus lie just on the dermal side of the epidermal basal lamina.[26]

The cause of granuloma annulare is still unknown. It is possible that histologic changes and immunofluorescence of vessels are only secondary phenomena. However, the presence of immunoglobulins and complement in blood vessels of many patients with granuloma annulare suggests that a chronic immune vasculitis may be involved in the pathogenesis.

This investigation was supported by Public Health Service grant 5T01 AM 05560, and a grant from the Diabetes Research Fund of the American Diabetes Association–Minnesota Affiliate.

Isadore Fisher, MD, referred the initial patient, and Charles Balogh, MD, and Sheldon Mandel, MD, referred numerous other patients for study.

References

1. Lever WF, Schaumberg-Lever G: *Histopathology of the Skin*, ed 5. Philadelphia, JB Lippincott Co, 1975.

2. Wood MG, Beerman HC: Necrobiosis lipoidica, granuloma annulare, and rheumatoid nodule. *J Invest Dermatol* 34:139-147, 1960.

3. Laymon CW, Fisher I: Necrobiosis lipoidica (diabeticorum?): A histologic study and comparison with granuloma annulare. *Arch Dermatol* 59:150-167, 1949.

4. Allen AC: *The Skin: A Clinicopathological Treastise*, ed 2. New York, Grune & Stratton Inc, 1965.

5. Haim S, Shafrir A, Haim N, et al: Microangiopathy in cases of granuloma annulare. *Dermatologica* 147:261-266, 1973.

6. Dahl MV, Ullman S, Fisher I: Direct immunofluorescence in granuloma annulare and necrobiosis lipoidica. *Clin Res* 24:95A, 1976.

7. Ullman S, Wilk A, Kobayasi T, et al: Drug-induced lupus erythematosus syndrome. *Acta Derm Venereol (Stockh)*: 54:387-390, 1974.

8. Sewell MMH: A semi-quantitative technique using the LKB immunodiffusion apparatus. *Sci Tools* 14:11-21, 1967.

9. Wells AF, Miller CE, Nadel MK; Rapid fluorescein and protein assay method for fluorescent-antibody conjugates. *Appl Microbiol* 14:271-275, 1966.

10. Cochrane CG, Koffler D: Immune complex disease in experimental animals and man. *Adv Immunol* 16:185-264, 1973.

11. Cream JJ, Bryceson ADM, Ryder G: Disappearance of immunoglobulin and complement from the Arthus reaction and its relevance to studies of vasculitis in man. *Br J Dermatol* 84:106-109, 1971.

12. Sams WM, Claman HN, Kohler PF, et al: Human necrotizing vasculitis: Immunoglobulins and complement in vessel walls of cutaneous lesions and normal skin. *J Invest Dermatol* 64:441-445, 1975.

13. Sams WM, Thorne EG, Small P, et al: Leukocytoclastic vasculitis. *Arch Dermatol* 112:219-234, 1976.

14. Ruiter M: Vascular fibrinoid in cutaneous "allergic" arteriolitis. *J Invest Dermatol* 38:85-92, 1962.

15. Cream JJ, Turk JL: A review of the evidence of immune-complex deposition as a cause of skin disease in man. *Clin Allerg* 1:235-247, 1971.

16. Spector WG, Heesom N: The production of granulomata by antigen-antibody complexes. *J Pathol* 98:31-39, 1969.

17. Burnham TK, Neblett TR, Fine G: The application of the fluorescent antibody technique to the investigation of lupus erythematosus and various dermatoses. *J Invest Dermatol* 41:451-456, 1963.

18. Epstein JH, Tuffanelli DL, Epstein WL: Cutaneous changes in the porphyrias: A microscopic study. *Arch Dermatol* 107:689-698, 1973.

19. Bullock WE, Callerame ML, Panner BJ: Immunohistologic alteration of skin and ultrastructural changes of glomerular basement membranes in leprosy. *Am J Trop Med Hyg* 23:78-83, 1974.

20. Ullman S, Spielvogel R, Kersey J, et al: Immunoglobulins and complement in skin in graft versus host disease. *Ann Intern Med* 85:205, 1976.

21. van der Meer JB: Granular deposits of immunoglobulins in the skin of patients with dermatitis herpetiformis: An immunofluorescent study. *Br J Dermatol* 81:493-503, 1969.

22. Schroeter AL, Copeman PWM, Jordon RE, et al: Immunofluorescence of cutaneous vasculitis associated with systemic disease. *Arch Dermatol* 104:254-259, 1971.

23. Ullman S, Halberg P, Nielsen B, et al: Deposits of immunoglobulins and complement in the dermo-epidermal junction of patients with anaphylactoid purpura. *Acta Derm Venereol (Stockh)* 55:359-362, 1975.

24. Jones JB, Cumming RH, Asplin BM, et al: Necrotizing vasculitis: A circulating immune complex producing inflammatory skin lesions. *Br J Dermatol* 94:123-130, 1976.

25. Tuffanelli DL: Cutaneous immunopathology: Recent observations. *J Invest Dermatol* 65:143-153, 1975.

26. Schreiner E, Wolff K: Systemic lupus erythematosus: Electron microscopic localization of in vivo bound globulins at the dermal-epidermal junction. *J Invest Dermatol* 55:325-328, 1970.

Thrombocythemia as a Cause of Erythermalgia

Keith G. Redding, MD

• **Erythermalgia is a distinctive clinical entity characterized by local redness, warmth, and burning pain in the distal portions of the extremities. In this study, erythermalgia was observed in two patients with myeloproliferative disease. A new theory suggesting abnormally rapid platelet aggregation as a cause of erythermalgia was advanced. The following evidence is presented: (1) histologic evidence of thrombi occluding the arterioles and probably composed of platelet aggregates; (2) reversal of the clinical findings with platelet aggregating drugs, such as heparin sodium and acetylsalicylic acid; (3) disappearance of the erythermalgia with the adequate control of the myeloproliferative disease.**

(*Arch Dermatol* 113:468-471, 1977)

Erythermalgia has variously been called erythromelalgia and erythralgia since its original description by Weir Mitchell in 1878.[1] I prefer the first term because it emphasizes all three of the essential components of the syndrome: local redness, warmth, and burning pain of the extremities. These features are initiated by the internal heat of exercise or by external heat, and are diminished by cold.

Of 51 cases reviewed by Babb et al,[2] 30 were considered to be idiopathic because there was no associated disease. The idiopathic form appeared to occur in a younger population, more often male, and it was usually self-limited. The other 21 cases were associated with diabetes, venous insufficiency, hypertension, rheumatoid arthritis, or lupus erythematosus; particularly striking were ten cases of myeloproliferative disease, in some of which erythermalgia preceded all other manifestations by several years. Also described in the literature[3] is a familial group of 19 patients whose syndrome seemed to be inherited along with glomerulonephritis in a sex-linked dominant fashion.

Erythermalgia should be easily distinguished from other causes of painful limbs. The characteristic history of aggravating and relieving factors and careful delineation of the pain to the warm, reddened areas of the involved limb are almost pathognomonic. A history of cold exposure distinguishes the nodules of chillblains or cold panniculitis; a normal or cool temperature is found in arteriosclerosis obliterans, thromboangiitis, or peripheral neuropathy; weight bearing is the chief initiator of pain in osteoarthritis, metatarsalgia, march fracture, plantar neuroma, or plantar fasciitis.

The pathophysiologic nature of erythermalgia has, over the years, remained quite unknown. I recently have had the opportunity to study two patients with the syndrome, both in association with myeloproliferative disorders. The results have suggested an important role of the platelet elements of the blood in their erythermalgia.

Accepted for publication Feb 9, 1976.

From the Department of Dermatology, Marshfield Clinic, Marshfield, Wis. Dr Redding is now in private practice in Calgary, Alberta, Canada.

Reprints not available.

REPORT OF CASES

CASE 1.—A 72-year-old woman was first seen on Jan 7, 1974 because of continuous burning pain localized to patchy erythematous areas on the distal aspects of the feet and toes (Fig 1). The right little toe was cyanotic, but blanchable on diascopy. The erythematous areas were warmer than the surrounding skin and were very tender, though blanching, continuous pressure relieved the tenderness. Some immediate relief was gained by cooling the areas. Other than a few superficial varicosities and some onychomycosis, the local nutritional status and neurosensory status of the feet were good. The patient's general physical status was only fair because of long-standing asthma and compensated congestive heart failure.

Laboratory evaluation revealed an initial hemoglobin level of 13.5 gm/100 ml, but a WBC count of 13,100/cu mm and a platelet count of 1,700,000/cu mm. The peripheral blood smear confirmed a marked thrombocythosis and showed a differential cell count of 74% neutrophils, 2% basophils, 4% eosinophils, 14% lymphocytes, and 5% monocytes. Examination of bone marrow from the iliac crest showed a marked increase in megakaryocytes with platelet budding (Fig 2). The leukocyte alkaline phosphatase score was abnormally high (123; control, 202; normal range, 14,100).

Results of punch biopsy of the cyanotic toe included "artifactual loss of the upper layers of epidermis." Also, thrombi oc-

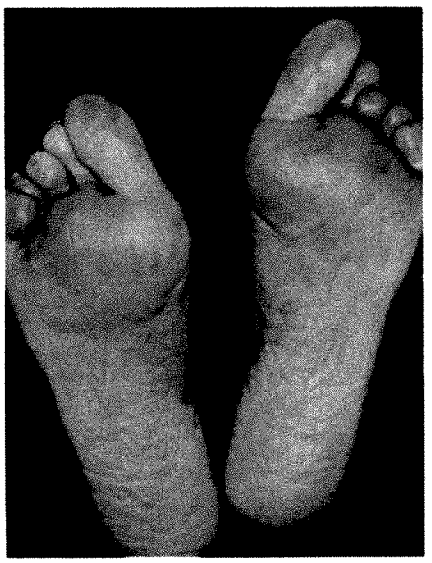

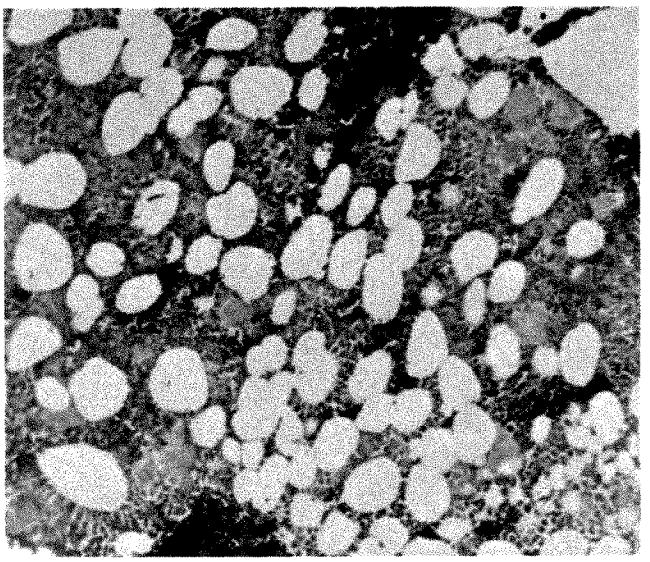

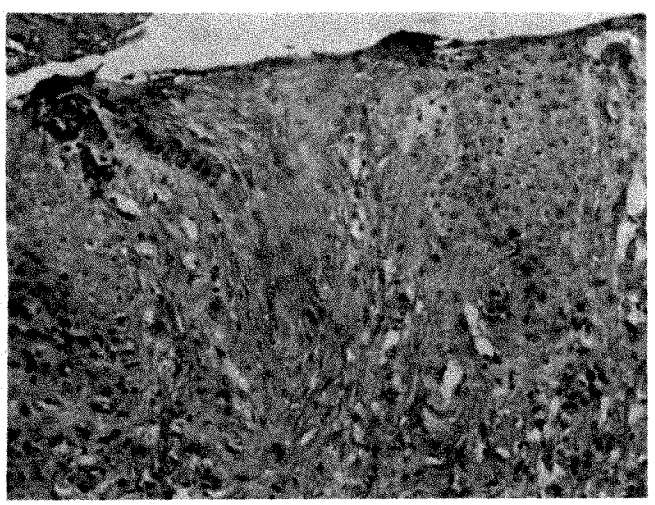

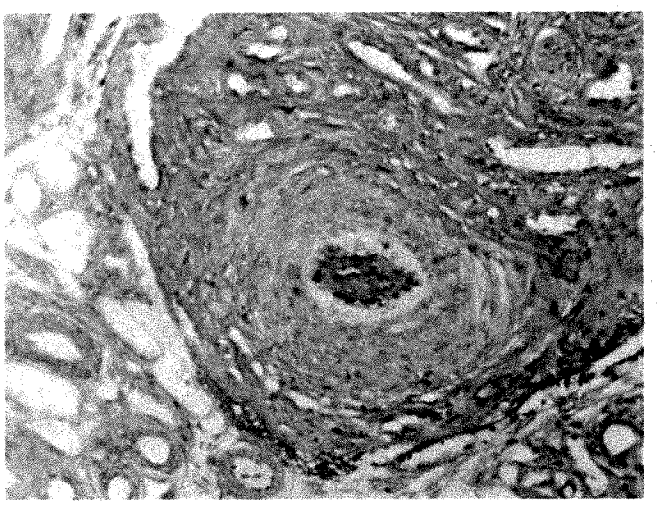

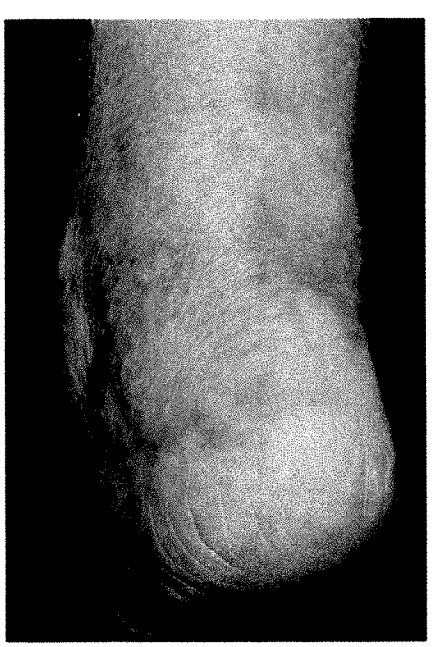

Fig 1.—Top left, Clinical picture of painful erythematous patches and cyanotic right little toe (case 1).

Fig 2.—Top right, Bone marrow specimen revealing hyperplasia of large pale eosinophilic megakaryocytes with platelet budding (arrow) (hematoxylin-eosin, original magnification ×400).

Fig 3.—Center left, Punch biopsy specimen from cyanotic toe. Upper layers of epidermis lost artifactually. Papillary dermis edematous with bright eosinophilic thrombi in some capillaries (hematoxylin-eosin, original magnification ×400).

Fig 4.—Center right, Lower part of dermis of same slide as Fig 3. Arteriole completely occluded by thrombus (hematoxylin-eosin, original magnification ×400).

Fig 5.—Bottom left, Warm painful erythema over heel (case 2).

cluded many capillaries in the edematous dermal papillae. Dermal vessels were dilated, and thrombi totally occluded some arteries, arterioles, and venules (Fig 3 and 4). The thrombi were fibrin-negative on staining with phosphotungstic acid hematoxylin and were granule-negative on staining with PAS.

Normal laboratory findings in this patient included serum electrolyte determinations, coagulation studies (Ivy bleeding time, prothrombin time (PT), partial thromboplastin time (PTT), and fibrin split products), porphyrin screening, rheumatoid arthritis titer, lupus erythematosus fluorescent antibody titer, VDRL test for syphilis, and serial 24-hour urine excretion studies for 5-hydroxyindoleacetic acid (5-HIAA).

The patient's hematologic diagnosis was essential thrombocythemia, which is a myeloproliferative disorder. Because of the biopsy evidence of continuing thrombosis, the patient was treated with heparin sodium by intravenous infusion sufficient to maintain PTT between 1.5 to 2.5 times control. Within minutes the patients erythermalgia was markedly relieved, and she was able to ambulate. An intravenous dose of 3 μCi of sodium phosphate P 32 was given to retard the uncontrolled platelet production. Two weeks later, 9 mg of uracil mustard was given to further decrease the platelet count. Two weeks later the platelet count was within normal limits. During the total treatment period, heparin had to be continued without break to control the erythermalgia and thrombosis. When the platelet counts had reached normal levels, heparin was no longer required for control. The patient was discharged free of pain.

Ten weeks after the onset of her hematologic illness the patient died of complications of asthma. Postmortem findings also noted an enlarged spleen (470 gm; normal, 150 gm) with small follicles but with a congested and firm parenchyma. There was megakaryocytic hyperplasia of the bone marrow, which was consistent with her myeloproliferative disorder. Vascular thrombi in various stages of organization were noted both in the myocardium and in the kidneys. The cyanotic toe had mirrored the thrombotic episodes internally.

CASE 2.—A 68-year-old woman was first seen May 1, 1974 with typical history and findings consistent with erythermalgia of both feet (Fig 5). She had been known to have polycythemia rubra vera since 1967, but had never received adequate treatment. A painful purple spot had developed on her left leg in November 1973. The patient suffered a splenic infarct at that time. These lesions healed, but the feet had been painful since.

Her general health was only fair because of hypertension and idiopathic Parkinson disease. The local nutritional status and neurosensory status of her feet were judged to be normal.

Laboratory findings included a hemoglobin level of 18.1 gm/100 ml, a RBC count of 8,200,000/cu mm, a WBC count of 12,500/cu mm, and a platelet count of 710,000/cu mm. Differential cell count was 80% segmented neutrophils, 10% band forms, and 10% lymphocytes. The blood glucose value two hours after eating was 142 mg/100 ml, the BUN value was 21 mg/100 ml, and the serum uric acid value was 7.9 mg/100 ml.

Results of the following tests were within normal limits: chemistry studies for alkaline phosphatase, total serum bilirubin, total serum protein, serum albumin, lactic dehydrogenase, serum calcium, inorganic serum phosphate, serum cholesterol, and SGOT; chest x-ray film, urinalysis, coagulation studies (PT, Lee-White clotting time, Ivy bleeding time, and PTT), serum vitamin B_{12}, cryoglobulins, cryofibrinogens, cold hemolysins, brain scan, and VDRL test for syphilis. Serial 24-hour urine test results for 5-HIAA remained normal throughout the hospital stay. Serum serotonin concentration in blood drawn simultaneously from the femoral artery and vein were normal and equal.

This patient's feet had no cyanotic areas. A punch biopsy specimen from an erythematous area showed no discernible changes in the epidermis, some dilation of capillaries in the dermis, and no discernible thrombi in the vessels.

The patient's hematologic diagnosis was polycythemia rubra vera, which is another of the myeloproliferative disorders. The patient was given 8 mg of busulfan daily for the 31 days of her hospitalization. The hematologic counts gradually decreased until therapy was discontinued, at which time the hemoglobin value was 17.4 gm/100 ml, the WBC count was 4,700/cu mm, and the platelet count was 344,000/cu mm.

Several observations of the effects of different medications for her erythermalgia were noted. Plain propoxyphene in the maximum recommended dosages seemed to have no effect. Within 30 minutes of ingestion, acetylsalicylic acid (650 mg orally) produced subjective and objective improvement that lasted about four days. Heparinization by continuous intravenous infusion in the previously mentioned control range provided rapid relief for a four-day test period of administration. The erythermalgia subsided toward the end of the patient's hospital stay, so that she was discharged with her feet symptom-free.

COMMENT

To my knowledge, patient 1 is the first reported case of erythermalgia as the initial manifestation of essential thrombocythemia. Erythermalgia has been reported to occur in perhaps 3% of cases of polycythemia rubra vera.[2] The classification of either of these diseases within the broader group of myeloproliferative disorders is made on the basis of the predominant hyperplastic elements of the bone marrow. The former is predominantly hyperplasia of the megakaryocytic-platelet series; the latter is predominantly hyperplasia of the RBC series. Polycythemia rubra vera commonly has some increased numbers of the other series as well.

Both myeloproliferative disorders must be distinguished from reactive hyperplasias. Thrombocythemia can occur briefly following splenectomy and can occur in infection, hemorrhage, or disseminated malignant neoplasm.[4] Reactive polycythemia can occur in chronic lung disease, in mountain-dwellers, in cardiac right-to-left shunt, and in hematopoietin-producing tumors.

Some interesting features of erythermalgia must be taken into account in explaining its cause. Each of 31 patients had his own consistent "critical skin temperature point" measured in Babb's laboratory.[2] Above this temperature, whether produced by active exercise or passive external heating, the redness and pain appeared, and below it they disappeared. Range for the 31 patients was 31 to 36 C. Most of the patients achieved prolonged relief from single small doses of acetylsalicylic acid. Also, there is a strong association with myeloproliferative diseases.[5]

Jelinek,[6] Pepper,[7] and Catchpole,[8] have been proponents of a chemically mediated theory. They suggest a temperature-triggered release of pain-mediating and vasoactive substances in the sensitive areas of predisposed persons. These may be identical with the agents released in normal subjects by noxious stimuli, such as burns, frostbite, and ischemia. The known pain-producing substances in human plasma include acetylcholine, histamine, serotonin, prostaglan-

dins, and kinins.[9] All three authors implicate serotonin because their subjects with idiopathic erythermalgia responded to treatment with methysergide, an antiserotonin agent. We found no evidence in our patients of increased circulating serotonin or increased total excretion of serotonin metabolites. Our methods may, of course, be too crude.

Whatever chemicals may be involved, it is tempting to speculate that in our patients, the abnormal quantity of circulating platelets played a role in the erythermalgia. The platelets in the sluggish distal parts of the circulation were aggregating and releasing powerful vasoactive substances. When only small numbers of aggregates occurred, only erythermalgia was produced. When larger numbers were produced, cyanosis and microinfarction occurred. Even whole organs can become infarcted, such as the spleen in the second case. The success of heparin in relieving the conditions of both patients on several occasions fits with its known antithrombin action, slowing platelet aggregation and vasoactive chemical release. When the platelet counts became normal following appropriate therapy for the myeloproliferative disease, the erythermalgia disappeared. The second patient's prolonged relief from the single ingestion of aspirin is explained by knowledge of platelet physiologic characteristics. Aspirin permanently alters platelet membranes so that they cannot aggregate. Three or four days must elapse before sufficient numbers of new active platelets are generated. Then aggregation may begin again. This aggregation of platelets is dependent on a series of chemical reactions that are logarithmically temperature-dependent. When the temperature decreases below the "critical skin temperature point," erythermalgia is relieved.

Quantitative changes in the platelets in both of these patients appeared to play a major role in the production of their erythermalgia and to be a rational target for its therapy.

The cost of reproducing the color illustrations was paid by Westwood Pharmaceutical, Inc.

E. Beltoas, MD, performed the histologic examinations. R. Winemiller, MD, referred the patient in case 1. L. Schloesser, MD, referred the patient in case 2.

Nonproprietary Names and Trademarks of Drugs

Busulfan—*Myleran.*
Sodium phosphate P 32—*Phosphotope.*

References

1. Mitchell SW: On a rare vaso-motor neurosis of the extremities, and on the maladies with which it may be confounded. *Am J Med Sc* 76:2, 1878.

2. Babb RR, Alarcon-Segovia D, Fairbairn JF II: Erythermalgia: Review of 51 cases. *Circulation* 29:136-141, 1964.

3. Cross EG: The familial occurrence of erythromelalgia and nephritis. *Can Med Assoc J* 87:1-4, 1962.

4. Gunz FW: Essential thrombocythemia, in Williams WJ, Beutler E, Erslev AJ, et al (eds): *Hematology.* New York, McGraw-Hill Book Co Inc, 1972, pp 704-706.

5. Erslev AJ: Classification of erythrocyte disorders, in Williams WJ, Beutler E, Erslev AJ, et al (eds): *Hematology.* New York, McGraw-Hill Book Co Inc, 1972, pp 198-201.

6. Jelinek VM: A study of erythromelalgia. *Aust Ann Med* 19:139-144, 1970.

7. Pepper H: Primary erythromalgia: Report of a patient treated with methysergide. *JAMA* 203:1066-1067, 1965.

8. Catchpole BN: Erythromelalgia. *Lancet* 1:909-911, 1964.

9. Armstrong D, Jepson JB, Kaele CA, et al: Pain-producing substances in human inflammatory exudates and plasma. *J Physiol* 135:350, 1957.

Hidrotic Ectodermal Dysplasia With Diffuse Eccrine Poromatosis

Ralph D. Wilkinson, MD, FRCP(C); Paula Schopflocher, MD, FRCP(C); Maria Rozenfeld, MD, FRCP(C)

• **Eccrine poromatosis (EP) of remarkable severity has been observed in a patient with hidrotic ectodermal dysplasia (HED), a member of the kindred originally described by Clouston. Neither the EP nor its association with HED has been previously reported.**

(*Arch Dermatol* 113:472-476, 1977)

We have observed hyperplastic alterations of the sweat ducts typical of eccrine poromata, but occurring in diffuse sheets over the distal parts of the extremities in a fashion previously unreported. The patient also manifested the severe form of hidrotic ectodermal dysplasia (HED), and is one of the kindred from southern Quebec described by Clouston.[1] Features of the poromata in this case suggest that the eccrine sweat gland may become the dominant element of the ectoderm on the distal extremities, and when this occurs may be a feature of the full expression of the Clouston HED.

According to Clouston's[1,2] description, the trait is dominant, and easily recognized by changes in the nails, hair, and skin. The nails reflect the severity of the genodermatosis. The nail plate is slightly thickened, discolored, and striated in the mildest, and obliterated by scar in the severest cases.

Recurrent infection of the nail is common and squamous cell carcinoma of the nail plate and palmar tissues was reported by Campbell and Keokarn[3] and Mauro et al.[4] Hair defects usually parallel those of the nail. In the mildest, the scalp hair may appear normal, but the outer one third of the eyebrows is sparse and the lashes and body hair may be sparse and short. In more severe cases the scalp hair is fair, short, and slow-growing. Genital hair may be absent. In the severest, there is total absence of scalp hair, usually noted from birth. Of the remaining follicular elements, the sebaceous glands are normal or atrophic and the apocrine glands and breasts usually well developed.

The skin surface appears normal, except for pebbling at the nail folds, erythema of the palms and soles, and coarse ridges and furrows about the joints. Pigmentation is often prominent on the knees, elbows, axillae, and phalangeal joints.

Ocular abnormalities were frequent.[5] The common abnormalities were strabismus, pterygium, conjunctivitis, and cataracts. Teeth were not typically affected. Other anomalies such as sensorineural hearing loss, polydactylism, and syndactylism have been reported.[6]

Eccrine sweat glands have been mentioned as unremarkable though functionally active in response to both emotional and thermal stimuli. Periungual pebbling of the skin surface has been prominent in some descriptions,[1] but no reference to these being papules related to eccrine duct tumors has been made. In the case reported below, the eccrine duct tumors, or poromata, comprise a prominent feature of clinical and histological presentation.

REPORT OF A CASE

A 44-year-old mother of nine children, a member of the family originally described by Clouston,[1] in Huntingdon, Quebec, had verrucous growths on the feet that bled and interfered with walking.

The history revealed that she was born with short brown scalp hair that was lost early in infancy. Eyebrows and lashes were absent from birth, and the body and extremities were always hair-free. In infancy, the fingernails were thick, convex, and brittle. Although the fingernails were lost at age 7, the toenails persisted as thick yellow masses that required frequent trimming. Perspiration was always copious during hot weather. Heat tolerance seems to have been reduced in recent years.

At age 40 years, small reddish spots appeared on the insteps. The lesions enlarged and appeared on the ankles and wrists, thence on the forearms and legs.

Accepted for publication Feb 19, 1976.

From the Division of Dermatology, McGill University Clinic, Royal Victoria Hospital, Montreal.

Reprint requests to Division of Dermatology, Royal Victoria Hospital, 687 Pine Ave W, Montreal, Quebec H3W 1A1, Canada (Dr Wilkinson).

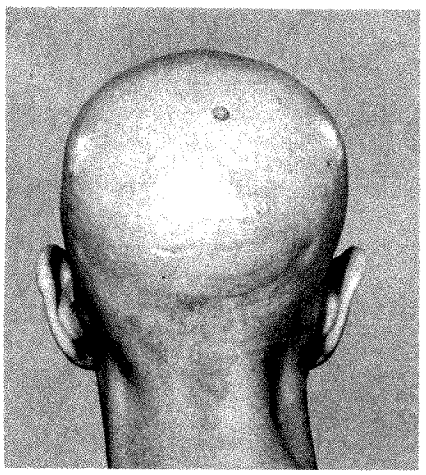

Fig 1.—Alopecia totalis universalis. Occipital papule was an intradermal nevus pigmentosus.

Fig 2.—Globose papules, solitary and clustered together, were present on the feet. Fingers were similarly affected.

Fig 3.—Globose papules were very prominent on lateral aspects of feet, ankles, and wrists. Note also plantar dyskeratosis and fissures.

Fig 4.—Small solitary papules and comedonic-like lesions were present on thighs, legs, and to a lesser extent, on trunk and upper extremities.

Fig 5.—Flexor surface of forearm. Poromatous nodules dominate surface features (top). Viewed through an oil film (bottom), capillaries can be seen in centers and rims of each nodule (arrow) (× 80).

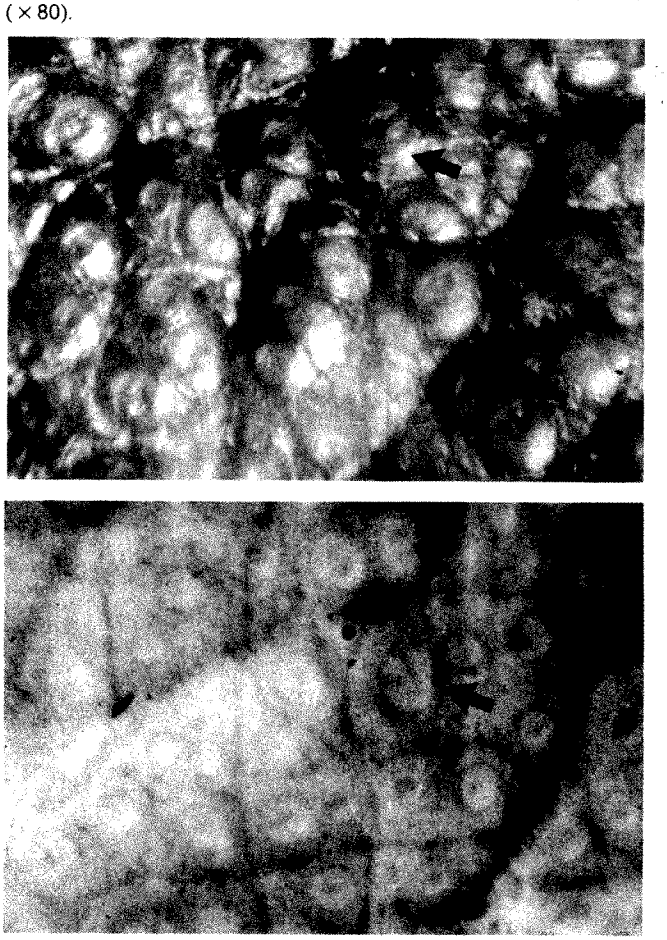

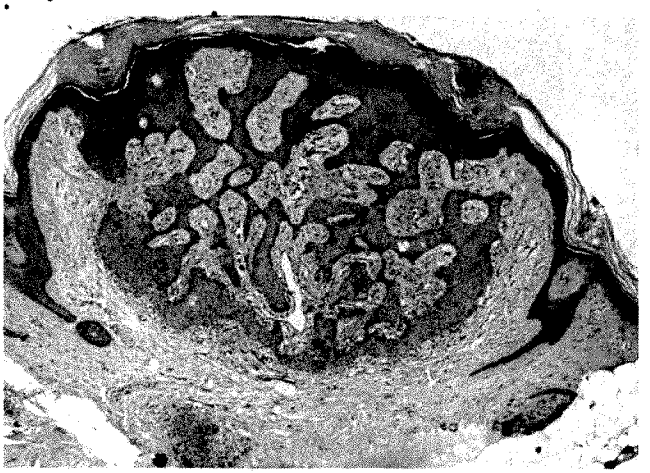

Fig 6.—Histopathology of a large globose papule from foot. There is hyperkeratosis with focal invaginations of keratin into epidermis. Thick, anastomosing tracts of small cuboidal cells proliferate into dermis. Tumor is embedded in highly vascular stroma (hematoxylin-eosin, ×50).

Fig 7.—Sweat duct in continuity with tumour and coursing through it. Hyperplasia of duct cells is noted in sweat duct adjacent to poroma (hematoxylin-eosin, ×200).

The palms were "cracked and sore."

In her family, members of many generations had poor nails and hair. The patient could not recall others with the tumors on the feet and wrists. In this respect she considered herself slightly different, although she described her sister as having small tumors too. The sister was not available for examination.

On system review, vision was poor in the left eye, and arthritic pains occurred in spring and during changes in weather, but no joint swelling was noted. The remainder of the review was noncontributory.

The patient appeared healthy, wore glasses and a hairpiece to effectively mask the features of the genodermatosis. Vital signs were normal, and the physical findings of importance were limited to the skin and eyes.

Hair was "totally" absent from the head, trunk, and extremities (Fig 1). Three hairs of 1 to 3 inches in length were present on the scalp.

The fingernails were short, friable, and thinned, except for the lateral one third of the right ring-finger. These findings were considered grade 4 nail changes (Clouston). The toenails were relatively narrow, irregular thick keratotic masses. The palms were erythematous, scaly, and fissured, and the dermatoglyphics, though barely discernible, were present and not unusual. The fingertips were broad and thickened and showed fine pebbling of the print lines. In several areas the tiny white orifices of the eccrine pores in the centers of the pebble papules could be seen easily with the naked eye.

A striking feature was the presence of globose erythematous papules and tumors on the insteps, ankles, and wrists with smaller lesions on the dorsal surfaces of the toes, calves, and forearms (Fig 2 to 4). The lesions measured 1 to 4 mm in diameter and up to 3 to 4 mm in height; they were smooth, soft, and erythematous and separated by deep crevices. Solitary lesions were seen on the thighs, buttocks, and abdomen. Numerous keratinous spines, resembling comedones, were also noted on the thighs and arms.

Eye examination showed bilateral corneal opacities. Results of the remainder of the physical examination were noncontributory.

Examination of the surface with a capillary microscope revealed vellus hairs on the scalp and markedly reduced numbers on the proximal portions of the extremities. They were absent from the distal portions of the extremities. A normal relationship between hair follicle and surface topography was preserved on the head, neck, and trunk to the waist. Patent and plugged follicles were evident at the junctions of the skin furrows. Occasionally spiny structures occupied the follicles. These could easily be extracted with a fine needle. The plug was soft, tooth-like, and occasionally contained a fine vellus hair. Interspersed throughout this pattern were almost invisible eccrine pores, revealed by bromphenol blue stain when the patient was heated.

The wrists and feet had a broad range of lesions from prominent eccrine pores to vascular tumors with pore-like apical punctae.

Follicles could not be found on the lower parts of the extremities. The eccrine pore gradually became the dominant element, surrounded by a keratotic ring, and accentuated with a rich capillary loop network (Fig 5). In the tumor regions the globose lesions replaced all other features. Sweat secretion could be detected from the apexes as well as the furrows between the tumors. On the palms and flat plantar surfaces the pores were located regularly along the crests of the ridges.

LABORATORY INVESTIGATIONS

Results of the following laboratory tests were within *normal* limits: hemogram, ESR, SMA 12, AC and PC glucose, urinalysis, ECG, EEG, thyroid function tests, upper gastrointestinal series, and urinary amino acids. Vaginal smears showed no evidence of keratinization. Buccal smears showed intermediate and superficial cells without evidence of keratinization. Serum carotene level was 118 μg/100 ml (normal

Fig 8.—Sections of a keratotic papule from thigh. Hyperkeratosis, hypergranulosis, and acanthosis are noted. Sweat duct ascends through vertical axis of lesion, from eccrine gland below (hematoxylin-eosin, ×200).

Fig 9.—Melanin is absent from basal layer of tumor below arrows (DOPA stain, ×400).

100 to 200 μg/100 ml) and the serum vitamin A level was 41.0 IU (normal 30 to 130 IU).

Results of the following laboratory tests were *abnormal:* skeletal survey showed dorsal kyphosis and slight scoliosis. Barium enema indicated diverticulosis along the transverse and descending colon. Immunoglobulin determinations on two occasions showed increased IgA of 550 to 750 mg/100 ml (normal 100 to 380 mg/100 ml).

HISTOPATHOLOGICAL FINDINGS

Sections of glabrous skin demonstrated no change in the surface epidermis with the exception of those in the cutaneous appendages described below. Melanocytes were demonstrated in normal distribution at the dermoepidermal junction.

In scalp sections the pilosebaceous units were small, superficial, and reduced in numbers. The hair follicles were dilated and filled with keratin. Prominent hypergranulosis was noted at the follicular orifices. The sebaceous glands were normal in distribution and morphology, as were the eccrine glands, except that the eccrine acrosyringia appeared hypercellular.

Sections from the axillae showed normal active apocrine glands, sebaceous glands, and occasional vellus hairs in cross section. A few eccrine ducts present on the section showed hypertrophic walls.

Examination of numerous tumors excised from the feet and wrists revealed a consistent picture (Fig 6) of absolute and relative hyperkeratosis. The underlying granular layer was prominent. Thick, anastomosing tracts of uniform cuboidal cells with preserved intercellular bridges proliferated into the dermis. Many were penetrated by dilated spiraling ducts lined with an eosinophilic cuticle and often containing eosinophilic material. The tumors were embedded in a highly vascular collagenous stroma. Islands of angioectatic stroma were seen within the tumors. Melanin was not demonstrated within the tumors either by DOPA or Fontana stains. Cells in the upper half of the tumor stained with PAS. The cuticle of the duct-like spaces was PAS-positive, diastase resistant. Centered under each tumor and in continuity with it were seen sections of eccrine ducts, which descended through the dermis to morphologically intact eccrine coils (Fig 7).

Sections of a keratotic papule, or "eccrine pseudohair," from the thigh showed a surface projection, consisting of a stratified column of hyperkeratosis, through the vertical axis of which ran a narrow duct (Fig 8). Under this hyperkeratosis the granular layer was 10 to 12 cells thick and the keratohyalin granules were very large. The acanthotic mass below consisted of cuboidal cells that extended into the dermis and was permeated by duct-like spaces lined with eosinophilic cuticle. These ducts were in continuity with the transcor-

neal duct above and with normal appearing eccrine ducts and glands below. Fontana and DOPA stains failed to reveal melanin in this lesion (Fig 9).

COMMENT

The salient clinical and histological features of this case were the profuse epithelial tumors of acral distribution and hidrotic ectodermal dysplasia. The evidence that the tumors were of acrosyringeal origin is as follows:

Clinical Findings

The tumors occurred in the distribution of eccrine syringia in proportion to the normal distribution of sweat glands in the involved regions. On capillary microscopy each of the tumors had a pore. Thermal sweat was produced by the tumors as detected by bromphenol blue dye.

Histological Findings

Eccrine ducts and coils were invariably associated with the tumors. The tumors contained ducts lined with PAS positive, diastase resistant material, typical of the lining of eccrine sweat ducts. The cells of the tumors had a uniform cuboidal appearance, and the prickles were preserved. The PAS-positive material was present in the tumor cells as it is in the case of eccrine poromas. Melanin was not found in the tumors, although it was present in the epidermis immediately adjacent to the tumors. This is typical of eccrine poromas,[7] although melanin has been observed in some cases.[8] Capillary ectasia and fibrosis surrounded the tumor. This is typical of eccrine poromas.

Sanderson et al[9] referred to benign solitary tumors arising from sweat duct epithelium as eccrine acrospiromas and they divided them into three types: intraepidermal (hidroacanthoma simplex), juxtaepidermal (eccrine poroma), and intradermal (dermal-duct tumor). They concluded there was no indication that heredity or external agents caused these tumors. Our patient had a spectrum of lesions, from eccrine pseudohairs, which are probably the product of hyperplasia and hyperkeratosis of the intraepidermal sweat duct unit, to juxtaepidermal lesions and intradermal tumors.

Pinkus et al[7] presented the first description of eccrine poroma of the solitary type. Goldner[10] reported the first case of multiple eccrine poromatosis in a 65-year-old woman, whose tumors affected the palm and the soles in circumscribed areas for 20 years. They were not associated with other abnormalities. The poromas in our case involved other parts of the extremities besides the palms and soles, and are diffuse in distribution. We consider this a different type of process from that described by Goldner, and suggest the term eccrine poromatosis to emphasize the diffuse nature. The presence of eccrine poromatosis in HED offers some difficulties in the conceptualization of pathogenesis. The abnormalities in this patient might stem from a single gene defect. Therefore eccrine poromatosis with hair and nail defects could represent the full expression of HED. In favor of this are the following points: (1) In many of the published cases of HED, pebbling was noticed over the acral areas in the distribution of eccrine glands, but was not examined histologically. (2) Abnormally dilated sweat ducts were noticed by Clouston.[1,2] (3) Our patient has features of the most severe expression of HED. (4) Our patient's sister, with severe HED, was reported to have similar tumors and HED findings. However, she was not available for examination.

The sporadic association of poromata and HED should also be considered. Evidence for this is as follows: (1) the absence of published cases of proven sweat gland tumors associated with HED, and (2) the onset of tumors after 40 years of age. This late onset is reported in sporadic cases of solitary and multiple nonsymetrical poromatosis.

Gold[11] proposed that abnormalities in hair keratin in HED is due to mutation of a single gene for matrix polypeptide. This leads to a deletion of a low sulfur segment of this polypeptide causing destabilization of intermolecular disulfide bonds in keratin. Could a defective gene for matrix keratin lead to development of acrosyringeal tumors and deletion of hair follicles in acral areas?

It is of interest that the sebaceous and apocrine glands showed no defect in their ductal structure, while the hair components of the follicle were markedly defective.

Squamous cell carcinoma of the nail bed and palms has been reported in HED.[4] Increased mitotic figures in poromata were also seen. The presence of eccrine acrosyringeal hyperplasia, though histologically benign, warrants regular medical supervision.

The investigation was supported in part by grant MA-3075 from the Medical Research Council of Canada.

Frederick Kalz, MD, referred this patient for investigation.

References

1. Clouston HR: A hereditary ectodermal dystrophy. *Can Med Assoc J* 21:18-31, 1921.

2. Clouston HR: The major forms of hereditary ectodermal dysplasia. *Can Med Assoc J* 40:1-7, 1939.

3. Campbell GJ, Keokarn TK: Squamous cell carcinoma of the nail bed in epidermal dysplasia. *J Bone Joint Surg* 48:98-99, 1966.

4. Mauro J, Maslyn R, Stein A: Squamous cell carcinoma of nail bed in hereditary ectodermal dysplasia. *NY State J Med* 1:1065-1066, 1972.

5. Wilkey WD, Stevenson GH: A family with inherited ectodermal dystrophy. *Can Med Assoc J* 53:226-230, 1945.

6. Robinson GC, Miller JR, Bensimon DR: Familial ectodermal dysplasia with sensorineural deafness and other abnormalities. *Pediatrics* 30:797-802, 1962.

7. Pinkus H, Rogin RJ, Goldman P: Eccrine poroma, tumours exhibiting features of the epidermal sweat duct unit. *Arch Dermatol* 74:511-521, 1956.

8. Yasuda T, Kawada A, Yoshida K: Eccrine poroma. *Arch Dermatol* 90:428-431, 1964.

9. Sanderson FV, Rook A, Wilkinson DS, et al: Tumours of the skin, in *Textbook of Dermatology*. Oxford, England, Blackwell Scientific Publications, 1972.

10. Goldner R: Eccrine poromatosis. *Arch Dermatol* 101:606-608, 1970.

11. Gold RJM: The characterization of hereditary abnormalities of keratin: Clouston's ectodermal dysplasia. *Birth Defects: Original Article Series*, vol 7, No. 28, 1971, pp 91-95.

Phenytoin-Induced Pseudolymphoma Syndrome

An Immunologic Study

Maj Ernest N. Charlesworth, MC, USAF

• In vitro and in vivo immunologic studies were performed on a 28-year-old woman with phenytoin sodium-induced pseudolymphoma syndrome. During the acute phase of the syndrome, the patient appeared immunologically depressed. Six months after resolution of lymphadenopathy, repeat studies demonstrated a return to immunologic competence. In vitro studies of the patient's lymphocytes when incubated with phenytoin failed to indicate a delayed hypersensitivity reaction to the drug. These findings suggest that the patient developed a clinical lymphatic proliferation at a time when she was immunologically depressed. This may result in an increased chance of a mutant malignant clone developing at a time when the immunosurveillance system is impaired and explains why a rare patient with this syndrome may develop a frank malignant lymphoma.

(*Arch Dermatol* 113:477-480, 1977)

Accepted for publication Feb 23, 1976.

From the Department of Medicine, Wilford Hall USAF Medical Center, Lackland Air Force Base, San Antonio, Tex. Maj Charlesworth is now with the Keesler USAF Medical Center, Biloxi, Miss.

Read in part before the American Academy of Dermatology meeting, San Francisco, Dec 8, 1975.

The opinions expressed herein are those of the author and are not necessarily those of the USAF.

Reprints not available.

Since the introduction of phenytoin in 1938 by Merrill and Putnam, numerous adverse reactions to the drug have been reported.[1,2] The most common dermatologic reaction is a morbilliform eruption occurring in 2% to 5% of patients; however, other types of dermatitis, including erythema multiforme and exfoliative dermatitis, can occur.[3] Phenytoin has been shown to cause a pseudolymphoma syndrome characterized by a generalized erythematous macular skin eruption, generalized lymphadenopathy, hepatosplenomegaly, fever, arthralgias, abnormal liver function tests, eosinophilia, and occasionally true lymphoma.[4-10]

An immunologic study of a patient with phenytoin sodium-induced pseudolymphoma syndrome was undertaken in an attempt to determine if patients with this syndrome have a depressed immunologic response.

REPORT OF A CASE

A 28-year-old black woman was discharged on a regimen of 300 mg of phenytoin sodium for treatment of an idiopathic seizure disorder. After six weeks of medication, she developed a severely pruritic generalized erythematous macular eruption, arthralgia, and diffuse lymphadenopathy. She was admitted to the Dermatology Service, and the medication was discontinued with no subsequent seizure activity.

Admission laboratory studies disclosed the following values: WBC, 6,500/cu mm, with 24% eosinophils; an elevated SGOT of 126 units (normal is 6 to 40 Karmen units); serum alkaline phosphatase of 26 units (normal is 4 to 13 King-Armstrong units), and a normal serum bilirubin level. A right cervical lymph node biopsy specimen showed reactive hyperplasia. A blood level of phenytoin drawn two weeks after discontinuation of the drug showed no detectable drug.

The patient was treated with 25 mg of hydroxyzine hydrochloride every six hours and topical 0.1% triamcinolone acetonide with resolution of the skin lesions and the pruritus.

MATERIAL AND METHODS

Acute Phase Testing

This phase of the testing was done at a time when there was no detectable blood level of phenytoin, when substantial lymphadenopathy was present. These studies consisted of both in vivo and in vitro testing.

In Vivo Acute Phase Tests.—All delayed hypersensitivity skin tests were done by the Allergy Department and included 0.1 ml of tuberculin purified protein derivative (5 TU/0.1 ml; Connaught Labs), histoplasmin (0.1 ml of a 1:100 concentration; Parke-Davis Co), coccidioidin (1:100 concentration diluted to 1:1,000; Bioproducts Iatric Corp), trichophyton (1:10 weight by volume [W/V] diluted to 1:500; Holister-

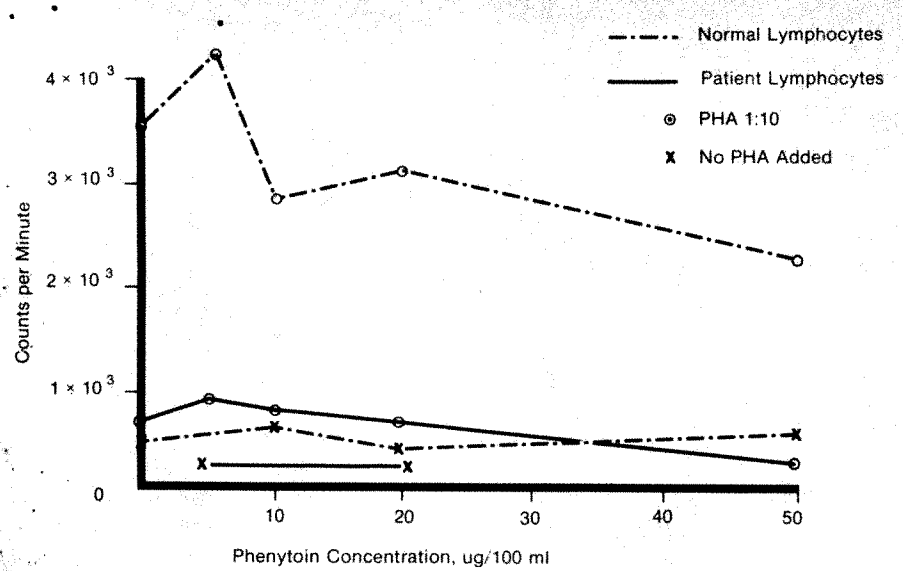

Fig 1.—Lymphocyte response to phytohemagglutinin and phenytoin. Patient was clinically symptomatic and anergic by skin tests to common antigens.

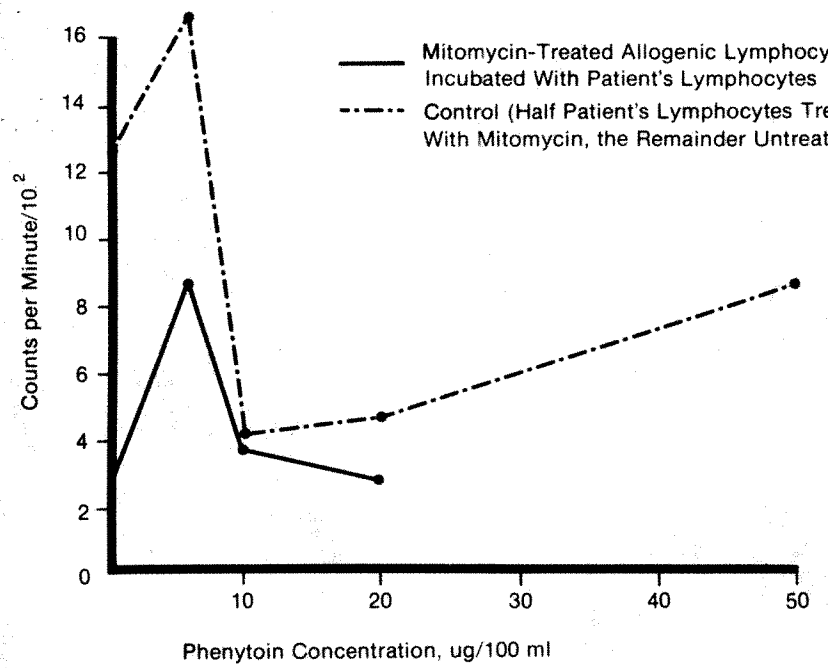

Fig 2.—Results of mixed lymphocyte reaction.

Stier Lab), mumps antigen; Lilly, and *Candida albicans* (1:10 W/V diluted to 1:500; Holister-Stier). Immunization with 0.5 ml of *Salmonella typhi* vaccine (typhoid bacilli 1,000 million/ml (Lilly) was attempted after drawing blood for baseline titers. All of these in vivo tests were initiated two weeks after the phenytoin had been discontinued.

In Vitro Acute Phase Tests.—All in vitro lymphocyte studies during the acute phase were done in the renal transplant immunology laboratory. A modification of the method of Senegar and Terasaki was used to study the response of peripheral blood lymphocytes to stimulation by phytohemagglutinin (PHA) and phenytoin.[11] Venous whole blood mixed with 100 units of heparin per milliliter was centrifuged. One milliliter of buffy coat and RBCs was recentrifuged in a polystyrene tube. The second buffy coat was mixed with 0.4 ml anti-H (prepared in the renal transplant laboratory from commercially obtained *Ulex europaeus* seeds) to remove RBC antigens. This was agitated for five minutes. The lymphocytes were purified by centrifugation and were concentrated on Ficoll-sodium diatrizoate gradients. The interface was removed and was washed with a culture medium of 10 ml of medium 199 (Difco), 14 ml of HEPES, 1.2 ml of penicillin-streptomycin solution (10^5 units of penicillin and 10 mg of streptomycin), and distilled water adjusted to 100 ml. To this, 20% of either pooled normal serum or the patient's serum was added to designated concentrations of phenytoin or PHA. After incubation for 96 hours at 36 C, the cells were pulsed with tritiated thymidine. After an additional 16 hours of incubation, the cells were harvested according to the method of Hartzman et al.[12] The vials were counted for ten minutes in a liquid scintillation spectrometer.

All mixed lymphocyte cultures were done in triplicate. Stimulating lymphocytes were treated with mitomycin to prevent DNA replication according to the method described by Bach and Voynow.[13] Such treatment prevents the cells from undergoing blastogenesis while enabling them to act as stimulating cells. This rendered the cells incapable of division and achieved a one-way mixed lymphocyte culture. The remaining procedures have been described previously.

Convalescent Phase Testing

This phase of the study was undertaken six months after all clinical evidence of the pseudolymphoma syndrome had resolved. These studies were divided into in vivo and in vitro testing as during the acute phase.

The same skin test antigens and concentrations for in vivo convalescent phase tests were applied as during the acute phase testing. When in vitro convalescent phase tests were attempted, the renal transplant immunology laboratory was unavailable to repeat the PHA and mixed lymphocyte cultures because of temporary technical problems. The convalescent PHA testing was done in the clinical research laboratory.

Seventy-two-hour tissue cultures of peripheral lymphocytes were evaluated according to the protocol of Claman and Brunstetter[14] with the following three modifications: 0.5×10^6 lymphocytes were used instead of 1.0×10^6 lymphocytes; 20% heat-inactivated human serum was used instead of fetal calf serum; and three dilutions (0.1 ml of 1:1, 1:10, and 1:25 of stock PHA solution) were tested with each culture. A terminal three-hour pulse of tritiated thymidine was used to evaluate the stimulatory response of the lymphocytes from the 69th to the 72nd hour of tissue culture. A separate set of cultures using various concentrations of phenytoin

Lymphocyte Response (Six Months After Convalescence)		
Substrate*	Patient, Counts/min	Control, Counts/min
Normal saline	574.8	1,108.1
PHA 1.00	173,871.8	167,138.2
PHA 0.10	389,909.7	379,766.8
PHA 0.04	281,017.1	297,886.0
Phenytoin 10ug/100 ml	124.1	197.6
20ug/100 ml	162.5	218.1
30ug/100 ml	189.0	189.6
40ug/100 ml	254.4	253.0
50ug/100 ml	332.3	292.4

*PHA indicates phytohemagglutinin.

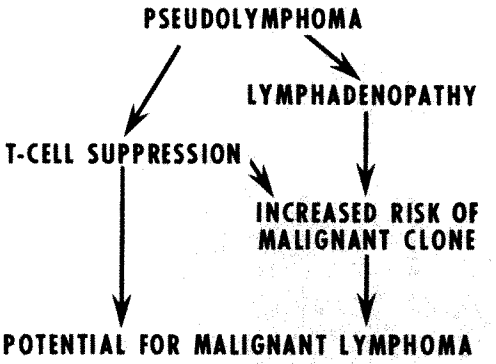

Fig 3.—Hypothesis for development of lymphoma.

were also done. All studies were done in triplicate, and normal saline was used as the control.

RESULTS

During the acute phase, the patient failed to show any reactions to the applied skin test antigens. The patient also failed to demonstrate a rise in typhoid O, typhoid H, or paratyphoid antibodies in four weekly serum samples after an initial immunization with *S typhi* vaccine. The effects of PHA on the patient's lymphocytes and the effect of various concentrations of phenytoin on the lymphocytes are shown in Fig 1. The graph shows no lymphocyte response to PHA or to phenytoin when compared with the matched control. The higher concentrations of phenytoin inhibited blast transformation and thymidine incorporation by the patient's lymphocytes. When the control and patient curves (Fig 1) were compared by statistical analysis, the results were highly significant ($P < .001$). This confirmed the incapability of the patient's lymphocytes to respond to either PHA or phenytoin. The failure of a lymphocyte response to phenytoin would not support this syndrome being a type IV[15] delayed hypersensitivity reaction to the drug.

The results of the mixed lymphocyte reaction done at the same time during the acute phase as the previous PHA testing are shown in Fig 2. The patient's lymphocytes showed a suppressed response to stimulation by the lymphocytes of an unrelated person that were viable but rendered nonresponsive by mitomycin. When the two curves (Fig 2) were subjected to statistical analysis, the P value was .1, indicating a 10% chance of random occurrence. While supporting the concept of the inability of the patient's lymphocytes to undergo blast transformation, it lacks the strong statistical significance of the acute phase PHA study.

The results of in vivo convalescence intradermal skin testing showed that the patient reacted with 6 mm of erythema to mumps and 8 mm of induration with 12 mm of erythema to *C albicans* at 24 hours. At 48 hours, she reacted to mumps with 12 mm of erythema and to *C albicans* with 9 to 10 mm of induration. The results of an in vitro study that was performed six months after complete convalescence are given in the Table. At this time, the patient's lymphocyte response to PHA was comparable to that of the normal control lymphocytes. Phenytoin showed no increased uptake of tritiated thymidine in either the patient's lymphocytes or the control lymphocytes. The lack of lymphocyte blast transformation in any of the concentrations of phenytoin indicates that the pseudolymphoma syndrome may not be a delayed hypersensitivity reaction.[16,17]

COMMENT

The present patient has the clinical syndrome that has been associated with phenytoin-induced pseudolymphoma. The histologic features of the lymph node and the lack of neoplastic evolution would place the patient in the "hyperplasia" group of pseudolymphoma as classified by Gams et al.[9]

The cause of this unusual reactive phenomenon remains obscure. Holland and Mauer[15] published data that demonstrated in vitro lymphocyte blast transformation in a patient with the pseudolymphoma syndrome attributable to phenytoin. They concluded that this syndrome may represent a delayed hypersensitivity reaction. Sorrell et al[19] studied 63 patients on long-term phenytoin therapy who had no evidence of any type of drug reaction. They found depression of in vitro lymphocyte transformation by PHA in .07%, absence of a delayed hypersensitivity reaction (type IV reaction)[15] to common antigens in 22%, and the failure of an antibody response to *S typhi* antigen in 9%. MacKinney and Booker studied patients with reactions to phenytoin and showed that the drug depressed DNA synthesis in cultured lymphocytes as measured by thymidine incorporation.[20]

The studies performed in the present case failed to show in vitro stimulation of the patients' lymphocytes by phenytoin. This does not support the concept of the pseudolymphoma syndrome resulting from delayed hypersensitivity reaction (type IV reaction).[15] The study fails to support the earlier findings of Holland and Mauer

and suggests that further studies are needed. The failure to elicit an antibody response to *S typhi* antigen suggests that the humeral immune-response may also be depressed, as well as the cell-mediated immunity, which corresponds with the data by Sorrell et al.[19]

An interesting hypothesis that attempts to explain the increased risk of lymphoid malignancy in diseases of depressed immunity has been proposed by Gershwin and Steinberg.[21] They have suggested that certain diseases, such as ataxia telangiectasia, the Wiskott-Aldrich syndrome, and the phenytoin-induced pseudolymphoma syndrome, may have an increased propensity to malignant transformation because of the loss of a normally occurring T-cell suppression. They suggest that this loss of T-cell suppression could result in the unregulated lymphatic proliferation favoring the development of a mutant clone of malignant cells. In this setting of depressed immunologic response, the body's immunosurveillance system may be unable to cope with the development of a malignant clone, resulting in a true lymphoma (Fig 3).

The studies presented here suggest that an immunologic hyporesponsiveness may exist in patients with pseudolymphoma induced by phenytoin during the period of lymphoproliferation. This may spontaneously abate when the medication is discontinued or may, in a rare patient, develop into a malignant lymphoma. This study adds credence to the hypothesis that certain diseases, including pseudolymphoma, may predispose the patient to the development of a frank malignant lymphoma when a proliferative lymphadenopathy is present in conjunction with an altered immunosurveillance system. These findings indicate that patients with this reaction to phenytoin need to be studied further before any firm conclusions can be drawn.

Lt Col Robert London, MD, and Sgt Ted Ball, MS, performed the technical studies during the acute phase. Lt Col Frank Brunstetter, MD, performed the convalescent phase testing.

Nonproprietary Names and Trademarks of Drugs

Mitomycin—*Mitocin-C, Mutamycin.*
Phenytoin—*Dihycon, Dilabid, Di-Lan, Dilantin.*

References

1. Goodman LS, Gilman A (eds): Drugs effective in convulsive disorder: *The Pharmacological Basis of Therapeutics*, ed 5. London, The Macmillan Co Publishers, 1975, pp 207-219.
2. Robinson HM, Stone JH: Exanthem due to diphenylhydantoin therapy. *Arch Dermatol* 101:462-465, 1970.
3. Ritchie EB, Kolb W: Reaction to sodium diphenyl hydantoinate (Dilantin sodium): Hemorrhagic erythema multiforme terminating fatally. *Arch Dermatol* 46:856-859, 1942.
4. Bajoghli M: Generalized lymphadenopathy and hepatosplenomegaly induced by diphenylhydantoin. *Pediatrics* 28:943-945, 1961.
5. Saltzstein SL, Ackerman LV: Lymphadenopathy induced by anticonvulsant drugs and mimicking clinically and pathologically malignant lymphomas. *Cancer* 12:164-182, 1959.
6. Hyman GA, Sommers SC: The development of Hodgkin's disease and lymphoma during anticonvulsant therapy. *Blood* 28:416-427, 1966.
7. Siegal S, Berkowitz J: Diphenylhydantoin (Dilanti) hypersensitivity with infectious mononucleosis-like syndrome and jaundice. *J Allergy* 32:447-451, 1961.
8. Anthony J: Malignant lymphoma associated with hydantoin drugs. *Arch Neurol* 22:450-454, 1970.
9. Gams RA, Neal JA, Conrad FG: Hydantoin-induced pseudolymphoma. *Ann Intern Med* 69:557-568, 1968.
10. Cougn PA, Weber MJ: Trois cas de lymphome malin ou pseudo-lymphome chez des 'epileptiques traites' par la diphen'ylhydantoine. *Schweiz Med Wochenschr* 101:1773-1774, 1970.
11. Senegar DP, Terasaki PI: A semimicro mixed leukocyte culture test. *Transplantation* 11:260-267, 1971.
12. Hartzman R, Segall M, Bach M, et al: Histocompatibility matching. *Transplantation* 11:268-273, 1971.
13. Bach FH, Voynow NK: One-way stimulation in mixed leukocyte culture. *Science* 153:545-547, 1966.
14. Claman HN, Brunstetter FH: Effects of anti-lymphocyte serum and phytohemagglutinin upon cultures of human thymus and peripheral blood lymphoid cells *Lab Invest* 18:757-762, 1968.
15. Coombs RRA, Gell PGH: The classification of allergic reactions responsible for clinical hypersensitivity and disease, in Gell PGH, Coombs RRA (eds): *Clinical Aspect of Immunology*. Philadelphia, FA Davis Co, 1968, pp 575-596.
16. Halpern B, Ky NT, Amache N: Diagnosis of drug allergy *in vitro* with the lymphocyte transformation test. *J Allergy* 40:168-181, 1967.
17. Sarkony I: Clinical and laboratory aspects of drug allergy. *Proc R Soc Med* 61:23-26, 1968.
18. Holland P, Mauer AM: Drug-induced in vitro stimulation of peripheral lymphocytes. *Lancet* 1:1368-1369, 1964.
19. Sorrell TC, Forbes IJ, Burness FR, et al: Depression of immunological function in patients treated with phenyltoin sodium (sodium diphenylhydantoin). *Lancet* 1:1233-1235, 1971.
20. MacKinney AA, Booker HE: Diphenylhydantoin effects on human lymphocytes in vitro and in vivo. *Arch Intern Med* 129:988-992, 1972.
21. Gershwin ME, Steinberg AD: Loss of suppressor function as a cause of lymphoid malignancy. *Lancet* 2:1174-1176, 1973.

Hidrotic Ectodermal Dysplasia

Study of a Large Chinese Pedigree

Krishna Rajagopalan, MB, MRCP, DDM, Chong Hai Tay, MB, FRCP

• Hidrotic ectodermal dysplasia was found, to our knowledge, for the first time in a Chinese family in Malaysia, and it affected 15 members in five generations. The disease, which is transmitted as a non-sex-linked autosomal dominant trait, presumably originated from southern China. All 15 members had the typical nail, hair, and skin lesions, and we observed three different types of nail defects. Scalp alopecia was more extensive in the female members, while keratoderma of the palms and soles was more notable in the male members. The nail and skin lesions also became severer with age. Except for the infectious eczematoid dermatitis present in the propositus, none had other skin or systemic disorders. All were relatively healthy and had normal life expectancies.

(*Arch Dermatol* 113:481-485, 1977)

Hidrotic ectodermal dysplasia (HED) is an uncommon autosomal dominant genodermatosis that is characterized by dystrophy of the nails, defects of the hair, keratoderma of the palms and soles, and, in a few instances, the presence of sensorineural deafness, polydactylism, syndactylism, mental retardation, and dwarfism.[1-4] In contrast to the anhidrotic ectodermal dysplasia, which is a sex-linked recessive condition, patients with HED have normal sweating, normal facies, and no specific dental abnormalities or an increased susceptibility to infections.

Although it is rare, this disease has been reported in many Western countries, in particular, Canada, where several families with large pedigrees have been described.[1,5-7] To our knowledge, the disease has not been previously reported in Asians. We describe a clinical study of a Chinese family from Malaysia with 15 affected members in five generations.

REPORT OF A CASE

A 28-year-old Chinese man was admitted to General Hospital, Johore Bahru, West Malaysia, for one week for treatment of extensive acute infectious eczematoid dermatitis (Fig 1). In the past, he had had a patch of lichen simplex chronicus on the left ankle, which was treated periodically with topical creams for about a year. For years he had been allergic to prawns, beef, mutton, aspirin, and certain seafood and had avoided these substances.

Since birth, his parents had observed that his nails, scalp hair and the skin of his hands and feet were abnormal. The nails of all of his fingers and toes rapidly became thick and discolored, and they were easily damaged at the edge by trauma or were infected around the nail folds. The badly damaged nails were often replaced by other imperfectly formed nails. The hair on the scalp, eyebrows, and eyelashes had remained sparse since infancy, although there was no excessive hair loss, increased hair brittleness, or abnormal color changes. He seldom shaved. For no apparent reason, too, the skin of his palms and soles gradually thickened and turned yellow. Cutaneous sensation and sweating, however, remained intact, Other than the previously mentioned cosmetic disfigurement that did not bother him, his physical, mental, dental, and sexual developments were all normal. There was no past history of drug allergies, contact dermatitis, bronchial asthma, hay fever, chronic infections, syphilis, exposure to heavy metals or toxic substances, or any other important systemic disorder.

When he was examined, except for a temperature of 38.3 C, his mental functions and general appearance, including the facies, were normal for his age and sex. Systemic abnormalities were not detected; the substantial findings were confined mainly to the skin, nails, hair, palms and soles. Numerous discoid eczematous lesions of varying sizes were found on the earlobes, cheek, upper part of the chest wall, right inner thigh, groin, left thigh, and dorsum of left foot. There was no regional lymphadenopathy. In addition to the infectious eczematoid dermatitis, he had the classical lesions of HED.

Notable dystrophic changes were found in all of the nails of his fingers and toes. They were smaller and opaque white to yellow, and either the whole or the distal part of the nail plate was considerably thickened. The nails that were severely involved, eg, the great toes and the right middle finger, showed substantial onycholysis and were cone-shaped or triangular

Accepted for publication Feb 19, 1976.

From the Skin Clinic, Johore Bahru General Hospital, Kuala Lumpur, Malaysia (Dr Rajagopalan), and the Department of Medicine, Singapore General Hospital, Republic of Singapore (Dr Tay).

Reprints not available.

(Fig 2). There was complete or partial shedding of the nails in the little toes. Less-affected nails were normal in size, but showed cracks and chippings at their edges and margins, as well as pits, linear striations, and ridges on their surfaces (Fig 3). In most nails, especially those that were severely affected, there was lifting up of the distal portion of the plates from the nail bed by several millimeters, thus allowing the accumulation of dirt and subungual debris. The skin of all of the affected fingers and toes were hypertrophied with tissue enlargement and with papillary furrowing of the periungual skin distal to the nail (Fig 2 and 3). There was mild alopecia with moderate thinning of the hair over the parietooccipital areas of the scalp, but there was no detectable scalp lesion. Likewise, the hair of his eyebrows and eyelashes, as well as that of the axillae and pubis, was scanty, shorter, and finer than normal. Microscopical examination and culture studies of these types of hair did not show any abnormality. The palms and soles were yellow; they were hyperkeratotic with accentuation of the creases, and there was callus-like keratoderma with small fissures present in both soles (Fig 4 and 5).

The skin on other parts of the body was normal in texture and color. Sweating was normal, and no dental or bony defects were observed.

Laboratory investigations showed normal blood and urinary findings. Results of a VDRL test for syphilis were negative, and results of a glucose tolerance test were normal. The pus from the infected skin lesions grew *Staphylococcus pyogenes* that was sensitive to all common antibiotics. For one week he received 1 gm of oral tetracycline hydrochloride daily together with 15 mg of oral prednisolone in divided doses daily. The eczematous lesions were bathed with potassium permanganate. The fever rapidly subsided, and the eczematoid dermatitis cleared up by the end of the week and he was discharged. Since he gave a history that many members of his family were similarly affected by the same nail, hair, and skin defects, they, too, were investigated.

FAMILY STUDY

Almost all of the members of this family, except those who were already dead or who had left Malaysia, were personally examined by one of us. As shown in Fig 1, another 14 members in the five generations in this family had HED. Four of them, however, were reliably reported, since they had died long ago (cases 1 and 2) or were no longer in the country (cases 5 and 6).

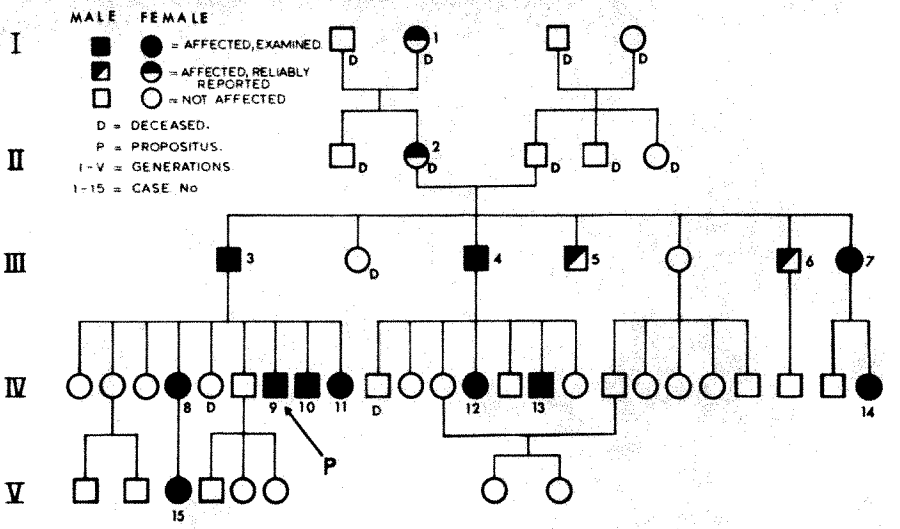

Fig 1.—Family pedigree. Arrow denotes propositus (P).

The numbers found in each of the five generations were 1, 1, 5, 7, and 1, respectively. It appeared that the disease originated from the propositus' paternal great-grandmother (case 1, generation I, who, with her daughter (case 2, generation II), were early immigrants from southern China. Both died of "old age" when they were 60 and 72 years old, respectively (Table). The family had lost track of their close relatives in China after the world wars, and it was impossible to trace whether other members were similarly affected by HED.

Inheritance

In this family, HED was transmitted as an autosomal dominant trait with almost complete penetrance. Half or almost half of the offspring from the affected members showed the classical lesions of the disease, while the unaffected members produced normal offspring. Even an intermarriage between two unaffected members in generation IV failed to transmit the disease to their two children.

CLINICAL FINDINGS

The detailed clinical findings of the 15 cases are listed in the Table. There were eight female members and seven male members, and their ages ranged from 1 to 72 years. The majority of them were in their third and fourth decades, and all were in good physical health. There were no premature deaths; the older members had perished from natural causes of death unrelated to HED. None had abnormalities of physical, mental, dental, or sexual developments. All had normal facies and sweating.

Nail Lesions

Practically all of the nails of the fingers and toes of those examined showed dystrophic changes of varying severity. Three types of defects characteristic of HED were observed. The commonest and most severe of all defects was the small cone-shaped or triangular nail found in the propositus, as well as in the older members of both sexes. Fingers and toes were affected with equal frequency. The second type of nail defect, sometimes is found together with the first in the same hand or foot. It consists of a normal-sized, moderately thickened plate, but the nail surface shows evidence of early dystrophy, eg, multiple grooves, pits, ridges, longitudinal striations, and/or irregular chips at the edges and sides. The propositus and most of the younger members (eg, cases 10, 11, and 13) had this form of nail lesion. The third defect was often seen in younger children and infants (eg, cases 14 and 15). The nail appeared smaller, but without much thickening, and was less convex in shape. The distal half of the plates was often separated from the nail bed by a gap at the center of the free edge. The nails of these children usually looked uncleaned, since dirt and other

Fig 2.—Classical cone-shaped or triangular nail with hypertrophy and papillary furrowing of periungual skin distal to small and discolored nails.

Fig 3.—Normal-sized thumbnails with ridges, broad linear striations, and chipped edges on surface and sides of brittle nails. Note clubbed-like appearance of hypertrophied distal phalange.

Fig 4.—Keratoderma of palm.

Fig 5.—Callus-like keratoderma of soles with multiple small fissures.

Clinical Findings of 15 Cases of Hidrotic Ectodermal Dysplasia*

Case/Generation	Relationship to Propositus	Age, yr/ Sex	Nail Lesion	Alopecia	Kerato-derma
1/I	Paternal great-grandmother	60/F	+ + +	+ + +	+ +
2/II	Paternal grand-mother	72/F	+ + +	+ + +	+ +
3/III	Father	64/M	+ + +	+	+ + +
4/III	First uncle	56/M	+ + +	+ +	+ + +
5/III	Second uncle	40/M	+ + +	+ +	+ + +
6/III	Third uncle	38/M	+ + +	+ +	+ +
7/III	Aunt	30/F	+ +	+ + +	+ +
8/IV	Eldest sister	34/F	+ +	+ + +	+
9/IV	Propositus	28/M	+ + +	+	+ + +
10/IV	Brother	24/M	+ +	+ +	+
11/IV	Sixth sister	22/F	+ +	+ + +	+
12/IV	First uncle's daughter	24/F	+ + +	+ + +	+
13/IV	First uncle's son	14/M	+	+ +	−
14/IV	Aunt's daughter	1/F	+	+ + +	−
15/V	Eldest sister's daughter	1/F	+	+ + +	−

*− indicates no lesion; +, mild lesion; + +, moderately severe lesion; + + +, severe lesion.

debris often filled the hollow space and could not be washed off easily.

Finger and Hand Lesions

In older members with the moderate and severe types of nail defects, the distal phalanges were thicker and wider than normal and also appeared clubbed because of tissue hypertrophy. The increased length of the rough, furrowed periungual skin looked as if it had displaced the affected nails proximally from the plump finger tips (Fig 2 and 3).

Hair Defects

Scalp alopecia in affected members varied from mild thinning (eg, in the propositus) to complete baldness (eg, cases 14 and 15). In some, alopecia appeared maximally soon after birth, and they remained bald throughout their lives, after shedding their lanugo hair. In the majority, hair loss was gradual and less severe, and occurred only after puberty. Female members, however, were more severly affected than male members, and most of them had to wear wigs. Men generally had scanty beards, and both sexes had sparse or total absence of eyebrows, eyelashes, and hair of the pubis and axillae. Macroscopical and microscopical examination of this hair showed no structural defects, brittleness, or pigmentary changes, but it was generally shorter, more downy, and finer than the normal hair.

Skin Lesions

Hyperkeratosis of the palms and soles were found in all of the members, except in the young. The thickness increased gradually with age. Those with severe hyperkeratosis and keratoderma had rough, dry skin with yellow callosities over the fingers. The palmar lines were deepened and prominent. The soles were usually more affected than the palms, and multiple small fissures developed in the keratodermal areas. As shown in the Table, the male members in this family generally had severer forms of keratodermal involvement than the female members. None, however, had developed malignant complications from these lesions.

COMMENT

Hidrotic ectodermal dysplasia is not excessively rare. The disease has been reported in a number of Western countries,[2-8] particularly Canada, where several large families of French or French-Canadian ancestries were discovered.[1,4-7]

The rarity of reported cases in Asians might be attributable to the lack of documentation or to the lack of awareness of the disease. Indeed, the milder forms of HED are easily mistaken for some commoner conditions. The present study of 15 cases in one Chinese family is probably one of the largest reported for this race.

As is classical of this disease, the transmission in this family was that of the non-sex-linked autosomal dominant trait, since almost half of the siblings of the affected members had the disease.[1,7] Normal members of the family rarely passed the disease on to their children, but skip generations have been reported.[5] Of interest was the intermarriage of two unaffected members in generation IV in this family; their offspring, as predicted by Wilkey and Stevenson,[6] in such a situation, were normal.

The disease in this Chinese family was traced to the propositus' great-grandmother, who was an immigrant from southern China. Although we were unable to trace her relatives in China, it would be assumed that this condition is also present in that part of the world.

In most studies, both sexes are equally affected, but a slight female preponderance was found in this study. Female members had a higher incidence of the severe form of scalp alopecia, while the male members suffered more from keratoderma. Persons of all ages were affected, since HED can appear initially either in infancy or, as found in our cases, soon after puberty.

We confirmed the observation made by Williams and Fraser[7] that the severity of the condition increases with age. This was particularly true for the nail and skin lesions. On the other hand, once the hair defect was present, it tended to remain unchanged throughout life. Earlier, Clouston,[1] using an elaborate point system, had argued that successive generations tend to have decreased severity of the disease. But when his cases were later reviewed, it was found that the severity was really related more to the age than to the diminished transmission in subsequent generations.[7]

Dystrophy of the nails, a key feature of HED, was found in all cases, but it is also well known that in 30% of those who are affected, especially young children, this lesion

might not be obvious.[5] This is because the nails in the young had slightly smaller nail plates that were not grossly thickened or deformed. The uplifting of the distal portion of the plate with the accumulation of debris between the nail bed and the nail may be minimal and may be mistaken for dirtiness, since these nails are difficult to keep clean. All three types of nail defects described by Wilkey and Stevenson[6] were found in our cases. The children's variety often changed into the adult types soon after puberty. Both the adult types of nail defects may be present in the same hand and foot. We found that the severer form affected the men more than the women. Part of the explanation might be because of the frequent trauma these brittle nails were subjected to.

Sparsity of the hair of the scalp, face, eyebrows, eyelashes, axillae, and genitalia also varied in severity in those who were affected. Substantial alopecia was encountered in two children (cases 14 and 15) and most of the female cases in this family. This cosmetic setback, however, did not prevent the affected female members from marriage, because they wore wigs and also drew in their eyebrows. The hair growth was slow and the shaft was fine and shorter than normal, but there was no apparent structural or pigmentary change. The third component of the syndrome, keratoderma of the palms and soles, was present in all but the youngest members of the family. Male members had a higher incidence of the severe form of this skin lesion. Others reported that skin thickening had spread from the palms to finger knuckles, knees, and elbows,[5] and that squamous cell carcinoma had developed from the keratosis on one occasion.[3]

Besides the infectious eczematoid dermatitis found in the propositus, the other affected members in this family did not demonstrate any skin lesions or congenital defects such as sensorineural deafness, polydactylism, syndactylism, or mild mental deficiency, as reported by others.[3-6]

In contrast to the anhidrotic ectodermal dysplasia, which is a sex-linked recessive disease, sweating was normal, and there was absence of anodontia, typical facies, dermatoglyphic abnormalities, hyperpyrexia, and tendency for recurrent infections. In the absence of a positive family history, one has to consider several differential diagnoses, such as congenital syphilis, pachyonychia congenita, nail-patella syndrome, familial tylosis, fungal nail infection, and psoriatic nail lesion.

The diagnosis of HED usually can be established by classical nail dystrophy in a patient with normal facies, no specific dental defects, normal sweating, and in the absence of other systemic or cutaneous involvement. Except for a single lethal case occurring in the homozygous state,[7] patients with HED, as shown in this and other family studies, generally have normal life expectancies.

References

1. Clouston, HR: A hereditary ectodermal dystrophy. *Can Med Assoc J* 21:18-26, 1929.
2. Joachim H: Hereditary dystrophy of the hair and nails in six generations. *Ann Intern Med* 10:400-402, 1936.
3. Feinmesser M, Zelig S: Congenital deafness associated with onychodystrophy. *Arch Otolaryngol* 74:507-508, 1961.
4. Robinson GC, Miller JR, Bensimon JR: Familial ectodermal dysplasia with sensorineural deafness and other anomalies. *Pediatrics* 30:797-802, 1962.
5. Clouston HR: Hereditary ectodermal dystrophy. *Can Med Assoc J* 40:1-7, 1939.
6. Wilkey WD, Stevenson GH: A family with inherited ectodermal dystrophy. *Can Med Assoc J* 53:226-230, 1945.
7. Williams M, Fraser FC: Hydrotic ectodermal dysplasia: Clouston's family revisited. *Can Med Assoc J* 96:36-39, 1967.
8. Rook A: Genetics in dermatology, in Rook A, Wilkinson DS, Ebling FJG (eds): *Textbook of Dermatology*, ed 2. Oxford, England, Blackwell Scientific Publications, 1972, vol 1, pp 107-109.

Unilateral Nevoid Telangiectasia

Three New Cases and the Role of Estrogen

Jonathan K. Wilkin, MD

• Over a period of one month three patients attending a women's outpatient clinic at a general hospital were observed to have unilateral telangiectatic lesions. To our knowledge, only 12 cases of unilateral nevoid telangiectasia have been previously reported; this report would bring to 15 the number of cases of this syndrome. The temporal aspect of the onset of the lesions among these patients strongly supports the role of estrogen in the appearance of unilateral nevoid telangiectasia.

(*Arch Dermatol* 113:486-488, 1977)

Telangiectatic lesions have undergone several classifications, one of the most recent presented by Anderton and Smith.[1] The lesions are first divided into primary telangiectasia and telangiectasia presumably caused by, or associated with, other disorders. They classify unilateral nevoid telangiectasia syndrome as primary and include two subdivisions, viz, without systemic involvement and with systemic involvement. The latter subdivision was based on the very interesting case that they reported.

The following three intriguing cases led us to an examination of the previous reports of similar cases and the temporal aspects of the onset of this syndrome.

REPORT OF CASES

CASE 1.—A 17-year-old white primigravida, 18 weeks' pregnant by size and 22 weeks by dates, had an initial prenatal examination in May 1975. Telangiectatic lesions (Fig 1) were observed over the region of the scapula, extending along the posterolateral aspect of the arm, sparing the deltoid area and becoming somewhat anterior just above the elbow, but remaining lateral, and ending just below the elbow. The lesions were in a continuous distribution and were limited to the right side (Fig 2). The patient claimed that the telangiectases had been present for several months; and, although the area had not become larger, the lesions had become a brighter red. The patient denied previous lesions, previous exposure to oral contraceptives, bleeding or bruising tendency, and a family history of similar lesions. The patient did report that she had been treated for several weeks for infectious hepatitis in 1973.

Laboratory studies disclosed normal values for total protein, albumin, calcium, phosphorus, cholesterol, uric acid, creatinine, total and direct bilirubin, alkaline phosphatase, lactic dehydrogenase (LDH), SGOT, BUN, glucose, and electrolytes. Arterial blood gases while breathing room air showed pH 7.46, Po_2 99.9 mm Hg, and Pco_2 30.8 mm Hg, whereas after breathing 100% oxygen for a period of 15 minutes the values were pH 7.53, Po_2 558.0 mm Hg, and Pco_2 26.0 mm Hg.

A VDRL test for syphilis was nonreactive and a cervical culture for the *Gonococcus* showed no growth. The group and type was A-positive. A complete blood cell count revealed the following: hematocrit, 34%; WBCs, 11,300/cu mm; and platelet count, 325,000/cu mm. Prothrombin time was 13 seconds (control reading, 12.5 seconds).

CASE 2.—A 27-year-old white multigravida in the 26th week of pregnancy had an initial prenatal examination in May 1975. Telangiectases were noted in an area approximately 10 cm in length by 5 cm in width in the middle third of the right forearm on the extensor aspect (Fig 3). No similar lesions were noted elsewhere. The patient claimed that the telangiectasias had been present for several months; and, although the area had not become larger, the lesions had become a brighter red. The patient noted that this lesion appeared in the same manner and in the same location in each of three normal pregnancies in 1963, 1965, and 1972. Further, she claimed that the lesions disappeared within several weeks after delivery. The patient denied previous lesions, except for those during the previous pregnancies. The patient denied previous exposure to oral contraceptives, bleeding or bruising tendency, a family history of similar lesions, and a past history of jaundice, hepatitis, or other hepatic disorder. Laboratory studies disclosed normal values for total protein, albumin, calcium, phosphorus, cholesterol, uric acid, creatinine, total and direct bilirubin, alkaline phosphatase, LDH, SGOT, BUN, glucose, and electrolytes. Arterial blood gases while breathing room air showed pH 7.50, Po_2 98.6 mm Hg, and Pco_2 33.3 mm Hg, whereas after breathing 100% oxygen for a period of 15 minutes the values were pH 7.51, Po_2 530.0 mm Hg, and Pco_2 31.2 mm Hg.

A VDRL test for syphilis was nonreactive and a cervical culture for the *Gonococcus* showed no growth. The group and type was A-positive. A complete blood cell count revealed the following: hematocrit, 36%; WBCs, 11,600/cu mm; and platelet count, 315,000/cu mm. Prothrombin time was 11.5 seconds (control reading, 12.5 seconds.) Partial thromboplastin time was 36.4 seconds (control reading, 39 seconds).

CASE 3.—A 16-year-old white primigravida, ten weeks pregnant was evaluated for a voluntary abortion in June 1975. Telangiectatic lesions were observed in the area from the right preauricular area along the mandible to the right of the mentum to the origin of the sternocleidomastoid laterally to the acromion and medially along the posterior margin of the sternocleidomastoid. A small patch of telangiectases was also observed inferior to the clavicle and to the right side of the midline (Fig 4). The patient claimed that the lesions were first noted at 10 or 11 years of age and had not undergone any changes in size or color, until an increase in redness during the preceding month. The patient claimed that a maternal aunt had a similar lesion on her neck. The patient denied previous exposure to oral contraceptives, bleeding or bruising tendency, and a past history of jaundice, hepatitis, or other hepatic disorder. The patient's history was corroborated by her mother.

Laboratory studies disclosed normal values for total protein, albumin, calcium, phosphorus, cholesterol, uric acid, creatinine, total and direct bilirubin, alkaline phosphatase, LDH, SGOT, BUN, glucose, and electrolytes. Arterial blood gases while breathing room air showed pH 7.46, Po_2 112.1 mm Hg, Pco_2 30.0 mm Hg, whereas after breathing 100% oxygen for a period of 15 minutes the values were pH 7.45, Po_2

Accepted for publication Feb 20, 1976.

From the Division of Dermatology, University of Tennessee Center for the Health Sciences, Memphis, and the Department of Obstetrics and Gynecology, University of Louisville (KY) School of Medicine.

Reprint requests to the Division of Dermatology, University of Tennessee Center for the Health Sciences, 800 Madison Ave, Memphis, TN 38103 (Dr Wilkin).

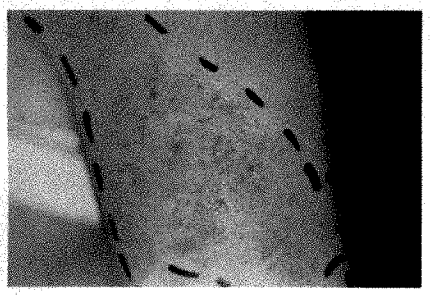

Fig 1.—Telangiectasia in case 1.

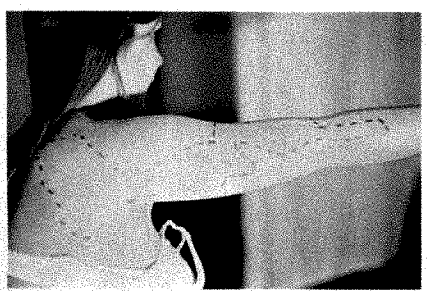

Fig 2.—Nevoid distribution of telangiectasia in case 1.

Fig 3.—Nevoid distribution of telangiectasia in case 2.

Fig 4.—Nevoid distribution of telangiectasia in case 3.

539.7 mm Hg, and P_{CO_2} 31.8 mm Hg.

A VDRL test for syphilis was nonreactive and a cervical culture for the *Gonococcus* showed no growth. The group and type was O-positive. A complete blood cell count revealed the following: hematocrit, 36%; WBCs, 6,400/cu mm; and platelet count 230,000/cu mm. Prothrombin time was 14 seconds (control reading, 13 seconds). Partial thromboplastin time was 35.5 seconds (control reading, 39 seconds).

COMMENT

The brief report of Zeisler[2] of a pregnant patient with scattered telangiectases in a unilateral distribution along the left arm and shoulder is perhaps the first recorded case of the unilateral nevoid telangiectasia syndrome. He noted that the lesions were present during pregnancy and disappeared thereafter only to return in a subsequent pregnancy. Tommasi[3] reported the onset of telangiectases in a unilateral distribution in a patient three years prior to onset of menses. Further, the lesions also became redder during the proliferative phase of the menstrual cycle. Bean et al[4] observed the appearance of vascular spiders and palmar erythema in normal pregnancies, noting the symmetrical scattering of lesions and postulating that increased estrogen may lead to the appearance of these lesions. Billings[5] reported the case of a pregnant patient who first noted unilateral telangiectases of the right hand and forearm in the fifth month of pregnancy that became brighter as the pregnancy progressed, although the area of skin involved did not increase. In the first week postpartum the lesions had faded, becoming very faint two months later and subsequently disappearing altogether. Bowen[6] had a patient in whom unilateral telangiectatic lesions appeared on the left side of the neck and left arm one year after the onset of menses.

Fig 5.—Temporal relationship between nevoid telangiectasia and level of circulating estrogens (arrow denotes menarche).

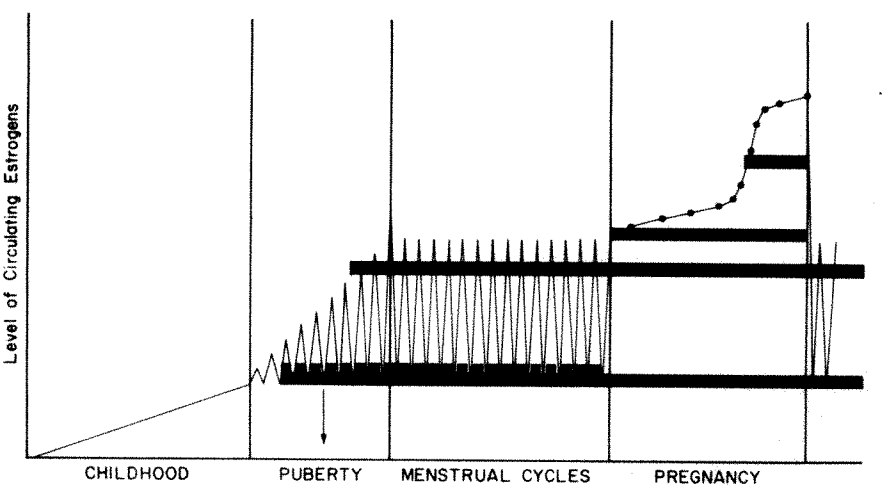

Selmanowitz[7] presented two cases of unilateral nevoid telangiectasia. In the first case the lesions appeared at puberty and had been present for seven years in a nonpregnant, 21-year-old woman. The telangiectases occurred on the left side of the face, the left portion of the neck, the left shoulder, the left supraclavicular and medial infraclavicular regions, and the lateral aspect of the left upper extremity terminating at the wrist. In the second case the telangiectases had been present in a 47-year-old man since birth in a similar distribution on the left side, except that the face was not involved and the lesions extended somewhat lower on the chest and on the dorsum over the left scapula. Aram and Solomon[8] reported two cases of telangiectasia in a unilateral distribution. The first patient was a 28-year-old gravida who had lesions on

Summary of Unilateral Nevoid Telangiectasia Syndrome Cases				
Case No.	Source	Sex	Condition Present at Onset of Lesions	Distribution
1	Zeisler[2]	F	Pregnancy	L; C-4,5
2	Tommasi[3]	F	Puberty	Unknown
3	Billings[5]	F	Pregnancy	R; C-2,3,6,7,8, T-2
4	Bowen[6]	F	Puberty	L; unknown
5	Selmanowitz[7]	F	Puberty	L; V, C-3,4,5,6
6	Selmanowitz[7]	M	Congenital	L; C-3,4, T-2
7	Aram & Solomon[8]	F	Pregnancy	R; C-4,5,6
8	Aram & Solomon[8]	F	Hormone therapy (puberty)	R; C-4,5
9	Mirrer[9]	F	Alcoholism/cirrhosis	R; upper and lower limbs, truck, & face
10	Greer[10]	M	Alcoholism/cirrhosis	R; C-4
11	Frankel[11]	M	Alcoholism/cirrhosis	R; C-4,5
12	Anderton & Smith[1]	M	Alcoholism/cirrhosis	L; V-1,2,3, C-3,4,5, T-1
13	Present study	F	Pregnancy	R; C-4,5,6, T-2
14	Present study	F	Pregnancy	R; C-6, T-1
15	Present study	F	Puberty	R; C-2,3, T-2

the right side of the chest, arm, and forearm. This was the second time she had lesions, having had unilateral telangiectases during her previous pregnancy, which faded postpartum. The second patient was a 25-year-old woman who received estrogen-progesterone compounds intramuscularly for menstrual disturbances prior to the appearance of telangiectases approximately five years earlier on the right anterior part of the chest, shoulder, and upper arm. Mirrer et al[9] reported the onset of telangiectatic lesions over the right side of the body; upper and lower extremities; and the central part of the face, nose, lips, and oral mucosa in a 52-year-old woman with cirrhosis of the liver, upper gastrointestinal bleeding, and a long history of alcohol abuse. Greer[10] presented a second case of unilateral nevoid telangiectasia developing in association with cirrhosis of the liver. The patient was a 54-year-old man who had telangiectatic lesions of the right anterior part of the chest of one month's duration prior to admission for alcoholic cirrhosis of the liver. Frankel[11] reported a third case of unilateral nevoid telangiectasia developing in association with alcoholism, although liver damage or findings of cirrhosis were not demonstrated. The patient was a 45-year-old man with a four-year history of telangiectatic lesions over the right part of the thorax and right arm; the patient admitted to increased alcoholic consumption during this time. Anderton and Smith[1] presented a 40-year-old man, the fourth reported case of alcoholic cirrhosis of the liver, who had telangiectases over the left trigeminal, C-3, C-4, C-5, and T-1 dermatomal areas that appeared nine years previously; also, endoscopy revealed scattered telangiectases over the entire gastric mucosa. Further, they reviewed some of the earlier information concerning the unilateral nevoid telangiectasia syndrome and presented a new classification of the telangiectatic syndromes.

With the exception of those cases of unilateral nevoid telangiectasia appearing in association with alcoholism (cases 9, 10, 11, and 12), the acquired cases seem to appear coincident with a physiologic state in which the level of estrogen is increased. This may be interpreted as circumstantial evidence that estrogen triggers the telangiectasia. Thus, the highest bar in Fig 5 indicates telangiectasia occurring only in the latter half of pregnancy when the highest levels of estrogen occur (case 3). In the same figure the second highest bar indicates telangiectasia occurring throughout pregnancy when estrogen levels are high (cases 1, 7, 13, and 14). Also depicted are case 4 in which the telangiectasia appeared slightly after menarche, and case 2 in which the telangiectasia appeared slightly before menarche and demonstrated proliferative phase reddening.

In 14 of the known 15 cases of unilateral nevoid telangiectasia syndrome the telangiectasia was acquired. In the only congenital case the patient was male (case 6). Of the acquired cases ten were unrelated to alcoholism, were exclusively female, and did not exhibit systemic involvement. The remaining four acquired cases were related to alcoholism, were predominantly male (three of four cases), and included the single case with systemic involvement. Thus, a subclassification of the unilateral nevoid telangiectasia syndrome may be proposed:

Unilateral Nevoid Telangiectasia
I. Congenital
II. Acquired
  A. Estrogen-related
  B. Alcohol/hepatic-related
    1. Without systemic involvement
    2. With systemic involvement

In summary (Table), three new cases of the unilateral nevoid telangiectasia syndrome have been presented, circumstantial evidence implicating estrogen in the onset of the telangiectases has been noted, and a subclassification of the unilateral nevoid telangiectasia syndrome has been suggested.

References

1. Anderton RL, Smith JG Jr: Unilateral nevoid telangiectasia with gastric involvement. *Arch Dermatol* 111:617-621, 1975.
2. Zeisler: Telangiectasia associated with syphilis and pregnancy. *Arch Dermatol Syphil* 5:781, 1922.
3. Tommasi L: *Giornale Italiano Della Malattie Veneree I Della Pelle.* 64:275, 1923.
4. Bean WB, Cogswell R, Dexter J, et al: Vascular changes of the skin in pregnancy. *Surg Gynecol Obstet* 88:739-752, 1949.
5. Billings FT: Unusual distribution of vascular spiders in pregnancy. *Arch Intern Med* 112:835-839, 1963.
6. Bowen EJ: Neo-eruptive microangiomatosis tardive systemized (microtelangiectasis essential progressive unilateral) Tommasi? *Arch Dermatol* 89:615-616, 1964.
7. Selmanowitz VJ: Unilateral nevoid telangiectasia. *Ann Intern Med* 73:87-90, 1970.
8. Aram H, Solomon LM: Linear telangiectasia. *Acta Derm Venereol* 50:302-304, 1970.
9. Mirrer E, Cipriano A, McGuire J: Unilateral nevoid telangiectasia. *Arch Dermatol* 103:320-323, 1971.
10. Greer KE: Unilateral nevoid telangiectasia. *Arch Dermatol* 109:100, 1974.
11. Frankel EB: Unilateral nevoid telangiectasia. *Arch Dermatol* 110:638, 1974.

Secondary Syphilis Presenting as a Pruritic Dermatosis

Gary W. Cole, MD; Robert B. Amon, MD; Paul S. Russell, MD

• Three patients had secondary syphilis with severely pruritic skin lesions. This presentation contradicts several modern medical texts in which the lesions of secondary syphilis are described as nonpruritic.

(*Arch Dermatol* 113:489-490, 1977)

In a number of modern medical texts and recent articles, the cutaneous eruption of secondary syphilis has been described as nonpruritic.[1-6] Certain authors advise that the presence of pruritic skin lesions virtually rules out the diagnosis of secondary syphilis.[7] Recently, we diagnosed and treated three patients with secondary syphilis who presented with severely pruritic eruptions.

REPORT OF CASES

CASE 1.—A 42-year-old man first came to the Portland Veterans Administration Hospital in February 1975, with severe pruritus confined to his perineum. Nits were identified, and he was treated with benzene hexachloride, gamma. Following treatment, the patient's pruritus rapidly resolved.

Accepted for publication March 16, 1976.

From the Department of Dermatology, University of Oregon Health Sciences Center, Portland.

Reprint requests to University of Oregon Health Sciences Center, 3181 SW Sam Jackson Park Rd, Portland, OR 97201 (Dr Cole).

The patient returned two weeks later, again complaining of pruritus, but this time confined to his back, abdomen, and flexor forearms. He denied the presence of preceding genital, anal, or oral lesions. He also disclaimed any previous history of syphilis or recent antibiotic therapy. On physical examination, groups of excoriated papules localized to his back (Fig 1), forearms (Fig 2), and abdomen were present. No evidence of pediculosis or scabies was found. Except for generalized lymphadenopathy, the remainder of the physical examination was normal. Laboratory tests included a WBC of 5,100/cu mm with a normal differential. Values for hematocrit, alkaline phosphatase, SGOT, CPK, BUN, and urinalysis were all within normal limits. The VDRL test for syphilis was positive at a titer of 1:128. The FTA-ABS was also positive. The patient was treated with 2.4 million units of penicillin G benzathine, and the skin lesions and pruritus cleared within two days. He did not exhibit a Herxheimer reaction. During the ensuing six months, the patient's quantitative VDRL test for syphilis declined to a titer of 1:4 with no recurrence of pruritus.

CASE 2.—A 35-year-old man presented to the Portland Dermatology Clinic with a three-week history of an intensely pruritic skin eruption confined to his lower extremities, his perineum, and the palms of both hands. Some of these lesions were slightly scaly while others appeared nodular and erythematous. He denied any preceding genital or oral lesions. The patient had a normal CBC and a negative throat culture.

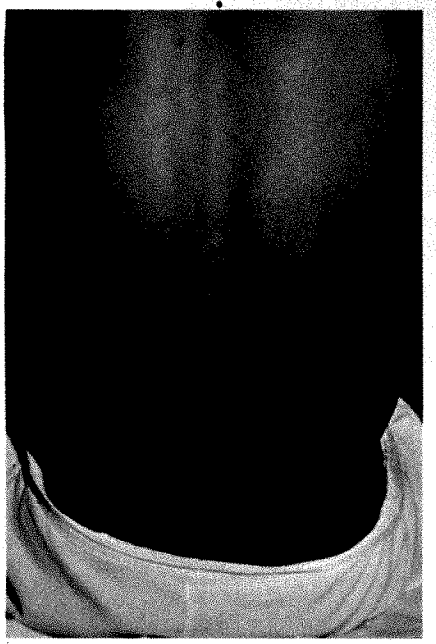

Fig 1.—Excoriated papules on lower back of patient 1.

Fig 2.—Papules on forearms of patient 1.

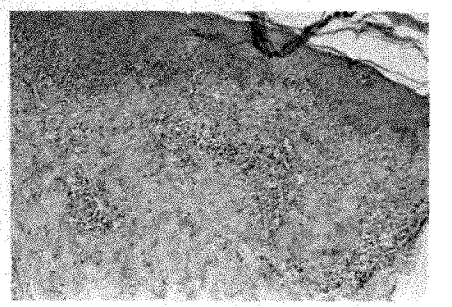

Fig 3.—Skin biopsy from patient 2 showing a mononuclear cell infiltrate in the dermis (hematoxylin-eosin, original magnification ×80).

The VDRL test for syphilis was positive at a titer of 1:64, and the FTA-ABS was positive. A skin biopsy was done (Fig 3) that showed liquifaction degeneration of the basal layer of the epidermis with a cellular infiltrate near the dermal-epidermal junction composed of histiocytes, lymphocytes, and plasma cells.

The patient was treated with 2.4 million units of penicillin G benzathine with subsequent resolution of his pruritus and skin eruption. He developed no Herxheimer reaction. His VDRL titer has shown a steady decline, and his pruritus has not returned.

CASE 3.—A 38-year-old woman was seen in early October 1975 in the Outpatient Clinics of the University of Oregon Health Sciences Center for menstrual cramps and a nondescript vulvar ulcer. No Darkfield examination was done, and a VDRL test for syphilis drawn at that time was nonreactive. The patient returned two weeks later complaining of a four-day history of an intensely itchy eruption over her entire body.

On physical examination, a generalized papular rash was present that also involved her palms and soles. Except for tender, inguinal lymphadenopathy, the remainder of the physical examination was normal. No vulvar nor oral lesions were present, and her pruritus was treated symptomatically with diphenhydramine hydrochloride. As part of the routine follow-up of the original vulvar ulcer, a VDRL test for syphilis and FTA-ABS were obtained. The VDRL was reactive at a titer of 1:32 and the FTA-ABS was positive.

The patient was treated with 2.4 million units of penicillin G benzathine. She noted no Herxheimer reaction, and her pruritic skin eruption resolved within four days. The patient's quantitative VDRL titer has shown a steady decline, and there has been no recurrence of her pruritic dermatosis.

COMMENT

In all of our patients, the presenting symptom of secondary syphilis was pruritus. In this manifestation of the "great imitator" so rare that the physician may feel secure that its presence virtually rules out syphilis? We think not. Conant[8] reported one patient with a papulonodular syphilid who itched slightly. Lockner and Pomeranz[9] reported three patients with "lichenoid" secondary syphilis who experienced some itching during their illness. All of our patients as well as two of Lockner and Pomeranz' were black. Stokes et al[10] referred to a follicular syphilid seen in black patients that may be pruritic. King and Nicol[11] described a pruritic, papular syphilid seen in patients with pigmented skins.

It is our intention to emphasize that pruritus as a presenting symptom in the presence of skin lesions suggestive of syphilis should not blind the physician to the possibility that *Treponema pallidum* may be the etiological agent. This appears to be especially true in darkly pigmented patients with papular syphilids.

Westwood Pharmaceuticals Inc supplied a grant that made possible the publication of the color reproductions.

References

1. Lomholt G, in Rook A (ed): *Textbook of Dermatology*. London, Blackwell Scientific Publications, 1972, p 645.
2. Pillsbury D, Shelly W, Kligman A: *Dermatology*. Philadelphia, WB Saunders Co, 1956, p 552.
3. Allen A: *The Skin*. New York, Grune & Stratton Co, 1967, p 451.
4. *Syphilis. A Synopsis*. US Department of Health, Education, and Welfare, 1968, p 57.
5. Druzin L: The diagnosis and treatment of infectious and latent syphilis. *Med Clin North Am* 56:1161-1173, 1972.
6. Sutton RL Jr, Waisman M: *The Practitioners' Dermatology*. New York, Dun-Donnelley Publishing Corp, 1975, p 171.
7. Olansky S, Norins L, in Fitzpatrick TB (ed): *Dermatology in General Medicine*. New York, McGraw-Hill Book Co, 1971, p 1961.
8. Conant M: Syphilis. *West J Med* 120:41-54, 1974.
9. Lockner J, Pomeranz J: Lichenoid secondary syphilis. *Arch Dermatol* 109:81-83, 1974.
10. Stokes JH, Beerman H, Ingraham NR: *Modern Clinical Syphilology*. Philadelphia, WB Saunders Co, 1944, p 582.
11. King A, Nicol C: *Venereal Diseases*. Philadelphia, FA Davis Co, 1975, pp 26-33.

Giant Melanosomes in Multiple Lentigines Syndrome

Larry W. Weiss, MD, PhD, Alvin S. Zelickson, MD

• **Biopsy specimens of normal skin and lentigines from an 82-year-old man with multiple lentigines syndrome were examined with light and electron microscopes. Giant melanosomes were found in dermal melanophages, melanocytes, and keratinocytes in all epidermal layers. Morphologic characteristics of these melanosomes are described, and other conditions in which they have been found are discussed.**

(*Arch Dermatol* 113:491-494, 1977)

Recently, giant melanosomes have been reported in the pigmented macules of neurofibromatosis[1,2] and in nevus spilus.[3,4] We studied biopsy specimens of normal skin and lentigines from a patient with multiple lentigines syndrome and found giant melanosomes in these latter sites by both light and electron microscopy.

REPORT OF A CASE

An 82-year-old man had generalized pigmented macules, which included the palms and soles, that apparently developed when the patient was a young child. Other findings included ocular hypertelorism, shortness of stature, kyphoscoliosis, pectus excavatum, bilateral partial sensorineural deafness, and an absent left testicle that was undescended and surgically removed at age 6 or 7. There were no clinically detectable cardiac abnormalities. Laboratory studies disclosed a leukocyte count of 3,900/cu mm and a hemoglobin level of 11.8 gm/100 ml. The ECG showed a first-degree atrioventricular block, a left axis deviation, and low voltage and posterior rotation. The patient has also had a malignant melanoma excised from the posterior aspect of his left ear in 1973.

Accepted for publication March 16, 1976.

From the Department of Dermatology, University of Minnesota, Minneapolis.

Reprints not available.

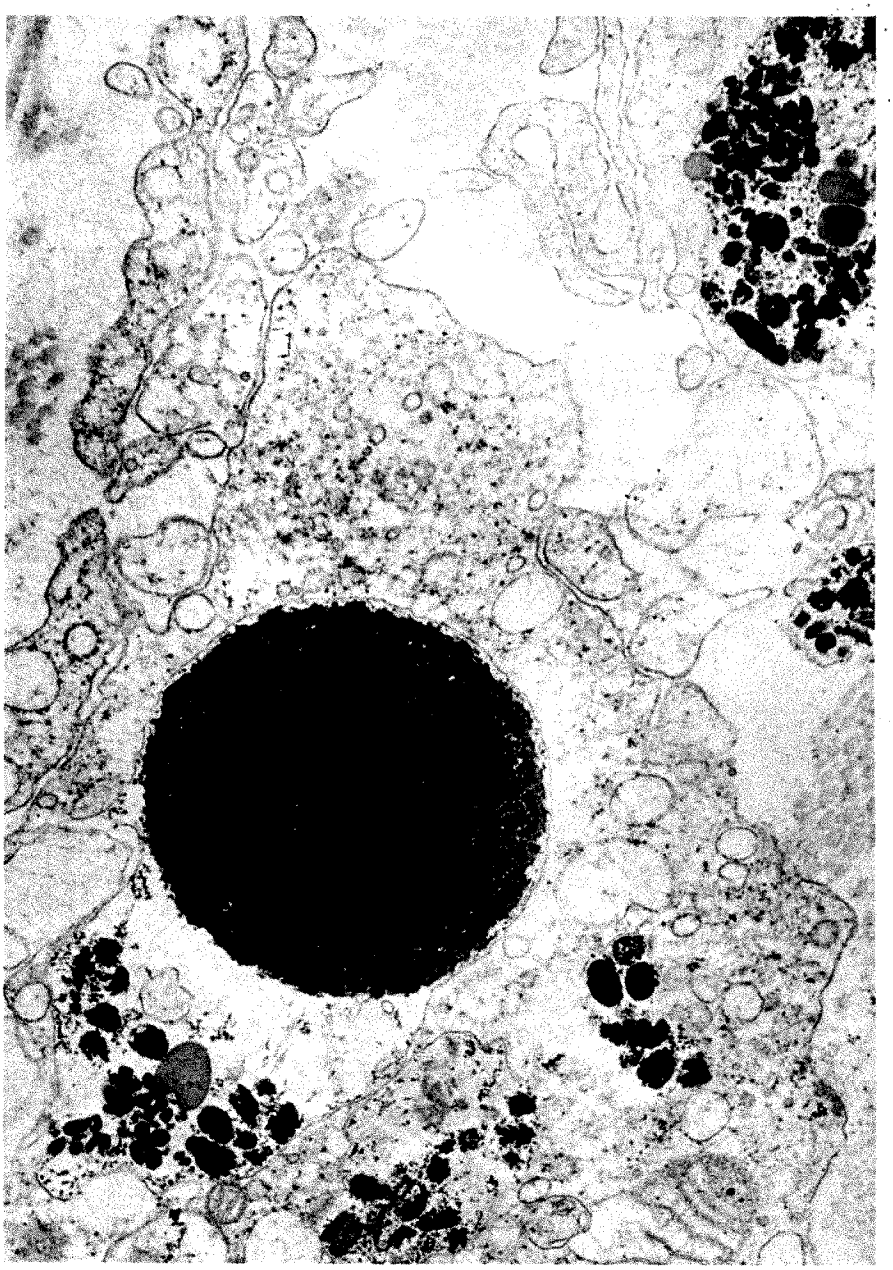

Fig 1.—Portion of dermal macrophage. Note giant melanosome, as well as numerous melanosome complexes comprised of normal melanosomes (original magnification ×27,000).

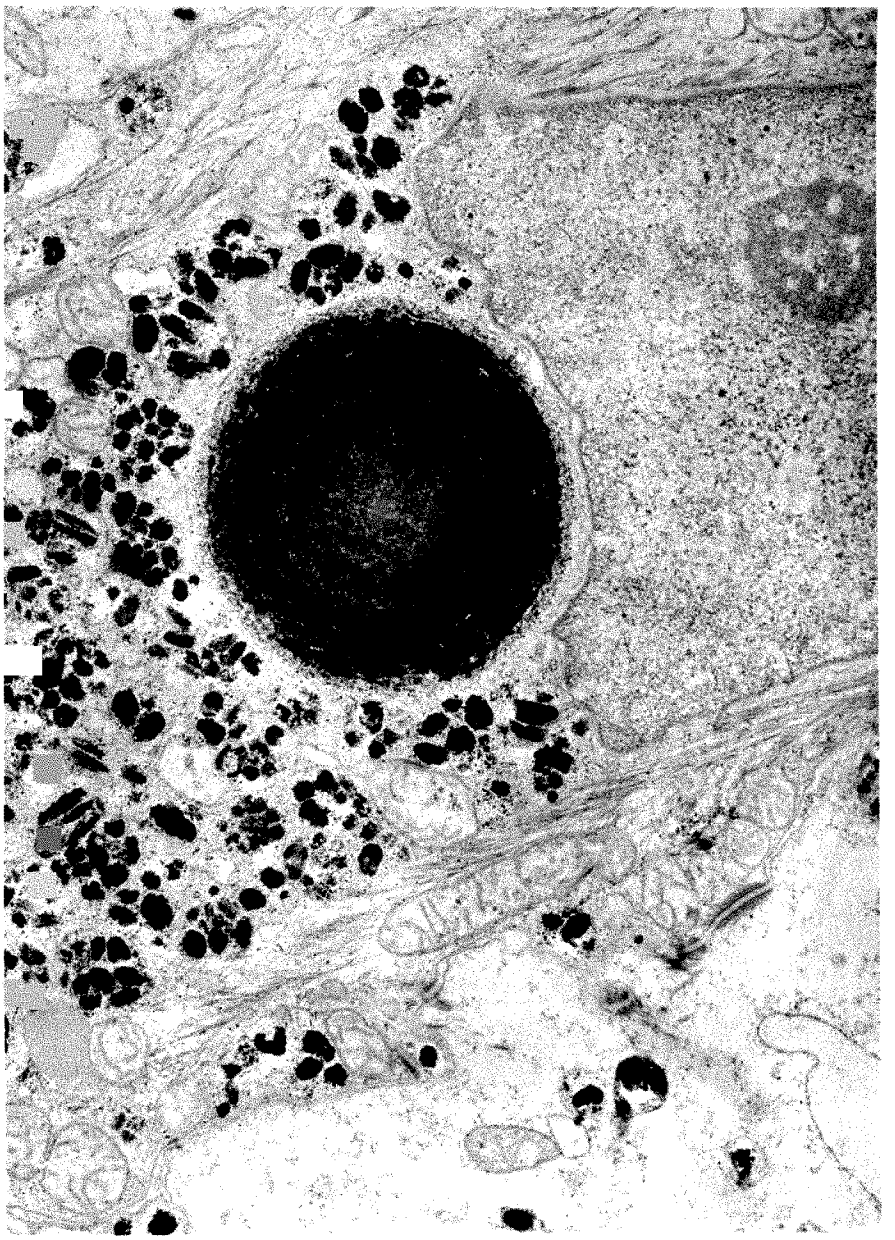

Fig 2.—This basal cell contains many normal melanosome complexes and one giant melanosome in which numerous vesicles, as well as concentric layers of varying electron density, are visible (original magnification ×17,400).

HISTOPATHOLOGIC FINDINGS

Punch biopsy specimens of normal skin and pigmented macules of the abdominal area were obtained for light and electron microscopical studies. The tissue for light microscopy was fixed in a 3.7% formaldehyde solution and was embedded in paraffin, and the sections were stained with hematoxylin-eosin. Specimens for electron microscopy were fixed in glutaraldehyde, postfixed in osmium tetroxide, and embedded in Spurr,[5] and the thin sections were stained with uranyl acetate and lead citrate.

Light microscopical studies showed proliferation of the epidermal rete ridges and an increased number of epidermal melanocytes. The basal layer contained large amounts of pigment, and giant melanosomes were present in focal areas throughout the epidermis, including the stratum corneum. A few giant melanosomes were also noted within dermal melanophages.

Ultrastructural studies also showed the presence of giant melanosomes within melanocytes and keratinocytes in the lowermost layers of the stratum corneum and in dermal melanophages (Fig 1). Numerous normal melanosomes were present principally within the melanocytes and basal cells. The normal melanosomes were generally aggregated into melanosome complexes within keratinocytes, whereas the giant melanosomes were singly dispersed, and there was rarely more than one giant melanosome within the same keratinocyte (Fig 2 and 3).

The giant melanosomes measured up to 5 μ in diameter and often indented the keratinocyte nucleus. These melanosomes were membrane-limited. At times the membrane was partially disrupted. Giant melanosomes within the stratum corneum often distended the cell cytoplasm, and no limiting unit membrane was observed (Fig 4).

Most of the giant melanosomes were spherical, and the internal structure was characterized by a dense central core of uniform electron density (Fig 3). Peripheral to the central core, there were more irregular electron-dense deposits and numerous electron lucent puncta that were

arranged in concentric layers. In the region just inside the limiting membrane, less electron-dense material was present, and the puncta were more easily visualized. Even in the fully melanized giant melanosomes that were present in keratinocytes, puncta were still visible in the outermost coritcal area of the granule. The filamentous substructure present in normal melanosomes was notably absent within the giant melanosomes, and no evidence of fusion of vesicles with giant melanosomes within the melanocytes was observed. The peripheral portions of giant melanosomes within the stratum corneum had some fragmentation, suggesting degradation.

COMMENT

Multiple lentigines syndrome is characterized by a variety of abnormalities and an autosomal dominant hereditary pattern of inheritance. The mnemonic "leopard syndrome" is often used to characterize many of the known abnormalities: lentigines, ECG conduction abnormalities, ocular hypertelorism, pulmonary stenosis, abnormalities of genitalia, retardation of growth, and deafness of the sensorineural type.[6] Our patient had all of these except pulmonary stenosis.

Ultrastructural studies of skin in patients with multiple lentigines syndrome have shown the presence of extensive normal melanosome complexes, but not the presence of giant melanosomes.[7] Recently published ultrastructural studies have shown that giant melanosomes are present in the pigmented or café au lait macules of neurofibromatosis[1,2] and in nevus spilus.[3,4]

At the light microscopical level, the giant melanosomes have been observed in keratinocytes and melanocytes in the normal skin of patients with neurofibromatosis, as well as in the pigmented macules.[8] They are rarely present in Albright syndrome[8] and in the nevus spilus.[3,4]

Ultrastructural studies indicate that the giant melanosomes are inherently electron dense and can be visualized without heavy metal staining or osmium tetroxide fixation (special stains were not used in our study).[2]

Fig 3.—Giant melanosome within this keratinocyte displays characteristic dense central core and concentric peripheral area in which melanization is incomplete (original magnification ×22,000).

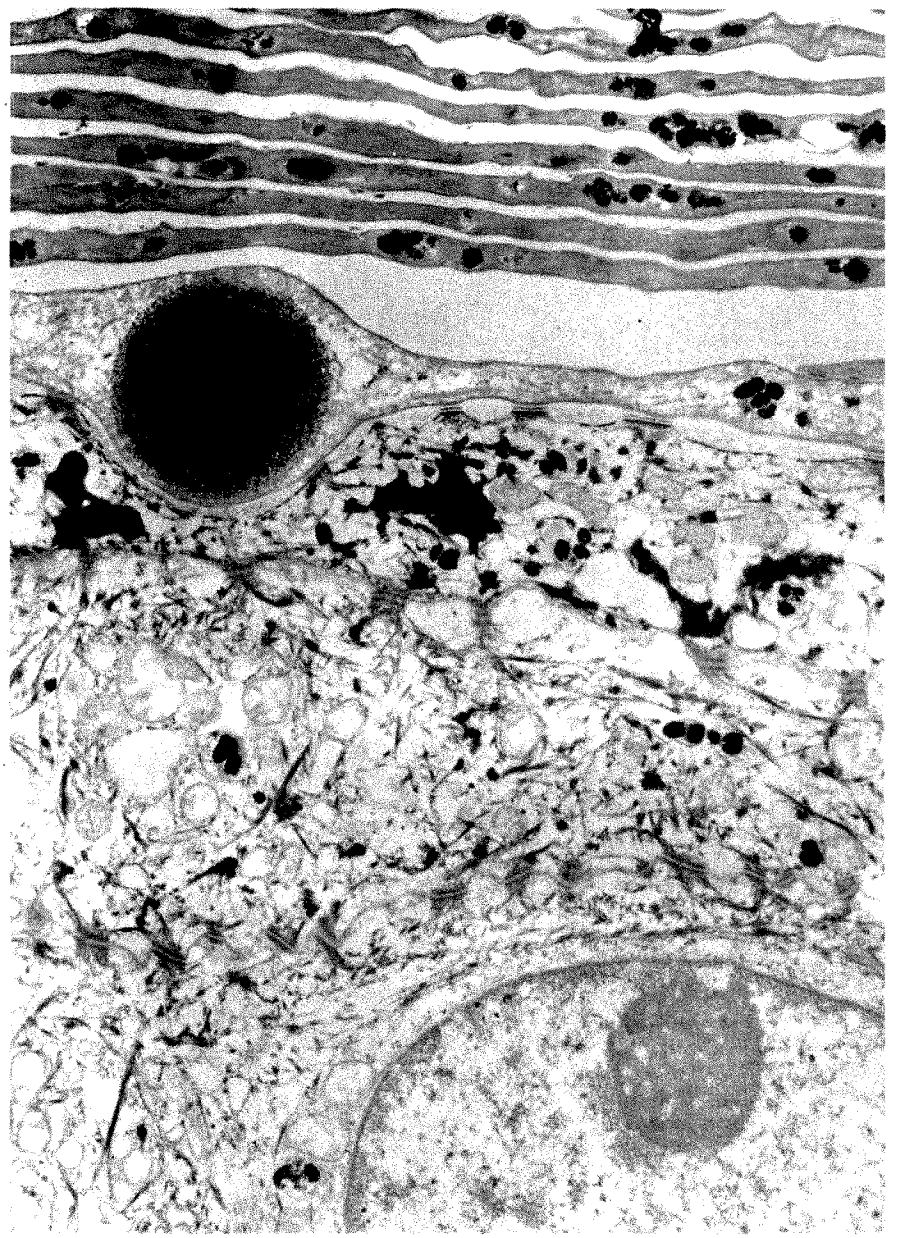

Fig 4.—Lowermost cell within stratum corneum contains giant melanosome that distends cell. Many normal melanosomes are also present within stratum corneum. Note absence of limiting membrane surrounding giant melanosome (original magnification ×13,600).

These melanosomes are also tyrosinase-positive after eight or more hours of incubation, but lack acid phosphatase activity.[3] Giant melanosomes may be classified as such in that they seem to be formed within melanocytes and exhibit tyrosinase activity, although the size as well as the vesicular rather than filamentous substructure do not agree with the classical features of normal melanosomes. Melanosomes in pigmented hair bulbs also demonstrate puncta similar to those in giant melanosomes, thus providing evidence for a further relationship.[3,9] The mode of giant melanosome formation remains elusive, but it has been suggested that a reasonable possibility may be by fusion of cytoplasmic vesicles that have been observed in the vicinity of giant melanosomes. However, such actual fusion has not been observed.[3]

The peripheral fragmentation and, at times, lack of limiting membrane surrounding giant melanosomes in the stratum corneum suggests that some degradation does occur. The individual dispersion of giant melanosomes is in agreement with previous studies, indicating that even normal melanosomes of a larger size tend to be singly dispersed.[10] It has been suggested that giant melanosomes form as a result of deranged morphogenesis, perhaps at the stage preceding the assembly of melanosomal filaments in which microvesicles may be involved.[3] Careful searches of specimens from various pigmentary conditions need to be made, now that there is increased awareness of the presence of giant melanosomes, so that new clues for their formation may possibly be uncovered.

References

1. Jimbow K, Szabo G, Fitzpatrick TB: Macromelanosomes in café-au-lait spots of neurofibromatosis. *J Invest Dermatol* 60:241-242, 1973.

2. Jimbow K, Szabo G, Fitzpatrick TB, et al: Ultrastructure of giant pigment granules (macromelanosomes) in the cutaneous pigmented macules of neurofibromatosis. *J Invest Dermatol* 61:300-309, 1973.

3. Konrad K, Wolff K, Honigsmann H: The giant melansomes: A model of deranged melanosome-morphogenesis. *J Ultrastruct Res* 48:102-123, 1974.

4. Konrad K, Wolff K: Giant melanosomes, in Program of European Society for Dermatological Research. Amsterdam, April 25-26, 1973, #8, p 6.

5. Spurr AR: A low-viscosity epoxy resin embedding medium for electron microscopy. *J Ultrastruct Res* 26:31-43, 1969.

6. Gorlin RJ, Anderson RC, Blaw M: Multiple lentigines syndrome. *Am J Dis Child* 117:652-662, 1969.

7. Nordlund JJ, Lerner AB, Braverman IM, et al: The multiple lentigines syndrome. *Arch Dermatol* 107:259-261, 1973.

8. Benedict PH, Szabo G, Fitzpatrick TB, et al: Melanotic macules in Albright's syndrome and in neurofibromatosis. *JAMA* 205:618-626, 1968.

9. Mottaz JH, Zelickson AS: in Montagna W, Dobson RL (eds): *Hair Growth*. Oxford, England, Pergamon Press, 1969, p 471.

10. Konrad K, Wolff K: Hyperpigmentation, melanosome size, and distribution patterns of melanosomes. *Arch Dermatol* 107:853-860, 1973.

Depressed Immune Function in Epidermodysplasia Verruciformis

Steven E. Prawer, MD; Franklin Pass, MD; James C. Vance, MD;
Leonard J. Greenberg, PhD; Edmond J. Yunis, MD; Alvin S. Zelickson, MD

• **Epidermodysplasia verruciformis (EV) is a rare disease characterized by the early onset and unremitting progression of wart-like lesions and frequent association of cutaneous carcinomas. We report two siblings with EV. Immunologic study of both patients demonstrated normal immunoglobulin levels, normal numbers of T-lymphocytes and B-lymphocytes, but markedly depressed in vitro blastogenic reactivity to mitogens and antigens. Cutaneous anergy to a variety of common skin test antigens was noted. These observations may reflect an inherited abnormality in immune function, or the depressed immune function may result from the viral infection of EV.**

(*Arch Dermatol* 113:495-499, 1977)

Epidermodysplasia verruciformis (EV) is a rare disease characterized by multiple wart-like tumors beginning in early childhood.[1] The wart-like tumors resemble flat warts both clinically and histologically, and virus particles have been observed repeatedly in electron microscopic specimens.[2] Warty lesions persist throughout life and are often associated with epithelial carcinomas in early adult life.[3] The disease often occurs in several members of a family, so EV has been classified as a genodermatosis.

We wish to report two siblings with characteristic EV. Both patients displayed depressed immune function as indicated by anergy to multiple skin tests and depressed blastogenic reactivity in vitro. This may represent an inherited defect in immune function, which predisposed the patients to widespread cutaneous viral infection and viral carcinogenesis, or conversely, the widespread viral infection caused a depression of their immune function.

REPORT OF CASES

Case 1.—A 43-year-old woman was first seen in March 1975, for evaluation. Before age 10, she began to develop wart-like lesions over the dorsum of her hands, and over the years, many similar lesions appeared elsewhere. In 1974, a squamous cell carcinoma was excised from her right cheek. In March 1975, lesions removed from her left wrist and right second finger showed varying degrees of irregular epithelial growth and dyskeratosis compatible with an actinic keratosis and squamous cell carcinoma in situ. The patient was in otherwise good health.

Examination showed many discrete and some confluent papular lesions which resembled warts. Individual lesions were grey to tan, slightly elevated, and ranged from several millimeters to 1 cm in diameter (Fig 1). Lesions occurred in a generalized distribution, but the dorsum of her hands, the extensor surfaces of her forearms, the area around her knees, and her neck were most heavily involved. Many of the lesions were less raised and deeper tan with a wrinkled scale. Evidence of prior surgical procedures was noted. None of the lesions present showed ulceration or inflammation.

The patient's mother had died at age 49 after a prolonged hospitalization for pulmonary disease in 1953. Her medical records have been misplaced, but a report of her autopsy was located. It described multiple warts on her hands and arms and pulmonary nodules that contained yeast-like organisms. No identification of the organisms in the lungs nor biopsy of the skin lesions was recorded. The patient's father and one sibling were deceased. Three siblings including the female twin of case 2 were alive, well, and free of warts. The patient had four children and four grandchildren. One grandchild had several common warts on his fingers.

Case 2.—A 39-year-old male sibling of the patient in case 1 was first examined in April 1975. He recalled having wart-like lesions before the age of 9. He continually developed additional lesions, but no malignancy had occurred. His general health was good. He had not married and had no children.

Examination revealed multiple lesions over the dorsum of his hands, forearms, legs, and neck. Lesions on his hands resem-

Accepted for publication March 1, 1976.

From the Departments of Dermatology (Drs Prawer, Pass, Vance, and Zelickson) and Laboratory Medicine and Pathology (Drs Greenburg and Yunis), University of Minnesota Medical School, Minneapolis.

Reprint requests to Department of Dermatology, Box 98 Mayo, University of Minnesota Hospitals, Minneapolis, MN 55455 (Dr Pass).

Fig 1.—Wart-like lesions over dorsum of hand of patient 1.

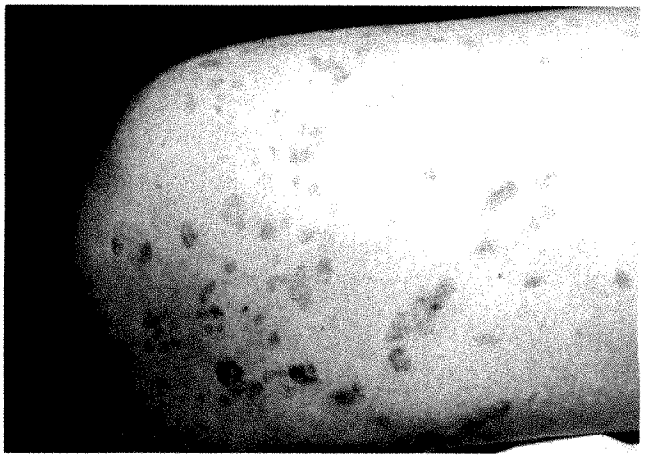

Fig 2.—Flat, broad lesions with wrinkled scale surrounding knee in patient 2.

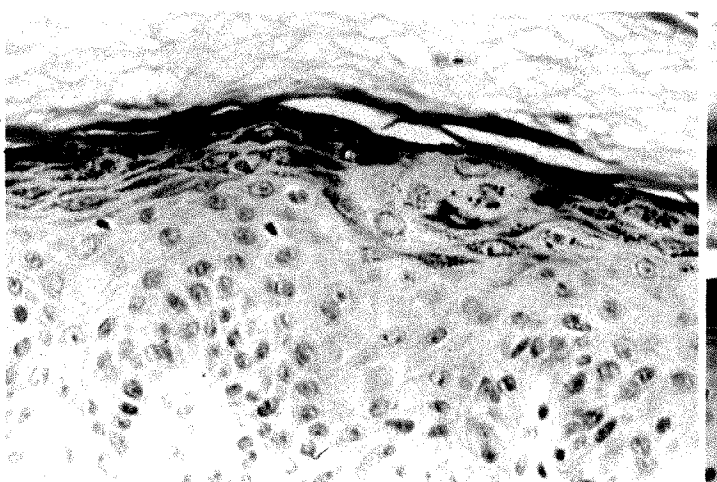

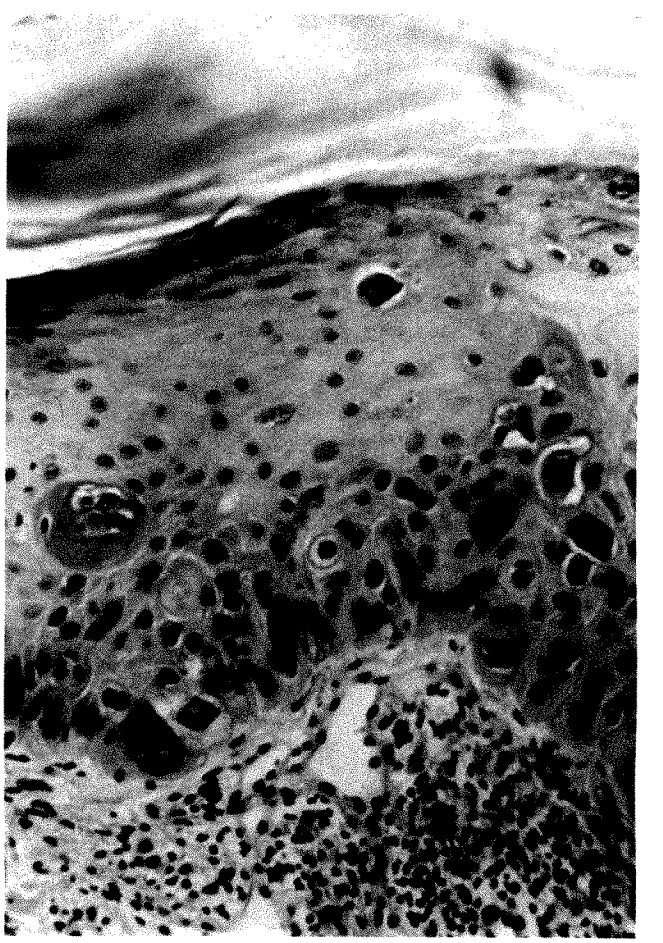

Fig 3.—Left, Stained section from wart-like lesion. Pale staining cells extend from stratum granulosum to midmalphigium (hematoxylin-eosin, original magnification ×400). Right, Stained section from carcinoma in situ. Pleomorphic cells with multiple nuclei, pyknotic nuclei, and prominent nucleoli present within epidermis. Dermis contains chronic inflammatory infiltrate (hematoxylin-eosin, original magnification ×400).

bled flat warts, but many of the lesions on his neck and knees seemed broader, less elevated, scaly, and pigmented (Fig 2). No evidence of malignancy was observed.

MATERIALS AND METHODS

Biopsies were performed on wart-like lesions from both patients. Specimens were embedded and sectioned for light microscopy in a routine fashion and stained with hematoxylin and eosin. Biopsy specimens taken of wart-like lesions from both patients were fixed in 2.5% gluteraldehyde, rinsed in sodium cacodylate buffer (pH 7.4), and postfixed in 1% buffered osmium tetroxide. Specimens were embedded in epoxy resin and stained with uranyl acetate and lead citrate. Sections prepared with an ultramicrotome (LBK) were examined with an electron microscope (RCA).

Venous blood was collected from the patients in sterile heparinized syringes. Blood was also collected from the 40-year-old sister of the patients, the 22-year-old daughter of patient 1, and three normal young adult men, who were to serve as reagent controls for in vitro studies. An

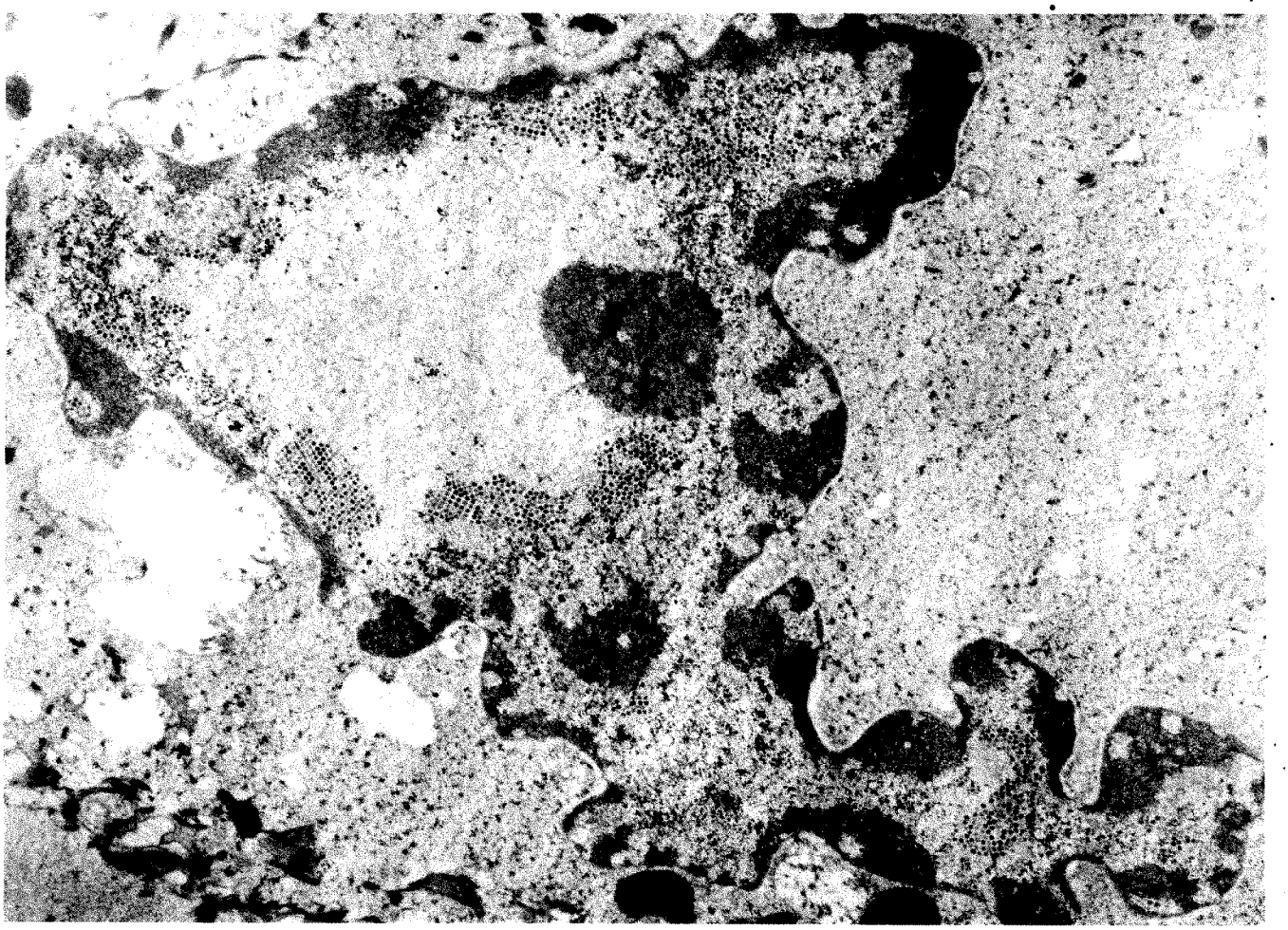

Fig 4.—Electron micrography showing crystalline arrangement of papovavirus virions within nucleus of keratinocyte at level of stratum granulosum (original magnification ×17,200).

aliquot of plasma was removed for determination of immunoglobulin levels by radial immunodiffusion. Lymphocytes were purified on Ficoll-Hypaque density gradients.[3] The T-lymphocyte populations were identified by a sheep red blood cell (SRBC) rosette assay.[4] Unsensitized SRBCs were incubated with lymphocytes for five minutes at 37 C, centrifuged at 200xg for three minutes, and further incubated at 4 C for one hour. The pellet was gently resuspended and the cells examined in a hemocytometer. Cells binding three or more SRBCs were counted as T-lymphocytes. An erythrocyte antibody complement (EAC) rosette assay was used to quantitate numbers of B-lymphocytes.[6] The SRBCs were incubated with antibody (E hemolysin) and complement (B10 D2 mouse serum) before mixing with the lymphocytes. The B-cell rosettes were counted as in the T-lymphocyte assay.

The response of purified lymphocytes to multiple dilutions of mitogens, a crude preparation of phytohemagglutinin (PHA-M), a highly purified PHA-HA17, and conconavalin-A (CON-A) was determined by incubating triplicate aliquots of 10^5 lymphocytes in plastic culture plates at 37 C in a humidified atmosphere with 5% CO_2. After 67 hours, 50 μl of tritiated thymidine (1 μCi/ml) was added. The plates were incubated an additional 24 hours, harvested, and assayed for radioactivity. Response to multiple concentrations of streptokinase-streptodornase (SK/SD) was assayed as previously described.[7] Three normal control individuals were studied simultaneously with the patients. The stimulating and responding potential of the patients' lymphocytes was determined in mixed lymphocyte cultures (MLC).[8] Unidirectional reactivity was achieved by prior treatment of stimulator cells with mitomycin.

The patients were skin tested to a variety of antigens. Intracutaneous tests were performed using *Candida* antigen, purified protein derivative–intermediate strength, histoplasmi, coccidiodin, trichophytin, and SK/SD. Epicutaneous tests to 34 common contact allergens employed a standardized screening try. Skin tests were read at 48 hours.

RESULTS

All histologic specimens examined by light microscopy were essentially identical in appearance. The stratum corneum was thickened in a basket-weave pattern. There were focal areas of thickened stratum granulosum containing enlarged cells with glassy, pale-staining cytoplasm and large empty nuclei. Clusters of these cells extend deep into the stratum malphigium (Fig 3, left). The epidermis was only slightly thickened, and the basal cell layer was not altered.

Specimens obtained from surgery performed on patient 1 in March 1975, were reviewed. The lesion removed from the left wrist showed moderate

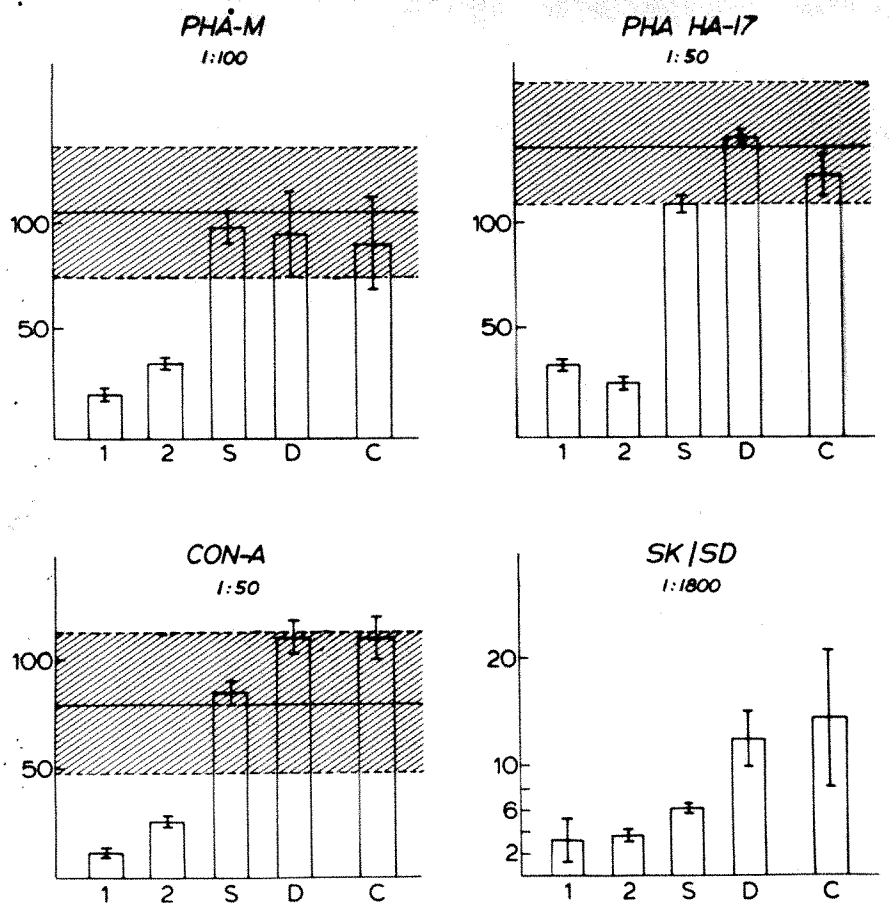

Fig 5.—In vitro responses to mitogens and SK/SD. Bar graphs represent tritium uptake of triplicate cultures for each patient (1 and 2), a sister (S), the daughter of patient 1 (D), and nine cultures from three normal controls (C). Data expressed as counts per minute × 10^{-3} with one standard deviation. Shaded area plots the mean and standard deviation of 300 normal individuals tested in same laboratory.

dysplastic changes; the epidermis was thickened, and the cells of the stratum malphigium were in a disorganized pattern. The underlying dermis contained a chronic inflammatory infiltrate. A lesion removed from the right second finger was a squamous cell carcinoma in situ; the epidermis was thickened and irregular, and the squamous cells were pleomorphic with basophilic cytoplasm and multiple large nuclei with prominent nucleoli. Individual cell keratinization and mitoses were noted. The basal cell layer was intact, and the dermis contained an inflammatory infiltrate with plasma cells and lymphocytes (Fig 3, right). Epidermal keratinocytes in the region of the stratum granulosum contained virions packed in a crystalline arrangement at the periphery of the nuclei. Virions displayed the capsid structure characteristic of papova viruses (Fig 4).

The patients had normal levels of plasma immunoglobulins. Values for case 1 in units of milligrams per 100 ml were as follows: IgA, 280; IgG, 1,700; IgM, 58; and IgE, 131. The corresponding values for case 2 were 468, 1,770, 58, and 418 mg/100 ml. Both patients had normal percentages of T-lymphocytes and B-lymphocytes as determined by the rosette assays; case 1 had 70% to 78% T-rosettes and 6% B-rosettes, and case 2 had 64% to 74% T-rosettes and 8.5% B-rosettes. Because WBC counts were normal, these figures also reflected normal absolute numbers of lymphocytes. Stimulation and response in MLC was within the normal range. Optimal blastogenic concentrations of mitogens and antigens were identical in the two patients, one sister, a daughter, and three control individuals. The data in Fig 5 reflect dilutions of PHA-M 1:100, PHA HA-17 1:50, CON-A 1:50, and SK/SD 1:1800. The graphs are expressed as the mean counts per minute (cpm) of triplicate cultures for the patients and relatives and the means of nine cultures from the three control individuals. The means and one standard deviation are plotted against a background of data obtained from the study of 300 normal adults in the same laboratory. These data represent normal mitogen responses through the seventh decade of life.[9] The blastogenic responses to mitogens of the patients' relatives and the three normal individuals run simultaneously as reagent controls agree with the normal laboratory values of the assays, but both patients are markedly depressed with 20% to 25% of normal function. Statistical analysis of each mean mitogen response results in a value of $P < .01$. Response to SK/SD antigens cannot be compared in the same fashion to a control population, because the response is under genetic control.[7] However, the patients show a much lower response to SK/SD than their relatives or the reagent controls. All intracutaneous and epicutaneous tests performed on the patients were negative. The only cutaneous reaction was that of patient 1, who develped 0.5 cm of erythema and induration to trichophyton.

COMMENT

Epidermodysplasia verruciformis was first described by Lewandowsky and Lutz in 1922.[10] Although the disease is very rare, in recent years several groups of investigators have been able to study small numbers of patients. The results of these investigators include the electron microscopic demonstration of virions by Ruiter and van Mullen,[2] autoinoculation and heteroinoculation experiments by Jablonska and Formas,[11] and the study of thymidine and uridine incorporation in the warty and carcinomatous lesions.[12,13] Several investigators have been intrigued by the presence of virions in wart-like lesions and precancerous keratoses but not in the carcinomas.[14,15] These reports have not explored the role of immunity in the pathogenesis of EV.

We report two siblings with EV. The appearance of many of their skin lesions was identical to that of large, flat warts or common warts, but both patients had flatter, more pigmented lesions with adherent and wrinkled scales. The latter lesions seem particularly characteristic of EV. The histologic appearance of the wart-like and flatter lesions was identical. Like warts, the pathologic changes appeared in foci at the stratum granulosum, but rather than profound vacuolation, the involved cells were enlarged with glassy cytoplasm and empty nuclei. The involvement extended deep into the stratum malphigium. These subtle clinical and histologic differences seem to place EV apart from patients with extensive, disseminated warts. Also, the recorded familial association and the appearance of carcinomas in patient 1 support the diagnosis of EV.

The wart-like lesions were packed with a crystalline array of papovavirus virions at the periphery of nuclei within the stratum granulosum. The malignant lesions were not available for electron microscopic study, so we could not show that the carcinomas arose from wart-like lesions. However, other investigators have observed virions in premalignant lesions,[14] and this supports the concept of viral carcinogenesis in EV. The clinical association of warts leading to carcinoma is similar to that of rabbits, where Shope papilloma virus is oncogenic in nonregressor rabbits.[16] The EV patient in a sense is a nonregressor human.

We have measured depressed mitogen and antigen responses in both patients. The patients had normal numbers of T-lymphocytes and B-lymphocytes and normal serum immunoglobulin levels. Mixed lymphocyte cultures measure function of a small subset of lymphocytes, and this function appeared intact. However, neither patient's lymphocytes reacted adequately to plant mitogens or SK/SD antigens, and the patients had cutaneous anergy to a variety of test antigens.

Depressed immune function in these patients with EV may indicate an inherited defect in an immune response gene. This defect must differ from patients with primary immunodeficiency states, who in addition, have lower numbers of T-lymphocytes and an increased susceptibility to a variety of viral and fungal diseases. The EV patients had the childhood viral diseases without complications. Could then the alteration of immune function have resulted from an extensive viral infection? Depressed T-lymphocyte function occurs transiently following infection with certain viruses,[17] and may accompany chronic diseases, eg, sarcoid or lymphoma. If the depressed immune function resulted from viral infection, it cannot account for the infection but could explain the susceptibility to viral carcinogenesis. In this situation, the EV patients would be analogous to patients treated with immunosuppressive therapy, who are at increased risk in regard to tumor formation. The questions raised by our observations cannot be answered from studies of these patients alone. It will be necessary to compare additional cases of EV and follow the immune factors of uninvolved family members.

A final consideration is the identity of the virus involved in EV and its relationship to the immunologically compromised host. Yabe and Sadakane[18] presented evidence for the presence of human papilloma virus (HPV) in EV lesions using antisera prepared to HPV. Virions isolated from EV lesions were not examined or used for antisera. The recent descriptions of small human papovaviruses isolated from immunosuppressed patients[19] and the oncogenic potential of the small viruses,[20] emphasize that more than one human papovavirus does exist, and more direct identification of EV virus is necessary. We have successfully isolated virions from case 1 and plan further experiments to identify the virus involved.

This investigation was supported by Public Health Service grant CA15955 and contract CB43853 from the National Cancer Institute, and training grant T01-AM05560.

Nonproprietary Name and Trademarks of Drug

Mitomycin—*Mitocin C, Mutamycin.*

References

1. Waisman M: Epidermodysplasia verruciformis: A retrospective glance and current appraisal. *Cutis* 16:627-632, 1975.

2. Ruiter M, van Mullen PJ: Demonstration by electron microscopy of an intranuclear virus in epidermodysplasia verruciformis. *J Invest Dermatol* 47:247-252, 1966.

3. Aaronson CM, Lutzner MA: Epidermodysplasia verruciformis and epidermoid carcinoma. *JAMA* 201:775-777, 1967.

4. Fleisher TA, Luckasen JR, Sabad A, et al: T and B lymphocyte subpopulations in children. *Pediatrics* 55:162-165, 1975.

5. Jondal M, Holm G, Wigzell H: Surface markers on human T and B lymphocytes: I. A large population of lymphocytes forming nonimmune rosettes with sheep red blood cells. *J Exp Med* 136:207-215, 1972.

6. Shevach EM, Heberman R, Frank MM, et al: Receptors for complement and immunoglobulin on human leukemia cells and human lymphoblastoid cell lines. *J Clin Invest* 51:1933-1938, 1972.

7. Greenberg LJ, Gray ED, Yunis EJ: Association of HL-A5 and immune responsiveness in vitro to streptococcal antigens. *J Exp Med* 141:935-943, 1975.

8. Greenberg LJ, Reinsmoen N, Yunis EJ: Dissociation of stimulation (MLR-S) and response (MLR-R) in mixed leukocyte culture by serum blocking factors. *Transplantation* 16:520-522, 1973.

9. Hallgren HM, Buckley CE III, Gelbertsen VA, et al: Lymphocyte phytohemagglutinin responsiveness, immunoglobulins and auto antibodies in aging humans. *J Immunol* 111:1101-1107, 1973.

10. Lewandowsky F, Lutz W: Ein fall einer bisher nicht beschriebenen hauterkrankung (epidermodysplasia verruciformis). *Arch Dermatol Syph* 141:193-203, 1922.

11. Jablonska S, Formas I: Weitere positive ergelnisse mit auto-und heteroinokulation bei epidermodysplasia verruciformis Lewandowsky-Lutz. *Dermatologica* 118:86-93, 1959.

12. Grupper C, Prunieras M, Delescluse C, et al: Epidermodysplasia verruciformis: Etude ultrastructurale et autoradiographique. *Ann Dermatol Syphiligr* (Paris) 98:33-48, 1971.

13. Delescluse C, Regnier M, Prunieras M: Epidermodysplasia verruciformis: II. Uridine incorporation. *Arch Dermatol Forsch* 247:89-97, 1973.

14. Ruiter M, van-Mullen PJ: Behavior of virus in malignant degeneration of skin lesions in epidermodysplasia verruciformis. *J Invest Dermatol* 54:324-331, 1970.

15. Delescluse C, Prunieras M, Regnier M, et al: Epidermodysplasia verruciformis: I. Electron microscope autoradiography and tissue culture studies. *Arch Dermatol Forsch* 242:202-215, 1972.

16. Rous P, Beard JW: Carcinomatous changes in virus-induced papillomas of the skin of the rabbit. *Proc Soc Exp Biol Med* 32:578-580, 1935.

17. Notkins AL, Mergenhagen SE, Howard RJ: Effect of virus infections on the function of the immune system. *Ann Rev Microbiol* 24:525-538, 1970.

18. Yabe Y, Sadakane H: The virus of epidermodysplasia verruciformis: Electron microscopic and fluorescent antibody studies. *J Invest Dermatol* 65:324-330, 1975.

19. Gardner SD, Field AM, Coleman DV, et al: New human papovavirus (B.K.) isolated from urine after renal transplantation. *Lancet* 1:1253-1257, 1971.

20. Shah KV, Daniel RW, Strandberg JD: Sarcoma in a hamster inoculated with BK virus, a human papovavirus. *J Natl Cancer Inst* 54:945-949, 1975.

Eruptive Vellus Hair Cysts

Nancy B. Esterly, MD; David F. Fretzin, MD; Hermann Pinkus, MD

• **Two children had a hyperpigmented monomorphous papular eruption of several years' duration. Biopsy specimens demonstrated cysts in the middle dermis that contained multiple fragmented vellus hair shafts. The eruption in one child involuted spontaneously. The cause of these lesions is obscure. The term eruptive vellus hair cysts is proposed for this entity.**

(*Arch Dermatol* 113:500-503, 1977)

Noninfectious, asymptomatic, and persistent papular eruptions are relatively uncommon in young children. The differential diagnosis includes diseases characterized by perforating lesions, as well as nevi and hamartomas involving adnexal structures. Histologic studies are often required for definitive diagnosis of these disorders. A few chronic papular eruptions that do occur with reasonable frequency in the pediatric age group, such as milia, keratosis pilaris, and granuloma annulare, are usually recognizable by their clinical morphology alone.

We recently encountered two children with a papular eruption that was atypical in clinical appearance and distribution for the common cutaneous disorders. On histologic examination, these lesions were found to be an unusual cystic alteration of the hair follicle.

Accepted for publication March 9, 1976.

From the Division of Pediatric Dermatology, Department of Pediatrics (Dr Esterly), and Division of Dermatology, Departments of Medicine and Pathology (Dr Fretzin), Michael Reese Hospital and Medical Center, Chicago; and the Department of Dermatology, Wayne State University School of Medicine, Detroit (Dr Pinkus).

Reprint requests to Department of Pediatrics, Michael Reese Hospital and Medical Center, 29th St and Ellis Ave, Chicago, IL 60616 (Dr Esterly).

REPORT OF CASES

CASE 1.—A 6-year-old girl was seen in the Pediatric Dermatology Clinic in May 1974, because of a papular eruption of approximately two years' duration. The lesions were first noted on the chest in the parasternal areas. Subsequently, additional lesions developed on the flexor surface of both forearms and in the popliteal fossa bilaterally. The papules were persistent, but asymptomatic, and never became infected or crusted. There was no evidence of antecedent trauma to the involved skin and, other than occasional applications of an emollient, (Lubriderm) no skin preparations were used. The family history was negative for skin disorders.

Her past medical history was of note in that she had numerous episodes of upper respiratory infection, tonsillitis, and otitis media, as well as two episodes of pneumonia during the first few years of life. At age 3 years, cardiomegaly was discovered on a routine chest film obtained for a preschool medical examination, and on the basis of abnormal ECG findings, a diagnosis of resolving viral myocarditis was made. During the past two years, she has enjoyed good health and attended school regularly.

Physical examination at the time of presentation was normal except for the cutaneous findings. Scattered over the flexor surface of the forearms were 30 to 50 discrete, red-brown, 1 to 2 mm, soft, smooth papules, only one of which had a hyperkeratotic crust (Fig 1 and 2). Similar lesions, numbering about 20, were grouped in each popliteal fossa. Another 30 or so less sharply demarcated 1 mm lesions were seen on the anterior chest wall. Two biopsies were obtained, one from the flexor surface of the forearm and another from the popliteal fossa (see below).

There was no resolution following application of various keratolytic agents and acne preparations. Peeling by daily use of salicylic acid in a propylene glycol gel (Keralyt) under occlusive wraps resulted in decreased prominence of the lesions, but was not felt to be of lasting benefit. During the first year of observation, none of the lesions regressed spontaneously, and occasionally new papules developed in involved areas. Suddenly, approximately 14 months after the first visit, the papules regressed spontaneously and disappeared completely on the chest and legs. When examined in August 1975, only a few papules were evident on the forearms.

Histopathological Findings.—Multiple hematoxylin-eosin sections were reviewed from two papules that revealed similar histopathologic findings. The overlying epidermis appeared minimally acanthotic. In the midcorium, there was a small cystic structure lined by squamous epithelium 3 to 7 cell layers thick that contained laminated keratinous material and vellus hairs presenting as multiple transverse or oblique sections. In some areas there was maturation of the squamous cells with the production of keratohyaline granules. In several adjacent sections, a ventral bulge composed of more basaloid cells extended from the cyst wall. However, serial sections in this area failed to demonstrate progres-

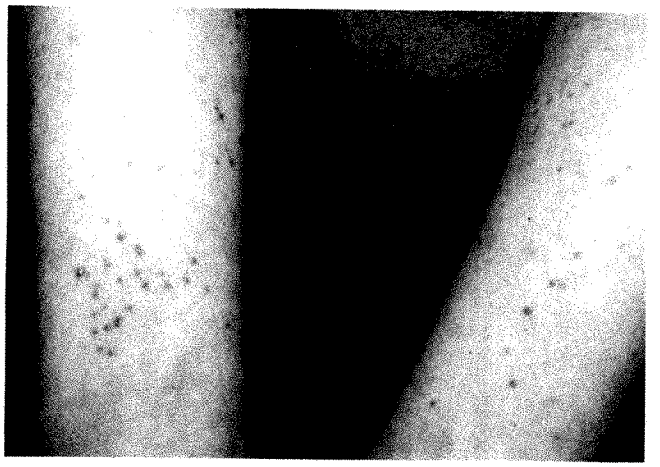

Fig 1.—Multiple hyperpigmented papules on flexor surface of forearms of patient 1.

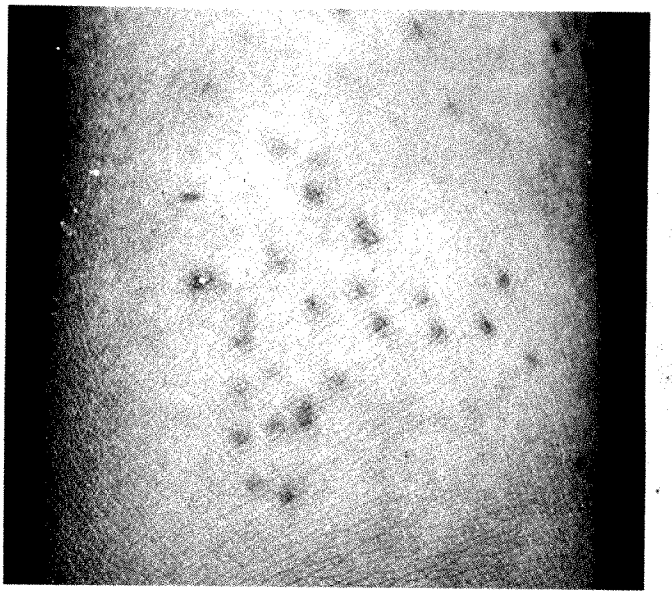

Fig 2.—Papules on forearm of patient 1. Normal markings are retained on overlying skin.

sion to a hair bulb, nor was an attachment to the overlying epidermis seen in either of the two specimens. A modest fibrous sheath, numerous supporting capillaries, and a sparse perivascular lymphocytic inflammatory cell reaction surrounded the keratin cyst (Fig 3 and 4).

Case 2.—A 7-year-old boy was referred to the Pediatric Dermatology Clinic in April 1975, because of a papular eruption on the anterior chest that had been present for approximately three years. It was first noticed by his mother during the summer months when he usually did not wear a shirt. The papules were asymptomatic and never became infected or hyperkeratotic. They gradually darkened during subsequent months, but it was unclear whether new lesions had continued to appear.

The patient was said to be in excellent health; he took no medications and used nothing but ordinary toilet soaps on his skin. The family history was negative for skin diseases.

Physical examination was completely normal except for the skin. There was a 3 cm, cafe au lait spot on the left-upper arm and another smaller lesion on the anterior chest. Over the central portion of the anterior thorax was an eruption consisting of about 50 dark brown, noninflammatory, 1 to 2 mm papules (Fig 5). Two of the papules were removed by punch biopsy for histologic examination. No therapy was instituted.

Histopathological Findings.—Serial hematoxylin-eosin sections were examined from each of two small papules removed from the anterior chest wall. Both specimens showed a small keratin-filled cyst in the middle dermis containing numerous transversely or obliquely cut portions of vellus hair. One cyst had a telogen hair bulb extending from the lower surface towards the subcutis.

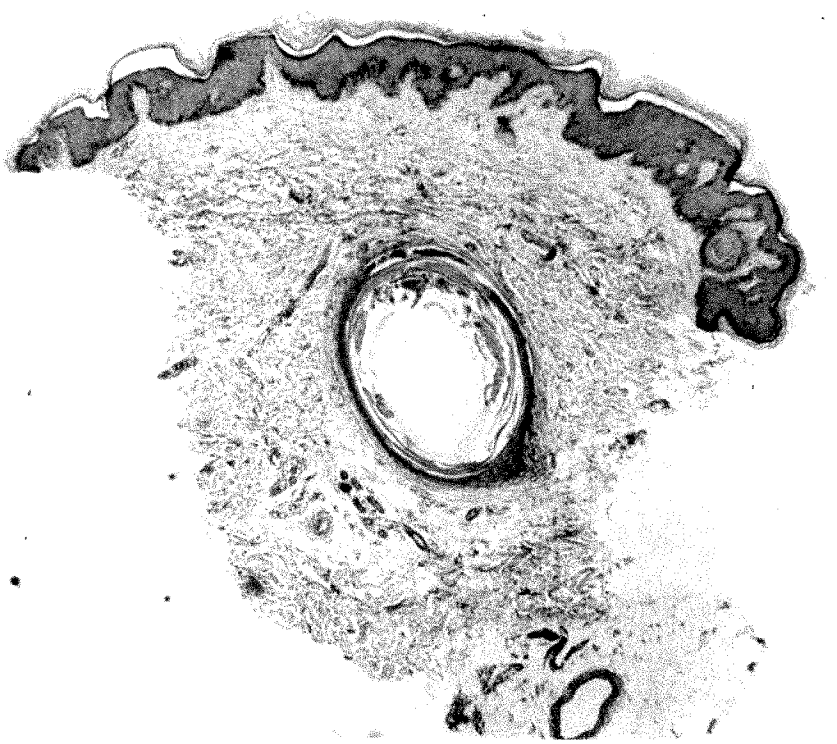

Fig 3.—Hair cyst in midcorium containing laminated keratinous material (hematoxylin-eosin, original magnification ×75).

There was also an epithelial invagination from the surface epidermis toward the hair cyst, although no definite connection was found in serial sections of this area. The cyst walls were composed of 5 to 12 layers of keratinizing epithelium with focal areas of a granular layer noted. A modest lymphocytic inflammatory reaction surrounded several small vessels adjacent to the cyst wall. The cyst was enclosed in a loose fibrous sheath (Fig 6).

COMMENT

The two children described in this report had a distinctive focal papular eruption that seemed unlike any

previously known disease. Despite the banal and asymptomatic nature of the lesions, the unusual distribution and monomorphous quality of the eruption in the first child prompted us to seek a histologic diagnosis. A pediatric resident who had seen this patient in the clinic then referred the second patient because of the striking similarity in the appearance of the lesions.

Although all of the perforating disorders might be considered in the differential diagnosis, vellus hair cysts differ clinically from other entities in many respects. They lack the central umbilication and keratotic plugs characteristic of perforating collagenosis.[1-5] In addition, since the lesions of perforating collagenosis are induced by trauma, a Koebner response can usually be identified, and sites of predilection are the dorsum of the hands, the forearms, and the knees. The lesions of perforating collagenosis disappear spontaneously after a course of a few weeks, and lesions in all stages of development usually can be identified. Perforating folliculitis[6] might be considered as well, however, these erythematous follicular papules predominate on the extremities and also contain a visible central keratotic plug. Kyrle disease,[7-8] rare in young children, consists of large follicular and parafollicular papules that aggregate to form plaques in involved areas. Elastosis perforans serpiginosa[9] is an eruption of annular, ovoid, or serpiginous configuration, often occurring in isolated anatomic sites. Milia are discrete and pearly in appearance and have a predilection for the face and sites of trauma.

The absence of inflammation made a diagnosis of bacterial folliculitis unlikely. The sites of involvement and clinical appearance of the lesions were incompatible with a diagnosis of keratosis pilaris. Although appendageal malformations were also considered, the lesions in these children did not resemble any known adnexal tumors.

The histological description of epithelial cysts of the skin can be readily found in standard dermatopathology textbooks. The distinguishing patho-

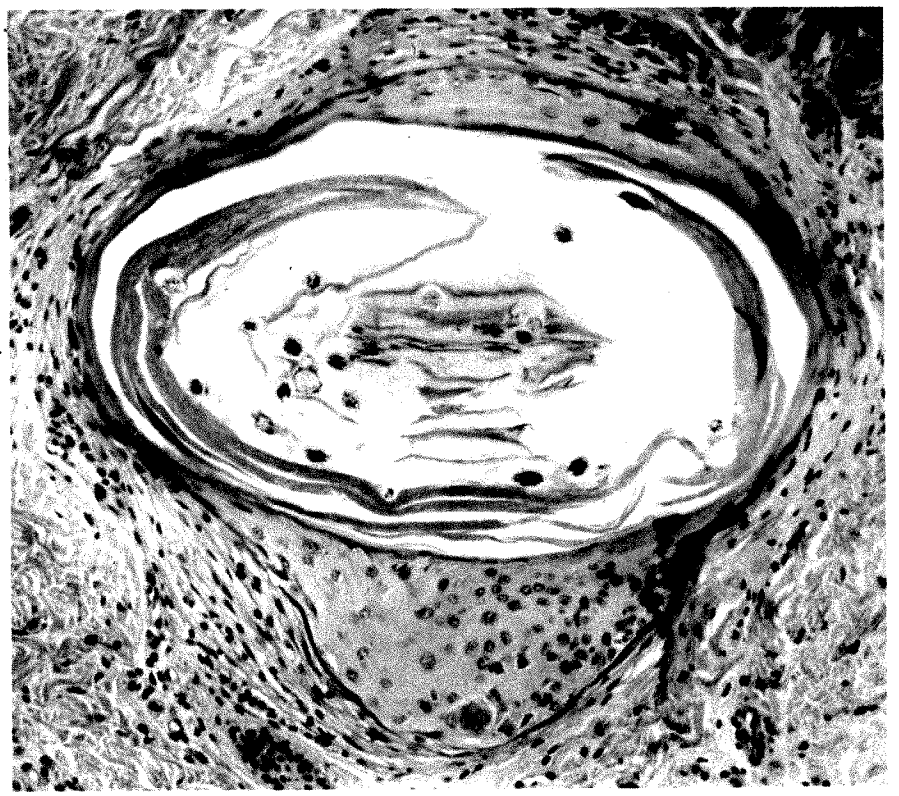

Fig 4.—Keratinous hair cyst lined by squamous epithelium and showing cut portions of hair shaft. Ventral bulge suggests follicle remnant (hematoxylin-eosin, original magnification ×375).

Fig 5.—Numerous hyperpigmented papules on anterior thorax of patient 2.

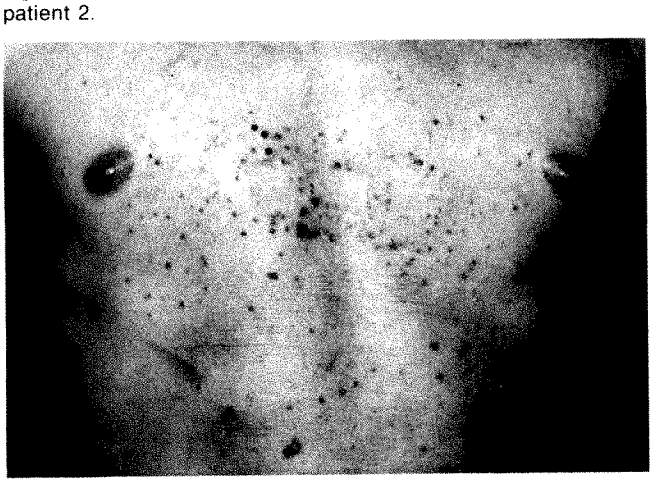

Fig 6.—Keratinous hair cyst in midcorium containing vellus hair cut transversely or obliquely in numerous places. Telogen hair follicle projects from its base (hematoxylin-eosin, original magnification ×100).

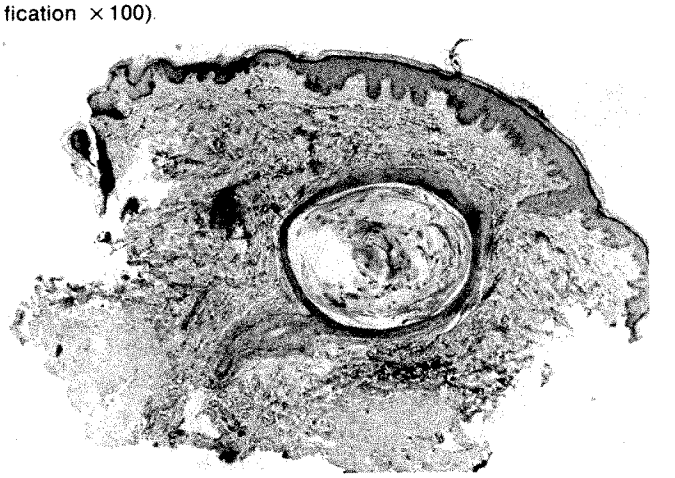

logical changes in our two patients appear to be the size and location of the cysts in the middle and deep dermis and the inclusion of vellus hair shafts (trichostasis). The presence of a true telogen hair bulb or an epithelial bulge extending from the proximal edge of the cyst in serially sectioned specimens identifies the lesion as arising in a true hair follicle. A definite attachment, however, to the superficial portion of a pilar complex could not be clearly substantiated. One may speculate that the pathogenetic development of the cyst is initiated by the loss of epidermal contact allowing for retention of keratinous material and hair shafts. Secondary hair bulb atrophy may be a consequence of this process.

Except for the uncommon dermoid cysts and steatocystoma multiplex, most of the ordinary keratinous cysts do not contain hairs. Additionally, the absence of sebaceous glands or other adnexal structures associated with the cyst wall in our patients clearly differentiated these lesions from the former variety of cysts. The possibility of the cysts being young dermoid cysts prior to the hyperplasia of sebaceous or adnexal structures is not likely, especially in view of their disappearance in one patient. The clinical and histological features readily allow differentiation from milia.

A reference from the early German literature[10] suggested the term "rollhaarcyst" for cystic lesions containing coiled hairs. However, the authors describe an acquired lesion in adults, probably due to traumatic obstruction of the follicle of a terminal hair on the abdomen.

The exact etiology of eruptive vellus hair cysts is obscure. We were unable to elicit a history of trauma, friction or occlusion of affected areas in either patient. The establishment of a hamartomatous origin for vellus hair cysts is difficult since clinical data indicate that the lesions are not present at birth or in infancy and because of their spontaneous involution in one of the two children.

Since this manuscript was submitted, two additional children have been seen with eruptive vellus hair cysts. The lesions of both were so characteristic that the correct diagnosis was made prior to biopsy. The first child, a 4-year-old girl, noted her lesions one week prior to the clinic visit. Date of onset was unknown in the second child, a 9-year-old boy, who was brought in by a new foster parent for routine physical examination. Papules were distributed on the flexor surfaces of the wrists, medial surfaces of the upper arms and thighs, popliteal fossae, and anterior chest.

The histopathological findings of a lesion from one of these patients was similar to our original cases. However, serial sections of a lesion from the second patient revealed several unique features (H.P.). There was a mid-dermal cyst with two separate pilar muscle attachments laterally and two rudimentary hair roots. Within the cyst were one or more rolled-up vellus hair shafts. At the upper pole, the cyst was connected to the surface epidermis. A keratotic plug devoid of hair occupied the follicular infundibulum. The following possible pathogenetic mechanisms can be suggested to explain the above findings: (1) a keratinous plug at the follicular infundibulum deflected the hair to the deeper part of the follicle causing cystic dilatation; (2) at least in one instance, two hair roots of a compound follicle united below the surface and had a common infundibulum; (3) there is gradual disruption of the connection between the proximal and distal follicle; and (4) an initially abnormal hair follicle is predisposed to these cystic changes.

Irene Goldberger provided technical assistance.

References

1. Mehregan AH, Schwartz OD, Livingood CS: Reactive perforating collagenosis. *Arch Dermatol* 96:277-282, 1967.

2. Weiner AL: Reactive perforating collagenosis. *Arch Dermatol* 102:540-544, 1970.

3. Bovermeyer DA: Reactive perforating collagenosis. *Arch Dermatol* 102:313-317, 1970.

4. Kanan MW: Familial reactive perforating collagenosis and intolerance to cold. *Br J Dermatol* 91:405-414, 1974.

5. Nair BKH, Sorojini PA, Basheer AM, et al: Reactive perforating collagenosis. *Br J Dermatol* 91:399-403, 1974.

6. Mehregan AH, Coskey RJ: Perforating folliculitis. *Arch Dermatol* 97:394-399, 1968.

7. Carter VH, Constantine VS: Kyrle's disease: I. Clinical findings in five cases and review of literature. *Arch Dermatol* 97:624-632, 1968.

8. Constantine VS, Carter VH: Kyrle's disease: II. Histopathologic findings in five cases and review of the literature. *Arch Dermatol* 97:633-639, 1968.

9. Mehregan AH: Elastosis perforans serpiginosa. *Arch Dermatol* 97:381-393, 1968.

10. Hoffmann E, Hochstetter B: Uber eine Rollhaarcyste des Menschen nebist Bemerkungen zum Schrotausschlag des Schweines. *Dermatol Zeitschrift* 20:857-890, 1913.

Laser Treatment of Extensive Mixed Cavernous and Port-Wine Stains

Leon Goldman, MD, Ronald Dreffer

• **An extensive, disfiguring, mixed nodular cavernous and port-wine stain of the face of an adult who had psoriasis and diabetes was treated with ruby and argon lasers for a period of seven years with substantial cosmetic improvement. There was no deep scarring, secondary granuloma telangiectatic reactions, or chronic radiation changes. Prolonged treatments were necessary because of the small size of the laser emission impact areas.**

(*Arch Dermatol* 113:504-505, 1977)

The port-wine stain has continued to offer a therapeutic challenge because of its intractable nature. The vascular component of the port-wine stain is an adult type of blood vessel and not the blastoma found in the cavernous type of angioma. The port-wine stain never disappears or rarely ever fades spontaneously. It is not responsive to x-ray radiation. Tattooing with pigments such as titanium dioxide or zinc oxide often gives a mottled grayish appearance. Port-wine stains in the eyelid cannot be tattooed. In the older adult, the port-wine stain may become pendulous as connective tissue changes develop. At

Accepted for publication March 17, 1976.

From the Laser Laboratory, Department of Dermatology, Medical Center, University of Cincinnati.

Reprint requests to Department of Dermatology, Medical Center, University of Cincinnati, Cincinnati, OH 45267 (Dr Goldman).

Fig 1.—Nodular mixed cavernous and port-wine stain before therapy, 1968.

Fig 2.—After repeated ruby and argon laser treatments for seven years.

this stage, plastic surgery may be of use.

In the mixed type of port-wine stain are superficial areas of the small port-wine-fixed capillary-type vessels plus deeper areas of large cavernous vessels. Unlike the primary cavernous angioma, this cavernous component does not subside spontaneously. The consequent nodular appearance does not lend itself well to covering preparations.

For more than 13 years port-wine stains have been treated with investigative laser surgery at the Laser Laboratory of the University of Cincinnati Medical Center. The laser was used because laser emissions in the range of visible light show greater absorption in pigmented masses. This includes melanin, so-called melanoid, hemoglobin, and oxyhemoglobin pigments. The ruby laser emissions of 694.3 nm are absorbed more in black pigment but with high enough energy densities, 70 to 90 joules/sq cm, these emissions are absorbed more in red than in white areas. In energy densities of 20 to 40 joules/sq cm there is but little absorption in red areas. As we indicate subsequently, the emissions of the argon laser are absorbed more in hemoglobin. Treatment with the pulsed ruby laser produces small 2.1-sq cm circular whitened areas in port-wine stains. The Q-switched ruby laser, nanosecond-pulsed, is not effective in the treatment of port-wine lesions, most likely because its emissions with such short pulses are mostly reflected by the red color of the stain.

Our early investigative studies have shown that the argon laser emission spectra, 488.0 to 514.5 nm, is effective in the treatment of port-wine stains. Its emissions are similar to the absorption spectra of hemoglobin. Often the narrow beam diameter makes this instrument impractical for the treatment of large areas, in spite of repetitive treatments. However, commercial models for the argon laser treatment of port-wine stains are available for dermatologic therapy. Also, the Nd-YAG laser is now being used experimentally in the same manner as the argon laser. Another type of irradiation under investigative study is high-output incoherent infrared.

The following case is reported to show the effect of the laser treatment for an extensive disfiguring mixed port-wine mark.

REPORT OF A CASE

A 54-year-old man had had this lesion ever since birth, with the nodularity of the surface becoming more marked in recent years. Electrocoagulation and cryosurgery had been tried without benefit. Examination showed an intense reddened nodular lesion occupying the entire right half of the forehead, extending into the scalp and involving the eyelid. There was no intraocular involvement (Fig 1).

For a period of seven years, repeated ruby laser treatments were given at intervals of three to four weeks to the entire area. The treatments were not painful and were given without anesthesia. Usually five to six impacts were given at each session. The energy density of each impact of the pulsed ruby laser was 55 to 75 joules/sq cm, 2.1-sq cm area, 2.0-m sec pulses. Argon laser treatments were given with power densities of 1 to 3 watts with beam diameter 1.5 to 3.5 mm. With special eye protection,[1-3] only the upper portion of the eyelids were treated.

The tissue reaction of the ruby laser was a coagulation necrosis of a circular area approximately 1.6 cm in diameter. This required about three weeks to heal.

Argon laser treatments were started Jan 23, 1975, repeated every other month, and have continued to the present, 20 to 30 impacts given at each session. These were small areas, 1.5 to 4.0 mm, 1.5 to 4.0 watts, 0.5 to 1.0 m sec.

RESULTS

After laser treatments, flattened areas of decreased color developed. It is evident that even with the current primitive instrumentation there has been significant improvement in this patient. The obvious difficulty is the small target areas produced and the need for higher output instrumentation with increased energy and power densities to provide for treatment of larger areas. With adequate protection there was no hazard to the eyes of the patient. To date, there has been no evidence of any recurrence in any area treated, even those areas affected seven years ago.

At present, the patient has flattened, reddened areas with occasional irregular whitish areas (Fig 2).

The port-wine mark on the eyelids can be treated if the patient desires. This can be done with the use of protective shields in the eyes, while the patient is under tetracaine hydrochloride (Pantocaine) anesthesia.[1-3]

References

1. Goldman L, Rockwell, RJ, Jr: *Lasers in Medicine*. New York, Gordon & Breach Science Publishers Inc, 1971.

2. Goldman L, Rockwell RJ Jr, Dreffer R, et al: Laser treatment of port-wine spots. Exhibited at the American Academy of Dermatology, Chicago, Dec 4-9, 1971.

3. Goldman L: *Applications of the Laser*. Cleveland, Chemical Rubber Co, 1973.

You don't have to ask your patients to sacrifice their skin to effectively treat their acne.



Use Persa-Gel.

A clinical test* shows Persa-Gel to be as effective as tretinoin cream in the lowering of the lesion count (pustules, papules and comedones), on unselected patients, **without** excessive erythema and peeling.

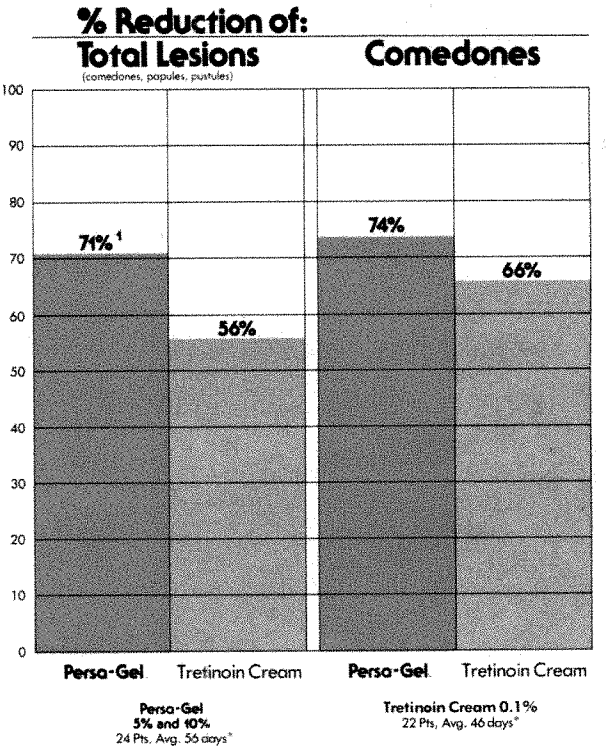

*Data on file, Texas Pharmacal Company.
See next page for full prescribing information.

Persa-Gel™

(BENZOYL PEROXIDE)

Unique Acetone Gel 5% and 10%

TEXAS PHARMACAL COMPANY
San Antonio, Texas 78296

Unique acetone base enhances stability and cosmetic acceptability.

Two and one-half year dating
No refrigeration required

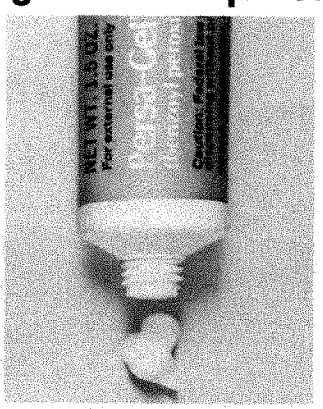

CAUTION: Federal law prohibits dispensing without prescription.
DESCRIPTION: Persa-Gel™ 5% contains 5% benzoyl peroxide; Persa-Gel™ 10% contains 10% benzoyl peroxide; in a gel base containing acetone, carboxyvinyl polymer, triethanolamine, sodium lauryl sulfate, propylene glycol and purified water.
ACTIONS: Benzoyl peroxide is primarily effective because of its drying, peeling and antiseptic action.
INDICATION: For adjunctive topical therapy of acne vulgaris.
CONTRAINDICATIONS: Benzoyl peroxide is contraindicated in patients with acute inflammation and in patients with a history of hypersensitivity to any of the components of the preparation.
PRECAUTIONS: If excessive irritation develops, discontinue use and institute appropriate therapy. After the reaction clears, treatment may often be resumed with less frequent applications. Avoid contact with eyes, eyelids, lips and other mucous membranes, and anterior neck. May bleach hair and colored fabrics.
ADVERSE REACTIONS: Allergic contact dermatitis and severe erythema with crusting have been reported with topical benzoyl peroxide.
DOSAGE AND ADMINISTRATION: Persa-Gel™ (benzoyl peroxide) should be applied thinly to cover affected area after cleansing with non-medicated soap and water or a degreaser. Initial application once daily before bedtime is recommended, increasing to twice daily as tolerance develops. Feelings of warmth and stinging and slight erythema may be noted initially. It is advisable to initiate therapy with Persa-Gel™ 5% shifting to the use of Persa-Gel™ 10% after 3 or 4 weeks, or earlier if tolerance to the 5% has been determined. Therapeutic results are usually seen within 2 weeks with continued improvement therafter.
HOW SUPPLIED: Persa-Gel™ 5% 1.5 oz. tubes
(NDC0064-8610-31)
Persa-Gel™ 10% 1.5 oz. tubes
(NDC0064-8600-31)

Persa-Gel™
(BENZOYL PEROXIDE)
Unique Acetone Gel 5% and 10%

TPC
TEXAS PHARMACAL COMPANY
San Antonio, Texas 78296

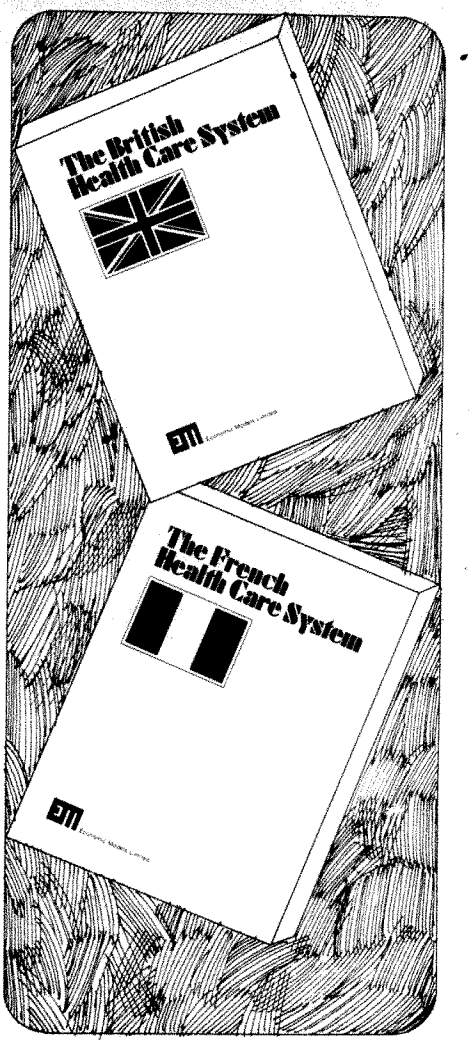

in depth studies of the health care systems of Britain and France

How they operate
and what they mean
to users and to people
who work in them.

Britain's health care system is predominantly nationalized. France offers its citizens a national health and social insurance plan. These comprehensive references cover each system's evolution...operation...application... problems...achievements...and personnel.

The French Health Care System (OP-460) costs $3.50; **The British Health Care System** (OP-461), $7.50. The set is $10. To order your copies, write **Order Dept., AMA, 535 N. Dearborn St., Chicago, Ill. 60610.**

New From Dermik

Hytone®

CREAM (HYDROCORTISONE)

2½%

hydrocortisone safety . . . new high potency . . .

- Atopic Dermatitis
- Severe Diaper Dermatitis
- Seborrheic Dermatitis
- Lichen Simplex Chronicus
- Pruritus Ani

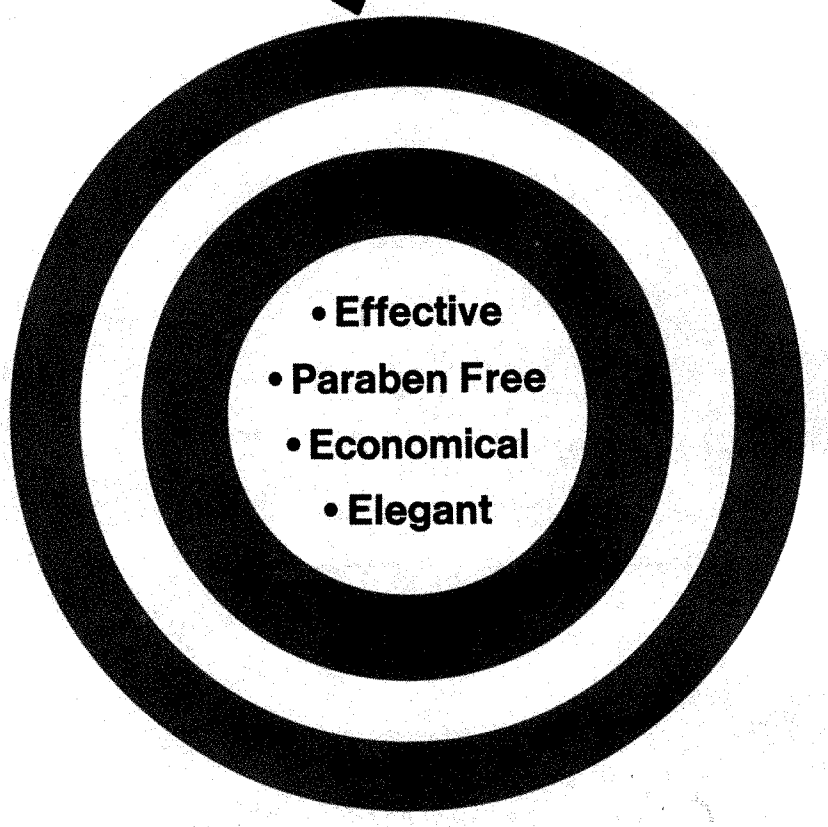

Dermik Laboratories, Inc., Fort Washington, Pa. 19034
WHERE RESEARCH AND ECONOMY COME FIRST!

DESCRIPTION – Hydrocortisone 2½%, 1% and ½% in a water-washable cream containing purified water, propylene glycol, isopropyl myristate, cholesterol and related sterols, cetyl alcohol, sorbic acid, glyceryl monostearate, polysorbate 60, sorbitan monostearate and polyoxyl 40 stearate.
ACTIONS – Topical corticosteroids are effective primarily because of their antiinflammatory, antipruritic, and vasoconstrictive actions.
INDICATIONS – For relief of the inflammatory manifestations of corticosteroid-responsive dermatoses.
CONTRAINDICATIONS: In viral diseases of the skin such as varicella and vaccinia and in patients with a history of hypersensitivity to any component. Not for ophthalmic use. Topical steroids should not be used when circulation is markedly impaired.
WARNING: Should not be used extensively, in large amounts, or for prolonged periods in pregnancy.
PRECAUTIONS – If irritation develops, the product should be discontinued and appropriate therapy instituted. In the presence of an infection, the use of appropriate antifungal or antibacterial agents should be instituted. If a favorable response does not occur promptly, the corticosteroid should be discontinued until the infection has been adequately controlled. If extensive areas are treated or if the occlusive technique is used, the possibility exists of increased systemic absorption of the corticosteroid and suitable precautions should be taken.
ADVERSE REACTIONS – The following local adverse reactions have been reported with topical corticosteroids, either with or without occlusive dressings: burning sensations, itching, irritation, dryness, folliculitis, secondary infection, skin atrophy, striae, hypertrichosis, acneform eruption and hypopigmentation.
DOSAGE AND ADMINISTRATION – Apply to affected areas 3 or 4 times daily.
HOW SUPPLIED: Tubes – ½ oz., 1 oz.
CAUTION – Federal law prohibits dispensing without prescription.

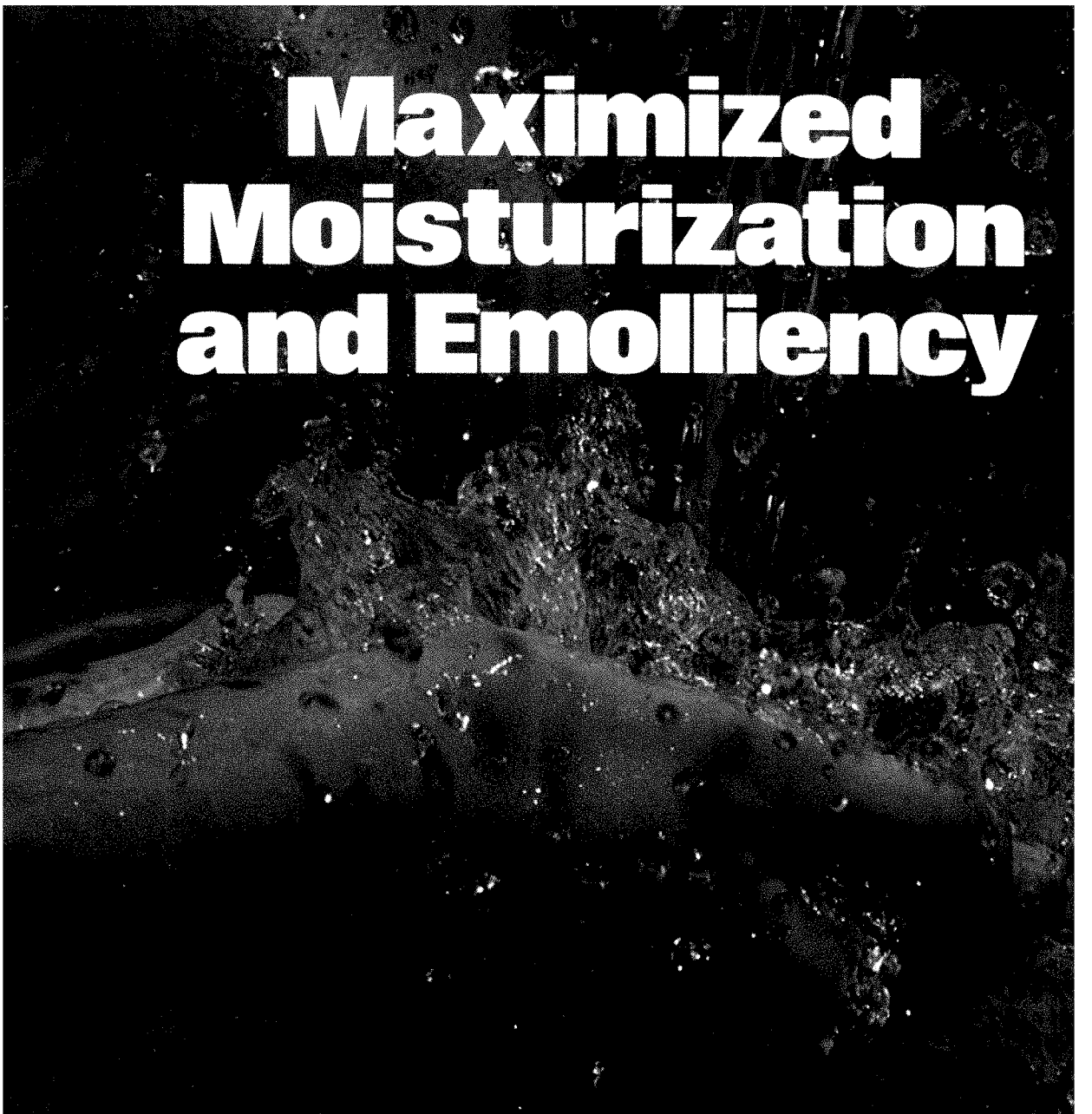

Maximized Moisturization and Emolliency

A natural humectant which occurs in normal healthy skin:

Sodium pyrrolidone carboxylate (NaPCA):
Proven superior to the most commonly-used humectants in water-holding capability and restoration of extensibility.[1] NaPCA is extremely hygroscopic, imbibing 60% of its weight in water at a humidity of 58%.[2]

A superior humectant which *locks* moisture into the stratum corneum:

Lactic Acid:
Lactic acid has the unique ability to be adsorbed onto the cells of the stratum corneum and to be retained there even after rinsing with water for 30 minutes, long after "the effect of other humectants was lost."[1]

An occlusive lipid barrier to h retard evaporation:

Special emulsion base is highly conce trated and helps reduce water loss fr the stratum corneum.

Formula: Lactic Acid USP 5.0%
Na-PCA 2.5%
in an oil-in-water lotion base containing: purified water mineral oil, isopropyl palmitate, coceth-6, sodium hy glyceryl stearate, myristyl lactate, cetyl alcohol, carbor imidazolidinyl urea, fragrance, dehydroacetic acid.
Please see LactiCare File Card for full prescribing info

LactiCar

Loti

How Supplied: In 8 Oz. Polyethylene Bottles With Flip-Top Dispenser Caps

STIEFEL
Logical Dermatologicals since 1847
Stiefel Laboratories, Inc., Oak Hill, N.Y. 12460
Stiefel Laboratories (Canada) Ltd., St. Laurent, Quebec, Can

1. Middleton, J.D.: Development of a skin cream designed to reduce dry and flaky skin. *J. Soc. Cosm. Chem.*, **25**, 519-534, 1974.

2. Laden, Karl: Natural moisturizing factors in skin. *Ame Perfumer and Cosmetics*, **82**, 77-79, Oct. 1967

new LactiCa

A genuine breakthro in the management of dry skin.

More physiologic: LactiCare's unique formula restores humectants which occur naturally in normal healthy skin.

Prolonged protection that won't easily wash away: Unlike most humectants which easily may be rinsed away, lactic acid is adsorbed onto the cells of the stratum corneum and remains there to improve their water-retention ability, even after extended immersion in water.

Better moisture-binding ability: Both of the major humectants in LactiCare have been shown superior to the most commonly-used hygroscopic agents in their ability to absorb moisture and supply it to the stra corneum.[1]

Greater economy: LactiCare is a h centrated lotion with a pleasant, t consistency. It should be used sp less often than ordinary lotions. over body use costs only pennie

Formula: Lactic Acid USP 5.0%
Na-PCA 2.5%
in an oil-in-water lotion base containing: purifi mineral oil, isopropyl palmitate, coceth-6, so glyceryl stearate, myristyl lactate, cetyl alcoho imidazolidinyl urea, fragrance, dehydroacetic

Please see LactiCare file card for full prescribing

STIEFEL
Logical Dermatologicals since 1847

Stiefel Laboratories, Inc.,
Oak Hill, N.Y. 12460
Stiefel Laboratories (Canada) Ltd.,
St. Laurent, Quebec, Canada H4R 1E1

The Society Proceedings are edited by Dr Morris Waisman, 806 First Federal Bldg, 220 Madison St, Tampa, FL 33602. Transactions and photographs should be sent, in duplicate, directly to him.

THE LOS ANGELES DERMATOLOGICAL SOCIETY
March 12, 1975

Marian M. Brubaker, MD, Recorder

Porphyria Cutanea Tarda With Sclerodermoid Changes. Presented by PERRY SCHOLNICK, MD, NORMAN BROOKS, MD.

A 61-year-old man with a four-year history of tightening of the skin of the chest, neck, scalp, and arms has had occasional bullous lesions and fragility of the skin on the dorsa of the hands. There was no history of photosensitivity, except for mild burning of the eyes on exposure to sunlight. He had been a heavy consumer of alcohol for ten years, but not for the past three years. The important findings were hidebound skin on the anterior portion of the chest, neck, and scalp, with erosions on the dorsa of the hands. Conjunctival infection was present.

Laboratory studies showed elevated levels of uroporphyrins (2,090 μg/24 hr; normal, <57 μg/24 hr) and coproporphyrins (348 μg/24 hr; normal, <234 μg/24 hr). The hematocrit reading was 42%, the serum iron value was 113 μg/100 ml (normal, 65 to 175 μg/100 ml), and the serum iron-binding capacity was 298 μg/100 ml (normal, 250 to 400 μg/100 ml). The results of liver function tests were normal, except for a slightly elevated SGPT level. Hepatomegaly was noted on a liver-spleen scan.

The skin biopsy specimen showed thickening of the dermis, with loss of distinction between papillary and reticular layers and focal infiltration by chronic inflammatory cells. The pathologic diagnosis was consistent with morphea.

Discussion

DR LEO INDIANER: Histologically, the epidermis is relatively normal and has binding of the sweat coils with loss of the subcutaneous fat around the sweat coils. There is replacement of the subcutaneous fat by light-staining collagen. One point that has never been made in the literature distinguishing ordinary scleroderma from scleroderma of porphyria is the looser weave of the collagen in sclerodermoid porphyria.[1] In the upper area of the dermis, there are dilated lymphatics and a mild inflammatory infiltrate with edema and basophilic amorphous material that represents hyaluronic acid deposits. This is reported in small quantities in scleroderma as well.[2] The lower area of the dermis, adjacent to subcutaneous fat, has a blood vessel with eosinophilic fibrillar material in its wall. So we see a scleroderma-like picture, with a lighter weave of the bundles, hyaluronic acid, and alterations of the blood vessels. The usual histologic character of porphyria cutanea tarda is that of a subepidermal bullous process with a minimal cellular infiltrate. Often in lesions of erythropoietic protoporphyria, less often in porphyria cutanea tarda, there are deposits of amorphous materials around the blood vessels of glycolipoproteins. Epstein and Tuffanelli,[1] in a study of lesions of porphyria of all types, found not only accumulations of lipids, globulins, and protein polysaccharides, but also tryptophan, sometimes in high degree.

DR WILLIAM REED: Recently, I had a call from Dr Bickers of Columbia University. He said, "You won't believe this, but there's no literature on sclerodermoid porphyria cutanea tarda. There are a lot of case reports, but there is no literature." And, there isn't! There are cases of porphyria cutanea tarda with calcification that have been studied. Authors mention the changes around the blood vessels before various treatments, but no one has done a biopsy after treatment, when the skin becomes soft and almost normal.

DR SCHOLNICK: This is not the only collagen disease in which porphyria cutanea tarda may be present. Early cases of lupus erythematosus were reported in 1955 to 1956 by Irving London in Alabama. He presented several cases of porphyria cutanea tarda that were precipitated in patients receiving chloroquin. Several of these patients were shown to have porphyria cutanea tarda as their only disease.

Why patients get sclerodermoid changes or lupus changes in porphyria cutanea tarda really isn't known, but it is unlikely that it is due solely to the porphyrins. Other porphyrias, in which the porphyrin levels are equally high, do not show sclerodermoid changes or lupus erythematosus. We have taken skin biopsy specimens from this patient, and are going to study his fibroblasts prior to and after treatment to see if there is any identifiable abnormality.

I have no ideas as to what is unique about these particular fibroblasts in presenting a sclerodermoid picture in sun-exposed areas. Biopsy specimens show the classic changes of scleroderma, but if you stain with IgG, you find the changes reported in the blood vessels of porphyria cutanea tarda. The sclerodermoid improves with phlebotomy or other therapy for porphyria cutanea tarda, but why it does is not known. I do not think anyone has any good ideas as to what the relationship between the scleroderma and the porphyria cutanea tarda is.

References

1. Epstein JH, Tuffanelli DL, Epstein WL: Cutaneous changes in the porphyrias. *Arch Dermatol* 107:689-698, 1973.
2. Fleischmajer R, Krol S: Chemical analysis of the dermis in scleroderma. *Proc Soc Exp Biol Med* 125:252-256, 1967.

Ligneous Conjunctivitis. Presented by VICTOR NEWCOMER, MD, ARNOLD KLEIN, MD

A 45-year-old woman developed inflammation of the right eye at the age of two, three weeks after an upper respiratory tract infection, that was diagnosed as diphtheritic or streptococcal conjunctivitis. Enucleation of the right eye was performed, and during the next four to five years, the patient experienced several episodes of inflammation of the right eyelid. At the age of 7, the patient developed a small mass of granulation tissue on the left upper eyelid. This growth was treated by electrocoagulation, silver nitrate application, curettage, 12 grenz-ray treatments, and other modalities, but still the growth continued to recur. She was seen at the University of California at Los Angeles Medical Center at the age of 32, and has been seen subsequently by Dr Victor Newcomer. The lesion of the left eyelid continues to recur, despite multiple excisions. There was no family history of ocular disease. The important finding was a firm, yellow-red, pedunculated lesion of the left conjunctiva. Results of all laboratory tests were within normal limits.

Discussion

DR ARNOLD KLEIN: Ligneous conjunctivitis was first described in 1933 by Borel.[1] The natural course of the disease involves the onset of acute pseudomembranous conjunctivitis at an early age, followed by the appearance of woody-hard, asymptomatic granulomas of the conjunctiva in adulthood. The acute conjunctivitis is frequently accompanied by nasopharyngitis, vulvovaginitis, and other systemic findings. It is a disease of chronicity; our patient had been observed for 44 years, while the patient of Verhoeff[2] was observed for 36 years. Ligneous means "woody-hard" and refers to the clinical characteristics of the chronic granulomas. This case has been recorded in the ophthalmologic literature by Spencer et al.[3]

DR INDIANER: The original cases of

ligneous conjunctivitis were classified as granulomas. The entire dermis in this patient was replaced by an eosinophilic homogenized amorphous material resembling amyloid. In addition, there was an inflammatory infiltrate with plasma cells, eosinophils, lymphocytes, histiocytes, and dilated and proliferating capillaries that contained thrombin. Endothelial cells were enlarged. Atypical fibroblasts were noted. Congo red stain was red in color, but when examined under polarized light the dichroism or shifting in color that is expected with amyloid was absent. With the crystal violet stain, the homogenized material was violet, and therefore negative for the metachromatic red color of amyloid. Can this represent colloid deposits, or porphyrin deposits? The patient had been treated with roentgen radiation, which can produce eosinophilic homogenized deposits of material with enlarged fibroblasts and vascular stasis. This would be a good case for electron microscopy in order to determine the exact nature of the deposit.

DR KLEIN: Another interesting finding in our patient is her exfoliative vaginal cytologic feature that initially appeared malignant, but subsequently, a cervical biopsy specimen showed a histologic pattern identical to the conjunctival granuloma and accounted for the suspicious cytologic pattern. We are dealing with an unusual systemic disease, rather than a simple conjunctivitis.

References

1. Borel G: Un nouveau syndrom palpebral. *Bull Soc Franc Ophtalmol* 46:168-180, 1933.
2. Verhoeff FH: A case of ligneous conjunctivitis now 36 years in duration. *Am J Ophthalmol* 45:246-251, 1958.
3. Spencer LM, Straatsma BR, Foos RY: Ligneous conjunctivitis. *Arch Ophthalmol* 80:365-367, 1968.

METROPOLITAN DERMATOLOGICAL SOCIETY OF LOS ANGELES

Nov 25, 1975 Robert I. Freedman, MD, Recorder

Hyperpigmentation of the Basal Layer. Presented by ROBERT FREEDMAN, MD; MANLEY COHEN, MD, FACP; ROBERT PARKE, MD

A 26-year-old Filipino woman complained of discoloration of her left leg. The lesion first appeared as a reddish discoloration at the left ankle in 1970 and progressed to involve most of the skin of the left leg between the ankle and the knee. Shortly after her arrival in this country in 1974, she was seen in the dermatology clinic of Harbor General Hospital. The initial diagnosis was linear scleroderma vs pretibial myxedema, and results of a punch biopsy were interpreted as "consistent with scleroderma (later stage)."

Admission to the Memorial Hospital of Long Beach was required because of cellulitis and superficial thrombophlebitis in the right calf. Results of physical examination showed the left calf to be heavily pigmented and warmer than the surrounding skin; it was covered with coarse, black hair, and it felt firm, although there was no pitting edema. A 2 × 4-cm tender left inguinal lymph node was present. A punch biopsy specimen taken from the left leg showed hyperpigmentation of the basal layer. Congo red stain for amyloid was negative.

The patient's menstrual history is of interest in that the cessation of regular menses was generally followed by swelling, tenderness, and warmth in the affected left leg, which may have lasted 24 to 48 hours. Her menstrual periods were normal, she was gravida 0, and had not received oral contraceptives. The medical history was unremarkable, particularly with reference to trauma, chronic infection, infestation, or ulceration.

Results of laboratory studies showed that complete blood cell count, liver enzymes, pancreatic enzymes, serum protein electrophoresis, serum calcium, serum phosphorus, and serum uric acid levels were normal. T_4 was 12.1 (normal, 4.5 to 11.5). Fungal culture of skin and potassium hydroxide preparation were negative. Roentgenograms of the right and left legs were normal, and results of an ultrasound examination of the left leg were normal.

Discussion

LEO INDIANER, MD: I was impressed by the prominent basalar zone pigmentation. The question clinically, is whether this was a Becker nevus with pigmentation and hair as the primary nevoidal event, or whether the pigmentation and hair increase were on the basis of an underlying vascular or metabolic process. I do not think the biopsy specimen really showed the hairs, to demonstrate if they extend deeper than they should in this particular area as compared with usual hairs on the opposite extremity. Neither was the biopsy specimen deep enough to exclude other causes, and the question was raised repeatedly as to whether there was a difference in temperature on this leg. This is either a nevoidal process that is primary, with a vascular component, or it is vascular, with the pigmentation and hair increases as secondary phenomena.

GEORGE GEMMINGEN, MD: This patient had the same number of hairs on both legs, which is important. If she had a Becker nevus, then she should have a difference in the number of hairs. Trichogenesis does not occur in people; in fact it does not occur in any animal, except maybe for in antlers of deer. I think that this woman has solid edema of her leg. It was a pitting type of edema, and she states that she has an enlarged lymph node in the groin. If she does indeed have a solid edema, then one must look for a chronic infection, or a lymphostatic process, or even a vascular anomaly of some sort. It might be worth doing a lymphangiogram or arteriogram.

MEYER BERKE, MD: Clinically, she has scleroderma and an accentuation of hairs that are already there. They are coarser, darker, and longer, much as in porphyria cutanea tarda.

STANTON MAY, MD: Each month, at the time of her period, this condition worsened considerably, with a good deal more swelling. Among the things to consider in the work-up would be an examination by a gynecologist to see if there is any disease in the pelvis.

DR FREEDMAN: I believed that this was an edema rather than a scleroderma. I would expect atrophy of the hair with scleroderma rather than the hypertrichosis that we saw. The hypertrichosis and the hyperpigmentation remind me of vascular process, such as erythema ab igne, that was reactivated time after time, along with the edema. The puzzling thing is that it is limited; it begins above the ankle and ends below the knee, whereas if this was a lymphedema with blockage in the inguinal area, one would expect to see the swelling extending up higher. It may be that the vessels are sensitive to estrogen or progesterone and become dilated at certain times.

Multiple Keratoacanthomas on Upper Extremities. Presented by WALTER S. GREEN, MD, LAURENCE J. UNDERWOOD, MD, ROLIN GREEN, MD

A 55-year-old woman first noted lesions on her forearm in 1969. Gradually, more lesions appeared, and larger areas became involved. Spontaneous regression was not noted, nor were the lesions symptomatic, except for tenderness if bumped. There was no family history of similar lesions, nor had she had a previously known viral or "wart" problem. There had been no exposure to tars or other chemicals or carcinogens, although the patient had used baby oil on her skin for years. Through the years she exposed her skin to much sunlight. She has had hypertension for many years, and at present is receiving spironolactone (Aldactazide).

On the dorsa of the hands, the knuckles, and the extensor surface of the arms and forearms were symetric plaques of pinkish papules and nodules. The larger lesions were elevated, dome-shaped, and had a crusted keratinous center. A biopsy specimen taken from the right forearm by her family doctor was interpreted by a general pathologist as a keratoacanthoma. A biopsy specimen from a 1.5-cm "growing" nodule of six weeks' duration was presented. The pathologic findings were those found in a keratoacanthoma, namely, substantial hyperkeratosis and, pseudoepitheliomatous hyperplasia, entrapping keratin masses and surrounded by a chronic inflammatory infiltrate.

For treatment, lubricants, intralesional injection of an unknown medication, kera-

tolytic "Freezone," and a limited trial of lactic acid-salicylic acid, 15% of each in collodion, and salivylic acid (Keralyt) under occlusion were used.

Results of a biopsy showed there was an epithelial proliferation in which masses of relatively mature squamous epithelium extended to the level of the reticular dermis. The squamous dysplasia was moderate. I do not believe that this was pseudoepitheliomatous hyperplasia of a reactive character. I would agree with the diagnosis of keratoacanthoma (Bernard Gottlieb, MD).

Discussion

MEYER BERKE, MD: For these lesions, I have used local triamcinolone acetonide liquid nitrogen with variable results. Many of them regress spontaneously. If any lesion gets too large. I would surgically remove it.

DR INDIANER: Other things that might be considered in the differential are swimming pool granuloma, bromoderma, iododerma, and reactive hyperplasia with folliculitis. One of the tests of the keratoacanthoma is that it comes and goes. If it does not go, then eventually some other etiologic factors may have to be looked for.

DR MAY: Assuming that the diagnosis of keratoacanthoma is correct, I suggest treating these lesions with tincture of podophyllin. I once presented a patient to the Los Angeles Dermatological Society who had a huge keratoacanthoma on her lip. Within a few weeks after I applied the podophyllin, this lesion miraculously cleared up.

STUART MARTEL, MD: The patient shows evidence of considerable sun damage. She spends every weekend at the beach and does not use any protective sun screen.

JOHN WATSON, MD: In addition to being a sun-lover, the patient has been taking two photosensitizing sulfonamides for ten years, namely saccharin for weight control and thiazides for essential hypertension. All sulfonamides should be avoided in patients with solar dermatoses.

STEVEN KARASSIK, MD: You might consider using immunotherapy with dinitrochlorobenzene; you would sensitize the patient to it and challenge the individual lesions with this immunogen.

The Case of the Vanishing Lesions: Mycosis Fungoides? Presented by VINCENT P. BURBY, MD.

This woman has had a variety of skin lesions since 1965. They arise, then disappear after a short period of time, but always present a diagnostic problem. The patient first had a yellowish-red, raised lesion on her forehead suspected to be a lymphoma. It disappeared spontaneously after the biopsy specimen was taken. In 1969, dull red annular lesions appeared on her hand, clinically resembling granuloma annulare. The biopsy examination was consistent with a diagnosis of premycotic mycosis fungoides. These lesions became eczematized and then disappeared. In 1970, lesions typical of erythema multiforme appeared on the right forearm. At that time, the patient was receiving Donnatal Plus. More lesions of the same type developed two weeks later after dental surgery was performed under thiopental sodium (Pentothal Sodium) anesthesia; atropine, meperidine (Demerol), hydrochloride and lincomycin hydrochloride monohydrate were also given at that time.

Her latest eruption occurred in October 1975. The lesions were shiny, raised, yellowish-red nodules on the dorsal surface of the hands and wrists. The biopsy specimen from the wrist was interpreted as suggestive of early parapsoriasis. Another specimen from a scaling, red lesion on the leg was interpreted as parapsoriasis, possible premycotic mycosis fungoides.

Results of a bone marrow study, done elsewhere, were reported to be normal. Results of a complete blood cell count were as follows: hemoglobin, 12.8%; hematocrit, 38%; erythrocytes, 4.11 million/cu mm; mean corpuscular volume, 93 cuμ; mean corpuscular hemoglobin, 31 $\mu\mu$g; mean corpuscular hemoglobin concentration, 33%; leukocytes, 9,200/cu mm; segmented neutrophils, 83%; lymphocytes, 17%; sedimentation rate, 39 mm/hr. Results of a biochemical profile ordered by her family physician were normal. Presently the patient has been receiving indomethacin (Indocin), methocarbamol (Robaxin), and conjugated estrogens (Premarin).

Discussion

DR INDIANER: Three slides were presented, all with a dense infiltrate of small and large lymphocytes and mononucleated cells within the dermis. One of the slides demonstrated pure hyperkeratosis and exocytosis of these cells into the epidermis. In the second biopsy specimen, there was a focal delicate parakeratosis with exocytosis of cells into the epidermis. The third slide showed hyperkeratosis, hypergranulosis, and a lichenoid type of infiltrate extending into the epidermis. Some of the lymphocytes were enlarged, but there were not clusters of these cells in the epidermis to a sufficient degree to be diagnostic of mycosis fungoides. The second biopsy specimen might be called a parapsoriasis-type subchronic dermatitis, while the third one could be classified as a lichenoid subchronic dermatitis. I would not agree that this is a malignant lesion. There are lesions that do resolve that are inflammatory, and also there is lymphomatoid papulosis, where you can have weird, atypical, bizarre cells. Also, Sezary-type cells or T-type cells under the electron microscope mimic those cells that you see in mycosis fungoides, yet the lesions resolve. I was not impressed with the atypia and would call this a dermatitis.

DR GOTTLIEB: I was impressed with the dermal-epidermal interplay in all biopsy specimens. I would put erythema multiforme and drug eruption at the top of my list.

DR MAY: These lesions occur only on the exposed extremities, and I wondered if this could be a polymorphous light sensitivity eruption, since it comes and goes so dramatically.

Nonproprietary Name and Trademark of Drug

Lincomycin hydrochloride monohydrate—*Lincocin.*

PSORIASIS
The Capricious Dermatosis

LIDEX® (fluocinonide) 0.05%
A Stabilizing Influence

Psoriasis. Mere mention of the word can make an afflicted patient cringe. And, because of the capricious, unpredictable nature of the disease, the patient rarely knows where or when it will recur.

Obviously, the goal is control. And, though varied treatment modalities are available today, none offers universal

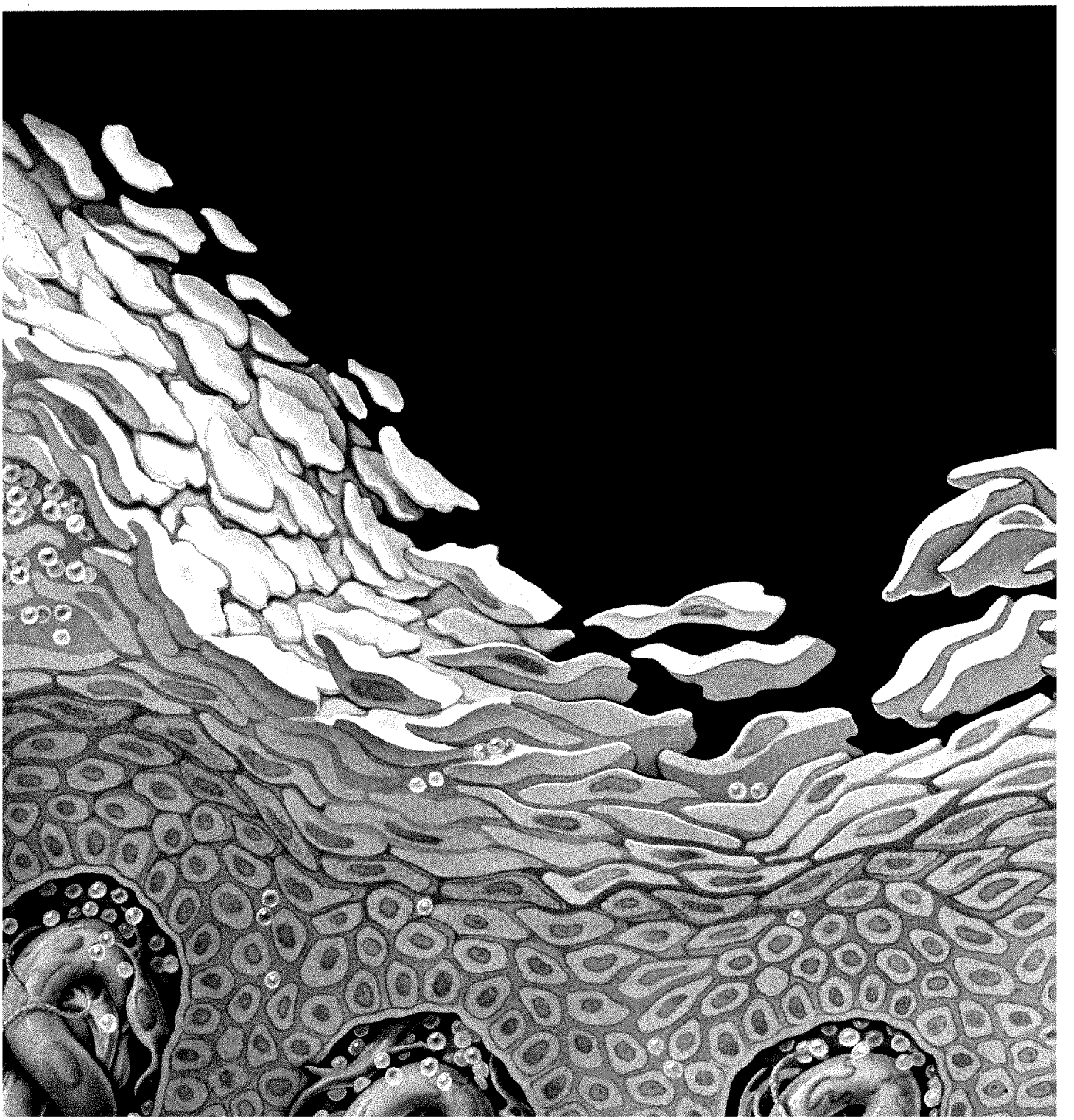

efficacy for all patients, all of the time.

Yet, very often a highly effective topical steroid, like Lidex, (fluocinonide) can help stabilize psoriasis.

Lidex. A highly effective topical steroid with anti-inflammatory, vasoconstrictive, antipruritic actions.

100% dissolved for optimal penetration, important in stages that exhibit thickened, scaly lesions.

Totally free of preservatives.

Available in cream, ointment, and Topsyn® (fluocinonide) gel.

SYNTEX

SYNTEX LABORATORIES, INC.
PALO ALTO, CALIFORNIA 94304



(See following page)

LIDEX® (fluocinonide)
0.05% Cream and Ointment

TOPSYN® (fluocinonide)
0.05% Gel

Summary of prescribing information

Description
LIDEX cream 0.05%, LIDEX ointment 0.05% and TOPSYN gel 0.05% contain the active compound fluocinonide. Fluocinonide, which is the 21-acetate ester of fluocinolone acetonide, has the chemical formula 6α, 9α, -difluoro-11β, 16α, 17α, 21-tetrahydroxypregna-1,4-diene-3, 20-dione, cyclic 16, 17-acetal with acetone 21-acetate. LIDEX cream contains fluocinonide in FAPG® cream, a specially formulated cream base consisting of stearyl alcohol, polyethylene glycol 6000, propylene glycol, 1, 2, 6-hexanetriol and citric acid. This white cream vehicle is greaseless, non-staining, anhydrous and completely water miscible. The base provides emollient and hydrophilic properties. In this formulation, the active ingredient is totally in solution.

LIDEX ointment contains fluocinonide in a specially formulated ointment base consisting of Amerchol CAB (mixture of sterols and higher alcohols), white petrolatum, propylene carbonate and propylene glycol. It provides the occlusive and emollient effects desirable in an ointment. In this formulation the active ingredient is totally in solution.

TOPSYN gel contains fluocinonide in a specially formulated gel base consisting of propylene glycol, propyl gallate, disodium edetate, and Carbopol 940 (carboxypolymethylene) with NaOH and/or HCL added to adjust the pH. This clear, colorless, thixotropic vehicle is greaseless, non-staining and completely water miscible. In this formulation, the active ingredient is totally in solution.

Indications
LIDEX cream and ointment and TOPSYN gel are intended for the relief of inflammatory manifestations of corticosteroid responsive dermatoses.

Contraindications
Topical steroids are contraindicated in vaccinia and varicella. Topical steroids are contraindicated in those patients with a history of hypersensitivity to any of the components of the preparation.

Precautions
If irritation develops, the cream, ointment or gel should be discontinued and appropriate therapy instituted. In the presence of an infection the use of an appropriate antifungal or antibacterial agent should be instituted.

If a favorable response does not occur promptly, the corticosteroid cream, ointment or gel should be discontinued until the infection has been adequately controlled.

If extensive areas are treated, the possibility exists of increased systemic absorption and suitable precautions should be taken.

Although topical steroids have not been reported to have an adverse effect on pregnancy, the safety of their use in pregnant females has not absolutely been established. Therefore, they should not be used extensively on pregnant patients, in large amounts or for prolonged periods of time.

LIDEX® (fluocinonide) cream and ointment and TOPSYN® (fluocinonide) gel are not for opthalmic use.

Adverse reactions
The following local adverse reactions have been reported with topical corticosteroids:

burning	folliculitis
itching	acneform eruptions
irritation	hypopigmentation
dryness	striae
secondary infection	skin atrophy

Dosage and administration
A small amount should be gently massaged into the affected area three or four times daily, as needed.

How supplied
LIDEX 0.05% Cream—15 g 30 g and 60 g tubes.
LIDEX 0.05% Ointment—15 g 30 g and 60 g tubes.
TOPSYN Gel 0.05% 15 g and 60 g tubes.

SYNTEX
SYNTEX LABORATORIES, INC.
PALO ALTO CALIFORNIA 94304

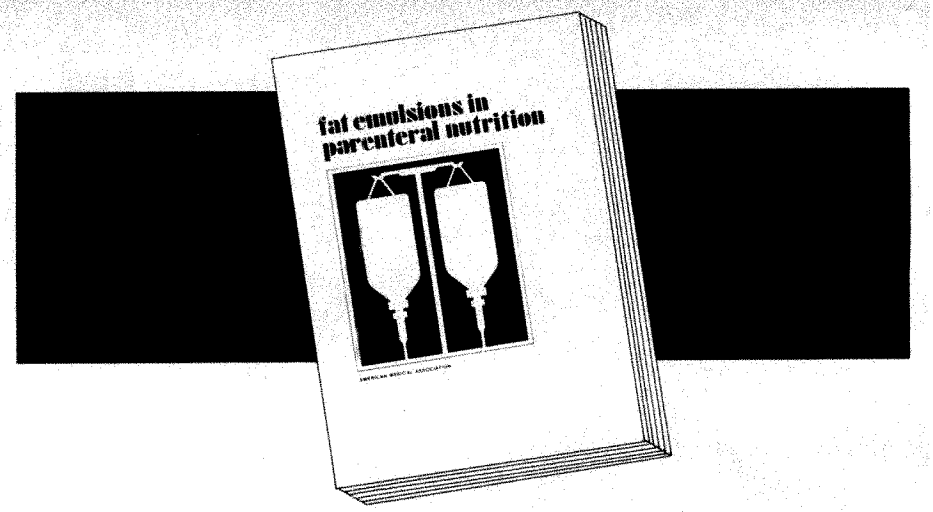

FDA soon to approve fat emulsions for clinical use!
Prepare yourself with this new AMA book...

Fat Emulsions in Parenteral Nutrition

A digest of the latest important research findings

FAT EMULSIONS IN PARENTERAL NUTRITION, the proceedings of the June, 1975 meeting sponsored by the Department of Foods and Nutrition and the Nutrition Advisory Group of the AMA, will provide you with a review of experimental and clinical studies and discussions of problems encountered with the use of fat emulsions.

Divided into three sections, the book covers the metabolism of fatty acids and function of essential fatty acids with information on EFA deficiency; fat as an energy source; and the pathophysiology with discussions on side effects, interrelations with other nutrients, and the current status of products available.

To avoid potential problems and to become thoroughly acquainted with the intricacies of this about-to-be-approved nutritional supplement, every hospital physician, nurse and pharmacist should make this publication required reading.

Order Dept. OP-140, AMA, 535 N. Dearborn St., Chicago, Ill. 60610

Please send _____ copy(ies) of FAT EMULSIONS IN PARENTERAL NUTRITION, OP-140, $7 in U.S. and U.S. Possessions, $7.50 elsewhere.

Name _____

Institution _____

Address _____

City _____ State _____ Zip _____

Remittance, made payable to AMA, must accompany order. S/J

IN SKIN INFECTIONS, WHERE CLEANLINESS REQUIRES MORE THAN SOAP

BETADINE® Skin Cleanser

Degerms as it cleanses

atients can use BETADINE Skin Cleanser to degerm and cleanse face, hands and body, gently and thoroughly—articularly when it is essential to prevent autoinoculation of new sites, as may be the case in infected acne pimples.

BETADINE Skin Cleanser, with its rich, golden lather, provides these advantages:

- Prompt, broad-spectrum microbicidal action—kills both gram-positive and gram-negative bacteria (including antibiotic-resistant strains), fungi, viruses, protozoa and yeasts.
- Maintains microbicidal activity in the presence of blood, pus and serum.
- Virtually nonirritating to skin and mucosa.*
- Nonstaining to skin and natural fabrics.

Supplied: 4 fl. oz. plastic bottles.

*In the rare instance of local irritation or sensitivity, discontinue use by the individual.

Purdue Frederick © COPYRIGHT 1976, THE PURDUE FREDERICK COMPANY

NORWALK, CONN. 06856 A8196 172076



Letters to the Editor

Cutaneous Polyarteritis Nodosa

To the Editor.—Cutaneous polyarteritis nodosa is a benign disease that involves the deeper dermis and subcutis, muscle, and nerves, with only rare cases developing systemic involvement.[1] Remissions occur spontaneously[2] or following steroid therapy.[2-4] We here report a case associated with tuberculosis and responding to antituberculous therapy.

Report of a Case.—A 24-year-old man was admitted to the hospital because of weakness, pain, and swelling of both lower extremities, associated with painful erythematous nodules over the legs of about six weeks' duration. Some of these ulcerated and discharged necrotic material. He also had a 15-kg (33-lb) weight loss and fever. Eight weeks prior to admission, he had fever and an upper respiratory tract infection lasting ten days. He was a former heroin user but had been drug-free for the past 1½ years. On examination, he had a remittent fever, with a nightly rise in temperature to about 38.3 C (101 F). He was normotensive and had well-circumscribed, tender, nonulcerated subcutaneous nodules on both calves and in the pretibial area, without involvement of overlying skin. Small and shotty cervical, axillary, and epitrochlear lymph nodes were palpable. There was weakness of both lower extremities with right foot drop but no sensory loss. The right epididymis was painful and tender. The ESR was 112 mm in the first hour (Westergren); serum albumin value, 3 gm/100 ml; globulin, 4.7 gm/100 ml; γ-globulin, 2 gm/100 ml; VDRL test, positive at 2+; latex fixation test, positive at 1:160; antinuclear antibody test, negative; febrile agglutinins (OX-19), positive 1:160; and anti-streptolysin O (ASO) titer, 333 Todd units. The WBC count was normal. The purified protein derivative skin test for tuberculosis was strongly positive, with sloughing of the reaction site. The reaction had been negative six months earlier. The patient admitted contact with an active case of tuberculosis.

A subcutaneous nodule and a muscle biopsy specimen from the right calf were submitted for histological examination.

Histological Findings.—A necrotizing inflammatory process was found, involving a small muscular artery in the subcutaneous tissue (Fig 1). The necrosis was eccentric, destroying the entire thickness of the arterial wall and producing a pseudoaneurysm. Polymorphonuclear leukocytes were found in this area. The lumen was occluded by a fresh thrombus. A limited chronic inflammatory reaction was present immediately surrounding the vessel. Panniculitis was minimal and a solitary ill-formed, nonnecrotizing granuloma was present in this area. The muscle contained a thrombosed vessel, with complete replacement of its wall by macrophages, fibroblasts, and a few lymphocytes (Fig 2).

Treatment was started three weeks after admission with penicillin G benzathine (Bicillin), 2.4 million units intramuscularly twice daily on the first and seventh days, isoniazid, 300 mg daily; and rifampin, 600 mg daily. Within ten days, the skin lesions regressed and he became afebrile. The serum globulin two months later was 2.9 gm/100 ml. Now one year later, the patient is still receiving antituberculous therapy but has had no recurrence or residua of the arteritis or epididymitis.

Comment.—The etiology of cutaneous polyarteritis nodosa remains obscure. One patient in Borrie's[3] series of 15 cases had pulmonary tuberculosis and developed the arteritis two months after beginning a nine-month course of streptomycin sulfate. Since the lesions regressed in the presence of continuing streptomycin therapy, it is probable that they were causally related to tuberculosis rather than to the drug. Cutaneous polyarteritis nodsa responding to penicillin has been reported in associa-

Fig 1.—Muscular artery in subcutaneous tissue, showing mural and perivascular leukocytic infiltrate, thrombosis, partial destruction of internal elastic lamina, and eccentric destruction of media with formation of pseudoaneurysm (arrows) (Weigert elastic stain and hematoxylin-eosin, ×50).

Fig 2.—Blood vessel in gastrocnemius muscle, showing total destruction of vessel wall, transmural and perivascular infiltrate of macrophages, lymphocytes, and fibroblasts, and thrombus occluding lumen (hematoxylin-eosin, ×50).

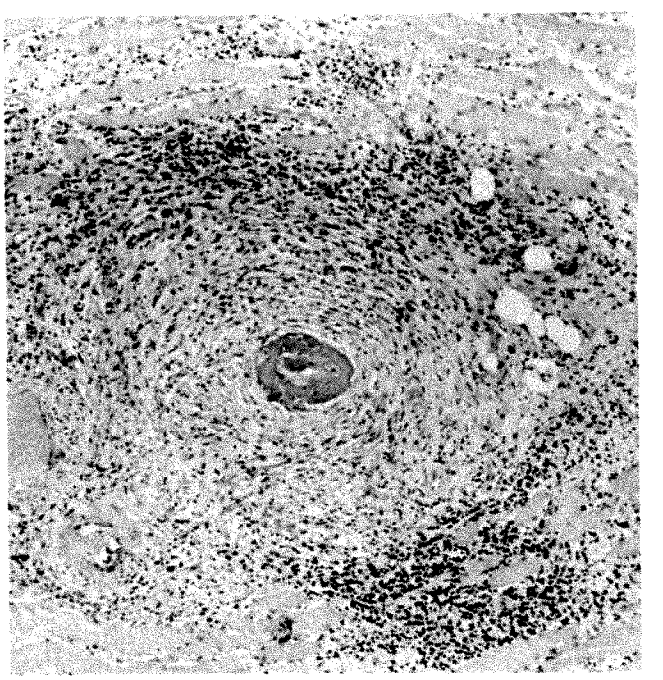

tion with streptococcal infection.[3-5] The raised ASO titer suggests that the initial respiratory infection was streptococcal.

The time lag of ten days between the onset of therapy and the regression of the lesions is strong evidence for a cause-and-effect relationship. For a necrotic, thrombosed muscular artery of the size involved in this case to organize, recanalize, and become functional again, a time requirement of one to two weeks seems entirely reasonable. It is not possible to state unequivocally which of the two modalities of therapy, penicillin or antituberculous drugs, was responsible for the remission. Our personal bias is for the latter, in view of the stronger evidence of active tuberculous than of any other infection in this patient.

LIZA ANTONY, MD
GURDIP S. SIDHU, MD
New York

1. Dyk T: Cutaneous polyarteritis. *Br Med J* 1:551, 1973.
2. Bradford WD, Cook CD, Vawder GF: Livedo reticularis: A form of allergic vasculitis. *J Pediatr* 60:266-276, 1962.
3. Borrie P: Cutaneous polyarteritis nodosa. *Br J Dermatol* 87:87-95, 1972.
4. Diaz-Perez JL, Winkelmann RK: Cutaneous periarteritis nodosa. *Arch Dermatol* 110:407-414, 1974.
5. Cutaneous periarteritis nodosa, SOCIETY TRANSACTIONS. *Arch Dermatol* 102:571-572, 1970.

Nonathletic Calcaneal Petechiae

To the Editor.—A black spot developed on my right heel in December 1975, at which time I was not engaged in any athletic activity. The lesion persisted for several months and spontaneously cleared.

Recently (August 1976), I had difficulty in getting into my shoes, I recalled similar trouble with the same shoes when the black spot appeared.

It seems that trauma, athletic or otherwise, may cause calcaneal petechiae.[1]

THOMAS S. SAUNDERS, MD
Portland, Ore

1. Crissey JT, Peachey JC: Calcaneal petechiae. *Arch Dermatol* 83:501, 1961.

Lichen Planus and Xanthoma

To the Editor.—The development of unusual changes in hypertrophic lichen planus may indicate the development of epitheliomatous change. We wish to report a case of hypertrophic lichen planus that changed its clinical appearance as a result of underlying xanthoma formation.

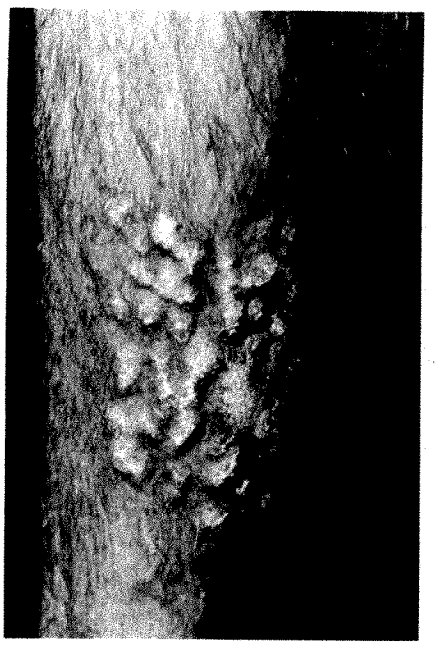

Fig 1.—Lesion on right leg.

Report of a Case.—A 33-year-old man was referred to Royal Brisbane Hospital in 1969 with recurrent bouts of jaundice, abdominal pain, and fevers. A cholecystoduodenostomy was performed to relieve a strictured common bile duct. He remained well until 1972 when he presented with recurrence of his symptoms. He was noted to have a large plaque of hypertrophic lichen planus on his right shin with smaller areas on the left. These had been present for two years. The diagnosis was confirmed by biopsy. Mild diabetes mellitus and chronic pancreatitis had also developed. A further drainage procedure was carried out on his common bile duct. When next seen in 1975 with recurrent cholangitis, he reported recent thickening of his plaques of lichen planus (Fig 1). Biopsy revealed numerous foam cells in the upper and mid dermis with overlying lichen planus (Fig 2). There were no xanthomata present elsewhere, although his serum cholesterol level was 656 mg/100 ml; triglycerides, 685 mg/100 ml; and there was a type II B electrophoretic pattern. There has been some decrease in the size of the skin plaques and improvement in his biochemical values following further surgery to the common bile duct.

Comment.—Animal experiments suggest that the primary factor determining the distribution of xanthomata in hyperlipidemic states is local increase in vascular permeability perhaps determined by the release of vasoactive substances at sites of trauma! Vascular permeability could also be increased in an area of skin

Fig 2.—Xanthoma cells with overlying hypertrophic lichen planus (hematoxylin-eosin, ×65).

previously affected by a dermatosis. While there has been a report of skin xanthomata following erythroderma and long-standing atopic eczema,[2] we know of no reports of a xanthoma developing preferentially in a plaque of hypertrophic lichen planus.

DAVID WEEDON, MB, FRCPA
IVAN ROBERTSON, MB
Brisbane, Australia

1. Walton KW, Thomas C, Dunkerby DJ: The pathogenesis of xanthomata. *J Pathol* 109:271-289, 1973.
2. Walker AE, Sneddon IB: Skin xanthoma following erythroderma. *Br J Dermatol* 80:580-587, 1968.

Tinea Versicolor

To the Editor.—Through the years, up until six years ago, I have examined the skin of a few hundred college football players and many fewer basketball players as part of their preschool-year physicals at the University of Kentucky. Beyond doubt, other than acne, the most common affliction in these athletes was tinea versicolor, with perhaps a majority having the disease, and often an accompanying tinea cruris or tinea pedis and, rarely, toenail tinea as well.

The number infected and the extent varied directly with the number of years of athletic participation, the incoming freshmen players being the least afflicted by the now culturable *Malassezia furfur*.[1-3] However, it was noted that even those with but

minimal involvement about the chest or shoulders often revealed a small, typical, fine scaling, pink to tan yellowish macule or two in the upper portion of the pubic hair as did virtually all of those heavily infected. Here then are four reasons for the high rate of relapse or reinfection in college athletes: (1) an inherent relative inability to resist infection by superficial fungi; (2) failure to treat the relatively hidden focus in the upper pubes, which reinfects the other skin areas and clothing; (3) an everburgeoning number of organisms in the athletes' environment; including towels, linens, uniforms, and equipment; and finally (4) the antigenically proved relationship of *M furfur* to the normal saprophytic yeast *Pityrosporon ovale* present on lipid-rich areas of the skin which in favorable, little-known circumstances may transform into the pathogenic *M furfur*.

Two novel cellular reactions induced by *M furfur* have been reported: (1) extracellular glycogen deposits in the upper epidermis[4] associated with increased stratum corneum turnover and (2) macromelanosomes in the lower epidermis in hyperpigmented tinea versicolor, singly distributed in the keratinocytes and hypermelanized. This latter effect is in direct contradistinction to the cutaneous effect of the fungus when it produces hypopigmentation (usually in sun-exposed areas) where it appears that production of abnormally small melanosomes is induced that are not properly transferred to keratinocytes.[5]

WILLIAM E. MCDANIEL, MD
Lexington, Ky

1. Roberts SOB: *Pityrosporum orbiculare*: Incidence and distribution on clinically normal skin. *Br J Dermatol* 81:264-269, 1969.

2. Roberts SOB: Pityriasis versicolor: A clinical and mycological investigation. *Br J Dermatol* 81:315-326, 1969.

3. Lii S: Cultivation and pathogenicity of *Malassezia furfur*, with special respect to mycological studies on etiological fungus of tinea (pityriasis) versicolor. *Tokushima J Exp Med* 16:127-151, 1969.

4. Keddie FM: A novel cellular reaction caused by tinea versicolor: Extracellular glycogen deposits. *J Invest Dermatol* 53:363-372, 1969.

5. Allen HB, Charles CR, Johnson BL: Hyperpigmented tinea versicolor. *Arch Dermatol* 112:1110-1112, 1976.

Onycholysis Through Phototoxicity

To the Editor.—Onycholysis through a phototoxic mechanism, in patients taking a tetracycline derivative, was described by Orentreich et al[1]. The following is a report of an unusual manifestation of this reaction.

Report of a Case.—A 20-year-old undergraduate had painful, swollen fingertips. One week earlier, she had experienced paresthesias in both hands, which had lasted a full day. Two days prior to her visit, her left fourth fingertip became tender and edematous; by the next morning, all fingers, except the thumbs, were similarly involved. There was no history to suggest contact dermatitis or trauma. Apart from studying, her activities included only sunbathing, which she does frequently, and has always tolerated well. Current medications were limited to levothyroxine sodium (Synthroid) (dose unknown) and tetracycline hydrochloride, 250 mg/day, taken for two years.

The patient was well tanned and healthy-appearing, and had edematous fingertips. The nail beds were pale, and the nail plate was raised up 2 mm from the hyponychium, without distal or lateral detachment (Figure). The nail was extremely sensitive to pressure. Her thumbs and toenails were spared, the latter being covered with nail polish. There was no other evidence of an acute sunburn reaction.

A shallow puncture was made with a No.12 Bard-Parker scalpel blade just below each nail plate, and clear, colorless fluid poured out freely. This maneuver relieved her discomfort considerably. Air bubbles could then be moved across the full area of the nail bed, indicating complete detachment to the proximal and lateral nail folds.

Comment.—Frank et al[2] reported three cases of tetracycline-induced photo-onycholysis. Two of their patients were taking tetracycline hydrochloride for 4 to 12 months, and at least one had a fair complexion. All showed sunburn elsewhere, as did the patients in the article by Orentreich et al.[1]

The two patients with photoonycholysis and discoloration described by Kestel[3] and the one by Bettley and Samman[4] were taking tetracycline (Achromycin) and demeclocycline hydrochloride, respectively. None had other signs of acute sun injury. The discoloration was considered secondary to hemorrhage. In a study by Frost et al,[5] 12 of 13 patients taking demeclocycline experienced paresthesias within 48 hours of their initial sun exposure.

This patient is unusual in that photosensitivity reactions to tetracycline are much less common than with its cogeners. Furthermore, she had previously had significant exposure to sunlight while taking the medication and had no adverse affects. The patient's deep tan may explain the localization of the reaction to her nails. The toenails were protected by polish but one must presume that the thumbnails were less exposed because of their positioning.

The nailplate is a poor sunscreen and may even concentrate solar radiation.[1] The incomplete separation of the nailplate from the bed, induced by the buildup of fluid, may be an initial

Nailbeds of patient with onycholysis.

stage of a more typical onycholysis that did not proceed to completion. Perhaps this is a clue to the mechanism of onycholysis in photosensitivity reactions.

MANFRED S. ROTHSTEIN, MD
Durham, NC

1. Orentreich N, Harber LC, Tromovitch TA: Photosensitivity and photo-onycholysis due to demethylchlortetracycline. *Arch Dermatol* 83:730-737, 1961.
2. Frank SB, Cohen HJ, Minkin W: Photo-onycholysis due to tectracycline hydrochloride and doxycycline. *Arch Dermatol* 103:520-521, 1971.
3. Kestel JL Jr: Tetracycline-induced onycholysis unassociated with photosensitivity. *Arch Dermatol* 106:766, 1971.
4. Bettley FR, Samman PD: Photo-onycholysis. *Proc Roy Soc Med* 67:600, 1974.
5. Frost P, Weinstein GD, Gomez EC: Methacycline and demeclocycline in relation to sun light. *JAMA* 216:326-329, 1971.

An Aqueous Solution?

To the Editor.—I am not really enlightened by Bernard Ackerman's reply to Dr Samuelson's query in the July ARCHIVES (111:925, 1975). If the antigens were "suspended in an aqueous solution," one immediately wonders "a solution of what?" If it was a solution of nothing or if the antigens were not in fact suspended, but dissolved, then it would have been best to come right out and say "water" instead of an aqueous solution—if water is what was meant.

HARRY L. ARNOLD, JR, MD
Honolulu

Dermatolipidectomy of Elephantiasis Nostras Verrucosa of the Panniculus

To the Editor.—In 1973, Rudolph and Gross reported in the *Archives of Dermatology* (108:832, 1973) a case of elephantiasis nostra verrucosa of the panniculus. An etiology of obesity, repeated episodes of erysipelas, and chronic passive congestion was proposed.

During the past three years, the patient had been receiving erythromycin and had been free of cutaneous infection. In spite of stable weight, the massive abdominal apron had become a physical and social problem (Fig 1).

The patient recently was operated upon for relief of her physical complaints. An abdominal dermatolipectomy was done, with resection of 6.8 kg of fat, scarred subcutaneous tissue, and the plate of verrucoid skin (Fig 2). Significantly enlarged vascular channels were found supplying this dependent tissue mass. Primary wound healing was achieved, and the patient obtained marked relief.

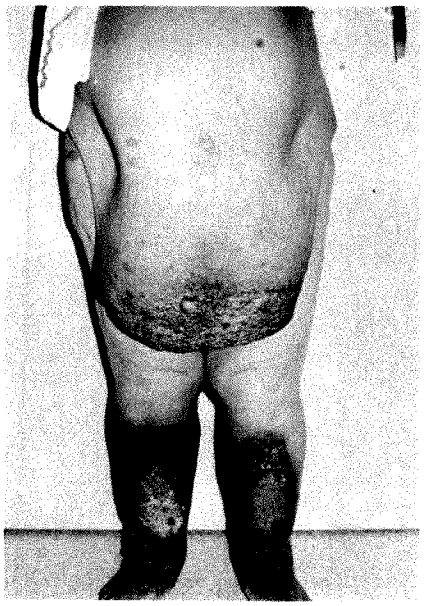

Fig 1.—Elephantiasis nostras verrucosa of panniculus. Note verrucoid pattern of abdominal skin.

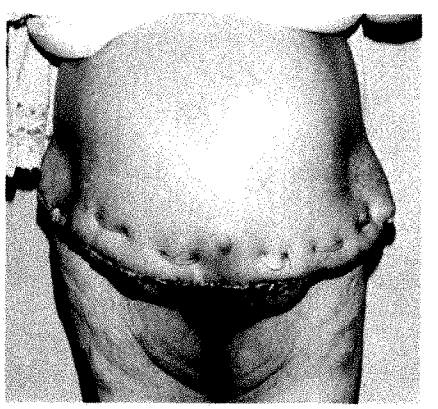

Fig 2.—Early postoperative view. There was no evidence of visceral herniation.

PAUL R. GROSS, MD
R. BARRETT NOONE, MD
WILLIAM D. JONES III, MD
Philadelphia

Report on Levamisole Hydrochloride for Warts

To the Editor.—Levamisole hydrochloride, an antihelminthic, has been reported as a successful method for treating resistant warts.[1] In view of the difficulty of treating some patients with persistent recurring warts, it seemed worthy to further pursue the evaluation of levamisole for this indication. Ten patients from my private practice who have a history of chronic, resistant warts were entered into the study. However, two were lost to follow-up and were therefore deleted from all tabulations and analyses. Of the remaining eight patients, four were male and four were female. The ages ranged from 7 to 57 years.

Response to Levamisole

Patient	No. of Warts Pretreatment	No. of Warts Posttreatment
1	15	1
2	4	1
3	3	0
4	13	22
5	16	0
6	6	6
7	15	0
8	10	20

Each patient was instructed to take 150 mg of levamisole hydrochloride on two consecutive days a week. The patients were treated for periods up to seven months. Of the eight patients entering the study and completing treatment, three had complete regression of their warts. Two other patients had a significant beneficial effect from the levamisole therapy (Table). Two of the patients who did not respond were clearly obese and may have been underdosed. The third patient who had no response was a 27.6-kg, 7-year-old child who actually had an increased number of warts. This patient may have been overdosed. The only adverse reaction reported was stomach cramps in one patient who was unable to continue the therapy.

The natural history of warts is one in which spontaneous regression can occur. It is also known that there can be a significant placebo effect. However, all the patients in this study have suffered from warts for one to six years and had previously been treated for 4 to 21 months with conventional therapy. More studies, particularly double-blind studies, are necessary to evaluate the effectiveness of levamisole in the treatment of this common dermatologic condition.

JOSEPH D. SUTTON, MD
Suffern, NY

1. Helin P, Bergh M: Levamisole for warts. *N Engl J Med* 291:1311, 1974.

Nonproprietary Name and Trademark of Drug

Levamisole hydrochloride.—*Tramisol.*

"The First Report of. . ."

To the Editor.—"To the best of our knowledge, this is the first report of . . ." is one of those hackneyed phrases that evokes a yawn from the average medical journal reader. If the claim is unjustified, a sense of mild irritation may accompany the yawn. The recent article by Campo and McDonald (112:687-689, 1976) elicited such a reaction. Contrary to the self-serving statement of these authors, Neldner and Hambridge published the first report of the successful treatment of acrodermatitis enteropathica with zinc sulfate in the US literature (*N Engl J Med* 292:879-882, 1975). Since this report appeared prior to the publication acceptance date of the article by Campo and McDonald, there was plenty of time for these authors to amend their final manuscript prior to actual publication.

Not satisfied with trying to be "first in the US," Campo and McDonald seek even greater glory by proudly proclaiming that their paper is "possibly the second formal case report in the world literature" describing successful treatment of acrodermatitis enteropathica with zinc sulfate. The authors apparently consider Moynahan's 1974 report of nine patients so treated as "informal" and therefore unworthy (*Lancet* 2:399-400, 1974). Nevertheless, they overlooked a "formal" paper published one year ago, describing five patients with acrodermatitis enteropathica successfully treated with zinc.

Contributors to medical journals should address themselves to the question, "what's important?" not "who's first?" Treatment of acrodermatitis enteropathica with zinc *is* important; who was "first in the US" or "second in the world" to use this treatment is not.

DAVID A. VORON, MD
Arcadia, Calif

Chondrodermatitis Nodularis

To the Editor.—Chondrodermatitis of the ears was first described by Winkler[1] in 1915 under the title of "Chondrodermatitis Nodularis Chronica Helicis." The lesions described in that study were small painful nodules with central crusts. The first report in the American literature was Foerster's[2] in 1918 that reported painful nodular growths on the helix of the ear. Since these original case descriptions, further case reports have shown this lesion to be characterized as a painful nodule that occurs primarily in patients older than 40 years of age and rarely occurs before one is 20 years of age. Men are involved in approximately 90% of the cases in which the lesions occur predominantly located on the helix of the ear. Less common sites include the antihelix, tragus, concha, and the antitragus. This entity, infrequently described in women, seems to occur more often on the antihelix than on the helix. This observation has led some investigators to believe that the pathogenesis of these two lesions is different.[3]

I have recently treated a patient from whom a biopsy specimen was taken that proved chondrodermatitis nodularis, as interpreted by Dr. Daniel Richfield, and report it because of its unusual nature. The patient was an 18-year-old, white woman who had a four-month history of a completely asymptomatic nodule on the superior posterior aspect of her right ear. The lesion was a firm nodule that had a central crust that on removal yielded a small, well-defined ulcer that was nontender. Biopsy of the nodule revealed the diagnosis of chondrodermatitis nodularis. I report this interesting case because of the unusual location, the asymptomatic nature, and the early onset in an adolescent female.

ARNOLD I. LESTER, MD
Cincinnati

1. Winkler M: Knötchen Erkrankung am Helix. *Arch Dermatol Syph* 121:278-285, 1915.
2. Foerster OH: A painful nodular growth of the ear. *J Cutan Dis* 36:154-156, 1918.
3. Barker LP, Young AW, Sachs W: Chondrodermatitis of the ears: A differential study of nodules of the helix and antihelix. *Arch Dermatol* 81:15-25, 1960.

Penetration of Topical Steroid Preparations

To the Editor.—We read with interest the comments of Drs Lee and Rapp in your columns (*Arch Dermatol* 112:261, 1976). We agree with them that increased percutaneous penetration and increased potency of topical corticosteroids will not solve all the problems of inflammatory skin disease. It has long been recognized that increased percutaneous penetration leads to adverse systemic effects such as suppression of the hypothalamic-pituitary-adrenal (HPA) axis, although this has so far been observed mainly in children, adults with extensive inflammed skin, or adults treated with occlusion.

Recently, a new topical corticosteroid, clobetasol propionate (Dermovate cream and ointment [Britain]) has been marketed in this country. It was found to be extremely effective and is now widely used. However, after a period, cases of pustular psoriasis began to appear, generally following cessation of treatment with this preparation. Some patients were clinically Cushingoid and showed evidence of adrenocortical insufficiency on withdrawal of the topical corticosteroid, even though occlusion had not been used. These patients were shown to have pituitary-adrenal axis suppression.[1] This is analogous to the appearance of pustular psoriasis on withdrawal of systemic corticosteroids.[2]

Impressed with the potency of this corticosteroid formulation, we examined its effect on volunteers with normal skin; 12.5 gm of the cream applied to half the body surface area without occlusion was sufficient to produce profound HPA axis suppression in the majority of subjects.[3] We concluded from data on patients and normal volunteers that the "safe" weekly dose of clobetasol propionate is less than 50 gm.

We believe that the search should not be for increased potency and percutaneous penetration. It is essential to discover whether the effect on the epidermis and dermis may be separated from each other and from the systemic effects. Glaxo Laboratories Ltd, the manufacturer of Dermovate, have recently reported an attempt to do this with clobetasone butyrate (Molivate), although this assertion has yet to be proved in clinical practice. We think this is a more fruitful line for future investigations.

J. A. CARRUTHERS
R. C. D. STAUGHTON
P. J. AUGUST
London

1. Staughton RCD, August PJ: Cushing's syndrome and pituitary-adrenal suppression due to clobetasol propionate. *Br Med J* 2:419, 1975.
2. Baker H, Ryan TJ: Generalised pustular psoriasis: A clinical and epidemiological study of 104 cases. *Br J Dermatol* 80:771, 1968.
3. Carruthers JA, August PJ, Staughton RCD: Observations on the systemic effect of topical clobetasol propionate (Dermovate). *Br Med J* 4:203, 1975.
4. Munro DD, Wilson L: Clobetasone butyrate, a new topical corticosteroid: Clinical activity and effects on pituitary-adrenal-axis function and model of epidermal atrophy. *Br Med J* 3:626-628, 1975.

Demonstration of Herpes Virus by Electron Microscopy in the Crust of a Healing Lesion of Eczema Herpeticum

To the Editor.—The diagnosis[1,2] of eczema herpeticum can be confirmed or supported by demonstration of multinucleated epithelial giant cells in Tzanck cytological smears prepared from vesicular lesions; by demonstration of herpes simplex virus (HSV) particles by electron microscopy in phosphotungstic acid-stained material obtained from vesicle contents and base scrapings; by demonstration of multinucleated epithelial giant cells with eosinophilic intranuclear inclusions in biopsy specimen sections processed for light microscopy; by demonstration of HSV particles in biopsy specimen sections of vesicular lesions prepared for electron microscopy; by demonstration of direct culture of HSV from the lesions; by demonstration of HSV antigen in biopsy specimen sections by means of fluorescent antibody; or by demonstration of a rise in titer of HSV-specific antibody in the blood.

With the exception of the last method, fresh lesions are required for these diagnostic demonstrations since older herpetic lesions often yield negative results. The most frequently used diagnostic techniques have been the first three as listed.

We here report a case of widespread eczema herpeticum on the face and trunk of a 73-year-old woman with mycosis fungoides in whom only nonvesicular 3- to 4-mm crusted lesions were available for examination and where the diagnosis was established by electron microscopic demonstration of numerous HSV virions only in the crust of a healing lesion. In this case, Tzanck smear, electron microscopic examination of phosphotungstic acid-stained scrapings from the base of the lesions after removal of crusts, viral cultures, and examination of hematoxylin-eosin-stained biopsy specimen sections by light microscopy all failed to establish the diagnosis. The HE-stained sections revealed a regenerating epidermis covered with a purulent crust. A few grouped pyknotic nuclei (Fig 1) in the crust resembled degenerating multinucleated epithelial giant cells. The regenerating epidermis and hair follicles did not show multinucleated epithelial giant cells. A moderately dense inflammatory infiltrate in the dermis consisted of lymphocytes, histiocytes, neutrophils, a few plasma cells, and a few large, somewhat atypical mononuclear cells along with cellular debris.

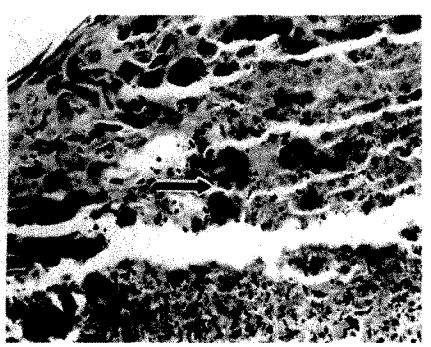

Fig 1.—Light micrograph showing grouped pyknotic nuclei (arrow) in crust of healing lesion (hematoxylin-eosin, original magnification × 500)

However, in the biopsy specimen sections prepared from a crusted lesion for electron microscopy, numerous HSV virions, many surrounded with envelopes, were observed only in the crust (Fig 2), the remainder of the epidermis and dermis being free of virus particles.

The purpose of this communication is to point out that even old crusted herpetic lesions can be used for definitely diagnostic demonstration of virus particles if crusts processed and sectioned for electron microscopy are examined.

Supported in part by a grant from the American Cancer Society.

MARIA MEDENICA, MD
THOMAS STEINBERG, MD
Chicago

1. Nohmias A, Roizman B: Infection with herpes simplex viruses I and II. *N Engl J Med* 289:781-788, 1973.

2. Liu C, Llanes-Rodas R: Application of the immunofluorescent technique to the study of pathogenesis and rapid diagnosis of viral infections. *Am J Clin Pathol* 57:829, 1972.

Fig 2.—Electron micrograph showing numerous virions (arrows) in crust (original magnification ×5,000).

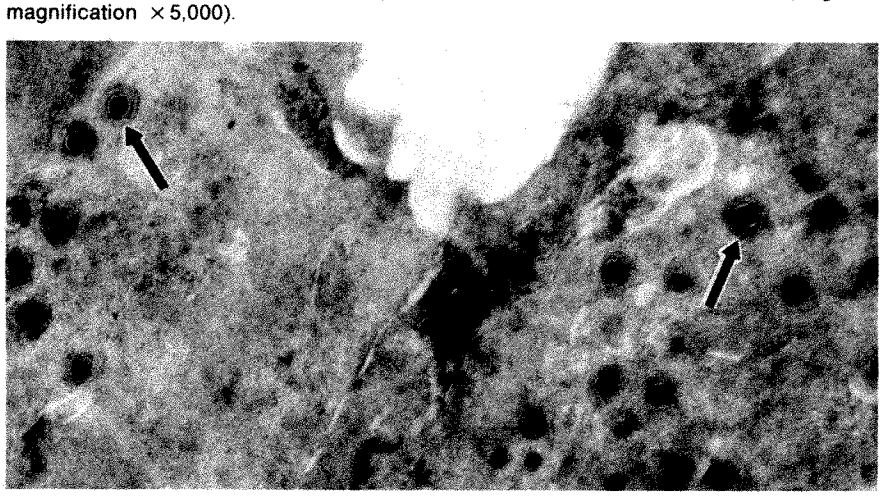

Allergic Reactions to Chocolate

To the Editor.—I am interested in finding the incidence of allergic reactions to chocolate because of a recent query I received from a chocolate manufacturer.

I would appreciate hearing from physicians the estimated number of their patients who are allergic to chocolate, and the symptoms produced. I would also appreciate receiving specific case reports, results of laboratory tests, and any other comments on the subject.

CLAUDE A. FRAZIER, MD
Asheville, NC

Viral Hepatitis Type B

To the Editor.—Since viral hepatitis type B is a major public health problem in the United States, the reevaluation of dermatological office procedures seems to be in order. Hepatitis B was formerly called serum hepatitis and was thought to be transmitted only by parenteral routes such as inoculation or blood transfusion. Recent evidence indicates that viral hepatitis type B can enter the body orally through mucous membranes or per cutaneously. Minute fissures of the hands could easily be a source of entrance of the virus. It is not an uncommon practice to perform various surgical procedures without

gloves, including the curettement of warts, basal cell carcinomas, and incision and drainage of acne lesions. A good source with regard to the epidemiology of viral hepatitis type B, particularly in health personnel, is a supplement on the control of viral hepatitis type B found in *Morbidity and Mortality Weekly Report* (25 (17): May 1976).

It is my contention that the dermatologist should wear disposable gloves with all surgical procedures, both for the protection of the patient if the physician might unknowingly be a viral hepatitis type B carrier, or obviously to protect the physician himself.

EDWARD M. MOSS, MD
Fresno, Calif

Pro and Con of Continuing Education

To the Editor.—There has been much discussion pro and con in regard to continuing education, self-assessment examinations, and recertification of board-certified dermatologists. Most of the efforts seem to be centered around the concept of "boning up" on the more academic and scholarly aspects of the ever-expanding developments in our specialty. We are enthusiastically in favor of these efforts to keep the troops in top form. There are, however, two sides to this coin. We think that while we as humdrum daily practitioners and bearers of the colors brace ourselves for the coming educational ordeal, it would only be fair that those who dedicate their lives to teaching and research and the care of only a few patients a day share in the fun and games.

What we are proposing is that those primarily engaged in research and teaching in turn be examined on their knowledge and ability in handling the large parade of mundane acne, wart, and hand eczema cases. We suggest that these individuals slip on a smock and for a week, nay even one day, and get into the trenches where the action really is. The private practitioner would, of course, serve as the peer evaluator and perforce come up with some sort of value judgment on the examinee's ability to handle the realities of the practice of dermatology.

It is all very well to say, as some have done recently, that the dermatologist should leave the warts and acne to the "primary" practitioner. Let's face it, *mes enfants*, we are now, willy nilly, practicing primary dermatology whether we like it or not. All of us in active practice, as our plantar calluses thicken, our fingers tingle with writers cramp, and our voices turn raspy with overuse, conjure up visions of the ideal practice—a relaxed armchair approach to some difficult and challenging referral, with adequate time to prove the nuances of the situation. But, alas, the harrassed family practitioner, an endangered species in our area, when presented with any (we underline any) skin case smilingly shrugs his shoulders, proudly proclaims his total ignorance of the field, and faster than one can say "chondrodermatitis nodularis helicis chronica" shuttles the patient to his friendly dermatological colleague who always seems able to work in "just one more."

We need to ask ourselves some questions. How important is it to treat our average run of patients with acne and warts with skill and dispatch? How much time do we allow for the difficult complicated situation while squads of angry eczema and psoriasis cases crowd our waiting rooms in frustrated impatience? Do we burden the already crowded hospitals with these toughies and spend the remainder of a hectic and exhausting day meticulously working them up? We speak now of brownie points for attending seminars and medical meetings and we consider the imperatives of accumulating thus and so many credits to maintain our peer standing. Shall we have no time now for simple vacations? Or will we consider ourselves fortunate just to get to enough busman's holidays at medical conclaves during the year to stay current?

We, the undersigned, do make an effort to keep up with things within the limits of our abilities. We do go to some meetings; we do read journals; we do listen to tapes; we do discuss cases even though we may not carry in our minds the classification of the xanthomas. The subtleties of the HLA antigens and the complement cascade may not spring automatically to our lips, but we have the references in our private library and we know where and how to find them.

Think about it.

WILLIAM E. LAUR, MD
RANDAL E. POSEY, MD
JACK D. WALLER, MD
Amarillo, Tex

FULVICIN-U/F® Tablets brand of griseofulvin (microsize) tablets, U.S.P.
CLINICAL CONSIDERATIONS—
INDICATIONS Griseofulvin is indicated for the treatment of ringworm infections of the skin, hair, and nails, namely: *Tinea corporis, Tinea pedis, Tinea cruris, Tinea barbae, Tinea capitis, Tinea unguium* (onychomycosis) when caused by one or more of the following genera of fungi: *Trichophyton rubrum, Trichophyton tonsurans, Trichophyton mentagrophytes, Trichophyton interdigitalis, Trichophyton verrucosum, Trichophyton megnini, Trichophyton gallinae, Trichophyton crateriform, Trichophyton sulphureum, Trichophyton schoenleini, Microsporum audouini, Microsporum canis, Microsporum gypseum, Epidermophyton floccosum.*
NOTE: Prior to therapy, the type of fungi responsible for the infection should be identified.
The use of this drug is not justified in minor or trivial infections which will respond to topical agents alone.
Griseofulvin is not effective in the following: Bacterial infections, Candidiasis (Moniliasis), Histoplasmosis, Actinomycosis, Sporotrichosis, Chromoblastomycosis, Coccidioidomycosis, North American Blastomycosis, Cryptococcosis (Torulosis), *Tinea versicolor*, Nocardiosis.
CONTRAINDICATIONS This drug is contraindicated in patients with porphyria, hepatocellular failure, and in individuals with a history of sensitivity to griseofulvin.
WARNINGS **Prophylactic usage:** Safety and efficacy of griseofulvin for prophylaxis of fungal infections have not been established.
Animal toxicology: Chronic feeding of griseofulvin, at levels ranging from 0.5-2.5% of the diet, resulted in the development of liver tumors in several strains of mice, particularly in males. Smaller particle sizes result in an enhanced effect. Lower oral dosage levels have not been tested. Subcutaneous administration of relatively small doses of griseofulvin, once a week, during the first three weeks of life has also been reported to induce hepatomata in mice. Although studies in other animal species have not yielded evidence of tumorogenicity, these studies were not of adequate design to form a basis for conclusions in this regard.
In subacute toxicity studies, orally administered griseofulvin produced hepatocellular necrosis in mice, but this has not been seen in other species. Disturbances in porphyrin metabolism have been reported in griseofulvin-treated laboratory animals. Griseofulvin has been reported to have a colchicine-like effect on mitosis and cocarcinogenicity with methylcholanthrene in cutaneous tumor induction in laboratory animals.
Usage in pregnancy: The safety of this drug during pregnancy has not been established.
Animal reproduction studies: It has been reported in the literature that griseofulvin was found to be embryotoxic and teratogenic on oral administration to pregnant rats. Pups with abnormalities have been reported in the litters of a few bitches treated with griseofulvin. Additional animal reproduction studies are in progress.
Suppression of spermatogenesis has been reported to occur in rats, but investigation in man failed to confirm this.
PRECAUTIONS Patients on prolonged therapy with any potent medication should be under close observation. Periodic monitoring of organ system functions, including renal, hepatic, and hematopoietic, should be done.
Since griseofulvin is derived from species of *Penicillium*, the possibility of cross sensitivity with penicillin exists; however, known penicillin-sensitive patients have been treated without difficulty.
Since a photosensitivity reaction is occasionally associated with griseofulvin therapy, patients should be warned to avoid exposure to intense natural or artificial sunlight. Should a photosensitivity reaction occur, lupus erythematosus may be aggravated.
Griseofulvin decreases the activity of warfarin-type anticoagulants so that patients receiving these drugs concomitantly may require dosage adjustment of the anticoagulant during and after griseofulvin therapy.
Barbiturates usually depress griseofulvin activity and concomitant administration may require a dosage adjustment of the antifungal agent.
ADVERSE REACTIONS When adverse reactions occur, they are most commonly of the hypersensitivity type, such as skin rashes, urticaria, and rarely, angioneurotic edema, and may necessitate withdrawal of therapy and appropriate counter-measures. Paresthesias of the hands and feet have been reported rarely after extended therapy. Other side effects reported occasionally are oral thrush, nausea, vomiting, epigastric distress, diarrhea, headache, fatigue, dizziness, insomnia, mental confusion, and impairment of performance of routine activities.
Proteinuria and leukopenia have been reported rarely. Administration of the drug should be discontinued if graulocytopenia occurs.
When rare, serious reactions occur with griseofulvin, they are usually associated with high dosages, long periods of therapy, or both.
AVAILABLE in 125 mg., 250 mg., and 500 mg. scored tablets.
010 AUGUST 1973
For more complete details, consult package insert or Schering literature available from your Schering Representative or Professional Services Department, Schering Corporation, Kenilworth, New Jersey 07033.

SUSTAINED THERAPEUTIC PLASMA LEVELS WITH ONLY ONE TABLET A DAY

Schering

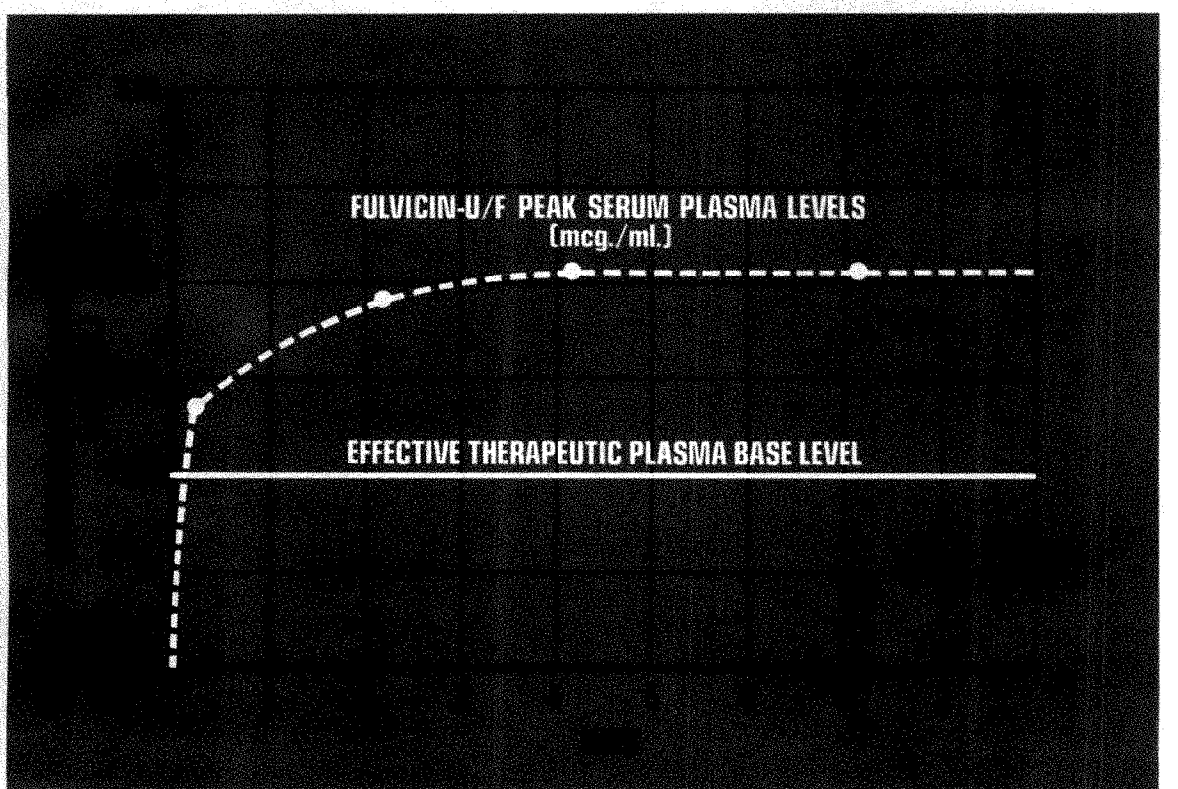

Adapted from Symchowicz, S., and Katchen, B.: J. Pharm. Sci. 57:1383, 1968.

The above graph depicts average peak serum plasma levels of FULVICIN-U/F following once-daily dosage of one FULVICIN-U/F 500 mg. tablet given before breakfast to six normal subjects for a seven-day period.

Hours of fungistatic action at ringworm sites

The above graph on plasma levels of FULVICIN-U/F 500 mg. in once-daily dosage indicates that this dosage is adequate to keep the antibiotic available for antifungal action in the keratin precursor cells where fungi have invaded. With the growth checked by the fungistatic action, the fungi are cast off as the keratin grows out and sloughs off. Healthy tissue replaces infected keratin of skin, hair, and nails.

Clinical efficacy, safety, and convenience

The Ultra-Fine form of FULVICIN®—in clinical use for over 15 years—possesses two vital keys to success in long-term ringworm therapy: product familiarity, and the confidence that comes after years of effective and safe therapy. For your patient: dosage simplicity. The easy-to-remember, once-a-day routine that helps avoid dosage delinquency and the possibility of therapeutic setbacks when therapeutic plasma levels are not maintained.

FULVICIN-U/F® 500mg.

brand of

griseofulvin [microsize] tablets, U.S.P.

JUST ONCE a DAY

See Clinical Considerations on opposite page.

COPYRIGHT © 1975, SCHERING CORPORATION. ALL RIGHTS RESERVED.

SLS-534

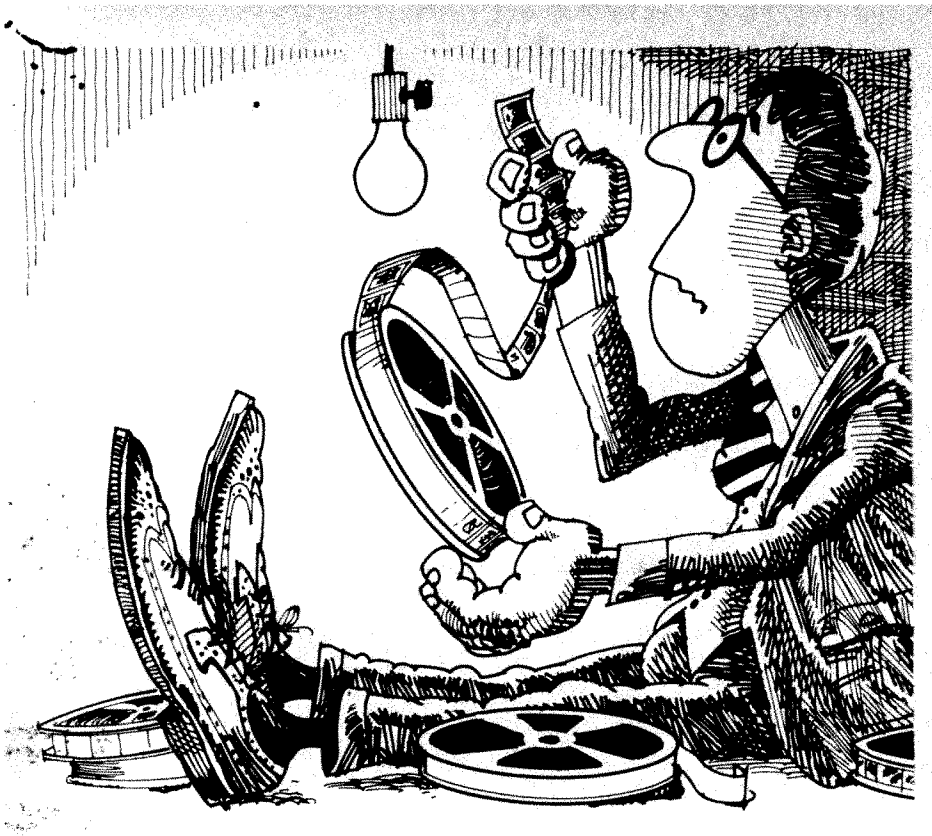

a quick reference to the AMA's large collection of medical films

and its yours free with the coupon below

You'll find nearly 100 pages of medical motion picture titles and descriptions in this new catalog—well over 300 titles and many of them brand new! All are available on loan basis for a slight service charge.

Reserve your copy today—supply is limited.

S/J

American Medical Association
535 N. Dearborn St.
Chicago, Ill. 60610
ATTN: Dept. of Audio Visual
Self Learning Programs.

Please send me your catalog:
AMA Medical Health Film Library 1976 when it's ready.

Name _____

Title _____

Organization _____

Address _____

City _____

State/Zip _____

Sulfoxyl® Lotion Regular ℞
Sulfoxyl® Lotion Strong
Composition: Sulfoxyl Lotion Regular contains 5% benzoyl peroxide and 2% sulfur; Sulfoxyl Lotion Strong contains 10% benzoyl peroxide and 5% sulfur, each in a lotion base formulated with polyethylene glycol monostearate, stearic acid, glycerol monostearate, isopropyl palmitate, propylene glycol, zinc soap and purified water.
Indications: Use as a topical aid in the treatment of acne.
Dosage and Administration: After cleansing the skin, smooth Sulfoxyl Lotion gently into the affected areas, once daily for three days. If no discomfort is felt, frequency of application can then be increased to twice daily. The amount of drying and desquamation can be modified by adjusting the dosage schedule.
Contraindications: Patients with a known sensitivity to benzoyl peroxide, sulfur or any of the other formulation ingredients should not use these medications.
Precautions: For external use only. Avoid contact with eyes, mucous membranes and sensitive areas of the neck. Notify physician if excessive dryness or irritation occurs or increases.
Keep from heat.
Caution: Patients should be warned that these formulations may bleach colored linens, towels and apparel.
How Supplied: 1.0 ounce plastic bottles.
Caution: Federal law prohibits dispensing without prescription.

Benoxyl® 5 and 10 Lotion: Benoxyl 5 contains 5% benzoyl peroxide and Benoxyl 10, 10% benzoyl peroxide in a grease-free washable lotion base.
How Supplied: 1 oz. and 2 oz. plastic bottles.

PanOxyl® 5, PanOxyl® 10 ℞
Composition: PanOxyl 5 contains 5% Benzoyl Peroxide. PanOxyl 10 contains 10% Benzoyl Peroxide. PanOxyl 5 and PanOxyl 10 also contain 6% polyoxyethylene lauryl ether and 40% ethyl alcohol in a gel base formulated with colloidal magnesium aluminum silicate, hydroxypropylmethylcellulose, citric acid and purified water.
Action and Uses: The topical use of PanOxyl 5 and PanOxyl 10 provides therapeutic control of acne through drying and desquamative action, as well as providing antiseptic activity.
Indications: Use as an aid in the treatment of acne.
Dosage and Administration: Apply 1 or more times daily to affected areas. Washing the face with soap and water prior to application greatly enhances the efficacy of the medication.
Contraindications: Patients with a known sensitivity to Benzoyl Peroxide should not employ these medicatons.
Precautions: For external use only. Avoid contact with the eyes or mucosal membranes. Very fair individuals should always be started on a single application at bedtime, allowing the medication to remain on the skin overnight. PanOxyl may bleach colored fabrics.
How Supplied: 2 oz. and 4 oz. plastic tubes.
Caution: Federal law prohibits dispensing without prescription.

STIEFEL
Logical Dermatologicals since 1847

Stiefel Laboratories, Inc.,
Oak Hill, N.Y. 12460
Stiefel Laboratories (Canada) Ltd.,
St. Laurent, Quebec, Canada H4R 1E1

Th. ee Dimensions of Acne Care

The widest range of benzoyl peroxide formulations gives you maximum therapeutic flexibility

New Sulfoxyl® Lotion

The drying and desquamating effects of sulfur added to benzoyl peroxide can be particularly valuable in acne complicated by excessive oiliness. "...Sulfur with benzoyl peroxide produces a greater keratolytic effect than either substance alone."[1] The exfoliative properties of sulfur can help benzoyl peroxide to penetrate deeper into sebaceous follicles.

Two Strengths:
Sulfoxyl® Lotion Regular (5% benzoyl peroxide and 2% sulfur) and Sulfoxyl® Lotion Strong (10% benzoyl peroxide and 5% sulfur) in a grease-free washable base.

Benoxyl® Lotion

A good way to start benzoyl peroxide therapy. Benzoyl peroxide alone has been described as "a triple action drug: (1) it suppresses *C. acnes* in vivo; (2) it is comedolytic and (3) it is a counter-irritant."[3]

Two Strengths
Benoxyl® 5 Lotion (5% benzoyl peroxide) and Benoxyl® 10 Lotion (10% benzoyl peroxide) in a grease-free washable base.

PanOxyl® Gel

"The most potent forms of benzoyl peroxide are the new alcohol gels such as PanOxyl. Once the gel is applied to the skin, the solvent evaporates and deposits a concentrated form of depot free-radical oxygen which...is capable of penetrating into the sebaceous follicles and suppressing the *C. acnes*. This topical agent is much more effective in suppressing the fatty acids and the bacterial counts than systemic tetracycline and also produces a more rapid clinical improvement... No new lesions usually appear after 3 weeks and after 2 months the patient is usually free of the acne problem."[2]

Two Strengths:
PanOxyl® 5 Gel (5% benzoyl peroxide) and PanOxyl® 10 Gel (10% benzoyl peroxide) in an alcohol gel base.

STIEFEL

Stiefel Laboratories, Inc., Oak Hill, New York 12460
Stiefel Laboratories (Canada) Ltd.
St. Laurent, Quebec, Canada H4R 1E1
Logical Dermatologicals since 1847

e opposite page for prescribing information

Kirton, V. and Wilkinson, D.S.: *Practitioner*. **204**: 683, 1970 2. Fulton, J.E., Jr.: Acne Vulgaris. *Current Ther.* ed. Conn, H.F., 558-560, 1975
Fulton, J.E., Jr. et al. in *Acne Morphogenesis and Treatment*. Plewig, G. and Kligman, A.M., Springer-Verlag, 290-1, 1975

Tars have an important place in the management of seborrhea and psoriasis, but there is no clear cut agreement on when to use which.
A prudent approach:

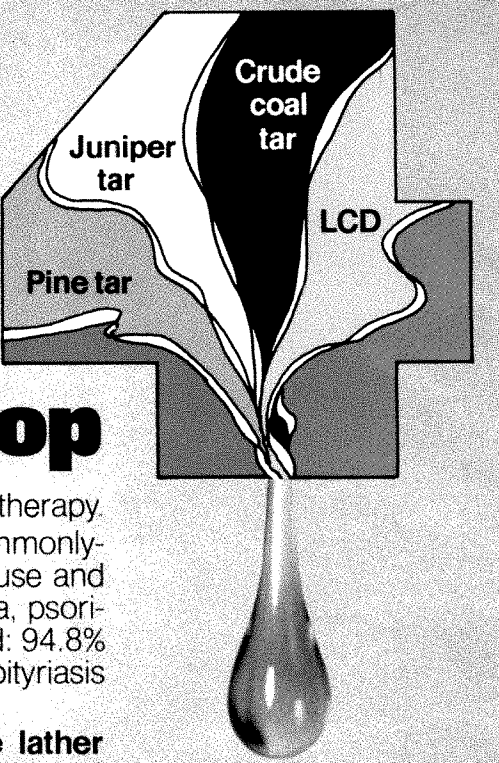

Four tars in every golden drop

Now, a spectrum of tars maximizes the benefits of tar therapy. Polytar® Shampoo combines four of the most commonly-prescribed tars in one formula that is pleasant to use and therapeutically effective against dandruff, seborrhea, psoriasis and pityriasis capitis. Excellent results reported: 94.8% "very good" and 5.2% "good" in one study of both pityriasis capitis and psoriasis.*

And patients are pleased with the pure white lather that is as esthetically pleasing as a fine cosmetic and leaves hair lustrous and manageable.

*Bastos, A. O Medico, Vol. LXVI: 758-762, 1973

Polytar®
Shampoo

STIEFEL

Stiefel Laboratories, Inc., Oak Hill, New York 12460
Stiefel Laboratories (Canada) Ltd., St. Laurent, Quebec, Canada H4R 1E1
Logical Dermatologicals since 1847

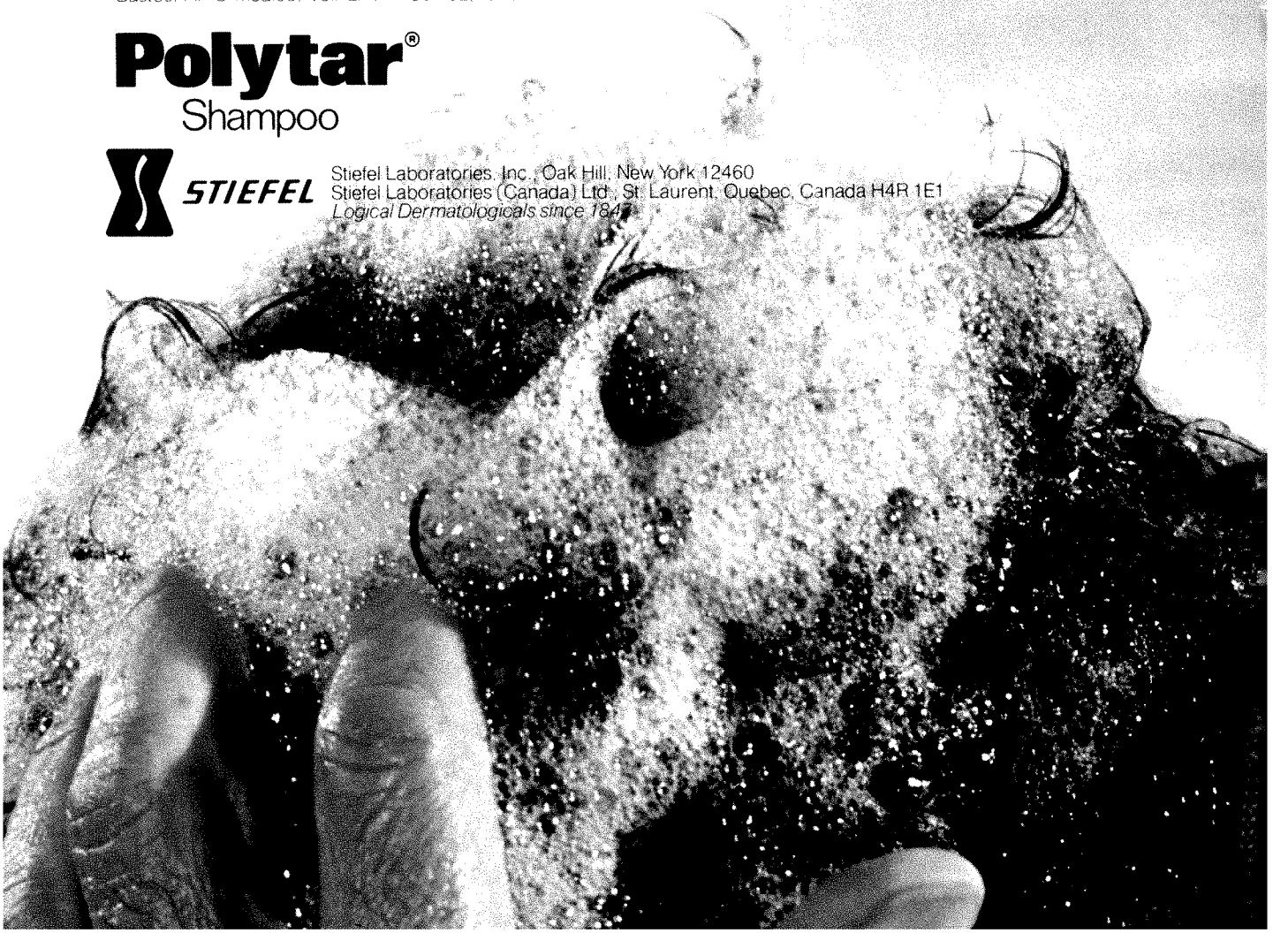

Books

Malignant Melanoma: Clinical and Histological Diagnosis, by Vincent J. McGovern, MD, 178 pp, 121 illus, $22.50, John Wiley & Sons, Inc, 1976.

Melanoma is one of the oversubscribed subjects. Perhaps more is written about this cutaneous tumor in a year than on any other comparable topic in dermatology. Now, Vincent McGovern, a long-standing giant in the field, offers a slim, slick volume about melanoma that is neatly divided into 12 short essays, commencing with "Pigmented Nevi" and concluding with "Problems." The book is a good deal thinner than the listed pages, because in addition to pictures and text there are very wide margins and numerous blank pages, presumably for notes. In addition, while many of the pictures are of good quality and well printed, others are not, and there are no color prints of clinical lesions. Even more appalling is the hasty and unevenly written text which at times is downright awkward. Basically it reflects Dr McGovern's own personal experiences and his assessment of the literature before 1974. Since the melanoma field is rapidly evolving, the book will offer little to experts in the field because it does not consider or evaluate the newer information developed subsequent to 1974. Also most of the information has been published elsewhere and is fairly common knowledge, so that informed residents will gain nothing from an encounter with this book. Perhaps the only persons to benefit would be young medical students becoming interested in the field of melanoma for the first time and advanced nursing students. I predict this period piece will languish on medical school library shelves as a historical contribution. As of 1977 it is virtually out of date.

WILLIAM L. EPSTEIN, MD
San Francisco

Biomedical Aspects of Human Wart Virus Infection (Proceedings of a Fondation Mérieux Seminar held in Lyon, France, Dec 15-16, 1975), edited by Michel Prunieras, 286 pp, with illus, Fondation Mérieux, 1976.

A famous Indian medicine man once stated categorically that "I don't fool around with no warts. There's more serious diseases to be worked on than warts." While many dermatologists heartily concur, virologists, molecular biologists, and cancer experts are looking at the wart virus as a potential probe to investigate transformation of human epidermal cells into benign hyperplasias called warts and into potentially malignant lesions of epidermodysplasia verruciformis. Because of this interest a small group of wartologists met in cold, dank Lyon in December 1975, where they were immeasurably warmed by the gracious hospitality, excellent food, and very stimulating and often speculative discussions. Fortunately the deliberations of the august group were recorded in a large paperback book edited by Michel Prunieras and available gratis on a first come, first served basis by writing to Dr Renee Triau in care of the Institut Merieux, 17, Rue Bourgelat, Lyon, France 69002.

The book is divided into three sections. The first consists of six papers concerned with in vivo and in vitro studies of the biologic behavior of papilloma viruses. The second part deals with the clinical appearance, especially of epidermodysplasia verruciformis, and a number of light and electron microscopic autoradiographic studies of these viral tumors in man. The final section consists of 15 papers on the immunology of human warts and overall is an excellent review of the subject. Although the book is printed on soft paper, there are innumerable large illustrations, many of which are of excellent quality, that clearly make the point that patients with epidermodysplasia verruciformis virtually look alike. It should be cautioned that because none of these papers were refereed, a degree of speculation creeps into many of the articles so that a wary reader will do well to keep a pinch of salt handy. However, the book is very easy reading, partially because it is printed in large, bold type, mostly in English, and it accurately portrays the state of the art at the present time. Unfortunately, the stimulating papers by Crossant and Orth presented at the seminar were not included in the final publication. Their important new studies with wart virus hybrids have been left out. The interested reader is referred to the later issues of the *Comptes Rendus Hebdomadaires des Seances de l'Academie des Sciences* where these authors are want to publish their findings. The sum—any freeloader who is interested in warts will be well served to spend a few pennies to write for this interesting and often intriguing volume.

WILLIAM L. EPSTEIN, MD
San Francisco

Selections From the Transactions of the Dermatological Society of Greater New York, excerpted and annotated by Henry Silver, MD, and Morris Leider, MD, assisted by Andrew G. Franks, MD, 587 pp, privately published, 1976.

This is an extraordinary publication—in numerous ways a unique one.

If you want to learn and read about recent theories of pathogenesis and find new laboratory procedures, do not look for them in this volume. But if you are as interested as every American dermatologist should be in the evidences of the day-by-day accre-

tion of clinical dermatologic knowledge, reading the fascinating presentations in this volume will bring you rich rewards.

There are also invaluable facts and findings brought to light in the 50 years of proceedings and the hundreds of case presentations and their discussions by the members of this relatively small, private, unendowed New York dermatological society. And in the progression of years, you will find documented the development of dermatology and syphilology during half a century covering one of the most critical and revolutionary periods of medicine. The gamut of diagnoses of rare and instructive cases and the profuse commentaries display the mutation of our specialty from a masterly, morphologically oriented discipline to a leading biological science that exercises profound influences on all clinical medicine.

But some of the most fascinating features of this book will be found between the lines. For example, you will find in these pages clear evidence of the melting pot of American medicine and proof of how much was contributed to medicine in the United States by the diversity of knowledge, background, training and philosophies of colleagues who emigrated from abroad. You will be sad to note in the sequential years of the discussions the demise of old tenets and approaches, devoutly held and fondly followed; and you will be astonished and pleased by the prescience and "modern" thinking—by the ideas and concepts—forcefully expressed so many years ago. Among these are numerous ideas and concepts that are being advanced as new today.

Perhaps the most impressive and remarkable of all is this volume's proof of how much can be accomplished by the dedication and ability of a small, heterogeneous group of physicians, held together, guided and inspired by a selfless and indefatigable leader, Dr Henry Silver, who founded the society in 1924 and has been its executive secretary and treasurer ever since. Every page of these annotated and edited transactions bears the stamp of Dr Silver's unflagging devotion, plus the etymological dexterity of Dr Morris Leider and the patient precision of Dr Andrew Franks.

I do not know where or how you can obtain this privately published book. But if you have an ounce of historical interest in dermatology, write and ask Dr Silver at 1 W 85th St, New York, NY 10024.

MARION B. SULZBERGER, MD
San Francisco

Seventh International Conference on Sarcoidosis and Other Granulomatous Disorders, edited by Louis E. Siltzbach, 751 pp, with illus, $53, New York Academy of Sciences, 1976.

Every year members of the New York Academy of Sciences are rewarded by being allowed to select gratis a number of volumes of the Annals of the New York Academy of Sciences. These volumes always include a wide range of interesting topics presented in the form of conferences or as monographs, and every member thus comes away satisfied with his or her selections. Unfortunately most of these volumes are never consulted again except for very special reasons. Since the center of medical interest has shifted westward from the New York environs, many young physicians are completely unaware of the Annals, and the data contained in these volumes often slips into the backwater of medical information.

As there are so many publications of the Annals, these are seldom if ever reviewed in the ARCHIVES, but it seemed appropriate to consider volume 278, *Seventh International Conference on Sarcoidosis and Other Granulomatous Disorders.* This 750-page volume is crammed with 83 reports, which cover all aspects of sarcoidosis including epidemiology, clinical, immunology, etiologic suggestions, and animal models, as well as therapy. The sections on other granulomas unfortunately cover a very small spectrum and concentrate for the most part on Crohn disease. Despite the unevenness of the reports and the fact the volume is published on inferior paper, which makes the photomicrographs and electron micrographs virtually useless, this book should be read by all scholars of sarcoidosis and granulomas and by others interested in learning the state of the art of this intriguing subject.

WILLIAM L. EPSTEIN, MD
San Francisco

DESCRIPTION

Synalar® (fluocinolone acetonide) has the c
6α, 9α-difluoro-16α-hydroxyprednisolone-16, 1

Synalar® Solution 0.01%—contains 0.01% fluo
acetonide in propylene glycol with citric ac

Synalar® Ointment 0.025%—contains 0.025%
acetonide in white petrolatum.

Synalar-HP® Cream—contains 0.2% fluocino
in a water-washable aqueous base of stear
alcohol, mineral oil, propylene glycol, sorbit
stearate, polyoxyethylene sorbitan monoste
citric acid, with methylparaben and propyl
preservatives.

Synemol™ (fluocinolone acetonide) has the
6α, 9α-difluoro-16α-hydroxyprednisolone-16, 1

The vehicle is a water-washable aqueous e
stearyl alcohol, cetyl alcohol, mineral oil, pro
sorbitan monostearate, polyoxyethylene sor
stearate and citric acid.

INDICATIONS

For relief of the inflammatory manifestations
steroid-responsive dermatoses.

CONTRAINDICATIONS

Topical steroids are contraindicated in vac
varicella.

Topical steroids are contraindicated in thos
history of hypersensitivity to any of the comp
preparation.

Synalar-HP Cream should not be used on in
years of age.

PRECAUTIONS

If irritation develops, the product should be
appropriate therapy instituted.

In the presence of an infection the use of ar
antifungal or antibacterial agent should be
favorable response does not occur promptl
steroid should be discontinued until the infe
adequately controlled.

If extensive areas are treated or if the occlus
used, the possibility exists of increased syste
of the corticosteroid and suitable precautio
taken.

Although topical steroids have not been repo
adverse effect on pregnancy, the safety of t
pregnant females has not absolutely been
Therefore, they should not be used extensive
patients, in large amounts, or for prolonged

Topical steroids are not for ophthalmic use.

Synalar-HP Cream should not be used for pr
and the quantity per day should not exceed
formulated material.

ADVERSE REACTIONS

The following local adverse reactions have
with topicalcorticosteroids: burning, itching,
dryness, folliculitis, hypertrichosis, acneform
hypopigmentation.

Synalar Cream and Ointment, Synemol Cre

The following may occur more frequently wi
dressings than without such therapy: macer
secondary infection, skin atrophy, striae, mili

HOW SUPPLIED

Synalar® (fluocinolone acetonide)
Cream 0.025%—15, 60 g tubes; 120, 425 g ja
Cream 0.01%—15, 45, 60 g tubes; 120, 425 g
Ointment 0.025%—15, 60 g tubes; 425 g jars.
Solution 0.01%—20, 60 cc plastic squeeze b
Synalar-HP® (fluocinolone acetonide) 0.2%
tubes.
Synemol™ (fluocinolone acetonide)
Cream 0.025%—15, 60 g tubes.

These preparations are available on prescri

SYNTEX
SYNTEX LABORATORIES, INC.
PALO ALTO, CALIFORNIA 94304

INFLAMMATION OF
CONTACT DERMATITIS

SOLVED

SYNALAR® TOPICALS

FLU[redacted]NIL[redacted]NIDE)

News and Notes

Fellowship in Bangkok, Thailand.—Anyone who is interested in a fellowship at the Institute of Dermatology, Bangkok, Thailand, may write to Dr Renoo Kotrajaras, Institute of Dermatology, 420/7 Rajavithi Rd, Bangkok 4.

Faculty Position.—The Department of Dermatology, University of California at San Francisco School of Medicine, is searching for a young dermatologist to set up a full-time research unit at San Francisco General Hospital. Candidates should be board eligible or board certified dermatologists who have had at least two years of basic science training and who would be willing to spend up to 75% of their time in the laboratory. Individuals with a chemistry background and who have worked with mediators of inflammation are encouraged to apply. The position being offered is for assistant professor, and the salary is negotiable. The University of California is an equal opportunity employer with an affirmative-action faculty recruitment program. Please send resumés or inquiries for further information to William L. Epstein, MD, chairman, Department of Dermatology, A-342, University of California, San Francisco, CA 94143.

American Board of Dermatology Examinations.—The next examinations of the American Board of Dermatology will be held on Nov 12, 13, and 14, 1977, in Chicago, at the Holiday Inn, O'Hare/Kennedy Convention Complex. The written and practical examinations will be given during a three-day period with all candidates taking both parts. All physicians who complete the required training by June 30, 1977, are eligible to apply to take the 1977 examinations. Applications must be received by the Board office by not later than June 1, 1977. Clarence S. Livingood, MD, Executive Director.

Annual Meeting.—The annual meeting of the Society for Investigative Dermatology, Inc, will be held at the Sheraton Park Hotel in Washington, DC, April 28 to 30, 1977.

Atlantic Dermatological Conference.—The next meeting of the Atlantic Dermatological Conference will be held at the Waldorf-Astoria Hotel, New York City, Friday and Saturday, May 6 and 7, 1977. Address all inquiries to Peter Lombardo, MD, 120 E 64th St, New York, NY 10021.

International Symposium.—An international symposium on dermatopathology entitled "Histological Differential Diagnosis of Skin Diseases," organized by the Department of Dermatology of the University of Munich, Germany, and the Departments of Dermatology and Pathology of New York University School of Medicine will be held in Munich, Germany, on Friday, Saturday, and Sunday, June 16 through 18, 1978. The chairman will be Otto Braun Falco, University of Munich and A. Bernard Ackerman, New York University School of Medicine. The symposium will be conducted in English, will have an international faculty, and will focus on 45 difficult problems in histologic differential diagnosis of cutaneous diseases. Special emphasis will be given to histologic patterns that are diagnostically distinctive of inflammatory skin diseases and to current concepts of cutaneous and systemic malignant lymphomas.

A special group flight at considerable savings for registrants in the symposium has been arranged. For additional information write to A. Bernard Ackerman, MD, Dermatopathology Section, New York University Medical Center, 562 First Ave, New York, NY 10016, or Helmut H. Wolff, MD, Dermatologische Klinik, Frauenlobstrasse 9, 8000 Munchen, West Germany.

Pacific Dermatologic Association Essay Contest.—The 29th annual meeting of the Pacific Dermatologic Association will be held in Portland, Ore, July 24-28, 1977. Each year the Pacific Dermatologic Association encourages young dermatologists to submit essays on original work. The Nelson Paul Anderson Memorial Essay Contest is open to all physicians who are in graduate dermatologic training or who are not more than five years from completing such training. Essays may be submitted by doctors residing in the geographical area of the Pacific Dermatologic Association, ie, the western United States (California, Oregon, Alaska, Nevada, Washington, Idaho, Utah, Arizona, Hawaii, Montana, Wyoming, Colorado, New Mexico), British Columbia and Alberta, Canada, Mexico, Australia, New Zealand, Japan, and the Philippines. The winning essayist will receive a cash prize of $500 and his expenses will be paid to the next annual meeting. Essays will be judged on the following considerations: (1) originality of idea, (2) potential importance of work, (3) evaluation of results, (4) experimental methods and use of control, and (5) clarity of presentations. Six copies of the essay shall be submitted under a nom de plume, with no information in the paper that will lead to recognition by the judges of the institution or clinic where the work was done. The essay with nom de plume shall be accompanied by a plain, sealed envelope enclosing the name and address and nom de plume of the author. Entries must be received by the secretary, Jack E. McCleary, MD, 4955 Van Nuys Blvd, Sherman Oaks, CA 91403, no later than June 1, 1977.

Desquam-X®

5 or 10% Benzoyl Peroxide 6% Polyoxyethylene Lauryl Ether

the topical side of C. acnes control

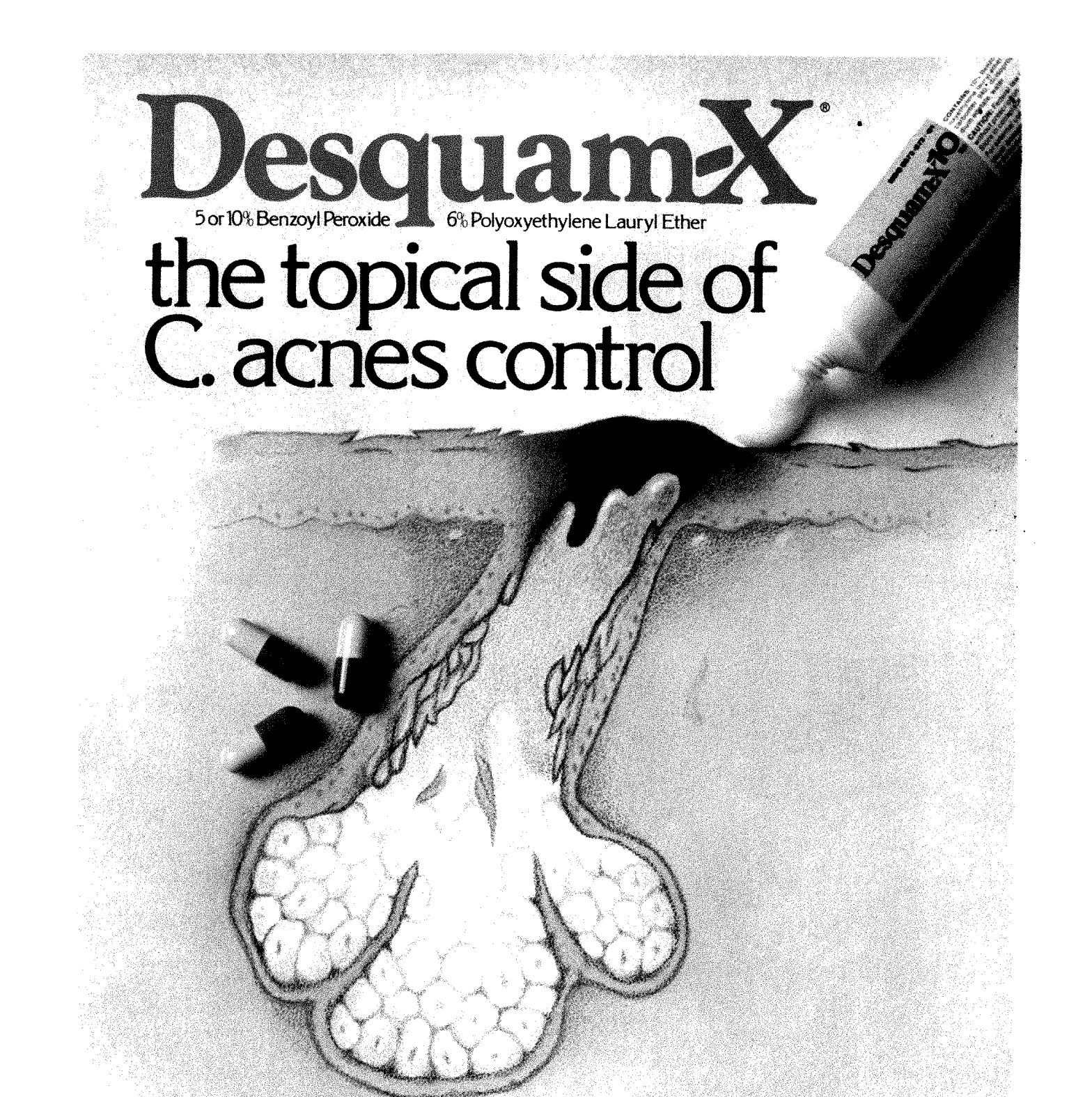

Desquam-X5®

Desquam-X10®

CONTENTS: Desquam-X 5 contains 5% Benzoyl Peroxide, 6% polyoxyethylene lauryl ether, 37% ethyl alcohol, carbomer 940, di-isopropanolamine, disodium edetate and water.

Desquam-X 10 contains 10% Benzoyl Peroxide, 6% polyoxyethylene lauryl ether, 37% ethyl alcohol, carbomer 940, di-isopropanolamine, disodium edetate and water.

INDICATION: A topical aid for the control of acne vulgaris.

ACTION: Provides the desirable drying and desquamation needed in the topical treatment of acne. Desquam-X has been demonstrated to have anti-bacterial effects, especially against Corynebacterium acnes.

DIRECTION FOR USE: After washing as instructed, rub Desquam-X into affected areas twice daily. In fair-skinned individuals or under excessively dry atmospheric conditions it is suggested that therapy be initiated with one application daily. The desired degree of drying and peeling can be obtained by modification of the dosage schedule.

CONTRAINDICATIONS: Not to be used in patients known to be sensitive to any ingredient of Desquam-X.

PRECAUTIONS: Avoid contact with eyes and mucous membranes. For external use only. Keep this and all medication out of the reach of children.

NOTE: May bleach colored fabrics.

HOW SUPPLIED: Plastic tubes 1.5 oz. (42.5 gm.)

CAUTION: Federal law prohibits dispensing without prescription.

WESTWOOD
PHARMACEUTICALS INC.
Buffalo, New York 14213
In Canada, Belleville, Ontario K8N1E2

©1975 W. P. Inc.

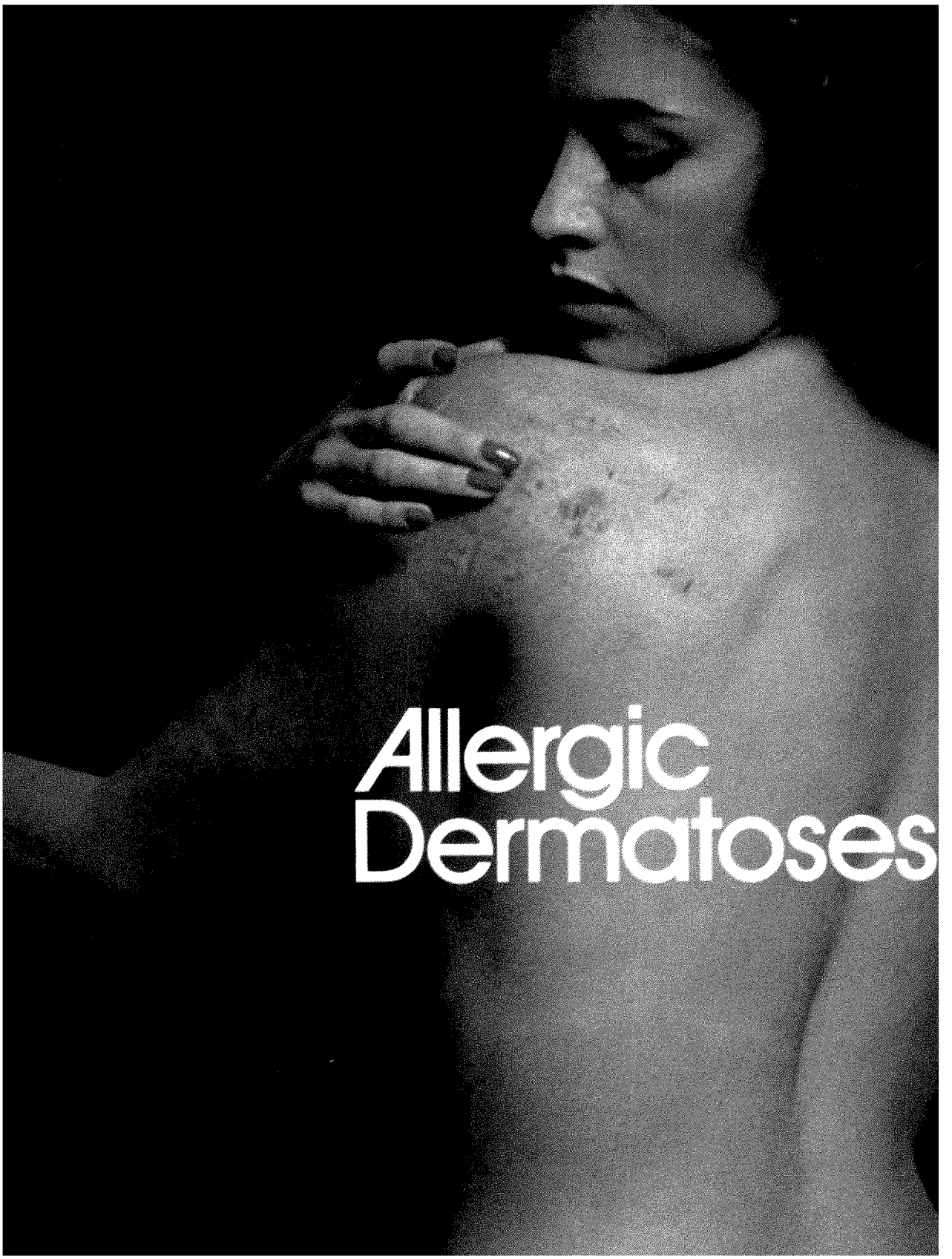
Allergic
Dermatoses

rat, and rabbit, induced fetal abnormalities in the rat at doses substantially above the human therapeutic range. Clinical data in human beings are inadequate to establish safety in early pregnancy. Until such data are available, hydroxyzine is contraindicated in early pregnancy.

Precautions: Hydroxyzine may potentiate the action of central nervous system depressants such as meperidine and barbiturates. In conjunctive use, dosage for these drugs should be reduced. Because drowsiness may occur, patients should be cautioned against driving a car or operating dangerous machinery.

Adverse Reactions: Drowsiness may occur; if so, it is usually transitory and may disappear in a few days of continued therapy or upon dosage reduction. Dryness of the mouth may occur with higher doses. Involuntary motor activity, including rare instances of tremor and convulsions, has been reported, usually with higher than recommended dosage.

Supply: Tablets, containing 10 mg, 25 mg, or 50 mg hydroxyzine hydrochloride, 100's and 500's; Tablets, containing 100 mg, 100's; Syrup, containing 10 mg per teaspoonful (5 ml) and ethyl alcohol 0.5% v/v, pint bottles.

Before prescribing or administering, see package circular.

with strong emotional overlay

the cause can be obscure

Factors precipitating allergic dermatoses with strong emotional overlay, which can range from allergens to anxiety, can be difficult to identify.

successful treatment often includes

Atarax®
(hydroxyzine HCl)

TABLETS: 10 mg, 25 mg, 50 mg, and 100 mg

- rapid antianxiety action
- demonstrated antihistaminic activity

For Skin Without Water

Neutrogena® Dry Skin products are specially formulated to supplement surface fats and aid in the retention of moisture.

- Neutrogena® Dry-Skin Soap contains humectants, lubricants, and emollients to soften and moisturize, and is nonirritating to sensitive skin.
- Neutrogena® Rainbath® Dry Skin Bath Gel is lipid-free, cleanses with a rich lather without the drying effect of ordinary soap, and leaves skin soft and smooth. Available both scented and unscented.
- Neutrogena® Hand Cream is a heavy-duty formula containing a special blend of naturally occurring oils and glycerin, and is a useful adjunct in steroid-responsive hand dermatoses.[1]

1. Da
Medi
Ne

Neutrogena®

Dedicated to Sensitive Skin Care

Neutrogena
5755 West 96th
Los Angeles, California

CLINICAL APPOINTMENTS

PHARMACEUTICAL RESEARCH

Selected client companies, long respected for leadership in medical research, offer attractive appointments to their clinical staffs. Candidates should have credentials from a first line medical school, with a background in internal medicine, pediatrics, dermatology, clinical pharmacology, anaesthesiology, cardiology or similar specialty area. Board or Board eligibility will be a distinct asset. Experience in industry will also be valuable, though not necessary. A serious interest in the design and assessment of clinical studies is, however, essential.

We believe, these appointments, together with their excellent fringe benefits, regularity of hours and association with professional associates working at the forefront of medical research offer an attractive, meaningful alternative for the physician.

Your curriculum vitae or similar particulars will re-

For the part-time occupational physician...



An invalua quick refe guide to occupatio dermatose

The AMA's new guid *Occupational Derma* is an invaluable aid physicians working time in occupationa programs.

It provides a read reference for specifi formation on the ca diagnosis, preventio treatment of occupa skin diseases. It also discusses manageme prolonged and recu

For Skin Plagued by Acne



Neutrogena® Acne products aid in drying while they clean and degrease acne-plagued skin.

- Neutrogena® Acne-Cleansing Soap gently cleanses and degreases the skin, and does not interfere with topical or systemic acne treatment.
- Neutrogena® Acne-Drying Gel combines antisepsis with astringency, contains 47% active drying agents, is perfume-free, can be applied under or over makeup, and is imperceptible on the skin.

Neutrogena®
Dedicated to Sensitive Skin Care

Neutrogena Corp.
5755 West 96th Street
Los Angeles, California 90045



Perma Tweez®

ELECTROLYSIS FOR PERMANENT HAIR REMOVAL

Clinical study (copy on request) proves safety and efficacy of laity self-use electrolysis. Study shows chin and even axilla can be self-treated effectively through use of mirror. This permanent hair remover features the only patented self-correcting needle in existence. Battery operated instrument sterilizes itself when current flows. No-puncture safety feature also helps prevent infection.

Thousands of units sold to physicians for such varied application as removal of inverted eyelashes to cosmetic use.

PERMA TWEEZ & ATTACHMENT $22.45

☐ Invoice after 30 days

☐ Check enclosed

30 DAY FREE TRIAL EXAMINATION

(MAY BE RETURNED WITH NO OBLIGATION)

GENERAL MEDICAL CO., Dept. D-84
1935 Armacost Ave
West Los Angeles, CA 90025

DR _____
STREET _____
C/S _____ ZIP _____

antifungal
antipruritic
antibacterial
anti-
inflammatory
TAXI

Clear choice

When dermatoses become infected with bacteria or fungi, plain topical steroids are generally not the recommended therapeutic choice.

A clear choice, however, is Vioform-® Hydrocortisone. With its unique four-way action, it supplies the kind of comprehensive treatment many common dermatoses* require.

*This drug has been evaluated as possibly effective for these indications. See brief prescribing information.

Vioform®-Hydrocortisone
(iodochlorhydroxyquin and hydrocortisone)

INDICATIONS
Based on a review of this drug by the National Academy of Sciences-National Research Council and/or other information, FDA has classified the indications as follows:
"Possibly" effective: Contact or atopic dermatitis; impetiginized eczema; nummular eczema; infantile eczema; endogenous chronic infectious dermatitis; stasis dermatitis; pyoderma; nuchal eczema and chronic eczematoid otitis externa; acne urticata; localized or disseminated neurodermatitis; lichen simplex chronicus; anogenital pruritus (vulvae, scroti, ani); folliculitis; bacterial dermatoses; mycotic dermatoses such as tinea (capitis, cruris, corporis, pedis); moniliasis; intertrigo. Final classification of the less-than-effective indications requires further investigation.

CONTRAINDICATIONS
Hypersensitivity to Vioform-Hydrocortisone, or any of its ingredients or related compounds; lesions of the eye; tuberculosis of the skin; most viral skin lesions (including herpes simplex, vaccinia, and varicella).

WARNINGS
This product is not for ophthalmic use.
In the presence of systemic infections, appropriate systemic antibiotics should be used.

Usage in Pregnancy
Although topical steroids have not been reported to have an adverse effect on pregnancy, the safety of their use in pregnant females has not been established. Therefore, they should not be used extensively on pregnant patients in large amounts or for prolonged periods of time.

PRECAUTIONS
May prove irritating to sensitized skin in rare cases. If this occurs, discontinue therapy. May stain.
If used under occlusive dressings or for a prolonged period, watch for signs of pituitary-adrenal axis suppression.
May interfere with thyroid function tests. Wait at least one month after discontinuance of therapy before performing these tests. The ferric chloride test for phenylketonuria (PKU) can yield a false-positive result if Vioform is present in the diaper or urine.
Prolonged use may result in overgrowth of nonsusceptible organisms requiring appropriate therapy.

ADVERSE REACTIONS
Few reports include: Hypersensitivity, local burning, irritation, pruritus. Discontinue if untoward reaction occurs. Rarely, topical corticosteroids may cause striae at site of application when used for long periods in intertriginous areas.

DOSAGE
Apply a thin layer to affected areas 3 or 4 times daily.

HOW SUPPLIED
Cream, 3% iodochlorhydroxyquin and 1% hydrocortisone in a water-washable base containing stearyl alcohol, cetyl alcohol, stearic acid, petrolatum, sodium lauryl sulfate, and glycerin in water; tubes of 5 and 20 Gm. *Ointment*, 3% iodochlorhydroxyquin and 1% hydrocortisone in a petrolatum base; tubes of 20 Gm. *Lotion*, 3% iodochlorhydroxyquin and 1% hydrocortisone in a water-washable base containing stearic acid, cetyl alcohol, lanolin, propylene glycol, sorbitan trioleate, polysorbate 60, triethanolamine, methylparaben, propylparaben, and perfume Flora in water; plastic squeeze bottles of 15 ml. *Mild Cream*, 3% iodochlorhydroxyquin and 0.5% hydrocortisone in a water-washable base containing stearyl alcohol, cetyl alcohol, stearic acid, petrolatum, sodium lauryl sulfate, and glycerin in water; tubes of ½ and 1 ounce. *Mild Ointment*, 3% iodochlorhydroxyquin and 0.5% hydrocortisone in a petrolatum base; tubes of 1 ounce.

Consult complete product literature before prescribing.

CIBA Pharmaceutical Company
Division of CIBA-GEIGY Corporation
Summit, New Jersey 07901

2/6867 17

Vioform®-Hydrocortisone
(iodochlorhydroxyquin and hydrocortisone)

The most widely prescribed form... 20-Gm Cream

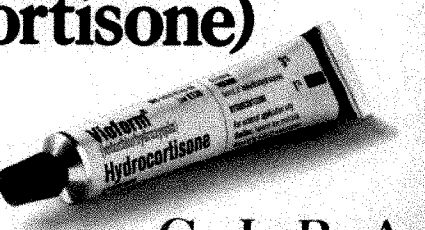

CIBA

ok closely at these patients. heir dermatologist had them on a KOMEX®/KOMED® regimen.

Step 1 KOMEX®

"...toward keeping the skin meticulously clean...to decrease the usually concomitant oiliness."[1]

Cleanses thoroughly yet gently.

The detergent cleansing effect of Komex acne cleanser is uniquely enhanced with mild dissolving sodium borate particles (Scrubules) for effective yet gentle cleansing of the skin. Komex removes surface debris. Clears comedones. Cleans clogged pores. Unplugs hair follicles. And removes oils.

Mild abradancy won't damage skin.

"A frequently overlooked source of excessive friction is the practice of vigorous scrubbing in an attempt to wash acne away. The use of brushes and other scrubbing techniques can induce significant inflammatory lesions...Elimination of sources of excessive friction lead to rapid improvement[2]

The patented Komex Scrubules enable doctor and patient to control particle dissolution from 0-60 seconds, depending on water dilution. Acne patients can't overabrade with Komex. A significant exclusive.

Conditions the skin.

In fact, the skin *conditioning* effect of Komex acne soap is truly phenomenal. You can detect some of it in the patient photos. But it really must be seen – and felt.

Step 2 KOMED®

"...to peeling of the skin so that the follicular orifices are kept open."[1]

Employs a non-comedogenic form of sulfur.

Komed Lotion works beautifully with Komex.
"The sovereign remedy in the topical management of acne vulgaris is sulfur."[3]
"Sulfur...still the most effective remedy...In addition ...salicylic acid and other peeling chemicals are used in cosmetically elegant lotions..."[4]
The exclusive Komed formulation keeps skin dry and desquamating with salicylic acid and *non-comedogenic* sodium thiosulfate.

"Suspensions and creams containing elemental sulphur were shown to be capable of inducing comedones in the rabbit ear and on human backs."[5]

Has "excellent patient appeal."

"All of the patients liked the fact that (Komed) dries quickly to an invisible film...the female patients found that the lotion did not interfere with the use of non-oily cosmetics. Male patients also appreciated the lack of a masking effect, the absence of staining properties, and the fact that the lotions blend with natural skin tone."[6]

Barnes-Hind Pharmaceuticals, Inc.
895 Kifer Road, Sunnyvale, California 94086

KOMEX®/KOMED® Classical topical therapy. Still the effective treatment for mild acne.



1. Domonkos AN: Andrews' diseases of the skin. 6:257, Saunders: Philadelphia, 1971
2. Leyden JJ: Antibiotic resistant acne. Cutis 17:593, 1976
3. Frank L: Active oxygen in acne therapy. Cutis 1:306, 1965
4. Domonkos AN: Andrews' diseases of the skin. 6:257-258, Saunders: Philadelphia, 1971
5. Mills OH Jr, Kligman AM: Is sulphur helpful or harmful in acne vulgaris? Br J Derm 86:620, 1972
6. Sewell JW Jr: Therapeutic and cosmetic advantages of a nonpigmented acne lotion. Cutis

What are Leon Jaworski, Treasury Secretary William Simon and the president of the American Medical Association all doing in one book?

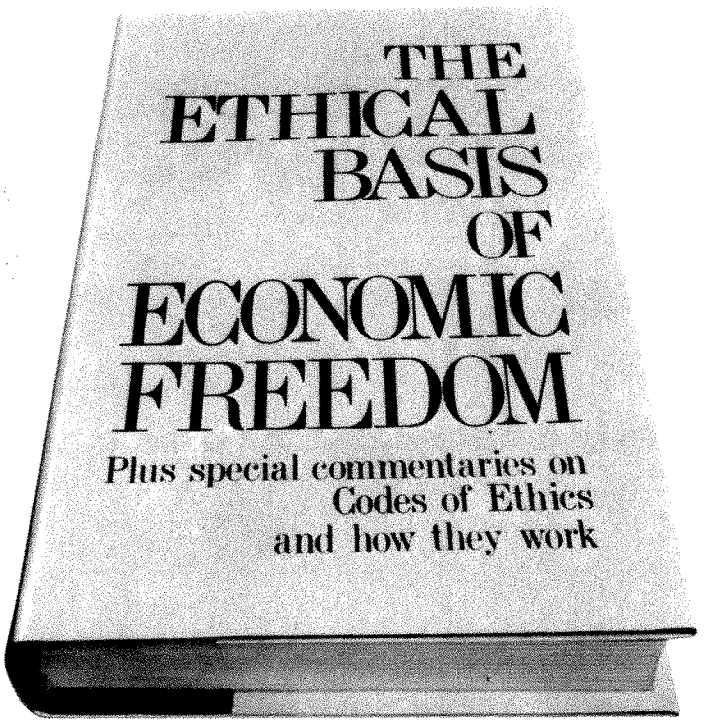

They have joined with eminent economists, anthropologists, lawyers, association executives and other experts to discuss the headline issue of today—everyday ethics—America's urgent problem

Authors on ethics include Leon Jaworski, the celebrated lawyer, Dr. Max Parrott, president of the American Medical Association, the articulate Treasury Secretary William E. Simon, anthropologists Dr. Roy Rappaport and Dr. James Peacock, economic historians Dr. Wolfram Fischer and Dr. John B. Condliffe. Dr. Jack Behrman writes on transnational corporate practices, Earl Kintner on regulatory law, Kenneth Fiester on labor ethics. Andrew Kneier discusses conflicts of interest in government. Clifford Graese, partner in the world's largest accounting firm, presents new concepts in accounting ethics.

THE ESSAYS ON ETHICS present the problem in perspective and draw a clear relationship between ethics and the viability of our free enterprise system.

THE COMMENTARIES ON CODES OF ETHICS begin with an introduction by Arch N. Booth, past president of the Chamber of Commerce of the U. S., and continue with analyses of complete codes of ethics by executive officers of national trade and professional associations, with emphasis on how to make such codes more effective.

If your bookstore does not have "The Ethical Basis of Economic Freedom," please order direct from American Viewpoint, Inc. 448 pages in attractive hard cover, $12.50 postpaid.

AMERICAN VIEWPOINT, INC.

University Square, Chapel Hill, North Carolina 27514

A 54-year-old nonpartisan, nonsectarian, nonprofit educational corporation

---

HALOG® CREAM (Halcinonide Cream 0.1%)

Each gram of Halog Cream (Halcinonide Cream 0.1%) contains 1 mg. halcinonide (0.1%) in a cream base.

INDICATIONS: This product is intended for topical application for adjunctive therapy and symptomatic relief of inflammatory manifestations of acute and chronic corticosteroid responsive dermatoses.

CONTRAINDICATIONS: Topical steroids are contraindicated in vaccinia, varicella, and in those patients with a history of hypersensitivity to any of the components of the preparation. This preparation is not for ophthalmic use.

PRECAUTIONS: *General*—If local infection exists, suitable concomitant antimicrobial or antifungal therapy should be administered. If a favorable response does not occur promptly, application of the corticosteroid should be discontinued until the infection is adequately controlled. Although systemic side effects associated with absorption of topical corticosteroid preparations are rare, their possible occurrence must be kept in mind when these preparations are used over large areas or for an extended period of time. If irritation or sensitization develops, the preparation should be discontinued and appropriate therapy instituted. Although topical steroids have not been reported to have an adverse effect on pregnancy, the safety of their use during pregnancy has not been absolutely established; therefore, they should not be used extensively on pregnant patients, in large amounts, or for prolonged periods of time.

Occlusive Dressing Technique—The use of occlusive dressing increases the percutaneous absorption of corticosteroids; their extensive use increases the possibility of systemic effects. For patients with extensive lesions it may be preferable to use a sequential approach, occluding one portion of the body at a time. The patient should be kept under close observation if treated with the occlusive technique over large areas and over a considerable period of time. Occasionally, a patient who has been on prolonged therapy, especially occlusive therapy, may develop symptoms of steroid withdrawal when the medication is stopped. Thermal homeostasis may be impaired if large areas of the body are covered. Use of the occlusive dressing should be discontinued if elevation of the body temperature occurs. Occasionally, a patient may develop a sensitivity reaction to a particular occlusive dressing material or adhesive and a substitute material may be necessary. If infection develops, discontinue the use of the occlusive dressing and institute appropriate antimicrobial therapy.

ADVERSE REACTIONS: The following local adverse reactions have been reported with topical corticosteroids: burning, itching, irritation, striae, skin atrophy, secondary infection, dryness, folliculitis, hypertrichosis acneform eruptions, and hypopigmentation. The following may occur more frequently with occlusive dressings: maceration of the skin, secondary infection, skin atrophy, striae, and miliaria. Contact sensitivity to a particular dressing material or adhesive may occur occasionally (see PRECAUTIONS).

For full prescribing information, consult package insert.

HOW SUPPLIED: In tubes of 15 and 60 g. and in jars of 240 g. (8 oz.).

SQUIBB® The Priceless Ingredient of every product is the honor and integrity of its maker.™

© 1976 E.R. Squibb & Sons, Inc. 357-504

"Major improvement" in 5 days



Contact Dermatitis

Condition due to excessive use of 5-FU. Patient presented with intense pruritus, severe pain. Facial involvement sharply demarcated and acutely eczematous, erythematous and swollen – extending up into infra-orbital regions, but sparing eyelids and eyebrows.

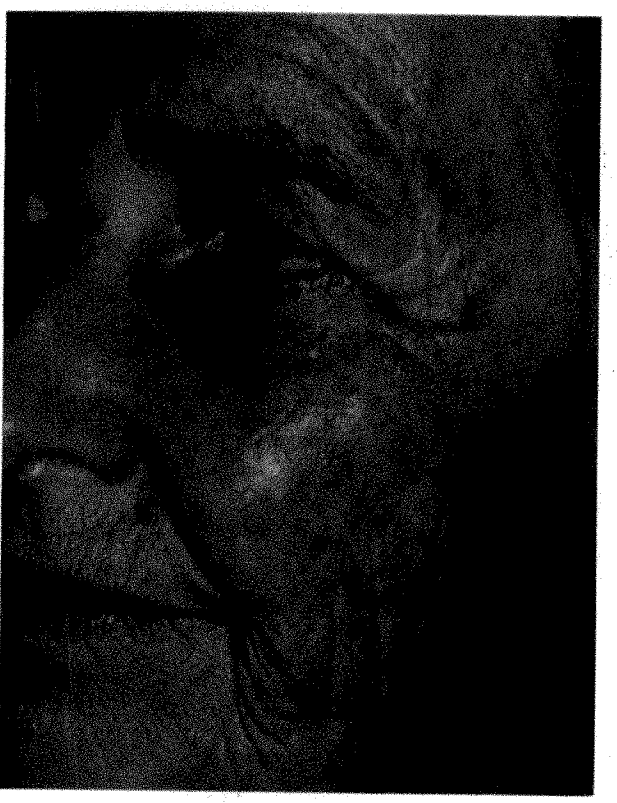

After 5 days

Halog 0.1% cream applied twice daily. Pruritus and pain relieved within 48 hours. Examination on day 5 of therapy revealed major improvement with only mild, residual erythema still present. Total resolution of all lesions nine days later, at which time therapy was discontinued.

Case history on file at Squibb Institute for Medical Research.

after Halog® Cream b.i.d

Halcinonide Cream 0.1%

See adjacent **SQUIBB®** column for brief summary.

INDEX TO ADVERTISERS

A

Abbott Laboratories 398-399

B

Barnes-Hind Pharmaceuticals 395, 540-541
Burroughs Wellcome Company 397

C

Ciba Pharmaceuticals 538-539
Cooper Laboratories, Inc. 418
Cutler Associates 536

D

Dermik Laboratories 404-405, 508
Doak Pharmacal Company 408
Dorsey Laboratories 411-412

G

General Medical Company 537

H

Herbert, G.S., Laboratories, Division of Allergan Pharmaceuticals 413

I

International Light Inc. 404

J

Johnson & Johnson 406-407

L

Lederle Laboratories, Division of American Cyanamid Company 402-403

N

Neutrogena Corporation 536-537

O

Owen Laboratories, Inc. ..... 3rd Cover

P

Person & Covey, Inc. 410
Purdue Frederick Company 517

R

Remedco Analytical Laboratory 404
Robins, A.H., Company 414-415
Roerig, J.B., Company Division of Pfizer, Inc. 534-535

S

Schering Corporation 419, 524-525
Squibb, E.R., & Sons, Inc. 542-543
Stiefel Laboratories, Inc. 509-510, 526-528
Syntex Laboratories, Inc. 514-516, 530-531

T

Texas Pharmacal Company 506-507

W

Westwood Pharmaceuticals, Inc. ..... 2nd Cover, 401, 409, 416-417, 420, 533, 4th Cover

While every precaution is taken to insure accuracy, we cannot guarantee against the possibility of an occasional change or omission in the preparation of this index.

A NEW PRESCRIPTION TO ASSURE YOUR TRAVELING PATIENTS A BON VOYAGE.

Physician's Guide to Medical Advice for Overseas Travelers

Jet lag fatigue, Montezuma's Revenge, airport coronaries--they've become all too common words in the medical vocabulary as increasingly larger numbers of people avail themselves of the speed and ease of jet travel for overseas vacation and business trips. And, in the process, they expose themselves to health risks rarely encountered at home.

Physician's Guide to Medical Advice for Overseas Travelers was developed by the AMA to help practicing physicians render preventive medical services to traveling patients.

It provides a wealth of information, such as how to protect patients against tropical diseases, time zone changes, parasites, tuberculosis and complications of existing handicaps. What to advise about diets and personal hygiene in the tropics, overseas medical care, immunizations.

Order your copy today. The price is only 60¢. Write: ORDER DEPT., at the address below, and specify pamphlet OP-411. Enclose check.

American Medical Association
535 N. Dearborn St.
Chicago, Ill. 60610





a completely dissolved hydrocortisone for optimal cutaneous penetration with a rapid release vehicle for maximum hydrocortisone effectiveness

nutracort® Gel

(1.0% Hydrocortisone Gel)

DESCRIPTION. Nutracort® Gel 1.0% provides 1.0% hydrocortisone in a non-aqueous clear gel base containing propylene glycol, alcohol 22% (w/w), hydroxypropyl cellulose, and citric acid. CONTRAINDICATIONS. In viral diseases of the skin such as varicella and vaccinia and in patients with a history of hypersensitivity to any component. Not for ophthalmic use. Topical steroids should not be used when circulation is markedly impaired. PRECAUTIONS. If irritation develops, discontinue and institute appropriate therapy. In presence of infection, use of appropriate antifungal or antibacterial agents should be instituted. If a favorable response is not obtained promptly, discontinue until the infection has been adequately controlled. Suitable precautions should be taken against increased systemic absorption which may occur if extensive areas are treated or the occlusive

ADVERSE REACTIONS. Burning sensation, itching, irritation, dryness, folliculitis, secondary infection, skin atrophy, striae, hypertrichosis, acneform erupti and hypopigmentation have been reported with or without occlusive dressings. DOSAGE. Apply to affected areas 3 to 4 times daily. HOW SUPPLIED. Nutracort® Gel (1.0% hydrocortisone gel) is availabl in a 60 gram tube. Nutracort® Lotion is available in 0.25%, 0.5% and 1.0% strengths, 2 oz. and 4 oz. bot Nutracort® Cream available in 0.25%, 0.5% and 1.0% strengths, 2 oz. and 4 oz. jars. Nutracort® Cream 1.0% also available in 1 lb. jars.

Owen Owen Laboratories

When treating tar-responsive dermatoses...
You'll have to tell your patients it's tar.
NEW
estar™
Therapeutic Tar Gel
The odor won't.
For full product information, see PDR.
WESTWOOD
PHARMACEUTICALS INC.
Buffalo, New York 14213

Published by the American Medical Association

May 1977

archives of Dermatology

Mixed Connective Tissue Disease Syndrome . . . 583

Methotrexate-Serum Albumin Binding . . . 588

Papillary Eccrine Adenoma . . . 596

Cutaneous Marker in Hunter Syndrome . . . 602

Psychogenic Purpura . . . 606

Bullous Pemphigoid Treatment . . . 610

Chloracne From a New Herbicide . . . 616

Volume 113 Number 5

Complete Contents . . . 546

Percutaneous Absorption of Hydrocortisone . . . 620

Perfume Dermatitis . . . 623

Vascular Reactions in Atopic Dermatitis . . . 627

Newer Concepts of Atopic Dermatitis . . . 663

LIBRARY

CONTEMPORARY AND EFFECTIVE

For seborrhea oleosa and the oily hair and scalp associated with acne

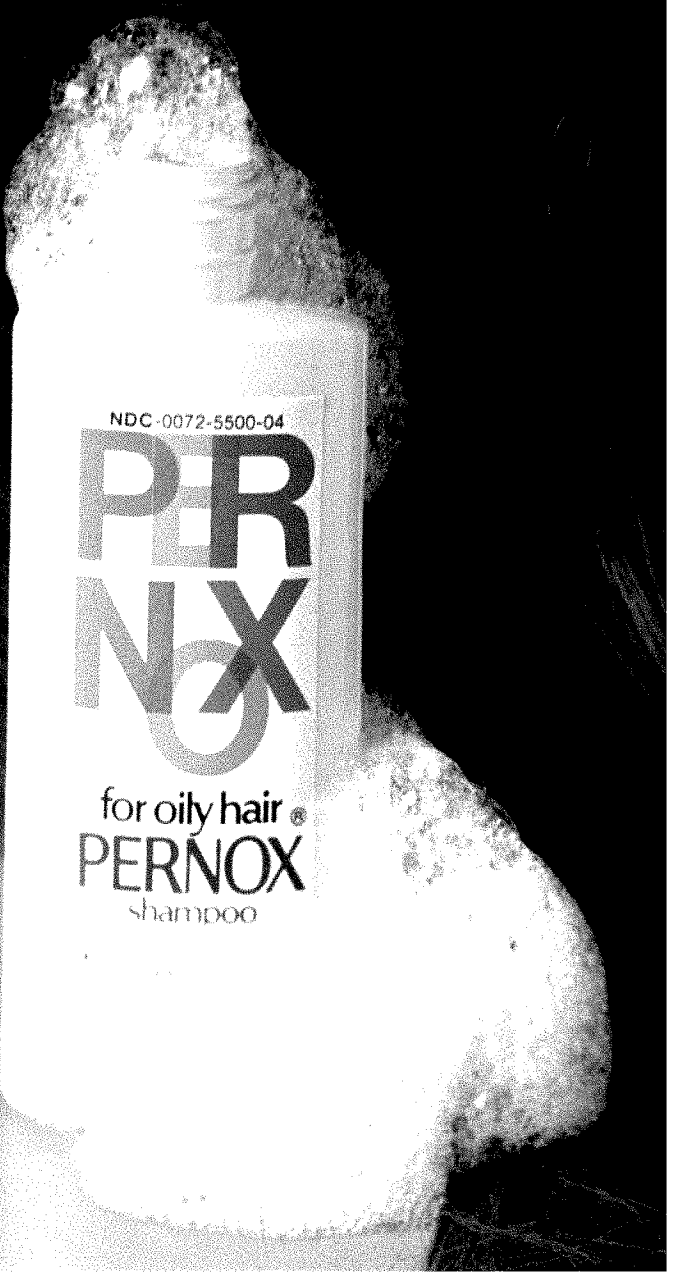

- Thorough cleansing of oily hair and scalp.
- Leaves patients' hair soft, manageable, fresh smelling.
- Elegant herbal scented shampoo.
- A special formulation designed to cleanse and condition oily hair.
- Its pH of 5.5 is gentle to the scalp.
- Can be used as often as necessary, preferably every day, to keep hair looking fresh and healthy.
- CONTAINS NO FORMALDEHYDE.

Supplied: 4 oz. and 8 oz. plastic bottles.

Pernox Shampoo® is adjunctive therapy especially formulated for oily scalps associated with acne.

WESTWOOD
PHARMACEUTICALS INC.
Buffalo, New York 14213

Inflammatory manifestations of psoriasis and atopic dermatitis...

Effectiveness demonstrated in only 8 days*

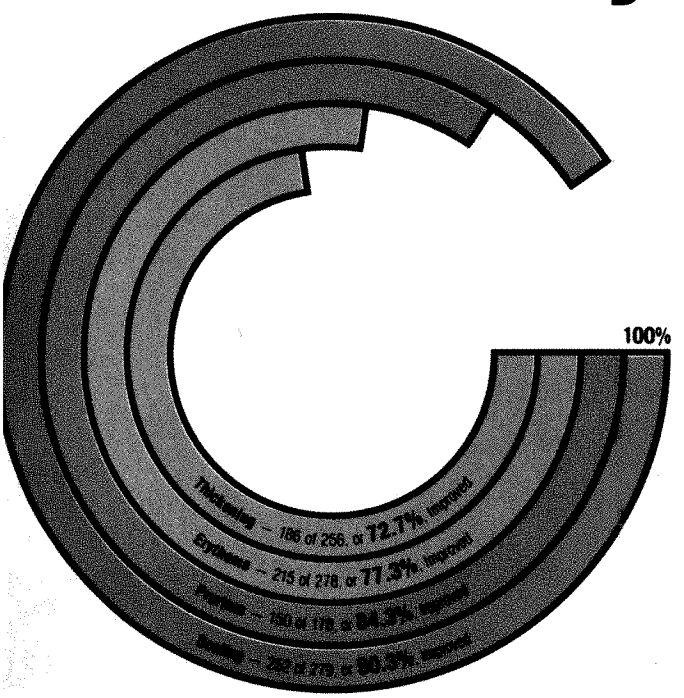

Psoriasis

In a study of 279 psoriatic patients

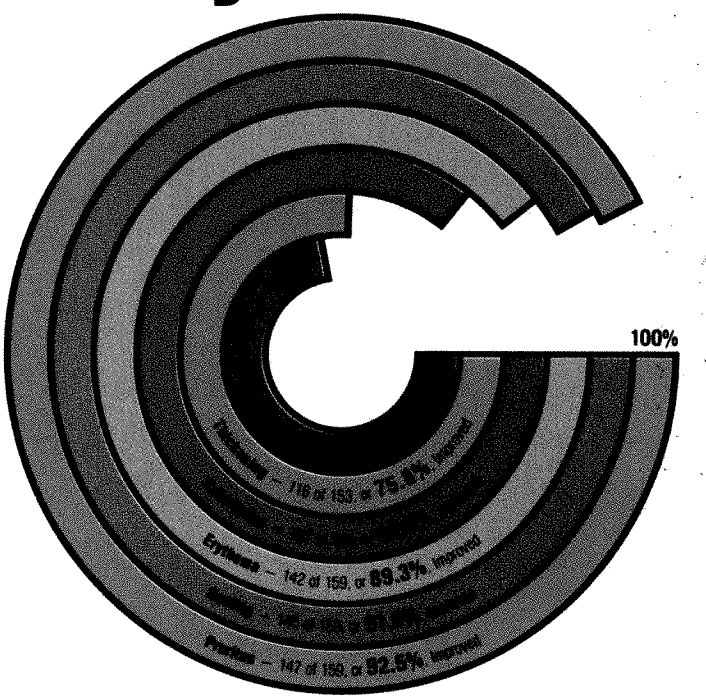

Atopic Dermatitis

In a study of 162 atopic dermatitis patients

Cordran® (Flurandrenolide)

Description: Cordran* (flurandrenolide, Dista) is a potent corticosteroid intended for topical use. **Actions:** Cordran is primarily effective because of its anti-inflammatory, antipruritic, and vasoconstrictive actions. **Indications:** For relief of the inflammatory manifestations of corticosteroid-responsive dermatoses. **Contraindications:** Topical corticosteroids are contraindicated in vaccinia and varicella and in patients with a history of hypersensitivity to any of their components. **Precautions:** If irritation develops, the product should be discontinued and appropriate therapy instituted. In the presence of an infection, an appropriate antifungal or antibacterial agent should be used. If a favorable response does not occur promptly, the corticosteroid should be discontinued until the infection has been adequately controlled. If extensive areas are treated or if the occlusive technique is used, there is a possibility of increased systemic absorption of the corticosteroid, and suitable precautions should be taken. Although topical corticosteroids have not been reported to have an adverse effect on pregnancy, the safety of their use on pregnant women has not been absolutely established. Therefore, they should not be used extensively, in large amounts, or for prolonged periods of time on pregnant patients. These products are not for ophthalmic use. **Adverse Reactions:** The following local adverse reactions have been reported with topical corticosteroid formulations: acneform eruptions, burning, dryness, folliculitis, hypertrichosis, hypopigmentation, irritation, itching. The following may occur more frequently with occlusive dressings: maceration of the skin, miliaria, secondary infection, skin atrophy, striae. **Administration and Dosage:** For moist lesions, a small quantity of the cream or lotion should be rubbed gently into the affected areas two or three times a day. For dry, scaly lesions, the ointment is applied as a thin film to affected areas two or three times daily. [111875]

Cream, Ointment, and Lotion Cordran®, 0.05%
flurandrenolide

Cream and Ointment Cordran, 0.025%

*Data on file at Dista Products Company.

DISTA

Dista Products Company
Division of Eli Lilly and Company
Indianapolis, Indiana 46206

700136

Additional information available to the profession on request.

Cream

Cordran®

Flurandrenolide

Efficacy is its strength

Archives of DERMATOLOGY

Copyright © 1977 by the AMERICAN MEDICAL ASSOCIATION

VOL 113, NO. 5 **May 1977**

ORIGINAL CONTRIBUTIONS

Mixed Connective Tissue Disease Syndrome
James N. Gilliam, MD, Stephen D. Prystowsky, MD, Dallas **583**

Effect of Sodium Salicylate and Indomethacin on Methotrexate-Serum Albumin Binding
J. Richard Taylor, MD, Kenneth M. Halprin, MD, Miami **588**

Clinical and Histological Study of Coal Tar Phototoxicity in Humans
Kays H. Kaidbey, MD, Albert M. Kligman, MD, PhD, Philadelphia **592**

Papillary Eccrine Adenoma
David B. Rulon, MD, Elson B. Helwig, MD, Washington, DC **596**

Betamethasone Valerate Ointment Compared With Fluocinonide FAPG
Dowling D. Munro, MD, FRCP; Trevor W. E. Robinson, MB, FRCP; Anthony W. P. du Vivier, MRCP; Dorothy M. France, MB, MRCP; Roger Clayton, MB, MRCP, London; Christopher G. Sparkes, PhD, Greenford, England **599**

A Cutaneous Marker in the Hunter Syndrome
Stephen D. Prystowsky, MD, Dallas; Irene H. Maumenee, MD, Baltimore; Robert G. Freeman, MD; James H. Herndon, Jr, MD; Mary Jo Harrod, PhD, Dallas **602**

Psychogenic Purpura
William W. Stocker, MD; O. Ross McIntyre, MD; William E. Clendenning, MD, Hanover, NH **606**

Bullous Pemphigoid Responding to Sulfapyridine and the Sulfones
John R. Person, MD, Roy S. Rogers III, MD, Rochester, Minn **610**

Chloracne From Manufacture of a New Herbicide
James S. Taylor, MD; Richard C. Wuthrich, MD, Cleveland; Kenneth M. Lloyd, MD, Youngstown, Ohio; Alan Poland, MD, New York **616**

Frequency of Application on Percutaneous Absorption of Hydrocortisone
Ronald C. Wester, PhD; Patrick K. Noonan, Chicago; Howard I. Maibach, MD, San Francisco **620**

Perfume Dermatitis
Walter G. Larsen, MD, Portland, Ore **623**

Abnormal Vascular Reactions in Atopic Dermatitis
Masami Uehara, MD, Shigeo Ofuji, MD, Kyoto, Japan **627**

CASE REPORTS

Elastosis Perforans Serpiginosa Induced by Penicillamine
Nevelle Kirsch, MD, Peter B. Hukill, MD, Farmington, Conn **630**

Immunoblastic Lymphadenopathy With Purpura and Cryoglobulinemia
Harry L. Wechsler, MD, Alexander Stavrides, MD, Pittsburgh **636**

Lymphocutaneous Nocardiosis Due to *Nocardia brasiliensis*
Eliezer Zecler, MD; Yigal Gilboa, MD; Luba Elkina, MD; Gerald Atlan, MD; David Sompolinsky, PhD, Zerifin, Israel **642**

Eosinophilic Ulcer of the Tongue
Gordon H. Burgess, MD, Buffalo, NY; Amir H. Mehregan, MD, Detroit; Alan J. Drinnan, MD, DDS, Buffalo, NY **644**

(Continued on page 548)

EDITORIAL BOARD

Chief Editor
John H. Epstein, MD
450 Sutter Street
San Francisco 94108

Assistant Chief Editor
Kimie Fukuyama, MD
San Francisco

Assistant Chief Editor
Denny L. Tuffanelli, MD
San Francisco

Donald C. Abele, MD
Augusta, Ga.

Harry L. Arnold, Jr, MD
Honolulu

Walter C. Lobitz, Jr, MD
Portland, Ore

Frederick D. Malkinson, MD
Chicago

Sigfrid A. Muller, MD
Rochester, Minn

W. Mitchell Sams, Jr, MD
Denver

John S. Strauss, MD
Boston

Morris Waisman, MD
Tampa, Fla

Gerald D. Weinstein, MD
Miami

This is a pabafilm™ stain.

Pabafilm™: The non-staining sunscreen
(amyl dimethyl PABA)



CONTENTS—Continued

Foot Ulceration and Vertebral Osteomyelitis With *Corynebacterium haemolyticum*
Roger I. Ceilley, MD, Iowa City 646

Osler Node, Janeway Lesions, and Splinter Hemorrhages
W. Lee Fanning, MD, Mark Aronson, MD, Burlington, Vt 648

Modern Radiotherapy for Malignant Epitheliomas
Anthony T. Farina, MD; Morris Leider, MD; Joseph Newall, MD; Richard J. Carella, MD, New York 650

Panniculitis of the Legs With Urate Crystal Deposition
Kirsti-Maria Niemi, MD, Helsinki 655

Skin Changes in Short-Bowel Syndrome
Stephen Z. Smith, MD, San Francisco 657

REVIEW ARTICLE

Newer Concepts of Atopic Dermatitis
Jon M. Hanifin, MD, Walter C. Lobitz, Jr, MD, Portland, Ore 663

REGULAR DEPARTMENTS

Short Reports 675

Dermal Metastases From a Follicular Carcinoma of the Thyroid Richard M. Auty, BSc, MD, MRCP, Zaria, Nigeria . . . **Ulcerative Sarcoidosis** Judith Schiffner, MD, Om P. Sharma, MD, Los Angeles

Letters to the Editor 683

Macrocytosis and Hydroxyurea Therapy in Psoriatics Ullin W. Leavell, Jr, MD; Philip DeSimone, MD; Philip Reeder, MD, Lexington, Ky . . . **Hydroxyzine Products** Patricia G. Engasser, MD, Redwood City, Calif . . . **Neonatal Anaerobic (Clostridial) Cellulitis and Omphalitis** Daniel Gormley, MD, Glendora, Calif . . . **Fragmentation of Elastic Fibers** Hermann Pinkus, MD; Amir H. Mehregan, MD, Monroe, Mich; Margery A. Scott, MD; Young C. Kauh, MD; Herbert A. Luscombe, MD, Philadelphia . . . **Hypothyroidism and Lichen Myxoedematosus** G. C. Archibald, MRACP, H. T. Calvert, FRCP, Reading, England . . . **Familial Lupus: Spectrum of Disease in One Family** Sidney Barsky, MD; David Knapp, MD; Bruce Bennin, MD, Chicago . . . **Pachyonychia Congenita With Recessive Inheritance** Tay Chong-Hai, FRECP, Republic of Singapore, K. Rajagopalan, DDM, MRCP, Kuala Lumpur, West Malaysia . . . **Erythema Multiforme Resulting From Insecticide Spray** R. K. Bhargava; Virendra Singh; Vinay Soni, Jaipur, India . . . **Pachyonychia Congenita With Cardiac Involvement** S. Premalatha, MD, DD, A. S. Thambiah, FRCP, FAMS, Madras, India . . . **Toxic Epidermal Necrolysis in a Patient With Ovarian Carcinoma** F. Charles Tring, MA, MD, Ronald E. Church, MA, MD, Sheffield, England . . . **Thymus Lymphocytes of the Peripheral Blood in Patients With Alopecia Areata** Algie C. Brown, MD; Zbigniew L. Olkowski, MD; John R. McLaren, MD, Atlanta . . . **Hypopigmentation With Punctate Keratosis of the Palms and Soles** Samuel B. Pratt, MD; Tommy B. Griffin, MD; George S. Stretcher, MD, Spartanburg, SC; Lt Col Lonnie A. Cole, MC, USAF, Tampa, Fla . . . **Iatrogenic Traumatic Purpura Masquerading as Vasculitis** Paul G. Hazen, MD, Allen D. Kallor, MD, Cleveland

Society Transactions 692

News and Notes 698

Index to Advertisers 706

Instructions for Authors 552

SUBSCRIPTION RATES: The yearly rate of the ARCHIVES OF DERMATOLOGY is as follows: United States and US Possessions, one year, $18; two years, $28; all other countries, one year, $28; two years, $38. Special yearly price to residents, interns and medical students in the United States and US Possessions, $9.

THE ARCHIVES OF DERMATOLOGY is published monthly by the American Medical Association, 535 N Dearborn St, Chicago, IL 60610, and is an official publication of the Association. Second-class postage paid at Chicago and at additional mailing office.

Selsun®
(SELENIUM SULFIDE LOTION, U.S.P.) ℞

Brief Summary

Contains:
Selenium sulfide, 2½%, w/v; bentonite; lauric diethanolamide; ethylene glycol monostearate; titanium dioxide; amphoteric—2; sodium lauryl sulfate; sodium phosphate (monobasic); glyceryl monoricinoleate; citric acid; captan; perfume; and water.

Indications:
For the treatment of dandruff and seborrheic dermatitis of the scalp.

Contraindications:
Should not be used by patients allergic to any of its components.

Warnings:
Safety for use on infants has not been established.

Precautions:
Cutaneous sensitization of the scalp or adjacent areas has been reported; if sensitivity reactions should occur, discontinue use. Chemical conjunctivitis may result if product enters the eyes. Do not use when acute inflammation or exudation is present as an increase in absorption may occur.

Adverse Reactions:
As with other shampoos, oiliness or dryness of the hair and scalp may occur following use; there have been occasional reports of an increase in the amount of normal hair loss. Hair discoloration may occur; can be avoided or minimized by thorough rinsing.

ABBOTT

703318

Announcing Selsun.

What?

New Selsun®

(SELENIUM SULFIDE LOTION, U.S.P.)

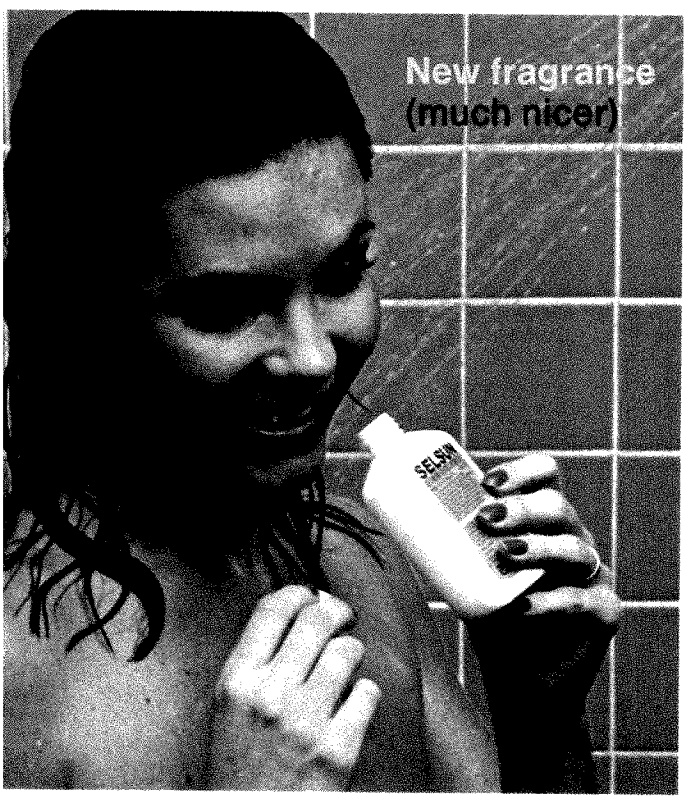

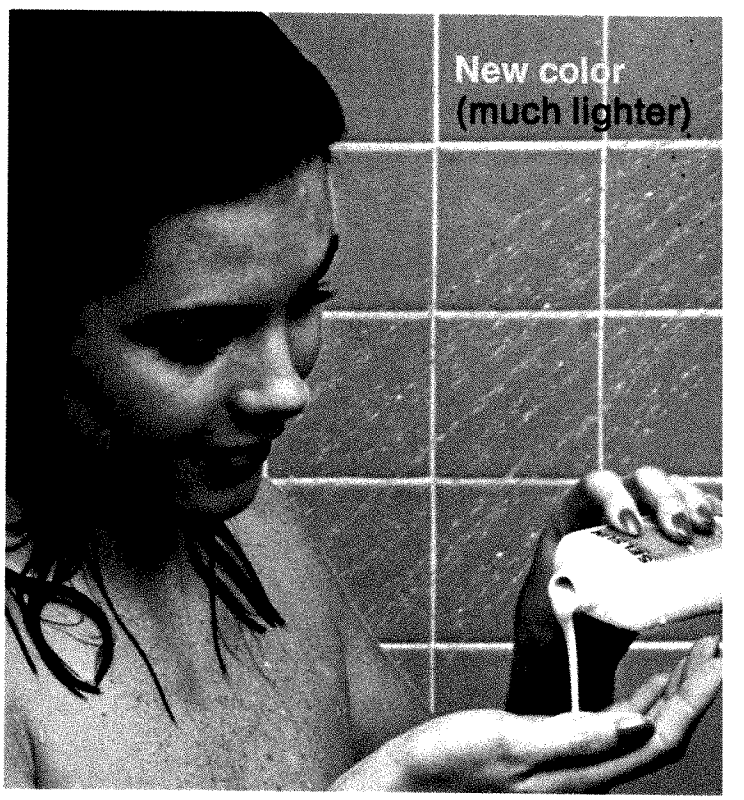

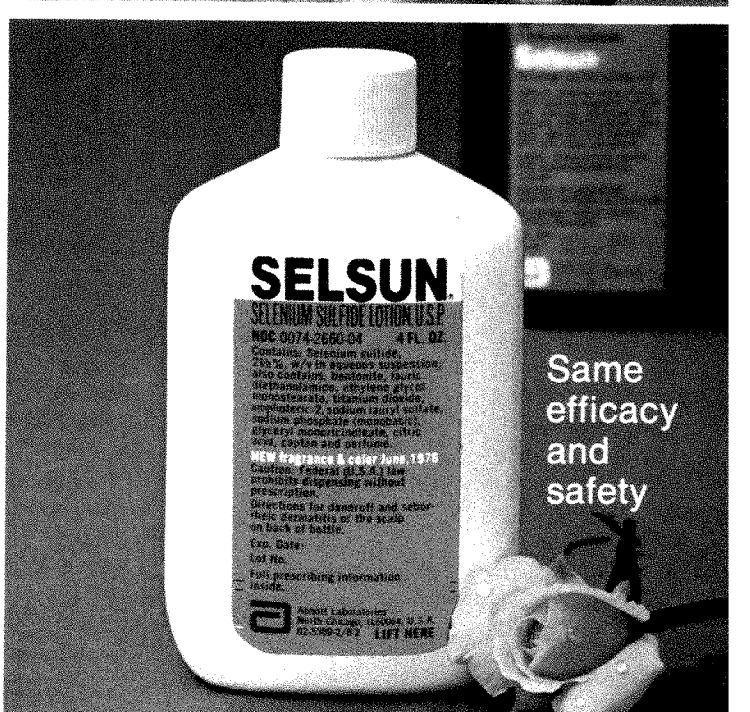

Archives of Dermatology

James H. Sammons, MD
Executive Vice-President

Thomas F. Hannon
Group Vice-President,
Publishing Operations

William R. Barclay, MD
Group Vice-President,
Scientific Publications

Norman D. Richey
Director, Publication
Production Division

John T. Baker
Director, Marketing Division

Helen R. Mazur
Acting Fulfillment Manager

John T. Baker, General Sales Manager; **Robert Corcoran,** Eastern Sales Manager; **Fred Bauman, Richard M. Johnson,** Eastern Sales Representatives; **William J. Healy,** Midwest Sales Representative; **Thomas J. Carroll,** West Coast/Northern Sales Representative

PUBLICATION STAFF

Offices: 535 N Dearborn St
Chicago, IL 60610

William R. Barclay, MD, Director
Scientific Publications Division

Robert W. Mayo, Executive Editor

Marlene M. Hinsch, Production Manager

Editorial Processing Manager: Diana A. Morgan

Copy Editing: Rosanne Schulenberg (Supervisor), Rae Usinger

Proofreading: Lorraine L. Kruse (Supervisor), Helen Grzeskiewicz, Elizabeth Petrikenas, Patricia Simmers, Dorothy Troy

Production Supervisors: Julia Bero (Layout), Thomas J. Handrigan (Illustrations), Marlene M. Hinsch (Editorial), James P. Bagniewski (Advertising)

Art and Senior Production Assistants: Betty Frigerio, Shirley Latronica, Deborah Orent, Donna Pender, Nancy Keyes, Susan Routhier, JoAnne Weiskopf

Production Assistants: Karen Branham, E. Linda Eisenberg, Anna Goins, Lucille Kuznicki

Manuscript Records: Mary Paino

Indexing: Phyllis H. McLaren (Supervisor), Jane P. Mauldin, Helen F. Topel

Please address communications concerning accepted or published communications to: AMA Specialty Journals, 535 N Dearborn St, Chicago, IL 60610.

Conditions for Acceptance of Color Illustrations

Illustrations in full color are accepted for publication in ARCHIVES OF DERMATOLOGY if the editor believes that color will add significantly to the published manuscript.

When color illustrations are accepted, the American Medical Association will pay part of the expense of reproduction and printing, the remainder to be borne by the author or the institution with which he is affiliated. After deducting AMA's contribution, the author's share is $275 for up to six square finished illustrations. Additional illustrations and special effects, such as outlining, opaquing, or surprinting, will be billed to the author at cost.

Color transparencies must be submitted for evaluation. Do not send color prints unless accompanied by original transparencies. If transparencies are mounted in frames or glass, the material should be carefully packed in gauze and sent with the manuscript in a separate container or between two pieces of pressboard.

Advertising and Subscription Information

ADVERTISING OFFICES: 535 N Dearborn St, Chicago, IL 60610, Area Code 312, 751-6000; and 600 Third Ave, New York, NY 10016, Area Code 212-867-6640.

ADVERTISING PRINCIPLES: Each advertisement in this issue has been reviewed and complies with the principles governing advertising in AMA scientific publications. A copy of these principles is available on request.

CHANGE OF ADDRESS: Please notify the publisher at least six weeks in advance, including both old and new address, and a mailing label taken from the most recent copy. Include your new zip code number.

Desquam-X®

5 or 10% Benzoyl Peroxide 6% Polyoxyethylene Lauryl Ether

the topical side of C. acnes control

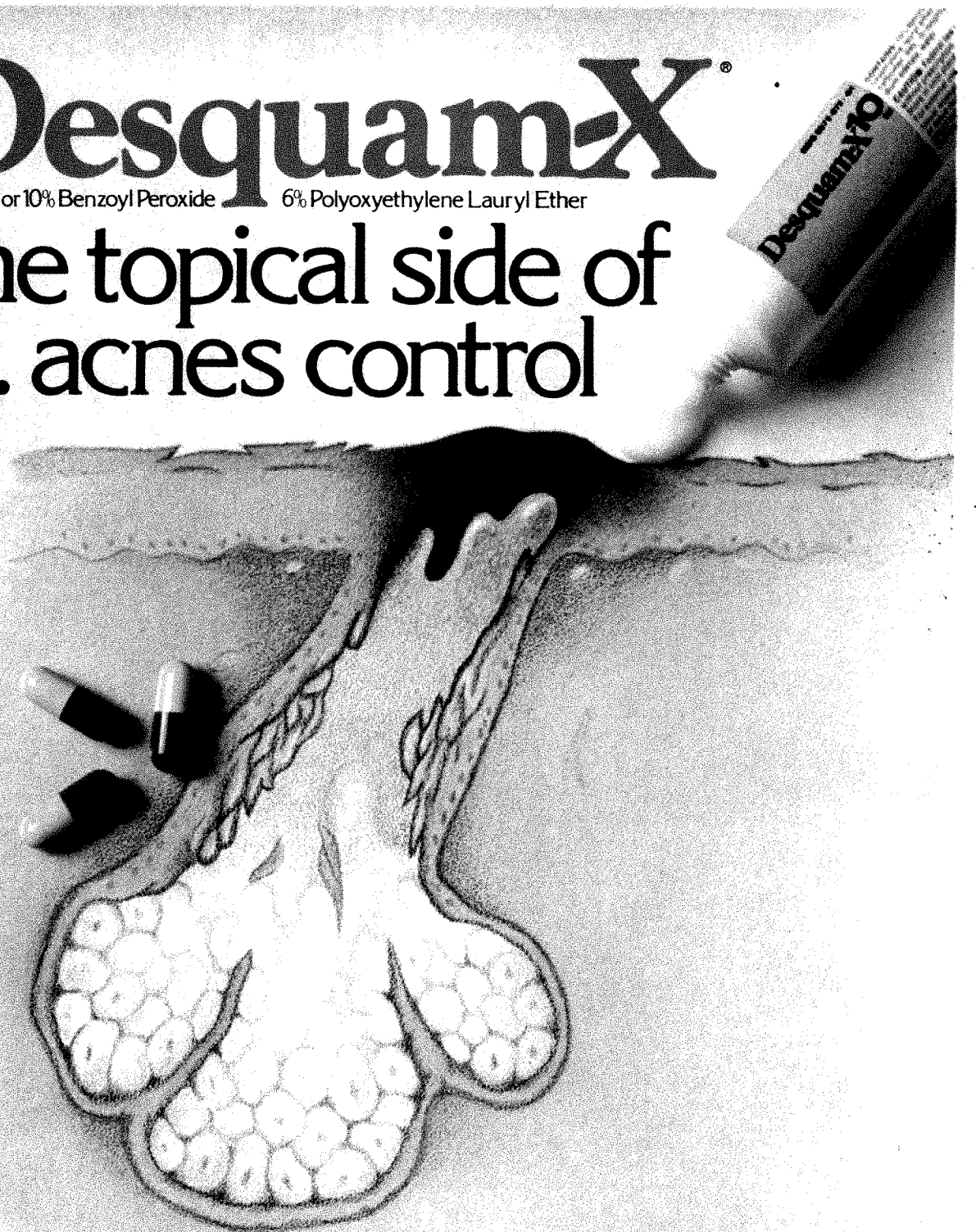

Desquam-X5®

Desquam-X10®

CONTENTS: Desquam-X 5 contains 5% Benzoyl Peroxide, 6% polyoxyethylene lauryl ether, 37% ethyl alcohol, carbomer 940, di-isopropanolamine, disodium edetate and water.

Desquam-X 10 contains 10% Benzoyl Peroxide, 6% polyoxyethylene lauryl ether, 37% ethyl alcohol, carbomer 940, di-isopropanolamine, disodium edetate and water.

INDICATION: A topical aid for the control of acne vulgaris.

ACTION: Provides the desirable drying and desquamation needed in the topical treatment of acne. Desquam-X has been demonstrated to have anti-bacterial effects, especially against Corynebacterium acnes.

DIRECTION FOR USE: After washing as instructed, rub Desquam-X into affected areas twice daily. In fair-skinned individuals or under excessively dry atmospheric conditions it is suggested that therapy be initiated with one application daily. The desired degree of drying and peeling can be obtained by modification of the dosage schedule.

CONTRAINDICATIONS: Not to be used in patients known to be sensitive to any ingredient of Desquam-X.

PRECAUTIONS: Avoid contact with eyes and mucous membranes. For external use only. Keep this and all medication out of the reach of children.

NOTE: May bleach colored fabrics.

HOW SUPPLIED: Plastic tubes 1.5 oz. (42.5 gm.)

CAUTION: Federal law prohibits dispensing without prescription.

WESTWOOD
PHARMACEUTICALS INC.
Buffalo, New York 14213
In Canada, Belleville, Ontario K8N 1E2

©1975 W. Pharm.

Instructions for Authors

Send manuscripts by first-class mail to the Chief Editor, John H. Epstein, MD, 450 Sutter St, San Francisco, CA 94108. Manuscripts are received with the understanding that they are not under simultaneous consideration by another publication. Accepted manuscripts become the permanent property of the ARCHIVES and may not be published elsewhere without permission from the publisher (AMA).

Author Responsibility.—All accepted manuscripts are subject to copy editing. The author will receive an edited typescript rather than galley proofs for approval. The author is responsible for all statements in his work, including changes made by the copy editor.

Designate one author as correspondent and provide his address and telephone number. Order reprints at the time the typescript is returned after editorial processing. Specify address to which requests for reprints should be sent.

Manuscript Preparation.—Submit an original typescript and two high-quality copies of the entire manuscript. All copy (including references, legends, and tables) must be typed double-spaced on 22 × 28-cm (8½ × 11-inch), heavy-duty white bond paper. Ample margins should be provided.

Refer to patients by number (or, in anecdotal reports, by fictitious given names). Real names or initials should not be used in the text, tables, or illustrations.

Titles.—Titles should be short, specific, and clear. They should not exceed 42 characters per line, including punctuation and spaces, and be limited to two lines, if possible. The title page should include the full names and academic affiliations of all authors, the address to which requests for reprints should be sent, and, if the manuscript was presented at a meeting, the name of the organization, place, and date on which it was read.

Style of Writing.—The style of writing should conform to acceptable English usage and syntax. Slang, medical jargon, obscure abbreviations, and abbreviated phrasing are to be avoided.

Informed Consent.—Manuscripts reporting the results of experimental investigations of human subjects must include a statement to the effect that informed consent was obtained after the nature of the procedure(s) had been fully explained.

Abstract.—Provide an abstract (135-word maximum) of the article, including statements of the problem, method of study, results, and conclusions. The abstract replaces the summary.

References.—List references in consecutive numerical order (not alphabetically). Once a reference is cited, all subsequent citations should be to the original number. All references must be cited in the text or tables. Unpublished data and personal communications should not be listed as references. References to journal articles should include (1) author, (2) title, (3) journal name (as abbreviated in *Index Medicus*), (4) volume number, (5) inclusive page numbers, and (6) year, in that order. References to books should include (1) author(s), (2) chapter title (if any), (3) editor (if any), (4) title of book, (5) city of publication, (6) publisher, and (7) year. Volume and edition numbers, specific pages, and name of translator should be included when appropriate. The author is responsible for the accuracy and completeness of the references and for their correct text citation.

Metrication.—All measurements must be in metric units. English units may also be given parenthetically if the measurements were originally done in English units.

Illustrations.—Use only those illustrations that clarify and augment the text. Submit illustrations in duplicate, unmounted and untrimmed. Do not send original artwork. Send high-contrast glossy prints (not photocopies). Figure number, name of senior author, and arrow indicating "top" should be typed on a gummed label and affixed to the back of each illustration. All lettering must be legible after reduction to column size. Artwork submitted for publication may be relettered to achieve uniformity of lettering style throughout the journal. Magnification and stain should be provided when pertinent. Illustrations should preferably be in a proportion of 12.5 × 18 cm (5 × 7 inches).

An experienced medical illustrator should be employed whenever possible for the preparation of all artwork. Template lettering or preset type is preferred to hand-lettered labels. If halftone artwork with labels is submitted, affix type and leaders to a clear acetate overlay registered to the base drawing. Labels and leaders should be applied directly to the drawing board surface if the artwork consists only of line ink technique.

Illustrations in full color are accepted for publication if the editors believe that color will add significantly to the published manuscript. The ARCHIVES will pay part of the expense of reproduction and printing color illustrations, the remainder to be borne by the author or his sponsor. After deducting the ARCHIVES contribution, the author's share is $275.00 for up to six square-finished illustrations that can be arranged on a one-page layout. Any additional illustrations or special effects will be billed to the author at cost. Positive color transparencies (35 mm preferred) must be submitted for an evaluation. Do not send color prints unless accompanied by original transparencies. All transparencies should be carefully packed and sent with the manuscript.

Legends.—Legends should be typed double-spaced, beginning on a separate sheet of paper. Length should be limited to a maximum of 40 words.

Photographic Consents.—A letter of consent must accompany all photographs of patients in which a possibility of identification exists. It is not sufficient to cover the eyes to mask identity.

Acknowledgments.—Illustrations from other publications must be acknowledged. Include the following when applicable: author(s), title of article, title of journal or book, volume number, page(s), month, and year. The publisher's permission to reprint should be submitted to the ARCHIVES after the manuscript has been formally accepted.

Statistical Review.—Manuscripts containing statistical evaluations should include the name and affiliation of the statistical reviewer.

Tables.—Each table should be typed double-spaced, including all headings, on a separate sheet of 22 × 28-cm (8½ × 11-inch) paper. Do not use larger size paper. If a table must be continued, use a second sheet and repeat all heads and stubs. Each table must have a title.

When patient acceptance is half the problem.

sebutone®

is the answer.

Tar is effective therapy, but it has one big drawback . . . most shampoos look like tar and, worst of all, they smell like it, too.

Sebutone® provides tar therapy with unique patient acceptance.

- Itching usually stops after the first shampoo.
- It has a clean, fresh odor patients will like.
- It is a rich, lathering shampoo with a pleasant color.
- It contains the first chemically and biologically standardized tar, developed by Westwood.
- Sebutone's tar is bioassayed to insure therapeutic activity from batch to batch.
- Available in both lotion and cream.
- In addition to 0.5% Westwood® Tar, Sebutone contains 2% sulfur and 2% salicylic acid, for increased effectiveness.
- Wood's light shows that microfine particles remain on the scalp for up to three days to provide sustained antiseborrheic action.



sebutone® Therapeutic Tar Shampoo

Substantive therapy...proven by Wood's light.

Available—Sebutone in 4 and 8 oz. bottles; Sebutone Cream in 4 oz. tubes.

WESTWOOD
PHARMACEUTICALS INC.
Buffalo, New York 14213

©1977, W. P. Inc.

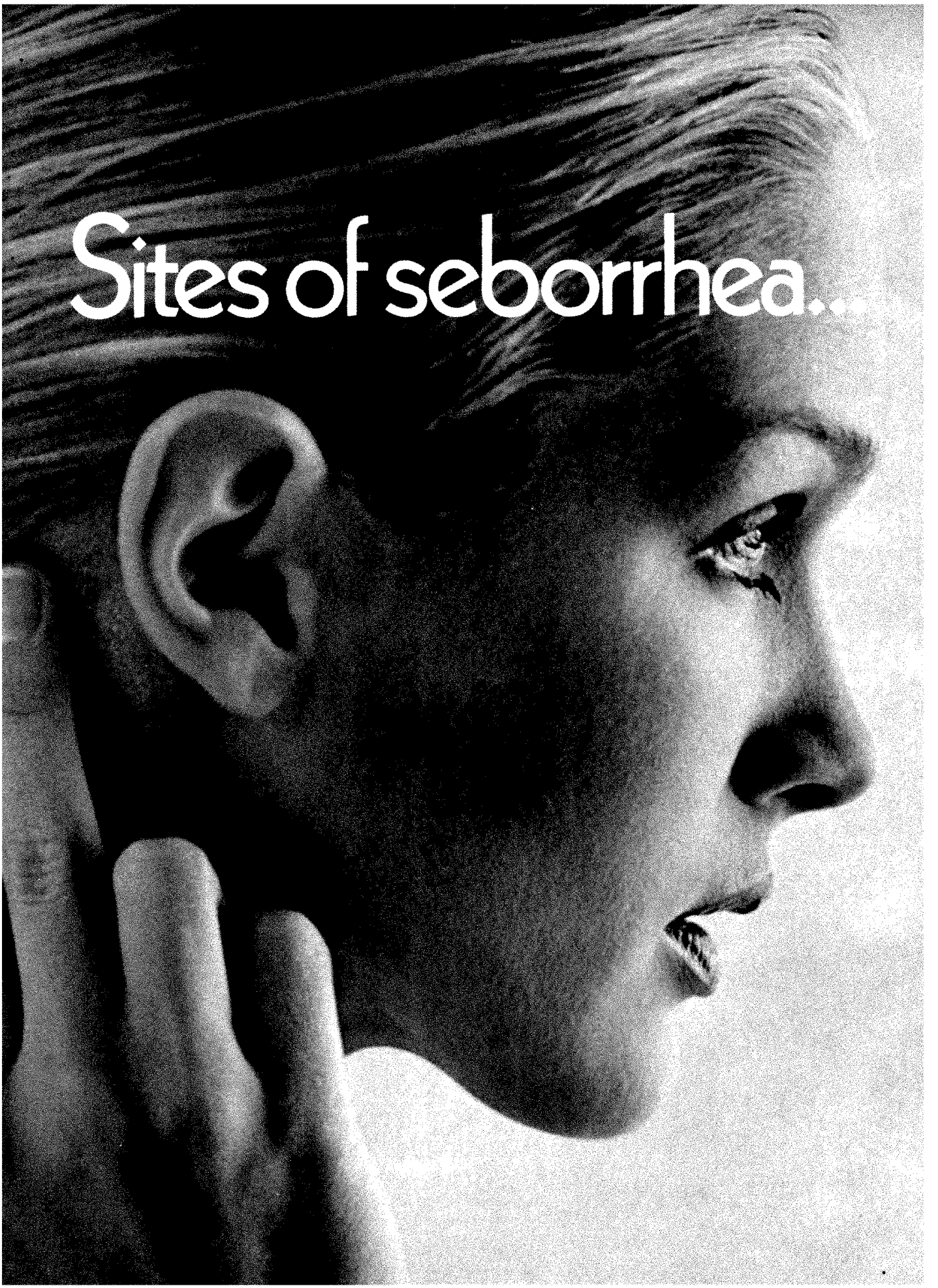
Sites of seborrhea...



Uticort™

(betamethasone benzoate)

a highly effective topical steroid in a special base

UTICORT contains the fluorinated corticosteroid ester — betamethasone benzoate 0.025% — in a specially formulated, clear, self-liquefying gel base to increase steroid activity.
Patients with seborrheic dermatitis treated with UTICORT improved 86% in an average of 11.6 days.

liquefies on application for better surface contact

UTICORT is especially valuable in the treatment of seborrheic dermatitis on hairy areas of the body.

cosmetically acceptable

UTICORT dries to a clear film and can be used confidently on either smooth or hairy skin areas. Moreover, it is greaseless, nonstaining, and nonsticky.

preservative free

Contains no parabens or other potentially sensitizing preservatives.

Brief summary of prescribing information

INDICATIONS. Uticort Gel (betamethasone benzoate) is intended for relief of the inflammatory manifestations of corticosteroid-responsive dermatoses.

CONTRAINDICATIONS. Topical steroids are contraindicated in viral diseases of the skin, such as varicella and vaccinia. Topical steroids are contraindicated in patients with a history of sensitivity to any of the components of the preparation.

This preparation is not for ophthalmic use.

PRECAUTIONS. If irritation develops, the gel should be discontinued and appropriate therapy instituted. In the presence of an infection, the use of appropriate antifungal or antibacterial agents should be instituted. If a favorable response does not occur promptly, the corticosteroid should be discontinued until the infection has been adequately controlled.

If extensive areas are treated, or if the occlusive technique is used, the possibility exists of increased systemic absorption of the corticosteroid, and suitable precautions should be taken.

Although topical steroids have not been reported to have an adverse effect on pregnancy, the safety of their use in pregnant females has not absolutely been established. Therefore, they should not be used extensively on pregnant patients, or in large amounts, or for prolonged periods of time.

Due to the alcohol content of the vehicle, Uticort Gel (betamethasone benzoate) may cause mild, transient stinging without irritation if used on excoriated skin.

ADVERSE REACTIONS. The following local adverse reactions have been reported with topical corticosteroids: burning sensations, itching, irritation, dryness, folliculitis, secondary infection, skin atrophy, striae, hypertrichosis, acneform eruptions, and hypopigmentation.

DOSAGE AND ADMINISTRATION. Apply to affected areas two to four times daily as needed.

HOW SUPPLIED. N 0071-3025 Uticort Gel is supplied in 15-g and 60-g tubes.

Caution: Federal law prohibits dispensing without prescription.

PARKE-DAVIS

Gets to deep fungal infections

Actual photograph of tinea unguium infection (onychomycosis).
Note typical worm-eaten appearance of fingernail destroyed by fungus.

when topicals can't.

Potent, systemic fungistat

GRISACTIN provides the antifungal activity needed to control tinea infections, including onychomycosis, that invade the dermis and deeper regions. Systemic action penetrates where topical action often fails.

GRISACTIN is effective against a wide range of fungi: *Trichophyton rubrum, T. mentagrophytes, T. tonsurans, T. interdigitalis, T. verrucosum, T. megnini, T. gallinae, T. crateriform, T. sulphureum, T. schoenleini, Microsporum canis, M. audouini, M. gypseum,* and *Epidermophyton floccosum.*

Peak serum levels are usually produced in about four hours with a single 500 mg. tablet. To meet the requirements of different patients—depending on body weight, age, severity, and location of infection—dosage is easily individualized with 125 mg. and 250 mg. capsules, and 500 mg. tablets.

Grisactin® 500

BRAND OF

griseofulvin (microsize) TABLETS

BRIEF SUMMARY
(For full prescribing information, see package circular.)

Grisactin®
Brand of
Griseofulvin (microsize)

Indications: Griseofulvin is indicated for the treatment of ringworm infections of the skin, hair, and nails, namely: *Tinea corporis, Tinea pedis, Tinea cruris, Tinea barbae, Tinea capitis, Tinea unguium* (onychomycosis) when caused by one or more of the following genera of fungi: *Trichophyton rubrum, T. tonsurans, T. mentagrophytes, T. interdigitalis, T. verrucosum, T. megnini, T. gallinae, T. crateriform, T. sulphureum, T. schoenleini, Microsporum audouini, M. canis, M. gypseum, Epidermophyton floccosum.*
NOTE: Prior to therapy, the type of fungi responsible for the infection should be identified.
The use of this drug is not justified in minor or trivial infections which will respond to topical agents alone.
Griseofulvin is *not* effective in the following: Bacterial infections, candidiasis (moniliasis), histoplasmosis, actinomycosis, sporotrichosis, chromoblastomycosis, coccidioidomycosis, North American blastomycosis, cryptococcosis (torulosis), *Tinea versicolor,* nocardiosis.
Contraindications: This drug is contraindicated in patients with porphyria, hepatocellular failure, and in individuals with a history of hypersensitivity to griseofulvin.
Warnings: *Prophylactic Usage*—Safety and efficacy of griseofulvin for prophylaxis of fungal infections has not been established.
Animal Toxicology—Chronic feeding of griseofulvin, at levels ranging from 0.5-2.5% of the diet, resulted in the development of liver tumors in several strains of mice, particularly in males. Smaller particle sizes result in an enhanced effect. Lower oral dosage levels have not been tested. Subcutaneous administration of relatively small doses of griseofulvin, once a week, during the first three weeks of life has also been reported to induce hepatomata in mice. Although studies in other animal species have not yielded evidence of tumorigenicity, these studies were not of adequate design to form a basis for conclusions in this regard.
In subacute toxicity studies, orally administered griseofulvin produced hepatocellular necrosis in mice, but this has not been seen in other species. Disturbances in porphyrin metabolism have been reported in griseofulvin-treated laboratory animals. Griseofulvin has been reported to have a colchicine-like effect on mitosis and cocarcinogenicity with methylcholanthrene in cutaneous tumor induction in laboratory animals.
Usage in Pregnancy—The safety of this drug during pregnancy has not been established.
Animal Reproduction Studies—It has been reported in the literature that griseofulvin was found to be embryotoxic and teratogenic on oral administration to pregnant rats. Pups with abnormalities have been reported in the litters of a few bitches treated with griseofulvin. Additional animal reproduction studies are in progress.
Suppression of spermatogenesis has been reported to occur in rats, but investigation in man failed to confirm this.
Precautions: Patients on prolonged therapy with any potent medication should be under close observation. Periodic monitoring of organ system function, including renal, hepatic, and hematopoietic, should be done.
Since griseofulvin is derived from a species of Penicillium, the possibility of cross-sensitivity with penicillin exists; however, known penicillin-sensitive patients have been treated without difficulty.
Since a photosensitivity reaction is occasionally associated with griseofulvin therapy, patients should be warned to avoid exposure to intense natural or artificial sunlight. Should a photosensitivity reaction occur, lupus erythematosus may be aggravated.
Griseofulvin decreases the activity of warfarin-type anticoagulants so that patients receiving these drugs concomitantly may require dosage adjustment of the anticoagulant during and after griseofulvin therapy.
Barbiturates usually depress griseofulvin activity and concomitant administration may require a dosage adjustment of the antifungal agent.
Adverse Reactions: When adverse reactions occur, they are most commonly of the hypersensitivity type such as skin rashes, urticaria, and rarely, angioneurotic edema, and may necessitate withdrawal of therapy and appropriate countermeasures. Paresthesias of the hands and feet have been reported rarely after extended therapy. Other side effects reported occasionally are oral thrush, nausea, vomiting, epigastric distress, diarrhea, headache, fatigue, dizziness, insomnia, mental confusion, and impairment of performance of routine activities.
Proteinuria and leukopenia have been reported rarely. Administration of the drug should be discontinued if granulocytopenia occurs.
When rare, serious reactions occur with griseofulvin, they are usually associated with high dosages, long periods of therapy, or both.
Dosage and Administration: Accurate diagnosis of the infecting organism is essential. Medication must be continued until the infecting organism is completely eradicated as indicated by appropriate clinical or laboratory examination. General measures in regard to hygiene should be observed to control sources of infection or reinfection. Concomitant use of appropriate topical agents is usually required, particularly in treatment of *tinea pedis.*
Dosage should be individualized, depending on age and severity of infection. *Adults*—0.5 Gm. daily (125 mg. q.i.d., 250 mg. b.i.d., or 500 mg./day). *Children*—10 mg./kg. daily is usually adequate (from 30 to 50 lb., 125 mg. to 250 mg. daily; over 50 lb., 250 mg. to 500 mg. daily, in divided doses).
How Supplied: GRISACTIN [griseofulvin (microsize)]—No. 442—GRISACTIN 125, each capsule contains 125 mg., in bottles of 100 and 500. No. 443—GRISACTIN 250, each capsule contains 250 mg., in bottles of 100 and 500. No. 444—GRISACTIN 500, each tablet (scored) contains 500 mg., in bottles of 60.

Ayerst®
Ayerst Laboratories
New York, N.Y. 10017

7719

PSORIASIS
The Capricious Dermatosis

LIDEX® (fluocinonide) 0.05%
A Stabilizing Influence

Psoriasis. Mere mention of the word ca
make an afflicted patient cringe. And,
because of the capricious, unpredictab
nature of the disease, the patient rarely
knows where or when it will recur.

Obviously, the goal is control. And,
though varied treatment modalities are
available today, none offers universal

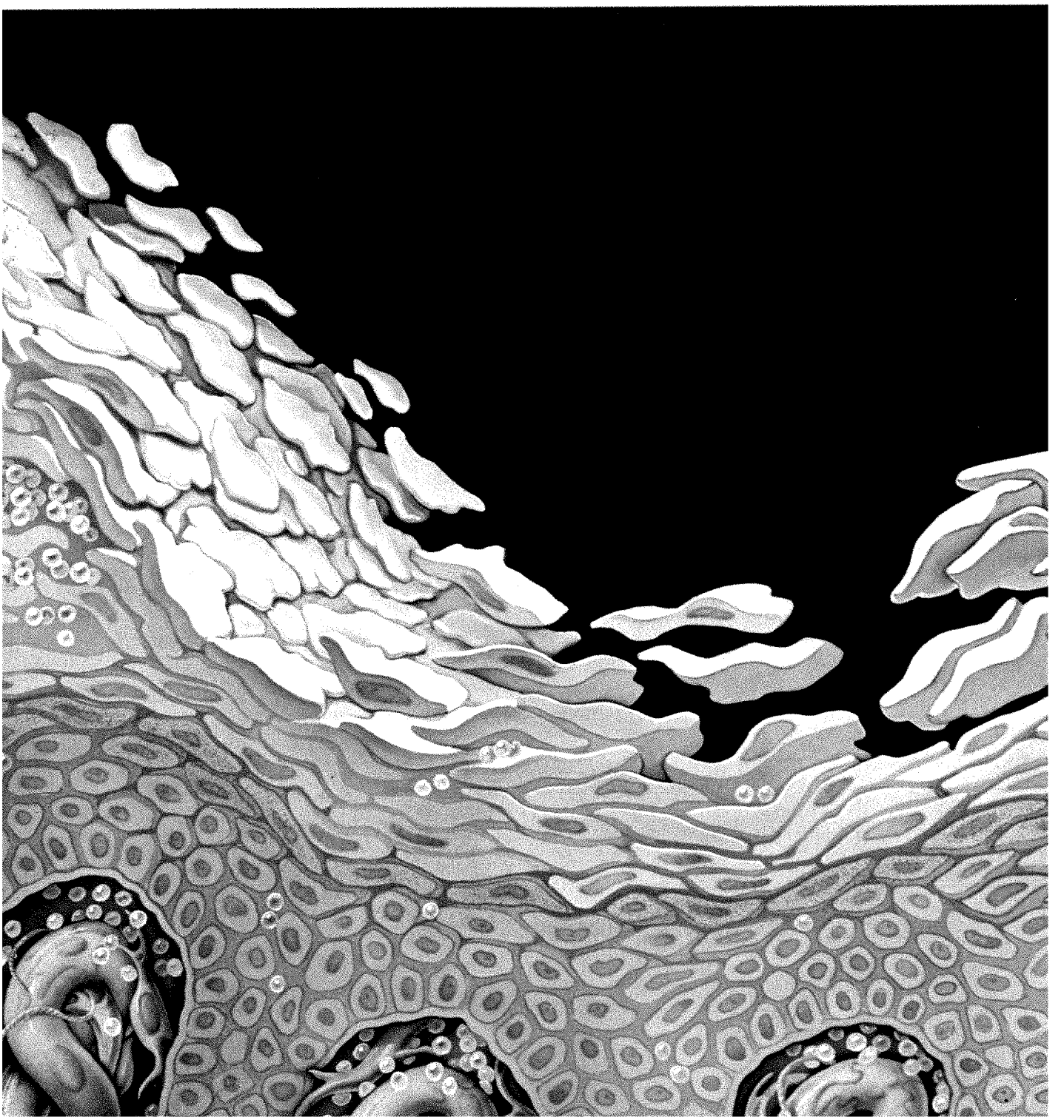

fficacy for all patients, all of the time.

Yet, very often a highly effective topical teroid, like Lidex, (fluocinonide) can ıelp stabilize psoriasis.

Lidex. A highly effective topical steroid vith anti-inflammatory, vasoconstrictive, ntipruritic actions.

100% dissolved for optimal penetration, important in stages that exhibit thickened, scaly lesions.

Totally free of preservatives.

Available in cream, ointment, and Topsyn® (fluocinonide) gel.

SYNTEX

SYNTEX LABORATORIES, INC.
PALO ALTO, CALIFORNIA 94304



(See following page.)

LIDEX® (fluocinonide)
0.05% Cream and Ointment

TOPSYN® (fluocinonide)
0.05% Gel

Summary of prescribing information

Description
LIDEX cream 0.05%, LIDEX ointment 0.05% and TOPSYN gel 0.05% contain the active compound fluocinonide. Fluocinonide, which is the 21-acetate ester of fluocinolone acetonide, has the chemical formula 6α, 9α, -difluoro-11β, 16α, 17α, 21-tetrahydroxypregna-1,4-diene-3, 20-dione, cyclic 16, 17-acetal with acetone 21-acetate. LIDEX cream contains fluocinonide in FAPG® cream, a specially formulated cream base consisting of stearyl alcohol, polyethylene glycol 6000, propylene glycol, 1, 2, 6-hexanetriol and citric acid. This white cream vehicle is greaseless, non-staining, anhydrous and completely water miscible. The base provides emollient and hydrophilic properties. In this formulation, the active ingredient is totally in solution.

LIDEX ointment contains fluocinonide in a specially formulated ointment base consisting of Amerchol CAB (mixture of sterols and higher alcohols), white petrolatum, propylene carbonate and propylene glycol. It provides the occlusive and emollient effects desirable in an ointment. In this formulation the active ingredient is totally in solution.

TOPSYN gel contains fluocinonide in a specially formulated gel base consisting of propylene glycol, propyl gallate, disodium edetate, and Carbopol 940 (carboxypolymethylene) with NaOH and/or HCL added to adjust the pH. This clear, colorless, thixotropic vehicle is greaseless, non-staining and completely water miscible. In this formulation, the active ingredient is totally in solution.

Indications
LIDEX cream and ointment and TOPSYN gel are intended for the relief of inflammatory manifestations of corticosteroid responsive dermatoses.

Contraindications
Topical steroids are contraindicated in vaccinia and varicella. Topical steroids are contraindicated in those patients with a history of hypersensitivity to any of the components of the preparation.

Precautions
If irritation develops, the cream, ointment or gel should be discontinued and appropriate therapy instituted. In the presence of an infection the use of an appropriate antifungal or antibacterial agent should be instituted.

If a favorable response does not occur promptly, the corticosteroid cream, ointment or gel should be discontinued until the infection has been adequately controlled.

If extensive areas are treated, the possibility exists of increased systemic absorption and suitable precautions should be taken.

Although topical steroids have not been reported to have an adverse effect on pregnancy, the safety of their use in pregnant females has not absolutely been established. Therefore, they should not be used extensively on pregnant patients, in large amounts or for prolonged periods of time.

LIDEX® (fluocinonide) cream and ointment and TOPSYN® (fluocinonide) gel are not for opthalmic use.

Adverse reactions
The following local adverse reactions have been reported with topical corticosteroids:

burning	folliculitis
itching	acneform eruptions
irritation	hypopigmentation
dryness	striae
secondary infection	skin atrophy

Dosage and administration
A small amount should be gently massaged into the affected area three or four times daily, as needed.

How supplied
LIDEX 0.05% Cream – 15 g 30 g and 60 g tubes.
LIDEX 0.05% Ointment – 15 g 30 g and 60 g tubes.
TOPSYN Gel 0.05% 15 g and 60 g tubes.

SYNTEX
SYNTEX LABORATORIES, INC.
PALO ALTO, CALIFORNIA 94304

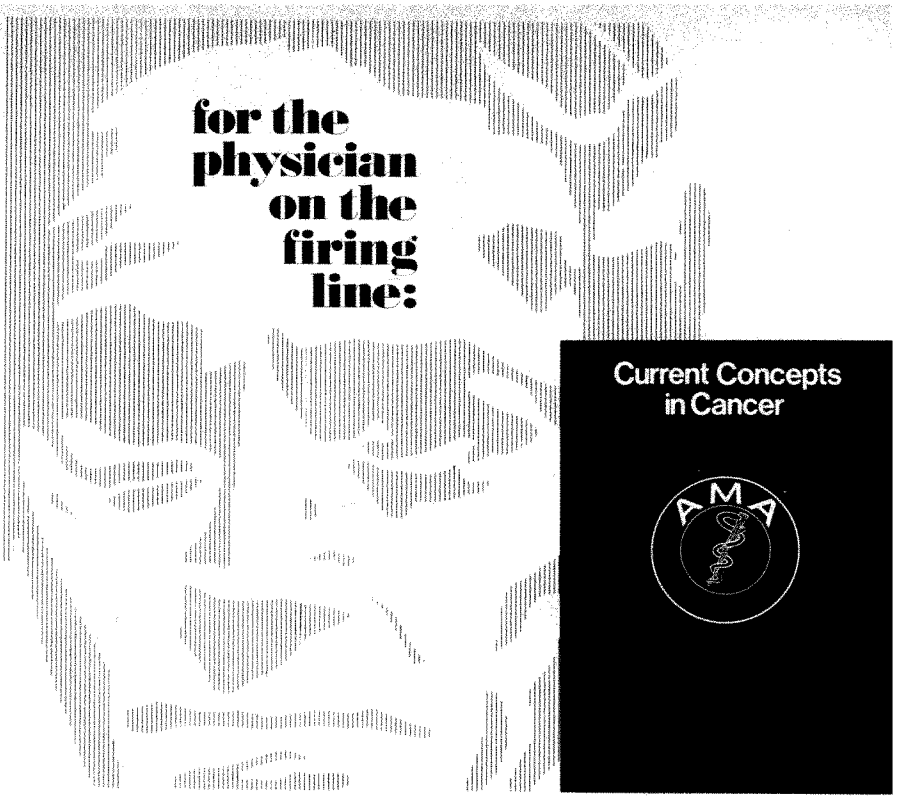

A valuable guide to diagnostic and therapeutic procedures for the cancer patient

Current Concepts in Cancer

While national attention focuses on cancer through specialized cancer centers, physicians are aware that the majority of cancer patients are treated in office practices. For most practicing physicians, cancer treatment is not a research objective, but a very practical problem in patient management.

Current Concepts in Cancer, a compilation of articles originally published in the *Journal of the American Medical Association,* is designed to be a guide for the practitioner in the choice of diagnostic and therapeutic procedures for many types of malignancies. It presents an objective interdisciplinary view by MDs outstanding in their respective fields, emphasizing principles of diagnosis and surgical radiotherapeutic, and chemotherapeutic treatment.

Make this important resource a part of your reference file. Order your copy today.

American Medical Association S/J
535 North Dearborn Street
Chicago, Illinois 60610

Please send me _____ copy(ies) of **Current Concepts in Cancer** (OP-281). Price is $10 per copy. Please enclose your remittance with order.

Please Print

Name _____

Address _____

City _____ State _____ Zip _____



MINOCIN Minocycline HCl
Oral and Intravenous Brief Summary
Contraindications: Hypersensitivity to any tetracycline.
Warnings: Intravenous use, particularly in pregnancy, in daily doses exceeding 2 grams has been associated with deaths through liver failure. When need for intensive treatment outweighs potential dangers, perform renal and liver function tests before and during therapy; also follow serum concentrations. In renal impairment, usual doses may lead to excessive accumulation and liver toxicity. Under such conditions, use lower total doses, and, in prolonged therapy, determine serum levels. This hazard is of particular importance in I.V. use in pregnant or postpartum patients with pyelonephritis. In such cases, the blood level should not exceed 15 mcgm/ml, and liver function tests should be made at frequent intervals. Do not prescribe other potentially hepatotoxic drugs concomitantly. The use of tetracyclines during tooth development (last half of pregnancy, infancy and childhood to the age of 8 years) may cause permanent discoloration of the teeth (yellow-gray-brown). This is more common during long-term use but has been observed following repeated short-term courses. Enamel hypoplasia has also been reported. Tetracyclines, therefore, should not be used in this age group unless other drugs are not likely to be effective or are contraindicated. Photosensitivity manifested by an exaggerated sunburn reaction has been observed in some individuals taking tetracyclines. Advise patients apt to be exposed to direct sunlight or ultraviolet light that such reaction can occur, and discontinue treatment at first evidence of skin erythema. Studies to date indicate that photosensitivity is rarely reported with MINOCIN *Minocycline HCl*. In patients with significantly impaired renal function, the antianabolic action of tetracycline may cause an [illegible] acidosis. CNS side effects (lightheadedness, dizziness, vertigo) have been reported, may disappear during therapy, and always disappear rapidly when drug is discontinued. Caution patients who experience these symptoms about driving vehicles or using hazardous machinery while taking this drug. **Pregnancy:** In animal studies, tetracyclines cross the placenta, are found in fetal tissues, and can have toxic effects on the developing fetus (often related to retardation of skeletal development). Embryotoxicity has been noted in animals treated early in pregnancy. **Newborns, infants and children:** All tetracyclines form a stable calcium complex in any bone-forming tissue. Prematures, given oral doses of 25 mg./kg. every 6 hours, demonstrated a decrease in fibula growth rate; reversible when drug was discontinued. Tetracyclines are present in the milk of lactating women who are taking a drug in this class.
Precautions: Use may result in overgrowth of nonsusceptible (cont'd)

Staph infection: Skin deeper

When the patient is penicillin-hypersensitive, when bacteriologic testing shows *Staph. aureus* to be resistant or the infection has proved unresponsive, MINOCIN *Minocycline HCl* may be an effective alternative.* Clinical studies have demonstrated satisfactory response in 156 of 173 simple or mixed skin and soft tissue infections due to staphylococci.

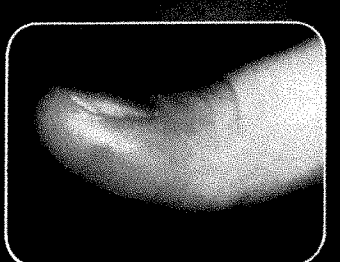

Actual patient photograph after 7 days of MINOCIN.

MINOCIN®
MINOCYCLINE HCl

CAPSULES 50 mg and 100 mg
SYRUP 50 mg/5 cc
INTRAVENOUS 100 mg/vial

100 or 200 mg initially, 50 mg *q.i.d.*
or 200 mg initially, 100 mg *b.i.d.*

*Tetracyclines are not the drugs of choice in the treatment of any type of staphylococcal infection. MINOCIN is indicated for treatment of *Staphylococcus aureus* skin and soft tissue infections only when bacteriologic tests indicate appropriate susceptibility to the drug.

MINOCIN Minocycline HCl
Oral and Intravenous Brief Summary (continued)
organisms, including fungi. If superinfection occurs, institute appropriate therapy. In venereal diseases when coexistent syphilis is suspected, darkfield examination should be done before treatment is started and blood serology repeated monthly for at least four months. Patients on anticoagulant therapy may require downward adjustment of such dosage. Test for organ system dysfunction (*e.g.*, renal, hepatic and hemopoietic) in long-term use. Treat all group A beta-hemolytic streptococcal infections for at least 10 days. Avoid giving tetracycline in conjunction with penicillin.
Adverse Reactions: GI: (with both oral and parenteral use): anorexia, nausea, vomiting, diarrhea, glossitis, dysphagia, enterocolitis, inflammatory lesions (with monilial overgrowth) in anogenital region. **Skin:** maculopapular and erythematous rashes. Exfoliative dermatitis (uncommon). Photosensitivity is discussed above ("Warnings"). **Renal toxicity:** rise in BUN, dose-related (see "Warnings"). **Hypersensitivity reactions:** urticaria, angioneurotic edema, anaphylaxis, anaphylactoid purpura, pericarditis, exacerbation of systemic lupus erythematosus. In young infants, bulging fontanels have been reported following full therapeutic dosage, disappearing rapidly when drug was discontinued. **Blood:** hemolytic anemia, thrombocytopenia, neutropenia, eosinophilia. **CNS:** (see "Warnings"). When given in high doses, tetracyclines may produce brown-black microscopic discoloration of thyroid glands; no abnormalities of thyroid function studies are known to occur. **NOTE: Concomitant therapy:** Antacids containing aluminum, calcium, or magnesium impair absorption; do not give to patients taking oral minocycline. Studies to date indicate that absorption of MINOCIN *Minocycline HCl* is not notably influenced by foods and dairy products.

CNS side effects including lightheadedness, dizziness, or vertigo have been reported with MINOCIN. Patients who experience these symptoms should be cautioned about driving vehicles or using hazardous machinery while on minocycline therapy.

Lederle

LEDERLE LABORATORIES
A Division of American Cyanamid Com
Pearl River, N.Y. 10965

New From Dermik

Hytone®

CREAM (HYDROCORTISONE)

2½%

hydrocortisone safety . . . new high potency . . .

- Atopic Dermatitis
- Severe Diaper Dermatitis
- Seborrheic Dermatitis
- Lichen Simplex Chronicus
- Pruritus Ani

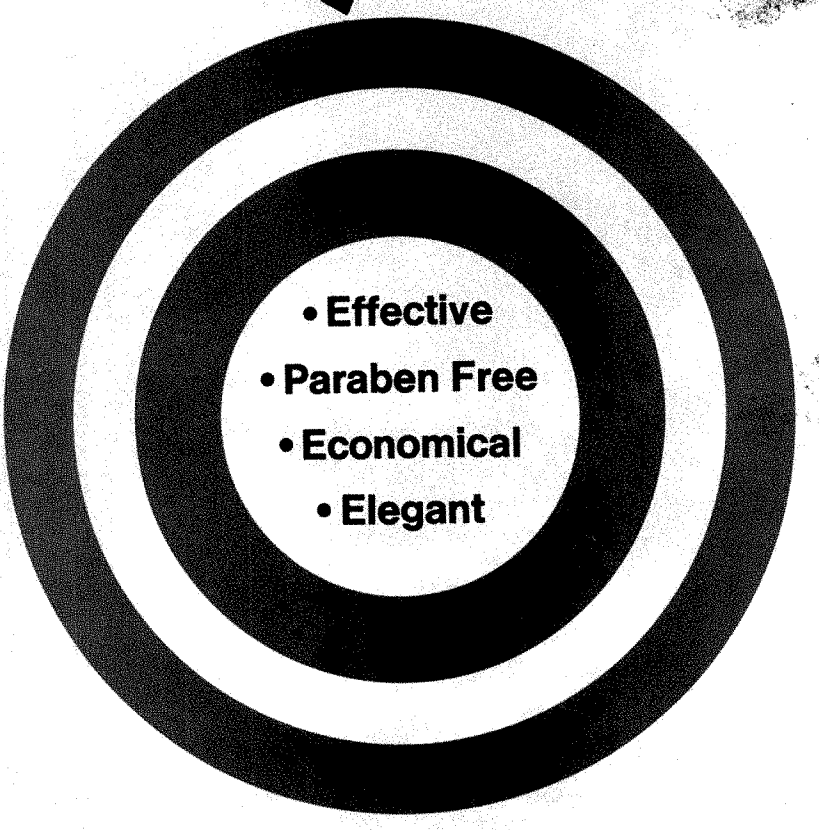

Dermik

Dermik Laboratories, Inc., Fort Washington, Pa. 19034
WHERE RESEARCH AND ECONOMY COME FIRST!

DESCRIPTION – Hydrocortisone 2½%, 1% and ½% in a water-washable cream containing purified water, propylene glycol, isopropyl myristate, cholesterol and related sterols, cetyl alcohol, sorbic acid, glyceryl monostearate, polysorbate 60, sorbitan monostearate and polyoxyl 40 stearate.

ACTIONS – Topical corticosteroids are effective primarily because of their antiinflammatory, antipruritic, and vasoconstrictive actions.

INDICATIONS – For relief of the inflammatory manifestations of corticosteroid-responsive dermatoses.

CONTRAINDICATIONS: In viral diseases of the skin such as varicella and vaccinia and in patients with a history of hypersensitivity to any component. Not for ophthalmic use. Topical steroids should not be used when circulation is markedly impaired.

WARNING: Should not be used extensively, in large amounts, or for prolonged periods in pregnancy.

appropriate therapy instituted. In the presence of an infection, the use of appropriate antifungal or antibacterial agents should be instituted. If a favorable response does not occur promptly, the corticosteroid should be discontinued until the infection has been adequately controlled. If extensive areas are treated or if the occlusive technique is used, the possibility exists of increased systemic absorption of the corticosteroid and suitable precautions should be taken.

ADVERSE REACTIONS – The following local adverse reactions have been reported with topical corticosteroids, either with or without occlusive dressings: burning sensations, itching, irritation, dryness, folliculitis, secondary infection, skin atrophy, striae, hypertrichosis, acneform eruption and hypopigmentation.

DOSAGE AND ADMINISTRATION – Apply to affected areas 3 or 4 times daily.

HOW SUPPLIED: Tubes – ½ oz., 1 oz.

In depth studies of the health care systems of Britain and France

how they operate and what they mean to users and to people who work in them.

To order your copies, return the coupon below today!

Order Handling, AMA, 535 N. Dearborn St., Chicago, IL 60610

Please send me _____ copy(ies) of the book(s) below.

☐ The French Health Care System	OP-460	at $3.50
☐ The British Health Care System	OP-461	at $7.50

Name _____

Address _____

City/State/Zip _____

Remittance, made payable to AMA, must accompany order.

S/J

Britain employs a predominantly nationalized free-to-user health care system. France offers its citizens a comprehensive health and social insurance system.

These highly readable, comprehensive studies, prepared by a research firm in London and published by the American Medical Association, offer an opportunity to step inside each system to examine its administration...evaluate its achievements and problems...and to get a feel for what it's like to use it and work within it.

What's more, you'll learn how and why the present systems evolved...how they are financed ...the range and quality of services available... the training and distribution of medical personnel...and what effects each system has had upon the health of the general population.

Everyone in the medical profession should read both of these fascinating studies on how other nations have organized the delivery of health care.

what's best for the care of dry, or premature aging or wrinkled skin... DUE TO EPIDERMAL DEHYDRATION?

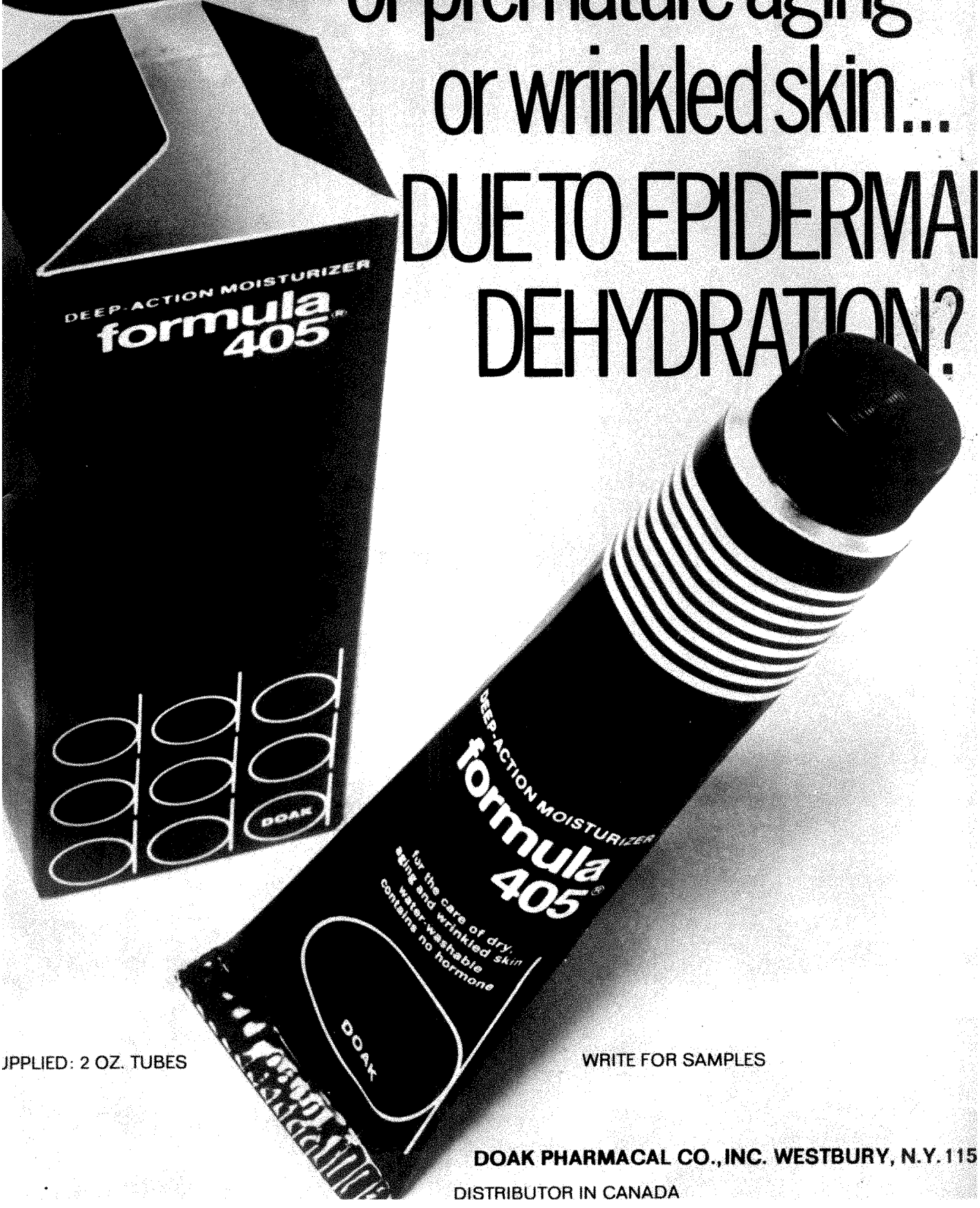

JPPLIED: 2 OZ. TUBES

WRITE FOR SAMPLES

DOAK PHARMACAL CO., INC. WESTBURY, N.Y. 115

DISTRIBUTOR IN CANADA

For Skin Without Water

Neutrogena® Dry Skin products are specially formulated to supplement surface fats and aid in the retention of moisture.

- Neutrogena® Dry-Skin Soap contains humectants, lubricants, and emollients to soften and moisturize, and is nonirritating to sensitive skin.
- Neutrogena® Rainbath® Dry Skin Bath Gel is lipid-free, cleanses with a rich lather without the drying effect of ordinary soap, and leaves skin soft and smooth. Available both scented and unscented.
- Neutrogena® Hand Cream is a heavy-duty formula containing a special blend of naturally occurring oils and glycerin, and is a useful adjunct in steroid-responsive hand dermatoses.[1]

1. Data on file, Medical Dept., Neutrogena Corp.

Neutrogena®
Dedicated to Sensitive Skin Care

Neutrogena Corp.
5755 West 96th Street
Los Angeles, California 90045

This timely volume explores how plant and animal life has evolved to adapt to the ultraviolet "load" from the sun including the continuous repair of radiation damage. Focusing on ultraviolet photobiology, the author details the factors that might upset the delicate balance between radiation injury and repair, such as:

LIVING WITH OUR SUN'S ULTRA-VIOLET RAYS

- reduction of the ozone layer by stratospheric pollution
- natural dyes, medications, and pollutants which absorb light and pass its energy to sensitive chemicals in the cell
- the absence of radiation repair mechanisms in mutant cells.

by **Arthur C. Giese,**
Stanford University

The book reviews the nature of the sun's ultraviolet radiation as it reaches the surface of the earth today, and as it probably affected the earth in the distant past. It covers both the beneficial and harmful effects of such radiation on all life—unicellular organisms as well as multicellular plants and animals. Since the effects of the rays on an organism are primarily a result of their action upon cells, and interactions between cells, the major emphasis is on cellular response to the sun's ultraviolet radiation. Specific problems of pollution and skin damage, particularly sunburn, premature aging, and cancer induction, are discussed in detail.
185 pages, illus., 1976, $19.50

PLENUM PUBLISHING CORPORATION, 227 West 17th Street, New York, N.Y. 10011
In United Kingdom: Black Arrow House, 2 Chandos Road, London NW10 6NR, England
Prices subject to change without notice. Prices slightly higher outside the U.S.

Laboratory Services

(On Hair and Other Organic Materials*)

1. Amino Acid Analysis
2. Mechanical Optical Properties
3. Scanning Electron Microscopy
4. Trace Metal Analysis
   Lead, Arsenic, Cadmium, Mercury, Zinc, Copper, Magnesium and many more
5. Transmission Electron Microscopy
6. plus many other capabilities and their...

... **Medical** importance are described in the new **Laboratory Handbook.**

Yours for the asking from

**including blood and urine*

P.S.
Call Toll Free
(800) 423-3062
In California
Call Collect
(213) 781-4934

REMEDCO
ANALYTICAL LABORATORY
HEW Lic. #04-1156
14721 Califa Street, Van Nuys, CA 91411

For Skin Plagued by Acne

Neutrogena® Acne products aid in drying while they clean and degrease acne-plagued skin.

- Neutrogena® Acne-Cleansing Soap gently cleanses and degreases the skin, and does not interfere with topical or systemic acne treatment.
- Neutrogena® Acne-Drying Gel combines antisepsis with astringency, contains 47% active drying agents, is perfume-free, can be applied under or over makeup, and is imperceptible on the skin.

Neutrogena®
Dedicated to Sensitive Skin Care

Neutrogena Corp.
5755 West 96th Street
Los Angeles, California 90045

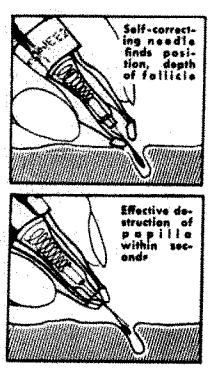

Perma Tweez®

ELECTROLYSIS FOR PERMANENT HAIR REMOVAL

Clinical study (copy on request) proves safety and efficacy of laity self-use electrolysis. Study shows chin and even axilla can be self-treated effectively through use of mirror. This permanent hair remover features the only patented self-correcting needle in existence. Battery operated instrument sterilizes itself when current flows. No-puncture safety feature also helps prevent infection.

Thousands of units sold to physicians for such varied application as removal of inverted eyelashes to cosmetic use.

PERMA TWEEZ & ATTACHMENT $22.45

☐ Invoice after 30 days

☐ Check enclosed

30 DAY FREE TRIAL EXAMINATION

(MAY BE RETURNED WITH NO OBLIGATION)

GENERAL MEDICAL CO., Dept. D-85
1935 Armacost Ave
West Los Angeles, CA 90025

DR _____

STREET _____

C/S _____ ZIP _____


anti-
inflammatory
antifungal
antipruriti
antibacterial

Clear choice

When dermatoses become infected with bacteria or fungi, plain topical steroids are generally not the recommended therapeutic choice.

A clear choice, however, is Vioform-® Hydrocortisone. With its unique four-way action, it supplies the kind of comprehensive treatment many common dermatoses* require.

*This drug has been evaluated as possibly effective for these indications. See brief prescribing information.

Vioform®-Hydrocortisone (iodochlorhydroxyquin and hydrocortisone)

INDICATIONS
Based on a review of this drug by the National Academy of Sciences-National Research Council and/or other information, FDA has classified the indications as follows:
"Possibly" effective: Contact or atopic dermatitis; impetiginized eczema; nummular eczema; infantile eczema; endogenous chronic infectious dermatitis; stasis dermatitis; pyoderma; nuchal eczema and chronic eczematoid otitis externa; acne urticata; localized or disseminated neurodermatitis; lichen simplex chronicus; anogenital pruritus (vulvae, scroti, ani); folliculitis; bacterial dermatoses; mycotic dermatoses such as tinea (capitis, cruris, corporis, pedis); moniliasis; intertrigo.
Final classification of the less-than-effective indications requires further investigation.

CONTRAINDICATIONS
Hypersensitivity to Vioform-Hydrocortisone, or any of its ingredients or related compounds; lesions of the eye; tuberculosis of the skin; most viral skin lesions (including herpes simplex, vaccinia and varicella).

WARNINGS
This product is not for ophthalmic use.
In the presence of systemic infections, appropriate systemic antibiotics should be used.

Usage in Pregnancy
Although topical steroids have not been reported to have an adverse effect on pregnancy, the safety of their use in pregnant females has not been established. Therefore, they should not be used extensively on pregnant patients in large amounts or for prolonged periods of time.

PRECAUTIONS
May prove irritating to sensitized skin in rare cases. If this occurs, discontinue therapy. May stain.
If used under occlusive dressings or for a prolonged period, watch for signs of pituitary-adrenal axis suppression.
May interfere with thyroid function tests. Wait at least one month after discontinuance of therapy before performing these tests. The ferric chloride test for phenylketonuria (PKU) can yield a false-positive result if Vioform is present in the diaper or urine.
Prolonged use may result in overgrowth of nonsusceptible organisms requiring appropriate therapy.

ADVERSE REACTIONS
Few reports include: Hypersensitivity, local burning, irritation, pruritus. Discontinue if untoward reaction occurs. Rarely, topical corticosteroids may cause striae at site of application when used for long periods in intertriginous areas.

DOSAGE
Apply a thin layer to affected areas 3 or 4 times daily.

HOW SUPPLIED
Cream, 3% iodochlorhydroxyquin and 1% hydrocortisone in a water-washable base containing stearyl alcohol, cetyl alcohol, stearic acid, petrolatum, sodium lauryl sulfate, and glycerin in water; tubes of 5 and 20 Gm. *Ointment*, 3% iodochlorhydroxyquin and 1% hydrocortisone in a petrolatum base; tubes of 20 Gm. *Lotion*, 3% iodochlorhydroxyquin and 1% hydrocortisone in a water-washable base containing stearic acid, cetyl alcohol, lanolin, propylene glycol, sorbitan trioleate, polysorbate 60, triethanolamine, methylparaben, propylparaben, and perfume Flora in water; plastic squeeze bottles of 15 ml. *Mild Cream*, 3% iodochlorhydroxyquin and 0.5% hydrocortisone in a water-washable base containing stearyl alcohol, cetyl alcohol, stearic acid, petrolatum, sodium lauryl sulfate, and glycerin in water; tubes of ½ and 1 ounce. *Mild Ointment*, 3% iodochlorhydroxyquin and 0.5% hydrocortisone in a petrolatum base; tubes of 1 ounce.
C75-38 Rev. 7/75

Consult complete product literature before prescribing.

CIBA Pharmaceutical Company
Division of CIBA-GEIGY Corporation
Summit, New Jersey 07901

2/7853 17

Vioform®-Hydrocortisone (iodochlorhydroxyquin and hydrocortisone)

The most widely prescribed form... 20-Gm Cream

CIBA

Acne illustrated by artist.

VECTRIN Capsules, 100 mg
(minocycline HCl capsules, USP)
Brief Summary of Prescribing Information

Indicated in severe acne as adjunctive therapy. Consult package insert for complete prescribing information.

Contraindication: Hypersensitivity to any tetracycline.

Warnings: When need for intensive treatment outweighs potential dangers, perform renal and liver function tests before and during therapy; also follow serum concentrations. In renal impairment, usual doses may lead to excessive accumulation and liver toxicity. Under such conditions, use lower total doses, and, in prolonged therapy, determine serum levels. The use of tetracyclines during tooth development (last half of pregnancy, infancy, and childhood to the age of 8 years) may cause permanent discoloration of the teeth (yellow-gray-brown). This is more common during long-term use but has been observed following repeated short-term courses. Enamel hypoplasia has also been reported. Tetracyclines, therefore, should not be used in this age group unless other drugs are not likely to be effective or are contraindicated. Photosensitivity manifested by an exaggerated sunburn reaction has been observed in some individuals taking tetracyclines. Advise patients apt to be exposed to direct sunlight or ultraviolet light that such reaction can occur, and discontinue treatment at first evidence of skin erythema. Studies with minocycline HCl indicated that photosensitivity did not occur. However, reports have been received. In patients with significantly impaired renal function, the antianabolic action of tetracycline may cause an increase in BUN leading to azotemia, hyperphosphatemia, and acidosis. **CNS side effects:** (light-headedness, dizziness, vertigo) have been reported, may disappear during therapy, and always disappear rapidly when drug is discontinued. Caution patients who experience these symptoms about driving vehicles or using hazardous machinery while taking this drug. **Pregnancy:** In animal studies, tetracyclines cross the placenta, are found in fetal tissues, and can have toxic effects on the developing fetus (often related to retardation of skeletal development). Embryotoxicity has been noted in animals treated early in pregnancy. The safety of minocycline HCl for use during pregnancy has not been established. **Newborns, infants, and children:** All tetracyclines form a stable calcium complex in any bone-forming tissue. Prematures, given oral doses of 25 mg/kg every six hours, demonstrated a decrease in fibula growth rate reversible when drug was discontinued. Tetracyclines

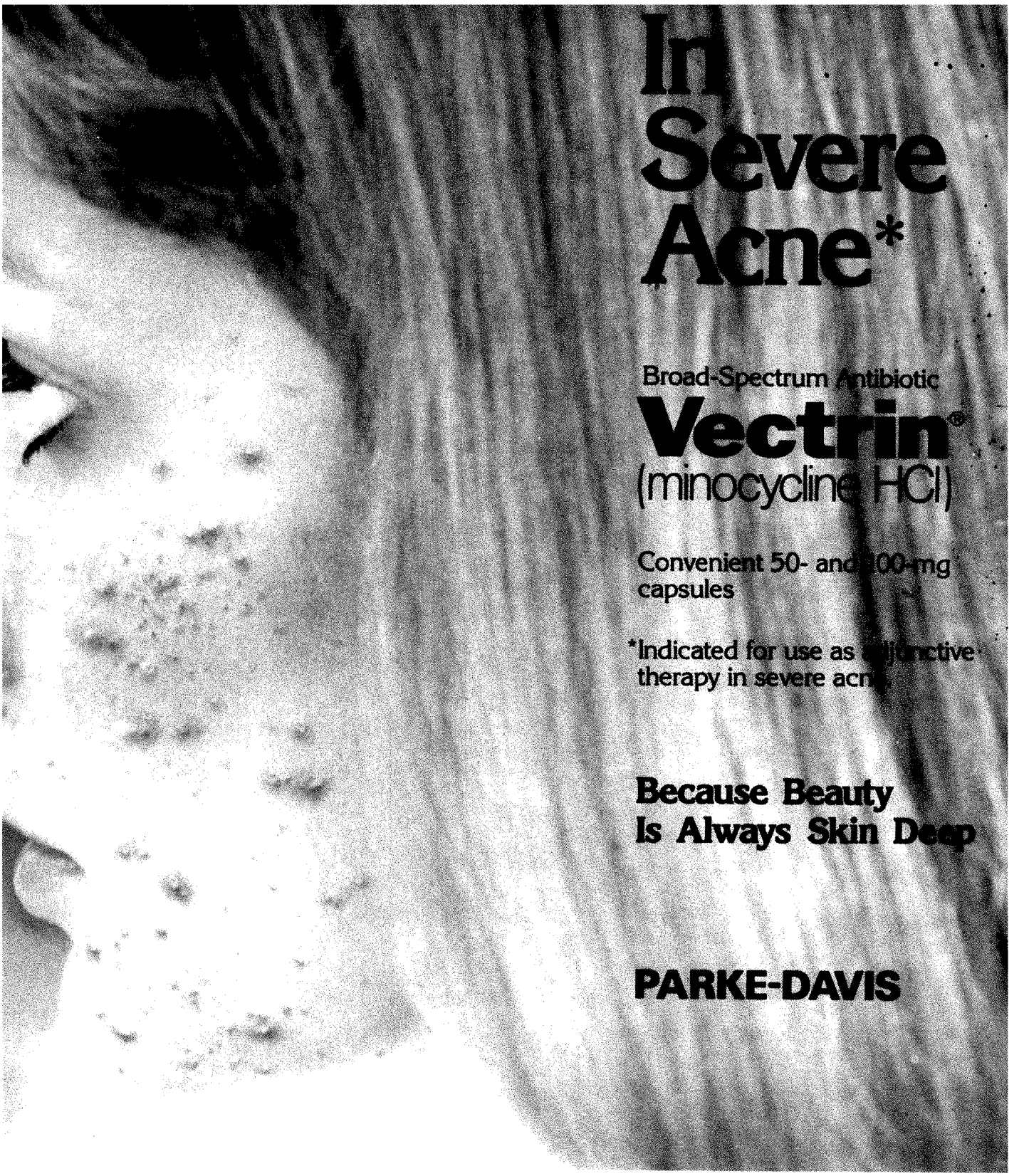

In Severe Acne*

Broad-Spectrum Antibiotic

Vectrin®

(minocycline HCl)

Convenient 50- and 100-mg capsules

*Indicated for use as adjunctive therapy in severe acne.

Because Beauty Is Always Skin Deep

PARKE-DAVIS

are present in the milk of lactating women who are taking a drug in this class.

Precautions: Use may result in overgrowth of non-susceptible organisms, including fungi. If superinfection occurs, antibiotics should be discontinued and appropriate therapy instituted. In venereal diseases when coexistent syphilis is suspected, darkfield examination should be done before treatment is started and blood serology repeated monthly for at least four months. Patients on anticoagulant therapy may require downward adjustment of such dosage. Test for organ system dysfunction (eg, renal, hepatic, and hemopoietic) in long-term use. Treat all group A beta-hemolytic streptococcal infections for at least 10 days. Avoid giving tetracycline in conjunction with penicillin.

Adverse Reactions: GI: Anorexia, nausea, vomiting, diarrhea, glossitis, dysphagia, enterocolitis, inflammatory lesions (with monilial overgrowth) in anogenital region. **Skin:** Maculopapular and erythematous rashes. Exfoliative dermatitis (uncommon). Photosensitivity is discussed above. (See Warnings.) **Renal toxicity:** Rise in BUN, dose-related. (See Warnings.) **Hypersensitivity reactions:** Urticaria, angioneurotic edema, anaphylaxis, anaphylactoid purpura, pericarditis, exacerbation of systemic lupus erythematosus. In young infants, bulging fontanels have been reported following full therapeutic dosage, disappearing rapidly when drug was discontinued. **Blood:** Hemolytic anemia, thrombocytopenia, neutropenia, eosinophilia. **CNS:** (See Warnings.) When given over prolonged periods, tetracyclines may produce brown-black microscopic discoloration of thyroid glands; no abnormalities of thyroid function studies are known to occur.

NOTE: Concomitant therapy: Antacids containing aluminum, calcium, or magnesium impair absorption; do not give to patients taking oral tetracycline. Studies to date indicate that absorption of VECTRIN (minocycline hydrochloride) is not notably influenced by foods and dairy products.

Full prescribing information available upon request.

PARKE, DAVIS & COMPANY
Detroit, Michigan 48232

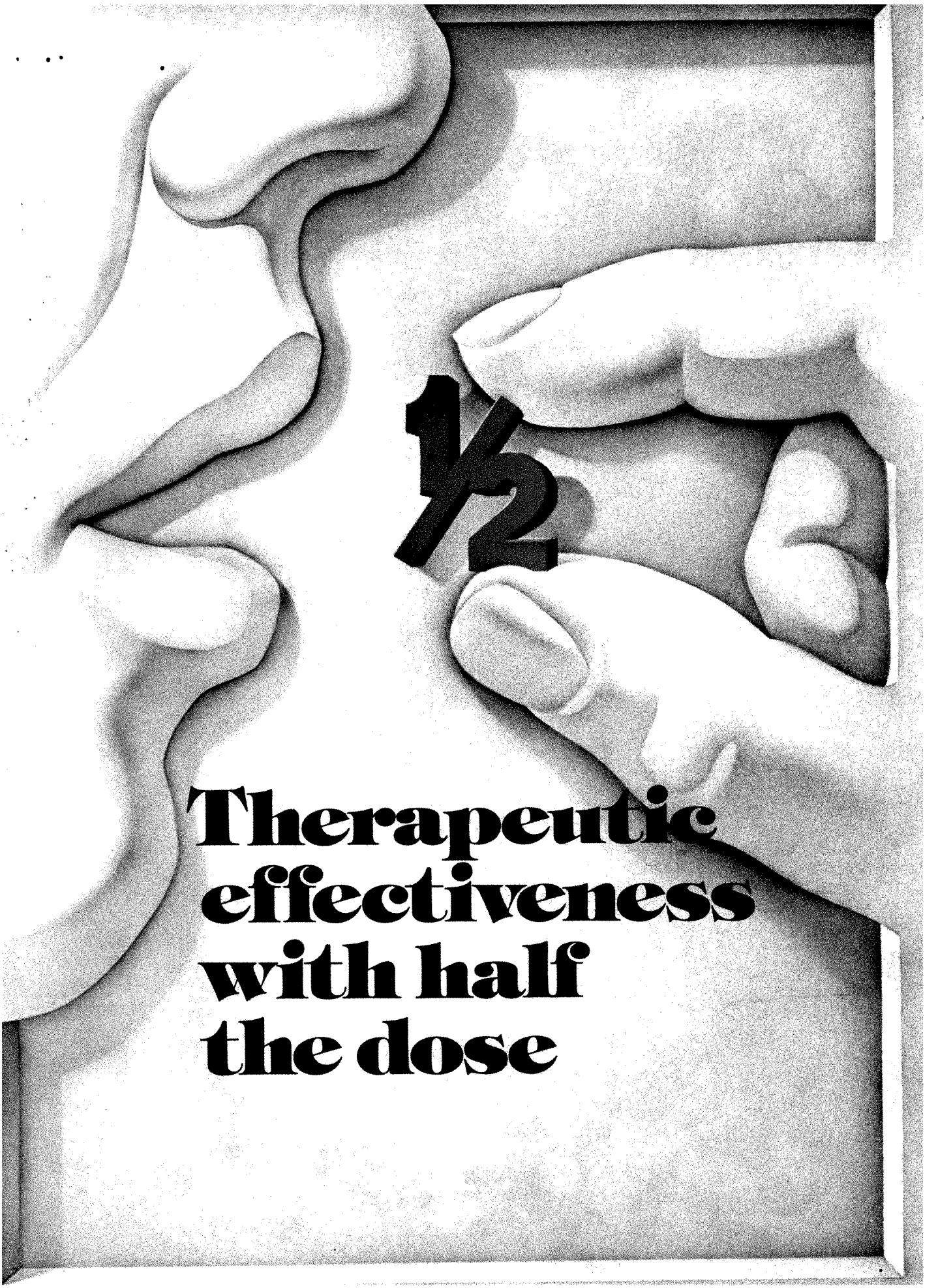
½
Therapeutic effectiveness with half the dose

Schering

Once-a-day dosage

NEW Fulvicin® P/G*

brand of griseofulvin [ultramicrosize], USP

(specially processed) **125 mg. tablets**

***"P/G" means a new polyethylene glycol system for enhanced absorption –**

A 250 mg. daily dose (two 125 mg. tablets) of new FULVICIN P/G can replace 500 mg. of griseofulvin (microsize), USP. This is made possible by a special process in which the ultramicrosize griseofulvin crystals are partly dissolved in polyethylene glycol and dispersed through the tablet matrix for enhanced absorption.

Patient convenience –

FULVICIN P/G can be prescribed as two 125 mg. tablets once a day. Compliance is further assured by the easy-to-swallow size of the tablets.

Patient savings –

FULVICIN P/G is up to 35 per cent less expensive per dose than all microsize griseofulvin formulations.**

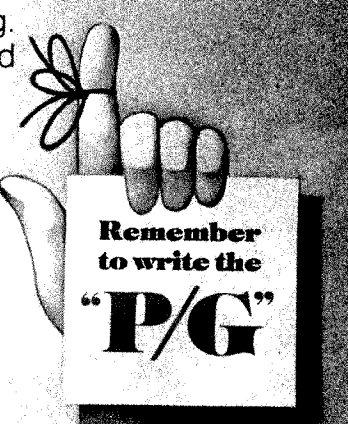

**Based on list-price comparison.

See Clinical Considerations section on following page.

COPYRIGHT ©1977, SCHERING CORPORATION. ALL RIGHTS RESERVED. SLS-703

Schering

NEW P/G Fulvicin P/G

griseofulvin [ultramicrosize], USP

(specially processed) **125 mg. tablets**

Clinical Considerations: INDICATIONS FULVICIN P/G Tablets are indicated for the treatment of ringworm infections of the skin, hair, and nails, namely, tinea corporis, tinea pedis, tinea cruris, tinea barbae, tinea capitis, tinea unguium (onychomycosis) when caused by one or more of the following genera of fungi: *Trichophyton rubrum, Trichophyton tonsurans, Trichophyton mentagrophytes, Trichophyton interdigitalis, Trichophyton verrucosum, Trichophyton megnini, Trichophyton gallinae, Trichophyton crateriform, Trichophyton sulphureum, Trichophyton schoenleini, Microsporum audouini, Microsporum canis, Microsporum gypseum,* and *Epidermophyton floccosum.* Note: Prior to therapy, the type of fungi responsible for the infection should be identified. The use of this drug is not justified in minor or trivial infections which will respond to topical agents alone. Griseofulvin is not effective in the following: Bacterial infections, Candidiasis (Moniliasis), Histoplasmosis, Actinomycosis, Sporotrichosis, Chromoblastomycosis, Coccidioidomycosis, North American Blastomycosis, Cryptococcosis (Torulosis), Tinea versicolor, and Nocardiosis. **CONTRAINDICATIONS** This drug is contraindicated in patients with porphyria, hepatocellular failure, and in individuals with a history of hypersensitivity to griseofulvin. **WARNINGS** *Prophylactic Usage.* Safety and efficacy of griseofulvin for prophylaxis of fungal infections have not been established. *Animal Toxicology.* Chronic feeding of griseofulvin, at levels ranging from 0.5-2.5% of the diet, resulted in the development of liver tumors in several strains of mice, particularly in males. Smaller particle sizes result in an enhanced effect. Lower oral dosage levels have not been tested. Subcutaneous administration of relatively small doses of griseofulvin once a week during the first three weeks of life has also been reported to induce hepatomata in mice. Although studies in other animal species have not yielded evidence of tumorogenicity, these studies were not of adequate design to form a basis for conclusions in this regard. In subacute toxicity studies, orally administered griseofulvin produced hepatocellular necrosis in mice, but this has not been seen in other species. Disturbances in porphyrin metabolism have been reported in griseofulvin-treated laboratory animals. Griseofulvin has been reported to have a colchicine-like effect on mitosis and cocarcinogenicity with methylcholanthrene in cutaneous tumor induction in laboratory animals. *Usage in Pregnancy.* The safety of this drug during pregnancy has not been established. *Animal Reproduction Studies.* It has been reported in the literature that griseofulvin was found to be embryotoxic and teratogenic on oral administration to pregnant rats. Pups with abnormalities have been reported in the litters of a few bitches treated with griseofulvin. Additional animal reproduction studies are in progress. Suppression of spermatogenesis has been reported to occur in rats but investigation in man failed to confirm this. **PRECAUTIONS** Patients on prolonged therapy with any potent medication should be under close observation. Periodic monitoring of organ system function, including renal, hepatic, and hematopoietic, should be done. Since griseofulvin is derived from species of penicillin, the possibility of cross sensitivity with penicillin exists; however, known penicillin-sensitive patients have been treated without difficulty. Since a photosensitivity reaction is occasionally associated with griseofulvin therapy, patients should be warned to avoid exposure to intense natural or artificial sunlight. Should a photosensitivity reaction occur, lupus erythematosus may be aggravated. Griseofulvin decreases the activity of warfarin-type anticoagulants so that patients receiving these drugs concomitantly may require dosage adjustment of the anticoagulant during and after griseofulvin therapy. Barbiturates usually depress griseofulvin activity, and concomitant administration may require a dosage adjustment of the antifungal agent. **ADVERSE REACTIONS** When adverse reactions occur, they are most commonly of the hypersensitivity type, such as skin rashes, urticaria, and rarely, angioneurotic edema, and may necessitate withdrawal of therapy and appropriate countermeasures. Paresthesias of the hands and feet have been reported rarely after extended therapy. Other side effects reported occasionally are oral thrush, nausea, vomiting, epigastric distress, diarrhea, headache, fatigue, dizziness, insomnia, mental confusion, and impairment of performance of routine activities. Proteinuria and leukopenia have been reported rarely. Administration of the drug should be discontinued if granulocytopenia occurs. When rare, serious reactions occur with griseofulvin, they are usually associated with high dosages, long periods of therapy, or both.

10705231 JANUARY 1977

For more complete details, consult package insert or Schering literature available from your Schering Representative or Professional Services Department, Schering Corporation, Kenilworth, New Jersey 07033.



FACULTY POSITION DERMATOLOGY

Full-time position in Section of Dermatology, Department of Medicine, State University of New York, Upstate Medical Center, an equal opportunity employer. Academic rank commensurate with individual qualifications. Interested candidates should submit credentials including a statement of research interest to:

Dr. Fuad S. Farah, Chief, Section of Dermatology, Department of Medicine, Upstate Medical Center, 750 E. Adams Street, Syracuse, New York 13210.



the health effects of trace elements

For timely, authoritative information, read *The Physician's Guide to Inorganic Environmental Pollutants,* prepared by the AMA. Write: Order Dept., OP-427, AMA, 535 N. Dearborn, Chicago, IL 60610. 75¢ each.

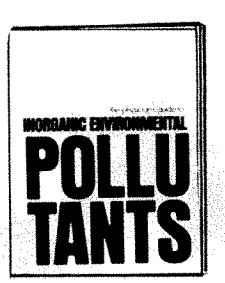

Sulfoxyl® Lotion Regular ℞
Sulfoxyl® Lotion Strong

Composition: Sulfoxyl Lotion Regular contains 5% benzoyl peroxide and 2% sulfur; Sulfoxyl Lotion Strong contains 10% benzoyl peroxide and 5% sulfur, each in a lotion base formulated with polyethylene glycol monostearate, stearic acid, glycerol monostearate, isopropyl palmitate, propylene glycol, zinc soap and purified water.

Indications: Use as a topical aid in the treatment of acne.

Dosage and Administration: After cleansing the skin, smooth Sulfoxyl Lotion gently into the affected areas, once daily for three days. If no discomfort is felt, frequency of application can then be increased to twice daily. The amount of drying and desquamation can be modified by adjusting the dosage schedule.

Contraindications: Patients with a known sensitivity to benzoyl peroxide, sulfur or any of the other formulation ingredients should not use these medications.

Precautions: For external use only. Avoid contact with eyes, mucous membranes and sensitive areas of the neck. Notify physician if excessive dryness or irritation occurs or increases.
Keep from heat.

Caution: Patients should be warned that these formulations may bleach colored linens, towels and apparel.

How Supplied: 1.0 ounce plastic bottles.

Caution: Federal law prohibits dispensing without prescription.

Benoxyl® 5 and 10 Lotion: Benoxyl 5 contains 5% benzoyl peroxide and Benoxyl 10, 10% benzoyl peroxide in a grease-free washable lotion base.

How Supplied: 1 oz. and 2 oz. plastic bottles.

PanOxyl® 5, PanOxyl® 10 ℞

Composition: PanOxyl 5 contains 5% Benzoyl Peroxide. PanOxyl 10 contains 10% Benzoyl Peroxide. PanOxyl 5 and PanOxyl 10 also contain 6% polyoxyethylene lauryl ether and 40% ethyl alcohol in a gel base formulated with colloidal magnesium aluminum silicate, hydroxypropylmethylcellulose, citric acid and purified water.

Action and Uses: The topical use of PanOxyl 5 and PanOxyl 10 provides therapeutic control of acne through drying and desquamative action, as well as providing antiseptic activity.

Indications: Use as an aid in the treatment of acne.

Dosage and Administration: Apply 1 or more times daily to affected areas. Washing the face with soap and water prior to application greatly enhances the efficacy of the medication.

Contraindications: Patients with a known sensitivity to Benzoyl Peroxide should not employ these medicatons.

Precautions: For external use only. Avoid contact with the eyes or mucosal membranes. Very fair individuals should always be started on a single application at bedtime, allowing the medication to remain on the skin overnight. PanOxyl may bleach colored fabrics.

How Supplied: 2 oz. and 4 oz. plastic tubes.

Caution: Federal law prohibits dispensing without prescription.

STIEFEL
Logical Dermatologicals since 1847

Stiefel Laboratories, Inc.,
Oak Hill, N.Y. 12460
Stiefel Laboratories (Canada) Ltd.,
St. Laurent, Quebec, Canada H4R 1E1

Th. tt. Dimtn_iun. of Acne Care

The widest range of benzoyl peroxide formulations gives you maximum therapeutic flexibility

lew Sulfoxyl® Lotion

he drying and desqua-iating effects of sulfur dded to benzoyl per-xide can be particu-rly valuable in acne omplicated by exces-ve oiliness. "...Sulfur ith benzoyl peroxide .produces a greater eratolytic effect than ither substance lone."[1] The exfoliative roperties of sulfur can elp benzoyl peroxide penetrate deeper nto sebaceous folli-les.

wo Strengths:
ulfoxyl® Lotion Regu-r (5% benzoyl perox-le and 2% sulfur) and ulfoxyl® Lotion Strong 0% benzoyl peroxide nd 5% sulfur) in a rease-free washable ase.

Benoxyl® Lotion

A good way to start benzoyl peroxide therapy. Benzoyl peroxide alone has been described as "a triple action drug: (1) it suppresses *C. acnes* in vivo; (2) it is comedolytic and (3) it is a counter-irritant."[3]

Two Strengths
Benoxyl® 5 Lotion (5% benzoyl peroxide) and Benoxyl® 10 Lotion (10% benzoyl peroxide) in a grease-free washable base.

PanOxyl® Gel

"The most potent forms of benzoyl peroxide are the new alcohol gels such as PanOxyl. Once the gel is applied to the skin, the solvent evaporates and deposits a concentrated form of depot free-radical oxygen which...is capable of penetrating into the sebaceous follicles and suppressing the *C. acnes*. This topical agent is much more effective in suppressing the fatty acids and the bacterial counts than systemic tetracycline and also produces a more rapid clinical improvement... No new lesions usually appear after 3 weeks and after 2 months the patient is usually free of the acne problem."[2]

Two Strengths:
PanOxyl® 5 Gel (5% benzoyl peroxide) and PanOxyl® 10 Gel (10% benzoyl peroxide) in an alcohol gel base.

STIEFEL

Stiefel Laboratories, Inc., Oak Hill, New York 12460
Stiefel Laboratories (Canada) Ltd.
St. Laurent, Quebec, Canada H4R 1E1
Logical Dermatologicals since 1847

e opposite page for prescribing information

Kirton, V. and Wilkinson, D.S.: *Practitioner*, **204**: 683, 1970 2. Fulton, J.E., Jr.: Acne Vulgaris. *Current Ther.* ed. Conn, H.F., 558-560, 1975
Fulton, J.E., Jr. et al. in *Acne Morphogenesis and Treatment*. Plewig, G. and Kligman, A.M., Springer-Verlag, 290-1, 1975

Tars have an important place in the management of seborrhea and psoriasis, but there is no clear cut agreement on when to use which.
A prudent approach:

Four tars in every golden drop

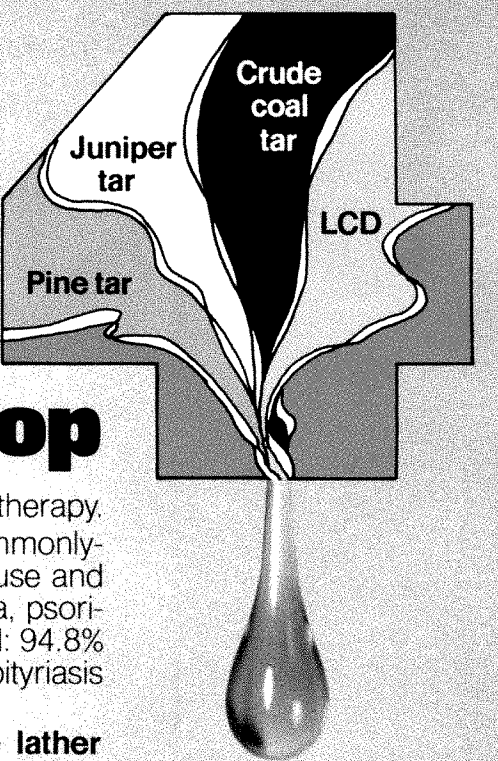

Now, a spectrum of tars maximizes the benefits of tar therapy. Polytar® Shampoo combines four of the most commonly-prescribed tars in one formula that is pleasant to use and therapeutically effective against dandruff, seborrhea, psoriasis and pityriasis capitis. Excellent results reported: 94.8% "very good" and 5.2% "good" in one study of both pityriasis capitis and psoriasis.*

And patients are pleased with the pure white lather that is as esthetically pleasing as a fine cosmetic and leaves hair lustrous and manageable.

*Bastos, A., O Medico, Vol. LXVI, 758-762, 1973

Polytar®
Shampoo

STIEFEL

Stiefel Laboratories, Inc., Oak Hill, New York 12460
Stiefel Laboratories (Canada) Ltd., St. Laurent, Quebec, Canada H4R 1E1
Logical Dermatologicals since 1847

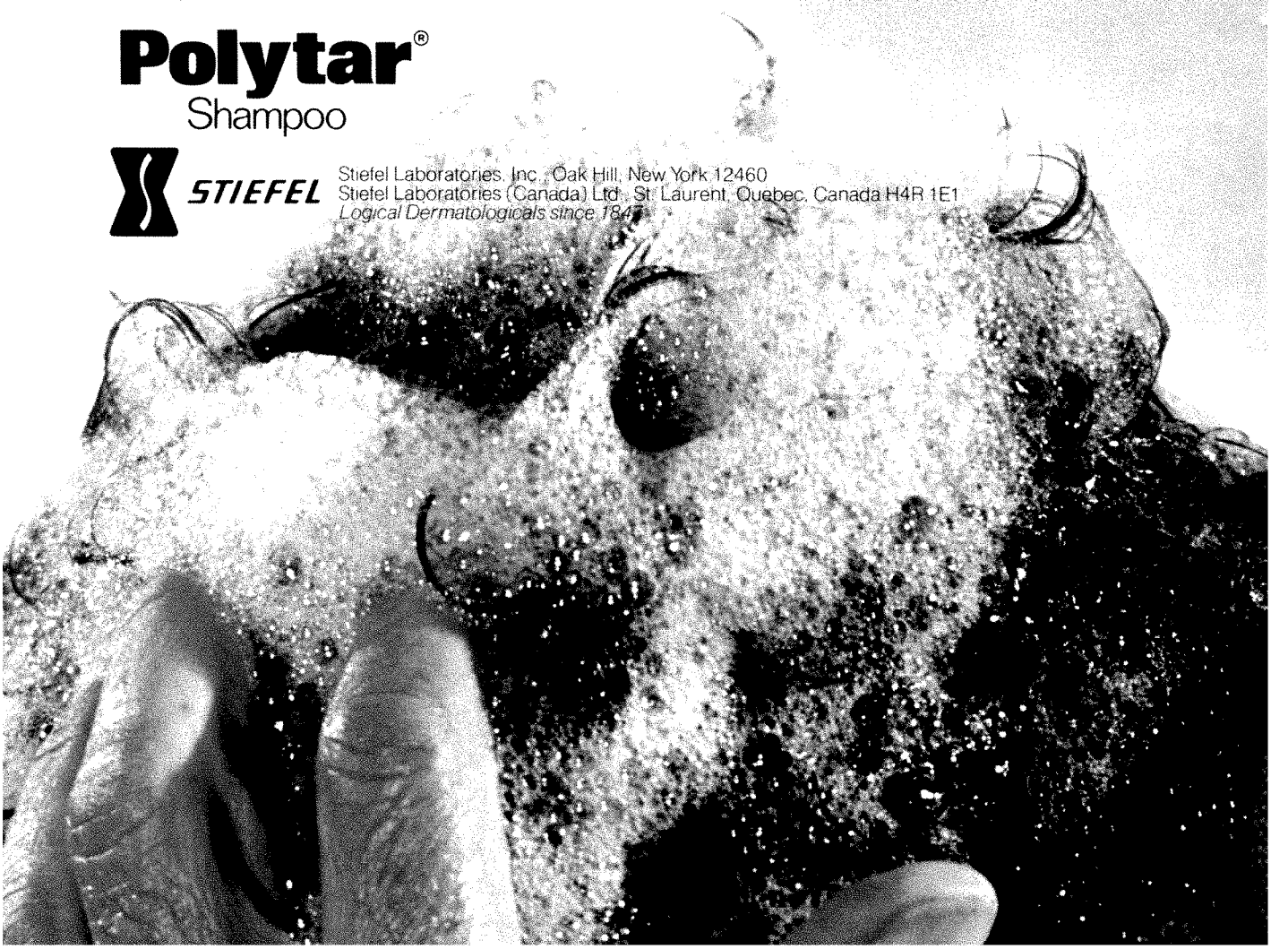

ECLIPSE®

(3% glyceryl PABA and 3% octyl dimethyl PABA)

For your patients

who can't-or won't-stay out of the sun.

For some, it's occupation. For others, the social desirability of a tan. Whatever the reason, many of your patients may be spending more time in the sun than you'd like.

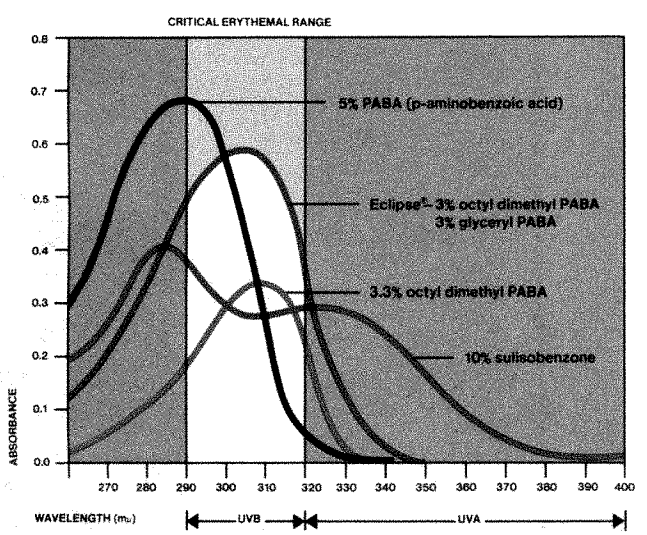

Unique Eclipse formulation combines two PABA derivatives for maximum UVB absorption.

They need Eclipse—a highly effective sunscreen that works immediately upon application, resists wash-off, and contains our exclusive Aquacare® base to help relieve sun and wind-dried skin.

Can other sunscreens do all that? Take a minute to read the labels: we're confident you'll recommend Eclipse.

- Absorbs more than 99% of erythemogenic solar UVB.
- Spreads smoothly and predictably for even protection.
- Permits slow tanning.
- Resists wash-off; protects after swimming or sweating.
- Formulated in Aquacare® to relieve sun and wind-dried skin.

Herbert Laboratories
Dermatology Division of
Allergan Pharmaceuticals
Irvine, CA 92713 U.S.A.

"Group Therapy"



Aristocort®

Triamcinolone Acetonide Topicals

a form and strength for every patient....every type of steroid-responsive dermatosis

A standard for effectiveness in fluorinated topicals.

The first triamcinolone preparation to remove common sensitizers—contains no parabens, phenol preservatives, lanolin.

One of the most economical topical steroids available.

In cosmetically-pleasing forms that have become traditional patient favorites.



0.5% Cream	0.5% Ointment	0.1% Cream	0.1% Ointment	0.025% Cream	0.1% Gel

Indications: For relief of inflammatory manifestations of corticosteroid-responsive dermatoses.
Contraindications: Viral skin diseases, such as varicella and vaccinia; hypersensitivity to any component (not for ophthalmic use); when circulation is markedly impaired.
Warnings: Safety of use in pregnancy has not been absolutely established. Do not use extensively, in large amounts, or for prolonged periods of time in pregnant patients.
Precautions: If irritation develops, discontinue use and institute appropriate therapy. In infections, use appropriate antifungal or antibacterial agents; if a favorable response does not occur promptly, discontinue the corticosteroid until the infection is adequately controlled. If extensive areas are treated or the occlusive technique is used, increased systemic absorption of the corticosteroid may occur; take suitable precautions.
Adverse Reactions: (local) Burning sensations, itching, irritation, dryness, folliculitis, secondary infection, skin atrophy, striae, hypertrichosis, acneform eruption and hypopigmentation.
Supplied: *Cream 0.5%*—Per Gm.: triamcinolone acetonide 5 mg., sorbic acid 0.1% and potassium sorbate 0.1% as preservatives; *Cream 0.1%*—Per Gm.: triamcinolone acetonide 1 mg., sorbic acid 0.1% and potassium sorbate 0.1% as preservatives; *Cream 0.025%*—Per Gm.: triamcinolone acetonide 0.25 mg., sorbic acid 0.1% and potassium sorbate 0.1% as preservatives; all potencies are in a water base of mono and diglycerides, squalane, polysorbate 80 USP, polysorbate 60, cetyl esters wax NF, stearyl alcohol USP, Tenox II, and sorbitol solution USP. *Ointment 0.5%*—Per Gm.: triamcinolone acetonide 5 mg.; inactive ingredient: white petrolatum; *Ointment 0.1%*—Per Gm.: triamcinolone acetonide 1 mg.; inactive ingredient: white petrolatum. *ARISTOGEL® Gel 0.1%*—Per Gm.: triamcinolone acetonide 1 mg., 1.8% benzyl alcohol as preservative; inactive ingredients in a water base: polysorbate 80 USP, polyoxyethylene (20) cetyl ether, glycerin USP, and citric acid USP.

777-6

Lederle

Lederle Laboratories
A Division of American Cyanamid Company
Pearl River, New York 10965

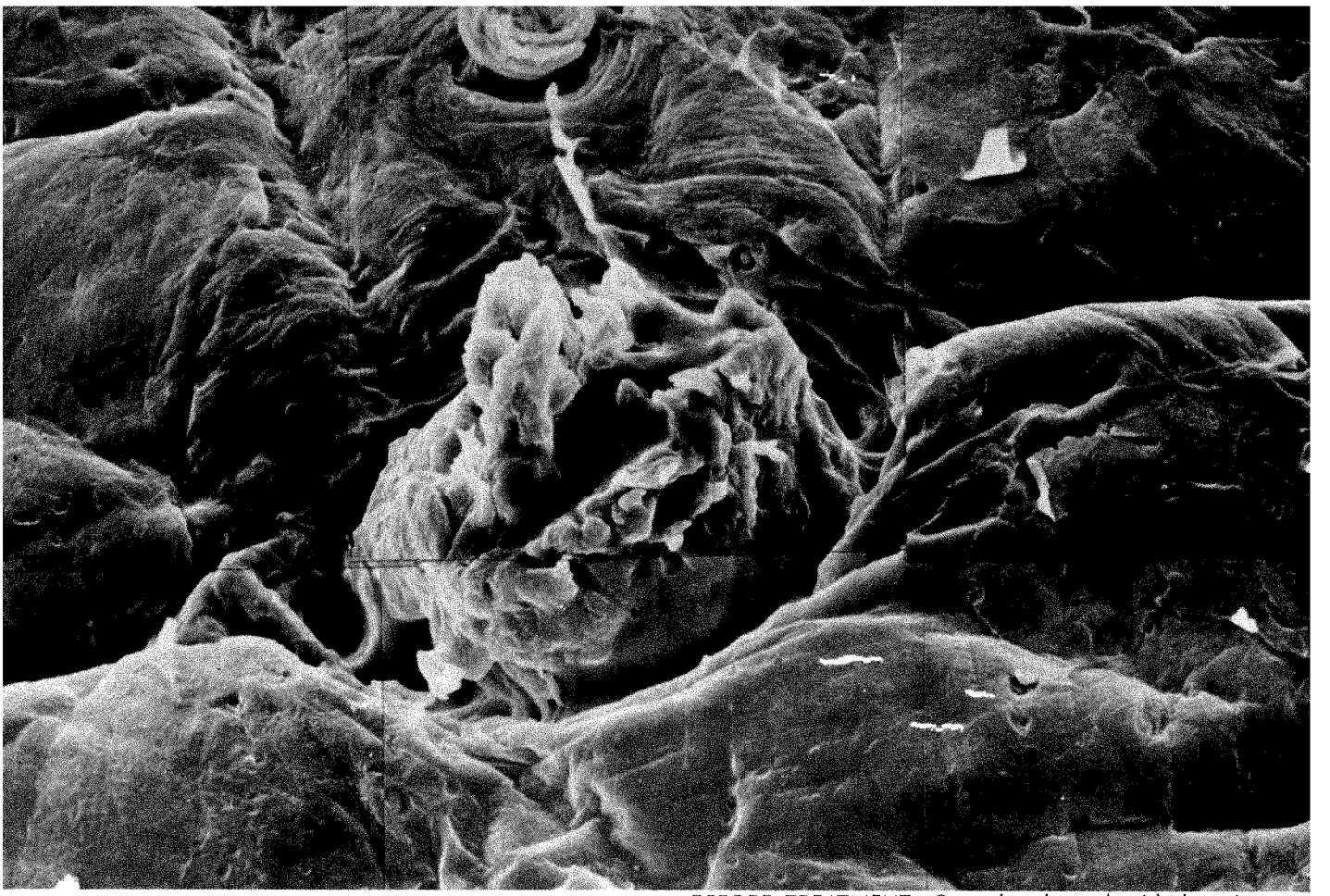

BEFORE TREATMENT: Comedo plugged with keratinous debris. Directly above is a smaller comedo, and in the lower left hand corner a vellus hair is apparent. Note absence of sharp lines of demarcation between layers of cells.*

Pernox® Begins to Improve an Acne Lesion in 2 Days

Rapid resolution of an acne lesion is graphically demonstrated with Scanning Electron Microscopy.

We formulated Pernox® Abradant Scrub to make it effective yet gentle enough for acne skin.

Patients respond to Pernox rapidly, often noticing improvement after the first wash. Pernox Scrub/Lotion is a unique combination of therapeutic agents to emulsify oil and desquamate affected areas. Both forms of Pernox offer significant patient benefits.

Pernox® Lotion offers less desquamation and additional flexibility for your therapeutic acne regimen.

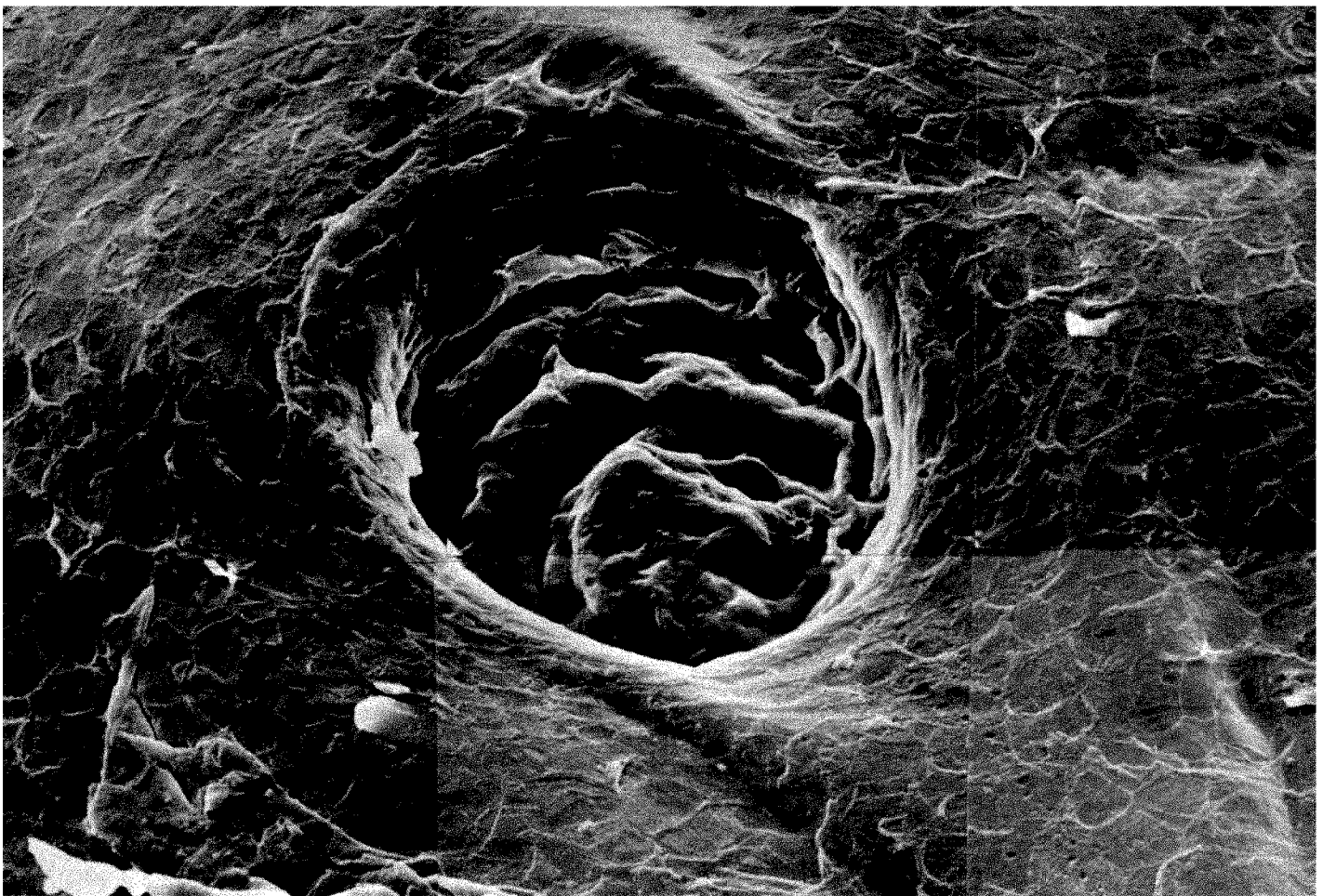

AFTER 2 DAYS: Depth of orifice indicates removal of plug in both large central and smaller top comedo. Surface desquamation and excellent hexagonal demarcations of individual epithelial cells are apparent.*

Pernox . . . an acne regimen formulated to give you an alternative to your present acne therapy or to be used adjunctively with other topical modalities for acne. Washing varies from patient to patient. You determine the regimen by frequency of washing and the amount of water used during the wash.

INDICATIONS: Acne vulgaris, oily skin, comedones.
CONTAINS: Gentle abradant microfine granules of polyethylene, 2% sulfur, 1.5% salicylic acid in SEBULYTIC® brand of unique penetrating surface-active combination of soapless cleansers and wetting agents.
CONTRAINDICATIONS: Not indicated when acute inflammation is present or in nodular or cystic acne.
ADMINISTRATION AND DOSAGE: After wetting the skin, PERNOX is applied with the fingertips and massaged into the skin for about one-half to one minute. The skin is then thoroughly rinsed. Used one to two times daily, or as directed.
CAUTION: If undue skin irritation develops or increases, adjust usage schedule or discontinue use. If necessary, anti-inflammatory measures may be used after discontinuance. For external use only. Contact with eyes should be avoided. In case of contact, flush eyes thoroughly with water.

*These photographs were part of a study in which participants cleansed twice

The Abradant Of Choice

PERNOX®

Scrub/Lotion

Lathering Abradant Cleanser for Acne

Scrub: 2 oz. and 4 oz. tubes, regular or lemon-scented

Lotion: 6 oz., lemon-scented

WESTWOOD PHARMACEUTICALS INC
Buffalo, New York 14213

How are you keeping up with happenings in your specialty?

Keep up-to-date with an AMA Specialty Journal. Month after month, it will bring you articles on original research, news of medical significance, and comments on current events in the specialty field of your interest.

Start an AMA Specialty Journal coming today.

- ☐ American Journal of Diseases of Children
- ☐ Archives of Dermatology
- ☐ Archives of General Psychiatry
- ☐ Archives of Internal Medicine
- ☐ Archives of Neurology
- ☐ Archives of Ophthalmology
- ☐ Archives of Otolaryngology
- ☐ Archives of Pathology and Laboratory Medicine
- ☐ Archives of Surgery

	U.S. & Poss.	All Other Countries
☐ 24 issues.....	$28.00	$38.00
☐ 12 issues.....	$18.00	$28.00

Payment must accompany all orders. Make checks payable to the American Medical Association.

Name _____

Address _____

City _____ State _____ Zip _____

Return to: Subscription Department, AMA
535 North Dearborn St., Chicago, Ill. 60610

S/J

HALOG® CREAM (Halcinonide Cream 0.1%)

Each gram of Halog Cream (Halcinonide Cream 0.1%) contains 1 mg. halcinonide (0.1%) in a cream base.

INDICATIONS: This product is intended for topical application for adjunctive therapy and symptomatic relief of inflammatory manifestations of acute and chronic corticosteroid responsive dermatoses.

CONTRAINDICATIONS: Topical steroids are contraindicated in vaccinia, varicella, and in those patients with a history of hypersensitivity to any of the components of the preparation. This preparation is not for ophthalmic use.

PRECAUTIONS: *General*—If local infection exists, suitable concomitant antimicrobial or antifungal therapy should be administered. If a favorable response does not occur promptly, application of the corticosteroid should be discontinued until the infection is adequately controlled. Although systemic side effects associated with absorption of topical corticosteroid preparations are rare, their possible occurrence must be kept in mind when these preparations are used over large areas or for an extended period of time. If irritation or sensitization develops, the preparation should be discontinued and appropriate therapy instituted. Although topical steroids have not been reported to have an adverse effect on pregnancy, the safety of their use during pregnancy has not been absolutely established; therefore, they should not be used extensively on pregnant patients, in large amounts, or for prolonged periods of time.

Occlusive Dressing Technique—The use of occlusive dressing increases the percutaneous absorption of corticosteroids; their extensive use increases the possibility of systemic effects. For patients with extensive lesions it may be preferable to use a sequential approach, occluding one portion of the body at a time. The patient should be kept under close observation if treated with the occlusive technique over large areas and over a considerable period of time. Occasionally, a patient who has been on prolonged therapy, especially occlusive therapy, may develop symptoms of steroid withdrawal when the medication is stopped. Thermal homeostasis may be impaired if large areas of the body are covered. Use of the occlusive dressing should be discontinued if elevation of the body temperature occurs. Occasionally, a patient may develop a sensitivity reaction to a particular occlusive dressing material or adhesive and a substitute material may be necessary. If infection develops, discontinue the use of the occlusive dressing and institute appropriate antimicrobial therapy.

ADVERSE REACTIONS: The following local adverse reactions have been reported with topical corticosteroids: burning, itching, irritation, striae, skin atrophy, secondary infection, dryness, folliculitis, hypertrichosis, acneform eruptions, and hypopigmentation. The following may occur more frequently with occlusive dressings: maceration of the skin, secondary infection, skin atrophy, striae, and miliaria. Contact sensitivity to a particular dressing material or adhesive may occur occasionally (see PRECAUTIONS).

For full prescribing information, consult package insert.

HOW SUPPLIED: In tubes of 15 and 60 g. and in jars of 240 g. (8 oz.).

SQUIBB® The Priceless Ingredient of every product is the honor and integrity of its maker.™

© 1977 E.R. Squibb & Sons, Inc. 357-503

Pruritus relieved "within 24 hours"

Eczematoid Dermatitis

Condition of six months' duration. Patient complaining of acute itching and soreness of finger. Examination revealed erythematous, eroded, fissured, scaling and crusted dermatitis. KOH test negative for fungal hyphae; no other skin involvement or history of skin problems.

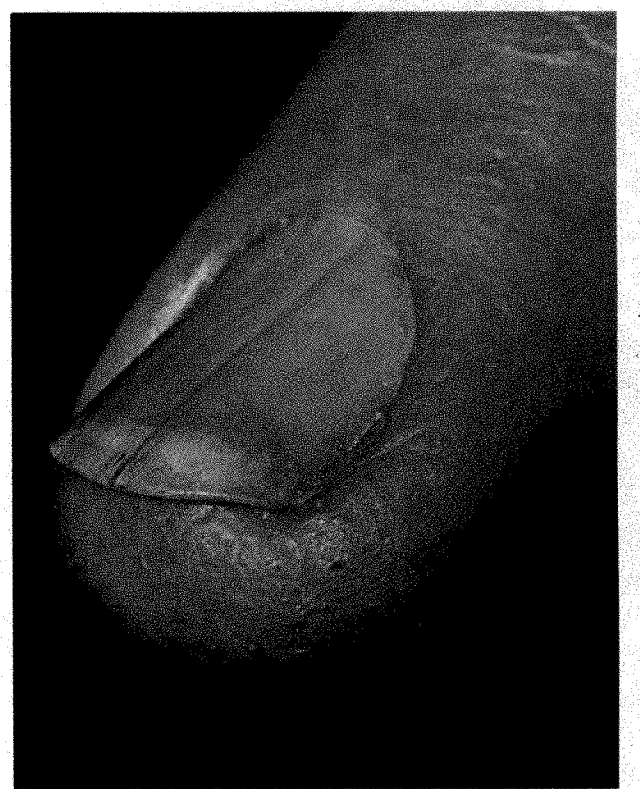

After 1 week

Halog 0.1% Cream applied twice daily. Patient reported pruritus relieved within 24 hours after first application of cream. Examination showed essentially complete resolution of dermatitis. Halog Cream discontinued and patient discharged.

Case history on file at Squibb Institute for Medical Research.

after Halog® Cream b.i.d

Halcinonide Cream 0.1%

See adjacent **SQUIBB®** column for brief summary.

For dry skin care on a day-to-day basis, consider the soothing, softening, nondetergent cleansing properties of Alpha Keri Soap.

- Excellent cleansing properties eliminate harshness and irritation
- Contains Alpha Keri® therapeutic bath oil to soothe and soften skin
- Rich lather and delicate scent create outstanding patient acceptance

Alpha Keri® soap

The soothing, smoothing detergent-free cleanser

WESTWOOD
PHARMACEUTICALS INC.
Buffalo, New York 14213

Mixed Connective Tissue Disease Syndrome

Cutaneous Manifestations of Patients With Epidermal Nuclear Staining and High Titer Serum Antibody to Ribonuclease-Sensitive Extractable Nuclear Antigen

James N. Gilliam, MD, Stephen D. Prystowsky, MD

• Fifteen patients with epidermal nuclear staining on direct immunofluorescence of normal skin and high titer serum antibody to ribonuclease-sensitive extractable nuclear antigen (ENA) had diffuse nonscarring and focal alopecia, abnormal pigmentation, swollen hands with sclerodactyly, and chronic cutaneous lupus erythematosus (LE) as the most common dermatologic features. Direct immunofluorescence of normal, unexposed skin revealed a particulate ("speckled") epidermal nuclear staining pattern in all 15 patients and subepidermal immunoglobulin deposits in 5. Ribonucleoprotein antibodies in high titer are associated with this characteristic type of epidermal nuclear staining. These findings provide easily detectable markers for a less aggressive subset of LE characterized by distinctive clinical and laboratory features consistent with mixed connective tissue disease.

(*Arch Dermatol* 113:583-587, 1977)

Sharp and co-workers[1] have recently described a group of patients designated as having mixed connective tissue disease (MCTD) with benign features often compatible with systemic lupus erythematosus (SLE) but suggestive of scleroderma or polymyositis or both. Most of these patients had considerable hypergammaglobulinemia and they all had high titer antibody to a saline-soluble (extractable) nuclear antigen, referred to as ENA.

Since many patients with typical features of SLE have similar ENA antibody titers, attempts were made to differentiate the antibody of MCTD from SLE by enzymatic treatment of the ENA with ribonuclease (RNase).[2] In SLE, the ENA antibody reaction was unaffected by RNase treatment of the antigen. However, such treatment greatly reduced or abolished the reaction in MCTD. This finding suggested that patients with MCTD had antibody to an RNase-sensitive antigenic component of the ENA whereas in patients with typical SLE the antibody was to an RNase-resistant ENA. These and other studies[3-5] have shown that at least two distinct antigens are present in the ENA. One is a ribonucleoprotein (RNP) that is sensitive to RNase and trypsin; the other is resistant to RNase and appears to be identical to the previously described glycoprotein Sm antigen.[3] In patients with MCTD, the antibody is directed to the RNase-sensitive RNP antigen. The clinical course of patients with this syndrome is usually benign and many of the clinical manifestations disappear with steroid therapy.

In direct immunofluorescence studies of apparently normal skin from patients with rheumatic diseases, particulate ("speckled") epidermal nuclear staining has been reported.[6-8] This epidermal nuclear staining was found to correlate with high titer antibodies to both the RNase-sensitive (RNP) and RNase-resistant (Sm) ENA.[9-11] This finding brought to our attention a group of patients with anti-RNP antibodies. The purpose of this article is to describe the cutaneous manifestations in these patients with epidermal nuclear staining and high titer antibody to RNP.

MATERIALS AND METHODS

Subjects

Twenty patients with epidermal nuclear staining on direct immunofluorescence of

Table 1.—Cutaneous Manifestations in Patients With Serum Antibody to RNase-Sensitive ENA* (RNP)†

Manifestation	No. of Patients	No. Positive	% Positive
Alopecia	15	10	67
Dyspigmentation	15	10	67
Swollen hands and sclerodactyly	15	7	47
Chronic cutaneous LE‡	15	5	33
Subacute LE	15	2	13
Acute LE (malar eruption or "butterfly rash")	15	1	7
Scleroderma	15	1	7

*ENA indicates extractable nuclear antigen.
†RNP indicates ribonucleoprotein.
‡LE indicates lupus erythematosus.

Accepted for publication June 30, 1976.
From the Division of Dermatology, Department of Internal Medicine, The University of Texas Southwestern Medical School, Dallas. Dr Prystowsky is now at the Letterman Army Institute of Research, San Francisco.
Reprint requests to 5323 Harry Hines Blvd, Dallas, 75235 (Dr Gilliam).

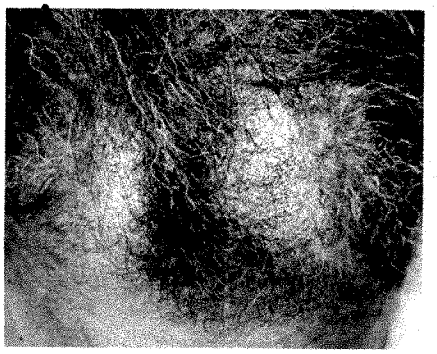

Fig 1.—Diffuse, nonscarring alopecia.

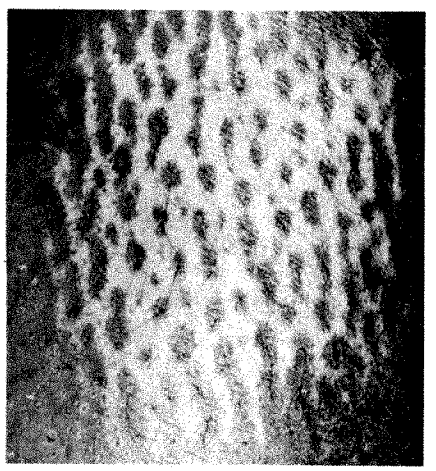

Fig 3.—Hypopigmentation of morphea-like plaque on thigh with follicular retention of pigment.

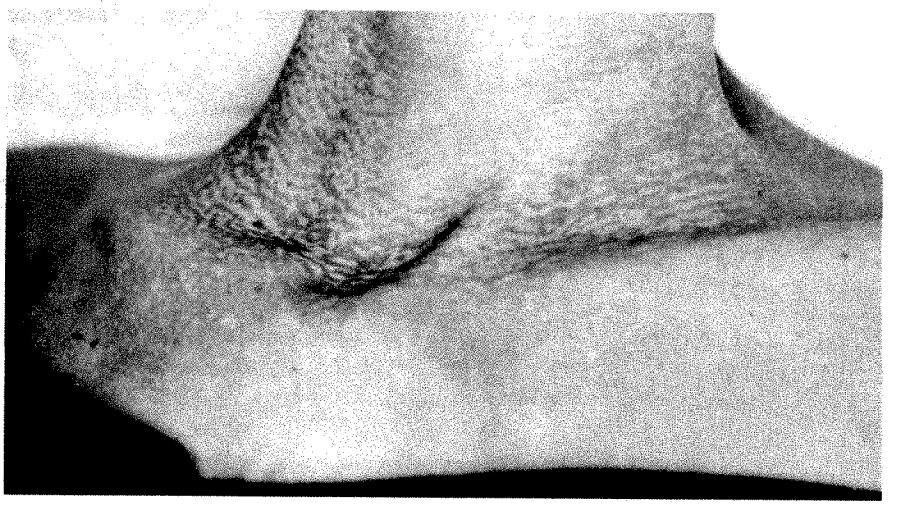

Fig 2.—Spotty hypopigmentation and hyperpigmentation as commonly seen in scleroderma.

Fig 4.—Hyperpigmented swollen hands with sausage-shaped fingers.

uninvolved, nonexposed skin were studied. Fifteen of the 20 patients had high titer antibody to an RNase-sensitive ENA (RNP); data are reported only for these 15 patients. This group consisted of 14 women and 1 man; their ages ranged from 14 to 61 years, with a mean age of 36 years. Thirteen were black and 2 were white. All of the patients were personally examined by one of us (JNG) on one or more occasions.

Immunologic Studies

Antinuclear antibodies were determined by the method of Holborow et al[12] using fresh rat kidney sections and human squamous carcinoma cells (BK) as the substrate. Total hemolytic complement (CH50) was measured by the microtitration technique of Nelson et al,[13] and antibodies to double-stranded DNA (anti-nDNA) were measured by the method of Ginsberg and Keiser.[14]

The extractable nuclear antigen was determined by the hemagglutination method of Sharp et al.[2] This test was performed with ENA-coated sheep erythrocytes before and after RNase treatment. A fall in titer of more than two dilutions after treatment was interpreted as RNase sensitivity and was an indication of antibody to RNP. Immunoglobulin deposits at the dermal-epidermal junction were detected by direct immunofluorescence on biopsy specimens of normal, unexposed skin as previously described.[15]

RESULTS

Table 1 gives the cutaneous manifestations in the 15 patients with the MCTD syndrome. Alopecia was observed in 10 (67%) patients and was usually nonscarring and diffuse (Fig 1). Focal hair loss and alopecia areata were also observed. The alopecia was unusually persistent and failed to correlate closely with disease activity in contrast to the diffuse alopecia of acute SLE. Pigmentary disturbances were found in 10 (67%) patients. Three had hypopigmentation with follicular retention of pigment as in scleroderma or repigmenting vitiligo (Fig 2 and 3). Areas of hyperpigmentation (both diffuse and focal) were observed in seven additional patients. Sclerodactyly with swelling of the fingers that results in a tapered or sausage appearance was present in seven (49%) patients (Fig 4 and 5). Eight patients (53%) had cutaneous forms of

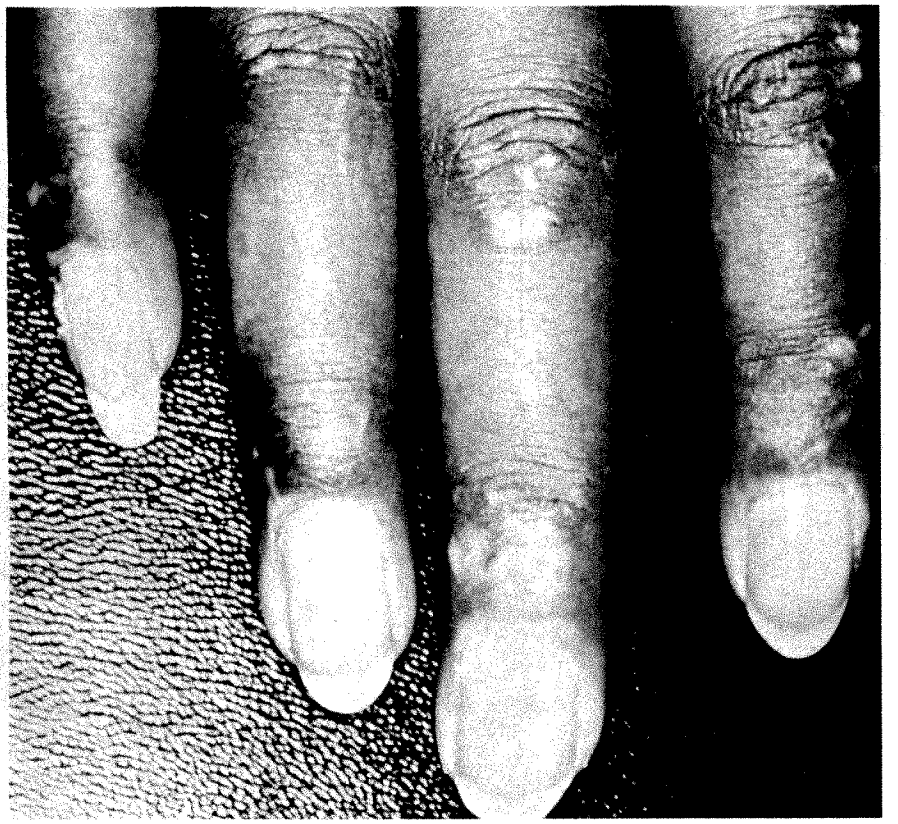

Fig 5.—Sclerodactyly with hypopigmented, atrophic papules over knuckles (Gottron papules).

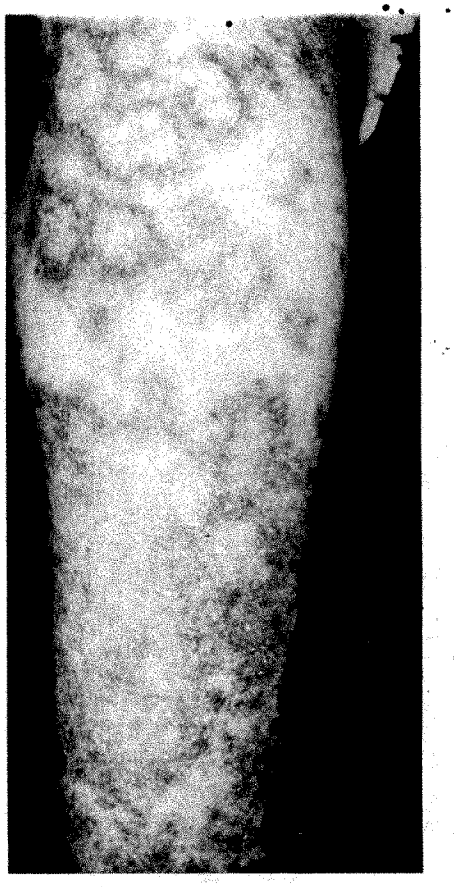

Fig 6.—Diffuse erythematous, nonscarring subacute cutaneous lupus erythematosus.

Table 2.—Clinical Features of Patients With Serum Antibody to RNase-Sensitive ENA* (RNP)†

Clinical Feature	No. of Patients	No. Positive	% Positive
Arthritis/arthralgia	15	14	93
Raynaud phenomenon	15	13	87
Lymphadenopathy	15	6	40
Serositis	15	6	40
Myositis	15	3	20
Pulmonary fibrosis	15	1	7
CNS disease	15	1	7
Renal insufficiency	15	0	0

*ENA indicates extractable nuclear antigen.
†RNP indicates ribonucleoprotein.

LE. Five (33%) had persistent, chronic scarring discoid-type lesions. Two patients had the diffuse, nonscarring, erythematous, papulosquamous variety of subacute cutaneous LE (Fig 6). One patient had an acute malar (butterfly) eruption. One patient had cutaneous sclerosis that almost completely resolved with prednisone therapy.

Table 2 gives the clinical features of the 15 patients with high titer antibody to RNP. Arthritis or arthralgia (93%) and the Raynaud phenomenon (87%) were present in most patients. Lymphadenopathy (40%) and serositis (40%) were also common features. Myositis with increased muscle enzyme values was noted in only three (20%) patients. Clinically notable interstitial lung disease with reduced diffusion capacity was observed in one case (7%). Pulmonary function studies were not done on the other 14 patients. One patient had episodes of psychosis and seizures. Renal insufficiency, defined as azotemia or a creatinine clearance below 85 ml/min, was not observed.

Table 3 and Figure 7 show the laboratory findings for these patients. All had high titer antinuclear antibodies with a particulate (speckled) staining pattern. Extractable nuclear antigen antibody titers ranged from 1:32,000 to > 1:500,000 in serums from all 20 patients with epidermal nuclear staining (Fig 7). In 32 patients with SLE with positive antinuclear antibody test results and negative ENA antibody or titers below 1:16,000, skin biopsy specimens failed to show epidermal nuclear staining (Fig 8). Hypergammaglobulinemia was present in 12 (80%) patients. Subepidermal immunoglobulin in normal, nonexposed skin was observed in five (33%) patients. Depressed CH50 occurred in three (20%) patients. Lupus erythematosus cells were seen in only two of the ten patients tested. Rheumatoid factor was present in two (13%) patients. None of these patients had sub-

stantially elevated levels of antibody to native DNA.

COMMENT

Ribonucleoprotein antibodies in high titer and epidermal nuclear staining seem to provide readily detectable indicators for a less aggressive connective tissue disease.[5] These patients often have the clinical features of MCTD as described by Sharp and co-workers.[1,2] Such "overlap" syndromes have been described previously,[16,17] but Sharp et al[2] were the first to associate the RNP antibody with certain distinctive clinical and laboratory features. The most striking clinical manifestation associated with high titer RNP antibody seems to be the Raynaud phenomenon. Our data confirm the apparent low incidence of renal involvement associated with RNP antibodies.[2,18-20]

In addition to epidermal nuclear staining, RNP antibody is associated with a mixture of cutaneous features. A diffuse, nonscarring alopecia was observed in 67%. In contrast, Tuffanelli and Dubois[21] found a similar type of hair loss in only 21% of 520 unselected patients with classic SLE. Hyperpigmentation or hypopigmentation or both was present in 67% of our patients with RNP antibody. In comparison, Tuffanelli and Dubois[21] observed hyperpigmentation in only 8% of their patients with SLE. However, Tuffanelli and Winkelmann[22] noted pigmentary abnormalities in 32% of 727 cases with systemic scleroderma. Sclerodactyly with swelling of the hands and a tapered or sausage appearance of the fingers was present in 47% of the patients in

Table 3.—Laboratory Findings in 15 Patients With Serum Antibody to RNase-Sensitive ENA* (RNP)†

Findings	No. Tested	No. Positive	% Positive
Positive ANA‡ (particulate)	15	15	100
Particulate epidermal nuclear staining	15	15	100
Hypergammaglobulinemia	15	12	80
Subepidermal Ig (normal skin of volar forearm)	15	5	33
Hypocomplementemia§ (CH50)	15	3	20
LE‖ cells	10	2	20
Rheumatoid factor	15	2	13
Elevated anti-nDNA #	15	0	0

*ENA indicates extractable nuclear antigen.
†RNP indicates ribonucleoprotein.
‡All were positive at serum titers of 1:1280 or greater on a human squamous carcinoma cell line (BK) substrate. ANA indicates antinuclear antibody.
§Less than 60 hemolytic units.
‖LE indicates lupus erythematosus.
#Greater than 2.5 μg DNA bound per milliliter of serum.

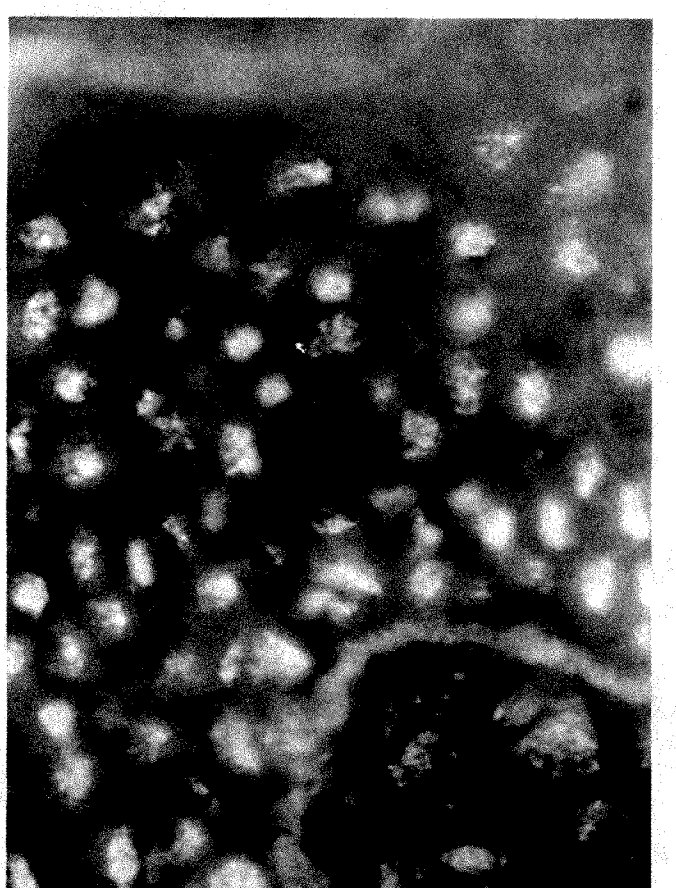

Fig 7.—Direct immunofluorescence staining of apparently normal skin with particulate epidermal and dermal nuclear staining. Staining is also present along dermal-epidermal junction (original magnification ×700).

Fig 8.—Anti-extractable nuclear antigen titers in patients with connective tissue disease (CTD) with epidermal nuclear staining (open circle) compared with patients with systemic lupus erythematosus (SLE) without epidermal nuclear staining (ENS) (solid circle).

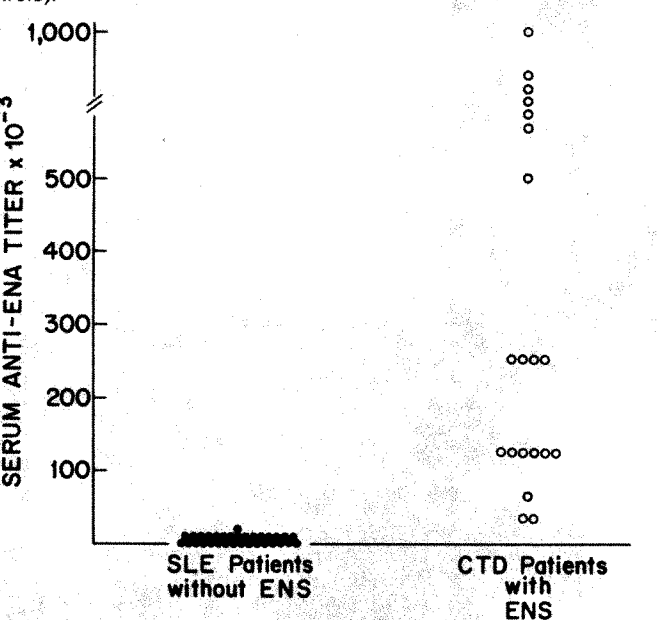

this study, a finding well described in MCTD by Sharp and co-workers.[2] An unexpected and previously unrecognized finding was that one third of these patients had chronic destructive or discoid-type skin involvement. Discoid-type lesions are present in only 10% to 15% of unselected patients with SLE.[23,24] We have recently shown that these patients with SLE with discoid-type LE skin lesions also have a low incidence of DNA antibodies and insignificant renal disease.[25] It is of interest that Dubois et al[17] noted that 43% of the patients with a scleroderma-SLE overlap syndrome had discoid skin lesions.

Antibody to RNP seems to be another in a growing list of immunologic markers associated with certain distinct clinical manifestations. Antibodies to native DNA are associated with lupus nephritis[26]; antibodies to the Sm antigen are found almost exclusively in SLE.[27] Marker antibodies may be associated with certain forms of scleroderma[28,29]; some of these are directed to uracil and are thus specific for single-stranded RNA.[28] Specific immunofluorescence staining patterns may correlate with many of these autoantibodies and thus aid in diagnosis and management.[30]

It seems likely that future investigation may reveal antigen-antibody systems that are related to other distinct connective tissue disease syndromes. Since the MCTD syndrome has many features of typical SLE, the early differentiation of this group with a less aggressive clinical course, absence of renal disease, and good response to steroids is important for prognostic purposes. Epidermal nuclear staining and RNP antibodies seem to provide easily detectable immunologic markers for such cases.

References

1. Sharp GC, Irvin WS, Laroque RL, et al: Association of autoantibodies to different nuclear antigens with clinical patterns of rheumatic disease and responsiveness to therapy. *J Clin Invest* 50:350-359, 1971.
2. Sharp GC, Irvin WS, Tan EM, et al: Mixed connective tissue disease: An apparently distinct rheumatic disease syndrome associated with a specific antibody to an extractable nuclear antigen (ENA). *Am J Med* 52:148-159, 1972.
3. Tan EM, Kunkel HG: Characteristics of a soluble nuclear antigen precipitating with sera of patients with systemic lupus erythematosus. *J Immunol* 96:464-471, 1966.
4. Northway JD, Tan EM: Differentiations of antinuclear antibodies giving speckled staining patterns in immunofluorescence. *Clin Immunol Immunopathol* 1:140-154, 1972.
5. Reichlin M, Mattioli M: Correlation of a precipitin reaction to an RNA-protein antigen and a low prevalence of nephritis in patients with systemic lupus erythematosus. *N Engl J Med* 286:908-911, 1972.
6. Tuffanelli DL: The immunopathology of lupus erythematosus: A comparison of immunohistochemical techniques. Part I—Immunofluorescence, in Montagna W and Billingham RE (eds): *Immunology and the Skin*. New York, Appleton-Century-Croft, 1969, pp 287-293.
7. Windhorst DB, Steblay RW, Rudofsky UH, et al: New findings regarding autoimmune factors in skin disease. *Med Clin North Am* 54:95-104, 1970.
8. Gilliam JN: The significance of cutaneous immunoglobulin deposits in lupus erythematosus and NZB/NZW F1 hybrid mice. *J Inv Dermatol* 65:154-161, 1975.
9. Gilliam JN, Smiley JD, Ziff M: Correlation between serum antibody to extractable nuclear antigen and immunoglobulin localization in epidermal nuclei, abstracted. *Clin Res* 22:611A, 1974.
10. Gilliam JN, Smiley JD, Ziff M: Association of mixed connective tissue disease (MCTD) with immunoglobulin localization in epidermal nuclei of biopsies from areas of normal skin, abstracted. *Clin Res* 23:229A, 1975.
11. Shu S, Beutner E: Studies on apparent reactivity of ANA with viable cells, abstracted. *Fed Proc* 35:512, 1976.
12. Holborow EJ, Weir DM, Johnson CD: A serum factor in lupus erythematosus with affinity for tissue nuclei. *Br Med J* 2:732-734, 1957.
13. Nelson RA, Jenson J, Gigli I, et al: Methods for the separation, purification, and measurement of nine components of hemolytic complement in guinea pig serum. *Immunochemistry* 3:111-135, 1966.
14. Ginsberg B, Keiser H: A millipore filter assay for antibodies to native DNA in sera of patients with systemic lupus erythematosus. *Arthritis Rheum* 16:199-207, 1973.
15. Gilliam JN, Cheatum DE, Hurd ER, et al: Immunoglobulin in clinically uninvolved skin in systemic lupus erythematosus. *J Clin Invest* 53:1434-1438, 1974.
16. Tuffanelli DL, Winkelmann RK: Scleroderma and its relationship to the "collagenoses": Dermatomysitis, lupus erythematosus, rheumatoid arthritis and Sjögren's syndrome. *Am J Med Sci* 243:133-146, 1962.
17. Dubois EL, Chandor S, Friou GJ, et al: Progressive systemic sclerosis (PSS) and localized scleroderma (morphea) with positive LE cell test and unusual systemic manifestations compatible with systemic lupus erythematosus (SLE). *Medicine* 50:199-222, 1971.
18. Sharp G, Irvin W, May C, et al: Association of antibodies to ribonucleoprotein and Sm antigens with mixed connective tissue disease (MCTD), systemic lupus erythematosus (SLE), and other rheumatic diseases, abstracted. *Clin Res* 23:50A, 1975.
19. Hench PK, Edgington T, Tan EM: The evolving clinical spectrum of mixed connective tissue disease (MCTD), abstracted. *Arthritis Rheum* 18:404, 1975.
20. Farber S, Bole GG: Clinical features of patients with antibody (Ab) to extractable nuclear antigen (ENA), abstracted. *Arthritis Rheum* 18:397, 1975.
21. Tuffanelli DL, Dubois EL: Cutaneous manifestations of systemic lupus erythematosus. *Arch Dermatol* 90:377-386, 1964.
22. Tuffanelli DL, Winkelmann RK: Systemic scleroderma: A clinical study of 727 cases. *Arch Dermatol* 84:359-371, 1961.
23. Estes D, Christian CL: The natural history of systemic lupus erythematosus by prospective analysis. *Medicine* 50:85-95, 1971.
24. Rothfield NF, March CH: Lupus erythematosus, in Fitzpatrick TB, Arndt KA, Clark WH, et al (eds): *Dermatology in General Medicine*, ed 1. New York, McGraw-Hill Book Co, 1971, p 1514.
25. Prystowsky SD, Gilliam JN: Discoid lupus erythematosus as part of a larger disease spectrum: Correlation of clinical features with laboratory findings in lupus erythematosus. *Arch Dermatol* 111:1448-1452, 1975.
26. Schur PH, Sandson J: Immunologic factors and clinical activity in systemic lupus erythematosus. *N Engl J Med* 278:533-538, 1968.
27. Notman DD, Kurata N, Tan EM: Profiles of antinuclear antibodies in systemic rheumatic diseases. *Ann Intern Med* 83:464-469, 1975.
28. Alarcon-Segovia D, Fishbein E: Immunochemical characterization of the anti-RNA antibodies found in scleroderma and systemic lupus erythematosus: I. Differences in reactivity with poly (J) and poly (A)-poly (U). *J Immunol* 115:28-31, 1975.
29. Tan EM, Rodnan GP: Profile of antinuclear antibodies in progressive systemic sclerosis (PSS), abstracted. *Arthritis Rheum* 18:430, 1975.
30. Burnham TK, Bank PW: Antinuclear antibodies: I. Patterns of nuclear immunofluorescence. *J Invest Dermatol* 63:526-534, 1974.

Effect of Sodium Salicylate and Indomethacin on Methotrexate-Serum Albumin Binding

J. Richard Taylor, MD, Kenneth M. Halprin, MD

• **Approximately 60% of methotrexate in serum is protein bound and this binding occurs primarily to serum albumin. The fraction of methotrexate bound remains relatively constant despite changes in free methotrexate concentrations over the range observed clinically.**

Indomethacin did not influence methotrexate-albumin binding, but salicylate in therapeutic concentrations produced a 20% to 60% decrease in binding. The clinical significance of these findings for patients requiring concomitant methotrexate and salicylate is discussed.

(*Arch Dermatol* 113:588-591, 1977)

The affinity of a drug for plasma proteins and the extent to which it is bound at therapeutic concentrations can greatly influence its distribution, excretion, and interaction with other drugs. Methotrexate is frequently used in the treatment of severe psoriasis. Studies of methotrexate absorption and excretion exist,[1,2] but little is known about methotrexate binding to plasma proteins and how this binding is influenced by concomitant ingestion of other medications. Psoriatic arthritis is frequently associated with severe psoriasis and may require the use of salicylates or indomethacin in addition to methotrexate. The purpose of this study was to investigate the influence of these drugs on methotrexate binding.

This was done in the following manner. We first determined that methotrexate is bound predominantly to the albumin fraction of serum protein. This was done by separating serum electrophoretically and determining the methotrexate concentration in the various fractions. We next studied the influence of albumin concentration and methotrexate concentration on binding. Binding was determined by ultrafiltration with the use of a membrane that allowed unbound methotrexate to pass but that retained albumin and any methotrexate bound to it. After these variables of methotrexate-albumin binding in this system had been determined, we studied the effects of adding sodium salicylate or indomethacin on binding.

MATERIALS AND METHODS

Drugs

Tritium-labeled methotrexate (methotrexate $-3',5'-H3(n)$ sodium salt; specific activity, 13 Ci/mmole) was obtained and after thin-layer chromatographic purification was determined to be greater than 98% radiochemically pure. Nonradioactive methotrexate, sodium salicylate, and indomethacin were obtained in crystalline form. All drugs were buffered with phosphate buffer with a pH of 7.4 and prepared so that the final solution had an ionic strength of 0.16 M.

Proteins

Normal human serum control was obtained lyophilized and was reconstituted just before use by the addition of distilled water. Crystalline human serum albumin was obtained and was found to be electrophoretically pure and to contain 0.05 mM of fatty acid per millimolar of albumin. Various albumin concentrations were prepared by dissolving an appropriate amount

Accepted for publication Oct 13, 1976.

From the Dermatology Service, Miami Veterans Administration Hospital and the Department of Dermatology, University of Miami School of Medicine, Miami.

Reprint requests to VA Hospital, Dermatology Service, 1201 NW 16 St, Miami 33125 (Dr Taylor).

of crystalline albumin in 0.16 M phosphate buffer (pH of 7.4).

Which Serum Protein Binds Methotrexate?

To determine which serum protein binds methotrexate, the following was done. Sufficient tritium-labeled methotrexate (specific activity, 13 Ci/mmole; 0.5 mCi/ml) was added to 5 ml each of normal human serum, 5% normal human albumin, and phosphate buffer to produce a final concentration of 5 μCi/ml. The three solutions were incubated at 25 C with occasional gentle mixing for two hours to assure equilibration. Two 1 × 3-inch cellulose acetate-coated mylar strips were prepared from each solution by placing 2 μl one half inch from the end (Fig 1). The strips were subjected to electrophoresis in 0.075 M barbital buffer with a pH of 8.6 for 45 minutes with 100 volts dc. After migration, one set of strips was fixed in 5% acetic acid for ten minutes, dried, and set aside for scintillation counting. The duplicate set of strips was stained for protein with ponceau S dye (0.09% ponceau S, 1.34% trichloroacetic acid, 1.34% sulfosalicylic acid), destained in 5% acetic acid, and cleared in glacial acetic acid-ethyl acetate (7:3 v/v).

The location of the stained protein in the stained set of slides was used to divide the unstained set into appropriate sections for counting. Each resulting section was dissolved in a scintillation vial containing 15 ml of modified Bray solution, and the radioactivity present was determined in a liquid scintillation spectrometer. Quench variations among samples were corrected using an automatic external standard.

Methotrexate-Albumin Binding

Methotrexate binding to serum albumin was determined by ultrafiltration using a model 8-MC ultrafiltration cell equipped with a PM-10 membrane and 2 kg/sq cm pressure was maintained with nitrogen gas. (PM-10 membrane retains all molecules greater than a molecular weight of 10,000. Membranes were presoaked in distilled water for 24 hours and transferred to buffer one to two hours before use.) This method for determining ligand-protein binding has been described by several investigators,[3-5] and is an accepted method for such studies.[6] The model 8-MC ultrafiltration cell has a 5-ml sample chamber to which the membrane is attached and is provided with a magnetic stirring bar to prevent concentration polarization of the protein retent over the membrane. The cell is also equipped with a 100-ml reservoir as part of the closed pressurized system. As the stirred sample is filtered through the membrane, reservoir solution enters the sample chamber at the same rate that ultrafiltrate is formed and, therefore, the retent is maintained at a constant volume and is continually exposed to fresh reservoir solution.

Ultrafiltrate was collected in separate preweighed tubes by a fraction collector. When the ligand concentration in the ultrafiltrate equals its concentration in the reservoir solution, binding equilibrium has occurred. At equilibrium, aliquots of reservoir solution, retent, and ultrafiltrate were collected, their volumes determined, and the amount of drug and protein present measured. Albumin concentrations were determined fluorometrically with 1-anilinonaphthalene-8-sulfonic acid using the method described by Elevitch.[7] Methotrexate was determined by placing 100 μl of each sample in vials containing 15 ml of modified Bray solution and comparing the activity present with known dilutions of tritium-labeled methotrexate in a liquid scintillation spectrometer. Variations in quench among samples were corrected by use of an automatic external standard.

Effect of Salicylate and Indomethacin on Methotrexate-Albumin Binding

In these experiments, 5% serum albumin was allowed to reach equilibrium binding with a reservoir solution that contained 10^{-6}M methotrexate (0.1 μCi/ml). After removal of 100 μl of retent for determination of binding without drug, the reservoir solution was replaced with phosphate buffer containing the same concentration of methotrexate as before but to which appropriate amounts of salicylate or indomethacin had also been added. Ultrafiltration was continued until equilibrium was again obtained and binding of methotrexate to albumin again determined.

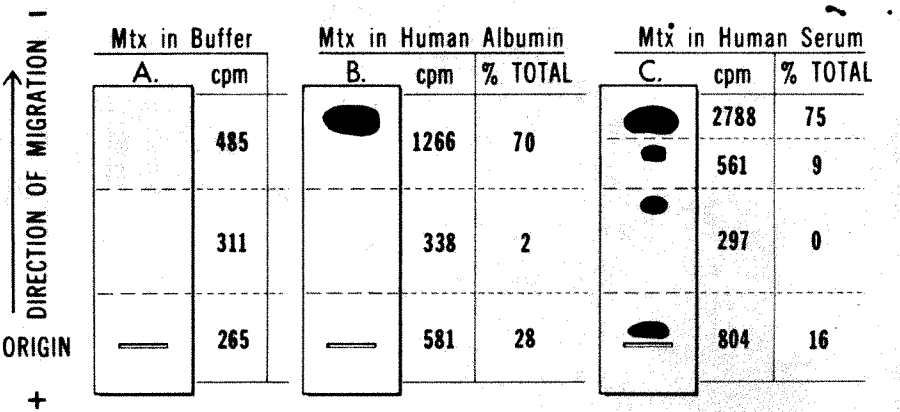

Fig 1.—Diagram of distribution of methotrexate after electrophoresis on cellulose acetate strips. For procedure and calculations see text. Dark areas indicate stainable proteins and dashed lines indicate strip separation for determination of radioactivity.

RESULTS

Serum Protein Fraction Binding Methotrexate

Figure 1 shows the protein separation and corresponding counts per minute of tritium-labeled methotrexate present in the different sections of the cellulose acetate strips. Nonspecific binding of tritium-labeled methotrexate to the strips occurred as indicated by the counts per minute present in the three sections of strip A. These background values were subtracted from the counts per minute present in corresponding sections of strips B and C before determining the percent of total counts per minute present in each.

Methotrexate is bound predominantly by albumin. The small amount of binding to other serum proteins is insignificant compared with albumin. Normal human serum albumin was therefore used for the equilibrium studies.

Methotrexate-Albumin Binding

To determine the effect of albumin concentration on methotrexate binding, 10^{-6}M methotrexate (0.1 μCi/ml, tritium-labeled methotrexate) was equilibrated with albumin in concentrations of 2 to 7 gm/100 ml and the fraction bound was determined. The results are illustrated in Figure 2. The fraction of methotrexate bound is proportional to the albumin concentration ranging from 30% with an albumin concentration of 2 gm/100 ml to more than 70% with an albumin concentration of 7 gm/100 ml. Ap-

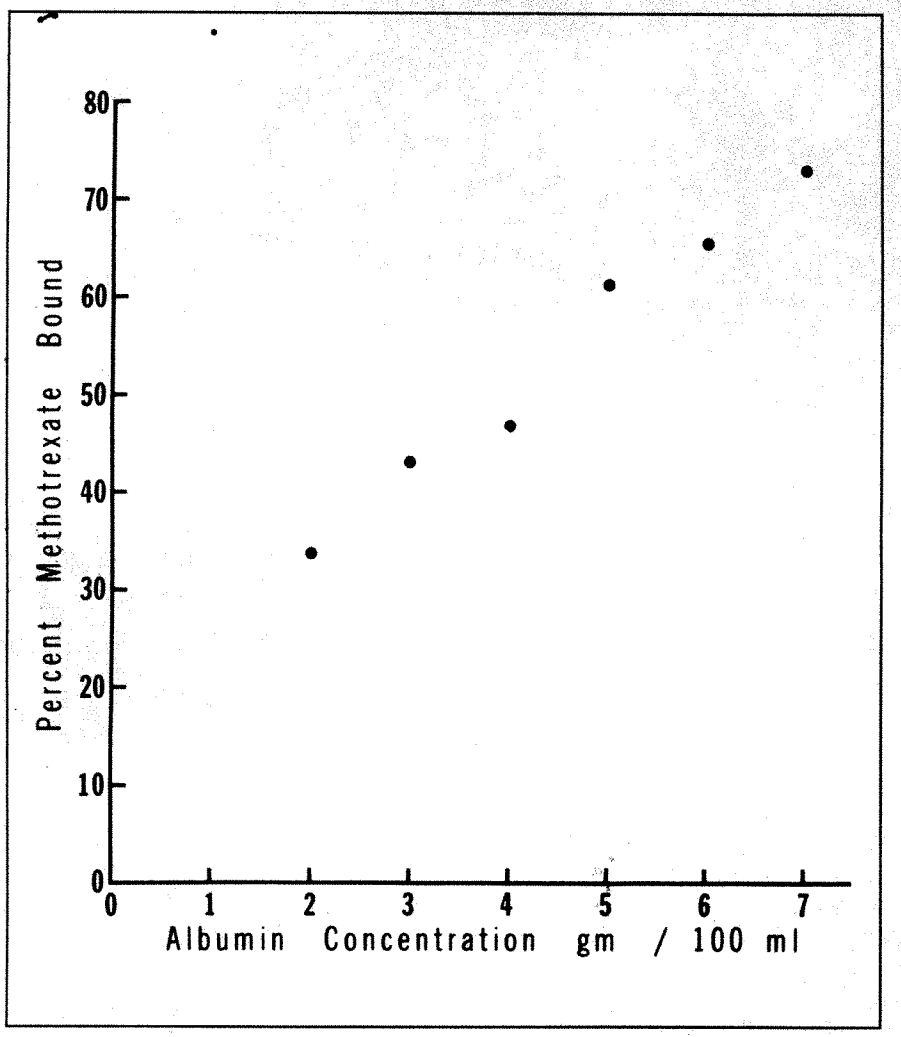

Fig 2.—Percent of methotrexate bound at albumin concentrations from 2 to 7 gm/100 ml. Free methotrexate concentration, 10^{-6}M.

Table 1.—Influence of Methotrexate Concentration on Binding to 5% Albumin

Experiment	Methotrexate Concentration, µg/ml	Methotrexate Concentration, Moles/Liter	% Methotrexate Bound	SD
3	0.005	1×10^{-8}	60	8.4
1*	0.09	2×10^{-7}	66	...
1*	0.41	9×10^{-7}	55	...
10*	0.46	1×10^{-6}	61	3.9
1*	1.14	2.5×10^{-6}	54	...
1*	2.27	5.0×10^{-6}	53	...
1	4.60	1×10^{-5}	44	...
3	0.09	2×10^{-5}	51	6.2
1	27.29	6×10^{-5}	39	...
3	45.46	1×10^{-4}	39	5.1
2	113.64	2.5×10^{-4}	54	...
2	181.80	4×10^{-4}	55	...
2	454.55	1×10^{-3}	40	...
1	1136.37	2.5×10^{-3}	41	...
1	2272.74	5×10^{-3}	16	...

*The methotrexate concentrations for these experiments were observed clinically.

proximately 50% to 60% of the methotrexate is bound at normal albumin concentrations of 4.5 to 5.5 gm/100 ml.

Table 1 gives the percent of methotrexate bound at free methotrexate concentrations from 1×10^{-8} to 5×10^{-3}M. The albumin concentration was 5 gm/100 ml for all determinations. When more than one determination was done at the same methotrexate concentration, the results were averaged. The number of determinations performed at a given free methotrexate concentration and when possible the standard deviation are also included in Table 1. The percent of methotrexate bound is remarkably constant and does not begin to decrease until very high free methotrexate concentrations are used. This decrease is of only theoretical interest since binding remains constant at methotrexate concentrations seen clinically (2×10^{-7} to 5×10^{-6}M).

Effect of Salicylate and Indomethacin on Methotrexate-Albumin Binding

The percent of methotrexate bound to human serum albumin is decreased in the presence of salicylate. The binding of 1×10^{-6}M methotrexate to 5 gm/100 ml of albumin with four concentrations of salicylates is given in Table 2. These concentrations of salicylate are all comparable to serum levels of salicylate that might be observed clinically. As the salicylate concentration increases, a greater amount of bound methotrexate is displaced from albumin as indicated by the decrease in the percent of methotrexate bound.

The influence of a therapeutic concentration of indomethacin on the same concentrations of methotrexate and albumin used as just described was also studied and the results are included in Table 2. There was no significant change in binding in the presence of 0.014 M of indomethacin.

COMMENT

A considerable amount of literature exists in the field of drug-protein binding.[4-6,8,9] Most of these studies describe systems that react in a

Table 2.—Change in Methotrexate-Albumin Binding With Various Concentrations of Salicylate and Indomethacin

Salicylate Concentration		% Methotrexate Bound		Indomethacin Concentration		% Methotrexate Bound	
mg/100 ml	Moles/Liter	With Salicylate	Without Salicylate	mg/100 ml	Moles/Liter	With Indomethacin	Without Indomethacin
2	1.25×10^{-4}	46	58	0.5	1.4×10^{-5}	59	63
6	3.75×10^{-4}	45	62	...	...	...	...
10	6.25×10^{-4}	34	57	...	...	...	...
33	2.06×10^{-3}	23	68	...	...	...	...

predictable manner to a given change in drug or protein concentration. Newer analytical methods for measuring small concentrations of commonly used drugs have demonstrated several systems where binding to serum appears to be independent of the free drug concentrations,[10-12] which is analogous to methotrexate-albumin binding found in this study. Approximately 60% of methotrexate in serum is bound and this binding occurs primarily to serum albumin. Others have reported 70%[13] and 50%[14] bound and substantiate our finding that percent binding varies little with changes in free methotrexate concentration over the range observed clinically.

Indomethacin did not influence methotrexate binding, but salicylate in concentrations seen under clinical conditions displaced bound methotrexate. Methotrexate binding was decreased 20% to 60% by the salicylate concentrations tested. The clinical implications of these findings are not known and it is not possible to predict changes that might occur in vivo from these limited in vitro studies. In vivo, displaced methotrexate is rapidly redistributed into the total body water and is available for interaction with other tissues and for more rapid excretion. It is probable that even total displacement of bound methotrexate by salicylate would result in only a slight and transient increase in free methotrexate concentrations in serum because of these factors. Dettli[15] has studied the pharmacokinetics of drug interaction in some detail and concludes that for displacement from binding sites to be of practical significance, the displaced drug must originally be 90% bound and once displaced its distribution volume should not exceed the volume of the extracellular water. From these criteria, displacement of bound methotrexate would not be of practical significance.

Numerous articles are available that deal specifically with drug interaction[8] or with this as one of the many types of adverse drug reactions.[16] Many contain extensive tabulations of potential drug interactions. Unfortunately, few contain sufficient information to allow critical appraisal of the likelihood or clinical significance of a given interaction. When the original data from which these lists were developed is examined, one finds animal studies not directly applicable to man, clinically unimportant interactions, isolated case reports of questionable significance, and some instances of frank speculation.[17,18] Methotrexate-salicylate interaction invariably appears in these lists, and it, too, is based on a limited number of uncritical case reports.[19]

Although salicylate can displace methotrexate bound to serum albumin, the small transient increase in free methotrexate concentration produced would be of doubtful clinical significance. This is particularly true in the treatment of psoriasis where methotrexate is given once weekly and the dosage is determined by the patient's clinical response. Because of these factors, this potential drug interaction should not preclude the judicious use of these drugs concomitantly in patients requiring the effects of both substances.

References

1. Halprin KM, Fukui K, Ohkawara A: Blood levels of methotrexate and the treatment of psoriasis. *Arch Dermatol* 103:243-249, 1971.
2. Freeman MV: Fluorometric measurement of the absorption distribution and excretion of single doses of amethopterin in man. *J Pharmacol Exp Ther* 122:154-162, 1958.
3. Blatt WF, Robinson SM, Bixler HJ: Membrane ultrafiltration: The diafiltration technique and its application to microsolute exchange and binding phenomenon. *Anal Biochem* 26:151-173, 1968.
4. Chignell CF: Optical studies of drug-protein complexes: II. Interaction of phenylburazone and its analogues with human serum albumin. *Mol Pharmacol* 5:244-252, 1969.
5. Chignell CF: Physical methods for studying drug-protein binding, in Brodie BB, Gillette JR (eds): *Concepts in Biochemical Pharmacology*. Berlin, Heiffter-Heubner, 1971, vol 28, pp 181-212.
6. Goldstein A: The interaction of drugs and plasma proteins. *Pharmacol Rev* 1:102-165, 1949.
7. Elevitch FR: *Fluorometric Techniques in Clinical Chemistry*. Boston, Little Brown & Co, 1973, pp 280-283.
8. Goldstein A, Arnonow L, Kalman SM: *Principles of Drug Action*, ed 2. New York, John Wiley & Sons, 1974, pp 47-66, 158-164, 826.
9. Scratchard G: The attractions of proteins for small molecules and ions. *Ann NY Acad Sci* 51:660, 1949.
10. Franksson G, Añggård E: The plasma protein binding of amphetamine, catecholamines and related compounds. *Acta Pharmacol Toxicol* 28:209-214, 1970.
11. Olsen GD: Methadone binding to human plasma albumin. *Science* 176:525-526, 1972.
12. Borgå O, Azarnoff DL, Forshell GP, et al: Plasma protein binding of tricyclic antidepressants in man. *Biochem Pharmacol* 18:2135-2143, 1969.
13. Liegler DG, Henderson ES, Hahn MA, et al: The effect of organic acids on renal clearance of methotrexate in man. *Clin Pharmacol Ther* 10:849-857, 1969.
14. Henderson ES, Adamson RH, Oliverio VT: The metabolic fate of tritiated methotrexate: II. Absorption and excretion in man. *Cancer Res* 25:1018-1024, 1965.
15. Dettli L: Pharmacokinetic aspects of drug interactions, in Cluff LE, Petrie JC (eds): *Clinical Effects of Interaction Between Drugs*. New York, American Elsevier Pub Co, Inc, 1974, p 59.
16. Karch FE, Lasagna L: Adverse drug reactions. *JAMA* 234:1236-1241, 1975.
17. Goodman LS, Gilman A: *The Pharmacological Basis of Therapeutics*, ed 5. New York, Macmillan Co, 1975, p 36.
18. Hansen PD: *Drug Interactions*. Philadelphia, Lea & Febiger, 1971, pp 133, 144-145.
19. Baker H: Intermittent high dose oral methotrexate therapy in psoriasis. *Br J Dermatol* 82:65-69, 1970.

Clinical and Histological Study of Coal Tar Phototoxicity in Humans

Kays H. Kaidbey, MD, Albert M. Kligman, MD, PhD

• **Coal tars of different origin were compared with regard to their capacity to cause a phototoxic reaction in human skin. The photosensitizing potencies were found to differ. Tars that were partially refined had less activity than crude coal tar. An extract of tar, liquor carbonis detergens, was the least photosensitizing.**

The phototoxic reaction to coal tar was found to be a two-stage process, an immediate wheal associated with sharp burning, followed by a raised, red, infiltrated lesion peaking at 24 to 48 hours. The phototoxic reaction was completely prevented when arterial blood flow was cut off.

The histological findings were prominently epidermal, with strong intracellular edema sometimes leading to microvesicles.

It seems a possibility that assaying phototoxic potentiality may provide a convenient measure of therapeutic efficacy of materials derived from coal tar.

(*Arch Dermatol* 113:592-595, 1977)

Physicians usually view phototoxic reactions as undesirable side effects of commonly administered drugs. The benefits of certain of these drugs, such as phenothiazines and tetracyclines, far outweigh the mischief they do and physicians continue to use them despite their phototoxic potentialities. Dermatologists, however, have adapted some photosensitizers to therapeutic advantage. The photosensitizing action of coal tar may be a factor in the Goeckerman[1] method of phototherapy for psoriasis.[2] Plant extracts containing phototoxic psoralens have been used for centuries in conjunction with sunlight to treat vitiligo. Recently, 8-methoxypsoralen has been shown to be effective in treating psoriasis both locally and orally in conjunction with long ultraviolet light.[3-5]

Curiously, long-standing familiarity with the photosensitizing properties of coal tar, whether in outdoor workers exposed to tars or in psoriatics undergoing the Goeckerman regimen, have seemed to stifle curiosity regarding the nature of the reaction. Pitch workers have long experienced an immediate stinging response (the smarts) after exposure to sunlight.[6] Clinicians, however, do not seem to be aware that immediate wheal reactions are characteristic of coal tar phototoxicity. Aside from realizing that photosensitization requires long ultraviolet rays (> 320 nm), little is known about the histopathology and pathophysiology of the reaction.

Because of its unwelcome appearance and odor, many efforts have been made to develop more agreeable tar products. The extent to which pharmacologic activity is sacrificed for cosmetic improvement is generally hard to estimate. That is unfortunate when one considers that tars are perhaps second only to corticosteroids in being the most widely prescribed topicals for diverse chronic dermatoses. Clinical assessments of efficacy are difficult and notoriously unreliable. No standards are available for determining the therapeutic potency of various tars except by clinical trial. We propose to show that phototoxic capacity can be readily measured in human skin and may provide a means for estimating the clinical efficacy of tars in chronic dermatoses.

MATERIALS AND METHODS

Subjects

The participants were adult, student volunteers between 20 and 30 years of age.

Light Source

Long ultraviolet light rays (UVA) were obtained from five 20-W blacklight fluorescent tubes housed in a reflecting bank. These emit a continuous spectrum beyond the sunburn range, with a peak output at about 360 nm. The source-to-skin distance was 2 inches and the intensity was 3.46 mW/59 cm as measured by a calibrated thermopile.

Coal Tar Phototoxicity

The phototoxic response was studied in 26 subjects each of whom received 50 mg of 5% crude coal tar in hydrophilic ointment to a 1-square inch site over the volar aspect of the forearm. The sites were occluded for two hours, cleansed with acetone-soaked gauze, and immediately exposed to UVA for ten minutes.

Phototoxic Assay

Details of the procedure have been given previously.[7] Briefly, 50 mg of the test material is applied uniformly with a glass rod to 1-inch squares of skin outlined with

Accepted for publication January 27, 1976.

From the Department of Dermatology, School of Medicine, University of Pennsylvania, Philadelphia.

Reprint requests to Duhring Laboratories, Department of Dermatology, University of Pennsylvania, Suite 203, 3500 Market St, Philadelphia 19104 (Dr Kligman).

adhesive tape on the volar aspect of the forearm. The site is then covered with a 1-sq inch patch of nonwoven cotton cloth. The forearm is then encircled with plastic film held securely in place by adhesive tape. Two hours later, the site is wiped with acetone-soaked gauze. Exposure to UVA for four minutes follows immediately (0.83 J/sq cm). Reactions were graded by one of us (K. K.) as follows: 0 indicated normal skin; 1, minimal erythema; 2, more intense erythema; and 3, intense erythema and edema. Each test site was graded at 24 and again at 48 hours and both readings were averaged. Student t test was used to test significance.

Comparison of Coal Tars

Five percent concentrations of seven different tars in hydrophilic ointment were assayed in each of eight subjects. The tars were applied randomly to the volar aspects of both forearms (seven sites per subject). We have shown previously that hydrophilic ointment is a particularly good vehicle for coal tar.[7] Samples of crude coal tar were obtained from four different manufacturers. These are putatively USP crude coal tars. In addition, two partially refined tars from two different manufacturers were evaluated. Liquor carbonis detergens was also secured.

Histopathology

A total of three biopsy specimens were obtained from each of four subjects. Three sites in each individual were sensitized with 5% crude coal tar in hydrophilic ointment and exposed to UVA for ten minutes. Biopsy specimens were obtained immediately after irradiation and after 24 and 48 hours. The specimens were fixed in a 10% formaldehyde solution and stained with hematoxylin-eosin and PAS.

Studies of Wheal Reaction

The possibility that histamine mediated the immediate wheal reaction was studied in the following ways. The tests were conducted on the volar aspect of the forearms, using 5% crude coal tar in hydrophilic ointment. The irradiation was extended to ten minutes to ensure the development of wheals.

Depletion of Skin Histamine.—Two and three tenth-centimeter squares of filter paper were saturated with an aqueous solution of compound 48-80 (0.07 mg/ml) and placed on the forearm of seven subjects. An iontophoretic current was applied at a current density of 0.19 ma/sq cm for three minutes. A similar application 15 minutes after the wheal subsided did not provoke a new wheal, indicating depletion of histamine stores in mast cells. Two hours after flattening of the wheal, 25 mg of the tar ointment was applied to one half-square inch areas for two hours and then irradiated in the usual way.

Phototoxicity of Coal Tars (5% Concentration in Hydrophilic Ointment)*

Tar†	Mean ± SE‡
Crude coal tars	
A	1.92 ± 0.08
B	1.75 ± 0.13
C	1.50 ± 0.22
D	1.14 ± 0.14
Partially refined tars	
A	0.80 ± 0.07
B	0.71 ± 0.15
Wright LCD	0.58 ± 0.15

*Phototoxicity measured by intensity of erythema and edema on a four-point scale: 0, normal skin; 3, intense erythema and edema.

†Each sample was obtained from a different manufacturer. LCD indicates liquor carbonis detergens.

‡Mean values represent averages of eight readings for each tar obtained at 24 and 48 hours after irradiation.

Antihistamine.—Five percent crude coal tar was applied to two sites for two hours in each of ten subjects. Thirty-five minutes before irradiation, one site was injected intradermally with 0.2 ml of chlorpheniramine maleate (1:1,000) in physiologic saline; the other received 0.2 ml of saline.

Influence of Corticosteroids

A 0.05% fluocinonide ointment (Lidex, Syntex) was applied to five subjects under an occlusive dressing for 24 hours before inducing a phototoxic response. A control site received white petrolatum. In another four subjects, the phototoxic reaction was evaluated five hours after a single orally administered dose of 12 mg of triamcinolone acetonide.

Influence of Arterial Occlusion

A sphygmomanometer cuff was placed on the upper arm of six subjects and inflated to greater than arterial pressure five minutes before irradiation of a tar-treated site. The blood supply was curtailed during the entire ten-minute irradiation period. A similar tar site over the opposite arm served as the control.

RESULTS

Evolution of the Phototoxic Response

The gross events were similar in all subjects and developed in the following pattern. Within one to two minutes of exposure, the subject experiences a sharp burning sensation in the absence of any visible sign. The burning is similar to a hot object placed close to the skin. It increases in intensity and becomes very pronounced after four to six minutes, at about which time erythema becomes apparent with a surrounding flare. By the end of the exposure time (ten minutes) a solid erythematous wheal develops, localized to the irradiated site and surrounded by an erythematous flare. The burning gradually dissipates after irradiation stops and is replaced by a slight dull pain. The wheal resolves in 30 to 60 minutes. During the next two to four hours, the flare regresses, becoming exactly localized to the site of irradiation. After about 12 hours, the erythema deepens and the site becomes palpably raised. These changes peak in 24 to 48 hours. Thus, the phototoxic reaction is a two-stage process: an immediate wheal followed by a late infiltrated reaction. In 5 of the 26 subjects who had a darker complexion an immediate response developed, namely, erythema, flare, and pain without whealing. They also had a mild delayed response. Intense reactions healed slowly over a period of 10 to 14 days, after becoming crusted. Pigmentation became evident seven to ten days after exposure and was more intense in the dark-complexioned individuals. In three of these subjects, pigmentation was still present three months after exposure.

Comparison of Tars

The tars differed appreciably in regard to the intensity of the late reaction (Table). Two partially refined tars were equivalent but significantly less phototoxic than the crude tars ($P < .05$). Liquor carbonis detergens was less active than the refined products.

Histopathology

Biopsy specimens obtained from wheals immediately after irradiation showed only dilated vessels and perivascular edema in the upper dermis. By 24 hours, epidermal changes became evident. These ranged from moderate spongiosis with intracellular

Fig 1.—Twenty-four-hour reaction. Spongiosis and intracellular edema are notable in basal portion of epidermis whereas necrobiotic changes are underway at top. Dermal vessels are dilated but inflammatory cells are meager (hematoxylin-eosin, original magnification ×210).

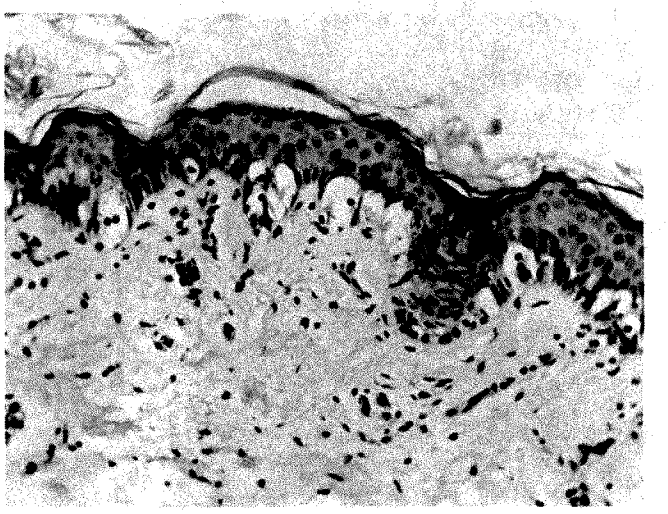

Fig 2.—Twenty-four-hour reaction. Considerable vacuolar degeneration of basal cells with dermo-epidermal separation. Dermis is edematous. (hematoxylin-eosin, original magnification ×260).

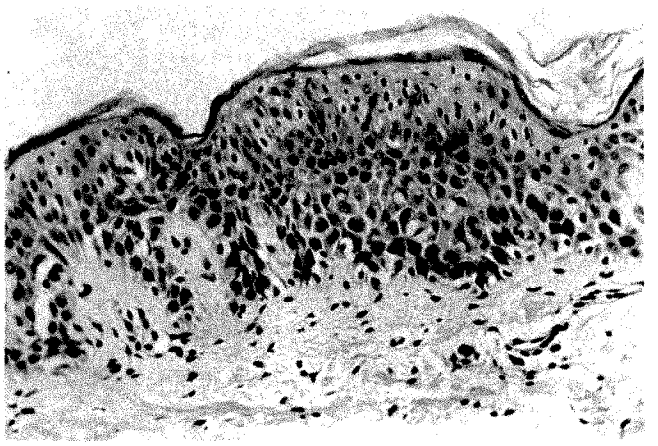

Fig 3.—Forty-eight-hour reaction. Spongiosis and vacuolar degeneration of keratinocytes, with necrosis of superficial cell layers (hematoxylin-eosin, original magnification ×260).

edema (Fig 1) to pronounced swelling and vacuolar degeneration of the basal cells with the formation of microvesicles (Fig 2). The latter were located above the PAS-positive basement membrane, resulting in subepidermal clefts. In the superficial layers, only a few foci of mild intracellular vacuolization were occasionally present. Sunburn cells were absent. The papillary dermis appeared diffusely edematous. The upper dermal vessels were dilated and surrounded by a sparse mononuclear infiltrate. By 48 hours, epidermal injury was even more pronounced, though dermal edema and vascular dilatation were somewhat lessened. In addition to vesiculation, there was extensive intracellular edema and almost all the keratinocytes appeared vacuolated (Fig 3). The cells in the superficial malpighian layers appeared swollen and their outlines hazy. Their cytoplasm was homogenized and stained less intensely. Most showed prominent perinuclear halos.

Wheal Reaction

Iontopheresis of Compound 48/80.—Only two of the seven subjects showed a diminished wheal and flare response in sites pretreated with compound 48/80. The burning sensation was not affected. The late reaction in the two subjects who showed a decreased immediate response was less pronounced.

Chlorpheniramine Maleate.—In two of ten subjects, prior injection of the antihistamine completely suppressed whealing, whereas in two others the wheals were diminished in size. Erythema and the flare-like response were also diminished but not abolished. The reaction was not altered in the other six subjects. The delayed response was also less pronounced in the four subjects in whom whealing was suppressed or diminished.

Corticosteroids

Neither topical nor oral steroids had any influence on the immediate or delayed phase of the phototoxic reaction in any of the nine subjects. The burning was unaffected.

Arterial Occlusion

In all six subjects, arterial occlusion completely suppressed the burning, erythema, and whealing. The delayed response was also completely abolished. Control sites over the opposite arms developed a brisk reaction. After the cuff was removed, a faint erythema developed in the irradiated site of only one subject.

COMMENT

The finding of variable activity among crude coal tars was not unexpected. Using chromatographic techniques, Gruber et al[5] found considerable differences among random samples of USP tars. Tar is an incred-

ibly complex mixture made up of literally thousands of substances. Samples will invariably vary with the source and mode of distillation. Chemical standardization is not a likelihood in the near future. The components that possess therapeutic activity are not even roughly known. At present, therapeutic efficacy is assessed by clinical testing in chronic dermatoses, such as psoriasis, an arduous and uncertain task. More reliable and simpler means of assay are needed. We have found that the antipsoriatic activity of various tars paralleled their phototoxic potentialities (unpublished observations). Crude coal tars were more effective than fractions derived therefrom. Vegetable and bituminous tars had no photosensitizing activity and were ineffective in psoriasis. These findings are similar to the observations made by Obermayer and Becker.[2] It seems possible, therefore, that a phototoxic assay could provide a means of predicting the efficacy of various tars in chronic dermatoses. Different tars and tar fractions could be quickly and easily appraised by a standard test of phototoxic capacity. However, more study is needed to substantiate our hypothesis that therapeutic activity and phototoxicity go hand in hand.

It should be pointed out that the reciprocal situation does not hold. Potent photosensitizers in tars such as anthracene and fluoranthene have no intrinsic activity when used alone in treating psoriasis (unpublished observations).

The phototoxic reaction can be clinically and histologically separated into two phases: an immediate urticarial reaction preceded by intense burning and erythema followed by a late phase characterized by considerable epidermal injury. The two phases blend into each other. Histamine liberation may play a role in mediating the immediate wheal and flare response. However, the results obtained in this study were not consistent enough to clarify this point. Further evaluation of this aspect of the immediate response is needed.

Prevention of the wheal and the late reaction by excluding arterial blood flow during irradiation suggests that the reaction is oxygen dependent (photodynamic). Other effects of arterial occlusion such as change in local pH or flow of mediators may also be important. Crow et al[6] also found that phototoxic reactions to anthracene were not influenced by antihistamines but could be blocked by arterial occlusion. Steroids had no effect on the course of the reaction. It should be noted that the microscopic signs of inflammation were minimal in the dermis, especially regarding cellular infiltration.

Studies by others provide some clue as to how phototoxic agents might incite an immediate wheal response. Anthracene, a photosensitizer in coal tar, has been shown to localize in lysosomes when incubated with macrophages in vitro.[9] Subsequent irradiation by UVA caused increased permeability of lysosomal membranes, with leakage of lytic enzymes and subsequent cell death. Anthracene can also damage cell membranes, as evidenced by hemolysis of irradiated RBCs.[10] Both types of membrane injury require oxygen. Allison et al[10] found that photosensitizers are readily taken up by lysosomes of mast cells and endothelial cells. The release of enzymes and other mediators from these different sources could explain the loss of fluid from vessels and account for the edema in the upper dermis.

Epstein[11] noted that immediate stinging and swelling will develop after coal tar photosensitization. This should be emphasized. Among the reactions to common contact photosensitizers, whealing is a singular characteristic of coal tar phototoxicity. The late reaction, however, is perhaps not very distinctive, showing mainly diffuse epidermal injury. The epidermal findings resemble those produced by other topical phototoxic agents such as chlorpromazine and bergamot oil.[11,12] Little is known about the histopathology of phototoxic reactions produced by different chemicals in human skin. The photosensitizing ingredients in tar include anthracene, fluoranthene, phenanthrene, benzpyrine, and acridine.[13,14] We found that anthracene, fluoranthene, and phenanthrene, in that order of phototoxic potency, produced responses indistinguishable from that produced by coal tar (unpublished observations).

Finally, mention should be made of the pigmentation that develops after resolution of the phototoxic reaction. This tends to be quite persistent. Hyperpigmentation is one of the most prominent features in the sun-exposed skin of pitch workers.[15] The phototoxic psoralens are also known to produce considerable stimulation of melanogenesis and as such have been successfully applied to the treatment of vitiligo. It is conceivable that coal tar might also prove beneficial in the treatment of that disease.

Nonproprietary Names and Trademarks of Drugs

Fluocinonide—*Lidex, Topsyn.*
Chlorpromazine—*Chlor-PZ, Thorazine.*

References

1. Goeckerman WH: The treatment of psoriasis. *Northwest Med* 24:229-231, 1925.
2. Obermayer ME, Becker SW: A study of crude coal tar and allied substances. *Arch Dermatol Syphilol* 31:796-810, 1935.
3. Walter JF, Voorhees JJ: Psoriasis improved by psoralen plus black light. *Acta Derm Venereol* 53:469-472, 1973.
4. Weber G: Combined 8-methoxypsoralen and black light therapy of psoriasis. *Br J Dermatol* 90:317-323, 1974.
5. Parrish JA, Fitzpatrick TB, Tanenbaum L, et al: Photochemotherapy of psoriasis with oral methoxsalen and longwave ultra-violet light. *N Engl J Med* 291:1207-1211, 1974.
6. Crow KD, Alexander E, Buck WHL, et al: Photosensitivity due to pitch. *Br J Dermatol* 73:220-232, 1961.
7. Kaidbey KH, Kligman AM: Topical photosensitizers: Influence of vehicles on penetration. *Arch Dermatol* 110:868-870, 1974.
8. Gruber M, Klein R, Fox M: Chemical standardization and quality assurance of whole crude coal tar USP utilizing GLC procedures. *J Pharm Sci* 59:830-834, 1970.
9. Allison AC, Mallucci L: Uptake of hydrocarbon carcinogens by lysosomes. *Nature* 203:1024-1027, 1964.
10. Allison AC, Magnus IA, Young MR: Role of lysosomes and of cell membranes in photosensitization. *Nature* 209:874-878, 1966.
11. Epstein S: Chlorpromazine photosensitivity: Phototoxic and photoallergic reactions. *Arch Dermatol* 98:354-363, 1968.
12. Epstein JH: Photoallergy: A review. *Arch Dermatol* 106:741-748, 1972.
13. Foerster HR, Schwartz L: Industrial dermatitis and melanosis due to photosensitization. *Arch Dermatol Syphilol* 39:55-68, 1939.
14. Burckhardt W: Photoallergy and phototoxicity due to drugs: The biologic effects of ultraviolet radiation, in Urbach F (ed): *Proceedings of the First International Symposium on the Skin.* New York, Pergamon Press, 1969, pp 527-532.
15. Foerster HR, Schwartz L: Occupational melanosis from pitch. *Arch Dermatol Syphilol* 39:955-968, 1939.

Papillary Eccrine Adenoma

David B. Rulon, MD, Elson B. Helwig, MD

• **We studied in 14 patients a distinctive eccrine sweat gland tumor that we have termed papillary eccrine adenoma. There was a majority of black patients, and the tumors were located most often on the distal extremities. Eleven patients were followed up for an average of 35 months after excision of the tumor. No tumor metastasized but one recurred, and since re-excision the patient has been followed up 30 months without further regrowth. Although previously regarded sometimes as malignant, the papillary eccrine adenoma is considered benign on the basis of our experience. Excision, with assurance from pathologic examination that the surgical margins are free of tumor, is the treatment of choice.**

Recognition of the neoplasm is based on the microscopic appearance of a pattern of structures resembling eccrine ducts, usually dilated, associated with intraluminal papillations.

(*Arch Dermatol* 113:596-598, 1977)

Fourteen examples of a distinctive neoplasm were found in the case records on file at the Armed Forces Institute of Pathology (AFIP). These cases were filed under sweat gland carcinoma or sweat gland adenoma. They were difficult to interpret and had been believed to occupy the gray zone separating benign and malignant neoplasms of the sweat glands. Since none was found to have metastasized, this lesion is provisionally considered benign. The diagnostic term of papillary eccrine adenoma is suggested.

Accepted for publication June 28, 1976.

From the Division of Skin and Gastrointestinal Pathology, Armed Forces Institute of Pathology, Washington, DC. Dr Rulon is associated with Union Hospital, Dover, Ohio.

The opinions or assertions contained herein are the private views of the authors and are not to be construed as official or as reflecting the views of the Department of the Army or the Department of Defense.

Reprint requests to Armed Forces Institute of Pathology, Washington, DC 20306 (Dr Helwig).

METHODS

Special stains were carried out as described in the *Manual of Histologic Staining Methods of the Armed Forces Institute of Pathology*.[1]

RESULTS
Clinical Information and Diagnoses

The clinical information is summarized in the Table. Eight tumors (57%) were on the distal extremities, one on the wrist, and seven on the hands or feet. Eleven occurred in women and three in men, a ratio of about 4:1. Eight patients were black, one white, one American Indian, and in four the race was unknown.

The size of the tumors ranged from 0.5 to 2.0 cm in greatest diameter. The clinical appearance varied from red to brown and gray. None was painful, but two were tender. None was ulcerated. The lesions had been present for several months to 12 years before excision. The ages of the patients at the time of excision ranged from 9 to 69 years. Five were 20 years of age or younger, and six were older than 50.

Clinical diagnoses were made in five patients; these included rhinophyma, neuroma, fibroma, giant cell tumor of the tendon sheath, and sebaceous cyst.

The initial pathologic diagnosis was known in 12 patients. All lesions were considered to be neoplasms of sweat gland origin. One was regarded as a low-grade carcinoma by the contributor, and in three other cases the possibility of malignancy was noted in the diagnosis.

Clinical Data on 14 Cases of Papillary Eccrine Adenoma

Case No.	Age at Excision, yr	Sex	Race	Location	Duration	Size, cm	Length of Follow-up, mo	Additional Information
1	12	F	Black	Left middle finger	12 yr	2.0	99	Finger amputated
2	12	F	Black	Dorsum, left wrist	?	1.0	109	Re-excised
3	30	M	Black	Dorsum, left hand	Several mo	1.0	35	...
4	20	M	American Indian	Abdomen	11 mo	0.6	37	...
5	49	F	Black	Dorsum, foot	?	0.5	16	...
6	61	F	White	Nose	18 mo	1.5	30	Punch biopsy, then excision; surgery three previous times in 18 mo
7	62	F	Black	Lateral surface, hip	Several yr	0.5	26	...
8	63	F	?	Shoulder	?	0.7	None	...
9	14	F	Black	Foot	?	1.4	24	...
10	69	F	?	Foot	Several yr	1.0	14	...
11	52	F	?	Great toe	6 yr	1.3	13	...
12	9	F	Black	Fifth toe	5 mo	0.9	12	...
13	52	M	Black	Upper thigh	Many yr	?	None	...
14	40	F	?	Leg	?	1.3	None	...

The AFIP consultant made an initial diagnosis of sweat gland carcinoma in one of the 14 cases and probable adenocarcinoma in another; the other 12 cases were interpreted as examples of sweat gland adenoma.

Of the 14 patients, 3 were lost to follow-up. Four were followed less than two years; four patients two to three years; one patient three to five years; and two patients for more than five years.

Eight of the 11 patients with follow-up information had no recurrence after excision. Two had additional surgical procedures (re-excision in one case and amputation of finger in the other) because a malignant condition was diagnosed or suspected on the basis of the histologic examination of the original material.

One lesion recurred. It was located on the nose of a 61-year-old white woman. The clinical diagnosis was rhinophyma. Surgical procedures were done 17, 12, and 6 months before two punch biopsy sections were taken, which were submitted for examination to AFIP. The extent of the first three excisions (or biopsies) is not known, and this material was not reviewed. The specimens from the punch biopsies were interpreted as atypical sweat gland adenoma (appendage carcinoma?), and a wider excision was done. The material from the punch biopsies showed mild nuclear pleomorphism and no mitotic figures in 50 high-power fields. Since the wide excision, no recurrence has occurred in the ensuing 30 months.

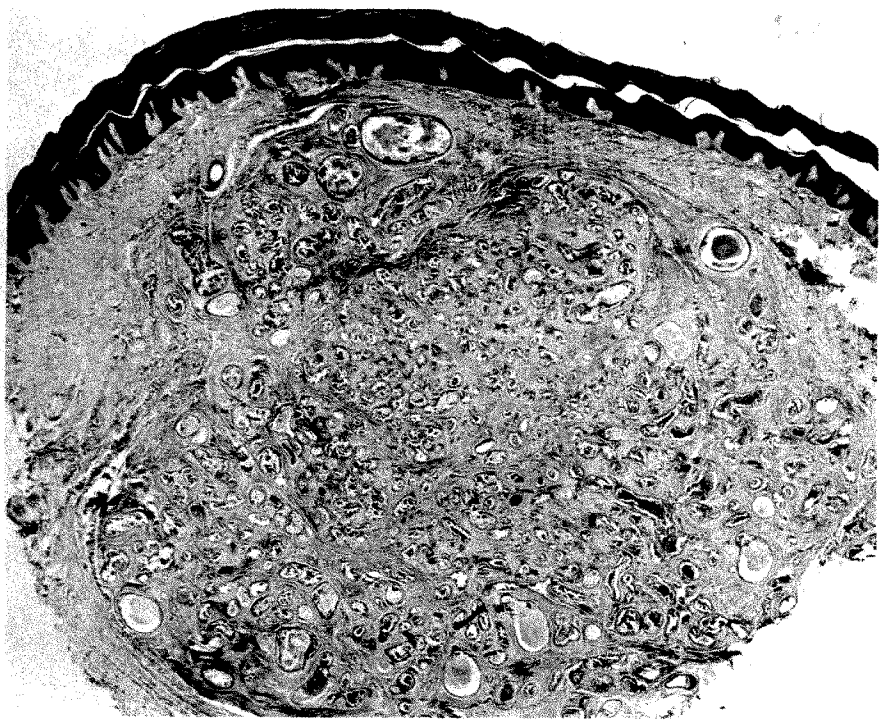

Fig 1.—Case 2: A disorganized fairly well circumscribed mass of ducts is localized in corium (hematoxylin-eosin, original magnification ×12).

Gross Features

The gross descriptions of the excised tissue were not distinctive. Poorly defined grayish-white areas of the dermis were noted, and in one instance the tissue was honeycombed with tiny cysts.

Microscopic Features

The distinctive microscopic appearance is characterized by the presence of dilated ducts of varying size (Fig 1). The ducts are lined by a double layer of uniform epithelial cells that form papillations projecting into the lumen and are surrounded by fibrous stroma (Fig 2-5). The ducts may contain amorphous eosinophilic material.

The epithelium lining the duct is, for the most part, two cells thick (Fig

Fig 2.—Case 4: Dilated ducts lined by double layer of epithelium with intraluminal epithelial papillations and eosinophilic secretion are surrounded by dense fibrous stroma (hematoxylin-eosin, original magnification ×115).

Fig 3.—Case 3: Pronounced and complex intraluminal papillations in large ducts surrounded by dense fibrous stroma (hematoxylin-eosin, original magnification ×115).

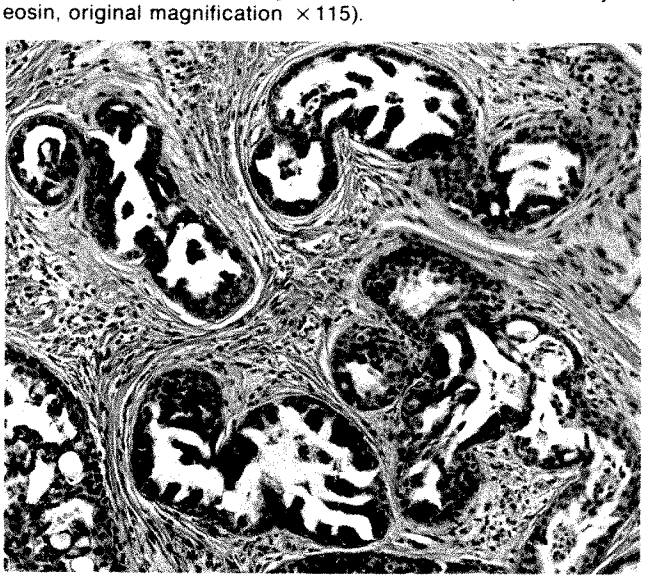

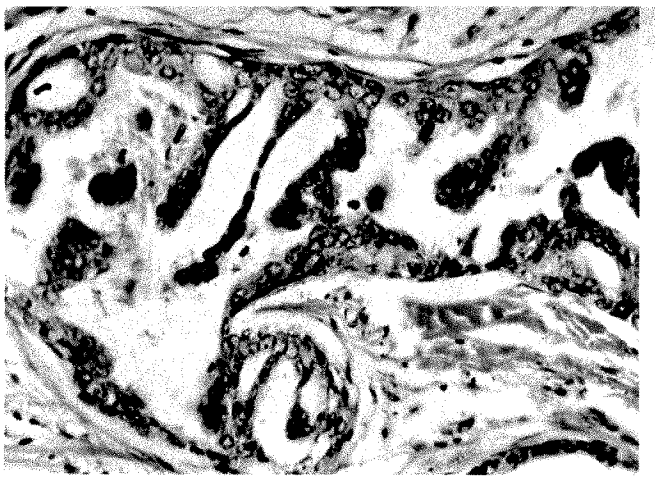

Fig 4.—Case 1: Intraluminal papillations are complex, and some have bullous tips (hematoxylin-eosin, original magnification ×285).

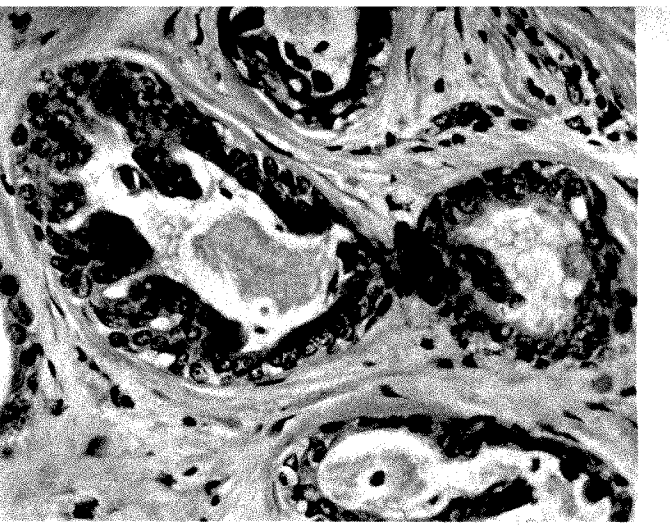

Fig 5.—Case 4: Cellular detail within duct. Nuclei are uniform and mitotic figures are absent (hematoxylin-eosin, original magnification ×285).

5). The outer layer of cells is cuboidal to flattened, and the inner layer may be flattened, cuboidal, or columnar. The cells in the inner layer may be crowded and pseudostratified, piling up into the lumen and forming complex patterns and papillations (Fig 3). The intraluminal papillations vary from two cells to several cells thick as the papillations become bulbous at the tip (Fig 4). The nuclei of the epithelial cells are uniform in size, oval to round, and have a thin rim, densely staining around the nuclear membrane, and often a prominent small eosinophilic or basophilic nucleolus (Fig 5). The cytoplasm of the cells is homogeneous and slightly eosinophilic. Mitotic figures are infrequent or absent.

The general outline of the lesion may either be circumscribed or have infiltrative margins. In one of the 14 cases the tumor infiltrated into the subcutaneous fat. The neoplasm has its own distinctive stroma replacing the normal pattern of dermal collagen. Some ducts are surrounded by a concentric arrangement of cellular fibrous tissue with fibrillar basophilic or amphophilic cytoplasm that often contains scattered lymphocytes. Other ducts are surrounded by dense sclerotic concentrically arranged hypocellular connective tissue. In the stroma investing some of the ducts are ill-defined small elongate cells suggesting myoepithelial cells. Large lymphocytic aggregates may be present in the fibrous stroma, and in two instances lymphoid follicles with reactive centers were noted. Epidermal ulceration and invasion of vascular or perineural spaces were absent. No tumors showed apocrine change, squamous differentiation, or clear cell areas.

Histochemical Findings

Tissue was available for preparation of special histochemical stains in seven of the 14 cases. The PAS stain, with and without prior diastase digestion, was done for the identification of glycogen and neutral mucosubstances. For identification of acid mucopolysaccharides, the Mowry modification of the Hale colloidal iron stain, with and without prior digestion by hyaluronidase, and the aldehyde-fuchsin stain at pH 1.0 and 1.7 were carried out.

Diastase-labile, PAS-positive granules interpreted as glycogen were present in the cytoplasm of epithelial cells lining the duct-like structures. In all seven examples, acid mucopolysaccharide was present along the luminal margins of the epithelial cells lining the ducts and within the ducts. This material stained with PAS after diastase digestion and with colloidal iron with and without hyaluronidase digestion. It did not stain with the aldehyde-fuchsin technique at either pH 1.0 or pH 1.7.

COMMENT

This peculiar tumor has not been previously recognized as a distinct category of sweat gland neoplasm. In four of our cases the contributor was concerned about malignant potential, and in one of these both the contributor and the AFIP consultant favored the diagnosis of sweat gland carcinoma. As yet the lesions on clinicopathologic correlation have not shown malignant potential. The lesion is uncommon. No similar cases were found in published reviews of sweat gland carcinoma.[2-8]

Surgical excision with assurance of complete removal by histologic examination of the surgical margins is considered the treatment of choice. The lesion is considered benign on the basis of available follow-up information.

References

1. Luna LG (ed): *Manual of Histologic Staining Methods of the Armed Forces Institute of Pathology*, ed 3. New York, McGraw-Hill Book Co Inc, 1968.
2. Gates O, Warren S, Warvi N: Tumors of sweat glands. *Am J Pathol* 19:591-631, 1943.
3. Keasbey LE, Hadley CG: Clear cell hidradenoma. *Cancer* 7:934-951, 1954.
4. Miller WL: Sweat gland carcinoma. *Am J Clin Pathol* 47:767-780, 1967.
5. Stout AP, Cooley SGE: Carcinoma of sweat glands. *Cancer* 4:521, 1951.
6. Berg JW, McDivitt RW: Pathology of sweat gland carcinoma, in *Pathology Annual*. New York, Appleton-Century-Crofts, 1968, vol 3, pp 123-144.
7. Mendoza S, Helwig EB: Mucinous (adenocystic) carcinoma of the skin. *Arch Dermatol* 103:68-78, 1971.
8. Helwig EB: Benign tumors of the sweat glands, in Helwig EB, Mostofi FK (eds): *The Skin*, International Academy of Pathology Monograph No. 10. Baltimore, Williams & Wilkins Co, chap 24, pp 455-475, 1971.

Betamethasone Valerate Ointment Compared With Fluocinonide FAPG

Use in the Treatment of Psoriasis and Eczema

Dowling D. Munro, MD, FRCP; Trevor W. E. Robinson, MB, FRCP; Anthony W. P. du Vivier, MRCP; Dorothy M. France, MB, MRCP; Roger Clayton, MB, MRCP; Christopher G. Sparkes, PhD

• Betamethasone 0.1% as valerate in an ointment base and fluocinonide 0.05% in a fatty alcohol propylene glycol (FAPG) base have been compared in a double-blind trial of 76 patients with either eczema or psoriasis. The results show betamethasone valerate ointment to be significantly ($P < .05$) superior to fluocinonide FAPG in the treatment of both these skin conditions. In the light of publications from other studies on betamethasone valerate cream this trial indicates that the ointment base considerably increases the efficacy of betamethasone valerate.

(*Arch Dermatol* 113:599-601, 1977)

The intrinsic topical activity of corticosteroids, as predicted by the vasoconstrictor assay, and the influence of bases are both recognized as factors that affect the clinical efficacy of formulated preparations. Vasoconstrictor assays using alcoholic solutions of fluocinonide and betamethasone valerate have shown fluocinonide to be the more active.[1,2] Similar tests comparing fluocinonide in a fatty alcohol propylene glycol (FAPG) base with betamethasone valerate cream have shown fluocinonide FAPG to be marginally superior.[3] Some previous clinical trials, in which occlusive dressings were not used, have shown fluocinonide FAPG to be superior to betamethasone valerate cream in eczema[4-7] and in psoriasis.[4-6,8,9] Other trials have shown no difference between fluocinonide FAPG and betamethasone valerate formulated in a cream in eczema[5,10] or in psoriasis,[7,10] and one trial has shown a tendency for betamethasone valerate cream to be superior to fluocinonide FAPG in eczema.[11] Thus, although in some trials the number of patients studied was small and in some the results not statistically significant, it does appear that clinical experience parallels the results of the vasoconstriction tests in which the vehicle for betamethasone valerate is a cream.

Vasoconstriction tests comparing fluocinonide FAPG and betamethasone valerate in its ointment base have again shown fluocinonide FAPG to give marginally greater vasoconstriction values than betamethasone valerate ointment.[3] A similar comparison of betamethasone valerate cream with betamethasone ointment has shown the ointment to be superior to the cream.[12] The following report is the first comparing fluocinonide FAPG and betamethasone valerate ointment in the treatment of eczema and psoriasis.

METHODS

The severity of the cases reported represent those patients in the moderate to severe end of the disease spectrum for eczema and psoriasis who have failed to respond to general practitioner care and required hospital referral. Outpatients with clinically similar bilateral lesions were studied. The preparations were allocated at random to left or right sides and the identical looking tubes were labeled accordingly. Neither the clinician nor the patient was aware of their distribution. Patients were asked to treat their lesions twice daily. Assessment of the response was made at, or as near as possible to, seven days after the start of the trial and in all cases before 14 days. At each visit the following features of the lesions were assessed; erythema, scaling, induration, and exudation. An overall assessment of the relative improvment in these modalities was considered in making the final assessment; healed, improved, static, or worse. In similar previous trials this has been shown to give as good results as a more detailed way of recording the symptoms. In addition the clinician and patient were asked to record whether the response had been better on one side or the other or if no difference was detectable. It was recognized that the two bases were of a very different nature and were any to be left on the skin at the time of assessment such residues could give the clinician a clue as to the identity of the materials. To overcome this unlikely event patients were instructed not to apply the preparations on the day they visited their doctor. Clinicians were also asked to make their assessment before the patient had made any comments about the treatment.

As each patient completed the trial the observations were decoded by an independent observer. Preferences in favor of one or other preparation were plotted on a sequential analysis design[13] as they were decoded, thus permitting the trial to be stopped after treating the minimum number of patients. The boundary line was set to indicate a significance of 0.05%. Results showing that there had been an equal response to both preparations were defined as tied pairs and were not plotted.

The preparations used in this study were those commercially available in the United Kingdom, namely, fluocinonide 0.05% (Metosyn [England]; Lidex, comparable US product) and betamethasone valerate 0.1%

Accepted for publication April 21, 1976.

From St Bartholomew's Hospital (Dr Munro); University College Hospital (Drs Robinson and France); St Mary's Hospital (Drs du Vivier and Clayton), London; and the Clinical Research Unit, Glaxo Laboratories Ltd, Greenford, England (Dr Sparkes). Dr France is now with the Crawley Hospital, Crawley, Sussex, England.

Reprint requests to Medical Department, Glaxo Laboratories Ltd, Greenford, Middlesex, England (Dr Sparkes).

(Betnovate [England]; Valisone, comparable US product). There is no substantial difference between Metosyn and Lidex, but in 1973 Betnovate ointment base was changed, with 10% hydrogenated lanolin being replaced by 5% propylene glycol and it thus differs from Valisone ointment in this respect. The "new" and "old" Betnovate ointment bases have been compared in a trial similar to that described here and although the new formulation was more frequently chosen, the difference was not significant statistically.[14]

RESULTS

Seventy-six patients were included in the trial; the diagnosis and response to treatment is shown in Tables 1 and 2 and the Figure. The original protocol was for treatment with or without polythene occlusion, whichever was indicated on clinical grounds. However, as the trial continued it became clear that the occlusion was tending to obliterate differences between the two test substances, eg, in psoriasis of 14 patients without occlusion 11 showed a preference whereas of 15 patients with occlusion only 7 showed a preference. Therefore the nonocclusive cases were considered to reflect differences more accurately and this has been confirmed in other studies.[15] As a consequence only those patients treated without occlusion have been plotted sequentially. Also only those preferences recorded by the clinician have been plotted though these happened to coincide very closely with the patient preferences (see Table).

There were significantly (P .05) more preferences for betamethasone valerate ointment than there were for fluocinonide FAPG, in both eczema and psoriasis, and this level of significance was achieved in psoriasis with only half the number of patients required in the eczema study. This was mainly due to the fact that there were only 3 tied pairs in the psoriasis section and 13 in the eczema group.

In the majority of cases both sides were recorded as healed or improved. However one patient with psoriasis was improved after one week and was worse after two weeks on both sides and another, also with psoriasis, remained static on both sides for two weeks in spite of having polythene occlusion on both sides for the second week. All patients were asked if they experienced any sensation on application of the preparations. Twenty-four patients reported stinging or burning when applying fluocinonide FAPG and eight had similar symptoms with the betamethasone valerate ointment.

Numbers of Preferences* for Betamethasone Valerate and Fluocinonide

	Betamethasone Valerate	Fluocinonide	Equal	Total
	Without Occlusive Dressing			
Eczema	16 (16)	4 (5)	13 (12)	**33 (33)**
Psoriasis	10 (8)	1 (1)	3 (5)	**14 (14)**
	With Occlusive Dressing			
Eczema	2	3	9	**14**
Psoriasis	6	1	8	**15**

*Patient preference figures within parentheses.

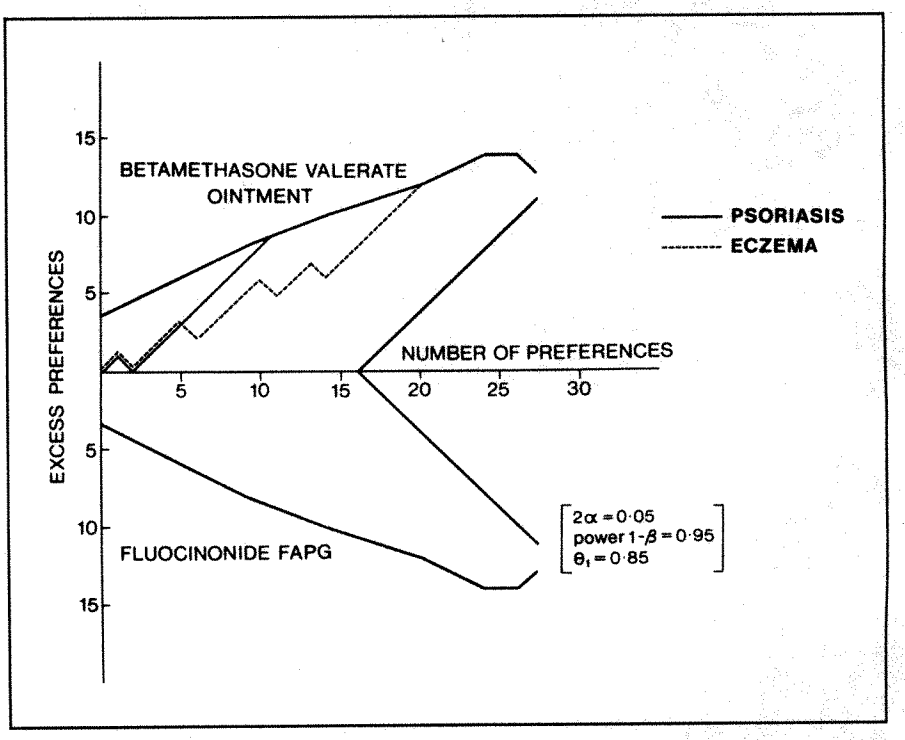

Restricted sequential design that compares clinician's preference for one or another preparation.

COMMENT

In double-blind clinical trials improvement may be assessed either over a fixed period or until healing occurs. Clearly the two systems each have their advantages and in the present investigation a fixed period was used as this had been shown in other trials[15,16] to give good results while not increasing the duration and labor for the physician and patient, of the longer assessment period.

It has been shown that the use of propylene glycol in vehicles as a solvent for corticosteroids increases their activity both clinically and in vasoconstrictor tests, provided it is not present in excess of the optimal concentration.[17-19] Poulsen et al,[20] using fluocinolone acetonide and fluocinolone acetonide acetate (fluocinonide), have shown that maximal release for a given concentration of steroid is obtained from vehicles containing approximately the minimum amount of propylene glycol necessary to dissolve the steroid completely. They also observed that a base that is optimal for one corticosteroid is not necessarily suitable for another. Both fluocinonide in the FAPG base[21]

and betamethasone valerate in its ointment base[11] are in solution in propylene glycol. However, betamethasone valerate in its cream base is not in solution but is dispersed in microcrystalline form.[22] Thus it is not surprising that maximal activity of betamethasone valerate in vasoconstriction tests is seen in the ointment base.

Although the differences between the three preparations was very small, fluocinonide FAPG has been shown to cause more vasoconstriction than either of the betamethasone valerate preparations.[3] From this it might have been predicted that fluocinonide FAPG would prove to be clinically superior to both betamethasone valerate cream and ointment. Previous clinical studies have shown this to be true for the cream, but this trial points to the clinical superiority of betamethasone valerate ointment over fluocinonide FAPG. Thus the ointment base of betamethasone valerate would appear considerably to increase the activity of the steroid in clinical situations, this effect being particularly evident in the treatment of psoriasis.

Studies on the influence of vehicles on percutaneous absorption have shown that white soft paraffin has a substantial occlusive effect on the stratum corneum.[23] This occlusion leads to increased hydration of the epidermis with increased permeability allowing greater penetration of the corticosteroid. In addition it has been found that occlusion with polyethylene in humans reduces the epidermal hyperproliferation found in psoriatic lesions.[24] Recently Tree and Marks[25] have shown that various bases (without containing any corticosteroid) have an antimitotic effect when applied under occlusive dressings to the backs of mice. They found that white soft paraffin was the most effective of the bases tested and they suggested that the effect may have been due to the greasy nature of the base slowing the rate of desquamation, which in turn might affect cell production. Thus the results seen in the study reported here may also be due in part to an intrinsic effect of the base.

These results possibly signify that the FAPG base lacks the occlusiveness and emolliency of traditional greasy ointments and does not therefore have the properties of both a cream and an ointment as has been claimed previously.[6] The increased irritancy seen with the FAPG base would indicate that lack of patient acceptability might limit its use. Hence, it would seem that manipulation of the physical environment can have a profound effect on the treatment of skin diseases and it may be that the triple effect of optimal solubility of the steroid and the use of a base that provides both occlusivity and a reduction in mitotic activity are factors necessary to get the maximal effect from a given topically active corticosteroid.

The differences in results between this trial and others suggest the relevancy of further inquiry into the influence of vehicles on the clinical efficacy of topically active steroids.

Nonproprietary Names and Trademarks of Drugs

Betamethasone valerate—*Valisone.*
Fluocinonide—*Lidex, Topsyn.*

References

1. Stoughton RB: Vasoconstrictor activity and percutaneous absorption of glucocorticosteroids: A direct comparison. *Arch Dermatol* 99:753-756, 1969.
2. Place VA, Velazquez JG, Burdick EH: Precise evaluation of topically applied corticosteroid potency. *Arch Dermatol* 101:531-537, 1970.
3. Coldman MF, Lockerbie L, Laws EA: The evaluation of a novel corticosteroid formulation fluocinonide in "FAPG" base in the blanching test. *Br J Dermatol* 85:573-576, 1971.
4. Binder R, McLeary J: Comparison of fluocinonide in a double blind study with bethamethasone valerate. *Curr Ther Res* 14:35-38, 1972.
5. Mendelson CG: Fluocinonide: A new topical corticosteroid. *Acta Derm Venerol* 67 (suppl): 63-65, 1972.
6. Portnoy B, Sarkany I: "Metosyn" in psoriasis and eczema. *Br J Dermatol* 86:310-311, 1972.
7. Cunliffe WJ, Nicholls JT: A comparison of Metosyn and Betnovate in the treatment of eczema and psoriasis. *J Int Med Res* 2:71-75, 1974.
8. Meenan FOC: Metosyn: A new steroid for topical use. *J Ir Med Assoc* 65:89-90, 1972.
9. O'Quinn SE: Cooperative study of fluocinonide (Lidex) 0.05% cream versus bethamethasone valerate (Valisone) 0.1% cream in the treatment of psoriasis. *Acta Derm Venerol* 67 (suppl):66, 1972.
10. Neumann L: Efficacy of two fluorinated topical steroids in the treatment of common eczemas, on a once a day treatment schedule. *Acta Derm Venerol* 67 (suppl):74-76, 1972.
11. Sarkany I: Comparative double-blind clinical trial of fluocinonide and betamethasone valerate. *Acta Derm Venerol* 67 (suppl):70-71, 1972.
12. Coldman MF, Lockerbie L, Laws EA: The evaluation of several topical corticosteroid preparations in the blanching test. *Br J Dermatol* 85:381-387, 1971.
13. Armitage P: *Sequential Medical Trials.* Oxford, England, Blackwell Scientific Publications, 1960.
14. Wilson L: Betamethasone-17-valerate ointment in a lanolin-free base. *Curr Med Res Opin* 1:228-232, 1973.
15. Wilson L: The clinical assessment of topical corticosteroid activity. *Br J Dermatol* 94 (suppl 12):33-42, 1976.
16. Munro DD, Wilson HTH, Rhodes EL: Comparison of betamethasone 17-valerate ointment with fluocortolone and fluocortolone caproate ointment. *Br Med J* 4:275-276, 1967.
17. Barrett CW: Skin penetration. *J Soc Cosmetic Chemists* 20:487-499, 1969.
18. Burdick KH, Poulsen BJ, Place VA: Extemporaneous formulation of corticosteroids for topical usage. *JAMA* 211:462-466, 1970.
19. Ostrenga J, Haleblain J, Poulsen B, et al: Vehicle design for a new topical steroid fluocinonide. *J Invest Dermatol* 56:392-399, 1971.
20. Poulsen BJ, Young E, Coquilla V, et al: Effect of topical vehicle composition on the in vitro release of fluocinolone acetonide and its acetate ester. *J Pharm Sci* 57:928-933, 1968.
21. Brogden RN, Speight TM, Avery GS: Fluocinonide in its FAPG base: A review of its therapeutic efficacy in inflammatory dermatoses. *Drugs* 7:337-343, 1974.
22. *British Pharmaceutical Codex, 1973.* The Pharmaceutical Society of Great Britain, p 656.
23. Baker H: Experimental studies on the influence of vehicles on percutaneous absorption. *J Soc of Cosmetic Chemists* 20:239-252, 1969.
24. Baxter DL, Stoughton RB: Mitotic index of psoriatic lesions treated with Antralin, glucocorticosteroid and occlusion only. *J Invest Dermatol* 54:410-412, 1970.
25. Tree S, Marks R: An explanation for the "placebo" effect of bland ointment bases. *Br J Dermatol* 92:195-198, 1975.

A Cutaneous Marker in the Hunter Syndrome

A Report of Four Cases

Stephen D. Prystowsky, MD; Irene H. Maumenee, MD;
Robert G. Freeman, MD; James H. Herndon, Jr, MD; Mary Jo Harrod, PhD

• A report of four patients and review of the literature suggest that a cutaneous marker exists for the Hunter syndrome. All previously described patients with this eruption have been males with clear corneas. The distinctive lesions consist of firm ivory-white papules and nodules that may coalesce to form ridges or a reticular pattern. The papules are usually seen in symmetrical areas between the angles of the scapulas and posterior axillary lines, the pectoral regions, the nape of the neck and/or on the lateral aspects of the upper arms and thighs. These lesions are seen in both allelic forms and cannot be used to separate a benign from a rapid course.

(*Arch Dermatol* 113:602-605, 1977)

In 1917 Hunter[1] first described the syndrome that was to bear his name when he described two brothers with severe shortness of stature, stiff joints, claw-like hands, deafness, hepatosplenomegaly, cardiomegaly, unusual facies, and a peculiar nodular skin lesion over the scapulas. Patients with similar findings but with additional features of pronounced dwarfism, corneal clouding, gibbus, and mental retardation were described in 1919 by Hurler on the suggestion of Dr. Pfaundler[2]; no skin lesions were noted. Additional disorders with similar phenotypes were added by other authors.[3]

In 1946 Nja[4] recognized that certain families with gargoylism could be distinguished. An X-linked form of inheritance was inferred from reports of families in which all affected members were males. No corneal clouding occurred in these patients. Other forms of gargoylism occurred in siblings of both sexes in equal proportions, did not occur in successive generations, and occurred more frequently to consanguineous unions, suggestive of an autosomal recessive mode of inheritance. McKusick introduced the first classification of the mucopolysaccharidoses in 1960.[5] The Hunter syndrome, mucopolysaccharidosis II, is due to a deficiency of sulfoiduronate sulfatase.[6]

However, at least two forms of the Hunter syndrome have been recognized clinically: a severe form with mental retardation and early death and a mild form, in which mental function is normal and which is compatible with survival to adult life. Intermediate forms probably exist. It was the mild form that Hunter originally described. No other clinical differences consistently distinguish the two types; each seems to segregate uniformly in affected families. Biochemical investigation of the two forms has indicated that they lack the same corrective factor. Characterization of this group of degradative enzymes has hardly begun, however, and it seems possible that the two (or more) forms of the disorder may depend upon separate classes of instabilities in the same enzyme molecule or defects in separate isoenzymes with different distributions in tissue. In genetic terms, these possibilities may reflect abnormal genes that behave as alleles at the same locus on the X-chromosome.[7,8]

The purpose of these case reports is to define further the distinctive cutaneous lesion of the Hunter syndrome[9] and to examine previous reports to

Accepted for publication July 20, 1976.

From the Division of Dermatology (Drs Prystowsky and Herndon), Medical Genetics of the Department of Internal Medicine (Dr Harrod), and Department of Pathology (Dr Freeman), University of Texas Southwestern Medical School, Dallas; and the Departments of Medicine and Ophthalmology (Dr Maumenee), Johns Hopkins University School of Medicine and Johns Hopkins Hospital, Baltimore. Dr Prystowsky is now with the Letterman Army Institute of Research, San Francisco.

Reprint requests to Division of Dermatology, University of Texas Southwestern Medical School, 5323 Harry Hines Blvd, Dallas, TX 75235 (Dr Herndon).

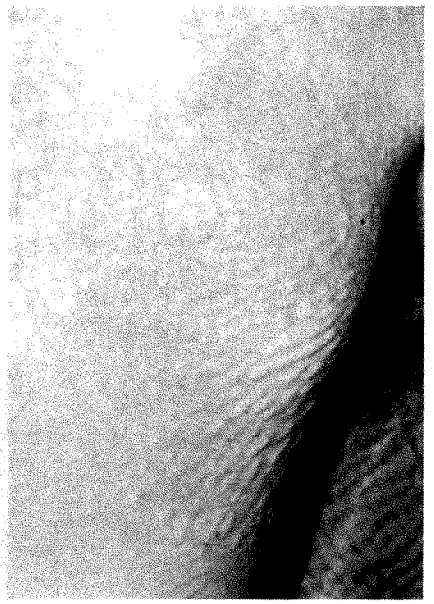

Fig 1.—Characteristic nodules of Hunter syndrome are forming ridges in reticular pattern over scapula and posterior axillary line (case 1).

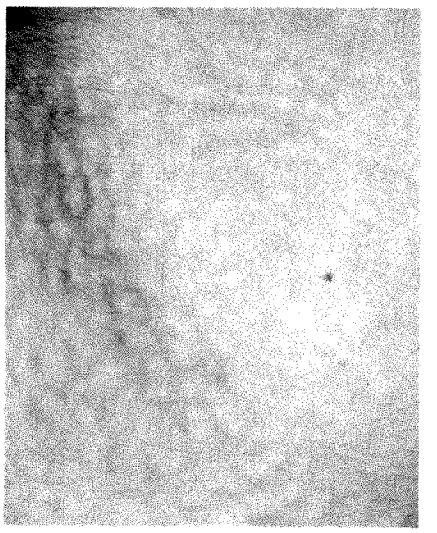

Fig 2.—Diagnostic papules and nodules are seen in scapular region (case 1).

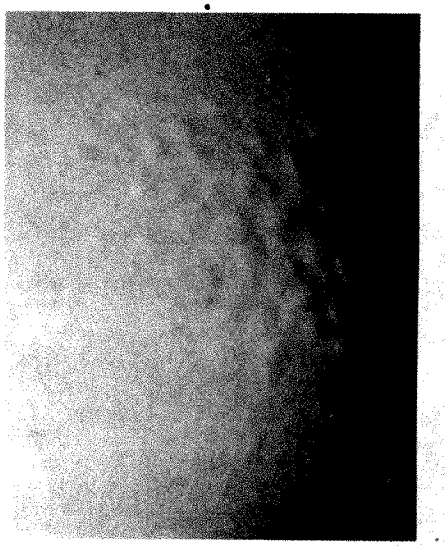

Fig 3.—Cutaneous pebbling in pectoral region (case 1).

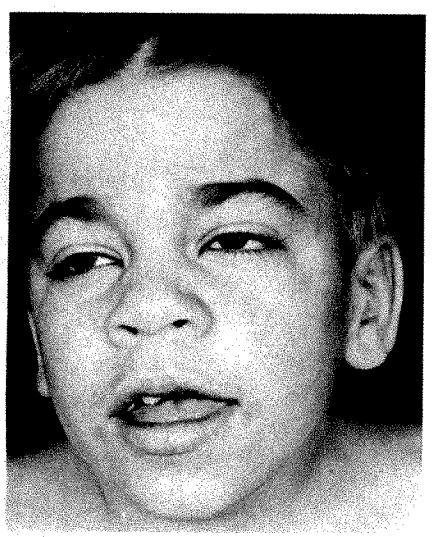

Fig 4.—Coarse facial features (case 3).

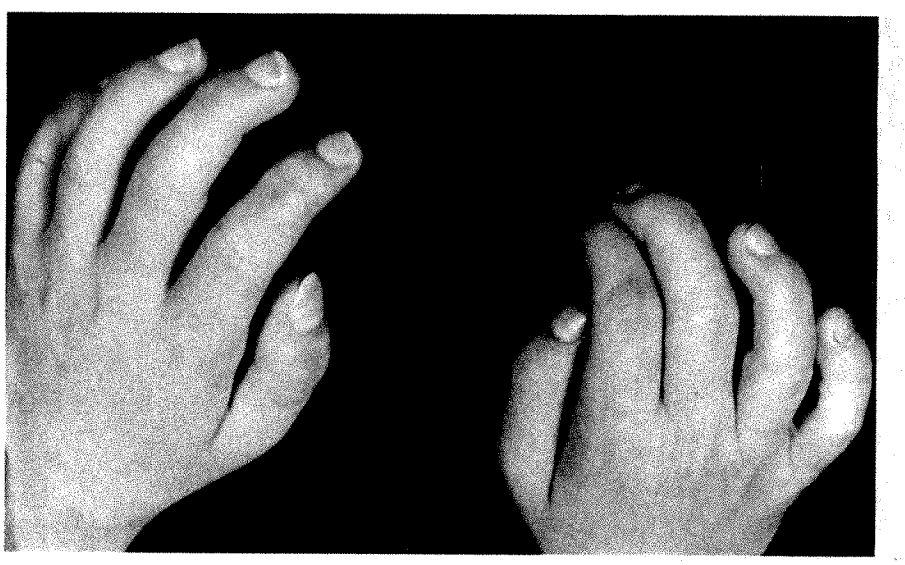

Fig 5.—Claw-like contracture of hand (case 3).

document the specific character of this finding.

REPORT OF CASES

CASE 1.—An 8-year-old white boy was the product of a normal pregnancy and delivery. Psychometric evaluation placed his developmental age at 2 years. He had severe physical and mental retardation and frequent upper respiratory infections. The cause of his retardation had not been established until characteristic dermal nodules and ridges were noted by a consultant dermatologist. A family history disclosed none of 43 close relatives affected.

Firm, ivory-white, 2- to 10-mm papules and nodules, which coalesced to form ridges in a reticular pattern, were seen in symmetrical areas between the angles of the scapulas and posterior axillary lines (Fig 1 and 2). Similar lesions were present on the upper arms, lateral aspects of the thighs, and pectoral regions. The lesions first appeared on the arms and back prior to age 1. Lesions appeared in the pectoral region at age 6 (Fig 3). The nodules have enlarged with age and none have disappeared. Additional pertinent physical findings included generalized downy hypertrichosis, broad hands with stubby fingers resulting in a claw-like contracture of the hands, coarse facial features, hepatosplenomegaly, stiff joints, and clear corneas. Hearing difficulty has recently been noted.

A karyotype showed the chromosome complement of a normal male (46, XY). The urinary glucosaminoglycan levels were elevated to 14 mg/100 ml. Roentgenograms showed broad ribs, short clavicles, no lumbar gibbus, a mild flexion deformity of the fingers, thickened calvaria, rounded scapulae, and proximal tapering of the metacarpal bones characteristic of the Hunter syndrome.

Histopathology of the papules revealed foci of irregularly organized collagen bundles separated by interfibriller material. Sections stained with toluidine blue contained deposits of metachromatic material. The epidermis and appendages ap-

UNIVERSITY COLLEGE OF MEDICINE LIBRARY

Reported Cases With Characteristic Lesions of Hunter Syndrome						
References	No. of Cases	Sex	Cornea	Pertinent Family History	Age of Onset, yr	Allelic Variant
Hunter[1]	1	M	Not mentioned	One older affected male sibling without nodular eruption.	Present at age 8	Mild
Cole et al[10]	2	M	Clear in both	Uncle and nephew both have skin lesions	1; under 1; disappeared at 12	Both mild
Anderson & Tandberg[11]*	1	M	Clear	Lesions not reported in pedigree with five other affected male members	Present at age 6½	Severe
Levin[12]	2	M	Clear in both	"Seven relatives on the maternal side had died early in life with signs and symptoms suggestive of gargoylism"	3 4	One mild One severe
Society transactions[13]	1	M	Clear	Four normal sisters	5½	Mild
Thurmon et al[14]†	1	M	Not mentioned	Lesions not present in pedigree with six other affected male members "within family heterogeneity"	Present at age 11	Mild
Ghatia & Blum[15]	1	M	Not mentioned	None given	8	Unknown
Prystowsky et al						
Case 1		M	Clear	None of 43 close relatives affected	Under 1	Severe
Case 2		M	Clear	Two affected brothers, not known if lesions were present	Present at age 6	Severe
Case 3		M	Clear	One normal sister	5	Severe
Case 4		M	Clear	Three normal sisters	7; disappeared at 8	Intermediate

*Same family as described by Nja.[4]
†Same family as described by McKusick.[8]

peared normal.

CASE 2.—A 6-year-old white boy is the third child in the family to have Hunter syndrome. Two older brothers were affected and died at 7 and 12 years, respectively. Shortly after birth, the parents noted that the patient was "blockier" than other babies. He has severe mental and physical retardation.

Pale, 3- to 4-mm papules and nodules are present in symmetrical areas on the upper pectoral regions and scapular areas. The corneas are clear. Other pertinent physical findings include short stature, coarse facies, large head, saddle-shaped nose, thick lips, large tongue, deformed teeth, hepatomegaly, and hirsutism.

Severely elevated glucosaminoglycan levels were present in the patient's blood and urine samples. The pathologic findings were identical to those of case 1, and are being reported separately.

CASE 3.—A 13-year-old white boy with the Hunter syndrome was first referred at age 10 years with the diagnosis of Sanfilippo syndrome. He was a big baby at birth, and grew rapidly in the first years. He did develop an umbilical hernia during his first year of life. His early development measurements were reached within the normal limits. He developed speech normally and, by age 4 years, entered nursery school. At the end of that school year, the mother was told that the boy was somewhat slow and clumsy. Examination of the skin at age 5 years showed pebbling over both pectoral and scapular areas and over the thighs. There were flexion contractions over many joints. The liver was about 5 cm below the right costal margin and the spleen about 2.5 to 3 cm below the left costal margin. He still appeared of normal intelligence and was active and cooperative. The diagnosis of "mild Hurler disease" was made. A year later an IQ of 62 was established. His general features and the organomegaly became more prominent. At a slow rate, he acquired new skills until 1970, when he started regressing. In 1971 he had lost almost all of his vocabulary; also, at about that age he stopped growing. He has one normal sister.

On physical examination at age 10 years, he had coarse facial features (Fig 4), clear corneas, thickened earlobes, hepatosplenomegaly, and umbilical hernia, as well as joint limitations involving primarily the upper extremities (Fig 5). On dermatologic examination he was mildly hirsute over his trunk and extremities. His scalp hair and eyebrows were coarse. He had skin pebbling over the nape of the neck, the scapular areas bilaterally, and the pectoralis muscles. In 1972 he was given a trial of plasma infusions for one year; there was no improvement except for substantial diminution of the cutaneous lesions. The lesions were still present in January 1975. Iduronide sulfate sulfatase deficiency had been documented in this boy.

CASE 4.—An 8-year-old white boy was above the 97th percentile for height and weight until age 2½. His early development measurements were delayed. He was hyperactive and had frequent respiratory infections and asthmatic episodes during the first years. He has three normal sisters.

On physical examination at age 2½ years, he was mildly hirsute over his back and extremities. His scalp hair was sparse but coarse. He did not have the characteristic pebbles over the chest and back. The child continued to be followed up in the Moore Clinic, and from age 5 to 7 years was infused with plasma without significant sustained improvement. In 1974 he developed for the first time the characteristic skin pebbles over his scapula area only. On re-evaluation in 1975, the classical features of the Hunter syndrome progressed. However, he continued to have an IQ of 80, the level of low normal intelligence. Iduronide sulfate sulfatase deficiency, diagnostic for the Hunter syndrome, was found. The skin lesions had spontaneously improved during the previous year and were barely detectable in May 1975.

COMMENT

The Table provides details of our and the previously reported cases with the characteristic cutaneous lesions of the Hunter syndrome. Nine patients

had lesions whose descriptions closely resemble those of the present cases. From these descriptions one can draw a picture of the distinctive lesions of the Hunter syndrome: they consist of firm, flesh-colored to ivory-white papules and nodules that often coalesce to form ridges or a reticular pattern and occur in symmetrical areas between the angles of the scapulas and posterior axillary lines, the pectoral regions, the nape of the neck and/or the lateral aspects of the upper arms and thighs. They appear before age 10, and can spontaneously disappear. Reference to previous reports[1,10-15] and to experience of clinical geneticists[6] suggests that this eruption is probably pathognomonic for the Hunter syndrome. The available data show the following: (1) all reported cases with this lesion were in males; (2) all such patients had clear corneas; and (3) all affected siblings of index cases were male. Since the Hunter syndrome is the only X-linked mucopolysaccharidosis recognized so far, and nearly all patients with the otherwise similar but autosomally transmitted Hurler syndrome have cloudy corneas, the exclusively male occurrence of the characteristic skin lesion and its uniform accompaniment of clear corneas strongly supports our contention that the eruption indicates a diagnosis of the Hunter syndrome. The Sanfilippo syndrome is the only other mucopolysaccharidosis in which there is a clear cornea. The best way to provide conclusive proof for the association would be to assay for the specific enzyme deficiency in all cases. These tests are available only at a few research centers. Moreover, most authorities agree that neither total nor fractionated urinary mucopolysaccharide determinations can differentiate the Hurler syndrome from the Hunter syndrome: chondroitin sulfate B (dermatan sulfate) and heparitin (heparin) sulfate are excreted excessively in both.[8] In short, recognition of the cutaneous marker (when present) may be helpful in making a diagnosis with important implications for the patient's future development, as well as for genetic counseling of the family. We interpret the concordance in 13 reports (including the present 4) as adequate indirect evidence for the association with the Hunter syndrome.

McKusick has recently reclassified the genetic mycopolysaccharidoses,[8] taking into account the two presumably allelic forms of the Hunter syndrome. Unfortunately, the cutaneous lesions of the Hunter syndrome are seen in both allelic forms and cannot be used to differentiate a benign from a rapid course. Review of the cases shown in the Table demonstrate that six patients had the benign form, five had the severe form, one had an intermediate form, and in one previous report the data were insufficient to determine the allelic type.

Although the cutaneous abnormality discussed is a reliable marker, the majority of cases reported with the Hunter syndrome do not mention this finding. A review of recent cases followed up at the Johns Hopkins Hospital showed that only 2 of 11 patients with the Hunter syndrome, ranging in age from 18 months to 31 years, had the cutaneous marker.

Only one of four pedigrees with more than one affected member reported skin lesions in more than one patient. This variability of expression suggests that unknown secondary factors affect the appearance of the cutaneous marker. It is also unknown why no patients with any of the other mucopolysaccharidoses have a similar eruption.

This study was supported in part by grants 5 P01 GM 19489, 5 T01 GM 00795, and 1 M01 RR00722 from the National Institutes of Health; grant CRBS-322 from the National Foundation–March of Dimes; by the Bob Hope Fight for Sight grant, Fight for Sight, Inc, New York City; and a grant from the Syntex Corp, Palo Alto, Calif. Dr Maumenee is supported by Research Career Development award GM 70124 from the National Institutes of Health.

Victor A. McKusick, MD, made helpful suggestions during the preparation of the manuscript.

References

1. Hunter C: A rare disease in two brothers. *Proc R Soc Med* 10:104-116, 1917.
2. Hurler G: Ueber einen Typ multipler Abartungen, vorwiegend am Skelettsystem. *Z Kinderheilkd* 24:220, 1919.
3. McKusick VA: The nosology of the mucopolysaccharidoses. *Am J Med* 47:730-747, 1969.
4. Nja A: A sex-linked type of gargoylism. *Acta Paediatr* 33:267-286, 1946.
5. McKusick VA: *Hunter's Syndrome, Heritable Disorders of Connective Tissue*, ed 2. St Louis, CV Mosby Co, 1960, p 271.
6. Bach S, Eisenberg F, Cantz M, et al: The defect in the Hunter syndrome: Deficiency of sulfoiduronate sulfatase. *Proc Natl Acad Sci* 70:2134-2138, 1973.
7. Lichtenstein JR, Bilbrey GL, McKusick VA: Clinical and probably genetic heterogeneity within mucopolysaccharidosis: II. Report of a family with a mild form. *Johns Hopkins Med J* 131:425-435, 1972.
8. McKusick VA: *The Mucopolysaccharidoses, Heritable Disorders of Connective Tissue*, ed 4. St Louis, CV Mosby Co, 1972, pp 521-686.
9. McKusick VA: Heritable disorders of connective tissue with skin changes, in Fitzpatrick TB, Arndt KA, Clark WH, et al (eds): *Dermatology in General Medicine*, ed 1. New York, McGraw Hill Book Co Inc, 1971, p 1226.
10. Cole HN, Irving RC, Lund HZ, et al: Gargoylism with cutaneous manifestations. *Arch Dermatol* 66:371-383, 1952.
11. Anderson B, Tandberg O: Lipochondrodystrophy (gargoylism, Hurler's syndrome) with specific cutaneous deposits. *Acta Paediatr* 41:161-167, 1952.
12. Levin S: A specific skin lesion in gargoylism. *Am J Dis Child* 99:444-450, 1960.
13. Mucopolysaccharidosis II (Hunter's syndrome): transactions of the Minnesota Dermatological Society (Sept 7, 1969). *Arch Dermatol* 102:578-580, 1970.
14. Thurmon TF, DeFraites EB, Anderson AA: Clinical heterogeneity in mucopolysaccharidoses: II. Evidence for epistasis: *Birth Defects* 10:125-127, 1974.
15. Ghatia SG, Blum J: Hunter syndrome: Transactions of the Michigan Dermatological Society (Feb 14, 1973). *Arch Dermatol* 109:749-750, 1974.

Psychogenic Purpura

William W. Stocker, MD; O. Ross McIntyre, MD; William E. Clendenning, MD

• Two young women had painful ecchymoses of their extremities. In one, this purpuric syndrome followed a chronic course and resulted in severe joint disability. In the other woman, the problem was transient and relatively benign. Emotional factors in their disease were of major importance. No abnormalities of hemostasis or immune function were found. These cases demonstrate the many problems encountered in the diagnosis and management of such patients.
(*Arch Dermatol* 113:606-609, 1977)

Hemorrhage into the skin leading to painful ecchymoses and disability is a well-recognized syndrome that occurs predominantly in women. Three different proposed mechanisms have been emphasized by the names suggested for this syndrome: autoerythrocyte sensitization,[1] psychogenic purpura,[2-4] and factitial purpura.[5,6]

In 1955 Gardner and Diamond[1] reported a painful bleeding syndrome in four women in whom no coagulopathy could be found. They demonstrated skin reactions to the patients' own erythrocytes and postulated an autoimmune mechanism whereby trauma (either accidental or surgical) leads to sensitization to erythrocytes. Then subsequent minimal daily trauma was thought to result in an allergic reaction to extravasated RBCs. This led to the designation "autoerythrocyte sensitization" syndrome.

The second major idea regarding these patients is that psychogenic factors are paramount in the pathogenesis. Ratnoff and Agle[2] and Agle et al[3] did extensive studies on 28 women with this syndrome. They proposed that the hemorrhage into the skin represents a conversion symptom that results from emotional stress in women who have strong masochistic and hysterical character traits. They postulated that the conversion reaction might be mediated through the kinin system and suggested that the syndrome be called "psychogenic purpura."[4]

Self-infliction of the purpuric lesions is the third mechanism that has been discussed in the literature. Cases similar to those reported earlier have been proved to be factitial.[5,6] The similar personalities of these patients and patients with factitial diseases indirectly support this mechanism.[7] "Factitial purpura" is the term used to describe these patients.

Scattered reports of abnormalities in platelet function have been reported.[8] However, in the vast majority of these patients, most of whom have been extensively studied, no abnormalities of hemostasis or immune function have been demonstrated.

The purpose of this article is to review this complex entity and to present the case reports of two disturbed women who had similar initial complaints but whose illnesses differed greatly in duration and in morbidity.

REPORT OF CASES

Case 1.—A 21-year-old woman was first seen at her local hospital in March 1974 for a soft tissue mass over her distal right ulna that had developed from a painful bruise first noted in January 1974. There was a history of striking the area on a car door. The mass was excised and showed benign hypertrophic fibrous tissue. This sequence of events, involving the same area, was repeated in May 1974. The soft tissue mass was reexcised with the same tissue diagnosis.

She was hospitalized for the third time in June 1974 for severe vomiting at which time hysterical behavior was observed. A diagnosis of psychogenic vomiting was made.

During the summer of 1974 the right wrist bruise and swelling recurred again. She was seen at a second hospital in the fall where the mass and the distal head of the right ulna were excised to allow proper movement of the wrist.

She returned to the original hospital in December 1974 with swelling over the left wrist that had developed from a painful, bruised area during the preceding eight weeks. The mass and distal head of the left ulna were excised and a cast was applied.

In January 1975, further bruises of the left knee, left ankle, and right wrist developed. Results from clotting studies were normal. The diagnosis of autoerythrocyte sensitization was considered; skin tests to her own RBCs were negative. She was then referred to our hospital for further evaluation.

Physical Examination and Laboratory

Accepted for publication June 30, 1976.

From the Sections of Dermatology (Drs Stocker and Clendenning) and Hematology (Dr McIntyre), Department of Medicine, Mary Hitchcock Memorial Hospital, Hanover, NH.

Reprint requests to Hitchcock Clinic, Hanover, NH 03755 (Dr Clendenning).

Fig 1.—Painful ecchymosis of left knee in case 1. Hemarthrosis was demonstrated.

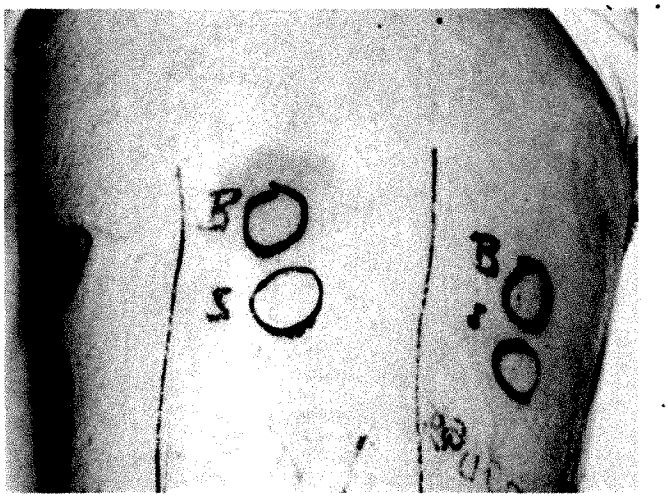

Fig 2.—Case 1: skin test site at 48 hours. B sites were injection sites of blood. S sites were sterile saline injections. Patient thought that only middle B site was her own blood.

Fig 3.—Painful ecchymoses of right upper arm suggesting finger and thumb imprints.

Fig 4.—Case 2: skin test sites immediately after injection of patient's blood.

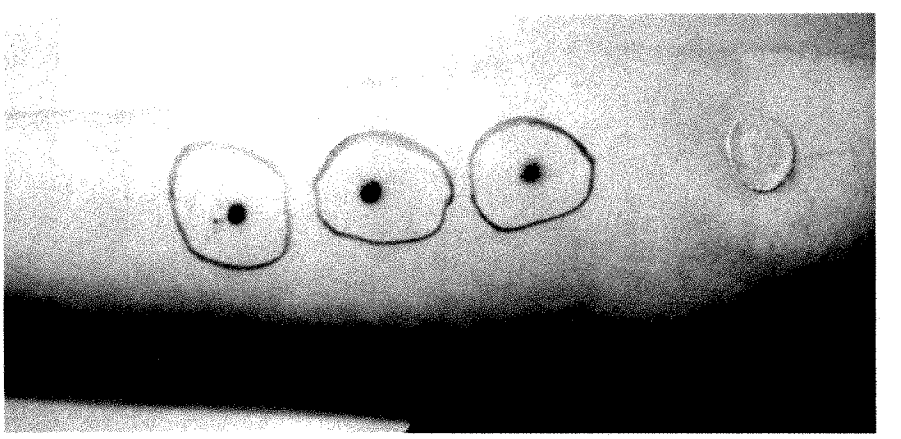

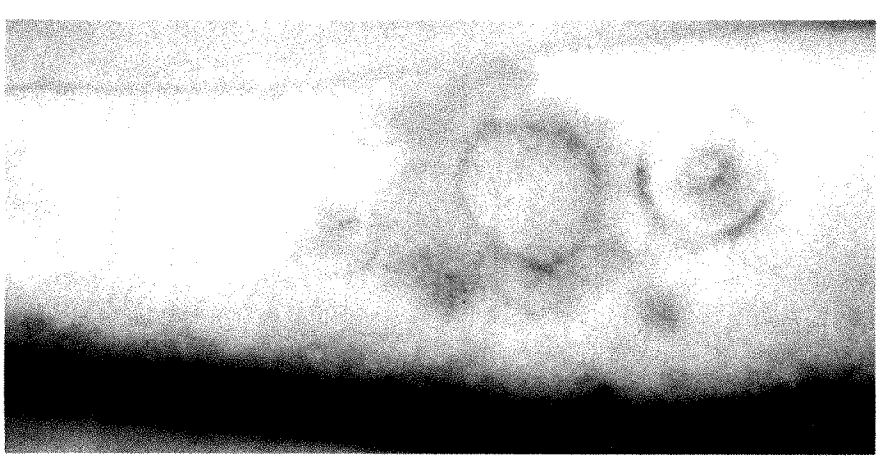

Fig 5.—Case 2: skin test sites at 48 hours showing extensive ecchymosis only of center site.

Studies.—Results of the physical examination were normal except for multiple, painful ecchymoses of the extremities (Fig 1). Results from an extensive clotting and connective tissue workup were normal. For the clotting studies results from the following tests were normal: CBC, platelet count, recalcification time, bleeding time, fibrinogen titer, fibrin split products, thrombin time, special clotting studies—clot retraction, platelet factor 3, platelet aggregation

studies, platelet size, glass-plastic ratio, activated partial thromboplastin time (APTT)-auto APTT, Hyland APTT, factor II, VIII, IX, XI, and XII assays—urea clot solubility, and monochloracetic acid clot solubility. The other tests performed, the results of which were normal, are as follows: protein electrophoresis, antinuclear antibody, rheumatoid factor, antistreptolysin O (titer), VDRL, cold agglutinins, antiglobulin screen, Cl esterase inhibitor, C3 complement, and sedimentation rate.

Skin Test.—Skin tests to her own erythrocytes were performed as will be described. A "positive" test developed as shown in Fig 2. A biopsy specimen from this site revealed only hemorrhage. There was no inflammation or vasculitis.

Hospital Course.—The pain and bleeding around the left knee became more severe to the point where she could not bend it or bear weight. She was taken to the operating room where, under general anesthesia, 5 ml of blood was aspirated from the joint space and the knee was easily manipulated. A long leg cast was applied. She refused inpatient psychiatric care and was discharged.

Subsequently, she had two admissions for bleeding around her left knee and right elbow. After the application of casts, she improved and new lesions did not develop under the cast. When the casts were removed, new lesions developed in the same areas within one to three days. She was able to predict the site and onset of new lesions.

In April 1975, she agreed to admission to the psychiatric unit for evaluation. Her psychiatric history was of importance in several respects. During the past five years, her mother had undergone treatment for laryngeal cancer. Six months before the onset of her symptoms, her brother had been severely beaten by an uncle. Also before the onset she had had morbid nightmares about death and injury to her family. She related the onset of her first bruising as coinciding with the return of her fiancé from Viet Nam. Hysterical symptoms in 1974 had led to neurologic and cardiac evaluation that included coronary arteriograms.

During her psychiatric admission, two additional casts were removed from extremities and no new lesions were seen. The next day after the cast removal a medical student, walking into her room, heard a regular thumping noise from her bathroom over the sound of running water. She was not confronted. The same day pain and swelling developed around her left knee. This progressed to ecchymosis during the next two days. She refused audio or visual monitoring and at her strong demand was discharged and has not returned.

Throughout her course, she showed relative indifference to her serious crippling problems and a martyr-like acceptance of herself as a chronic invalid. She has postponed her wedding date.

CASE 2.—The patient was also a 21-year-old woman who came to the hematology clinic of this medical center in February 1970 complaining of tender bruises of her chin, upper arms, and upper legs of two to three days' duration. Her occupation was as a licensed practical nurse. She was engaged and planning to be married in August 1970. There was a history of a recent nose bleed, but no other hemorrhagic episodes. On examination, some of the ecchymoses were in a pattern that suggested finger marks (Fig 3).

Results of the following laboratory tests were normal: CBC, platelet count, bleeding time, clot retraction, prothrombin time, partial thromboplastin time, thrombin time, and recalcification time.

Skin tests to her erythrocytes were performed (Fig 4) as will be described. A positive skin test developed as shown in Figure 5.

The test and the implication that this was a self-induced problem related to emotional stress was explained to her. She then admitted to being afraid that she was pregnant. She was seen by a psychiatrist as an outpatient in March 1970. The bruising symptoms have not recurred over the subsequent six years.

Her history and present findings are, however, important. At age 12 she had a laparotomy for suspected appendicitis; a normal appendix was found. From 1967 to 1976 she has undergone multiple urologic procedures for evaluation of severe flank pain. She underwent cystoscopy and meatal dilitation several times as a teenager. In 1970 a calcium oxalate stone was passed. Because of her persistent symptoms, but in spite of normal x-ray film studies, she had an extensive metabolic workup that included normal results from a neck exploration for parathyroid adenoma. She continued to complain frequently to several physicians of severe flank pain. Her urologists are convinced that many of her symptoms are hysterical, although she has passed two calcium stones in the past.

She was married in August 1970. She took an overdose of a mixture of propoxyphene hydrochloride, aspirin, phenacetin, and caffeine (Darvon Compound) in November 1970, was admitted to intensive care, and recovered without complications. A history of emotional deprivation as a child has been obtained.

Comparison of Features of Psychogenic Purpura With the Cases Presented

Common Features of Psychogenic Purpura[2]	Case 1	Case 2
Most frequent in women aged 14-40 yr	Yes	Yes
Ecchymoses occur predominantly on the extremities	Yes	Yes
Severe emotional turmoil preceding symptoms	Yes	Yes
Multiple somatic complaints without objective findings	Yes	Yes
Subjective prodrome before new lesions	Yes	Uncertain
History of multiple surgical procedures	Yes	Yes
Hysterical and masochistic character traits	Yes	Yes
Ability to manipulate lesions in some patients under hypnosis[3]	Not tested	Not tested
Variable results of skin tests to patient's RBCs	Yes	Tested only once
A biopsy of lesions shows absent or minimal findings	Yes	Not done

METHODS FOR SKIN TESTS

Before the test was done, the physician explained to the patient that her bleeding problem might be due to a reaction or sensitivity to her own blood. She was told that only the middle of the three test sites was her own blood, and that the other two test sites were cross matched donor blood. She was told that a positive test is the development of a bruise in the center site.

Six milliliters of the patient's blood was drawn into a sterile, heparinized tube. In another room away from the patient, three 0.1-ml aliquots of this blood was drawn into three tuberculin syringes. These 3 aliquots were then injected intradermally into a reachable area (Fig 4). A positive test was the development of a painful ecchymosis during the subsequent 24 to 48 hours in the central site only (Fig 2 and 5).

COMMENT

These cases illustrate many features and questions regarding the entity that is perhaps best designated

as psychogenic purpura. First is the question of autoerythrocyte sensitization. The patient in case 1 showed variable results when tested with her own RBCs. Specifically, the initial tests were negative and the subsequent ones were positive only in areas she was told were her own RBCs. A biopsy specimen from a positive skin test site showed no evidence of a vasculitis or inflammation. Both patients underwent several surgical procedures without hemostasis problems. These features have been emphasized by Ratnoff and Agle[2] in their patients with psychogenic purpura. In case 1 and that of Levin et al's,[6] initial skin tests were negative and later ones were positive. The failure to consistently demonstrate sensitivity to injected RBCs, the absence of inflammation in the skin of test sites, and the ability of these patients to undergo repeated surgery without hemorrhagic or immune castastrophies all suggest that the autoerythrocyte sensitization hypothesis is untenable.

The term psychogenic purpura has been used to imply purpura caused by a true conversion reaction.[2-4] The Table gives many of the common features of these patients and shows that the present cases "fit" this profile quite well, particularly the psychiatric and personality profiles. Levin et al's[6] case report was of a 16-year-old girl with a similar background. Her lesions were proved to be factitial by direct observation. It is reasonable to speculate that the purpura in all of these cases has a similar mechanism, but it is impossible to resolve this hypothesis because of the difficulty in completely disproving factitial causation and proving a mechanism that results from a conversion reaction.

The present case reports show some of the criteria that can be used to help distinguish a factitial mechanism from a conversion reaction. A major factitial component seems reasonably established for the patient in case 1 for the following reasons: (1) new ecchymoses never developed under casts and old ecchymoses resolved under casts; (2) lesions regularly developed on extremities one to three days after the removal of a cast from the extremity; (3) suspicious "banging" noises that were heard in her bathroom were followed by new bruises; and (4) she refused audio or visual monitors in her room. The "finger" pattern of the bruises on the patient in case 2 was strong objective evidence for self-infliction.

The usefulness of skin tests to the patient's RBCs in this syndrome has been controversial. As just discussed, true sensitization to erythrocytes has never been shown to be the mechanism of this syndrome, but skin tests may be helpful in other ways. Painful ecchymoses developed in both of these women at sites that they were told were their own RBCs and not in sites that they thought were donor's blood. Besides confirming the absence of autoerythrocyte sensitization, these results cannot be explained by any known coagulopathy and obviate the need for an extensive clotting and immune evaluation. Case 2 shows the potential benefit of performing this test early and recommending early intervention by a psychiatrist.

The performance of this test requires several conditions. First, the physician must explain the test and suggest that the patient will react only to the site he is told are his own RBCs. Second, the patient must choose to inflict the positive test at the site. Third, the patient must be able to reach the test site. A positive result is consistent with a factitial cause but does not rule out a true conversion reaction. A positive reaction in a reachable area, and a negative test in an unreachable area would be further evidence for a factitial mechanism. This approach was used by Levin et al[6] in their case that was proved to be factitial by direct observation. A negative test in all areas does not rule out either a factitial cause or a conversion reaction.

Several points require emphasis. Patients with factitial purpura seem to have personality traits and emotional backgrounds similar to those of patients described with psychogenic purpura. If direct observation of a patient is not possible, factitial causes may be implied by the improvement of old lesions and failure of new lesions to develop under casts; by development of positive skin tests to the patient's own RBCs only in reachable sites that the patient has been told are his own RBCs; and by the morphology or pattern of the skin lesions. Extensive laboratory evaluation, hospital admissions, and surgical procedures potentially can be avoided by early recognition of the emotional and personality factors and by early application of these techniques.

The term psychogenic purpura should be broadened to include both purpura resulting from a conversion reaction and purpura resulting from self-inflicted injury since these patients share many common features and frequently are difficult to separate. All such patients are emotionally disturbed and in need of psychiatric care.

Lee R. Zacharski, MD, of the White River Junction Veterans Administration Hospital, White River Junction, Vt, performed the special clotting studies.

References

1. Gardner FH, Diamond LK: Autoerythrocyte sensitization: A form of purpura, producing painful bruising following autosensitization to red blood cells in certain women. *J Hematol* 10:675-690, 1955.

2. Ratnoff OD, Agle DP: Psychogenic purpura: A reevaluation of the syndrome of autoerythrocyte sensitization. *Medicine* 47:475-500, 1968.

3. Agle DP, Ratnoff OD, Wasman M: Studies in autoerythrocyte sensitization: The induction of purpuric lesions by hypnotic suggestion. *Psychosom Med* 29:491-503, 1967.

4. Agle DP, Ratnoff OD, Wasman M: Conversion reactions in autoerythrocyte sensitization: Their relationship to the production of ecchymoses. *Arch Gen Psychiatry* 20:438-447, 1969.

5. Davidson E: Factitious purpura presenting as autoerythrocyte sensitization. *Br Med J* 1:104, 1964.

6. Levin RM, Chodash R, Sherman JD: Factitious purpura simulating autoerythrocyte sensitization. *Ann Intern Med* 70:1201-1206, 1969.

7. Lyell A: Dermatitis artifacta and self-inflicted disease. *Scot Med J* 17:187-196, 1972.

8. Psychogenic purpura: Platelet factor 3 deficiency, SOCIETY TRANSACTIONS. *Arch Dermatol* 104:444-445, 1971.

Bullous Pemphigoid Responding to Sulfapyridine and the Sulfones

John R. Person, MD, Roy S. Rogers III, MD

• **Since 1968, a total of 84 patients with bullous pemphigoid have been seen at the Mayo Clinic. Of these, 41 were given a trial of sulfapyridine or dapsone, and six showed a significant response. In five patients, the condition was controlled completely. All responsive patients showed indirect and direct immunofluorescent tests indistinguishable from typical bullous pemphigoid. The patients, however, were somewhat younger (mean 54 years) than others having pemphigoid; and in two patients, biopsy specimens showed a reversal of the usual eosinophilic predominance over neutrophils. Three of the six patients were also diabetic.**

(*Arch Dermatol* 113:610-615, 1977)

Bullous pemphigoid is not generally considered to be a sulfa-responsive dermatosis. Lever,[1] in his second monograph on pemphigus and pemphigoid, stated, "The sulfones and sulfapyridine are of little or no value in the treatment of bullous pemphigoid. Only an exceptional patient with bullous pemphigoid responds to treatment with these drugs." Indeed, in the past, a bullous dermatosis responsive to sulfas and sulfones was considered by some to be diagnostic of dermatitis herpetiformis.[2-4] However, in 1953, Rook and Waddington[5] reported using sulfapyridine to treat 17 of 38 patients with bullous pemphigoid. The condition of four of these 17 was controlled, that of seven improved, and that of six remained uninfluenced or was aggravated by the medication. Little has been written regarding this mode of therapy for pemphigoid since that time.

In 1972, Honeyman et al[6] described five patients who shared clinical, histopathologic, and immunofluorescent criteria for both dermatitis herpetiformis and bullous pemphigoid. Although the authors failed to mention specifically which patients responded to sulfapyridine or dapsone at a given stage in their clinical course, we assume that the condition of at least some of their patients was best classified as sulfa-responsive bullous pemphigoid.

Before 1965, at least four cases were described in which the patient had an atypical bullous dermatosis and responded favorably to treatment with sulfonamides. The pathologic findings in these cases showed intraepidermal bullae with variable amounts of acantholysis suggestive of pemphigus vulgaris.[7-9] Emmerson and Wilson-Jones[10] described seven cases of pemphigus in which early biopsies showed eosinophilic spongiosis without acantholysis. In three of their cases, the lesions initially resembled dermatitis herpetiformis clinically but did not respond to dapsone. More recently, four cases of both histologically and immunologically confirmed pemphigus with clinical features of dermatitis herpetiformis have been described. The condition in all patients was completely controlled by sulfapyridine or dapsone.[11-13]

We would like to report six cases of immunologically typical bullous pemphigoid in which the patient responded to therapy with sulfapyridine or dapsone.

PATIENTS

Between 1968 and 1975, 84 patients with bullous pemphigoid were seen at the Mayo Clinic. Of these, 41 had trials of sulfapyridine or dapsone although not all of the trials resulted in therapeutic blood levels of sulfapyridine. Three patients were given sulfapyridine only in conjunction with corticosteroids and three had only mild or transient responses. Six patients showed a significant response (Tables 1 and 2), and these cases are presented.

REPORT OF CASES

CASE 1.—A 65-year-old man first came to the Mayo Clinic in April 1968, with a five-year history of pruritic, papular, excoriated scalp lesions. Two years before this, he had had a brief episode of conjunctivitis and eyelid erosions, which cleared with the use of eyedrops containing polymyxin B, neomycin, and hydrocortisone (Cortisporin); at that time, nonpainful dysphagia and oral erosions also developed and had persisted. Thirteen months previously, bullae and erosions of the groin, genitalia, and buttocks, which by history demonstrated a positive Nickolsky sign, had begun. He had been hospitalized twice for this problem and had been taking 30 mg of prednisone daily for the preceding year. He also related a ten-year history of diabetes mellitus controlled by sulfonylureas and a one-month history of progressive, nonradiating low back pain.

On examination, crusted erythematous plaques were noted on the elbows, buttocks, and perianal and pretibial regions as well as numerous, discrete, 1-cm crusted lesions on the scalp. Erythematous erosions were noted on the palate and left buccal mucosa; in addition, he had a 5-mm flaccid bulla on the left buccal mucosa.

A biopsy specimen taken from the soft palate showed only subepithelial inflammation. Biopsies of skin from the left scapular area and the right knee showed inflammatory subepidermal bullae consistent with pemphigoid. Results of an ophthalmologic examination were normal.

Accepted for publication July 21, 1976.

From the Mayo Clinic and Mayo Foundation, Rochester, Minn.

Reprint requests to Section of Publications, Mayo Clinic, 200 First St SW, Rochester, MN 55901 (Dr Person).

Table 1.—Clinical Data

Age at Onset (yr) & Sex	Clinical Involvement	Other Diseases	Duration of Bullous Pemphigoid	Follow-up, 1975
61M	Scalp 3 yr before other areas. Eventually generalized skin & nonscarring oral, pharynx, ocular, perianal, & esophageal involvement	Diabetes mellitus	2 yr 10 mo (of generalized disease)	Died 2/70 of unknown causes; eruption controlled with sulfapyridine until death
66F	Generalized skin & oral involvement (Fig 1)	Diabetes mellitus	5 yr 5 mo	Died 4/19/72 of myocardial infarction; eruption controlled with sulfapyridine until death
42M	Generalized skin involvement; minimal oral involvement	None	9 yr 9 mo to present	Disease active; controlled with sulfapyridine
46M	Generalized skin & oral involvement	None	10 mo when last seen	No follow-up
53F	Generalized skin & oral involvement by exam; eyes & nose by history only	Diabetes mellitus	3 yr 9 mo to present	Disease active; substantially but not completely controlled with dapsone
58F	Generalized skin involvement	Increased fasting blood sugar not in diabetic range	15 mo	Disease now inactive; sulfapyridine discontinued

Table 2.—Immunofluorescence and Biopsy Data*

Age at Onset (yr) & Sex	Biopsy Data	Indirect (Serum)	Direct (Biopsy)
61M	1. Back—SEB 2. Knee—SEB 3. Esophagus—nonspecific inflammation	1. 1/320 positive BMZ 2. 1/160 positive BMZ	Not done
66F	1. Arm—SEB & neutrophilic papillary microabscesses (Fig 2) 2. Arm—SEB; eosinophilic & neutrophilic papillary microabscesses	1. 1/640 positive BMZ	Not done
42M	1. Arm—SEB	1. 1/2560 positive BMZ 2. 1/2560 positive BMZ 3. 1/640 positive BMZ 4. 1/320 positive BMZ 5. 1/320 positive BMZ 6. Positive by history only	Not done
46M	1. Axilla—SEB with many neutrophils (Fig 3 & 4)	1. 1/20 positive BMZ 2. 1/80 positive BMZ 3. Negative BMZ, 1/320 pos ICS	1. BMZ positive in linear pattern with IgG, IgM, C3, properdin, & weak factor B
53F	1. Arm—healing SEB, papillary edema & fibrin deposition 2. Back—?early SEB 3. Palate—healing mucosa	1. Negative 2. Positive 1/80 BMZ 3. Negative	1. BMZ positive with linear IgA, C1q, & properdin. IgM cytoid bodies also present 2. BMZ positive with linear IgG, IgA, C3, properdin, & fibrin. IgM, IgA, & C1q cytoids also present
58F	1. Abdomen—nonspecific dermal inflammation 2. Leg—nonspecific dermal inflammation	1. 1/20 positive BMZ 2. 1/20 positive BMZ 3. 1/20 positive BMZ 4. 1/20 positive BMZ 5. 1/40 positive BMZ 6. Negative 7. Negative	1. BMZ positive with linear IgM, C3, properdin, & fibrin 2. BMZ positive with IgG & C3

*SEB indicates subepidermal bulla; BMZ, basement membrane zone; and ICS, intercellular substance.

Roentgenograms of the spinal column showed compression fractures of thoracic and lumbar vertebrae (T-6 through T-10, T-12, and L-1). A bone biopsy (ninth right rib) was characteristic of hypercortisonism. Proctosigmoidoscopy and barium examination of the gastrointestinal tract showed no abnormality. Sulfapyridine (500 mg) was given orally four times daily; this, along with topical steroid creams, seemed to control the skin disease and allowed the dosage of prednisone to be tapered from 30 to 15 mg daily. Sulfapyridine blood levels were more than adequate on two occasions (8.2 and 9.6 mg/100 ml). Also prescribed were sodium bicarbonate to alkalinize the urine, anabolic steroids and a back brace for the osteoporosis, and a strict diet for the diabetes. The patient was dismissed after a 29-day hospitalization and was estimated to be 60% improved. The dosage of prednisone was gradually tapered and was discontinued by June 1968. The anabolic steroid was stopped at the same time. His disease was well-controlled with the sulfapyridine, and erosions developed only after trauma.

In September 1968, however, the patient decided to discontinue the use of sulfapyridine; six weeks later, the generalized

Fig 1.—Bullae on ankle.

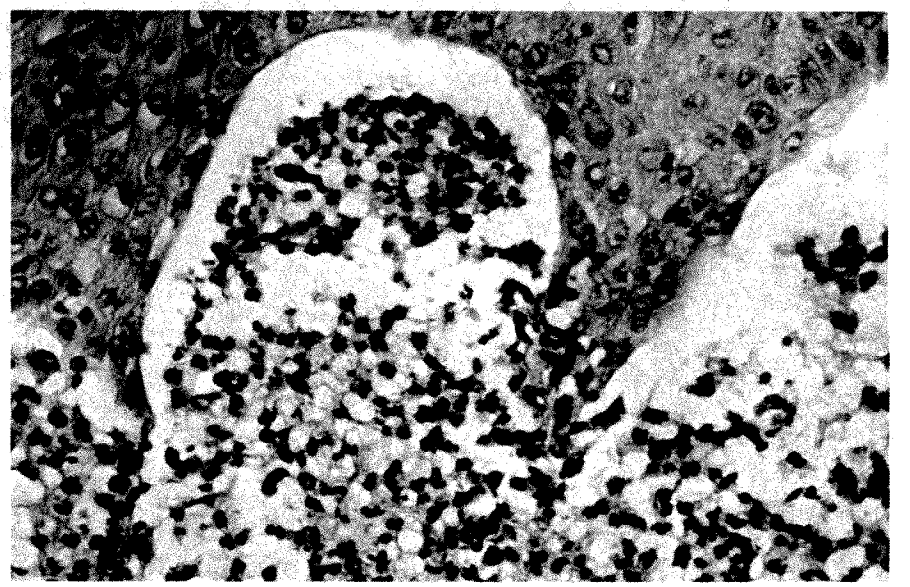

Fig 2.—Papillary neutrophilic microabscesses (hematoxylin-eosin, original magnification ×400).

blistering eruption recurred with the lesions most prominent on the scalp, in the groin, and in the mouth. Considerable dysphagia also developed. He returned to this clinic in November 1968 and was again hospitalized. A barium swallow showed no adhesions, but a 4-cm diverticular pouch was noted anterior and to the right of the aortic arch. On esophagoscopy, numerous ulcerations were apparent in the hypopharynx and esophageal introitus. Much of the esophagus was covered with a whitish membrane, which was friable and bled easily, and two adhesions were noted and lysed. An esophageal biopsy specimen showed nonspecific inflammation, and culture revealed *Candida albicans* and *Streptococcus viridans*, but viral cultures were negative. Serum (indirect) immunofluorescent examinations on two occasions showed antibasement membrane zone antibodies to be present in a titer of 1:320 and 1:160. The patient was again treated with 500 mg of sulfapyridine four times daily given with sodium bicarbonate; a blood level of 5.2 mg/100 ml was achieved. Steroids were used topically on the scalp. The patient again responded well with 80% improvement during his 21-day hospitalization. He was dismissed in late November 1968 and was not seen again at this clinic.

A follow-up letter in 1975 revealed that the patient had died of unknown causes in February 1970 and that his cutaneous disease had remained well-controlled on the sulfapyridine.

CASE 2.—An obese 66-year-old Iowa housewife came to this clinic in August 1967 with an eight-month history of papulovesicular and bullous eruption that had begun on the palms and had become generalized over a few weeks. Nasal and oral ulcerations also were noted. The amount of pruritus was moderate. One month before the onset of the eruption, the patient was found to be diabetic and an oral sulfonylurea was begun; at the same time she had a urinary tract infection and had been treated with an unknown antibiotic. She had been hospitalized elsewhere soon after the onset of the eruption that was thought to be due to a drug. She was treated with steroids used topically only.

On presentation at this clinic, the patient was noted to have numerous excoriated, erythematous papular lesions in a generalized distribution but with accentuation over the extensor extremities. A 5 × 7 cm tense bulla was noted over the left medial malleolus (Fig 1), and a recently ruptured 4-mm vesicle was noted on the left buccal mucosa. Splenomegaly also was noted.

A specimen of skin taken from the right arm for biopsy showed a subepidermal bulla with peripheral papillary neutrophilic microabscesses (Fig 2). Liver function and hematologic measurements were within normal limits, but in view of the patient's severe splenomegaly, laparotomy and splenectomy were performed. Splenic pathological findings showed severe fibrocongestive changes, and liver biopsy revealed fatty change and early portal cirrhosis. A roentgenogram of the chest, barium examination of the entire gastrointestinal tract, excretory urogram, and a mammogram revealed no evidence of malignancy. Results of tests for fat in a 24-hour stool were normal.

The patient was treated with antihistamines and topical fluorinated corticosteroids, and 95% improvement was obtained during her 24-day hospitalization. Her diabetes responded to vigorous dietary control, and the oral hypoglycemic agent was discontinued.

After her dismissal, the patient did well and was able to control her disease topically until early July 1968 when the bullous eruption flared. She returned to this clinic and was noted to have numerous tense 1- to 1.5-cm bullae over the extensor surfaces of the extremities and scattered papular excoriated lesions over the buttocks and back. No mucosal lesions were present. The patient had also gained 32.7 kg (72 lb) over the previous ten months. She was again hospitalized. Biopsy of a specimen from the right volar forearm showed a subepidermal bulla with papillary microabscesses. The serum (indirect) immunofluorescent test showed antibasement membrane zone antibodies to be present in a titer of 1:640. Direct immunofluorescent examination revealed IgG, IgM, and C3 at the basement membrane zone of lesional skin. Uninvolved skin showed nothing on direct immunofluorescent testing. The patient had restarted the oral use of the hypoglycemic agent, and in light of her poor adherence to her diet, this was continued. She was treated topically for her dermatosis, and in addition, 900 mg of sulfapyridine was given orally four times daily with appropriate doses of sodium bicarbonate. A sulfapyridine blood level of 3.2 mg/100 ml was achieved, and the eruption was rapidly controlled. She was dismissed from the hospital after 12 days.

The patient was not seen again at this

clinic. A follow-up letter in 1975 revealed that she had died of unknown causes in April 1972.

CASE 3.—A 45-year-old man first came to this clinic in January 1969 with a 35-month history of a pruritic, generalized papulovesicular eruption that had begun on the scalp and chest. Results of a biopsy done elsewhere seemed consistent with dermatitis herpetiformis, and administration of sulfapyridine for two to three weeks was followed by resolution of the lesions. The patient suffered intolerable nausea while taking this medication, however, and it was discontinued. Trials of sulfoxone (Diasone), dexamethasone (0.75 mg four times daily), and dapsone had failed to control the dermatosis, and he was referred to this clinic.

On examination, the patient was noted to have a generalized, symmetrical excoriated papular eruption with scattered vesicles and rare large bullae and eroded areas. Vesicles and bullae had arisen on both normal and urticarial skin. One erosion was noted on the right buccal mucosa. A biopsy specimen of skin from the left arm showed subepidermal bulla with eosinophilia. Indirect immunofluorescent examination showed antibasement membrane zone antibodies in a titer of 1:2,560, and results of serial titers over the next 15 months were 1:2,560, 1:640, 1:320, and 1:320. Routine tests showed results in the normal range, and sigmoidoscopy and a barium examination of the entire gastrointestinal tract did not reveal evidence of malignancy. Administration of an enteric-coated sulfapyridine was started and was well tolerated, along with appropriate amounts of bicarbonate. Taking 1 gm of sulfapyridine four times daily, a blood level of 7.1 mg/100 ml was achieved. Steroids were used topically, concurrently, and the patient's dermatosis cleared rapidly; he was dismissed after ten days.

The eruption continued to be well-controlled with sulfapyridine, which was reduced to one tablet per day over the next two years. At the time of this report, the patient has not returned to this clinic since 1970; however, a follow-up letter in 1975 revealed that he still required sulfapyridine to control the dermatosis, but that otherwise he was doing well.

CASE 4.—A 46-year-old man came to this clinic in March 1974 with a three-month history of generalized vesiculobullous eruption. The process had begun with oral bullae that had developed two weeks after having a tooth extracted. The nasal mucosa was soon involved, and the bullous lesions gradually spread to the axillae, groin, and legs. The pruritus was described as moderate, but "burning" was considerable. A biopsy done elsewhere showed a "subepidermal bulla most consistent with bullous pemphigoid." The patient was treated with varying intramuscular and oral doses of triamcinolone, which controlled the eruption in amounts of 16 mg or greater daily; but he had repeated flare-ups when the steroids were tapered below this level.

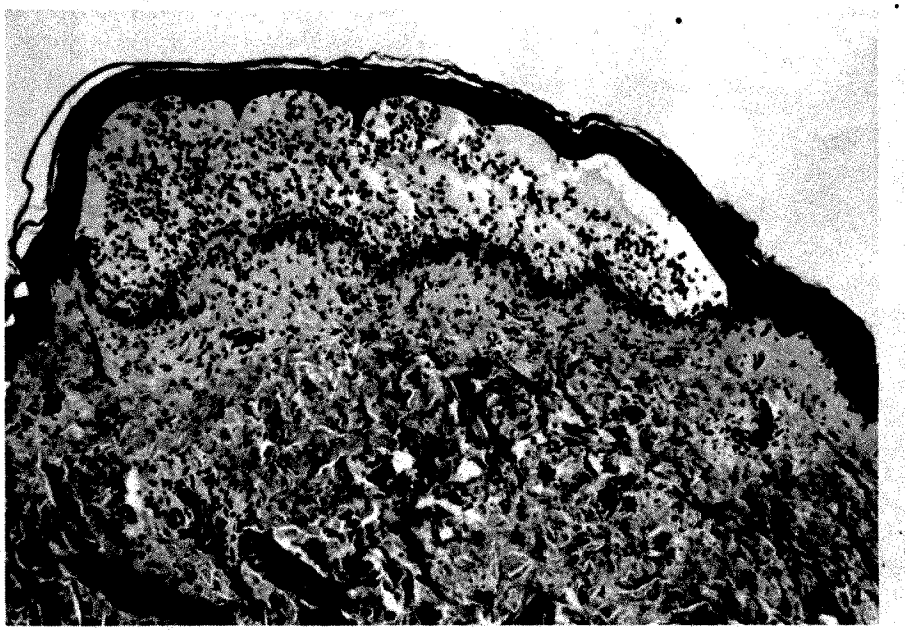

Fig 3.—Low-power view of bulla (hematoxylin-eosin, original magnification ×100).

On admission to this clinic, the patient had numerous 4- to 10-mm tense vesicles and bullae arising on an erythematous base in the axillae, left groin, abdomen, and left supraclavicular area. Moderate obesity and multiple actinic keratoses also were noted. Biopsy specimen from the right axilla was interpreted as showing subepidermal bulla consistent with bullous pemphigoid (Fig 3 and 4). Direct immunofluorescent examination revealed IgG, IgM, C3, properdin, C1q, and factor B in a linear pattern at the basement membrane zone. Indirect immunofluorescent testing demonstrated antibasement membrane zone antibodies in a titer of 1:20. Results of routine laboratory tests were in the normal range. Administration of enteric-coated sulfapyridine, 650 mg three times daily, was begun with rapid regression of the bullae and excellent control of the eruption.

The patient was next seen in June 1974 and was free of blisters. Results of the indirect immunofluorescent test were positive for antibasement membrane zone antibodies in a titer of 1:80, and a sulfapyridine blood level was 3.9 mg/100 ml. He was last seen in October 1974 and continued to be free of lesions while taking the sulfapyridine. Indirect immunofluorescent testing, however, showed anti-intracellular substance antibodies in a titer of 1:320. Unfortunately, we have been unable to obtain follow-up information on this patient.

CASE 5.—A massively obese, 55-year-old woman was first admitted to this clinic in February 1974 with a two-year history of generalized bullous eruption. The lesions had begun on the arms as a maculopapular eruption that had developed one day after having had a tetanus toxoid injection; during the next few weeks, a generalized bullous eruption, characterized by numerous, tense, dime-sized bullae, began to appear. Oral, conjunctival, and nasal lesions also were noted. The lesions were intensely pruritic. The patient had had numerous evaluations of the eruption elsewhere; a previously taken biopsy specimen had shown a subepidermal bulla, and results of immunofluorescent studies were reported to the patient as negative. She had had an unsuccessful trial of an unknown sulfa preparation, but significant improvement followed the systemic use of steroids and dapsone. Unfortunately, the former exacerbated the patient's mild congestive heart failure and unmasked previously unrecognized diabetes mellitus; and the latter had to be discontinued because of anemia. She was then referred to this clinic.

On initial examination, a generalized, symmetrical vesiculobullous eruption without regional accentuation was noted. The blisters were tense and 3 to 10 mm in diameter; most had been excoriated. Mucosal lesions were limited to the oral and nasal mucosa. Biopsy specimens of skin

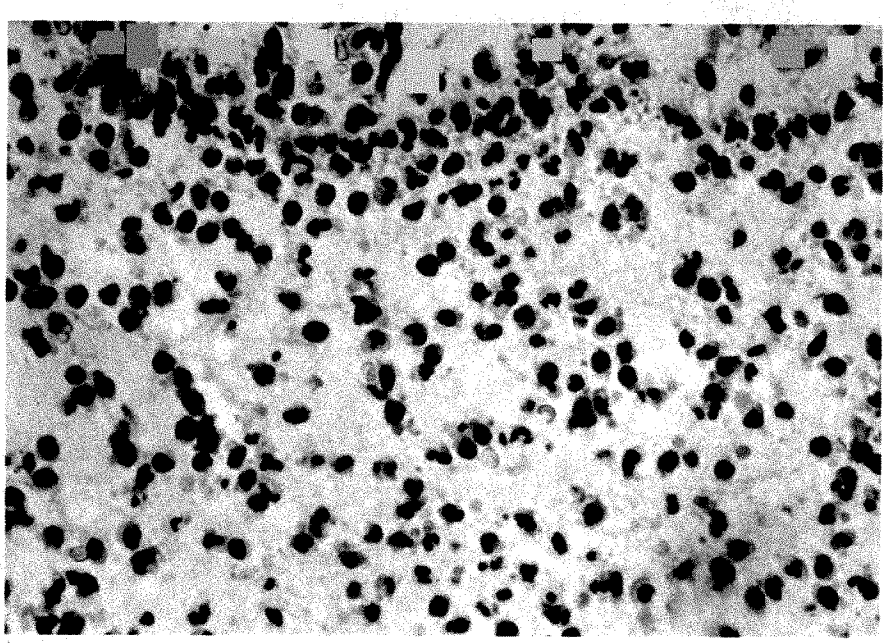

Fig 4.—High-power view of bulla showing predominantly neutrophilic infiltrate (hematoxylin-eosin, original magnification ×500).

from the left arm revealed inflammatory subepidermal bullae most consistent with erythema multiforme. Biopsy specimens of tissues from the back and palate showed nonspecific results. Direct immunofluorescent examination of lesional skin revealed a linear pattern of IgA, C1q, and properdin at the basement membrane zone. A repeat direct immunofluorescent examination one week later revealed a linear pattern of IgG, IgM, IgA, fibrin, C1q, factor B, C3, and properdin at the basement membrane zone. Indirect immunofluorescent testing was negative on one occasion; on another it showed antibasement membrane zone antibodies in a titer of 1:80. Mammography, sigmoidoscopy, and barium examination of the gastrointestinal tract were negative for malignancy. The patient's diabetes was controlled by diet. A gynecologic consultation for postmenopausal hemorrhage revealed only a cystocele and rectocele, and dilatation and curettage was adamantly refused. The patient was treated for her dermatosis with topical fluorinated corticosteroids, antihistamines, and sulfapyridine. A sulfapyridine blood level of 3.5 mg/100 ml was achieved, and she was dismissed considerably improved.

The patient has not been seen at this clinic since, but a follow-up letter from her in November 1975 revealed that she was taking dapsone with good, but not complete, control of her dermatosis.

CASE 6.—A 58-year-old woman came to this clinic in January 1974 with a six-week history of a generalized bullous eruption that had begun on her arms and gradually spread to the legs, back, and abdomen. Pruritus was moderate. Previous treatment had included topical use of steroid creams, antihistamines, and an unknown intramuscular injection.

On her admission to this clinic, physical examination showed an erythematous papular, occasionally excoriated, eruption on the back, abdomen, and extremities with scattered tense blisters ranging in size from 0.3 to 2.5 cm. Most of the blisters were in flexural areas, and there were no mucosal lesions.

Biopsy specimens from the abdomen and leg revealed nonspecific dermal inflammation. Direct immunofluorescent examination revealed a linear deposition of C3, fibrin, and properdin at the basement membrane zone on one occasion, and two weeks later it showed IgG and C3 in a linear pattern in the same zone. Indirect immunofluorescent testing revealed antibasement membrane zone antibodies in a titer of 1:20. Sigmoidoscopy, barium examination of the entire gastrointestinal tract, excretory urogram, and cervical smear showed no evidence of malignancy. Dilatation and curettage, performed because of postmenopausal bleeding, revealed only atrophic endometrium. Mild glucose intolerance was noted with the fasting plasma glucose ranging from 91 to 131 mg/100 ml (upper limit of normal, 100 mg/100 ml).

Treatment included topical use of steroid creams and oral administration of enteric coated sulfapyridine, 650 mg three times daily, with appropriate amounts of sodium bicarbonate. This achieved a sulfapyridine blood level of 7.4 mg/100 ml. The patient responded rapidly to this regimen, with a 90% clearing of lesions and no new bullae during her 19-day hospitalization.

Over the next year, the patient remained free of blisters while taking sulfapyridine. Serial indirect immunofluorescent tests over this period showed the following titers of antibasement membrane zone antibodies: 1:20, 1:20, 1:20, 1:40, negative, negative. The patient, meanwhile, gradually reduced the sulfapyridine and found that 1,300 mg in one weekly dose would control the eruption.

The patient has not been seen at this clinic since February 1975. A follow-up letter, however, revealed that she discontinued use of the sulfapyridine entirely in May 1975 without ill effects. Erythematous guttate macular lesions develop occasionally; she treats these topically with steroid creams. Thus far, this has completely controlled her disease.

COMMENT

Discernible differences were noted between the sulfa-responsive patients and those with typical bullous pemphigoid. The sulfa-responsive patients were younger, with a mean age of 54 years. Histopathologically, neutrophilic infiltration was more common and more dense, while eosinophils were less common than is usual in pemphigoid; but only one patient showed the papillary neutrophilic microabscesses typical of dermatitis herpetiformis.[7-11] Three of the six patients had overt adult-onset diabetes mellitus, and a fourth had an elevated fasting blood sugar that was not in the diabetic range. Interestingly, at last report one patient (case 4) had a negative titer of basement membrane zone antibodies, but a titer of 1/320 to the intercellular substance antibody had developed. He may be evolving into the sulfa-responsive pemphigus group mentioned,[7-10,12,13] but evolution is unclear at this time.

Despite these minor differences, however, we believe that all six cases represent bullous pemphigoid. Clinically, only one patient (case 6) did not have oral lesions. As previously mentioned, papillary microabscesses were apparent on histopathologic examination in only one patient (case 2). All patients on whom direct immunofluorescent examinations were performed showed linear deposition of IgG and other immunoreactants characteristic of pemphigoid.[15,16] Although

the presence of a linear deposition of IgA (case 5) is mildly suggestive of dermatitis herpetiformis, the presence of IgG, IgM, C3, factor B, properdin, and C1q in a linear pattern is most consistent with the pemphigoid spectrum of diseases.[16] All six patients had circulating antibasement membrane zone antibodies on at least one occasion by indirect immunofluorescent testing—again, characteristic of bullous pemphigoid.[16,17]

These patients emphasize the necessity for immunopathologic confirmation in the diagnosis of bullous dermatoses. We believe that some confusion has arisen from the use of sulfapyridine and the sulfones as a supposedly specific therapeutic test for dermatitis herpetiformis. Our contention is that a response to sulfapyridine or sulfones is a sensitive indicator of dermatitis herpetiformis, but we do not believe that it is a specific indicator of the disease.

The mechanism of action of sulfapyridine and the sulfones in these patients is unknown. These agents also have been used with some success in many other dermatoses, including pyoderma gangrenosum,[18,19] subcorneal pustular dermatosis of Sneddon-Wilkinson,[20,21] acrodermatitis continua (acrodermatitis of Hallopeau),[22-24] erythema elevatum diutinum,[25-27] acne conglobata,[28] and necrotizing angiitis.[29,30] All these dermatoses are characterized histologically by polymorphonuclear leukocyte infiltration of varying but significant degree. The well-known response of ulcerative colitis to salicylazosulfapyridine is probably similarly grouped.[31] It seems reasonable to assume that sulfapyridine and the sulfones might act by inhibiting neutrophilic function in some way.

Barranco[32] presented evidence that dapsone may inhibit lysosomal enzymes in rabbits with induced hypervitaminosis A. Normally, hypervitaminosis A results in lysosomal instability with subsequent enzyme release and breakdown of chondroitin sulfate in the cartilage of affected animals. In the rabbit, the visible result is floppy ears, and dapsone, like methylprednisolone, will prevent this effect. Mier and van den Hurk[33] have recently presented evidence that the concentration of dapsone that directly inhibits such enzymes is 20-fold the serum concentration. Thus, unless dapsone is concentrated by lysosomes, direct enzyme inhibition may not be its mode of action. However, any mechanism that inhibits the function of neutrophils, lysosomes, or lysosomal enzymes would account for the histologic similarities of the diseases in which sulfapyridine and the sulfones are effective. One also wonders if the rare, idiosyncratic agranulocytosis occurring with these drugs might somehow be related to this effect. If a sulfapyridine or sulfone effect on neutrophils is indeed responsible for their therapeutic efficacy, finding a predominance of neutrophils over eosinophils on biopsy of a bullous pemphigoid lesion may be therapeutically significant.

Immunofluorescent studies were performed in the laboratory of Robert E. Jordon, MD.

Nonproprietary Names and Trademarks of Drugs

Triamcinolone—*Aristocort Tablets, Kenacort.*

Salicylazosulfapyridine—*Accucol, Azulfidine, Rorasul, S.A.S.-500.*

References

1. Lever WF: *Pemphigus and Pemphigoid.* Springfield, Ill, Charles C Thomas Publisher, 1965, pp 79-81, 222.

2. Costello MJ: Sulfapyridine in the treatment of dermatitis herpetiformis. *Arch Dermatol Syphilol* 56:614-624, 1947.

3. Tolman MM, Moschella SL, Schneiderman RN: Dermatitis herpetiformis—specific entity or clinical complex? *J Invest Dermatol* 32:557-560, 1959.

4. Spier HW, Thies W: Zur Sulfonbehandlung der dermatitis herpetiformis Duhring. *Hautarzt* 6:415-418, 1955.

5. Rook A, Waddington E: Pemphigus and pemphigoid. *Br J Dermatol* 65:425-431, 1953.

6. Honeyman JF, Honeyman A, Lobitz WC Jr, et al: The enigma of bullous pemphigoid and dermatitis herpetiformis. *Arch Dermatol* 106:22-25, 1972.

7. Flodén C-H, Gentele H: A case of clinically typical dermatitis herpetiformis (MB DUHRING) presenting acantholysis. *Acta Dermatol Venereol* 35:128-131, 1955.

8. Doepfmer R: Über eine nosologisch ungeklärte bullöse Dermatose (Pemphigus chronicus vulgaris oder Dermatitis herpetiformis Duhring). *Hautarzt* 12:452-456, 1961.

9. Winkelmann RK, Roth HL: Dermatitis herpetiformis with acantholysis or pemphigus with response to sulfonamides: Report of two cases. *Arch Dermatol* 82:385-390, 1960.

10. Emmerson RW, Wilson-Jones E: Eosinophilic spongiosis in pemphigus: A report of an unusual histological change in pemphigus. *Arch Dermatol* 97:252-257, 1968.

11. Seah PP, Fry L, Cairns RJ, et al: Pemphigus controlled by sulfapyridine. *Br J Dermatol* 89:77-81, 1973.

12. DeMento FJ, Grover RW: Acantholytic herpetiform dermatitis. *Arch Dermatol* 107:883-887, 1973.

13. Barranco VP: Mixed bullous disease. *Arch Dermatol* 110:221-224, 1974.

14. Lever WF, Schaumburg-Lever G: *Histopathology of the Skin,* ed 5. Philadelphia, JB Lippincott Co, 1975, p 119.

15. Jordon RE, Triftshauser CT, Schroeter AL: Direct immunofluorescent studies of pemphigus and bullous pemphigoid. *Arch Dermatol* 103:486-491, 1971.

16. Jordon RE, Schroeter AL, Good RA, et al: The complement system in bullous pemphigoid: II. Immunofluorescent evidence for both classical and alternate-pathway activation. *Clin Immunol Immunopathol* 3:307-314, 1975.

17. Jordon RE, Beutner EH, Witebsky E, et al: Basement zone antibodies in bullous pemphigoid. *JAMA* 200:751-756, 1967.

18. Perry HO, Brunsting LA: Pyoderma gangrenosum: A clinical study of 19 cases. *Arch Dermatol* 75:380-386, 1957.

19. Ayres S Jr, Ayres S III: Pyoderma gangrenosum with an unusual syndrome of ulcers, vesicles, and arthritis. *Arch Dermatol* 77:269-278, 1958.

20. Sneddon IB, Wilkinson DS: Subcorneal pustular dermatosis. *Br J Dermatol* 68:385-394, 1956.

21. Burns RE, Fine G: Subcorneal pustular dermatosis. *Arch Dermatol* 80:72-80, 1959.

22. Sulzberger MB: Effect of treatment with sulfapyridine on acrodermatitis continua (Hallopeau), abstracted. *Arch Dermatol Syphilol* 40:853, 1939.

23. Sulzberger MB: Acrodermatitis continua pustulosa (Hallopeau) treated with sulfapyridine, abstracted. *Arch Dermatol Syphilol* 40:1019, 1939.

24. Lever WF: Acrodermatitis continua (Hallopeau): Effect of treatment with sulfapyridine. *Arch Dermatol Syphilol* 49:273-277, 1944.

25. Kalkoff KW: Zur Behandlung des erythema elevatum diutinum mit 3-Sulfanilamido-6-methoxypyridazin (Lederkyn). *Dermatol Wochenschr* 142:788-800, 1960.

26. Vollum DI: Erythema elevatum diutinum—vesicular lesions and sulphone response. *Br J Dermatol* 80:178-183, 1968.

27. Cream JJ, Levene GM, Calnan CD: Erythema elevatum diutinum: An unusual reaction to streptococcal antigen and response to dapsone. *Br J Dermatol* 84:393-399, 1971.

28. Andrews GC, Domonkos AN, Post CF: Treatment of acne vulgaris. *JAMA* 146:1107-1112, 1951.

29. Winkelmann RK, Ditto WB: Cutaneous and visceral syndromes of necrotizing or "allergic" angiitis: A study of 38 cases. *Medicine* 43:59-89, 1964.

30. Wells GC: Allergic vasculitis (tri-symptom of Gougerot) treated with dapsone. *Proc R Soc Med* 62:665-666, 1969.

31. Lorincz AL, Pearson RW: Sulfapyridine and sulfone type drugs in dermatology. *Arch Dermatol* 85:2-14, 1962.

32. Barranco VP: Inhibition of lysosomal enzymes by dapsone. *Arch Dermatol* 110:563-566, 1974.

33. Mier PD, van den Hurk JJMA: Inhibition of lysosomal enzymes by dapsone. *Br J Dermatol* 93:471-472, 1975.

Chloracne From Manufacture of a New Herbicide

James S. Taylor, MD; Richard C. Wuthrich, MD; Kenneth M. Lloyd, MD; Alan Poland, MD

• Forty-one chemical company workers had chloracne as a result of exposure to 3,4,3′,4′-tetrachloroazoxybenzene (TCAB), an extraneous intermediate produced during the manufacture of a new herbicide. There was no laboratory evidence of significant hepatotoxicity or porphyria during the short time the herbicide was produced. An acnegenic when applied to the rabbit ear, TCAB is also a potent inducer of the microsomal enzyme aryl hydrocarbon hydroxylase. Prevention of chloracne is a difficult industrial engineering task and treatment of the disease is even more perplexing.

(*Arch Dermatol* 113:616-619, 1977)

Chloracne is an extremely refractory form of occupational acne produced by exposure to various chlorinated aromatic compounds, and may be accompanied by serious systemic toxicity.[1-4] These chemicals are also environmentally important, having produced epidemics of X disease in cattle and chick edema in chickens. Many are teratogenic.[5]

This report describes the first reported cases of chloracne from 3,4,3′,4′-tetrachloroazoxybenzene (TCAB), an extraneous intermediate formed during the manufacture of the new herbicide, 2-(3,4-dichlorophenyl)-4-methyl-1,2,4-oxadiazolidine-3,5-dione.[6,7] Workers in a small chemical company first noted cases of the "bumps" one to two months after herbicide production began. We first visited the company several months later when more than 90% of the workers had chloracne.

METHODS

Clinical

Forty-one workers participated in a study that included relevant dermatologic history and examination. A quantitative screening test for total porphyrins (method of Schlenker, and Kitchell)[8] and an SGOT were obtained from 37 and 32 workers, respectively. Skin biopsy specimens of chloracne lesions were obtained from two workers.

Experimental

Acetone solutions of 0.1%, 0.001%, and 0.0001% technical grade TCAB were applied to the ears of 2.3- to 3.2-kg albino rabbits, according to the method of Adams et al.[9] Solutions were applied daily (five days of seven) for four weeks and acnegenic responses were recorded weekly. Acetone and 50% Halowax 1014 in mineral oil served as negative and positive controls, respectively.

Following injections of TCAB and 2,3,7,8-tetrachlorodibenzo-*p*-dioxin (TCDD) the activity of aryl hydrocarbon hydroxylase (AHH) in chick embryo liver was assayed, as previously described by Poland and Glover.[10] The TCDD is a potent chloracnegen and also an inducer of δ-aminolevulinic acid synthetase.

RESULTS

Clinical

The clinical results are summarized in Table 1 and Fig 1 through 8.

Experimental

Rabbit ear bioassay results are summarized in Table 2. In addition to the comedone formation, the 0.1% TCAB acetone solution was irritating to the rabbit ear, producing erythema, edema, and necrosis of the epithelium. The higher dilutions were nonirritating. The 0.1% and 0.01% solutions of the final product (herbicide) were only slightly irritating (D. D. Knutson, MD, written communication June 1974). Dennis D. Knutson, MD, of the University of Oregon Medical School, also tested TCAB by rabbit ear bioassay and found a 0.05% TCAB alcohol solution to be acnegenic.

The results of AHH induction by TCAB and TCDD in chick embryo liver are summarized in Table 3. A standard dose of TCDD, which elicits about 70% of the maximal response,

Accepted for publication July 23, 1976.

From the Section of Industrial Dermatology, Department of Dermatology, Cleveland Clinic Foundation and Cleveland Clinic Educational Foundation, Ohio (Drs Taylor and Wuthrich), and Department of Pharmacology and Toxicology, University of Rochester School of Medicine and Dentistry, New York (Dr Poland). Dr Lloyd is in private practice in Youngstown, Ohio.

Read before the Section on Dermatology at the 123rd annual convention of the American Medical Association, Chicago, June 24, 1974.

Reprint requests to Section of Industrial Dermatology, Department of Dermatology, Cleveland Clinic Foundation, 9500 Euclid Ave, Cleveland, OH 44106 (Dr Taylor).

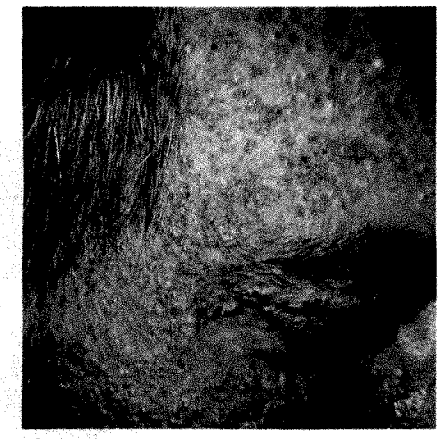

Fig 1.—3,4,3′,4′-tetrachloroazoxybenzene chloracne of face with multiple comedones and typical noninflammatory straw-colored cysts in worst-affected worker.

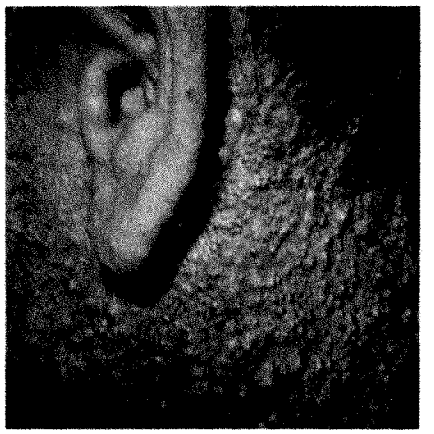

Fig 2.—Severe auricular and retroauricular 3,4,3′,4′-tetrachloroazoxybenzene chloracne in worst-affected worker.

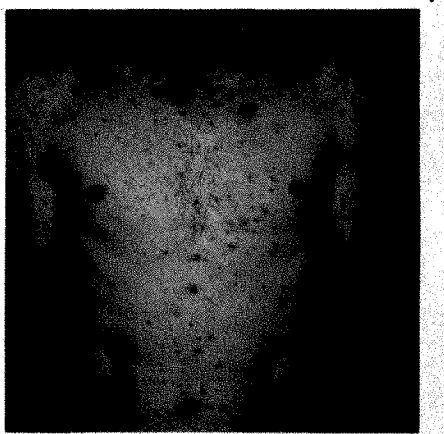

Fig 3.—Diffuse 3,4,3′,4′-tetrachloroazoxybenzene chloracne of chest and arms with inflammatory papules and cysts in worst-affected worker.

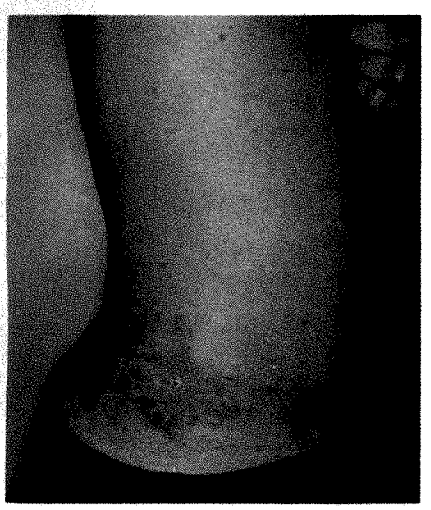

Fig 4.—3,4,3′,4′-Tetrachloroazoxybenzene chloracne involving waist.

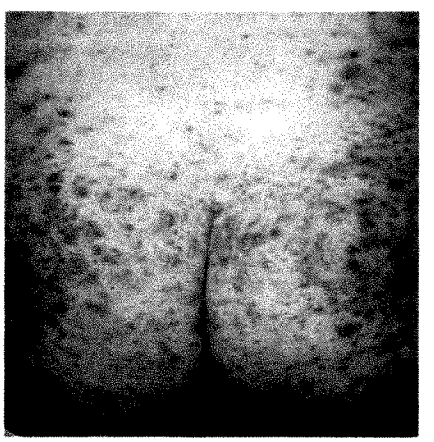

Fig 5.—3,4,3′,4′-Tetrachloroazoxybenzene chloracne on low back and buttocks.

Fig 6.—3,4,3′,4′-Tetrachloroazoxybenzene chloracne on thighs.

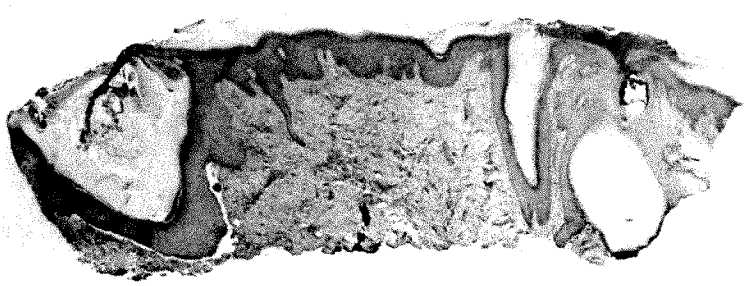

Fig 7.—Skin biopsy section of comedone from forearm of worker with 3,4,3′,4′-tetrachloroazoxybenzene chloracne showing hyperkeratosis, acanthosis, and marked follicular plugging (hematoxylin-eosin, original magnification ×10).

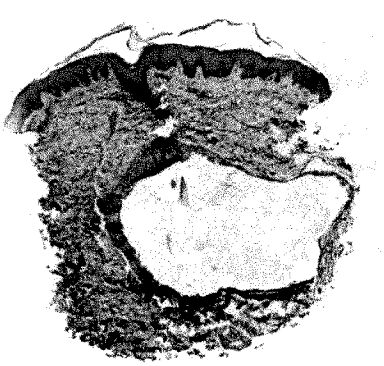

Fig 8.—Skin biopsy section of noninflammatory straw-colored cyst from forearm of worker with 3,4,3′,4′-tetrachloroazoxybenzene chloracne showing an epidermal-like cyst in dermis with minimal surrounding chronic inflammation (hematoxylin-eosin, original magnification ×10).

Table 1.—Clinical Findings in 41 Herbicide Workers	
Race	
White, 37; black, 4	
Age, yr:	
19-64 (average 29)	
Type of work*	
Production & maintenance	36
Laboratory	3
Office	3
Active acne score*†	
1-8, mild	15
9-19, moderate	14
> 20, severe	12
Distribution of chloracne lesions*	
Face	38
Neck	33
Arms	31
Legs	31
Trunk	27
Genitalia	15
Other medical history data*	
Hirsutism	1
Dark urine	1
Anorexia	3
Weight loss	2
Headaches	1
Frequency & dysuria	2
Paranoid schizophrenia	1
Laboratory data*	
Total urinary porphyrins	
≤ 100 mEq/liter	36
120 mEq/liter	1
SGOT	
≤ 40 Karmen units	29
41-61 Karmen units	3

*Number of workers.

†Active acne score (per method of Poland et al[11]) is sum of severity (graded 0-4) of cysts, comedones, and pustules in each of five locations: face, neck, chest, and other (maximal possible score: grade 4 in all five locations = 20 for each of three lesions = 60.

Table 2.—Rabbit Ear Bioassay		
Test Material*	Concentration, %	Reaction
TCAB	0.1 acetone	Comedone formation
TCAB	0.001 acetone	Comedone formation
TCAB	0.0001 acetone	Comedone formation†
Acetone, control	100.0	No comedones
Halowax, 1014 control	50.0 mineral oil	Comedone formation
Final product, herbicide	0.1‡	No comedones§
Final product herbicide	0.01‡	No comedones§

*3,4,3′,4′-tetrachloroazoxybenzene is indicated by TCAB.

†Comedone response most closely resembled 50% Halowax 1014.

‡Diluent unknown.

§Undisclosed source, written communication.

Table 3.—Aryl Hydrocarbon Hydroxylase (AHH) Induction in Chick Embryo Liver			
Substance*	Amount Injected, moles/egg	AHH Activity, pmole/mg liver/min	Response, %
Control solvent		1.34 ± 0.07	0
TCDD	4.7×10^{-11}	12.24 ± 0.86	100
TCAB	4.7×10^{-11}	6.88 ± 1.92	51
TCAB	4.7×10^{-10}	12.96 ± 3.99	107
TCAB	4.7×10^{-9}	16.73 ± 0.72	141

*2,3,7,8-tetrachlorodibenzo-*p*-dioxin is indicated by TCDD; 3,4,3′,4′-tetrachloroazoxybenzene, TCAB.

was administered for comparison. The TCAB is about one half as potent as TCDD. Both compounds elicited the same maximal induction of AHH, and maximally induced doses of both drugs administered simultaneously produced no greater response than that produced by either drug alone (data not shown).

COMMENT

The herbicide was manufactured in a two-story building subdivided into partially enclosed bays, and TCAB was formed as an extraneous intermediate during an early stage of the production. Exposure to TCAB occurred around centrifuges and discharge stills by direct skin contact during loading, unloading, and maintenance of equipment; sampling for laboratory analysis; and accidental breaks in pipes. Aerosolization of the TCAB during centrifugation with resultant inhalation or ingestion was also possible. Only a fraction of a percent of the contaminant TCAB is present in the final product (herbicide), and no chloracne has occurred in the plant where the herbicide is formulated. Equipment available for the workers included rubber aprons, face shields, sleeves, gloves, work uniforms, hard hats, safety glasses, and boots. The acne lesions ranged from large fluctuant cysts to typical straw-colored cysts, comedones, and pustules. In most workers the chloracne appeared during their first two months of employment (ranging from one week to eight months). It was not possible to fully evaluate the systemic complaints, except to determine that the workers with hirsutism and dark urine had no evidence of porphyria.

Family members of four workers, who had never been inside the plant, developed chloracne. Direct contact most probably occurred because contaminated work clothes or tools were brought home.

The company instituted significant personal hygiene and industrial engineering changes, but production ceased two months later without adequate evaluation of these improvements.

As has been the experience of others[1-4,11] we found chloracne to be extremely refractory to treatment with the usual measures employed for acne vulgaris. Acne surgery was probably most beneficial, and a combination of tetracycline and short courses of orally administered prednisone helped in those workers with severe inflammatory cases. A trial regimen of methotrexate, 25 mg every ten days for several months, did not help the most severely affected worker. Most recently, success in treating chloracne has been reported by Plewig,[12,13] with use of varying concentrations (0.05% to 0.3%) of vitamin A acid (retinoic acid) in different bases. We found vitamin A acid solution or cream to be beneficial in the mild cases with comedones and papules. Approximately 40% of the workers, including some of those with more severe cases, are now free of active acne lesions, including comedones. In one outbreak, chloracne was reported to persist as long as 15 years after all exposure to the chemical had ceased.[14] The most essential part of any treatment program is recognition of the problem and strict avoidance of any further exposure to the chloracnegen.

The acnegenicity of the TCAB was confirmed by use of rabbit ear bioas-

say, but other herbicide intermediates should also be investigated. The herbicide itself is not acnegenic and no chlorinated dibenzo-*p*-dioxins are produced during its manufacture. The chlorinated dibenzo-*p*-dioxins have a number of similarities to TCAB. The prototype compound, TCDD, is formed as a trace contaminant during the manufacture of the herbicide, 2,4,5-trichlorophenoxyacetic acid. This compound has produced chloracne in workers and has been experimentally produced in the rabbit ear test.[10] In addition, TCDD is hepatoxic, teratogenic, and porphyrinogenic.[5,10] Both TCDD and TCAB, at very low doses (10^{-10} moles/egg), induce hepatic AHH activity, a microsomal monooxygenase responsible for aromatic hydroxylation of numerous compounds.

Although there was no laboratory evidence of significant hepatotoxicity among the workers, a more complete and long-term physical and laboratory evaluation is indicated.

Evidence for chlorobenzene compounds causing chloracne is sketchy.[2] A few cases were reported during dichlorodiphenyltrichloroethane (DDT) manufacture,[15] and most recently chloracne has been reported in workers producing the herbicide 2,6-dichlorobenzonitrile.[16] Both reports are clinical and no studies on the toxicity of intermediate compounds are mentioned. Rimington and Ziegler[17] produced keratotic plugging of follicles with sebaceous gland atrophy after feeding rats 1,2,3,4-tetrachlorobenzene.

We know of two other outbreaks of chloracne from TCAB during herbicide manufacture, one in Great Britain (Donald Williamson, MB, written communication, May 1974) and the other in the United States. In the former cases electron microscopic studies of the pilosebaceous ducts were similar to those previously reported for acne vulgaris.[18]

The extreme toxicity of the herbicide intermediate TCDD has great environmental importance.[5,10] Because azobenzene compounds similar to TCAB may be produced in minute quantities by the action of soil bacteria on certain aniline pesticides,[19] TCAB may also have potential environmental impact.

In conclusion, chloracne is a cutaneous disease that represents one form of biologic response to certain chlorinated aromatic compounds. Chloracne serves as a marker of the medical and environmental impact of contamination of technical grade chemicals with potentially highly toxic intermediates.

Since the acceptance of this paper for publication, another article[20] has been published and shows the ability of TCAB and its congeners to induce AHH correlates with their capacity to induce acne.

This report was supported in part by the Cleveland Clinic Foundation research project CRP-100 and by the National Institute of Environmental Health Sciences grant 1-RO1-ES-00965-03.

References

1. Taylor JS: Chloracne: A continuing problem. *Cutis* 13:585-591, 1974.
2. Crow KD: A critical review, including a comparison of two series of acne from chloronaphthalene and pitch fumes. *Trans St Johns Hosp Dermatol Soc* 56:79-99, 1970.
3. Bauer H, Schulz KH, Spregelberg U: Occupational intoxications in manufacturing chlorophenol compounds. *Arch Gewerbepath* 18:538-555, 1961.
4. Bleiberg J, Wallen M, Brodkin R, et al: Industrially acquired porphyria. *Arch Dermatol* 89:793-797, 1964.
5. Kimbrough RD: Toxicity of chlorinated hydrocarbons and related compounds. *Arch Environ Health* 25:125-131, 1972.
6. *Pesticide Manual, British Crop Production Council*, ed 2. Worcester, England, 1971, p 165.
7. *Pesticide Manual, British Crop Production Council*, ed 3. Worcester, England, 1973, p 325.
8. Schlenker FS, Kitchell CL: Analysis of porphyrins in the clinical laboratory. *Am J Clin Pathol* 29:593-597, 1958.
9. Adams EM, Irish DD, Spencer HC, et al: The response of rabbit skin to compounds reported to have caused acneform dermatitis. *Ind Med Surg* 2:1-4, 1941.
10. Poland A, Glover EL: Studies on the mechanisms of toxicity of the chlorinated dibenzo-*p*-dioxins. *Environ Health Perspect*, experimental issue No. 5, 1973, pp 245-251.
11. Poland AP, Smith D, Metter G, et al: A health survey of workers in a 2,4,5-T plant. *Arch Environ Health* 22:316-327, 1971.
12. Plewig G: Vitamin A acid treatment of chloracne. *Hautarzt* 22:341-345, 1971.
13. Plewig G: Local treatment of chlorine acne (Halowax acne) with vitamin A acid. *Hautarzt* 21:465-470, 1970.
14. May G: Chloracne from the accidental production of tetrachlorodibenzodioxin. *Br J Ind Med* 30:276-283, 1973.
15. Bowen SS, Moursund MP: Chloracne in the manufacture of DDT. *Arch Dermatol* 75:743-746, 1957.
16. Deeken JH: Chloracne induced by 2,6-dichlorobenzonitrile. *Arch Dermatol* 109:245-246, 1974.
17. Rimington C, Ziegler G: Experimental porphyria in rats induced by chlorinated benzenes. *Biochem Pharmacol* 12:1387-1397, 1963.
18. Cunliffe WJ, Williams M, Edwards JC, et al: An explanation for chloracne: An industrial hazard. *Acta Derm Venereol* 55:211-214, 1975.
19. Bartha R, Pramer D: Pesticide transformation to aniline and azo compounds in soil. *Science* 156:1617-1618, 1967.
20. Poland A, Glover E, Kende AS, et al: 3,4,3',4'-Tetrachloro azoxybenzene and azobenzene: Potent inducers of aryl hydrocarbon hydroxylase. *Science* 194:627-630, 1976.

Frequency of Application on Percutaneous Absorption of Hydrocortisone

Ronald C. Wester, PhD; Patrick K. Noonan; Howard I. Maibach, MD

• This study determines the percutaneous absorption of hydrocortisone when applied as a single dose or on a repetitive basis. Application was to the shaved ventral forearm of the rhesus monkey, an animal model in which some relevance to man has been shown. Absorption was quantified by measuring ^{14}C in aliquots of urine over five days. There was no substantial difference in total absorption when 13.3 μg/sq cm was applied as a single dose or when the 13.3 μg/sq cm was applied three times, totaling 40 μg/sq cm. However, when 40 μg/sq cm was applied as a single dose, absorption was substantially increased over 13.3 μg/sq cm applied either once or three times. Additionally, when the skin was washed between applications to remove previously applied material in the three application experiment, there was a statistically significant increase over *not* washing the skin. The clinical importance of these results to man will await appropriate clinical studies.

(*Arch Dermatol* 113:620-622, 1977)

Most physicians, by tradition, recommend to patients that therapeutic agents be applied to skin on a repetitive basis. For instance, topical corticoids package inserts suggest two to four applications daily; in fact, in the hospital situation it is not unusual to apply it even more frequently. This study documents the effect of single repetitive application of hydrocortisone on the total quantity of compound absorbed. This study is performed in an animal model that may reflect the situation in man.

Accepted for publication Aug 13, 1976.

From the Department of Drug Metabolism, Searle Laboratories, Chicago (Dr Wester and Mr Noonan); and the Department of Dermatology, University of California School of Medicine, San Francisco (Dr Maibach).

Reprint requests to Department of Drug Metabolism, Searle Laboratories, Box 5110, Chicago, IL 60680 (Dr Wester).

MATERIALS AND METHODS

Absorption was quantified on the basis of the percent radioactivity excreted in urine for five days following application of a known amount of the labeled compound to the skin. This method used for measuring percutaneous penetration is the procedure of Feldmann and Maibach[1,2] that has been adapted to the rhesus monkey.[3] Methodology is detailed within these papers.

Female rhesus monkeys (4 to 8 kg), trained for metabolic studies, were randomly selected from the colony. The only criteria for selection was that the animal was clear of any previously administered ^{14}C-compound. Hydrocortisone labeled with radioactive carbon (^{14}C) was applied to lightly clipper-shaved skin of the ventral forearm. Previous experience with testosterone absorption showed that shaving does not alter penetration in this animal.[3] Each application dose contained 5 μCi of radioactivity. The area was not occluded[3] and the application area was always a constant 6 sq cm.

For topical application the monkeys were placed in a metabolism chair for the first 24 hours of the study. The hands of the monkey were secured to the sides of the chair to avoid its wiping off the applied compound. The animals were not anesthetized during the study. Hydrocortisone was applied to the skin in acetone, and the solvent quickly evaporated by gentle blowing. For the next 24 hours urine was collected in a container below the metabolism chair. Then the site of application was washed with soap and water and the monkey returned to a metabolism cage to continue the urine collection. In the metabolism chair the site of application is totally separated with a barrier from the area of urine collection. This insures against any possibility of chemical falling off the skin and contaminating the urine.

Daily urinary excretion values were corrected for excretion of radioactivity by other routes and retention of radioactivity in the body by administration of an intravenous dose of hydrocortisone ^{14}C.[3]

The percent dose excreted was based on the total amount of compound applied to the skin during the first 24-hour period. This would be the percent of the single dose applied, and when three applications, the percent of the total accumulated dose. All data were then calculated to percent absorption based on a square centimeter area.

RESULTS

The data for the percutaneous absorption of hydrocortisone are given in Tables 1 and 2 and in the Figure. Table 1 shows the percutaneous absorption values expressed as

Table 1.—Percutaneous Absorption of Hydrocortisone Following Single and Multiple Dose Applications to Rhesus Monkey Skin

Topical Dose, μg/ sq cm	Application*	No. of Animals	Percent Dose Excreted, hrs†					Total Absorption ±SD†	
			0-24	24-48	48-72	72-96	96-120	Percent	Area, μg/sq cm
13.3	1X	5	0.25	0.45	0.27	0.20	0.20	1.37 ± 0.97	0.18 ± 0.13
13.3	3X (no wash)	4	0.06	0.18	0.11	0.11	0.10	0.55 ± 0.06	0.22 ± 0.03
13.3	3X (wash)	3	0.17	0.21	0.16	0.08	0.10	0.72 ± 0.06	0.29 ± 0.02
40.0‡	1X	3	0.95	0.68	0.27	0.13	0.07	2.1 ± 0.6	0.84 ± 0.25

*1X is single dose applied for 24 hours, then area washed with soap and water. 3X is three applications (9 AM, 2:30 PM, 9 PM), then area washed with soap and water 24 hours after first application. "No wash" is dose applied over previous dose. "Wash" is area washed with soap and water immediately prior to applying next multiple dose.

†Values are corrected for incomplete excretion.

‡Data previously reported.[6]

percent absorbed and as micrograms of absorption per square centimeter area of application. Table 2 summarizes the statistical comparisons between group means for the absorption values as micrograms per square centimeter.

One application of 13.3 μg of hydrocortisone/square centimeter area was the baseline concentration applied to skin. When the same dose was applied three times (without any washing) there was a slight but not statistically significant increase in absorption.

The more important point is that when this is compared to one single application of 40 μg/sq cm, there was a large and statistically significant ($P < .05$) increase over 13.3 μg/sq cm applied either once or three times.

When the skin was washed between applications in the three application experiment, there was a statistically significant increase ($P < .05$) over not washing the skin.

COMMENT

It is not possible to compare this data to percutaneous absorption data from previous experiments as there is no literature available on the pharmacokinetics of single and multiple application of topical compounds.

The first question that might be asked is what is the relevance of the monkey to human percutaneous absorption. Limited experiments document that at least in some situations the parallel in penetration is striking. These experiments have been limited to application of the radioactive labeled chemical on the intact skin of

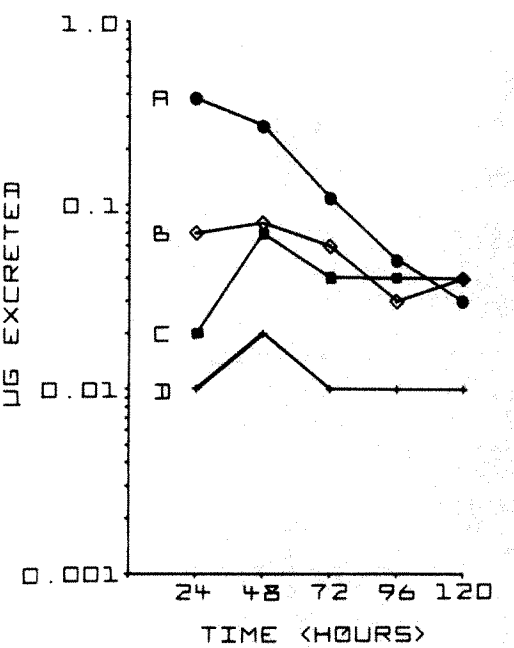

Effect of frequency of application on percutaneous absorption of hydrocortisone from ventral forearm of rhesus monkey. Ordinate is micrograms excreted and abscissa is time (hours). Each point represents mean microgram excreted in urine per square centimeter area of topical application of hydrocortisone. A is 40 μg/sq cm of hydrocortisone applied once; B and C are 13.3 μg/sq cm applied three times (total to 40 μg/sq cm) with area washed between applications for B; D is 13.3 μg/sq cm applied once.

Table 2.—Summary of Statistical Comparison Between Two Group Means: Absorptions as Micrograms per Square Centimeter Area

First Group, μg/sq cm	Secong Group, μg/sq cm	t Value*
13.3—1X	40—1X	5.00†
13.3—1X	13.3—3X (no wash)	0.53
13.3—1X	13.3—3X (wash)	1.35
40—1X	13.3—3X (no wash)	5.10†
40—1X	13.3—3X (wash)	3.80†
13.3—3X (no wash)	13.3—3X (wash)	3.87†

*Student two-tailed *t* test.
†Significant difference ($P < .05$).

the forearm of the rhesus monkey[3,4] and back skin of the squirrel monkey[5] in comparison to man. The compounds previously studied include hydrocortisone, testosterone, and benzoic acid in the rhesus and the pesticides DDT, gamma benzene hexachloride (lindane), parathion, and malathion in the squirrel monkey. Only for melathion was there a notable difference between a monkey (squirrel) and man. From these observations it appears that the forearm of the rhesus is a reasonable model for the forearm of man.

Additional correlative data are those of dose (concentration) response curve studies done on the percutaneous absorption of the rhesus monkey in vivo and man in vivo.[6] In these studies dose response curves for hydrocortisone, testosterone, and benzoic acid going from a range of 4 μg/sq cm to 400 μg/sq cm show similar results. This, again, suggests a close correlation between the two models for these three chemicals.

The results seen here are surprising, indeed. Common sense suggests that repeated applications would produce substantially more penetration. This is not the case for hydrocortisone in this model and in this vehicle system. We cannot predict that the same will occur for human skin, although the possibility does seem reasonable. There are also no data on diseased skin that would allow us to extrapolate to this at present. Also, we do not know if this observation will hold for other chemicals.

In the data for hydrocortisone it is clear that 40 μg/sq cm produced substantially more penetration than did the 13.3 μg/sq cm applied three times in the day. It is known from previous dose response studies[6] with one application that generally the more one applies to the skin the more penetration that will occur. This response is not necessarily linear for all compounds. The practical ramification is that it is possible that one application of a high concentration may in fact be more effective than several applications of a lower concentration. We emphasize, though, that this pharmacokinetic data should not be interpreted out of context but that it should point the way to appropriate clinical studies to verify this point.

It is curious that removing the hydrocortisone by washing did not decrease total penetration. Statistically, it produced an increase in penetration. We believe that this observation is of more than passing interest. In prior studies with pesticides (unpublished observations) we have repeatedly observed this phenomenon. This suggests that when we wash off compounds to decrease the chance of toxicity, we may be doing the exact opposite—,increasing the risk of toxicity. Perhaps it is that the soap and water wash hydrates the skin and this would account for the increased absorption when the skin is washed between applications. We do not wish to generalize on this but believe that these observations deserve serious consideration.

J. Pautsch and B. Nicolova, DVM, gave assistance in this study.

References

1. Feldmann RJ, Maibach HI: Percutaneous penetration of steroids in man. *J Invest Dermatol* 52:89-94, 1969.
2. Feldmann RJ, Maibach HI: Absorption of some organic compounds through the skin in man. *J Invest Dermatol* 54:399-404, 1970.
3. Wester RC, Maibach HI: Percutaneous absorption in the rhesus monkey compared to man. *Tox Appl Pharmacol* 32:394-398, 1975.
4. Wester RC, Maibach HI: Rhesus monkey as an animal model for percutaneous absorption, in Maibach H (ed): *Animal Models in Dermatology*. New York, Churchill Livingstone, 1975, pp 133-137.
5. Bartek MJ, LaBudde JA: Percutaneous absorption *in vitro* in Maibach H (ed): *Animal Models in Dermatology*. New York, Churchill Livingstone, 1975, pp 103-120.
6. Wester RC, and Maibach, HI: Relationship of topical dose and percutaneous absorption in rhesus monkey and man. *J Invest Dermatol* 67:518-520, 1976.

Perfume Dermatitis

A Study of 20 Patients

Walter G. Larsen, MD

• Patch tests to several screening sets of fragrance materials were performed on 20 perfume-sensitive patients. The most common allergens were found to be a jasmin synthetic (18 of 20 patients), cinnamic alcohol (15 of 20 patients), and hydroxycitronellal (9 of 20 patients). More than half of the patients were also contact sensitive to other ingredients of cosmetics and over-the-counter and prescription preparations.

***(Arch Dermatol* 113:623-626, 1977)**

Perfumes are complex mixtures consisting of a few to several hundred individual fragrance components. Because of their complexity, there is great difficulty in identifying specific fragrance components responsible for allergic reactions.

Perfume appears to be one of the major allergens found in cosmetics.[1] This study was attempted to identify the specific fragrance chemicals responsible for allergic reactions to perfumes. Cosmetic sensitivity was the complaint from 15 of 20 patients; reactions to over-the-counter or prescription creams accounted for the remaining five.

Accepted for publication Aug 27, 1976.

From the Department of Dermatology, University of Oregon Health Sciences Center, Portland.

Reprint requests to 2250 NW Flanders St, Portland, OR 97210 (Dr Larsen).

METHODS AND MATERIALS

Twenty perfume-sensitive patients were given patch tests during a one-year period (1975) with the following groups of allergens: (1) North American Contact Dermatitis Group (NACDG) Screening Series (Table 1); (2) Research Institute for Fragrance Materials (RIFM) Experimental Screening Series (Table 2); (3) Preservative Screening Series (experimental, designed by the NACDG) (Table 3); (4) Perfume Screening Series (experimental, designed by the NACDG) (Table 4); (5) Peruvian balsam components (Trolabs) (Table 5); and (6) Miscellaneous perfumes and fragrance materials (ie, anisyl alcohol, 5% in

Table 1.—North American Contact Dermatitis Group Screening Series (1975)*

1.	Nickel sulfate, 2.5%
2.	Potassium dichromate, 0.5%
3.	Neomycin sulfate, 20%
4.	Ethylenediamine, 1%
5.	Peruvian balsam, 25%
6.	Thimerosal (Merthiolate), 0.1%
7.	Ammoniated mercury, 1%
8.	Methylparaben, ethylparaben propylparaben, butylparaben, & benzylparaben mixture, 15% (3% of each)
9.	Formaldehyde solution, (2% aqueous)
10.	Paraphenylendiamine, 1%
11.	Turpentine, 1% (in olive oil)
12.	Caine mixture, 8% (benzocaine, dibucaine, tetracaine, and cyclomethycaine)
13.	Wood alcohols, 30%
14.	Mercapto mixture, 1%
15.	Disulfiram mixture, 1%
16.	Naphthyl mixture, 1%
17.	Paraphenylenediamine mixture, 0.60%
18.	Carba mixture, 3%
19.	Epoxy resin, 1%
20.	Lanolin, 100%
21.	*p*-tertiary-butyl phenol, 2%
22.	PCMX, 1% (*p*-chloro-m-xylenol)
23.	MBT, 1% (mercaptobenzothiazole)

*All prepared in white petrolatum unless otherwise indicated.

Table 2.—Research Institute for Fragrance Materials Testing Series*

1.	α-Amyl cinnamaldehyde, 2%
2.	Amyl salicylate, 5%
3.	Anisic aldehyde, 5%
4.	Benzyl acetate extra, 5%
5.	Benzyl alcohol, 5%
6.	Benzyl benzoate, 5%
7.	Cinnamic alcohol, 4%
8.	Citronellol, 5%
9.	Coumarin, 5%
10.	Diethyl phthalate, 5%
11.	Dimethyl phthalate, 5%
12.	Eugenol extra, 5%
13.	Geraniol pure, 5%
14.	Heliotropin extra, 5%
15.	Hydroxycitronellal, 5%
16.	Linalool synthetic, 5%
17.	Linalyl acetate, 5%
18.	Menthol natural, 5%
19.	Phenylethyl alcohol, 5%
20.	Terpineol alpha, 5%
21.	Methyl anthranilate, 1%
22.	Anethole, 1%
23.	Diphenyl oxide, 2%
24.	Isoeugenol, 5%
25.	β-Pinene, 1%
26.	Geranyl acetate, 2%
27.	α-Pinene, 5%
28.	Vanillin, 2%
29.	Benzophenone, 5%
30.	Thymol, 1%

*All prepared in white petrolatum.

petrolatum; Treemoss absolute in benzyl benzoate, 5% in petrolatum; and α-amyl cinnamic alcohol, 5% in petrolatum). Patients were also given patch tests to some partitioned components of perfumes when available.

The standard patch-testing technique with use of an aluminum-backed strip was employed. Patch tests were applied to the patient's back and were left for 48 hours. Readings were made at the time of removal or 24 hours after removal. Patients were instructed to return if an additional delayed reaction occurred. All the fragrance allergens were tested on 50 control patients with negative results. To avoid the "angry back" phenomenon, patients were tested during a period of several months.

Table 3.—Preservative Screening Series*

1. Butylated hydroxyanisole (BHA), 2%
2. Butylated hydroxytoluene (BHT), 2%
3. Ethylenediaminetetraacetic acid (EDTA), 1%
4. Imidazolidinyl urea (Germall-115), 2% in water
5. p-choro-m-cresol (chlorocresol, PCMC), 1%
6. Sorbic acid, 2%
7. Dichlorophen (G-4), 2%
8. 2-Bromo-2-nitropropane 1,3-diol (bronopol), 1% in water
9. PEG-8 (polyethylene glycol 400), as is
10. Stearyl alcohol (commercial grade), 30%
11. Quaternium-15 (Dowicil 200), 2% in water
12. Quaternium-15 (Dowicil 200), 2%
13. Captan (Vancide-89 RE), 2%
14. Triclosan (Irgasan DP 300), 2%

*All prepared in petrolatum unless otherwise indicated.

RESULTS

Tables 6 and 7 show the results of the study. Of the 20 patients tested, 2 representative cases are presented.

Table 4.—Perfume Screening Series*

1. Cinnamaldehyde, 1%
2. Cinnamic alcohol, 5%
3. Benzyl salicylate, 2%
4. Methyl salicylate, 2%
5. Benzyl benzoate, 2%
6. Benzyl alcohol, 5%
7. Musk ambrette 5%, in ethyl alcohol
8. Eugenol, 2%
9. Isoeugenol, 2%
10. Coumarin, 5%
11. Hydroxycitronellal, 4%
12. Jasmin absolute, 10%
13. Jasmin synthetic, 10%
14. Costus root oil, 0.1%
15. Oil of sandlewood, 2%

*All prepared in petrolatum, unless indicated.

REPORT OF CASES

Case 1.—An 82-year-old man had perianal dermatitis of 18 years' duration. He had used many different types of over-the-counter preparations containing local anesthetics, antihistamines, and antibiotics. Most recently, he had been using a cream that was a mixture of triamcinolone acetonide, neomycin sulfate, gramicidin, and nystatin (Mycolog). He was intolerant of most lubricating creams and antiperspirants.

He showed positive patch-test reactions to this cream itself and to the following constituents of the cream (see Tables 6 and 7): (1) neomycin; (2) ethylenediamine; and (3) perfume (E-1991). He showed positive patch-test reactions to the following dilu-

Table 5.—Peruvian Balsam and Balsam Components*

1. Peruvian balsam, 25%
2. Benzyl cinnamate, 5%
3. Eugenol, 2%
4. Methyl cinnamate, 5%
5. Benzyl benzoate, 5%
6. Vanillin, 10%
7. Cinnamic acid, 5%
8. Cinnamic alcohol, 5%
9. Cinnamaldehyde, 1%
10. Benzyl salicylate 2%

*All prepared in white petrolatum.

Table 6.—Fragrance Materials

	Patients*																				Total No. Positive
	1	2	3	4	5	6	7	8	9	10	11	12	13	14	15	16	17	18	19	20	
Patient age, yr	82	48	82	36	25	25	50	45	62	51	62	55	26	27	64	24	58	59	45	66	
Patient sex	M	F	M	F	F	F	M	F	F	F	M	F	M	F	F	F	F	M	F	F	
Synthetic aromatic chemicals																					
Cinnamic alcohol	+	+	+	+	+	+	+	−	−	+	+	+	−	+	+	−	+	+	+	−	15
Hydroxycitronellal	−	+	−	−	+	−	+	+	−	+	−	−	+	+	+	−	−	−	−	+	9
Citronellol	−	+	−	−	−	−	+	+	−	−	+	−	+	−	+	−	−	−	−	+	7
Cinnamaldehyde	+	+	−	−	+	−	−	−	−	−	−	−	−	−	+	−	+	+	−	−	6
Geraniol	−	−	−	−	−	−	+	−	−	−	+	+	+	−	+	−	−	−	−	+	6
Isoeugenol	−	+	−	−	−	−	−	−	−	−	−	+	−	+	−	+	+	−	−	−	5
Eugenol	−	+	−	−	−	−	−	−	+	−	−	+	−	+	−	−	−	−	−	−	4
Anisyl alcohol	−	−	−	+	+	+	−	−	−	−	−	−	−	−	−	−	−	−	+	−	4
Benzyl alcohol	+	−	−	−	+	+	−	−	−	−	−	−	−	−	−	−	−	−	−	−	3
Benzyl salicylate	−	−	+	−	+	−	−	−	−	−	−	−	−	−	−	−	−	−	−	−	2
Coumarin	−	−	+	−	+	−	−	−	−	−	−	−	−	−	−	−	−	−	−	−	2
α-Amyl cinnamic alcohol	+	−	−	−	−	−	−	−	+	−	−	−	−	−	−	−	−	−	−	−	2
Synthetic & natural substances																					
Jasmin synthetic	+	+	+	+	+	+	+	−	−	+	+	+	+	+	+	+	+	+	+	+	18
Jasmin absolute	−	+	−	+	+	+	−	−	−	−	−	+	−	+	−	−	−	−	+	−	7
Peruvian balsam	+	+	−	−	+	−	−	−	−	+	−	+	−	+	−	+	+	−	−	+	9
Treemoss absolute	−	−	+	−	+	+	+	−	−	−	−	−	+	+	−	−	−	−	−	−	6

*Positive reactions were noted for the following: patient 1, α-amyl cinnamaldehyde (2%) and hexyl cinnamaldehyde (2%); patient 3, resorcinol (2%) and amyl salicylate (5%); patient 5, benzyl acetate (5%), heliotropine (5%), benzyl benzoate (5%), and artificial oak moss resin (5%); patient 6, benzyl acetate (5%) and phenyl ethyl alcohol (5%); patient 7, artificial oak moss resin (5%); patient 11, α-terpineol (5%), anethole (1%), camphor (5%), eucalyptus (5%), sandlewood oil (2%), terpinyl acetate (5%), resorcinol (2%), isopulegol (5%), and artificial oak moss resin (5%); and patient 14, natural menthol (5%), thymol (1%), and isopulegol (5%). When patient 6 was initially tested, she had negative reactions to benzyl acetate, phenyl ethyl alcohol and natural jasmin, which later became positive.

Table 7.—Miscellaneous Allergens

	Patients*																				Total No. Positive
	1	2	3	4	5	6	7	8	9	10	11	12	13	14	15	16	17	18	19	20	
Patient age, yr	82	48	82	36	25	25	50	45	62	51	62	55	26	27	64	24	58	59	45	66	
Patient sex	M	F	M	F	F	F	M	F	F	F	M	F	M	F	F	F	F	M	F	F	
Allergens																					
Ethylenediamine	+	–	–	–	–	–	–	–	+	+	–	+	–	–	–	–	–	–	–	+	5
Caine mixture	+	–	+	–	–	–	–	–	–	+	+	–	+	–	–	–	–	–	–	+	6
Neomycin	+	–	–	–	–	–	–	–	–	+	+	–	–	–	–	–	–	–	–	–	3
Lanolin	–	+	–	–	–	–	–	–	–	+	–	+	–	–	+	–	–	–	–	–	4
Wood alcohol, 30%	–	–	–	–	–	–	–	–	–	+	–	–	–	–	+	–	–	–	–	–	2
Dichlorophen	–	+	+	–	–	–	–	–	–	–	–	NT†	–	+	–	–	–	–	–	–	3
Formaldehyde solution	–	+	–	–	–	–	–	–	–	–	–	–	–	–	–	–	+	–	–	+	3
Quaternium-15	–	+	–	–	–	–	–	–	–	–	–	–	–	–	–	–	–	–	–	+	2

*Positive reactions were noted for the following: patient 3, sorbic acid (2%), potassium dichromate (0.5%), and methyl paraben (5%); patient 4, imidazolidinyl urea (2%); patient 5, nickel sulfate (2.5%), ammoniated mercury (1%), and *p*-phenylenediamine mixture (0.6%); patient 10, nickel sulfate (2.5%), thiuram mixture (1%), and carba mixture (3%); patient 12, thiuram mixture (1%) and carba mixture (3%); patient 14, nickel sulfate (2.5%) and ammoniated mercury (1%); patient 16, *p*-phenylenediamine (2%); and patient 17, potassium dichromate (0.5%).

Table 8.—Multiple Positive Reactions (Patient 2)

1. Cinnamic alcohol
2. Cinnamaldehyde
3. Hydroxycitronellal
4. Citronellol
5. Eugenol
6. Isoeugenol
7. Peruvian balsam
8. Jasmin synthetic
9. Jasmin absolute
10. Lanolin
11. Quaternium-15 (Dowicil-200)
12. Dichlorophen
13. Formaldehyde
14. Many perfumes and cosmetics

tions of the perfume: 5% concentration in petrolatum, 0.5% in petrolatum, 0.05% in petrolatum; there was a negative response at 0.005% in petrolatum.

The 28 components of the cream's perfume were tested individually at a concentration of 5% in petrolatum, and positive reactions to cinnamic alcohol, amyl cinnamic alcohol, and benzyl alcohol were noted.

This patient reacted in the following manner to various concentrations of cinnamic alcohol: positive at 5% concentration in petrolatum, 0.5% in petrolatum, 0.1% in petrolatum, and 0.05% in petrolatum. There was a negative reaction at 0.005% in petrolatum.

CASE 2.—A 48-year-old woman had contact dermatitis of the face and neck. She stated that for years she has reacted adversely to almost all perfumes, cosmetics, and creams.

Patch-testing elicited many positive reactions (Table 8). The dermatitis was finally cleared when she began using nonfragranced materials that were also free of lanolin, quaternium-15 (Dowicil-200), and dichlorophen. It may be noted that quaternium-15, which is a formaldehyde releaser, is finding increasing use as a preservative in topical preparations, and that dichlorophen is used as a preservative in foot powder and in lubricants such as Nivea cream.

COMMENT

Fifteen of the 20 patients came to the office with dermatitis due to a cosmetic. The remaining five patients had dermatitis from a topical medicament (four due to a prepared cream [Mycolog] and one due to a liquid preparation containing phenol and camphor [Campho-Phenique] and a prepared cream containing benzocaine, chlorothymol, and resorcinol [Lanacane]). Five patients were allergic to the prepared cream (Mycolog) (one past relevant) and had positive reactions to ethylenediamine and also to the perfume. Allergy to the perfume in Mycolog cream has previously been reported.[2,3]

Five patients had axillary dermatitis due to the perfume in their deodorant or antiperspirant. From their clinical history, many of the other patients were intolerant of various deodorants and antiperspirants.

I postulate that many of these patients were sensitized to the fragrance materials and other allergens by using topical preparations on eczematous skin. Irritated or eczematous skin is known to be more readily sensitized than normal skin. Some of the patients allergic to cosmetics were possibly sensitized by the use of underarm deodorants or antiperspirants, or both. These preparations are used frequently on a daily basis in a warm, moist occluded area subject to friction. Irritation from axillary shaving plus the presence of an irritant (aluminum salts) might also facilitate sensitization.

A surprising finding in the study was the frequency of positive reactions to other ingredients commonly found in topical medicaments and cosmetics. Allergens, which produced positive reactions, included lanolin, ethylenediamine, neomycin, caine mixture, dichlorophen, methylparaben, quaternium-15, imidazolidinyl urea (Germall 115), sorbic acid, and formaldehyde solution. Some fragrance materials such as benzyl alcohol and benzyl benzoate are used as preservatives as well as in perfumes.

Cinnamic alcohol and hydroxycitronellal were the chemical components most frequently responsible for perfume allergy in the 20 patients. However, in most patients, more than one fragrance substance produced a positive reaction. Nine of 20 patients showed positive reactions to Peruvian balsam. It seems possible that a synthetic jasmin used by the NACDG may prove to be a superior perfume-screening mixture, since 18 of 20 patients showed positive reactions to this formulation.

Cinnamic alcohol is a synthetic aromatic alcohol that is widely used in perfume compositions. Use in frag-

rances in the United States amounts to approximately 6,818 kg per year.[4] Cinnamic alcohol and its esters have been reported to occur in about a dozen natural products, mainly in various resins and balsams.

Predictive testing utilizing the Kligman maximization test on 25 volunteers at a concentration of 4% in petrolatum produced no sensitization reactions to cinnamic alcohol.[4] Jordan repeated this experiment in 1975 with similar results.[5] He then repeated the Kligman maximization test using a different vehicle (ie, cinnamic alcohol, 4%, in ethyl alcohol), and 1 of 27 males was sensitized. Cinnamic alcohol, 4%, in ethyl alcohol was also simultaneously tested by a modified Draize technique, and 4 of 150 subjects were sensitized (4 of 33 females, and 0 of 122 males).[5]

Hydroxycitronellal is one of the most frequently used floralizing perfume materials. Use in fragrances in the United States amounts to more than 22,727 kg per year.[6] Hydroxycitronellal has not been found to occur in nature. However, it is an indispensable ingredient in most perfume compositions.

Hydroxycitronellal tested with the Kligman maximization test on 25 volunteers produced no sensitization reactions.[6] Jordan sensitized 1 of 150 subjects using hydroxycitronellal, 4%, in petrolatum, with the Draize predictive test.[5]

Gutman and Somov patch-tested patients with eczema who worked in a perfume factory with a battery of fragrance materials.[7] They found that cinnamic alcohol was the most common allergen (13 positive reactions in 22 fragrance-sensitive patients). In a more recent study, Novak found that three of ten fragrance-sensitive patients were allergic to cinnamic alcohol.[8]

Some fragrance chemicals are used in dentistry (eugenol), in counterirritants (eugenol, menthol, and camphor), and as preservatives in topical preparations (benzyl alcohol and benzyl benzoate). Chemicals of the cinnamate family are used in toothpastes and sunscreens. Fragrances are frequently used in medicated topical preparations including some topical prescription medications. Therefore, in the evaluation of a patient with contact dermatitis due to a cosmetic or topical medicament, it is important to test with the fragrance component of the preparation.

Fragrance materials that are reported to be sensitizers should be deleted from preparations designed for use on irritated or dermatitic skin.

References

1. Hannuksela M, Kousa M, Pirila V: Allergy to ingredients of vehicles. *Contact Dermatitis* 2:105-110, 1976.
2. Goldberg HS: Allergic contact dermatitis from the perfume in Mycolog cream. *Arch Dermatol* 105:896-897, 1972.
3. Coskey RJ, Bryan HG: Contact dermatitis due to perfume in Mycolog cream. *Arch Dermatol* 111:131, 1975.
4. Opdyke DLJ: Monographs on fragrance raw materials: Cinnamic alcohol. *Food Cosmet Toxicol* 12:855, 1974.
5. Jordan WP: The maximazation and the modified draize revisited. Read before the American Academy of Dermatology meeting, San Francisco, December 1975.
6. Opdyke DLJ: Monographs on fragrance raw materials: Hydroxycitronellal. *Food Cosmet Toxicol* 12:921, 1974.
7. Gutman SG, Somov BA: Allergic reactions caused by components of perfumery preparations. *Vestn Dermatol Venereol* 12:62-66, 1968.
8. Novak M: Contact sensitization in perfume composition components in antiphlogistic ointment. *Czech Dermatol* 49:375-378, 1974.

Abnormal Vascular Reactions in Atopic Dermatitis

Masami Uehara, MD, Shigeo Ofuji, MD

• Vascular reactions to mechanical stroking, topical application of nicotinic acid ester, and methacholine chloride were examined in both the normal and abnormal skin of 100 patients with atopic dermatitis and 20 patients with allergic contact dermatitis. White dermographism, nicotinic acid blanching, and delayed blanch with methacholine consistently occurred in areas of skin with eczematous change of patients with atopic dermatitis and those with allergic contact dermatitis. Normal skin of atopic patients did not show the abnormal vascular reactions. It is suggested that white dermographism, nicotinic acid blanching, and delayed blanch with methacholine seen in atopic dermatitis are secondary phenomena that give no definite information concerning the diagnosis of this disease.

(*Arch Dermatol* 113:627-629, 1977)

Patients with atopic dermatitis commonly show abnormal vascular reactions to mechanical and pharmacologic stimuli. Stroking on the skin is not followed by the normal "triple response," instead there is white dermographism. Lobitz and Dobson[1,2] state that the phenomenon of white dermographism has clinical, diagnostic, and prognostic significance for atopic dermatitis because it is the first to appear as the skin begins to become involved in atopy and it is the last to disappear when the skin is returning to normal. Epicutaneous absorption of nicotinic acid esters normally produces erythema, but yields an "anemic reaction" in patients with atopic dermatitis. The nicotinic acid blanching has also been used as a diagnostic test for atopic dermatitis.[3,4] Intracutaneous injection of methacholine chloride is normally followed by reddening, while patients with atopic dermatitis exhibit blanching around the wheal. The delayed blanch, according to Lobitz and Dobson,[1,2] has great diagnostic significance for atopic dermatitis in the same way as white dermographism. Various investigators[5,6] believe that a thorough knowledge of the abnormal vascular reactions might lead to a better understanding of the pathogenesis of atopic dermatitis.

From a review of the literature,[1-12] however, it was difficult to determine whether patients with atopic dermatitis produce the abnormal vascular responses in both the involved and uninvolved skin or exhibit the abnormal reactions only in their affected skin.

In the present study we examined vascular responses to mechanical stroking, topical application of nicotinic acid ester, and methacholine simultaneously in the diseased and normal skin of patients with atopic dermatitis. The results also are compared with the vascular reactivity of the affected skin of patients with allergic contact dermatitis to the same mechanical and pharmacologic stimuli.

Accepted for publication Sept 13, 1976.

From the Department of Dermatology, Kyoto University, Shogoin Sakyo-ku, Kyoto, Japan.

Reprint requests to Department of Dermatology, Kyoto University, Shogoin, Sakyo-ku, Kyoto, Japan (Dr Uehara).

SUBJECTS AND METHODS

A total of 100 patients with atopic dermatitis, 50 children and 50 adults, were selected for this study. The diagnosis was made on the basis of morphology and distribution of skin lesions, clinical course, and a positive family history of respiratory atopy or eczema.

Clinical controls were 20 adult patients with allergic contact dermatitis (12 were cases of contact dermatitis due to cosmetics; 3, cement dermatitis; 2, rubber dermatitis; 2, watchband dermatitis; and 1, photoallergic contact dermatitis due to bithionol). All had suffered from the dermatitis for more than a year. They had lichenified lesions on the face or the forearms. Personal or family history of asthma or eczema was present in (3) of the 20 controls.

Test Sites

The following test sites were used for patients with atopic dermatitis: (1) lichenified patch on the face, the trunk, or the antecubital fossa; (2) dry and rough skin on the trunk or the forearm, which had sallow complexion and exhibited keratosis pilaris-like papules (evidence of scratching was often present); and (3) normal-appearing, bright, and smooth skin on the trunk or the forearm. (Severe cases with acute exacerbation were omitted from this study because the total body of such patients was frequently covered by skin eruptions and dry and rough skin.)

For those patients with allergic contact dermatitis, the following test sites were used: (1) lichenified patch on the face or the

forearm and (2) normal skin on the trunk or the forearm.

Tests with stroking were performed by the test site being firmly stroked with a blunt instrument. Readings of dermographism were classified into red, intermediate, or white.

Tests with tetrahydrofurfuryl ester of nicotinic acid (Trafuril) were performed by a drop of 0.5% thurfyl nicotinate solution placed on the test site and covered with a piece (1 × 1 sq cm) of cellophane. After 15 minutes of the application, readings were made as follows: (1) red indicated severe redness with or without central edema; (2) intermediate, very weak erythema or no reaction; and (3) blanching, substantial pallor with or without peripheral erythema.

Tests with methacholine chloride (Mecholyl) were performed as follows: instead of the intradermal injection, topical application of a drop of 1:1,000 methacholine solution was placed on the test site and the reactions were read as described in the thurfyl nicotinate test.

Histological Examination

Eight biopsy specimens were obtained from the sallow and dry skin on the upper back of adult patients with atopic dermatitis.

RESULTS

Reactions to Stroking

Patients with atopic dermatitis usually produced white dermographism if their lichenified skin was stroked (Table 1). In the sallow and dry skin of these patients, intermediate or white reactions were commonly obtained. When the normal skin without these skin changes was stroked, a typical red line was produced almost constantly. Patients with allergic contact dermatitis showed intermediate or white dermographism if their lichenified skin was stroked (Table 2). When their normal skin was tested, a typical red line occurred constantly.

Reactions to Thurfyl Nicotinate

Patients with atopic dermatitis consistently produced abnormal vascular reactions to thurfyl nicotinate if the test was performed on their lichenified skin (Table 3). In their sallow and dry skin, the reaction also was abnormal in most patients. In their normal-appearing, bright, and smooth skin, however, typical erythematous reactions occurred in almost all of the cases. Patients with allergic contact dermatitis produced abnormal reactions to thurfyl nicotinate if the test was done on their lichenified skin (Table 2), but they showed typical erythematous reactions in their normal skin.

Table 1.—Dermographism in Atopic Dermatitis

Dermographism	Normal Skin	Dry & Rough Skin	Lichenified Skin
Red	96	3	0
Intermediate	3	21	14
White	1	76	86
Total	**100**	**100**	**100**

Table 2.—Vascular Reactions in Contact Dermatitis

	Dermographism		Thurfyl Nicotinate Reaction		Methacholine Chloride Reaction	
Vascular Reactions	Normal Skin	Lichenified Skin	Normal Skin	Lichenified Skin	Normal Skin	Lichenified Skin
Red	20	0	19	0	20	0
Intermediate	0	2	1	7	0	4
White	0	18	0	13	0	16
Total	**20**	**20**	**20**	**20**	**20**	**20**

Table 3.—Thurfyl Nicotinate Reaction in Atopic Dermatitis

Thurfyl Reaction	Normal Skin	Dry & Rough Skin	Lichenified Skin
Red	92	5	0
Intermediate	7	44	37
White	1	51	63
Total	**100**	**100**	**100**

Table 4.—Methacholine Chloride Reaction in Atopic Dermatitis

Methacholine Reaction	Normal Skin	Dry & Rough Skin	Lichenified Skin
Red	92	6	2
Intermediate	4	36	23
White	4	58	75
Total	**100**	**100**	**100**

Reactions to Methacholine

Patients with atopic dermatitis almost constantly produced abnormal vascular reactions to methacholine when the test was done on the lichenified skin or the sallow and dry skin (Table 4). But most patients exhibited normal red reactions if the test was performed on their normal, bright, and smooth skin. Patients with allergic contact dermatitis also produced abnormal reactions to the drug if the test was performed on their lichenified skin (Table 2). All of these patients, however, showed typical red reactions when the tests were performed on the normal skin.

Histology of the Sallow and Dry Skin of Atopic Dermatitis

Focal areas of parakeratosis, mild acanthosis, and slight intercellular edema were present in all of the specimens examined (Fig 1). Spongiotic vesicles and migration of mononuclear cells were often seen in the surface epidermis as well as in the follicular wall (Fig 2). The dermis contained perivascular infiltrates of predominantly mononuclear cells.

COMMENT

The present study demonstrated that lichenified skin of patients with atopic dermatitis consistently produced white dermographism, nicotinic

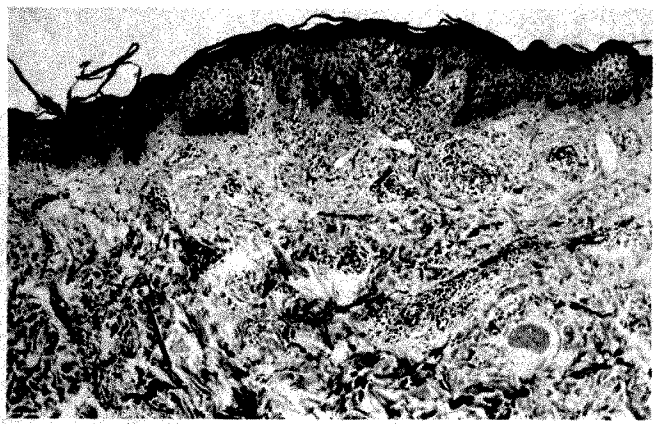

Fig 1.—Sallow and dry skin of atopic dermatitis. Epidermis shows mild acanthosis and intercellular edema. Dermis contains perivascular infiltrate of mononuclear cells (hematoxylin-eosin, original magnification ×40).

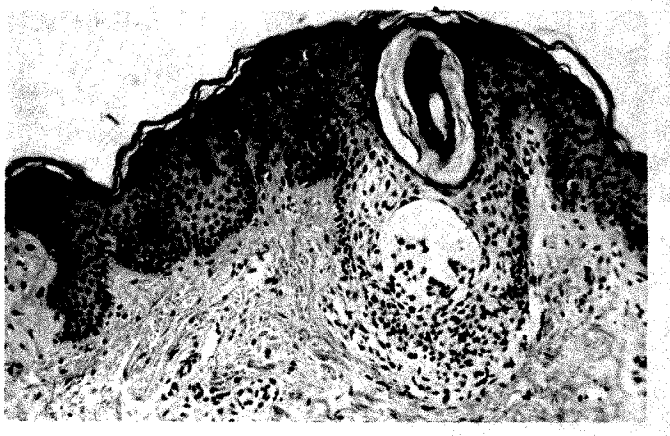

Fig 2.—Follicular change in sallow and dry skin of atopic dermatitis. Note spongiosis, vesicle formation, and mononuclear cell infiltrate (hematoxylin-eosin, original magnification ×100).

acid blanching, and delayed blanch with methacholine, while normal-appearing, bright, and smooth skin of these patients did not show the abnormal vascular reactions.

Several investigators have already pointed out that it is the affected skin of atopic patients that exhibits white dermographism,[2-8] pallor reaction to nicotinic acid ester,[5] and delayed blanch with methacholine.[2-9] But others have reported that the abnormal vascular reactions occur in both the involved and uninvolved skin of these patients.[10-12] The difference of opinions might be due largely to the difficulty to define the "uninvolved skin" of patients with atopic dermatitis. To our knowledge, there is no universally accepted concept of the uninvolved skin of this disease. But it is generally agreed that the skin manifestation of atopic dermatitis consists of eczematous patch, lichenified plaque, and prurigo.[13,14] Therefore, the uninvolved skin may be defined as areas of skin where the three types of skin lesion are absent. On the basis of this concept, in the present study we classified the uninvolved skin of atopic dermatitis into two categories, ie, the bright and smooth skin and the sallow and dry skin. Then, it became evident that the sallow and dry skin almost constantly yielded the paradoxic vascular reactions to mechanical stroking and topical application of thurfyl nicotinate or methacholine. This sallow and dry skin histologically showed an eczematous change in the surface epidermis or in the follicular epidermis. The histologic change of follicular wall resembled that of "follicular eruptions" of atopic dermatitis.[15] Thus, it appears evident that the sallow and dry skin is a manifestation of eczematous inflammation of atopic dermatitis, although this dry skin has been included with the stigmata of unaffected skin of the disease.[16] It is therefore most reasonable to consider that patients with atopic dermatitis show the abnormal vascular reactions only in their skin sites where an eczematous change exists.

The present study also demonstrated that the lichenified skin of patients with allergic contact dermatitis constantly produced white dermographism, nicotinic acid blanching, and delayed blanch with methacholine, while the normal skin of these patients did not show the abnormal vascular reactions. This strongly suggests that all these paradoxic vascular responses can occur over areas of skin with eczematous change of a different cause. We therefore believe that the white dermographism, nicotinic acid blanching, and delayed blanch with methacholine seen in atopic dermatitis are secondary phenomena that may give no definite information concerning the diagnosis of this disease.

References

1. Lobitz WC, Dobson RL: Physical and physiological clues for diagnosing eczema. *JAMA* 161:1221-1229, 1956.
2. Lobitz WC: Atopic dermatitis. *J Dermatol* 3:39-44, 1976.
3. Illig L: Die Reaktion der Haut des Neurodermitikers auf zwei nikotinsäureesterhaltige Reizstoffe. *Derm Wochenschr* 126:753-763, 1952.
4. Schultz H, Zachariae H: The trafuril test in recurrent juvenile eczema of hands and feet. *Acta Dermatovenereol* 52:398-400, 1972.
5. Murrell TW, Taylor WM: The cutaneous reaction to nicotinic acid (niacin)-furfuryl. *Arch Dermatol* 79:545-552, 1959.
6. Champion RH: Abnormal vascular reactions in atopic eczema. *Br J Dermatol* 75:12-15, 1963.
7. Davis MM, Lawler CJC: Observations on the delayed blanch phenomenon in atopic subjects. *J Invest Dermatol* 30:127-132, 1958.
8. Reed WB, Kierland RR, Code CF: Vascular reactions in chronically inflamed skin: I. Mechanical stimuli to the skin; inhibition of white dermographism. *Arch Dermatol* 77:91-96, 1958.
9. Reed WB, Kierland RR: Vascular reactions in chronically inflamed skin: II. Action of epinephrine and phentolamine (Regitine); action of acetylcholine and methacholine (Mecholyl), and the "delayed blanch." *Arch Dermatol* 77:181-186, 1958.
10. Engelhardt AW: Hautreaktion auf Nikotinsäurebenzylester und ihre Bedeutung für die Differentialdiagnostik von Dermatosen. *Hautarzt* 12:346-355, 1961.
11. Thomsen K, Osmunsen PE: Guanethidine in the treatment of atopic dermatitis. *Arch Dermatol* 92:418-421, 1965.
12. Rajka G: *Atopic Dermatitis.* London, WB Saunders, 1975, pp 111-121.
13. Sulzberger MB, Wolf J, Witten VH, et al: *Dermatology, Diagnosis and Treatment,* ed 2. Chicago, Year Book Publishers Inc, 1961, pp 196-226.
14. Schnyder UW, Borelli S: Neurodermitis constitutionalis sive atopica, in Jadassohn J (ed): *Handbuch der Haut- und Geschlechtskrankheiten,* vol II/1. Berlin, Springer-Verlag, 1962, pp 228-253.
15. Ofuji S, Uehara M: Follicular eruptions of atopic dermatitis. *Arch Dermatol* 107:54-55, 1973.
16. Sulzberger MB: Atopic dermatitis: III, in Fitspatrick TB, Arnt KA, Clark WH, et al (eds): *Dermatology in General Medicine.* New York, McGraw-Hill Book Co Inc, 1971, pp 687-697.

Elastosis Perforans Serpiginosa Induced by Penicillamine

Electron Microscopic Observations

Nevelle Kirsch, MD, Peter B. Hukill, MD

• **A patient with Wilson disease, under prolonged treatment with penicillamine, developed lesions of elastosis perforans serpiginosa (EPS). Examination of biopsy specimens by light microscopy revealed the characteristic changes of EPS. Examination by transmission electron microscopy revealed structural changes in the elastic fibers not previously described. The appearance of the lesions by scanning electron microscopy is described for the first time. It is suggested that penicillamine induced EPS may be morphologically distinct from the idiopathic form.**

(*Arch Dermatol* 113:630-635, 1977)

Elastosis perforans serpiginosa (EPS) is a skin disease manifested by keratotic papules in an annular or serpiginous pattern. Often the annular lesions tend to spread peripherally, leaving atrophic and sometimes hypopigmented skin in the center. The basic histological defect seems to be a localized abnormality of dermal elastic fibers, which increase in size and number and penetrate the epidermis, where they fill a tract or canal that extends to the surface, allowing the fibers to be extruded from the body. The abnormal elastic fibers in the dermis also incite an inflammatory response, sometimes polymorphonuclear, but often characterized by granulomas that may contain giant cells actively phagocytozing and destroying the injured elastic material.[1]

The disease was first described by Lutz[2] in 1953, and as further defined by Miescher[3] and others,[4] it is generally accepted as a distinct clinical and pathological entity. Although it most often appears as an isolated lesion, about one fourth of reported cases of EPS have been associated with generalized systemic disorders, such as Down syndrome (mongolism), or with specific connective tissue defects, including the Ehlers-Danlos syndrome, osteogenesis imperfecta, pseudoxanthoma elasticum, Marfan syndrome, and cutis laxa.[1-5] The lesions may be confined to one anatomic area, often the neck, sometimes the extremities, but disseminated lesions have been described.[6]

Elastosis perforans serpiginosa has been reported in four patients under treatment with penicillamine for Wilson disease,[7,8] but it has not been reported associated with untreated Wilson disease. Penicillamine has been associated with a variety of other skin changes, including hemorrhages and easy bruising, allergic eruptions, milia, peeling and desquamation, cheilosis, stomatis, glossitis, and vulvar ulcers.[8-10] It has also been held responsible for an instance of congenital diffuse connective tissue defect in an infant whose mother received penicillamine during pregnancy,[11] and for a case of cutis hyperelastica.[12] Therefore, it would appear very likely that penicillamine either directly or indirectly produces the lesions of EPS. Assuming that penicillamine does in fact produce the EPS lesion, it appears that study of the effects of the drug might shed light on the pathogenesis of EPS in general and perhaps on other elastic and connective tissue disorders.

Wilson disease, or hepatolenticular degeneration, is an inborn error of metabolism, characterized by accumulation of excessive amounts of copper in the brain, the liver, and other tissues, leading to progressive neuro-

Accepted for publication April 23, 1976.

From the Departments of Medicine (Dermatology) (Dr Kirsch) and Pathology (Dr Hukill), University of Connecticut School of Medicine, Farmington, Conn.

Reprint requests to Department of Pathology, University of Connecticut Health Center, Farmington, CT 06032 (Dr Hukill).

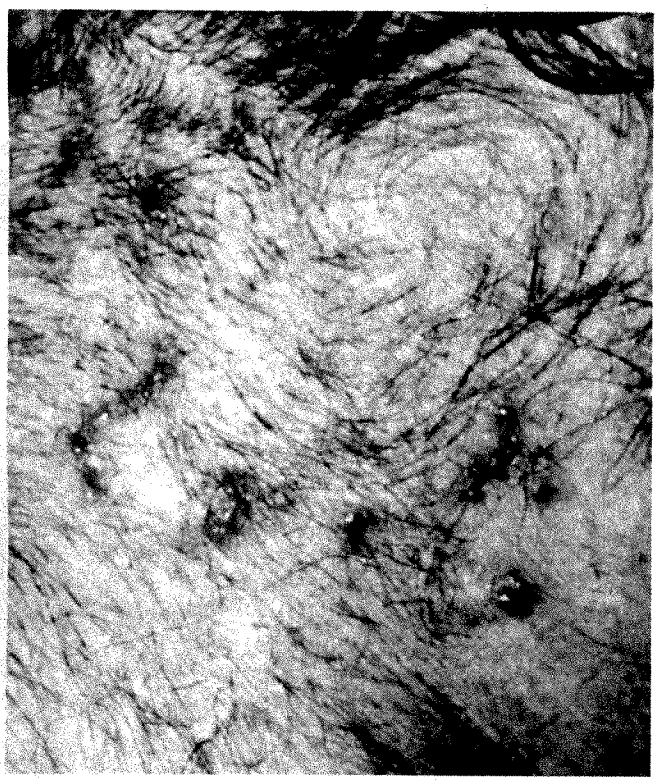

Fig 1.—Raised, keratotic papules, coalescent to form serpentine and arciform pattern on sides of neck.



Fig 2.—Discoid, firm bordered elevated lesion with central fibrosis and semicircular area of ulceration.

logic deficits and to cirrhosis. Serum copper is low, while copper absorption, as well as urinary excretion are elevated. It would appear that the basic defect is a deficiency in an enzyme that facilitates the binding of copper to the plasma copper-binding protein, apoceruloplasmin. Thus, plasma free copper is high and is transferred to the tissues in unrestricted amounts.[13] Penicillamine is a chelating agent that binds copper and is excreted in the urine. Its administration to patients with Wilson disease will deplete the excessive copper deposits and arrest the progress of the disease.

REPORT OF A CASE

This 22-year-old man first consulted the senior author for a dermatologic problem in June 1972. The patient stated that he had noted the onset of an eruption in 1971, mostly confined to the sides of his neck and back. The lesions were asymptomatic with only very infrequent, mild pruritus. The skin lesions had slowly evolved over the preceding year.

Dermatological examination on his initial office visit showed multiple lesions on the sides of the neck, the anterior portion of the neck, and the nape of the neck, consisting of keratotic papules, both discrete and in linear and arcuate patterns (Fig 1). The surrounding skin was normal in appearance. In July 1972, there was noted the appearance of a single, red, firm papule on the glans penis, which has slowly and progressively enlarged to form a ringed lesion.

The patient was again seen in September 1972, at which time there was noted a red, macular, and irregular patch of redness that was firm to the touch on the right side of the glans penis.

In August 1974, there was progression of the lesion on the penis, which now measured about 2 cm in diameter. At this examination, there was a discoid, firm bordered, elevated lesion with a central depressed area, and within the inner margin of the hyperkeratotic ring, there was a semicircular area of ulceration (Fig 2).

The patient had known Wilson disease since 1958 when he was 9 years old. At that time, he had an enlarged liver, dystonic facies, dysarthric speech, and dystonic posturing of the right upper extremity. Oral administration of penicillamine was started, at a dosage of 1 gm per day. After several months the dose was increased to 2 gm per day and maintained at that level for several years.

The patient was seen for a follow-up examination by his neurologist in April 1965, at which time his main complaint was easy bruising over the extensor surfaces of the elbows and knees on very mild trauma. The patient stated that the bruises persisted for at least a few weeks after mild contact. At that time, the hepatic status was stable, and slight neurological improvement had been achieved with penicillamine therapy, 2 gm per day, but the patient was very concerned about the ecchymotic skin lesion from a cosmetic point of view. The neurologist was reluctant to change the apparently successful regimen and treatment of a serious illness for merely cosmetic reasons. However, since the skin lesions appeared to some extent dose related, it seemed acceptable to try to decrease the dose to 1.5 gm of penicillamine per day.

A further report from the neurologist in July 1972, showed that the patient was taking penicillamine in a dosage that varied from 1.5 to 2 gm per day. He had noted some easy bruising, but had not developed any large ecchymoses at this time. The neurologist advised that the patient continue to take 2 gm of penicillamine daily, and pyridoxine hydrochloride, 50 mg a day, until he returned at a later date for follow up.

Biopsy specimens were taken from the neck lesions on July 11, 1972 and on Jan 10, 1975. The latter was examined electron microscopically.

Light Microscopic Findings

Both biopsy specimens showed simi-

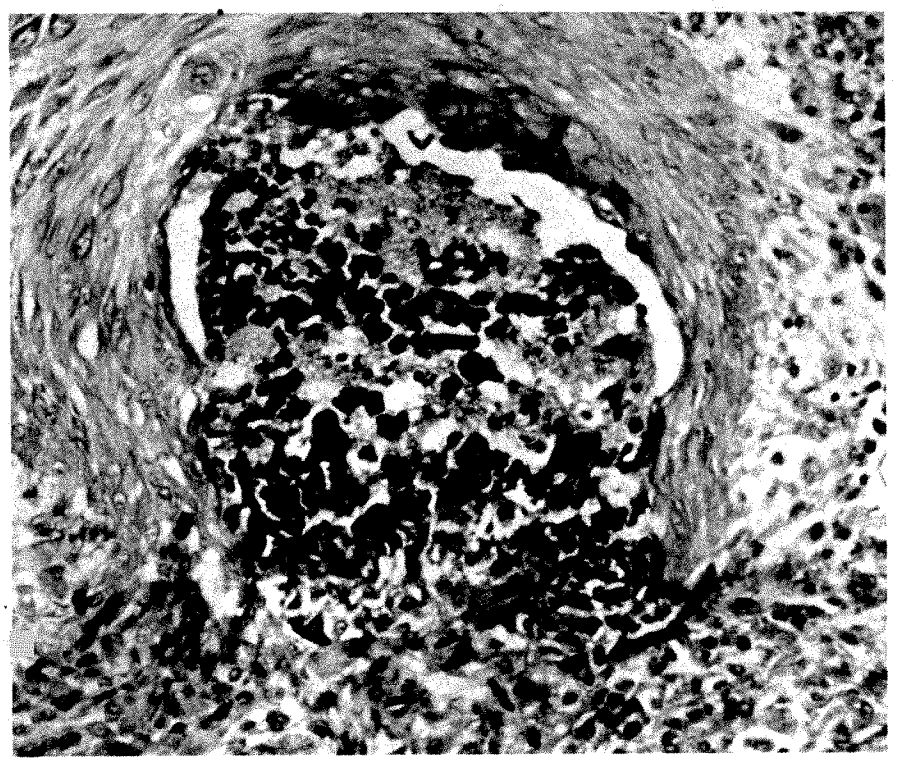

Fig 3.—Pathognomonic lesion of elastosis perforans serpiginosa. Coarse eosinophilic elastic fibers are found within the epidermis (hematoxylin-eosin, green filter, original magnification ×200).

Fig 4.—Granulomatous reaction in reticular dermis. Note coarse elastic fibers with serrated borders at left. Fibers are sparse within granuloma, possibly destroyed by granulomatous process. An elastic fiber is seen at right within cytoplasm of giant cell (Verhoeff-van Gieson, original magnification ×400).

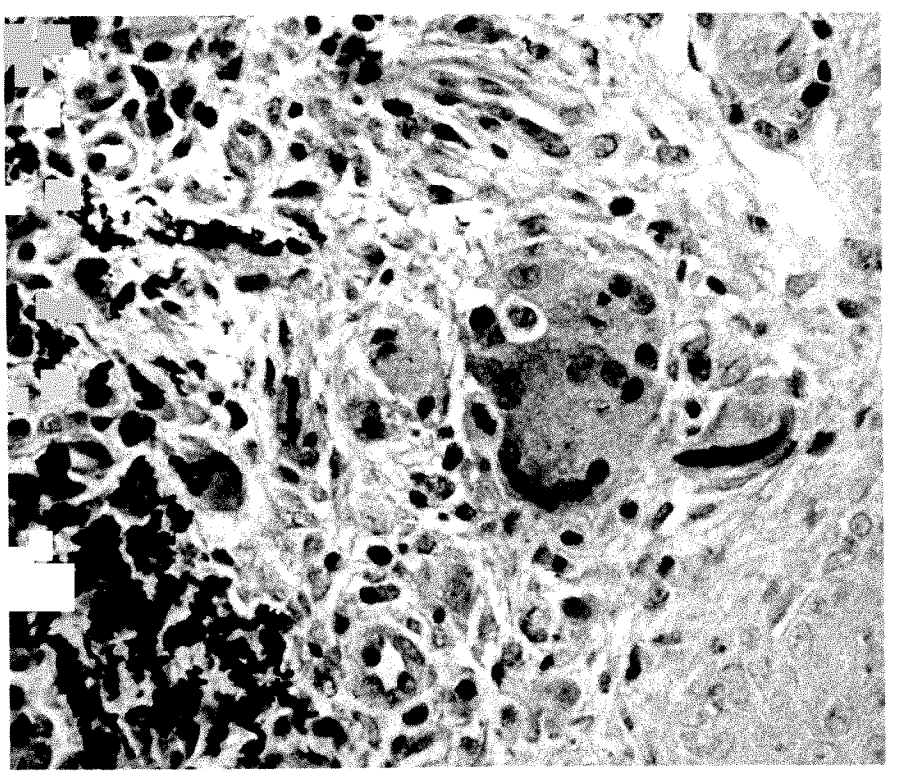

lar changes. Sections stained with hematoxylin-eosin and by the Verhoeff–van Gieson (EvG) method for elastic fibers were available for examination. The epidermis showed a localized area of acanthotic thickening, which was perforated by a canal leading from the dermis into the Malpighian layer. The canal contained granular, basophilic debris, necrotic cells, and large, tortuous, and strikingly eosinophilic fibers (Fig 3). Although eosinophilic, the fibers reacted in the manner of elastic fibers in the EvG stained sections. Near the surface, the canal also contained parakeratotic keratin.

In the underlying papillary dermis, there were increased numbers of unusually coarse elastic fibers, associated with a granulomatous reaction characterized by fibroblastic proliferation, histiocytic infiltration, and multinucleated giant cells of the foreign body type, many of which contained fragments of elastic fibers within their cytoplasm. The reticular dermis contained considerably increased numbers of coarse elastic fibers, only focally associated with a granulomatous reaction. A conspicuous feature of the coarse elastic fibers was their serrated, sawtooth-like borders (Fig 4).

Transmission Electron Microscopic Findings

The tissue was fixed in buffered 10% formalin, transferred to cacodylate buffer, postfixed with osmic acid, and embedded in an epoxy resin. Sections were cut at about 600 A thickness and stained with uranyl acetate and lead citrate. They were examined in an electron microscope (Philips EM-300).

Throughout the reticular dermis, the elastic fibers in the present case were considerably larger in caliber than those in control material. The fibers averaged about 40,000 A (4 μ) in diameter, whereas elastic fibers in our control reticular dermis averaged about 20,000 A (2 μ) in diameter. They consisted of a distinct inner core, or medulla, an outer cortex, and a dense, fibrillar cuticular border. The inner core closely resembled, in size and in structure, normal elastic fibers. It

consisted of fine, skeletal fibrils, oriented parallel to the length of the elastic fiber, embedded in a moderately dense amorphous or finely granular matrix (Fig 5, top). The fibrils were 200 to 600 A in thickness; they showed no obvious periodicity or striations. The outer cortex consisted entirely of matrix material similar to that found among the fibrils in the medulla. The homogeneous cortical layer was not uniform in thickness but was irregularly serrated, ranging in thickness from 5,000 to 20,000 A (0.5 to 2 μ). The bumpy, irregular cortex appeared to correspond to the serrated outline of the elastic fibers as observed in the EvG stained paraffin sections.

The surface of the elastic fibers in EPS was not marked by any discernible membrane; instead it was marked by numerous fibrils about 200 A in diameter. These often showed periodic cross banding or beading with a period of about 150 A, and resembled protocollagen filaments.

Scanning Electron Microscopic Findings

Tissue that had been embedded in paraffin for light microscopy was deparaffinized with xylol and taken through alcohol to water. It was then incubated in 0.05% bovine testicular hyaluronidase buffered to pH 5 at 37 C for two hours to remove ground substance. The tissue was then dehydrated with absolute acetone and dried with CO_2 by the critical point method. The tissue was shadowed with gold, and examined with a scanning electron microscope. The surface examined was that produced by the microtome knife in cutting the paraffin sections, and thus closely corresponds to that seen in the light microscopic slides.

Atypically large fibers, doubtless corresponding to the large elastic fibers seen in the EvG preparations, were easily found in the papillary dermis adjacent to the epidermal perforation. These fibers appeared to extend through the epidermal basement membrane below the epidermal perforating canal. They were seen not only in the lumen of the canal, but also in the interstices of the keratinocytes adjacent to the canal (Fig 6). Occasionally, they appeared to penetrate the cytoplasm of the cells and destroy them.

Fig 5.—Transmission electron micrograph of dermal elastic fiber, from EPS (top), compared to elastic fiber from normal dermis (bottom). Inner core of fiber from EPS closely resembles normal fiber. Surrounding it there is homogeneous cortex. Surface is intimately related to numerous fibrillar structures (top and bottom, original magnification, ×18,000).

COMMENT

Our observations made by light microscopy are generally similar to those described previously in cases of EPS, both idiopathic and penicillamine associated.

Especially notable in our material was the intense eosinophilia of the elastic fibers penetrating the epidermis, while those in the reticular dermis were either eosinophilic or basophilic. The eosinophilia has been noted before[6,14] but seldom emphasized. It has also been noted[15] that elastic fibers may be eosinophilic in early actinic elastosis, later becoming basophilic.

The rough, serrated, sawtooth-like outlines of the enlarged elastic fibers noted in the Verhoeff preparations of our material have not previously been described. At first we were inclined to ascribe it to artifact, until the electron micrographs confirmed its presence. This irregular structure was conspicuous by light microscopy in both biopsies. We have not observed this serration in other cases of EPS recently examined, none of which

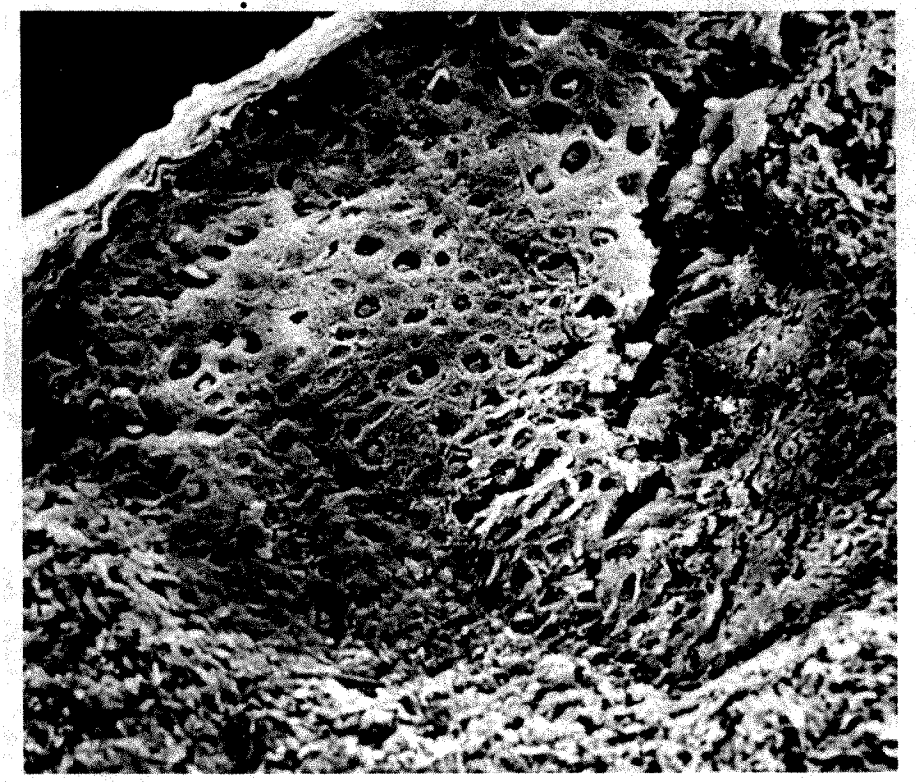

Fig 6.—Scanning electron micrograph. Elastic fibers (white) can be seen in interstices between keratinocytes adjacent to intraepidermal canal (×800).

were associated with penicillamine. Possibly this change is unique to the lesion induced by penicillamine.

The electron microscopic finding in EPS have been described in three cases, none penicillamine induced. Cohen and Hashimoto,[14] using osmium fixed, methacrylate embedded but unstained sections, noted that the Verhoeff–positive material was amorphous without periodic striations and resembled normal elastic fibers. It is apparent that the unavailability of heavy metal staining at the time of their report did not allow observation of structural subtleties. Hashimoto[16] later described the fine structure of the elastic fibers in EPS and compared it to their structure in normal skin as well as other pathologic conditions. He noted that the dense elastic matrix substance was deposited not only on protofilaments, as in normal skin, but also on reticulum fibrils and collagen fibers in the papillary dermis. He neither described nor illustrated the outer cortex of structureless matrix material overlying the central, fibril-containing core seen in our case. Subsequently, Hashimoto and Kanzaki[17] have reinterpreted the dense material within the fibers as an amorphous granular material ("dense bundles") rather than as microfibrils and have described the ultrastructural alterations in cases of cutis laxa not related to penicillamine therapy.

More recently, Meves and Vogel[18] described in detail the ultrastructural changes in a case of idiopathic EPS. They described and illustrated increased number of elastic fibers of large caliber, convoluted and branching. On the surface of the fibers, they described numerous fine filaments which they noted were similar to those seen in normal embryonic elastic fibers and interpreted as being newly formed. They also emphasize reduplications and discontinuities in the epidermal basement membrane in the area of perforation. They neither describe nor illustrate the peripheral, fibril-free cortex of the elastic fibers seen in our case.

The pathogenic mechanism of EPS in general is unknown, and how penicillamine initiates these mechanisms is equally unknown. Normal elastic fibers by transmission electron microscopy appear to be composed of a skeleton of delicate fibrils, resembling collagen or precollagen, which are embedded in a dense homogeneous matrix.[16] Only the matrix material is susceptible to elastase, the fibrils being resistant.[19] Properly then, only the homogeneous matrix material should be designated *elastin*. The penetration of elastic fibers into the epidermis and their subsequent extrusion onto the surface is apparently unique to EPS. However the accumulation of neutrophils and the formation of granulomas with phagocytosis are not unique. Phagocytosis of elastic fibers is prominent in actinic granulomas[20] and has been noted in healing wounds. It has been produced experimentally by implantation of bovine elastin subcutaneously in rats,[21] and by degrading vivo vascular elastic fibers by injecting pancreatic elastin into the carotid arteries in rabbits.[22] It would appear that injured or foreign elastic tissue regularly in vivo incites a polymorphonuclear response, followed by a granuloma that phagocytizes and effectively removes the elastic material.

It has been known for some time that copper deficiency produces vascular disease and changes in the elastic tissue in swine.[23,24] Waisman and Carnes[25] produced copper deficiency in swine and noted that the internal elastic lamina of the coronary arteries became fragmented and thinned. Electron microscopy demonstrated fenestrations and eventual fragmentation of the fibers. They believe that copper is necessary for the formation of cross-links between fibrils of the elastic precursor.

Simpson and Harms[26] also examined by electron microscopy the vascular lesions of copper deficient chicks. They found dissolution of matrix of elastic fibers, with persistence of the skeleton fibrils. The elastic tissue changes seen in experimental copper deficiency are not identical to those reported in human EPS nor do they closely resemble changes in our own material.

Because it is established on an experimental basis, that copper is neces-

sary for normal elastic tissue formation, and because it is known that penicillamine is capable for depleting tissues of copper, it is tempting to hypothesize that EPS, at least in penicillamine induced cases, is due to depletion of copper.

However, there is good evidence that Menke kinky hair syndrome is primarily due to a defect in copper absorption, and that all its clinical manifestations are caused by tissue copper deficiency.[13] Notably, the histologic changes seen in the elastica of vessels[27] closely resemble those produced experimentally in copper deficient animals.[25] But patients with Menke syndrome do not develop the clinical changes of EPS nor do they get the elastic tissue changes observed by us. Therefore, it is suggested that EPS may be due to deficiency of another trace metal that is bound by penicillamine.

Our observations in the single case of penicillamine induced EPS are different from those previously described by others,[16-18] and different from our own observations in a case of EPS associated with Down syndrome. If examination of further cases of penicillamine-induced EPS confirms that the appearance of the elastic fibers is constantly different from their appearance in idiopathic EPS, it would suggest the penicillamine-induced lesion arises through a different pathogenetic process. Possibly, the clinical (and light microscopic) picture of EPS, as well as other granulomatous and perforating elastoses, is the final tissue reaction to a variety of injuries to elastic fibers. In penicillamine-related cases, the injury may be due to deficiency of copper or other trace metal, while the injury to the elastica may be qualitatively different and arise through an entirely different mechanism in idiopathic cases. It is hoped that examination of further cases by electron microscopy, together with tissue assay for trace metals will shed some light on the problem.

Nonpropietary Name and Trademark of Drug

Penicillamine—*Cuprimine.*

References

1. Reed RJ, Clark WH, Mihm MC: The cutaneous elastoses. *Hum Pathol* 4:187-199, 1973.
2. Lutz W: Keratosis follicularis serpiginosa. *Dermatologica* 106:318-320, 1953.
3. Miescher G: Elastoma intrapapillare perforans serpiginosa. *Dermatologica* 110:254-266, 1955.
4. Hitch JM, Lund HZ: Elastosis perforans serpiginosa. *Arch Dermatol* 79:407-421, 1959.
5. Klein AW, Newcomer VD: Elastosis perforans serpiginosa: Report of a family. *Cutis* 16:259-261, 1975.
6. Pedro SD, Garcia RL: Disseminate elastosis perforans serpiginosa. *Arch Dermatol* 109:84-85, 1974.
7. Guilaine J, Benhamou JP, Molas G: Elastome perforant verruciforme chez un malade traite par penicillamine pour maladie de Wilson. *Bull Soc Franc Dermatol Syphilol* 79:450-453, 1972.
8. Pass F, Goldfischer S, Sternlieb I, et al: Elastosis perforans serpiginosa during penicillamine therapy for Wilson disease. *Arch Dermatol* 108:713-715, 1973.
9. Katz R: Penicillamine induced skin lesions: A possible example of human lathyrism. *Arch Dermatol* 95:196-198, 1967.
10. Kueppers F, Daniels F Jr: Penicillamine induced skin lesions in patient with Wilson's disease. *Cutis* 5:35-39, 1969.
11. Mjolnerod OK, Dommerud SA, Rasmussen K, et al: Congenital connective tissue defect probably due to D-penicillamine treatment in pregnancy. *Lancet* 1:673-675, 1971.
12. Charlebois G, Cadotte M, Barbeau A: Cutis hyperelastica following prolonged administration of penicillamine in a patient with Wilson's disease. *Union Med Can* 101:893-895, 1972.
13. Matsuda I, Pearson T, Holtzman NA: Determination of apoceruloplasmin by radioimmunoassay in nutritional copper deficiency, Menkes' kinky hair syndrome, Wilson's disease, and umbilical cord blood. *Pediatr Res* 8:821-824, 1974.
14. Cohen AS, Hashimoto K: Electron microscopic observations on the lesion of elastosis perforans serpiginosa. *J Invest Dermatol* 35:15-19, 1960.
15. Banfield WG, Brindley DC: Preliminary observations on senile elastosis using the electron microscope. *J Invest Dermatol* 41:9-17, 1963.
16. Hashimoto K: Fibroblast, collagen, and elastin, in Zeligson AS: *Ultrastructure of Normal and Abnormal Skin.* Philadelphia, Lea & Febiger, 1967.
17. Hashimoto K, Kanzaki T: Cutis laxa. *Arch Dermatol* 111:861-873, 1975.
18. Meves C, Vogel A: Elecktron mikroskopische Untersuchungen auf einem Fall von Elastosis perforans serpiginosa. *Dermatologica* 145:218-221, 1972.
19. Bader L: Disorders of elastic tissue. *Pathology* 5:269-289, 1973.
20. O'Brien JP: Actinic granuloma. *Arch Dermatol* 111:460-466, 1975.
21. Papajiannis SP, Spina M, Gotte L: Sequential degradation and phagocytosis of heterologous elastin. *Arch Pathol* 89:434-439, 1970.
22. Shionoya S, Tsunekawa S, Kamiya K: Elastolysis and giant cell reaction against disintigrated elastic fibers. *Nature* 207:311-312, 1965.
23. Shields GS: Studies of copper metabolism: Cardiovascular lesions in copper deficient swine. *Am J Pathol* 41:603-610, 1962.
24. Miller EJ, Martin GR, Mecca CE, et al: The biosynthesis of elastin crosslinks: The effect of copper deficiencies and a lathryogen. *J Biol Chem* 240:3623-3627, 1965.
25. Waisman J, Carnes WH: Cardiovascular studies on copper-deficient swine: The fine structure of the defective elastic membranes. *Am J Pathol* 51:117-135, 1967.
26. Simpson CF, Harms RH: Pathology of the aorta of chicks fed a copper-deficient diet. *Exp Mol Pathol* 3:390-400, 1964.
27. Danks DM, Campbell PE, Stevens BJ, et al: Menke's kinky hair syndrome: An inherited defect in copper absorption with widespread effects. *Pediatrics* 50:188-201, 1972.

Immunoblastic Lymphadenopathy With Purpura and Cryoglobulinemia

Harry L. Wechsler, MD, Alexander Stavrides, MD

• **Immunoblastic lymphadenopathy is a recently described lymphoproliferative disorder, presumably of B-cell origin. It is characterized by regional or generalized lymphadenopathy, usually associated with hypergammaglobulinemia or dysproteinemia. Other findings may be hepatosplenomegaly, dermatitis, fever, malaise, weight loss, and various altered immunologic reactions. Histologically, the involved lymph nodes show immunoblast, plasmacytoid, and plasma cell proliferation. This may be extranodal as well.**

The case reported here is one of the few followed up prospectively. The patient's purpuric eruption was an apparent manifestation of a type II mixed cryoglobulinemia. Differing from what has usually been reported, we noted hypogammaglobulinemia and findings in part of altered cell-mediated immunity. Despite leukopenia and anemia there were no infectious episodes. Although a satisfactory treatment regimen has not been established, there was beneficial response to prednisone and short courses of melphalan.

(*Arch Dermatol* 113:636-641, 1977)

Accepted for publication March 10, 1976.

From the Departments of Dermatology (Dr Wechsler) and Pathology (Dr Stavrides), Western Pennsylvania Hospital and University of Pittsburgh.

Reprint requests to 502 Fifth Ave, McKeesport, PA 15132 (Dr Wechsler).

Recent retrospective clinical and pathologic studies have suggested the existence of a lymphoproliferative disorder separate and distinct from malignant lymphoma, with which it had been grouped. This syndrome has been referred to as angioimmunoblastic lymphadenopathy with dysproteinemia,[1] immunoblastic lymphadenopathy (IBL),[2] lymphogranulomatosis X[3], and immunoblastic lymphadenopathy with mixed cryoglobluinemia.[4] The characteristic findings are nodal immunoblastic proliferation, apparently of B-cell origin, associated with or giving rise to elevated γ-globulin levels.[1-3,5,6] The clinical course is characterized by lymphadenopathy usually with hepatosplenomegaly, weight loss, fever and sweating, and a nonspecific dermatitis. A usual feature has been hypergammaglobulinemia of a polyclonal type but, on occasion, also monoclonal. Cryoglobulins have been identified as the responsible paraproteins in a few of the cases.[2-4] Histologic changes in the lymph nodes are quite characteristic, consisting of proliferation of immunoblasts, plasmacytoid lymphocytes, and plasma cells; prominence and arborization of small vessels; and interstitial deposition of eosinophilic material.[1-3] These may be extranodal as well. Since only a limited number of cases have been observed, the course of the disease has been unpredictable. Spontaneous remission has been noted in some patients who did not have treatment. On the other hand, rapid termination has occurred in others in spite of treatment. A frequent complication has been recurrent infections, which accounted for the death of seven patients in one series.[1] This has prompted Rappaport and Moran[5] to suggest that if therapy is undertaken, cytotoxic agents may be contraindicated and that a corticosteroid should be the drug of choice. Lukes and Tindle,[2] in a review of their autopsy findings, noted frank neoplastic change in three of the cases that they diagnosed as immunoblastic sarcoma. However, most observers do not regard IBL to be a malignant lymphoma. Frizzera et al[1] and others[2] have suggested that clinically and histopathologically the process resembles a graft-vs-host reaction. Some investigators, because of the history of chronic drug and chemical exposure in some of the patients, have proposed that the cause of the disease is due to chronic antigenic stimulation.[2-4]

The case reported here afforded one of the few opportunities to follow up

Fig 1.—Purpura of legs in 53-year-old patient.

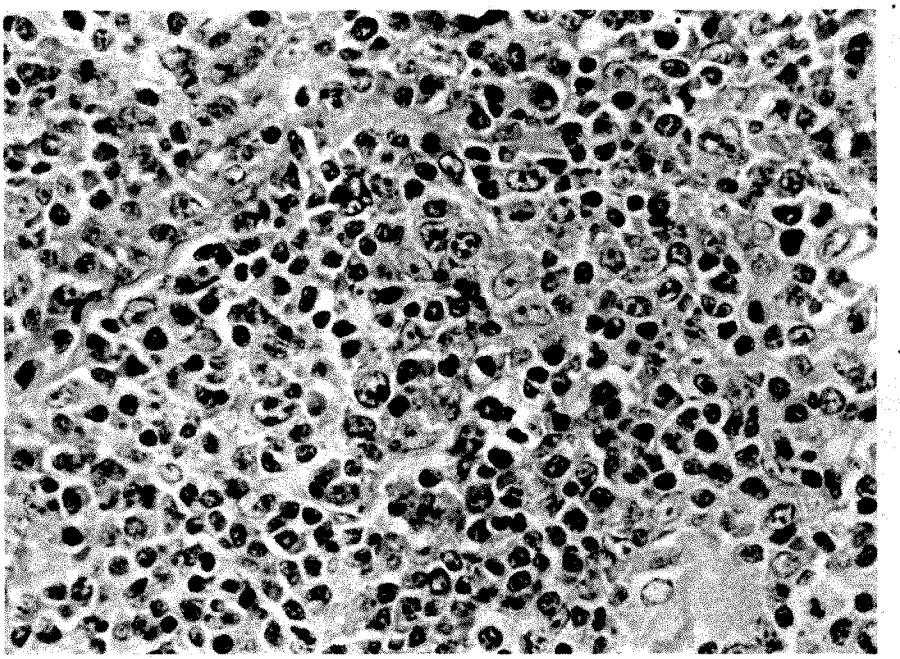

Fig 2.—Pleomorphic infiltrate composed of immunoblasts, lymphocytes, and plasma cells. Deposits of amorphous eosinophilic material (hematoxylin-eosin, original magnification ×240).

the course of the disease in a patient for whom the diagnosis had been established beforehand.

REPORT OF A CASE

A 53-year-old woman was admitted to the Western Pennsylvania Hospital Jan 6, 1975, because of progressive left cervical lymphadenopathy of three months' duration. Petechiae of the lower extremities were present for two months (Fig 1). The eruption was pruritic, first appeared about the ankles, then spread proximally to involve the buttocks. Histologic examination of a nodal biopsy specimen at a neighboring hospital showed "chronic inflammation." Bone marrow and toxoplasmosis studies were reported to be negative. The patient denied malaise, weight loss, or weakness. She did complain of discomfort, tightness, and pain in the calves of the legs on walking. There was no history of exposure to chemicals or oral or parenteral administration of drugs, vitamins, or both.

Physical examination showed an obese woman in no apparent distress. Lymphadenopathy of the left anterior and posterior cervical chains was prominent, including a large mass over the parotid area, giving a lump-jaw-like appearance. The nodes were discrete, varying in size from 0.5 to 3.0 cm. There were bilateral moveable axillary nodes about 2.0 to 3.0 cm in diameter, and those of the inguinal area were shotty.

An erythematous nonblanching macular eruption, 3 to 5 mm in diameter, with central punctate hemorrhage involved the lower trunk and lower extremities (Fig 1). There was no hepatosplenomegaly.

Initial Laboratory Studies

Initial laboratory findings showed the following: hemoglobin, 10.2 gm/100 ml; hematocrit, 30%; WBCs, 4,100/cu mm, with 75% neutrophils, 11% lymphocytes, and 14% monocytes; platelets, 171,000/cu mm; and reticulocyte count, 1.8%. The peripheral blood film showed mild anisocytosis. Erythrocyte sedimentation rate at room temperature was 60 mm/hr in the first hour (Westergren). Serum iron level was 36 μg/100 ml (normal, 65 to 150 μg/100 ml); total iron binding capacity was 190 μg/100 ml (normal, 250 to 420 μg/100 ml). Haptoglobin value was 260 mg/100 ml (normal, 30 to 210 mg/100 ml). Serum protein level was 5.9 gm/100 ml; albumin, 3.1 gm/100 ml; and globulins, 2.8 gm/100 ml. The remainder of the results from automated blood chemical analyses were within normal limits.

Results of a direct Coombs test were negative. The VDRL and rapid plasma reagin test findings were nonreactive. Determinations for antinuclear, parietal cell, mitochondrial, smooth muscle, and thyroglobulin antibodies were negative.

Latex agglutination (rheumatoid arthritis factor) was positive 1:5,120. Toxoplasmosis antibodies by the passive microhemagglutination technique were positive 1:64. The Sia water test result was positive; heterophile antibodies, negative.

Histopathologic Findings

Microscopic sections were reviewed of two left cervical lymph node specimens taken at biopsies performed at another institution three months previously. Histologic examination of sections stained with hematoxylin-eosin and Foot reticulin showed extensive distortion of the normal lymph node architecture. Normal lymphoid follicles with germinal centers and medullary sinuses were rarely observed. There was a diffuse proliferation of immunoblasts, plasma cells, plasmacytoid lymphocytes, and histiocytes. There was an increased number of small blood vessels.

Biopsy specimens of cervical lymph nodes were obtained shortly after admission. The material consisted of a mass of matted lymph nodes, the largest of which was 1.5 cm in diameter. Histologic examination of sections stained with hematoxylin-eosin, Foot reticulin, methyl green-pyronine, Giemsa, and PAS showed diffuse alteration of the normal architecture. There was a mixed cellular proliferation of large immunoblasts and plasma cells (Fig 2). Distinct lymphoid follicles were not present. The immunoblastic cells had large round or oval nuclei with dispersed chromatin and one to two prominent basophilic nucleoli (Fig 3). These were surrounded by a thin rim of pyroninophilic cytoplasm. There was an increase in the number of blood vessels, which had prominent endothelial cells (Fig 4). Small quantities of amorphous, acidophilic interstitial material

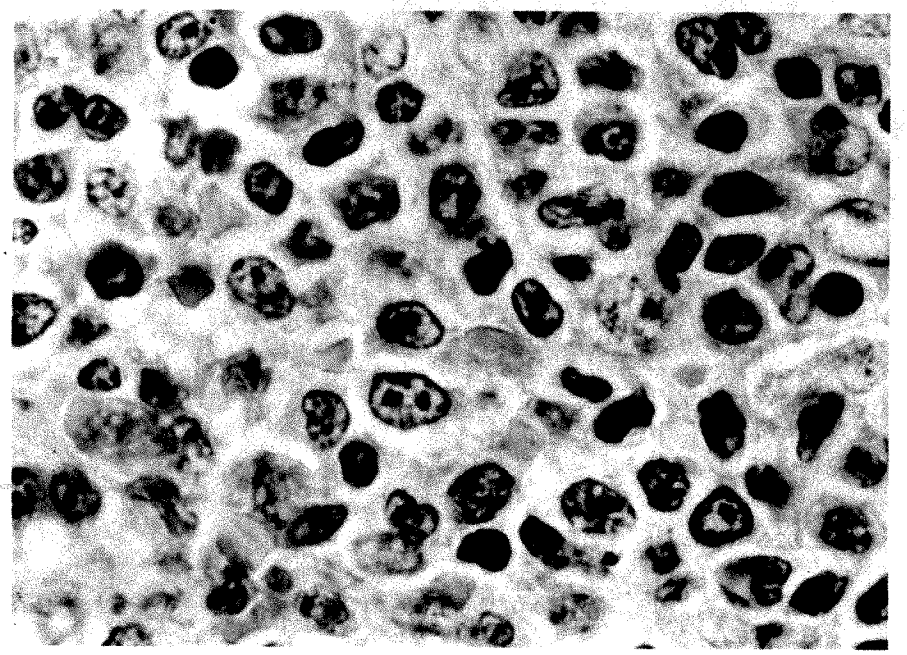

Fig 3.—Numerous immunoblasts having round or oval nuclei with dispersed chromatin, prominent one to two basophilic nucleoli, and thin rim of cytoplasm. Few plasma cells and plasmacytoid cells are seen (hematoxylin-eosin, original magnification ×600).

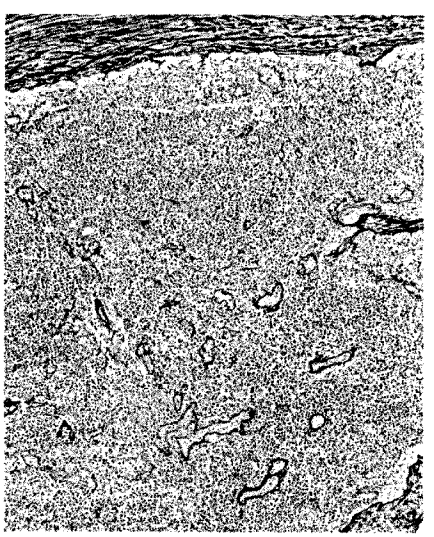

Fig 4.—Increased number of arborizing blood vessels (reticulin stain, original magnification ×90).

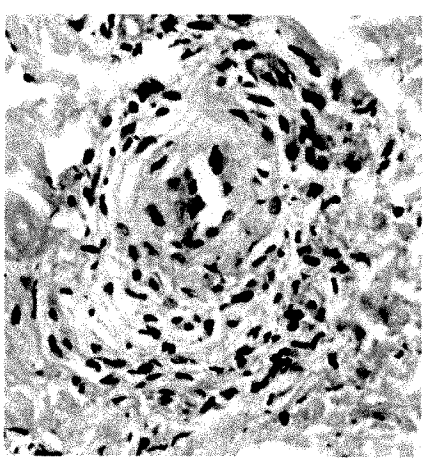

Fig 5.—Small arteriole showing swelling of endothelium and fibrinoid degeneration of wall surrounded by polymorphonuclear leukocytes, some of which are undergoing nuclear fragmentation (hematoxylin-eosin, original magnification ×600).

were noted (Fig 2). Small clusters of four to five histiocytic cells forming sarcoid-like nodules were seen.

Material from a biopsy specimen of a purpuric lesion of the leg was divided in two. Half was routinely fixed in formaldehyde solution and the other half quickly frozen and cut on a cryostat for immunofluorescent studies.

Histologic examination of sections stained with hematoxylin and eosin showed in the upper dermis degeneration of capillaries and small arterioles with disruption and swelling of the endothelium. Many polymorphonuclear leukocytes showed fragmentation of the nuclei and nuclear dust characteristic of leukocytoclastic angiitis (Fig 5).

Direct immunofluorescence of frozen sections of the skin, processed by standard procedure using monospecific human immunoglobulin, complement C3, and fibrinogen antisera, showed the presence of IgG, IgM, and C3 deposits in the wall of the blood vessels.[8] Fibrin was noted on and around the wall of the blood vessels.

Bone marrow biopsy showed a hypercellular bone marrow. The myeloid to erythroid ratio was 3:1. Megakaryocytes were normal. Plasma cells, plasmacytoid lymphocytes, and immunoblasts were noted in small numbers. The iron stores were depleted.

Immunologic Studies

Serum immunoglobulins and complement components C3 and C4 were determined by the radial immunodiffusion technique.[9]

Findings on admission were as follows: IgG 335 mg/100 ml (normal, 590 to 1,310 ± 2 SD); IgA, 183 mg/100 ml (normal, 80 to 200 ± 1 SD); IgM, 702 mg/100 ml (normal, 90 to 170 ± 1 SD); C3, 66 mg/100 ml (normal, 123 to 167); and C4, 5 mg/100 ml (normal, 20 to 50). Repeated studies showed progressive reduction of IgM, persistence of hypogammaglobulinemia, and return of C3 to normal levels (Fig 6).

Serum protein electrophoresis was performed on cellulose acetate and immunoelectrophoresis on agarose gel.[10] It showed on admission a small spike in the γ region, suggesting a monoclonal gammopathy. This was absent on repeated serum electrophoretic studies at three, six, and nine months (Fig 6).

Agarose gel immunoelectrophoresis of the serum showed an increase of the IgM fraction and a monoclonal gammopathy of IgM-κ specificity. Bence-Jones protein in urine (determined after fiftyfold concentration of the urine and by immunoelectrophoresis in agarose gel and diffusion against κ and λ light chains) was absent.

Cryoglobulin determination after drawing blood with prewarmed syringe and needle was performed by separating the serum from the blood, and allowing it to clot for 60 minutes at 37 C. The cryoglobulins were precipitated and isolated for immunochemical studies at 4 C. The cryocrit level was determined by the method of Peetom.[11]

On initial examination the cryocrit level was 13%. The protein concentration in the cryoglobulin precipitate was 1.4 mg/ml. By immunoelectrophoresis, the cyroglobulins were found to be mixed cryoglobulins of IgG-IgM type. All the rheumatoid factor activity was present in the cryoprecipitate without any detectable rheumatoid factor activity in the supernatant. The immunoglobulin Ig concentration in the cryoglobulins was IgG, 0.5 mg/ml, IgM, 0.7 mg/ml. There was a progressive reduction in the cryocrit and cryoglobulin concentrations during the course of treatment (Fig 6).

Peripheral blood T and B lymphocytes

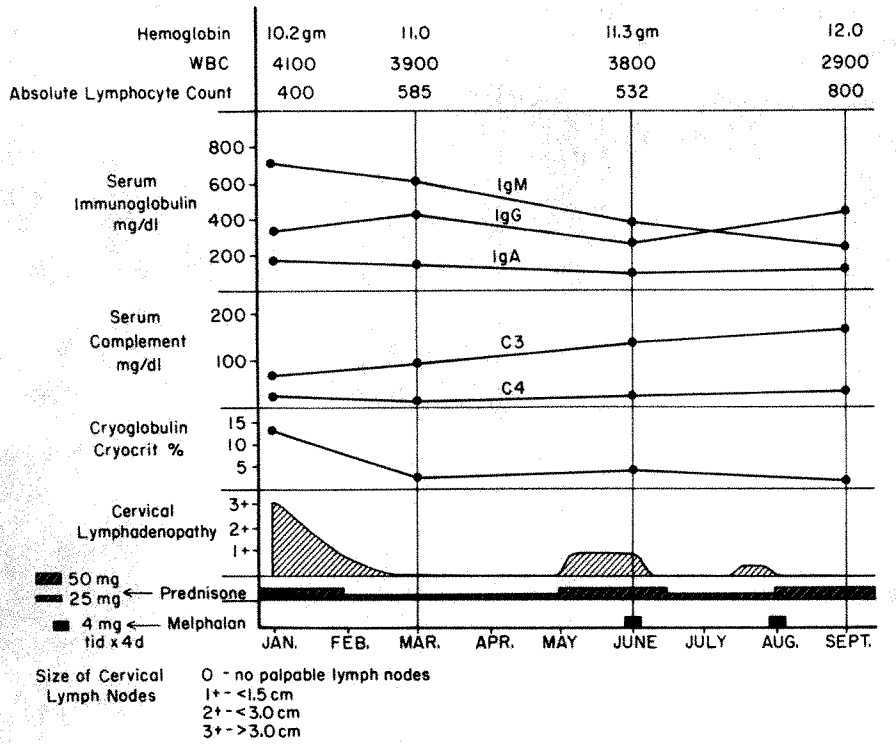

Fig 6.—Laboratory and clinical response to treatment.

were determined by separating lymphocytes from whole heparinized blood by the density gradient centrifugation technique of Böyum.[12] The sheep erythrocyte rosette assay for T lymphocytes was performed by a modification of the procedure of Jondal et al.[13] Surface immunoglobulins for B lymphocytes were detected by standard procedures, using fluorescein-conjugated polyspecific antihuman immunoglobulin fluorescein to protein (5.8) ratio.[14]

Findings on admission were WBC, 4,100/cu mm; lymphocyte count, 450/cu mm; T lymphocytes, 42% (normal, 60% to 70%); and B lymphocytes, 10% (normal, 20% to 30%). Two months later, WBC was 3,200/cu mm; lymphocyte count, 620/cu mm; T lymphocytes, 49%; and B lymphocytes, 46%.

Cell-mediated immunity studies were performed. Blastogenic transformation of lymphocytes to phytohemagglutinin (PHA) stimulation was determined by a microtechnique using heparinized whole peripheral blood. The incorporation of tritiated thymidine into DNA was measured and the stimulation index (SI) calculated as the ratio disintegration per minute (dpm) + mitogen/dpm – mitogen.[15]

On admission, the blastogenic transformation by PHA (SI) was 39 (normal, 60 to 200). Two months later, the SI was 33.

Mumps virus vaccine, Candida albicans, and tuberculin were injected intradermally. The mumps site was positive after 24 hours. There were no reactions at the other sites.

Sensitization to 2.04-dinitrochlorobenzene (DNCB) was attempted by applying 0.05 ml of a 1.0% solution in acetone to the volar aspect of the right forearm. Erythema was apparent in 24 hours. Challenging dose of DNCB of 0.05 ml of 0.1% solution applied to the volar aspect of the left forearm three weeks later failed to produce a reaction. During this time the patient had been taking prednisone, 50 mg/day.

Course

After the initial workup the patient was placed on a regimen of prednisone, 50 mg/day. There was prompt dramatic clearing of the purpura and substantial reduction in the size of the nodes. The patient was discharged after two weeks of hospitalization. Her condition remained well controlled for about five months, while she received prednisone, 25 mg/day. When the dose was changed to alternate daily administration, the purpura recurred. After about six months, cervical adenopathy reappeared. It persisted despite increasing the dose of prednisone to 50 mg/day. A short course of melphalan (Alkeran), 4 mg three times daily for four days, produced prompt resolution. This was successfully used again during lymphadenopathy at eight months. Allopurinol, 300 mg/day, and later 150 mg/day, was given during the patient's course. Other than mooning of the face and weight gain, the patient physically appeared to be normal.

In December the patient developed an acute respiratory infection manifested by spiking fever, chills, and dyspnea. Roentgenogram of the chest showed a diffuse infiltrate bilaterally. *Staphylococcus aureus* coagulase was cultured from the sputum. There was an accompanying rise in the cryocrit level to 13%.

The patient was hospitalized and treated with oxacillin, 250 mg four times daily, for a period of ten days. The fever and symptoms were reduced. A lung biopsy specimen was obtained by fiberoptic bronchoscopy. However, the tissue showed no pathologic change; cultures for bacteria, fungus, and virus were negative. Cytomegalovirus was cultured from the nasopharynx and urine. Otherwise, the patient's course has been maintained on varying doses of prednisone and allopurinol. There has been no important change in the chest roentgenogram after eight weeks.

The patient remained active and relatively well until June 1976. She then developed fever, malaise, leg cramps, and marked dyspnea but no demonstrable lymphadenopathy. A progressive deterioration in her condition was characterized by rapidly enlarging necrotizing ulcers of the left leg associated with local and systemic infections only temporarily abated by antibiotic therapy. A recalcitrant thrombocytopenia (platelet count ranged from 20,000 to 50,000/cu mm) was not altered by increasing prednisone to 75 mg daily and splenectomy. The hypoimmunoglobulinemia G became more severe; values ranged from 14 to 36 mg/100 ml. The last five days of her life there was frank hemoptysis and melana. Despite transfusions with packed red blood cells and platelets, she died Dec 30, 1976.

An autopsy was done. Principal findings were gastrointestinal hemorrhage, stress gastric and duodenal ulcers, necrotizing ulcerative proctitis, and pulmonary abscesses and small thrombi. A polymicrobial septicemia was due to *Escherichia coli* and *Streptococcus faecalis* infection. There was generalized cytomegalic inclusion disease.

Microscopic examination of sections of enlarged paraortic lymph nodes showed the characteristic findings of IBL as did the spleen that was removed surgically one month prior to death.

COMMENT

Evidence presented to date strongly supports the concept that IBL is a distinct entity or syndrome, the histologic measurements of which have been well established.[1-3] Since most of

the data has been collected retrospectively, the spectrum of clinical and laboratory variables has been incompletely defined.

In this case, one of the few prospective studies reported, the patient was without some of the so-called cardinal clinical features such as hepatosplenomegaly and hypergammaglobulinemia. Neither was there any history of fever, weight loss, or fatigue. Besides the regional bull-neck type of lymphadenopathy, the only other physical abnormality was the nonpruritic purpuric eruption involving the buttocks and lower extremities. Dermatitis has been frequently noted in IBL, but in most cases has been described as a nonspecific maculopapular eruption with or without pruritus.[1] In isolated instances, it has been urticarial or purpuric. Evidence suggests that in our patient the purpuric eruption was a manifestation of dysproteinemia, which in this instance was a mixed cryoglobulin. Supportive of this were the histologic findings of leukocytoclastic vasculitis and the presence of immune complexes. The latter were demonstrated by direct immunofluorescence of biopsy material of a purpuric lesion of a leg. As is characteristic, the immune complexes of IgG and IgM reflected the makeup of the cryoglobulin.[16] Cryoglobulinemia of the mixed type in a patient with IBL has been reported by Schultz and Yunis.[4] They found the cryoprecipitate to consist of IgG, IgM, and IgA. As previously noted, we isolated a mixed cryoglobulin consisting of IgG and IgM. The cryoglobulin was considered to be type II, according to the classification of Brouet et al.[17] The IgM was monoclonal of κ specificity and had an antibody activity directed against the IgG, which was of polyclonal type. This was consistent with the findings of Brouet et al[17] who demonstrated that in mixed cryoglobulinemia, a monoclonal IgM may act as an antibody against a polyclonal IgG. A reflection of this IgM-IgG interaction was the presence in our patient of a rheumatoid factor positive at more than 1:5,000, but absent when the cryoglobulin was removed from the serum. Further reason for classifying the cryoglobulin as type II is that lymphoproliferative disorders are more usually associated with type I or type II whereas autoimmune diseases are associated with type III.[17] The finding of cryoglobulinemia in our patient and in those of Lukes and Tindle,[2] and Schultz and Yunis[4] leads to speculation that if more cases of IBL had been diagnosed prospectively, cryoglobulins may have been found in several of them.

The accumulated data indicate that immunologic abnormalities in IBL vary considerably from case to case, despite the findings of a wide range of aberrant reactions including cryoglobulinemia, lymphopenia, Coombs-positive hemolytic anemia, thrombocytopenia, Bence-Jones proteins, and smooth muscle antibodies; only a few may be present in any one case. Hypergammaglobulinemia was found in most patients and was considered to be a cardinal feature of the disorder.[2] Conversely, hypogammaglobulinemia was present in our patient. Radaszkiewicz and Lennert[3] reported similar findings in several of their cases. Apropos to this situation, it is not unusual in immunoproliferative disorders, such as multiple myeloma where abnormal proteins are elaborated, for there to be a decrease in production and increased catabolism of normal γ-globulins.[18] A persistent finding in our patient was a lymphopenia that did not vary despite therapy. We did not look for lymphocytotoxic antibodies, but Lukes and Tindle[2] alluded to a lympholytic factor being the cause of lymphopenia in one of their cases.

What appears to be well established is the histologic pattern of the lymphadenopathy. The prominence of blood vessels (postcapillary venules) and obliteration of nodal germinal centers by proliferating immunoblasts, plasma, and plasmacytoid cells, which were evident in our patient, have been consistently described in previously reported cases.[1-4] Such an interrelationship of cells has suggested that the lymphoproliferative disorder may be of B-cell origin.[2] We failed to uncover any substantial evidence supporting this proposition. The results of repeated studies to determine circulating B lymphocytes by immunofluorescence and T lymphocytes by sheep-erythrocytes' rosette formation were equivocal. However, there was a somewhat increased percentage of B cells on a follow-up determination. This increase may have been secondary to the steroid therapy.[19] Also, the initial low B-lymphocyte count may have been indicative of circulating immature cells lacking surface immunoglobulins. On the other hand, there is evidence that the function of T lymphocytes may be impaired. Despite response to intradermal injection of mumps in our patient, there was poor lymphoblastic response to PHA and failure to sensitize to DNCB. This has been observed in similar conditions, particularly those involving plasma cell proliferation.[18] There is an ability to retain recognition of antigens previously sensitized to, but an inability to develop response to new antigens. Since the patient had been taking prednisone, it may be contended that this interfered with the mechanism to sensitize to DNCB, but studies both in the laboratory animal[20] and in man[21] have failed to show conclusively that cell-mediated immunity can easily be influenced. Claman[22] in his review states that cell-mediated immunity can be suppressed by corticosteroid therapy, but larger amounts are necessary over an extended period of time.

It has been purported that the development of IBL is due to chronic antigenic stimulation such as that considered in similar lymphoproliferative disorders.[23-25] Several of the patients with IBL had received drugs and therapeutic agents over a period of time.[2-4] No such history was obtained from our patient. Others have suggested the pathogenic mechanism to be a graft-vs-host-type reaction.[1,7]

Proper therapy has not been established. Remission and exacerbation have been reported despite treatment or lack of it. Rappaport and Moran[3] suggested that because of repeated infections, at times leading to death, cytotoxic agents should be avoided. A corticosteroid was suggested by them as the drug of choice. After prompt and dramatic improvement with con-

comitant reduction in the amount of cryocrit and serum IgM while receiving prednisone, 50 mg/day, our patient remained clinically well. It is noteworthy to point out that there had been no infection despite leukopenia with absolute lymphopenia and hypogammaglobulinemia. This was so despite giving prednisone 25 to 50 mg/day along with two short courses of melphalan, which was necessary to negate recurrence of the cervical lymphadenopathy. Our experience suggests that prednisone and judicious use of cytotoxic agents such as melphalan can be therapeutically beneficial.

Immunoblastic lymphadenopathy appears to be a distinctive lymphoproliferative disorder with characteristic clinical, laboratory, and histologic findings. Since dermatitis may be a prominent feature of the condition, the dermatologist may be the first to be sought out by the patient. Therefore, a prompt and correct diagnosis may well be his responsibility.

Nonproprietary Names and Trademarks of Drugs

Allopurinol—*Zyloprim.*
Melphalan—*Alkeran.*

References

1. Frizzera G, Moran EM, Rappaport H: Angioimmunoblastic lymphadenopathy with dysproteinemia. *Lancet* 1:1070-1073, 1974.
2. Lukes RJ, Tindle BH: Immunoblastic lymphadenopathy: A hyperimmune entity resembling Hodgkin's disease. *N Engl J Med* 292:1-8, 1975.
3. Radaszkiewicz T, Lennert K: Lymphogranulomatis X: Klinishes, bild therapie and prognose. *Dtsch Med Wochenschr* 100:1157-1163, 1975.
4. Schultz DR, Yunis AA: Immunoblastic lymphadenopathy with mixed cryoglobulinemia: A detailed case study. *N Engl J Med* 292:8-12, 1975.
5. Rappaport H, Moran EM: Angio-immunoblastic (immunblastic) lymphadenopathy, editorial. *N Engl J Med* 292:42-43, 1975.
6. Twomey JJ: Angio-immunoblastic lymphadenopathy with dysproteinemia, letter to the editor. *Lancet* 1:1345, 1974.
7. Horne CHW, Fraser RA, Petrie JC: Angioimmunoblastic lymphadenopathy with dysproteinemia, letter to the editor. *Lancet* 2:291, 1974.
8. Cormane RH, Szabo E, Hauge LS: Immunofluorescence of the skin: The interpretation of the staining of blood vessels and connective tissue aided by new techniques. *Br J Dermatol* 82(suppl 5):26-43, 1970.
9. Fahey JL, McKelvey EM: Quantitative determination of serum immunoglobulins in antibody-agar plates. *J Immunol* 94:84-90, 1965.
10. Schriedegger JJ: Une micro-methode de immuno-electrophorése. *Int Arch Allergy Appl Immunol* 7:103-110, 1955.
11. Nakamura RM: *Immunopathology, Clinical Laboratory Concepts and Methods.* Boston, Little Brown & Co, 1974, pp 190-191.
12. Böyum A: Isolation of leucocytes from human blood: Further observations. *Scan J Clin Lad Invest* 21(suppl 97):31-50, 1968.
13. Jondal M, Holm G, Wigzell H: Surface markers on human T and B lymphocytes: I. A large population of lymphocytes forming nonimmune rosettes with sheep red blood cells. *J Exp Med* 136:207-215, 1972.
14. Grey HM, Rabellino E, Pirofsky B: Immunoglobulins of the surface of lymphocytes. *J Clin Invest* 50:2368-2375, 1971.
15. Junge U, Hoekstra J, Wolfe L, Deinhardt F: Microtechnique for quantitative evaluation of in vitro lymphocyte transformation. *Clin Exp Immunol* 7:431-437, 1970.
16. Cream JJ: Immunofluorescent studies of the skin in cryoglobulinemic vasculitis. *Br J Dermatol* 84:48-53, 1971.
17. Brouet J-C, Clauvel J-P, Danon F, et al: Biologic and clinical significance of cryoglobulins: A report of 86 cases. *Am J Med* 57:775-788, 1974.
18. Shuster J: Disorders associated with hypergammaglobulinemia and proteinemia, in Friedman SO (ed): *Clinical Immunology.* New York, Harper & Row Publishers Inc, 1971, chapt 10, pp 314-341.
19. Yu DTY, Clements PJ, Paulus HE, et al: Human lymphocyte subpopulations effect of corticosteroids. *J Clin Invest* 53:565-571, 1974.
20. Jeter WS, Seebom PM: Effect of cortisone and adrenocorticotropic hormone of delayed hypersensitivity to 2,4-dinitrocholorbenzene in guinea pigs. *J Immunol* 73:44-48, 1954.
21. Bovornkitti S, Kangsadal P, Sathirapat P, et al: Reversion and reconversion rate of tuberculin skin reactions in correlation with the use of prednisone. *Dis Chest* 38:51-55, 1960.
22. Claman HN: Medical progress: Corticosteroid and lymphoid cells. *N Engl J Med* 287:388-397, 1972.
23. Salzstern SL, Ackerman LV: Lymphadenopathy induced by anticonvulsant drugs and mimicking clinically and pathologically malignant lymphoma. *Cancer* 12:164-182, 1959.
24. Schwartz RS, Beldotti L: Malignant lymphomas following allogenic disease: Transition from an immunological to a neoplastic disease. *Science* 140:1511-1514, 1965.
25. Anderson LG, Talal N: The spectrum of benign to malignant lymphoproliferation in Sjogren's syndrome. *Clin Ext Immunol* 9:199-221, 1971.

Lymphocutaneous Nocardiosis Due to *Nocardia brasiliensis*

Eliezer Zecler, MD; Yigal Gilboa, MD; Luba Elkina, MD; Gerald Atlan, MD; David Sompolinsky, PhD

• A farmer had chaining lymphocutaneous granuloma on the right hand and arm. Clinically the syndrome seemed typical for sporotrichosis. Bacteriological examination revealed *Nocardia brasiliensis* as the only etiologic agent. Since 1920, eight similar cases of sporotrichoid nocardiosis have been reported from various parts of the world. To our knowledge, isolation of *N brasiliensis* has not been reported previously in this geographical area.

(*Arch Dermatol* 113:642-643, 1977)

Infections with *Nocardia* may be systemic or localized. Affection of the lungs is most often due to *N asteroides*, and this infection has a tendency to hematogenous spread with multiple far-sited foci. Chronic granuloma of the skin (mycetoma) may be due to either *N asteroides* or *N brasiliensis*, and dissemination is uncommon. However, since 1920, eight cases of nocardial mycetoma advancing along the lymphways have been reported.[1-8] An additional case will be presented here, primarily to bring to attention the possibility of this etiology for a syndrome clinically typical for sporotrichosis.

Accepted for publication Feb 19, 1976.

From the Departments of Internal Medicine B and Microbiology, Asaf Harofe Hospital, Tel Aviv University, Sackler School of Medicine, Zerifin, Israel.

Reprint requests to Microbiology Department, Asaf Harofe Hospital, Zerifin, Israel (Dr Sompolinsky).

REPORT OF A CASE

A 64-year-old farmer was seen on Oct 23, 1972, complaining of an indurated, ulcerated pus-producing area, on the second finger of his right hand. He had been working in the field during the preceding weeks, but could not remember any particular trauma to the diseased site.

On admission, the body temperature was 37 C. On the dorsal surface of the affected finger, there was a circulated chancroid ulceration, 2 to 3 cm in diameter. Multiple subcutaneous, erythematous nodules, 1 to 4 cm in diameter, were noted as a necklace along the lymphatics on the extensor surface of the right forearm (Figure). These nodes were red, tender and painful. The axillar lymph nodes were also swollen and tender.

No abnormal findings were revealed by ECG, chest roentgenogram examinations, blood counts, blood chemistry (BUN, nitrogen, glucose, electrolytes, liver function tests) and urine examination.

The clinical diagnosis made was sporotrichosis. Treatment with a saturated solution of KI, 15 drops, three times daily, was started. A few days later, when the bacteriological diagnosis was known, sulfadiazine, 4 gm daily, was added. This schedule was continued for two months. The lesions healed gradually in the course of five to six weeks, leaving only superficial scarring. The patient was seen again for followup one year later, and his health was good both subjectively and objectively.

MICROBIOLOGICAL FINDINGS

Pus samples aspirated from two efflorescenses were examined. The material was yellow and turbid but without sulfur grains. Microscopic examination of smears revealed predominantly polymorphonuclear leukocytes and Gram-positive slightly branching filaments with fragmentation, but without coccoid forms. The specimens were inoculated on blood agar, Loewenstein medium, Sabouraud glucose agar with and without chloramphenicol (10 μg/ml) and also into tryptose phosphate broth. Growth was inhibited by chloramphenicol, but could be observed on all drugless media after five to seven days. The colonies were first small and velvety, later they became dry, large, and wrinkled. Colonies on Sabouraud agar were ocher to orange and had a strong earthy odor. Microscopically, the cultured organisms were partially acid fast. In broth cultures, the small,

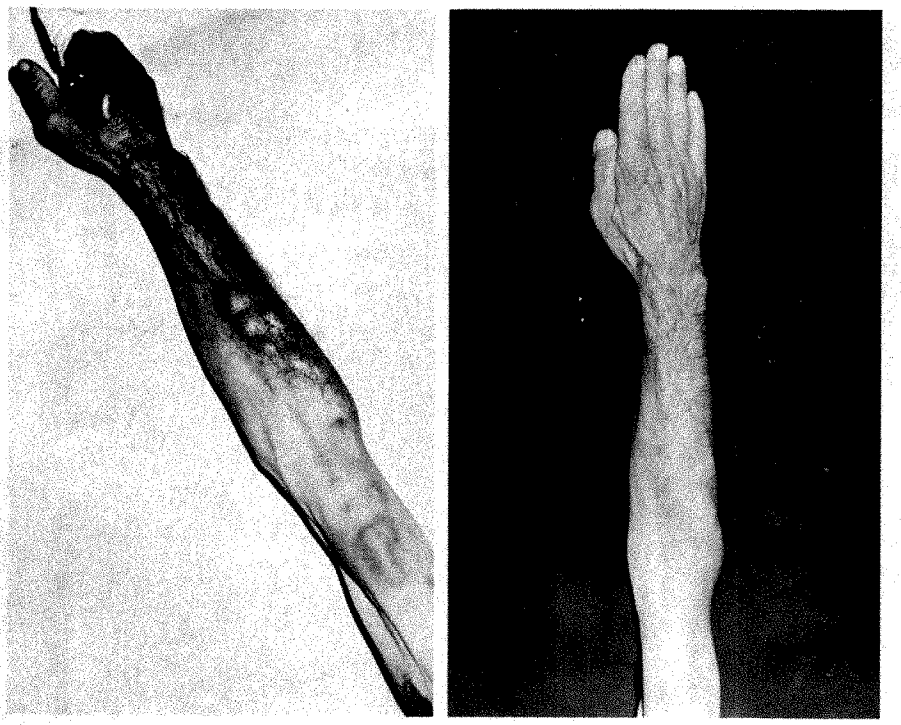

Left, diseased arm on day of admission, and right, same arm after six week's of treatment.

round, and heavy, whitish to yellowish, colonies adhered strongly to the glass. Growth occurred at both 30 C and 37 C, but not at 46 C.

The following biochemical reactions were observed: decomposition of casein and of tyrosine but not of xanthine and hydrolysis of urea but not of starch. Gelatin was also hydrolyzed and lithmus milk was peptonized without coagulation. After growth in 0.4% gelatin in water, the medium turned alkaline, and ninhydrin reaction was positive. Also in this fluid medium, small colonies developed that strongly adhered to the wall of the test tube. It should be added that acid was formed from glucose and inositol.

Injection of a heavy inoculum of the bacteria, suspended in 1% polysorbate (Tween 80), into the peritoneum of mice, proved fatal in four to seven days. Small bright noduli containing a thick purulent or necrotic material with sulfur granula occurred in the lungs, spleen, liver, and kidneys. By microscopic examination both coccoid, rod-shaped, and filamentous organisms were observed.

On the basis of the morphological, physiological, and pathogenic properties, the organism was identified as *N brasiliensis*.

COMMENT

Geographically, *N brasiliensis* is not restricted to South America. Infections with this organism in North America and Africa have been described. The present case is the first from Israel. The organism belongs to the normal soil flora; in all but one case of sporotrichoid nocardiosis published hitherto, the patients were working in the garden previous to the infection (5 cases) or playing with cats (two cases).

Although the spread of the infectious agent from a primary inoculation site through the lymphatics in a chaining nodular pattern is characteristic of sporotrichosis, a thorough microbiological examination for alternative etiological options should be performed, including the possibilities of tularemia and pseudomycoses due to *Nocardia*.

Dr Sompolinsky is an Established Investigator of the Chief Scientist's Bureau, Ministry of Health, Israel.

References

1. Guy WH: Nocardiosis cutis resembling sporotrichosis. *Arch Dermatol Syphilol* 2:137-143, 1920.

2. Alarcon CJ, Obadia J, Borelli D: *Nocardia brasiliensis* aislado de un caso de sinfangitis nodular aguda supurativa. *Dermatilogica* 1:269-285, 1959.

3. Bechmeyer WJ: Report of a successfully treated case of cutaneous granuloma. *Pediatrics* 25:35-39, 1959.

4. Baumgarten A: Nocardiosis: Report of a cae resembling sporotrichosis. *Med J Aust* 2:321-322, 1961.

5. Rapaport J: Primary chancriform syndrome caused by *Nocardia brasiliensis*. *Arch Dermatol* 93:62-64, 1966.

6. Moore M, Courad AH: Sporotrichoid nocardiosis caused by *Nocardia brasiliensis*. *Arch Dermatol* 95:390-393, 1967.

7. Bates R, Rifkind D: *Nocardia brasiliensis* lymphocutaneous syndrome. *Am J Dis Child* 121:246-247, 1971.

8. Padron S, Dominguez M, Drosd R, et al: Lymphocutaneous *Nocardia brasiliensis* infection mimicking sporotrichosis. *South Med J* 66:609-612, 1973.

Eosinophilic Ulcer of the Tongue

Report of Two Cases

Gordon H. Burgess, MD; Amir H. Mehregan, MD; Alan J. Drinnan, MD, DDS

• **Two cases of tongue ulcers are presented. Histopathologic examination of biopsy specimens obtained from each case showed marked submucosal and muscular infiltration of polymorphonuclear eosinophils compatible with the diagnosis of eosinophilic ulcer of the tongue. The disease entity appears to be uncommon, yet, it should be recognized as benign since in both instances, healing was spontaneous.**

***(Arch Dermatol* 113:644-645, 1977)**

Eosinophilic ulcer of the tongue (EUT) is an entity that is seldom recognized and rarely considered in the differential diagnosis of ulcerated lesions of the oral mucosa. It is mentioned in only one textbook of dermatology.[1] The purpose of this article is to describe the occurrence of this entity in two patients and to emphasize that wide excision of this lesion is rarely necessary. The clinical history in one case supports the theory that trauma plays a major role in the etiology of this disease.

REPORT OF CASES

CASE 1.—A 53-year-old man was seen for a painless lesion of the tongue of five days' duration. Examination showed on the middorsal surface of the tongue, a round, punched-out ulcer measuring 1.2 cm in diameter with a gray-colored base (Fig 1). By palpation, there was no evidence of deep infiltration. The lingual mucosa surrounding the ulcer was faintly erythematous. The clinical diagnosis at the time of the biopsy was squamous cell carcinoma of the tongue.

Histologic examination of hematoxylin-eosin (H-E) stained sections of a biopsy specimen showed an area of ulceration and replacement of the surface epithelium by a homogenous pink staining fibrinous material containing numerous neutrophils and eosinophils. There were also numerous budding spores and mycelia suggestive of *Candida albicans*. At the base of the ulcer, there were an increased number of capillaries with prominent endothelial cells and surrounded by a cellular infiltrate consisting predominantly of eosinophils and also including numerous lymphocytes and histiocytes. The infiltrate extended through the submucosa and inbetween the striated muscle bundles (Fig 2 and 3).

The patient returned in five days. The entire lesion including the site of biopsy was completely reepithelialized. No recurrence or new lesions have developed within the past two years.

CASE 2.—A 14-month-old boy who had congenital indifference to pain was seen because of multiple recurrent areas of ulceration on the lips, tongue, and buccal mucosa. These developed soon after the eruption of his desiduous teeth and were presumably due to accidental biting of these areas. At the time of examination, there was an ulcer on the right border of the tongue measuring 3 × 5 mm in diameter and a second ulcer on the left border of the tongue measuring 5 × 7 mm in diameter. The borders of the ulcers were well defined, and the bases were bright red.

A punch biopsy specimen was taken from each lesion. The histologic sections showed areas of partial loss of the surface epithelium of the tongue. An extensive and predominantly eosinophilic, inflammatory cell infiltrate was present throughout the submucosa and extended into the layers of striated muscle. When the infant was prevented from biting oral structures, the ulcers cleared rapidly.

COMMENT

Eosinophilic ulcer of the tongue is considered a self-limited, benign disorder well differentiated from other eosinophil-containing lesions of the skin and mucosa, such as granuloma faciale and histiocytosis X, by the constant presence of ulceration and absence of definite granuloma formation. The etiology of eosinophilic ulcer of the tongue is not clear. Bhaskar and Lilly,[2] in 1964, studied traumatic lesions induced by crushing the tongue of rats with forceps and found the histologic changes very similar to those of EUT. In their preparations, even the pseudoinvasive quality of the infiltrate extending inbetween the muscle bundles was present. The clinical history of our second case supports the possibility of traumatic etiology for these lesions. In the first case, even though the lesion was covered by a thick layer of grayish membrane heavily invaded by spores and mycelia of *C albicans*, we do not believe that *Candida* played a primary role in the production of this lesion. There were no other manifestations of candidiasis such as thrush, paronychia, or intertrigo present in these patients. Also, it is not uncommon to see mycotic elements in the necrotic portion of ulcerated carcinomas in the mouth.

A review of 14 cases[3] disclosed that most lesions were treated by surgical excision and indeed, our case 1 resembled a carcinoma in its clinical appearance. The authors wish to call attention to this benign condition in the hope of preventing potentially mutilating and unnecessary surgical procedures.

This investigation was supported in part by Grant 9 R01 CA 13599 from the National Cancer Institute; the Zelda Radow Weintraub Cancer Fund, Inc; the Cancer Research Institute; and the Albert and Mary Lasker Foundation.

Westwood Pharmaceuticals, Inc, provided assistance in reproduction of color photography.

Accepted for publication March 1, 1976.

From the Department of Dermatology, Roswell Park Memorial Institute, Buffalo (Dr Burgess), the Department of Dermatology, Wayne State University, Detroit (Dr Mehregan), and the Department of Oral Medicine, State University of New York at Buffalo, School of Dentistry, Buffalo (Dr Drinnan).

Reprint requests to 666 Elm St, Buffalo, NY 14263 (Dr Burgess).

References

1. Domonkos AN: *Andrew's Diseases of the Skin*. Philadelphia, WB Saunders Co, 1971, p 888.

2. Bhaskar SN, Lilly GE: Traumatic granuloma of the tongue (human and experimental). *Oral Surg* 18:206-218, 1964.

3. Shapiro L, Johlin EA: Eosinophilic ulcer of the tongue. *Dermatologica* 140:242-250, 1970.

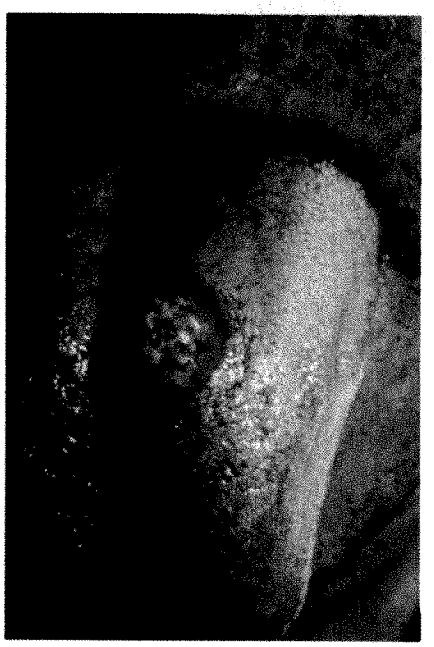

Fig 1.—Case 1 showing clinical lesion at time of initial visit.

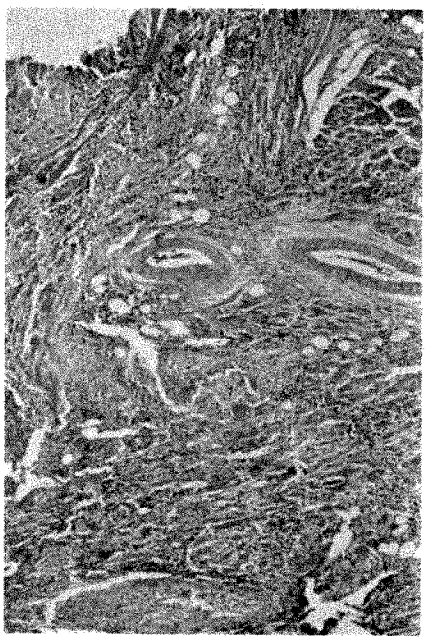

Fig 2.—Low power view of section through ulcerated central portion of lesion in case 1. Note absence of lingual epithelium and extensive cellular infiltrate between the muscular bundles (hematoxylin-eosin, original magnification ×50).

Fig 3.—High power view of Fig 2 showing mixed infiltrate containing numerous eosinophils (hematoxylin-eosin, original magnification ×200).

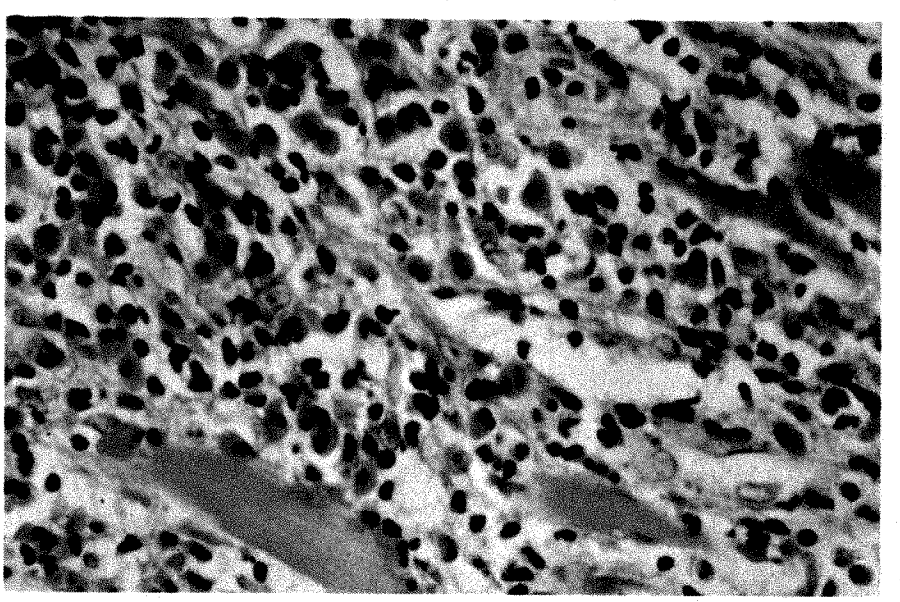

Foot Ulceration and Vertebral Osteomyelitis With *Corynebacterium haemolyticum*

Roger I. Ceilley, MD

• Diphtheroid or "coryneform" bacilli are usually considered to be nonpathogenic "normal flora" of human skin and mucous membranes. Because bacterial cultures are frequently contaminated with these organisms, the correct diagnosis and proper treatment may be delayed by the failure to recognize serious infections caused by them.

This is a report of a 71-year-old woman with a diabetic foot ulcer and *Corynebacterium haemolyticum* osteomyelitis with bacteremia.

(*Arch Dermatol* 113:646-647, 1977)

Cultures of wounds such as chronic leg ulcers growing diphtheroid organisms of *Corynebacterium* species are frequently reported as "normal flora" or "contaminants" by bacteriology laboratories. This group of organisms was thought to be a part of the harmless flora of human skin and mucous membranes and was implicated in lesser conditions such as acne,[1,2] erythrasma,[3] trichomycosis axillaris,[4] and pitted keratolysis.[5] However, there are a number of reports of more serious or fatal infections caused by them.

Goldberg[6] reported two cases of oral and facial infection with bacteremia caused from *Propionibacterium acnes* dental infection. Kaplan and Weinstein[7] reported nine cases of infection with diphtheroid organisms including endocarditis, wound infections, meningitis, osteomyelitis of the skull, and hepatitis. Other reports have included bacterial endocarditis,[8,9] meningitis and brain abscess,[10] osteomyelitis,[11] suppurative lymphadenitis,[12] pneumonia, and lung abscess.[13,14] Johnson and Kaye[15] reported 52 cases of serious infection caused by diphtheroid organisms; of these 60% of the patients had endocarditis and the remainder had a variety of infections including meningitis, osteomyelitis, and bacteremia. The most commonly identified organism in these reports has been *C pyogenes*, which is often associated with disease in farm animals. Infections in humans usually take the form of purulent lesions such as abscesses.[16]

Corynebacterium haemolyticum has been reported to cause acute respiratory illness, skin infection,[17] and brain abscess[10] but has not been implicated as a cause of osteomyelitis.

The following report concerns a diabetic woman with a foot ulcer and osteomyelitis who had pure cultures of *C haemolyticum* grown from specimens of her blood and first lumbar vertebra.

REPORT OF A CASE

A 71-year-old Pima Indian woman was admitted to the Phoenix Indian Medical Center with the complaint of "low back pain and foot ulceration." She had a 20-year history of diabetes mellitus that was controlled with diet and orally taken hypoglycemic agents. Complications of her diabetes included peripheral neuropathy with resultant foot ulcers, the most recent of which began three months prior to this admission. For the previous four to six weeks she had experienced increasingly severe back pain, especially in the upper lumbar region. She was bedridden for the three weeks prior to admission due to the severe pain.

Physical examination showed an elderly Indian woman who had complaints of back pain, and who had an oral temperature of 38.5 C. The chest was clear and there were no cardiac murmurs. There was kyphoscoliosis on the left side but no vertebral tenderness; however, there was significant paravertebral tenderness on the right side over the upper lumbar region. Straight-leg raising to 45° reproduced the patient's back pain. Her lower extremities demonstrated stasis changes. Her feet were severely deformed and several toes were absent, presumably due to neuropathy, trauma, and infection. There was a 2- × 3-cm ulcer with a clean base on the plantar surface of the right foot under the fourth and fifth metatarsal heads.

Pertinent laboratory data included the following: complete blood count with a hematocrit value of 28%, WBC count of 6,400/cu mm with a normal differential, and an erythrocyte sedimentation rate of 61 mm/hr. Urinalysis showed trace protein, and a urine culture grew less than 10,000 *Escherichia coli* per cubic centimeter. Serial measurements of fasting blood glucose were between 181 and 250 mg/100 ml. Serum protein electrophoresis revealed the following values: albumin, 2.65 mg/100 ml (normal, 3.5 to 4.7); α_1, 0.24 (normal, 0.23 to 0.39); α_2, 1.02 (normal, 0.59 to 0.91); β, 0.98 (normal, 0.69 to 1.37); γ, 4.09 (normal, 0.56 to 1.54); total protein, 9.00 (normal, 6.12 to 8.48); and albumin/globulin, 1:16. The remainder of the patient's laboratory tests, including urine for Bence-Jones protein, were normal or negative. Skin tests were negative for tuberculosis (both intermediate and second strength), coccidioidomycosis, and mumps.

A chest roentgenogram was normal. Roentgenograms of the feet disclosed considerable sclerosis of the metatarsals and proximal phalanges with multiple areas of bone fusion at the base of the metatarsals that were thought to be secondary to neuropathic changes. Roentgenograms of the lumbar spine demonstrated a destructive lesion of the anteroinferior aspect of the first lumbar vertebra, with definite disk-space narrowing of the pedicles (Figure). Vascular calcification and minimal changes of degenerative arthritis were also present.

Accepted for publication March 17, 1976.

From the Department of Dermatology, University of Iowa College of Medicine, Iowa City.

Reprint requests to Department of Dermatology, University Hospitals, Iowa City, IA 52242 (Dr Ceilley).

Biopsy needle entering destructive lesion in first lumbar vertebra.

The patient was initially treated with bedrest and symptomatic care. Culture from the foot ulcer at the time of admission grew a diphtheroid organism. The culture was then discarded by the laboratory because it was thought to be a contaminant. On the fifth hospital day, a diphtheroid organism was isolated from the patient's initial blood cultures under both aerobic and anaerobic conditions. Subsequently, a closed needle biopsy of her first lumbar vertebra was done under fluoroscopic observation (Figure). Histologically there was acute and chronic inflammation and special stain preparations were negative for acid-fast bacilli. A culture of material taken at the biopsy grew a diphtheroid species. *Corynebacterium haemolyticum* was then identified from the blood and vertebral cultures by the Clinical Bacteriology Section of the Center for Disease Control, Atlanta. During the interim the patient was treated for possible tuberculous osteomyelitis with streptomycin sulfate, isoniazid, and ethambutol. She remained febrile on this regimen.

After identifying the *C haemolyticum*, which was moderately sensitive to penicillin and highly sensitive to ampicillin, the antituberculous drugs were discontinued and ampicillin was begun intraveneously, 2 gm every four hours. She soon became afebrile and had a gradual diminution of her pain. After six weeks of bedrest and intravenously administered antibiotic therapy, medication was changed to orally given ampicillin, 500 mg, and probenecid, 500 mg, four times a day. A Jewitt hyperextension brace was fitted and gradual ambulation was started after six weeks. The foot ulcer healed uneventfully. Observation four months later showed gradual healing of the vertebra and slow resolution of her pain.

COMMENT

Corynebacterium haemolyticum was first identified in 1946 by MacLean and co-workers when they isolated a hemolytic Corynebacterium that resembled *C ovis* and *C pyogenes* from infections of the nasopharynx and skin of American soldiers in the South Pacific.[17] This species differs from *C pyogenes* primarily by its lack of proteolytic activity and from *C ovis* in its fermentative characteristics and its failure to produce a filterable dermal or lethal toxin.[17,18]

Washington et al[10] reported the first case of brain abscess caused by *C haemolyticum* in 1970. Kaplan and Weinstein[7] noted that serious infections (most commonly bacterial endocarditis) caused by species of *Corynebacterium* other than *C diphtheria* usually occurred in patients with predisposing underlying diseases. Johnson and Kaye[15] listed valvular heart disease with or without valvular prosthesis, surgery or trauma, malignancies, anatomic abnormalities of the CNS, otitis media, postpartum meningitis, hyaline membrane disease, diabetes, gangrene, cirrhosis, and systemic corticosteroid and immunosuppressant drug treatment as predisposing factors.

The pathogenesis of this case is not entirely clear. The ulceration of her foot antedated the back pain and may have been the source of her osteomyelitis. The initial culture from the foot was reported as "diphtheroid" and was unfortunately discarded by the laboratory. Subsequent cultures from the foot were negative. The patient had no contact with animals other than a house dog but she frequently walked barefoot outdoors and on the dirt floor of her home.

The concept that diphtheroids are nonpathogenic for man has been discarded. It is likely that this case represents an example of an opportunistic infection that began in the foot ulcer of this diabetic lady. This is especially true in the vulnerable host such as the diabetic or immunosuppressed patient. A high index of suspicion will be needed by both the clinician and laboratory to make the correct early diagnosis of serious infections caused by these organisms.

Kenneth S. Eades, MD, Chief, Department of Radiology, Phoenix Indian Medical Center, Ariz, interpreted the roentgenograms.

Robert E. Weaver, MD, PhD, Chief, Special Bacteriology Unit, Center for Disease Control, Atlanta, identified the organism in this case.

References

1. Shehadeh NH, Kligman AM: The bacteriology of acne. *Arch Dermatol* 88:829-831, 1963.
2. Kirschbaum JO, Kligman AM: The pathogenic role of *Corynebacterium acnes* in acne vulgaris. *Arch Dermatol* 88:832-833, 1963.
3. Sarkany I, Taplin D, Blank H: Erythrasma-common bacterial infection of the skin. *JAMA* 177:130, 1961.
4. Crissey JT, Rebell GC, Laskas JJ: Studies on the causative organism of trichomycosis axillaris. *J Invest Dermatol* 19:187-197, 1953.
5. Gill KA, Buckels LJ: Pitted keratolysis. *Arch Dermatol* 98:7-11, 1968.
6. Goldberg MH: Corynebacterium: An oral-systemic pathogen: Report of cases. *J Oral Surg* 29:349-351, 1971.
7. Kaplan K, Weinstein L: Diphtheroid infections of man. *Ann Intern Med* 70:919-929, 1969.
8. Blout JG: Bacterial endocarditis. *Am J Med* 38:909-922, 1965.
9. Merzbach D, Freundlich E, Metzker A, et al: Bacterial endocarditis due to *Corynebacterium*. *J Pediatr* 67:792-796, 1965.
10. Washington JA, Martin JW, Spiekerman RE: Brain abscess with *Corynebacterium haemolyticum*. *Am J Clin Pathol* 56:212-215, 1971.
11. Procek J, Hlaya H: Pyogenic *Corynebacterium* as a pathogen in osteomyelitis following a fracture. *Acta Chir Orthop Traumatol Cech* 28:546-548, 1961.
12. Roundtree PM, Carne HR: Human infection with an unusual *Corynebacterium*. *J Pathol Bacteriol* 94:19-27, 1967.
13. Williams GD, Flanigan WJ, Campbell GS: Surgical management of localized thoracic infections in immunosuppressed patients. *Ann Thorac Surg* 12:471-482, 1971.
14. Chlosta EM, Richards GK, Wagner E, et al: An opportunistic infection with *Corynebacterium pyogenes* producing empyema. *Am J Clin Pathol* 53:167-170, 1969.
15. Johnson WD, Kaye D: Serious infections caused by diphtheroids. *Ann NY Acad Sci* 174:568-576, 1970.
16. Vega LE, Gavan TL: *Corynebacterium pyogenes*: A pathogen in man. *Cleve Clin Q* 37:207-214, 1970.
17. MacLean PD, Liebow AA, Rosenberg AA: A hemolytic corynebacterium resembling *Corynebacterium ovis* and *Corynebacterium pyogenes* in man. *J Infect Dis* 79:69-90, 1946.
18. Hermann GJ: The laboratory recognition of *Corynebacterium haemolyticum*. *Am J Med Technol* 27:61-66, 1961.

Osler Node, Janeway Lesions, and Splinter Hemorrhages

Occurrence With an Infected Arterial Catheter

W. Lee Fanning, MD, Mark Aronson, MD

• This report documents the occurrence of an Osler node, subungual hemorrhages, and Janeway lesions peripheral to an infected arterial catheter. A brief review of these dermatological manifestations of infection is given and the importance of surgical removal of the involved artery after poor response to medical therapy is stressed.

***(Arch Dermatol* 113:648-649, 1977)**

Indwelling arterial catheters are utilized routinely to facilitate monitoring of blood pressure and blood gases in patients receiving intensive care for severe respiratory and cardiac disease. Complications described have included a 38% thrombosis rate,[1] a 23% peripheral embolization rate,[2] and a 4% infection rate.[3] Although common, these complications do not often cause serious difficulty. The following case report documents the unusual complication of an Osler node, Janeway lesions, and subungual splinter hemorrhages resulting from a staphylococcal infection of an indwelling arterial catheter.

REPORT OF A CASE

A 73-year-old woman was admitted to the Medical Center Hospital of Vermont for respiratory failure secondary to congestive heart disease. Because of the need for close monitoring of her blood gases, a right radial arterial catheter (18 gauge, 6 cm, catheter [Teflon]) was inserted percutaneously after 1% lidocaine anaesthesia and preparation of the skin with povidone-iodine (Betadine).

Four days after placement of the catheter, the patient complained of chills and developed a sudden temperature of 39.5 C. The WBC count was 12,000/cu mm with 78 neutrophils, nine nonsegmented neutrophils, 12 lymphocytes, and one eosinophil. Gentamicin sulfate, 100 mg every eight hours intramuscularly, was given after blood cultures were obtained from the arterial line and a peripheral vein. Twenty-four hours later purulent drainage was noted from around the arterial catheter. Gram stain revealed Gram-positive cocci in tetrads, the catheter was removed and cultured, the gentamicin stopped, and oxacillin 2 gm every four hours was begun. Coagulase positive *Staphylococcus aureus* sensitive to gentamicin and oxacillin grew from the catheter itself, blood obtained through the catheter, and blood from a peripheral vein.

Six days after catheter placement a tender erythematous nodule with a pale white center developed on the right ring finger (Osler node), subungual splinter hemorrhages were noted in the right hand, and multiple erythematous nontender papulo-nodular-hemorrhagic lesions (Janeway lesions) appeared on the dorsum of the hand, the palmar side of the fingers, and on the finger tips (Fig 1 to 3). No skin lesions developed at other sites and endocarditis was not clinically in evidence.

Despite continued oxacillin therapy, the patient remained febrile and developed a fluctuant erythematous area around the puncture site (Fig 4) that progressed despite antibiotic therapy. Surgical removal of the arterial segment was accomplished without difficulty under an axillary nerve block and a 5-cm segment of radial artery was removed that showed a false aneurysm. Microscopic examination of this segment revealed a large septic thrombus, severe suppurative arteritis, and periarteritis. Following surgery the patient recovered uneventfully receiving a total of two weeks of oxacillin and one week of di-cloxacillin. All lesions disappeared by two weeks after surgery.

COMMENT

Osler nodes, Janeway lesions, and subungual "splinter" hemorrhages are three of the major cutaneous manifestations of bacterial endocarditis. In the current antibiotic era they are infrequently seen in this disease,[4] but have been increasingly recognized as part of the clinical presentation of other illnesses.

Osler nodes were best described and given recognition as an important clue to endocarditis by William Osler[5] in 1909. In 1913 Weber[6] recognized Osler's contribution by calling the transient painful raised swollen areas with white centers seen in patients with bacterial endocarditis, Osler's sign. Pathologically, vascular inflammation has been found at the center of such lesions and bacteria have been demonstrated recently, suggesting an infectious pathogenesis.[7] Osler nodes have also been described in systemic lupus erythematosus, typhoid fever, gonococcemia, and hemolytic anemia.[8-10]

In commenting on the diagnosis of malignant endocarditis, Edward Janeway,[11] in 1899, described numerous small hemorrhages with a slight nodular involvement on the palms and soles and the arms and legs. Janeway lesions involving the fingers have also been described.[8] They appear in greater number than Osler nodes and unlike them, are nontender. In general, they are found with acute endocarditis, but are also found in subacute endocarditis.[8] Pathologically they show polymorphonuclear infiltration of capillaries with microabscess formation.[8]

Horder[12] in 1920 and Blumer[13] in

Accepted for publication March 2, 1976.

From the Infectious Disease Unit, Department of Medicine, University of Vermont College of Medicine, Burlington, Vt. Dr Aronson is now with Department of Medicine, Beth Israel Hospital, Boston. Dr Fanning is now with the Department of Medicine, Berkshire Medical Center, Pittsfield, Mass.

Reprints not available.

Fig 1.—Osler node on right ring finger; note small pale center. Lesion was extremely tender. A Janeway lesion is seen on palmar side of index finger.

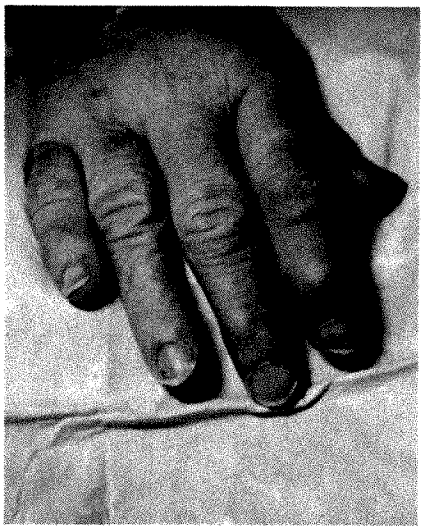

Fig 2.—Splinter hemorrhages are seen under fingernails of first and third fingers. Janeway lesions are noted on dorsum of hand and were nontender and slightly nodular.

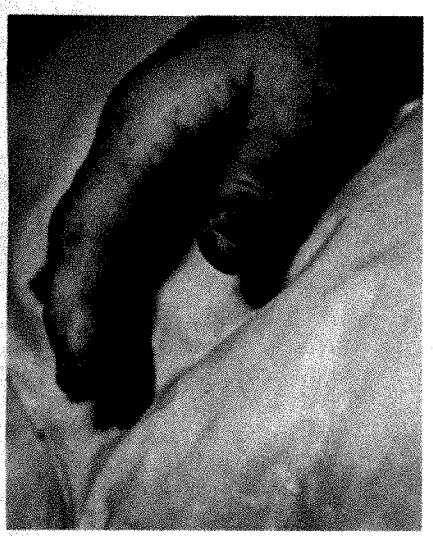

Fig 3.—Splinter hemorrhages are seen under thumb nail and a Janeway lesion is located on lateral aspect of index finger.

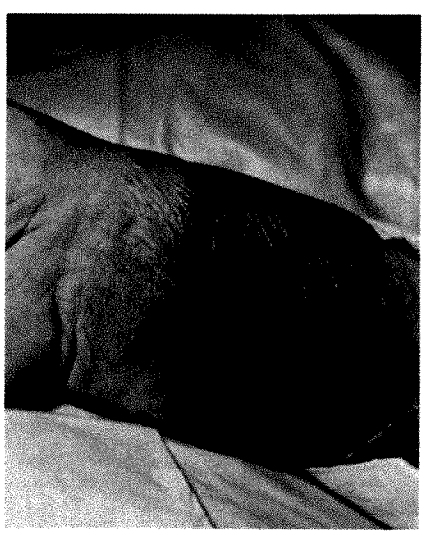

Fig 4.—Infected arterial catheter puncture site after removal of the catheter. Culture showed *Staphylococcus aureus*, coagulase positive.

1926 reported dark red streaks that resembled splinters underneath the fingernail in endocarditis. Although the specificity of this finding has been questioned since 18% of hospitalized patients have been reported to have splinters (primarily related to manual labor),[14] their development in a controlled setting without trauma and in the face of other signs of infection should make one suspect endocarditis. Other diseases in which they have been reported are trichinosis, vasculitis, and meningococcemia.[14]

The present case documents the development of an Osler node, Janeway lesions, and splinter hemorrhages in a patient with a staphylococcal infection of an indwelling arterial line. The pathogenesis of these skin lesions is unknown. Rarely have bacteria been cultured from these lesions and it is presently believed that they may be produced by an allergic mechanism,[1] although the rapidity of onset and their distribution in the current case argues in favor of an embolic etiology. The finding of an Osler node in a patient with an infected arterial catheter has been described once before with *Proteus mirabilis* being cultured from both blood and arterial catheter,[15] and splinter hemorrhages have been ascribed to noninfected arterial punctures.[16] Janeway lesions to our knowledge have not been previously described in this clinical setting.

Thus these three classical dermatologic signs may be produced from an infected indwelling arterial catheter and their presence dictates removal of the catheter for culture and initiation of antibiotics. Surgical removal of the infected artery may become as important as removal of an involved vein in septic thrombophlebitis.[17] Continued fever and clinical evidence of abscess formation around the vessel despite antibiotic therapy suggests the need for surgical intervention.

References

1. Bedford RF, Wollman H: Complications of percutaneous radial-artery cannulation. *Anesthesiology* 38:228-236, 1973.
2. Downs JB, Rackstein AD, Klein EF, et al: Hazards of radial-artery catheterization. *Anesthesiology* 38:283-286, 1973.
3. Gardner RM, Schwartz R, Wong HC, et al: Percutaneous indwelling radial-artery catheters for monitoring cardiovascular function. *N Engl J Med* 290:1227-1231, 1974.
4. Weinstein L: "Modern" infective endocarditis. *JAMA* 223:260-263, 1975.
5. Osler W: Chronic infectious endocarditis. *Q J Med* 2:219, 1909.
6. Weber FP: Osler's sign and certain cutaneous phenomenon sometimes associated with heart disease. *Q J Med* 6:284-290, 1913.
7. Alpert JS, Kerrs HF, Dalen JE, et al: Pathogenesis of Osler's nodes. *Ann Intern Med* 85:471-473, 1976.
8. Kerr A: *Subacute Bacterial Endocarditis*. Springfield, Ill, Charles C Thomas Publisher, 1956, pp 101-121.
9. Keil H: The rheumatic subcutaneous nodules and simulating lesions. *Medicine* 17:261-380, 1938.
10. Howard EJ: Osler's nodes. *Am Heart J* 59:633-634, 1960.
11. Janeway E: Certain clinical observations upon heart disease. *Med News* 75:257-262, 1899.
12. Horder T: Clinical significance and course of subacute bacterial endocarditis. *Br Med J* 2:301, 1920.
13. Blumer G: The digital manifestations of subacute bacterial endocarditis. *Am Heart J* 1:257-261, 1926.
14. Gross N: Splinter hemorrhages. *Br Med J* 2:1496, 1963.
15. Michaelson ED, Walsh RE: Osler's node—a complication of prolonged arterial cannulation. *N Engl J Med* 283:472-473, 1970.
16. Matthews J, Gibbons RB: Embolization complicating radial artery puncture. *Ann Intern Med* 75:87-88, 1971.
17. Stein JM, Pruitt BA: Septic thrombophlebitis. *N Engl J Med* 282:1452-1455, 1970.

Modern Radiotherapy for Malignant Epitheliomas

A Measure of Last Resort

Anthony T. Farina, MD; Morris Leider, MD; Joseph Newall, MD; Richard J. Carella, MD

• **There are exceptional cases of malignant epitheliomas in which radiotherapy is at once or eventually becomes a treatment of last resort. We recount the clinical facts, histologic findings, radiotherapeutic techniques, and results of treatment of seven such cases.**

(*Arch Dermatol* 113:650-654, 1977)

Basal cell and squamous cell carcinomas are the most common malignancies of the skin, the former indeed the most common of all malignancies of any tissue. Relative to them, cutaneous sarcomas (eg, Kaposi, dermatofibrosarcomas, angiosarcomas, and lymphosarcomas) and malignant melanomas are uncommon, although generally much more serious. Nevertheless, basal cell carcinomas on rare occasions and squamous cell carcinomas more often can be or can become as life threatening as the worst of malignancies of any type, anywhere. Ordinarily, these cutaneous malignancies are clinically suspected early, are usually easily recognized grossly and correctly by the trained dermatologic eye, and are readily confirmed by biopsies that are simple to perform. Ordinarily again, the average case is quickly and completely curable by any of several simple procedures that do not require highly complicated techniques or elaborate instruments. Curettage and electrodesiccation and minor, conventional scalpel surgery are the methods most commonly and satisfactorily employed because they are suitable for the usual case and practicable by most physicians. Radiotherapy could be used as often and as well for the general run of cases, but is used less often because it requires special skill and expensive, complex equipment. Cryotherapy with liquid nitrogen is a novel method that is reasonably effective for many cases, especially those that are multiple and superficial; chemosurgery is highly effective for any type of malignant epithelioma but is best reserved for the worst ones because of its requirement of several successive operations with a special technique and immediate, repeated histologic examinations of the surgical specimens—all by a team of specially trained personnel.

Recurrent and long-neglected malignant epitheliomas, those with instantly, inherently, and unusually aggressive biologic behavior (the multicentric, the "field fire," the burrowing varieties), those that are ill defined, and finally, those occurring around the eyes and in the nasal grooves are much more serious and difficult to manage than are average cases on the general expanse of the skin. The best and most definitive method for most such cases is, no doubt, chemosurgery, according to the original method of Mohs or recent refinements upon it (so-called fresh-tissue technique). There are, however, some such cases in which chemosurgery or major conventional surgery are contraindicated ab initio because the lesions have become too large from neglect, misdiagnosis, or rapid development or because they are situated in such a way in and about parts like the eyes,

Accepted for publication March 26, 1976.

From the Departments of Radiation Oncology (Drs Farina, Newall, and Carella) and Dermatology (Dr Leider), New York University Medical Center, New York.

Reprint requests to Department of Radiotherapy, New York University Medical Center, 566 First Ave, New York, NY 10016 (Dr Farina).

nose, ears, or deeper structures that must not be disturbed; or because poor general health, extreme debility, or advanced age does not permit surgery of any sort. And finally, there are occasional cases in which chemosurgery and conventional surgery of the most formidable sort fail to eradicate elusive malignant epitheliomas. In instances of these kinds radiotherapy becomes a modality of last resort that often ends in cure at best or control of progression for gratifyingly long times at least.

Following are seven representative cases in which radiotherapy was practiced in desperation when no other treatment was feasible or after all other reasonable forms of treatment had been accorded and failed. They illustrate what can be accomplished by modern radiotherapy under such circumstances.

REPORT OF CASES

Case 1.—About 20 years ago, a man now 74 years old had a squamous cell carcinoma resected from the upper lip followed by radiotherapy of unknown quality and quantity. Thirteen years later, in 1968, he developed several seemingly disparate lesions on the face about the nose. These lesions were treated indifferently until about a year later when he began to suffer continuous bloody discharge from the nose. By this time he was found to have an extensive, ill-defined mass involving the columella, septum, and walls of the nose (Fig 1). The tumor extended onto the upper lip. There were also two separate lesions, one in the right nasolabial groove and the other on the skin overlying the angle of the right mandible. Several biopsy specimens were taken and all were read as basal cell carcinoma. The process in and about the nose was deemed too extensive for chemosurgery or conventional surgery. Instead, it was irradiated with an apparatus that operated at 280 kV and 20 mamp, at a skin-target distance of 50 cm. The half-value layer was 3.1 mm of copper (Cu). From Oct 20 to Nov 7, 1969, a total dose of 5,000 rads was administered through a 6- × 8-cm portal in 15 fractions. The lesions in the right nasolabial groove and on the skin overlying the angle of the right mandible were simultaneously irradiated with an apparatus operating at 120 kV and 8 mamp, with added filtration of 3 mm of aluminum and a skin-target distance of 20 cm. The half-value layer was 3 mm aluminum. From Oct 20 to Oct 31, 1969, the lesions received a total dose of 4,500 rads each in ten fractions. The patient was seen at regular intervals until July 1973 (follow-up of 3½ years), at which time there was still no evidence of residual or recurrent disease (Fig 2).

Case 2.—A 58-year-old man became aware of a lesion on the pinna of the right ear seven years ago (1968). It was treated nonspecifically for two years and eventually was resolved by biopsy findings to be a basal cell carcinoma. By that time the lesion was extensive and involved the entire periauricular area. In November 1970 extirpation of the neoplasm was attempted by the chemosurgical technique. Four months later, in April 1971, recurrence of the malignancy was found and extirpation was again attempted by chemosurgery. Four months after that, in August 1971, the patient developed a deep ulceration at the angle of the mandible and a nodule behind his right ear (Fig 3). Results of a biopsy confirmed the clinical suspicion of more basal cell carcinoma. Tomograms of the right auditory canal and a routine skull series were normal. The malignancy was now considered too extensive to resect and the patient was referred for radiation therapy. The involved area was treated from Sept 9 to Oct 14, 1971, with a 280-kV apparatus (see other factors in case 1) and received a total dose of 6,000 rads in 25 fractions through a 6.5- × 6.5-cm portal. The mass responded well and seemed to disappear, although the area never epithelialized again completely. The local site remained reasonably well for about a year, at which time clinical evidence of cutaneous recurrence appeared and was proved by biopsy findings (Fig 4). It was the opinion of consultant surgeons that no definitively curative surgical procedure was possible because the malignancy was then found by use of roentgenography to involve the base of the skull. In October 1972 the accessible cutaneous component alone of the recurrent process was excised under local anesthesia. The patient survived comfortably for one year; he died at age 65 years of cardiovascular disease and not of the malignancy.

Case 3.—Six years ago, a 76-year-old man began to develop an elevated lesion on the left cheek. It was observed for an unduly long time and was eventually (in January 1972) resolved at biopsy to be a basal cell carcinoma. By then the lesion was extensive and involved nearly the entire left side of the face (cheek, upper and lower eyelids, upper lip, and nose) (Fig 5). The lower eyelid and ala nasi were nearly completely destroyed by the malignant process. The patient had bilateral cataracts and no useful vision in the left eye. Because the size and location of the malignancy and the patient's poor cardiovascular condition precluded surgery, radiotherapy was resorted to. The involved area was irradiated with an apparatus operated at 280 kV and 20 mamp, at a skin-target distance of 50 cm; the half-value layer was 3.1 mm Cu. Treatment was given over a period of a month (from Jan 17 to Feb 15, 1972). He received a total dose of 5,500 rads through a 8- × 9-cm portal in 20 fractions. During the course of radiation therapy the malignancy was seen to regress gradually, and within six weeks from the start of treatment, seemed to have vanished. The skin was completely epithelialized again in another six weeks. The patient has been followed up at regular intervals and at last examination in September 1975 (follow-up of 3½ years) there was no clinical evidence of disease (Fig 6).

Case 4.—A 39-year-old man, a native of Italy, developed a lesion on the bridge of the nose in 1960. A biopsy was done and the lesion was confirmed to be basal cell carcinoma; it was treated with a radium mold (technical details not available). In June 1967 the epithelioma recurred and was managed by local excision and skin graft. In the following four years several more recurrences appeared and were also treated by conventional scalpel surgery. All of the above treatments were accorded in his native land. By March 1971 the malignancy was extensively recurrent, involved the entire glabella, and extended onto both the right and left medial canthi. The patient was brought to the United States specifically for chemosurgery. Extirpation was attempted by the chemosurgical technique, but the procedure had to be abandoned when the underlying bone was found to be invaded by the malignant process. In April 1971 radical excision of the nasal bones, outer table of the frontal sinus, anterior ethmoid cells, and nasal process of the frontal bone were done here. The histologic sections showed basal cell carcinoma in fragments of bone and in all specimens of the exposed respiratory epithelium. One year later (May 1972) extensive, recurrent basal cell carcinoma developed in the middle third of the left side of the face with invasion and destruction of the left globe. There was also suspicion of malignant process on the medial wall of the right orbit. Exenteration of the left orbit was done and biopsy specimens were taken of the right posterior ethmoid cells, medial wall of the right orbit, and conjunctiva of the right eye. All of these sites were histologically positive for malignancy (Fig 7). The patient was referred for radiotherapy, and from June 22 to Aug 8, 1972, the entire area judged to be affected by the malignancy was irradiated with a telecobalt

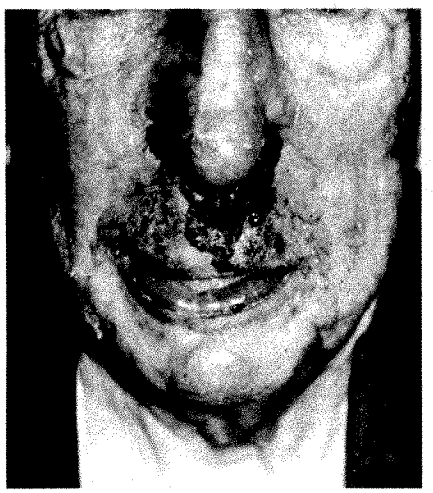

Fig 1.—Basal cell carcinoma in and about nose in patient (case 1). Note hemorrhage from erosion.

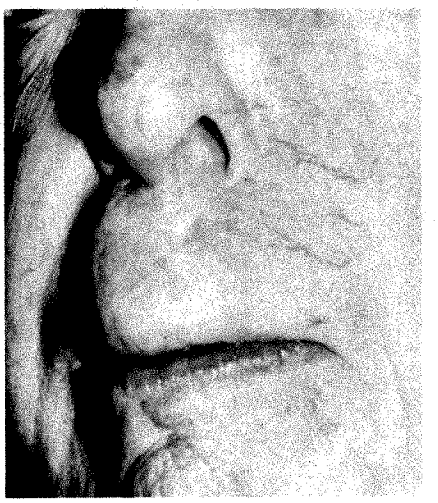

Fig 2.—Clinical appearance of patient shown in Fig 1, taken 3½ years after radiotherapy.

Fig 3.—Basal cell carcinoma in and about ear in patient (case 2). Note ulceration.

Fig 4.—Clinical appearance of patient shown in Fig 3, three months after radiotherapy. There is still some failure of epithelialization.

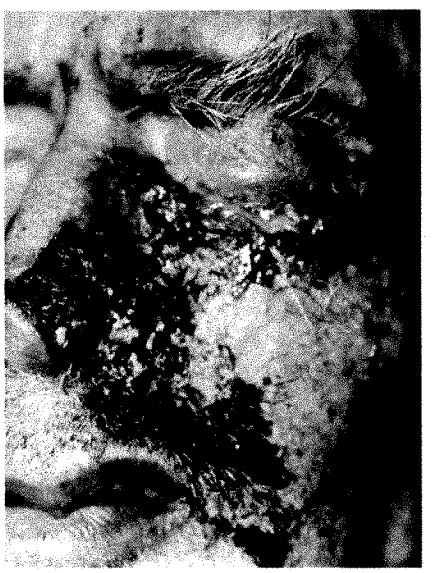

Fig 5.—Basal cell carcinoma of nearly half the face in patient (case 3). Note extensive erosion.

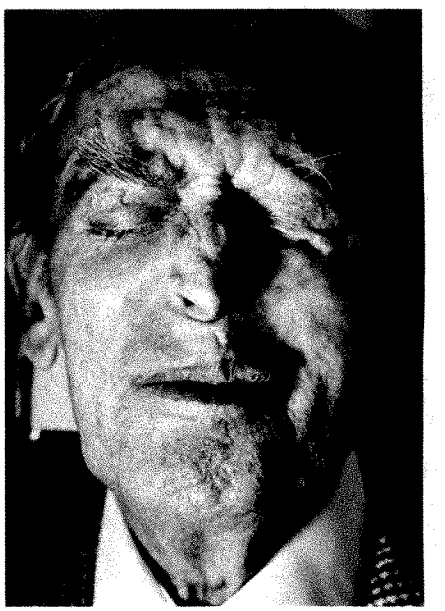

Fig 6.—Clinical appearance of patient shown in Fig 5, three years after radiotherapy.

apparatus. A total dose of 6,500 rads in 28 fractions over a period of 47 days was administered through a 9- × 9-cm portal. A bolus in the form of gauze was placed over the area to be irradiated throughout the course of treatment to bring the maximum action of the cobalt 60 gamma rays to bear upon the most superficial part of the malignant process.

The patient returned to Italy. At last follow-up by correspondence in December 1974 (2½ years after radiotherapy) he was alive, well, and had vision in the remaining right eye, although otherwise he was sadly mutilated.

CASE 5.—A 61-year-old woman developed a "swelling" in the region of the left nasolabial fold in 1968. The lesion persisted, and it was not until 1972 that a biopsy was performed. At the time the lesion was reported to be a benign keratoma. In May 1973 the patient developed pain in the general area of the lesion. When that symptom persisted, another biopsy specimen was taken in September 1973; this time it was reported to be a trichoepithelioma. Dissatisfaction with the behavior of the process impelled a third biopsy in November 1973, and then the presence of morphea-type basal cell carcinoma was disclosed. By then the tumor was extensive and involved a large portion of the left cheek, the left lower eyelid, the left side of the nose, the left nasolabial groove and fold, and the left upper lip (Fig 8). The lower portion of the tumor on the upper lip extended beyond the midline to the right side. Roentgenographic examination of the facial bones was normal. In consultation, the consensus was that surgery would require so massive a resection that an unacceptable cosmetic result would ensue in this patient who, moreover, rejected the very idea of any surgery. Radiotherapy became the sole resort. The malignancy

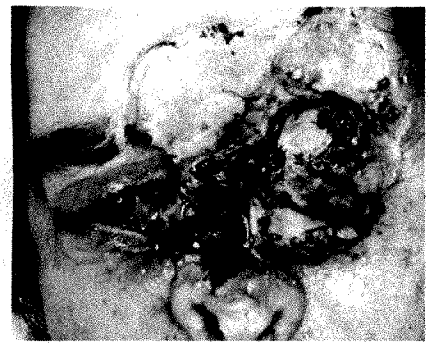

Fig 7.—Clinical appearance of patient (case 4) immediately prior to radiotherapy.

Fig 8.—Morphea type basal cell carcinoma in patient (case 5). Note palpable extent of lesion roughly outlined.

Fig 9.—Clinical appearance of patient shown in Fig 7 after radiotherapy. Note relatively normal appearance of previously affected skin.

Fig 10.—Basosquamous carcinoma around and on ear in patient (case 6). Palpable extent of process is marked out.

Fig 11.—Clinical appearance of patient (case 7) immediately prior to radiotherapy.

was irradiated with an apparatus operated at 280 kV and 20 mamp, at a skin-target distance of 50 cm; the half-value layer was 3.1 mm Cu. Treatment was given from Dec 5, 1973, to Jan 7, 1974. A total dose of 5,000 rads in 20 fractions through a 10- × 10-cm portal was received. During the course of treatment there was gradual regression of the tumid process, which upon completion of the full course was about half its original bulk. During the year following completion of the radiation therapy, the mass continued to regress slowly and in December 1974 was about a quarter of its original size (Fig 9). In the follow-up period to date (15 months), further regression has occurred, and there is as yet no compelling reason to warrant another biopsy.

Case 6.—An 81-year-old man began to develop a palpable mass behind the lobe of the right ear about three years ago. The lesion gradually enlarged and one year later involved the entire surface of the right earlobe and extended onto the posterior auricular groove. Results of a biopsy proved it to be basosquamous carcinoma. The malignancy was treated by electrodesiccation and curettage. One year after that, in November 1973, it was clinically evident that there was persistent disease on the lobe of the right ear, and extirpation was again attempted by electrodesiccation and curettage; however, it had to be abandoned when it became apparent that the process was too extensive to be eradicable by that method. A month later, in January 1974, the malignant process was found to extend from the now partially mutilated right earlobe onto the skin overlying the inferior temporal region and the parotid gland (Fig 10). It was the opinion of several surgeons that there was too high a risk of damaging the facial nerve if this lesion were to be excised by conventional scalpel surgery. It was therefore irradiated with an apparatus operated at 280 kV and 20 mamp, at a skin-target distance of 50 cm and a half-value layer of 3.1 mm Cu. Treatment was given from Jan 28 to Feb 14, 1974, to a total dose of 5,000 rads in 15 fractions through a 4 × 7-cm portal. Upon completion of the radiotherapy, the massive process had completely disappeared. To date, a regular follow-up for more than one year has disclosed no evidence of local disease.

Case 7.—A 74-year-old woman became aware of a skin change on the right side of the forehead four years ago. It was observed and treated conservatively for a time, but when it persisted unduly was finally resolved by biopsy to be a morphea-type basal cell carcinoma. By this time it was extensive and involved much of the skin on the right side of the forehead and scalp; numerous papules, crusts, and an ulcer measuring 1.5 cm in diameter were present in the area of involvement. Immediately prior to treatment, in July 1973, a biopsy specimen of the lesion was taken again, and basal cell carcinoma was reconfirmed. The lesion was excised by the fresh-tissue technique of Mohs, and all the margins were judged to be clear of malignancy. Three months later, however, in September 1973, there was clinical suspicion and then histologic proof of recurrence involving the frontal area of the scalp and brow, the eye, the ethmoid sinuses, and the zygomatic region, all on the right side. There was also exophthalmus of the right eye from extensive orbital involvement. The patient was then subjected to radical excision of the skin and subjacent tissue of the frontal area, orbital exenteration, and ethmoidectomy. Six months later, in March

1974, a lesion appeared on the left side of the forehead, which upon biopsy proved yet again to be a basal cell carcinoma. Extirpation was again attempted by the fresh-tissue technique of Mohs and this time had to be abandoned when it was found that the malignancy was too extensive and deep to be resectable by this method. It had extended from the supraorbital ridge deep into the left frontal bone (Fig 11). Tomograms of the left orbital bones were fortunately normal. In an attempt to save the remaining eye, which would have had to be sacrificed if surgery were practiced, the patient was referred for radiation therapy. The malignant process was irradiated with an apparatus operated at 280 kV and 20 mamp, at a skin-target distance of 50 cm and a half-value layer of 3.1 mm Cu. From March 18 to April 12, 1974, a total dose of 5,000 rads in 20 fractions was delivered to the area through a 6.6- × 8.0-cm portal. The eye was protected by lead shields. By the time the course of radiotherapy was completed, the extensive process had disappeared. As of the last follow-up in December 1974 (eight months later), no evidence of local disease could be detected, and the remaining eye was functional.

COMMENT

Electromagnetic energy of any wavelength and in any amount (particularly that of the spectrum from ultraviolet to gamma radiation) is harmful to animal tissues when directly applied. After plant life, living things have no means or need of utilizing electromagnetic energy directly applied, except in conversion of ergosterol to vitamin D early in life. Depending upon wavelength, duration of irradiation, and kind of tissue, the degree of harm from electromagnetic energy may be trivial, temporary, transient, and remediable or instantly severe and progressively and irremediably destructive. With modern knowledge of the relative radiosensitivities of normal and abnormal tissues and with versatile modern equipment, this fact of harmfulness of electromagnetic energy can be turned to good by selective focusing of it upon radiosensitive abnormal tissue. This is the fortunate situation in many instances of cancer in which cancerous tissue is more radiosensitive than normal tissue, in which it is not affordable to sacrifice much normal tissue surgically, or where normal tissue has to be preserved absolutely for functional and cosmetic reasons. Such were the circumstances in the cases recounted here.

It has become possible now, and may become even more so in the future, to apply electromagnetic energy so artfully that many more instances of seemingly hopeless cancers of the skin and elsewhere may be cured outright or significantly alleviated by this relatively clean and painless means. Given that the extent, depth, and dispersion of malignant process is determinable by clinical judgment and by other more precise means like standard and special radiography, given proper equipment (x-ray machines of grenz, superficial, orthovoltages and megavoltages, radioactive cobalt, and other sophisticated generators of electromagnetic and particle energy), and finally, given proved experience of effective and bearable dosage, skillful application of destructive energy can eliminate abnormal tissue that mechanical means (like the curette, knife, cautery, and refrigeration), cytotoxic drugs, and immunologic strategems may not as yet be able to do.

This is not the place to go into fine details about radiotherapeutic technique as practiced by nondermatologic specialists in radiotherapy beyond saying that field size, total dose, fractionation, shielding, penetrability, and depth of effective dose, choice of machine, and known radiosensitivity of normal and abnormal tissues are some of the factors that enter into the plan and design of treatment in particular cases. Such was the practice in the cases reported, and if the results were not in every instance curative, some good in the form of halting progression of malignancy and no worsening were always achieved.

Panniculitis of the Legs With Urate Crystal Deposition

Report of a Case

Kirsti-Maria Niemi, MD

• Dark red nodules that drained an opaque amber liquid developed on the extensor surfaces of both legs in a 69-year-old woman receiving furosemide and spironolactone for congestive heart failure. In addition to asymptomatic cholelithiasis, the serum amylase, lipase, and uric acid levels were elevated. Other skin signs and joint manifestations of gout were absent. A biopsy revealed a granuloma with the needle-like crystals characteristic of gout.

(*Arch Dermatol* 113:655-656, 1977)

In this report a patient is described who had subcutaneous fat necrosis on the legs as the only cutaneous sign of gout.

REPORT OF A CASE

This 69-year-old woman was admitted to the hospital because of tender suppurating nodules on the anterior aspects of her legs of six months' duration in August 1975. The nodules were large, thick, and dark and drained an opaque fluid (Fig 1). Both legs were edematous. For two years she was given spironolactone and furosemide regularly for cardiac failure. There had been varices of both legs for at least ten years and a superficial thrombophlebitis occurred in the right leg six years ago. She had a history of severe arthrosis of both hip joints for several years. Arthroplastic surgery with endoprothesis was performed on the left hip joint in 1972. Arthrosis was also manifest in the finger and knee joints.

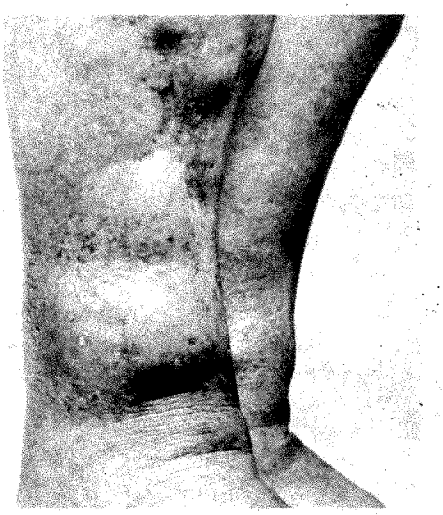

Fig. 1.—Large nodules around edematous legs. Nodules discharged opaque fluid from small fistules or real ulcers.

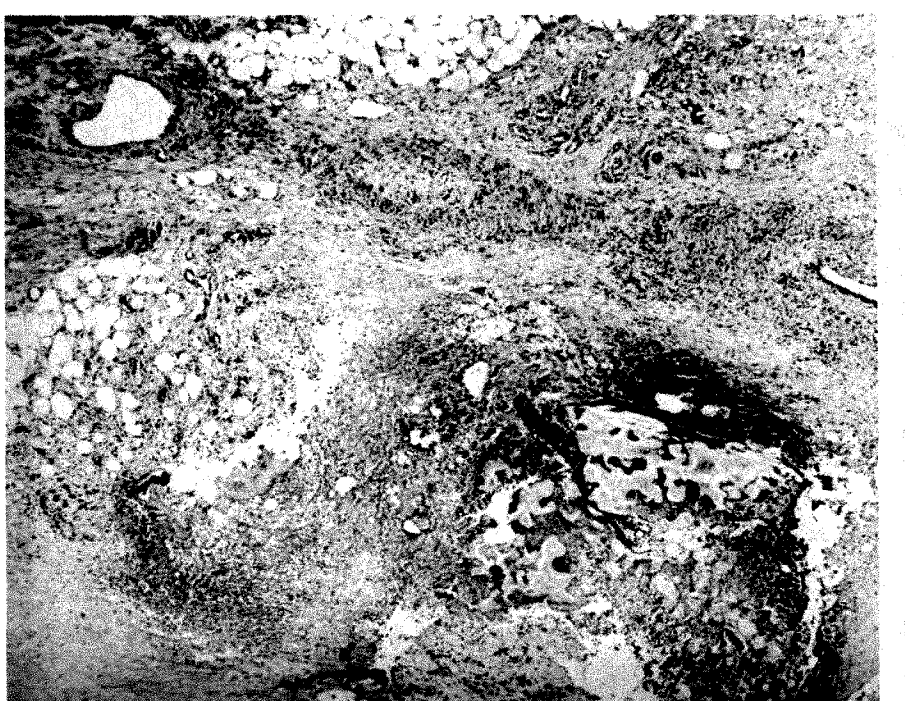

Fig 2.—Subcutaneous fat necrosis with palisade arrangement of fibroblasts (hematoxylin-eosin, 2.5 × 12.5).

Accepted for publication March 17, 1976.

From the Department of Dermatology, University Central Hospital, Helsinki.

Reprint requests to the Department of Dermatology, University Central Hospital, SF-00170 Helsinki 17, Finland (Dr Niemi).

Fig 3.—Blue-staining homogenous bodies within necrotic area (hematoxylin-eosin, 10 × 12.5).

Fig 4.—Doubly refractile needle-like structures consistent with urate deposits on polaroscopic examination (hematoxylin-eosin, 40 × 12.5).

Asymptomatic cholelithiasis was found during her hospitalization.

A skin biopsy (Fig 2) showed extensive subcutaneous fat necrosis. Palissading fibroblasts and histiocytes surrounded the necrotic area. Within this palissading granuloma were large, homogenous, discrete areas that stained pale blue (Fig 3). In one corner there were large needle-like crystals that were birefringent in polarized light (Fig 4). The amorphous areas and crystals were consistent with urate deposits.

Her serum uric acid concentration was 9.9 mg/100 ml, ie, twice the normal value. Also serum amylase concentration was 438 units/liter with normal 70 to 300 units/liter amylase test (Phadebas)[1] and serum lipase concentration of 1.95 Tietz-Units was elevated. Serum creatinine level was 1.3 mg/100 ml and creatinine clearance was 40 ml/min which is below normal. Serum glucose concentration was 105 mg/dl and in the oral glucose tolerance test the two-hour value remained at the level 205 mg/dl. Sedimentation rate was 92 mm/hr. Findings from hemoglobin level, hematocrit reading, WBC and differential cell counts, serum sodium, potassium, calcium, phosphate, total bilirubin, and protein concentrations were normal. Serum protein fractions in cellulose acetate electrophoresis were normal although serum albumin concentration 32 gm/liter was slightly below normal. Serum aspartate aminotransferase, alanine aminotransferase, lactate dehydrogenase, and alkaline phosphatase[2] as well as serum thyroxine were normal. A low protein, purine diet was ordered and allopurinol, 300 mg, and probenicid, 500 mg, were administered. Spironolactone (50 mg), furosemide, 80 mg daily, and digoxin were also continued. Within six weeks the lipase and uric acid levels returned to normal.

COMMENT

According to Lichtenstein et al,[3] extraskeletal deposits of urates in the skin and subcutis of gouty subjects are usually found on the ears, hands, and feet. Gottron and Korting[4] described skin deposits only on the hands adjacent to joints. In our patient tophi were not found on these usual locations. She had never had acute gouty arthritis, and had no family history of gout. This does not, however, exclude primary gout.[5] This patient had neither hemopoietic disorders nor other diseases that are known to cause an elevation of serum uric acid. Treatment with spironolactone and furosemide, well-known blocking agents of the renal secretion of uric acid, could explain the elevation in serum uric acid.[6] Antecedent fat damage caused by elevated serum amylase and lipase levels as well as circulatory stasis in the legs secondary to varices and cardiac failure, probably contributed to the deposition of urate in the skin. Pancreatic disease is known to cause suppurative panniculitis of the legs.[7,8] Secondary gout should be added to the growing list of disorders associated with nodose lesions of the lower extremities. The use of diuretics has increased the occurrence of secondary gout, and this could in turn lead to other unusual cutaneous manifestations.

Nonproprietary Name and Trademark of Drug

Allopurinol—*Zyloprim.*

References

1. Ceska M, Brown B, Birath K: Ranges of α-amylase activities in human serum and urine and correlations with some other α-amylase methods. *Clin Chim Acta* 26:445-453, 1969.
2. Committee on enzymes of the Scandinavian Society for Clinical Chemistry and Clinical Pathology. *Scand J Clin Lab Invest* 33 (suppl):291-306, 1974.
3. Lichtenstein L, Scott HW, Levin MH: Pathologic changes in gout. *Am J Pathol* 32:871-886, 1956.
4. Gottron HA, Korting GW: Chronische Hautgicht. *Arch Klin Exp Dermatol* 204:482-499, 1957.
5. Gutman AB: A view of gout as inborn error of metabolism. *Am J Med* 29:545-553, 1960.
6. Young DS, Pestamer LC, Gibberman V: Effects of drugs on clinical laboratory tests. *Clin Chem* 21:125D-212D, 1975.
7. Hughes PSH, Apisarnthanarax P, Mullins JF: Subcutaneous fat necrosis associated with pancreatic disease. *Arch Dermatol* 111:506-510, 1975.
8. Bennet RG, Petrozzi JW: Nodular subcutaneous fat necrosis. *Arch Dermatol* 111:896-898, 1975.

Skin Changes in Short-Bowel Syndrome

Kwashiorkor-like Syndrome

Stephen Z. Smith, MD

• An infant with short-bowel syndrome developed flexural desquamation and "enamel paint" skin in pressure-bearing areas. Hyperalimentation with amino acid and lipid solution was unsuccessful in correcting the malnutrition and skin changes.

(*Arch Dermatol* 113:657-659, 1977)

In severe malnutrition in infancy from the short-bowel syndrome, parenterally given nutrition must supply electrolyte, amino acid, vitamin, mineral, and fatty acid. The importance of adequate fatty acid supplementation has been demonstrated in animals,[1] infants,[2,3] and adults.[4,5] Dry, scaly, erythematous lesions of the neck, axilla, antecubital fossa, and groin and generalized xerosis are seen. The patient whose case we report had skin changes similar to those reported in other cases, but the changes fit the description of the cutaneous signs of kwashiorkor.[6,7]

REPORT OF A CASE

A 6-week-old male infant was the product of a normal term pregnancy and delivery. Vomiting occurred with formula-feeding, but abated with an alternate formula. He gained only 255 gm from his birth weight of 3,164 gm during the first month. He was admitted to another hospital with a four-day history of fever, vomiting, and diarrhea and was severely emaciated, dehydrated, and distended. Bowel sounds were diminished; x-ray films showed large- and small-bowel distension. Initial impression was a severe gastroenteritis with ileus. Exploratory laparotomy on Nov 26, 1975 disclosed multiple large segments of necrotic small bowel (lower jejunum and ileum), which were resected, and multiple liver abscesses. Pathological diagnosis was "necrotic bowel" of undetermined origin. Systemic administration of antibiotics was begun, and the patient was transferred to the University of California at San Francisco for hyperalimentation.

The infant was treated with fluids to compensate for severe third-space losses secondary to his disease, and surgical correction was carried out. He was placed on a regimen of gentamicin sulfate and ampicillin sodium because of apparent Gram-negative septicemia and shock. His hospital course was characterized by thrombocytopenia (platelet count, 50,000 to 60,000/cu mm), leukocytosis (WBC count, 30,000/cu mm with 89% polymorphonuclear leukocytes, 7% lymphocytes, 3% monocytes, and 1% eosinophils), and a decreasing hemoglobin level (14 to 8 gm/100 ml). Elevated prothrombin time and partial thromboplastin time were treated with phytonadione and fresh frozen plasma. Total serum protein, serum albumin, and serum globulin levels were 2.1, 1.1, and 0.9 gm/100 ml, respectively (all below normal), but immunoelectrophoresis results were normal. Phenobarbital was required to control grand mal seizures, which began on Nov 28. On Dec 3, an x-ray film disclosed a pneumoperitoneum; subsequently, exploratory laparotomy demonstrated several punctate bowel perforations. After this procedure, hyperalimentation was begun with 3% amino acid synthetic solution (Freamine) and 5% glucose in water.

There were no skin changes on admission, but on Dec 4, he was noted to have flexural erythema and scaling. Results of examination revealed antecubital and popliteal fossae with brownish-red, well-defined, waxy, scaled lesions that fissured along tension lines (Fig 1, left and right) and that easily desquamated large flakes of scale. His neck had similar, though less dramatic changes. The cheeks, buttocks, and localized areas of the back showed brown, scaling patches where contact with the incubator had been made. The groin and incisional regions had superficial ulcerations (Fig 2). Skin cultures grew a few colonies of *Staphylococcus epidermidis* and *Proteus mirabilis*. Completely normal-appearing skin on the extremities and trunk, aside from the areas described above, remained clear throughout the hospital course.

The scalp was normal, except for a 2-cm oval region of hair loss that resulted from protracted pressure. The clinical similarity of this patient's cutaneous eruption and the history of malabsorption suggested a protein and/or fatty acid deficiency. Initially, sunflower acetyl oil[8] was applied to the skin of the forearm; there was no improvement after three days. Intravenous administration of soybean oil (Intra-

Accepted for publication June 10, 1976.

From the Department of Dermatology, University of California at San Francisco. Dr Smith is now with the University of Louisville (Ky) School of Medicine.

Reprint requests to Department of Dermatology, University of California School of Medicine, San Francisco, CA 94143 (Dr Smith).

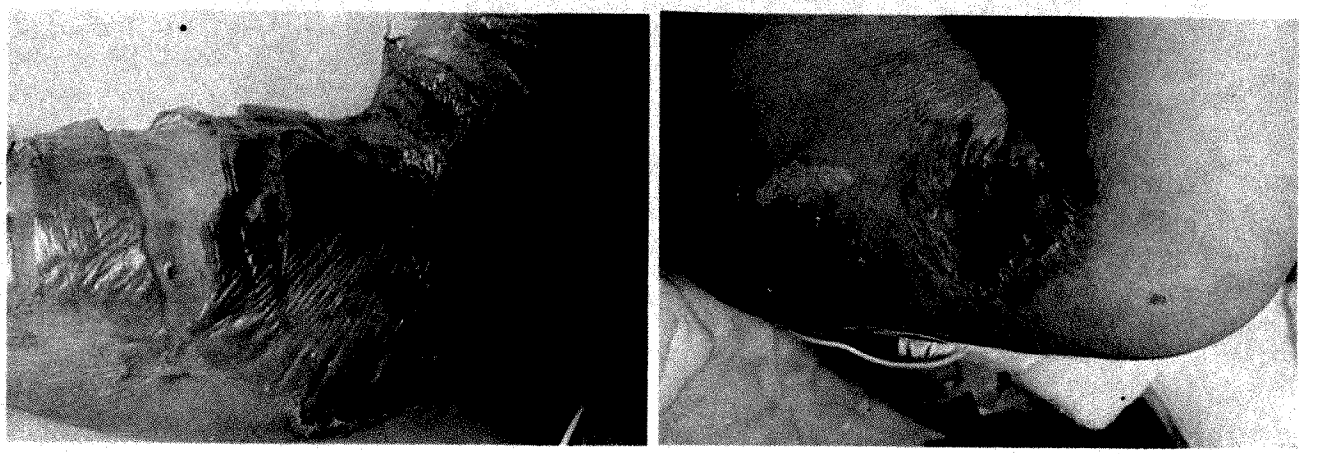

Fig 1.—Right antecubital fossa and right popliteal fossa showing waxy, scaled lesions fissuring along tension lines.

Fig 2.—Superficial erosions in groin and incisional region.

lipid [Sweden]; no comparable US product) in a 10% solution was begun. Progressive deterioration with recurrent bowel perforation, *Pseudomonas* sepsis, hematological chaos, and respiratory collapse led to death on Dec 9. No change in the skin lesions occurred during the last days of life.

Family history disclosed that one male sibling had died shortly after birth with gastroschisis.

Autopsy findings revealed malignant histiocytosis involving the small bowel, bone marrow, esophagus, liver, and spleen. Sections of involved and uninvolved skin showed no abnormal histiocytes. Neither lymph nodes nor thymus were abnormal. Involved skin showed minimal hyperkeratosis and acanthosis, with normal corium and subcutaneous tissue.

COMMENT

Kwashiorkor in its polar form results from a diet that is poor in protein, qualitatively and quantitatively, but that supplies adequate to excessive caloric intake, usually in the form of sugar or starch. Marasmus, on the other hand, is a condition that results from total caloric deprivation, including protein, sugar, starch, and other nutrients. The skin in the marasmic child is loose, wrinkled, and dry, but lacks the edema and dermatosis that delineate kwashiorkor.[6,7] Most reports of kwashiorkor are from the Middle East and Africa, where nutrition is usually adequate in calories but bereft of proteins. The stunted child with bulbous abdomen, moon facies, edematous skin, and psychomotor abnormalities is the frightful result. Trowell[9] gave the classical description of kwashiorkor's cutaneous findings. The "enamel paint" skin he described starts with erythema, but rapidly is followed by purple patches that feel waxy and are sharply demarcated from the adjacent normal skin. Since these changes occur in pressure areas (knees, elbows, buttocks) and flexures (groin, popliteal, and antecubital fossae), movement initiates cracking of the skin. Its "flaky paint" character, as described by Trowell et al,[10] can be seen in Fig 1 and 2, and in the photographs of McLaren and Gillman.[6,7] Less often, several lesions coalesce to form large reddish-brown flaking patches that are hard, dry, and fissured. Large areas of skin may be eroded.[6-9] Linear fissuring of the flexures (Fig 2) beneath the toes, foreskin, and oral commissures disclose raw, tender skin, which limits movement. Any shearing or pressure force is met with little resistance, and blister formation is common. Depigmentation, pallor, characteristic hair changes, and nail deterioration are hallmarks of advanced disease.[11]

The remarkable similarity of this infant's cutaneous changes to those described above and the remark of McLaren[6] that extensive intestinal

resection has resulted in similar cutaneous changes were the bases for the diagnosis of iatrogenic kwashiorkor. The loss of a substantial portion of the intestinal tract made nutrition impossible without total parenteral supplementation. The infant had been sustained seven to ten days with inadequate, but life-supporting nutritional intravenous mixtures, mainly carbohydrate in caloric content. The flexural erythema began shortly before parenteral hyperalimentation. The postmortem diagnosis of histiocytosis X was unsuspected. Cutaneous changes in histiocytosis X[12-14] classically show purpuric, greasy, scaly papules that occur in crops on the scalp, face, neck, trunk, and buttocks. Crusting lesions rarely occur in flexures, but have a papular component. There are no reports of the marked sheet-like desquamation that occurred in this case. Fatal familial histiocytosis (Barth et al[15]), a malignant histiocytic disease with invasion of the reticuloendothelial system, has eosinophilia, primary immunodeficiency, profound lymphocytic depletion of lymph nodes, thymus, spleen, and gut lamina propia, and a generalized maculopapular skin rash; these findings were not present in this case.

The reports of Riella et al,[5] Paulsrud et al,[2] and Caldwell et al[3] brought attention to the possible role of fatty acid metabolism in the pathogenesis of these skin changes. Aaes-Jorgensen[16] extensively described the scaly erythematous skin; none of these reports demonstrated the marked severity or extent of lesions as in our case. The impelling need to reverse the rapid, downhill clinical course precipitated the use of sunflower seed oil shown by Press et al[8] to be effective in replacing essential fatty acids, particularly linoleic acid. Simple regular application to flexor aspect of the forearms resulted in sufficient percutaneous absorption of lineoleic acid to reverse fatty acid deficiency syndrome in several weeks. Recent studies[16-18] reported a characteristic abnormal lipid pattern in fatty acid deficiency that reflected the requirement for lineoleic acid, a nonbiosynthesized fatty acid. However, administration of neither sunflower seed oil nor soybean oil in 10% solution reversed the clinical course. Riella et al[5] corrected fatty acid deficiency and reversed the cutaneous changes with soybean oil, but two weeks of therapy were required.

This case illustrates the cutaneous signs of malnutrition in infants with major bowel resection. Early recognition may permit institution of total parenteral alimentation with protein and fatty acid precursors. The necrotic bowel that required resection in this child resulted from terminal histiocytosis, but in other cases of short-bowel syndrome, adequate parenteral alimentation is very important. Perhaps the restitution of nutritional needs would make the seriously ill infant more capable of withstanding the attack of infections, electrolyte shifts, and hematologic abnormalities. Adults have similar cutaneous changes[5,19] that presage nutritional insufficiency; early recognition should be useful in managing patients receiving total parenteral alimentation.

The cost of the color reproduction was paid for by Westwood Pharmaceuticals Inc.

Nonproprietary Name and Trademark of Drug

Gentamicin sulfate—*Garamycin.*

References

1. Holman RT: Essential fatty acid deficiency, in Holman RT (ed): *Progress in the Chemistry of Fats and Other Lipids.* Oxford, England, Pergamon Press, 1968, vol 9, pt 2, pp 280-283.
2. Paulsrud JR, Pensler L, Whitten CF, et al: Essential fatty acid deficiency in infants induced by fat free intraveneous feeding. *Am J Clin Nutr* 25:897-904, 1972.
3. Caldwell MD, Johnson HT, Othersen HB: Essential fatty acid deficiency in an infant receiving prolonged parenteral alimentation. *J Pediatr* 81:894-898, 1972.
4. Richardson TJ, Sgoutas D: Essential fatty acid deficiency in four adult patients during total parenteral nutrition. *Am J Clin Nutr* 28:258-263, 1975.
5. Riella MC, Broviac JW, Wells M, et al: Essential fatty acid deficiency in human adults during total parenteral nutrition. *Ann Intern Med* 83:786-789, 1975.
6. McLaren DS: Nutritional diseases, in Fitzpatrick TB, Arndt KA, Clark WH (eds): *Dermatology in General Medicine.* New York, McGraw Hill Book Co Inc, 1971, pp 1074-1078.
7. Gillman T: Nutritional influences on the skin in man, in Champion RH, Gillman T, Rook AJ, et al (eds): *An Introduction to the Biology of the Skin.* Philadelphia, FA Davis Co, 1970, pp 355-386.
8. Press M, Hartop PJ, Prottey C: Correction of fatty acid deficiency in man by cutaneous application of sunflower seed oil. *Lancet* 1:597-599, 1974.
9. Trowell HC: Kwashiokor. *Trans Roy Soc Trop Med Hyg* 33:389, 1940.
10. Trowell HC, Davies JNP, Dean RFA: *Kwashiorkor.* London, Edward Arnold Publishers, Ltd, 1954.
11. El-Hefnawi H, Shakri AS, Rasheed A: Kwashiorkor in the United Arab Republic. *Br J Dermatol* 177:137-150, 1965.
12. Beare JM: Histiocytic proliferative disorders, in Rook A, Wilkinson DS, Ebling FJG (eds): *Textbook of Dermatology.* Oxford, England, Blackwell Scientific Publications, 1972, pp 1364-1378.
13. Crocker AC: The histiocytosis syndromes, in Fitzpatrick TB, Arndt KA, Clark WH (eds): *Dermatology in General Medicine.* New York, McGraw-Hill Book Co Inc, 1971, pp 1328-1339.
14. Avery ME, McAfee JG, Guild HG: The course and prognosis of reticuloendotheliosis (eosinophilic granuloma, Schuller-Christian disease, and Letterer-Siwe disease). *Am J Med* 22:636-652, 1957.
15. Barth RF, Vergara GG, Khurana SK, et al: Rapidly fatal familial histiocytosis associated with eosinophilial and primary immunological deficiency. *Lancet* 2:503-506, 1972.
16. Aaes-Jorgensen E: Essential fatty acids. *Physiol Rev* 41:1-51, 1961.
17. Wene JD, Connor WE, Den Beste L: The development of essential fatty acids in healthy men fed fat free diets intravenously and orally. *J Clin Invest* 56:127-134, 1975.
18. Weise HF, Hansen AE, Adam DJD: Essential fatty acids in infant nutrition. *J Nutr* 66:345-360, 1958.
19. Jeejeebhoy KN, Zoheab WJ, Langer B, et al: Total parenteral nutrition at home for 23 months without complication and with good rehabilitation. *Gastroenterology* 65:811-820, 1973.

ROCHE

Roche Laboratories announces an additional therapeutic application for Efudex® 5% Cream fluorouracil/Roche

now indicated for superficial basal cell carcinoma

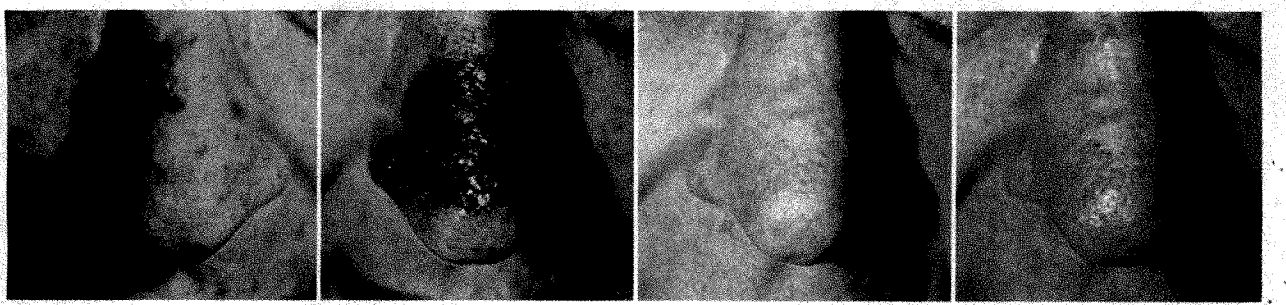

8/8/69
Before treatment a superficial, scaly, slightly excoriated lesion was present. Biopsy revealed the lesion to be a superficial basal cell carcinoma.

9/25/69
After 7 weeks of treatment with Efudex (fluorouracil) 5% Cream, lesion site is clearly delineated, markedly erythematous; surrounding skin shows no reaction to medication. Treatment terminated.

12/10/70
Follow-up approximately 14 months after treatment; healing has occurred with minimal scarring.

4/18/74
Patient has been followed continuously since treatment. **No evidence of recurrence.**

Efudex (fluorouracil) 5% Cream is recommended as an effective topical alternative to surgery for multiple lesions and difficult treatment sites.

A proven cytotoxic agent that exerts a marked effect on cells that grow more rapidly.

Cosmetically gratifying results, with minimal or no scarring. No systemic toxicity. Normal tissue rarely affected. Convenient, economical b.i.d. application.

Prolonged exposure to ultraviolet light may accelerate reaction to medication. If an occlusive dressing is used, there may be an increase in the incidence of inflammatory reactions in the adjacent normal skin.

An exclusive Roche formulation

Efudex® 5% Cream
fluorouracil/Roche

Before prescribing, please consult complete product information, a summary of which follows:
Indications: Multiple actinic or solar keratoses; superficial basal cell carcinomas when conventional methods are impractical (5% strength only).
Contraindications: If occlusive dressing is used, may increase inflammatory reactions in adjacent normal skin. Avoid prolonged exposure to ultraviolet rays. Safe use in pregnancy not established.
Precautions: If applied with fingers, wash hands immediately. Apply with care near eyes, nose and mouth. Solar keratoses failing to respond should be biopsied; perform follow-up biopsies in superficial basal cell carcinoma.
Adverse Reactions: Local—pain, pruritus, hyperpigmentation and burning at application site most frequent; also dermatitis, scarring, soreness, tenderness, suppuration, scaling and swelling. Also reported—insomnia, stomatitis, irritability, medicinal taste, photosensitivity, lacrimation, telangiectasia, leukocytosis, thrombocytopenia, toxic granulation and eosinophilia.
Dosage and Administration: *Actinic or solar keratosis*—apply sufficient quantity to cover lesions, twice daily. Usual length of therapy is 2 to 4 weeks. *Superficial basal cell carcinomas*—apply sufficient quantity **(only 5% strength recommended)** to cover lesions, twice daily. Continue treatment for at least 3 to 6 weeks, but possibly as long as 10 to 12.
How Supplied: Solution, 10-ml drop dispensers containing 2% or 5% fluorouracil on a weight/weight basis. Cream, 25-Gm tubes containing 5% fluorouracil in a vanishing cream base.

ROCHE

Roche Laboratories
Division of Hoffmann-La Roche Ir
Nutley, New Jersey 07110



So Why Shouldn't Abrasive Cleansers?

All patients' skins differ in some respects. Some acne patients are fair-skinned; others have "tough" skin. Some can tolerate only fine abrasive cleansers; others need more strenuous abrasion to provide proper desquamation.

Brāsivol—Fine, Medium and Rough—provides this range of abrasiveness and even is supplied without abrasive—as Brāsivol Base—for exquisitely sensitive skin.

Brāsivol Base, Fine, Medium and Rough are available in unbreakable jars.

Write for professional samples today.

BRĀSIVOL®

STIEFEL
Logical Dermatologicals since 1847

Stiefel Laboratories, Inc.,
Oak Hill, N.Y. 12460
Stiefel Laboratories (Canada) Ltd.,
St. Laurent, Quebec, Canada H4R 1E1

Review Article

Newer Concepts of Atopic Dermatitis

Jon M. Hanifin, MD, Walter C. Lobitz, Jr, MD

Atopic dermatitis is a disease of fascination and frustration to medical practitioners and researchers. This very common disorder is confusing from several standpoints. The confusion begins with nomenclature; in discussions with American nondermatologic physicians, we might hear atopic dermatitis referred to as "eczema," allergic dermatitis, allergic eczema, or even neurodermatitis. Many Europeans continue to use the term prurigo Besnier.

Diagnostic features of atopic dermatitis are another source of confusion. The skin lesions a pediatrician sees on a child's skin may be vastly different from the lesions the general practitioner sees on that same individual 15 years later. There may be no single distinguishing characteristic; diagnosis may depend on a combination of morphologic, distributional, and historical features. Histological findings provide very little aid in diagnosis, though a recent preliminary report by Mihm et al[1] raises the hope that new histologic techniques may reveal distinct histopathologic features in atopic dermatitis.

With such loose nomenclatural and diagnostic guidelines, many past studies of eczema might be questioned regarding the homogeneity of their patient populations. Realizing the need for better diagnostic criteria, we have recently proposed the following outline as a means for more uniform assessment and communication by investigators studying this disease:

Diagnostic Criteria for Atopic Dermatitis

Absolute Features—

Must Have Each of the Following:

1. Pruritus
2. Typical morphology and distribution:
   a. Flexural lichenification in adults
   b. Facial and extensor involvement in infancy
3. Tendency toward chronic or chronically-relapsing dermatitis

plus

Two or More of the Following Features:

1. Personal or family history of atopic disease (asthma, allergic rhinitis, atopic dermatitis)
2. Immediate skin test reactivity
3. White dermographism and/or delayed blanch to cholinergic agents
4. Anterior subcapsular cataracts

or

Four or More of the Following Features:

1. Xerosis/ichthyosis/hyperlinear palms
2. Pityriasis Alba
3. Keratosis pilaris
4. Facial pallor/infraorbital darkening
5. Dennie-Morgan infraorbital fold
6. Elevated serum-IgE
7. Keratoconus
8. Tendency toward nonspecific hand dermatitis
9. Tendency toward repeated cutaneous infections

Perhaps nowhere is confusion more rampant than in speculations regarding the pathogenesis of atopic dermatitis. Through the years, etiologic discussions have focused mainly around physiologic and immunologic considerations. Physiologic defects quickly become obvious to anyone who observes the skin of atopic dermatitis patients. This skin is extremely dry and pruritic; low thresholds for induced pruritus have been objectively demonstrated.[2] Signs of abnormal cutaneous vasoreactivity include decreased digital skin temperature,[3] white dermographism, and delayed blanch response to cholinergic agents.[4] Based on observations of similarly altered pharmacologic reactivity among asthmatics, as well as studies in animals, Szentivanyi[5] proposed the β-adrenergic theory of atopic disease in 1968. He suggested that the heightened sensitivity of atopics to acetylcholine and other agents could be due to a blockade of β-adrenergic receptors in tissues. Thus, he considered atopy a disease of disordered physiologic and pharmacologic reactivity. Immunologic reactions would be only one group along with infectious, chemical, physical, and psychic stimuli that might trigger the pathologic hyperreactivity. Szentivanyi's theory has stimulated considerable research that will be discussed below.

Immunologic associations with atopic dermatitis have long been appreciated. The frequent personal and familial association with asthma and allergic rhinitis originally sug-

Accepted for publication Jan 25, 1976.

From the Department of Dermatology, University of Oregon Health Sciences Center, Portland, Ore.

Reprint requests to Department of Dermatology, University of Oregon Health Sciences Center, 3181 SW Sam Jackson Park Rd, Portland, OR 97201 (Dr Hanifin).

gested that atopic dermatitis might also be due to reactions between antigen and tissue fixed, reaginic antibodies. We know, however, that we cannot clearly classify the lesions of atopic dermatitis as the urticarial wheals of type 1 hypersensitivity nor any other of the four commonly accepted types of immunologic reactions.

Immunologic studies relating to atopic dermatitis can be roughly categorized into the following: (*a*) abnormalities of humoral immunity; (*b*) defects of cell-mediated immunity; (*c*) associations with immunodeficient states; and (*d*) studies relating to the cyclic nucleotide system. In discussing each of these topics, we will attempt to focus on areas where abnormalities of one system might interrelate to abnormalities in others.

ABNORMALITIES OF HUMORAL IMMUNITY

Early studies of serum immunoglobulins recorded no clear differences between normal and atopic populations,[6-8] though a subsequent report suggested an increased frequency of IgA deficiency among a population of 641 atopic patients.[9] Taylor et al[10] studied the infant offspring of atopic parents and showed that transient deficiency of IgA at age 3 months was associated with increased risk of developing atopy within the first year. The authors presented the interesting hypothesis that this transient letdown of a mucosal IgA barrier against antigens could lead to inappropriate stimulation of IgE-producing lymphocytes and consequent development of atopy. A recent report recorded increased serum-IgG and IgM along with decreased IgD levels in a group of adults with atopic dermatitis.[11]

Perhaps the best known immunologic abnormality in atopic dermatitis relates to reaginic or cytotropic antibodies. It has been repeatedly shown that there is a higher than normal incidence of immediate wheal (type 1) reactions to common environmental allergens administered by scratch or intradermal routes. In Rajka's series,[12] nearly 80% of patients had positive responses, and Stone et al[13] noted that patients with a high percentage of positive responses tended to have more severe atopic dermatitis. These associations may merely be incidental to the disease, however, since a number of patients do not react, at least to a standard battery of antigens. Considerable doubt was cast on the role of skin sensitizing antibodies in the pathogenesis of atopic dermatitis in 1962 when Peterson et al[14] reported four boys with congenital x-linked agammaglobulinemia and typical flexural eczema. Skin tests with over 200 antigens failed to demonstrate wheal and flare sensitivity in these patients. Conversely, among atopic dermatitis patients with positive type 1 hypersensitivity, there is no evidence that the immediate wheal reactions lead to the changes we recognize in the skin as atopic dermatitis. This is not to say, however, that related mechanisms may not be operative; it is, perhaps, useful to recall Engman's report in which a child with confirmed wheat hypersensitivity was challenged orally with that antigen. Half his body was protected by dressings, and following wheat ingestion, atopic dermatitis lesions appeared only on the unprotected areas, apparently mediated by a reaction causing severe pruritus and subsequent traumatization.[15]

In spite of doubts as to its relevance in the pathogenesis of atopic dermatitis, reagin has received considerable attention in the years since Ishizaka identified this antibody as a distinct class called immunoglobulin E.[16]

Clinical studies soon established the presence of high serum IgE levels in patients with asthma,[17] allergic rhinitis,[18] parasitosis,[19] and Wiskott-Aldrich syndrome.[20] In 1969, Juhlin et al[21] reported elevated serum IgE levels in 23 of 28 patients with atopic dermatitis. These findings have been confirmed repeatedly with studies showing the following: (1) Levels tend to be highest in patients with atopic dermatitis and coexisting allergic respiratory disease (ARD)[22]; (2) The degree of elevation roughly corresponds to the severity of skin disease[12,22-24]; and (3) serum IgE levels may remain high in spite of resolution of the dermatitis.[25]

The recent report by Ohman and Johansson[11] suggested that serum IgE levels may not be elevated in patients with pure atopic dermatitis (ie, in the absence of ARD). If confirmed, this finding would present impressive evidence against a role for IgE in the pathogenesis of atopic dermatitis. The authors admitted, however, that their study suffered from lack of a concomitant normal adult control group. The recent study by Jones et al[22] showed significantly elevated serum IgE levels in patients with pure atopic dermatitis.

The two studies clearly agree that serum IgE levels are highest in combined atopic dermatitis with ARD and relatively low in atopic dermatitis alone. This fact, plus the presence of elevated IgE levels in dermatoses such as dyshidrosis, acne,[24] and bullous pemphigoid[26] may reflect a purely coincident association between atopic dermatitis and serum IgE. Certainly, every study has demonstrated patients with atopic dermatitis and normal serum IgE levels.

Interpretation of all these studies is clouded, however, by the fact that IgE is a tissue-fixing antibody and hence, serum levels do not necessarily indicate total body levels. IgE-bearing B lymphocytes have been reported in a patient with atopic dermatitis and agammaglobulinemia,[27] and a recent study demonstrated local production of antigen-specific IgE in respiratory mucosa without evidence of this antibody in the serum.[28] Skin IgE levels in patients with atopic dermatitis may be elevated independent of serum levels.[29]

At the present time, the role of IgE in the pathogenesis of atopic dermatitis remains unclear. Increased serum IgE can only be considered as one of the features of atopic dermatitis, possibly reflecting dysfunctional control of the immunoglobulin producing cells. As a practical test, serum IgE levels offer little aid to either diagnosis or prognosis in clinical situations.

DEFECTS OF CELL-MEDIATED IMMUNITY IN ATOPIC DERMATITIS

In addition to abnormalities of humoral immunity in atopic dermati-

tis, several lines of evidence attest to dysfunctional cell-mediated immunity (CMI) as well. Perhaps the most obvious is the susceptibility of these patients to unusually severe cutaneous infections, especially viral conditions such as disseminated vaccinia (eczema vaccinatum) and herpes simplex (eczema herpeticum). Atopic patients may also have an increased susceptibility to warts as was recently suggested by Currie et al.[30] We have also been impressed by the association between chronic dermatophyte infection and atopic disease. A study of 20 patients with unusually extensive and chronic *Trichophyton rubrum* infections revealed that 15 of the group demonstrated immediate wheal reactivity to intradermal trichophytin and ten of the 20 had clinical or historical evidence of atopy.[31] Occasional patients in our series have noted exacerbations of their chronic fungal infections coincident with atopic dermatitis flares.

Another area of study is related to delayed hypersensitivity reactions in atopics. For many years, the situation has been confused because some investigators noted an increased incidence of contact allergy in patients with atopic dermatitis[32,33] with particular emphasis on neomycin sensitivity.[34,35] In retrospect, these findings may simply represent the high frequency of exposure to sensitizing topical medications among atopic dermatitis patients. The actual situation with regard to contact allergy was predicted in 1937 by Rostenberg and Sulzberger who noted a surprisingly low incidence of positive patch tests in atopic dermatitis patients.[36] These findings have been amply confirmed and the bulk of evidence favors the concept that atopics are no more likely to develop allergic contact dermatitis than are normals.[37]

Several studies have indicated that atopic patients may actually have a decreased rate of sensitization to experimentally applied antigens. This was perhaps first enunciated by Becker (in a discussion of Rostenberg and Sulzberger's 1937 paper)[36] who cited the difficulty of obtaining positive patch test reactions to poison ivy extract in his patients with atopic dermatitis. In 1966, Palacios et al[38] reported that while atopic patients had normal humoral antibody responses to antigens, they were less easily sensitized to dinitrochlorobenzene (DNCB) than were normal subjects. More recently, Jones et al[39] noted that patch tests revealed 61% of normal controls were sensitive to *Rhus* but only 15% of atopics. A second testing of those patients who were negative to the first test showed that a third of the normals had been sensitized by that first test while only 6% of atopic dermatitis patients converted.

Atopic dermatitis-like skin lesions are a common manifestation of Wiskott-Aldrich syndrome, a disease with severely depressed cell mediated immunity. In 1972, Lobitz et al[40] described two atopic dermatitis patients with severely depressed CMI. These patients showed no delayed cutaneous hypersensitivity to natural antigens nor could they be sensitized to DNCB. Cultured lymphocytes from these patients showed abnormally low responses to phytohemagglutinin (PHA) though one patient showed normalization of this function during periods of remission. Histologic evaluation of these patients' lymphoid tissue revealed depletion of paracortical T cell areas and markedly hyperplastic B cell dependent areas. These latter areas showed a proliferation of IgE-bearing cells as indicated by immunofluorescence microscopy. Increased numbers of IgE-bearing leukocytes were also noted in the peripheral blood of these patients. Normally, immunoglobulin-bearing B cells comprise only approximately 20% of the lymphocytes in peripheral blood and less than 1% of those stain with fluoresceinated anti-IgE. A subsequent report by Cormane et al[41] demonstrated that 14% to 31% of the lymphocytes from ten atopic dermatitis patients stained for IgE. As with serum IgE, the pathologic significance of these findings remains unclear.

Because of the considerable evidence for depressed cell-mediated immunity in atopic dermatitis, and because the T lymphocyte is known to mediate CMI, we quantitated T cell levels using the rosette-forming cell (RFC) assay.[42] We found that patients with moderate to severe atopic dermatitis had significantly decreased RFC levels compared to normal (Fig 1).[43] Similar findings have since been noted by two other groups.[44,45] When we compared RFC levels with serum IgE levels, a rough inverse correlation was noted—ie, patients with the higher IgE levels tended to have lower numbers of circulating rosette-forming T cells. Furthermore, when normal lymphocytes were preincubated in serum from these atopic patients, the rosette-forming capacity was reduced; other studies using this assay provided indirect evidence that inhibition of rosette formation was due to IgE in the serum.[46] The possibility that IgE may produce a direct influence on T cells is an intriguing but not yet proven hypothesis.

It is important in this review to give some perspective to dysfunctional cell-mediated immunity in atopic dermatitis. Considerable confusion has arisen as a result of the finding of depressed lymphocyte function in patients with severe disease. Most atopic dermatitis patients manifest delayed cutaneous hypersensitivity and have normal in vitro leukocyte responses. In our study of 14 patients with moderate to severe atopic dermatitis, in vitro lymphocyte transformation was normal in seven of the patients. In the other seven patients, all with severe erythrodermatous involvement, not only was lymphocyte transformation to PHA and concanavalin-A depressed, but these patients also had markedly depressed chemotaxis of both the polymorphonuclear (PMN) and monocyte series. In three of the patients, chemotactic function was noted to improve markedly within as little as 48 hours as the patient's severe dermatitis regressed.[47] Preliminary studies indicate that an inhibitory factor in the plasma of atopic dermatitis patients may be responsible for the leukocyte dysfunctions seen in these patients during severe flares of their disease.[48] These factors of timing and severity of disease no doubt account for the variable in vitro findings in several recent studies of CMI in atopic dermatitis.[45,49-51] From

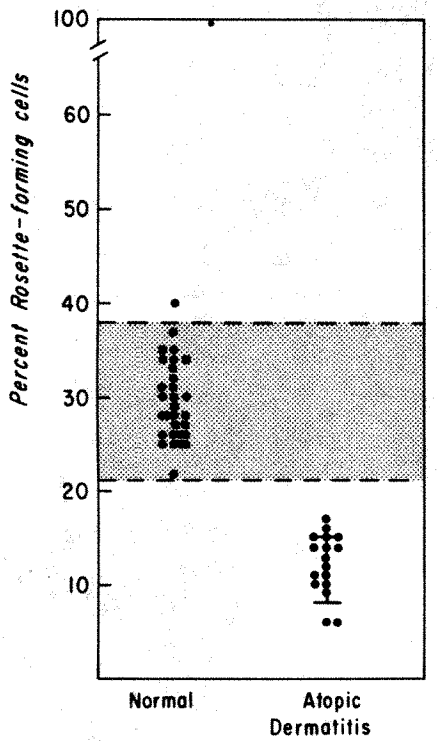

Fig 1.—Percentage of rosette-forming cells among isolated peripheral blood lymphocytes from normal subjects and atopic dermatitis patients. Shaded area represents the normal range (mean ± standard deviation).

our studies, it appears that each of the three cell types most directly involved with host resistance to infection may be dysfunctional in atopic dermatitis but that these functional abnormalities may be detectable only during periods of severe disease.

The problem of cutaneous anergy among atopics is likewise somewhat confusing. Some patients with atopic dermatitis fail to respond to a battery of naturally occurring antigens such as tuberculin, trichophytin, candidin, and streptokinase-streptodornase, yet may have normal in vitro lymphocyte responses to nonspecific mitogens.[47] The most likely explanation is that the in vitro studies assess only limited aspects of the total immune system while intradermal stimulation tests the intactness of the entire mechanism. The possibility must be considered, however, that anergy in these patients is due to a local, cutaneous defect. At the present time, there is simply not enough evidence to allow comment on the two possibilities.

Early in vitro studies in patients with atopic dermatitis raised the question of whether the disease might be an autosensitization to skin. A report by Hashem et al, in 1963,[52] suggested that cell-free skin extracts were capable of causing transformation of autologous lymphocytes cultured from the blood of patients with atopic dermatitis. Two subsequent studies[53,54] failed to confirm this finding. Using a somewhat different approach, Japanese investigators have suggested that some patients with atopic dermatitis may have cell-mediated reactivity against human dander,[55] but these studies are preliminary and await amplification.

RELATIONSHIP BETWEEN ATOPIC DERMATITIS AND IMMUNODEFICIENCY DISEASES

The association between immune deficiency and eczema similar to atopic dermatitis has been appreciated for many years. The x-linked Wiskott-Aldrich syndrome with eczema, thrombocytopenia, and recurrent infections is perhaps the best known of these.[56,57] Atopic dermatitis was noted in two of 22 patients with ataxia telangiectasia; a seborrheic-type dermatitis is a more common cutaneous feature in these patients.[58] Peterson[14] documented atopic dermatitis in four of 23 patients with x-linked agammaglobulinemia.

A condition receiving increasing attention in recent years is the hyper-immunoglobulin-E syndrome of Buckley.[59] In addition to elevated serum IgE levels, these patients have recurrent cutaneous staphylococcal infections, frequent candidosis, and many have an eczema similar to atopic dermatitis.[59-61] The basic defect is unclear; delayed hypersensitivity responses may be normal or abnormal. It appears that patients with this syndrome are a functionally heterogeneous group with a few constant features. Many of these patients have defective in vitro chemotaxis of PMNs[60] and/or monocytes.[62] In their chemotaxis studies, Hill and Quie[60] were unable to inhibit normal PMN migration with serum or plasma from hyper-IgE patients. These findings are at variance with our recent observations in patients with atopic dermatitis and may reflect basic pathogenetic differences in the two conditions or simply different technical approaches for assessing plasma inhibition. These authors did put forth the intriguing hypothesis that antigen-IgE interaction with leukocytes could cause release of histamine that in turn might account for the chemotactic defects which they observed. Their studies showed that histamine inhibited normal PMN chemotaxis, and more recent studies have shown similar depression of mitogen-induced lymphocyte blastogenic transformation.[62] High levels of blood and skin histamine could well account for the erythema and pruritus seen in patients with hyperimmunoglobulinemia-E and atopic dermatitis; likewise, at the same time, histamine would correlate with the elevated serum IgE levels and the dysfunctional chemotaxis and lymphocyte transformation we have observed in patients. Proof of this hypothesis awaits direct demonstration of elevated plasma histamine effects on leukocytes.

Increased serum IgE in combination with depressed CMI and eczema has been noted not only in Wiskott-Aldrich syndrome[20] and in the hyper-IgE syndrome, but also in at least one case of thymic alymphoplasia.[63] The DiGeorge syndrome[64] and some cases of Nezelof syndrome[65] likewise present with a combination of increased IgE and decreased CMI responsiveness, though eczema is generally not a feature of these conditions. Serum IgE is elevated in patients with selective IgA deficiency but so is the incidence of atopy[66]; among nonatopic IgA-deficient patients, IgE levels are normal.[65] Some of these patients have decreased rosette-forming T cells[67] and impaired lymphocyte responsiveness to PHA.[68] Also, as mentioned earlier, transient IgA deficiency in early infancy may be associated with later development of eczema and abnormally high serum IgE levels.[10]

In general, then, serum IgE levels are elevated in conditions with impaired CMI and frequently these in turn are associated with atopic dermatitis. The varied associations between atopic dermatitis, hyper-IgE, and impaired CMI strongly suggest a human

correlate to animal studies reported by Tada et al.[69] These workers showed abnormally high and prolonged IgE production in T cell depleted rats. Infusion of carrier-specific, syngeneic T lymphocytes resulted in a rapid return to normal IgE levels. Absence of a certain T cell subpopulation in humans with atopic dermatitis could account for the laboratory findings in these patients of elevated serum IgE, decreased rosette-forming T-cells, and impaired cellular immune responses. It is difficult, however, to outline a coherent relationship between these lymphocyte defects and the changes seen in the skin of atopic dermatitis patients.

A fascinating area of speculation in this regard is the possibility that human T cells and epidermal cells may have common characteristics. This suggestion is based on the fact that Hassall's corpuscles of the thymus appear to contain cornified squamous cells.[70] Also, the nude mouse lacks both normally differentiated T lymphocytes and hair,[71] and murine T cells and epidermal cells share specific membrane antigenic determinants.[72] It is possible that a common defect might account for the abnormalities seen in epidermal cells and T lymphocytes of patients with atopic dermatitis.

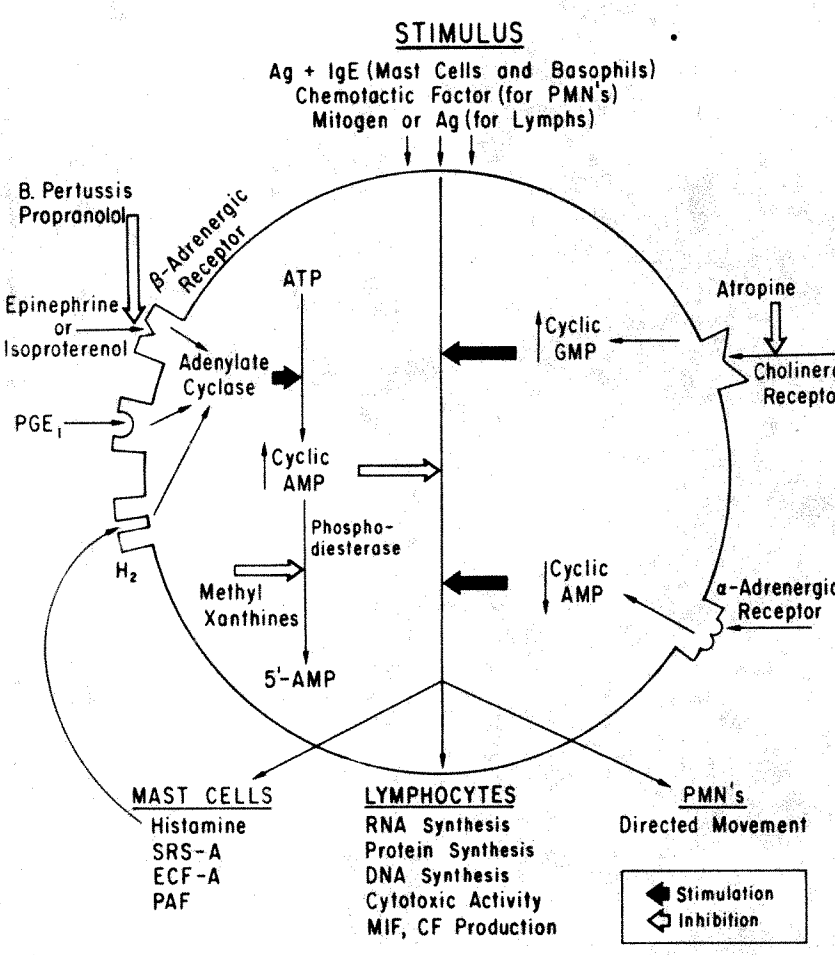

Fig 2.—Diagrammatic representation of pathways by which pharmacologic mediators might act on mast cell, lymphocyte and PMN leukocyte membrane receptors to alter intracellular cyclic nucleotides which in turn may either enhance or inhibit the function of those cells. Abbreviations include the following: Ag, antigen; PGE_1, prostaglandin E_1; SRS-A, slow-reacting substance of anaphylaxis; ECF-A, eosinophil chemotactic factor of anaphylaxis; PAF, platelet activating factor; MIF, migration inhibitory factor; CF, chemotactic factor.

ALTERED PHARMACOLOGIC ACTIVITY IN ATOPIC DERMATITIS

Increased sensitivity of atopics to histamine and cholinergic agents has been appreciated for many years. Patients with atopic dermatitis show greater than normal erythema in response to parenteral histamine, and interestingly, this effect occurs mainly in the knee and elbow flexures, sites of predilection for atopic dermatitis.[73] Intradermal injection of cholinergic agents produces a delayed blanch response in atopic dermatitis patients,[4] a phenomenon thought to be due either to excessive vasoconstriction,[74,75] or to a sudden increase of vascular permeability.[76,77] Acetylcholine also produces increased sweat production in atopic dermatitis patients,[78] although this may not be clinically apparent because these patients appear to have a defective sweat delivery system.[79] The β-adrenergic blocking agent propranolol causes enhanced acetylcholine-induced sweat production in normals but has no effect on atopics.[80] Patients with atopic dermatitis also appear to have increased adrenergic sensitivity of cutaneous vasculature.[81-83]

Most of these abnormalities could be explained by Szentivanyi's β-adrenergic blockade theory. Increased cholinergic and α-adrenergic sensitivity could be the result of an inadequate β-adrenergic counterbalance. This concept has stimulated considerable investigation of isolated tissues in vitro with regard to pharmacologic influences on cell function, proliferation, and cyclic-adenosine monophosphate (AMP) levels.

Bullough[84] showed that β-adrenergic stimulation with catecholamines inhibited epidermal cell division and subsequent studies indicated that cyclic AMP decreases epidermal mitosis.[85] Carr et al[86] compared DNA synthesis in cultured epidermis from normal subjects and patients with atopic dermatitis. They noted no difference in untreated cultures, but catecholamines inhibited DNA synthesis of normal cells while having no effect on epidermal cells from atopics. Epidermal cyclic AMP assays recorded no differences between normals and atopics, either in resting cultures or in isoproterenol-treated cultures.[87] These studies were in accord with others that failed to show any abnor-

mality of adenyl cyclase,[88] phosphodiesterase,[89] or cyclic AMP-dependent protein kinase[90] in the skin of patients with atopic dermatitis. Likewise, levels of enzymes related to glucose metabolism were normal in isolated sweat glands of atopic patients.[91]

Several investigators have elected to study the isolated leukocyte populations in atopics. Decreased adenyl cyclase responses to β-adrenergic agents have been noted in asthma patients.[92,93] Parker and Eisen, in 1972,[94] presented data showing a subnormal cyclic-AMP response to isoproterenol in mixed leukocytes from patients with atopic dermatitis, and similar findings have been noted in purified lymphocytes by Reed et al.[87] This latter group has likewise noted a diminished lymphocyte cyclic AMP response to isoproterenol but a normal response to prostaglandin E-1.[87] These authors suggest that, while atopics have intact adenyl cyclase, phosphodiesterase, and protein kinase systems, they may have a defect antecedent to activation of adenyl cyclase and specific for the β-adrenergic receptor. Incomplete evidence suggests that a factor in atopic serum may confer the subnormal cyclic AMP response to β-adrenergic agonists in these various cell systems.[95]

A considerable amount of research has focused, in recent years, on the relationship of the cyclic AMP system to normal function of those cells involved with mediation of immune responses; the mast cell, basophil, lymphocyte, and PMN (Fig 2). This interrelationship has been especially well elucidated in studies of mast cells and basophils. When two or more IgE molecules on the surface of these cells are bridged by either specific divalent antigen or by antibody to IgE, an energy requiring sequence is activated leading to release of histamine and other inflammatory mediators. The β-adrenergic agonists, PGE-1 and even histamine, act via distinct receptors through adenyl cyclase to cause increased levels of intracellular cyclic AMP which in turn has an inhibitory influence on release of histamine, etc. Conversely, cholinergic agents, act via less well-defined pathways to decrease cyclic AMP and enhance mediator release, as do agents acting on α-adrenergic receptors.[96-99]

Ishizaka and Ishizaka[100] compared histamine release from leukocytes of normals and atopics under control situations. They found the number of IgE-binding sites per basophil similar in the two groups, and under saturation conditions, there was no difference in number of IgE molecules per basophil. The atopic group did, however, tend to have a lower threshold of maximum histamine release by anti-IgE. These studies suggested that the number and binding affinity of IgE molecules probably determine the sensitivity of basophils to allergen while the percentage of histamine release is dependent on regulatory intracellular systems. An imbalance caused by β-adrenergic blockade could account for accentuated release of inflammatory mediators from mast cells and basophils of atopics.

Leukocyte studies have indicated that elevated cyclic-AMP levels are associated with inhibition of cytotoxic activity,[101] immunoglobulin synthesis,[102] and DNA synthesis[103,104] in lymphocytes and decreased chemotaxis[105] by PMNs. As mentioned above, measurably decreased lymphocyte DNA synthesis along with monocyte and PMN chemotaxis is seen in patients with severe atopic dermatitis and plasma from such patients will confer these functional defects on normal leukocytes. Since we must assume an ultimate cellular source for such an inhibitory factor, it is conceivable that loss of cellular control (ie, β-adrenergic blockade) could account for inappropriate production of an inhibitory mediator such as histamine by mast cells along with overproduction of IgE by B lymphocytes. Such an hypothesis fails, however, to clearly account for the decreased numbers of rosette-forming T cells in the blood of atopic dermatitis patients, though this phenomenon could simply reflect a differentiative or maturational defect among these cells. Extrapolation from studies on this subject suggests that the quantity of undifferentiated or null cells (lymphocytes with neither B cell or T cell characteristics) is increased in patients with atopic dermatitis.[44,45]

Immunopharmacologic studies in atopy are very much in their infancy, but these shreds of preliminary evidence predict an exciting and potentially fruitful realm of investigation in coming years.

In summary, atopic dermatitis is a disease characterized by abnormalities related to both type 1 and type 4 immune responses, yet the skin lesions cannot be classified under either of these reaction types. The disease is difficult to define; diagnosis depends on a combination of morphologic, distributional, and historical features.

Skin lesions typical of atopic dermatitis are seen in a number of immune deficiency conditions, especially those characterized by depressed cell-mediated immunity, elevated IgE production, and in some instances, IgA deficiency suggesting a common disorder in the ontogeny of immunoglobulin-producing cells. Defective T lymphocyte mediation of the B lymphocytes producing these immunoglobulins may explain the combined cellular and humoral abnormalities observed. Homologies between T cells and epidermal cells could account for the combined immunologic and cutaneous defects seen in atopic dermatitis.

Recent evidence suggests the possibility of an even more basic disorder in atopic dermatitis. Preliminary studies indicate that a factor in serum from atopic dermatitis patients can depress in vitro leukocyte function and inhibit epidermal cell cyclic AMP responses to β-adrenergic agonists. Such a factor could account for many of the indications of β-adrenergic blockade seen in patients with atopic dermatitis. Considerably more work will be necessary to identify the primary defect responsible for the disease which presents as atopic dermatitis.

References

1. Mihm MC Jr, Soter NA, Dvorak HF, et al: The structure of normal skin and the morphology of atopic eczema. *J Invest Dermatol* 67:305-312, 1976.

2. Arthur RP, Shelley WB: The nature of itching in dermatitic skin. *Ann Intern Med* 49:900-908, 1958.

3. Eyster WH Jr, Roth GM, Kierland RR: Studies on the peripheral vascular physiology of patients with atopic dermatitis. *J Invest Dermatol* 18:37-46, 1952.

4. Lobitz WC Jr, Campbell CJ: Physiologic studies in atopic dermatitis (disseminated neurodermatitis): I. The local cutaneous response to intradermally injected acetyl choline and epinephrine. *Arch Dermatol* 67:575-589, 1953.

5. Szentivanyi A: The beta adrenergic theory of the atopic abnormality in bronchial asthma. *J Allergy Clin Immunol* 42:203-232, 1968.

6. Huntley CC, Lyerly A: Gamma globulin determinations in allergic children. *Am J Dis Child* 106:55-64, 1963.

7. Buckley RH, Dees SC, O'Fallon W: Serum immunoglobulin levels in normal children and in uncomplicated childhood allergy. *Pediatrics* 41:600-611, 1968.

8. Collins-Williams C, Tkachyk SJ, Toft B, et al: Quantitative immunoglobulins in children with intractable asthma. *Ann Allergy* 25:177-182, 1967.

9. Kaufman HS, Hobbs JR: Immunoglobulin deficiencies in an atopic population. *Lancet* 2:1061-1063, 1970.

10. Taylor B, Norman AP, Orgel HA, et al: Transient IgA-deficiency and pathogenesis of infantile atopy. *Lancet* 2:111-113, 1973.

11. Ohman S, Johansson SGO: Immunoglobulins in atopic dermatitis. *Acta Derm Venereol* 54:193-202, 1974.

12. Rajka G: Prurigo Besnier (atopic dermatitis) with special reference to the role of allergic factors: II. The evaluation of the results of skin reactions. *Acta Derm Venereol* 41:1-39, 1961.

13. Stone SP, Muller SA, Gleich GJ: IgE levels in atopic dermatitis. *Arch Dermatol* 108:806-811, 1973.

14. Peterson RDA, Page AR, Good RA: Wheal and erythema allergy in patients with agammaglobulinemia. *J Allergy Clin Immunol* 33:406-411, 1962.

15. Engman MF, Weiss RS, Engman MF Jr: Eczema and environment. *Med Clin North Am* 20:651-663, 1936.

16. Ishizaka K, Ishizaka T, Hornbrook MM: Identification of gamma E antibodies as a carrier of reaginic activity. *J Immunol* 99:1187-1198, 1967.

17. Johansson SGO: Raised levels of a new immunoglobulin class (IgND) in asthma. *Lancet* 2:951-953, 1967.

18. Berg T, Johansson SGO: IgE concentrations in children with atopic diseases. *Int Arch Allergy Appl Immunol* 36:219-232, 1969.

19. Bennich H, Johansson SGO: Structure and function of human immunoglobulin E. *Adv Immunol* 13:1-55, 1971.

20. Berglund G, Finnstrom O, Johansson SGO, et al: Wiskott-Aldrich syndrome: A study of six cases with determination of the immunoglobulins A, D, G, M and ND. *Acta Paediatr Scand* 57:89-97, 1968.

21. Juhlin L, Johansson SGO, Bennich H, et al: Immunoglobulin E in dermatoses: Levels in atopic dermatitis and urticaria. *Arch Dermatol* 100:12-16, 1969.

22. Jones HE, Inouye JC, McGerity JL, et al: Atopic disease and serum immunoglobulin-E. *Br J Dermatol* 92:17-25, 1975.

23. Ogawa M, Berger PA, McIntyre OR, et al: IgE in atopic dermatitis. *Arch Dermatol* 103:575-580, 1971.

24. Gurevitch AW, Heiner DC, Reisner R: IgE in atopic dermatitis and other common dermatoses. *Arch Dermatol* 107:712-715, 1973.

25. Johansson SGO, Juhlin L: Immunoglobulin E in healed atopic dermatitis and after treatment with the corticosteroids and azathioprine. *Br J Dermatol* 82:10-13, 1970.

26. Arbesman CE, Wypych JI, Reisman RE, et al: IgE levels in sera of patients with pemphigus or bullous pemphigoid. *Arch Dermatol* 110:378-381, 1974.

27. Gajl-Peczalaka KJ, Ballow M, Hansen JA, et al: IgE-bearing lymphocytes and atopy in a patient with x-linked infantile agammaglobulinemia. *Lancet* 1:1254, 1973.

28. Huggins KG, Brostoff J: Local production of specific IgE antibodies in allergic rhinitis patients with negative skin tests. *Lancet* 2:148-150, 1975.

29. Jansen CT, Haapalahti J, Hopsu-Havu VK: Immunoglobulin E in the human atopic skin. *Arch Dermatol Forsch* 246:299-302, 1973.

30. Currie JM, Wright RC, Miller OW: The frequency of warts in atopic patients. *Cutis* 8:244-245, 1971.

31. Hanifin JM, Ray LF, Lobitz WC Jr: Immunologic reactivity in dermatophytosis. *Br J Dermatol* 90:1-8, 1974.

32. Malten KE: The occurrence of hybrids between contact allergic eczema and atopic dermatitis (and vice versa) and their significance. *Dermatologica* 136:404-406, 1968.

33. Epstein S, Mohigern AH: Incidence of contact sensitivity in contact dermatitis. *Arch Dermatol* 90:284-288, 1964.

34. Epstein S: Neomycin sensitivity and atopy. *Dermatologica* 130:280-286, 1965.

35. Jillson OF, Corwen WL, Alexander BR: Problems of contact dermatitis in the atopic individual. *Ann Allergy* 17:215-223, 1959.

36. Rostenberg A Jr, Sulzberger MB: Some results of patch tests. *Arch Dermatol* 35:433-454, 1937.

37. Cronin E, Bandmann HJ, Calnan CD, et al: Contact dermatitis in the atopic. *Acta Derm Venereol* 50:183-187, 1970.

38. Palacios J, Fuller EW, Blaylock WK: Immunological capabilities of patients with atopic dermatitis. *J Invest Dermatol* 47:484-490, 1966.

39. Jones HE, Lewis C, McMarlin SL: Allergic contact sensitivity in atopic dermatitis. *Arch Dermatol* 107:217-222, 1973.

40. Lobitz WC Jr, Honeyman JF, Winkler MW: Suppressed cell-mediated immunity in two adults with atopic dermatitis. *Br J Dermatol* 86:317-328, 1972.

41. Cormane RH, Hamerlinck F, Husz S: B and T lymphocytes in certain varieties of dermatitis. *Ann NY Acad Sci* 254:592-599, 1975.

42. Papamichail M, Holborow EJ, Keith HI, et al: Subpopulations of human peripheral blood lymphocytes distinguished by combined rosette formation and membrane immunofluorescence. *Lancet* 2:64-66, 1972.

43. Gottlieb BR, Hanifin JM: Circulating T-cell deficiency in atopic dermatitis. *Clin Res* 22:159A, 1974.

44. Luckasen JR, Sabad A, Goltz RW, et al: T and B lymphocytes in atopic dermatitis. *Arch Dermatol* 110:375-378, 1974.

45. McGeady SJ, Buckley RH: Depression of cell-mediated immunity in atopic eczema. *J Allergy Clin Immunol* 56:393-406, 1975.

46. Hanifin JM, Gottlieb BR: IgE inhibits T-cell rosette formation. *Clin Res* 22:328A, 1974.

47. Rogge JL, Hanifin JM: Immunodeficiencies in severe atopic dermatitis. *Arch Dermatol* 112:1391-1396, 1976.

48. Hanifin JM, Bauman R, Rogge JL: Chemotaxis inhibition by plasma from patients with atopic dermatitis. *Clin Res* 25:198A, 1977.

49. Dahl B, Thestrup-Pedersen K, Ellegaard J, et al: Lymphocyte transformation, IgE and T-cells in eczema vaccinatum treated with transfer factor. *Acta Dermatol Venereol* 55:187-190, 1975.

50. Schoepf E, Boehringer D: IgE in cell-mediated immunity in atopic dermatitis. *J Dermatol* 1:133-144, 1974.

51. Grove DI, Reid JG, Forbes IJ: Humoral and cellular immunity in atopic eczema. *Br J Dermatol* 92:611-618, 1975.

52. Hashem N, Hirschorn K, Sedlis E, et al: Infantile eczema: Evidence of auto-immunity to human skin. *Lancet* 2:269-270, 1963.

53. Pass F, Larsen WG, Lobitz WC Jr: Cultured lymphocytes of atopic patients. *Ann Allergy* 24:426-429, 1966.

54. Fjelde A, Kopecka B: Effect of autologous skin extract and phytohemagglutinin on blood leukocytes of atopic dermatitis patients. *Dermatologica* 134:95-100, 1967.

55. Uehara M, Ofuji S: The leukocyte migration test in atopic dermatitis. *Acta Dermatol Venereol* 54:279-281, 1974.

56. Rostenberg A Jr, Solomon LM: Infantile eczema in systemic disease. *Arch Dermatol* 98:41-46, 1968.

57. Aldrich RA, Steinberg AG, Campbell DC: Pedigree demonstrating a sex-linked recessive condition characterized by draining ears, eczematoid dermatitis and bloody diarrhea. *Pediatrics* 13:133-139, 1954.

58. Reed WB, Epstein WL, Boder E, et al: Cutaneous manifestations of ataxia-telangiectasia. *JAMA* 195:746-753, 1966.

59. Buckley RH, Ray BB, Belmaker EZ: Extreme hyperimmunoglobulinemia-E and undue susceptibility to infection. *Pediatrics* 49:59-70, 1972.

60. Hill HR, Quie PG: Raised serum-IgE levels and defective neutrophil chemotaxis in three children with eczema and recurrent bacterial infections. *Lancet* 1:183-187, 1974.

61. Snyderman R, Buckley RH: Defects of monocyte chemotaxis in patients with hyperimmunoglobulinemia-E and undue susceptibility to infection. *Clin Res* 23:25A, 1975.

62. Jones HE, Artis WM: Histamine inhibition of human lymphocyte transformation. *Clin Res* 23:452A, 1975.

63. Kikkawa Y, Kamimura K, Hamagaima T, et al: Thymic alymphoplasia with hyper-IgE-globulinemia. *Pediatrics* 51:690-696, 1973.

64. Polmar SH, Waldmann TA, Terry WD: IgE in immunodeficiency. *Am J Pathol* 69:499-512, 1972.

65. Buckley RH, Fiscus SA: Serum-IgD and IgE concentrations in immunodeficiency diseases. *J Clin Invest* 55:257-265, 1975.

66. Schwartz D, Buckley RH: Serum IgE concentrations and skin reactivity to anti-IgE antibody in IgA-deficient patients. *N Engl J Med* 284:513-571, 1971.

67. Schiff RI, Buckley RH, Gilbertsen RB, et al: Membrane receptors and in vitro responsiveness of lymphocytes in human immunodeficiency. *J Immunol* 112:376-386, 1974.

68. Epstein LB, Ammann AJ: Evaluation of T lymphocyte effector function in immunodeficiency diseases: Abnormality in mitogen-stimulated interferon in patients with selective IgA deficiency. *J Immunol* 112:617-626, 1974.

69. Tada T, Okumura K, Taniguchi M: Cellular and humoral controls of reagenic antibody synthesis in the rat, in Goodfriend L, Sehon AH, Orange RP (eds): *Mechanisms in Allergy*. New York, Marcel Dekker, 1973, pp 43-61.

70. Smith SB: *Pathology*, ed 6, Anderson WAD (ed). St Louis, CV Mosby, 1972, p 1387.

71. Pantelouris EM: Absence of thymus in a mouse mutant. *Nature* 217:370-371, 1968.

72. Scheid M, Boyse EA, Carswell EA, et al: Serologically demonstrable alloantigens of mouse epidermal cells. *J Exp Med* 135:938-955, 1972.

73. Williams DH: Skin temperature reaction to histamine in atopic dermatitis (disseminated neurodermatitis). *J Invest Dermatol* 1:119-129, 1938.

74. Kalz F, Fekete Z: Studies on the mechanism of the white response and of the delayed blanch phenomenon in atopic subjects by means of coomassie blue. *J Invest Dermatol* 35:135-140, 1960.

75. Juhlin L: Vascular skin reactions in atopic dermatitis. *Acta Dermatol Venereol* 42:218-229, 1962.

76. Bystryn JC, Freedman RI, Hyman C: Clearance of iodoantipyrene from methocholine blanched skin in atopics. *Arch Dermatol* 100:165-168, 1969.

77. Ramsay C: Vascular changes accompanying white dermographism and delayed blanch in atopic dermatitis. *Br J Dermatol* 81:37-43, 1969.

78. Warndorff JA: The response of the sweat glands to acetylcholine in atopic subjects. *Br J Dermatol* 83:306-309, 1970.

79. Davis MJ, Lawler JC: Observations on the delayed blanch phenomenon in atopic subjects. *J Invest Dermatol* 30:127-132, 1958.

80. Hemels HG: The affect of propranolol on the acetylcholine-induced sweat gland response in atopic and in non-atopic subjects. *Br J Dermatol* 83:312-315, 1970.

81. Weber RG, Roth GM, Kierland RR: Further contributions to the vascular physiology of atopic dermatitis. *J Invest Dermatol* 24:19-30, 1955.

82. Johnson LA, Winkelmann RK: Cutaneous vascular reactivity in atopic children. *Arch Dermatol* 92:621-624, 1965.

83. Juhlin L: Skin reactions to iontophoretically administered epinephrine and norepinephrine in atopic dermatitis. *J Invest Dermatol* 37:201-205, 1961.

84. Bullough WS: The control of mitotic activity in adult mammalian tissues. *Biol Rev* 37:307-342, 1962.

85. Voorhees JJ, Duell EA, Kelsey WH: Dibutyryl cyclic AMP inhibition of epidermal cell division. *Arch Dermatol* 105:384-386, 1972.

86. Carr RH, Russe WW, Reed CE: Failure of catecholamines to inhibit epidermal mitosis in vitro. *J Allergy Clin Immunol* 55:255-262, 1973.

87. Reed CE, Busse WW, Lee TP: Adrenergic mechanisms and the adenyl cyclase system in atopic dermatitis. *J Invest Dermatol* 67:333-338, 1976.

88. Mier PD, Urselmann E: The adenylcyclase of skin: II. Adenylcyclase levels in atopic dermatitis. *Br J Dermatol* 83:364-366, 1970.

89. Holla SWJ, Hollman EPMJ, Mier PD, et al: Adenosine 3′, 5′-cyclic monophosphate phosphodiesterase in skin: II. Levels in atopic dermatitis. *Br J Dermatol* 86:147-149, 1972.

90. Mier PD, v/d Hurk J, Holla SWJ, et al: Cyclic 3′, 5′ adenosine monophosphate-dependent protein kinase of skin: 2 Levels in atopic dermatitis and psoriasis. *Br J Dermatol* 87:577-579, 1972.

91. Cotton DWK, Van Rossum E: Hexokinase, glucose-6-phosphate dehydrogenase and malate dehydrogenase in the isolated sweat glands of normal and atopic subjects. *Br J Dermatol* 89:459-465, 1973.

92. Logsden PJ, Middleton E Jr, Coffey RG: Stimulation of leukocyte adenylcyclase by hydrocortisone and isoproterenol in asthmatic and nonasthmatic subjects. *J Allergy Clin Immunol* 50:45-56, 1972.

93. Parker CW, Smith JW: Alterations in cyclic adenosine monophosphate metabolism in human bronchial asthma: I. Leukocyte responsiveness to beta adrenergic agents. *J Clin Invest* 52:48-59, 1973.

94. Parker CW, Eisen AZ: Altered cyclic-AMP metabolism in atopic eczema. *Clin Res* 20:418, 1972.

95. Lee TP, Storms W, Busse W, et al: A study of atopic epidermis: Adenylcyclase system and mitosis. *J Allergy Clin Immunol* 53:99, 1974.

96. Lichtenstein LM, Margolis S: Histamine release in vitro: Inhibition by catecholamines and methylxanthines. *Science* 161:902-903, 1968.

97. Assem ISK, Schild HO: Inhibition by sympathomimetic amines of histamine release induced by antigen in passively sensitized human lung. *Nature* 224:1028-1029, 1969.

98. Orange RP, Laliner MA, Austen KF: The immunological release of histamine and slow reacting substance of anaphylaxin from human lung, in Austen KF, Becker LL (eds): *Biochemistry of the Acute Allergic Reactions*. Philadelphia, FA Davis Company, 1971, pp 189-204.

99. Kaliner MA, Orange RP, Koopman WJ, et al: Pharmacologic enhancement of the IgE-mediated release of histamine and slow reacting substance of anaphylaxis in the rat, in Lepow IH, Ward PA (eds): *Inflammation Mechanisms and Control*. New York, Academic Press, 1972, pp 139-150.

100. Ishizaka T, Ishizaka K: IgE molecules and their receptor sites on basophils, in Goodfriend L, Sehon AH, Orange RP (eds): *Mechanisms in Allergy*. New York, Marcel Dekker, 1973, pp 221-234.

101. Henney CS, Bourne HR, Lichtenstein LM: The role of cyclic 3′, 5′ adenosine monophosphate in the specific cytolytic activity of lymphocytes. *J Immunol* 108:1526-1534, 1972.

102. Melmon KL, Bourne HR, Weinstein Y, et al: Hemolytic plaque formation by leukocytes in vitro. *J Clin Invest* 53:13-21, 1974.

103. Gillette RW, McKenzie GO, Swanson MH: Modification of the lymphocyte response to mitogens by cyclic-AMP and GMP. *J Reticuloendothel Soc* 16:289-299, 1974.

104. Glasgow A, Polgar P, Saporoschetz I, et al: Phytohemagglutinin stimulation of human lymphocytes: Failure to detect an early increase in cyclic-AMP concentration. *Clin Immunol Immunopathol* 3:353-362, 1975.

105. Rivkin I, Rosenblatt J, Becker EL: The role of cyclic AMP in the chemotactic responsiveness and spontaneous motility of rabbit peritoneal neutrophils. *J Immunol* 115:1126-1134, 1975.

CUT THE GRISEOFULVIN DOSE IN HALF

Gris-PEG®
(griseofulvin ultramicrosize) Tablets 125 mg

For fungal infections sensitive to griseofulvin

- Only half the dose required*
- Absorption nearly complete without fatty meals
- Once-a-day or b.i.d. dosage
- Reduced cost for patients

*250 mg of Gris-PEG® provides plasma levels equivalent to those obtained with 500 mg microsize griseofulvin. This improved absorption permits the oral intake of half as much griseofulvin but there is no evidence at this time that this confers any clinical difference in regard to safety or efficacy.

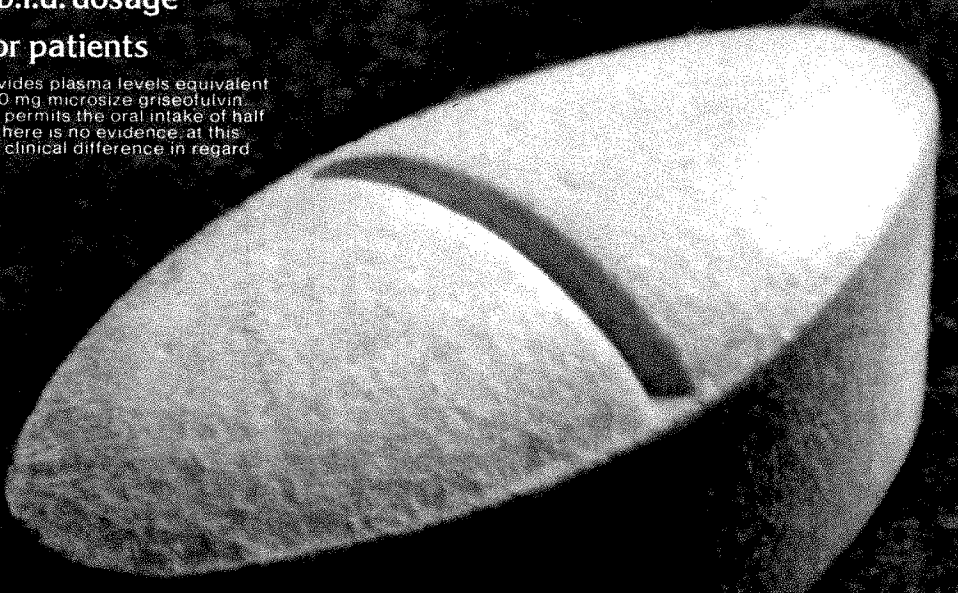

Dorsey LABORATORIES
Division of Sandoz, Inc.
LINCOLN, NEBRASKA 68501

Gris-PEG®
(griseofulvin ultramicrosize) Tablets 125 mg
The ½ dose griseofulvin.

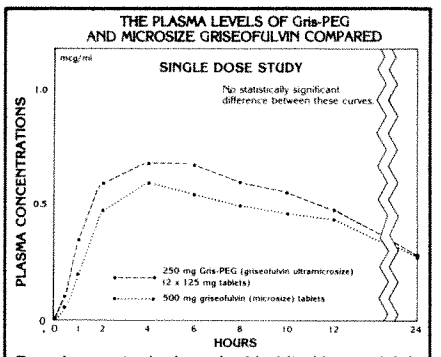

Based on a single dose double-blind bioavailability study conducted in 24 human volunteers comparing the average griseofulvin (microsize) and Gris-PEG plasma levels. There is no significant difference between peak plasma levels, times to peak, and areas under the curve. Gas chromatographic assay.

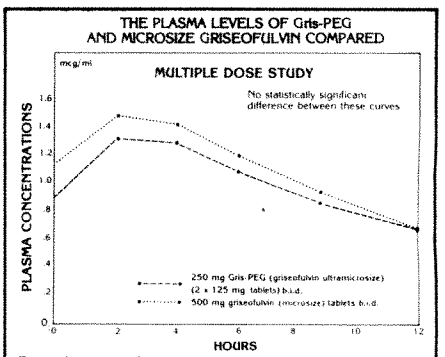

Based on a double-blind multiple dose steady state crossover bioavailability study conducted in 17 human volunteers comparing the average griseofulvin (microsize) and Gris-PEG plasma levels obtained on days 9, 11 and 13. There is no significant difference between times to peak, peak plasma levels, and areas under the curve. Gas chromatographic assay.

DESCRIPTION

Griseofulvin is an antibiotic derived from a species of *Penicillium*.

Gris-PEG is an ultramicrocrystalline solid-state dispersion of griseofulvin in polyethylene glycol 6000.

Gris-PEG tablets differ from griseofulvin (microsize) tablets USP in that each tablet contains 125 mg of ultramicrosize griseofulvin biologically equivalent to 250 mg of microsize griseofulvin.

ACTION

Microbiology: Griseofulvin is fungistatic with *in vitro* activity against various species of *Microsporum, Epidermophyton* and *Trichophyton*. It has no effect on bacteria or other genera of fungi.

Human Pharmacology: The peak plasma level found in fasting adults given 0.25 g of Gris-PEG occurs at about four hours and ranges between 0.37 to 1.6 mcg/ml.

Comparable studies with microsize griseofulvin indicated that the peak plasma level found in fasting adults given 0.5 g occurs at about four hours and ranges between 0.44 to 1.2 mcg/ml.

Thus, the efficiency of gastrointestinal absorption of the ultramicrocrystalline formulation of Gris-PEG is approximately twice that of conventional microsized griseofulvin. This factor permits the oral intake of half as much griseofulvin per tablet but there is no evidence, at this time, that this confers any significant clinical differences in regard to safety and efficacy.

Griseofulvin is deposited in the keratin precursor cells and has a greater affinity for diseased tissue. The drug is tightly bound to the new keratin which becomes highly resistant to fungal invasions.

INDICATIONS

Gris-PEG (griseofulvin ultramicrosize) is indicated for the treatment of the following ringworm infections.

Tinea corporis (ringworm of the body)
Tinea pedis (athlete's foot)
Tinea cruris (ringworm of the thigh)
Tinea barbae (barber's itch)
Tinea capitis (ringworm of the scalp)
Tinea unguium (onychomycosis; ringworm of the nails)

when caused by one or more of the following genera of fungi:

Trichophyton rubrum
Trichophyton tonsurans
Trichophyton mentagrophytes
Trichophyton interdigitalis
Trichophyton verrucosum
Trichophyton megnini
Trichophyton gallinae
Trichophyton crateriform
Trichophyton sulphureum
Trichophyton schoenleini
Microsporum audouini
Microsporum canis
Microsporum gypseum
Epidermophyton floccosum

NOTE: Prior to therapy, the type of fungi responsible for the infection should be identified.

The use of the drug is not justified in minor or trivial infections which will respond to topical agents alone.

Griseofulvin is *not* effective in the following:

Bacterial infections
Candidiasis (Moniliasis)
Histoplasmosis
Actinomycosis
Sporotrichosis
Chromoblastomycosis
Coccidioidomycosis
North American Blastomycosis
Cryptococcosis (Torulosis)
Tinea versicolor
Nocardiosis

CONTRAINDICATIONS

This drug is contraindicated in patients with porphyria, hepatocellular failure, and in individuals with a history of sensitivity to griseofulvin.

WARNINGS

Prophylactic Usage: Safety and Efficacy of Griseofulvin for Prophylaxis of Fungal Infections Has Not Been Established.

Animal Toxicology: Chronic feeding of griseofulvin, at levels ranging from 0.5-2.5% of the diet, resulted in the development of liver tumors in several strains of mice, particularly in males. Smaller particle sizes result in an enhanced effect. Lower oral dosage levels have not been tested. Subcutaneous administration of relatively small doses of griseofulvin, once a week, during the first three weeks of life has also been reported to induce hepatomata in mice. Although studies in other animal species have not yielded evidence of tumorigenicity, these studies were not of adequate design to form a basis for conclusions in this regard.

In subacute toxicity studies, orally administered griseofulvin produced hepatocellular necrosis in mice, but this has not been seen in other species. Disturbances in porphyrin metabolism have been reported in griseofulvin treated laboratory animals. Griseofulvin has been reported to have a colchicine-like effect on mitosis and cocarcinogenicity with methylcholanthrene in cutaneous tumor induction in laboratory animals.

Usage in Pregnancy: The safety of this drug during pregnancy has not been established.

Animal Reproduction Studies: It has been reported in the literature that griseofulvin was found to be embryotoxic and teratogenic on oral administration to pregnant rats. Pups with abnormalities have been reported in the litters of a few bitches treated with griseofulvin. Additional animal reproduction studies are in progress.

Suppression of spermatogenesis has been reported to occur in rats, but investigation in man failed to confirm this.

PRECAUTIONS

Patients on prolonged therapy with any potent medication should be under close observation. Periodic monitoring of organ system function, including renal, hepatic and hematopoietic, should be done.

Since griseofulvin is derived from species of *Penicillium*, the possibility of cross sensitivity with penicillin exists; however, known penicillin-sensitive patients have been treated without difficulty.

Since a photosensitivity reaction is occasionally associated with griseofulvin therapy, patients should be warned to avoid exposure to intense natural or artificial sunlight. Should a photosensitivity reaction occur, lupus erythematosus may be aggravated.

Griseofulvin decreases the activity of warfarin-type anticoagulants so that patients receiving these drugs concomitantly may require dosage adjustment of the anticoagulant during and after griseofulvin therapy.

Barbiturates usually depress griseofulvin activity and concomitant administration may require a dosage adjustment of the antifungal agent.

ADVERSE REACTIONS

When adverse reactions occur, they are most commonly of the hypersensitivity type such as skin rashes, urticaria, and rarely, angioneurotic edema, and may necessitate withdrawal of therapy and appropriate countermeasures. Paresthesias of the hands and feet have been reported rarely after extended therapy. Other side effects reported occasionally are oral thrush, nausea, vomiting, epigastric distress, diarrhea, headache, fatigue, dizziness, insomnia, mental confusion and impairment of performance of routine activities.

Proteinuria and leukopenia have been reported rarely. Administration of the drug should be discontinued if granulocytopenia occurs.

When rare, serious reactions occur with griseofulvin, they are usually associated with high dosages, long periods of therapy, or both.

DOSAGE AND ADMINISTRATION

Accurate diagnosis of the infecting organism is essential. Identification should be made either by direct microscopic examination of a mounting of infected tissue in a solution of potassium hydroxide or by culture on an appropriate medium.

Medication must be continued until the infecting organism is completely eradicated as indicated by appropriate clinical or laboratory examination. Representative treatment periods are—*tinea capitis*, 4 to 6 weeks; *tinea corporis*, 2 to 4 weeks; *tinea pedis*, 4 to 8 weeks; *tinea unguium*—depending on rate of growth—fingernails, at least 4 months; toenails, at least 6 months.

General measures in regard to hygiene should be observed to control sources of infection or reinfection. Concomitant use of appropriate topical agents is usually required particularly in treatment of *tinea pedis*. In some forms of athlete's foot, yeasts and bacteria may be involved as well as fungi. Griseofulvin will not eradicate the bacterial or monilial infection.

An oral dose of 250 mg of Gris-PEG (griseofulvin ultramicrosize) is biologically equivalent to 500 mg of griseofulvin (microsized), USP (see ACTION Human Pharmacology).

Adults: A daily dose of 250 mg will give a satisfactory response in most patients with *tinea corporis, tinea cruris* and *tinea capitis*. One 125 mg tablet twice per day or two 125 mg tablets once per day is the usual dosage. For those fungal infections more difficult to eradicate such as *tinea pedis* and *tinea unguium*, a divided daily dose of 500 mg is recommended. In all cases, the dosage should be individualized.

Children: Approximately 5 mg per kilogram (2.5 mg per pound) of body weight per day is an effective dose for most children. On this basis, the following dosage schedule for children is suggested:

Children weighing over 25 kilograms (approximately 50 pounds)—125 mg to 250 mg daily.

Children weighing 15-25 kilograms (approximately 30-50 pounds)—62.5 mg to 125 mg daily.

Children 2 years of age and younger—dosage has not been established.

Dosage should be individualized, as is done for adults. Clinical experience with griseofulvin in children with *tinea capitis* indicates that a single daily dose is effective. Clinical relapse will occur if the medication is not continued until the infecting organism is eradicated.

HOW SUPPLIED

Gris-PEG (griseofulvin ultramicrosize) Tablets (white) differ from griseofulvin (microsize) tablets (USP) in that each tablet contains 125 mg of ultramicrosize griseofulvin biologically equivalent to 250 mg of microsized griseofulvin. Two 125 mg tablets of Gris-PEG are biologically equivalent to 500 mg of microsized griseofulvin. In bottles of 100 and 500 scored, film-coated tablets.

Dorsey LABORATORIES
Division of Sandoz, Inc. • LINCOLN, NEBRASKA 68501

IN SKIN INFECTIONS, WHERE CLEANLINESS REQUIRES MORE THAN SOAP

BETADINE® Skin Cleanser

Degerms as it cleanses

Patients can use BETADINE Skin Cleanser to degerm and cleanse face, hands and body, gently and thoroughly—particularly when it is essential to prevent autoinoculation of new sites, as may be the case in infected acne pimples.

BETADINE Skin Cleanser, with its rich, golden lather, provides these advantages:

- Prompt, broad-spectrum microbicidal action—kills both gram-positive and gram-negative bacteria (including antibiotic-resistant strains), fungi, viruses, protozoa and yeasts.
- Maintains microbicidal activity in the presence of blood, pus and serum.
- Virtually nonirritating to skin and mucosa.*
- Nonstaining to skin and natural fabrics.

Supplied: 4 fl. oz. plastic bottles.

*In the rare instance of local irritation or sensitivity, discontinue use by the individual.

Purdue Frederick © COPYRIGHT 1976, THE PURDUE FREDERICK COMPANY

NORWALK, CONN. 06856 A8196 172078



For effective and individualized control of acne....

Prescribe the only benzoyl peroxide acne medication available in cover-up lotions....

LOROXIDE® Acne Lotion and LOROXIDE-HC® Lotion

(benzoyl peroxide 5.5%, chlorhydroxyquinoline ¼%) (benzoyl peroxide 5.5%, chlorhydroxyquinoline ¼%, hydrocortisone ½%)

- Contains the proved synergistic bactericidal combination of benzoyl peroxide and chlorhydroxyquinoline (300% greater antibacterial activity[1]) — which topically reduces C. Acnes *within* comedones[2]
- LOROXIDE-HC® effectively treats papular, pustular and cystic acne[3] — a favorable response has been reported in 75% of patients in as short a period as two weeks[4]
- Ideal therapy providing "all day," penetrating antimicrobial activity with controlled drying and desquamation — at school, work or play.
- No sun-sensitizing properties — no need to restrict your patient's outdoor activities or eliminate the known benefits of natural UV exposure.
- *The only* adjustable tint-intensity benzoyl peroxide lotions available.
- Replaces and helps to prevent abuse with over-the-counter cosmetics.
- For *day-long control* of all grades of acne vulgaris.
- Lesion-masking base helps to eliminate the..."natural but distorted feelings that other people perceive him as 'acne with a person attached rather than as a person who happens to have acne'."

REFERENCES: 1. Kuflik, E. G.: *Benzoyl Peroxide Gel in Acne Therapy,* Derm. Digest May, 1976, Pgs. 44-45. 2. Frank, L. and Petrou, P.: *Active Oxygen Plus Chlorhydroxyquinoline in Acne and Pyodermas,* Cutis, 3:3, Pg. 256-260, March, 1967. 3. Lubowe, I.: *Adolescent Skin Problems,* Cutis, Vol. 17, Pg. 369-374, February, 1976. 4. Frank, L.: *Active Oxygen in Acne Therapy,* Cutis 1:306, 1965. 5. Reisner, R.: *The Rational Therapy of Acne,* Cutis, Vol. 17, Pgs. 527-530, March, 1976.

Plus "Instant Social Confidence"

Dermik Color Blender™

EXCLUSIVE!



Dermik

Dermik Laboratories, Inc.
Fort Washington, Pa. U.S.A. 19034

LOROXIDE® Acne Lotion and LOROXIDE-HC® Lotion

DESCRIPTION: Loroxide Acne Lotion contains (as dispensed) benzoyl peroxide 5.5%, and chlorhydroxyquinoline 0.25%; incorporated in a water washable lotion consisting of purified water, propylene glycol, hydroxyethylcellulose, caramel color, cholesterol-sterol, cetyl alcohol, propylene glycol stearate, polysorbate 20, lanolin alcohol, propylparaben, decyl oleate, purcelline oil syn., antioxidants, vegetable oil, methylparaben, tetrasodium EDTA, buffers, cyclohexanediamine tetraacetic acid, calcium phosphate, silicone emulsion, silica, kaolin, talc and titanium dioxide, with "Dermik Color Blender™" supplied separately.

Loroxide-HC Lotion contains (as dispensed) hydrocortisone 0.5%, benzoyl peroxide 5.5% and chlorhydroxyquinoline 0.25% incorporated in a lotion identical to Loroxide Lotion (see above).

Actions: Provides keratolytic, peeling and drying action.

Indications: An aid in the treatment of acne and oily skin.

Contraindications: This product is contraindicated for use by patients having known hypersensitivity to hydrocortisone, benzoyl peroxide, chlorhydroxyquinoline or any other component of this preparation. Topical steroids are contraindicated in viral diseases of the skin, such as varicella and vaccinia.

Warning — Usage in Pregnancy: Although topical steroids have not been reported to have an adverse effect on the fetus, the safety of their use during pregnancy has not been absolutely established. Therefore, they should not be used extensively, or in large amounts or for prolonged periods of time on pregnant patients.

Precautions: For external use only. Keep away from eyes. If irritation develops, the product should be discontinued and appropriate therapy instituted. In the presence of an infection, the use of appropriate antifungal or antibacterial agents should be instituted. If a favorable response does not occur promptly, the corticosteroid should be discontinued until the infection has been adequately controlled. If extensive areas are treated, or if the occlusive technique is used, the possibility exists of increased systemic absorption of the corticosteroid and suitable precautions should be taken.

Do not add any other medicaments or substances to this lotion unless specifically directed by physician to do so. Patients should be observed carefully for possible local irritation or sensitization during long-term topical therapy. Apply with caution on neck and/or other sensitive areas. There may be a slight, transitory stinging or burning sensation on initial application which invariably disappears on continued use. Ultraviolet and cold quartz light should be employed in lesser amounts, as this lotion is keratolytic and drying. Harsh, abrasive cleansers should not be used simultaneously with this lotion. Colored or dyed garments may be bleached by the oxidizing action of benzoyl peroxide. Chlorhydroxyquinoline may cause temporary light-yellowish skin staining in rare cases. Keep out of the reach of children.

Adverse Reactions: The following local adverse reactions have been reported with topical corticosteroids: burning sensations, itching, irritation, dryness, folliculitis, secondary infection, skin atrophy, striae, hypertrichosis, acneiform eruptions, and hypopigmentation. The sensitizing potential of benzoyl peroxide and chlorhydroxyquinoline are low, but they can, on occasion, produce allergic reaction. Occurrence of excessive redness or peeling indicates that the amount and frequency of application should be reduced.

Directions: Shake well before using. Apply a small quantity to affected areas with light massaging 1 to 3 times daily, or in accordance with the physician's directions.

(Important information directed to the Pharmacist: At time of dispensing, add contents of vial* to the bottle. Shake well and/or stir with a glass rod to insure a uniform dispersion. Place expiration date of three (3) months on bottle label.)

*"Benzie-Pak" vials contain a mixture of benzoyl peroxide 35% and calcium phosphate 65%.

Net weight of each vial is 3.8 grams.

How Supplied: Bottles, 25 Gm.

Caution: Federal law prohibits dispensing without prescription.

Dermal Metastases From a Follicular Carcinoma of the Thyroid

Richard M. Auty, BSc, MD, MRCP

Cutaneous metastases from internal cancer are relatively uncommon, occurring in only two (5%) of all cases of cancer.[1,2] The carcinomas most frequently responsible for such lesions are those that produce extensive secondary deposits in the internal organs;[1] follicular carcinoma of the thyroid gland is such a tumor, producing widespread visceral lesions,[3] but no previous report of metastases to the skin in this condition has been found, to my knowledge.

From the Department of Medicine, Ahmadu Bello University, Zaria, Nigeria. Dr Auty is now with Fisons Ltd, Loughborough, Leicestershire, England.

Reprints not available.

REPORT OF A CASE

A 41-year-old Tiv man from Plateau Stage of Nigeria was first seen at Ahmadu Bello University Hospital, Zaria, in April 1976. Four years previously he had developed a painless swelling in the root of his neck, and a partial thyroidectomy was performed elsewhere. The operative specimen is now unavailable, but it was reported to show "follicular adenoma of the thyroid." The patient remained asymptomatic for two years after the operation, but in 1974 he began to develop painless nodules in the skin, first over the thyroidectomy scar, and then in the scalp, the face (including the nose), the neck, and the upper thorax.

On examination, he was a fit looking man with 26 nodules of various sizes on his head and chest (Fig 1). Each nodule was in the skin; those that were superficial were deep magenta, but the deep nodules were skin colored. All were pulsatile. The largest were in the long axis of the thyroidectomy scar (1 × 2 cm), and the smallest were hemispherical with a diameter of 0.5 cm. No lesions were found around or inside the mouth. Clinically the lesions were indistinguishable from those of Kaposi's sarcoma, as seen in northern Nigeria.

The arterial pulse was collapsing, and the blood pressure was 110/60 mm Hg. A few crepitations were audible at both lung bases. No other abnormal physical signs were detected. The chest roentgenogram showed multiple radio-opaque lesions in both lung fields, compatible with pulmonary metastases. No skeletal metastases were detected radiographically, nor were there any bony lesions underlying the skin nodules. A biopsy specimen of one of the cervical nodules showed a secondary depos-

Fig 1.—Multiple, pulsatile nodules on face and scalp, suggesting Kaposi's sarcoma.

Fig 2.—Histologic appearance of one nodule taken from neck. Normal dermis and secondary deposit of follicular carcinoma of thyroid gland (hematoxylin-eosin, original magnification ×40, left; ×100, right).

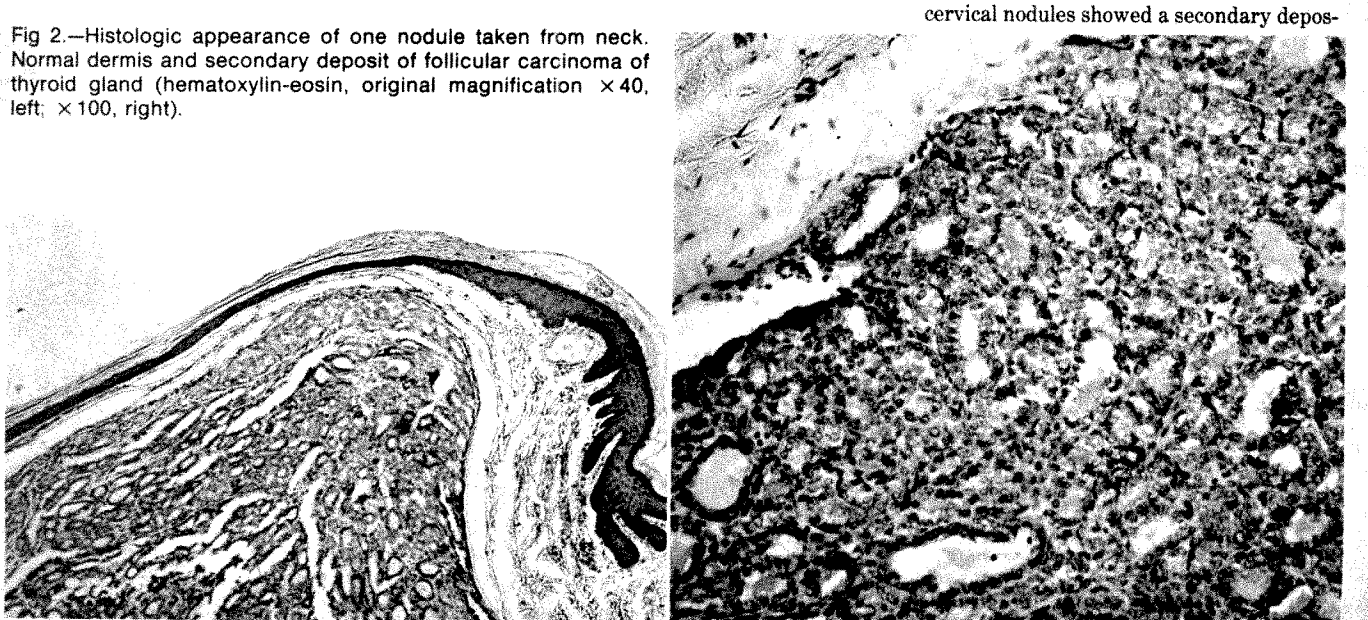

it of follicular carcinoma of the thyroid in the skin (Fig 2). The patient was treated with an initial dose of 80 μCi of radioactive iodine 125, followed four weeks later by a further dose of 150 μCi of radioactive iodine 125. He is being followed up as an outpatient.

COMMENT

Follicular carcinoma is the most malignant of the well-differentiated thyroid carcinomas (follicular carcinoma, papilliary carcinoma, and mixed carcinoma), and it has the worst prognosis at the time of diagnosis.[3] It spreads by the blood stream, and metastasis to the lungs and bones is typical.[4-6] Metastases have been found in almost every visceral organ, but not in the skin, although other malignant lesions of the thyroid are known to produce skin metastases.[5]

Gates[1] commented that tumors that produce extensive metastases to the internal organs are those most likely to metastasize to the skin. Clearly, follicular carcinoma of the thyroid falls into this category, but in her own extensive series she found only one case of "thyroid carcinoma" (type unspecified) metastasizing to the skin, and only two such cases (type again unspecified) in her review of the literature that extended back beyond 1900.

Mehregan[2] reported 22 cases of metastatic carcinoma to the skin, none from a thyroid neoplasm, and commented on his own and other workers' observation of the disproportionate frequency of lesions in the scalp. Gates[1] suggested that the apparent predilection for the scalp could be due to the vascularity and relative immobility of the skin at this site.

It appears, therefore, that this is the first documented case of metastasis to the skin by a follicular carcinoma of the thyroid.

Dr Charles Awunor-Renner gave permission to report a case admitted under his care, and Prof Eldryd H.O. Parry gave helpful advice and criticism.

References

1. Gates O: Cutaneous metastases of malignant disease. *Am J Cancer* 30:718-730, 1937.
2. Mehregan AM: Metastatic carcinoma to the skin. *Dermatologica* 123:311-325, 1961.
3. Russell WO: Follicular (organoid) carcinoma of the thyroid gland: Report of 84 cases, in Hedinger CE (ed): *Thyroid Cancer*, International Union Against Cancer, monograph No. 12, Berlin, Springer, 1969, pp 14-25.
4. Siliphant WM, Klinck GM, Leventin MS: Thyroid carcinoma and death. *Cancer* 17:513-525, 1964.
5. Ibanez ML, Russell WO, Albores-Saavedra J, et al: Thyroid carcinoma—biologic behavior and mortality. *Cancer* 19:1039-1052, 1966.
6. Silverberg SG, Vidone RA: Adenoma and carcinoma of the thyroid. *Cancer* 19:1053-1062, 1966.

Ulcerative Sarcoidosis

Report of an Unusual Case

Judith Schiffner, MD, Om P. Sharma, MD

Sarcoidosis is a systemic granulomatous disease of unknown cause that may involve almost any organ of the body. The skin is involved in approximately 25% of patients with the disease. Characteristically, the skin lesions do not ulcerate, do not become necrotic, and do not form sinuses. This report describes a patient with extensive multisystem sarcoidosis who had numerous ulcerated cutaneous plaques and nodules.

REPORT OF A CASE

A 79-year-old black woman was referred to Los Angeles County-University of Southern California Medical Center in February 1974 for evaluation of increasingly severe skin lesions. She was in excellent health until 1950, when she developed a chronic malar erythematous "butterfly eruption" and a swollen right fifth digit. Three years prior to admission, the facial lesions had become nodular and crusted. Because of the increase in number and severity of the skin lesions, as well as the apparent multisystem involvement of the process, she was referred to this institution.

On admission, the physical examination showed erythematous, ulcerated nodules and plaques over both malar areas with serous exudation and crusting. Involvement of the left upper and lower eyelids resulted in near-complete closure of the left eye (Fig 1). Granulomatous lesions were observed on mucosa of the soft and hard palate and uvula. Collapse of the septum and crusting of the nasal mucosa were also noted. The entire right fifth digit and right fourth digit about the proximal interphalangeal joint demonstrated fusiform violaceous swelling (Fig 2). There were several ulcerated nodules on the dorsum of the right wrist and forearm. The rest of the physical examination was normal.

Important laboratory data included a reversed albumin-globulin ratio and absence of complement-fixing antibodies against coccidioidomycosis and histoplasmosis. Intradermal skin testing with purified protein derivative, coccidioidin, histoplasmin, mumps antigen, *Candida* and *Trichophyton* antigens, streptokinase-streptodornase were all negative at 48 hours.

The chest x-ray film showed parenchymal linear densities in the right upper lung zone at both bases with associated calcification in the right perihilar and peritracheal nodes. X-ray films of the hands showed extensive soft-tissue swelling of the right fourth and fifth fingers with radiolucent cystic changes involving the proximal right fourth and fifth phalanges and middle phalanx of the right fifth finger. A biopsy specimen from a forearm and facial nodules showed noncaseating epithelioid granulomas (Fig 3). In certain areas substantial lymphocytic and polymorphonuclear infiltration was present. Special stains for fungi and acid-fast and pyogenic bacteria were negative. Culture of the biopsied tissue also did not grow fungi or acid-fast bacilli. Guinea pig inoculations were negative. Examination of the

From the Departments of Dermatology (Dr Schiffner) and Medicine, Pulmonary Disease Service (Dr Sharma), Los Angeles County/University of Southern California Medical Center, Los Angeles.

Reprint requests to University of Southern California School of Medicine, 2025 Zonal Ave, Los Angeles, CA 90033 (Dr Sharma).

Fig 1.—Erythematous, indurated nodules and plaques over both malar area and left upper eyelid. Note extensive exudation and crusting. Patient is not able to open her left eye.

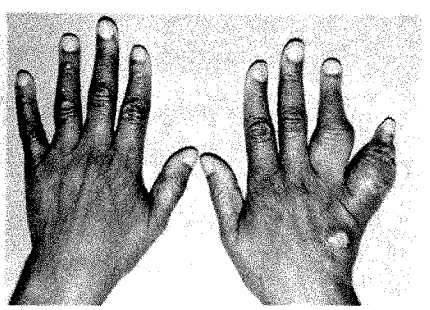

Fig 2.—Fusiform erythematous swelling with exudation and ulceration of right fourth and fifth digits.

biopsy specimens under polarized light did not show birifringent particles.

The diagnosis of sarcoidosis was made, and the patient received 500 mg of chloroquine phosphate daily. She also received weekly intralesional triamcinolone acetonide (5 mg/ml) injections to the left upper eyelid for one month with reduction of the swelling. After two months of the chloroquine therapy, there was only modest improvement, but when treatment with prednisone (15 mg daily) was added, skin lesions cleared rapidly. After ten months of therapy, the chloroquine was discontinued, and the prednisone was tapered to 5 mg daily. All skin lesions have resolved completely, leaving residual atrophic scars.

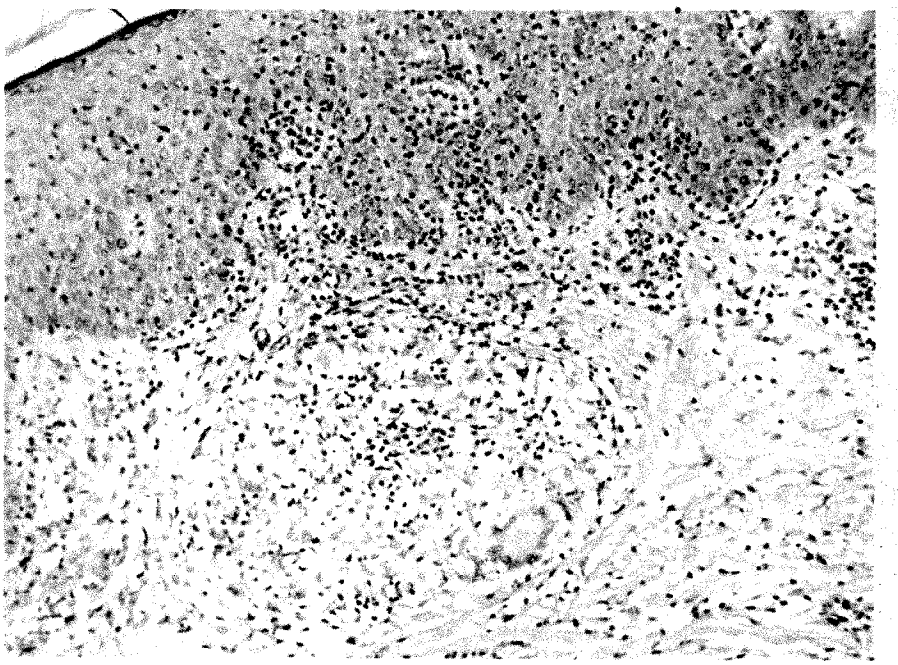

Fig 3.—Biopsy specimen of facial nodule showing discrete noncaseating epithelioid cell granuloma. Note presence of multinucleated giant cell and lymphocytes (hematoxylin-eosin, ×100).

COMMENT

The differential diagnosis of the type of skin lesions seen in this patient with histologic evidence of noncaseating granulomas includes infectious granulomas (lupus vulgaris, tertiary syphilis, deep mycosis, leprosy, swimming pool granuloma), foreign-body granulomas (silica, beryllium, and zirconium), and sarcoidosis.[1-3] The patient's history, physical examination, negative laboratory findings, and negative cultures for acid-fast bacilli and fungi effectively ruled out the existence of either the infectious or foreign-body granulomatous diseases.

The diagnosis of sarcoidosis of the skin requires the following: (1) clinical evidence of multisystem involvement or the radiologic picture consistent with sarcoidosis, or both; (2) histologic evidence of noncaseating granulomas; and (3) negative culture of tissues for acid-fast bacilli and fungi. Our patient fulfilled these criteria. In addition to her skin lesions, she showed characteristic lung, bone, and mucous membrane involvement. She was anergic to tuberculin, coccidioidin and histoplasmin, and blastomycin intradermal antigens. Her chronic indolent course of 20 years and the response to antimalarials and corticosteroids support the diagnosis of sarcoidosis.

The various skin manifestations of sarcoidosis include erythema nodosum, maculopapular rash, nodules, hypopigmented or hyperpigmented patches, scar sarcoid, lupus pernio, and plaques.[4] The presence of ulceration or necrosis of skin lesions is rare. In a few affected cases of ulcerative sarcoidosis, the legs have been a common site of ulceration. Ulcerative facial lesions of the type seen in our patient are distinctly unusual.[5,6] Another infrequent finding in this case was a mixed lymphocytic and polymorphonuclear infiltrate in certain areas.

References

1. Sharma OP: Cutaneous sarcoidosis Clinical features and management. *Chest* 61:320-325, 1972.
2. James DG: Dermatological aspects of sarcoidosis. *Q J Med* 28:109-124, 1959.
3. Sharma OP, James DG: Differential diagnosis of sarcoidosis. *Practitioner* 202:619-623, 1969.
4. Sharma OP: *Sarcoidosis: A Clinical Approach*. Springfield, Ill, Charles C Thomas Publisher, 1975.
5. Irgang S: Ulcerative cutaneous lesions in sarcoidosis. *Br J Dermatol* 67:155-260, 1955.
6. Brodkin RH: Leg ulcers: A report of two cases caused by sarcoidosis. *Acute Derm Venereol* 49:584-587, 1969.

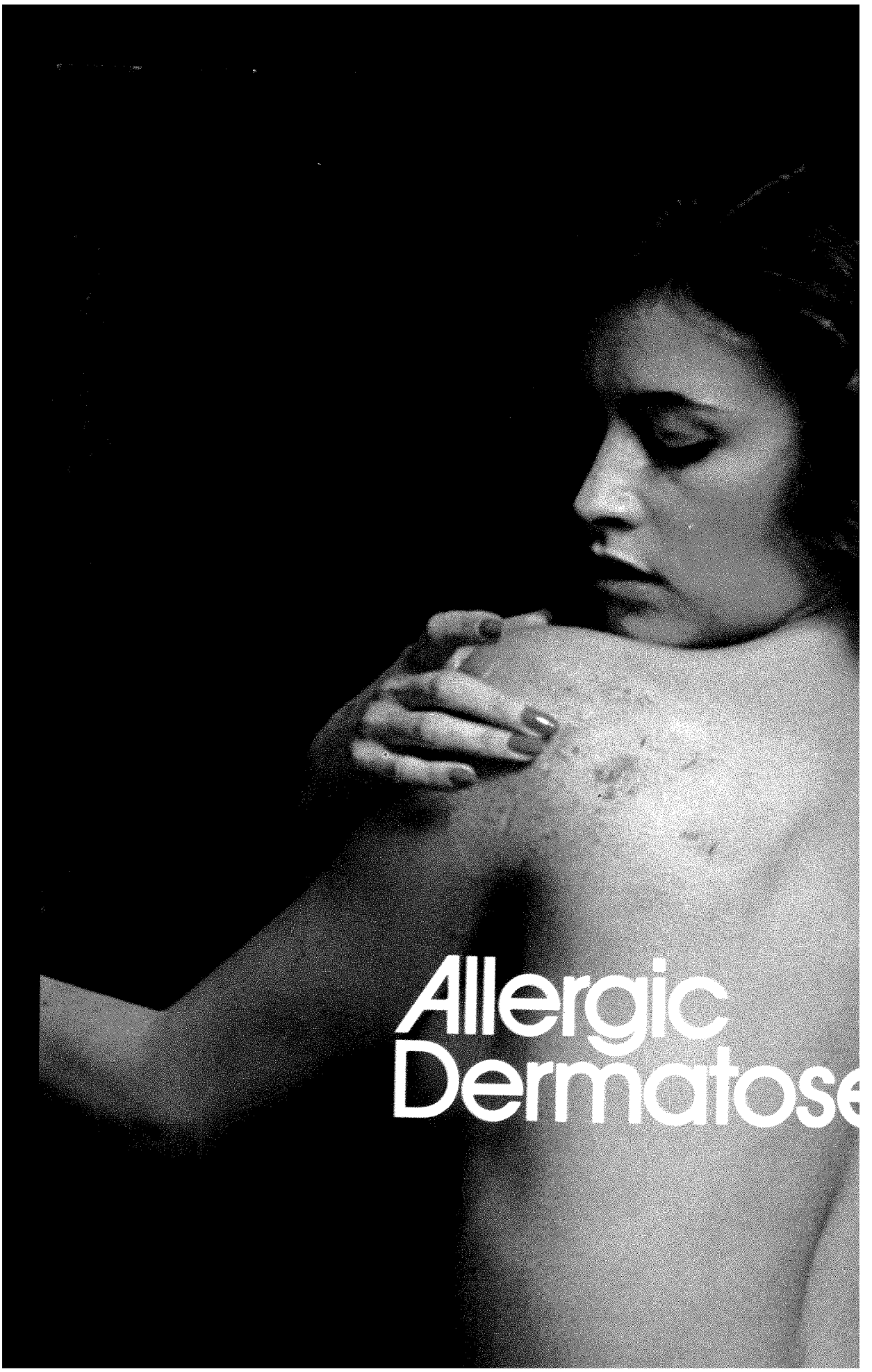
Allergic
Dermatose

rat, and rabbit, induced fetal abnormalities in the rat at doses substantially above the human therapeutic range. Clinical data in human beings are inadequate to establish safety in early pregnancy. Until such data are available, hydroxyzine is contraindicated in early pregnancy.

Precautions: Hydroxyzine may potentiate the action of central nervous system depressants such as meperidine and barbiturates. In conjunctive use, dosage for these drugs should be reduced. Because drowsiness may occur, patients should be cautioned against driving a car or operating dangerous machinery.

Adverse Reactions: Drowsiness may occur; if so, it is usually transitory and may disappear in a few days of continued therapy or upon dosage reduction. Dryness of the mouth may occur with higher doses. Involuntary motor activity, including rare instances of tremor and convulsions, has been reported, usually with higher than recommended dosage.

Supply: Tablets, containing 10 mg, 25 mg, or 50 mg hydroxyzine hydrochloride, 100's and 500's; Tablets, containing 100 mg, 100's; Syrup, containing 10 mg per teaspoonful (5 ml) and ethyl alcohol 0.5% v/v, pint bottles.

Before prescribing or administering, see package circular.

with strong emotional overlay

the cause can be obscure

Factors precipitating allergic dermatoses with strong emotional overlay, which can range from allergens to anxiety, can be difficult to identify.

successful treatment often includes

Atarax®
(hydroxyzine HCl)

TABLETS: 10 mg, 25 mg, 50 mg, and 100 mg

- rapid antianxiety action
- demonstrated antihistaminic activity

ROERIG Pfizer

A division of Pfizer Pharmaceuticals

New York, New York 10017

Acne on back and shoulders—now within easy reach.

BUF BODY SCRUB provides "epidermabrasion"—the mechanical exfoliation of the outer layer of dead skin cells.

- thoroughly cleanses the skin and removes excess oil
- helps to loosen and remove comedones
- aids removal of coarse, rough skin of hyperkeratosis
- high patient acceptance of BUF-PUF documented by clinical studies

NEW BUF™ BODY SCRUB

A unique new product that features BUF-PUF® Nonmedicated Cleansing Sponge on a contoured, reusable handle.

BUF BODY SCRUB is another new and unique dermatologic product from Riker Laboratories, Inc., makers of BUF-PUF Nonmedicated Cleansing Sponge, BUF™ Acne Cleansing Bar, and BUF™ Kit for Acne.

Riker Laboratories, Inc.
NORTHRIDGE, CALIFORNIA 91324

SUBSIDIARY OF 3M COMPANY

Letters to the Editor

Macrocytosis and Hydroxyurea Therapy in Psoriatics

To the Editor.—Macrocytosis has been reported as a side effect of hydroxyurea therapy in psoriatics. There have been no long-term follow-up reports of patients with psoriasis who were treated with hydroxyurea.

Ten psoriatics treated with hydroxyurea six years previously were recalled for observation and blood studies. In eight patients, there was no macrocytosis. Two patients had macrocytosis; one of these patients was a chronic alcoholic and the other was taking hydroxyurea. It was thought that the macrocytosis was due to the alcoholism and current hydroxyurea medication in these patients. There was no evidence of folic acid or vitamin B_{12} deficiency. There were no long-term ill effects from hydroxyurea.

ULLIN W. LEAVELL, JR, MD
PHILIP DESIMONE, MD
PHILIP REEDER, MD
Lexington, Kentucky

Hydroxyzine Products

To the Editor.—Patients who have urticaria are frequently treated with hydroxyzine. A number of articles have implicated sensitivity to tartrazine (FD&C Yellow No. 5) as a causative factor in cases of chronic urticaria.[1,2] It is important for the dermatologists to be aware of which hydroxyzine products are free of this dye.

I have been informed in a letter from the manufacturer of these products that hydroxyzine hydrochloride (Atarax), 25 mg and 50 mg, and all hydroxyzine (Vistaril) pamoate capsules and suspension contain tartrazine. However, hydroxyzine hydrochloride, 10 mg, 100 mg, and syrup forms, does not contain tartrazine dye.

PATRICIA G. ENGASSER, MD
Redwood City, Calif

1. Ros AM, Julin L, Michaelsson G: A follow-up study of patients with recurrent urticaria and hypersensitivity to aspirin, benzoates, and azo dyes. *Br J Dermatol* 95:19, 1976.

2. Fiedelman W, Martens J: Hypersensitivity to tartrazine (FD&C Yellow No. 5) and other dyes present in pharmaceutical products. *Cutis* 15:576, 1975.

Neonatal Anaerobic (Clostridial) Cellulitis and Omphalitis

To the Editor.—The following case is reported as an example of an unusual anaerobic infection with cutaneous findings.

Report of Case.—A 3.4-kg baby girl was delivered without incident of a 22-year-old primipara. At age 4 days, the infant was hospitalized 14 hours after the development of erythema and induration of the periumbilical skin. A brown watery discharge developed that was found to contain Gram-positive rods and cocci. The rod, identified as a clostridial species, grew as an anaerobe. *Staphylococcus aureus* and *Streptococcus faecalis* were also cultured, the former growing as a facultative anaerobe. Antibiotics failed to halt the process and after 48 hours of illness the skin in the periumbilical region had become dusky purple-gray and necrotic in appearance to a point 1.5 cm from the umbilicus. Vesicles were apparent centrally. Peripheral to the devitalized area was a 3- to 5-cm thick zone of sharply demarcated viable but faintly purpuric skin. This discolored front advanced behind a still wider area of erythema and induration. There was no crepitus. White blood cell count was 36,000/cu mm with a left shift. x-Ray films showed no abnormal foci of gas production.

The patient was moved to another hospital, observed for 24 hours, and taken to surgery. A circle of periumbilical skin 5 cm in diameter was excised, the dissection being carried down to the rectus sheath. The postoperative course was marked by many complications including seizures (no trismus), bleeding from the operative site, cardiac arrest, and finally, death 36 hours after surgery. Necropsy revealed fibrinoid necrosis of the periumbilical skin. Suppuration and necrosis were found in the umbilicus involving portions of the umbilical vasculature in the abdominal wall. Vessels within the abdominal cavity were not involved. There was no evidence of frank peritonitis, there being only a small focus of fibrin deposition on the peritoneum deep to the operative site. Induration and edema with a sparse inflammatory infiltrate had extended to the dermis and subcutaneous fat of the chest wall and also into retroperitoneal and mediastinal areas. Neuronal degenerative changes were found in the brain. Blood and tissue cultures were negative.

The clostridial species that was also isolated from the mother's vagina was identified as *Clostridium sordelleii.* The species is widely distributed in nature and is rarely pathogenic in man.[1(p220)] *Clostridium sordelleii* produces a β toxin that has a dermonecrotic effect in laboratory animals.[1(pp226-227)]

Comment.—In this fulminating case, the precise role of each of the possible pathogens is difficult to assess, but the findings suggest that exotoxins were a factor. A clostridial organism was cultured from a focus of putrefaction. Well-defined zones of tissue damage were evident clinically and anatomically. Rapid systemic deterioration occurred despite surgery and antibiotic therapy. No evidence of disseminated infection was found.

Clostridial infection and exotoxin elaboration result when contamination occurs under conditions of diminished oxygen tension. These prerequisites can be created by a variety of processes including trauma, natural tissue sloughing (eg, umbilical stump), stasis, and infection. Often other kinds of bacteria help set the stage for clostridial sepsis.[2] Anaerobic infections have been classified into three general categories: superficial with minimal tissue destruction, anaerobic cellulitis, and deep infection with catastrophic events such as gas gangrene, necrotizing myositis, and toxemia.[2(pp406-408),3] The consensus seems to be that the first two categories are easily treated with antibiotic therapy and timely debridement.

It is worth emphasizing that the

presence of clostridia plus putrefaction constitutes almost prima facie evidence that necrotic tissue is present. Such a devitalized focus can serve as an enclave for proliferating bacteria and accumulating toxins. Thus, pathogenic agents lie beyond the reach of blood-borne defenses, drugs, and antitoxins but are quite capable of local extension or systemic dissemination. The kinds of toxins elaborated vary from species to species. Although not all clostridia are regarded as being pathogenic for man, the toxin-producing potential for some organisms is not well known and could vary in unpredictable ways. In light of these facts, much can be said for prompt debridement of tissue that is undergoing putrefaction and digestion, although the timing of surgery is a matter of judgment subject to many variables. Clinicians should be alert for the superficial and cutaneous findings just described that are only rarely seen in modern practice.

DANIEL GORMLEY, MD
Glendora, Calif

1. Trevor WA: *Clostridia of Wound Infections.* London, Butterworth & Co, 1969, pp 220, 226-227.
2. Smith LDS, Holdeman LU: *The Pathogenic Anaerobic Bacteria.* Springfield, Ill, Charles C Thomas Publisher, 1968, pp 406-408 and 411.
3. MacLennan JD: The histotoxic clostridial infections of man. *Bacteriol Rev* 26:177-274, 1962.

Fragmentation of Elastic Fibers

To the Editor.—The June 1976 issue of the ARCHIVES contains an interesting report of a case of acquired cutis laxa.[1] Although we do not doubt the authors' statement that they observed "fragmentation and granulation" of elastic fibers in the skin sections they studied, we submit that Figure 4 of their article does not document that statement.

As we pointed out in 1969,[2] fragmentation of elastic fibers is difficult to prove. Many normal elastic fibers, because of their three-dimensional distribution in the skin, are chopped into short pieces by the microtome knife, and this effect is recognized by the sharp edges of the "fragments" as illustrated in Figure 4 of the article by Scott et al[1] and in Figures 63 and 247 of the second edition of our book.[3] True elastolysis is illustrated in Figure 257 of *A Guide to Dermatohistopathology.*

HERMANN PINKUS, MD
AMIR H. MEHREGAN, MD
Monroe, Mich

1. Scott MA, Kauh YC, Luscombe HA: Acquired cutis laxa associated with multiple myeloma. *Arch Dermatol* 112:853-855, 1976.
2. Pinkus H, Mehregan AH: *A Guide to Dermatohistopathology.* New York, Appleton-Century-Crofts, 1969.
3. Pinkus H, Mehregan AH: *A Guide to Dermatohistopathology,* ed 2. New York, Appleton-Century-Crofts, 1976.

In Reply.—It has been well acknowledged that fragmentation of elastic fibers is difficult to prove as Dr. Pinkus stated. When we prepared the special stains for elastic fibers, we were keenly aware of this difficulty. Therefore, we compared the preparation of our patient with three other normal specimens.

Even though complete elastolysis was not demonstrated in our patient, we strongly believe that the findings differed significantly from the controls. According to *A Guide to Dermatohistopathology* by Drs Pinkus and Mehregan, it was stated that "The severity of changes varies topographically and some areas of skin may look quite normal."

In addition, the patient died since the publication was submitted, and autopsy material further supported our contention.

MARGERY A. SCOTT, MD
YOUNG C. KAUH, MD
HERBERT A. LUSCOMBE, MD
Philadelphia

Hypothyroidism and Lichen Myxoedematosus

To the Editor.—Case reports and studies to date on lichen myxoedematosus, in particular its rare variant scleromyxoedema of Gottron[1] have stressed the absence clinically and biochemically of associated or complicating hypothyroidism.

Most recently, Hill et al[2] described the successful use of radiation therapy in a patient with lichen myxoedematosus who had laboratory confirmation of normal thyroid function. They propose as one of three criteria for the diagnosis of this condition the exclusion of thyroid dysfunction by clinical and laboratory means. We think this is too restricted a view.

Brigden[3] recently reported a case from our Unit of lichen myxoedematosus in a now 60-year-old man who has been troubled throughout the course of his disease by symptoms attributable to occlusive vascular disease that affect his left internal carotid artery. Increasing lethargy and poverty of thought led to assessment of his thyroid status. Clinical evidence of hypothyroidism was masked by his almost universal cutaneous scleromyxoedema.

Laboratory values from examinations included a serum thyroxine level of 3.0 μg/100 ml (normal range 3.5 to 11.0), a T3 uptake of 88 (normal range 100 ± 20), and a free thyroxine index of 2.6 ng/100 ml (normal range 3 to 13). Thyroid antibodies were not found. The patient's fresh serum was turbid. Lipoprotein electrophoresis revealed raised beta and pre-beta lipoprotein levels. His fasting serum cholesterol level was 338 mg/100 ml; serum triglyceride level was 306 mg/100 ml. These findings were consistent with a type IIB pattern of hyperlipoproteinemia, as defined by Brown.[4] L-thyroxine sodium therapy was commenced; a dramatic improvement in our patient's cerebral symptoms was noted.

It is possible that thyroid dysfunction in this case could have resulted from mucinous infiltration of the gland, as part of a possible systemic mucinosis, but proof would require more detailed investigation. Hypothyroidism thus, may develop with lichen myxoedematosus.[5]

Hill et al,[2] also state that they know of only one case of lichen myxoedematosus, associated with a serum paraproteinemia, having light chains of Kappa type. Our case[3] also is of interest, in that he too demonstrates the characteristic serum IgG paraprotein, having Kappa light chains, making this to our knowledge the second such reported association in the literature.

We wish to state that exclusion of thyroid dysfunction should not be a criterion for the diagnosis of lichen myxoedematosus. Thorough evaluation of thyroid function, perhaps by radiological, histological, and immunofluorescent techniques, should be performed in the continued attempt to elucidate the pathogenesis of this disease.

G. C. ARCHIBALD, MRACP
H. T. CALVERT, FRCP
Reading, England

1. Gottron HA: Scleromyxoedema (Eine Eigenartige Erschein Angys Form Von Myxothesaurodermis). *Arch Dermatol Syph* 199:71-91, 1954.
2. Hill TG, Crawford JN, Rogers CC: Successful management of lichen myxoedematosus: Report of a case. *Arch Dermatol* 112:67-69, 1975.
3. Brigden WD: Papular Mucinosis (Scleromyxoedema of Arndt-Gottron) associated with paraprotein IgG Kappa type. *Proc R Soc Med* 67:200-201, 1974.

4. Brown HB, Lewis LA, Page IH: Mixed hyperlipidaemia: A sixth type of hyperlipoproteinaemia. *Atherosclerosis* 17:181-196, 1973.

5. Lai a Fat FRM, Suurmond D, Radl J, et al: Scleromyxoedema (lichenmyxoedematous) associated with a paraprotein, IgG of type Kappa. *Br J Dermatol* 88:107-116, 1973.

Familial Lupus: Spectrum of Disease in One Family

To the Editor.—In a recent study on lupus erythematosus (LE), Prystowsky and Gilliam[1] separated their patients into the following three groups: a group of patients with LE limited to the skin; a group with active discoid lesions plus visceral involvement; and a group with proliferative glomerulonephritis. We found this particularly interesting for we were observing at that time a case of familial lupus in which the three probands corresponded to these three distinct groupings.

Report of Cases.—**Case 1.**—A 26-year-old woman was seen in August 1975, with atrophic, tender, hypopigmented areas on her palms and soles, breasts, thighs, and scalp that were accompanied with arthralgia, morning stiffness, recent weight loss, and Raynaud phenomenon. The patient appeared ill and was hospitalized. A test for antinuclear antibody (ANA) was positive in titer of 1:1,280 and was reported as 3+ shaggy. The anti-DNA was less than 1:10 μg/ml. Lupus erythematosus cell preparation was strongly positive. Rheumatoid factor was negative. The C'H50 was 50 units (normal, 25 to 57 units); C3 was 100 mg/100 ml (normal, 125 to 175 mg/100 ml), and the C4 was 28mg/100 ml (normal, 20 to 50 mg/100 ml). Urine reaction for protein was 2+ and the 24-hour urine protein was 735 mg/100 ml. A skin biopsy specimen was taken that was typical of LE. HLA type was 2,9;7,17. The ENA was undetectable. Severe pleuritic chest pain developed during the patient's hospitalization which was diagnosed as lupus pleuritis. She responded to bed rest and salicylate therapy.

Case 2.—This 34-year-old woman, the sister of patient 1, had typical discoid lesions on her scalp, ears, fingers, toes, abdomen, and nostrils, which on biopsy were interpreted as discoid LE. The results of all laboratory studies including the ANA, LE preparation, and complement were either normal or negative. HLA type was 2,9;7,17. The ENA was undetectable.

Case 3.—A 15-year-old female adolescent (another sister) was admitted to the hospital in January 1968, because of a one-week history of generalized edema. Physical examination revealed a cachectic-appearing girl with 1 – 2+ generalized edema. The patient had marked proteinuria and a renal biopsy was performed that demonstrated lupus nephritis. Despite high-dose steroid therapy, her condition steadily deteriorated. Pleural effusion, pneumonia, and renal failure developed and she died in March 1968. An autopsy consent was not obtained, but the laboratory studies shortly before her death revealed the following: hemoglobin level, 6.4 mg/100 ml; urea nitrogen level, 97 mg/100 ml; creatinine clearance, 34 mg/100 ml; 24-hour urine protein level, 6 mg/100 ml; and ANA, 4+. HLA type was not available.

Comment.—Apart from adding another report of familial lupus to the growing literature of familial occurrence of LE,[2] we thought that these cases were interesting because the entire spectrum of LE is demonstrated in one family whereas other familial reports tend to demonstrate a familial systemic or familial discoid lupus.[3-7]

The mother and father were deceased; however, three other siblings were studied extensively. There was no clinical or laboratory evidence of LE. Because of the reported association of HL-A1 and HL-A8[8] with systemic lupus, HLA typing was done on all available family members. HLA types of the involved siblings were already presented. The following types were noted in the uninvolved siblings: HLA type 2,30;14,17; HLA type 2,30;17; and HLA type 2,9;7,17.

Sidney Barsky, MD
David Knapp, MD
Bruce Bennin, MD
Chicago

1. Prystowsky S, Gilliam J: Discoid lupus erythematosus as part of a larger disease spectrum. *Arch Dermatol* 111:1448-1452, 1975.

2. Dubois E: *Lupus Erythematosus.* Los Angeles, University of Southern California Press, 1974, p 383.

3. First M: Familial lupus erythematosus. *S Afr Med J* 47:742-744, 1973.

4. Gall R, Forde D: Familial chronic discoid lupus erythematosus and hypergammaglobulinemia. *Arch Intern Med* 117:627-631, 1966.

5. Spector D, Jampol L, Hayslett J: Report of the familial occurence of systemic lupus erythematosus in male siblings. *Arthritis Rheum* 16:221-224, 1973.

6. Steagal R, Ash H, Fentanes L: Familial lupus erythematosus. *Arch Dermatol* 85:394-396, 1962.

7. Arnett F, Bias W, Shulman L: Studies in familial systemic lupus erythematosus, abstracted. *Arthritis Rheum* 15:102, 1972.

8. Goldberg M, Arnett F, Bias W, et al: Histocompatibility antigens in systemic lupus erythematosus. *Arthritis Rheum* 19:129-132, 1976.

Pachyonychia Congenita With Recessive Inheritance

To the Editor.—Pachyonychia congenita (PC), a rare genodermatosis, to our knowledge was first described by Jadassohn and Lewandowsky in 1906.[1] It is characterized by the typically thickened dystrophic nails, keratoderma of the palms and soles, hyperhidrosis, plantar blisters, keratosis pilaris, leukokeratosis oris, ichythosis, steatocytoma multiplex, epidermal cysts, and other features of dyskeratosis such as corneal dystrophy, cataract, hypoplastic hair, and changes in the teeth, nose, ears, and mucous membranes.

A majority of the cases were reported from Europe and America, and studies from several large families have demonstrated that PC is transmitted as a simple mendelian dominant gene with incomplete penetrance.[2-6]

Asian cases were rarely reported, and the disease, as far as we are aware, has not been known to be inherited as an autosomal recessive trait.

Recently, an Indian girl from Western Malaysia was found to have PC, but the disease appeared to be a recessive disorder, as she was the product of a consanguineous marriage. The inheritance of this interesting patient is briefly discussed.

Report of a Case.—A 4-year-old Indian girl from Johore Bahre, Western Malaysia, was recently seen at our clinic because of her abnormal nails since infancy. Several months after birth, her parents observed that the nails of all her toes and fingers were grossly thickened, distorted, and broke easily at the free edge. Frequent clippings did not prevent this reappearance. The nail beds were readily infected after minor trauma, and occasionally, the whole nail was shed to be replaced by another abnormal nail. She had a transient erythematous rash at the age of 6 months, and was suffering from recurrent "boils" and "dandruff." There was no residual pigmentation or hair loss. Her palms and feet sweated freely, and when she started to walk at approximately one year of age, small blisters and peeling of the skin appeared on the sides of the toes and feet. A year later, small, discrete calluses developed on the sides of the feet and the plantar surface of the toes. About two years ago, her parents noted that small horny lesions developed on both sides of her knees, her elbows, and one buttock. These caused mild irritation and itch. She had no other systemic symptoms. Her birth and milestones were normal and her physical and mental development, too, were normal. Physical examination showed that she was normal for her race, sex, and age. There were no systemic abnormalities, and the significant findings were confined to the nails, skin, and oral mucosa.

Nail Lesions.—All the nails of the

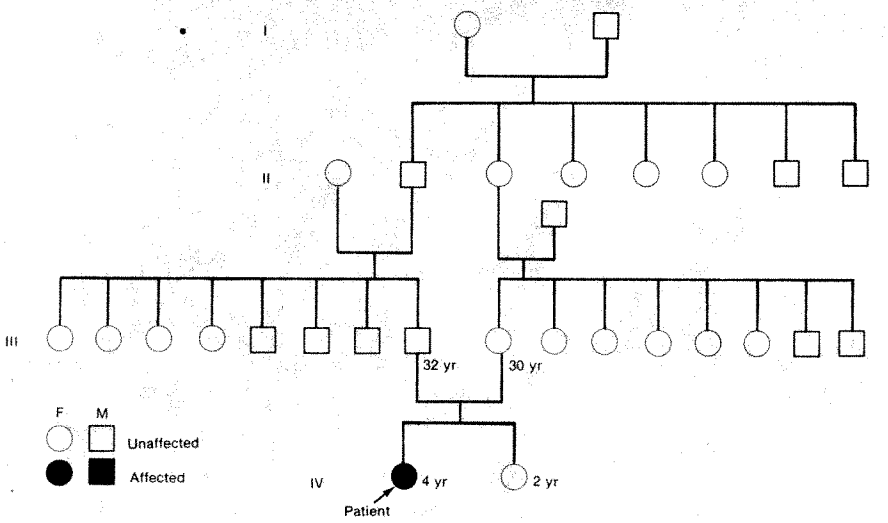

Pedigree, showing autosomal recessive transmission.

fingers and toes were markedly hyperkeratotic, deformed, and dystrophic. The affected nails appeared "pinched up," with narrowing of the lateral nail edges and upward and outward growth of the free edges. Although the nail plate was normally attached to the proximal and lateral grooves, the distal part often protruded beyond the tip of the digits and was considerably raised and arched transversely. Because of the brittleness, the free edges were often jagged and cracked, exposing the piling up of hard keratinous debris from the nail bed under the raised-up nails. Some nails, however, had the appearance of a claw-like incomplete cylinder or cone, eg, the big toes. Subungual keratoses and scars of previous infections were observed in several fingers and toes. On the sides of the toes and feet, peeling of skin from blisters and hyperhidrosis were found.

Skin Lesions.—Besides blisters and skin peeling, the plantar surface of the feet had a number of callosities or keratoderma. These were found on the sites of pressure. Her palms, however, showed mild, diffuse thickening without callus formation. On her knees, elbows, and gluteal surface were numerous follicular keratotic grayish-black papules. The horny cones in the center of these papules fit into the crater-like depressions, and removal of the cones produced points of slight bleeding. On her forehead were five to six small, asymptomatic, soft cystic lesions, and biopsy of one disclosed an epidermal cyst. The patient had no pigmentation, skin atrophy, skin tumors, or other skin lesions on other parts of the body.

Oral Lesion.—A few small patches of white mucosal lesions (leukokeratosis oris) were found in the buccal mucosa, but consent for biopsy was denied. No mucosal lesion was detected in the nose, throat, tongue, or rectum.

Her mental and physical status were normal, and no abnormalities were detected in her eyes, hair, teeth, or other major body organs.

Investigations.—Results of the hematological, urinary, and biochemical tests were all normal. A blood VDRL test was negative. No roentgenological abnormalities were found in the skull and chest. Microscopic examination of the hair did not yield any abnormal findings.

Family Study.—Four generations in this family were examined but none were found to have the features of PC. The family members were all born and bred in Western Malaysia. The patient's father (aged 32) and mother (aged 30) were first cousins. They as well as the patient's younger sister (aged 2) did not show any nail, skin, or other lesions of PC. All of them were well and healthy (Figure).

Comment.—The diagnosis of PC in this Indian girl was established by the clinical picture of the classical dystrophic nails, the presence of hyperhidrosis, plantar blisters, callosities of the soles and palms, keratosis pilaris lesions on the knees, elbows, and one buttock, the epidermal cysts on the forehead, and the leukokeratosis in the buccal mucosa. According to the classification of Kumer and Loos,[2] she belongs to the type II category of PC as she did not have the corneal lesions. Other uncommon associations with this disease but not found in this patient are hypoplastic or kinky hair, natal teeth, microphthalmos, cataract, corneal dystrophy, scrotal tongue, intestinal diverticulosis, and leukoplakia of mucosal membrane.[2-6] The rarity of this disease in Asians is not known. Lack of documentation aside, the nail and skin lesions of PC might often be mislabeled as some common local conditions unless one is aware of the disease and unless a family history is obtained. Most studies in the literature have demonstrated that PC is transmitted as a simple autosomal dominant gene with incomplete penetrance.[2-6]

The disease transmission in our patient is most likely that of the autosomal recessive trait since she was the product of a consanguineous marriage between two first cousins and both of them and the other sibling were unaffected by the disease. The other family members in the four generations too were not affected. However, PC is a very heterogenous disorder, probably involving multiple genes, and hence the possibility of a spontaneous mutation in this family cannot be entirely ruled out.

TAY CHONG-HAI, FRECP
Republic of Singapore
K. RAJAGOPALAN DDM, MRCP
Kuala Lumpur, West Malaysia

1. Jadassohn J, Lewandowsky F: Pachyonychia congenita. *Ikonograph Derm* 1:29, 1906.

2. Kumer L, Loos HO: Uber Pachyonychia (Types Riehl). *Wien Klin Wochenschr* 6:174-182, 1935.

3. Jackson ADM: Pachyonychia congenita. Report of six cases in one family. *Ann Eugen* 16:141-145, 1961.

4. Mullins FJ, Murray N, Shapiro EM: Pachyonychia Congenita: A review and new approach to treatment. *Arch Dermatol* 71:265-268, 1955.

5. Joseph HL: Pachyonychia congenita. *Arch Dermatol* 90:594-603, 1964.

6. Soderquist NA, Reed WB: Pachyonychia congenita with epidermal cysts and other congenital dyskeratoses. *Arch Dermatol* 97:31-33, 1968.

Erythema Multiforme Resulting From Insecticide Spray

To the Editor.—Recently, we have come across an interesting case, in which erythema multiforme developed in a woman 25 years of age merely a few hours after coming in contact with an insecticide, methyl parathion (Dalf) (2% fanthion), sprayed for killing bedbugs. She had multiple erythematous papulosquamous iris pattern lesions all over her body, with the greatest amount occurring over the extensor aspects of her legs, hands, chest, back, and abdomen that persisted for 20 days. She was not taking any other drugs, had not had a recent vaccination, and had no allergic reactions to food. She did not have a history of similar lesions. All the investigations were within normal limits, except for mild albuminuria and an increase in the eosinophil value. Skin biopsy specimen taken were consistent with the diagnosis of erythema multiforme. She responded well to antiallergic tablets and vitamin C.

Re-exposure to a provocative dose

of methyl parathion insecticide in the form of snuff produced similar lesions. To our knowledge, erythema multiforme produced by inhalations of insecticide, particularly Dalf, has not yet been reported.

R. K. Bhargava
Virendra Singh
Vinay Soni
Jaipur-4 (Raj), India

Pachyonychia Congenita With Cardiac Involvement

To the Editor.—A case of pachyonychia congenita with cardiac involvement has been recorded and reported. A 9-year-old girl had all the characteristic features of pachyonychia congenita. In addition, there was clinical and roentgenographic evidence of cardiomegaly, with abnormal ECG and angiographic studies. She also had a pigmented nevus in the left iris, spinabifida occulta L5, rudimentary 12th rib, sparse kinky hair over the scalp, and carious teeth.

Report of a case.—A 9-year-old girl born to consanguinous parents was brought to the Dermatology Department on Aug 18, 1974.

When her history was taken, it was noted that approximately three months after birth blisters in frictional areas started to develop. At the age of 7 months, horny follicular lesions mostly over the extremities developed. Nail dystrophy in the form of thickening and lifting up of the nail plates started at the age of 1 year. When the child started walking, blisters developed on the soles and lead to painful peeling off of the skin. At the age of 6 years carious teeth developed as did sparse kinky hair over the scalp. History was suggestive of cyanotic spells with crying that started at the age of 2 years and persisted until the age of 5 years.

On examination she was moderately nourished and slightly anemic. Dermatological examination showed sparse kinky hair over the scalp, keratoderma on the palms and soles, follicular papular lesions over the extremities, verrucous plaques over the elbows, knees, and gluteal folds, large ruptured bullae with exfoliation in both soles, and leukokeratosis in the buccal mucosa. All the nail plates were thickened with subungual hyperkeratosis and lifting up of the nail plates distally. Systemic examination showed clinical and roentgenographic evidence of cardiomegaly; the pulmonic second sound was loud and split; her pulse rate was 108 beats per minute; and blood pressure was 100/80 mm Hg.

Fluoroscopy revealed cardiomegaly. The C/T ratio was 60:40. Visible pulsations and minimal enlargement of both ventricular chambers were present. Electrocardiogram showed normal sinus rhythm, left anterior fascicular block, and nondiagnostic T wave changes anterolaterally. Though mere T wave with S-T segment changes can happen in any primary myocardial disease, the Q-S pattern in V_2 and V_3 was more in favor of a specific anamolous origin of coronary artery from pulmonary artery.

The angiography report by Dr T.J. Cherian was as follows:

> Catheter in the pulmonary artery in the AP view shows normal pulmonary artery and its branches and on recirculation the left atrium and left ventricle opacified normally. The left ventricular contraction appears to be sluggish but there was no evidence of thinning of the ventricular musculature. Aortic root injection in AP view shows both right and left coronary arteries filling normally and the right coronary artery appears to be the dominant artery. The left ventricular injection in the RAO shows a dilated left ventricle with a number of premature ventricular contractions but in the later phase ventricular contractions appear to be sluggish. The overall impression was suggestive of myocarditis.

Correction of the anemia did not improve her cardiac condition.

Comment.—This case had all the characteristic features of pachyonychia congenita as described in the literature. In addition, this case had a cardiac abnormality along with an abnormality of the left iris that to our knowledge have not been reported in the literature so far. It is worthwhile in the future to look for a cardiac abnormality in cases of pachyonychia congenita to decide whether this association we have reported is merely fortuitous or whether a cardiac anamoly might also occur in a full-fledged case of pachyonychia congenita.

S. Premalatha, MD, DD
A. S. Thambiah, FRCP, FAMS
Madras, India

Dr T. J. Cherian, physician, did the investigations and the report on the cardiac condition.

Toxic Epidermal Necrolysis in a Patient With Ovarian Carcinoma

To the Editor.—Toxic epidermal necrolysis is recognized with increasing frequency in association with an enlarging variety of other diseases and is apparently precipitated by a very wide spectrum of triggering mechanisms. Rarer but important associations have also been reported and we would like to report another example in this category of toxic epidermal necrolysis occurring in association with a systemic neoplasm.

Report of a Case.—A 66-year-old housewife had a hysterectomy for fibroids 16 years previously and had been active and well until recently when indigestion and water brash developed and she began to lose weight. Her epigastric pain was related to eating food and the pain radiated to the back and was adequately relieved by antacids. On examination, the only abnormal physical sign was an aortic systolic (grade 2) murmur.

Laboratory studies on admission revealed an ESR of 104 mm/hr, a hemoglobin value 11.4 gm/100 ml, an erythrocyte count of 3.8×10^6/liter, and a leukocyte count of 6,000/cu mm with normal differential distribution. The plasma urea value was 84 mg/100 ml. Plasma potassium was persistently low at a value of 2.8 mEq/liter. Liver function test results showed strongly positive thymol flocculation and thymol turbidity at 9 MacLagen units. The urinary protein level was 30 mg/liter of urine. No Bence-Jones protein was detected. Immunoglobin IgA and IgM values were normal, but the IgG level was raised at 21.40 gm/liter. Other investigations reported to be normal were x-ray films of the chest and abdomen, barium meal examination of the esophagus, stomach, and duodenum and findings from biopsy of the liver and biopsy of the temporal artery. Results from the bacteriological examination of the skin, nose, mouth, and sputum were all reported to be normal apart from the usual commensals. There were no lupus erythematosus cells in the blood and results from immunofluorescent tests for antinuclear, mitochondrial, and smooth muscle antibodies were all normal. Her protein-bound iodine value was within normal range at 5.6 μg/100 ml.

The patient continued to receive antacids and was about to be discharged home to await a lymphangiogram when an itchy vesicular eruption rapidly developed on the legs and trunk. Swabs taken from these sites for bacteriological culture were reported negative for *Staphylococcus aureus* and other pathogenic organisms. After several days, the skin rash developed into a blistering skin eruption that showed grouped tense clear vesicles on erythematous bases scattered over the trunk and elbows.

A provisional diagnosis of bullous pemphigoid or dermatitis herpetiformis was made at this time. A biopsy specimen was taken for histological examination and serum for immunofluorescence tests. Dapsone 50 mg twice daily was prescribed. Six days later, however, the patient's condition rapidly deteriorated. In the words of her own physician, "Her skin had come off overnight" and she was found to have the characteristic eruption of toxic epidermal necrolysis. The trunk and limbs were covered with widespread areas of erythema on which were scattered clear vesicles and bullae. Certain denuded friction sites looked like severe scalds. The patient was given prednisolone phosphate 60 mg daily and during the first week of this treatment

the skin eruption improved, fresh blisters ceased to appear, and erosions began to heal. Unfortunately, this remission was a brief one. Her hemoglobin level was found to have decreased to 7.4 gm/100 ml and the blood film showed a leuko-erythroblastic picture with lymphopenia, and marked toxic granulation of neutrophils. The erythrocyte sedimentation rate was 53 mm in one hour. Her blood urea level rose to 119 mg/100 ml.

Histological section of the blister biopsy specimen reported the following; a subepidermal bulla in which there were eosinophils, there was no acantholysis, and vasculitis was not a feature. Immunofluorescent staining of the skin biopsy specimen revealed IgG fixation along the basement membrane and considerable excess of IgG-producing cells in the dermis. Immunofluorescent tests for antibody to skin basement membrane were positive but negative to skin desmosomes.

After four weeks, she died and at necropsy the left ovary was found to be replaced by a neoplasm 5 cm in diameter. Secondary deposits were found in the para-aortic lymph nodes. Histological examination of the ovarian and para-aortic metastases confirmed a papillary carcinoma.

Comment.—An association of malignant neoplasia with vesico-bullous skin eruptions has been alleged since 1909 when a dermatitis herpitiformis-like rash appeared on a 28-year-old woman who was found two months later to have carcinoma of the labium.[1] However, a recent retrospective survey of patients who attended the Mayo Clinic failed to find any significant association between systemic malignant disease and bullous skin eruptions. The case reported here, therefore, may be no more than a rare coincidental pathological relation between an ovarian tumor and toxic epidermal necrolysis. The provocative role of dapsone cannot be excluded particularly in view of its known association with toxic epidermal necrosis.[2] The significance of this case lies in the peculiar change of form of the skin eruption. For example, an itchy erythematous rash is certainly a remarkable antecedent for toxic epidermal necrosis, whereas the late dramatic dermatological changes were more characteristic. Transitional stages of pemphigus into toxic epidermal necrosis have previously been described without the presence of a tumor.[3]

F. Charles Tring, MA, MD
Ronald E. Church, MA, MD
Sheffield, England

1. Stone SP, Schroeter AL: Bullous pemphigoid and associated malignant neoplasia. *Arch Dermatol* 111:991-994, 1975.
2. Brown SG, Ridge E: Toxic epidermal necrolysis. *Br Med J* 1:550-553, 1961.
3. Schuppli R: Zur frage der abgrenzung des Lyell syndrome. *Hautarzt* 18:518-521, 1967.

Thymus Lymphocytes of the Peripheral Blood in Patients With Alopecia Areata

To the Editor.—Previous authors have reported depression of peripheral thymus lymphocytes (T-cells) in atopic dermatitis.[1,2] Atopic dermatitis is frequently associated with another autoimmune disease, alopecia areata (AA).[3] We evaluated T-cell levels in 60 patients with AA who were between the ages of 2 and 52 years. T-cell levels in AA were compared to 51 normal controls.[4] The mean percentage of T-lymphocytes in AA was 58.9% compared with the normal control population of 74.9%. The T-cell number per cubic millimeter was 1,184 in subjects with AA, compared with the normal control of 1,461/cu mm (Table 1). The T-cell percentage and T-cell number of AA was significantly different from the controls at $P < .001$. A total of 97% of our patients with AA had depressed T-cells in the peripheral blood (Table 2). A total of 58% of the patients with AA had less than 1,200 T-cells per cubic millimeter of peripheral blood (Table 3).

Autoimmune-type endocrine diseases and autoantibodies in AA have been previously reported.[5] Depressed T-cells would also support an autoimmune process responsible for AA rather than attributing the disease process strictly to psychic stress. Further studies are in progress to correlate the levels of T-lymphocytes with other tests of immune competence, different stages of AA, ie, AA totalis and universalis, and the age of onset. These studies will indicate the usefulness of the T-cell assay in the diagnosis and prognosis of alopecia areata. Our study should stimulate the physician to consider an autoimmune origin and endocrine disease in AA.

Algie C. Brown, MD
Zbigniew L. Olkowski, MD
John R. McLaren, MD
Atlanta

Table 1.—Relative and Absolute T-lymphocyte Values in Patients With Alopecia Areata

Group	No. of Cases	Mean Relative*	Mean T-cells/cu mm
Control	51	0.75	1,461
Alopecia areata	60	0.59†	1,184†

*Ratio of T-lymphocytes to total mononuclear cells.
†Significantly different from control at $P < .001$.

Table 2.—Proportion of Patients With Alopecia Areata With Low T-lymphocyte Values Relative* to Total Mononuclear Cells

%T	Control	Alopecia Areata
≤ 0.70	3/51 (6%)	58/60 (97%)
≤ 0.60	0/51	31/60 (52%)
≤ 0.50	0/51	6/60 (10%)

*Ratio of T-lymphocytes to total mononuclear cells.

Table 3.—Proportion of Patients With Alopecia Areata With Low Absolute* T-cell Values

T-Cells/cu mm	Control	Alopecia Areata
≤ 1,200	15/51 (29%)	35/60 (58%)
≤ 1,000	6/51 (12%)	24/60 (40%)
≤ 500	0/51	2/60 (3%)

*T-lymphocytes per cubic millimeter.

1. Luckasen JR, Sabad A, Goltz RW, et al: T and B lymphocytes in atopic eczema. *Arch Dermatol* 110:375-377, 1974.
2. Carapeto FJ, Winkelmann RK, Jordon RE: T and B lymphocytes in contact and atopic dermatitis. *Arch Dermatol* 112:1095-1100, 1976.
3. Muller SA, Winkelmann RK: Alopecia areata: An evaluation of 736 patients. *Arch Dermatol* 88:290-297, 1963.
4. Olkowski ZL, Wilkins SA: T-lymphocyte levels in the peripheral blood of patients with cancer of the head and neck. *Am J Surg* 130:440-444, 1975.
5. Kern F: Laboratory evaluation of patients with alopecia areata, in Brown AC (ed): *The First Human Hair Symposium*. New York, Medcom Press, 1974.

Hypopigmentation With Punctate Keratosis of the Palms and Soles

To the Editor.—I read with interest the article entitled "Hypopigmentation with Punctate Keratosis of the Palms and Soles," by Maj Lonnie A. Cole, MC, USAF, that appeared in the July 1976 issue of the ARCHIVES (112:998-1000).

In connection with that case report, I should like to advert to an article entitled "Hereditary Sclerosing Poikiloderma" by Weary PE et al, that appeared in the October 1969 issue of the ARCHIVES (100:413-422) and that described several patients bearing striking resemblance to those reported by Dr Cole.

Although apparently differing in several respects, there seems to be sufficient clinical similarity between the patients comprising the two series to warrant critical comparison.

SAMUEL B. PRATT, MD
TOMMY B. GRIFFIN, MD
GEORGE S. STRETCHER, MD
Spartanburg, SC

In Reply.—I am indebted to Dr Pratt for pointing out to me the considerable visual similarities of my patient and those reported by Weary et al (ARCHIVES 100:413-422, 1969). In fact, the dyschromia present in any of the various poikilodermas shows some resemblance to that of my patient. However, the findings of atrophy, telangiectasia, and hyperpigmentation were completely lacking in my patient. In addition, Dr Weary's patients had sclerotic bands in their flexural areas that were absent in the patient I reported. My patient did not have more extensive involvement of the elbows and knees, clubbing of the fingers, or calcinosis cutis. Finally, the diffuse sclerotic changes in the palms and soles of Dr Weary's patients differed from the punctate keratoses of my patient. Despite the similarities, I believe there are enough differences to establish these cases as two separate entities.

LT COL LONNIE A. COLE, MC, USAF
Tampa, Fla

Iatrogenic Traumatic Purpura Masquerading as Vasculitis

To the Editor.—Palpable purpura suggests a number of disease states including necrotizing vasculitis, drug eruption, purpura fulminans, insect bite, and the progressive pigmented dermatoses. Histologically, an inflammatory infiltrate that is made up of either polymorphonuclear leukocytes or lymphocytes is often seen in a perivascular distribution. The following cases point out a further cause of palpable purpura that should be of particular interest to the hospital-based dermatologist.

Report of Cases.—Case 1.—A 76-year-old man was brought to the emergency room complaining of the abrupt onset of left-sided weakness, accompanied by stool and urine incontinence. The patient was admitted. In-hospital physical examination demonstrated an elderly, alert man with mild hypertension and left-sided hemiparesis. In addition, there were multiple, slightly palpable, well-demarcated, grouped, violaceous, nonblanching, 0.5 × 0.5-cm lesions, with a central area of hemorrhage over both lower extremities; they were more frequent on the paretic extremity. The lesions were present over the dorsa and the soles of the feet, extending to the thighs. There was an area on the left thigh where the lesions appeared in a linear distribution. There were similar purpuric lesions over the posterior upper arms bilaterally. Nonblanching erythema of the palms and soles was also noted.

Laboratory findings showed normal clotting studies. Lumbar puncture demonstrated many RBCs, and no WBCs. Lupus erythematosus preparation, antinuclear factor, and VDRL test were negative. A skin biopsy of one of the lesions showed dermal hemorrhage without evidence of vasculitis.

Further history revealed that on admission to the emergency room the sensory portion of the neurologic examination was performed with a hollow-bore needle. The initial examination was concentrated on the paretic side of the body and the lesions could be subsequently duplicated by performing the sensory examination with a No. 18- to No. 26-gauge needle. The patient's lesions gradually resolved without treatment.

Case 2.—A 31-year-old man came as an outpatient to the Dermatology Section with a two-day history of an asymptomatic eruption primarily over the left side of the body. He had noted mild paresis of the left upper and lower extremities for several months and had been evaluated in the Orthopedics Section several days earlier.

The physical examination showed multiple, 3- to 6-mm, grouped, erythematous, nonblanching, slightly palpable lesions primarily over the left side of the body. Each lesion had a hemorrhagic center. Mild weakness of the left upper and lower extremities was noted. Laboratory findings including clotting studies were within normal limits. Additional history revealed that the neurologic examination had been performed with a hollow-bore needle at the time of the previous evaluation. Subsequently, the lesions were reproduced with No. 20- and No. 26-gauge needles.

The causes of purpura are usually classified according to extravascular, vascular, or intravascular etiologies. Among the vascular etiologies, traumatic purpura is included.[1] The essentials for diagnosis include a normal hematologic workup and a history of trauma directly to the area of involvement. We are reporting a characteristic type of acquired vascular purpura, ie, traumatic purpura secondary to neurologic examination performed with a hollow-bore needle. It is important to distinguish these hemorrhagic lesions from those of necrotizing vasculitis wih CNS involvement. Both of our patients came to the dermatologist after evaluation for a neurologic deficit. Both had a grouped, or even linear distribution of their lesions, and more were noted on the affected side. In both patients, the lesions were asymptomatic and were able to be reproduced by performing the sensory portion of the neurologic examination with a hollow-bore needle. Similar lesions were produced in normal controls. The lesions uniformly resolved in five to seven days without treatment.

PAUL G. HAZEN, MD
ALLEN D. KALLOR, MD
Cleveland

1. Harrington WJ: The purpuras. *DM* July 1957.

Halotex® (haloprogin) 1% Cream/Solution stops usually

Proven in tinea pedis.

Comparative efficacy of Haloprogin and a leading topical antifungal agent in tinea pedis.[1]

	No. of Patients Treated	Improved After 27 Days Rx	Maintained Improvement 8 Days Post-Rx	P**
Clinical Improvement				
1% Haloprogin	61	56	56	N.S.
1% Tolnaftate	20	17	16	
	No. of Patients Treated	Negative After 27 Days Rx	Maintained Negative 8 Days Post-Rx	
KOH				
1% Haloprogin	62	56	50	P<0.001
1% Tolnaftate	20	12	5	
	No. of Patients Treated	Negative After 27 Days Rx	Maintained Negative 8 Days, Post-Rx	
Culture				
1% Haloprogin	52	46	41	P<0.01
1% Tolnaftate	17	11	7	

**Final cure rate comparing haloprogin and tolnaftate therapy.

Pre-Treatment | After 4 Weeks of Treatment | After 6 Weeks of Treatment

Halotex has been proven in other tineas; tinea cruris, tinea corporis, tinea manuum, and tinea versicolor.

tinea in its tracks, with one Rx.

Consider the many benefits of Halotex when you next write for a topical antifungal agent.

- **Effective: Proven against most common tinea pathogens.**
- **Proven: In 1,062 patients, only 29 reported either itching or burning associated with application.[2]**
- **Economical: Priced with patient economy in mind.**

Halotex provides controlled therapy, Rx only. It is available in both liquid and cream forms packaged in 30 g tubes for cream and in 30 ml bottles of liquid . . . adequate dosage for full treatment periods. A 10 ml bottle of liquid is available for small areas. It is a single entity product, nongreasy, nonstaining.

Halotex® (haloprogin)

1% Cream/Solution

One Rx is usually enough.

1. Carter, Vernon H.: Current Therapeutic Research, Vol. 14, No. 6, June 1972, pp. 307-310.
2. Data on file Westwood Pharmaceuticals Inc.

See next page for full prescribing information.

WESTWOOD
PHARMACEUTICALS INC.
Buffalo, New York 14213
In Canada, Belleville, Ontario K8N5E9

©1976, W.P. Inc.

Halotex®
(haloprogin)
1% Cream/Solution
Caution: Federal law prohibits dispensing without prescription.

Description: Halotex cream provides 1% haloprogin in a water-dispersible, semi-solid cream base. Each gram contains 10 mg. haloprogin solubilized in polyethylene glycol 400, polyethylene glycol 4000, diethyl sebacate and polyvinylpyrrolidone. Halotex solution provides 1% (10 mg. per ml.) haloprogin in a homogeneous vehicle of diethyl sebacate and alcohol.

Action: Halotex is a synthetic antifungal agent for the treatment of superficial fungal infections of the skin.

Indications: Halotex cream and solution are indicated for the topical treatment of tinea pedis, tinea cruris, tinea corporis and tinea manuum due to infection with Trichophyton rubrum, Trichophyton tonsurans, Trichophyton mentagrophytes, Microsporum canis, and Epidermophyton floccosum. It is also useful in the topical treatment of tinea versicolor due to Malassezia furfur.

Contraindications: Halotex preparations are contraindicated in those individuals who have shown hypersensitivity to any of the components.

Warning: USAGE IN PREGNANCY—Safety for use in pregnancy has not been established.

Precautions: In case of sensitization or irritation due to Halotex cream or solution or any of the ingredients, treatment with these preparations should be discontinued and appropriate therapy instituted.

If a patient shows no improvement after four weeks of treatment with Halotex cream or solution, the diagnosis should be redetermined. In mixed infections where bacteria or nonsusceptible fungi are present, supplementary systemic anti-infective therapy may be indicated.

For external use only. KEEP OUT OF EYES.

Adverse Reactions: Reactions reported include: (1) local irritation, burning sensation, vesicle formation, and (2) increased maceration, pruritus or exacerbation of pre-existing lesions.

Dosage and Administration: Halotex cream and solution should be applied liberally to the affected area twice daily for two to three weeks. Interdigital lesions may require up to four weeks of therapy.

How Supplied: Halotex® cream 1% (10 mg. per g.) 30 g. collapsible aluminum tube NDC 0072-7130-02.

Halotex® solution 1% (10 mg. per ml.) 10 ml. polyethylene bottle with controlled drop tip NDC 0072-7210-02 and 30 ml. polyethylene bottle with controlled drop tip NDC 0072-7230-02.

WESTWOOD
PHARMACEUTICALS INC.
Buffalo, New York 14213
In Canada, Belleville, Ontario K8N 1E2

Society Transactions

The Society Proceedings are edited by Dr Harry L. Arnold, Jr, Straub Clinic, Honolulu, HI 96813. Transactions and photographs should be sent, in duplicate, directly to him.

CHICAGO DERMATOLOGICAL SOCIETY
May 5, 1974

David F. Fretzin, MD, Recorder

Prurigo Nodularis. Presented by DAVID F. FRETZIN, MD.

A 56-year-old woman has a three-year history of a persistent pruritic eruption involving most areas of her body except the head, neck, and the anterior part of her chest. She has severe episodic pruritus at which time she scratches lesions until they excoriate and bleed. Individual lesions may gradually recede, leaving hyperpigmented macules. Pruritus seems worse in the spring "grass season" and with stress. In 1972, a clinical diagnosis of Mucha-Habermann's syndrome was suggested elsewhere, but a biopsy specimen showed only chronic psoriasiform dermatitis. Treatment in the past had consisted of long-term high doses of tetracycline, systemic corticosteroids, tranquilizers, diuretics, thyroid pills, and a variety of topical remedies, including steroid preparations. She has a past history of hay fever as a girl and sinusitis since that time. She also has occasional episodes of eczematous eruptions on her hands, legs, feet, and ears. There is a questionable history of decreased thyroid activity.

Results of physical examination show numerous discrete, firm, uniform, shiny to hyperpigmented nodules scattered evenly on portions of her trunk, arms, and legs (Figure). Some are excoriated and crusted. A scaling hyperpigmented chronic eczematous eruption is present on her ankles. A biopsy specimen of a nodular lesion shows focal hyperkeratosis and parakeratosis, as well as notable pseudoepitheliomatous hyperplasia. The papillary and upper dermis is highly vascular and associated with a primarily chronic, but focal, inflammatory reaction. Some fibrosis is present. There is exocytosis of inflammatory cells. No distinct hyperplastic nerve bundles are noted.

Discussion

DR FREDERICK MALKINSON: The only temporary success I have had has been with the use of tar preparations locally. Topical steroids are often ineffective. In some patients, the lesions are almost impossible to eradicate short of surgical removal. I have seen one patient in whom some of the nodules were excised.

DR RICHARD WINKELMANN: Do you have any comments about the relationship to atopy?

DR MALKINSON: I have seen few cases, perhaps one every year or two. I have not been impressed that most occur in patients with atopy.

DR. WINKELMANN: This patient had hay fever and has a daughter with hay fever and a niece with severe atopic dermatitis, so this is a factor to be considered. Some of the patients we have seen with prurigo nodularis have had high IgE values. Patients with prurigo nodularis have a tendency to itch based on the pharmacology, physiology, and/or immunologic and perhaps IgE reactivity of their skin.

DR WILLIAM CARO: The histology is characteristic and yet not very specific. It shows essentially a hyperplastic epithelium with irregular acanthosis with maturing keratinocytes. In the dermis is a nonspecific inflammatory infiltrate of lymphocytes and histiocytes. About ten years ago, there was some discussion in the literature by a British dermatologist on the finding of hyperplastic nerve endings in the upper portion of the dermis. He believed that this might have something to do with the extreme itching that these patients experience. I have had an opportunity to look at four or five of these cases since then and have not identified abnormal, large nerve endings. The picture is a nonspecific one, and some of these both clinically and histologically start to merge with multiple keratoacanthomas.

DR DAVID FRETZIN: Serial sections were obtained on a biopsy specimen of a lesion, and we were unable to find any large nerve bundles. The interesting thing is that most

Multiple discrete prurigo nodules on arms of patient.

textbooks report that the itching is episodic and occurs only on the lesion. However, our patient complains that she itches in areas where she does not have lesions. I am not sure whether this relates to an atopic tendency, since at times she has eczematous patches, which are obviously different from the prurigo nodularis that we see here.

DR LAWRENCE SOLOMON: Dr Winkelmann's suggestion that IgE is related to atopic dermatitis might lead one to the erroneous conclusion that IgE causes atopic dermatitis. I think the evidence is accumulating rather rapidly and convincingly that IgE may be considered as the crowd that gathers at the accident; it is not necessarily the cause of the accident (ie, dermatitis). There are patients with atopic dermatitis who do not have raised IgE levels, and there are patients with high IgE levels who do not have atopic dermatitis. There is also convincing evidence that patients with atopic dermatitis are T-cell deficient. It is entirely possible that the purpose of increased IgE levels in patients with atopic dermatitis is simply an attempt by the organism to make up for a T-cell deficiency by stimulating B cells, where such stimulation has been initiated by an appropriate antigen.

CHICAGO DERMATOLOGICAL SOCIETY
March 20, 1974

David F. Fretzin, MD, Recorder

Chronic Mucocutaneous Candidiasis, Vitiligo, Polyendocrinopathy, Pernicious Anemia: Subacute Combined Degeneration of the Spinal Cord. Presented by RUTH K. FREINKEL, MD and MICHAEL S. ASHMAN, MD.

This 34-year-old woman is being followed up for multiple endocrine and cutaneous problems. At age 4 years, the patient's diarrhea, photophobia, and growth retardation were diagnosed as attributable to idiopathic hypoparathyroidism. At age 6 years, she developed moniliasis affecting the hands, nails, mouth, and vagina, which has persisted. The patient was unavailable for follow-up, while episodes of tetany and progressive loss of vision occurred. Treatment with oral calcium and vitamin D was instituted at 12 years of age. A macrocytic anemia was detected and was treated with folic acid. Progressive neurologic symptoms compatible with subacute degeneration of the spinal cord developed at age 15 years. At age 18 years, pernicious anemia was diagnosed, and vitamin B_{12} therapy was begun. Menarche occurred at age 15, and menses ceased at 22 years of age. Decreased estrogen effect on vaginal smear was detected at this time. At age 17 years, there was sudden onset of total scalp alopecia that progressed to alopecia universalis. By age 24 years, she had extensive vitiligo. In 1971, she was examined for muscle weakness and muscle spasm, diarrhea, and parathesias in the hands. An intensive examination showed hypoparathyroidism, partial blindness with corneal vascularization and lenticular opacities, and cutaneous moniliasis. Thyroid and adrenal function were normal. No serum thyroid antibodies were detected.

She responded to treatment with intravenously administered calcium and steroids. Steroid dosage was decreased, and treatment with vitamins D and B_{12}, oral calcium, and cyclic Enovid E was maintained. Her cutaneous moniliasis continued to worsen, and she was readmitted for evaluation of her endocrine and immunologic status. Moniliasis now involved her hands, nails, tongue, and lips. While she had normal baseline cortisol levels, her adrenal reserve was diminished, as shown by a three-day adrenocorticotropic hormone stimulation test. Primary ovarian hypofunction was demonstrated by diminished urine estrogens and high urinary gonadotropins. Pituitary gland growth hormone assay was normal by insulin stress. The patient had a positive skin test to mumps antigen and was negative for *Candida*, *Trichophyton*, and purified protein derivative intermediate. Previous therapy was continued, and it was elected not to treat her skin condition. She has had a left corneal transplant, with improvement of vision. Her two brothers, mother, and father are in excellent health.

On examination, her blood pressure was 117/80 mm Hg, and her pulse rate was 78 beats per minute. She appears alert and intelligent. There is total body alopecia; her finger and toe nails are gray, dystrophic, irregularly formed, and crumbling. Vitiligo is noted around her eyes and mouth and at pressure points on her elbows, knees, hands, and fingers. There are confluent, round, erythematous, and scaling plaques on her wrist, fingers, and feet. Her right cornea is opaque, and her left cornea has a transplant. The pupils react poorly to light and in accommodation. The retina is not visualized. Her throat shows typical moniliasis, and her teeth are pointed, malformed, and brown-stained. There is gross motor weakness in her legs; the patellar reflexes are brisk, and her toes are upgoing. She has normal sensation and no Chvostek sign.

Her hemogram, serum calcium, serum phosphorus, and serum electrolyte levels; and urinalysis are normal. A chest roentgenogram is normal. A culture of scales from the dorsum of the hand grew *Candida albicans*. Her 24-hour urine excretion of 17-ketosteroids was 5.8 mg/24 hr (normal, 5 to 15 mg), and her 17-hydroxycorticosteroids excretion was 2.6 mg/24 hr (normal, 3 to 8 mg). A 24-hour urine for free cortisol was reported as 40.2 μg (normal, 20 to 100 μg). At present the patient has normal thyroid function and reserve, and normal thyroid-stimulating hormone levels. Direct and indirect immunofluorescence studies were negative for immunoglobulin and complement in her skin. Skin testing with four standard antigens was negative (*Candida*, mumps, *Trichophyton*, and streptokinase-streptodornase). The patient's lymphocytes responded normally to pokeweed mitogen and phytohemagglutinin antigen stimulation. When cultured in 20% autologous plasma, the patient's lymphocyte response to both pokeweed mitogen and phytohemagglutinin antigen stimulation was diminished, indicating the presence of circulating lymphocyte inhibitors. However, her serum did not inhibit normal lymphocytes. *Candida* antigen also could not include patient lymphocyte response in both autologous and normal allogeneic plasma. The patient's peripheral blood T- and B-lymphocyte percentages were within normal limits. The IgD-bearing B-lymphocytes were increased ten times the normal number, for reasons that are unclear. Her treatment consists of vitamin D (100,000 and 50,000 units on alternate days), Enovid E, one glass of milk a day, and vitamin B_{12} (0.1 ml intramuscularly administered every week).

Discussion

DR ALVIN ZELICKSON: It is not unusual to see immunologic problems associated with vitiligo. We have been studying these patients and trying to come up with a morphologic definition of vitiligo. It would be interesting to see if she has an increase in Langerhans cells. We have studied several cases with immunologic disorders, especially one family with an IgE problem, and in those cases we found no Langerhans cells and no melanocytes. This woman fits into the class of what I would call leukodermas that need more evaluation.

DR RICHARD WINKELMANN: I was interested that her delayed hypersensitivity tests presently seem to be normal.

DR RUTH FREINKEL: Her cutaneous sensitivity is not entirely normal since she is negative to *Candida*. Ratios of B cells and T cells are normal. However, there is a group of patients with chronic moniliasis who respond normally to the usual sort of mitogens, suggesting that their T cells have some normal receptor sites but will not respond with mitogenic activity to *Candida*. In addition to that, her serum inhibits the response of her lymphocytes to phytohemagglutinin, but does not inhibit the response of normal lymphocytes. We have not seen this patient without skin disease, since she refuses systemic treatment. Presently, we do not know if inhibition of mitogenic stimulation is related to activity of the disease. I would like to ask Dr Zelickson if this is not vitiligo in the ordinary sense of the word. Why do patients with these types of endocrine disorders and pernicious anemia develop leukoderma?

DR ZELICKSON: At our institution, Dr Katz reported a series of cases associating pernicious anemia with vitiligo. The question he was concerned with is: If someone has vitiligo is he predisposed to these other

problems? The question I ask is how do we know this is vitiligo? Some believe that anyone who has gray hair has vitiligo. There will be a certain group that has a definite relationship to immunologic problems and others that have no relationship whatsoever. Also some of these patients tend to repigment well with the psoralens, whereas others do not.

DR WINKELMANN: What I find confusing about this group of interesting polyendocrinopathies with candidiasis is that they can occur at various ages, but they all seem to be related to delayed hypersensitivity dysfunction. There are half a dozen cases in the literature where erythroderma and lack of thymus function is apparently the reason for *Candida* overgrowth, and this patient seems to be at the other end, where the polyendocrinopathies occurred from either some congenital problem like the Sipple syndrome or from some kind of inflammatory attack on the organs.

DR H. BURSTEIN: This patient shows impaired cellular immunity and cutaneous anergy as seen in chronic mucocutaneous candidiasis, thymoma, and myopathy. The four cases of this triad reported to date were also women, but were more than 50 years of age when cutaneous lesions developed. Thymectomy was performed 14 years ago on my patient, but her candidiasis has persisted. In a recent letter, she mentioned improvement of her skin the past year after treatment with intensive oral vitamin E in addition to multivitamin tablets.

CHICAGO DERMATOLOGICAL SOCIETY
October 1974

DAVID F. FRETZIN, MD, Recorder

Pustular Psoriasis in a Child. Presented by MARSHALL BLANKENSHIP, MD.

A 2½-year-old boy was born in May 1972 after a normal pregnancy and delivery. The mother was taking a diuretic three weeks prior to delivery. There was mild jaundice and hyperbilirubinemia 12 hours after birth that was most likely due to polycythemia. He received ultraviolet light treatments, and the jaundice cleared within one week. Within the first month of life, he developed erythema and scaling on his neck and diaper area. The eruption became generalized and has continued with short remissions and exacerbations. At times there are severe acute flares with superficial pustules and a febrile state. There has always been dystrophy of the nails. He has failed to gain weight, but pediatric examinations have found no evidence of any other disease process. He has not had diarrhea or other gastrointestinal symptoms. Results of a biopsy elsewhere were consistent with psoriasis. Topical steroids have produced symptomatic improvement but have not altered the clinical course. Oral antibiotics have no definite effect. Our biopsy was consistent with psoriasis.

Discussion

HAROLD PERRY, MD: Small discrete pustules clustered in serpiginous erythematous plaques are present on the palms, and less distinctly over the trunk. The biopsy specimen showed the pustular reaction of Kogoj that I associate with pustular psoriasis. This child is quite young to have pustular psoriasis of Zumbusch. There are any number of insults that tend to aggravate the disease. Streptococcal infections, superimposed contact reactions, sun exposure, and trauma to the skin in some way precipitate an exaggerated pustular reaction. The presence of recurrent fever in patients with pustular psoriasis and the alteration of the calcium levels are things one must evaluate. Pustular psoriasis is a cyclical disease; there will be exacerbations but there will also be remissions. I would treat this child gently with topical steroid creams and wet dressings as required; perhaps some tar and light (the Goeckerman program). Severely toxic chemotherapeutic agents should generally be avoided. I would avoid methotrexate in a child of this age. Under most circumstances, the cutaneous reaction eventually will wane following topical treatment. The child will be able to live with this disease. A major problem is to omit any treatment that will precipitate irreversible physiologic changes.

ALLEN LORINCZ, MD: Occasionally a patient with pustular psoriasis responds to sulfapyridine or sulfone therapy. This might be worthwhile, particularly if the systemic illness is life threatening.

WILLIAMS CARO, MD: Both the histopathologic and the clinical pictures are good for pustular psoriasis. I did not see in the protocol whether the investigators had checked for the possibility of candidal infection. Some of the lesions were somewhat circinate in configuration, with heaped up, almost rupial appearance. Although such a lesion can appear in psoriasis, it also can be a hallmark of an early candidal granuloma. Testing for candidal infection with cultures and a PAS stain on the biopsy might give additional information.

WILLIAM RUSSELL, MD: There is support for the concept of streptococci as etiologic factors in some cases of psoriasis. Antistreptolysin titers have been significantly elevated in psoriatic patient populations. This has been interpreted as indicating possible increased susceptibility to streptococcal infections in HL-A13 patients.[1] Clinically, evidence has been presented implicating a relationship of HL-A13 psoriatic patients with antecedent streptococcal infections.[2] Tissue typing may be of value in this patient. I would also be aggressive with serial antistreptolysin O and streptozyme titers, as well as repeated throat cultures for upper respiratory infections. Resumption of prophylactic antibiotic therapy is also a consideration.

ADOLPH ROSTENBERG, MD: What are you going to do with this boy in a few years when he becomes of school age? Dr Rothman used to say "psoriasis does not destroy life, it merely ruins it." It's easy to be complacent and treat patients on the safe side because you sleep better that way, but you may not be making the best decision for the patient. If this boy were of school age, or older, one would have to be more aggressive. You have to take chances so that this child may lead a more or less normal life.

RICHARD WINKELMANN, MD: An article in the ARCHIVES in 1974 summarized the cases of 47 children with pustular psoriasis. The authors pointed out that this annular form has a recurrent course and a better prognosis, and I hope that this patient will fall into the category of their favorable cases and not require the intensive therapy that might be proposed. We've used tar in massive amounts in many patients with psoriasis almost on a yearly basis for many years, and we have never seen a substantial problem.

MARSHALL BLANKENSHIP, MD: The clinical course has been one of exacerbations and remissions, and thus far the treatments have not shortened or prevented the flares. The patient was placed on sulfapyridine at the Mayo Clinic, and there was no change. His condition exacerbated at one time with topical tars, and the mother will not use tars again. Dr Gerald Weinstein agreed that methotrexate was not indicated at present. When he has acute exacerbations, he often has a fever, but I cannot determine whether he has had an infection that causes the pustules and erythema or whether the acute changes produce the febrile state. Antibiotics given prophylactically have never changed the course, shortened the flares, or reduced the fever. He does much better in the summer. I will try ultraviolet-light therapy alone initially, and then maybe I can slowly get his mother to accept the use of a mild tar preparation.

References

1. Bertrams J, Lattke CL, Kuwert E: Correlation of antistreptolysin-O titer to HL-A13 in psoriasis. *N Engl J Med* 291:631, 1974.
2. Krain LS: Histocompatibility antigens: A laboratory and epidermiologic tool. *J Invest Dermatol* 62:67-73, 1974.

Familial Macular Amyloidosis Masquerading as Incontinentia Pigmenti. Presented by ANA M. ENG, MD.

A 41-year-old man was admitted for evaluation of his cardiopulmonary status because of progressive shortness of breath. Pulmonary stenosis with cardiomegaly was diagnosed in 1963. He has had diabetes mellitus since 1957, controlled with 40 units of isophane insulin suspension. An asymptomatic, generalized hyperpigmentation on his trunk has been present since childhood, not preceded by blisters or verrucous changes. Two sisters, two brothers, and a paternal uncle have diabetes mellitus. One

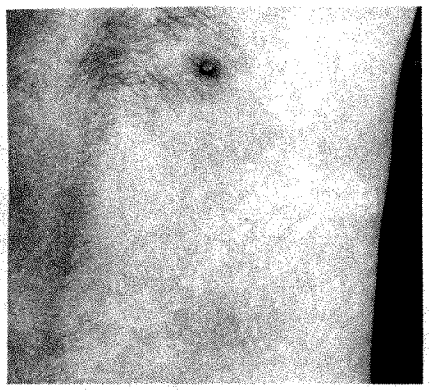

Fig 1.—Swirling pattern of hyperpigmentation and hypopigmentation on left flank.

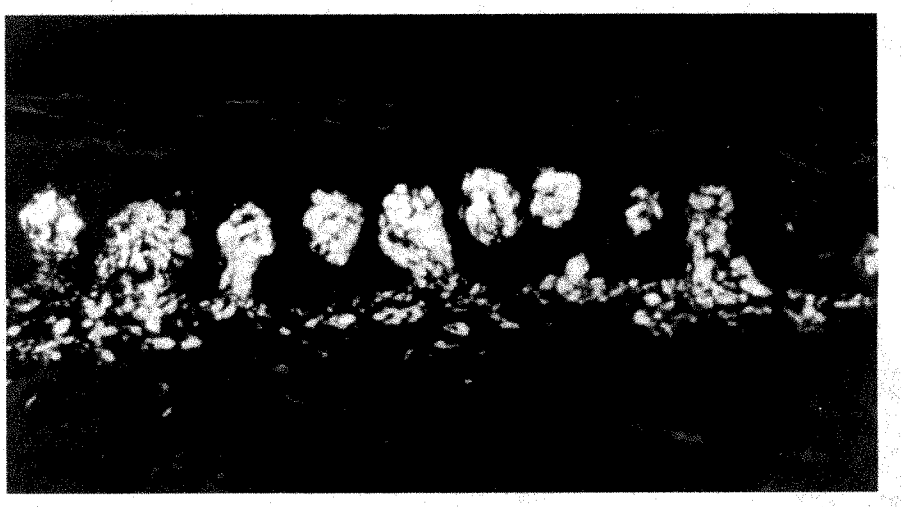

Fig 2.—Thioflavin T preparation with polarization demonstrating amyloid in papillary dermis.

of the sisters has similar skin manifestations, diabetes, and cardiomegaly of unknown cause. The daughter of this sister has been deaf since birth.

Physical examination results showed a systolic murmur at the second intercostal space. His skin showed generalized hyperpigmentation with hypopigmented 2- to 5-mm macules on the trunk. Hypopigmented whorls and swirls were present on the left lateral trunk. Biochemical screening tests were normal except for an LDH of 300 IU/liter. Chest x-ray film revealed a reticulonodular pattern suggestive of chronic fibrosis. Results of pulmonary function tests suggested alveolar-capillary block. An electrocardiogram showed sinus bradycardia, right ventricular hypertrophy, and right atrial enlargement. On cardiac catherization, there was evidence of moderate pulmonic valvular stenosis and normal left and right ventricular function. A lung biopsy demonstrated interstitial fibrosis with a suggestion of amyloidosis. Skin biopsy specimens from the patient's hyperpigmented areas showed amyloid in the papillary dermis with increased melanin in the epidermal cells. Biopsy specimens from hypopigmented spots on his left trunk and back showed amyloid in the papillary dermis with melanin incontinence. Skin biopsy specimens from the sister also revealed amyloid in the papillary dermis. The patient's pulmonary status was improved on a regimen of 30 mg of prednisone a day.

BERNARD ACKERMAN, MD: When I saw this patient, I did not think instinctively of macular amyloidosis. I saw the hematoxylin-eosin-stained slide very briefly. The one glance that I had of this case of apparent macular amyloidosis showed homogeneous eosinophilic material in the papillary dermis, but one has to be careful about making a diagnosis in difficult cases such as this without confirmation by special stains such as crystal violet, Congo red, or polarization of thioflavin T. I think that lichenoid amyloidosis is simply macular amyloidosis with superimposed lichen simplex chronicus.

DR WINKELMANN: As I read through this protocol, I did not see any evidence of staining for iron or effort to look at the liver function. Here is a young patient with diabetes and pigmentation, and I think we should look aggressively rather than passively. I would agree that a possibility of some secondary degenerative change like amyloid in the skin might exist. What is the evidence that the family has amyloid?

DR ANA ENG: My initial impression was that of a pigmentary disorder. I agree that clinically it is very difficult to make a diagnosis of amyloidosis on this patient, because the lesions are not typical. The clinical features of this case are expressed as an apparently normal but hyperpigmented skin, some areas of which are dotted with hypopigmentation (Fig 1). The histologic features consist of small amyloid deposits in the dermal papilla, which might be overlooked by hasty observation. These deposits stain positively with thiofavine T (Fig 2) and appear as amyloid fibers on ultrastructural studies.

A similar report of cutaneous amyloidosis manifested by "dyschromia" is reported.[1] Our case is unique because of (1) the amyloid deposits generalized throughout the body; (2) the familial nature of the disease; and (3) the presence of pulmonary and probably pancreatic involvement. Internal or systemic involvement of amyloidosis may be discovered by doing a skin biopsy on apparently normal-appearing skin and looking for amyloid deposits in the dermal papillae.

An interesting finding in our patient is the marble cake-like whorls of hypopigmentation on his flank. A biopsy specimen from this area was no different from the hyperpigmented and hypopigmented areas on the rest of his body. The hyperpigmented areas show increased melanin deposits in the epidermis with amyloid globules in the papillae. The hypopigmented areas show melanin incontinence in the dermis in addition to the amyloid deposits. The amount of amyloid appears directly proportional to the amount of dermal incontinence. On his flank the pattern is similar to incontinentia pigmenti or incontinentia pigmenti achromians or a nevoid abnormality. Perhaps there is a genetically or embryologically predisposed site at the flank for pigment incontinence to occur in a swirl pattern. Recently, Black and Maibach reported a case of amyloidosis masquerading as a nevoid abnormality resembling our case.[2]

LAWRENCE SOLOMON, MD: A patient may have two problems, as I think this patient does. There may very well be deposits of amyloid in the hyperpigmented areas. By no stretch of the imagination, however, can the term "incontinentia pigmenti" be applied to this patient's problem in order to encompass everything we see. Even the entity incontinentia pigmenti achromians does not apply appropriately to the hypopigmented areas. We have seen a number of patients, and others have been reported, in which large hypochromic areas are associated with mental retardation. Even in these patients the terminology is confused, although some have been called incontinentia pigmenti achromians. Nevus achromicus appears at birth, and an attentive nurse can usually identify the affected areas in the newborn infant. The hypopigmented areas in these nevi are not really achromic or vitiliginous. Pigment is usually present in reduced quantity. These hypochromic areas tan in the summer but usually not to the same degree as the surrounding skin. To sum up, I believe this patient has hypochromic nevus which has been caught up in a process resulting in the deposit of amyloid. Therefore, one should consider the patient as suffering from two problems: hypochromic nevus and hyperpigmentation with deposits of amyloid.

References

1. Takafuni M: A clinical variety of primary localized cutaneous amyloidosis characterized by dyschromia. *Jap J Dermatol* 80:43-48, 1970.
2. Black MM, Maibach HI: Macular amyloidosis simulating naevoid hyperpigmentation. *Br J Dermatol* 90:461-464, 1974.

Look closely at these patients. Their dermatologist had them on a KOMEX®/KOMED® regimen.

Step 1 KOMEX®

"...toward keeping the skin meticulously clean...to decrease the usually concomitant oiliness."[1]

Cleanses thoroughly yet gently.

The detergent cleansing effect of Komex acne cleanser is uniquely enhanced with mild dissolving sodium borate particles (Scrubules) for effective yet gentle cleansing of the skin. Komex removes surface debris. Clears comedones. Cleans clogged pores. Unplugs hair follicles. And removes oils.

Mild abradancy won't damage skin.

"A frequently overlooked source of excessive friction is the practice of vigorous scrubbing in an attempt to wash acne away. The use of brushes and other scrubbing techniques can induce significant inflammatory lesions...Elimination of sources of excessive friction lead to rapid improvement[2]

The patented Komex Scrubules enable doctor and patient to control particle dissolution from 0-60 seconds, depending on water dilution. Acne patients can't overabrade with Komex. A significant exclusive.

Conditions the skin.

In fact, the skin *conditioning* effect of Komex acne soap is truly phenomenal. You can detect some of it in the patient photos. But it really must be seen – and felt.

Step 2 KOMED®

"...to peeling of the skin so that the follicular orifices are kept open."[1]

Employs a non-comedogenic form of sulfur.

Komed Lotion works beautifully with Komex.
"The sovereign remedy in the topical management of acne vulgaris is sulfur."[3]
"Sulfur...still the most effective remedy...In addition ...salicylic acid and other peeling chemicals are used in cosmetically elegant lotions..."[4]
The exclusive Komed formulation keeps skin dry and desquamating with salicylic acid and *non-comedogenic* sodium thiosulfate.

"Suspensions and creams containing elemental sulphur were shown to be capable of inducing comedones in the rabbit ear and on human backs."[5]

Has "excellent patient appeal."

"All of the patients liked the fact that (Komed) dries quickly to an invisible film...the female patients found that the lotion did not interfere with the use of non-oily cosmetics. Male patients also appreciated the lack of a masking effect, the absence of staining properties, and the fact that the lotions blend with natural skin tone."[6]

KOMEX®/KOMED®
Classical topical therapy. Still the effective treatment for mild acne.



Barnes-Hind Pharmaceuticals, Inc.
895 Kifer Road, Sunnyvale, California 94086

1. Domonkos AN: Andrews' diseases of the skin. 6:257, Saunders: Philadelphia, 1971
2. Leyden JJ: Antibiotic resistant acne. Cutis 17:593, 1976
3. Frank L: Active oxygen in acne therapy. Cutis 1:306, 1965
4. Domonkos AN: Andrews' diseases of the skin. 6:257-258, Saunders: Philadelphia, 1971
5. Mills OH Jr, Kligman AM: Is sulphur helpful or harmful in acne vulgaris? Br J Derm 86:620, 1972
6. Sewell JW Jr: Therapeutic and cosmetic advantages of a nonpigmented acne lotion. Cutis 1:475-476, 1965

Dermatology Section, AMA Annual Convention, San Francisco, June 18-22, 1977.—The Dermatology Section will include five courses, including cosmetics in dermatology, cutaneous surgery for the dermatologists, refresher dermatopathology, "live" case presentations for dermatologists, and dermatology for nondermatologists.

In addition, there will be a symposium on the practice and progress in sexually transmitted diseases, symposium on sunlight and skin, pros and cons, symposium on management of common dermatoses. Also, there will be 34 general papers on dermatological subjects. A no-host cocktail party will be held at the Fort Mason Officers' Club on Sunday evening, 6:00 to 8:00 PM, June 19, 1977.

The Program Director for the above meeting is Dr George W. Hambrick, Jr, University of Cincinnati Medical Center, 231 Bethesda Ave, Cincinnati, OH 45267. For information contact Robert J. McNamara, MD, 2828 Telegraph Ave, Berkeley, CA 94705.

Pediatric Dermatology.—On July 27-29, 1977, The Given Institute of Pathobiology, Aspen, Colo, will be giving a course in pediatric dermatology. This course is the second scientific meeting of the Society for Pediatric Dermatology, Inc, and is cosponsored by the Office of Postgraduate Medical Education of the University of Colorado School of Medicine. It is intended as an advanced seminar in pediatric dermatology, with didactic sessions, scientific papers, a "case of the year" session, clinicopathologic conferences, and a treatment panel.

Guest faculty include Robert A. Briggaman, MD, University of North Carolina; Blaise E. Favara, MD, The Children's Hospital, Denver; Loren E. Golitz, MD, University of Colorado; Elson B. Helwig, MD, Armed Forces Institute, Washington, DC; James T. Kushner, MD, University of Utah; Kenneth H. Neldner, MD, University of Colorado. In addition, eminent participating members of the Society are as follows: Nancy B. Esterly, MD, Michael Reese Medical Center, Chicago; Sidney Hurwitz, MD, Yale University; Alvin H. Jacobs, MD, Stanford University; Michael Jarratt, MD, Baylor University; James Rasmussen, MD, State University of New York at Buffalo; Lawrence Solomon, MD, University of Illinois; Samuel Weinberg, MD, New York University.

Registration fee is $125, including a nonrefundable administrative charge of $25. Colorado physicians and members of the Society for Pediatric Dermatology are cordially invited to attend for $100.

(A general dermatology meeting follows this meeting through Sunday, July 31. If interested in receiving a program for both meetings, please so indicate.)

Credit is approved for American Medical Association Category I. For further information, contact the Office of Postgraduate Medical Education, University of Colorado School of Medicine, 4200 E Ninth Ave, Denver, CO 80262, or call (303) 394-5241.

Annual Scientific Session.—The West Coast Allergy Society will hold its 16th annual Scientific Session, Dec 14-17, 1977, at the Camelback Inn, Scottsdale, Ariz. For further information, contact Robert L. Cutter, MD, Program Chairman, West Coast Allergy Society, 5210 SW Corbett Ave, Portland, ORE 97201.

Clinical Center Study of Patients With the Sézary Syndrome.—The cooperation of physicians is requested in the referral of patients with the Sézary syndrome (erythroderma, diffuse lymphocytes with cerebriform nuclei, and membrane properties of T cells) for a study being conducted by the National Cancer Institute at the Clinical Center, National Institutes of Health, Bethesda. For the purposes of this investigation, patients should have an abnormal lymphocyte count greater than 15,000 cu mm. Operative reports, pathology reports, and slides should be forwarded for review.

Patients will receive a complete evaluation of their neoplasm and their overall immune status. They may be considered for systemic chemotherapy if appropriate for the patient's stage of disease. This will require long-term follow-up in collaboration with the referring physicians.

A summary of the work-up, findings, and ultimate disposition will be sent to the referring physician.

Physicians interested in having their patients considered for admission may write or telephone: Dr Samuel Broder, Bldg 10, Rm 4N115, National Institutes of Health, Bethesda, MD 20014 (telephone: [301] 496-6653) or Dr Richard Fisher, Bldg 10, Rm 12N226, National Institutes of Health, Bethesda MD 20014 (telephone: [301] 496-4916).

DESCRIPTION

Synalar® (fluocinolone acetonide) has the
6α, 9α-difluoro-16α-hydroxyprednisolone-1

Synalar® Solution 0.01%—contains 0.01% fl
acetonide in propylene glycol with citric

Synalar® Ointment 0.025%—contains 0.02
acetonide in white petrolatum.

Synalar-HP® Cream—contains 0.2% fluoci
in a water-washable aqueous base of ste
alcohol, mineral oil, propylene glycol, sorl
stearate, polyoxyethylene sorbitan monos
citric acid, with methylparaben and prop
preservatives.

Synemol™ (fluocinolone acetonide) has th
6α, 9α-difluoro-16α-hydroxyprednisolone-1

The vehicle is a water-washable aqueous
stearyl alcohol, cetyl alcohol, mineral oil,
sorbitan monostearate, polyoxyethylene
stearate and citric acid.

INDICATIONS

For relief of the inflammatory manifestatio
steroid-responsive dermatoses.

CONTRAINDICATIONS

Topical steroids are contraindicated in vc
varicella.

Topical steroids are contraindicated in th
history of hypersensitivity to any of the com
preparation.

Synalar-HP Cream should not be used on
years of age.

PRECAUTIONS

If irritation develops, the product should b
appropriate therapy instituted.

In the presence of an infection the use of
antifungal or antibacterial agent should b
favorable response does not occur promp
steroid should be discontinued until the in
adequately controlled.

If extensive areas are treated or if the occl
used, the possibility exists of increased syst
of the corticosteroid and suitable precaut
taken.

Although topical steroids have not been re
adverse effect on pregnancy, the safety o
pregnant females has not absolutely bee
Therefore, they should not be used extens
patients, in large amounts, or for prolonge

Topical steroids are not for ophthalmic use

Synalar-HP Cream should not be used for
and the quantity per day should not exce
formulated material.

ADVERSE REACTIONS

The following local adverse reactions hav
with topicalcorticosteroids: burning, itchin
dryness, folliculitis, hypertrichosis, acneform
hypopigmentation.

Synalar Cream and Ointment, Synemol C

The following may occur more frequently
dressings than without such therapy: mace
secondary infection, skin atrophy, striae, m

HOW SUPPLIED

Synalar® (fluocinolone acetonide)
Cream 0.025%—15, 60 g tubes; 120, 425 g
Cream 0.01%—15, 45, 60 g tubes; 120, 425
Ointment 0.025%—15, 60 g tubes; 425 g jar
Solution 0.01%—20, 60 cc plastic squeeze
Synalar-HP® (fluocinolone acetonide) 0.2%
tubes
Synemol™ (fluocinolone acetonide)
Cream 0.025%—15, 60 g tubes

These preparations are available on presc

SYNTEX
SYNTEX LABORATORIES, INC.
PALO ALTO, CALIFORNIA 94304

INFLAMMATION OF
CONTACT DERMATITIS

SOLVED

SYNALAR® TOPICALS

FLUOCINOLONE ACETONIDE

or the [illegible] ne hello...

ACNAVEEN® BAR

Soothes and cleans sensitive skin, and helps bring their guards down...

Hiding their embarrassment compounds the misery. Incessant picking and rubbing of acne lesions often causes more irritation. Urge them to wash with soap-free ACNAVEEN® Bar, logical adjunctive therapy in whatever treatment you've chosen:

- 2% salicylic acid and 2% sulfur provide a peeling and drying effect.
- Aveeno Colloidal Oatmeal soothes the skin and reduces irritation.

ACNAVEEN® BAR: Special mild cleansing bar for acne.

Available in 3.5 oz. bars

Cooper Cooper Laboratories, Inc., Wayne, New Jersey 07470

Obviously, efficacy is foremost in your mind when you recommend a therapeutic shampoo. And efficacy, coupled with cosmetic acceptability, usually guarantees a successful therapeutic course.

That's why Head & Shoulders is so highly regarded in the treatment of dandruff.

Clinically effective

For years, Head & Shoulders has proved effective in the treatment of dandruff—whether for initial therapy or long-term control. And now, research shows that Head & Shoulders is effective in the treatment of seborrheic dermatitis.*

Cosmetically pleasing

Head & Shoulders lathers well, has a pleasant odor and appearance, and need not be left on the scalp for an extended period of time. Also, it leaves hair clean, manageable, and attractive.

Head & Shoulders®

You'll like it for its therapeutic benefits. Your patients will like it for its cosmetic appeal.

*Orentreich, N.: A clinical evaluation of two shampoos in the treatment of seborrheic dermatitis, J. Soc. Cosmet. Chem. 23:189 (March 3) 1972.

© 1974 Procter & Gamble HSS-6

Now, m jor
the lice infestation.

advance to break reinfestation cycle.

Kills lice that remain on upholstery, bedding, carpeting...that may reinfest the patient or infest his family.



R&C Spray™ INSECTICIDE

with synergised pyrethrins and gamma benzene hexachloride

Pediculi and their ova can survive (for a short time) off the human host. Thus, even though the patient may have been successfully disinfested of lice on his person, immediate reinfestation is possible or a fresh infestation of other family members may occur.

To help break this infestation/reinfestation cycle, *when washing or dry cleaning is not possible,* R&C Spray can be applied to upholstery, bedding, carpeting and other objects where lice and their eggs are known to linger.

R&C Spray is specially formulated with synergised pyrethrins to provide effective parasite control. "Pyrethrins are exceptionally rapid in their effect upon insects...."[1] The other important active ingredient is gamma benzene hexachloride which, as a pediculicide, has been shown to be virtually 100% effective.[2]

After you have prescribed a specific for parasites on the scalp or body, complete the regimen with the specific for parasites off the body with R&C Spray Insecticide.

Caution: Not for use on humans or animals. Avoid spraying in eyes. May be absorbed through skin. Avoid breathing spray mist. Avoid contact with skin. In case of contact, wash immediately with soap and water. Avoid contamination of feed and foodstuffs. Harmful if swallowed. Vacate room after treatment and ventilate before reoccupying. **References: 1.** Osol, A. and Farrar, G.E., eds., *United States Dispensatory,* Philadelphia, J. B. Lippincott Co., 25th edition, 1960, p. 2012. **2.** *Patient Care* 7:94, Nov. 1, 1973.

Reed & Carnrick/Kenilworth, N.J. 07033

R&C Spray. Keeps lice from making a comeback.

INDEX TO ADVERTISERS

A

Abbott Laboratories 548-549
Ayerst Laboratories 556-557

B

Barnes-Hind Pharmaceuticals 696-697

C

Ciba Pharmaceuticals 566-567
Cooper Laboratories, Inc. 700

D

Dermik Laboratories 561, 674
Dista Products Company 545
Doak Pharmacal Company 563
Dorsey Laboratories 671-672

G

General Medical Company 565

H

Herbert, G.S., Laboratories, Division of Allergan Pharmaceuticals 575

J

Johnson & Johnson ..... 706–3rd Cover

L

Lederle Laboratories, Division of American Cyanamid Company 560A-560B, 576-577

N

Neutrogena Corporation 564-565

O

Owen Laboratories, Inc. 547

P

Parke-Davis & Company 554-555, 568-569, 704
Plenum Publishing Corp. 564
Procter & Gamble Company 701
Purdue Frederick Company 673

R

Reed & Carnrick 702-703
Remedco Analytical Laboratory 564
Riker Laboratories, Inc. 680
Roche Laboratories, Division of Hoffmann-LaRoche, Inc. 660-661
Roerig, J.B., Company Division of Pfizer, Inc. 678-679

S

Schering Corporation 570-572,705
Squibb, E.R., & Sons, Inc. 580-581
Stiefel Laboratories, Inc. 572-574, 662, 681-682
Syntex Laboratories, Inc. 558-560, 698-699

U

Upstate Medical Center 572

W

Westwood Pharmaceuticals, Inc. 2nd Cover, 551, 553, 578-579, 582, 690-692, 4th Cover

While every precaution is taken to insure accuracy, we cannot guarantee against the possibility of an occasional change or omission in the preparation of this index.

Schering

When it's all you want, it's all they get.

pure and simple

Chlor-Trimeton® 12mg.

brand of
chlorpheniramine maleate, USP

Repetabs® Tablets, brand of repeat-action tablets

Available on prescription only.

Also available:
Chlor-Trimeton®
8 mg. Repetabs®
Injection 100 mg./ml.
and 10 mg./ml.

Copyright © 1977, Schering Corporation. All rights reserved.

SWW-9340

The seven most important reasons to prescribe a topical antifungal. Right at your fingertips.

1 It is effective against the most prevalent fungal pathogens. MicaTin brand miconazole nitrate 2% offers exceptional effectiveness against the most difficult-to-treat pathogen—*Trichophyton rubrum*, and is equally effective against *Trichophyton mentagrophytes, Epidermophyton floccosum, Candida albicans* and *Malassezia furfur.*

2 It clears the most common fungal infections. MicaTin provides outstanding clinical and mycological efficacy in tinea pedis,* tinea corporis* and tinea cruris* as well as candidiasis and tinea versicolor.

3 It relieves symptoms quickly. Within 72 hours for the majority of patients. Within 1 to 2 weeks for virtually all patients.

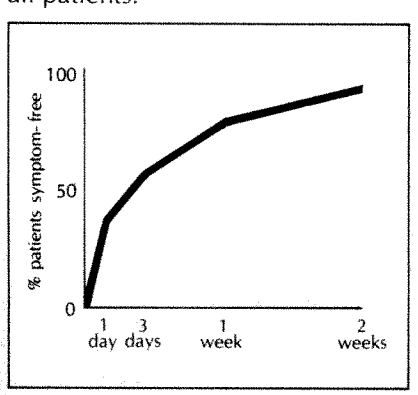

4 It demonstrates effectiveness in extensive studies. Clinical studies† demonstrate the outstanding success rate of MicaTin in the treatment of tinea pedis, tinea corporis and tinea cruris, when used with the recommended dosage of twice daily for one month. At the end of therapy, 88—94% of the patients were clinically clear.

The clinical studies of patients with candidiasis and tinea versicolor are equally impressive. Nine out of ten patients with candidiasis or tinea versicolor were clinically and mycologically clear within two weeks—the recommended duration of treatment.

Pathogen	Infection	Conversion KOH	Culture	Clinical Clearance or Improvement
Trichophyton rubrum	Tinea pedis	82%	86%	88%
Trichophyton mentagrophytes / *Epidermophyton floccosum*	Tinea corporis / Tinea cruris	93%	90%	94%
Candida albicans	Candidiasis†	92%	86%	88%
Malassezia furfur	Tinea versicolor	89%	—	92%

5 Its low relapse rate promises an outstanding chance of cure. To prove how effective MicaTin really is in keeping fungal infections clear, we evaluated these same patients one month later (median).† Of the 121 patients who were clear of tinea pedis, tinea corporis and tinea cruris at the end of treatment *and* were available for follow-up, 92% showed no clinical or mycological recurrence of the original infection.

And of the 34 patients cleared of cutaneous candidiasis *and* available for follow-up, 91% were still clear two weeks later (median).

6 It has a low incidence of side effects. Reports of "burning" sensation, irritation and maceration with MicaTin have been few and isolated. Naturally, it should not be used in patients with known hypersensitivity to any of its ingredients.

7 It is economically priced. The retail price of MicaTin is usually lower than that of other prescription antifungals.

Introducing new
MicaTin Lotion
brand miconazole nitrate 2%
12 ml. and 30 ml. bottles
MicaTin cream
brand miconazole nitrate 2%
new 85 g. (3 oz.) tube
and familiar 1 oz. and 15 g. sizes

Description: MicaTin brand miconazole nitrate cream 2% and lotion 2% each contain miconazole nitrate‡ 2%, formulated into a water miscible base consisting of pegoxol 7 stearate, peglicol 5 oleate, mineral oil, benzoic acid, and butylated hydroxyanisole.

Actions: Miconazole nitrate is a synthetic antifungal agent which inhibits the growth of the common dermatophytes, *Trichophyton rubrum, Trichophyton mentagrophytes,* and *Epidermophyton floccosum,* the yeast-like fungus, *Candida albicans,* and the organism responsible for tinea versicolor *(Malassezia furfur).*

Indications: For topical application in the treatment of tinea pedis (athlete's foot), tinea cruris, and tinea corporis caused by *Trichophyton rubrum, Trichophyton mentagrophytes,* and *Epidermophyton floccosum,* in the treatment of cutaneous candidiasis (moniliasis), and in the treatment of tinea versicolor.

Contraindications: MicaTin has no known contraindications.

Precautions: If a reaction suggesting sensitivity or chemical irritation should occur, use of the medication should be discontinued.

For external use only. Avoid introduction of MicaTin brand miconazole nitrate cream 2% and lotion 2% into the eyes.

Adverse Reactions: There have been isolated reports of irritation, burning, and maceration associated with application of MicaTin.

Dosage and Administration: Sufficient MicaTin cream should be applied to cover affected areas twice daily (morning and evening) in patients with tinea pedis, tinea cruris, tinea corporis, and cutaneous candidiasis and once daily in patients with tinea versicolor. It is preferable to use MicaTin lotion in intertriginous areas; if the cream is used, it should be applied sparingly and smoothed in well to avoid maceration effects.

Early relief of pruritus (first week) and early clinical improvement (one to two weeks) have been seen in treatment of infections caused by common dermatophytes. Even though clinical improvement may be seen fairly soon after treatment is begun, *Candida* infections should be treated for two weeks and dermatophyte infections for one month in order to reduce the possibility of recurrence. If a patient shows no clinical improvement after a month of treatment, the diagnosis should be redetermined. Patients with tinea versicolor usually exhibit clinical and mycological clearing after two weeks of treatment.

How Supplied: MicaTin brand cream 2% containing miconazole nitrate at 2% strength is supplied in 1 oz., 15 g., and 3 oz. tubes. MicaTin brand lotion 2% containing miconazole nitrate at 2% strength is supplied in polyethylene squeeze bottles in quantities of 12 and 30 ml.

*When infecting organisms are *Trichophyton rubrum, Trichophyton mentagrophytes* and *Epidermophyton floccosum.*

†Data for tinea pedis is based on 4 weeks' therapy in 138 patients; for tinea cruris and tinea corporis—4 weeks' therapy in 50 patients; for tinea versicolor—2 weeks' therapy in 38 patients; for candidiasis—2 weeks' therapy in 23 patients and 4 weeks' therapy in 20 patients. (There was no significant difference in effectiveness between the two candidiasis groups.) Data on file, Dermatological Division, Johnson & Johnson.

‡Chemical name: 1-[2,4-dichloro-β-{(2,4-dichlorobenzyl) oxy} phenethyl] imidazole mononitrate.

An ethical specific from the Dermatological Division of

Johnson & Johnson

New Brunswick, New Jersey 08903

© Johnson & Johnson 1977

MicaTin Cream/Lotion

BRAND miconazole nitrate 2%

It all adds up to confidence.

PreSun® for proven sunscreen protection

(5% PABA LOTION/GEL)

helps protect against premature aging of skin and skin cancer caused by the sun

©1977, W.P. Inc.

WESTWOOD
PHARMACEUTICALS INC.
Buffalo, New York 14213

Published by the American Medical Association

June 1977

archives of Dermatology

Glucagonoma Syndrome . . . 749

Verrucose Epidermal Nevus . . . 767

Phototoxicity to Ink . . . 770

Radiation Therapy for Basal Cell Carcinomas . . . 783

Pruritic Lesions of Chronic Prurigo . . . 787

Necrolytic Migratory Erythema . . . 792

Atopic Dermatitis in Job's Syndrome . . . 801

Graft-vs-Host Reaction . . . 806

Volume 113 Number 6

Complete Contents . . . 708

Drechslera spicifera Phaeohyphomycosis . . . 813

Fatal Herpes Simplex Type 2 . . . 816

Erythema Elevatum Diutinum . . . 819

Supernumerary Areolae . . . 823

Lupus Band Test . . . 830

AMA AMERICAN MEDICAL ASSOCIATION

LIBRARY

CONTEMPORARY AND EFFECTIVE

For seborrhea oleosa and the oily hair and scalp associated with acne



- Thorough cleansing of oily hair and scalp.
- Leaves patients' hair soft, manageable, fresh smelling.
- Elegant herbal scented shampoo.
- A special formulation designed to cleanse and condition oily hair.
- Its pH of 5.5 is gentle to the scalp.
- Can be used as often as necessary, preferably every day, to keep hair looking fresh and healthy.
- CONTAINS NO FORMALDEHYDE.

Supplied: 4 oz. and 8 oz. plastic bottles.

Pernox Shampoo® is adjunctive therapy especially formulated for oily scalps associated with acne.

WESTWOOD
PHARMACEUTICALS INC.
Buffalo, New York 14213

© 1977, W.P. INC.

New From Dermik

Hytone®

CREAM (HYDROCORTISONE)

2½%

hydrocortisone safety . . . new high potency . . .

- Atopic Dermatitis
- Severe Diaper Dermatitis
- Seborrheic Dermatitis
- Lichen Simplex Chronicus
- Pruritus Ani

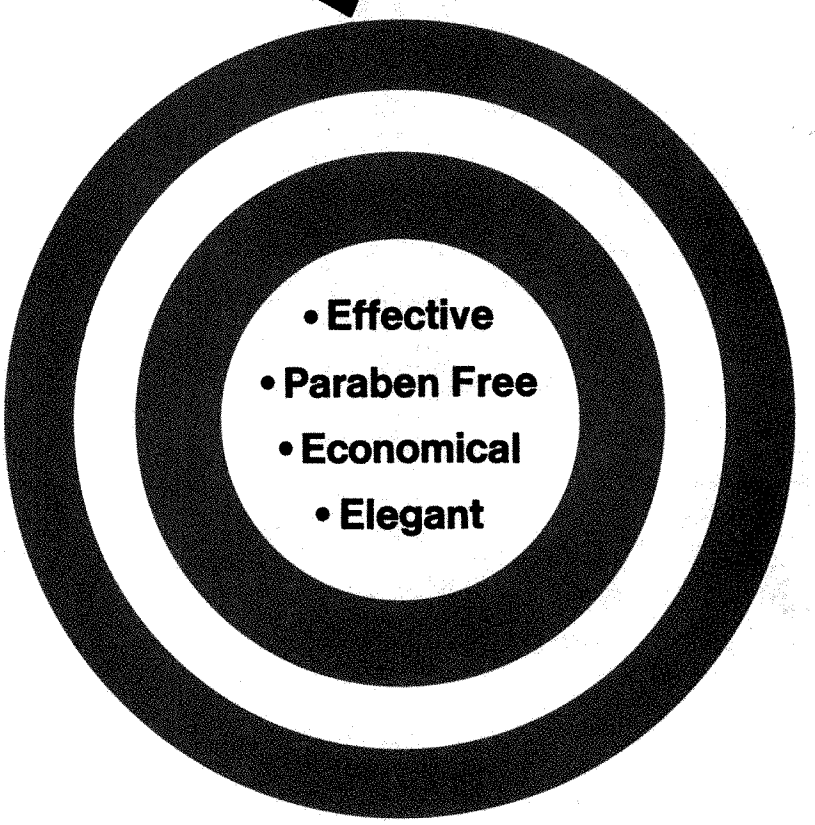

Dermik

Dermik Laboratories, Inc., Fort Washington, Pa. 19034
WHERE RESEARCH AND ECONOMY COME FIRST!

DESCRIPTION – Hydrocortisone 2½%, 1% and ½% in a water-washable cream containing purified water, propylene glycol, isopropyl myristate, cholesterol and related sterols, cetyl alcohol, sorbic acid, glyceryl monostearate, polysorbate 60, sorbitan monostearate and polyoxyl 40 stearate.

ACTIONS – Topical corticosteroids are effective primarily because of their antiinflammatory, antipruritic, and vasoconstrictive actions.

INDICATIONS – For relief of the inflammatory manifestations of corticosteroid-responsive dermatoses.

CONTRAINDICATIONS: In viral diseases of the skin such as varicella and vaccinia and in patients with a history of hypersensitivity to any component. Not for ophthalmic use. Topical steroids should not be used when circulation is markedly impaired.

WARNING: Should not be used extensively, in large amounts, or for prolonged periods in pregnancy.

PRECAUTIONS – If irritation develops, the product should be discontinued and appropriate therapy instituted. In the presence of an infection, the use of appropriate antifungal or antibacterial agents should be instituted. If a favorable response does not occur promptly, the corticosteroid should be discontinued until the infection has been adequately controlled. If extensive areas are treated or if the occlusive technique is used, the possibility exists of increased systemic absorption of the corticosteroid and suitable precautions should be taken.

ADVERSE REACTIONS – The following local adverse reactions have been reported with topical corticosteroids, either with or without occlusive dressings: burning sensations, itching, irritation, dryness, folliculitis, secondary infection, skin atrophy, striae, hypertrichosis, acneform eruption and hypopigmentation.

DOSAGE AND ADMINISTRATION – Apply to affected areas 3 or 4 times daily.

HOW SUPPLIED: Tubes – ½ oz., 1 oz.

CAUTION – Federal law prohibits dispensing without prescription.

Archives of DERMATOLOGY
Copyright © 1977 by the AMERICAN MEDICAL ASSOCIATION

VOL 113, NO. 6 June 1977

ORIGINAL CONTRIBUTIONS

Unusual Variant of Lupus Erythematosus or Lichen Planus
Robert W. Romero, MD; Lee T. Nesbitt, Jr, MD; Richard J. Reed, MD, New Orleans 741

Glucagonoma Syndrome
Alan N. Binnick, MD; Steven K. Spencer, MD, Hanover, NH; W. Landon Dennison, Jr, MD; Edward S. Horton, MD, Burlington, Vt 749

Ultrastructural Studies of Vitiligo, Vogt-Koyanagi Syndrome, and Incontinentia Pigmenti Achromians
Masaaki Morohashi, MD, PhD; Ken Hashimoto, MD; Thomas F. Goodman, Jr, MD; Dennis E. Newton, MD; Toivo Rist, MD, Memphis 755

Inflammatory Linear Verrucose Epidermal Nevus
André Dupre, Bernadette Christol, Toulouse Cedex, France 767

Phototoxicity Occurring During the Manufacture of Ultraviolet-Cured Ink
Edward A. Emmett, MB, BS; Barbara R. Taphorn; John R. Kominsky, MS, Cincinnati 770

Vegetables Responsible for Contact Dermatitis of the Hands
Syamalendra M. Sinha, MD; Jagjit S. Pasricha, MD, PhD; Ramesh C. Sharma, MSc, PhD; Kahn C. Kandhari, FRCP, New Delhi 776

Microbial Flora of Atopic Dermatitis
Raza Aly, PhD; Howard I. Maibach, MD; Henry R. Shinefield, MD, San Francisco 780

Treatment of Morphea-Type Basal Cell Carcinomas With Radiation Therapy
Robert S. Bart, MD; Alfred W. Kopf, MD; Arthur H. Gladstein, MD, New York 783

Cutaneous Neural Proliferation in Highly Pruritic Lesions of Chronic Prurigo
Uee Runne, Constantin E. Orfanos, Cologne, West Germany 787

Necrolytic Migratory Erythema
Ronald S. Kahan, MD; Maj Rafael A. Perez-Figaredo, MC, USAF; Lt Col Andris Neimanis, MC, USAF, Boston 792

CASE REPORTS

Arcuate Dermal Erythema in a Carrier of Chronic Granulomatous Disease
Craig E. Nelson, MD; Mark V. Dahl, MD; Robert W. Goltz, MD, Minneapolis 798

Atopic Dermatitis and Impaired Neutrophil Chemotaxis in Job's Syndrome
David Paslin, MD, Michael E. Norman, MD, Philadelphia 801

Graft-vs-Host Reaction
Maj Thomas M. Grogan, MC, USA, MD; Lt Col Richard B. Odom, MC, USA, MD; John H. Burgess, Presidio of San Francisco, Calif 806

Primary Cutaneous Phaeohyphomycosis Caused by *Drechslera spicifera*
Stephen A. Estes, MD; William G. Merz, PhD; Lynne G. Maxwell, MD, Baltimore 813

(Continued on page 710)

EDITORIAL BOARD

Chief Editor
John H. Epstein, MD
450 Sutter Street
San Francisco 94108

Assistant Chief Editor
Kimie Fukuyama, MD
San Francisco

Assistant Chief Editor
Denny L. Tuffanelli, MD
San Francisco

Donald C. Abele, MD
Augusta, Ga.

Harry L. Arnold, Jr, MD
Honolulu

Walter C. Lobitz, Jr, MD
Portland, Ore

Frederick D. Malkinson, MD
Chicago

Sigfrid A. Muller, MD
Rochester, Minn

W. Mitchell Sams, Jr, MD
Denver

John S. Strauss, MD
Boston

Morris Waisman, MD
Tampa, Fla

Gerald D. Weinstein, MD
Miami

THREE-IN-ONE THERAPY AGAINST TOPICAL INFECTION

Neosporin® Ointment

(Polymyxin B-Bacitracin-Neomycin)

This potent broad-spectrum antibacterial provides overlapping action to help combat infection caused by common susceptible pathogens (including staph and strep). The petrolatum base is gently occlusive, protective and enhances spreading.

Neomycin
Staphylococcus
Haemophilus
Klebsiella
Aerobacter
Escherichia
Proteus
Corynebacterium
Streptococcus
Pneumococcus

Bacitracin
Staphylococcus
Corynebacterium
Streptococcus
Pneumococcus

Polymyxin B
Pseudomonas
Haemophilus
Klebsiella
Aerobacter
Escherichia

In vitro overlapping antibacterial action of Neosporin® Ointment (polymyxin B-bacitracin-neomycin).

Wellcome

Burroughs Wellcome Co.
Research Triangle Park
North Carolina 27709

Neosporin® Ointment

(Polymyxin B-Bacitracin-Neomycin)

Each gram contains: Aerosporin® brand Polymyxin B Sulfate 5,000 units; zinc bacitracin 400 units; neomycin sulfate 5 mg (equivalent to 3.5 mg neomycin base); special white petrolatum qs; in tubes of 1 oz and 1/2 oz and 1/32 oz (approx.) foil packets.

WARNING: Because of the potential hazard of nephrotoxicity and ototoxicity due to neomycin, care should be exercised when using this product in treating extensive burns, trophic ulceration and other extensive conditions where absorption of neomycin is possible. In burns where more than 20 percent of the body surface is affected, especially if the patient has impaired renal function or is receiving other aminoglycoside antibiotics concurrently, not more than one application a day is recommended.

When using neomycin-containing products to control secondary infection in the chronic dermatoses, it should be borne in mind that the skin is more liable to become sensitized to many substances, including neomycin. The manifestation of sensitization to neomycin is usually a low grade reddening with swelling, dry scaling and itching; it may be manifest simply as failure to heal. During long-term use of neomycin-containing products, periodic examination for such signs is advisable and the patient should be told to discontinue the product if they are observed. These symptoms regress quickly on withdrawing the medication. Neomycin-containing applications should be avoided for that patient thereafter.

PRECAUTIONS: As with other antibacterial preparations, prolonged use may result in overgrowth of nonsusceptible organisms, including fungi. Appropriate measures should be taken if this occurs.

ADVERSE REACTIONS: Neomycin is a not uncommon cutaneous sensitizer. Articles in the current literature indicate an increase in the prevalence of persons allergic to neomycin. Ototoxicity and nephrotoxicity have been reported (see Warning section).

Complete literature available on request from Professional Services Dept. PML.

Generalized Acute Mucocutaneous Herpes Simplex Type 2 With Fatal Outcome
Louis Lopyan, MD; Alexander W. Young, Jr, MD; Marilyn Menegus, PhD, New York 816

Erythema Elevatum Diutinum
Lt Col Samuel L. Fort, MC, USA, Lt Col Orlando G. Rodman, MC, USA, El Paso, Tex 819

Supernumerary Areolae
Lt Comdr Stephen W. Shewmake, MC, USN, Capt Gene T. Izuno, MC, USN, San Diego 823

REVIEW ARTICLE

Lupus Band Test
Eugene W. Monroe, MD, Ann Arbor, Mich 830

REGULAR DEPARTMENTS

Short Reports 837

Segmental Neurofibromatosis Robert M. Miller, MD, Robert S. Sparkes, MD, Los Angeles . . . **Pancreatic Carcinoma With Dissemination to Umbilicus and Skin** Anup K. Chakraborty, MD; Atigadda N. Reddy, MD; Saul J. Grosberg, MD; Simon Wapnick, MD, Brooklyn, NY . . . **Contact Dermatitis Caused by ECG Electrode Jelly** Ralph J. Coskey, MD, Detroit

Letters to the Editor 845

Psoriasis and Bullous Pemphigoid A. Razzaque Ahmed, MD, Norman W. Winkler, MD, PhD, Buffalo, NY . . . **Dapsone-Induced Neuropathy** Louis K. Gehlmann, MD; William C. Koller, MD; Frederick D. Malkinson, MD, DMD, Chicago . . . **Bi-Directional Isomorphism: Coexistence of Psoriasis Vulgaris and Familial Benign Chronic Pemphigus** J. D. Boxley, MA, MB, B Chir, MRCP; J. P. H. Byrne, MA, MB, MRCP (1), MRCP; R. Summerly, MB, ChB, FRCP, FRCPE, Stoke-on-Trent, England . . . **Syncope Associated With Liquid Nitrogen Therapy** Allen M. Epstein, MD, Jerome L. Shupack, MD, New York . . . **Carcinoma Occurring in Rhinophyma** Daniel B. Brubaker, DO, Richard H. Hellstrom, Pittsburgh . . . **Acquired Zosteriform Cavernous Hemangiomas: Brief Clinical Observation** David M. Steinway, DO, David F. Fretzin, MD, Chicago . . . **Double-Blind Trial of 1% Clotrimazole Cream and Whitfield Ointment in the Treatment of Pityriasis Versicolor** Roger Clayton, MB, MRCP; Anthony Du Vivier, MB, MRCP; Michael Savage, London . . . **Ferrous Iron and Porphyria Cutanea Tarda** Ronald D. Wise, MD, Frederick D. Malkinson, MD, DMD, Chicago . . . **Congenital Disseminate Organoid Tumors** Lawrence M. Solomon, MD, Ana M. Eng, MD, Chicago . . . **Trioxsalen Bath and Ultraviolet Light Treatment of Psoriasis** T. Fischer, MD, L. Juhlin, MD, Upsala, Sweden . . . **Benign Chronic Bullous Dermatosis of Childhood** David A. Voron, MD, Arcadia, Calif

Society Transactions 856

Books 860

News and Notes 863

Index to Advertisers 868

Instructions for Authors 714

SUBSCRIPTION RATES: The yearly rate of the ARCHIVES OF DERMATOLOGY is as follows: United States and US Possessions, one year, $18; two years, $28; all other countries, one year, $28; two years, $38. Special yearly price to residents, interns and medical students in the United States and US Possessions, $9.

THE ARCHIVES OF DERMATOLOGY is published monthly by the American Medical Association, 535 N Dearborn St, Chicago, IL 60610, and is an official publication of the Association. Second-class postage paid at Chicago and at additional mailing office.



Selsun®
(SELENIUM SULFIDE LOTION, U.S.P.) ℞

Brief Summary

Contains:
Selenium sulfide, 2½%, w/v; bentonite; lauric diethanolamide; ethylene glycol monostearate; titanium dioxide; amphoteric—2; sodium lauryl sulfate; sodium phosphate (monobasic); glyceryl monoricinoleate; citric acid; captan; perfume; and water.

Indications:
For the treatment of dandruff and seborrheic dermatitis of the scalp.

Contraindications:
Should not be used by patients allergic to any of its components.

Warnings:
Safety for use on infants has not been established.

Precautions:
Cutaneous sensitization of the scalp or adjacent areas has been reported; if sensitivity reactions should occur, discontinue use. Chemical conjunctivitis may result if product enters the eyes. Do not use when acute inflammation or exudation is present as an increase in absorption may occur.

Adverse Reactions:
As with other shampoos, oiliness or dryness of the hair and scalp may occur following use; there have been occasional reports of an increase in the amount of normal hair loss. Hair discoloration may occur; can be avoided or minimized by thorough rinsing.

ABBOTT
7033184

Announcing Selsun.

What?

New Selsun®

(SELENIUM SULFIDE LOTION, U.S.P.)





Archives of Dermatology

James H. Sammons, MD
Executive Vice-President

Thomas F. Hannon
Group Vice-President,
Publishing Operations

William R. Barclay, MD
Group Vice-President,
Scientific Publications

Norman D. Richey
Director, Publication
Production Division

John T. Baker
Director, Marketing Division

Helen R. Mazur
Acting Fulfillment Manager

John T. Baker, General Sales Manager; **Robert Corcoran,** Eastern Sales Manager; **Fred Bauman, Richard M. Johnson,** Eastern Sales Representatives; **William J. Healy,** Midwest Sales Representative; **Thomas J. Carroll,** West Coast/Northern Sales Representative

PUBLICATION STAFF

Offices: 535 N Dearborn St
Chicago, IL 60610

William R. Barclay, MD, Director
Scientific Publications Division

Robert W. Mayo, Executive Editor

Marlene M. Hinsch, Production Manager

Editorial Processing Manager: Diana A. Morgan

Copy Editing: Rosanne Schulenberg (Supervisor), Rae Usinger

Proofreading: Lorraine L. Kruse (Supervisor), Patricia Coyne, Helen Grzeskiewicz, Elizabeth Petrikenas, Dorothy Troy

Production Supervisors: Julia Bero (Layout), Thomas J. Handrigan (Illustrations), Marlene M. Hinsch (Editorial), James P. Bagniewski (Advertising)

Art and Senior Production Assistants: Betty Frigerio, Shirley Latronica, Deborah Orent, Donna Pender, Nancy Keyes, Susan Routhier, JoAnne Weiskopf

Production Assistants: Karen Branham, E. Linda Eisenberg, Anna Goins, Lucille Kuznicki

Manuscript Records: Mary Paino

Indexing: Phyllis H. McLaren (Supervisor), Jane P. Mauldin, Helen F. Topel

Please address communications concerning accepted or published communications to: AMA Specialty Journals, 535 N Dearborn St, Chicago, IL 60610.

Conditions for Acceptance of Color Illustrations

Illustrations in full color are accepted for publication in ARCHIVES OF DERMATOLOGY if the editor believes that color will add significantly to the published manuscript.

When color illustrations are accepted, the American Medical Association will pay part of the expense of reproduction and printing, the remainder to be borne by the author or the institution with which he is affiliated. After deducting AMA's contribution, the author's share is $275 for up to six square finished illustrations. Additional illustrations and special effects, such as outlining, opaquing, or surprinting, will be billed to the author at cost.

Color transparencies must be submitted for evaluation. Do not send color prints unless accompanied by original transparencies. If transparencies are mounted in frames or glass, the material should be carefully packed in gauze and sent with the manuscript in a separate container or between two pieces of pressboard.

Advertising and Subscription Information

ADVERTISING OFFICES: 535 N Dearborn St, Chicago, IL 60610, Area Code 312, 751-6000; and 600 Third Ave, New York, NY 10016, Area Code 212-867-6640.

ADVERTISING PRINCIPLES: Each advertisement in this issue has been reviewed and complies with the principles governing advertising in AMA scientific publications. A copy of these principles is available on request.

CHANGE OF ADDRESS: Please notify the publisher at least six weeks in advance, including both old and new address, and a mailing label taken from the most recent copy. Include your new zip code number.

UVAL helps prevent sunburn by screening out the sun's rays most harmful to human skin. Offers sun-sensitive patients real protection with a broad range of ultraviolet absorption (220-350nm).
UVAL prevents burning, drying, wrinkling and freckling due to overexposure to the sun. Helps maintain softer, more youthful-looking skin. Provides protection with a low incidence of side effects.
UVAL has a creamy rich emollient base and may be used under makeup without loss of its sunscreening effectiveness.
UVAL frees your patients from the worry of painful sunburn. Lets them participate in outdoor work activity and enjoy fun in the sun year-round.
UVAL is alcohol-free and won't sting or dry skin. It protects with a nongreasy, almost invisible film that won't stain fabrics, skin or hair. Unlike PABA/Alcohol preparations, UVAL need not be applied one hour before sun exposure.
a sensible answer for sun-sensitive skin
HELPS PREVENT SUNBURN
UVAL (sulisobenzone) SUNSCREEN LOTION
NET WT. 2.64 OZ.
DIRECTIONS: Shake well before using. Apply UVAL evenly to exposed skin, rub in well and allow to dry. To maintain protection, reapply after swimming or excessive perspiring. CAUTION: Avoid getting lotion into eyes. If skin sensitivity develops, [illegible] and consult [illegible] external [illegible] this prepara- [illegible] reach.
NOTE: If tanning is desired and permissible, direct your patients to follow The Guide to Tanning printed on every package of UVAL.
[illegible] Sandoz, Inc.
[illegible] NEBRASKA 68501
D--

Instructions for Authors

Send manuscripts by first-class mail to the Chief Editor, John H. Epstein, MD, 450 Sutter St, San Francisco, CA 94108. Manuscripts are received with the understanding that they are not under simultaneous consideration by another publication. Accepted manuscripts become the permanent property of the ARCHIVES and may not be published elsewhere without permission from the publisher (AMA).

Author Responsibility.—All accepted manuscripts are subject to copy editing. The author will receive an edited typescript rather than galley proofs for approval. The author is responsible for all statements in his work, including changes made by the copy editor.

Designate one author as correspondent and provide his address and telephone number. Order reprints at the time the typescript is returned after editorial processing. Specify address to which requests for reprints should be sent.

Manuscript Preparation.—Submit an original typescript and two high-quality copies of the entire manuscript. All copy (including references, legends, and tables) must be typed double-spaced on 22 × 28-cm (8½ × 11-inch), heavy-duty white bond paper. Ample margins should be provided.

Refer to patients by number (or, in anecdotal reports, by fictitious given names). Real names or initials should not be used in the text, tables, or illustrations.

Titles.—Titles should be short, specific, and clear. They should not exceed 42 characters per line, including punctuation and spaces, and be limited to two lines, if possible. The title page should include the full names and academic affiliations of all authors, the address to which requests for reprints should be sent, and, if the manuscript was presented at a meeting, the name of the organization, place, and date on which it was read.

Style of Writing.—The style of writing should conform to acceptable English usage and syntax. Slang, medical jargon, obscure abbreviations, and abbreviated phrasing are to be avoided.

Informed Consent.—Manuscripts reporting the results of experimental investigations of human subjects must include a statement to the effect that informed consent was obtained after the nature of the procedure(s) had been fully explained.

Abstract.—Provide an abstract (135-word maximum) of the article, including statements of the problem, method of study, results, and conclusions. The abstract replaces the summary.

References.—List references in consecutive numerical order (not alphabetically). Once a reference is cited, all subsequent citations should be to the original number. All references must be cited in the text or tables. Unpublished data and personal communications should not be listed as references. References to journal articles should include (1) author, (2) title, (3) journal name (as abbreviated in *Index Medicus*), (4) volume number, (5) inclusive page numbers, and (6) year, in that order. References to books should include (1) author(s), (2) chapter title (if any), (3) editor (if any), (4) title of book, (5) city of publication, (6) publisher, and (7) year. Volume and edition numbers, specific pages, and name of translator should be included when appropriate. The author is responsible for the accuracy and completeness of the references and for their correct text citation.

Metrication.—All measurements must be in metric units. English units may also be given parenthetically if the measurements were originally done in English units.

Illustrations.—Use only those illustrations that clarify and augment the text. Submit illustrations in duplicate, unmounted and untrimmed. Do not send original artwork. Send high-contrast glossy prints (not photocopies). Figure number, name of senior author, and arrow indicating "top" should be typed on a gummed label and affixed to the back of each illustration. All lettering must be legible after reduction to column size. Artwork submitted for publication may be relettered to achieve uniformity of lettering style throughout the journal. Magnification and stain should be provided when pertinent. Illustrations should preferably be in a proportion of 12.5 × 18 cm (5 × 7 inches).

An experienced medical illustrator should be employed whenever possible for the preparation of all artwork. Template lettering or preset type is preferred to hand-lettered labels. If halftone artwork with labels is submitted, affix type and leaders to a clear acetate overlay registered to the base drawing. Labels and leaders should be applied directly to the drawing board surface if the artwork consists only of line ink technique.

Illustrations in full color are accepted for publication if the editors believe that color will add significantly to the published manuscript. The ARCHIVES will pay part of the expense of reproduction and printing color illustrations, the remainder to be borne by the author or his sponsor. After deducting the ARCHIVES contribution, the author's share is $275.00 for up to six square-finished illustrations that can be arranged on a one-page layout. Any additional illustrations or special effects will be billed to the author at cost. Positive color transparencies (35 mm preferred) must be submitted for an evaluation. Do not send color prints unless accompanied by original transparencies. All transparencies should be carefully packed and sent with the manuscript.

Legends.—Legends should be typed double-spaced, beginning on a separate sheet of paper. Length should be limited to a maximum of 40 words.

Photographic Consents.—A letter of consent must accompany all photographs of patients in which a possibility of identification exists. It is not sufficient to cover the eyes to mask identity.

Acknowledgments.—Illustrations from other publications must be acknowledged. Include the following when applicable: author(s), title of article, title of journal or book, volume number, page(s), month, and year. The publisher's permission to reprint should be submitted to the ARCHIVES after the manuscript has been formally accepted.

Statistical Review.—Manuscripts containing statistical evaluations should include the name and affiliation of the statistical reviewer.

Tables.—Each table should be typed double-spaced, including all headings, on a separate sheet of 22 × 28-cm (8½ × 11-inch) paper. Do not use larger size paper. If a table must be continued, use a second sheet and repeat all heads and stubs. Each table must have a title.

Schering

When it's all you want, it's all they get.

pure and simple

Chlor-Trimeton® 12mg.

brand of

chlorpheniramine maleate, USP

brand of

Repetabs® Tablets, repeat-action tablets

Available on prescription only.

Also available:
Chlor-Trimeton®
8 mg. Repetabs®
Injection 100 mg./ml.
and 10 mg./ml.

Copyright © 1977, Schering Corporation. All rights reserved.

SWW-9340

PSORIASIS
The Capricious Dermatosis

LIDEX® (fluocinonide) 0.05%
A Stabilizing Influence

Psoriasis. Mere mention of the word can make an afflicted patient cringe. And, because of the capricious, unpredictable nature of the disease, the patient rarely knows where or when it will recur.

Obviously, the goal is control. And, though varied treatment modalities are available today, none offers universal

ficacy for all patients, all of the time.

Yet, very often a highly effective topical eroid, like Lidex, (fluocinonide) can elp stabilize psoriasis.

Lidex. A highly effective topical steroid ith anti-inflammatory, vasoconstrictive, ntipruritic actions.

100% dissolved for optimal penetration, important in stages that exhibit thickened, scaly lesions.

Totally free of preservatives.

Available in cream, ointment, and Topsyn® (fluocinonide) gel.

SYNTEX

SYNTEX LABORATORIES, INC.
PALO ALTO, CALIFORNIA 94304



(See following page for brief summary)

LIDEX® (fluocinonide)
0.05% Cream and Ointment

TOPSYN® (fluocinonide)
0.05% Gel

Summary of prescribing information

Description
LIDEX cream 0.05%, LIDEX ointment 0.05% and TOPSYN gel 0.05% contain the active compound fluocinonide. Fluocinonide, which is the 21-acetate ester of fluocinolone acetonide, has the chemical formula 6α, 9α, -difluoro-11β, 16α, 17α, 21-tetrahydroxypregna-1,4-diene-3, 20-dione, cyclic 16, 17-acetal with acetone 21-acetate. LIDEX cream contains fluocinonide in FAPG® cream, a specially formulated cream base consisting of stearyl alcohol, polyethylene glycol 6000, propylene glycol, 1, 2, 6-hexanetriol and citric acid. This white cream vehicle is greaseless, non-staining, anhydrous and completely water miscible. The base provides emollient and hydrophilic properties. In this formulation, the active ingredient is totally in solution.

LIDEX ointment contains fluocinonide in a specially formulated ointment base consisting of Amerchol CAB (mixture of sterols and higher alcohols), white petrolatum, propylene carbonate and propylene glycol. It provides the occlusive and emollient effects desirable in an ointment. In this formulation the active ingredient is totally in solution.

TOPSYN gel contains fluocinonide in a specially formulated gel base consisting of propylene glycol, propyl gallate, disodium edetate, and Carbopol 940 (carboxypolymethylene) with NaOH and/or HCL added to adjust the pH. This clear, colorless, thixotropic vehicle is greaseless, non-staining and completely water miscible. In this formulation, the active ingredient is totally in solution.

Indications
LIDEX cream and ointment and TOPSYN gel are intended for the relief of inflammatory manifestations of corticosteroid responsive dermatoses.

Contraindications
Topical steroids are contraindicated in vaccinia and varicella. Topical steroids are contraindicated in those patients with a history of hypersensitivity to any of the components of the preparation.

Precautions
If irritation develops, the cream, ointment or gel should be discontinued and appropriate therapy instituted. In the presence of an infection the use of an appropriate antifungal or antibacterial agent should be instituted.

If a favorable response does not occur promptly, the corticosteroid cream, ointment or gel should be discontinued until the infection has been adequately controlled.

If extensive areas are treated, the possibility exists of increased systemic absorption and suitable precautions should be taken.

Although topical steroids have not been reported to have an adverse effect on pregnancy, the safety of their use in pregnant females has not absolutely been established. Therefore, they should not be used extensively on pregnant patients, in large amounts or for prolonged periods of time.

LIDEX® (fluocinonide) cream and ointment and TOPSYN® (fluocinonide) gel are not for opthalmic use.

Adverse reactions
The following local adverse reactions have been reported with topical corticosteroids:

burning	folliculitis
itching	acneform eruptions
irritation	hypopigmentation
dryness	striae
secondary infection	skin atrophy

Dosage and administration
A small amount should be gently massaged into the affected area three or four times daily, as needed.

How supplied
LIDEX 0.05% Cream—15 g 30 g and 60 g tubes.
LIDEX 0.05% Ointment—15 g 30 g and 60 g tubes.
TOPSYN Gel 0.05% 15 g and 60 g tubes.

SYNTEX
SYNTEX LABORATORIES, INC.
PALO ALTO, CALIFORNIA 94304

Vanoxide® Acne Lotion and Loroxide® Acne Lotion

Description: Vanoxide Acne Lotion contains (as dispensed) benzoyl peroxide 5% and chlorhydroxyquinoline 0.25%, incorporated in a water washable lotion.

Loroxide Acne Lotion contains (as dispensed) benzoyl peroxide 5.5%, and chlorhydroxyquinoline 0.25%, incorporated in a water washable lotion, with "Dermik Color Blender" supplied separately.

How Supplied: Vanoxide—Bottles, 25 and 50 grams; Loroxide—Bottles, 25 grams

Vanoxide-HC® and Loroxide-HC® Lotions

Description: Vanoxide-HC Lotion contains (as dispensed) hydrocortisone 0.5%, benzoyl peroxide 5.0% and chlorhydroxyquinoline 0.25%, incorporated in a water washable lotion containing purified water, propylene glycol, hydroxyethylcellulose, FD&C color, cholesterol-sterol, cetyl alcohol, propylene glycol stearate, polysorbate 20, lanolin alcohol, propylparaben, decyl oleate, purcelline oil syn., antioxidants, vegetable oil, methylparaben, tetrasodium EDTA, buffers, cyclohexanediamine tetraacetic acid, calcium phosphate, silicone emulsion, and silica.

Loroxide-HC Lotion contains (as dispensed) hydrocortisone 0.5%, benzoyl peroxide 5.5% and chlorhydroxyquinoline 0.25%, incorporated in a water washable lotion containing purified water, propylene glycol, hydroxyethylcellulose, caramel color, cholesterol-sterol, cetyl alcohol, propylene glycol stearate, polysorbate 20, lanolin alcohol, propylparaben, decyl oleate, purcelline oil syn., antioxidants, vegetable oil, methylparaben, tetrasodium EDTA, pH buffers, cyclohexanediamine tetraacetic acid, calcium phosphate, silicone emulsion, silica, kaolin, talc and titanium dioxide, with "Dermik Color Blender" supplied separately.

Actions: Provides keratolytic, peeling and drying action.

Indications: An aid in the treatment of acne and oily skin.

Contraindications: Contraindicated for patients having known hypersensitivity to hydrocortisone, benzoyl peroxide, chlorhydroxyquinoline or any other component of this preparation. Topical steroids are contraindicated in viral diseases of the skin, such as varicella and vaccinia.

Warning—Usage in Pregnancy: Safety of use of topical steroids during pregnancy has not been absolutely established. Therefore, they should not be used extensively, or in large amounts or for prolonged periods of time on pregnant patients.

Precautions: For external use only. Keep away from eyes. Discontinue use if irritation develops. Use of appropriate antifungal or antibacterial agents should be instituted in presence of infection. If a favorable response does not occur promptly, the corticosteroid should be discontinued until the infection has been adequately controlled. If extensive areas are treated, or if the occlusive technique is used, the possibility exists of increased systemic absorption of the corticosteroid and suitable precautions should be taken. Observe patients carefully for possible local irritation or sensitization during long-term topical therapy. Apply with caution on neck and/or other sensitive areas. There may be a slight, transitory stinging or burning sensation on initial application which invariably disappears on continued use. Ultraviolet and cold quartz light should be employed in lesser amounts, as this lotion is keratolytic and drying. Harsh, abrasive cleansers should not be used simultaneously with this lotion. Colored or dyed garments may be bleached by the oxidizing action of benzoyl peroxide. Chlorhydroxyquinoline may cause temporary light-yellowish skin staining in rare cases. Keep out of the reach of children.

Adverse Reactions: Local adverse reactions reported with topical corticosteroids: burning sensations, itching, irritation, dryness, folliculitis, secondary infection, skin atrophy, striae, hypertrichosis, acneiform eruptions, and hypopigmentation. The sensitizing potential of benzoyl peroxide and chlorhydroxyquinoline are low; but they can produce allergic reaction. Reduce amount and frequency of application if excessive redness or peeling occurs.

How Supplied: Bottles, 25 grams.

Caution: Federal law prohibits dispensing without prescription.

5-Benzagel® and 10-Benzagel® Acne Gels

Description: 5% or 10% benzoyl peroxide, 6% polyoxyethylene lauryl ether and 40% alcohol in an astringent gel containing colloidal magnesium aluminum silicate, hydroxypropyl methylcellulose, citric acid, fragrance, and purified water.

Action: Provides drying, desquamative and antiseptic activity.

Indication: An aid in the treatment of acne.

Dosage and Administration: Wash affected areas prior to application. Apply once or more daily or as directed by physician.

Contraindications: Should not be used by patients having known sensitivity to either benzoyl peroxide or polyoxyethylene lauryl ether.

Precautions: For External Use Only. Not for ophthalmic use. Keep away from eyes and mucosae. Very fair individuals should begin with a single application at bedtime allowing overnight medication. May bleach colored fabrics. Keep this and all other medications out of the reach of children.

Caution: Federal law prohibits dispensing without prescription.

How Supplied: Plastic tubes, 1½ oz. and 3 oz.

Dermik

DERMIK LABORATORIES, INC.
Fort Washington, Pa., U.S.A. 19034

Now!... a full family of products for intensive acne care from

Dermik

originator and leader in Benzoyl Peroxide Acne Therapy at practical patient cost

For Benzoyl Peroxide Acne Therapy with superior, penetrating, antibacterial action...

INVISIBLE

- Vanoxide® and Vanoxide-HC® are indicated for severe, recalcitrant, oily acne

FLESH-TINTED

- Loroxide® and Loroxide-HC® are the only tinted benzoyl peroxide products available, and they can be used as a daily make-up. These products provide the same formulation and therapeutic benefits as Vanoxide and Vanoxide-HC.
- Chlorhydroxyquinoline—benzoyl peroxide lotions provide substantially greater action than benzoyl peroxide alone. It is topical acne medication with proven ability to reduce *C. acnes* within the pilosebaceous structures.

For Benzoyl Peroxide Therapy in acne where maximal drying effect is desired...

- 5 Benzagel® and 10 Benzagel® contain 5% or 10% benzoyl peroxide, 6% polyoxyethylene lauryl ether and 40% alcohol in an astringent, colloidal magnesium aluminum silicate gel vehicle.
- This combination provides superior drying action and achieves dramatic improvement in comedone and papular stages of acne... WITHOUT EXCESSIVE ERYTHEMA OR IRRITATION.


Sites of seborrhea...
Seborrhea illustrated by artist.



spots for Uticort™ (betamethasone benzoate)

a highly effective topical steroid in a special base

UTICORT contains the fluorinated corticosteroid ester — betamethasone benzoate 0.025% — in a specially formulated, clear, self-liquefying gel base to increase steroid activity.

Patients with seborrheic dermatitis treated with UTICORT improved 86% in an average of 11.6 days.

liquefies on application for better surface contact

UTICORT is especially valuable in the treatment of seborrheic dermatitis on hairy areas of the body.

cosmetically acceptable

UTICORT dries to a clear film and can be used confidently on either smooth or hairy skin areas. Moreover, it is greaseless, nonstaining, and nonsticky.

preservative free

Contains no parabens or other potentially sensitizing preservatives.

Brief summary of prescribing information

INDICATIONS. Uticort Gel (betamethasone benzoate) is intended for relief of the inflammatory manifestations of corticosteroid-responsive dermatoses.

CONTRAINDICATIONS. Topical steroids are contraindicated in viral diseases of the skin, such as varicella and vaccinia. Topical steroids are contraindicated in patients with a history of sensitivity to any of the components of the preparation.

This preparation is not for ophthalmic use.

PRECAUTIONS. If irritation develops, the gel should be discontinued and appropriate therapy instituted. In the presence of an infection, the use of appropriate antifungal or antibacterial agents should be instituted. If a favorable response does not occur promptly, the corticosteroid should be discontinued until the infection has been adequately controlled.

If extensive areas are treated, or if the occlusive technique is used, the possibility exists of increased systemic absorption of the corticosteroid, and suitable precautions should be taken.

Although topical steroids have not been reported to have an adverse effect on pregnancy, the safety of their use in pregnant females has not absolutely been established. Therefore, they should not be used extensively on pregnant patients, or in large amounts, or for prolonged periods of time.

Due to the alcohol content of the vehicle, Uticort Gel (betamethasone benzoate) may cause mild, transient stinging without irritation if used on excoriated skin.

ADVERSE REACTIONS. The following local adverse reactions have been reported with topical corticosteroids: burning sensations, itching, irritation, dryness, folliculitis, secondary infection, skin atrophy, striae, hypertrichosis, acneform eruptions, and hypopigmentation.

DOSAGE AND ADMINISTRATION. Apply to affected areas two to four times daily as needed.

HOW SUPPLIED. N 0071-3025 Uticort Gel is supplied in 15-g and 60-g tubes.

Caution: Federal law prohibits dispensing without prescription.

PARKE-DAVIS

PD-JA-2150-1-P (4-77)

PARKE, DAVIS & COMPANY Detroit, MI 48232

Acne on back and shoulders—now within easy reach.

BUF BODY SCRUB provides "epidermabrasion"—the mechanical exfoliation of the outer layer of dead skin cells.

- thoroughly cleanses the skin and removes excess oil
- helps to loosen and remove comedones
- aids removal of coarse, rough skin of hyperkeratosis
- high patient acceptance of BUF-PUF documented by clinical studies

NEW BUF™ BODY SCRUB

A unique new product that features BUF-PUF® Nonmedicated Cleansing Sponge on a contoured, reusable handle.

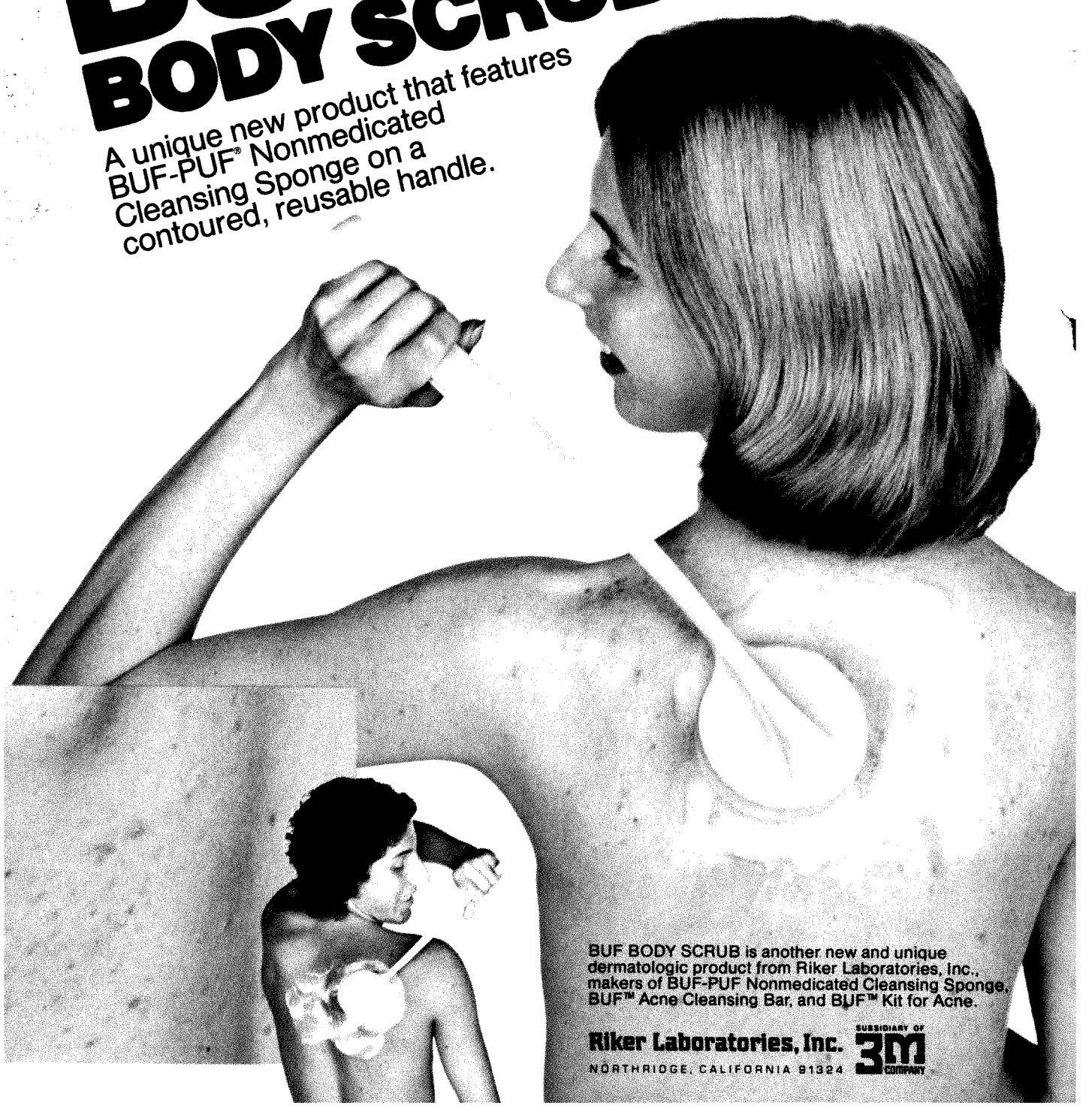

BUF BODY SCRUB is another new and unique dermatologic product from Riker Laboratories, Inc., makers of BUF-PUF Nonmedicated Cleansing Sponge, BUF™ Acne Cleansing Bar, and BUF™ Kit for Acne.

Riker Laboratories, Inc.
NORTHRIDGE, CALIFORNIA 91324

SUBSIDIARY OF 3M COMPANY

CUT THE GRISEOFULVIN DOSE IN HALF

Gris-PEG®
(griseofulvin ultramicrosize)
Tablets 125 mg

For fungal infections sensitive to griseofulvin

- Only half the dose required*
- Absorption nearly complete without fatty meals
- Once-a-day or b.i.d. dosage
- Reduced cost for patients

*250 mg of Gris-PEG® provides plasma levels equivalent to those obtained with 500 mg microsize griseofulvin. This improved absorption permits the oral intake of half as much griseofulvin but there is no evidence at this time that this confers any clinical difference in regard to safety or efficacy.

Dorsey LABORATORIES
Division of Sandoz, Inc.
LINCOLN, NEBRASKA 68501

Please see other side for full prescribing information.

Gris-PEG®
(griseofulvin ultramicrosize) Tablets 125 mg
The ½ dose griseofulvin.

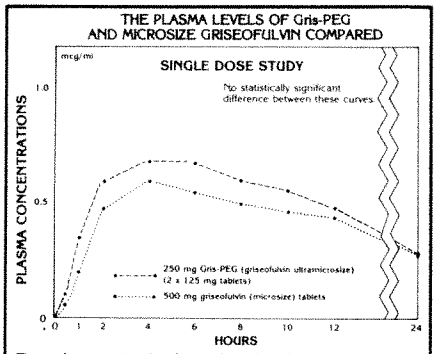

Based on a single dose double-blind bioavailability study conducted in 24 human volunteers comparing the average griseofulvin (microsize) and Gris-PEG plasma levels. There is no significant difference between peak plasma levels, times to peak, and areas under the curve. Gas chromatographic assay.

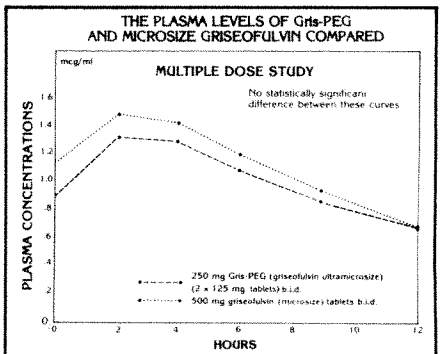

Based on a double-blind multiple dose steady state crossover bioavailability study conducted in 17 human volunteers comparing the average griseofulvin (microsize) and Gris-PEG plasma levels obtained on days 9, 11 and 13. There is no significant difference between times to peak, peak plasma levels, and areas under the curve. Gas chromatographic assay.

DESCRIPTION

Griseofulvin is an antibiotic derived from a species of *Penicillium*.

Gris-PEG is an ultramicrocrystalline solid-state dispersion of griseofulvin in polyethylene glycol 6000.

Gris-PEG tablets differ from griseofulvin (microsize) tablets USP in that each tablet contains 125 mg of ultramicrosize griseofulvin biologically equivalent to 250 mg of microsize griseofulvin.

ACTION

Microbiology: Griseofulvin is fungistatic with *in vitro* activity against various species of *Microsporum, Epidermophyton* and *Trichophyton*. It has no effect on bacteria or other genera of fungi.

Human Pharmacology: The peak plasma level found in fasting adults given 0.25 g of Gris-PEG occurs at about four hours and ranges between 0.37 to 1.6 mcg/ml.

Comparable studies with microsize griseofulvin indicated that the peak plasma level found in fasting adults given 0.5 g occurs at about four hours and ranges between 0.44 to 1.2 mcg/ml.

Thus, the efficiency of gastrointestinal absorption of the ultramicrocrystalline formulation of Gris-PEG is approximately twice that of conventional microsized griseofulvin. This factor permits the oral intake of half as much griseofulvin per tablet but there is no evidence, at this time, that this confers any significant clinical differences in regard to safety and efficacy.

Griseofulvin is deposited in the keratin precursor cells and has a greater affinity for diseased tissue. The drug is tightly bound to the new keratin which becomes highly resistant to fungal invasions.

INDICATIONS

Gris-PEG (griseofulvin ultramicrosize) is indicated for the treatment of the following ringworm infections.

Tinea corporis (ringworm of the body)
Tinea pedis (athlete's foot)
Tinea cruris (ringworm of the thigh)
Tinea barbae (barber's itch)
Tinea capitis (ringworm of the scalp)
Tinea unguium (onychomycosis; ringworm of the nails)

when caused by one or more of the following genera of fungi:

Trichophyton rubrum
Trichophyton tonsurans
Trichophyton mentagrophytes
Trichophyton interdigitalis
Trichophyton verrucosum
Trichophyton megnini
Trichophyton gallinae
Trichophyton crateriform
Trichophyton sulphureum
Trichophyton schoenleini
Microsporum audouini
Microsporum canis
Microsporum gypseum
Epidermophyton floccosum

NOTE: Prior to therapy, the type of fungi responsible for the infection should be identified.

The use of the drug is not justified in minor or trivial infections which will respond to topical agents alone.

Griseofulvin is *not* effective in the following:

Bacterial infections
Candidiasis (Moniliasis)
Histoplasmosis
Actinomycosis
Sporotrichosis
Chromoblastomycosis
Coccidioidomycosis
North American Blastomycosis
Cryptococcosis (Torulosis)
Tinea versicolor
Nocardiosis

CONTRAINDICATIONS

This drug is contraindicated in patients with porphyria, hepatocellular failure, and in individuals with a history of sensitivity to griseofulvin.

WARNINGS

Prophylactic Usage: Safety and Efficacy of Griseofulvin for Prophylaxis of Fungal Infections Has Not Been Established.

Animal Toxicology: Chronic feeding of griseofulvin, at levels ranging from 0.5-2.5% of the diet, resulted in the development of liver tumors in several strains of mice, particularly in males. Smaller particle sizes result in an enhanced effect. Lower oral dosage levels have not been tested. Subcutaneous administration of relatively small doses of griseofulvin, once a week, during the first three weeks of life has also been reported to induce hepatomata in mice. Although studies in other animal species have not yielded evidence of tumorigenicity, these studies were not of adequate design to form a basis for conclusions in this regard.

In subacute toxicity studies, orally administered griseofulvin produced hepatocellular necrosis in mice, but this has not been seen in other species. Disturbances in porphyrin metabolism have been reported in griseofulvin treated laboratory animals. Griseofulvin has been reported to have a colchicine-like effect on mitosis and cocarcinogenicity with methylcholanthrene in cutaneous tumor induction in laboratory animals.

Usage in Pregnancy: The safety of this drug during pregnancy has not been established.

Animal Reproduction Studies: It has been reported in the literature that griseofulvin was found to be embryotoxic and teratogenic on oral administration to pregnant rats. Pups with abnormalities have been reported in the litters of a few bitches treated with griseofulvin. Additional animal reproduction studies are in progress.

Suppression of spermatogenesis has been reported to occur in rats, but investigation in man failed to confirm this.

PRECAUTIONS

Patients on prolonged therapy with any potent medication should be under close observation. Periodic monitoring of organ system function, including renal, hepatic and hematopoietic, should be done.

Since griseofulvin is derived from species of *Penicillium*, the possibility of cross sensitivity with penicillin exists; however, known penicillin-sensitive patients have been treated without difficulty.

Since a photosensitivity reaction is occasionally associated with griseofulvin therapy, patients should be warned to avoid exposure to intense natural or artificial sunlight. Should a photosensitivity reaction occur, lupus erythematosus may be aggravated.

Griseofulvin decreases the activity of warfarin-type anticoagulants so that patients receiving these drugs concomitantly may require dosage adjustment of the anticoagulant during and after griseofulvin therapy.

Barbiturates usually depress griseofulvin activity and concomitant administration may require a dosage adjustment of the antifungal agent.

ADVERSE REACTIONS

When adverse reactions occur, they are most commonly of the hypersensitivity type such as skin rashes, urticaria, and rarely, angioneurotic edema, and may necessitate withdrawal of therapy and appropriate countermeasures. Paresthesias of the hands and feet have been reported rarely after extended therapy. Other side effects reported occasionally are oral thrush, nausea, vomiting, epigastric distress, diarrhea, headache, fatigue, dizziness, insomnia, mental confusion and impairment of performance of routine activities.

Proteinuria and leukopenia have been reported rarely. Administration of the drug should be discontinued if granulocytopenia occurs.

When rare, serious reactions occur with griseofulvin, they are usually associated with high dosages, long periods of therapy, or both.

DOSAGE AND ADMINISTRATION

Accurate diagnosis of the infecting organism is essential. Identification should be made either by direct microscopic examination of a mounting of infected tissue in a solution of potassium hydroxide or by culture on an appropriate medium.

Medication must be continued until the infecting organism is completely eradicated as indicated by appropriate clinical or laboratory examination. Representative treatment periods are—*tinea capitis*, 4 to 6 weeks; *tinea corporis*, 2 to 4 weeks; *tinea pedis*, 4 to 8 weeks; *tinea unguium*—depending on rate of growth—fingernails, at least 4 months; toenails, at least 6 months.

General measures in regard to hygiene should be observed to control sources of infection or reinfection. Concomitant use of appropriate topical agents is usually required particularly in treatment of *tinea pedis*. In some forms of athlete's foot, yeasts and bacteria may be involved as well as fungi. Griseofulvin will not eradicate the bacterial or monilial infection.

An oral dose of 250 mg of Gris-PEG (griseofulvin ultramicrosize) is biologically equivalent to 500 mg of griseofulvin (microsized), USP (see ACTION Human Pharmacology).

Adults: A daily dose of 250 mg will give a satisfactory response in most patients with *tinea corporis, tinea cruris* and *tinea capitis*. One 125 mg tablet twice per day or two 125 mg tablets once per day is the usual dosage. For those fungal infections more difficult to eradicate such as *tinea pedis* and *tinea unguium*, a divided daily dose of 500 mg is recommended. In all cases, the dosage should be individualized.

Children: Approximately 5 mg per kilogram (2.5 mg per pound) of body weight per day is an effective dose for most children. On this basis, the following dosage schedule for children is suggested:

Children weighing over 25 kilograms (approximately 50 pounds)—125 mg to 250 mg daily.

Children weighing 15-25 kilograms (approximately 30-50 pounds)—62.5 mg to 125 mg daily.

Children 2 years of age and younger—dosage has not been established.

Dosage should be individualized, as is done for adults. Clinical experience with griseofulvin in children with *tinea capitis* indicates that a single daily dose is effective. Clinical relapse will occur if the medication is not continued until the infecting organism is eradicated.

HOW SUPPLIED

Gris-PEG (griseofulvin ultramicrosize) Tablets (white) differ from griseofulvin (microsize) tablets (USP) in that each tablet contains 125 mg of ultramicrosize griseofulvin biologically equivalent to 250 mg of microsized griseofulvin. Two 125 mg tablets of Gris-PEG are biologically equivalent to 500 mg of microsized griseofulvin. In bottles of 100 and 500 scored, film-coated tablets.

Dorsey LABORATORIES
Division of Sandoz, Inc. • LINCOLN, NEBRASKA 68501

O- -YB

When patient acceptance is half the problem

sebutone®

is the answer.

Tar is effective therapy, but it has one big drawback . . . most shampoos look like tar and, worst of all, they smell like it, too.

Sebutone® provides tar therapy with unique patient acceptance.

- Itching usually stops after the first shampoo.
- It has a clean, fresh odor patients will like.
- It is a rich, lathering shampoo with a pleasant color.
- It contains the first chemically and biologically standardized tar, developed by Westwood.
- Sebutone's tar is bioassayed to insure therapeutic activity from batch to batch.
- Available in both lotion and cream.
- In addition to 0.5% Westwood® Tar, Sebutone contains 2% sulfur and 2% salicylic acid, for increased effectiveness.
- Wood's light shows that microfine particles remain on the scalp for up to three days to provide sustained antiseborrheic action.



sebutone® Therapeutic Tar Shampoo

Substantive therapy...proven by Wood's light.

Available—Sebutone in 4 and 8 oz. bottles; Sebutone Cream in 4 oz. tubes.

WESTWOOD
PHARMACEUTICALS INC.
Buffalo, New York 14213

©1977, W. P. Inc.

ECLIPSE®

(3% glyceryl PABA and 3% octyl dimethyl PABA)

For your patients

who can't-or won't-stay out of the sun.

For some, it's occupation. For others, the social desirability of a tan. Whatever the reason, many of your patients may be spending more time in the sun than you'd like.

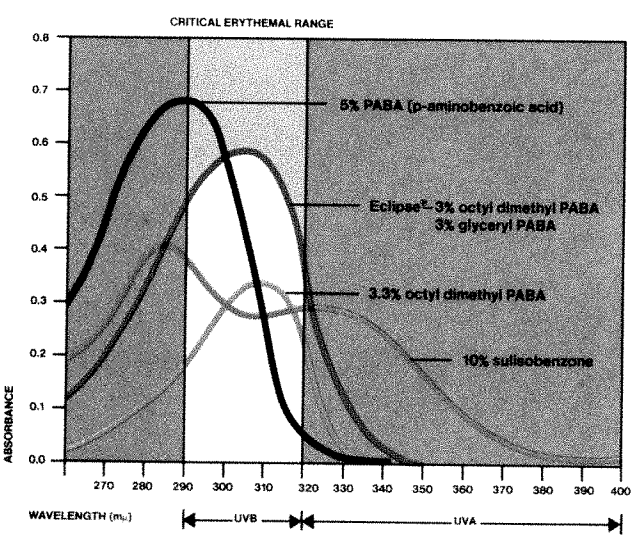

Unique Eclipse formulation combines two PABA derivatives for maximum UVB absorption.

They need Eclipse—a highly effective sunscreen that works immediately upon application, resists wash-off, and contains our exclusive Aquacare® base to help relieve sun and wind-dried skin.

Can other sunscreens do all that? Take a minute to read the labels: we're confident you'll recommend Eclipse.

- Absorbs more than 99% of erythemogenic solar UVB.
- Spreads smoothly and predictably for even protection.
- Permits slow tanning.
- Resists wash-off; protects after swimming or sweating.
- Formulated in Aquacare® to relieve sun and wind-dried skin.



Herbert Laboratories
Dermatology Division of
Allergan Pharmaceuticals
Irvine, CA 92713 U.S.A.

...safe for your patients to use, ...effective and less traumatic than cryosurgery or curettage[1]

Duofilm®

(Salicylic Acid, USP, 16.7% and Lactic Acid, USP, 16.7% in Flexible Collodion, USP)

for warts

et remedies for warts are almost as ommon as warts themselves. How- ver, one specific formulation has gain clinically proven its value.

. B. Rees reported, *"My favorite wart emedy is . . . equal parts of salicylic cid and lactic acid in four parts of lexible collodion (Duofilm)".*[2]

Bunney and associates find the Duofilm ormula, used at home, at least as ffective as, and less traumatic than, ryotherapy and curettage.[1]

Arndt[3], in a double-blind controlled tudy of patients with multiple warts, onfirmed Bunney's findings.

Duofilm is safe and simple to use. Special patient instruction pads and upplies of Duofilm for your treatment able are available on request.

omposition: Salicylic Acid, USP, 16.7% and Lactic Acid, USP, 6.7% in Flexible Collodion, USP.

ndications: DUOFILM is indicated as a keratolytic agent for the re- oval of benign epithelial tumors such as common warts.

osage and Administration: Prior to the application of DUOFILM, oak the affected area in hot water for at least five minutes. Dry horoughly with a clean towel.

pply DUOFILM directly to the wart using the plastic applicator. Each rop should be permitted to dry before re-application of the liquid. are should be taken to see that DUOFILM is not applied to the sur- ounding skin. A Band-Aid® or similar bandage should then be pplied lightly.

reatment should take place once daily and continue as directed by hysician.

ontraindications: Diabetics or patients with impaired blood circu- ation should not use DUOFILM. Do not use on moles, birthmarks or nusual warts with hair growing from them.

recautions: For external use only.

UOFILM is highly flammable and should be kept away from fire or lame. Keep bottle tightly capped when not in use. Store at con- rolled room temperature.

f spilled on mucous membranes or in eyes, flush with water, remove recipitated collodion, and flush with water for an additional 15 inutes.

eep this and all medication out of the reach of children.

ow Supplied: DUOFILM is available in ½ oz. bottles with plastic pplicators.

aution: Federal law prohibits dispensing without a prescription.

1. Bunney, M.H.; Nolan, M.W.; Williams, D.A.: An assessment of methods of treating viral warts by comparative treatment trials based on a standard design. *Brit. J. Derm.* **94**, 667, 1976.
2. Rees, R.B.: Post-graduate course in Dermatology, sponsored by Cleveland Clinic and U. of Cal., San Fran., Nov. 5-10, 1976, Maui, Hawaii.
3. Arndt, K.A.: Double-blind study of salicylic and lactic acid lotion in treating warts. Study on file at Stiefel Research Institute.

STIEFEL
Logical Dermatologicals since 1847

Stiefel Laboratories, Inc.,
Oak Hill, N.Y. 12460
Stiefel Laboratories (Canada) Ltd.,
St. Laurent, Quebec, Canada H4R 1E1

9-1085

You don't have to ask your patients to sacrifice their skin to effectively treat their acne.

Use Persa-Gel.



A clinical test* shows Persa-Gel to be as effective as tretinoin cream in the lowering of the lesion count (pustules, papules and comedones), on unselected patients, **without** excessive erythema and peeling.

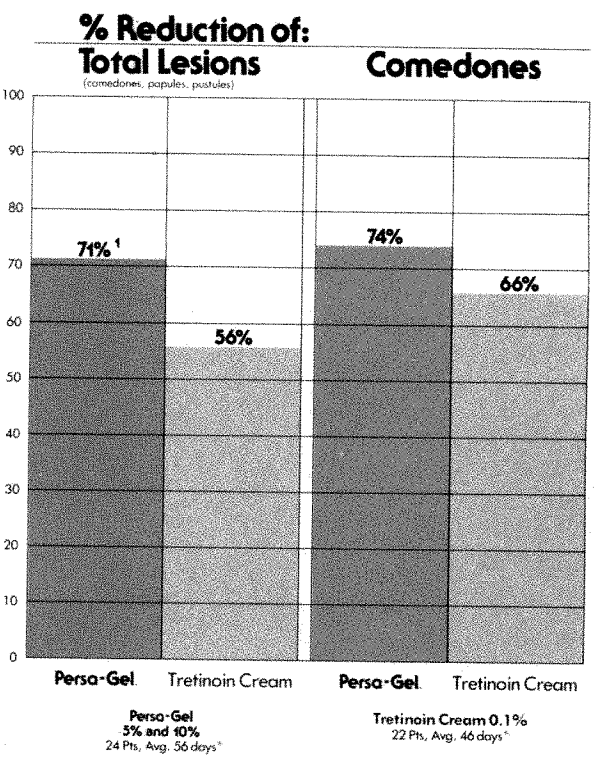

*Data on file, Texas Pharmacal Company.
See next page for full prescribing information.

Persa-Gel™
(BENZOYL PEROXIDE)
Unique Acetone Gel 5% and 10%

TPC
TEXAS PHARMACAL COMPANY
San Antonio, Texas 78296

Unique acetone base enhances stability and cosmetic acceptability.

Two and one-half year dating
No refrigeration required

CAUTION: Federal law prohibits dispensing without prescription.
DESCRIPTION: Persa-Gel™ 5% contains 5% benzoyl peroxide; Persa-Gel™ 10% contains 10% benzoyl peroxide; in a gel base containing acetone, carboxyvinyl polymer, triethanolamine, sodium lauryl sulfate, propylene glycol and purified water.
ACTIONS: Benzoyl peroxide is primarily effective because of its drying, peeling and antiseptic action.
INDICATION: For adjunctive topical therapy of acne vulgaris.
CONTRAINDICATIONS: Benzoyl peroxide is contraindicated in patients with acute inflammation and in patients with a history of hypersensitivity to any of the components of the preparation.
PRECAUTIONS: If excessive irritation develops, discontinue use and institute appropriate therapy. After the reaction clears, treatment may often be resumed with less frequent applications. Avoid contact with eyes, eyelids, lips and other mucous membranes, and anterior neck. May bleach hair and colored fabrics.
ADVERSE REACTIONS: Allergic contact dermatitis and severe erythema with crusting have been reported with topical benzoyl peroxide.
DOSAGE AND ADMINISTRATION: Persa-Gel™ (benzoyl peroxide) should be applied thinly to cover affected area after cleansing with non-medicated soap and water or a degreaser. Initial application once daily before bedtime is recommended, increasing to twice daily as tolerance develops. Feelings of warmth and stinging and slight erythema may be noted initially. It is advisable to initiate therapy with Persa-Gel™ 5% shifting to the use of Persa-Gel™ 10% after 3 or 4 weeks, or earlier if tolerance to the 5% has been determined. Therapeutic results are usually seen within 2 weeks with continued improvement thereafter.
HOW SUPPLIED: Persa-Gel™ 5% 1.5 oz. tubes (NDC0064-8610-31)
Persa-Gel™ 10% 1.5 oz. tubes (NDC0064-8600-31)

Persa-Gel™
(BENZOYL PEROXIDE)
Unique Acetone Gel 5% and 10%

TEXAS PHARMACAL COMPANY
San Antonio, Texas 78296



Let's dispense with unusual amenities.

Cryo-surgery is a highly specialized science and surgical skill. And of course liquid nitrogen storage is especially critical.

Cryenco Biostat® Model 350 LN_2 dispensing dewars are unsurpassed in the field for efficiency, durability and dependability.

Each Model 350 is hand-crafted with long-life stainless steel outer shell construction and a 2-year warranty.

Engineered for consistant service, Model 350 dispenses LN_2 conveniently and efficiently for dermatological use and boasts a working duration of up to 3 months, without a refill.

Engineering, service and design features all add up to a storage facility with truly unusual advantages. Write today for a free catalog or contact your local Cryenco representative.

Cryenco
A HELIX COMPANY

Sales Division / 11055 Leroy Drive
Denver, Colorado 80233 (303) 451-1031

ROCHE

Roche Laboratories announces an additional therapeutic application for Efudex® 5% Cream fluorouracil/Roche

now indicated for superficial basal cell carcinoma

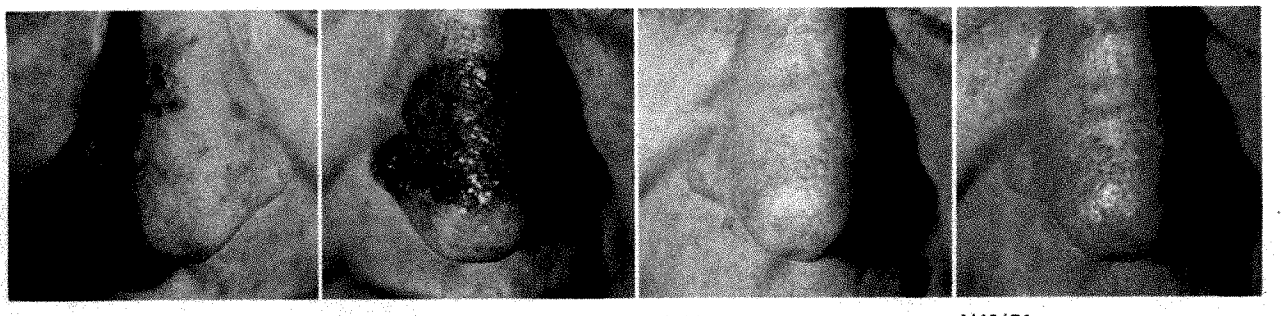

8/8/69
Before treatment a superficial, scaly, slightly excoriated lesion was present. Biopsy revealed the lesion to be a superficial basal cell carcinoma.

9/25/69
After 7 weeks of treatment with Efudex (fluorouracil) 5% Cream, lesion site is clearly delineated, markedly erythematous; surrounding skin shows no reaction to medication. Treatment terminated.

12/10/70
Follow-up approximately 14 months after treatment; healing has occurred with minimal scarring.

4/18/74
Patient has been followed continuously since treatment. **No evidence of recurrence.**

Efudex (fluorouracil) 5% Cream is recommended as an effective topical alternative to surgery for multiple lesions and difficult treatment sites.

A proven cytotoxic agent that exerts a marked effect on cells that grow more rapidly.

Cosmetically gratifying results, with minimal or no scarring. No systemic toxicity. Normal tissue rarely affected. Convenient, economical b.i.d. application.

Prolonged exposure to ultraviolet light may accelerate reaction to medication. If an occlusive dressing is used, there may be an increase in the incidence of inflammatory reactions in the adjacent normal skin.

An exclusive Roche formulation

Efudex® 5% Cream

fluorouracil/Roche

Before prescribing, please consult complete product information, a summary of which follows:
Indications: Multiple actinic or solar keratoses; superficial basal cell carcinomas when conventional methods are impractical (5% strength only).
Contraindications: If occlusive dressing is used, may increase inflammatory reactions in adjacent normal skin. Avoid prolonged exposure to ultraviolet rays. Safe use in pregnancy not established.
Precautions: If applied with fingers, wash hands immediately. Apply with care near eyes, nose and mouth. Solar keratoses failing to respond should be biopsied; perform follow-up biopsies in superficial basal cell carcinoma.
Adverse Reactions: Local—pain, pruritus, hyperpigmentation and burning at application site most frequent; also dermatitis, scarring, soreness, tenderness, suppuration, scaling and swelling. Also reported—insomnia, stomatitis, irritability, medicinal taste, photosensitivity, lacrimation, telangiectasia, leukocytosis, thrombocytopenia, toxic granulation and eosinophilia.
Dosage and Administration: *Actinic or solar keratosis*—apply sufficient quantity to cover lesions, twice daily. Usual length of therapy is 2 to 4 weeks. *Superficial basal cell carcinomas*—apply sufficient quantity **(only 5% strength recommended)** to cover lesions, twice daily. Continue treatment for at least 3 to 6 weeks, but possibly as long as 10 to 12.
How Supplied: Solution, 10-ml drop dispensers containing 2% or 5% fluorouracil on a weight/weight basis. Cream, 25-Gm tubes containing 5% fluorouracil in a vanishing cream base.

ROCHE

Roche Laboratories
Division of Hoffmann-La Roche I
Nutley, New Jersey 07110

Gets to deep fungal infections

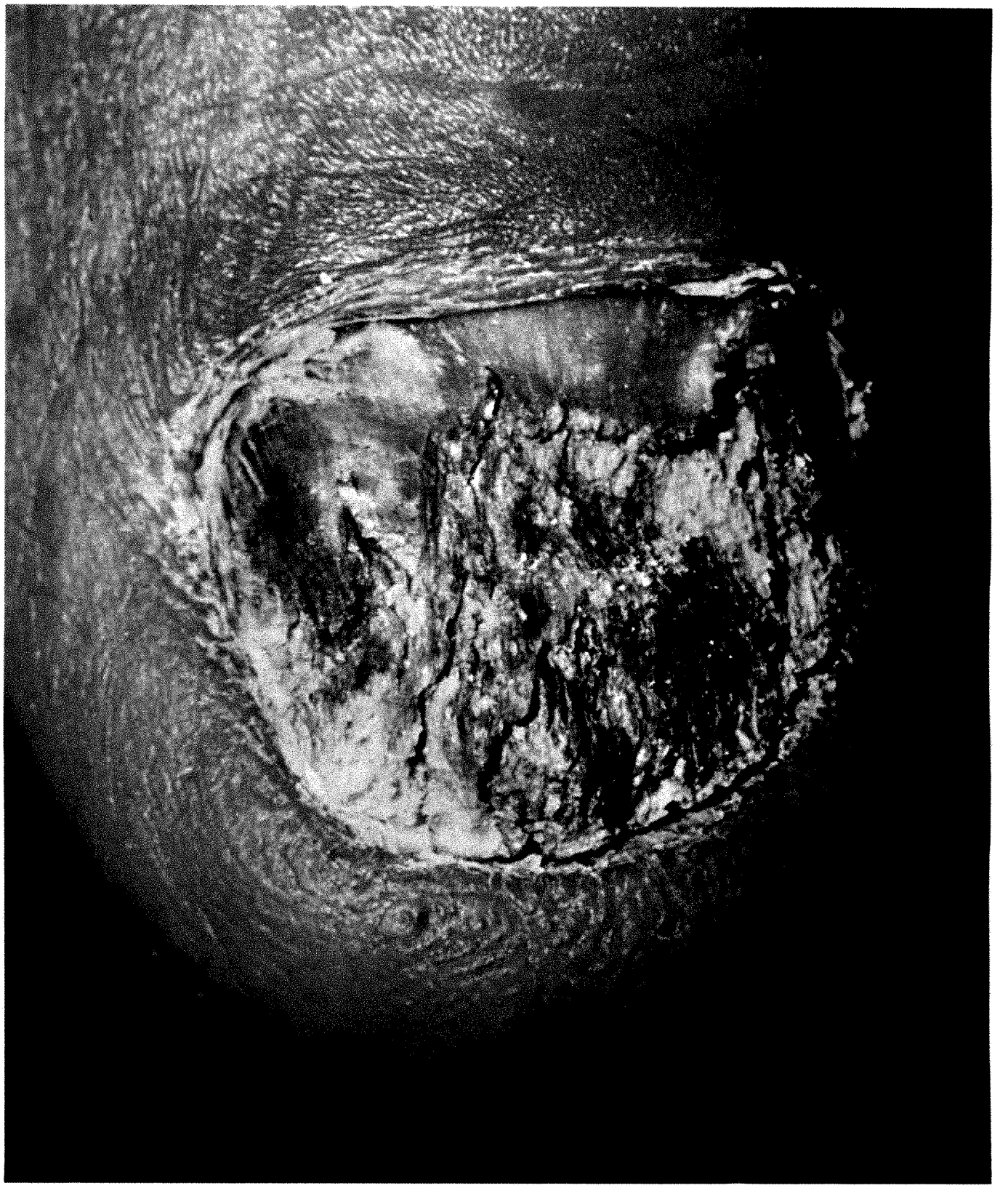

Actual photograph of tinea unguium infection (onychomycosis).
Note typical worm-eaten appearance of fingernail destroyed by fungus.

when topicals can't.

Potent, systemic fungistat

GRISACTIN provides the antifungal activity needed to control tinea infections, including onychomycosis, that invade the dermis and deeper regions. Systemic action penetrates where topical action often fails.

GRISACTIN is effective against a wide range of fungi: *Trichophyton rubrum, T. mentagrophytes, T. tonsurans, T. interdigitalis, T. verrucosum, T. megnini, T. gallinae, T. crateriform, T. sulphureum, T. schoenleini, Microsporum canis, M. audouini, M. gypseum,* and *Epidermophyton floccosum.*

Peak serum levels are usually produced in about four hours with a single 500 mg. tablet. To meet the requirements of different patients—depending on body weight, age, severity, and location of infection—dosage is easily individualized with 125 mg. and 250 mg. capsules, and 500 mg. tablets.

Grisactin® 500

BRAND OF

griseofulvin (microsize) TABLETS

BRIEF SUMMARY
(For full prescribing information, see package circular.)

Grisactin®
Brand of
Griseofulvin (microsize)

Indications: Griseofulvin is indicated for the treatment of ringworm infections of the skin, hair, and nails, namely: *Tinea corporis, Tinea pedis, Tinea cruris, Tinea barbae, Tinea capitis, Tinea unguium* (onychomycosis) when caused by one or more of the following genera of fungi: *Trichophyton rubrum, T. tonsurans, T. mentagrophytes, T. interdigitalis, T. verrucosum, T. megnini, T. gallinae, T. crateriform, T. sulphureum, T. schoenleini, Microsporum audouini, M. canis, M. gypseum, Epidermophyton floccosum.*
NOTE: Prior to therapy, the type of fungi responsible for the infection should be identified.
The use of this drug is not justified in minor or trivial infections which will respond to topical agents alone.
Griseofulvin is *not* effective in the following: Bacterial infections, candidiasis (moniliasis), histoplasmosis, actinomycosis, sporotrichosis, chromoblastomycosis, coccidioidomycosis, North American blastomycosis, cryptococcosis (torulosis), *Tinea versicolor,* nocardiosis.
Contraindications: This drug is contraindicated in patients with porphyria, hepatocellular failure, and in individuals with a history of hypersensitivity to griseofulvin.
Warnings: *Prophylactic Usage*—Safety and efficacy of griseofulvin for prophylaxis of fungal infections has not been established.
Animal Toxicology—Chronic feeding of griseofulvin, at levels ranging from 0.5-2.5% of the diet, resulted in the development of liver tumors in several strains of mice, particularly in males. Smaller particle sizes result in an enhanced effect. Lower oral dosage levels have not been tested. Subcutaneous administration of relatively small doses of griseofulvin, once a week, during the first three weeks of life has also been reported to induce hepatomata in mice. Although studies in other animal species have not yielded evidence of tumorigenicity, these studies were not of adequate design to form a basis for conclusions in this regard.
In subacute toxicity studies, orally administered griseofulvin produced hepatocellular necrosis in mice, but this has not been seen in other species. Disturbances in porphyrin metabolism have been reported in griseofulvin-treated laboratory animals. Griseofulvin has been reported to have a colchicine-like effect on mitosis and cocarcinogenicity with methylcholanthrene in cutaneous tumor induction in laboratory animals.
Usage in Pregnancy—The safety of this drug during pregnancy has not been established.
Animal Reproduction Studies—It has been reported in the literature that griseofulvin was found to be embryotoxic and teratogenic on oral administration to pregnant rats. Pups with abnormalities have been reported in the litters of a few bitches treated with griseofulvin. Additional animal reproduction studies are in progress.
Suppression of spermatogenesis has been reported to occur in rats, but investigation in man failed to confirm this.
Precautions: Patients on prolonged therapy with any potent medication should be under close observation. Periodic monitoring of organ system function, including renal, hepatic, and hematopoietic, should be done.
Since griseofulvin is derived from a species of Penicillium, the possibility of cross-sensitivity with penicillin exists; however, known penicillin-sensitive patients have been treated without difficulty.
Since a photosensitivity reaction is occasionally associated with griseofulvin therapy, patients should be warned to avoid exposure to intense natural or artificial sunlight. Should a photosensitivity reaction occur, lupus erythematosus may be aggravated.
Griseofulvin decreases the activity of warfarin-type anticoagulants so that patients receiving these drugs concomitantly may require dosage adjustment of the anticoagulant during and after griseofulvin therapy.
Barbiturates usually depress griseofulvin activity and concomitant administration may require a dosage adjustment of the antifungal agent.
Adverse Reactions: When adverse reactions occur, they are most commonly of the hypersensitivity type such as skin rashes, urticaria, and rarely, angioneurotic edema, and may necessitate withdrawal of therapy and appropriate countermeasures. Paresthesias of the hands and feet have been reported rarely after extended therapy. Other side effects reported occasionally are oral thrush, nausea, vomiting, epigastric distress, diarrhea, headache, fatigue, dizziness, insomnia, mental confusion, and impairment of performance of routine activities.
Proteinuria and leukopenia have been reported rarely. Administration of the drug should be discontinued if granulocytopenia occurs.
When rare, serious reactions occur with griseofulvin, they are usually associated with high dosages, long periods of therapy, or both.
Dosage and Administration: Accurate diagnosis of the infecting organism is essential. Medication must be continued until the infecting organism is completely eradicated as indicated by appropriate clinical or laboratory examination. General measures in regard to hygiene should be observed to control sources of infection or reinfection. Concomitant use of appropriate topical agents is usually required, particularly in treatment of *tinea pedis.*
Dosage should be individualized, depending on age and severity of infection. *Adults*—0.5 Gm. daily (125 mg. q.i.d., 250 mg. b.i.d., or 500 mg./day). *Children*—10 mg./kg. daily is usually adequate (from 30 to 50 lb., 125 mg. to 250 mg. daily; over 50 lb., 250 mg. to 500 mg. daily, in divided doses).
How Supplied: GRISACTIN [griseofulvin (microsize)]—No. 442—GRISACTIN 125, each capsule contains 125 mg., in bottles of 100 and 500. No. 443—GRISACTIN 250, each capsule contains 250 mg., in bottles of 100 and 500. No. 444—GRISACTIN 500, each tablet (scored) contains 500 mg., in bottles of 60.

Ayerst

Ayerst Laboratories
New York, N.Y. 10017

7719

anti-
inflammatory
antifungal
antipruritic
antibacterial

Clear choice

When dermatoses become infected with bacteria or fungi, plain topical steroids are generally not the recommended therapeutic choice.

A clear choice, however, is Vioform®-Hydrocortisone. With its unique four-way action, it supplies the kind of comprehensive treatment many common dermatoses* require.

*This drug has been evaluated as possibly effective for these indications. See brief prescribing information.

Vioform®-Hydrocortisone (iodochlorhydroxyquin and hydrocortisone)

INDICATIONS
Based on a review of this drug by the National Academy of Sciences-National Research Council and/or other information, FDA has classified the indications as follows:
"Possibly" effective: Contact or atopic dermatitis; impetiginized eczema; nummular eczema; infantile eczema; endogenous chronic infectious dermatitis; stasis dermatitis; pyoderma; nuchal eczema and chronic eczematoid otitis externa; acne urticata; localized or disseminated neurodermatitis; lichen simplex chronicus; anogenital pruritus (vulvae, scroti, ani); folliculitis; bacterial dermatoses; mycotic dermatoses such as tinea (capitis, cruris, corporis, pedis); moniliasis; intertrigo.
Final classification of the less-than-effective indications requires further investigation.

CONTRAINDICATIONS
Hypersensitivity to Vioform-Hydrocortisone, or any of its ingredients or related compounds; lesions of the eye; tuberculosis of the skin; most viral skin lesions (including herpes simplex, vaccinia, and varicella).

WARNINGS
This product is not for ophthalmic use.
In the presence of systemic infections, appropriate systemic antibiotics should be used.

Usage in Pregnancy
Although topical steroids have not been reported to have an adverse effect on pregnancy, the safety of their use in pregnant females has not been established. Therefore, they should not be used extensively on pregnant patients in large amounts or for prolonged periods of time.

PRECAUTIONS
May prove irritating to sensitized skin in rare cases. If this occurs, discontinue therapy. May stain.
If used under occlusive dressings or for a prolonged period, watch for signs of pituitary-adrenal axis suppression.
May interfere with thyroid function tests. Wait at least one month after discontinuance of therapy before performing these tests. The ferric chloride test for phenylketonuria (PKU) can yield a false-positive result if Vioform is present in the diaper or urine.
Prolonged use may result in overgrowth of nonsusceptible organisms requiring appropriate therapy.

ADVERSE REACTIONS
Few reports include: Hypersensitivity, local burning, irritation, pruritus. Discontinue if untoward reaction occurs. Rarely, topical corticosteroids may cause striae at site of application when used for long periods in intertriginous areas.

DOSAGE
Apply a thin layer to affected areas 3 or 4 times daily.

HOW SUPPLIED
Cream, 3% iodochlorhydroxyquin and 1% hydrocortisone in a water-washable base containing stearyl alcohol, cetyl alcohol, stearic acid, petrolatum, sodium lauryl sulfate, and glycerin in water; tubes of 5 and 20 Gm. *Ointment,* 3% iodochlorhydroxyquin and 1% hydrocortisone in a petrolatum base; tubes of 20 Gm. *Lotion,* 3% iodochlorhydroxyquin and 1% hydrocortisone in a water-washable base containing stearic acid, cetyl alcohol, lanolin, propylene glycol, sorbitan trioleate, polysorbate 60, triethanolamine, methylparaben, propylparaben, and perfume Flora in water; plastic squeeze bottles of 15 ml. *Mild Cream,* 3% iodochlorhydroxyquin and 0.5% hydrocortisone in a water-washable base containing stearyl alcohol, cetyl alcohol, stearic acid, petrolatum, sodium lauryl sulfate, and glycerin in water; tubes of ½ and 1 ounce. *Mild Ointment,* 3% iodochlorhydroxyquin and 0.5% hydrocortisone in a petrolatum base; tubes of 1 ounce.
C75-38 Rev. 7/75

Consult complete product literature before prescribing.

CIBA Pharmaceutical Company
Division of CIBA-GEIGY Corporation
Summit, New Jersey 07901

2/7853 17

Vioform®-Hydrocortisone (iodochlorhydroxyquin and hydrocortisone)

The most widely prescribed form... 20-Gm Cream



CIBA

what's best for the care of dry, or premature aging or wrinkled skin... DUE TO EPIDERMAL DEHYDRATION?

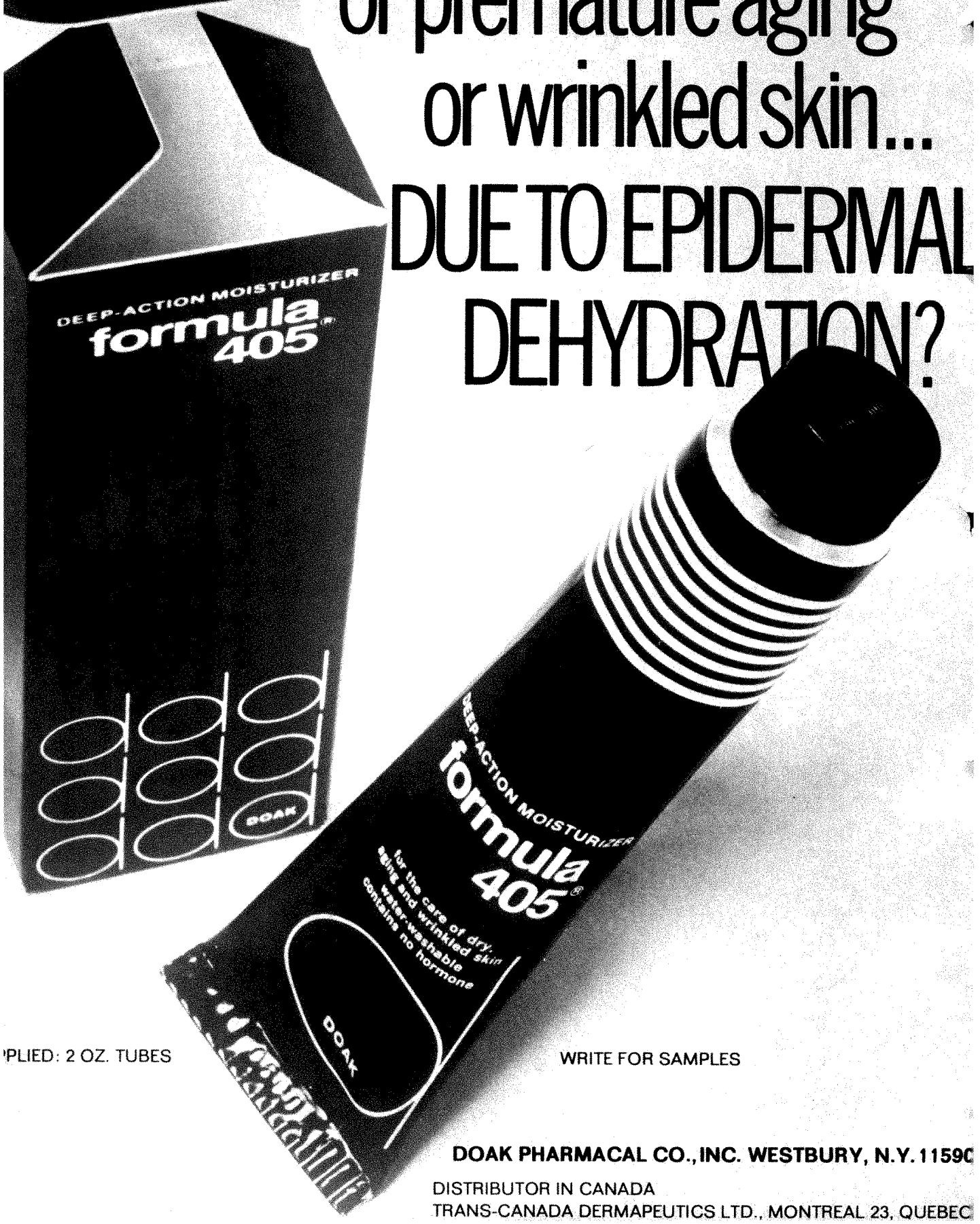

PLIED: 2 OZ. TUBES

WRITE FOR SAMPLES

DOAK PHARMACAL CO., INC. WESTBURY, N.Y. 1159C

DISTRIBUTOR IN CANADA
TRANS-CANADA DERMAPEUTICS LTD., MONTREAL 23, QUEBEC

IN SKIN INFECTIONS, WHERE CLEANLINESS REQUIRES MORE THAN SOAP

BETADINE® Skin Cleanser

Degerms as it cleanses

Patients can use BETADINE Skin Cleanser to degerm and cleanse face, hands and body, gently and thoroughly—particularly when it is essential to prevent autoinoculation of new sites, as may be the case in infected acne pimples.

BETADINE Skin Cleanser, with its rich, golden lather, provides these advantages:

- Prompt, broad-spectrum microbicidal action—kills both gram-positive and gram-negative bacteria (including antibiotic-resistant strains), fungi, viruses, protozoa and yeasts.
- Maintains microbicidal activity in the presence of blood, pus and serum.
- Virtually nonirritating to skin and mucosa.*
- Nonstaining to skin and natural fabrics.

Supplied: 4 fl. oz. plastic bottles.

*In the rare instance of local irritation or sensitivity, discontinue use by the individual.

Purdue Frederick © COPYRIGHT 1976, THE PURDUE FREDERICK COMPANY

NORWALK, CONN. 06856 A8196 172076



The little book no mother should be without.

What? Buy another book on child-raising when you've already covered the subject from Spock to Salk?

What makes this little paperback different? It gives you in concise, capsule form what other books take pages of thumbing through and reading to give—authoritative answers to your questions on child-raising.

Published by the American Medical Association, GROWING PAINS is a quick reference guide to most of the questions you're likely to have about your child's physical, mental and emotional development and problems.

In it, respected pediatricians answer commonly asked questions about diet and eating habits, sibling relations, emotional problems, discipline and punishment, toilet training, speech disorders, sex education and dozens more.

Shouldn't you have a copy? To order yours, use the coupon on the right.

American Medical Association
535 No. Dearborn Street
Chicago, Ill. 60610

Price:
$2.00 (U.S., U.S. Possessions, Canada, Mexico)
$2.50 (All other countries)

Please send me _____ copy(ies) of GROWING PAINS, OP-244. Enclosed is $_____. Payment must accompany order.

Name_____
Address_____
City/State/Zip_____

S/J

HALOG® CREAM (Halcinonide Cream 0.1%)

Each gram of Halog Cream (Halcinonide Cream 0.1%) contains 1 mg. halcinonide (0.1%) in a cream base.

INDICATIONS: This product is intended for topical application for adjunctive therapy and symptomatic relief of inflammatory manifestations of acute and chronic corticosteroid responsive dermatoses.

CONTRAINDICATIONS: Topical steroids are contraindicated in vaccinia, varicella, and in those patients with a history of hypersensitivity to any of the components of the preparation. This preparation is not for ophthalmic use.

PRECAUTIONS: *General*—If local infection exists, suitable concomitant antimicrobial or antifungal therapy should be administered. If a favorable response does not occur promptly, application of the corticosteroid should be discontinued until the infection is adequately controlled. Although systemic side effects associated with absorption of topical corticosteroid preparations are rare, their possible occurrence must be kept in mind when these preparations are used over large areas or for an extended period of time. If irritation or sensitization develops, the preparation should be discontinued and appropriate therapy instituted. Although topical steroids have not been reported to have an adverse effect on pregnancy, the safety of their use during pregnancy has not been absolutely established; therefore, they should not be used extensively on pregnant patients, in large amounts, or for prolonged periods of time.

Occlusive Dressing Technique—The use of occlusive dressing increases the percutaneous absorption of corticosteroids; their extensive use increases the possibility of systemic effects. For patients with extensive lesions it may be preferable to use a sequential approach, occluding one portion of the body at a time. The patient should be kept under close observation if treated with the occlusive technique over large areas and over a considerable period of time. Occasionally, a patient who has been on prolonged therapy, especially occlusive therapy, may develop symptoms of steroid withdrawal when the medication is stopped. Thermal homeostasis may be impaired if large areas of the body are covered. Use of the occlusive dressing should be discontinued if elevation of the body temperature occurs. Occasionally, a patient may develop a sensitivity reaction to a particular occlusive dressing material or adhesive and a substitute material may be necessary. If infection develops, discontinue the use of the occlusive dressing and institute appropriate antimicrobial therapy.

ADVERSE REACTIONS: The following local adverse reactions have been reported with topical corticosteroids: burning, itching, irritation, striae, skin atrophy, secondary infection, dryness, folliculitis, hypertrichosis, acneform eruptions, and hypopigmentation. The following may occur more frequently with occlusive dressings: maceration of the skin, secondary infection, skin atrophy, striae, and miliaria. Contact sensitivity to a particular dressing material or adhesive may occur occasionally (see PRECAUTIONS).

For full prescribing information, consult package insert.

HOW SUPPLIED: In tubes of 15 and 60 g. and in jars of 240 g. (8 oz.).

SQUIBB® The Priceless Ingredient of every product is the honor and integrity of its maker.™

© 1977 E.R. Squibb & Sons, Inc. 357-503

Pruritus relieved "within 24 hours"

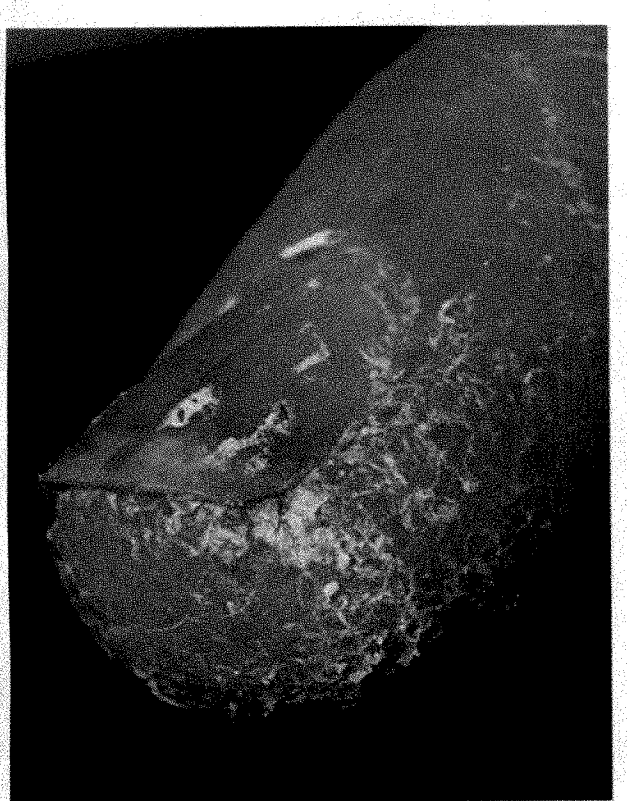

Eczematoid Dermatitis

Condition of six months' duration. Patient complaining of acute itching and soreness of finger. Examination revealed erythematous, eroded, fissured, scaling and crusted dermatitis. KOH test negative for fungal hyphae; no other skin involvement or history of skin problems.

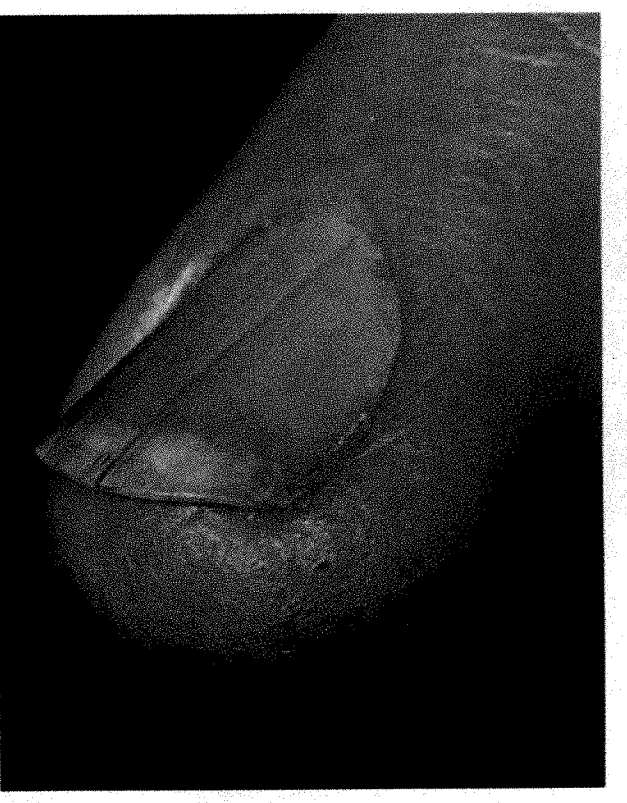

After 1 week

Halog 0.1% Cream applied twice daily. Patient reported pruritus relieved within 24 hours after first application of cream. Examination showed essentially complete resolution of dermatitis. Halog Cream discontinued and patient discharged.

Case history on file at Squibb Institute for Medical Research.

after Halog® Cream b.i.d

Halcinonide Cream 0.1%

See adjacent **SQUIBB®** column for brief summary.

Pernox® Can Improve an Acne Lesion in Two Days

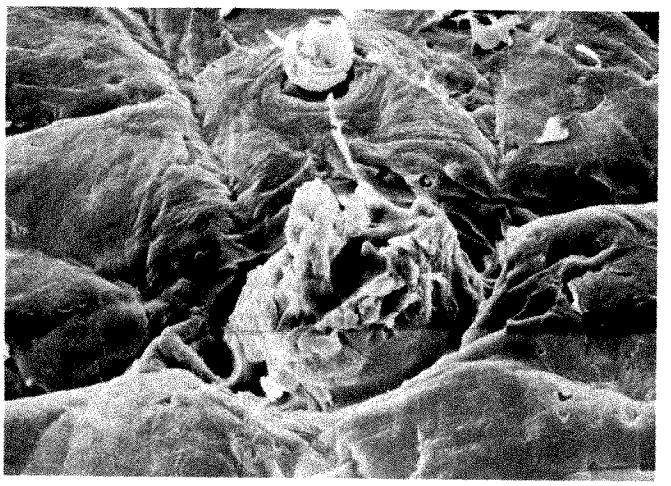

BEFORE TREATMENT: Comedo plugged with keratinous debris. (Scanning electron microscopy courtesy of Structure Probe Inc.)

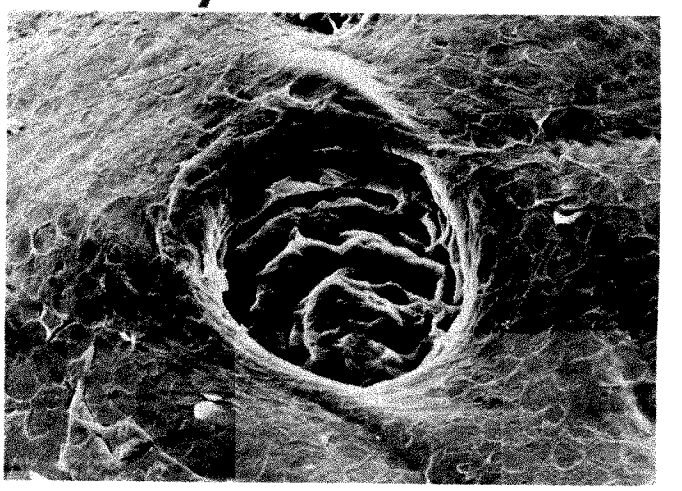

AFTER 2 DAYS (Two one-minute Pernox® Scrub washes daily): Depth of orifice indicates removal of plug in large central comedo.

When we formulated Pernox® Scrub, we had a goal in mind. Make it abradant . . . a harsh word, yet make it smooth for acne skin. Pernox accomplishes just that.

Washing varies from patient to patient. You determine the regimen by frequency of washing and the amount of water used during the wash.

Patients respond to Pernox rapidly, often noticing improvement after the first wash. The unique combination of ingredients in Pernox emulsifies oil and dries affected areas, contributing to this success.

Two pleasant forms, regular and lemon-scented scrub and lemon-scented lotion offer you a choice for your patients' therapy.

Pernox . . . an acne regimen formulated to give you more than you're now getting from your present acne scrub.

PERNOX®

Scrub/Lotion

Lathering Scrub Cleanser for Acne

Pernox Scrub, Regular and Lemon-Scented in 2 and 4 oz. plastic tubes.

New Lemon-Scented Pernox Lotion in 6 oz. bottles.

The Abradant of Choice

WESTWOOD
PHARMACEUTICALS INC.
Buffalo, New York 14213

©1977, W.P. Inc.

Unusual Variant of Lupus Erythematosus or Lichen Planus

Clinical, Histopathologic, and Immunofluorescent Studies

Robert W. Romero, MD; Lee T. Nesbitt, Jr, MD; Richard J. Reed, MD

• Eleven patients with a skin disorder in which clinical, histopathologic, and immunofluorescent findings showed overlap features of both lupus erythematosus (LE) and lichen planus (LP) were observed for several years.

Clinical lesions were extremely long-term and consisted primarily of livid red to violaceous atrophic patches and plaques, most common on acral aspects of the extremities. Nails were also commonly involved, often showing anonychia.

Histologic changes combined cell-rich and cell-poor lichenoid patterns in the papillary dermis, suggesting both LP and LE. The major immunofluorescent finding in all patients was the presence of ovoid bodies at the dermal-epidermal (D-E) junction and in the upper dermis. Most patients showed both a linear arrangement and a clustering pattern of these bodies. Four patients also had coexistant but poorly developed linear deposits of immunoglobulins and complement at the D-E junction.

(*Arch Dermatol* 113:741-748, 1977)

Lupus erythematosus (LE) and lichen planus (LP) are two disorders affecting the skin that usually have different clinical, histopathologic, and immunofluorescent patterns. In occasional patients, however, the features of these two diseases may overlap.[1] Immunofluorescent studies in cases of this type have been infrequent. This report deals with 11 patients in whom the clinical, histopathologic, and immunofluorescent features in cutaneous lesions show overlap features between LE and LP, which in most instances cannot be clearly differentiated.

MATERIALS AND METHODS

During the period of 1969 to 1976, a total of 11 patients with a chronic skin disorder combining features of both LE and LP were observed and followed up in the dermatology clinic at Charity Hospital of Louisiana or the Veterans Administration Hospital in New Orleans. Clinical lesions from these patients were carefully studied and documented with photographs. Laboratory examinations were done to evaluate the patients for systemic LE.

Biopsy specimens from representative lesions were submitted for routine histopathology and direct immunofluorescent studies. Most patients had several biopsies for both types of examinations. Normal uninvolved skin was also taken from each patient for direct immunofluorescence.

For immunofluorescence studies, each specimen was immediately frozen in liquid nitrogen or placed in a recently described fixative solution.[2] Sections were cut at −20 C, placed on glass slides, and stained by fluorescent techniques previously described.[3] Conjugates consisted of commercially available lyophilized fluorescein-conjugated antihuman IgG, IgM, IgA, B_1C-B_1A (C3), and fibrinogen diluted 1:20, 1:5, 1:10, 1:5, and 1:2, respectively, with buffered saline and with fluorescein to protein ratios of 3.0, 3.3, 2.8, 2.3, and 2.8, respectively.

Accepted for publication Jan 6, 1977.

From the Department of Dermatology, Louisiana State University Medical Center (Drs Romero and Nesbitt), and the Department of Pathology, Tulane University School of Medicine (Dr Reed), New Orleans.

Reprint requests to Department of Dermatology, Louisiana State University Medical Center, 1542 Tulane Ave, New Orleans, LA 70112 (Dr Romero).

Clinical, Histopathologic, and Immunofluorescent Features of 11 Study Patients

Case/Race/Sex/Age, yr	Duration, yr	Clinical Features	Histopathology	Immunofluorescence
1/B/F/41	16	Livid red to violet atrophic ulcerative patches with telangiectasia and bullae: acral extremities, trunk, face, nails	Cell-rich & cell-poor patterns equally admixed; band-like infiltrate in some specimens with thickened basement membrane & liquefaction degeneration in others; numerous colloid bodies	Ovoid bodies: IgG, IgM; ANA negative*
2/B/M/49	21	Verrucoid atrophic erythematous to violaceous plaques with telangiectasia: palms, soles, dorsal hands, and feet, nails, trunk, penis	Cell-rich & cell-poor patterns admixed; thickened basement membrane in some & lichenoid cell-rich response in others	Ovoid bodies: IgG, IgM, C3; linear band on one occasion: IgG, IgM; ANA negative
3/B/F/72	2	Erythematous atrophic patches with hypopigmentation & hyperpigmentation & telangiectasia: face	Cell-rich pattern predominant but atrophy & follicular plugging in some areas.	Ovoid bodies: IgG, IgM, C3; ANA positive: 1:80; speckled
4/B/F/45	3	Atrophy & telangiectasia of proximal nail folds & nailbeds with loss of nail plates: nails only	Cell-rich pattern predominant with liquefaction degeneration & necrosis of keratinocytes, but basement membrane thickening & basal layer hypertrophy in others	Ovoid bodies: IgG, IgM; ANA negative
5/B/F/40	3	Atrophic erythematous to violaceous patches with hypopigmentation of distal phalanges & nailbeds & loss of nail plates; lower lip & oral mucosa also involved	Cell-rich pattern predominant, but with atrophy, liquefaction degeneration, telangiectasia, & numerous plasma cells	Ovoid bodies: IgG, IgM, C3; ANA negative
6/B/M/46	20	Erythematous atrophic areas with poikiloderma, mild follicular plugging, & nail dystrophy: nails, extremities, lip, face, scalp; oral mucosa also involved	Cell-rich & cell-poor patterns equally admixed with band-like infiltrate in some areas, & basement membrane thickening with few cells in others	Ovoid bodies: IgG, IgM, C3; ANA positive: 1:40; homogeneous
7/W/M/23	15	Atrophic, erythematous areas with hypopigmentation, telangiectasia, & anonychia: nail beds only	Cell-rich pattern predominant, but with atrophy, hyperkeratosis, & basement membrane thickening in several areas; numerous plasma cells	Ovoid bodies: IgG; ANA negative
8/W/M/58	7	Atrophic erythematous to violaceous areas with hypopigmentation, telangiectasia, scaling: dorsal hands, fingers, nails, extremities, neck	Cell-poor pattern predominant with thickened basement membrane, dermal fibrosis, & telangiectasia	Ovoid bodies: IgG; linear band on one occasion: IgG, IgM, C3; ANA negative
9/B/F/44	16	Erythematous atrophic plaques: arms, face, trunk	Cell-poor pattern predominant, but with cell-rich in some areas of papillary dermis & in perifollicular connective tissue	Ovoid bodies: IgM; linear band on one occasion: IgG, IgM, C3; ANA positive: 1:40; homogeneous
10/W/M/63	15	Atrophic violaceous to erythematous scaling plaques: dorsal hands, proximal nail folds, fingers, face, scalp	Cell-rich & cell-poor patterns admixed with smudgy basement membrane & thickening of blood vessel walls	Ovoid bodies: IgG, IgM; linear band on one occasion: IgG, IgM, C3; ANA negative
11/B/M/63	1.5	Atrophic violaceous scaling, plaques: face	Cell-rich pattern predominant, but with some areas showing thickened basement membrane	Ovoid bodies: IgG, IgM, C3; ANA negative

*ANA signifies antinuclear antibody.

CLINICAL FINDINGS

Clinical features are summarized in the Table. The lesions most commonly represented were large circumscribed atrophic patches and plaques with hypopigmentation and a livid red to blue-violet color, mild hyperpigmentation at the borders, minimal silvery scaling, fine telangiectasia, and a very thin epithelium that occasionally tended toward ulceration (Fig 1). Transient bullae occasionally occurred over a few lesions and some lesions developed a verrucoid surface. Follicular plugging was seem minimally in only two of these patients, and small lichenoid flattopped papules were not seen in any patients. Lesions tended to be fixed and stationary, and were generally poorly responsive to therapy, which consisted of topical and intralesional corticosteroids and systemic medications in a few patients, including corticosteroids, antimalarials, and immunosuppressive drugs. Pruritus was uncommon, but pain and tenderness were seen in lesions from some patients. Photosensitivity was not usually noted.

Lesions were most prominent on

the extremities, especially over acral aspects of extensor surfaces. Involvement of the skin of the distal phalanges and proximal nail fold areas with atrophy, severe nail dystrophy, and loss of some nail plates occurred in six cases (Fig 2). Palm and sole involvement was rather common (Fig 3). Lesions occurred on the face or trunk in some patients, but much less commonly and less extensive than on the extremities. Scalp involvement was seen in only two of our patients. Oral mucosal lesions, consisting of whitish to erythematous, slightly reticulated patches, occurred in two patients.

The disease process was notoriously chronic, having lasted for as many as 20 years in these patients with persistence of active lesions. There was an absence of clinical and laboratory evidence of systemic LE in most patients, with only three having low titer antinuclear antibody examinations and otherwise negative workup results for systemic LE. One patient (case 1) had coexistent rheumatoid arthritis with a very high titer rheumatoid factor. Systemic corticosteroids and immunosuppressive drugs were used to treat this patient, but gold therapy was never employed. Another patient (case 2) developed a deeply infiltrating squamous cell carcinoma of the sole of the foot on previously involved atrophic skin that eventuated in metastasis and death.

Fig 1.—Large atrophic lesions of hands with livid red to blue-violet color and tendency toward ulceration (case 1).

Fig 2.—Atrophy of nail beds and anonychia (Case 7).

Histopathology

In this discussion, lichenoid reaction is defined histologically as an inflammatory process that closely follows and extends across a basement membrane to produce lysis and destruction of epithelial cells.[4,5] This definition includes two basic patterns of lichenoid reactions pertinent in our cases, one of which is typified by the reaction seen usually in LP and the other by the reaction seen usually in LE.[5,6] In the former, the lichenoid pattern is substantially cellular, with lysis and dissolution of keratinocytes apparently mediated by aggressive lymphocytes. In the latter type, the histologic evidence for a role by aggressive lymphocytes migrating into the epidermis is meager, and lymphocytes do not comingle with keratinocytes in areas of their lysis and destruction. In the papillary dermal cell-rich variant (LP type), the dermal infiltrates are characteristically band-like, hug the epidermis, and extend across the basement membrane to attack keratinocytes. In the papillary dermal cell-poor variant (LE type), infiltrates tend to be perivascular in distribution, often

Fig 3.—Atrophic, hypopigmented lesions of palm with surrounding hyperpigmentation (case 6).

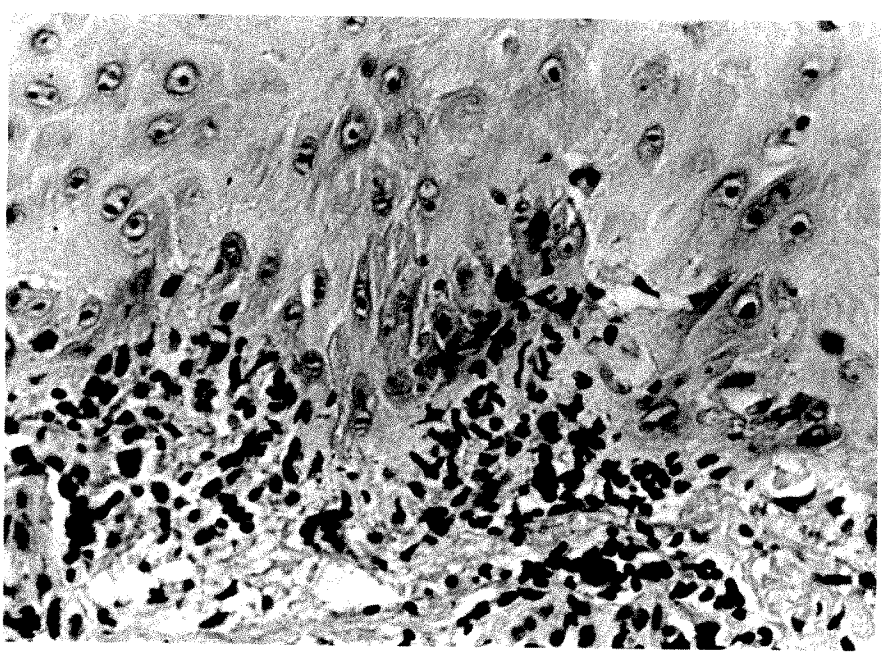

Fig 4.—Band-like lymphocytic infiltrate (cell-rich) that focally lyses basal keratinocytes and collects in irregular epidermal clefts (case 11) (hematoxylin-eosin, original magnification ×250).

are most prominent in perivascular areas of the reticular dermis, are spotty in the papillary dermis, and are loosely aggregated at the dermal-epidermal (D-E) junction. In some examples of LE, the thickened basement membrane appears to function as a barrier that confines infiltrates to the dermis and limits their migration into the epidermis.

In our 11 cases, both patterns are often represented in a single specimen, or multiple specimens from a single patient often show one or the other pattern. In these cases, the histologic differentiation between LP or LE is difficult. Major histologic features of each patient are summarized in the Table.

In five patients, the histologic pattern is predominantly a cell-rich response (Fig 4). Infiltrates of lymphocytes and histiocytes in the papillary dermis are band-like, hug the epidermis, and migrate across the basement membrane. The migrating lymphocytes concentrate in basal epidermal clefts and intermingle with clusters of necrotic keratinocytes (Fig 5). In spotty areas of some biopsy specimens, the epidermis shows mild liquefaction degeneration at the D-E junction but contains a loose infiltrate of lymphocytes. The epidermis usually is hyperplastic with compact hyperkeratosis and a prominent granular layer. In some lesions, the cell-rich pattern alternates with areas in which inflammatory cells are loosely aggregated in a widened fibrotic papillary dermis (Fig 6). In an occasional patient, multiple biopsy specimens have shown either a cell-rich pattern or a pattern of papillary dermal fibrosis.

In two patients, the biopsy material shows a predominant cell-poor pattern in the papillary dermis (Fig 7). The rete ridges are effaced and the basement membrane is often thickened. Vacuoles are distributed on both sides of the basement membrane. Lymphocytes are perivascular and loosely infiltrate the papillary dermis to cluster on the dermal side of the basement membrane. Lymphocytic infiltrates often are diffuse in the perifollicular sheaths and hug the follicles.

In four patients, the cell-poor and cell-rich patterns are admixed so that one pattern cannot be called predominant (Fig 8). Even in the two cases with a cell-poor pattern and in the five cases with a cell-rich pattern, there are commonly small foci in which the predominant pattern gives way to its counterpart, or several biopsy spec-

imens from different lesions in these patients show the opposite pattern in at least one specimen.

In addition to lymphocytes, plasma cells are a feature of the infiltrates in some of our specimens. These cells are found primarily in cell-rich reactions in our cases. Eosinophils are also seen in some of the dermal infiltrates in our patients.

In two cases, mucous membrane (oral) lesions had biopsies performed. In this material, the reaction is cell rich and contains numerous plasma cells.

Immunofluorescence

The Table also summarizes the immunofluorescent results. All 11 patients demonstrate deposits of IgG, IgM, and C3 in the form of fluorescent subepidermal ovoid or globular bodies on direct immunofluorescence of involved skin. These bodies are the major immunofluorescent finding in all specimens, and are found along the D-E junction zone and in the dermis, primarily in the papillary dermis, but occasionally extending into the upper third of the reticular dermis. The bodies are sharply defined, and are oval, round, or irregular in shape. In some specimens, the bodies have a greater tendency to hug the D-E junction zone (Fig 9), while in other specimens they are found primarily in aggregates or clusters extending well into the dermis (Fig 10 and 11). Both these patterns, however, are combined in several specimens, and multiple biopsy sections from the same patient often disclose one or the opposite pattern from specimen to specimen.

In addition to ovoid bodies, a coexistent but less prominent thin linear granular band of immunoglobulins and C3 is present along the D-E junction zone of involved skin in one of the biopsy specimens taken from four patients, but in specimens from other lesions in the same patients, only ovoid bodies without the presence of a linear band are noted. The four specimens with a fluorescent band suggest that feature seen usually in LE, but the linear deposits are poorly developed. Linear deposition of fibrinogen at the D-E zone, often seen in both LP and LE, is also present in many of the

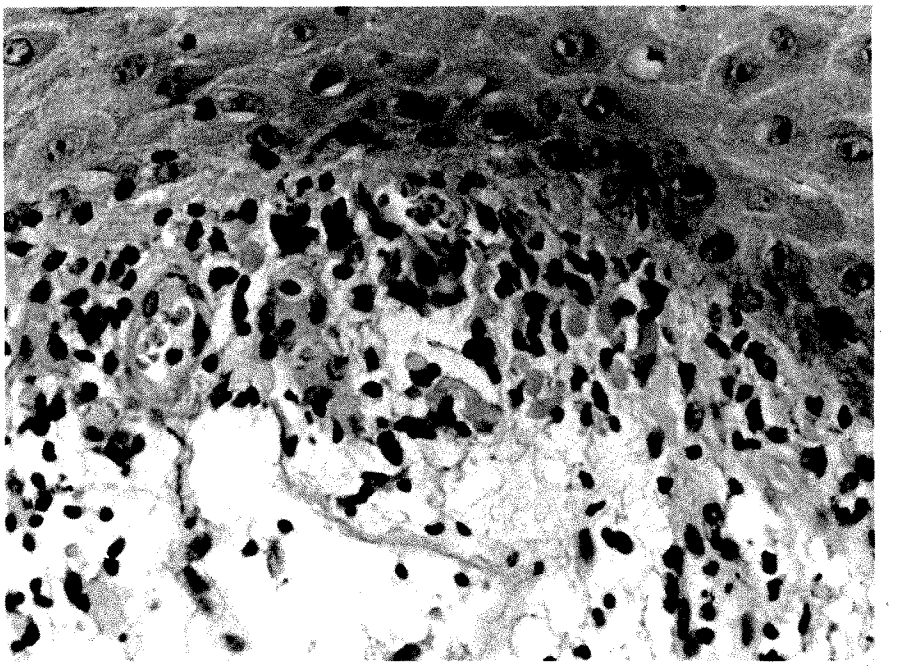

Fig 5.—Cell-rich pattern of lymphocytes in edematous papillary dermis admixed with colloid bodies. Infiltrate abuts upon keratinocytes without intervening basal layer (case 1), (hematoxylin-eosin, original magnification ×250).

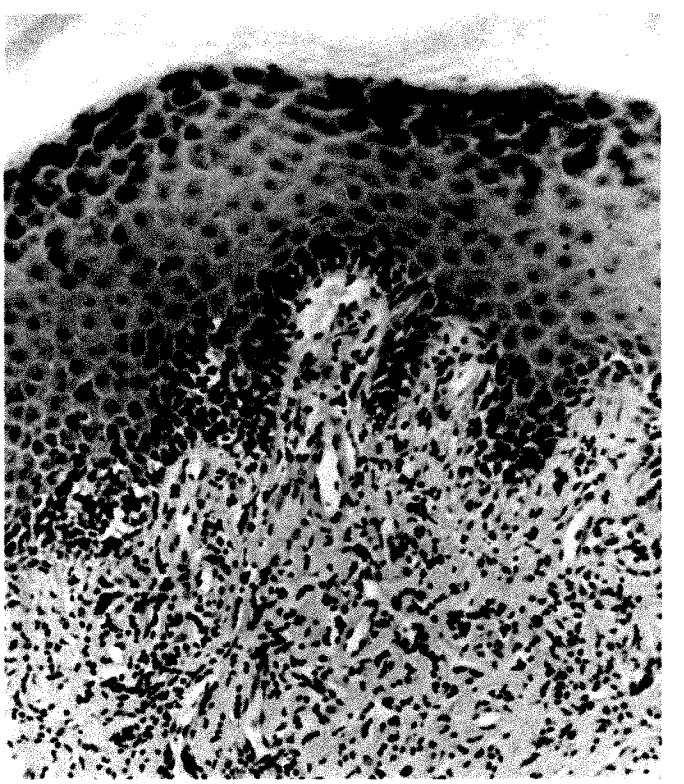

Fig 6.—Cell-rich lichenoid pattern with widened and fibrotic papillary dermis (case 4), (hematoxylin-eosin, original magnification ×120).

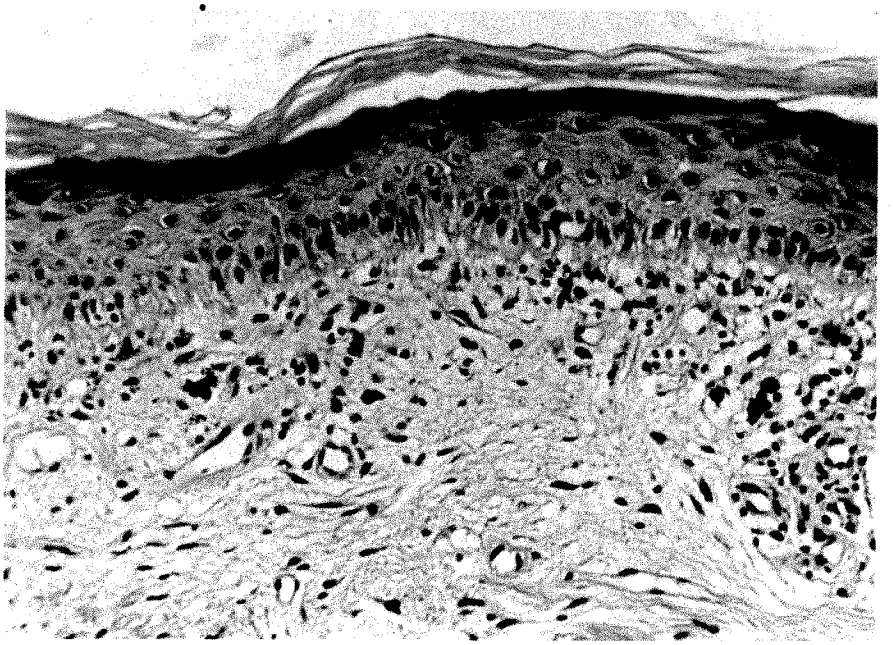

Fig 7.—Cell-poor pattern of lymphocytes confined to vascular adventitia and dermal side of basement membrane, which is thickened with vacuoles with tortuous capillaries (case 8) (hematoxylin-eosin, original magnification ×160).

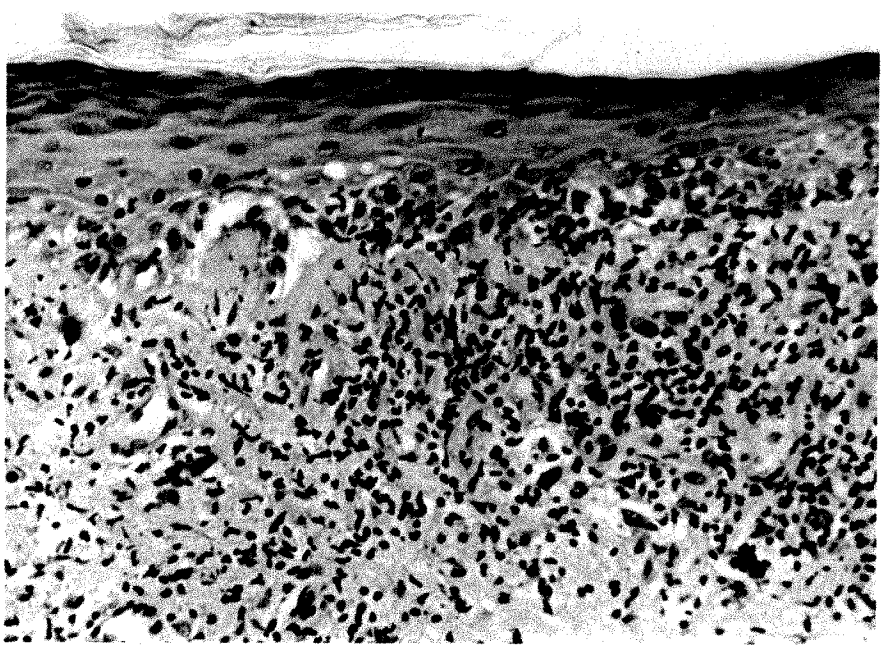

Fig 8.—Cell-rich lichenoid reaction (right) with effacement of rete and thickened basement membrane (left) more characteristic of cell-poor lichenoid pattern (case 6) (hematoxylin-eosin, original magnification ×160).

patients' skin lesions (Fig 12). Fluorescence confined to blood vessel walls or in a perivascular location is not noted in any of our biopsy specimens.

Normal uninvolved skin biopsy sections from each patient did not demonstrate deposition of immunoglobulins or C3 at any sites in any of the 11 patients.

COMMENT

The 11 patients in this report demonstrate a disease process with clinical, histopathologic, and immunofluorescent features suggesting both LE and LP, but in which a definitive diagnosis of one or the other disease cannot be made with certainty.

Clinical lesions in our patients were not diagnostic. Lichenoid flattopped papules typical of LP were not present. Follicular plugging and scalp involvement typical of LE were seen minimally in only two patients. Photosensitivity or pruritus was rarely a feature of our patients' skin lesions. Instead, the lesions tended to be most prominent on acral aspects of extensor surfaces of the extremities, and were characterized by livid red to violaceous atrophic patches and plaques. Nail involvement was commonly seen, as was involvement of the palms and soles. Lesions were extremely long-term, and generally responded poorly to most local and systemic treatment.

Histologically, LP and LE can commonly be separated on the basis of the concentration of lymphocytes in areas of keratinocyte damage.[6] In LP, the epidermis in sites of damage is heavily infiltrated with lymphocytes, and lysis of keratinocytes commonly produces clefts at the D-E junction zone. In LE, vacuoles form on both sides of a thickened basement membrane. They distort neighboring cells but seldom form clefts. Basement membrane thickening is a feature favoring a diagnosis of LE. Hyaline or colloid bodies can be seen in both LP and LE, but are usually more numerous and more compactly aggregated in LP. Two types of hyaline bodies have been identified[7]: (1) those of epidermal cell origin that can be shown to originate from degeneration of keratinocytes and that may be found in the epidermis and dermis, and (2) those originating from or continuous with thickened basement membrane that are found only along the D-E junction and in the uppermost dermis. Hyaline bodies of the first type occur in LP, but both types can be found in LE.[7]

Our patients show admixed features of cell-rich and cell-poor lichenoid patterns in the papillary dermis. There is variability in hyperkeratosis, acanthosis, epidermal atrophy, and

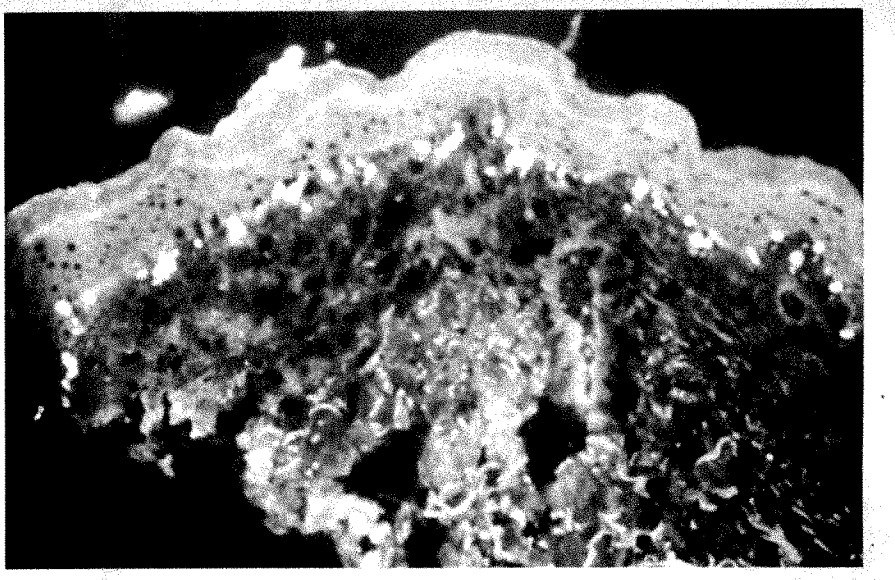

Fig 9.—Direct immunofluorescent specimen showing ovoid bodies in linear arrangement along dermal-epidermal junction suggesting lupus erythematosus pattern (case 3) (antihuman IgG staining, original magnification ×100).

follicular changes. Variability from specimen to specimen is also noted in degree of liquefaction degeneration of the basal layer, hyaline thickening of the basement membrane, and number of hyaline bodies present, with biopsy specimens from each patient more suggestive of LP in some instances and LE in others.

Certain histologic changes are seen in some specimens in our patients that are somewhat unusual for both LP and LE. These include a tendency toward papillary dermal fibrosis and increased numbers of plasma cells in the dermal infiltrates, both of which might be related to the chronicity and tendency toward ulceration of some lesions. Eosinophils are also seen in some of the dermal infiltrates, and have even caused us to consider lichenoid drug reactions in the histologic differential diagnosis.

Direct immunofluorescence of skin lesion biopsy specimens can commonly be used to separate typical cases of LE from LP. The LE lesions usually show a granular band of immunoglobulins and complement components in a linear pattern along the D-E junction,[8-10] and LP lesions almost always show fluorescent ovoid bodies in the D-E junction region and in the dermis.[11-13] Some LE lesions, however, may also show ovoid bodies alone or in conjunction with linear basement membrane fluorescence,[7,10,14] and LP lesions in one study showed linear D-E junction immunoglobulin and complement deposits in addition to fluorescent bodies.[13] In our typical cutaneous LE specimens, approximately 5% have shown only fluorescent bodies without linear staining, and these have usually been in long-standing lesions. All classes of immunoglobulins, complement, and sometimes fibrinogen may be deposited on the ovoid bodies. They correspond in size, shape, and anatomic location to the hyaline bodies seen histologically in LP and LE,[7,12] but they can be appreciated as being more numerous by fluorescence mi-

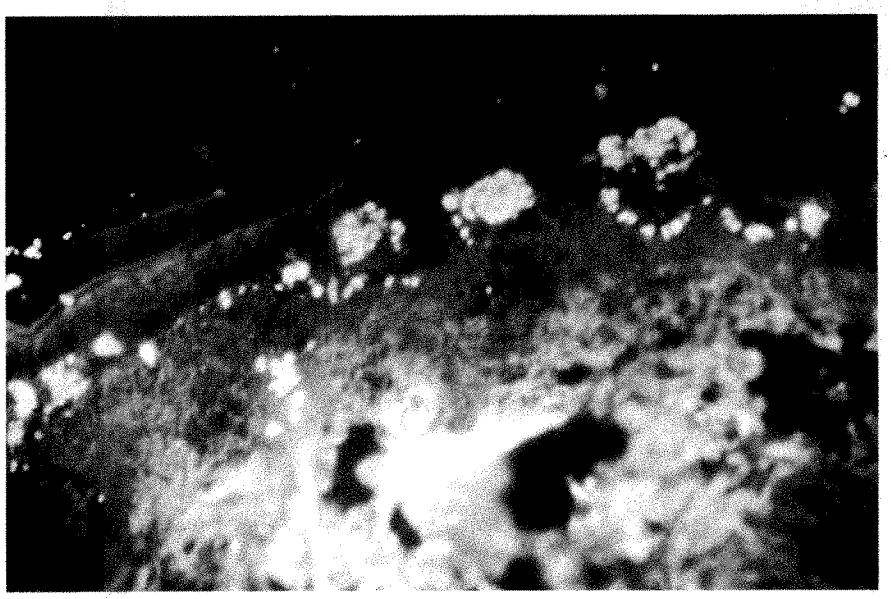

Fig 10.—Direct immunofluorescent specimen showing ovoid bodies in aggregates in papillary dermis suggesting lichen planus pattern, although some bodies show linear pattern (case 11) (antihuman IgM staining, original magnification ×100).

Fig 11.—Direct immunofluorescent specimen showing ovoid bodies in aggregates typical of lichen planus pattern (case 11) (antihuman IgM staining, original magnification ×450).

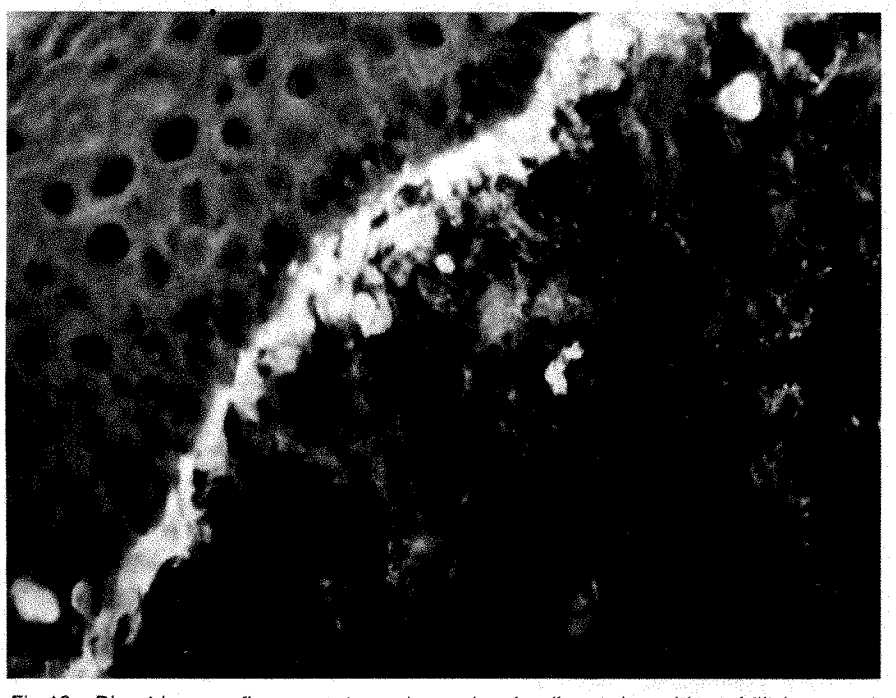

Fig 12.—Direct immunofluorescent specimen showing linear deposition of fibrinogen at dermal-epidermal junction zone (case 1) (antihuman fibrinogen staining, original magnification ×450).

croscopy. In LP, the bodies usually tend to cluster in large groups or aggregates, whereas in LE they tend to have a more linear arrangement along the D-E junction.[12] In our experience, fluorescent bodies in LP also usually attain greater depth into the dermis than those in LE. These bodies are not disease specific as they may be seen by immunofluorescence in smaller numbers in dermatomyositis and poikiloderma,[7,11,12] or in any disease process with appreciable destruction of epidermal keratinocytes or basement membrane material in which these substances become covered with immunoglobulins.

All of our patients demonstrate as their major immunopathologic finding the presence of fluorescent ovoid bodies at the D-E junction zone and in the dermis. In some instances there is more of a tendency toward clustering, and in others more of a linear arrangement, but often the pattern is mixed and different specimens from the same patient sometimes show opposite patterns. Four patients, on one of their immunofluorescent specimens, show a coexistent but poorly developed linear band of immunoglobulins and complement at the basement membrane zone in addition to ovoid bodies. This finding might suggest that LE is at least a part of the spectrum of these four patients' disease process. Linear deposits of fibrinogen, which may be seen at the D-E junction in both LE and LP,[12,13] are exhibited in several of our patients.

After having followed up this group of patients during many years, and having carefully studied their clinical findings and course, variable histopathologic features, and immunofluorescence, which does not completely settle the issue, we feel that these patients have a disease process in which LE or LP cannot definitely be diagnosed, and in which some of these patients may possibly have a coexistence of both diseases. Could it be that the Koebner reaction is doubly operative and synergistic in these patients?

This study was supported in part by a grant from the Veterans Administration.

References

1. Copeman PWM, Schroeter AL, Kierland RR: An unusual variant of lupus erythematosus or lichen planus. *Br J Dermatol* 83:269-272, 1970.

2. Michel B, Milner Y, David K: Preservation of tissue fixed immunoglobulins in skin biopsies of patients with lupus erythematosus and bullous diseases: Preliminary report. *J Invest Dermatol* 59:449-454, 1973.

3. Nesbitt LT, Gum OB: Direct cutaneous immunofluorescent test in lupus erythematosus. *South Med J* 66:991-997, 1973.

4. Pinkus H: Lichenoid tissue reactions. *Arch Dermatol* 107:840-846, 1973.

5. Reed RJ, Meek T, Ichinose H: Lichen striatus: A model for the histologic spectrum of lichenoid reactions. *J Cutan Pathol* 2:1-18, 1975.

6. Lever WF, Schaumburg-Lever G: *Histopathology of the Skin.* Philadelphia, JB Lippincott Co, 1975, pp 147-152, 423-433.

7. Ukei H: Hyaline bodies in subepidermal papillae. *Arch Dermatol* 100:610-617, 1969.

8. Burnham TK, Neblett TR, Fine G: The application of the fluorescent antibody technique to the investigation of lupus erythematosus and various dermatoses. *J Invest Dermatol* 41:451-456, 1963.

9. Tuffanelli DL, Kay D, Fukuyama K: Dermal-epidermal junction in lupus erythematosus. *Arch Dermatol* 99:652-662, 1969.

10. Tuffanelli DL: Lupus erythematosus. *Arch Dermatol* 106:553-566, 1972.

11. Michel B, Sy EK, David K, et al: Immunofluorescent studies in lichen planus. *J Invest Dermatol* 54:428, 1970.

12. Michel B, Sy EK: Tissue fixed immunoglobulins in lichen planus, in Beutner EH, Chorzelski TP, Bean SF, Jordon RE, et al (eds): *Immunopathology of the Skin.* Stroudsburg, Pa, Dowden, Hutchinson, & Ross Inc, 1973, pp 182-193.

13. Baart de la Faille-Kuyper EH, Baart de la Faille H: An immunofluorescent study of lichen planus. *Br J Dermatol* 90:365-371, 1974.

14. Tan EM, Kunkel HG: An immunofluorescent study of the skin lesions in systemic lupus erythematosus. *Arthritis Rheum* 9:37-46, 1966.

Glucagonoma Syndrome

Report of Two Cases and Literature Review

Alan N. Binnick, MD; Steven K. Spencer, MD;
W. Landon Dennison, Jr, MD; Edward S. Horton, MD

• The glucagonoma syndrome is characterized by dermatitis, stomatitis, elevated serum glucagon levels, abnormal glucose tolerance, weight loss, and anemia—all in association with a glucagon-secreting alpha-cell tumor of the pancreas. A review of 21 cases showed strikingly similar features. A generalized, symmetrical dermatitis initially appeared to be asteatotic or eczematous over the perineum, buttocks, and lower extremities. Gradually, a more characteristic migratory necrolytic erythema with transient bulla formation and erosions developed in intertriginous and dependent areas. Histologically, the most specific features included necrolysis of the upper epidermis, with liquefaction necrosis of the granular cell layer and subcorneal clefting or blister formation. The dermatologist is often first to examine such patients; early recognition of this syndrome with prompt surgical removal of the primary pancreatic lesion may afford cure of the neoplasm.

(*Arch Dermatol* 113:749-754, 1977)

The dermatologist armed with a thorough knowledge of the cutaneous manifestations of systemic disease is in a unique position to clarify the true nature of an otherwise obscure clinical problem. When malignant neoplasms are involved, early diagnosis is essential.

Some cutaneous manifestations of internal malignant neoplasms, ie, pruritus ichthyosis, and urticaria, are not specific for malignant neoplasms alone. More specifically, the flush of the carcinoid syndrome, cutaneous Paget disease, and the rash of dermatomyositis may herald an underlying tumor. A relative newcomer now joins this list: the glucagonoma syndrome. Recently described, it consists of a glucagon-secreting alpha cell tumor of the pancreas associated clinically with characteristic dermatitis, weight loss, anemia, glucose intolerance, and sore tongue. The case reports of two patients are presented as examples to introduce a clinical review of this uncommon, but striking syndrome.

Accepted for publication Nov 19, 1976.

From the Section of Dermatology (Drs Binnick and Spencer), Hitchcock Clinic and the Department of Medicine (Drs Binnick and Spencer), Dartmouth Medical School, Hanover, NH, and the Department of Medicine (Drs Horton and Dennison), University of Vermont College of Medicine, Burlington.

Reprint requests to Section of Dermatology, Hitchcock Clinic, Hanover, NH 03755 (Dr Spencer).

REPORT OF CASES

CASE 1.—A 58-year-old woman was noted to have a rash over her waist, buttocks, and extremities in 1973, when she was 56 years old. Increasing tiredness had developed and she had had a 5-kg weight loss in the previous six months. The dermatitis was accentuated on the inner thigh, perineum, and ankles, with symmetrical, crusted, scaling erythematous plaques and a few pustules. Potassium hydroxide examinations did not reveal fungal organisms. Several skin biopsy specimens were interpreted as nonspecific dermatitis, and the clinical differential included pemphigus variants, subcorneal pustular dermatosis, and impetiginized eczematous inflammation.

A sedimentation rate of 48 mm/hr and a normocytic normochromic anemia with a hemoglobin value of 10.8 gm/100 ml and a hematocrit reading of 33% accompanied by weight loss and tiredness prompted a search for malignant neoplasms. In March 1974, multiple tumor nodules, noted on liver scan, were delineated by celiac arteriography as a large, highly vascular mass in the right lower side of the liver, with scattered smaller nodules. A liver biopsy specimen was interpreted as probable hepatoma, with an unusual scirrhous pattern and only mild anaplasia.

She was treated from March 1974 until January 1976 with orally administered fluorouracil at a once weekly dosage of 500 to 700 mg. The rash, presumed to be related to hepatoma, persisted with a fluctuating course of flare-ups and improvement during treatment with topical lubrication, fluorinated corticosteroid creams, and intermittent wet dressings. Her general health, including her weight, remained stable.

It was apparent that the clinical course was not that of a hepatoma. She was again hospitalized in January 1976 to establish a diagnosis of glucagonoma syndrome, brought to our attention through a recent report.[1]

She appeared thin and pale. A generalized dermatitis involved her trunk and extremities. Crusted and eroded papules and plaques were most prominent on her buttocks, waist, and in the area where she wore a bra (Fig 1 to 2). Tender erythematous erosions and crusted plaques surrounded by brown hyperpigmentation were present in flexural areas and on the ankles and feet (Fig 3 to 4). Over the most erythematous areas on the dorsal part of the feet, there appeared to be superficial separation of the skin where bullae had formerly appeared. In lesions of one to two weeks' duration, hyperpigmentation and scaling developed, with a corresponding decrease in erythema and tenderness. The tongue was beefy with prominent furrows. A mild cheilitis was found to be normal on potassium hydroxide examination for fungus. The nails were friable and showed longitudinal ridging. A firm liver edge 2 cm below the right costal margin and a prominent hard small nodule in the inferior

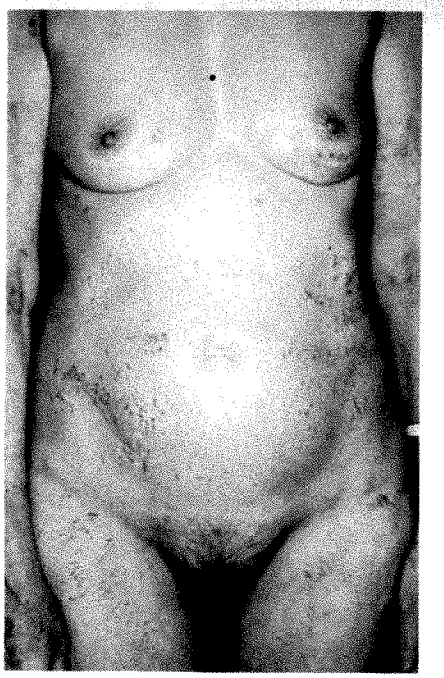

Fig 1.—Generalized symmetrical dermatitis on trunk and extremities. Note resemblance to asteatosis (eczema craquelé).

Fig 2.—Accentuation of dermatitis on pressure area of buttocks.

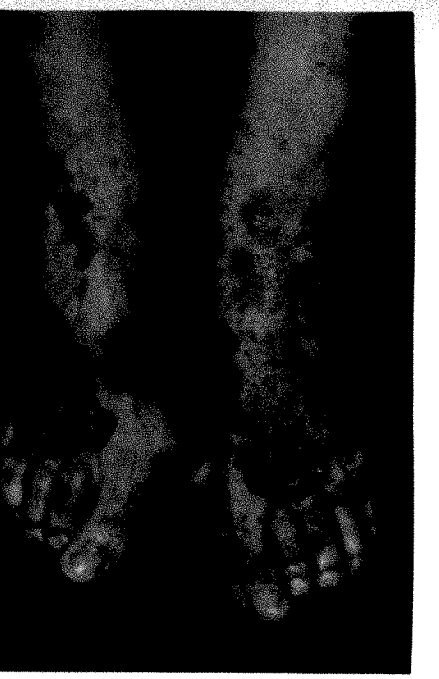

Fig 3.—Note irregular plaques with central erythema, crusting, and hyperpigmentation.

medial portion of the right lobe were palpated; the spleen was not felt. There was no lymphadenopathy and the remainder of the physical examination was normal.

Laboratory Data.—The hemoglobin level was 9.2 gm/100 ml and the hematocrit reading was 27.9%; the reticulocyte count was 1.4%. The serum vitamin B_{12}, folate, and iron determinations were normal. The erythrocyte sedimentation rate was 55 mm/hr. The serum cholesterol level was 125 mg/100 ml (normal, 135 to 270 mg/100 ml). A fasting serum insulin level was 30.5 μU/ml (normal, 6 to 26 μU/ml) and fasting gastrin 145 pg/ml (normal, 50 to 150 pg/ml). A three-hour glucose tolerance test revealed a fasting glucose of 95 mg/100 ml; at one hour, the value was 333 mg/100 ml; at two hours, the value was 353 mg/100 ml; and at three hours, the value was 193 mg/100 ml. Plasma amino acid values were greatly decreased. Test results were normal for urinalysis, blood urea nitrogen, serum creatinine, serum calcium, serum phosphorus, 24-hour urine 5-hydroxyindoleacetic acid, serum protein electrophoresis, and liver function enzymes.

The plasma glucagon determination was 6,750 pg/ml (normal, 100 to 200 pg/ml) fasting, and 8,500 pg/ml at the third hour of the glucose tolerance test. (Plasma glucagon was measured by radioimmunoassay using glucagon labeled with iodine 125 (^{125}I), antiglucagon antiserum 30K (Unger), and a double antibody separation method. Blood specimens were collected in an enzyme inhibitor, aprotinin, at 500 μ/ml, to retard degradation of glucagon by plasma enzymes.)

Fig 4.—Right foot. Bulla had been present on distal plaque several days before this photograph.

Celiac arteriography compared with studies performed two years previously showed an approximate doubling in size of the large, right hepatic lobe tumor mass. A small tumor "blush" was noted in the tail of the pancreas and was interpreted as the probable primary lesion (Fig 5).

Therapeutic measures such as systemic chemotherapy and surgery were not undertaken because of lack of definitive efficacy in published reports and because of the patient's relatively stable clinical course. A brief trial of zinc sulfate 220 mg orally three times a day was attempted because of the clinical resemblance of this dermatosis to acrodermatitis enteropathica; there was no improvement. The serum zinc level before this clinical trial was 96 μg/100 ml (normal, 80 to 165 μg/100 ml).

CASE 2.—A 52-year-old woman was first seen in February 1975, for sore mouth and a recurrent perineal rash. She had been well until August 1974 when she noticed a decrease in appetite, weight loss, and later menometrorrhagia. Two weeks after total abdominal hysterectomy for her pelvic symptoms, a sore mouth and dermatitis developed. Several cultures from the mouth and vagina yielded yeast organisms. She improved somewhat with oral and vaginal nystatin medication.

In May 1975, she was hospitalized with a widespread symmetrical eruption affecting the skin of the wrists, elbows, ankles, knees, clavicle, and the perioral and perianal areas. She was described as thin and appearing older than her 52 years. The rash consisted of reddish-brown patches with thin sheets of desquamating skin. The angles of her mouth were fissured and her tongue was bright red. The vulva was acutely inflammed, swollen, and covered with a serous exudate. The perineal dermatitis extended to the gluteal cleft. The margins of the eruption had hyperpigmented scaling with a few satellite pustules. Examination of the vagina showed slight inflammation and a yellow-brown discharge. There was no hepatosple-

nomegaly and the remainder of the physical examination was unremarkable. A skin biopsy specimen was interpreted as nonspecific dermatitis.

Laboratory Data.—The hemoglobin level was 10.8 gm/100 ml and the hematocrit reading was 35.1%; the leukocyte count was 7,500 (normal differential); the reticulocyte count was 1.4%. Values for serum total protein, albumin, calcium, and phosphorous were normal. A three-hour glucose tolerance test revealed a fasting glucose of 96 mg/100 ml; at one hour, the value was 242 mg/100 ml; at two hours, the value was 181 mg/100 ml; and at three hours, the value was 128 mg/100 ml. Plasma amino acid levels were greatly decreased.

Her appearance and examination findings suggested a nutritional or metabolic disorder. With wet compresses, topically administered corticosteroids, orally administered estrogen and multivitamins, she improved sufficiently to return home.

The possibility of glucagonoma syndrome was considered after review of a recent report.[1] A celiac arteriogram demonstrated a 10-cm tumor in the tail of the pancreas. At laparotomy in July 1975, the well-encapsulated tumor was removed by partial pancreatectomy, with no evidence of metastases found. Her preoperative plasma insulin value was 10 mcu/ml and plasma glucagon was 2,500 pg/ml. (Plasma glucagon was measured by radioimmunoassay using glucagon labeled with iodine 125, antiglucagon antiserum 30K (Unger), and a double antibody separation method. Blood specimens were collected in an enzyme inhibitor at 500 μ/ml to retard degradation of glucagon by plasma enzymes.) At surgery, the splenic arterial glucagon value was 2,800 pg/ml and the concentration of glucagon in a vein draining the tumor was 392,000 pg/ml. After surgery, her glucagon levels have ranged from 123 to 262 pg/ml. Electron microscopic examination of the tumor showed islet cells with a prevalence of alpha granules.

Two days after surgery, she noted that "her bottom didn't burn"; her dermatitis cleared during the next few weeks. Since surgery, she has gained weight with no evidence of tumor recurrence during 15 months of follow-up.

HISTOPATHOLOGICAL FINDINGS

Biopsy specimens were taken from the skin of the trunk and extremities of patient one and from the groin of patient two. Routine sections were stained with hematoxylin-eosin. The sections show alterations corresponding to those reported for glucagonoma syndrome.

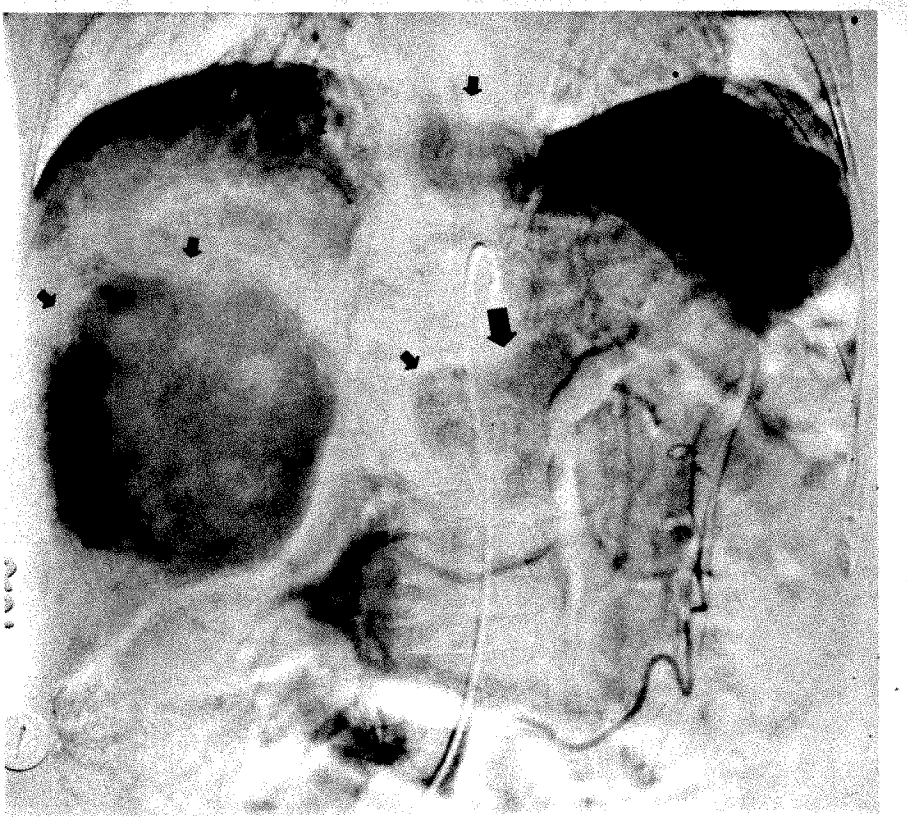

Fig 5.—Subtraction film of capillary phase celiac arteriogram. Note one large and multiple small vascular metastases within liver (small arrows). Large arrow points to vascular tumor in tail of pancreas

The most striking changes were in the epidermis, with spongiosis and necrosis in the upper layers of the stratum malpighii, with superficial cleft and bulla formation without acantholysis. A few sections showed hydropic degeneration in the subcorneal epidermis, with hypogranulosis and a few scattered dyskeratotic cells (Fig 6). Some sections showed psoriasiform hyperplasia with diminished or absent granular layer, parakeratosis, and clumps of bacteria. A mild perivascular upper dermal lymphocytic infiltrate was present. Immunofluorescent stains for immunoglobulin and complement (C3) deposition were negative.

HISTORICAL REVIEW

In 1942, Becker et al[2] reported the first case of what in retrospect was probably a glucagon-secreting islet cell tumor of the pancreas with associated characteristic dermatitis. Their patient had a widespread, symmetrical, scaly erythematous eruption, angular cheilitis, and glossitis. The clinical and histological description of the dermatitis was characteristic for that described in patients now known to have glucagonoma syndrome. A pancreatic neoplasm with histological islet cell features was found at postmortem examination.

McGavran et al[3] reported the first identified glucagon-secreting alpha-cell carcinoma of the pancreas in 1966. Their patient was described as having a bullous and eczematoid dermatitis of the hands, feet, and legs that defied specific diagnosis. The tumor contained alpha-cells and possessed increased glucagon-like activity.

Church and Crane[4] reported on a patient with migratory annular erythema combined with a superficial necrosis of the skin, glossitis, mild diabetes, weight loss, and normochromic anemia. Recognizing the similarities between their patient and that of Becker et al,[2] the authors had speculated that these symptoms and signs might indicate the presence of an islet cell carcinoma of the pancreas. At autopsy an islet cell pancreatic tumor was found.

Mallinson et al[5] published an exten-

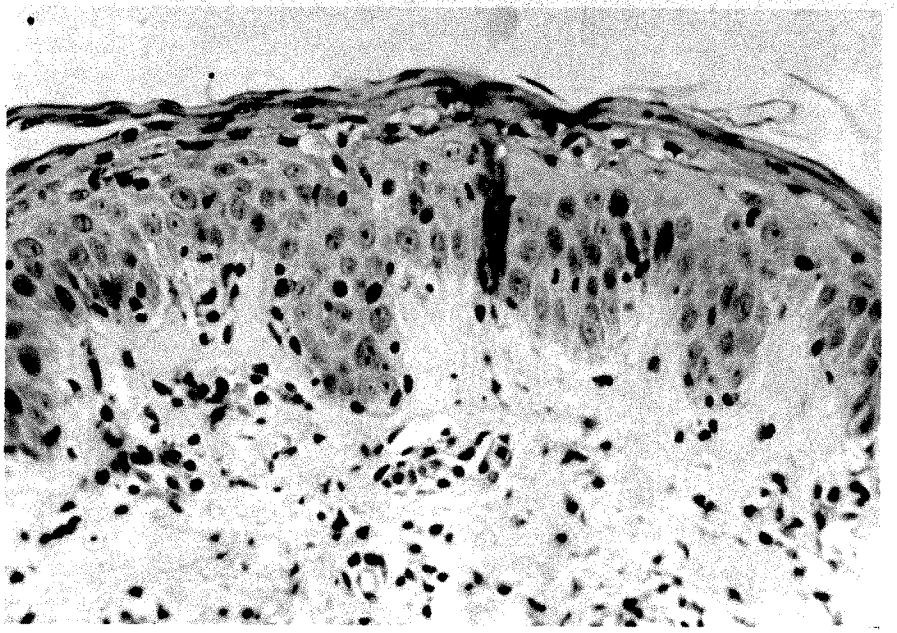

Fig 6.—This specimen shows characteristic absence of granular layer and hydropic degeneration in subcorneal epidermis (hematoxylin-eosin, original magnification ×100).

sive review on nine patients with the glucagonoma syndrome. Plasma amino acids were measured in four of these patients and most values were greatly lower than normal. The term necrolytic migratory erythema was first used by Wilkinson[6] to describe the rash clinically; the term superficial epidermal necrolysis was first used by Sweet[7] to describe the cutaneous histological process.

REVIEW OF CASES

Our two patients serve as classic examples of glucagonoma syndrome. Both patients had angiographically and pathologically verified islet cell pancreatic tumors, with greatly elevated plasma glucagon levels in association with dermatitis, stomatitis, weight loss, glucose intolerance, and anemia.

In reviewing the literature, we became aware of 19 other published case reports of the glucagonoma syndrome (Table). These cases were chosen for inclusion because of their characteristic clinical and pathological manifestations of the syndrome; in some instances, serum glucagon determinations had not been available at the time of presentation. There have been several other reports of patients possibly having the glucagonoma syndrome[8-10]; however, documentation was insufficient for inclusion in this review.

Skin lesions assumed one of two features. Often the initial dermatitis would suggest asteatotic eczematous dermatitis (eczema craquelé) with macular or barely palpable light-brown polygonal papules with slight superficial scaling. Unlike asteatotic dermatitis, this rash failed to respond to lubrication. The other pattern of dermatitis would begin as an erythematous area with gradual central blister formation progressing to central crusting and healing followed by hyperpigmentation 7 to 14 days after the initial erythema. This pattern was usually most severe on the perineum, buttocks, groin, lower abdomen, and lower extremities. Both patterns of dermatitis characteristically waxed and waned.

The clinical differential diagnosis of the dermatitis in the reported cases included Hailey-Hailey disease, pemphigus foliaceus, toxic epidermal necrolysis, subcorneal pustular dermatosis, acrodermatitis enteropathica, and generalized pustular psoriasis.

Many authors in early case reports stressed the nonspecificity of the skin biopsy specimens; however, if a biopsy of the early lesions is done, a rather characteristic histological picture like that described for our two patients may be seen. In several patients, direct immunofluorescence studies did not show any immunoglobulin or C3 complement deposits.

A beefy, sore tongue was present in 17 of the patients. Angular cheilitis was present in almost every patient. Occasionally, yeast organisms were identified from oral lesions. Nail dystrophy was a prominent feature in six patients.

In all of the patients examined for elevated levels of plasma glucagon, extremely high levels were found. Nineteen of the 21 patients had either elevated fasting blood glucose levels or glucose tolerance tests similar to those found in diabetic patients. In no instance was a positive family history of diabetes mentioned. No patient had any complications associated with diabetes. Normochromic normocytic anemia was present in the patients in 15 of the 16 case reports most recently reported. With one exception, weight loss was a consistent feature. Mallinson et al[5] excluded significant fat malabsorption in their patients. Serum cholesterol determination was mentioned in five case reports and in every instance was either low or low normal. The sedimentation rate varied from 30 to 100 mm/hr.

Liver metastases were noted in patients in more than half of the cases, local lymph node and spine involvement in two patients each, and metastases to the left adrenal gland in one patient. Because the head of the pancreas is rarely involved, jaundice is not a clinical feature.

There were 17 women and four men. Most of the patients were middle aged, with 16 of the 21 patients between 40 and 60 years old; only one patient was less than 40 years old (Table, case 20). It is difficult to determine survival rates from the limited number of case reports and from lack of follow-up data; however, the slow-growing nature of many malignant glucagonomas is apparent. In one series,[5] seven of nine patients had been symptomatic for two to 12 years. In four of the cases, the duration of symptoms was 5½ years or greater.

Our second case is the second reported patient to our knowledge in whom it was feasible to remove the primary lesion and therefore obtain a possible cure. In case 3 there has been

Review of Published Cases with the Glucagonoma Syndrome

Source of Reference	Case/Sex/Age, yrs	Hemoglobin gm/ml	Primary Tumor Site in Pancreas	Site of Metastases	Plasma Glucagon,* pg/ml
Present case 1	1/F/56	10.8	Tail	Liver	6,750
Present case 2	2/F/52	10.8	Tail	None	2,500
Mallinson et al[5]†	3/F/50	10.5	Head and neck	None	3,500
	4/F/52	6.0	Neck	Liver and spine	1,510
	5/F/65	9.8	Tail	Liver and spine	1,475
	6/F/58	9.0	Tail	None	850
	7/F/56	8.8	Tail	None	. . .
	8/M/56	7.2	Body	None	. . .
	9/F/48	4.1	Tail	Liver	. . .
	10/F/51	7.3	Body	Liver	. . .
	11/F/50	6.2	Tail	Liver	. . .
Freedberg and Galdabini[1]	12/M/40	9.1	Body	Liver	2,200
Becker et al[2]	13/F/45	11	Body and tail	Local and left adrenal	. . .
Church and Crane[4]	14/F/61	12.4	Body	Local and liver	. . .
McGavran et al[3]	15/F/42	11	Tail	Liver	. . .
Auerbach and Koehler[33]	16/F/42	. . .	Tail	Liver	. . .
Gossner and Korting[34]	17/F/51	12.1		. . .	. . .
Holst et al[35]	18/F/71	5.1	Body	. . .	6,600
	19/M/68	8.8	tail	. . .	700-1,000
Swenson et al[36]	20/F/20	. . .	. . .	Liver	380-510
Danforth et al[37]	21/M/48	. . .	Body and tail	Liver	4,800

*Assay methods may not be comparable. Normal plasma glucagon usually listed as up to 100 to 200 pg/ml.
†Case 3 is also presented in Sweet,[7] Lightman and Bloom[38] and Warin[39]; case 4 in Wilkinson;[6] and cases 5 to 9, 11 in Warin.[39]

no evidence of tumor recurrence three years after removal of the tumor (Mallinson, personal communication, 1976). With respect to dermatitis, almost complete clearing occurred within two weeks in the two patients in whom the primary tumor was successfully removed. About half the remaining patients noted significant improvement of the dermatitis with the use of topical corticosteroids.

COMMENT

Glucagon, one long polypeptide chain of 29 amino acids, is produced in the alpha-cells of the pancreatic islets of Langerhans. Mild hyperglucagonemia has been reported in patients with physiological stimuli to glucagon secretion such as protein ingestion or starvation,[11,12] insulin withdrawal, diabetic ketoacidosis,[13] uremia,[14] cirrhosis of the liver,[15] Cushings syndrome,[16] acromegaly, pheochromocytoma, and acute pancreatitis.[17] Greatly elevated plasma glucagon levels have been reported only with alpha-cell tumors of the pancreas.

There have been five distinctive clinical syndromes associated with neoplasms of the islets of Langerhans[18]: glucagonoma, insulinoma, Zollinger-Ellison syndrome, carcinoid syndrome, and the watery diarrhea hypokalemic syndrome. Any of these tumors may occur as part of the syndrome of multiple endocrine adenomatosis, resulting in a mixed clinical syndrome caused by the secretion of more than one hormone.

To be considered a glucagonoma, a tumor must be shown to be secreting an excess of glucagon. To constitute the glucagonoma syndrome, we concluded that at least the characteristic dermatitis referred to as migratory necrolytic erythema must be present in addition to the hyperglucagonemia. Glossodynia, diabetes, or abnormal results from a glucose tolerance test, weight loss, normochromic normocytic anemia, elevated sedementation rate, and perhaps also hypocholesterolemia are other associated features. Although not previously reported as being a feature of the syndrome, hypocholesterolemia is not a surprising finding since it has been shown that glucagon administration will lower blood cholesterol levels.[19-21]

Once the diagnosis is established (or if there is a high index of suspicion), a celiac arteriogram should be performed to localize the primary lesion and possible metastases. More than 60% of islet cell tumors are demonstrated by arteriography[22] in contrast with adenocarcinomas of the pancreas for which arteriography is often not helpful. A liver scan should also be done because of the high incidence of liver metastases. Various screening tests for other endocrinopathies may be indicated since a glucagonoma may be part of multiple endocrine adenomatosis.

It is very difficult histologically to determine whether endocrine tumors (including glucagonoma) are benign or malignant. Metastases occurred in 13 of 21 patients (62%) with glucagonoma syndrome. By contrast, approximately 20% of insulinomas are malignant.[23]

Any attempts to understand the cause of the dermatitis in glucagonoma syndrome have been speculative to our knowledge to date. Infusion of glucagon will substantially diminish plasma amino acids[24]; in those patients with glucagonoma who were tested, plasma amino acid levels have been greatly decreased. Mallinson et al[5] speculated that the skin rash might be based on excessive catabolism perhaps mediated through the hypoaminoacidemia.

Dermatitis and normocytic anemia occur in protein malnutrition.[25] In acute cases of kwashiorkor, superficial bullae may occur and the skin appearance may resemble that of a burn. Within a week, regardless of treatment, desquamation may be noted and with recovery, hyperpigmenta-

tion is usually seen.[26] Henington et al[26] reported three patients with kwashiorkor, all of them had some features resembling the dermatitis associated with glucagonomas. The dermatitis seen in kwashiorkor may be related to hypoaminoacidemia, and skin lesions of kwashiorkor have been cured with vitamin-free casein or a mixture of pure amino acids.[27]

Patients with essential fatty acid deficiency have an associated dermatitis characterized by erythema with a dry and scaly appearance accentuated in intertriginous areas.[28-31] We are not aware of any studies concerning fatty acid determinations in patients with glucagonomas.

The distribution of the dermatitis suggests pressure and friction as being important. Although essentially any area of the body may have the dermatitis, the buttocks, perineum, lower legs, ankles, and feet seem to be involved most often. There seems to be an increased incidence of bacterial and yeast infections; this may simply be due to the loss of structural integrity of the epidermis.

Treatment of the dermatitis is difficult to evaluate because of the irregularity of its natural course. Topical corticosteroids seem to be helpful in controlling the dermatitis in many cases. Mallinson et al[5] found diiodohydroxyquin treatment helpful in two patients and orally administered tetracycline therapy helpful in another; dapsone (two patients) and niacinamide (one patient) did not help.

Surgical and chemotherapeutic approaches have been considered for treatment of the tumor itself. If there is no evidence of metastases at the time of presentation, as in our second case report, resection of the tumor may afford cure of the neoplasm. It is not known whether resection of either the primary neoplasm in the presence of metastatic lesions or resection of most of the tumor mass will affect the natural history of the malignant neoplasm.

Streptozocin, a nitrosourea chemotherapeutic agent, has been effective in treating patients with malignant tumors of beta-cell origin[32] and may be of value in treating glucagonomas. Patient 21 seems to have undergone a remission after streptozocin therapy, with a return of his circulating immunoreactive glucagon level to normal.

Becker et al[2] wrote that "...a comment on our first case seems to be impossible at present, and we restrict ourselves to the recording of it. Only the observation of other cases of pancreatic tumor will decide whether the cutaneous changes in our case were primarily due to the neoplasm." It is now clear that although the mechanism is unknown, rather specific and recognizable cutaneous changes accompany pancreatic glucagonomas.

Supported in part by Public Health Service grant MO1-RR-109 (Clinical Research Center), and Westwood Pharmaceuticals.

Robert F. Jeffery, MD, performed the celiac arteriogram in case 1.

References

1. Freedberg IM, Galdabini JJ: Dermatitis, weight loss and filling defects in the liver (CPC). *N Engl J Med* 292:1117-1123, 1975.

2. Becker SW, Kahn D, Rothman S: Cutaneous manifestations of internal malignant tumors. *Arch Dermatol Syph* 45:1069-1080, 1942.

3. McGavran MH, Unger RH, Recant L, et al: A glucagon-secreting alpha-cell carcinoma of the pancreas. *N Engl J Med* 274:1408-1413, 1966.

4. Church RE, Crane WAJ: A cutaneous syndrome associated with islet-cell carcinoma of the pancreas. *Br J Dermatol* 79:284-286, 1967.

5. Mallinson CN, Bloom SR, Warin AP, et al: A glucagonoma syndrome. *Lancet* 2:1-5, 1974.

6. Wilkinson DS: Necrolytic migratory erythema with carcinoma of the pancreas. *Tran St Johns Hosp Dermatol Soc* 59:244-250, 1973.

7. Sweet RD: A dermatosis specifically associated with a tumor of pancreatic islet cells. *Br J Dermatol* 90:301-308, 1974.

8. Levin ME: Endocrine syndromes associated with pancreatic islet cell tumors. *Med Clin North Am* 52:295-312, 1968.

9. Bianchi, C, Macor M, Zar E: Dermatosi paraneoplastica in carcinoma di tipo endocrino del pancreas. *Riv Anat Patol Oncol* 33:319-329, 1968.

10. Braverman IM: *Skin Signs of Systemic Disease*. Philadelphia, W B Saunders Co, 1970, p 25.

11. Aoki TT, Müller WA, Brennan MF, et al: Effect of glucagon on amino acid and nitrogen metabolism in fasting man. *Metabolism* 23:805-814, 1974.

12. Aquilar-Parada E, Eisentraut AM, Unger RH: Effects of starvation on plasma pancreatic glucagon in normal man. *Diabetes* 18:717-727, 1969.

13. Müller WA, Faloona GR, Unger RH: Hyperglucagonemia in diabetic ketoacidosis. *Am J Med* 54:52-57, 1973.

14. Bilbrey GI, Faloona GR, White MG, et al: Hyperglucagonemia of renal failure. *J Clin Invest* 53:841-847, 1974.

15. Marco J, Diego J, Villanueva ML, et al: Elevated plasma glucagon levels in cirrhosis of the liver. *N Engl J Med* 289:1107-1111, 1973.

16. Wise JK, Hendler R, Felig P: Influence of glucocorticoids on glucagon secretion and plasma amino acid concentration in man. *J Clin Invest* 52:2774-2782, 1973.

17. Sherwin RS, Fisher M, Hendler R, et al: Hyperglucagonemia and blood glucose regulation in normal, obese and diabetic subjects. *N Engl J Med* 294:455-461, 1976.

18. Schein PS, DeLellis RA, Kahn CR, et al: Islet cell tumors: Current concepts and management. *Ann Intern Med* 79:239-257, 1973.

19. Rothfeld B, Margolis S, Varady A Jr, et al: Effects of glucagon on cholesterol and triglyceride deposition in tissues. *Biochem Med* 10:122-125, 1974.

20. Byers SO, Friedman M, Elek SR: Further studies concerning glucagon-induced hypocholesterolemia. *Soc Exp Biol Med* 149:151-157, 1975.

21. Friedman M, Byers SO, Rosenman RH: Effects of glucagon on blood-cholesterol levels in rats. *Lancet* 2:464-466, 1971.

22. Gray RK, Rosch J: Arteriography in the diagnosis of islet cell tumors. *Radiology* 97:39-44, 1970.

23. Broder LE, Carter SK: Pancreatic islet cell carcinoma. *Ann Intern Med* 79:101-107, 1973.

24. Marliss EB, Aokii TT, Unger RH: Glucagon levels and metabolic effects in fasting man. *J Clin Invest* 49:2256-2270, 1970.

25. Adams EB, Scragg JN, Naidoo BT, et al: Observations on the etiology and treatment of anemia in kwashiorkor. *Br Med J* 2:451-454, 1967.

26. Henington UM, Caroe E, Derbes V, et al: Kwashiorkor: Report of four cases from Louisiana. *Arch Dermatol* 78:157-168, 1958.

27. Truswell AS, Liadsky C, Wittmann W, et al: Are the skin lesions of kwashiorkor pellagrous? *S Afr Med J* 36:965-966, 1962.

28. Prottey C, Hartop PJ, Black JG, et al: The repair of impaired epidermal barrier function in rats by the cutaneous application of linoleic acid. *Br J Dermatol* 94:13-21, 1976.

29. Hansen AE, Haggard ME, Boelschie AN, et al: Essential fatty acids in infant nutrition. *J Nutr* 66:565-575, 1958.

30. Prottey C, Hartop PJ, Press M: Correction of the cutaneous manifestations of essential fatty acid deficiency in man by application of sunflower seed oil to the skin. *J Invest Dermatol* 64:228-234, 1975.

31. Riella MC, Broviac JW, Wells M, et al: Essential fatty acid deficiency in human adults during total parenteral nutrition. *Ann Intern Med* 83:786-789, 1975.

32. Broder LE, Carter SK: Pancreatic islet cell carcinoma—Results of therapy with streptozotocin in 52 patients. *Ann Intern Med* 79:108-118, 1973.

33. Auerbach RC, Koehler PR: The many faces of islet cell tumor. *Am J Roentgenol* 119:113-140, 1973.

34. Gössner VW, Korting GW: Metastasierendes inselzelkarzinom vom A-zelltyp bei einen fall von pemphigus foliaceus mit diabetes renalis. *Dtsch Med Wochenschr* 11:434-437, 1960.

35. Holst JJ, Jonsson L, Pedersen NB, et al: Glukagonomsyndromet. *Ugeskr Laeger* 137:2631-2633, 1975.

36. Swenson KH, Hanifin JM, Riddle M: The glucagonoma syndrome: A distinctive cutaneous marker of systemic disease, abstracted *Clin Res* 24:98A, 1976.

37. Danforth DN Jr, Triche T, Doppman JL, et al: Elevated plasma proglucagon-like component with a glucagon-secreting tumor. *N Engl J Med* 295:242-245, 1976.

38. Lightman SL, Bloom SR: Cure of insulin-dependent diabetes mellitus by removal of a glucagonoma. *Br Med J* I:367-368, 1974.

39. Warin AP: Necrolytic migratory erythema with glucagon-secreting tumor of the pancreas. *Proc Roy Soc Med* 67:1008-1010, 1974.

Ultrastructural Studies of Vitiligo, Vogt-Koyanagi Syndrome, and Incontinentia Pigmenti Achromians

Masaaki Morohashi, MD, PhD; Ken Hashimoto, MD; Thomas F. Goodman, Jr, MD; Dennis E. Newton, MD; Toivo Rist, MD

• **Studies of early progressive vitiligo, Vogt-Koyanagi syndrome, and incontinentia pigmenti achromians were made by electron microscopy. At the periphery of the depigmented lesions, the melanocytes had several subcellular abnormalities, ie, vacuolization of the cytoplasm, aggregation of melanosomes, autophagic vacuoles, fatty degeneration, pyknosis or homogeneous cytoplasmic degeneration, and others. Numerous nerve endings were seen in close contact with the basal lamina of the epidermis or even within the epidermis. Direct continuities between Schwann cell basal lamina of nerve endings and the basal lamina of the melanocytes were observed. Nerve endings could be associated with either normal or abnormal melanocytes.**

(*Arch Dermatol* 113:755-766, 1977)

Regarding the mechanisms involved in melanocyte disappearance in several depigmenting skin disorders, there is no consensus of opinions. Transformation of melanocytes into Langerhans cells (L-cell) or related cells in vitiligo has been proposed by Birbeck et al[1] and the idea followed by other authors.[2-5] An autoimmune mechanism has been proposed by Copeman et al[6] as appearing in vitiligo with demonstration of antimelanocyte antibody, whereas Hashimoto[7,8] suggested that the peripheral nerve might play a role in halo nevus, since a number of nerve endings were demonstrated in the basal layer of the epidermis where melanocytes have disappeared. The neurogenic hypothesis of vitiligo was advanced by Lerner[9] and Chanco-Turner and Lerner[10]; it was based upon their physiologic observations that predominance of cholinergic influences such as increased sweating exists in vitiliginous skin.

The present work was undertaken to elucidate the mechanism of depigmentation in three depigmentary conditions: vitiligo, Vogt-Koyanagi syndrome, and incontinentia pigmenti achromians. Emphasis was placed on the nerve-melanocyte relationship in the process of depigmentation.

REPORT OF CASES

Vitiligo

Studies of three patients with vitiligo of recent onset were made. The biopsy specimens were removed from a white hair area of the left frontal scalp and from the cheek of a 40-year-old black man (Case 1), the right cheek of a 5-year-old black girl (Case 2), and the right shoulder of an 18-year-old black woman (Case 3).

Incontinentia Pigmenti Achromians

CASE 1.—A female patient was born (Nov 24, 1968) with thin white lines in the shape of a mirror image of an "S" on the frontal and lateral portions of her left chest and abdomen. During the next several years these lesions gradually extended both toward the medial side anteriorly and the midline posteriorly. Eventually, the verti-

Accepted for publication Aug 18, 1976.

From the Veterans Hospital and Division of Dermatology, Department of Medicine, University of Tennessee Center for the Health Sciences, Memphis. Dr Newton is now with the Naval Hospital, Memphis, and Dr Rist with the USAF Regional Hospital, Maxwell Air Force Base, Montgomery, Ala.

Reprint requests to 1030 Jefferson Ave, Memphis, TN 38104 (Dr Hashimoto).

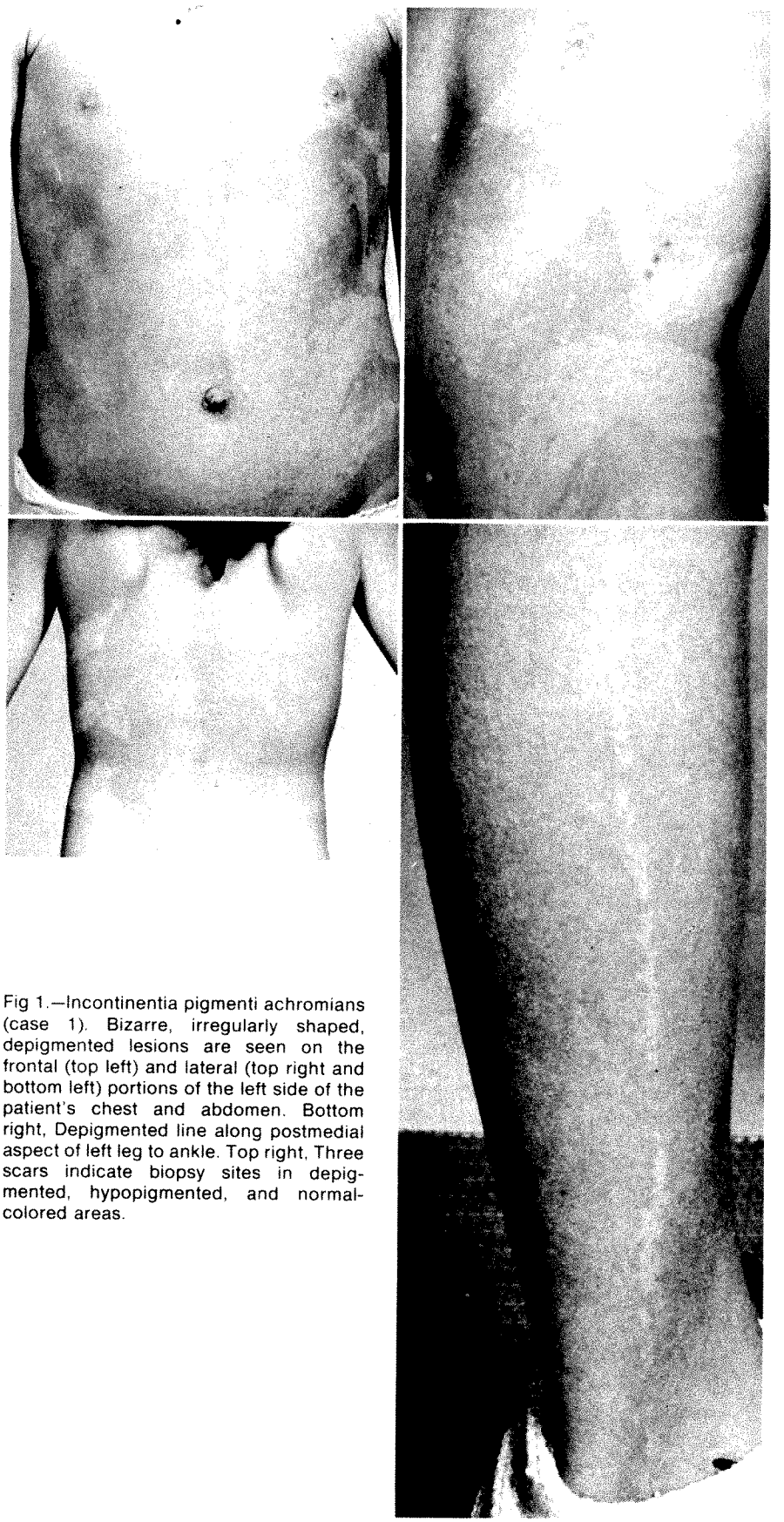

Fig 1.—Incontinentia pigmenti achromians (case 1). Bizarre, irregularly shaped, depigmented lesions are seen on the frontal (top left) and lateral (top right and bottom left) portions of the left side of the patient's chest and abdomen. Bottom right, Depigmented line along postmedial aspect of left leg to ankle. Top right, Three scars indicate biopsy sites in depigmented, hypopigmented, and normal-colored areas.

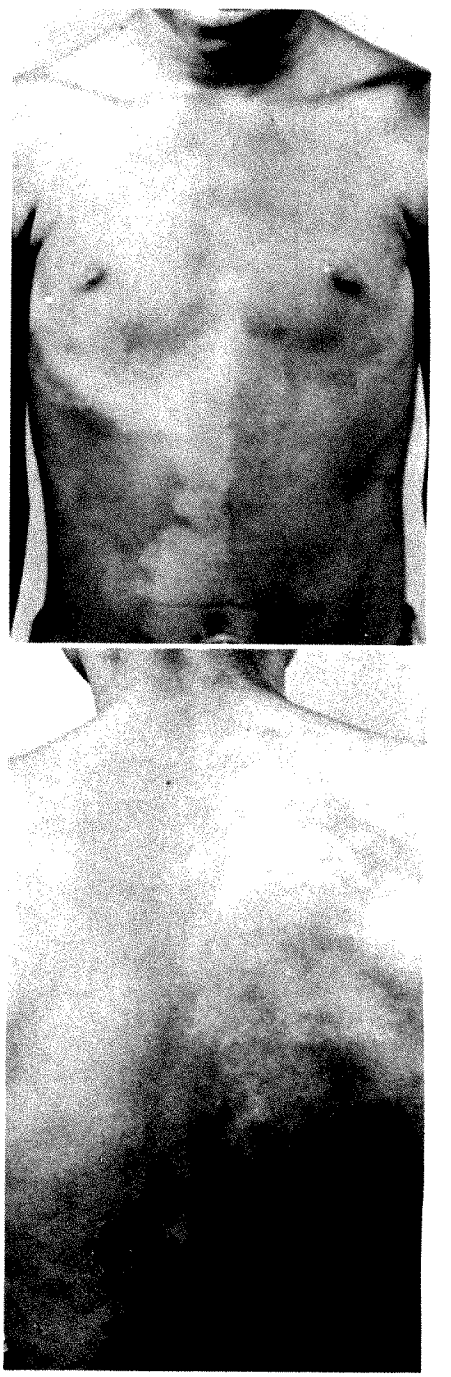

Fig 2.—Incontinentia pigmenti achromians (case 2). Bizarre, mottled hypopigmentation in right upper quadrant of both anterior (top) and posterior (bottom) part of thorax. Depigmentation extends over shoulder and neck.

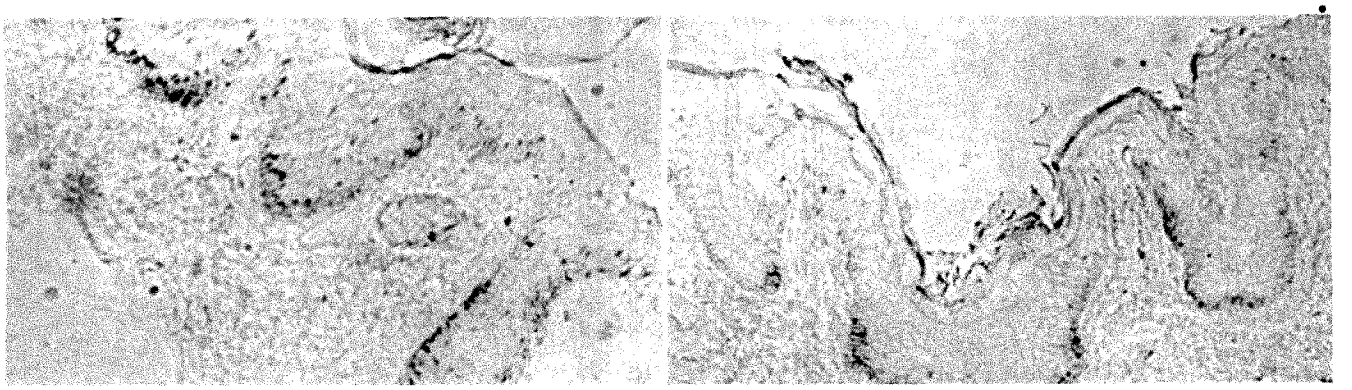

Fig 3.—Incontinentia pigmenti achromians (case 2). Levodopa-reactive melanocytes are less abundant in hypopigmented lesion than in pigmented control skin (left and right) (azure B stain, ×100).

Table 1.—Summary of Findings

	Vitiligo	Vogt-Koyanagi Syndrome	Incontinentia Pigmenti Achromians
Melanocyte degeneration in basal & lower malpighian layer	+	+	+
Effete melanocyte in granular layer	+	–	–
Nerve connection to normal melanocyte	+	+	+
Nerve connection to degenerated melanocyte	+	+	+
Intraepidermal nerve ending	+	+	+

Table 2.—Subcellular Abnormalities of Melanocyte

	Vitiligo	Vogt-Koyanagi Syndrome	Incontinentia Pigmenti Achromians
Vacuolization of cytoplasm	+	+	+
Aggregation of melanosomes	+	+	+
Autophagic vacuoles	+	+	+
Fatty degeneration	+	+	–
Pyknosis or homogeneous cytoplasmic degeneration	+	+	+

Fig 4.—Incontinentia pigmenti achromians (case 2). Note close association between melanocyte (M) and free nerve ending (N). Axons contain numerous mitochondria, dense bodies, and vesicles. Autophagic vacuole (black arrow) seen in cytoplasm of melanocyte. Melanocyte is attached to basal lamina with hemidesmosomes (hollow arrow). Melanosome indicated by M. Hypopigmented lesion (×40,000).

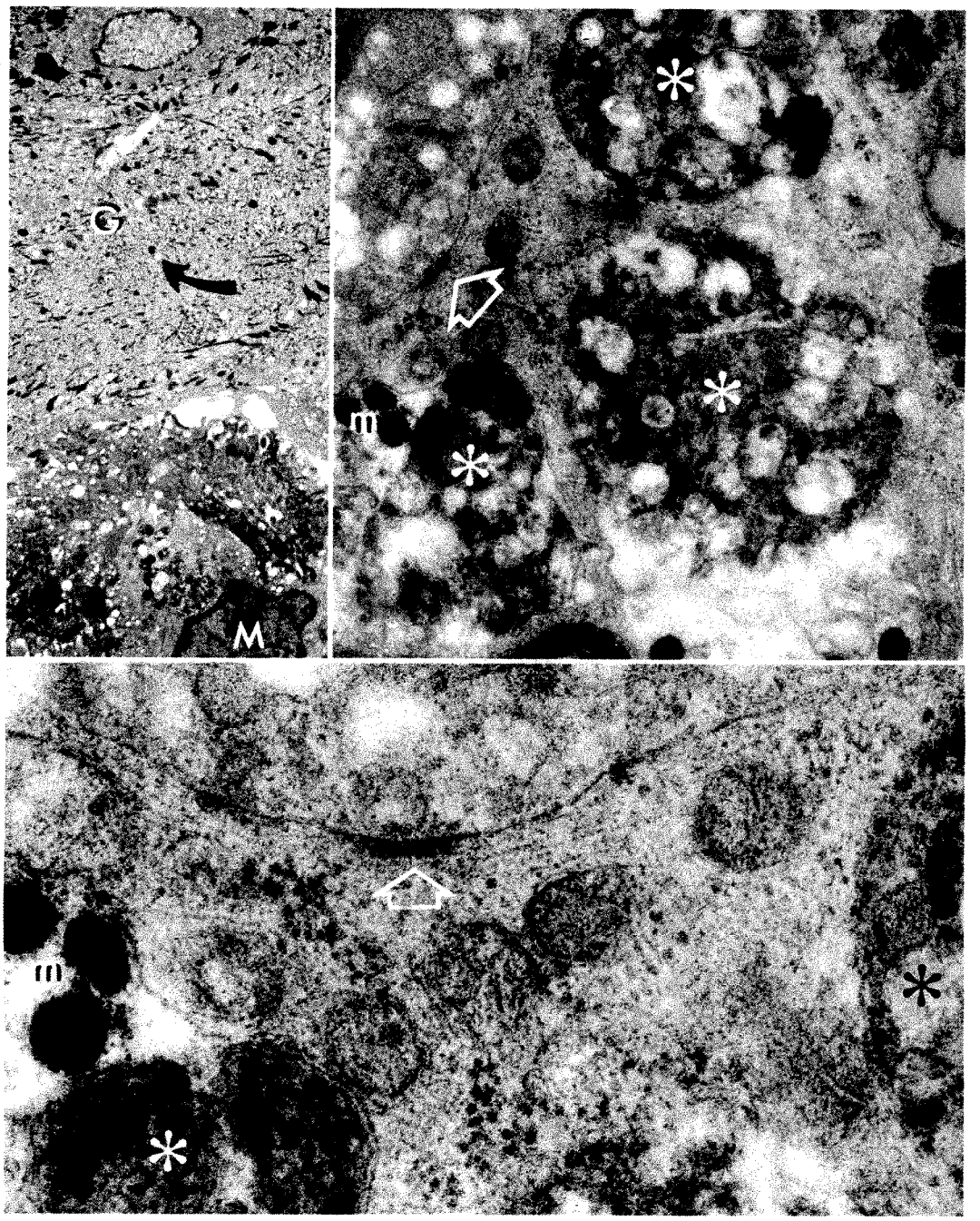

Fig 5.—Vitiligo (case 1). Top left, Low magnification of degenerated melanocyte (M) seen in high level of epidermis. Granular cells (G) containing keratohyaline granules (curved arrow) are just above degenerated melanocyte. Top right and bottom, Higher magnification is part of melanocyte; numerous autophagosomes (asterisks) digest their own melanosomes (m) and other organelles. Hollow arrows show hemidesmosomes of melanocyte. Hypopigmented lesion (top left: ×3,200; top right: ×32,000; bottom: ×80,000).

cal connections disappeared, leaving a series of three horizontal lines (Fig 1, top left and right and bottom left). At the age of 1½ years, an extremely thin hypopigmented line appeared from the perianal region of the left buttock down the posteriomedial thigh and leg to the ankle (Fig 1, bottom right). This also widened with time but to a much lesser extent than the trunk lesions. There has never been any paraesthesia or anesthesia in the area. The depigmented areas sunburned easily and have never shown any signs of tanning. She is a normally developed intelligent child.

No similar lesions were found in any other family members on either side of the family. The mother had many attacks of asthma and experienced mild hypertension. Medications for these conditions included antihistamines and phenobarbital. During her pregnancy there was no bleeding; no hormones were administered; and the delivery was normal.

The child has had several episodes of streptococcal sore throat and tonsillitis, as well as otitis media bilaterally and serous otitis media with some bilateral hearing loss.

CASE 2.—An 8-year-old black girl was admitted to the Pediatric Service, Medical College of Georgia, Eugene Talmadge Memorial Hospital, in December 1972, for evaluation of a seizure disorder. Because of large hypopigmented areas on her trunk that were present since birth (Fig 2), she was referred to the Department of Dermatology. A skin examination showed a bizarre streaking and whorling hypopigmented area on the right upper quadrant of both anterior and posterior thorax, extending slightly over the shoulder and neck.

She had had a mild febrile disease and headache one year prior to admission that was thought possibly to be viral meningitis. She had a five-month history of occasional episodes of eye blinking, progressing to a jerking of the head and right arm. No loss of consciousness occurred. These symptoms responded well to phenobarbital administration.

Results of a physical examination were normal except for increased deep tendon reflexes on the left side of the body.

Vogt-Koyanagi Syndrome

CASE 3.—A 42-year-old black woman came to Eugene Talmadge Memorial Hospital, Augusta, Ga, with one month's duration of loss of skin pigment, dysacusia, photophobia, decreased vision, and increased tearing, pain, burning, and itching of the eyes. The exact time relationship of the skin changes to the eye and ear symptoms was unclear to the patient. It is certain, however, that the skin changes preceded the eye and ear symptoms. Examination of the skin showed symmetrical loss of pigment of the face, shoulder, trunk, and extremities. A large confluent lesion was found over the shoulders. Results of an ocular examination showed her visual acuity to be profoundly decreased. There were 1+ aqueous cells and flare present bilaterally. On fundus examination, there was deep central cupping of the optic nerve head with nasal displacement of vessels. The retinal vessels appeared narrowed and arteriovenous nicking of a mild degree was noted. Macular edema was present. Circumferential bullous retinal detachments were noted bilaterally. An audiogram showed hearing loss that did not impair her ability to communicate.

The patient was treated in the hospital with 80 mg of prednisone daily for 12 days, and 40 mg of prednisone every other day for 6 days. At the end of this period, visual acuity had improved to 20/40 in the right eye and 20/50 in the left eye. Bullous retinal detachments remained unchanged bilaterally.

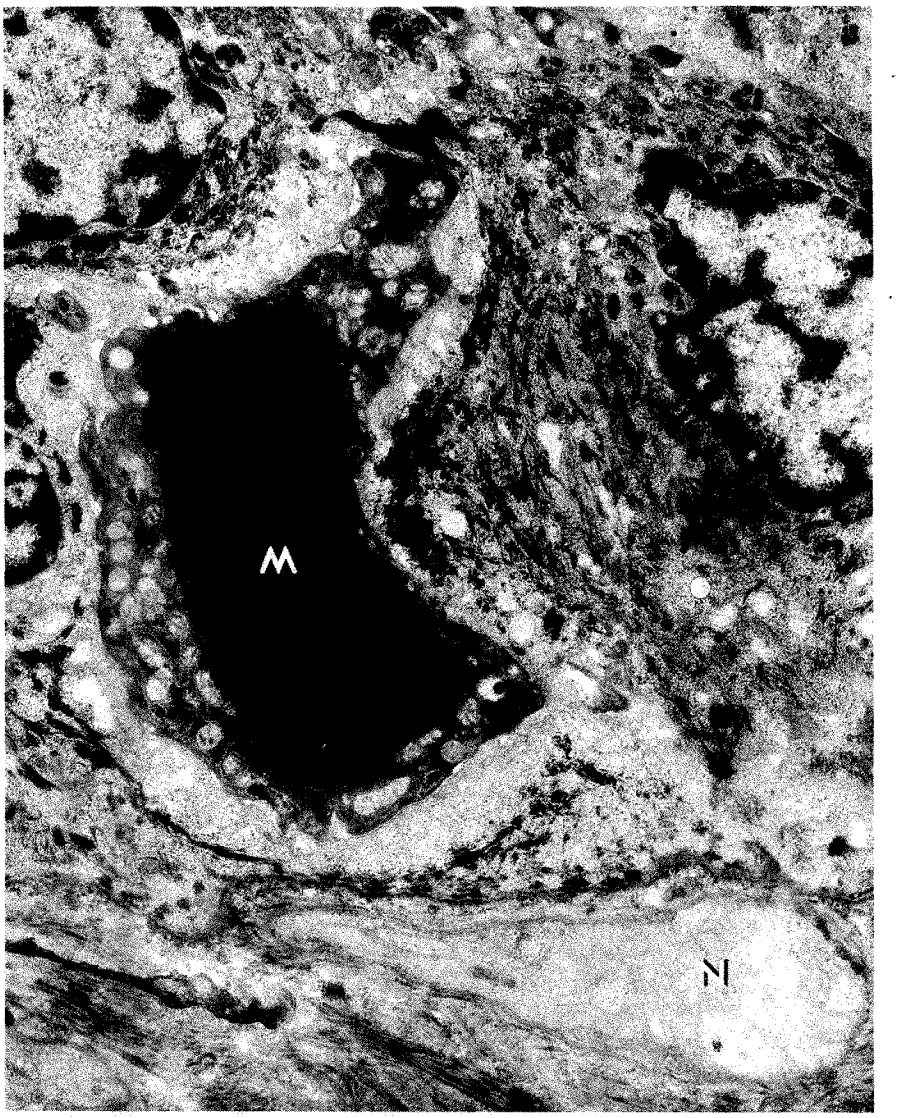

Fig 6.—Incontinentia pigmenti achromians (case 1). Melanocyte (M) shows pyknosis and homogeneous coagulation of cytoplasm. Note presence of nerve ending (N) seen close to degenerating melanocyte. Hypopigmented lesion (×8,000).

MATERIALS AND METHODS

In these depigmenting conditions the pigment loss in the lesion is usually not abrupt but gradual. In black patients there is a shade of gray between the depigmented center of the lesion and the normal skin. It was anticipated that there are gradients of pathologic changes if we

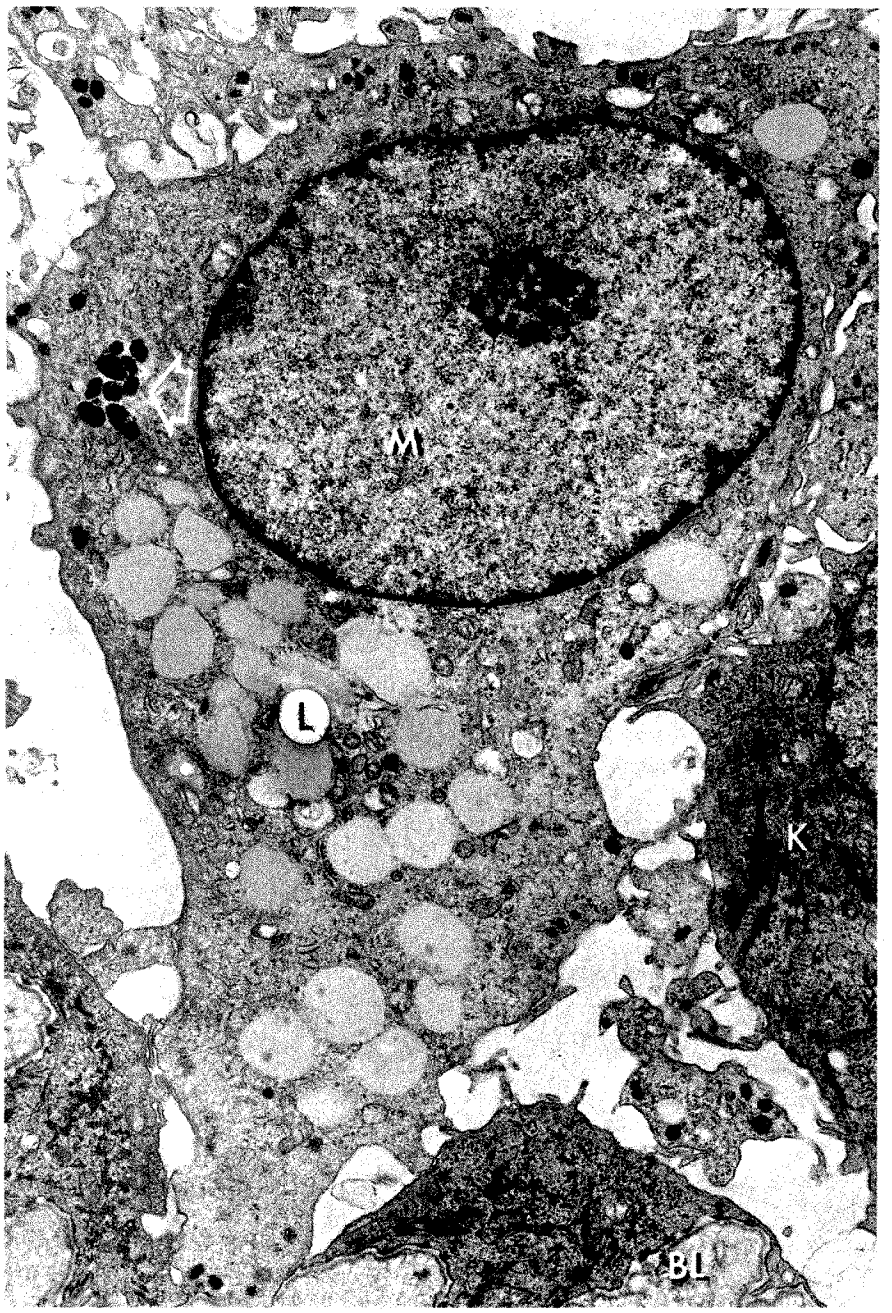

Fig 7.—Vitiligo (case 1). Melanocyte (M) shows fatty degeneration (L). Within cytoplasm of melanocyte, aggregation of melanosomes (hollow arrow) is seen. Basal lamina indicated by BL; K, keratinocyte. Hypopigmented lesion (×10,000).

examine three different areas in each specimen beginning from normally pigmented area, through an intermediate or hypopigmented area, and a completely depigmented area, usually located in the center of the lesion. In Fig 1 the biopsy scars show how this selection of biopsy sites was done in one lesion. Specimens were taken from the pigmented, hypopigmented, and depigmented areas of the lesion of three patients with vitiligo. Three specimens were obtained from the lesions of the left chest of case 1 of incontinentia pigmenti achromians; the center (depigmented), intermediate (hypopigmented), and peripheral (normal color) sites of the involved area (Fig 1, top right) had biopsy procedures. Normal skin was also taken from the right chest for a control. Specimens from case 2 of incontinentia pigmenti achromians were taken from the lesion on the right chest (Fig 2, left) in the same way (pigmented, hypopigmented, and depigmented areas) and from the left thigh to serve as a control. Each biopsy specimen of case 2 was further divided into two parts: one for histochemical studies of levodopa[11] and the other for electron microscopic examination. Biopsy specimens of Vogt-Koyanagi syndrome were performed in the same way (pigmented, hypopigmented, and depigmented areas) from the involved area of the left shoulder. All the biopsy specimens were taken with the patient under 1% procaine hydrochloride anesthesia.

All tissues for electron microscopic studies were immediately sliced into 1-cu mm blocks and fixed for three hours in 5% glutaraldehyde buffered to pH 7.4 with 0.1M cacodylate. After an overnight rinse in the same buffer, the tissue blocks were treated with 1% osmic acid in the same buffer for 30 minutes. Graded concentrations of ethanol (50% through absolute) and propylene oxide were used for dehydration; epoxy casting resin A was used for embedding the specimens. Thick sections were cut at 1 μ from each block and stained with 0.01% azure B on a hot plate. Thin sections were cut at 400 to 600 A in an ultramicrotome and stained with 15% uranyl acetate in 100% methanol and then with lead citrate.[12] Stained sections were observed in an electron microscope.

RESULTS

In case 2 of incontinentia pigmenti achromians, levodopa-reactive melanocytes were less abundant in the hypopigmented lesion than in the pigmented control skin (Fig 3, left and right).

The electron microscopic findings in

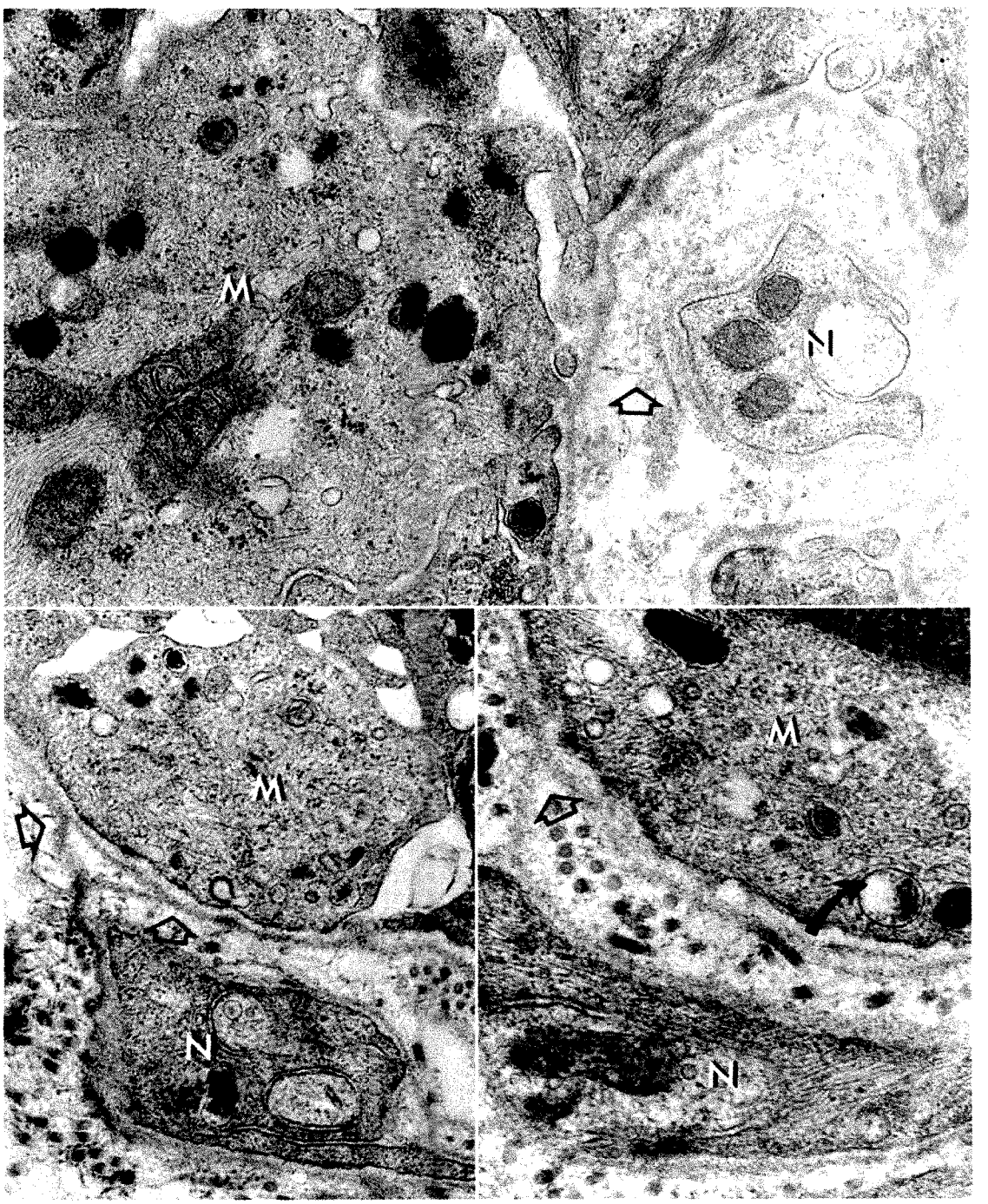

Fig 8.—Vitiligo (cases 1 and 2). Close (top) or direct (bottom left and right) association between melanocyte (M) and nerve ending (N) seen (hollow arrows). Bottom right, Lysosomal vacuole (curved arrow) in cytoplasm of melanocyte. Hypopigmented lesion (case 1) (top: ×30,000; bottom left: ×28,000; case 2, bottom right: ×45,000).

UNIVERSITY COLLEGE OF MEDICINE LIBRARY

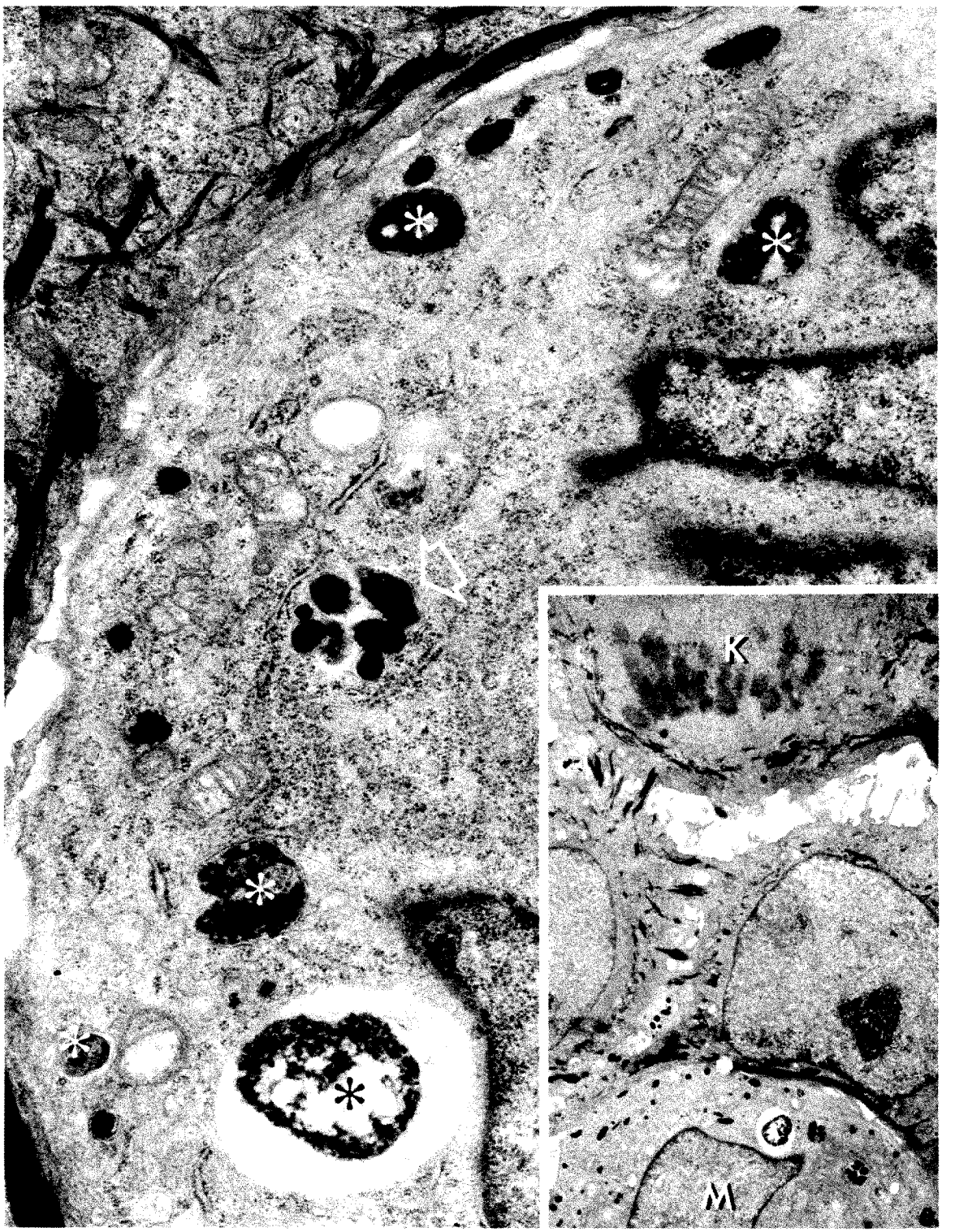

Fig 9.—Vitiligo (case 1). Keratinocyte (K) near degenerating melanocyte shows mitosis. Inset, Higher magnification of part of degenerating melanocyte (M). Note autophagocytosis within lysosomal vacuoles (asterisks) and aggregation of melanosomes (hollow arrow). Hypopigmented lesion (Fig 9: ×4,000; inset: ×24,000).

vitiligo, Vogt-Koyanagi syndrome, and incontinentia pigmenti achromians were almost identical (see Tables 1 and 2); the following descriptions, therefore, apply to all three depigmentary conditions.

In the depigmented area (the center of the lesion), no melanocytes were present and melanosomes in the keratinocytes were substantially decreased in number or absent. Most of the nonmelanocytic clear cells in the lesion of vitiligo and Vogt-Koyanagi syndrome were L-cells containing characteristic granules. In incontinentia pigmenti achromians, however, numerous cells that did not contain either melanosomes or L-cell granules were seen in the basal layers. Most of them were considered to be melanocytes since they were attached to the basal lamina with hemidesmosomes[13-15] (cf, Fig 4 and 5, bottom). At the epidermal-dermal junction, nerve endings were frequently observed.

In both the hypopigmented and the pigmented areas (the periphery of the lesion), many melanocytes had multiple abnormalities, ie, vacuolization of cytoplasm (Fig 6), fatty degeneration (Fig 7), autophagic vacuoles (Fig 4 and 8, bottom right), aggregation of melanosomes (Fig 7 and 9), and others (see Table 2). These abnormalities were present to a different degree in each cell. Degenerating melanocytes seen in the high level of the epidermis showed in their cytoplasm numerous autophagosomes at various stages of digestion (Fig 5, top right and left and bottom). A small number of melanocytes, however, showed no apparent sign of degeneration. Most of those in incontinentia pigmenti achromians showed a decrease in the number and size of their melanosomes. The L-cells found in the vicinity of these degenerating melanocytes appeared normal. No mitotic melanocyte or L-cell was found. Some basal keratinocytes surrounding the degenerated melanocytes showed mitosis (Fig 9).

Numerous nerve endings were seen in close contact with the basal lamina of the epidermis or even within the epidermis in both the hypopigmented and the pigmented areas of the lesion (Fig 4, 6, 8, 10, 11, top and bottom, and 12). These nerve endings were mostly associated with both normal (Fig 8, 10, and 11) and degenerated (Fig 4, 8, and 6) melanocytes of the basal layer of the epidermis. After serial sectioning, many nerve endings, which apparently were not associated with melanocytes in the first section, could be traced to the melanocytes or their dendritic processes. They consisted of one or more axons surrounded by small Schwann cell processes. Most of the axons were typical in that they contained many mitochondria, neurotubules, and small vesicles (Fig 4, 11, and 12, inset). Dense bodies, multivesicular bodies, and glycogen granules were also seen in various numbers. Direct continuities between Schwann cell basal lamina of nerve endings and the basal lamina of the melanocytes were observed (Fig 8 and 10).

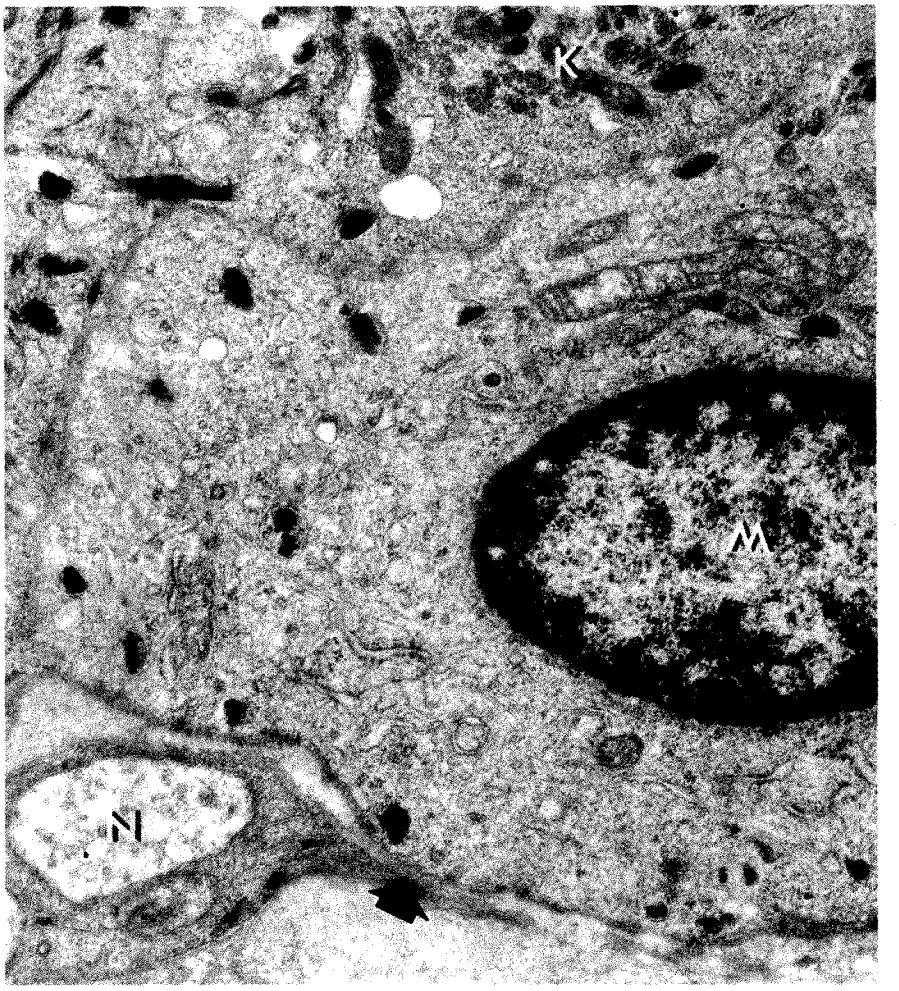

Fig 10.—Vogt-Koyanagi syndrome. Note direct association (dark arrow) between melanocyte (M) and nerve ending (N). Empty axon is due to fixation artifact. Keratinocyte indicated by K. Hypopigmented lesion (×17,000).

In the normal control skin taken from the incontinentia pigmenti achromians patients, nerve endings were also observed in close contact with the basal lamina of the epidermis. No melanocytes, however, showed either nuclear or cytoplasmic degeneration.

COMMENT

Degeneration of Melanocytes

In the present study, it was observed in all depigmenting conditions that melanocytes become coagulated, pyknotic, and presumably die. The same mechanisms of melanocyte degeneration were found in halo nevus.[7,8] The aggregation and autophagocytosis of melanosomes have been reported in degenerated melanocytes such as those in embryonic hair[16,17] and in other depigmenting

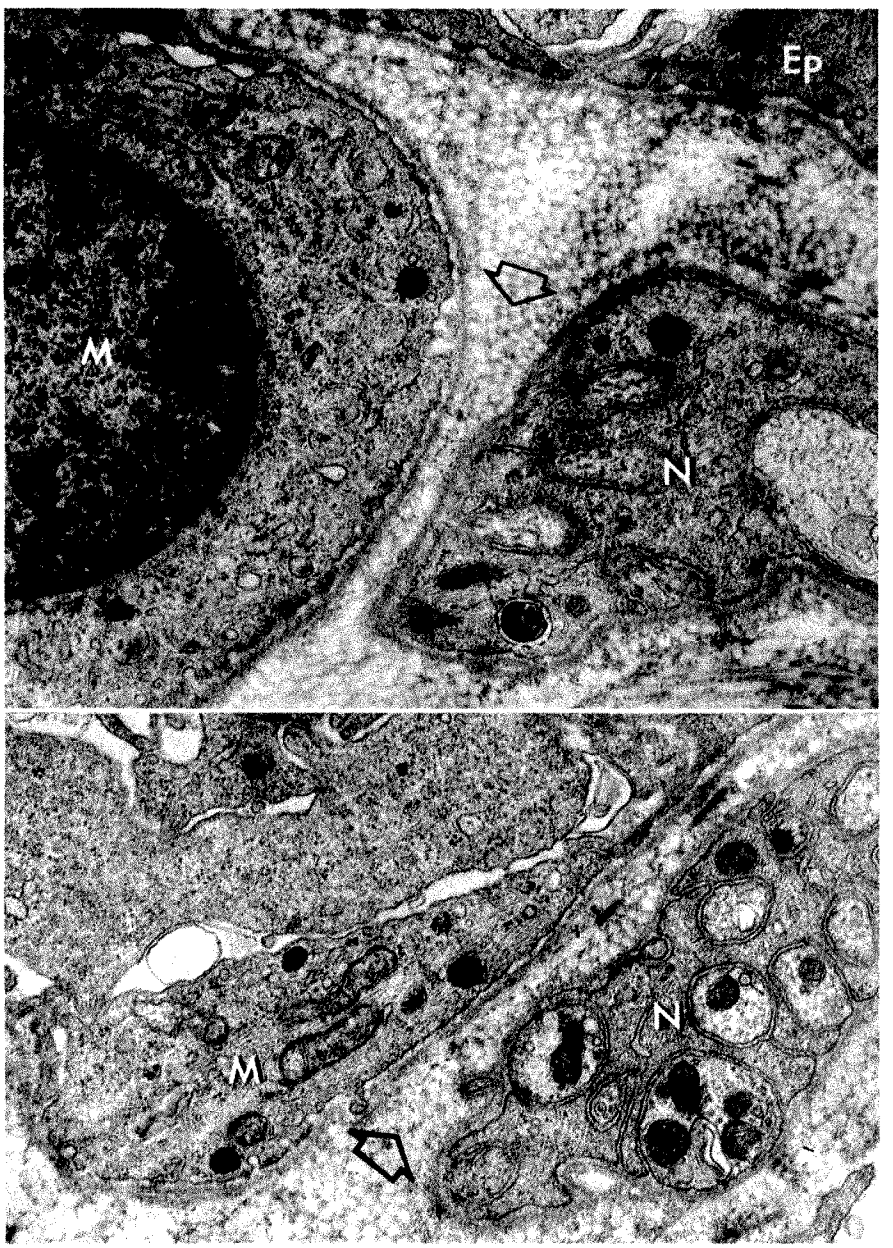

Fig 11.—Incontinentia pigmenti achromians (case 2). Top and bottom, Basal lamina of Schwann cells of nerve ending (N) in close association (hollow arrow) with basal lamina of melanocyte (M). Axons contain numerous mitochondria and neurotubules. Epidermis indicated by Ep. Hypopigmented lesion (×20,000).

conditions.[18,19] Since gradients of increasing severity of melanocyte degeneration were observed as the degree of depigmentation advanced from the normal to the hypopigmented areas in all diseases studied, it is surmised that a complete absence of melanocytes in the depigmented areas of these diseases also resulted from the same process of degeneration.

Applying the criterion that the epidermal melanocytes are connected to the basal lamina by hemidesmosomes,[13-15] many of the nonspecific basal dendritic cells[4,5] could be identified as nonpigment-producing melanocytes; the depigmentation in these diseases examined in the present study seems to be caused by both melanocyte degeneration and inactivation.

Nerve Connection to Melanocyte

The neural crest origin of the melanocyte is generally accepted and some investigators postulate that the epidermal melanocytes are under direct regulation of special nerves attached to them.[20] However, no ultrastructural proof has been presented. In the present study, a direct contact between melanocyte and nerve endings was shown in the hypopigmented skin lesions of three different depigmentary conditions. In a halo nevus case,[7] nerve endings were also demonstrated in the epidermis and the upper dermis. In view of the rarity of nerve ending-melanocyte association in the normal skin,[21-25] at least in the current literature, frequent association of nerve endings with melanocytes is, by itself, significant. Breathnach,[22] for example, stated that an axonal terminal with ensheathing Schwann cell process was observed to contact a basal epidermal cell "only once during five years of almost daily examination of the epidermal-dermal junction of interfollicular regions of human hairy skin."

On the other hand, Laties and Lerner,[26] while acknowledging the rare nerve-melanocyte association in the skin, reported that the sympathetectomized iris of brown-eyed rabbits became lighter. The tyrosinase activity of the melanocytes of such an iris decreased significantly (30% to 40%).

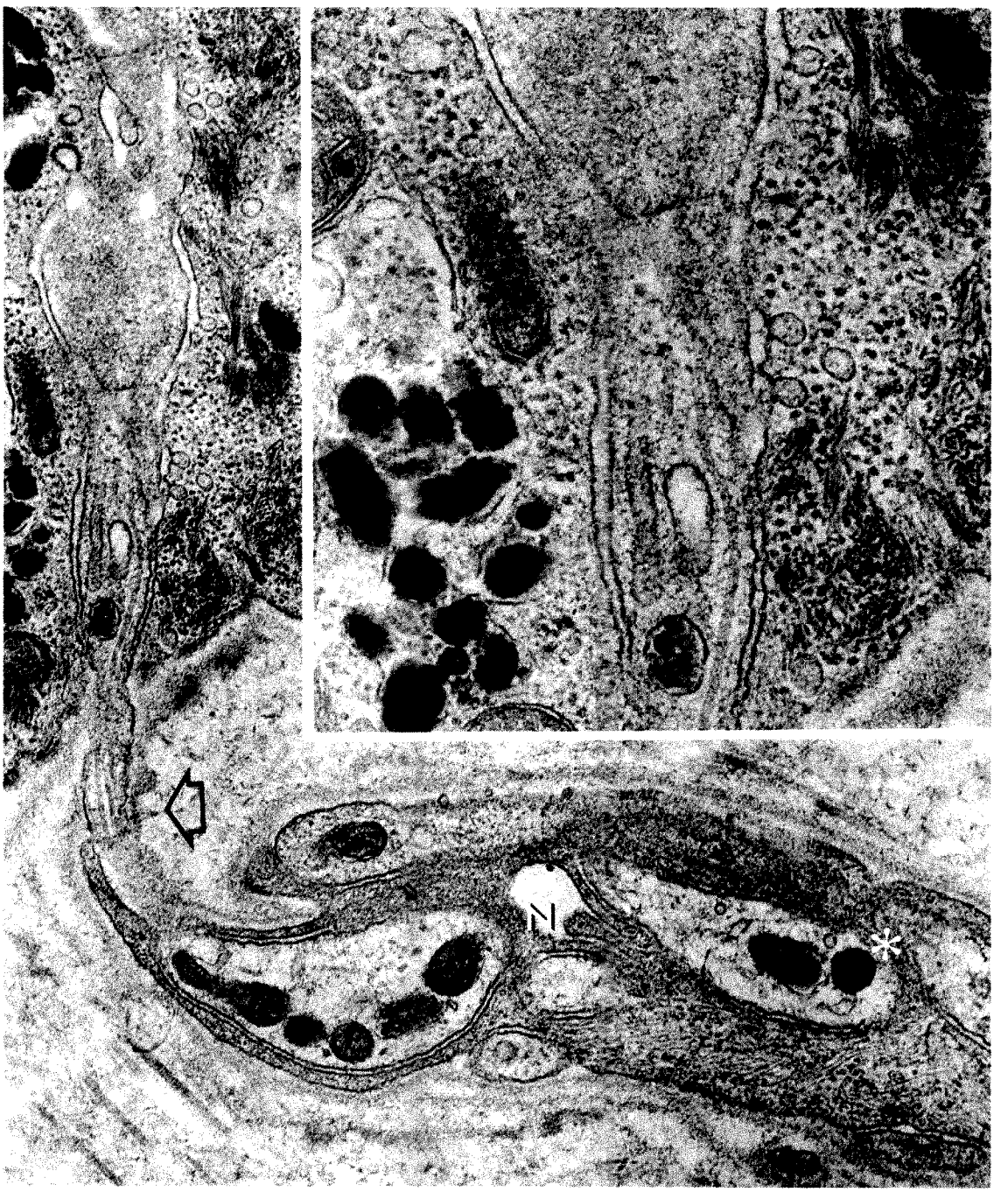

Fig 12.—Vitiligo (case 1). Low magnification of longitudinal section of nerve endings invading epidermis from dermis. Note direct continuity between Schwann cell basal lamina of nerve ending and basal lamina of epidermis (hollow arrow). Inset, Higher magnification of free nerve endings within epidermis. Hypopigmented lesion (×30,000; inset: ×58,000).

The assay of choroid melanocytes in the same eyes showed a similar decrease of tyrosinase activity. Although the iris contains stromal melanocytes that are directly innervated, it also has a posterior double lining of densely pigmented epithelial cells.

Since we have not engaged in an intensive search for nerve-melanocyte association in the normal skin, we are limited by the extent of the literature quoted.[21-25] We may have just detected in the lesion those nerve-melanocyte associations that may also be present in normal skin, simply because we examined the lesion very carefully.

With this reservation, one may speculate that an association of nerve endings with "normal" melanocytes in the lesion may signify the nerve-melanocyte contact initiates a degenerative process in the melanocytes; melanocytes undergo degeneration and the nerve invades the epidermis and replaces the melanocytes. Alternatively, those ultrastructurally "normal" melanocytes in the lesion may not be entirely normal in function; the nerve endings sense a subtle abnormality and approach them.

Dr Hashimoto is recipient of component projects 3499-01 and 3499-02 and the Medical Investigator award from the Veterans Administration.

References

1. Birbeck MS, Breathnach AS, Everall JD: An electron microscopic study of basal melanocytes and high-level clear cells (Langerhans) in vitiligo. *J Invest Dermatol* 37:51-64, 1961.
2. Breathnach AS: A new concept of the relation between the Langerhans cell and the melanocyte. *J Invest Dermatol* 40:279-281, 1963.
3. Breathnach AS, Bor S, Wyllie LMA: Electron microscopy of peripheral nerve terminals and marginal melanocytes in vitiligo. *J Invest Dermatol* 41:125-140, 1966.
4. Zelickson AS, Mottaz JH: Epidermal dendritic cells: A quantitative study. *Arch Dermatol* 98:652-658, 1968.
5. Mishima Y, Kawasaki H, Pinkus H: Dendritic cell dynamics in progressive depigmentations. *Arch Derm Forsch* 243:67-87, 1972.
6. Copeman PWM, Lewis MG, Phillips TM, et al: Immunological associations of the halo nevus with cutaneous malignant melanoma. *Br J Dermatol* 88:127-137, 1973.
7. Hashimoto K: Ultrastructural studies of halo nevus. *Cancer* 34:1653-1666, 1974.
8. Hashimoto K: A case of halo nevus with effete melanocytes. *Acta Dermatovener* (Stockholm) 55:87-95, 1975.
9. Lerner AB: Vitiligo. *J Invest Dermatol* 32:285-310, 1959.
10. Chanco-Turner ML, Lerner AB: Physiological changes in vitiligo. *Arch Dermatol* 91:390-396, 1965.
11. Pearse AGE: Oxidoreductases I (oxidases and peroxidases), in Histochemistry: Theoretical and Applied, ed 3. Baltimore, Williams & Wilkins Co, 1972, vol 2, pp 840-879.
12. Reynolds ES: The use of lead citrate at high pH as an electron-opaque stain in electron microscopy. *J Cell Biol* 17:208-212, 1963.
13. Odland GF: The fine structure of the interrelationship of cells in the human epidermis. *J Biophys Biochem Cytol* 4:529-538, 1958.
14. Tarnowski WM: Ultrastructure of the epidermal melanocyte dense plate. *J Invest Dermatol* 55:265-268, 1970.
15. Hashimoto K: Review of ultrastructure: Epidermal melanocyte. *Rinsho Derma* (Tokyo) 16:184-189, 1974.
16. Hashimoto K: The ultrastructure of the skin of human embryos: VIII. Melanoblast and intrafollicular melanocyte. *J Anat* 108:99-108, 1971.
17. Jimbow K, Szabo G, Fitzpatrick TB: Ultrastructural investigation of autophagocytosis of melanosomes and programmed death of melanocytes in white leghorn feathers: A study of morphogenetic events leading to hypomelanosis. *Dev Biol* 36:823, 1974.
18. Jimbow K, Fitzpatrick TB, Szabo G, et al: Congenital circumscribed hypomelanosis: A characterization based on electron microscopic study of tuberous sclerosis, nevus depigmentosus, and piebaldism. *J Invest Dermatol* 64:50-62, 1975.
19. Jimbow K, Obata H, Pathak MA, et al: Mechanism of depigmentation by hydroquinone. *J Invest Dermatol* 62:436-449, 1974.
20. Kawamura T, Ikeda S, Hori Y, et al: Pigmentary disorders, in Kawamura T, Fitzpatrick TB, Seiji M (eds): Asiatics: Biology of Normal and Abnormal Melanocytes. Baltimore, University Park Press, 1971, pp 351-367.
21. Winkelmann RK: Cutaneous nerves, in Zelickson AS (ed): *Ultrastructure of Normal and Abnormal Skin*. Philadelphia, Lea & Febiger, 1967, pp 202-227.
22. Breathnach AS: *An Atlas of the Ultrastructure of Human Skin*. London, Churchill, 1971, p 206.
23. Chouchkov CN: On the fine structure of free nerve endings in human digital skin, oral cavity and rectum. *Z Mikrosk Anat Forsch* 86:273-288, 1972.
24. Orfanos CE, Mahrle G: Ultrastructure and cytochemistry of human cutaneous nerves. *J Invest Dermatol* 61:108-120, 1973.
25. Cauna N: The free nerve endings of the human hairy skin. *J Anat* 115:277-288, 1973.
26. Laties AM, Lerner AB: Iris colour and relationship of tyrosinase activity to adrenergic innervation. *Nature* 255:152, 1975.

Inflammatory Linear Verrucose Epidermal Nevus

A Pathologic Study

André Dupre, Bernadette Christol

• We saw three patients with inflammatory linear verrucose epidermal nevus (ILVEN). The purpose of this study is to better delineate the histopathologic features of this type of nevus. In fact, in all three cases very particular, specific histologic lesions have been noted that permit us to better distinguish this recently outlined entity. The histologic features were depressed, cup-like areas of hypergranulosis with overlying orthokeratotic hyperkeratosis, alternating (with sharp demarcation) with raised, level areas of agranulosis with overlying parakeratotic hyperkeratosis.

(*Arch Dermatol* 113:767-769, 1977)

Altman and Mehregan[1] and Kaidbey and Kurban[2] have reported differentiation of inflammatory verrucose epidermal nevus (ILVEN) from various other linear eruptions. Recently, we reported three cases in the French literature,[3,4] and others have also recognized cases of ILVEN.[5-7] Furthermore, we consider that some cases reported by others[8,9] under various diagnoses seemed to be ILVEN rather than the diseases that were suspected. This literature survey strongly suggests the existence of a unique dermatosis that has already been singled out in the texts of Unna[10] and Pinkus and Mehregan,[11] but which has been somewhat forgotten. The purpose of the present study is to better delineate the histologic features of ILVEN and to emphasize their specificity.

MATERIALS AND METHODS

Our study is based on the observation of three patients, the photographs of whom have already been published.[3,4] Case 1 was a 7-year-old girl whose lesions appeared at the age of 6 months. They were three parallel linear lesions localized on the right buttock. Case 2 was a 22-year-old man. The lesions, which are localized on the inner aspect of the left thigh, appeared at about the age of 6 months. They formed a rectangular plaque with a large longitudinal axis. Some linear verrucose lesions were scattered over the dorsum of the left hand. Case 3 was a 10-year-old boy. The nevus appeared at the age of 1 year and involved the whole left lower extremity with predominance of lesions in the following areas: testicle, groin, buttock, anterior aspect of the thigh, inner aspect of the knee, and dorsal surface of the foot (Fig 1).

In these three cases there was a strictly unilateral eruption, elective involvement of the proximal part of the lower extremities, juxtaposed lichenoid or verrucous papules, which were linear or reticulated in distribution, psoriasiform or eczematous in character, and accompanied by constant pruritus.

RESULTS

The histopathologic lesions of ILVEN are of two different types: nonspecific and specific. The nonspecific lesions include the following: (1) a diffuse, lymphohistiocytic inflammatory dermal infiltrate that was always present, showing a pericapillary predominance, and occasionally containing some granulocytes; and (2) hyperacanthosis with papillomatosis of a psoriasis type. The epidermal ridges are elongated, often narrow, closely set, and sometimes coalescing. The thickness of the malpighian layer remains normal, but the coalescence of the ridges leads to the formation of a plaque rising slightly above the cutaneous surface.

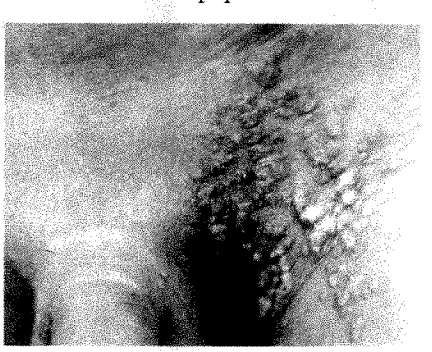

Fig 1.—Typical lesions on the thigh (case 3).

The epidermis very often consists of normal prickle cells. The occurrence of exoserosis and exocytosis in prickle cells has been emphasized by North American authors. These changes may lead to the formation of microabscesses, as occurs in psoriasis. In our cases, the exocytosis was mild or even absent.

The essential features of the specific lesions are as follows: There is an alternation of two types of keratinization processes, one with and the other without increase in granular cells (Fig 2 and 3). The areas of hypergranulosis are either very slightly or deeply depressed. When deeply depressed, they appear as cups, or as "pigeons' nests." There may be as many as four to eight layers of granular cells. Above each of these is an area of orthokeratotic hyperkeratosis, which is also depressed, cup-like, or funnel-like. The areas of agranulosis, on the contrary, are flattened, distinctly rising above the areas of hypergranulosis, forming an obtuse or table-like area. On top of these areas is thick parakeratosis.

The demarcation between the two areas is very sharp and very distinct at both levels: between the areas of agranulosis and hypergranulosis and between the areas of orthokeratotic and parakeratotic hyperkeratosis (Fig. 4).

Accessory Histopathologic Changes

Three histologic types of changes

Accepted for publication May 26, 1976.

From the Department of Dermatology, La Grave Hospital, Toulouse Cedex, France.

Reprint requests to Hôpital La Grave, Service de Dermatologie, 31052 Toulouse Cedex, France (Prof Dupre).

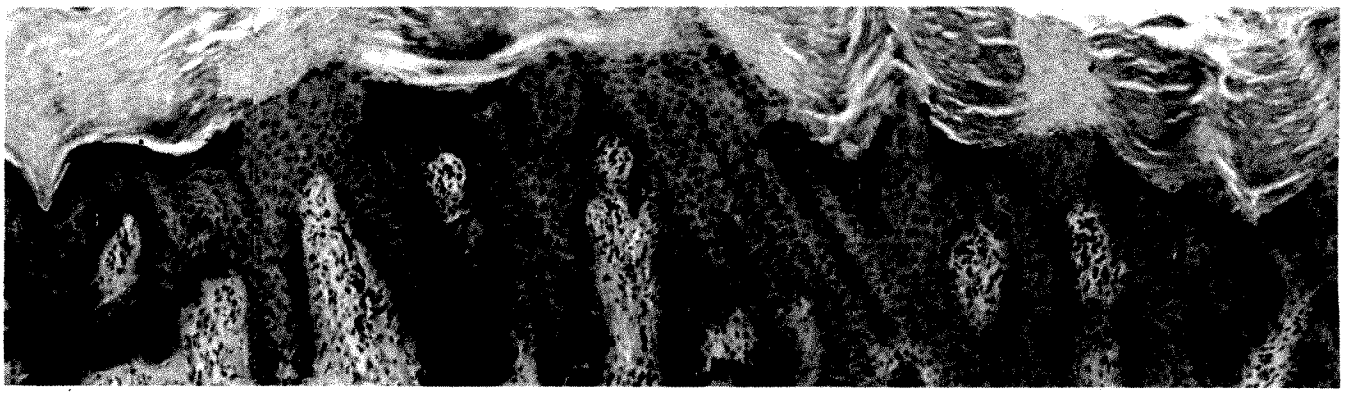

Fig 2.—General view (case 2) showing succession of areas of agranulosis with parakeratotic hyperkeratosis and cocoon-like areas of hypergranulosis with orthokeratotic hyperkeratosis.

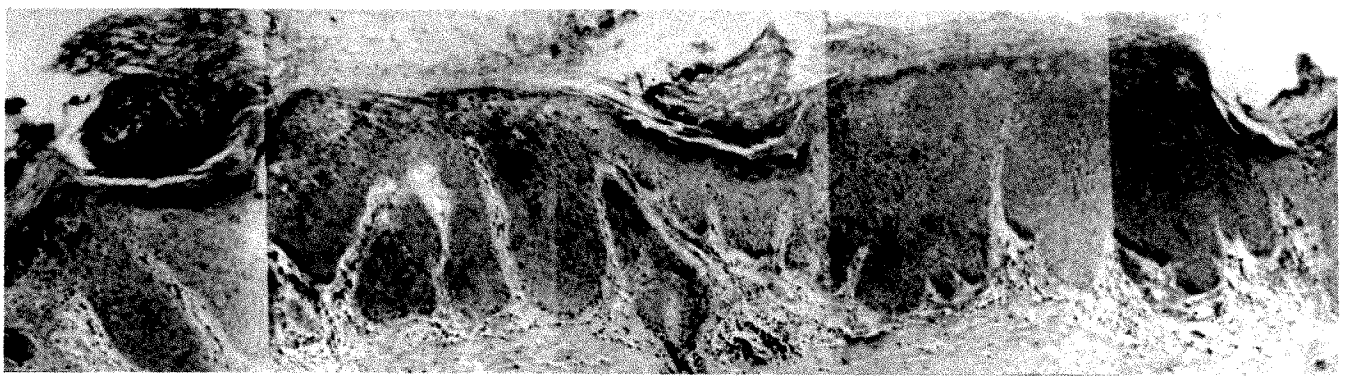

Fig 3.—General view (case 3) showing same succession of agranulosis and hypergranulosis areas.

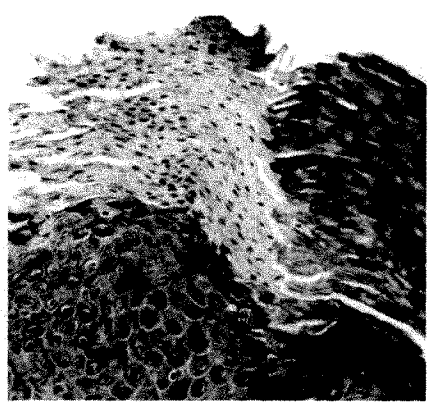

Fig 4.—Note sharp demarcation between areas of agranulosis and areas of hypergranulosis.

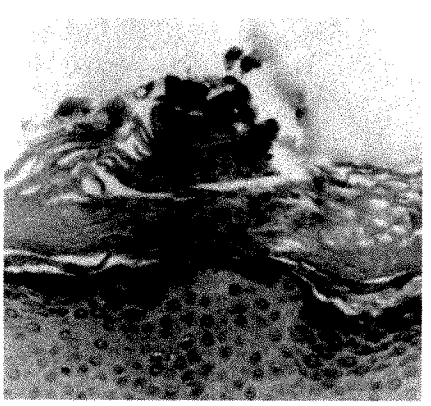

Fig 5.—"Pigeon's nest-like" area of hypergranulosis with overlying, orthokeratotic "comedo."

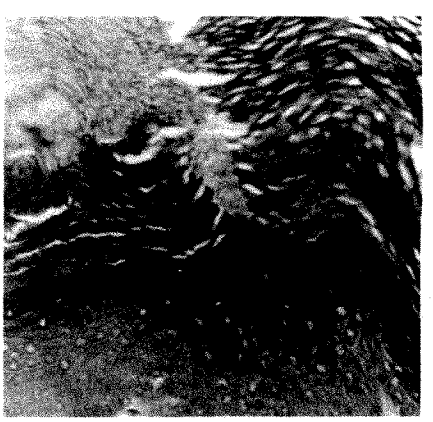

Fig 6.—Little area of hypergranulosis with overlying orthokeratotic whirlwind.

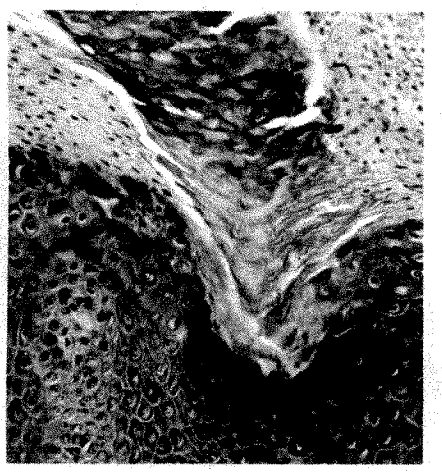

Fig 7.—Area of parakeratosis, presenting aspects as "piles of plates," within orthokeratotic area.

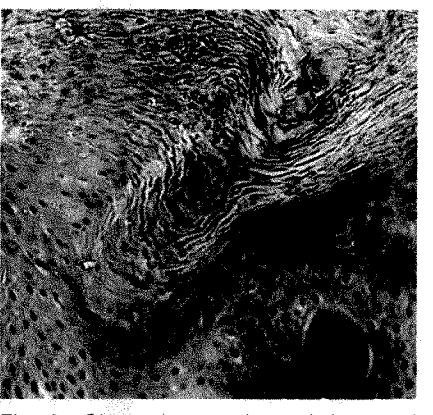

Fig 8.—Sharp interruption of layer of hypergranulosis resulting in column of parakeratotic cells.

are encountered in the areas of parakeratotic hyperkeratosis: (1) lamellar parakeratosis, in which there are numerous parakeratotic lamellae, arranged in dense and closely set strata, which sometimes tend to separate from each other but remain anastomosed together; (2) spongy parakeratosis of reticulated type with formation of globular horny masses varying in volume; and (3) parakeratosis with folded lamellae; in some areas, these lamellae seem to invaginate, to sink, wedge-shaped, into the epidermis. They appear, therefore, as "geological folds," tufts, or whorls (Fig 5 and 6). The areas of agranulosis may be very broad or, on the contrary, so narrow that the overlying area of parakeratosis may resemble a pile of plates (Fig 7 and 8), quite similar to the cornified lamella of Mibelli porokeratosis.

The two types of keratogenesis may alternate at short spatial intervals (Fig 2-4 and 7); in that case, the microscopic appearance is very distinctive and the diagnosis can be made readily. Sometimes the intervals are broad. That is, in one section there may be only a wide area of agranulosis delimited in the periphery by areas of hypergranulosis. These areas of hypergranulosis are then of great diagnostic value. However, this is evident in some complex pictures in which, for example, a layer of hypergranulosis, a layer of parakeratotic hyperkeratosis, and one of orthokeratotic hyperkeratosis are found one above the other. Such pictures indicate that the type of keratinization of a determinate area can change. An area that appears in a state of hypergranulosis later may become an area of agranulosis, and vice versa.

COMMENT

The consistent findings in three patients permit determination of the histologic criteria of ILVEN. Alterations in two types of keratinization have already been mentioned by several authors[1,2,8,9], but have not been explored enough. Our histologic criteria may not be found in all biopsy specimens; in some cases, and in particular when only a small biopsy specimen is available for study, the alternation perhaps will be less obvious than in our descriptions.

These findings indicate that ILVEN is a clinical and a histologic entity in which keratinization undergoes abrupt and complete changes to produce either orthokeratotic or parakeratotic hyperkeratosis. It seems as if the mixed keratinization has a mosaic structure consisting of the disorderly juxtaposition of variously sized areas of the opposite types. We believe that this phenomenon is unique in skin histopathology. An abrupt transition between or sharp margination of orthokeratotic from parakeratotic horn in alternating arrangement indeed is seen in such disparate pathologic processes as parakeratosis (Mibelli, disseminated superficial actinic, punctuate, and linear) and solar keratosis. However, in our opinion, the alternation of table-like parakeratotic areas and depressed orthokeratotic areas occurring at regular spatial intervals seems quite specific.

We cannot explain the sudden changes in the keratinization process. There is no alteration of the underlying acanthotic epidermis, and this seems to suggest that the pickle cell layer is apparently unaffected; exoserosis and exocytosis are often mild and sometimes absent. Moreover, the dermal infiltrate is definitely not responsible for the dyskeratogenesis. The infiltrate is very mild, nonspecific, and homogeneously distributed; it is found in the whole dermis, under the areas of agranulosis as well as under the areas of hypergranulosis. It is thus accessory, being the result and not the cause of the dyskeratogenesis. Therefore, ILVEN appears to be a disorder with very specific keratinization. Diseases with such a distinctive histologic substrate are rare in dermatology.

References

1. Altman J, Mehregan AH: Inflammatory linear verrucose epidermal nevus. *Arch Dermatol* 104:385-389, 1971.
2. Kaidbey H, Kurban K: Dermatotic epidermal nevus. *Arch Dermatol* 104:166-171, 1971.
3. Dupre A, Christol B, Vialars ML: Naevus épidermique verruqueux inflammatoire linéaire (N.E.V.I.L.): Dermatose lichénoide d'allure naevique, en plaques et en bandes prurigineuses (Boulle, Hewitt, Mme Boulle). Ses relations avec le syndrome du naevus épidermique de Solomon. *Ann Dermatol Syphiligr* 100:261-274, 1973.
4. Dupre A, Christol B, Vialars MI, et al: Naevus épidermique verruqueux inflammatoire linéaire. *Bull Soc Fr Dermatol Syphiligr* 82:163-164, 1975.
5. Delacretaz J, Belloni E: Naevus épidermique inflammatoire. *Bull Soc Fr Dermatol Syphiligr* 79:247, 1972.
6. Degos R, Belaich S, Larregue M, et al: Naevus épidermique verruqueux inflammatoire et linéaire. *Bull Soc Fr Dermatol Syphiligr* 80:270, 1973.
7. Stoitis G, Vigneron M, Paulmer M, et al: Naevus épidermique verruqueux inflammatoire linéaire. *Dermatologica* 148:189-197, 1974.
8. Boulle S, Hewitt J, Boulle M: Dermatose lichénoide d'allure naevique, en plaques et en bandes prurigineuses. *Bull Soc Fr Dermatol Syphiligr* 60:60-62, 1953.
9. Miguens MP, Guitian JP, Faya FV: Lesiones psoriasiformes de distribucion linear acompanadas de malformaciones congenitas. *Acta Dermato-Sifiliogr* 51:213-219, 1960.
10. Unna PG: *The Histopathology of the Disease of the Skin*. New York, MacMillan Book Co, 1896.
11. Pinkus H, Mehregan AG: *A Guide to Dermatohistopathology*. London, Butterworth, 1969, p 390.

Phototoxicity Occurring During the Manufacture of Ultraviolet-Cured Ink

Edward A. Emmett, MB, BS; Barbara R. Taphorn; John R. Kominsky, MS

• **Four workers employed in the manufacture of ultraviolet-cured inks complained of photosensitivity characterized by an intense burning sensation during sun exposure. Three of these workers developed dermatitis on exposed areas following sun exposure. Six compounds used as photoinitiators in the ink formulations were found to absorb solar ultraviolet radiation. Two preparations of mixed isomers (ortho and para) of amyl dimethylaminobenzoate were found to be phototoxic to Ehrlich ascites cells in vitro and to produce diphasic phototoxic reactions in vivo after topical application on symptomatic workers, asymptomatic workers, or previously unexposed subjects. These responses could be prevented in two subjects by the application of a 10% sulizobenzone sunscreen prior to sun exposure. Two other photoinitiators, Michler's ketone and thioxanthone were phototoxic in vitro but not after topical application in vivo.**

(*Arch Dermatol* 113:770-775, 1977)

Several men employed in the formulation of ultraviolet (UV)-cured inks complained of photosensitivity. In this article, we describe the investigation of these complaints and the finding that two preparations of mixed isomers of amyl dimethylaminobenzoate designated as absorber A and absorber B in the form in which they were used in this process were able to induce phototoxic responses both in vitro and after applications to human skin. Two other materials, thioxanthone and Michler's ketone were phototoxic in vitro, but a phototoxic response could not be demonstrated from topical application in vivo.

ULTRAVIOLET-CURED INKS

Ultraviolet cured inks are of relatively recent development but their use is becoming widespread. The ink composition varies but usually consists of one or more conventional pigments dispersed in a polymeric vehicle. The vehicle usually contains the following: (1) various polyfunctional acrylic monomers such as trimethylol propane triacrylate or pentaerythritol triacrylate, alone or in combination with monofunctional acrylic monomers; (2) an UV reactive unsaturated polymer such as acrylated urethane polyester oligomer, acrylated epoxy resin oligomer, and a variety of other types of acrylic base polymers; (3) one or more photoinitiators such as benzophenone, or isomers of amyl dimethylaminobenzoate; (4) diluents such as primary and aliphatic alcohols or phthalates; (5) hydrogen transfer agents such as triethanolamine; and (6) a variety of miscellaneous agents, including stablizers, surfactants, fillers, flattening agents, and polymerization inhibitors.

The first step in the curing process is the absorption of UV radiation by the photoinitiator (such as benzophenone). The absorption of UV results in the generation of free radicals or other photoexcited states, which in turn cause polymerization of the vehicle in which the pigments are incorporated and thus cure of the ink film. Medium pressure mercury arc lamps are generally used for the cure.

Accepted for publication Nov 15, 1976.

From the Department of Environmental Health, University of Cincinnati, (Dr Emmett and Ms Taphorn), and the National Institute for Occupational Safety and Health (Mr Kominsky), Cincinnati.

Reprint requests to Department of Environmental Health, Room 5251, College of Medicine, 231 Bethesda Ave, Cincinnati, OH 45267 (Dr Emmett).

Table 1.—Clinical Features in Four Employees Complaining of Photosensitivity

Characteristic	Employees 1	2	3	4
Symptoms	Burning on exposed areas within 5-10 minutes' sun exposure; exposure and swelling (lasting 2-3 days) after sun exposure	Burning on exposed areas within 5-10 minutes' sun exposure; erythema and swelling occur within a few hours of exposure	Burning on exposed areas within a few minutes of sun exposure, including sunlight through car window	Burning on exposed areas within a few minutes of sun exposure
Observed morphology	Erythema with sharp margin on V of neck and dorsal aspects of hands; lichenification of forearm	Erythema with fairly sharp margin on dorsal surface of both forearms	Erythema with sharp margins on forearms, outer surface of ears, and V of neck, sparing submental area	None
History of preexisting dermatitis	History of recent vesicular eruption on arms; severe exacerbation following sun exposure	No preexisting dermatitis	Recent intermittent itching, erythema, swelling, and scaling of forearm	Dermatophyte infection of feet
Results of closed patch testing with ink resin components*	Pentaerythritol triacrylate 0.2% in petrolatum: + +* Trimethylpropane triacrylate 1% in petrolatum: + + + Hexanediol diacrylate 1% in petrolatum: + + epoxy acrylate 1% in petrolatum: + +	No positive reactions	Pentaerythritol triacrylate 0.2% in petrolatum: + + Trimethylpropane triacrylate 1% in petrolatum: + + Hexanediol diacrylate 1% in petrolatum: + + Epoxy acrylate, 1% in petrolatum: +	No positive reactions

*Grading of reactions performed, using the scale recommended by the International Contact Dermatitis Group (1): negative reaction, —; doubtful reaction, ?+; weak (nonvesicular) reaction, +; strong (edematous or vesicular) reaction, + +; and extreme reaction, + + +.

CLINICAL FEATURES

Four white men, aged from 26 to 52, employed weighing, mixing, or milling UV-cured inks, complained of sensitivity to sunlight. The clinical characteristics in these subjects are given in Table 1. Subjective complaints included burning (smarting) on exposed areas occurring within a few minutes of sun exposure, persisting until the exposure ceased and erythema and swelling occurring within minutes to hours of sun exposure and lasting for up to several days. In two of the men, there was evidence of eczematous dermatitis, in both cases apparently due to allergic contact sensitization to certain acrylates used in the UV-cured ink formulation. The results of patch testing with these materials are shown in Table 1. In both men, the occurrence of marked smarting on sun exposure suggested additional photosensitivity, in one subject additional severe exacerbations of his eczematous lesions were described following sun exposure while gardening.

The unprotected skin and clothes of these men were frequently occupationally contaminated with components of the UV-ink. In no case was there a history of taking any known photosensitizing drug within the last year, a family history of photosensitivity, or clinical evidence of any disease known to be associated with photosensitivity. In each case, the burning sensation on sun exposure had not been present prior to exposure to UV-cured ink components and appeared temporally related to the manufacture of ultraviolet-cured ink.

INVESTIGATION OF PHOTOSENSITIVITY METHODS

Absorption Spectra.—In order to determine which of the materials used in the UV-cured ink formulation might cause photosensitization, the UV absorption spectra of all ingredients were determined in ethanol using a double beam spectrophotometer (Coleman 124).

In Vitro Phototoxicity.—Each of the UV-cured ink ingredients that absorbed UV radiation above 290 nm was evaluated for phototoxicity in an Ehrlich ascites cell system.

Ehrlich ascites cells were harvested from a mouse eight to ten days after implantation. After an initial staining with trypan blue and counting to ensure that the cells were viable, the cells were washed twice in lactated Ringer's solution before being put in suspension at a concentration of 2×10^6 cells/ml. Four sets (A, B, C, and D), each of two cell suspensions, were then studied. Sets A and B were incubated with the test material in the dark for two hours at room temperature, sets C and D were similarly incubated with the Ringer solution vehicle. After incubation, the cells were washed twice before being resuspended in lactated Ringer's solution in small Petri dishes. Sets A and C were then irradiated at a room temperature of 24 C, while sets B and D remained in the dark. The percentage of dead cells in each sample was determined 24 hours later by staining with the nonvital dye trypan blue. Cells were stained with this dye in the dark for at least two minutes before readings were made. Duplicate readings of at least 200 cells each were performed on each cell suspension. The mean and variance was calculated for the four percentage counts obtained on each set of results and the results for the different sets compared by the analysis of variance of a two by two factorial. In this way, it could be determined whether an interaction between the irradiation and the incubated chemical had occurred. Significance was determined using a two tailed t-test. The phototoxicity assay was recorded as positive when a statistically significant ($P < .05$) interaction between irradiation and the incubated chemical was determined in the above manner. The cells were irradiated either for ten minutes at a distance of 30 cm from a bank of four sunlamps (predominantly 293 to 325 nm radiation) or for one hour at a distance of 30 cm from a bank of four BLB40 black lights (predominently 330 to 380 nm radiation). The radiant exposure from the sunlamps measured with an IL700 spectroradiometer detector and narrow-band filter with a maximum spectral response at 297 nm and half power points at 291 and 303 nm was 9.4×10^{-6} joules/sq m. The

radiant exposure from the black lights measured with a IL700 spectroradiometer and detector with a wide-band filter with maximum response at 365 nm and half power points 330 and 400 nm was 4.1×10^{-4} joules/sq m. This exposure from the bank of sunlamps was sufficient to produce a slight decrease in the viability of control cells, whereas no alteration in the control cells was seen following this exposure from the blacklights. Where the compounds were not readily soluble in water, 5% ethanol in lactated Ringer's solution was used in place of lactated Ringer's solution for the incubation step. For each test, preliminary incubations at varying concentrations of the test material with the Ehrlich ascites cells were made in order to determine nontoxic concentrations for incubation.

Photopatch Testing.—Photopatch testing was performed on three employees (subjects 1 through 3), who complained of photosensitivity and four employees free of photosensitivity using the following UV-cured ink components: benzophenone, 5% in petrolatum; diethoxyacetophenone, 5% in petrolatum; thioxanthone, 5% in petrolatum; Michler's ketone, as is; absorber A, 5% in petrolatum; absorber B, 5% in petrolatum; absorber A, as is; and absorber B, as is.

Ink components used for photopatch testing were applied evenly to the central gauze portion of adhesive plastic strips 3.8 sq cm in size before application to the skin. Two duplicate sets of patches were applied to the back and were covered, secured, and occluded with several layers of hypoallergenic surgical tape. One set of patches was removed 24 hours after application and the area gently cleansed with 70% ethanol in water. These sites were then exposed to sunlight. Four employees working a day shift were exposed to 25 minutes of clear noon, July, Cincinnati (39 degrees north) sunlight and three employees to 35 minutes of sunlight from 3:50 PM that same day. Reactions were observed during the irradiation. The second set of patches that functioned as a dark control for the development of allergic contact or irritant reactions was removed 48 hours after application and the site gently cleansed with 70% alcohol. Reactions at both sites were read and graded one hour later.

In two subjects complaining of photosensitivity, the minimal erythema dose (MED) was determined as previously described,[2] an area 5 × 10 cm was irradiated with four times the MED and photopatch testing performed with a routine tray of diphenhydramine hydrochloride (Benadryl) cream; bergamot oil, 10% in petrolatum; bithionol 1% in petrolatum; 4'5 dibromosalicylanilide, 1% in petrolatum; eosin, as is; hexachlorophene, 0.5% in petrolatum; promethazine hydrochloride (Phenergan Cream), as is; tripelennamine (Pyribenzamine), 1% in petrolatum; tribromosalicylanilide, 1% in petrolatum; trichlorocarbanalide, 0.5% in petrolatum; triflurocarbanalide, 0.5% in petrolatum; and ragweed oleoresin.

In Vivo Phototoxicity and Photoprotection.—Two patches each of purified amyl *p*-dimethylaminobenzoate—absorber A and absorber B were applied as described above to the backs of four white subjects, aged 25 to 35, who had no previous industrial exposure to amyl *p*-dimethylaminobenzoates. Purified amyl *p*-dimethylaminobenzoate was also examined as were the two absorbers represent mixed isomers (para and ortho) dimethylaminobenzoate. After 24 hours one set of patches was removed and the area lightly cleansed with 70% ethanol in water while the second set was covered with an additional layer of black plastic tape. Twenty minutes after removal of the first set of patches, subjects were exposed to clear, noonday, Cincinnati (39 degree north) sunlight on Aug 5, 1975, for 30 minutes. Immediately afterwards, the second, previously occluded set of patches was removed and the area similarly cleansed with 70% ethanol in water. On three subjects, a third and fourth set of patches were applied that were also removed and the areas cleansed 20 minutes before sun exposure. The third set was immediately evenly covered with 2.5 μl/sq cm of a sunscreen containing 5%-*p*-aminobenzoic acid in alcohol (Presun) and the fourth evenly covered with 2.5 μl/sq cm of a sunscreen containing 10% sulisobenzone (Uval) 15 minutes prior to sun exposure. The reactions were observed during sun exposure, hourly for 5 hours and again 48 and 72 hours after patch application. No subjects had further sun exposure over this observation period.

RESULTS

Six photoinitiators used in UV-cured inks were found to absorb UV radiation above 250 nm namely benzophenone, thioxanthone, 2,2-diethoxyacetophenone, 4,4'-bis (dimethylamino) benzophenone (Michler's ketone), and two different commercial preparations of industrial grade mixed isomers of amyl dimethylaminobenzoate designated as absorber A and absorber B. The absorption peaks of these substances in alcohol are shown in Table 2. Absorber A had an absorption peak at 310 nm (ϵ -15,000) with one half the peak absorption at 288 and 326 nm, absorber B an absorption peak at 310 nm (ϵ = 20,000) with one half the peak absorption at 289 and 325 nm. Pharmaceutical grade amyl *p*-dimethylaminobenzoic acid had an absorption peak at 306 nm (ϵ = 30,000) with one half the peak absorption at 287 and 322 nm. Amyl ortho dimethylaminobenzoic acid has an absorption peak at 344 nm.

The results obtained from the in vitro phototoxicity assay of these substances using Ehrlich ascites cells are shown in Table 3. It will be seen that benzophenone and diethoxyacetophenone were not demonstrably phototoxic whereas Michler's ketone, thioxanthone, and the two absorbers containing mixed isomers of amyl dimethylaminobenzoate were phototoxic in this system. Both light sources, sunlamps and black lights, produce comparable results. Purified amyl *p*-dimethylaminobenzoate and *p*-aminobenzoate were also examined for phototoxicity in the same manner. As seen from the table, the amyl *p*-dimethylaminobenzoate was phototoxic whereas *p*-aminobenzoic acid was not. No phototoxicity was seen whether *p*-aminobenzoic acid was examined dissolved either in lactated Ringer's solution or 5% alcohol in lactated Ringer's solution.

The results of phototesting observed on three employees complaining of photosensitivity (subjects 1, 2, and 3 of Table 1) and four other employees not complaining of photo-

Table 2.—Absorption Peaks Above 250 nm of Certain Photoinitiators Used in UV-Cured Ink Formulations

Benzophenone	252, 338 nm
Thioxanthone	257, 286, 299, 379 nm
Diethoxyacetophenone	250, 330 nm
Michler's ketone	370 nm
Absorber A	310 nm
Absorber B	310 nm

Table 3.—In Vitro Phototoxicity of Photoinitiators Used in UV-Cured Inks and of Certain Other Chemically Related Substances

Test Substance	Concentration	Black Light (330-380 nm)	Sunlamp (293-325 nm)
Benzophenone	5×10^{-5} M	Negative	Negative
Thioxanthone	5×10^{-6} M	Positive ($P < .001$)	Positive ($P < .005$)
Diethoxyacetophenone	5×10^{-5} M	Negative	Negative
4,4'-bis (dimethylamino) benzophenone (Michler's ketone)	5×10^{-5} M	Positive ($P < .001$)	Positive ($P < .001$)
Absorber A (mixed isomers of amyl	5×10^{-5} M	Positive ($P < .001$)	Positive ($P < .001$)
p-Dimethylaminobenzoate)	5×10^{-6} M	Positive ($P < .02$)	
Absorber B (mixed isomers of)	5×10^{-5} M	Positive ($P < .001$)	Positive ($P < .001$)
Amyl *p*-dimethylaminobenzoate	5×10^{-6} M	Positive ($P < .001$)	
p-Aminobenzoate	5×10^{-5}	Negative	Negative
Amyl-*p*-dimethylamino	5×10^{-5} M	Positive ($P < .001$)	Positive ($P < .001$)
benzoate	5×10^{-6} M	Positive ($P < .05$)	

Table 4.—Reactions at Sun Exposed Sites*

	Subjects						
	1	2	3	5	6	7	8
Absorber A during sun exposure	+S	+S	?+S	?+S	+S	+S	—
24 hr after sun exposure	+ +	—	+	+ +	+	+	+
Absorber B during sun exposure	+S	+S	?+S	?+S	+S	—	—
24 hr after sun exposure	—	—	+	+	—	—	—

*S indicates smarting reaction during sun exposure. Grading of visible reactions was performed, using the scale recommended by the International Contact Dermatitis Group[1]: negative, —; doubtful reaction, ?+; weak (nonvesicular) reaction +; strong (edematous or vesicular) reaction, + +; and extreme reaction, + + +. Subjects 1, 6, 7, and 8 were exposed to Monday sun and subjects 2, 3, and 5 to afternoon sun.

Table 5.—Reactions Observed in Four Normal Volunteers at Completion of Sun Exposure and 24 Hours After Sun Exposure*

	At Completion of Sun Exposure Subjects				24 Hours After Sun Exposure Subjects			
Treatment	1	2	3	4	1	2	3	4
Kept in dark								
Purified amyl p-dimethylaminobenzoate	—	—	—	—	—	—	—	—
Absorber A	—	—	—	—	—	—	—	—
Absorber B	—	—	—	—	—	—	—	—
No treatment	—	—	—	—	—	—	—	—
30 Minute sun exposure								
Purified amyl p-dimethylaminobenzoate	2	—	—	—	1	—	—	—
Absorber A	3	2	—	2	2	2	—	2
Absorber B	3	2	—	2	2	2	—	2
No treatment	—	—	—	—	—	—	—	—
30 Minute sun exposure + 5% *p*-aminobenzoic acid screen								
Purified amyl p-dimethylaminobenzoate	—	—	—	NT	—	—	—	NT
Absorber A	2	1	—	NT	2	1	—	NT
Absorber B	2	1	—	NT	2	1	—	NT
No treatment	—	—	—	NT	—	—	—	NT
30 Minute sun exposure + 10% sulisobenzone screen								
Purified amyl p-dimethylaminobenzoate	—	—	—	NT	—	—	—	NT
Absorber A	—	—	—	NT	—	—	—	NT
Absorber B	—	—	—	NT	—	—	—	NT
No treatment	—	—	—	NT	—	—	—	NT

*Readings were recorded according to the criteria: No reaction, —; mild erythema with indistinct borders, 1; marked erythema with distinct borders, 2; erythema with edema, 3; erythema, edema and vesiculation, 4; and not tested, NT.

sensitivity are shown in Table 4. The majority of subjects complained of a sharp stinging or burning sensation within a few minutes of sun exposure localized to the exposed areas where absorber A as is, and absorber B, as is, had been applied. Four subjects developed sharply marginated erythema and two faint or questionable erythema responses on the absorber A site during sun exposure and three subjects sharply marginated erythema and two faint questionable erythema at the absorber B site during sun exposure. Twenty-four hours after sun exposure, six of the seven men (including subject 7, a deeply pigmented black) had a reaction consisting of uniform erythema and edema on the area exposed to undiluted absorber A and sunlight; two of the seven men also had reactions to undiluted absorber B under the same conditions. No reactions were seen to absorbers A or B on sites occluded from sunlight. No reactions were seen with the other UV ink components phototested either on exposed or occluded sites, apart from a single weak reaction to Michler's ketone on a patch test site occluded from sunlight that was interpreted as an irritant reaction. No reactions were seen on sun-exposed or control sites tested with either absorber A or absorber B diluted to 5% in petrolatum. Photosensitive subjects 2 and 3 had further testing. Both had a normal minimal erythema dose; negative photopatch testing with a routine tray, no demonstrable circulating antinuclear antibody, and no abnormal reaction at 24, 48, or 168 hours to irradiation with

four times the minimal erythema dose of UVB.

In order to examine the characteristics of the phototoxic responses to absorber A and absorber B more closely, further observations were made on the phototoxic responses in four individuals without previous known industrial exposure to these materials. Observations were also made on the photoprotective effect of sunscreens representative of two different classes of sunscreens in three of these individuals. Three of the four subjects noted a sharply localized intense burning sensation that commenced a few minutes after the areas patch tested with absorbers A and B were exposed to sunlight. No burning occurred on the covered areas. The burning sensation was accompanied by erythema, and in one case, prominent edema. One subject also developed erythema and a burning sensation at the site of application of the purified amyl *p*-dimethylaminobenzoate. In each case, the burning stopped within a few minutes of the cessation of sun exposure.

The reaction was observed to be diphasic, the erythema and swelling began to fade shortly after sun exposure ceased and had disappeared in two subjects within one hour and in the third, more severely affected subject, two hours after sun exposure ceased. Four to five hours after the sun exposure, erythema recurred and remained for two to five days. Mild discomfort and irritation accompanied the reappearance in each case, but the intense burning noted during sun exposure was not evident. The reactions noted in each subject immediately following and 24 hours after sun exposure are shown in Table 5.

Two of the three subjects to whom sunscreens were applied developed a phototoxic response so that the degree of photoprotection could be estimated. As seen from Table 5, the prior application of a 5% *p*-aminobenzoic acid sunscreen provided partial protection against the reaction whereas the application of a 10% sulisobenzone sunscreen was able to completely suppress the development of the phototoxic response under the conditions of exposure.

COMMENT

The two industrial preparations of mixed isomers of amyl dimethylaminobenzoate designated as absorber A and absorber B were demonstrated to be phototoxic with either UVA (280 to 315 nm) or UVB (315 to 400 nm) to Ehrlich ascites cells in vitro and with sunlight to human skin in vivo. The phototoxic reaction could be reproduced even in deeply pigmented black skin. The phototoxic nature of the in vivo responses was indicated by the relative immediacy of the response to sunlight, the intense burning sensation on exposure to sunlight, the ability to reproduce the reaction in other employees not complaining clinically of photosensitivity, as well as in previously unexposed persons, and the failure of reactions to occur when these substances were diluted. The chemical structure of amyl *p*-dimethylaminobenzoate is shown in the Figure. Although Michler's ketone was noted to be phototoxic in vitro, a phototoxic response to this substance could not be reproduced by topical application to human skin and subsequent exposure to sunlight. Thioxanthone also gave a phototoxic response in vitro, but not at 5% concentration in vivo and was not studied further as it had rarely been used in the industrial process.

Two of the four employees complaining of photosensitivity also had allergic contact sensitization to acrylic monomers and epoxy acrylate oligomers to which they had been exposed. However, sun exposure of skin involved in allergic contact dermatitis does not usually provoke the very intense burning sensation and the exacerbations of dermatitis that these subjects described.[3,4] Their photosensitivity seems better explained as clinical phototoxic reactions to the undiluted absorbers A and B that they handled during their work.

It has been previously suggested[5] that the allergenicity of benzyl salicylate, a weak contact sensitizer, may have been enhanced by the phototoxic effect of simultaneously applied topical methoxsalen. The same effect may have enhanced the allergenicity of the acrylate monomers and epoxy acrylate oligomers in this instance. One

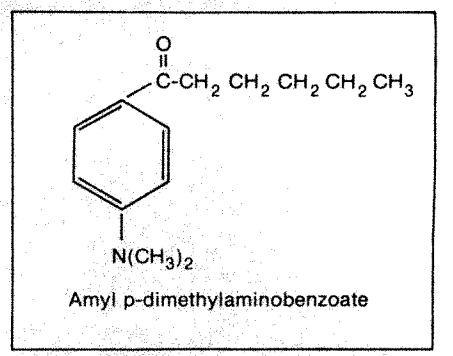

Chemical structure of amyl dimethylaminobenzoate.

could also speculate that the simultaneous allergic contact dermatitis in several of these employees with attendant damage to the epidermal barrier might have increased the penetration of the phototoxic materials and thus rendered the phototoxic response more easily elicitable.

The phototoxic reactions observed on human skin after experimental application of the two industrial absorbers were noted to be diphasic. The burning sensation (smarting reaction) described during sun exposure and the ensuing dermatitis observed by employees appear to parallel the two phases. The initial intense smarting reaction on sun exposure has been noted in other phototoxic reactions, such as those occurring in pitch workers[6] and is common to all crude coal tars. In addition, demeclocycline hydrochloride (Declomycin) phototoxicity is associated with paraesthesiae during sun exposure, and burning and itching during sun exposure are commonly observed in patients with erythrocytic protoporphyria. In the case of the mixed isomers of amyl dimethylaminobenzoate, the initial burning was also accompanied by erythema and sometimes transient wheal formation confined to the site of the reaction. This reaction disappeared completely before the recurrence of erythema and discomfort some hours later.

The phototoxic reactions observed with the two industrial preparations of undiluted mixed isomers of amyl dimethylaminobenzoate was somewhat surprising as purified amyl *p*-dimethylaminobenzoate is demonstrably effective at a 5% concentra-

tion as a sunscreen.[7] No phototoxicity was observed in these employees when a 5% concentration of amyl *p*-dimethylaminobenzoic acid was applied. A difference between protective and toxic responses depending on the circumstances of use would seem to illustrate the important toxicologic principle that the hazard from any material is highly dependent on the circumstances of its use. The phototoxic reaction on human skin with pure amyl *p*-dimethylaminobenzoate was less marked than with the mixed isomer preparations suggesting that other isomers may be the most important phototoxic agents. However, pure amyl *p*-dimethylaminobenzoate could be observed in vitro to be phototoxic, whereas neither benzophenone nor *p*-aminobenzoic acid were observed to be phototoxic in vitro.

The phototoxic effect observed on the skin of volunteers could be blocked by the prior topical application of a 10% sulisobenzone (2-hydroxy-4-benzophenone-5 sulphonic acid) preparation but only partially blocked by a similar application of 5% *p*-aminobenzoic acid in alcohol. This suggests that sulizobenzone preparations which are effective screens in the UVA as well as the UVB range[1] may prove useful sunscreening agents for use in accidental skin contamination by the amyl dimethylaminobenzoate esters. The relative ineffectiveness of *p*-aminobenzoic acid (absorption maximum in water 266 nm, absorption extending to 310 nm) presumably depends on its ineffectiveness against the wavelengths of 310 and greater. Although it has been held that only physical sunscreens such as zinc oxide, titanium dioxide, or red veterinary petrolatum are effective against industrial phototoxic agents,[8] there seems to be no good reason why a sunscreen eliminating the requisite wavelengths cannot satisfactorily block phototoxic responses as has been recently demonstrated in the case of vinblastine.[9]

This investigation was supported in part by the National Institute for Occupational Safety and Health and also by grant 00159-OH from the National Institute for Environmental Health Sciences.

Nonproprietary Names and Trademarks of Drugs

Tribromsalan—*Cuticura Soap, Lifebuoy, Praise, Temasept IV, Tuasal.*

Triclocarban—*Dial Soap, Creed Bar Soap, Jergens Deodorant Soap, Tackle Medicated Soap, TCC.*

References

1. Wilkinson DS, Fregert S, Magnusson B, et al: Terminology of contact dermatitis. *Acta Dermatol Venerol* 50:287-292, 1970.

2. Emmett EA: Fixed long ultraviolet light eruption. *Arch Dermatol* 111:212-214, 1975.

3. Fisher AA: *Contact Dermatitis*, ed 2. Philadelphia. Lea and Febiger, 1973.

4. Haniszko J, Suskind RR: The effect of ultraviolet radiation on experimental cutaneous sensitization in guinea pigs. *J Invest Dermatol* 40:183-191, 1963.

5. Kahn G: Intensified contact sensitization to benzyl salicylate. *Arch Dermatol* 103:497-500, 1971.

6. Crow KD, Alexander E, Buck WHL, et al: Photosensitivity due to pitch. *Br J Dermatol* 73:220-232, 1961.

7. Pathak MA, Fitzpatrick TB, Frenke E: Evaluation of topical agents that prevent sunburn: Superiority of para aminobenzoic acid and its esters in ethyl alcohol. *N Engl J Med* 280:1459, 1969.

8. Birmingham DJ, Key MM, Tubick GE, et al: Phototoxic bullae amongst celery harvesters. *Arch Dermatol* 83:73-87, 1961.

9. Breza TS, Halprin KM, Taylor JR: Photosensitivity reaction to vinblastine. *Arch Dermatol* 111:1168-1170, 1975.

Vegetables Responsible

Syamalendra M. Sinha, MD; Jagjit S. Pasricha, MD, PhD; Ramesh C. Sharma, MSc, PhD; Kahn C. Kandhari, FRCP

• **Fifty-three patients having contact dermatitis on the fingertips showed positive patch tests with several vegetables, the commonest being garlic, onion, tomato, and carrot in that order of frequency. Of several preparations, made from garlic, onion, tomato, and carrot, the juices used as such gave the maximum number of positive patch test reactions. Lyophilization of the juices led to false-negative patch tests in some cases. Patch tests in the controls were positive in some cases but these were probably cases of latent hypersensitivity, because some of them, like the patients, showed positive reactions even with the diluted juices. The antigens in garlic and onion were extractable in water, ether, acetone, or alcohol and were also present in the essential oils of these vegetables. Infrared spectra of the essential oils of garlic and onion were similar and showed straight chain acids, esters, and methylene groups. Clinically, there was no suggestion of cross-sensitivity between onion and garlic.**

(*Arch Dermatol* 113:776-779, 1977)

Many housewives in north India have hyperkeratosis, scaling and fissures on the tips of the thumb, the index, and the middle fingers of one or both hands associated with severe itching. Most of these patients report aggravations of the lesions following contact with raw vegetables, and in a pilot study, all the patients showed positive patch tests with the juices of one or more vegetables. The literature on this subject[1-9] tends to create the impression that contact dermatitis due to vegetables is uncommon and occurs mainly among workers in the canning industry. We are reporting our findings on the frequency with which various vegetables produce contact dermatitis, results of patch tests with various types of preparations from some vegetables, and some data on the identification of the chemicals responsible for hypersensitivity.

Accepted for publication Nov 8, 1976.

From the Departments of Dermato-Venereology (Drs Sinha, Pasricha, and Kandhari) and Pharmacology (Dr Sharma), All India Institute of Medical Sciences, New Delhi.

Reprint requests to Department of Dermatology, AIIMS, New Delhi-110016, India (Dr Pasricha).

CLINICAL DATA

In two years, 53 patients (49 women and four men) were seen with contact dermatitis due to vegetables. All the women were engaged in household work; while two men were employed as cooks and the remaining two men used to cook as a hobby. All patients showed hyperkeratosis, scaling, fissuring, and erythema on the palmar aspects of the tips of the thumb, the index, and the middle fingers. Three patients had involvement of the dorsal aspects of the fingers also. In 48 patients, both the hands were involved; in three, the lesions were present only on the right hand; and in the remaining two, only the left hand was involved.

PATCH TESTS

Patch tests were performed in every case with the freshly extracted juices of all the vegetables used by the patient, using 0.05 ml of the juice per patch. The results were read on the third day, and the patch test was considered to be positive only if it produced at least a 2+ reaction. In general, recommendations of Fisher[10] were followed.

Table 1 shows the number of patients who showed positive reactions to various vegetables. Garlic (*Allium sativum*), onion (*Allium cepa*), tomato (*Lycopersicon esculentum*), and carrot (*Daucus carota*) were responsible for the maximum number of positive reactions in that order of frequency. Less frequently, other vegetables also produced positive patch tests. By preventing further exposures to the respective vegetables, none of the patients had a recurrence. Routine patch tests with soaps, common household detergents, and nickel sulfate were negative in all cases.

Patch Tests With the Prepared Antigens of Garlic, Onion, Tomato, and Carrot

Standard varieties of onion (Pusa-Red),

or Contact Dermatitis of the Hands

tomato (Pusa-Ruby), and carrot (Pusa-Keshar) were obtained from the Indian Agricultural Research Institute, New Delhi, while garlic was purchased from the market. Each of these vegetables was cleaned, peeled, and crushed in a mechanical extractor to obtain the juice. The remaining pulp was mixed with one half its weight of water, kept at room temperature overnight, and filtered to obtain the extract. A part of the juice was evaporated to dryness in a lyophilizer, and the residue was redissolved in distilled water to make the original volume. This will henceforth be called the solution. To assess the degree of hypersensitivity of different patients, aliquots of each of the juice, the extract, and the solution were diluted with distilled water to make 50%, 20%, and 10% concentrations. Eleven patients each, known to be allergic to garlic and onion respectively, five patients allergic to tomato, and two patients allergic to carrot were tested with various preparations of the respective vegetables and their various dilutions. In addition, every patient was also tested with the freshly extracted juice of the respective vegetable to assess the possibility of nonspecific irritant reactions with fresh juices of vegetables.

The results are shown in Table 2. All the allergic patients showed positive patch tests with the freshly extracted juice of the corresponding vegetable; the prepared juices gave comparable results, except that two patients each tested with onion and tomato gave negative patch tests. The solution and the extract of various vegetables showed negative patch tests in several patients. Dilution of the vegetable juices to 50% concentration resulted in negative reactions in some patients, though some patients showed positive patch tests even with 10% concentration of the juice.

Controls

Four groups of 20 patients each, having contact dermatitis due to some other substance, were taken as controls and tested with the fresh as well as the prepared juices of garlic, onion, tomato, and carrot, respectively. They were also

Table 1.—Incidence of Positive Patch Tests With Various Vegetables

Vegetable	Botanical Name	No. of Patients Having Positive Patch Test
Garlic	*Allium sativum*	44
Onion	*Allium cepa*	30
Tomato	*Lycopersicon esculentum*	10
Carrot	*Daucus carota*	9
Lady's finger	*Hibiscus esculentus*	6
Ginger	*Zinziber officinale*	6
Brinjal	*Solanium malongena*	6
Radish	*Raphanus sativus*	5
Cauliflower	*Brassica oleracea*	5
Potato	*Solanum tuberosum*	4
Gourd	*Cucurbita maxima*	3
Pea	*Pisum arvense*	2
Colocasia	*Colocasia antiquorium*	2
Cucumber	*Cucumis sativus*	1
Bean	*Vicia faba*	1
Turnip	*Brassica rapo*	1
Bitter gourd	*Momordica dioica*	1
Coriander	*Coriandrum sativum*	1
Smooth luffa	*Luffa acutangula*	1
Spinach	*Spinacia oleracea*	1
Round gourd	*Citrullus vulgaris*	1

tested with various dilutions of the prepared juices.

With the fresh juices, seven controls were positive with garlic, three with onion, four with tomato, and one with carrot, while with the prepared juices, five controls were positive with garlic, and two each with onion and tomato. Some of these controls were positive even with the diluted vegetable juices.

Out of another group of 20 controls tested with fresh garlic juice only used as such, five showed positive patch tests.

Patch Tests With Different Varieties of Onion

The following five different varieties of onion were obtained: (1) N-53, red; (2) N-24-1, red; (3) N-257-9-1, white; (4) N-5-7-1, white; and (5) N-123-7-1, white. Onion juices were obtained from each of these varieties by a juice extractor and used as such for patch tests on five patients allergic to onion and one control subject.

Positive patch test reactions of almost equal intensity were obtained with all the five varieties of juices in all the five patients who were allergic to onion, but the tests in the control subject were negative.

Extraction of the Antigens From Onion and Garlic

One hundred grams of onion of the Pusa-Red variety were peeled, chopped, and kept immersed in 150 ml of petroleum ether in a percolator at room temperature for 24 hours. At the end of this period, the ether was decanted, and the onions were mixed with 150 ml more of petroleum ether. Three washings of petroleum ether collected on three consecutive days were pooled to constitute the ether soluble fraction. The residue of the onions was then extracted with three successive changes of 150 ml each of acetone and then with absolute alcohol, and finally with water to give acetone soluble, alcohol soluble, and water soluble fractions, respectively. Each of these fractions was evaporated to dryness and then redissolved in 1 ml of water.

One hundred grams of garlic purchased from the market were also processed in the same manner to obtain ether soluble, acetone soluble, alcohol soluble, and water soluble fractions of garlic.

Patch tests were performed with all these fractions of onion on four patients known to be allergic to onion and five control subjects, while fractions obtained from garlic were tested on seven patients allergic to garlic and six control subjects.

All the four patients allergic to onion showed positive patch tests with the ether soluble, acetone soluble, and alcohol soluble fractions, but patch tests with the water soluble fraction were negative in all. None of the other five patients taken as controls showed a positive patch test with any of the fractions.

With garlic, all seven patients allergic to garlic showed positive patch tests with all the fractions including the water soluble fraction, whereas all the six controls were negative.

Patch Tests With the Essential Oils of Onion and Garlic

Essential oil of onion was prepared by steam distillation of 100 gm Pusa-Red variety of onion bulbs at 100 C for four hours. The essential oil weighing 0.023 gm was dissolved in 1 ml of olive oil and used for patch tests on two patients allergic to onion and ten controls.

Essential oil of garlic was prepared in a similar manner from 100 gm of garlic bulbs and weighed 0.80 gm. It was also dissolved in 1 ml of olive oil and used for patch tests on five patients allergic to garlic and six controls.

Patch tests with the essential oil of onion were positive in both the patients allergic to onion, and also in one out of ten controls. With the essential oil of garlic, all the five patients allergic to garlic showed positive patch tests, while all the six controls were negative.

Infrared Spectra of the Essential Oils of Onion and Garlic

The infrared spectrophotometer, was used to determine the infrared spectra of the essential oils of onion and garlic. The spectra were taken in carbon tetrachloride using 0.1 mm of sodium chloride cells. Solubility of the essential oil of onion was

Table 2.—Efficiency of Juice, Extract, and Solution Compared to Freshly Extracted Juice of Vegetables as Patch Test Material

Vegetable	No. of Patients Tested	No. of Patients Having Positive Patch Test						
		Juice		Extract		Solution		
		As Such	50% Concentration	As Such	50% Concentration	As Such	50% Concentration	Fresh Juice
Garlic	11	11	Nil	9	Nil	10	Nil	11
Onion	11	9	2	7	4	6	2	11
Tomato	5	3	1	3	1	Nil	Nil	5
Carrot	2	2	1	1	Nil	1	Nil	2

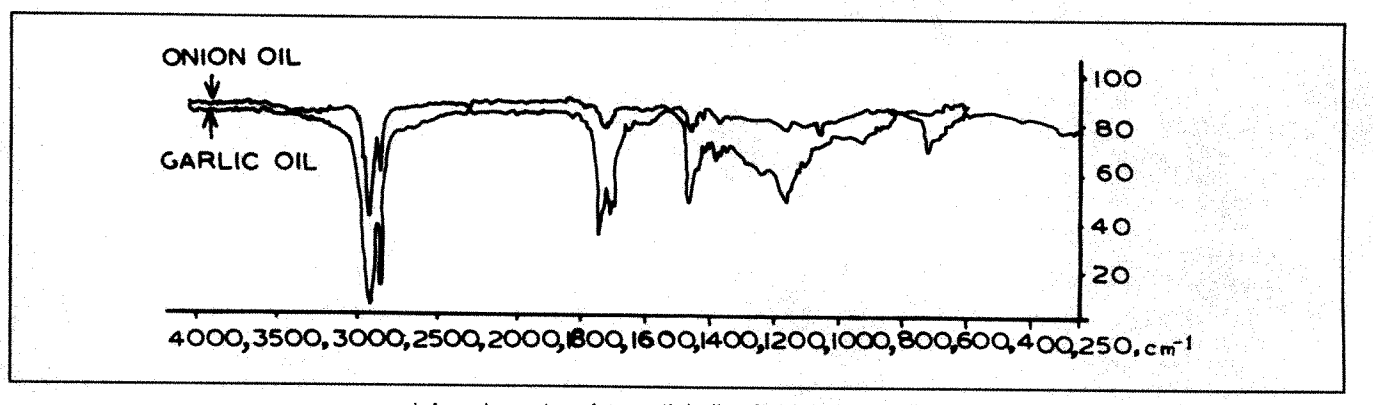

Infrared spectra of essential oils of onion and garlic.

very poor in carbon tetrachloride.

Essential oils of onion and garlic produced almost similar absorption bands; though the peaks produced by the essential oil of onion were much smaller as compared to those produced by garlic. The absorption bands were located at 3,100; 2,900; 1,743; 1,710; 1,468; 1,382; 1,245; 1,170; 922; and 720 cm^{-1} (Figure). The peaks at 3,100 and 1,710 corresponded to the straight chain acids, those at 1,743 and 1,170 to the esters, and those at 2,900, 1,468 and 720 to the methylene groups. The remaining bands were very weak. Allyl groups and sulfur bands were not demonstrable except in one out of two samples of essential oil of onion that showed a sulfur band.

COMMENT

Every year, 15 to 20 new patients with contact dermatitis due to vegetables are seen in our clinic. Many times this dermatological condition is discovered only during a routine examination, for it is often mistaken for knife cuts and ignored till it produces severe symptoms. Different vegetables have been incriminated by different workers[1-7,9]; however, our findings suggest that garlic and onion are the most common offenders. This is partly due to the fact that in north India, these two vegetables are used in almost every vegetarian or nonvegetarian dish, and are thus used every day throughout the year. In addition, the antigens in garlic and onion are also probably more potent sensitizers, because some other vegetables such as potato and tomato that are also frequently used, do not cause hypersensitivity with the same frequency. Nevertheless, in an individual patient, almost any vegetable can be responsible. Moreover, a patient may be sensitive to more than one vegetable. Therefore, it is necessary to test an individual patient with all the vegetables to which he or she is exposed. Otherwise, the contact dermatitis is likely to recur if the patient continues to be exposed to one or the other antigen.

It is difficult to ascertain the most ideal material for doing the patch tests. Freshly extracted juices of the vegetables are the most easily available materials, but some controls also showed positive patch tests. The prepared juices of the vegetables gave almost identical results in the patients, though a few patients were negative with the prepared juices. Among the controls, however more individuals gave positive reactions with the fresh juices than with the prepared juices. This difference could be attributed to the nonspecific irritant effect of the fresh juices, but since some controls were positive even with the diluted juices, it seems likely that some clinically normal individuals are having latent hypersensitivity but do not show clinical manifestations because they are not adequately exposed.

Tests with the diluted preparations of the juices showed that the degree of hypersensitivity in different patients varies; some patients gave a positive patch test with even 10% concentration of the juices, while others showed a negative test to even 50% concentration of the juice. With garlic juice, however, all the patients and the controls were negative when tested with a 50% concentration of the juice, while the juice used as such showed a high incidence of false-positive reactions. It is, therefore, considered necessary to reassess the situation using more purified components of garlic.

Attempts at preservation of the juice by lyophilization for patch tests at a later date proved unsuccessful because many patients showed a negative patch test with the solution when the patch test with the corresponding juice was positive. For routine use, therefore, it may be acceptable to use the juice of the vegetable without any dilution. Such a juice can be preserved for at least six months without any preservative by storing at 6 to 8 C. After the antigens are purified, it may be possible to use more specific materials for patch tests.

The antigens in onion and garlic are soluble in various fat solvents such as ether, acetone, and alcohol in addition to water as also reported by Burks[5] and Bleumink et al[9] and are present in the essential oils too. This information is useful for further purification and improvement of the patch test material. These antigens do not seem to be related to the sulfur-containing constituents, because none was found in the essential oils. Further studies will be necessary to characterize the antigenic substance.

Both these vegetables belong to the family Liliaceae to which tulips also belong. The essential oils extracted from onion and garlic produced similar spectra on infrared spectrophotometry, but other evidence suggests that the antigens in tulips, onion, and garlic responsible for contact dermatitis are probably different. Bleumink et al[9] and Bleumink and Nater[11] failed to observe cross-reactivity between onion, garlic, and tulip, and in our study also, out of 45 patients tested with both garlic and onion, only 25 patients were positive with both the vegetables. Nineteen patients showed a positive patch test with garlic only, and one patient was positive with onion only.

Bhag Chowdhary, PhD, Head, Division of Horticulture, Indian Agricultural Research Institute, New Delhi, supplied the standard samples of onion, tomato, and carrot, and M. L. Maheswari, PhD, Agro-chemical division of the same Institute, undertook infrared spectrophotometric analysis.

References

1. Vickers HR: The carrot as a cause of dermatitis. *Br J Dermatol* 53:52, 1941.
2. Peck SM, Spolyar LW, Masson HS: Dermatitis from carrots. *Arch Dermatol* 49:266, 1944.
3. Edelstein AJ: Dermatitis caused by garlic. *Arch Dermatol* 61:111, 1950.
4. Burgess JF: Occupational dermatitis to onion and garlic. *Can Med Assoc J* 66:275, 1952.
5. Burks JW: Classic aspects of onion and garlic dermatitis in housewives. *Ann Allergy* 12:592-596, 1954.
6. Klauder JV, Kimmich JM: Sensitization dermatitis to carrots. *Arch Dermatol* 74:149-158, 1956.
7. Behl PN, Captain RM, Bedi BMS, et al: *Skin Irritant and Sensitizing Plants Found in India.* New Delhi, Behl Publishers, 1966.
8. Agrup G: Hand eczema and other hand dermatoses in south Sweden. *Acta Derm Venereol* 49(suppl 61):40, 1969.
9. Bleumink E, Doeglas HMG, Klokke AH, et al: Allergic contact dermatitis to garlic. *Br J Dermatol* 87:6-9, 1972.
10. Fisher AA: *Contact Dermatitis*, ed 2. Philadelphia, Lea & Febiger, 1973.
11. Bleumink E, Nater JP: Contact dermatitis to garlic: Cross-reactivity between garlic, onion and tulip. *Arch Dermatol Forsch* 247:117-124, 1973.

Microbial Flora of Atopic Dermatitis

Raza Aly, PhD; Howard I. Maibach, MD; Henry R. Shinefield, MD

• **The microbial flora of dermatitic skin, uninvolved skin, and the anterior nares of subjects with atopic eczema were investigated. The carriage rate of *Staphylococcus aureus* was 79% for the anterior nares, 76% for the uninvolved skin (normal skin), and 93% for lesions. The counts of *S aureus* were 7.5 × 10^4/sq cm in lesions and 7.1 × 10^3/sq cm on adjacent normal skin. *Staphylococcus aureus* was the predominant organism in the lesions and constituted 91% of the total aerobic bacterial flora. The coagulase-negative staphylococci were the second predominant organisms (9%). On normal skin, coagulase-negative staphylococci were the predominant organisms, constituting 63% of the total flora, followed by *S aureus* (30% of the bacterial flora). The micrococci counts were lower in the lesions (1.6 × 10^2/sq cm) and higher on normal skin (9.5 × 10^2/sq cm). Lipophilic diphtheroids were fewer on normal skin (6.7 × 10/sq cm), and there were none in the lesions. Fifty-eight percent of the strains belonged to group 3, and 38% were nontypeable. *Staphylococcus aureus* strains belonging to phage groups 2 and 4 were not detected.**

(*Arch Dermatol* 113:780-782, 1977)

Dermatitic skin provides favorable conditions for bacterial colonization and multiplication. The overgrowth of normal flora and the colonization of certain pathogenic microorganisms not only present a threat to the patient, but also to those who come in contact with him. High prevalence of *Staphylococcus aureus* in eczematous lesions have been reported[1-3]; *S aureus* was the most dominant species in the majority of the lesions.[2]

Previous studies have been concerned with the presence of *S aureus* or its dispersal in the hospital environment.[1,2] Documentation of the cutaneous flora in atopic dermatitis is incomplete, and further research needs to be done. This study was designed to investigate systematically (1) density of total aerobic microflora of inflamed and noninflamed skin, (2) composition of the normal flora of the noninvolved skin and the lesions, (3) comparison of nasal carriage of *S aureus* to that in noninflamed skin and lesions, (4) determination of the antibiotic resistance of *S aureus* strains and their phage pattern, and (5) incidence of major groups of bacteria on normal and dermatitic skin.

SUBJECTS AND METHODS

Thirty-nine patients ranging from 4 to 52 years of age (average, 19 years; median, 16 years) were studied. Patients receiving topical antibiotics or those producing systemic effects were not included. Some of the patients had received intermittent corticosteroid therapy before but not during the investigation. With the exception of two subjects, the lesions were chronic, lichenified, and nonexudative types. The sites for sampling bacteria were the anterior nares, the inflamed skin, and the adjacent noninflamed skin (about 5 to 8 cm away from the inflamed skin).

Sampling Methods

Samples were obtained by the detergent scrub technique.[4] An aluminum cylinder, 6.15 sq cm in area, was held to the skin, and the surface was rubbed with a teflon "policeman" in 1 ml of tyloxapol solution for one minute. Nasal flora were removed by using a calcium alginate swab. Samples (0.1 ml) from ten-fold dilution series were cultured on blood agar plates (5% difibrinated sheep RBC agar), trypticase soy agar with polyoxyethylene sorbitan mono-oleate to enhance the growth of lipophilic diphtheroids, eosin-methylene blue agar for Gram-negative, crystal violet agar for streptococci, and Sabouraud glucose agar for fungi. The culture plates were incubated aerobically at 35 C for 48 hours. The Sabouraud plates were incubated at room temperature. Colonial types were used for picking representative strains of different groups of bacteria. Gram strains were performed on selected colonies. Organisms were classified according to their response to biochemical tests and by their growth and/or morphologic features on selective differential media. *Staphylococcus aureus* strains were sent to the *Staphylococcus* Laboratory, Center for Disease Control for phage typing. The Kirby-Bauer method was used for determining antibiotic sensitivity of *S aureus* strains.

RESULTS

Qualitative Estimation of Microbial Flora

Subjects selected for this investigation were outpatients. The incidence of microorganisms on the anterior nares, normal skin, and lesions is shown in Table 1. The incidence of *S aureus* was high in all test sites: 93% in the lesions, 76% on the normal skin, and 79% in the nose. The occurrence of lipophilic diphtheroids was 2% on uninvolved skin, 20% in the nose, and none in the lesions. The incidence of micrococci was higher on the normal skin (25%) than in the lesions (13%). The carriage of coagulase-negative staphylococci was not substantially

Accepted for publication Oct 6, 1976.

From the Department of Dermatology, University of California, San Francisco.

Reprint requests to Department of Dermatology, University of California, San Francisco, CA 94143 (Dr Aly).

Table 1.—Percent Incidence of Microorganism in 39 Patients With Atopic Eczema

	Anterior Nares, %	Lesions, %	Normal skin, %
Staphylococcus aureus	79	93	76
Coagulase-negative staphylococci	77	79	82
Micrococci	2	13	25
Streptococci	2	0	2
Nonlipophilic diphtheroids	61	15	18
Lipophilic diphtheroids	20	0	2
Bacillus sp	10	15	20
Gram-negative rods	2	5	5
Yeasts	0	0	2

Table 2.—Average Microbial Counts in Patients With Atopic Eczema

Microbe	Anterior Nares	Lesions	Normal Skin
Staphylococcus aureus	6.5×10^3	7.5×10^4	7.1×10^3
Coagulase-negative staphylococci	1.4×10^4	7.1×10^3	1.5×10^4
Micrococci	0.8×10^3	1.6×10^2	9.5×10^2
Streptococci	3.7×10	< 10	0
Nonlipophilic diphtheroids	2.4×10^4	1×10^2	4.4×10^2
Lipophilic diphtheroids	5.4×10^3	0	6.7×10
Bacillus sp	< 10	< 10	< 10
Gram-negative rods	< 10	< 10	< 10
Yeasts	0	0	< 10

different in uninvolved skin and lesions.

Semiquantitative Estimation of Microbial Flora

The mean density (39 subjects) of total aerobic flora was 8.2×10^4/sq cm in lesions and 2.4×10^3/sq cm on normal skin. Lesions had a mean density of 7.5×10^4 *S aureus* per square centimeter, compared with 7.1×10^3/sq cm on normal skin (Table 2). Pure *S aureus* (ie, no other organisms observed) with mean average counts of 2.6×10^5/sq cm was found in the lesions of seven subjects (18%); this ranged from 1.5×10^2 to 9.7×10^5/sq cm. The coagulase-negative staphylococci and micrococci were higher in density on normal skin than on the lesions. Lipophilic diphtheroids were not detected on the dermatitic skin; even on normal skin their density was extremely low (6.7 × 10/sq cm). *Staphylococcus aureus* was the predominant organism in the lesions and constituted 91% of the total aerobic bacterial flora. The coagulase-negative staphylococci were the second predominant organisms (9%). On normal skin, coagulase-negative staphylococci were the predominant organisms, constituting 63% of the total flora, followed by *S aureus* (30% of the total population).

Antibiogram of *S aureus*

The antibiotic resistance of 140 strains of *S aureus* was determined by using the paper disk (Baltimore Biological Laboratories) method and is shown in the following:

Antibiotic	Resistance, %
Penicillin (2 units)	63
Penicillin (10 units)	58
Cephalothin (30 μg)	0
Tetracycline (5 μg)	14
Erythromycin (2 μg)	20
Oxacillin (1 μg)	8
Novobiocin (5 μg)	2
Neomycin (5 μg)	1

Phage Types of *S aureus*

No phage group 2 or phage group 4 strains were detected in patients with atopic dermatitis. Thirty-eight percent of the strains belonged to group 3, and 38% were nontypeable. Thirteen percent of the strains were typeable with 29/52 only (group 1), and 12% were typeable with 94/96, for which no group is allotted. Different phage types were noted in the lesions, the noninflamed skin, and the anterior nares within the same subject.

COMMENT

The nasal carriage of *S aureus* in the normal population has a variable range of 10% to 45%[5,6]; while on the skin, with the exclusion of perineum, the occurrence is less than 10%.[7] In this study, the incidence of *S aureus* in patients with atopic dermatitis was not only higher in lesions (93%) and noninvolved skin (76%), but also on the anterior nares (79%). We have no specific explanation for the higher carriage of *S aureus* on the noninflamed skin and the anterior nares. Whether this is a continual dissemination from inflamed skin (a transient status) or actual colonization (a resident status) is difficult to answer. It has been postulated that this high density of *S aureus* may not only intensify previously existing lesions, but may play an important role in the practice of public health.[2] Patients with atopic dermatitis may present problems in the field of cross-infection, since they carry a large number of potentially pathogenic bacteria on dermatitic skin. Dispersion of *S aureus* from inflamed skin has been noted in hospital wards.[8,9] Wound infection associated with *S aureus* was traced to a resident physician who had atopic dermatitis.[2]

We did not see overt staphylococcal pyoderma or other clinical skin infection due to the overgrowth of *S aureus* in this population. Some patients complained of pruritus; we question if this may have been caused partly by staphylococcal toxins or other metabolites. Antibiotic treatment is sometimes helpful in impetiginized eczema.[10] The reduction in dermatitis may have been partly due to the elimination of *S aureus* by antibiotic treatments.

Huriez et al[11] demonstrated elevated antistreptolysin O titers in 23% of patients with eczema; we did not encounter hemolytic streptococci in our population. Hodes[12] reported the

spread of hemolytic streptococci over an entire ward from an infant with secondarily infected eczema.

Lipophilic diphtheroids are part of the normal cutaneous flora and are present most frequently on the skin. To our surprise, no lipophilic diphtheroids were detected in the lesions. Their incidence on normal skin was also minimal (2%). When the bacterial flora of the toe web was purposefully changed by the exaggerated use of antimicrobial soap, lipophilic diphtheroids were completely eliminated and were replaced with an overgrowth of Gram-negative rods.[13] Hyperkeratosis and maceration of the microbially altered toe webs were noted. It seems that the preponderance of lipophilic diphtheroids is indicative of normal healthy skin. A paucity of lipophilic diphtheroids was also noted on the normal skin adjacent to the lesions. Although nonlipophilics were encountered on normal skin and on the lesions, they constituted less than 1% of the total flora. An inverse relationship between diphtheroids and Gram-positive cocci has been noted for bacteria in the nose.[14]

Not only was the incidence of *S aureus* higher in the lesions of the patients with atopic eczema, but *S aureus* constituted 91% of the normal flora. On normal skin coagulase-negative staphylococci were the predominant organisms. The incidence and density of micrococci were also higher on normal skin than in the lesions. The occurrence of Gram-negative rods and *Candida albicans* was low in these patients. Our finding on the carriage of *S aureus* and their densities on the lesions and on normal skin is similar to those published by Leyden et al.[2]

We have no definite explanation for the high carriage of *S aureus* on the uninvolved skin and on the anterior nares. Whether this is dissemination from inflamed skin or actual inhabitation is an open question. It has been suggested that the uninvolved skin of patients with atopic dermatitis may be inherently favorable for *S aureus* colonization.[2] Clinically, healthy skin areas of patients with eczema are more suitable for the multiplication of *S aureus* than normal skin.[15]

The quantitative and qualitative estimations of normal flora, antibiotic sensitivity pattern, and phage types of *S aureus* have not been reported previously, to our knowledge. The finding that many strains of *S aureus* (38%) colonizing the skin of atopic patients belong to group 3 was unexpected, since most staphylococcal hospital epidemics in the 1950s through 1960s were of the types 52, 52A, 80/81 (group 1). The type 71 strains (group 2) have been associated with impetigo[16] and toxic epidermal necrolysis. No strain belonging to group 2 was detected.

It is perhaps biologically fortunate for these patients that they have been colonized by group 3 or nontypeable strains. Toxic epidermal necrolysis, bullous impetigo, recurrent furunculosis, and Ritter disease are most frequently caused by other than group 3 strains of *S aureus*. Is colonization with group 3 strains related to the patients' lack of contact with phage groups 1 and 2 (ie, a chance phenomena), or is there an ecologic reason for group 3 being favored over groups 1 and 2?

The fact that these patients have a reasonably high frequency of *S aureus* strains that are resistant to penicillin, erythromycin, and tetracycline must be viewed in perspective. At first thought, one might be tempted to suggest that these antibiotics might be contraindicated if frank cutaneous infection developed. Should the infection be serious, common sense would dictate this decision. In routine pyoderma (other than eczematous lesions), there are numerous examples of successful treatment with the antibiotics to which the probable pathogen were resistant.[17,18] It has been stated that this is because pyoderma was due to streptococci rather than *S aureus* seen in the culture.[19,20] At the moment the issue is subjudice; we suspect that there is a far from perfect correlation between antibiogram and clinical response in routine pyoderma.

This investigation was supported by research grant No. AI 1085604 from the National Institutes of Health.

The authors thank Charlene Shirley for her technical assistance and Dr H. Roth for his helpful advice.

References

1. Wilson PE, White PM, Noble WC: Infections in a hospital for patients with diseases of the skin. *J Hyg* 69:125-132, 1971.

2. Leyden JE, Marples RR, Kligman AM: *Staphylococcus aureus* in the lesions of atopic dermatitis. *Br J Dermatol* 90:525-530, 1974.

3. Selwyn S, Chalmer SD: Dispersal of bacteria from skin lesions: A hospital hazard. *Br J Dermatol* 77:349-356, 1965.

4. Williamson P, Kligman AM: A new method for the quantitative investigation of cutaneous bacteria. *J Invest Dermatol* 45:498-503, 1965.

5. William, REO: Healthy carriage of *Staphylococcus aureus*: Its prevalence and importance. *Bacteriol Rev* 27:56-71, 1963.

6. White A, Smith J: Nasal reservoir as the source of extranasal staphylococci. *Antimicrob Agents Chemother* 1963:679-683, 1963.

7. Noble WC: Skin carriage of Micrococcaceae. *J Clin Pathol* 22:249-253, 1969.

8. Davies RR, Noble WC: Dispersal of bacteria on desquamated skin. *Lancet* 2:1295-1297, 1962.

9. Selwyn S: Mechanism and prevention of cross infection in dermatology wards. *J Hyg* 63:59-71, 1965.

10. Wachs G, Maibach H: A cooperative double-blind study of an antibiotic/corticoid combination in impetiginized atopic dermatitis. *Br J Dermatol* 95:323-328, 1976.

11. Huriez C, Desmons F, Balldon J: Etude du taux des antistrepholysines O et dans antistaphylolysines dans le serum des malades atteints de diverses dermatoses. *Ann Dermatol Syphiligr* 85:5-25, 1958.

12. Holtle Jr (ed): Conference on infantile eczema. *J Pediatr* 66:153-223, 1965.

13. Ehrenkranz NJ, Taplin D, Butt P: Antibiotic resistant bacteria on the nose and skin: Colonization of cross-infection. *Antimicrob Agents Chemother* 6:255-264, 1966.

14. Aly R, Maibach HI, Shinefield HR, et al: Effect of a systemic antibiotic on nasal bacterial ecology in man. *Appl Microbiol* 20:240-244, 1970.

15. Muller E: Ecology of *Staphylococcus aureus* on the human skin surface. *Arch Klin Exp Dermatol* 233:376-382, 1969.

16. Parker MT, Williams REO: Further observations on the bacteriology of impetigo and pemphigus neonatorum. *Acta Paediatr* 50:101-112, 1961.

17. Markowitz M, Bruton HD, Kuttner AG, et al: The bacteriologic findings, streptococcal immune response, and renal complication in children with impetigo. *Pediatrics* 35:393-404, 1965.

18. Esterly NB, Markowitz M: The treatment of pyoderma in children. *JAMA* 212:1667-1670, 1970.

19. Dajani AS, Ferrieri P, Wannamaker L: Endemic superficial pyoderma in children. *Arch Dermatol* 108:517-522, 1973.

20. Dillon HC: The treatment of streptococcal skin infections. *J Pediatr* 76:676-684, 1970.

Treatment of Morphea-Type Basal Cell Carcinomas With Radiation Therapy

Robert S. Bart, MD; Alfred W. Kopf, MD; Arthur H. Gladstein, MD

• Eight patients received superficial x-ray therapy for morphea-type basal cell carcinomas. Seven lesions did not recur. One recurrence adjacent to an irradiated field was observed; it was considered to be a geographic miss and has led us to include a wider field (10 mm) of normal-appearing skin beyond the clinical perimeter of the tumor when the lesion is ill-defined. The cosmetic results after treatment were poorer than anticipated for this schedule of radiation therapy, based on our extensive experience with other types of basal cell carcinomas.

To obtain the best long-term results we believe that, where technically feasible, Mohs surgery and conventional surgical excision with histologic verification of free margins are the treatments of choice for morphea-type basal cell carcinomas. However, our experience indicates that morphea-type basal-cell carcinomas can be cured with radiation therapy; therefore, x-rays have a place in the armamentarium of therapeutic modalities for this tumor if surgery is not feasible or if it is refused by the patient.

(*Arch Dermatol* 113:783-786, 1977)

Some textbooks[1,2] and articles[3,4] state that x-ray therapy is ineffective in achieving an adequate cure rate for morphea-type basal cell carcinoma. Furthermore, we have been unable to find a reference to the usefulness of x-radiation in treating a series of morphea-type basal cell carcinomas, although x-ray therapy has been reported as curative[5] and implantation of low-intensity radium needles advocated.[3] It is generally accepted by dermatologists that x-ray therapy is not useful for these tumors, and this very likely accounts for the fact that this treatment was rarely used at the Skin and Cancer Unit, New York University Medical Center. It could be postulated that x-ray therapy might be less effective because the dense stroma, which is characteristic of these lesions, renders the epithelial strands relatively anoxic and thus relatively radioresistant. Because of the fibrotic nature of their stroma (Fig 1), curettage-electrodesiccation is usually considered poor treatment for these lesions. Excisional and Mohs surgery are the modalities generally preferred at the Skin and Cancer Unit.

This report summarizes our experience with x-radiation of morphea-type basal cell carcinoma.

CLINICAL MATERIAL

Of the more than 4,000 histologically verified basal cell carcinomas coded in the Oncology Section of the Skin and Cancer Unit, only eight lesions with typical clinical and histologic features of the morphea type were treated with x-radiation. Sclerosing "field-fire" basal cell carcinomas are excluded from this report. The morphea-type lesions were treated by the "standardized" method of x-ray therapy described in detail elsewhere.[6] In brief, therapy consisted of five doses of 680R delivered during a period of 9 to 14 days for a total air dose of 3,400R. The half-dose depth (ie, the depth of tissue that reduces the dose by 50%) was 12 mm and the half-value layer of the beam was 0.9 mm of aluminum. A port cut in the 0.3- to 0.5-mm thick lead shielding included a 5 mm or greater border of normal-appearing skin.

Two tumors were in men, six were in women. Follow-up ranged from 1 year and 6 months to 13 years and 11 months, with an average of 9 years. Judgments concerning the cosmetic results were made according to the criteria previously published.[6] The Table summarizes the data concerning these eight patients.

REPORT OF CASES

CASE 1.—A 65-year-old white man was seen in 1957 for a lesion that had been present for ten years. It was a 15-mm, hard, smooth, telangiectatic whitish plaque located on his right cheek that was skin-colored with some mottled pigmentation. Histopathologic study showed a morphea-type basal cell carcinoma with fine epitheliomatous strands embedded in a sclerotic stroma. In October 1957 the lesion was treated in a ten-day period with 3,400R of superficial x-radiation, according to the standardized schedule as previously outlined. A brisk radioreaction ensued. Biopsy in December 1958 revealed no basal cell carcinoma. Three years after the x-ray therapy, the cosmetic result was considered only fair because of radiodermatitis. Another biopsy specimen taken 5½ years after the x-ray therapy was again negative for tumor. The patient's last visit was in December 1969. There had been no recurrence of the carcinoma, but the cosmetic result was poor, with atrophy and telangiectasia.

CASE 2.—A 49-year-old white woman was first seen in the Oncology Section in November 1961 for a 21 × 33-mm sclerotic, oval lesion on her left mandibular area (Fig 2). The lesion had a slightly depressed

Accepted for publication Aug 2, 1976.

From the Oncology (Drs Bart and Kopf) and Physiotherapy (Dr Gladstein) Sections of the Skin and Cancer Unit, New York University Medical Center, and the Department of Dermatology, New York University School of Medicine.

Reprints not available.

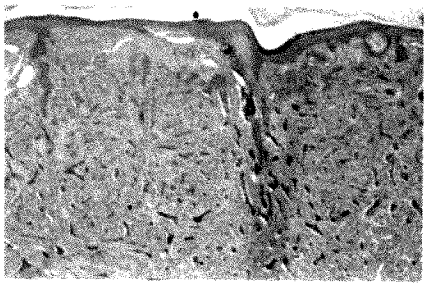

Fig 1.—Morphea-type basal cell carcinoma. Small islands and strands of basaloid carcinomatous cells are in dense, fibrotic stroma (hematoxylin-eosin, ×16).



Fig 2.—Morphea-type basal-cell carcinoma (case 2). Note ill-defined sclerotic plaque overlaid with telangiectatic vessels.

Fig 3.—Brisk radioreaction following 3,400R x-radiation (case 2).

Fig 4.—Nine months following completion of radiation therapy (case 2). Good cosmetic result achieved but irregularly marginated, fibrotic area within irradiated field present.

Fig 5.—Fair cosmetic result after three years (case 2) because of hypopigmentation. Suture line is from biopsy.

Fig 6.—Morphea-type basal cell carcinoma (case 4). Scar-like lesion is eroded and crusted.

Fig 7.—Basal cell carcinoma 11 months later (case 4). Cosmetic result is fair, with depigmentation and telangiectasia.

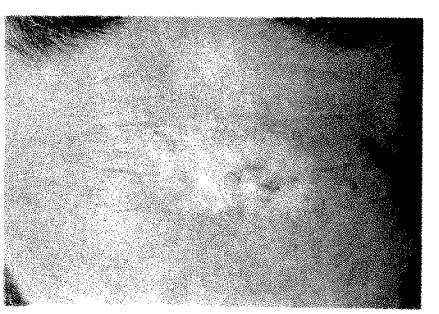

Fig 8.—Cosmetic result is fair to poor after treatment (case 4).

Fig 9.—Morphea-type basal-cell carcinoma (case 5). Tumor was irregularly shaped, hard, and telangiectatic.

Fig 10.—Basal cell carcinoma one month after radiation therapy with 3,400R (case 5). Within radiodermatitis, whitish, sclerotic areas were visible.

Fig 11.—Four months after completion of radiation therapy (case 5), radiodermatitis had subsided, but whitish fibrotic areas remained within treated site.

Fig 12.—Two years after completion of therapy (case 5), cosmetic result was considered poor. White sclerotic plaque remained.

Summary of Morphea-Type Basal Cell Carcinomas Treated With X-rays

Case No.	Sex	Age, yr	Duration	Location	Largest Diameter, mm	Recurrence	Cosmetic Results at Three Years	Follow-up	Cosmetic Results at Last Follow-up
1	M	65	10 yr	Cheek	15	None	Fair	12 yr, 2 mo	Poor
2	F	49	12 mo	Mandibular area	33	None	Fair	13 yr, 8 mo	Fair
3	F	48	14-18 mo	Upper lip	16	At 3 yr	Fair	5 y 9 mo	Fair
4	M	57	3 yr	Forehead	35	None	Fair to poor	13 yr 11 mo	Poor
5	F	74	47 yr	Forehead	35	None	Poor	9 yr	Poor
6	F	69	Unknown	Chin	25	None	Good	11 yr, 6 mo	Good
7	F	72	14-18 mo	Cheek	20	None	Fair	5 yr, 9 mo	Fair
8	F	63	2-4 mo	Forehead	16	None	...	1 yr, 6 mo	Good

center and barely raised borders overlaid by fine telangiectatic vessels. The patient stated the lesion had been present for one year. Results of an incisional biopsy verified the clinical impression of morphea-type basal cell carcinoma. The standardized x-ray treatment was given in a 13-day period between Dec 27, 1961 and Jan 8, 1962. A brisk radioresponse occurred (Fig 3). In September 1962 there was a good cosmetic result with only mild atrophy and no telangiectasia (Fig 4). However, in the center of the irradiated field was a macular, irregularly marginated, fibrotic whitish area that appeared to be scar tissue; this persisted until April 1963 at which time a biopsy was performed. The biopsy specimen did not contain neoplastic cells. There was no recurrence subsequently. The cosmetic result after three years (Fig 5) and again at the time of her last visit (August 1975) was considered fair.

CASE 3.—In 1961 a 48-year-old white woman was seen for a 16-mm, hard, skin-colored, eroded plaque on the left side of her upper lip. This had been present for many months and was adjacent to a site that had been treated elsewhere by curettage and electrodesiccation for a "skin cancer" approximately one year before. The histologic picture of the biopsy specimen was that of morphea-type basal cell carcinoma. In December 1961 the lesion was treated with 3,400R of x-radiation in a 14-day period, using the standardized schedule. A 5-mm margin of normal-appearing skin was included in the irradiated field. In September 1965 a histologically proved basal cell carcinoma was found adjacent to the irradiated field and excised. This was considered to be a peripheral recurrence. The patient remained free of recurrence and was last seen in the Skin and Cancer Unit in September 1967, at which time the cosmetic result was considered fair. She was last seen by her family physician in July 1972, at which time there was no clinical evidence of recurrence.

Comment.—Since the recurrence in this case was thought to be a geographic miss because of the ill-defined nature of the tumor, it was decided thereafter to include in the radiation port a 10-mm margin of normal-appearing skin around morphea-type basal cell carcinomas with ill-defined borders.

CASE 4.—A 57-year-old white man was first seen in the Oncology Section in January 1962 for a lesion of three years' duration on the center of his forehead. It measured 35 mm in its longest diameter and was oval, slightly depressed, skin-colored, telangiectatic, and "scar-like" (Fig 6). There was a 5-mm area of erosion and crusting. Results of a 3-mm punch biopsy confirmed the diagnosis of morphea basal cell carcinoma. From the 12th to the 22nd of January 1962 the patient was treated with 3,400R of x-radiation, employing the standard treatment schedule. Following this the patient developed a brisk erythematous response. In March of 1962 the patient had a sclerotic plaque surrounded by a zone of erythema. In December of 1962 the cosmetic result was considered fair with substantial depigmentation and some telangiectasis (Fig 7). By July 1963 the cosmetic result was considered poor because there was a circular depigmented, atrophic, telangiectatic area. The cosmetic result after three years was considered fair to poor (Fig 8). When the patient was last seen in December of 1975 the cosmetic result was considered poor. There had been no recurrence after 13 years and 11 months of follow-up.

CASE 5.—A 74-year-old white woman was first seen in the Skin and Cancer Unit in 1963 for a lesion on her forehead. She claimed the tumor had been present for 47 years. It measured 35 mm in its greatest diameter and was a hard, telangiectatic, irregularly shaped plaque (Fig 9). Histologic examination substantiated the diagnosis of morphea-type basal cell carcinoma. In March 1963 the lesion was treated with 3,400R in a period of 11 days. Subsequently, there was a severe radioreaction, which was still active one month later (Fig 10). By July 1963 the radiodermatitis had subsided and the cosmetic result was considered good, although a white fibrotic area remained in the center of the treated site (Fig 11). Two years after treatment the cosmetic result was considered poor and the white morpheaform plaque remained (Fig 12). This raised the question of whether the tumor was radioresistant or whether the epithelial component may have been destroyed, leaving behind its dense stroma. A biopsy was done and histologic examination of the specimen showed only dense fibrous tissue. The patient was followed up for nine years and no recurrence was seen.

CASE 6.—A 69-year-old white woman was seen in the Skin and Cancer Unit in September 1963 in follow-up for a basal cell carcinoma of the nose, which had been treated in 1957. A telangiectatic plaque, 25 mm in diameter, was found on the chin. Its duration was unknown. The histopathology of the biopsy showed morphea-type basal cell carcinoma. In November of 1963 the lesion was treated during a nine-day period with 3,400R of superficial x-radiation, using the standardized schedule. The expected acute radioreaction ensued. Some erythema and the sclerotic plaque per-

sisted for several months. In March 1965 a biopsy of the treated area was performed and showed fibrosis but no residual carcinoma. There was no recurrence during the 11½ years of follow-up. The cosmetic result after three years and at last follow-up at 11½ years was considered good.

CASE 7.—A 72-year-old white woman was first seen in the Skin and Cancer Unit in November 1963 concerning a lesion of about 18 months' duration on her left cheek. The tumor was a hard, telangiectatic plaque that measured 20 mm in its largest diameter. Study of a biopsy specimen confirmed the clinical diagnosis of morphea-type basal cell carcinoma. In December 1963, during an 11-day period, it was irradiated with 3,400R, using the standardized schedule. After 2½ years there was no evidence of recurrence and the cosmetic result was described as fair. The patient was followed up for five years and nine months after treatment; no evidence of recurrence of the lesion was noted. In 1969, when last seen, the cosmetic result was described as fair. Shortly after resolution of the radiodermatitis, and again two years later, biopsies of the treated area were performed and no tumor was found histologically.

CASE 8.—A 63-year-old white woman was seen in the Skin and Cancer Unit in April of 1974 because of a 16-mm, smooth, hard, skin-colored, telangiectatic plaque on the left side of her forehead. The tumor was said to have been of three months' duration. The histology was that of morphea-type basal cell carcinoma. It was irradiated with six doses of 680R each for a total dose of 4,080R in a 15-day period. The reason for the six treatments instead of the usual five was that after the initial treatment it was decided to enlarge the part to include an area not exposed in the first treatment. The factors used to treat this lesion were half-value layer of 0.85 mm of aluminum and a 10-mm tissue half-dose depth. When the patient was last seen in September of 1975, there was a good cosmetic result; however, there was alopecia on part of the left eyebrow, which had been in the irradiated field.

COMMENT

This series of eight morphea-type basal cell carcinomas, none larger than 35 mm in greatest diameter, which were treated with x-ray therapy, demonstrates that it is possible to use this modality to treat this type of tumor and achieve cure. The dosage schedule was the one generally used at the Skin and Cancer Unit for more ordinary basal cell carcinomas. This standardized schedule has been successful in achieving a five-year cumulative cure rate of 92% in 500 consecutive histologically proved basal cell carcinomas.[6] The width of normal-appearing skin that was irradiated averaged more than the usual 5 mm because of the frequent difficulty in accurately determining the borders of morphea-type basal cell carcinomas.

No clinical or histologic recurrences within the irradiated fields were found. Follow-up biopsies of irradiated sites were negative for tumor in the five patients so studied. A peripheral recurrence was assumed in case 3. This was thought to represent a geographic miss resulting from irradiating too narrow a margin of presumed uninvolved skin.

Mainly because of atrophy and telangiectasia, the cosmetic results were generally fair three years after treatment and fair or poor at follow-up examinations 5 to 14 years after treatment.

These cosmetic results were not as good as expected on the basis of our previous study of 500 basal cell carcinomas, not specified as to type, treated with x-rays. The reason for this is unclear. It may be related to the very dense stroma that characterizes this type of lesion, the vascular supply to the areas, the locations of these particular lesions, or the fact that this small number of patients might not be representative of a larger group.

There were no other significant complications or sequelae of the treatment other than alopecia.

Several features set apart morphea-type basal cell carcinomas from the more ordinary varieties. The morphea-type tends to be visually unobtrusive, with clinically very ill-defined irregular borders; therefore, it frequently is not diagnosed until it has become large. Because of the indistinct borders, dense stroma, and infiltrating nests and strands of tumor, morphea-type basal cell carcinomas are difficult to treat. The exception is for the Mohs surgeon who can trace out the extensions with microscopically controlled tissue removal.

The role of cryosurgery with liquid nitrogen spray remains unclear. Graham[7] claims that morphea-type basal cell carcinomas respond well to this modality whereas Zacarian[8] states that "sclerosing or morphea-like" lesions do not respond well; we await reports of long-term experience with this treatment.

Although for most morphea-type basal cell carcinomas we favor excision by Mohs surgery, or, if this is not available, conventional surgical excision with histologic verification of free margins, we were pleased to substantiate that cures can also be achieved with x-ray therapy. Thus, for selected patients who refuse or who are not candidates for surgery, this modality can be used to treat such lesions. Because this is a small series and because the cosmetic results were not as good as expected, we do not recommend x-radiation using our standardized schedule as a routine therapy for treating morphea-type basal cell carcinomas. However, it should be kept in mind that we have not reviewed the cure rates and cosmetic results for a series of morphea-type basal cell carcinomas treated by excision or Mohs surgery. Perhaps other schedules employing increased protraction and fractionation of x-radiation will result in a good cure rate and better cosmetic results than we have encountered with our standardized schedule.

This work was supported in part by the Chernow Fund and endowment funds of the Department of Dermatology. The cost of publishing the figures in color was defrayed by Westwood Pharmaceuticals Inc.

References

1. Sutton RL Jr: *Diseases of the Skin*, ed 11. St Louis, CV Mosby, 1956, pp 1243-1244.
2. Sulzberger M, Wolf J, Witten V, et al: *Dermatology: Diagnosis and Treatment*. Chicago, Year Book Medical Publishers, 1961, p 362.
3. Howell JB and Caro MR: Morphea-like epithelioma. *Arch Dermatol* 75:517-524, 1957.
4. Elton RF: Cryosurgery of difficult basal-cell epitheliomas. *Cutis* 16:474-476, 1975.
5. Costello MJ: Morphea-like epithelioma and basal-cell epithelioma of the face cured by roentgen ray therapy. *Arch Dermatol Syphilol* 55:585, 1947.
6. Bart RS, Kopf AW, Petratos MA: X-ray therapy of skin cancer: Evaluation of a "standardized" method for treating basal-cell epitheliomas, in *Proceedings of the Sixth National Cancer Conference*. JB Lippincott, Philadelphia, 1970, pp 559-570.
7. Graham GF: Cryosurgery of skin tumors. *NC Med J* 32:81-87, 1971.
8. Zacarian SA: Cryosurgery of skin cancer in proper perspective. *J Dermatol Surg* 1:33-38, 1975.

Cutaneous Neural Proliferation in Highly Pruritic Lesions of Chronic Prurigo

Uee Runne, Constantin E. Orfanos

• Nodular lesions of chronic prurigo correspond to highly sensitive pruritic areas of neural proliferation. This has been shown by light and electron microscopic studies in four patients. Axons and Schwann cells were participating in this process. Their ultrastructure appeared mostly normal; however, some disorganization, axonal swelling, and dystrophy were also observed. At places, newly formed nervous tissue imitated neuromas, surrounded by mononuclear cells and a peculiar cell type which we called "spider cell." The noninvolved skin near the nodules showed no alterations. Occlusion with elastic bandages for four weeks betters the clinical and histological picture. According to these findings, it seems that the neural proliferation in prurigo is a secondary phenomenon due to chronic traumatization by scratching. We also feel that the extreme pruritus in chronic lesions is related to the increased number of dermal nerves.

(*Arch Dermatol* 113:787-791, 1977)

Chronic pruritic nodular lesions are a clinical entity called prurigo nodularis described by Hyde in 1909.[1] This is a rare condition with severe pruritus and considerable discomfort for the patients. It does not respond to therapy, even to systemic corticosteroids.

The pathogenesis of prurigo nodularis and the extreme pruritus are still completely unknown. In earlier investigations, some information has been given on the morphological substrate of the lesions. By light microscopy, the nodules revealed nonspecific dermal and epidermal changes. However, some authors, particularly Pautrier (1934),[2] Perez and Maruri (1949),[3] Thies (1955),[4] Kantner et al (1963),[5] and Cowan (1964),[6] described an increase of neural tissue in the dermis. Moreover, Cowan (1964) found that numerous nerve fibers were swollen, and Kantner et al (1963) believed that some of them entered the epidermis.

The present investigation was scheduled in order to clarify the presence and the significance of neural proliferation in this highly pruritic condition. In the meantime, Feuerman and Sandbank (1975)[7] published an electron microscopic study; they also reported an increase of dermal nerves in one patient with prurigo nodularis. In this article, we present our data on four cases and will show that in chronic prurigo, a *cutaneous neural proliferation* exists, which seems to be the result of chronic irritation of the nodules.

PATIENTS AND METHODS

All investigated patients had a typical prurigo for 12 years or more. Three of the patients showed classical nodules (Fig 1, top and center), the fourth patient had

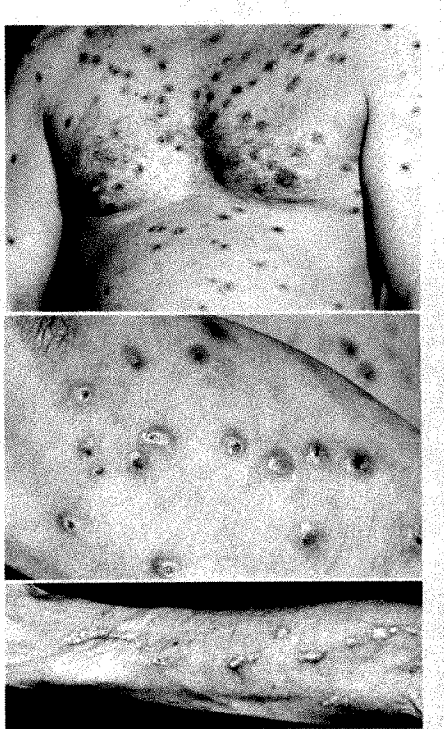

Fig 1.—Top, Multiple, widespread lesions of prurigo nodularis (48-year-old man). Center, Central part of most nodules is scratched and slightly ulcerated. Bottom, Highly pruritic linear skin lesions, persisting for more than 30 years (59-year-old woman).

Accepted for publication Sept 10, 1976.

From the Department of Dermatology, University of Cologne, Cologne, West Germany.

Reprint requests to Department of Dermatology, University of Cologne, 5000 Cologne 41, Joseph-Stelzmann-Str 9, West Germany (Dr Runne).

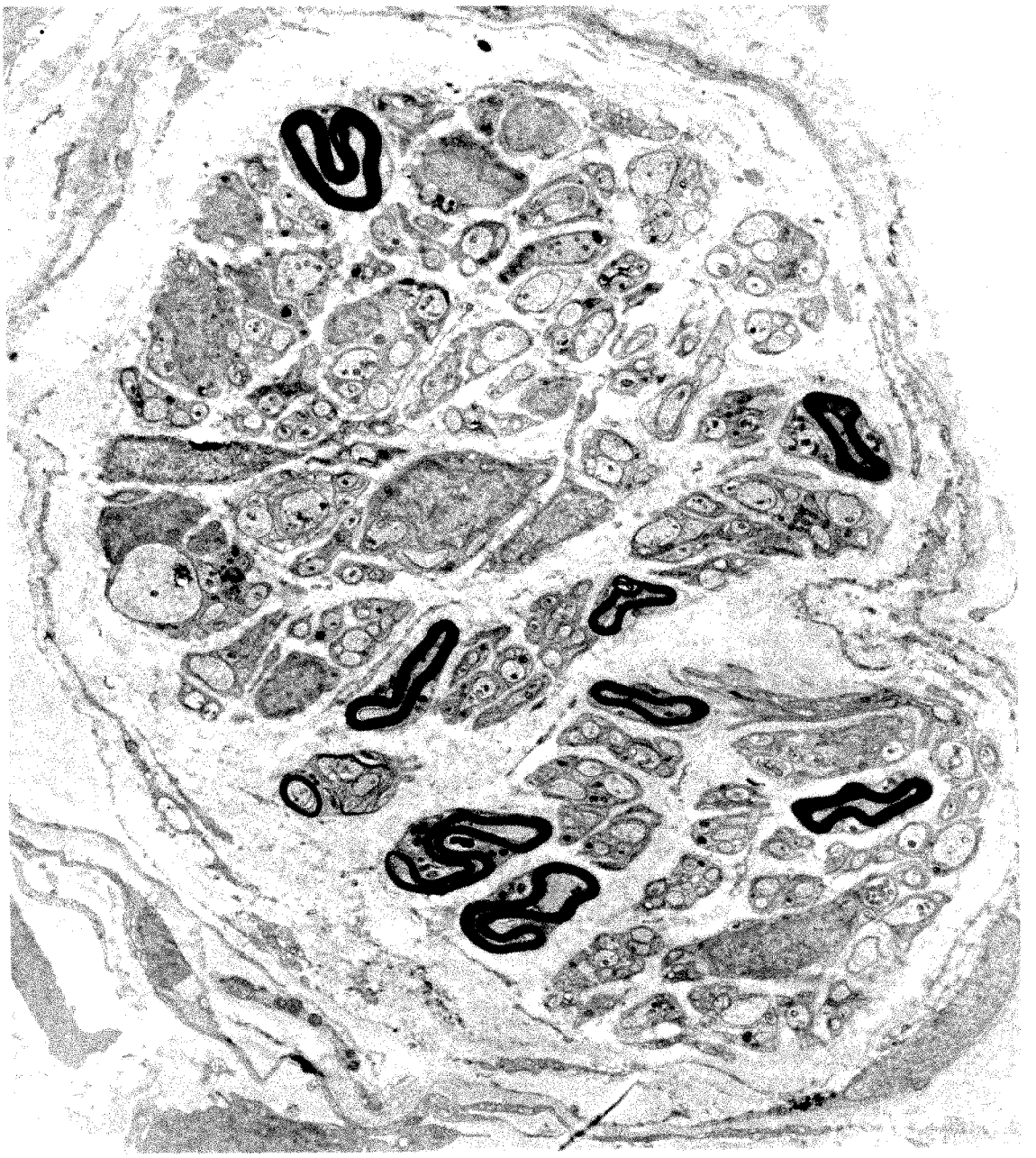

Fig 2.—Thick nerve from middle dermis (ø30 μm). Nerve is well-structured and contains normal myelinated and nonmyelinated axons (original magnification ×5,200).

Fig 3.—Inflammatory cells (IC) surround nerve but do not enter endoneural space (En). Perineural sheath (Pe) and most of axons seem intact. Asterisk indicates axonal dystrophy (original magnification ×6,500).

linear lesions all over the body (Fig 1, bottom). In previous clinical trials, no systemic or topical therapy has been proven effective in any of these patients. Antipruritic drugs, such as phenothiazines in high doses, had been given orally. Two, 4-mm punch biopsy specimens from typical prurigo lesions were taken from each patient under local anesthesia with 1% mepivacaine hydrochloride (Scandicain) (upper arm, forearm, and upper leg). All selected nodules had persisted for more than one year. Additional biopsy specimens were taken from the noninvolved skin near a typical nodule, and from a nodule on a leg that had been covered by elastic bandages for a period of four weeks to avoid scratching. After this period, the nodules in this area were still visible but they were significantly flattened, and the dermal infiltration seemed diminished. Another clinical experiment using intrafocal injections of cytarabine (cytosine arabinoside) (20 mg three times daily within four weeks) was not fully successful.

For conventional microscopic study, the skin specimens were fixed in 5% formaldehyde solution, embedded in paraffin, and stained with hematoxylin-eosin (H-E), Giemsa, PAS, and Palmgren stains. For the electron microscopic study, the specimens were fixed in ice-cold glutaraldehyde-paraformaldehyde solution (2.5:4.0%, buffered in cacodylate buffer, pH 7.2) for 18 hours and in 1% osmic acid solution for 1 hour and were embedded in an epoxy resin. Ultrathin sections were stained with uranyl acetate and lead nitrate.

RESULTS

Using a *light microscope*, we found an hyperproliferative epidermal reaction, partly with pseudocarcinomatous hyperplasia in two patients. Acanthosis, hyperkeratosis, some parakeratosis, elongation and interdigitation of the rete ridges, and some papillomatosis were present. In all dermal layers a patchy cellular infiltrate was seen, composed of lymphocytes, histiocytes, few mast cells, eosinophils, and fibroblasts. In old lesions, numerous collagen fibers were homogenized and seemed swollen; sometimes they were orientated in parallel as in scar tissue. Between the collagen fibers, several neural profiles were recognized, even in H-E stains. Moreover, neuroid structures similar to neurilemmoma were seen in some places surrounded by dense cellular infiltrate. Few dermal vessels showed swelling of their endothelial walls and deposits of eosinophilic fibrinoid material.

After a four-week period of wearing elastic bandages, the cutaneous infiltrate was markedly reduced, and no striking neural elements were seen, neither enlarged nerves nor neurolemmoma-like structures. Some epidermal changes were still present.

Histologic examination of the noninvolved skin near the nodules did not show any evidence of tissue alterations, especially no increase of nervous tissue was seen.

Under the *electron microscope*, it was obvious that cutaneous nerves were markedly increased in all dermal layers. Numerous profiles of normal nerves in all sizes and types were observed, alone or surrounded by cellular infiltrate. Some of them were surprisingly thick and contained myelinated and nonmyelinated axons (Fig 2 and 3). Most of the dermal nerves were well structured; the sheaths of Schwann cells, endoneural, perineural and epineural tissues were all normal. In some specimens, axonal

disorientation was seen; we called such profiles "*axonal seas*" because of their abundance and their peculiar appearance (Fig 4). We also had the impression that Schwann cell nuclei were present more often than usual and draw the conclusion that the peripheral neural proliferation involved axons and Schwann cells. Rarely, degenerative changes of individual axons and of proliferating Schwann cells were observed. At places, some axons and Schwann cells were enlarged and seemed swollen; also some bands of Büngner occurred, which is a rather rare phenomenon in normal human skin. We now examined thoroughly the epidermis, and in contrast to previous light microscopic studies we did not find any evidence for the occurrence of intraepidermal nerves.

The cellular infiltrate was mainly composed of mononuclear cells, which seemed somehow stimulated showing dense nuclear chromatin, abundant cytoplasm, and an increased amount of cytoplasmic organelles (Fig 5, top). Dermal Langerhans cells were found in one case and "wormlike" structures, characteristic of stimulated histiocytes, in another.

In some specimens, we repeatedly found an unusual cell type. This cell occurred in small numbers in the dermal infiltrate, had a small mostly excentric nucleus, and abundant cytoplasm. The cytomembranes were smooth and were organized in an extraordinary manner, similar to a labyrinth of wide, hollow spaces. For this reason, we called this cell type *spider cells* (Fig 5, bottom). They were coated by floccular material, resembling a basal lamina in some places, which distinguished them from plasma cells. There was no evidence of any physical connection between these cells and the neural tissue or the vascular walls.

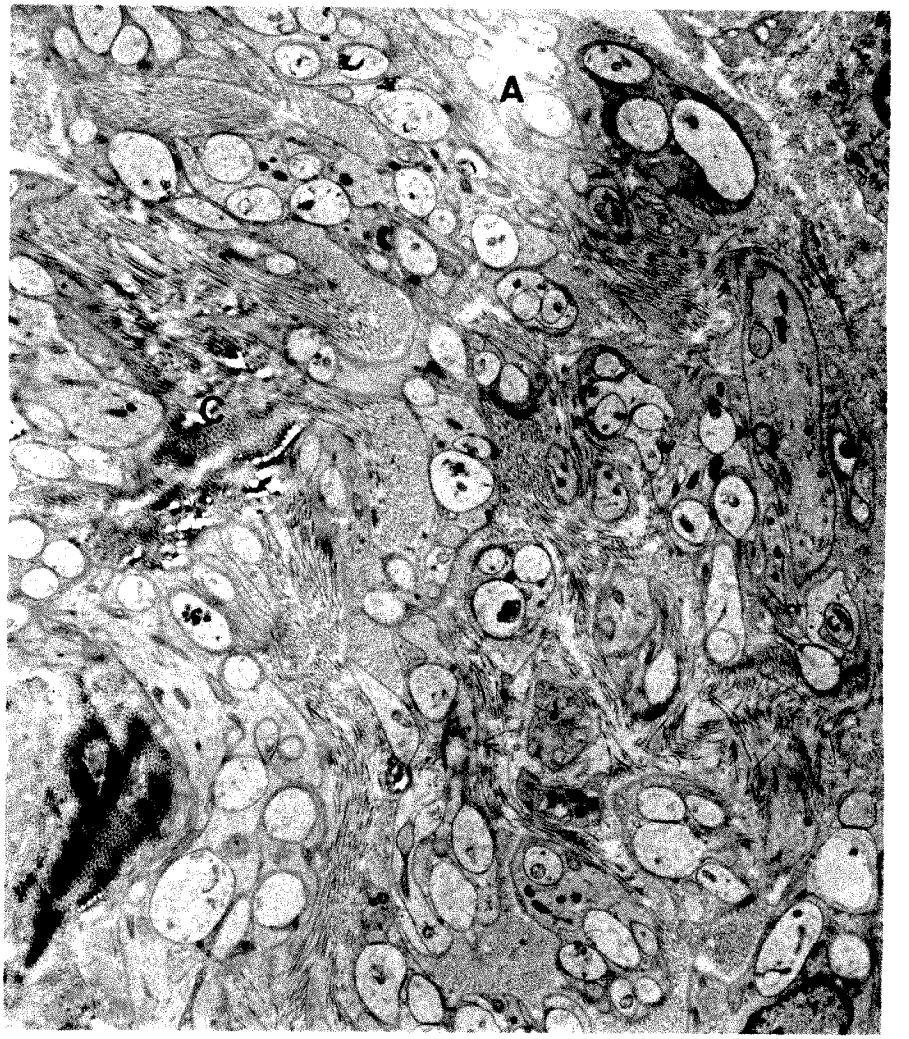

Fig 4.—Some dermal regions are crowded by axons (A) and their Schwann cells, irregularly distributed between collagen fibers (C); a perineural sheath is lacking (original magnification ×5,800).

COMMENT

The data presented in this study revealed that the cutaneous neural proliferation represents the most characteristic tissue change in prurigo nodularis and other types of chronic prurigo, since it has never been described in another comparable skin condition. This neural proliferation of the preterminal fibers is accompanied by hypertrophy of the larger cutaneous nerves. In noninvolved skin near the nodules, there was no increase in the number or size of cutaneous nerves.

Interestingly enough, the neural proliferation involves axons and Schwann cells simultaneously. The neurilemmoma-like formation that was observed light microscopically corresponds closely to fully developed nerve tissue. No true neurilemmoma was found in prurigo during this study, comparable to the ultrastructural data reported by Waggener (1966).[8] The ultrastructural findings suggest that some observed neural elements are newly formed nerve fibers with normal appearance, although some disorganization, axonal swelling, and axonal dystrophy, and bands of Büngner may occur. Thus, our observations confirm those described by Feuerman and Sandbank (1975), but we do not consider these findings to represent significant neural abnormalities. On the contrary, when we take into account the large amount of analgesic, sedative, and antipruritic drugs that all patients had to take, the ultrastructure of the nerves seemed nearly normal. As previously reported, drug abuse may cause marked alterations in cutaneous nerves though limited to a subclinical level (Runne and Orfanos 1975).[9]

In prurigo, the perineural sheaths,

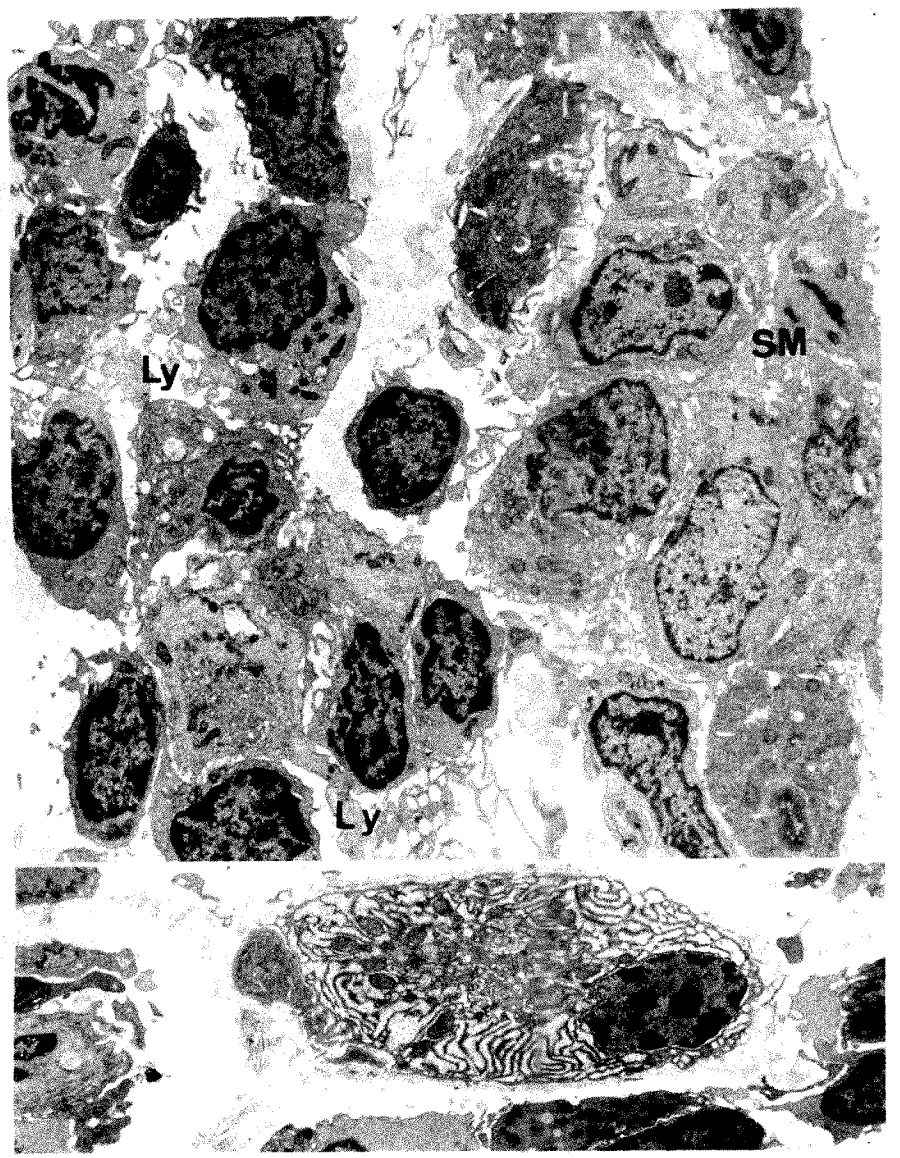

Fig 5.—Top, Dense cellular infiltrate mainly consisting of lymphocytes (Ly) and stimulated mononuclear cells with signs of cytoplasmic activity (SM) (original magnification, ×5,100). Bottom, Unusual cell with a large amount of cytoplasm and extreme organization of its cytomembranes; floccular material surrounds the cell surface resembling basal lamina (original magnification ×5,200).

if present, sufficiently protect the axons, especially against the dense cellular infiltrate. Therefore, the infiltrate does not seem responsible for the slight changes of the cutaneous nerves and their proliferation. On the other hand, no reasonable explanation can be given to the significance and the origin of the peculiar cell type that we called spider cells seen in some specimens. They are obviously highly active and seem to possess a secretory function.

In our view, in chronic prurigo a circulus vitiosus of pruritic lesions, scratching, and neural proliferation exists. It is obvious that scratching can damage preterminal nerve fibers and stimulate them to a reactive regeneration and new formation. Experimental data of O'Daly and Imaeda (1967)[10] and Dyck (1969)[11] suggest that mechanical trauma leads to degeneration and proliferative phenomena in peripheral nerves. Therefore, it seems likely that persistent scratching may cause neural proliferation in human skin and may intensify the pruritic sensations. From this point of view, the nodules of prurigo are highly sensitive "pruritic-islands" of neural origin. The flattening of the lesions and the decrease of cellular infiltrate and nervous elements after protection against scratching and after local pressure using elastic bandages shows that an interruption of this circulus vitiosus betters the clinical and histological findings.

Elisabeth Bodeux provided technical assistance.

References

1. Hyde JN: *A Practical Treatise on Diseases of the Skin for the Use of Students and Practitioners.* Philadelphia, Lea & Febiger, 1909, p 5174.

2. Pautrier LM: Le névrome de la lichénification circonscrite nodulaire chronique. *Ann Dermatol* 5:897-919, 1934.

3. Perez M, Maruri A: Polynévrite cutanée nodulaire chronique, allergique. *Ann Dermatol Syphiligr* 9:623-648, 1949.

4. Thies W: Neurohistologische Studie zur Differentialdiagnose der Prurigo nodularis Hyde und anderer Formen umschriebener Lichenifikation. *Arch Klin Exp Dermatol* 201:539-555, 1955.

5. Kantner M, Kantner G, Zierz P, et al: Zur Morphologie der peripheren Nerven bei juckenden Hautkrankheiten. *Acta Neuroveget* 24:412-437, 1963.

6. Cowan MA: Neurohistological changes in prurigo nodularis. *Arch Dermatol* 89:754-758, 1964.

7. Feuerman EJ, Sandbank M: Prurigo nodularis. *Arch Dermatol* 111:1471-1477, 1975.

8. Waggener JD: Ultrastructure of benign peripheral nerve sheath tumors. *Cancer* 19:699-709, 1966.

9. Runne U, Orfanos CE: Tumor- und Arzneimittel-induzierte cutane Axon-Dystrophie. Elektronenmikroskopischer Nachweis multipler lamellärer Körper. *Arch Dermatol Res* 254:55-66, 1975.

10. O'Daly JA, Imaeda T: Electron microscopic study of Wallerian degeneration in cutaneous nerves caused by mechanical injury. *Lab Invest* 17:744-766, 1967.

11. Dyck PJ: Experimental hypertrophic neuropathy. *Arch Neurol* 21:73-95, 1969.

Necrolytic Migratory Erythema

Distinctive Dermatosis of the Glucagonoma Syndrome

Ronald S. Kahan, MD; Maj Rafael A. Perez-Figaredo, MC, USAF; Lt Col Andris Neimanis, MC, USAF

• Glucagon-secreting tumors of the pancreatic islets (glucagonomas) produce a distinctive syndrome in which weight loss, diabetes mellitus, anemia, and prominent mucocutaneous findings occur. The cutaneous component—necrolytic migratory erythema—may be polymorphous, but most commonly manifests as erosions and crusts of the groin, perineum, buttocks, distal part of the extremities, and central area of the face. Alternatively, scaly papules and plaques may predominate in these areas. The eruption may resemble such dermatoses as pemphigus foliaceus, acrodermatitis enteropathica, chronic mucocutaneous candidiasis, psoriasis, and severe seborrheic dermatitis.

Two patients with chronic, previously undiagnosed dermatoses had necrolytic migratory erythemia, which led to the discovery of glucagonomas present in each. In one patient surgical resection of the tumor resulted in total clearing of the rash within 48 hours. Awareness of this distinctive entity may lead to early diagnosis and, possibly, cure.

(*Arch Dermatol* 113:792-797, 1977)

Changes in the skin can provide clues to the presence of internal malignant neoplasms. When cutaneous signs or symptoms antedate other manifestations of a malignancy, awareness of the relationship between dermatosis and neoplasm may lead to earlier diagnosis and possible cure. Such entities as acanthosis nigricans, dermatomyositis, acquired ichthyosis, and erythema gyratum repens have been associated with a variety of tumors. Rarely does a particular cutaneous disorder point directly to a particular type of internal malignancy.[1]

Accepted for publication Sept 24, 1976.

From the Department of Dermatology, Massachusetts General Hospital and Harvard Medical School, Boston.

Reprints not available.

A distinctive eruption termed necrolytic migratory erythema has recently been described in association with glucagon-secreting islet-cell tumors of the pancreas (glucagonomas).[2-5] This dermatosis has a characteristic gross morphology and histopathology that appear to be diagnostic of this neoplasm. This report describes two patients in whom the presence of necrolytic migratory erythema led to the discovery of glucagonomas. These cases are presented to acquaint physicians with the cutaneous manifestations of this disease.

REPORT OF CASES

CASE 1.—A 40-year-old male school teacher was first admitted to the Massachusetts General Hospital on Nov 1, 1974, because of an extensive rash. Eighteen months prior to admission progressive weight loss began, and nine months before admission the patient first noted a scaling eruption involving the groin, buttocks, and web spaces of his feet. The dermatitis did not improve with use of tolnaftate, griseofulvin, and antibiotics. In August 1974 he was briefly hospitalized because his dermatitis had become erosive. Astringent compresses and topical corticosteroid therapy were not helpful and he was discharged. During the three months before admission the rash fluctuated in severity, but generally worsened. Because of increasing weakness the patient could no longer work. His weight loss now totaled 25 kg. There was no history of anorexia, diarrhea, jaundice, abdominal pain, fever, polydipsia, polyuria, drug ingestion, or previous skin disease. His family history was noncontributory.

On physical examination the patient appeared pale, thin, and chronically ill. His vital signs were normal; weight was 47 kg. An eruption consisting of multiple brown and red-brown crusts, a few intact pustules, and focal erosions, all on a background of mottled erythema, was localized to the central one third of the face (Color Fig 1). In addition, there were extensive erythematous erosions with peripheral scale involving the groin, perianal area, and genitalia (Color Fig 2). Similar but smaller and more discrete lesions were focally scattered on the medial part of the thighs and legs near the ankles. Many of the erosions exhibited arciform or circinate patterns. The feet were involved with tender erosions of the interdigital spaces and dry exfoliation of the soles. Occasional intact, flaccid bullae could be identified, especially on the thighs (Color Fig 3). These evolved rapidly into the erythematous erosions. Prominent macular hyperpigmentation surrounded or abutted the erosive areas, and it became clear that the hyperpigmentation resulted from the healing of active lesions. Scalp hair was sparse; nails were thin and friable, with longitudinal ridging. The tongue was large and beefy but not tender. The liver was palpable 6 cm below the right costal margin; neither splenomegaly nor abdominal masses were present.

Laboratory test results included the following: an hematocrit level of 28.5%, an erythrocyte sedimentation rate of 90 mm/hr, and a urinalysis trace positive for glucose. Gram stains of crusted areas showed a few Gram-positive cocci; potassium hydroxide preparations of crusted areas and pustules disclosed no hyphae; fungal cultures were negative. Determinations for alkaline phosphatase, SGOT, lactic dehydrogenase (LDH), prothrombin time, iron and iron-binding capacity, thyroxine, BUN, creatinine, stool fat, VDRL, antinuclear antibody, lupus erythematosus (LE) preparation, and complement studies as well as chest and gastrointestinal roentgenograms were normal. The initial glucose tolerance test showed the following values: fasting blood glucose, 117 mg/100 ml; one hour, 258 mg; two hours, 247 mg; and three hours, 239 mg. Skin tests for delayed hypersensitivity were positive with mumps and candida antigens, and were negative with intermediate strength purified protein derivative (PPD) and streptokinase-streptodornase.

Multiple skin biopsy specimens showed subcorneal and midepidermal clefts containing neutrophils, lymphocytes, nuclear debris, and a few cocci (Fig 1). The clefting occurred in the midst of psoriasiform hyperplasia with occasional spongiform

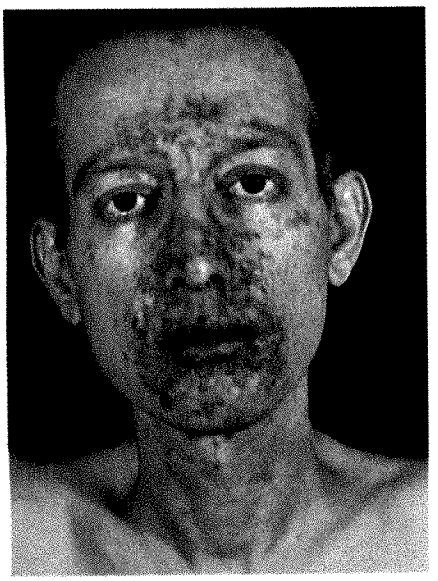

Color Fig 1.—Reticulated erythema with pustules and crusts on central part of face (patient 1).

Color Fig 2.—Extensive perineal erosions with peripheral scale and some hyperpigmentation (patient 1).

Color Fig 3.—Flaccid bullae (patient 1).

Color Fig 4.—Extensive erythema with peripheral fine scale on lower legs (patient 2).

Color Fig 5.—Guttate scaly erythematous papules and plaques involving groin and thigh, giving psoriasiform appearance (patient 2).

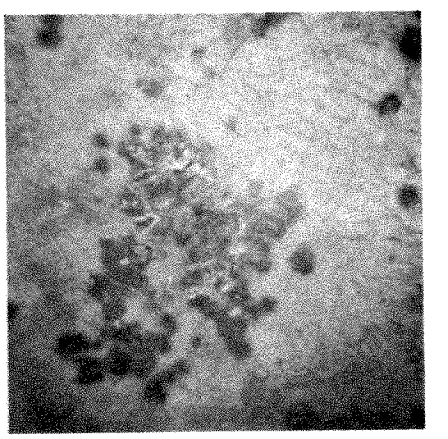

Color Fig 6.—Individual psoriasiform lesion exhibiting serpiginous borders (patient 2).

pustule formation. Of note was the presence of keratinocytes with fusiform shapes similar to those of parakeratotic cells, but lying free in the blister cavities. These cells had dot-like nuclei in the middle of strand-like, eosinophilic cytoplasm. In the dermis there was a loosely aggregated perivenular infiltrate of lymphocytes with some eosinophils and neutrophils. Direct immunofluorescent studies of involved and normal skin were negative for IgG, IgM, IgA, and complement.

A liver scan showed multiple filling defects consistent with a metastatic tumor. Results of a liver biopsy disclosed islands of small tumor cells with minimal mitotic activity. Special stains and immunochemical studies established the neoplasm as a glucagon-secreting alpha-cell tumor of the islets of Langerhans. A celiac angiogram confirmed the hepatic findings and showed a neoplasm in the body of the pancreas. A plasma glucagon level determined by radioimmunoassay and measured as total plasma glucagon immunoreactivity, using antiserum 30K,[7] was 2,200 pg/ml (normal, 106 ± 57 pg/ml). Plasma amino acid studies showed almost all amino acid levels to be below normal.

In view of the hepatic metastases and the patient's physical state, chemotherapy was instituted. He was treated first with streptozocin, later with vincristine sulfate, cyclophosphamide, and prednisone, and subsequently with additional streptozocin courses. During the 15 months of chemotherapy, the cutaneous findings improved, while his general physical state and laboratory measurements (including plasma glucagon) remained essentially unchanged.

Case 2.—A 39-year-old businessman was admitted to the Massachusetts General Hospital on Dec 10, 1974, because of a generalized skin eruption and two days of fever, chills, and tender erythema of the left side of the face. His health had been good until 4½ years prior to admission when he developed a scaling, red, nonpruritic scrotal rash, which during several weeks spread to involve the entire body. He also noticed intermittent scaling around the mouth and episodic "shedding of the lining of the mouth." He experienced burning and pain in areas of friction, and thus had been unable to wear shoes for

most of the 4½ years. His condition had been evaluated at several university centers and dermatologic society meetings. Past diagnoses included candidiasis, dermatophytosis, eczematous dermatitis, chronic erythema multiforme, pustular psoriasis, and generalized seborrheic dermatitis with exfoliation. Previous therapy included tar, ultraviolet light, topical corticosteroids, with and without occlusion, topical fungicides, griseofulvin, hydroxyurea, methotrexate, antibiotics, and systemic corticosteroids.

One year before admission the diagnosis of "erythema annulare centrifugum-like psoriasis" was made at another hospital. Subsequently, treatment with intramuscularly given triamcinolone, in high doses, partially controlled the eruption. Two days before admission he developed a redness and tenderness in his left ear and scalp with accompanying fever and chills. A review of systems disclosed an 11-kg weight loss; chemical diabetes and bilateral cataracts had been diagnosed nine months earlier.

Physical examination showed a thin, chronically ill-appearing man in moderate distress. His rectal temperature was 38.1 C. He had a mild "buffalo hump," and there was decreased muscle mass of his upper arms. The right inguinal and left cervical lymph nodes were enlarged and tender. The spleen and liver were not palpable.

A bright erythema with scaling involved much of the legs and feet. Several shallow, round erosions, from 1 to 5 cm in size, numerous large crusts, and scattered pustules were also present in these areas (Color Fig 4). The thighs, groin, trunk, and arms had areas of diffuse erythema with desquamation, as well as multiple guttate, scaly red papules, and tan-gray macules with peripheral scale (Color Fig 5 and 6). The scalp was moderately scaly; the hair and nails were normal. The buccal mucosa was clear but there was bilateral angular cheilitis. There was dusky erythema, induration, and pain on palpation involving the left ear, cheek, and frontotemporal scalp. The borders were discrete and slightly elevated.

Laboratory studies included an admission WBC of 14,200 cu mm with a normal differential and an erythrocyte sedimentation rate of 66 mm/hr. The following studies were normal: hematocrit, electrolytes, BUN, blood glucose, bilirubin, SGOT, LDH, alkaline phosphatase, amylase, prothrombin time, VDRL, antistreptolysin O titer, and chest roentgenogram. Blood cultures were negative, but skin cultures grew group A β-hemolytic streptococci. The urinalysis disclosed a glucose reaction of 2+ with moderate ketone. Fractional

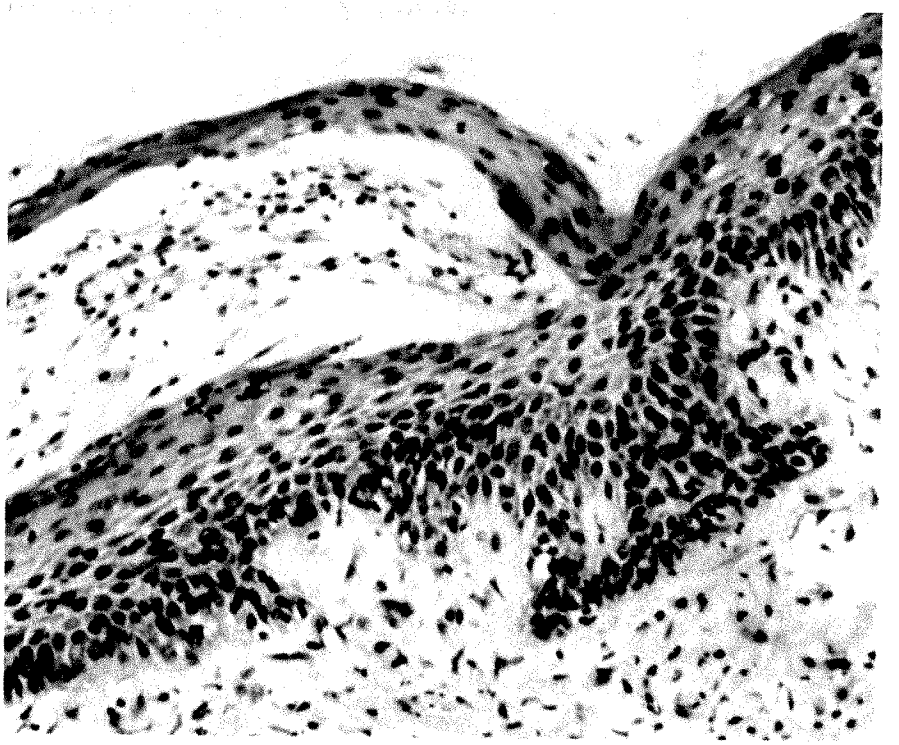

Fig 1.—Intraepidermal cleft, containing lymphocytes, neutrophils, and fusiform keratinocytes, some of which are dyskeratotic (patient 1) (hematoxylin-eosin, original magnifications ×300).

Fig 2.—Focal parakeratotic scale and stratum corneum form roof of blister containing tongue of dyskeratotic and fusiform cells. Underlying epidermis is hyperplastic, spongiotic, and infiltrated by neutrophils (patient 2) (hematoxylin-eosin, original magnification ×300).

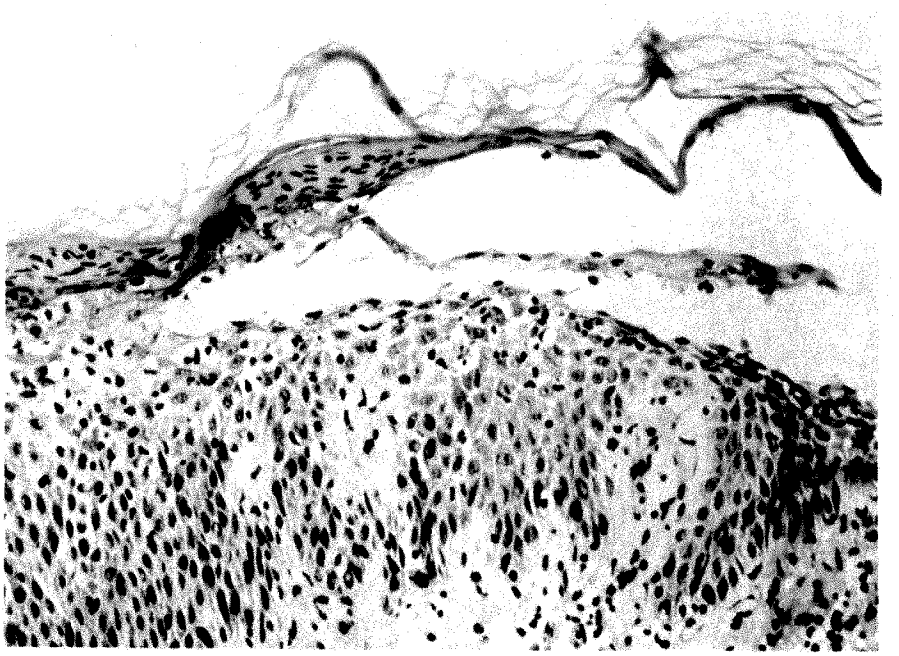

urine reactions for glucose varied from 1+ to 4+. The fasting cortisol level was 0.7 μg/100 ml.

Skin biopsies exhibited psoriasiform hyperplasia with focal spongiosis and occasional clefts in the upper epidermis. Elongate cells similar to those seen in case 1 were noted, though less prominently so. These fusiform cells were aggregated, showed dot-like to elongated nuclei, and exhibited cytoplasmic staining varying from red to blue (Fig 2).

The admission diagnoses were erysipelas of the face and glucagonoma syndrome. Bilateral cataracts, proximal myopathy, and probably osteoporosis were thought to be secondary to long-term corticosteroid use. The patient was started on a regimen of intravenously given oxacillin and replacement corticosteroids; the erosive lesions of the extremities and groin were treated with Burow compresses. On the third hospital day he was afebrile and the facial inflammation had subsided. After six days his skin was generally clear except for his feet, groin, and buttocks. Scrapings from these areas disclosed hyphae, for which tolnaftate cream was given.

The patient's skin was virtually normal 13 days after admission and he was granted a leave of absence for Christmas, during which time he was to take prednisone, 25 mg, every other day. On readmission eight days later, the eruption had flared badly. The groin, legs, and feet were uniformly deep red-purple and oozed clear fluid. On the abdomen and thighs the lesions consisted of centrally depressed, erythematous, annular macules with paler elevated borders, resembling "target" lesions. Shallow erosions were noted around the beltline and on the dorsa of the feet. Subsequently, the eruption progressed to involve the scalp and face with erythema and scales resembling seborrheic dermatitis. The remaining lesions became more scaly, developed crusts around the periphery, and showed central clearing.

The result of the initial plasma glucagon level was 700 pg/ml (normal, 106 ± 57 pg/ml). An angiogram of the pancreas showed tumor vascularity of the body and tail, consistent with primary endocrine pancreatic neoplasm. Liver and bone scans were normal. As a result, the tumor was totally resected along with the distal part of the pancreas and the spleen. There was no evidence of metastases at the time of surgery. Histologically, the tumor was a pancreatic islet-cell carcinoma, and special stains showed it to contain glucagon. A random liver biopsy specimen obtained at surgery disclosed no tumor.

Twenty-four hours after surgery, there was a substantial decrease in erythema, the lesions appeared dry, and the face was almost normal; 48 hours after surgery, the skin was virtually clear. Superficial scaling could easily be brushed off, leaving normal-appearing skin. The patient was discharged on the eighth postoperative day; his plasma glucagon level was normal. For 12 months he remained free of skin lesions or evidence of tumor recurrence. On Jan 27, 1976, however, he was readmitted because of hematemesis and back pain. A massive hemorrhage necessitated a hemigastrectomy and repair of a perforated duodenal ulcer. At operation the liver was seen to be studded with tumor nodules, which histologically were identical to the initial pancreatic tumor. The plasma glucagon level was now 150 pg/ml (normal, 106 ± 57 pg/ml).

COMMENT

The earliest report of a case of this type was by Becker et al,[1] who in 1942 described a 45-year-old woman with a migratory erosive dermatosis. She had lost 7.7 kg of weight, had perlèche, smooth tongue, and normochromic anemia. Results of a glucose tolerance test were abnormal, and an islet-cell tumor was found at autopsy. Although glucagon-secreting tumors were not appreciated at that time, the authors' detailed clinical account makes it clear that their patient had a glucagonoma. McGavran et al,[6] in 1966, studied a clinically similar patient. An electron microscopy of the tumor cells disclosed granules characteristic of alpha-cells, and a radioimmunoassay for glucagon showed the resected tumor to contain large amounts of the hormone.

The term necrolytic migratory erythema was coined in 1973 by Wilkinson[2] to describe the appearance and five-year course of a 52-year-old woman with cyclic episodes of annular and gyrate erythema of the legs. This term incorporated the clinical and histologic features of both the figurate erythemas and toxic epidermal necrolysis, which Wilkinson felt were the predominant characteristics of this eruption. In 1975 Mallinson et al[3] collected nine cases from Great Britain (some briefly reported previously[2,7-9]). Their series established the glucagonoma syndrome as a distinct entity consisting of necrolytic migratory erythema, weight loss, anemia, and diabetes mellitus, in association with a pancreatic alpha-cell tumor and elevated plasma glucagon level.

Both of our patients had chronic cutaneous eruptions associated with weight loss and diabetes mellitus; both were ultimately shown to have glucagon-secreting alpha-cell tumors. In patient 2, surgical resection of the primary tumor resulted in a prompt resolution of all cutaneous findings. Patient 1 had metastatic involvement that rendered his tumor inoperable; he continued to have elevated glucagon levels and new skin lesions. These two patients illustrate both the extent and the variability of the glucagonoma syndrome.

Including our patients, a total of 15 well-documented cases have been reported.[2,3,5-11] The composite features of this syndrome, gleaned from these cases, are listed below.

- Systemic
  - *Weight loss, often profound
  - Weakness
- Mucocutaneous
  - Lesions
    - *Scaly erythematous macules and papules, often annular or arciform
    - Flaccid bullae
    - *Erosions with crusting
    - Hyperpigmentation on healing
    - *Glossitis, stomatitis, angular cheilitis
    - Thin, friable nail plates
  - Distribution
    - *Central one third of face
    - *Lower abdomen, groin, buttocks, thighs, perineum
    - Distal part of extremities
  - Course
    - Spontaneous exacerbations and remissions
    - Variable response to any therapy
  - Histopathology
    - Irregular acanthosis with spongiosis
    - *Subcorneal and midepidermal clefts
    - *Fusiform keratinocytes with pyknotic nuclei
    - Absence of acantholysis
    - Negative immunofluorescent findings
- Hematologic
  - Normochromic, normocytic anemia
  - Elevated erythrocyte sedimentation rate
- Gastrointestinal
- Diarrhea
- Endocrine
  - *Diabetes mellitus
  - *Elevated plasma glucagon level
  - *Alpha-cell tumor of pancreatic islets, with or without metastases
  - Hypoaminoacidemia

The major diagnostic criteria are marked with asterisks. The mean age of onset for the 15 patients was 50.5 years, with a range from 34 to 65 years. Eleven of them have been women.

The cutaneous component, necrolytic migratory erythema, appears most often as erythematous erosions and crusts involving the buttocks, groin, perineum, thighs, and distal part of the extremities. Individual lesions begin as small, often irregular macules that enlarge, blister, and ultimately break down to superficially eroded, sometimes oozing areas. These erosive lesions may assume linear, annular, or serpiginous configurations, either by extension of a single area or by confluence of several. Extensive denudation may result. At a given time, different lesions may be in varying stages of development, or lesions may progress in synchronous waves. Size and shape changes occur continually. Drier lesions may show a collarette of scale, or an entire erythematous plaque may be surmounted by scale, giving a psoriasiform appearance. Erosions, though healing without scarring, produce prominent postinflammatory hyperpigmentation.

Perioral and paranasal crusting, often with extension onto the central forehead and cheeks, is almost invariably present at some time. Thinning of nails with distal friability, a decrease in hair density, atrophic glossitis, stomatitis, and angular cheilitis are frequently associated findings.

Typically, the skin changes wax and wane, responding poorly to therapy of any type, yet regressing without apparent cause. Transient favorable responses to antibiotics, antifungal agents, diiodohydroxyquin, and systemic corticosteroids have been noted, but results have been inconsistent.

Substantial weight loss, often totalling 10 to 25 kg, has been present in every case. Anorexia and malaise are infrequent, but patients do complain of weakness. A normocytic anemia is characteristic, though our second patient was free of anemia for 4½ years. Bone marrow studies are nondiagnostic; iron stores are normal, as are serum iron levels. The erythrocyte sedimentation rate is always elevated, often to high levels. The main gastrointestinal symptom is diarrhea.

Derangements in glucose metabolism are prominent. Patients exhibit intermittent glycosuria, although ketonuria is uncommon. An abnormal glucose tolerance test result is generally demonstrated. Plasma glucagon levels are elevated, often substantially so. Our patients had initial glucagon levels of 2,200 pg/ml and 700 pg/ml (normal, 106 ± 57 pg/ml), and values cited for other cases have been similar. Although systemic corticosteroid therapy may produce increased plasma glucagon levels in normal patients, these increments have been of the order of twofold elevations over control levels.[12,13] This may serve as a useful differential point in a patient whose clinical picture has been clouded by previous corticosteroid use (as in case 2). Plasma amino acid values are significantly reduced. Determinations of the plasma "amino acid pattern" may be helpful in establishing the diagnosis.

The characteristic histologic feature of this disorder appears to involve a separation of cells in varying stages of keratinization in a subcorneal or midepidermal location. These cells, generally fusiform, exhibit pyknotic nuclei and cytoplasm varying from bright pink to blue in sections stained with hematoxylin and eosin. This change occurs in association with psoriasiform hyperplasia and spongiosis. Similar findings have been noted by Wilkinson[2]; he described the keratinocyte alteration as necrolytic. Sampling appears important, as the characteristic clefts may be only focally present. Acantholysis is notably absent. The dermis contains a loosely aggregated, perivenular inflammatory infiltrate. Direct immunofluorescent studies have been negative.

Diseases to be considered in the differential diagnosis of necrolytic migratory erythema are listed below.

Pemphigus foliaceus
Chronic mucocutaneous candidiasis
Seborrheic dermatitis
Psoriasis vulgaris
Pustular psoriasis
Subcorneal pustular dermatosis (Sneddon-Wilkinson disease)
Chronic benign familial pemphigus (Hailey and Hailey disease)
Acrodermatitis enteropathica
Erythema annulare centrifugum
Chronic erythema multiforme
Toxic epidermal necrolysis

The entity most suggested by the gross morphology is pemphigus foliaceus, which may exhibit small flaccid blisters, crusting, spreading erosions, and scaly erythema of the central part of the face. Its histology, however, with acantholysis and positive direct immunofluorescence, should identify it. Chronic benign familial pemphigus (Hailey and Hailey disease) is suggested by chronic intertriginious erosions and crusts. A positive family history and extensive acantholysis on biopsy ("dilapidated brick wall") help to distinguish it from necrolytic migratory erythema.

Acrodermatitis enteropathica must also be considered here, as patients with this disease exhibit periorificial and acral crusting. However, this condition begins early in infancy; the youngest age at which a glucagonoma became clinically significant was 34 years (our patient 2). Serum zinc levels in acrodermatitis are substantially low and appear to be normal in necrolytic migratory erythema; both our patients had normal zinc levels. Chronic mucocutaneous candidiasis may show a similar clinical picture, though *Candida albicans* can usually be identified in large numbers. Patients with necrolytic migratory erythema have not shown deficiencies in cell-mediated immunity.

The subsiding, scaling phase of subcorneal pustular dermatosis (Sneddon-Wilkinson disease) should also be considered, because older lesions in this disease often have irregularly shaped contours, exhibit crusting or scaling, and prefer intertriginious areas. Hyperpigmentation on healing, which may be the only finding during a quiescent phase, is characteristic of both diseases. However, the prominent pustules that initiate Sneddon-Wilkinson disease are not seen in necrolytic migratory erythema. Histologically, the subcorneal pustule of Sneddon-Wilkinson disease must be distinguished from the cleft seen in

necrolytic migratory erythema, which may contain polymorphonuclear leukocytes because of impetiginization; the fusiform keratinocytes of necrolytic migratory erythema may prove helpful to differentiate the two conditions. The annular or serpiginous character of necrolytic migratory erythema may at times resemble erythema annulare centrifugum. The nonexudative, raised, and well-made border of this condition should aid in differentiation. Chronic erythema multiforme with target lesions and bullae may mimic necrolytic migratory erythema. In the latter, however, there is little plantar or palmar involvement, mucous membrane changes are not severe, and hemorrhagic lesions are uncommon.

Psoriasis vulgaris, pustular psoriasis, and seborrheic dermatitis may be considered in cases where a bullous component is minor and scaly erythema predominates. Here, lack of response to conventional therapy and atypical morphology should alert the clinician. Histology may not be helpful, as a biopsy section of necrolytic migratory erythema often shows only nonspecific psoriasiform hyperplasia. Multiple biopsy specimens and careful selection of active borders for sampling are required.

The role of glucagon in producing the characteristic changes observed clinically and histologically is unknown. Glucagon is a polypeptide hormone that acts to elevate the blood glucose level by promoting glycogenolysis and gluconeogenesis in the liver. Little is known regarding its effects on the skin under normal or pathologic conditions. Mallinson et al[14] found that high plasma glucagon levels were associated with low plasma amino acid levels in their glucagonoma patients, and postulated that amino acid metabolism plays an "intermediary" role in producing the syndrome. Tasman-Jones and Kay[15] noted skin findings similar to necrolytic migratory erythema in patients with zinc deficiency from parenteral alimentation; however, the rash resolved promptly with zinc supplementation. This observation seems relevent to acrodermatitis enteropathica; zinc abnormalities have not been observed in glucagonoma patients. At present, the mechanism producing migratory necrolytic erythema remains speculative.

Patients with the glucagonoma syndrome are likely to consult initially with a dermatologist, as the rash is often the first symptom prompting medical attention. The clinical and histologic features of this condition are sufficiently distinctive that, when their presence is noted, a glucagon-secreting tumor must be ruled out. Plasma glucagon determinations may not be readily available; however, the presence of reduced plasma amino acid levels may be suggestive. Because early diagnosis might result in excision and cure of a malignancy, it is recommended that selective celiac angiography be performed when clinical, laboratory, and histologic findings suggest the presence of an islet-cell tumor.

A grant from Stiefel Laboratories, Inc, supported reproduction of the color photographs.

Case 1 is reproduced with permission from the *New England Journal of Medicine* (292:1117-1123, 1975).

Thomas B. Fitzpatrick, MD, provided assistance and admitted one of the patients; Maurice Tolman, MD, referred one patient; and Martin C. Mihm, Jr, MD, interpreted the histologic sections for this report.

Nonproprietary Names and Trademarks of Drugs

Hydroxyurea—*Hydrea.*
Tolnaftate—*Tinactin.*
Triamcinolone—*Kenacort, Aristocort Tablets.*
Vincristine sulfate—*Oncovin.*

References

1. Fitzpatrick TB, et al (eds): *Dermatology in General Medicine.* New York, McGraw-Hill Book Co Inc, 1971, pp 1561-1581.
2. Wilkinson DS: Necrolytic migratory erythema with carcinoma of the pancreas. *Trans St Johns Hosp Dermatol Soc* 59:244-250, 1973.
3. Mallinson CN, Bloom SR, Warin AP, et al: A glucagonoma syndrome. *Lancet* 2:1-5, 1974.
4. Weir GC, Knowlton SD, Martin DB: High molecular weight glucagon-like immunoreactivity in plasma. *J Clin Endocrinol Metab* 40:296-302, 1975.
5. Becker SW, Kahn D, Rothman S: Cutaneous manifestations of internal malignant tumors. *Arch Dermatol Syphilol* 45:1069-1080, 1942.
6. McGavran MH, Unger RH, Recant L, et al: A glucagon-secreting alpha-cell carcinoma of the pancreas. *N Engl J Med* 274:1408-1413, 1966.
7. Lightman SL, Bloom SR: Cure of insulin-dependent diabetes mellitus by removal of a glucagonoma. *Br Med J* 1:367-368, 1974.
8. Warin AP: Necrolytic migratory erythema with carcinoma of pancreas. *Proc R Soc Med* 67:24-26, 1974.
9. Sweet RD: A dermatosis specifically associated with a tumor of pancreatic alpha cells. *Br J Dermatol* 90:301-308, 1974.
10. Church RE, Crane WA: A cutaneous syndrome associated with islet-cell carcinoma of the pancreas. *Br J Dermatol* 79:284-286, 1967.
11. Gossner VW, Korting GW: Metastasierendes Inselzellkarzinom vom A-Zelltyp bei einem Fall von Pemphigus foliaceus mit Diabetes renalis. *Dtsch Med Wochenschr* 85:434-437, 1960.
12. Wise JK, Hendler R, Felig P: Influence of glucocorticoids on glucagon secretion and plasma amino acid concentrations in man. *J Clin Invest* 52:2774-2782, 1973.
13. Marco J, Calle C, Roman D, et al: Hyperglucagonism induced by glucocorticoid treatment in man. *N Engl J Med* 288:128-130, 1973.
14. Mallinson CN, Cox B, Bloom SR: Plasma levels of amino acids and glucagon in patients with pancreatic glucagonomas. *Gut* 15:340, 1970.
15. Tasman-Jones C, Kay RG: Zinc deficiency and skin lesions. *N Engl J Med* 293:830, 1975.

Arcuate Dermal Erythema in a Carrier of Chronic Granulomatous Disease

Craig E. Nelson, MD; Mark V. Dahl, MD; Robert W. Goltz, MD

• A female carrier of chronic granulomatous disease developed arcuate, erythematous dermal plaques on her back and face. The lesions were clinically and histopathologically suggestive of Jessner benign lymphocytic infiltration of the skin. Some women with relatively fixed arcuate or annular, erythematous, dermal plaques may be carriers of chronic granulomatous disease.

(*Arch Dermatol* 113:798-800, 1977)

Discoid lupus erythematosus (LE) and Jessner benign lymphocytic infiltration of skin have been associated with the carrier state of chronic granulomatous disease.[1-6] We report a female carrier of chronic granulomatous disease who developed arcuate dermal erythematous plaques clinically resembling Jessner benign lymphocytic infiltration of skin.

REPORT OF A CASE

Our patient was defined as a carrier of chronic granulomatous disease in 1967, and her genetic pedigree has been published previously. The patient is the carrier mother of family S.[7] Mrs S is a 50-year-old woman first seen by us in March 1974, for evaluation of an indurated, erythematous, arcuate lesion over the midback, present for two months. It began as an erythematous plaque 1 to 2 cm in diameter and gradually enlarged peripherally with clearing of the center. It was mildly pruritic. Similar but smaller erythematous plaques were present on the bridge of the nose and on the malar eminences; these were asymptomatic and had been present for several years. At times they became more prominent; this could not be correlated with sunlight exposure. Mrs S had had no other skin disorders.

The patient's status as a carrier of chronic granulomatous disease was documented by leukocyte function studies. Her granulocytes showed roughly 50% of normal bacterial killing capacity by the method of Holmes et al.[8] Intermediate ability of the patient's granulocytes to increase the oxidation of the first carbon of glucose in response to phagocytosis by the method of Holmes et al[9] and an intermediate reduction of nitro-blue tetrazolium by the patient's cells were also shown using a modification of the method of Baehner and Nathan.[10]

One son and two nephews have chronic granulomatous disease. A second son died, probably from the same disease. A sister, daughter, and niece are carriers with abnormal leukocyte function.[7]

Examination showed areas of induration and telangiectasia of the skin on the bridge of the nose and both cheeks. There was no scaling, follicular plugging, atrophy, or scarring. Over the midback at the level of the scapula was a 9 to 10 cm, nontender, erythematous plaque with central clearing and a broken arcuate border (Fig 1). The border was readily palpable and blanched with pressure, but there was no evidence of scaling, follicular plugging, or vesiculation of the surface. Several telangiectatic vessels were noted, but atrophy was absent.

Mild tenderness was present in the left-upper quadrant and midepigastrium. Pin prick hypesthesia of the ophthalmic and maxillary branches of the left fifth cranial nerve extending into portions of the mandibular fifth cranial and second cervical dermatomes was found. There was an equivocally positive Babinski reflex on the right. The remainder of the neurologic and general physical examination was unremarkable.

The CBC was normal, as were values for

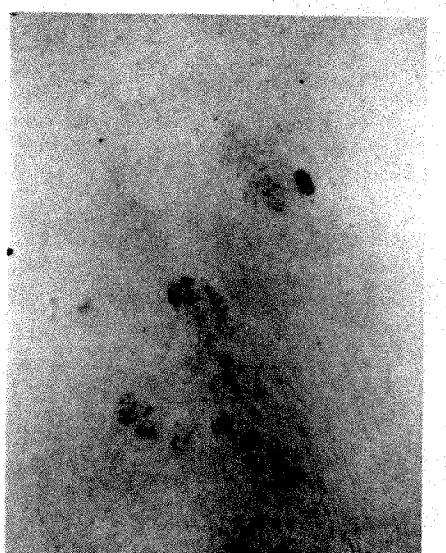

Fig 1.—A 9 to 10 cm, nontender, erythematous plaque with central clearing and a broken arcuate border was present over midback.

Accepted for publication March 9, 1976.

From the Department of Dermatology, University of Minnesota Medical School, Minneapolis.

Reprint requests to Department of Dermatology, Box 98 Mayo, University of Minnesota Hospitals, Minneapolis, MN 55455 (Dr Dahl).

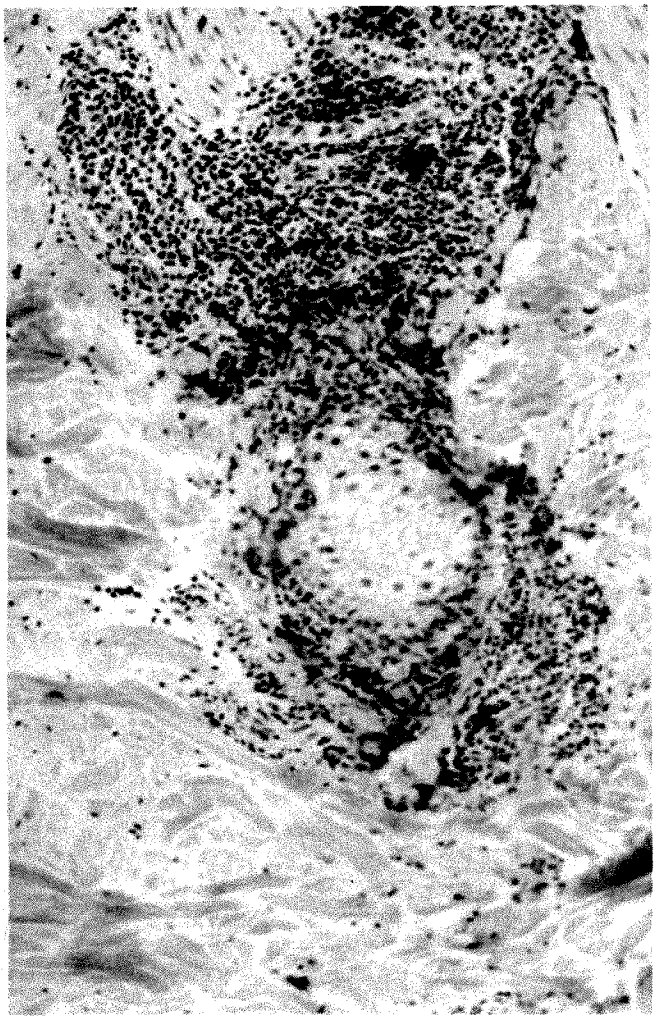

Fig 2.—A prominent infiltrate surrounds sebaceous glands and dermal blood vessels (hematoxylin-eosin, original magnification ×100).

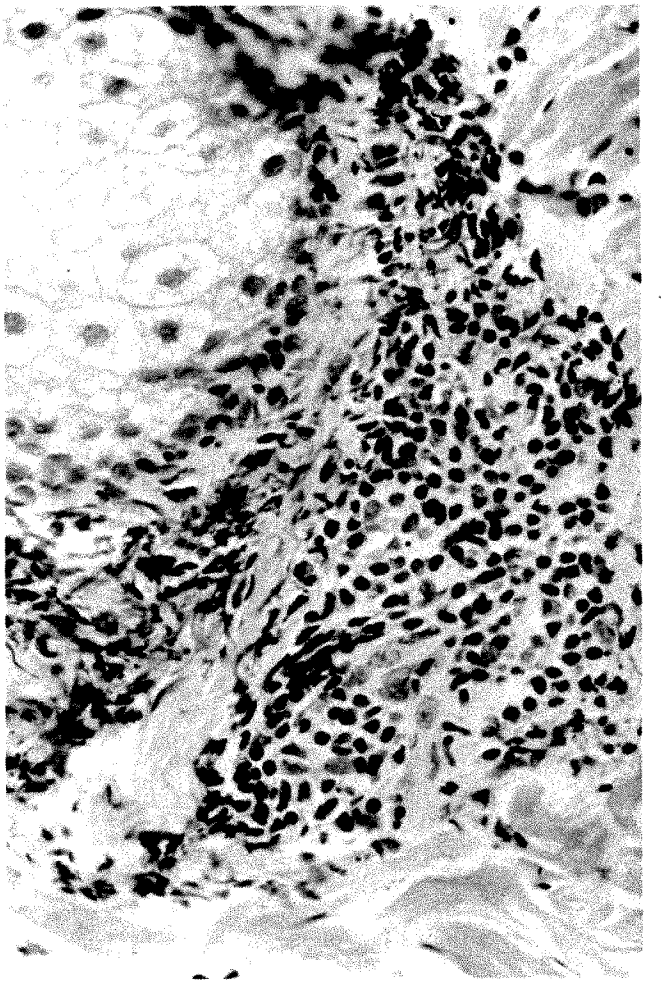

Fig 3.—Infiltrate is composed primarily of lymphocytes with some histiocytes (hematoxylin-eosin, original magnification ×160).

BUN, creatinine, fasting blood glucose, serum electrolytes, serum cholesterol and triglycerides, serum amylase, two-hour urinary amylase, SGOT, lactic dehydrogenase, alkaline phosphatase, prothombin time, partial thromboplastin time, thrombin time, urinalysis, ECG, proctoscopy, upper gastrointestinal series, barium enema, intravenous pyelogram, skull series, EEG, brain scan, intermediate purified protein derivative, bead defibrination tests for LE, and fluorescent antinuclear antibody tests. A mumps skin test showed 9 mm of erythema at 48 hours. An 8 to 13 mm nodule was present in the left-lower lobe. This was thought to be a calcified granuloma.

Histologically, the lesion on the back showed a somewhat flattened and thinned epidermis. In the middle and deep dermis, there were foci of dense, predominantly perivascular, round cell infiltration (Fig 2 and 3). Similar accumulations of lymphocytes were noted about pilosebaceous follicles and eccrine sweat glands in the deep dermis. Giant cells, neutrophil accumulations, necrosis, and lipid-laden histiocytes were not observed. A specimen from an indurated, telangiectatic area on the left cheek showed slightly thinned and flattened epidermis. There were basophilic degeneration of the connective tissue of the upper dermis and a moderate perivascular and perifollicular lymphocytic infiltrate in the mid and deep dermis. Aerobic and anaerobic bacterial cultures of tissue from the annular lesion on the back showed no growth.

Direct immunofluorescence was negative initially, but a second biopsy for direct immunofluorescence from the lesion on the back showed deposits of IgM and small amounts of C3 at the dermoepidermal junction in a diffuse, granular pattern. Deposits of IgG, IgA, and fibrinogen were not found.

COMMENT

Chronic granulomatous disease is a disorder in which granulocytes lack the ability to kill certain bacteria following phagocytosis.[11] The defect probably lies within the metabolic pathways normally triggered by the phagocytosis of bacteria. Intracellular hydrogen peroxide production is deficient in affected individuals,[12] and abnormalities in superoxide production[13] and the early phases of lysosomal degranulation[14] have also been demonstrated.

Chronic granulomatous disease is usually inherited as an x-linked recessive trait.[15] Occurrence in female subjects and in patients without carrier parents suggest an autosomal recessive form of the disease or spon-

taneous mutation.[16-18]

Affected individuals usually demonstrate superficial skin infection, eczematous dermatitis, and suppurative lymphadenitis in the first year of life.[19] Pulmonary infection and septicemia are frequent, and soft tissue abscesses, osteomyelitis, pyarthrosis, empyema, peritonitis, and meningitis may occur. Death before adolescence is common.

Female carriers show levels of granulocyte bacteriocidal and metabolic activity intermediate between the severely depressed levels of affected male subjects and normal controls.[20] Despite intermediate numbers of defective granulocytes, female carriers are usually phenotypically normal and show no tendency towards increased frequency of infection. However, there have been reports of discoid LE or discoid LE-like dermatoses[1-5] and one report of Jessner lymphocytic infiltration of the skin[6] in female carriers. These skin changes have, in individual cases, been accompanied by arthritis, pleuritis, fever, Raynaud phenomenon, photosensitivity, recurrent aphthous stomatitis, or hypergammaglobulinemia.[1] Serologic evidence of systemic LE is usually lacking in these patients, although one patient had a single positive clot test.

Skin lesions in our patient were most consistent with Jessner benign lymphocytic infiltration of skin. Relatively fixed erythematous plaques were present on the face, and a slowly enlarging, erythematous dermal plaque with central clearing was present on the back. In contrast to erythema annulare centrifugum which the back lesion superficially resembled, the lesion enlarged only very slowly over several months and lacked collarette scaling. Histopathological findings also favored Jessner infiltration since epidermal flattening and periappendageal inflammation were present in addition to a lymphocytic perivascular infiltrate.

The presence of deposits of IgM and C3 at the dermoepidermal junction of involved skin of the back supports other evidence that Jessner lymphocytic infiltration may at least sometimes be a form of chronic discoid LE, and further links previous reports of Jessner lymphocytic infiltrate and chronic discoid LE in other carriers of chronic granulomatous disease. Previous patients with Jessner lumphocytic infiltration of skin have lacked deposits of immunoglobulins in skin.[21,22]

Female patients with arcuate dermal plaques clinically resembling Jessner benign lymphocytic infiltration of skin, erythema annuare centrifugum, or discoid LE may sometimes be carriers of chronic granulomatous disease. Family history and impaired nitro-blue tetrazolium dye reduction should delineate the patients.

This investigation was supported by Public Health Service training grant 5T01 AM05560.

References

1. Schaller J: Illness resembling lupus erythematosus in mothers of boys with chronic granulomatous disease. *Ann Intern Med* 86:747-750, 1972.
2. Landing BH, Shirkey HS: A syndrome of recurrent infection and infiltration of viscera by pigmented lipid histiocytes. *Pediatrics* 20:431-438, 1957.
3. Klebanoff SJ, White LR: Iodination defect in the leukocytes of a patient with chronic granulomatous disease of childhood. *N Engl J Med* 280:460-466, 1969.
4. Douglas SD, Davis WC, Fudenberg HH: Granulocytopathies: Pleomorphism of neutrophile dysfunction. *Am J Med* 46:901-909, 1969.
5. Thompson EN, Soothill JF: Chronic granulomatous disease: Quantitative clinicopathological relationships. *Arch Dis Child* 45:24-32, 1970.
6. MacFarlane PS, Spiers AL, Sommerville RG: Fatal granulomatous disease of childhood and benign lymphocytic infiltration of the skin (congenital dysphagocytosis). *Lancet* 1:408-410, 1967.
7. Windhorst DB, Page AR, Quie PG, et al: The pattern of genetic transmission of the leukocyte defect in fatal granulomatous disease of childhood. *J Clin Invest* 47:1026-1034, 1968.
8. Holmes B, Quie PG, Windhorst DB, et al: Fatal granulomatous disease of childhood—an inborn abnormality of phagocytic function. *Lancet* 1:1225-1228, 1966.
9. Holmes B, Page AR, Good RA: Studies of the metabolic activity of leukocytes from patients with a genetic abnormality of phagocytic function. *J Clin Invest* 46:1422-1432, 1967.
10. Baehner RL, Nathan DG: Deficient glucose oxidation in the intact leukocytes of chronic granulomatous disease. *Blood* 28:1010, 1966.
11. Quie PG, White JG, Holmes B, et al: In vitro bacteriocidal capacity of human polymorphonuclear leukocytes: Diminished activity in chronic granulomatous disease of childhood. *J Clin Invest* 46:668-679, 1967.
12. Klebanoff SI: A peroxide mediated antimicrobial system in leukocytes. *J Clin Invest* 46:1078, 1967.
13. Curnutte JI, Whitten DM, Babior BM: Defective superoxide production by granulocytes from patients with chronic granulomatous disease. *N Engl J Med* 290:593-597, 1974.
14. Gold SB, Hanes DM, Stites DP, et al: Abnormal kinetics of degranulation in chronic granulomatous disease. *N Engl J Med* 291:332-337, 1974.
15. Windhorst DB, Good RA: A newly defined x-linked trait in man with demonstration of the Lyon effect in carrier females. *Lancet* 1:737-739, 1967.
16. Azimi DH, Bodenbender JG, Hintz RL, et al: Chronic granulomatous disease in three female siblings. *JAMA* 206:2865-2870, 1965.
17. Quie PG, Kaplan EL, Page AR, et al: Defective polymorphonuclear leukocyte function and chronic granulomatous disease in two female children. *N Engl J Med* 278:976-980, 1968.
18. Dupree E, Smith CW, MacDougall NLT, et al: Undetected carrier state in chronic granulomatous disease. *J Pediatr* 81:770-774, 1972.
19. Windhorst DB, Good RA: Dermatologic manifestations of fatal granulomatous disease of childhood. *Arch Dermatol* 103:351-357, 1971.
20. Ochs HE, Igo RP: The NBT slide test: A simple screening method for detecting chronic granulomatous disease and female carriers. *J Pediatr* 83:77-82, 1973.
21. Barthalmes H, Sonnichsen N: Differential diagnostische Untersuchungen zwishen Lupus Erythematoides chronicus discoides und lymphocytarer infiltration Jessner-Kanof mit Hilfe der Immunofluoreszenz-Histologie. *Arch Klin Exp Dermatol* 232:384-397, 1968.
22. Chorzelski T, Jablonska S, Blaszczyk M: Diagnostischer und differential-diagnostischer Wert der immunopathologischen Untersuchungen bei Erythematoides chronicus. *Arch Klin Exp Derm* 233:211-218, 1968.

Atopic Dermatitis and Impaired Neutrophil Chemotaxis in Job's Syndrome

David Paslin, MD, Michael E. Norman, MD

• A 22-year-old white woman with Job's syndrome was found to have atopic dermatitis and impaired neutrophil chemotaxis in vitro. Major clinical features of Job's syndrome included large, "cold" and recurrent staphylococcal abscesses, and intermittent bacterial and yeast infections. Evidence for atopic disease included infantile eczema progressing to flexural dermatitis, a family history of atopy, positive immediate hypersensitivity skin tests, and hyperimmunoglobulinemia E. Defective erythema responses to histamine, methyl niacinate, and methacholine (Mecholyl) chloride may explain the lack of redness, heat, or pain signalling the development of abscesses (hence the term "cold"). Impaired chemotaxis was probably due to an intrinsic neutrophil defect since patient's serum generated normal amounts of chemotactic factors and did not contain an inhibitor of neutrophil chemotaxis. A delay in neutrophil exudation in vivo may explain the abscess formations and the atopic diathesis may explain the absence of clinical signs of inflammation that have been described in this and other patients with Job's syndrome.

(*Arch Dermatol* 113:801-805, 1977)

Job's syndrome is characterized by large cold staphylococcal abscesses, early childhood dermatitis, and intermittent bacterial and yeast infections. The large, deforming, cold (here meaning no redness, no heat, and no tenderness), chronic, and recurrent subcutaneous staphylococcal abscesses are the outstanding feature. The syndrome, originally observed in two unrelated children, was described by Davis et al in 1966.[1] At least three[2,3] and perhaps six[4,5] additional cases have since been described, and a defect in neutrophilic chemotaxis has been reported.[2,3] Seven of eight have been female patients, and all have had markedly elevated serum IgE values.

This patient is described not only to review the clinical and laboratory findings of Job's syndrome but also to elucidate mechanisms likely to explain these findings.

REPORT OF A CASE

The patient, a 22-year-old white woman, had recurrent cold subcutaneous staphylococcal abscesses. Eczematous dermatitis of the face and scalp was first noted at 3 weeks of age. At 5 years of age, a large "tender" submental abscess was noted, followed by similar and recurrent hot abscesses of the legs, back, neck, buttocks, shoulders, scalp, and face. From the age of 13 years, however, the abscesses were described as being very large, nontender, and cold, appearing on the shoulders, back, vulva, and buttocks. Some of the cold abscesses were sufficiently large to distort bodily contour. Incision and drainage of these abscesses produced as much as 1,000 ml of purulent material. Bronchitis, otitis externa, and frontal and maxillary sinusitis, requiring surgical drainage, occurred between ages 11 and 16 years. Chronic, recurrent oral moniliasis had been present for the past five to six years. There was a positive allergic history for dust, grasses, and animal dander, confirmed by immediate skin tests. There was no personal or family history of diabetes. The half-brother and half-sister are healthy. The maternal grandmother had hay fever. The health of the biological father is unknown. In recent years, the patient has done quite well while receiving nafcillin therapy followed most recently by cephalexin monohydrate (Keflex) taken daily. While receiving such therapy, new abscesses have not appeared.

Physical examination revealed a well-nourished woman with normal vital signs. The hair was chestnut brown, and the eyes were gray, similar to that of other family members. There was eczematous dermatitis of the scalp, a papular acneiform eruption of the face, coarse leonine facial features, flexural dermatitis of the antecubital fossae, the popliteal fossae and the neck, oral and vulvar moniliasis, scattered follicular pustules, surgical scars, and a 4 × 3.5 cm cold, nontender abscess over the left shoulder of which the patient was not aware. (At the time of this examination, she had not taken cephalexin monohydrate for one week.)

Routine laboratory studies included normal values for hemoglobin, hematocrit, urinalysis, urine culture, fasting blood sugar, and electrolytes. White blood cell count was elevated at the time of infection at 13,500/cu mm, with 83% mature neutrophils, 2% band forms, 2% eosinophils, 5% monocytes, and 8% lymphocytes. The serum protein electrophoresis revealed moderate elevation of α_2-globulin at 1.2 gm (normal 0.34 to 0.72) and of gamma globulin at 2.0 gm (normal 0.62 to 1.20). Numerous cultures of the large, recurrent abscesses grew *Staphylococcus aureus*. Morphologically, mature neutrophils which had ingested bacteria, were demonstrated on gram stain (phase microscopy). No free

Accepted for publication May 11, 1976.

From the Departments of Dermatology and Pediatrics, University of Pennsylvania School of Medicine, Philadelphia. Dr Paslin is now with the University of California School of Medicine, San Francisco.

Reprints not available.

bacteria were seen. Cultures of the anterior nares, pubis, anus, and random sites on glabrous skin also grew *S aureus*. *Candida albicans* grew from the oral cavity and vaginal vault.

MATERIALS AND METHODS

Assays of cutaneous erythema and inflammatory response included topical, intradermal or oral challenges to histamine, compound 48-80, croton oil, methyl niacinate, methacholine, and niacin. Histamine, 0.1 ml, was given intradermally (ID) in a concentration of 1:100,000.[6] Compound 48-80, in a concentration of 35 mg/ml and in 0.02 ml, was administered ID.[7] Croton oil as a 10% solution in mineral oil was applied in 0.05 ml to a 1 × 1-cm square of a fine cotton mesh bandage and placed on the forearm skin under an occlusive polyethylene tape for 48 hours.[8] Methyl niacinate, 0.1 ml, was applied topically as a 1% aqueous solution.[9] Methacholine chloride, 0.1 ml in a concentration of 1:500, was injected ID.[10] Niacin was taken by mouth first in a dose of 150 mg, and a week later in a dose of 500 mg.[11]

Tests of humoral and cell-mediated immunity were performed and included the following: quantitative immunoglobulins IgA, IgG, and IgM were measured on immunoplates, IgE was measured by a double-antibody radioimmunoassay procedure; isohemagglutinins, antistreptolysin (ASLO) titers, and typhoid H titers after three immunizations were measured by standard techniques; agglutination titers were measured against *C albicans* and the patient's own *S aureus;* C_3 and total hemolytic complement (CH50) were measured as previously described from this laboratory[12]; delayed hypersensitivity skin tests were performed in standard fashion using both commercially available antigens and the primary immunogen keyhole limpet hemocyanin (KLH) and dinitrochlorobenzene; in vitro cellular immunity was tested by measuring the proliferative responses of the patient's and control peripheral blood lymphocytes to phytohemagglutinin (PHA) and pokeweed mitogen (PWM). All cultures were performed in duplicate, with 1×10^6 cells/tube, cultured in 10% autologous plasma.[13]

Tests of host defense immunity included the following: in vitro phagocytosis of yeast[14] and bacteria,[15] intracellular bactericidal activity,[15] in vitro opsonic activity for yeast and bacteria,[14,15] and in vivo inflammatory activity as measured by the Rebuck skin window.[16] Chemotactic assays were performed by a previously described modification of the Boyden assay.[17] A washed suspension of either control or patient polymorphonuclear leukocytes (PMNs) at a final concentration of 5×10^6/ml was placed on one side of a 3 micropore size membrane. Materials with chemotactic activity were placed on the other side. These materials were generated from fresh control or patient plasma or serum by incubation with preformed antigen-antibody complexes or endotoxin. In previous studies, serum complement has been shown to contribute the major chemotactic activity in this assay, based on (*a*) loss of hemolytic activity in antigen-antibody complex treated serum, (*b*) activation of C_3 as demonstrated by immunoelectrophoresis, (*c*) failure to generate chemotactic activity in ethylenediaminetetracetic acid (EDTA)-treated serum, and (*d*) inhibition of chemotactic activity with antihuman C_3 antiserum. Following incubation for three hours at 37 C, the average number of PMNs per high-power field reaching the lower-most surface was determined (ten contiguous high-power fields were counted). All experiments were performed in duplicate, and most experiments were counted in "blind fashion" by a second observer. Preincubation of patient and normal cells in patient and normal serum (1%, 5%, and 10%) respectively, was carried out for 30 minutes at 37 C. The cells were then washed, resuspended in buffer, and placed in the chambers.

RESULTS

The patient's cutaneous erythema and inflammatory responses to some chemical challenges are listed in Table 1. She developed a 20 mm wheal at 20 minutes to compound 48-80. A positive reaction is the development of a wheal greater than 10 mm in diameter, 20 minutes after injection. Topical application of croton oil provoked redness, itching, and blistering throughout the test site at 48 hours. This constitutes a positive response. Her brisk reactions to compound 48-80 and to croton oil indicate an ability to form an inflammatory response. Yet, she had clear-cut atopic responses, for no flare occurred 15 minutes after intradermal histamine 1:100,000, and no redness was seen 15 minutes after topical methyl niacinate, 1% aqueous solution. Blanching was present on observation 15 minutes after intradermal methacholine, 1:500. There was no flush of any kind to oral niacin at 150 mg. She became markedly flushed over most of the body, but only slightly flushed on the face after an oral dose of niacin at 500 mg. This response lasted one hour, and is inverse to what is normally present, ie, facial but not body-wide flushing. One of the investigators (DP) developed a brisk facial flush lasting two hours after oral niacin at 100 mg.

Routine immunologic studies are presented in Table 2. Of significance is diffuse hypergammaglobulinemia with extraordinary hyperimmunoglobulinemia E, normal antibody production, and generally normal cell-mediated immune responses in vivo and in vitro. Note, however, the lack of development of sensitization to *Bacillus* Calmette-Guérin or DNCB.

Phagocytosis of yeast particles, the patient's own *Staphylococcus*, and a stock preparation of *Staphylococcus* by the patient's neutrophils, was normal. Intracellular killing of *Staphylococcus* was also normal, as was her neutrophil reduction of nitroblue tetrazolium. Similarly, the patient's serum produced normal opsonic function in these phagocytic assays when normal neutrophils were employed.

The patient's overall inflammatory response as measured by the in vivo skin window technique, was also normal as seen below.

Table 1.—Assays of Cutaneous Erythema and Inflammatory Response

Test	Patient	Normal
Histamine 1:100,000, 0.1 ml ID	No flare	Flare
Compound 48-80, 35 mg/ml, 0.02 ml ID	Large wheal	Large wheal
Croton oil 10% in mineral oil, topically	Redness, itch, and blistering	Redness, itch, and blistering
Methyl niacinate 1% aqueous, topically	Not red	Red
Methacholine 1:500, 0.1 ml ID	Delayed blanch	Flare
Niacin 150 mg, PO	No flush	Flush at 100 mg, lasting two hours
Niacin 500 mg, PO	Inverse flush lasting one hour (see text)	(Flush expected, but not attempted)

Table 2.—Immunologic Studies

Humoral Immunity Immunoglobulins	IgG	IgA	IgM	IgE
Patient	1,700 mg/100 ml	400 mg/100 ml	160 mg/100 ml	12,000 IU/ml
Normals	(1,158 ± 305 mg/100 ml)*	(200 ± 61 mg/100 ml)*	(99 ± 27 mg/100 ml)*	(10-500 IU/ml)
Serum complement				
CH50				
Patient	157 U/ml			
Normals	(142 ± 32 U/ml)*			
C_3				
Patient	118 mg/100 ml			
Normals	(145 ± 22 mg/100 ml)*			
Antibody titers				
Isohemagglutinins	1:32 at 25C 1:64 at 37C			
ASLO	1:166 U/ml			
Antityphoid (H antigen)	1:60			
Candida agglutinins	+ undiluted			
Staphylococcus agglutinins	+++ at 1:512			
Cellular Immunity				
Delayed hypersensitivity skin tests	Positive†		Negative	
	Mumps, *Candida* (500 pnu/ml)		PPD—S, B, G, Y,‡ Histoplasmin, coccidioidin, SK/SD, trichophytin (1:30, 1:500), KLH, DNCB	
In vitro proliferative response of patient's lymphocytes	Specific Incorporation Index§			
	PHA		PWM	
Patient	366		27	
Normal	209		22	

* ± 1 SD.
† > 10 mm induration at 48 hours.
‡ The PPD challenges followed intradermal inoculation of BCG by one month.
§ The specific incorporation index = ratio cpm of mitogen stimulated culture/cpm of unstimulated culture.

Host Defense Immunity

Neutrophil function in vitro:	
1. Yeast phagocytosis	Normal
2. Staphylococcal phagocytosis	Normal
3. Staphylococcal bactericidal activity	Normal
4. Random motility	Normal
Serum opsonic function in vitro:	
1. Yeast phagocytosis	Normal
2. Staphylococcal phagocytosis	Normal
3. Staphylococcal bactericidal activity	Normal
Inflammatory response in vivo:	
1. Rebuck skin window	Normal

In vitro tests of neutrophil movement included normal random motility but deficient chemotaxis. The results of the chemotactic experiments are shown in the Figure.

When comparing the chemotactic activity of the patient's serum or plasma as a percentage of the normal control plasma or serum for a particular experiment (eg, 100%), the mean value is 75 ± 25% ($P > .10$ Student t test). When comparing the chemotactic responsiveness of patient's PMNs to normal PMNs, using normal serum as a source of chemotactic activity, the mean response is 65 ± 17% ($P < .001$); the mean response is 61 ± 17% when these experiments employed patient's serum as the source of chemotactic activity ($P < .001$).

The deficient migration of patient's neutrophils could be due either to an intrinsic cellular defect or a cell-directed inhibitor in patient's serum. Consequently, additional chemotactic experiments examined the capacity of patient's serum to inhibit the chemotactic migration of normal neutrophils, by preincubating the cells in the serum (eg, 1%, 5%, and 10%). The controls included preincubation of normal neutrophils in both normal, autologous, and normal pooled (ten adult donors) sera. There was no difference in the migration of these neutrophils whether incubated in normal or patient sera. Migration of the preincubated normal neutrophils was not significantly different from that of neutrophils not preincubated.

COMMENT

The outstanding and delineating feature of Job's syndrome is the occurrence of huge, cold, chronic, and recurrent staphylococcal abscesses that deform and distort bodily contour. Red hair and hyperextensible joints have been described in some patients.[1] Early childhood dermatitis and frequent bacterial and yeast infections complete the syndrome.

Hill et al[3] offered a perceptive explanation for the development of the large abscesses: patients with Job's syndrome, having defective chemotaxis of their neutrophils, do not develop a sufficiently early response to staphylococcal invasion through the skin. Multiplication of invading bacteria continue until finally checked by a massive tardive influx of neutrophils giving rise to abscess formation.

The explanation of Hill et al[3] may be extended. Once the mass of neutrophils arrive to form the abscess, they, being otherwise intact, perform the remaining tasks of leukocyte function. Hence, no free organisms are found on smear, and sepsis does not typically occur. It is therefore not surprising that these patients do not become septic in the face of huge abscesses, for when the Job's syndrome neutrophils are already present, as they are in the blood stream, they function normally.

Job's syndrome has been categorized as one of the disorders of leukocyte function.[18] With equal precision, it may also be categorized as one of the disorders of atopic dermatitis, in the sense that Wiskott-Aldrich is a disease of atopic dermatitis.[19] It is suggested that many of the composite features are the result of superimposing the chemotactic defect of

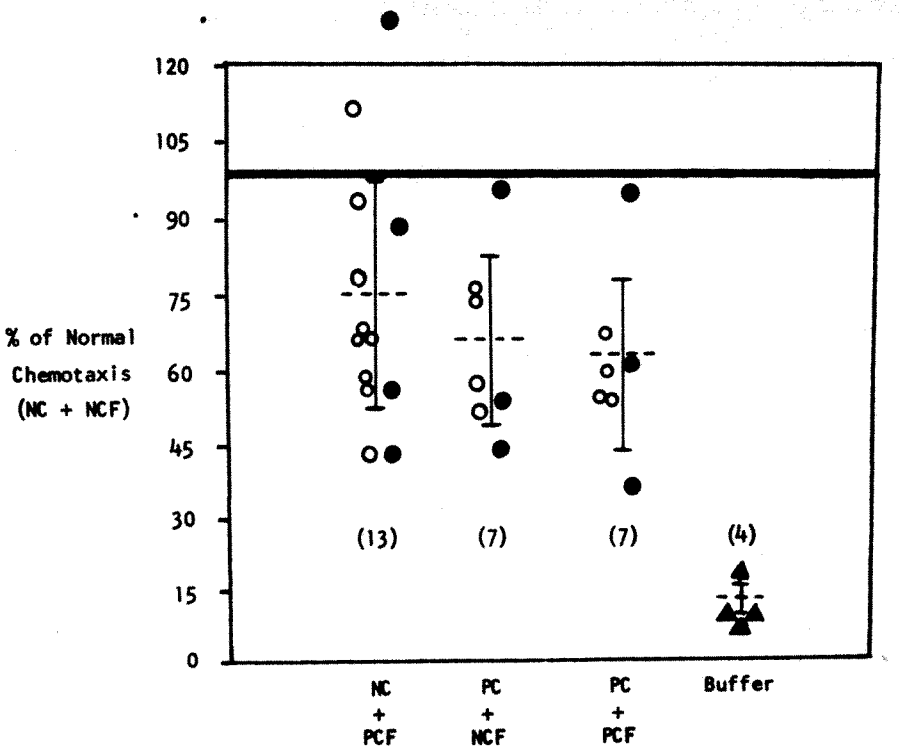

Results of chemotaxis experiments. Chemotactic response of normal neutrophils (NC) to chemotactic activity generated from normal serum or plasma (NCF) is set at 100% for each experiment. Chemotactic activity generated from patient serum (open circles) or plasma (closed circles) using either antigen-antibody complexes or endotoxin as activating agents (PCF) is compared to normal serum or plasma chemotactic activity (NC + NCF vs NC + PCF), for that experiment.

$$\% \text{ of normal chemotactic activity} = NC + PCF/NC + NCF \times 100$$

Number of experiments is shown in parentheses. Chemotactic migration of patient neutrophils (PC) is compared to that of normal neutrophils, when either normal serum or plasma was the source of chemotactic activity (PC + NCF vs NC + NCF), or patient serum or plasma was the source of chemotactic activity (PC + PCF vs NC + NCF). Group means ± 1 SD are indicated by the dotted horizontal and vertical lines, respectively.

Job's syndrome on the underlying vascular and inflammatory defects of atopic dermatitis. Patient's with Job's syndrome characteristically have an early childhood dermatitis. Our patient provides evidence that this early childhood dermatitis is atopic dermatitis and is an intrinsic part of Job's syndrome. She has a positive family history for atopic disease. She had infantile eczematous dermatitis and later developed chronic flexural dermatitis. She had a history of immediate type hypersensitivity to dust, grasses, and animals. She had negative delayed skin tests to purified protein derivative, histoplasmin, coccidioidin, SK/SD, KLH, and trichophytin. She could not be sensitized to DNCB. She developed no erythema after topical methyl niacinate 1% and developed a delayed blanch after intradermal methacholine, 1:500. Her IgE was highly elevated at 12,000 IU/ml. In sum, the evidence suggests that our patient had atopic dermatitis and has the atopic diathesis.

The general principle that persons with atopic dermatitis are prone to chronic bacterial[20] and fungal[21] infection is well established. Studies by Leyden et al[20] showed high counts of *S aureus* on the involved and uninvolved skin of patients with atopic dermatitis. Since the skin of patients with atopic dermatitis typically harbors large populations of *S aureus*, and since there is reason to believe that the skin of patients with Job's syndrome is atopic skin, it would be expected that Job's syndrome skin would also bear a large population of these organisms. Such was the case in our patient, who grew *S aureus* from both involved and uninvolved skin. One would expect, therefore, that abscesses in Job's syndrome would appear primarily on the skin rather than in some other organ. Yet, it has been observed that the large abscesses are often subcutaneous rather than dermal. The reason for this is not clear. It may be that an inoculum of bacteria in the subcutaneous tissue grows better than a comparable inoculum in the dermis. The differences may be related to the numbers of resident tissue mast cells and/or mononuclear cells and the richness of the blood supply.

Hill et al[3] could find no explanation for the lack of redness, heat, and pain in their patient's large cold abscesses. An explanation becomes apparent when it is realized that patients with Job's syndrome are atopic or at least have many of the stigmata of atopy. Study of our patient discloses defective erythema responses to a number of different stimuli. Lack of redness after intradermal methacholine has already been mentioned. This may simply represent an obfuscation of vasodilatation by edema formation, as seen in atopics and documented by Copeman et al,[22] Ramsey,[23] and Bystryn et al.[10] Yet our patient also shows lack of redness after topical methyl niacinate (as do other atopics—see Copeman et al[22]) and after oral niacin. The lack of normal erythema responses in our patient would suggest that impaired vasodilatation may be an additional characteristic of atopics with Job's syndrome. It is observed, however, that the large pus-filled abscesses not only lack redness, but they also lack heat and pain. Hence in Job's syndrome, there is leukocytic inflammation in the absence of these classic signs of clinical inflammation. Conversely, abundant clinical settings illustrate the presence of redness, heat, and/or pain in the absence of leukocytic inflammation. Examples include blushing, carcinoid flushing, horseradish ingestion, and erythromelalgia. Histamine, niacin, bradykinin, and serotonin are among the probable mediators of these vasodilator responses. In the above clinical settings, it is intense vasodilatation that gives rise to red-

ness, heat, and at times pain, not leukocytic infiltration. It is clear that leukocytic inflammation and the clinical signs of inflammation (redness, heat, and pain) can be independent phenomena.

The syndrome of defective neutrophil chemotaxis associated with recurrent bacterial infections and hyperimmunoglobulinemia E has recently been reviewed.[24] Several groups of patients have emerged and can be separated by the presence or absence of mucocutaneous candidiasis and the presence or absence of atopic features at the time of evaluation, in the face of a positive atopic history. In most of the patients reported, as well as our own, classical tests of humoral and cell-mediated immunity are normal. There is no evidence that IgE in the serum has a direct inhibitory effect on neutrophil chemotaxis; many patients with elevated IgE and/or atopic eczema have normal chemotaxis.[24] Thus, there is something uniquely different about the host defense response in these patients. The chemotactic abnormality in our patient's neutrophils was similar to that reported by others, and we were unable to detect inhibitory activity in her serum.

The dissociation of defective in vitro neutrophil chemotaxis from a normal in vivo inflammatory response has been observed in a number of patients with recurrent bacterial infections.[25] There is no well-established, in vivo assay of neutrophil chemotaxis in man; the Rebuck skin window measures the function of the overall inflammatory response, including both humoral and cellular mediators. Kinetic defects in early neutrophil responses are more easily detected in the current in vitro assays, as suggested by Hill et al.[3]

It cannot be excluded that the neutrophils in Job's syndrome are defective not only in their chemotactic response, but also in the manufacture and release of erythrogenic and pyrogenic polypeptides. Yet the atopic diathesis that is a part of this syndrome provides an alternative explanation for the absence of clinical inflammation in the face of leukocytic chemotaxis (albeit tardive) and phagocytosis. It is suggested that where there is no redness, there may be no heat and no pain. In like manner, the defective erythema responses of atopics with Job's syndrome may directly result in the lack of heat and pain—hence, no clinical inflammation. The cold abscesses of Job's syndrome vividly illustrate the dissociation of leukocytic function and the clinical signs of inflammation.

This investigation was supported in part by Public Health Service grant 5 M01-RR40 from the Department of Health, Education, and Welfare.

Richard K. Root, MD, performed the assays of staphylococcal phagocytosis and intracellular bactericidal activity.

References

1. Davis SD, Schaller J, Wedgwood RJ: Job's syndrome: Recurrent, "cold," staphylococcal abscesses. *Lancet* 1:1013-1015, 1966.

2. Clark RA, Root RK, Kimball HR, et al: Defective neutrophil chemotaxis and cellular immunity in a child with recurrent infections. *Ann Intern Med* 78:515-519, 1973.

3. Hill HR, Ochs HD, Quie PG, et al: Defect in neutrophil granulocyte chemotaxis in Job's syndrome of recurrent "cold" staphylococcal abscesses. *Lancet* 14:617-619, 1974.

4. Buckley RH, Wray BB, Belmaker EZ: Extreme hyperimmunoglobulinemia E and undue susceptibility of infection. *Pediatrics* 49:59-70, 1972.

5. VanScoy RE, Hill HR, Ritts RE, et al: Familial neutrophil chemotaxis defect, recurrent bacterial infections, mucocutaneous candidiases, and hyperimmunoglobulin E. *Ann Intern Med* 82:766-771, 1975.

6. Lobitz WC Jr, Campbell CJ: Physiologic studies in atopic dermatitis. *Arch Dermatol* 67:575-589, 1953.

7. Atkins P, Green GR, Zweiman B: Histologic studies of human skin test responses to ragweed, compound 48-80, and histamine. *J Allerg Clin Immunol* 51:263-273, 1973.

8. Johnson MW, Maibach HI, Salmon SE: Skin reactivity in patients with cancer. *N Engl J Med* 284:1255-1257, 1971.

9. Fountain RB, Baker BS, Hackgraft JW, et al: The role of absorption and deviation of action of four different solutions of methyl nicotinate. *Br J Dermatol* 81:202-206, 1969.

10. Bystryn JC, Freedman RI, Hyman C: Clearance of iodoantipyrene from methacholine blanched skin in atopics. *Arch Dermatol* 100:165-168, 1969.

11. Goodman LS, Gilman A: *The Pharmacological Basis of Therapeutics*, ed 3. New York, The Macmillan Co, 1965, pp 1659-1662.

12. Norman ME, Gall EP, Taylor A, et al: Serum complement profiles in infants and children. *J Pediatr* 87:912-916, 1975.

13. Daguillard F, Heiner DC, Richter M, et al: The response of leukocytes of agammaglobulinemia subjects to phytohemagglutinin and anti-immunoglobulin antiserum. *Clin Exp Immunol* 4:203-211, 1969.

14. Miller ME, Nilsson UR: A familial deficiency of the phagocytosis enhancing activity of serum related to a dysfunction of the fifth component of complement (C5). *N Eng J Med* 282:354-358, 1970.

15. Root RK, Rosenthal AS, Balestra DJ: Abnormal bactericidal, metabolic and lysosomal functions of Chediak-Higaski syndrome leukocytes. *J Clin Invest* 51:649-655, 1972.

16. Rebuck JW, Crowley JH: A method of studying leukocyte functions in vitro. *Ann NY Acad Sci* 59:757-805, 1955.

17. Miller ME, Oski FA, Harris MB: Lazy-leucocyte syndrome: A new disorder of neutrophil function. *Lancet* 1:665-669, 1971.

18. Baehner RL: Disorders of leukocyte function. *Adv Pediatr* 20:323-351, 1973.

19. Rostenberg A, Solomon LM: Infantile eczema and systemic disease. *Arch Dermatol* 98:41-46, 1968.

20. Leyden JJ, Marples RR, Kligman AM: *Staphylococcus aureus* in the lesions of atopic dermatitis. *Br J Dermatol* 90:525-530, 1974.

21. Jones HE, Reinhardt JH, Rinaldi MG: A clinical, mycological, and immunological survey for dermatophytosis. *Arch Dermatol* 108:61-65, 1973.

22. Copeman PWM, Winkelmann RK: Vascular changes accompanying white dermographism and delayed blanch in atopic dermatitis. *Br J Dermatol* 81:944-945, 1969.

23. Ramsey C: Vascular changes accompanying white dermographism and delayed blanch in atopic dermatitis. *Br J Dermatol* 81:37-43, 1969.

24. Hill HR, Quie PG: Defective neutrophil chemotaxis associated with hyperimmunoglobulinemia E, in Bellanti JA, Dayton DH (eds): *The Phagocytic Cell in Host Resistance*. New York, Raven Press, 1975, pp 249-266.

25. Miller ME: Cell movement and host defenses. *Ann Intern Med* 78:601-603, 1973.

Graft-vs-Host Reaction

Maj Thomas M. Grogan, MC, USA, MD; Lt Col Richard B. Odom, MC, USA, MD; John H. Burgess

• **Observations surrounding the clinical manifestations and pathological studies of a neonate who died at 9 weeks of age, indicate that distinctive cutaneous, histopathologic, and ultrastructural findings occur when graft-vs-host reaction (GVHR) complicates combined immune deficiency syndrome (CIDS). The prominence and specificity of the epidermal lesions, particularly a necrotic cell that occurs in association with satellite lymphocytes ("satellite cell necrosis" (SCN)), lead us to recommend that a cutaneous biopsy be performed to facilitate an early definitive diagnosis. Dermatologists can recognize GVHR at the bedside and establish the diagnosis with the pathological findings obtained from the skin biopsy.**

(*Arch Dermatol* 113:806-812, 1977)

Graft-vs-host reaction (GVHR) following introduction of allogeneic hematopoietic cells is a widely documented complication of transplantation. A recent paper by Slavin and Woodruff[1] emphasized the distinctive epidermal lesions in GVHR secondary to bone marrow transplantation. Several immunodeficient infants with GVHR secondary to allogeneic transplantation[2-7] and maternofetal cell transfer[8-10] have been described, but similar distinctive epidermal lesions have not been described in these circumstances.

We now have additional findings from our studies on a recently published case of GVHR in a neonate in whom combined immune deficiency syndrome (CIDS) occurred as a result of maternofetal cell transfer.[11] These observations indicated that distinctive epidermal lesions can occur in GVHR, complicating CIDS, as they do in adult allogeneic reactions. Furthermore, this entity may be readily recognized by the dermatologist at the bedside, and the diagnosis may be established by skin biopsy. We describe and illustrate the cutaneous lesions of GVHR, demonstrate the characteristic histopathologic features of GVHR, and for the first time, demonstrate that the specific diagnostic ultrastructural findings of GVHR seen in nonhuman primates (Woodruff et al),[12] do occur in man.

The distinctive epidermal lesion we describe has been referred to by Slavin and Santos[13] as an aggressor lymphocyte reaction, which causes single mummified epithelial cells with satellite lymphocytes. In earlier work we referred to this lesion as single cell necrobiosis with associated lymphocytes.[11] It has been described by Woodruff et al, in GVHR of primates as "satellite cell dyskeratosis."[12-14] As our ultrastructural findings demonstrate, it is a necrotic, not dyskeratotic, cell that occurs in association with satellite lymphocytes. Therefore, we now prefer the term "satellite cell necrosis" (SCN), as it is both descriptively accurate and concise.

REPORT OF A CASE

Cutaneous Manifestations

An erythematous, macular rash was apparent over the face and head of an infant girl when she was discharged from the hospital three days after delivery. A detailed description of the case was reported by Grogan and others in another work.[11] The rash progressed over her trunk and arms so that when she was readmitted to the hospital at 21 days of age for the treatment of interstitial pneumonia, the rash was diffuse, confluent, peeling, maculopapular, and erythematous. By 6 weeks of age, some areas of her skin appeared thin and parchment-like with a distinctive bronze hue. These areas enlarged, and at the age of 8 weeks (one week before death) the infant showed some persisting erythematous dermatitis, and large areas of skin appeared parchment-like and bronzed.

Accepted for publication May 10, 1976.

From the Department of Pathology (Dr Grogan and Mr Burgess) and the Dermatology Service (Dr Odom), Department of Medicine, Letterman Army Medical Center, Presidio of San Francisco.

The opinions or assertions contained herein are the private views of the authors and are not to be construed as official or as reflecting the views of the Department of the Army or the Department of Defense.

Reprint requests to Letterman Army Medical Center, Presidio of San Francisco, CA 94129 (Technical Publications Editor).



Fig 1.—Abdomen skin with extensive erythematous rash showing dermal infiltrate, exocytosis, and satellite cell necrosis (hematoxylin-eosin, ×100).

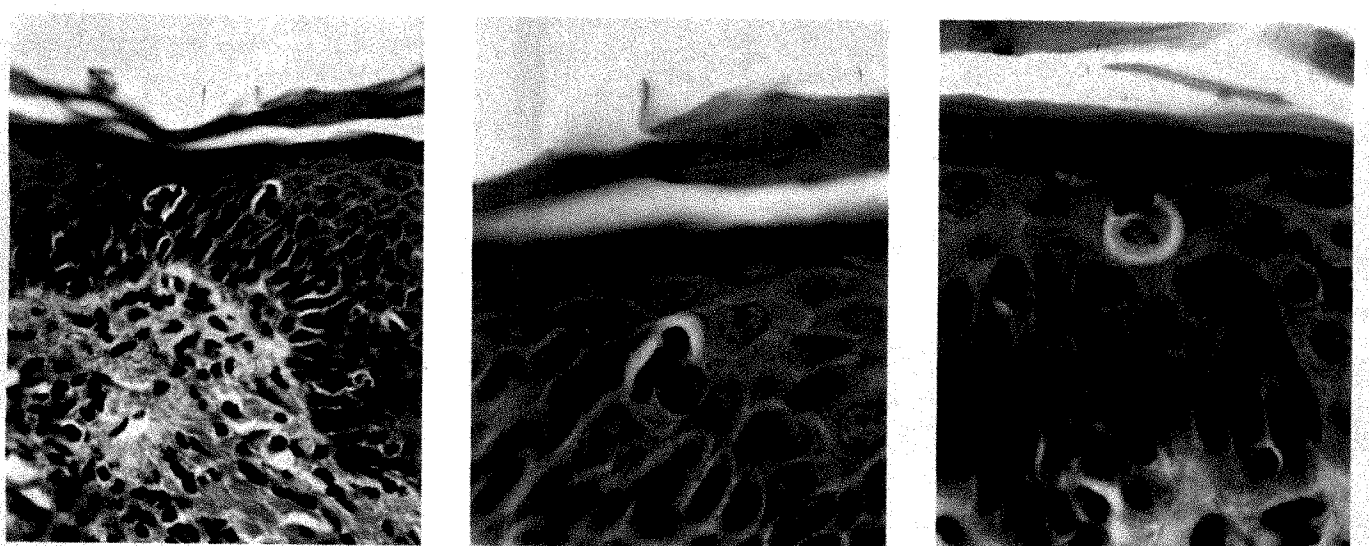

Fig 2.—Left, Skin of abdomen with satellite cell necrosis (SCN) occurring within discrete epidermal spaces of stratum spongiosum (hematoxylin-eosin, ×450). Center and Right, View of discrete epidermal space with degenerating epithelial cell and associated lymphocytes (SCN) (hematoxylin-eosin, ×950).

Histopathology of the Skin

Biopsy material for the microscopical studies was obtained from two sources: (1) the erythematous areas of the trunk (at 6 weeks and within one hour of death at 9 weeks), and (2) the bronzed, parchment-like regions of the trunk (within one hour of death at 9 weeks). Microscopical studies of the skin from regions of extensive erythematous rash demonstrated well-defined changes in the squamous epithelium (Fig 1). The papillary dermis had a diffuse infiltrate of small and large lymphocytes, with some associated histiocytes. The lymphocytes and histiocytes dissected the basal and spinous layers of the epidermis. In the regions with extensive lymphocytic invasion (eg, exocytosis), spongiosis and areas of discrete acantholysis were prominent findings (Fig 1). In the regions of extensive spongiosis, characteristic epidermal spaces were found. These spaces were distinctive because they were discrete (15 to 40 μ in diameter); they occurred largely in the stratum spongiosum of the epidermis; and they contained one or more large degenerating keratinocytes (Fig 2 left, center, and right). These discrete spaces have been referred to as "suprabasilar lacunae" by others.[1-13] The degenerated keratinocytes within these spaces had pyknotic, disrupted nuclei and eosinophilic, hyalinized cytoplasm. These necrotic cells were closely associated with one or more satellite lymphocytes. This distinctive lesion has now been identified by the term SCN.

Occasionally, hyalinized necrotic cells occurred without associated lymphocytes. Focal, vacuolar degeneration of the basal cell layer occurred at the sites of lymphocytic invasion. Frequently, a diffuse perivascular and periadnexal lymphocytic infiltrate was an associated finding. Occa-

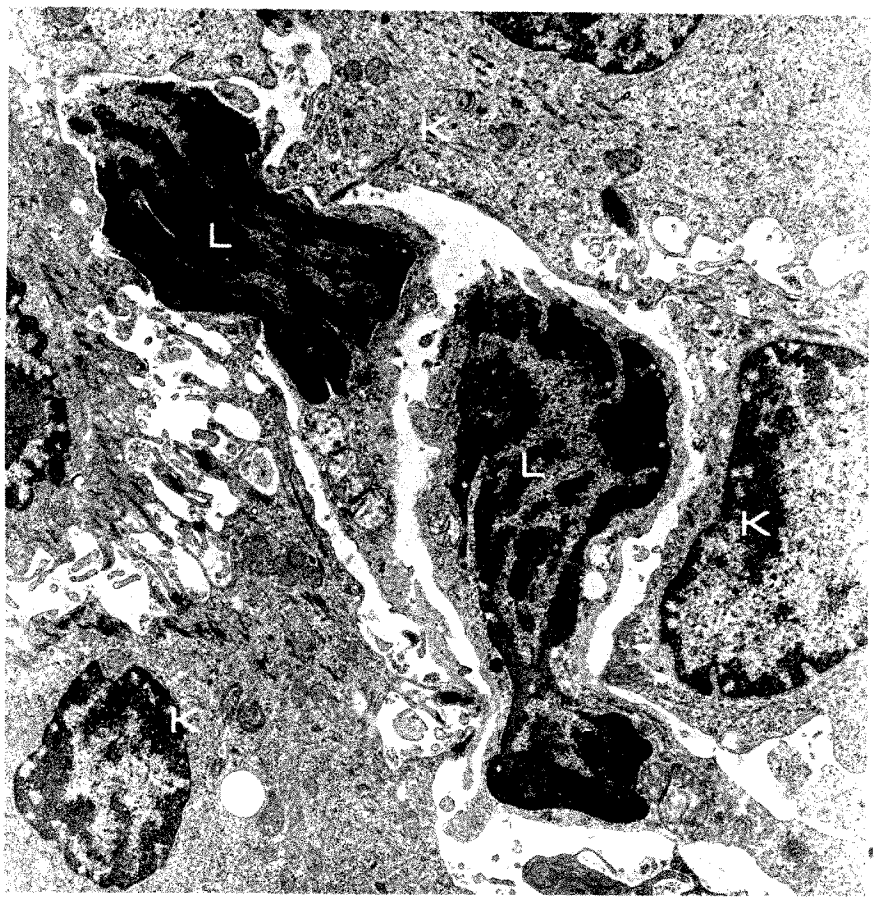

Fig 3.—Skin of abdomen showing two centrally located lymphocytes within stratum spongiosum demonstrating exocytosis. L indicates lymphocytes; K, keratinocyte (×4,000).

sionally, SCN was present within the pilosebaceous apparatus.

In the parchment-like and bronzed areas, focal, epidermal atrophy was observed. Many of these areas showed extensive parakeratosis and hyperkeratosis. Eosinophilic, hyalinized bodies were occasionally seen in these hyperkeratotic regions. There was some melanin pigment found in the papillary dermis in those atrophic regions.

Immunofluorescent and Ultrastructural Findings

Multiple biopsy specimens from the erythematous regions of the trunk were obtained when the neonate was 6 weeks old, and within one hour of her death at 9 weeks of age. The direct immunofluorescence studies were done on the skin tissue obtained at 6 weeks. The results of these studies demonstrated the absence of anti-human IgG, IgM, C, and fibrinogen in the tissue.

Portions of epidermis obtained within one hour of death were fixed in 4% glutaraldehyde, postfixed in 1% osmium tetroxide, embedded in a mixture of resins (Epon) and stained with 5% uranyl acetate and lead citrate. The results of ultrastructural examination revealed prominent migration of lymphocytes (exocytosis) within the stratum spongiosum (Fig 3). The lymphocytes were small or medium in size (most were 10 to 15 μ in diameter). The nuclei contained prominent nucleoli, and the cytoplasm showed an abundance of ribosomes and mitochondria. Many of the lymphocytes had elongated cytoplasm suggesting pseudopodia. Discrete lysis of desmosomes (ie, acantholysis) was apparent in the stratum spongiosum only in association with migrating lymphocytes (Fig 4).

Prominent epidermal spaces were present within the stratum spongiosum. These epidermal spaces showed a degenerating keratinocyte in close association with a lymphocyte (Fig 5). The epithelial nature of the degenerating cell was suggested by the presence of intracellular desmosomes and by many stacked tonofibrils within the

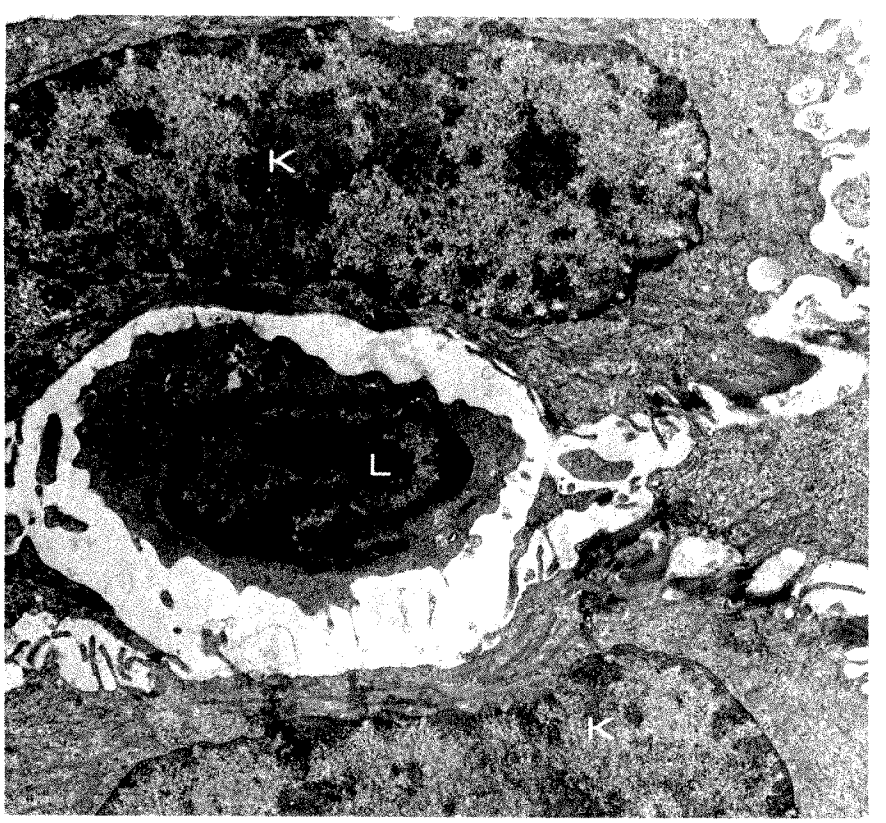

Fig 4.—Skin of abdomen showing lymphocyte within stratum spongiosum with associated focal lysis of desmosomes, ie, acantholysis. L indicates lymphocytes; K, keratinocyte (×4,000).

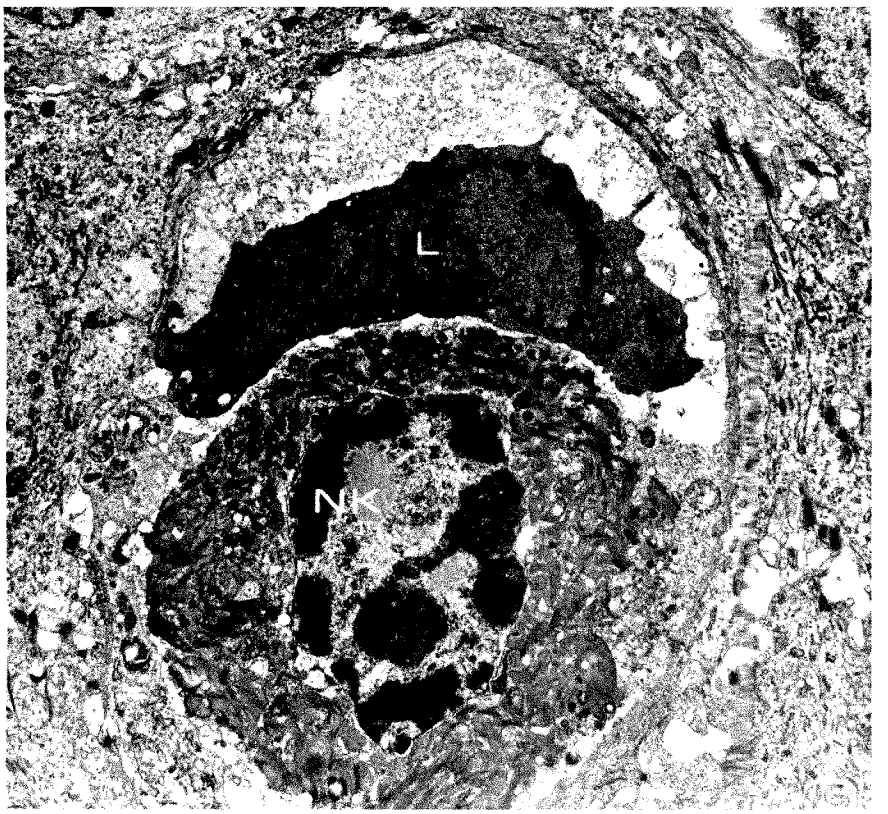

cytoplasm of the cell (Fig 6). The irregular, angular, disrupted, nuclear outline and the compacted, cytoplasmic tonofibrils suggested irreversible degeneration of the keratinocyte (Fig 6). The surrounding lymphocytes within the epidermal spaces contained abundant ribosomes and mitochondria. Some cytoplasmic projections were present, but intercytoplasmic bridges between lymphocyte and keratinocyte were not seen.

COMMENT
Acute vs Chronic GVHR

The cutaneous eruption of acute GVHR typically appears as an evanescent, erythematous, maculopapular rash that frequently begins on the face and head, and rapidly progresses

Fig 5.—Discrete epidermal space with necrotic keratinocyte in close association with lymphocyte (satellite cell necrosis). L indicates lymphocyte; S, epidermal space; NK, necrotic keratinocyte. Comparable to Fig 2, right (×4,000).

Fig 6.—Desmosomes (large arrowhead) and stacked tonofibrils (small arrows) within necrotic keratinocyte (nuclear chromatin clumped and nuclear membrane disrupted) (Fig 5 at ×7,700).

to the trunk and arms. As our case demonstrates, the eruption is initially so transient that careful observation is mandatory to document its existence. The morphologic features of the acute lesions usually are evident within a few days after the onset of clinical GVHR.[13]

While transient or abortive GVHR may follow the acute stage, typically the eruption becomes florid. It is characterized by a diffuse, confluent, erythematous, maculopapular dermatitis that is occasionally accompanied by bullae and alopecia. Frequently, the reaction then develops into a generalized, rather mild, exfoliative erythroderma. This represents the chronic state, which usually occurs within a few days or weeks after the onset of clinical GVHR.[13] Chronic GVHR may or may not be preceded by a clinically recognizable acute GVHR. The chronic GVHR may continue to evolve from exfoliative erythroderma to diffuse dermal sclerosis, epidermal atrophy, reticulate pigmentation, hyperkeratosis, and widespread ulceration that shows no tendency toward healing and resembles a poikilodermatous state.[15] The features of the florid stage predominated in our case when the 21-day-old infant was readmitted to the hospital.

After several weeks or months, the eruption enters a quiescent stage, and the skin appears thin and parchment-like, frequently with a bronze hue.

Differential Diagnosis

The cutaneous manifestations of GVHR usually present diagnostic problems to the clinician. The differential diagnosis of GVHR should include seborrheic dermatitis, Leiner disease, histiocytosis-X, drug eruption, exfoliative erythroderma, toxic epidermal necrolysis, lichen planus, and viral exanthem.

Seborrheic dermatitis may simulate the dermatological findings of GVHR, although the presence of systemic involvement in GVHR rules out this condition.[16] Leiner disease is characterized by generalized seborrheic dermatitis of the neonate; intractable, severe diarrhea; recurrent, local, and systemic infections, usually of Gram-negative origin; and marked wasting and dystrophy. Humoral and cellular immunity are normal although they did not occur in the case we report; hypergammaglobulinemia and leukocytosis are usually present. Demonstration of deficient opsonic activity of the patient's serum is diagnostic. This entity responds dramatically to administration of fresh plasma.[17]

The skin lesions in histiocytosis-X, particularly in the more severe form (Letterer-Siwe disease), are noteworthy for their constant appearance as individual, brown, scaling papules. These papules occur in crops on the scalp, face, neck, and trunk, and occasionally develop vesicles and pustules followed by erosions. The lesions frequently are purpuric, and often the surrounding region develops a petechial and hemorrhagic appearance.[18] Histiocytosis-X does not result in abnormalities of hair and nail growth, whereas bony defects and hormonal abnormalities not found in GVHR are characteristic of the histiocytic proliferative disorders.[16]

Drug reactions may provoke a variety of skin eruptions in different individuals, or even in the same individuals at different times.[19] Consequently, a drug eruption as a pathogenetic factor can only be ruled out by the knowledge of the absence of such an insult. In the past, exfoliative erythroderma was divided into distinct clinical entities, but recently this concept was abandoned. Exfoliative erythroderma is now considered a symptom complex that may be the result of many different causations.[20] It is now well established that the chronic stage of GVHR frequently demonstrates an exfoliative erythroderma.[1,3,9,21]

Toxic epidermal necrolysis (TEN) is a cutaneous reaction pattern of multiple causation that is characterized by desquamating sheets of epidermis. The eruption begins suddenly, spreads rapidly, and results in a painful, generalized erythema with flaccid bullae. Nikolsky sign is present. Peck et al[21] described TEN occurring in a patient with GVHR. The initial morbilliform eruption became intensely erythematous, and massive desquamation of large sheets of epidermis ensued. Early in the clinical course, cutaneous histopathologic studies revealed changes of GVHR. However, results of later biopsies were consistent with the diagnosis of TEN. Such results supported the concept of GVHR as a causal factor leading to TEN. A pattern resembling TEN has been observed in laboratory animals in which GVHR was experimentally induced.[22-25] Drug allergy, staphylococcal infection, viral infection, the association with underlying lymphoma,[26] and fumigant-induced reactions[27] are among the causal factors of TEN described. Since the patient of Peck et al[21] had received a bone marrow transplant for acute lymphocytic leukemia, and had received several immunosuppressive agents and antibiotics prior to the cutaneous eruption, the association of TEN with GVHR in man must await further elucidation.

Touraine et al[15] and Saurat et al[28] simultaneously reported GVHR and lichen planus-like eruptions in patients who received bone marrow transplants for posthepatitis aplastic anemia. Papular lesions typical of lichen planus developed in the skin; lesions of the erosive variety were noted in the buccal mucous membranes and nails of the patients described. In the case reported by Touraine et al,[15] severe, life-threatening, cutaneous sequelae developed in the absence of hematological, hepatic, or bowel disease, one year following the lichen planus-like eruption. Clinically, the patient had dermal sclerosis, epidermal atrophy, cicatricial alopecia, reticulate pigmentation, hyperkeratosis, and widespread ulceration showing no sign of healing. Histologically, the cutaneous lesions were characteristic of lichen planus. The lichen planus-like lesions, in both instances, occurred in the chronic stages (90 and 102 days) of GVHR.

The mild, acute GVHR is characterized by a subtle, transient, macular erythema that easily might be regarded as a viral exanthem. On both practical and theoretical bases, the possible role of a viral exanthem in these immunosuppressed patients must be considered in the diagnostic evaluation.

Light Microscopy and Ultrastructural Studies

The results of our microscopical studies confirmed that the basic changes of exocytosis, discrete acantholysis, and SCN do occur in GVHR-complicated CIDS. These are the same changes Slavin and Woodruff[1] described in allogeneic transplantation. Finding these three pathologic changes in combination with the appropriate clinical presentation should lead to a diagnosis of GVHR.

There are a number of skin diseases which show histologic features similar to GVHR. Mucha-Habermann, erythema multiforme, lupus erythematosus, lichen planus, actinic keratosis, and kerato-acanthoma may all show individual cell dyskeratosis. Darier disease and pemphigus vulgaris demonstrate the combination of acantholysis and dyskeratosis. Histopathologically, these entities can be excluded from consideration because the specific finding of SCN is not present. Clinically, they are excluded because they occur in settings unrelated to GVHR-complicated transplantation or CIDS. SCN has been reported in patients with squamous cell carcinoma and malignant melanoma,[12] but neither of these conditions present differential diagnostic problems.

The "mummified" body we identify in SCN may be similar to the colloid body in lichen planus. However, the specific change of satellite lymphocytes in epidermal spaces in association with mummified cells we described, is not described by Touraine et al[15] and Saurat et al[28] in lichen planus-like eruptions and GVHR. Therefore, we believe that while lichen planus and GVHR have some histologic features in common, they can be differentiated on strict clinical and histologic grounds. It may well be, as Slavin and Santos[13] have suggested, that lichen planus and the epidermal lesion of GVHR are similar pathogenetically.

There is a good correlation between histopathologic findings and the observed cutaneous manifestations. The areas of extensive erythematous, macular rash present in the infant in the florid stage of GVHR, correspond to the areas of acantholysis, exocytosis, and SCN on biopsy. The parchment-like areas with noticeable bronzing that are present in chronic GVHR, appear to correlate with the areas of hyperkeratosis, epidermal atrophy, and dermal melanin deposition.

Our electron microscopical studies of GVHR confirm exocytosis, discrete acantholysis, and SCN as prominent findings. Previously published works with reference to ultrastructural findings of GVHR in man were written by Kruger et al[29] and Dobbeleer et al.[30] Kruger et al[29] demonstrated acantholysis as the only significant finding in the epidermis. They made no specific mention of SCN or individual cell necrosis of keratinocytes. Dobbeleer et al,[30] in their ultrastructural studies of GVHR following leukocyte transfusion in man with lymphosarcoma, noted discrete dyskeratotic cells and acantholysis. However, exocytosis was sparse in the case they reported, and they found no intimate relationship between lymphocytes and dyskeratotic cells comparable to SCN.

Two ultrastructural studies[12,31] have come from experimental work on GVHR in animals. Weiner et al[31] emphasized the occurrence of mononuclear cell exocytosis in rabbits, but phenomena specifically related to SCN were not mentioned. The results of ultrastructural studies of GVHR in nonhuman primates by Woodruff et al[12] showed findings, including SCN, that are virtually identical to our findings in human GVHR. These observations suggest that the lesions of GVHR in man and in nonhuman primates are comparable, and that the pathogenesis of GVHR in man and nonhuman primates may be similar.

The mechanism of cell death (ie, rejection) in GVHR in man is unknown. Host cell death may be due to direct interaction between host cell and aggressor lymphocyte,[1] to the intermediate involvement of host leukocytes (aggressor lymphocytes/host lymphocytes/host cell)[22,33] or to cytotoxic humoral factors.[30,34] Dobbeleer et al[30] emphasized that epidermal cell damage appears to occur independent of direct aggressor lymphocytic interaction with host cells. They postulated that the dyskeratotic bodies were due to toxic damage to the epidermis caused by "immunologic phenomenon complicating GVHR."[30] They felt that this theory is corroborated by the work of Merritt et al[34] who found IgM antibody that is cytotoxic (in vitro) for epithelial cells in the serum of patients with GVHR.

Contrary to findings of Dobbeleer et al,[30] our electron photomicrographs indicate that direct interaction between host cell and aggressor lymphocyte is a definite factor in the pathogenesis of GVHR. Furthermore, on study by direct immunofluorescence, the absence of IgM, IgG, C, and fibrinogen on the surface of keratinocytes seems to discount any primary pathogenic effect of cytotoxic antibody. While cytotoxic antibodies may be a factor in the pathogenesis of GVHR, our findings support the speculation made by Slavin and Woodruff[1] that the basic lesion of GVHR probably represents direct epithelial (host cell) interaction with aggressor lymphocytes. This suggests that cellular, delayed hypersensitivity is a major component of graft rejection.

The prominence and specificity of GVHR lesions, particularly SCN, refute the concept that distinctive lesions are rare or absent in GVHR-complicated CIDS. While emphasis has previously been on the nonepidermal features as essential in the diagnosis of GVHR, we emphasize the specificity of the epidermal findings, and strongly recommend that a cutaneous biopsy be performed, and an evaluation of the histopathological findings be made to facilitate an early definitive diagnosis.

Immunofluorescence studies were done by Denny L. Tuffanelli, MD.

Photographic work was done by Harry J. Roberts.

References

1. Slavin RE, Woodruff JM: The pathology of bone marrow transplantation. *Pathol Annu* 9:291-344, 1974.

2. Hathaway WE, Githens JH, Blackburn WR, et al: Aplastic anemia, histiocytosis and erythrodermia in immunologically deficient children: Probable human runt disease. *New Eng J Med* 273:953-958, 1965.

3. Rubinstein A, Radl J, Cottier H, et al: Unusual combined immunodeficiency syndrome exhibiting kappa-IgD paraproteinemia, residual gut immunity and graft-versus-host reaction after plasma infusion. *Acta Paediatr Scand* 62:365-372, 1973.

4. Kretschmer R, Jeannet M, Merceu TR, et al: Hereditary thymic dysplasia: A graft-versus-host reaction induced by bone marrow cells with a partial 4a series histoincompatibility. *Pediatr Res* 3:34-40, 1969.

5. Miller ME: Graft-vs-host reactions in man with special reference to thymic dysplasia. New York, National Foundation March of Dimes, 1968, vol 4, pp 257-269.

6. Gatti RA, Kersey JH, Yunis EJ, et al: Graft-versus-host disease, in Stefani M (ed): *Progress in Clinical Pathology*. New York, Grune & Stratton Inc, 1973, vol 5, pp 1-18.

7. Meuwissen HJ, Kersey J, Pabst H, et al: Graft-versus-host reactions in bone marrow transplantation. *Transplant Proc* 3:414-417, 1971.

8. Kadowaki J, Thompson RI, Zuelzer WW, et al: XX/XY lymphoid chimaerism in congenital immunological deficiency syndrome with thymic alymphoplasia. *Lancet* 2:1152-1158, 1965.

9. Morhenn VB, Maibach HI: Graft vs host reaction in a newborn. *Acta Derm Venereol* (Stockh) 54:133-136, 1974.

10. Chen TK, Clawson CC, Yunis EJ, et al: Thymic aplasia with possible graft-versus-host disease. *J Pediatr* 86:904-907, 1975.

11. Grogan TM, Broughton DD, Doyle WF: Graft-versus-host reaction. A case report suggestng GVHR occurred as a result of materno-fetal cell transfer. *Arch Pathol Lab Med* 99:330-334, 1975.

12. Woodruff JM, Butcher WI, Hellerstein LJ: Early secondary disease in the rhesus monkey: II. Electron microscopy of changes in mucous membranes and external epithelia as demonstrated in the tongue and lip. *Lab Invest* 27:85-98, 1972.

13. Slavin RE, Santos GW: The graft versus host reaction in man after bone marrow transplantation: Pathology, pathogenesis, clinical features, and implication. *Clin Immunol Immunopathol* 1:472-498, 1973.

14. Woodruff JM, Eltringham JR, Casey HW: Early secondary disease in the rhesus monkey: I. A comparative histopathologic study. *Lab Invest* 20:499-511, 1969.

15. Touraine R, Revuz J, Dreyfus B, et al: Graft versus host reaction and lichen planus. *Br J Dermatol* 92:589, 1975.

16. Rook A, Wilkinson DS, Ebling FJG (eds): *Textbook of Dermatology*, ed 2. Oxford, England, Blackwell Scientific Publications, 1969, pp 196-200, 1223-1229.

17. Jacobs JC, Miller ME: Fatal familial Leiner's disease: A deficiency of the opsonic activity of serum complement. *Pediatrics* 49:225-232, 1972.

18. Winkelmann RK: The skin in histiocytosis-X. *Mayo Clin Proc* 44:535-549, 1969.

19. Baer RL: Cutaneous aspects of drug toxicity. *Ann NY Acad Sci* 123:354-365, 1965.

20. Nicolis GD, Helwig EB: Exfoliative dermatitis: A clinicopathologic study of 135 cases. *Arch Dermatol* 108:788-797, 1973.

21. Peck GL, Herzig GP, Elias PM: Toxic epidermal necrolysis in a patient with graft-vs-host reaction. *Arch Dermatol* 105:561-569, 1972.

22. Balner H, De Vries J, van Bekkum DW: Secondary disease in rat radiation chimeras. *J Natl Canc Inst* 32:419-459, 1964.

23. Billingham RE, Streilein JW: Toxic epidermal necrolysis and homologenous disease in hamsters. *Arch Dermatol* 98:528-539, 1968.

24. Streilein JW: Graft-versus-host disease in hamsters: What is the target tissue? *Exp Hematol* 20:49-50, 1970.

25. Merritt CB, Darrow CC II, Vaal L, et al: Bone marrow transplantation on rhesus monkeys following irradiation. *Transplantation* 14:9-20, 1972.

26. Lyell A: A review of TEN in Britain. *Br J Dermatol* 79:662-671, 1967.

27. Radimer GF, Davis JH, Ackerman AB: Fumigant-induced toxic epidermal necrolysis. *Arch Dermatol* 110:103-104, 1974.

28. Saurat JH, Didier-Jean L, Gluckman E, et al: Graft versus host reaction and lichen planus-like eruption in man. *Br J Dermatol* 92:591-592, 1975.

29. Kruger GRF, Berard CW, Elias PM, et al: Morphology of graft-versus-host reaction in HL-A-matched bone marrow transplantation and its differential diagnosis. *Exp Hematol* 21:4-7, 1971.

30. Dobbeleer GD, Ledoux-Corbusier MH, Achten GA: Graft versus host reaction: An ultrastructural study. *Arch Dermatol* 111:1597-1602, 1975.

31. Wiener J, Spiro D, Russell PS: An electron microscopic study of the homograft reaction. *Am J Pathol* 44:319-347, 1964.

32. Streilein JW, Billingham RE: An analysis of graft-versus-host disease in Syrian hamsters: I. The epidermolytic syndrome—its description and procurement. *J Exp Med* 132:163-180, 1970.

33. Streilein JW, Billingham RE: An analysis of graft-versus-host disease in Syrian hamsters: II. The epidermolytic syndrome: Studies on its pathogenesis. *J Exp Med* 132:181-197, 1970.

34. Merritt C, Mann D, Rogentine G: Cytotoxic antibody for epithelial cells in human graft versus host disease. *Nature* 232:638-639, 1971.

Primary Cutaneous Phaeohyphomycosis Caused by *Drechslera spicifera*

Stephen A. Estes, MD; William G. Merz, PhD; Lynne G. Maxwell, MD

• A primary cutaneous lesion in a 5-year-old boy who had recently received chemotherapy for acute lymphocytic leukemia was found to be caused by a dematiaceous fungus, *Drechslera spicifera*. The lesion was an erythematous macule that rapidly developed necrotic ulcerations. The fungus, which is commonly found in soil and as a plant pathogen, was isolated from cultures of the lesion and from an excisional biopsy specimen. Hyphae and swollen hyphal cells resembling chlamydospores were observed in the biopsy specimen. Septate pigmented hyphae were found in the tissue, which is consistent with phaeohyphomycosis. Resolution of the infection occurred following excisional biopsy and systemic amphotericin B therapy. There was a concomitant recovery from neutropenia.

(*Arch Dermatol* 113:813-815, 1977)

Opportunistic fungus infections in the immunocompromised host present a challenge to accurate diagnosis and treatment. Numerous reports substantiate the significant morbidity and mortality of such infections, and new organisms have recently been recognized as opportunistic pathogens.[1-3] Cutaneous manifestations have been reported with *Cryptococcus*,[4] *Aspergillus*,[5,6] *Candida*,[7] and *Mucor*[8,9] infections.

Members of the genus *Drechslera* are common soil saprophyte and plant pathogens known to occasionally cause cutaneous and subcutaneous lesions in dogs, cats, and horses.[10-12] These infections have been called maduromycotic mycetomas because masses of septate hyphae and chlamydospores were present in drainage and tissue from infected sites. Whether such infections possess true granules and can be termed mycetomas is disputed.[10] More recently, Ajello et al[13] proposed the term "phaeohyphomycosis" for subcutaneous and systemic infections characterized by dematiaceous septate mycelial elements in the tissue. *Drechslera* was not known to cause human disease until 1973, when a fatal case of a fungal meningoencephalitis caused by *Drechslera hawaiiensis* was recognized at postmortem examination in a 31-year-old woman with an unsuspected lymphocytic lymphosarcoma.[14] This report describes a primary cutaneous infection caused by a member of the genus *Drechslera*, and the first human infection, to our knowledge, caused by *Drechslera spicifera*.

REPORT OF A CASE

The patient was a 5-year-old boy with acute lymphoblastic leukemia first diagnosed in December 1973. He was admitted to the Children's Medical and Surgical Center of Johns Hopkins Hospital in relapse for the second time in August 1975 for chemotherapy with asparaginase and daunorubicin.

On the fifth day of chemotherapy his absolute neutrophil count dropped below 500/cu mm. On day 11 he developed a fever that was unresponsive to broad-spectrum antibiotics, and bacterial cultures were negative. On day 16, an erythematous 12 × 15-mm macule on the extensor surface of the left forearm was noted in an area that had been abraded by adhesive tape securing an intravenous catheter. By the next day (day 17) there were three pinpoint necrotic ulcerations on the surface of the lesion. Swabs of this lesion were sent for bacterial and fungal culture. Over the next 24 hours these necrotic areas rapidly expanded to 4 mm in diameter. Two days after this lesion was noted, a complete excisional biopsy was done (Fig 1). Frozen-section and touch preparation of the biopsy specimen revealed septate hyphae with acute angle branching, believed to be morphologically consistent with members of the genus *Aspergillus*. Cultures of both the surface swab and biopsy specimens grew an organism identified as *Drechslera* sp. No bacteria or viruses were recovered from the swabs or biopsy specimens. Amphotericin B therapy was begun on day 18, at a dosage of 1 mg/kg every other day for eight days. The total dose of amphotericin B was 45.8 mg; 100 units of sodium heparin and 50 mg of hydrocortisone were added to each 500 ml of intravenous fluid that was administered over a six-hour period. The decision to stop the amphotericin B was made when the patient's neutrophil count had increased to 1,012/cu mm concomitant with a well-healed biopsy site and no evidence of dissemination. No other cutaneous lesions appeared during the entire hospitalization.

Histopathologic Findings

The biopsy specimen was fixed in 10% neutral formaldehyde. Sections of the tissue were stained with hematoxylin-eosin, PAS, and the Grocott modification of the Gomori methenamine silver nitrate stain. Microscopic examination of the hematoxylin-eosin-stained sections demonstrated focal ulceration of the epidermis and necrotic areas within the papillary and mid-dermis (Fig 2). A lymphocytic and histiocytic reaction surrounded numerous small groups of irregular septate hyphae and enlarged mycelial elements (Fig 3). These microabscesses were present in the papillary and reticular dermis. Occasional neutrophils and foreign-body giant cells were also present in the microabscesses. No invasion of blood vessels or subcutaneous

Accepted for publication May 25, 1976.

From the Subdepartment of Dermatology (Drs Estes and Merz), Department of Laboratory Medicine (Pathology) (Dr Merz), and the Department of Pediatrics (Dr Maxwell), Johns Hopkins Medical Institutions, Baltimore.

Reprint requests to Department of Laboratory Medicine, Johns Hopkins Hospital, 601 N Broadway, Baltimore, MD 21205 (Dr Merz).

Fig 1.—Erythematous lesion with necrotic central areas prior to excisional biopsy.

Fig 2.—Focal ulceration and necrosis with microabscesses (hematoxylin-eosin, original magnification ×16).

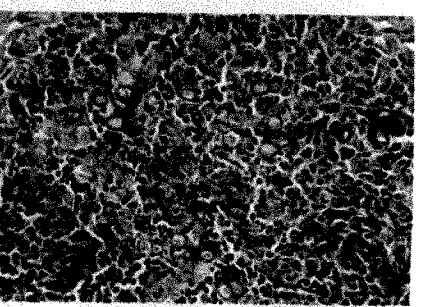

Fig 3.—Lymphocytic and histiocytic reaction surrounding fungal elements (hematoxylin-eosin, original magnification ×64).

tissue was noted.

PAS- and methenamine silver-stained sections showed septate hyphae (2.5 to 4.4 μ outside diameter) with acute branching and large swollen hyphal cells (5 to 31 μ outside diameter) resembling chlamydospores (Fig 4). One hyphal element was found within a foreign-body giant cell. An extensive review of unstained sections disclosed occasional golden-brown hyphae.

Mycological Findings

A pigmented organism grew out on Sabouraud dextrose agar after four days' incubation at 23 C from swabbings of the lesion taken on day 17. The fungus was identified as belonging to the *Helminthosporium-Drechslera* group and was considered a probable contaminant. Separate specimens of the skin biopsy were submitted to mycology, virology, and bacteriology laboratories. All three portions of the specimen also grew out a pigmented organism within five days. No other organisms were recovered from these specimens in any laboratory. During the time of the appearance of the cutaneous lesion, three blood specimens, an intravenous vascular catheter tip, and a bone marrow specimen were all negative for fungi.

The four isolates were studied further for a positive identification. Growth on Sabouraud dextrose agar at 23 C was rapid. The colony was approximately 6 cm in diameter after three days' incubation. The colony was fluffy, with a white border and dark gray center (Fig 5). On reverse, the colony was originally colorless and turned dark brown within seven days. Growth on brain-heart infusion agar at 37 C was slower than at 23 C; however, the colony morphology was similar in color but less fluffy than on Sabouraud dextrose agar at 23 C. No growth was noted on Sabouraud dextrose agar with chloramphenicol and cycloheximide at 23 C.

Examination of slide cultures prepared on corn meal-dextrose agar and incubated at 23 C for five days showed abundant production of pigmented, thick-walled conidia with four cells produced on unbranched pigmented conidiophores (Fig 6). The conidia measured an average of 25 μ in length and 9 μ in width. Up to four conidia were produced sympodially on each conidiophore. The conidiophores ranged from 13 to more than 100 μ in length, with an average outside diameter of 4.4 μ. These conidiophores gave the impression of producing a conidium, then growing around the spore, and producing another. The fungus was therefore identified as *Drechslera* sp, later specified as *Drechslera spicifera*, the imperfect state of the ascomycete *Cochliobolus spicifer*. Sensitivity testing determined that the organism was sensitive to flucytosine with a minimal inhibitory concentration of 0.78 μg/ml and a minimal fungicidal concentration of 6.2 μg/ml. Both inhibitory and fungicidal concentrations for amphotericin B were less than 0.05 μg/ml.

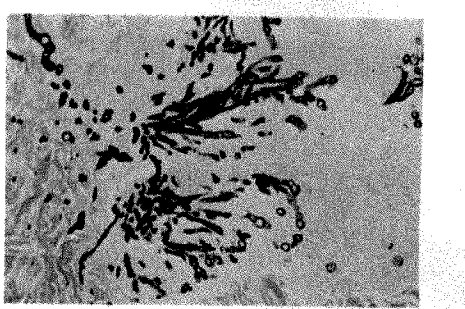

Fig 4.—Septate hyphae and large swollen hyphal cells (methenamine silver, original magnification ×64).

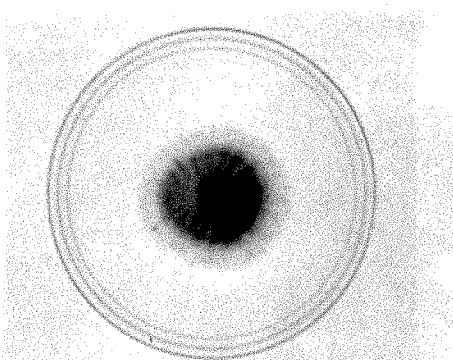

Fig 5.—Colony of *Drechslera spicifera* after three days' incubation on Sabouraud dextrose agar.

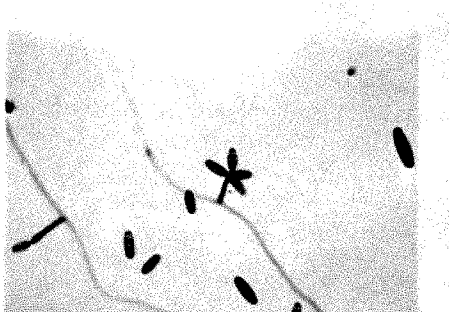

Fig 6.—Slide culture on corn mealdextrose agar after five days, showing conidia and conidiophores of *Drechslera spicifera* (original magnification ×10).

COMMENT

This case clearly illustrates the increasing variety of fungi that are capable of being opportunistic pathogens. Dematiaceous fungi have long been known to cause chronic subcutaneous infections. Ajello et al[13] have proposed that infections characterized by pigmented septate hyphae in tissue be designated as phaeohyphomycosis. In contrast, the fungi in mycotic mycetomas and chromomycosis are organized into discrete granules or sclerotic cells. *Drechslera spicifera* is a soil-, air-, and plant-borne organism known to cause subcutaneous phaeohyphomycosis in animals, presenting as chronic nodular granulomatous dermatitis.[10] However, this human case demonstrated a rapidly progressing necrotic cutaneous lesion with septate pigmented hyphae consistent with phaeohyphomycosis. Many other un-

suspecting fungi may be capable of producing similar infections in immunocompromised patients, and no fungi that are isolated may simply be ignored. Clinical and pathological investigations may be needed to resolve the clinical significance of any fungus isolated.

This case represents, to our knowledge, the first human cutaneous infection by *Drechslera spicifera* and the second time a member of this genus has been identified as a pathogen in humans. Fuste et al[14] reported a fatal case of meningoencephalitis caused by *Drechslera hawaiiensis* in a 31-year-old woman with an unsuspected lymphocytic lymphosarcoma. Similar histological findings have been reported in lung tissue taken from two patients without a detectable underlying neoplasm with bronchiectasis, chronic pneumonia, and, in one, multiple abscesses.[15] *Helminthosporium* was suggested as the pathogen in these cases, but definitive mycological identification was not done.

A number of factors probably contributed to this infection. The patient in the present case report was an immunocompromised host. He had a neoplastic process, was leukopenic, and had recently received cytotoxic therapy as well as broad-spectrum antibiotics. There was also a history of trauma from tape, which locally compromised his cutaneous barrier.

Opportunistic fungal infections such as in this case represent a real threat to the immunocompromised host. The morphology of the cutaneous lesion in this case was not distinctive. A rapidly spreading necrotic lesion in such hosts always raises the possibility of bacterial infection such as *Pseudomonas* as well as opportunistic fungal invaders such as *Aspergillus*. Indeed, we have recently observed cutaneous *Aspergillus* lesions in immunocompromised patients that looked remarkably similar to the lesion in this case.[16] These lesions provide the clinician a site in which an aggressive diagnostic approach can and must be initiated. Unlike fevers or pulmonary infiltrates in these patients, the cutaneous lesions allow rapid tissue diagnosis of a mycotic etiopathology. A biopsy of these lesions at their first appearance with frozen sections, touch preparation, and specimens for special mycological investigations is essential for diagnosis.

The diagnosis of phaeohyphomycosis rests on the observation of pigmented septate hyphae in tissue. The pigmented nature of the hyphae in this case was not obvious. An extensive review of unstained sections disclosed an occasional golden-brown hyphae. Muller et al[10] noted a similar sparsity of pigmented hyphae in their case of *Drechslera spicifera* in a cat.

No clinical, radiological, or cultural evidence of dissemination was found in this patient. During the time of the appearance of this cutaneous lesion, three blood specimens, an intravenous catheter tip, and a bone marrow specimen were all negative for fungi.

The successful resolution of this infection can probably be attributed to the early aggressive therapeutic approaches instituted. The initial excisional biopsy possibly removed all infected tissue. It was done with this intent and the entire lesion was excised. The amphotericin B therapy may have eradicated what organisms were left behind or had disseminated; it is speculative as to whether this was really of benefit or not. An alternative is that the patient's own immune status handled whatever organisms that remained, although it should be remembered that this lesion was growing rapidly prior to any therapy.

Cutaneous lesions caused by opportunistic fungi may be the primary site of infection that can lead to fatal disseminated disease rather than a secondary manifestation of disseminated infection. An aggressive diagnostic and therapeutic approach is strongly advocated in such instances.

M. B. Ellis, PhD, Commonwealth Mycological Institute, Kew, Surrey, England, identified the fungus as *Drechslera spicifera*. Smith Shadomy, PhD, Virginia Medical College, Richmond, did the sensitivity testing. George W. Hambrick, Jr, MD, and Patricia Charache, MD, critically reviewed this manuscript. Mary Zorn and June Lam gave secretarial assistance.

Westwood Pharmaceuticals, Inc, Buffalo, NY, financed the cost of the color reproductions.

Nonproprietary Names and Trademarks of Drugs

Amphotericin B—*Fungizone.*
Asparaginase—*Crasnitin.*

References

1. Hutter RVP, Collins HS: The occurrence of opportunistic fungus infections in a cancer hospital. *Lab Invest* 11:1035-1045, 1962.
2. Bodey GP: Fungal infections complicating acute leukemia. *J Chron Dis* 19:667-687, 1966.
3. Rifkind D, Marchioro TL, Schneck SA, et al: Systemic fungal infections complicating renal transplantation and immunosuppressive therapy. *Am J Med* 43:28-38, 1967.
4. Noble RC, Fajardo LF: Primary cutaneous cryptococcosis: a review and morphologic study. *Am J Clin Pathol* 57:13-22, 1972.
5. Cahill KM, Elmofty AM, Kawaguchi TP: Primary cutaneous aspergillosis. *Arch Dermatol* 96:545-547, 1967.
6. Findlay GH, Roux HF, Simson IW: Skin manifestations in disseminated aspergillosis. *Br J Dermatol* 85(suppl 7):94-97, 1971.
7. Balawdran L, Rothschild H, Pugh N, et al: A cutaneous manifestation of systemic candidiasis. *Ann Intern Med* 78:400-403, 1973.
8. Meyer RD, Kaplan MH, Ong M, et al: Cutaneous lesions in disseminated mucormycosis. *JAMA* 225:737-738, 1973.
9. Baker, RD, Seabury JH, Schneidau JD: Subcutaneous and cutaneous mucormycosis and subcutaneous phyomyocsis. *Lab Invest* 11:1091-1102, 1962.
10. Muller GH, Kaplan W, Ajello L, et al: Phaehyphomycosis caused by *Drechslera spicifera* in a cat. *J Am Vet Med Assoc* 166:150-154, 1975.
11. Schauffer AF: Maduromycotic mycetoma in an aged mare. *J Am Vet Med Assoc* 160:998-1000, 1972.
12. Bridges CH, Beasley JN: Maduromycotic mycetomas. *J Am Vet Med Assoc* 137:192-201, 1960.
13. Ajello L, Georg K, Steigbigel RT, et al: A case of phaeohyphomycosis caused by a new species of *Phialophora*. *Mycologia* 66:490-498, 1974.
14. Fuste FJ, Ajello L, Threlkeld R, et al: *Drechslera hawaiiensis:* Causative agent of a fatal fungal meningoencephalitis. *Sabouraudia* 11:59-63, 1973.
15. Dolan CT, Weed LA, Dines DE: Bronchopulmonary helminthosporiosis: *Am J Clin Pathol* 53:235-242, 1970.
16. Prystowsky SD, Vogelstein B, Ettinger DS, et al: Invasive aspergillosis. *N Engl J Med* 295:655-658, 1976.

Generalized Acute Mucocutaneous Herpes Simplex Type 2 With Fatal Outcome

Louis Lopyan, MD; Alexander W. Young, Jr, MD; Marilyn Menegus, PhD

• To our knowledge, we present the first culturally documented case of generalized acute mucocutaneous herpes simplex type 2 in an immunosuppressed adult who died during the course of the disease. The picture of the clinical spectrum of herpetic disease in immunosuppressed patients is detailed, and the need for typing the virus, particularly in the disseminated form, and for clarifying possible differences in epidemiology, clinical expression, and prognosis is emphasized.

(*Arch Dermatol* 113:816-818, 1977)

In 1974, Sutton et al[1] presented the first culturally documented and typed adult case of generalized acute mucocutaneous herpes simplex (HS) type 2 that occurred in a patient with thymic dysplasia. A review of the literature disclosed four other cases[2-5] that were proved culturally but were untyped, occurring in immunosuppressed adults without history of preexisting skin disease. The patient presented herein, who was receiving immunosuppressant drugs, is the first such culturally documented and typed case that, to our knowledge, has been reported.

REPORT OF A CASE

A 21-year-old woman with chronic glomerulonephritis was seen in the emergency room prior to hospitalization on April 9, 1973, complaining of fever, general malaise, and skin eruption of three weeks' duration. At this time, she appeared acutely ill and had a generalized, single and grouped, vesiculopustular, necrotic eruption of the glabrous skin and mucous membranes of the mouth, and an erosive, secondarily infected vulvitis and exudative vaginitis. Temperature was 39.1 C (Fig 1 through 3).

Medical history disclosed the first hospital admission to be in September 1971, when a diagnosis of stage 4 membranous glomerulonephritis on renal biopsy was made. Treatment with 10 mg of prednisone daily, 100 mg of azathioprine (Imuran) daily, and 400,000 units of penicillin three times a day was prescribed. On this regimen, the patient had remained well for two years, until the onset of her infection. The patient denied any past history of fever blisters or oral or vaginal lesions.

History of the illness indicated the onset of fever, shaking chills, myalgias, and skin disorder involving the vulva and buccal areas three weeks prior to admission. The eruption with fever (temperature rose on one occasion to 40.5 C) continued to develop and spread until the time of hospital admission. Dysuria and an erosive, necrotic vulvitis were prominent features throughout.

On hospital admission, results of urinalysis were the following: specific gravity, 1.009; protein, 2 +; WBC, 5 to 10/high-power field; RBC, 10 to 25/high-power field. Hemogram showed a hemoglobin level of 11.6 gm/100 ml, a hematocrit value of 34%, and a WBC count of 2,100/cu mm, with a normal differential cell count. Serum electrolyte determinations were normal, except for the following values: serum potassium, 5.5 mEq/liter; serum

Fig 1.—Bullae on erythematous base and necrotic erosions (from face).

Fig 2.—Close-up view of typical lesions of bullae and necrotizing ulcers (from thigh).

Accepted for publication May 19, 1976.

From the Dermatology Service, St Luke's Hospital Center, New York.

Reprint requests to Dermatology Service, St Luke's Hospital Center, Amsterdam Ave at 114th St, New York, NY 10025 (Dr Young).

glucose, 133 mg/100 ml; serum bilirubin, 136 mg/100 ml; serum creatinine, 13 mg/100 ml; serum calcium, 6.5 mg/100 ml; serum phosphorus, 6.8 mg/100 ml; serum cholesterol, 138 mg/100 ml; serum total protein, 4.5 gm/100 ml; serum albumin, 1.2 gm/100 ml; SGOT, 39 units lactic dehydrogenase, 570 units; serum alkaline phosphatase, 152 units. The chest roentgenogram and ECG were normal, except for sinus tachycardia.

Fig 3.—Edema and diffuse erosion of labia minora and multiple erosions extending to perianal region covered by prurulent exudate (from vulva).

A Tzank smear of a cutaneous lesion showed multinucleated giant cells with ballooning degeneration of the nuclei. A biopsy specimen of an intact vesicle showed intraepidermic acantholytic cells with ballooning degenerated and giant cells at the base and within the bulla cavity (Fig 4 and 5). Culture of fluid from an intact vesicle on the arm and the base of a vulvar erosion both grew HS virus, type 2.

Culture and typing of the virus was done in the following manner. Specimens for viral culture were obtained by vigorously rubbing a sterile cotton applicator over the lesion and then placing it in 2 ml of transport media (TM), minimum essential medium (MEM), with Earle salts containing 10 μg of amphotericin B, 100 μg of gentamicin sulfate, and 1,000 units of penicillin per milliliter (pH 7). Specimens were immediately transported to the laboratory where confluent monolayers of human embryonic kidney cells (HEK) and WI-38 cells in roller tubes were inoculated with 0.2 ml each of specimen. Before use, all cells were fluid changed to fresh maintenance medium consisting of MEM with Earle salts supplemented with 5% fetal calf serum and with 5 μg amphotericin B and 50 μg gentamicin sulfate added. All tubes were incubated at 2.2 C and were observed daily for evidence of viral cytopathic effect (CPE). Within 24 hours of inoculation, all HEK and WI-38 (human embryonic lung) cells inoculated with the vulvar lesion specimen showed focal CPE characteristic of HS virus type 2. Confirmation of viral type was performed by immunofluorescence study.

Initial therapy included cephalothin sodium (Keflin) (1 gm every six hours, intravenous), prednisone (10 mg daily), diphenhydramine hydrochloride (Benadryl) (25 mg four times daily), low potassium diet and potassium permanganate baths (1:9000

Fig 4.—Intact bulla taken from abdomen shows viral balloon giant cells admixed with inflammatory cells within bulla cavity (from abdomen) (hematoxylin-eosin, original magnification ×150).

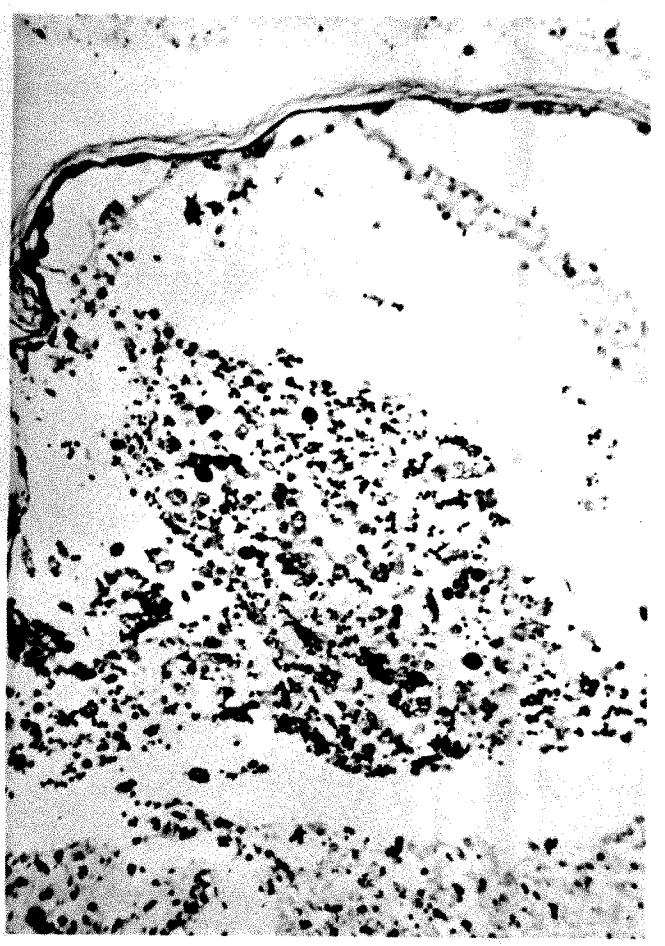

Fig 5.—High-power view of Fig 4 demonstrates multiple viral giant cells manifesting ballooning degeneration of nuclei (hematoxylin-eosin, original magnification ×450).

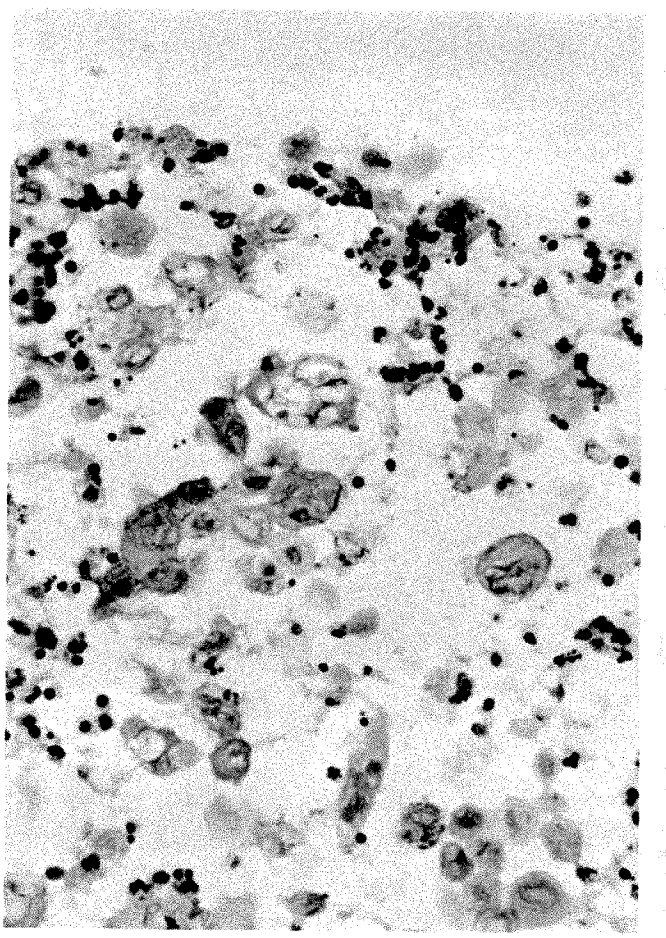

three times daily), and reverse isolation precautions.

The patient's condition remained stable until the third day of hospitalization, when she went into shock and sustained fatal cardiorespiratory arrest. Urine and blood cultures grew *Escherichia coli*.

Results of autopsy showed petechiae in the lungs, liver, adrenals, and kidneys; bilateral pleural effusions; a blood clot and hemorrhagic fluid in the peritoneal cavity; large, granular kidneys; and hemorrhages in the esophagus and stomach. Viral cultures of the lungs and kidneys were positive for cytomegalovirus (CMV); cultures of the spleen and adrenal gland were negative. Inclusion bodies consistent with CMV infection were seen in the lungs, kidneys, liver, pancreas, bone marrow, lymph nodes, and submucosal esophageal glands.

COMMENT

Certainly *E coli* sepsis as a preterminal event played a major role in the patient's death. The role of CMV in this patient is uncertain. Cytomegalovirus has been isolated from many immunosuppressed patients, but to our knowledge, its pathogenetic role has not been determined. Studies performed on patients undergoing renal transplants indicate that CMV may cause further immunosuppression[6] and may be a potential cause of injury to the lungs and liver.[7]

Nor has the exact pathogenetic role of HS virus been determined. However, review of the literature shows that more than 50% of the cases of generalized acute mucocutaneous HS virus have a fatal outcome. Whatever the exact pathogenetic role of the HS virus, this disease entity represents a grave prognostic sign.

The clinical disease and fatal outcome in this patient are remarkably similar to the case of thymic dysplasia presented by Sutton et al.[1] Both had an immunologic defect; both had generalized skin lesions including scalp and face and oral and vulvar disease caused by HS type 2 infection. In the latter, prednisone and azathioprine therapy for renal disease was associated with leukopenia (2,100/cu mm) predisposing to infection.

Cases of culturally documented but untyped disseminated HS have been reported. Those of Montgomerie et al (case 1)[2] and Lynfield et al[3] had a fatal termination; those of Rendtorf and Fowinkel[4] and Strom[5] were nonfatal. Although it is impossible to determine which type of HS was involved in these patients, those of Rendtorf and Fowinkel,[4] Lynfield et al,[3] and Strom,[5] which began in the genital area, clinically strongly suggest type 2 infection, whereas Montgomerie et al's case,[2] originating on the face, suggests type 1. Typing is recommended in future cases to identify possible differences in clinical expression and prognosis between HS, types 1 and 2.

The clinical spectrum of HS infection that develops in patients with immune deficiency varies. There have been numerous reports in the literature of localized ulcerations of the skin in immunosuppressed patients due to HS virus.[8-10] In 1971, Logan et al[9] described three cases of localized necrotizing herpetic ulcers in immunosuppressed patients, which he termed chronic cutaneous herpes.

At the other extreme is acute generalized mucocutaneous HS, as seen in our case and those of Montgomerie et al (case 1),[2] Lynfield et al,[3] Rendtorf and Fowinkel,[4] and Sutton et al.[1] These patients have a generalized skin and mucous membrane involvement that may extend to the viscera, an acute febrile course, and often, fatal outcome.

Within these limits is a clinical variety of HS infection that results from contiguous extension of the localized chronic cutaneous type. The lesions are usually long lasting and necrotic with regional spread. Montgomerie et al (cases 2 through 4)[2] and Muller et al(case 9)[10] have each presented examples of this picture. In the case herein, it is apparent that HS originated in the vulva and extended locally over a three-week period, prior to dissemination and fatal outcome. This course suggests that chronic cutaneous HS with regional spread has a potential to become generalized. For this clinical picture, the term regional chronic cutaneous HS is suggested.

This continuous spectrum of the clinical manifestation of HS infection in immunosuppressed patients is as follows: (1) localized form: ranging from localized recurrent HS with spontaneous healing (as seen in normal persons) to localized chronic cutaneous HS; (2) disseminated form: ranging from regional chronic cutaneous HS to generalized acute mucocutaneous HS (with or without visceral involvement).

Confirmation of viral type by immunofluorescence study was performed by Andre Nahmias, MD, at Emory University, Atlanta.

Nonproprietary Names and Trademarks of Drugs

Amphotericin B–*Fungizone*.
Azathioprine–*Imuran*.
Cephalothin sodium–*Keflin*.
Gentamicin sulfate–*Garamycin*.

References

1. Sutton AL, Smithwick EM, Seligman SJ, et al: Fatal disseminated herpesvirus hominis type II infection in an adult with associated thymic dysplasia. *Am J Med* 56:545-553, 1974.
2. Montgomerie JZ, Becroft DMO, Croxson MC, et al: Herpes-simplex-virus infection after renal transplantation. *Lancet* 2:867-871, 1969.
3. Lynfield YL, Farhangi M, Runnels JL: Generalized herpes simplex complicating lymphoma. *JAMA* 207:944-946, 1969.
4. Rendtorf CF, Fowinkel EW: Herpes simplex skin lesions simulating smallpox. *JAMA* 192:998-1000, 1965.
5. Strom J: Herpes simplex virus as a cause of allergic mucocutaneous reactions (ectodermosis erosiva pluriorificialis, Stevens-Johnson's syndrome, etc.) and generalized infection. *Scand J Infect Dis* 1:3-10, 1969.
6. Simmons RL, Lopez C, Balfour H, et al: Cytomegalovirus: Clinical virological correlations in renal transplant recipients. *Ann Surg* 180:623-634, 1974.
7. Millard PR, Herbertson BM, Nagington J, et al: The morphological consequences and the significance of cytomegalovirus infection in renal transplant patients. *Q J Med* 42:585-596, 1973.
8. Park RK, Goltz RW, Carey TB: Unusual cutaneous infections associated with immunosuppressive therapy. *Arch Dermatol* 95:345-350, 1967.
9. Logan WS, Tindall JP, Elson ML: Chronic cutaneous herpes simplex. *Arch Dermatol* 103:606-614, 1971.
10. Muller SA, Herrmann EC Jr, Wintelmann RK: Herpes simplex infections in hematologic malignancies. *Am J Med* 52:102-114, 1972.

Erythema Elevatum Diutinum

Response to Dapsone

Lt Col Samuel L. Fort, MC, USA, Lt Col Orlando G. Rodman, MC, USA

• A patient with a 20-year history is presented as a classic example of erythema elevatum diutinum, with a dramatic response to dapsone therapy, and with interesting features of improvement during pregnancies and occurrence of giant cell tumors of soft tissue, neither of these latter features having been previously reported.

***(Arch Dermatol* 113:819-822, 1977)**

Erythema elevatum diutinum (EED) is a rare, chronic inflammatory dermatosis characterized clinically by the symmetrical occurrence of persistent red elevated lesions with a predilection for the skin over the extensor articular surfaces. Frequently, arthralgia and constitutional symptoms are present, but the patient's general health is unaffected. The etiology is unknown, but the dermatopathologic process is clearly a leukocytoclastic angiitis, with some of the older lesions appearing to undergo fibroproliferative transformation. Treatment with any number of modalities has been notably unsuccessful.[1-3]

REPORT OF A CASE

In January 1974, a 29-year-old white woman came to the Walter Reed Army Medical Center Dermatology Service with complaints of 19 years' duration. At the age of 10 years, the patient had a febrile illness with pain and swelling of the knee joints. Rheumatic fever was diagnosed, and she spent six to eight weeks in bed. Several months later, she was thought to have had a relapse, and it was approximately at this time that she began to develop lesions on her hands, fingers, and elbows. Since that time she has had episodic malaise, weakness, polyarthralgia, and the appearance of asymptomatic erythematous lesions over the extensor surfaces of the finger joints, elbows, knees, and to a lesser extent over the forearms, some of the lesions persisting indefinitely and others resolving spontaneously. Her main complaint has been with the joint pain and malaise, beside which the asymptomatic cutaneous lesions have been insignificant. Aspirin has given some minimal relief of the arthralgia but otherwise has had no effect on the condition. She has seen numerous physicians with no firm diagnosis and no effective treatment; however, she has noted dramatic relief of all symptoms during each of her three pregnancies. Her general health has been excellent. In 1969, she consulted an orthopedic surgeon because of an asymptomatic nodule on the right index finger. The nodule had grown slowly over the previous year. It was excised, and the tissue diagnosis was giant cell tumor. In 1971, an identical lesion appeared on the distal phalanx of the right fifth finger and continued to slowly enlarge.

On physical examination positive findings were confined to the skin. Red infiltrated papules, nodules, and plaques were prominent over the dorsa of the hands, particularly over the metacarpophalangeal and interphalangeal joints (Fig 1). These were also present over the extensor surfaces of the knees and elbows, and a few firm yellowish lesions were present on the volar surface of the right forearm. Some of the red lesions blanched with pressure, and others did not. There was a 1 × 1 cm firm, smooth, shiny nodule over the dorsolateral aspect of the right fifth distal interphalangeal joint (Fig 2).

Laboratory determinations were all normal with the exception of a slightly elevated sedimentation rate on one occasion. These determinations included CBC and differential cell count, automated blood chemical analysis, urinalysis, serum triglycerides, cholesterol, throat culture, urine culture, VDRL test for syphilis, rheumatoid factor, fluorescent antibody, lupus erythematosus preparation, serum protein electrophoresis, and quantitative immunoglobulin determination.

Four biopsies were done at our clinic and reviewed by the Skin and Gastrointestinal Branch of the Armed Forces Institute of Pathology, all showing essentially identical pictures (Fig 3 and 4): leukocytoclastic angiitis with marked dermal infiltration with neutrophils and their fragments. Lesser numbers of lymphocytes, histiocytes, plasma cells, and eosinophils were seen. Hemorrhage was not seen. A few vessels showed fibrinoid degeneration of their walls (Fig 4). The epidermis was not involved, and an upper dermal grenz zone of uninvolved dermis was present. Excision of the right fifth finger nodule revealed it to be a giant cell tumor of tendon sheath, showing an incompletely encapsulated tumor composed of closely packed round and polyhedral basophilic-staining cells with large pale oval nuclei, foamy histiocytes, and multinucleated giant cells. Dense bands of hyalinized stroma extended from the capsule throughout the tumor (Fig 5).

In May 1974, a regimen of dapsone, 100 mg three times daily, was begun. Within one week, the patient experienced dramatic relief of her arthritic and malaise symptoms and some of the cutaneous lesions cleared entirely. Over the ensuing months, the dapsone dosage was decreased stepwise to her present dosage of 50 mg daily. She has been virtually asymptomatic since dapsone therapy was begun, the skin lesions diminishing in substance and new ones seldom occurring. An attempt at discontinuation of the dapsone resulted in relapse symptoms of arthralgia and malaise within 24 hours.

COMMENT

In 1894, Radcliffe-Crocker and Williams[4] coined the name "Erythema Elevatum Diutinum" for a condition first described by Hutchinson in

Accepted for publication April 9, 1976.

From the Dermatology Service, William Beaumont Army Medical Center, El Paso, Tex.

Reprint requests to Dermatology Service, William Beaumont Army Medical Center, El Paso, TX 79920 (Lt Col Fort).

Fig 1.—Erythematous elevated lesions, symmetrical, over metacarpophalangeal and interphalangeal joints.

Fig 2.—Giant cell tumor of soft tissue.

1878,[5,6] and by Bury in 1889.[7] For a long time, there was confusion between EED and granuloma annulare, but by the late 1920s the precise histopathology of EED, as well as of granuloma annulare, had been established, and the two were clearly separate entities.[1,8,9] Confusion lingered as to a Hutchinson type and a Bury type of EED, but this distinction is no longer considered valid.[1,2,10] Another confusing issue was introduced in the 1930s with reports of a seemingly new entity called extracellular cholesterolosis.[11,12] This is now considered to be a variant of EED[2,13] not deserving of separate nosologic status.

Erythema elevatum diutinum is a chronic disease, waxing and waning in severity. It is thought to eventually involute spontaneously, usually after five to ten years.[1] Our patient has had EED for 20 years. The longest case recorded in the literature is 25 years.[14] Neither sex predominates.[1,15,16] Most cases begin in middle age but the age at onset may vary from 6 months[17] to 75 years.[3] There is no familial tendency, although one instance of occurrence in mother and daughter has been reported.[17] Almost all reported patients have been white, but two were oriental.[10,18] One poorly documented case in a black has been reported.[19]

General health and longevity are unaffected, with no known systemic component other than constitutional.[3,15,16] The major pathological events are presumed to be confined to the skin. However, constitutional symptomatology is common, can be severe, and indeed can be the patient's chief complaint as was the case with our patient. Arthralgia in particular is to be emphasized.[1,9,16,17] Fever might occur but usually does not. There is no particular association of EED with any other disease.[3,15]

The skin lesions are red (erythema), raised (elevatum), and persistent (diutinum). Most of them are of a red, purplish or brownish color but some are strikingly xanthochromic. They may occur as papules, nodules, or plaques up to 6 cm in width.[1] Coalescence of lesions may produce irregular, arcuate or gyrate forms.[1,16] Vesicular or bullous lesions may occur.[2,10,15] Early lesions are soft to firm but older lesions may be quite hard, reflecting a fibrosing tendency as lesions age.[15,20] Although the lesions are characteristically persistent, the life history of any lesion is variable and unpredictable. It might arise and persist indefinitely, it might resolve completely, never to return, or it might recur in the same location. Once a lesion has resolved, residual hyperpigmentation is common, and slight atrophy may occur.[1,3]

The acral distribution with almost invariable truncal sparing is highly characteristic. Classically, the lesions are symmetrically distributed over the extensor surfaces of the finger joints, elbows, and knees. Other commonly involved sites are the buttocks, lower legs, and pinnae of the ears.[1-3] Lesions of EED are usually asymptomatic, but pruritus or pain may occur in an occasional case.[1-3,15]

The pathological process observed is that of a strikingly prominent leukocytoclastic angiitis,[1-3,9,20] with neutrophils and their fragments present not only in the walls of the small vessels of the dermis and their immediate perivascular area, but also diffusely infiltrating the dermis, distant from as well as near to the vessels.[1-3] The infiltrate is polymorphous, with lymphocytes, histiocytes, plasma cells, and eosinophils, but the overwhelming majority are neutrophils.[3,9] In some but not all biopsy specimens of EED, an eosinophilic hyaline material is noted within and around the vessel walls.[1,3,9,20] The term "toxic hyaline" was used by Weidman and Besancon to denote this material when they definitively established the histopathological features of EED in 1929.[9] There is no justification for the continued use of this special appellation, however, as the picture is essentially identical to that of fibrinoid

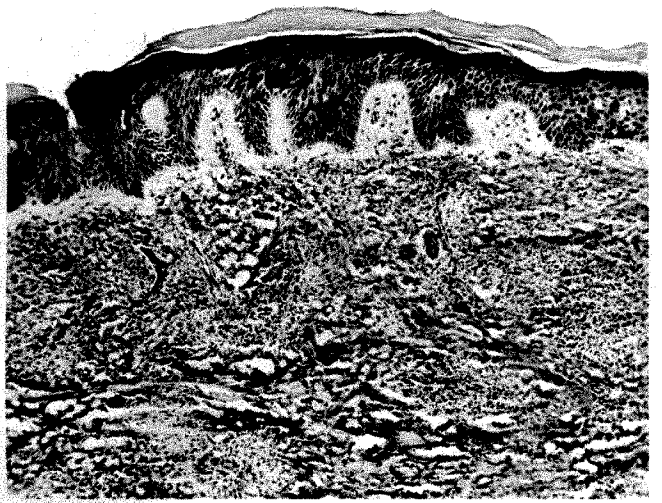

Fig 3.—Extensive necrotizing inflammation of dermis, with prominent infiltrate of neutrophils. Note grenz zone of uninvolved dermis (AFIP, Neg 75-7642) (hematoxylin-eosin, original magnification ×90).

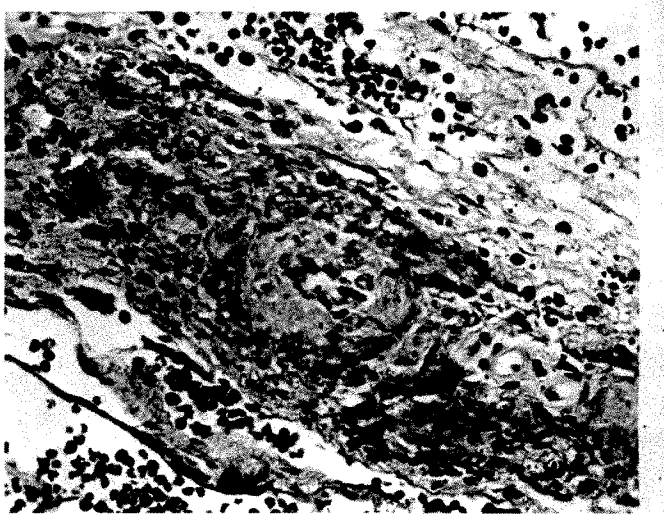

Fig 4.—Leukocytoclastic angiitis with fibrinoid degeneration of vessel wall, center of photograph (AFIP Neg 75-7648) (hematoxylin-eosin, original magnification ×350).

Fig 5.—Giant cell tumor of soft tissue. Foamy histiocytes in left half of field, dense collagen with giant cells in right half (AFIP Neg 7650) (hematoxylin-eosin, original magnification ×60).

degeneration. The epidermis is usually uninvolved, but secondary changes of acanthosis, spongiosis, and superficial necrosis are occasionally present.[1,2,21]

Giant cell tumor of soft tissue,[22-28] not to be confused with giant cell tumor of bone (osteoclastoma) or giant cell epulis of gingiva, connotes a distinctive histopathologic entity, which when forming a discrete nodule attached to a tendon is called giant cell tumor of tendon sheath, and when diffusely spread over a broad area such as a joint synovium is called villonodular synovitis. Giant cell tumor can occur in other soft tissues, so that "giant cell tumor of soft tissue" is an appropriate inclusive term. It is a fairly common condition, occurring more frequently in women, usually in the young to middle-aged, and occurring most commonly on a finger, usually as a solitary nodule 1 to 3 cm in size, of a yellowish color and a firm consistency. The lesion on our patient is a classical example both clinically and histopathologically (Fig 2 and 5). It is usually asymptomatic and slowly growing over months to years, but rapid acceleration of growth can occur. Giant cell tumor is benign histologically and in behavior, although mitotic figures are not uncommon and contiguous bone may be eroded by pressure of the tumor. Excision is usually curative but recurrences occasionally occur. The histopathological appearance is distinctive, being that of a fibrocellular tumor with histiocytic-appearing polyhedral cells, lipid-laden cells, hemosiderin-laden cells, and multinucleated giant cells. These latter give the entity its name, but they need not be a prominent component. There is a tendency for fibrous encapsulation and for hyalinization of the stroma.[27] Giant cell tumor is considered to be a variant of fibrous histiocytoma,[22,28] of which more familiar variants are dermatofibroma, sclerosing hemangioma, and dermatofibrosarcoma protuberans. As is the situation with dermatofibroma and other fibrous histiocytomas, it is unknown whether giant cell tumor is a "true neoplasm" or whether it is a reactive fibrocellular hyperplasia secondary to some inflammatory injury. One might speculate that the giant cell tumors in our patient represented a fibrohistiocytic proliferative response to repetitive inflammatory injury from the EED; there is, of course, no way of proving this. Intriguing in any case is the coexistence in the same patient of an inflammatory condition, EED, which can eventuate in a fibroproliferative response and a fibroproliferative lesion, giant cell tumor, which possibly originates from an inflammatory stimulus. The two conditions allude to each other in this patient.

The pathogenesis of EED is unknown. The occurrence of an Arthus-type of phenomenon is suggested by the histological findings of a leukocytoclastic angiitis.[1,29] No antinuclear antibodies have been found in the few cases tested. Elevated[3,19,29,30] as well as normal[31] levels of immunoglobulin have been reported. Our patient's immunoglobulin levels were normal in the midst of therapy, but pretreatment levels were not obtained. Examination for tissue deposits of immu-

noglobulin by the immunofluorescent technique has been done in at least one reported case, but the results were inconclusive.[29] Two cases have been reported in which intradermal injection of streptococcal antigen resulted in a delayed reaction whose histopathological finding was a leukocytoclastic angiitis identical to the clinical lesions.[29] Others have done this test with negative results.[31] There are no consistent laboratory abnormalities in EED.[3]

The striking response of our patient's EED to pregnancy is of particular interest, as it has not been reported before. With each of her three pregnancies, she noted a very definite improvement beginning within the first four to six weeks of pregnancy and continuing throughout the pregnancy, with relapse of the EED within two to three weeks after parturition. A reasonable speculation would be that some kind of hormonal influence was acting. In any case, she has taken norethindrone acetate-ethinyl estradiol as a contraceptive, with neither beneficial nor detrimental effect on the EED.

Erythema elevatum diutinum is notoriously resistant to treatment. Any number of agents and modalities, including systemic corticosteroids, have been attempted without consistent success.[2,3,16,29,30] Several instances of response to chloroquine have been quoted or reported,[16,17,32,33] but instances of failure with it and its hydroxy analog have been noted as well.[3,16,17,34] Since 1960, reports have come from Germany and England of a good response to sulfones. Including our patient, six cases of response to dapsone have been reported and in each instance the response has been dramatic.[19,29,30,35] Two cases of dapsone failure have been reported.[29,36] The mechanism of action of dapsone in EED is not known. Perhaps dapsone's action in EED is similar to its action in dermatitis herpetiformis: both are chronic diseases in which the neutrophil is conspicuous. It has been hypothesized that in dermatitis herpetiformis, dapsone might work by stabilizing the neutrophilic lysosomes[37] or by interfering with the deposition of complement (C3).[38] Whatever its mode of action in EED, dapsone is suppressive rather than curative. As in dermatitis herpetiformis, discontinuation of dapsone results in relapse.[19,29]

The clinical differential diagnosis of EED includes the multicentric syndromic form of reticulohistiocytoma, dermatomyositis, Sweet syndrome, granuloma annulare, hypertrophic lichen planus, xanthoma tuberosum, and cutaneous sarcoidosis. The histologic differential diagnosis would include granuloma faciale, Sweet syndrome, and leukocytoclastic angiitis of whatever etiology. Taken separately, either the clinical or the histologic features of EED are sufficiently characteristic as to suggest the diagnosis; taken together, there is hardly another condition to compete for the diagnosis, particularly after it has demonstrated its remarkable chronicity.

Nonproprietary Name and Trademark of Drug

Dapsone—*Avlosulfon.*

References

1. Haber H: Erythema elevatum diutinum. *Br J Dermatol* 67:121-145, 1955.
2. Laymon CW: Erythema elevatum diutinum: A type of allergic vasculitis. *Arch Dermatol* 85:22-27, 1962.
3. Mraz JP, Newcomer VD: Erythema elevatum diutinum: Presentation of a case and evaluation of laboratory and immunological status. *Arch Dermatol* 96:235-246, 1967.
4. Radcliffe-Crocker H, Williams C: Erythema elevatum diutinum. *Br J Dermatol* 6:1-9, 33-38, 1894.
5. Hutchinson J: *Illustrations of Clinical Surgery.* London, J & A Churchill Ltd, 1878, vol 1, p 42.
6. Hutchinson J: On two remarkable cases of symmetrical purple congestion of the skin in patches, with induration. *Br J Dermatol* 1:10-15, 1888.
7. Bury JS: A case of erythema with remarkable nodular thickening and induration of the skin, associated with intermittent albuminuria. *Illus Med News* 3:145-149, 1889.
8. Dalla Favera GB: Erythema elevatum diutinum und granuloma annulare. *Derm Z* 17:541-558, 1910.
9. Weidman FD, Besancon JH: Erythema elevatum diutinum: Role of streptococci, and relationship to other rheumatic dermatoses. *Arch Dermatol Syphilol* 20:593-620, 1929.
10. Vollum DI: Erythema elevatum diutinum: Vesicular lesions and sulphone response. *Br J Dermatol* 80:178-183, 1968.
11. Urbach E, Epstein E, Lorenz K: Beitrage zu einer physiologischen und pathologischen chemie der haut. IX Mitteilung. Extrazellulare Cholesterinose. *Arch Dermatol Syphilol (Berlin)* 166:243-272, 1932.
12. Laymon CW: Extracellular cholesterolosis. *Arch Dermatol Syphilol* 35:269-284, 1937.
13. Herzberg JJ: Die extracellulare cholesterinose (Kerl-Urbach), eine variante des erythema elevatum diutinum. *Arch Klin Exp Dermatol* 205:477-496, 1958.
14. Stanton DL, Wilson JW: Erythema elevatum diutinum. *Int J Dermatol* 12:10-19, 1973.
15. Ellis FB: Erythema elevatum diutinum, in Demis DJ, Crounse RG, Dobson RL, et al (eds): *Clinical Dermatology.* Hagerstown, Md, Harper & Row Publishers Inc, 1974, vol 2, pp 1-5.
16. Nordenskjold A, Wahlgren F: Erythema elevatum diutinum. *Acta Derm Venereol* 40:317-323, 1960.
17. Langhof H, Zabel R: Erythema elevatum et diutinum bei mutter und tochter. *Dermatol Wschr* 141:496-503, 1960.
18. Momose K: Erythema elevatum diutinum. *Jap J Dermatol Urol* 32:287-303, 1932.
19. Clarke GHV: *Skin Diseases in the African.* London, HK Lewis & Co Ltd, 1959, p 99.
20. Ketron LW: Erythema elevatum diutinum. *Arch Dermatol* 50:363-373, 1944.
21. Lever WF: *Histopathology of the Skin,* ed 4. Philadelphia, JB Lippincott Co, 1967, pp 175-176.
22. Stout PS, Lattes R: Fibrous histiocytomas, in Firminger HI (ed): *Tumors of the Soft Tissues.* Atlas of Tumor Pathology, second series, Armed Forces Institute of Pathology, 1967, fascicle 1, pp 38-52.
23. Ackerman LV, Rosai J: *Surgical Pathology,* ed 5. St Louis, CV Mosby Co, 1974, p 1084.
24. Hirsch EF: *Pathology in Surgery.* Baltimore, Williams & Wilkins Co, 1955, p 617.
25. Boyd W: *Pathology for the Surgeon,* ed 7. Philadelphia, WB Saunders Co, 1955, p 617.
26. Sherry JB, Anderson W: The natural history of pigmented villonodular synovitis of tendon sheaths. *J Bone Joint Surg* 37:1005-1011, 1955.
27. Jaffe HL, Lichtenstein L, Sutro CJ: Pigmented villonodular synovitis, bursitis, and tenosynovitis. *Arch Pathol* 31:731-765, 1941.
28. Foster LN: Benign giant cell tumor of tendon sheaths: An example of sclerosing hemangioma. *Am J Pathol* 23:567-583, 1947.
29. Cream JJ, Levene GM, Calnan CD: Erythema elevatum diutinum: An unusual reaction to streptococcal antigen and response to dapsone. *Br J Dermatol* 84:393-399, 1971.
30. Abdel-Aziz AHM, Robertson DEH: Erythema elevatum diutinum: Immunoglobulin, bacterial skin tests and response to dapsone. *Cutis* 12:549-553, 1973.
31. Goerttler E: Erythema elevatum diutinum mit alopecishen veranderungen. *Z Hautk* 48:809-817, 1973.
32. Hidano MA: Erythema elevatum diutinum: Action heureuse de la chloroquine. *Bull Soc Fr Dermatol Syphiligr* 70:153-155, 1963.
33. Roenigk HH: Necrotizing vasculitis (erythema elevatum diutinum). *Arch Dermatol* 104:103-105, 1971.
34. Brusting LA: Erythema elevatum diutinum. *Arch Dermatol* 85:679, 1960.
35. Kalkoff KW: Zur behandlung des erythema elevatum diutinum mit 3-sulfanilamido-6-methoxypyridazin (Lederkyn). *Dermatol Wschr* 142:788-800, 1960.
36. Lugt LVD: Erythema elevatum et diutinum. *Dermatologica* 119:65-74, 1959.
37. Barranco VP: Inhibition of lysosomal enzymes by dapsone. *Arch Dermatol* 110:563-566, 1974.
38. Provost TT, Tomasi TB: Evidence for the activation of complement via the alternate pathway in skin diseases: II. Dermatitis herpetiformis. *Clin Immunol Immunopathol* 3:178-186, 1974.

Supernumerary Areolae

Lt Comdr Stephen W. Shewmake, MC, USN, Capt Gene T. Izuno, MC, USN

• One of the more unusual forms of supernumerary breast tissue is characterized by the presence of areolar tissue only. The case presented describes a patient with three supernumerary areolae, including one located outside the embryonic milk line. There is a possibility that this finding represents an atavistic phenomenon.

(Arch Dermatol **113:823-825, 1977)**

Polythelia, polymastia, and other forms of supernumerary breast tissue are clinical entities that present an unusual and striking appearance. The reported incidence varies from 0.4% to 6%,[1-4] and the most common form is the isolated presence of an accessory nipple or nipples (polythelia).[1,5,6] One of the more unusual forms of aberrant breast tissue, characterized by the presence of areola only, is a condition known as polythelia areolaris.[3,6,7] The term "polythelia" is of Greek derivation meaning "many nipple."[3] Polythelia areolaris, when used to describe the isolated clinical presence of aberrant areolar tissue alone, is inaccurate and contradictory. It would be more aptly described as "supernumerary areolae."

This report discusses a case of supernumerary areolae as compared with other related types of supernumerary breast tissue. The patient in this report was also noted to have an aberrant areola located outside the milk line. The possibility that this finding may be an atavistic phenomenon is also considered.

REPORT OF A CASE

A 32-year-old woman of Italian descent was seen in the Dermatology Clinic at the Naval Regional Medical Center in San Diego in October 1974. She related a lifelong history of pigmented "wrinkled" lesions located on the right shoulder, right-upper abdomen, and right side of the pubic region (Fig 1). There was no history of previous injury or trauma to these areas. There was no history of tenderness or swelling associated with pregnancy or menses but, she stated, these lesions had become darker brown after each of her three pregnancies. She denied any family history of similar lesions. Physical examination revealed a 1.5 × 2.5 cm irregular atrophic pigmented lesion in the right shoulder region near the base of the neck. No nipple or hair was present. A 2.8 × 3.5 cm wrinkled, hyperpigmented depressed macular lesion was present on the right-upper abdomen, directly beneath the right breast (Fig 2). No erectile protuberance or nipple was noted and glandular tissue could not be palpated beneath the lesion. Surrounding the lesion was a collarette of dense dark hair. Examination of the pubic region revealed a 3.5 × 3.5 cm atrophic-appearing, hyperpigmented lesion located within the pubic hair of the right lateral aspect of the mons pubis (Fig 3). This lesion was nonhair-bearing and again, no nipple or glandular tissue was detected. Examination along the left milk line from the axilla to the groin revealed no similar lesions. Elliptical biopsies of all three lesions revealed similar histopathological findings.

All three tissue specimens demonstrated an irregular epidermal surface with tall connective tissue papillae and a small amount of hyperkeratosis and epidermal pigmentation. Vacuolar degeneration was abundant throughout all epidermal layers (Fig 4). Smooth muscle bundles were present in great numbers randomly interlacing in the mid and reticular portions of the dermis (Fig 5 and 6). This represents one of the most characteristic histopathological features of areolar tissue. Lactiferous ducts and the glands of Montgomery were not noted in any of the specimens.

The lack of lactiferous ducts and the accessory glands of Montgomery within the tissue specimens is explained by the fact that these ducts are found only at the tips of the nipples, and the glands of Montgomery are associated only with the palpable tubercles present on the areolar surfaces.[7] Since these clinical structures were not present in our patient's lesions,

Accepted for publication March 1, 1976.

From the Department of Dermatology and Clinical Investigation Center, Naval Regional Medical Center, San Diego.

The opinions and assertions contained herein are those of the authors and are not to be construed as official or as reflecting the views of the Navy Department or the naval services at large.

Reprints not available.

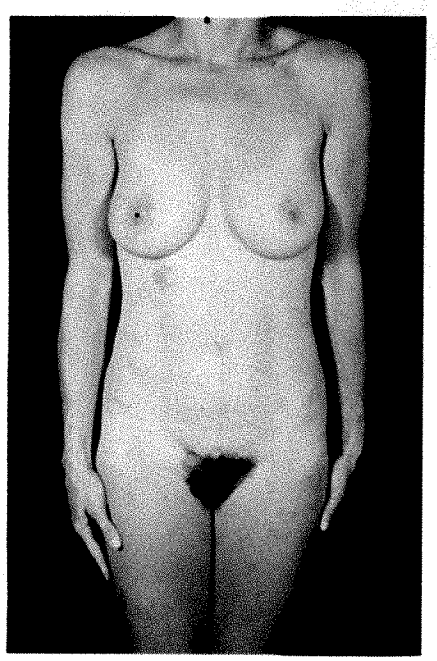

Fig 1.—Supernumerary areolae of right shoulder, right-upper abdomen, and the right pubic region.

Fig 2.—Supernumerary areola located at right margin of pubic region.

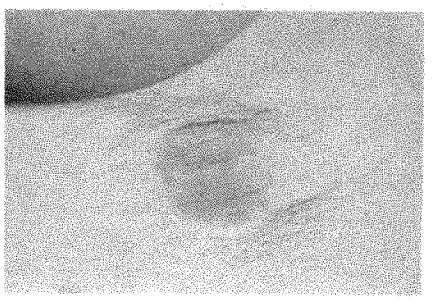

Fig 3.—Supernumerary areola of right-upper abdomen.

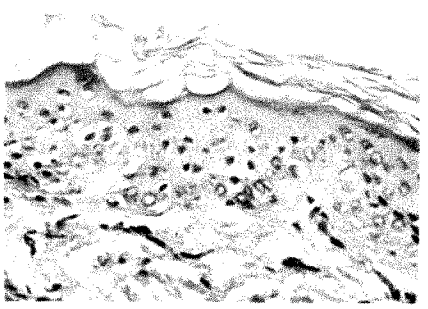

Fig 4.—Median power view of tissue from right shoulder showing slight hyperkeratosis and abundant vacuolar degeneration throughout the epidermis (hematoxylin-eosin, original magnification ×128).

Fig 5.—Scanning magnification of tissue from right abdomen showing irregular epidermal surface and numerous smooth muscle bundles interlacing in mid and lower dermis (hematoxylin-eosin, original magnification ×40).

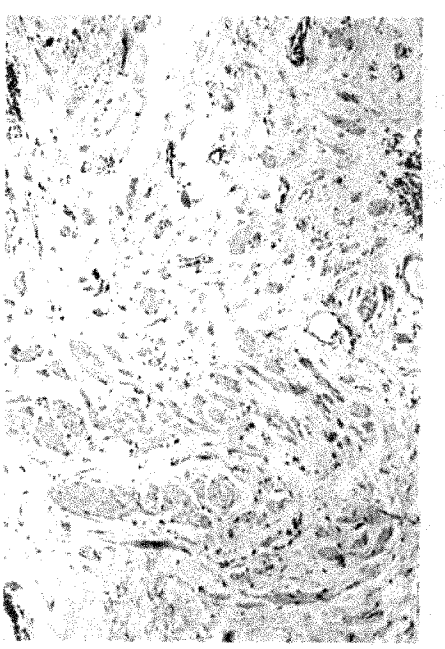

Fig 6.—Higher magnification of Fig 5 showing abundant smooth muscle bundles and scattered dilated capillaries within fine collagenous stroma (hematoxylin-eosin, original magnification ×102).

the absence of lactiferous ducts and the accessory glands of Montgomery in this case would not be inconsistent with the diagnosis of supernumerary areolae.

COMMENT

The presence of supernumerary breast tissue in humans has been well documented in the medical literature.[1-4] As most reports deal with only the subject of polythelia, the rare type of aberrant breast tissue reported here has seldom been mentioned. The classification of supernumerary breast tissue first described by Kajava in 1915 is still in use today and consists of the following categories[2,5,6]:

1. Complete breast with nipple, areola, and gland tissue.
2. Supernumerary breast without areola but with nipple and gland tissue.
3. Supernumerary breast without nipple but with areola and gland tissue.
4. Aberrant gland tissue only.
5. Nipple and areola with gland tissue replaced by fat–pseudomamma.
6. Nipples only–polythelia.
7. Areola only–polythelia areolaris.
8. Patch of hair only–polythelia pilosa.

In this classification, Kajava restricted the definition of the term "nipple" to mean only the protuberance in the center of the areola.[5] Unfortunately, most reports of polythelia or supernumerary nipples define this term in a very broad sense as follows: a papilla or protuberance, which may or may not be associated with areola, follicles, and/or hair.

Supernumerary breast tissue usually occurs only along the milk line that extends from the axillary area to the groin.[2-4] Polythelia and pseudomamma represent the most common forms of aberrant breast tissue.[5] Complete supernumerary breasts are exceptional but, when present, they can secrete milk during lactation and undergo cyclic as well as potentially malignant changes as does the normal breast.[2-4] Aberrant glandular tissue, alone, is observed infrequently and is almost exclusively limited to the axillary areas.[6] These lesions are commonly bilateral, usually becoming apparent at or after puberty and especially during pregnancy. This aberrant glandular tissue is also capable of developing the same pathophysiologic changes as normal breast tissue. Since there is no outward visible lesion, this condition is often misdiagnosed as lipoma, lymphoma, lymphadenitis, or hidradenitis suppurativa.[7]

The various types of supernumerary breast tissue develop most often in the embryonic milk lines, but they can also occur at atypical locations on the torso or extremities at sites that are normal in certain other mammals.[2] One theory as to why lesions occur outside the embryonic milk lines is based on the premise that misplaced embryonic anlage represents reversion to more primitive or ancestral characteristics.[2,3] This is known as the Geffroy-Saint-Hilaire-Darwin theory of atavism.[2,3] The lesion on our patient's right posterior shoulder may represent such an atavistic phenomenon since breasts are normally found in the same anatomical location of animals such as the nutria and the gentle lemur.[2] De Cholnoky reviewed 64 patients with supernumerary breasts in atypical locations and found that they occur at many unusual sites. He included three cases of lesions occurring in the shoulder region.[1,2] Other authors,[2,5] however, have regarded the presence of supernumerary breast tissue, regardless of its location, to be accidents of development having no phylogenic significance.

The presence of supernumerary breast tissue can also be an indicator of systemic disease. A number of authors have drawn attention to the association of aberrant breast tissue and peptic ulcer disease, neurosis, cardiovascular disease, and renal and gonadal hypoplasia.[3,6-8,9] Evans,[3] in a detailed study, found the incidence of polythelia much higher in patients with systemic hypertension who had either enlarged left ventricles, pulmonary hypertension with right ventricular hypertrophy, or cardiomyopathy. Ash-Upmark[10] found an association between inverted nipples and migraine headaches. Fleisher[11] noted that nipples that were lateral to the midclavicular line (wide set) were associated with an increased incidence of renal hypoplasia and gonadal dysplasia. The more unusual varieties of supernumerary breast tissue such as supernumerary areolae have not been reported as being associated with systemic disease.

Surgical treatment of supernumerary breast tissue, especially of supernumerary areolae, is usually performed for cosmetic reasons. If glandular tissue is present, carcinomatous change can occur, but does so only very rarely.[2,4,12]

This investigation was supported in part by Bureau of Medicine and Surgery Clinical Investigation Program.

Westwood Pharmaceuticals, Inc, supplied a grant for the publication of the color photographs.

References

1. De Cholnoky T: Accessory breast tissue in the axilla. *NY State J Med* 51:2245-2248, 1951.
2. De Cholnoky T: Supernumerary breast. *Arch Surg* 39:926-941, 1939.
3. Evans W: Polythelia in cardio-arterial disease. *Br Heart J* 21:130-136, 1959.
4. Looney CM, Reichman SC, Noel OF: Ectopic breast tissue: Report of unusual case. *Am Surg* 25:219-222, 1959.
5. Brightmore T: Bilateral double nipples. *Br J Surg* 59:55-57, 1972.
6. Greer KE: Accessory axillary breast tissue. *Arch Dermatol* 109:88-89, 1974.
7. Montagna W, Yun JJ: The glands of Montgomery. *Br J Dermatol* 86:126-133, 1972.
8. Harper R: Supernumerary nipples and neurosis. *Lancet* 1:899-903, 1948.
9. Harper R: The modern primitive. *Lancet* 2:1134-1136, 1951.
10. Ash-Upmark E: Inverted nipples and migraine. *Acta Med Scand* 147:191-196, 1954.
11. Fleisher DS: Lateral displacement of the nipple, a sign of bilateral renal hypoplasia. *J Pediatr* 69:806-809, 1966.
12. Wakeley C: Diseases of the nipple. *Br Med J* 1:468-470, 1951.

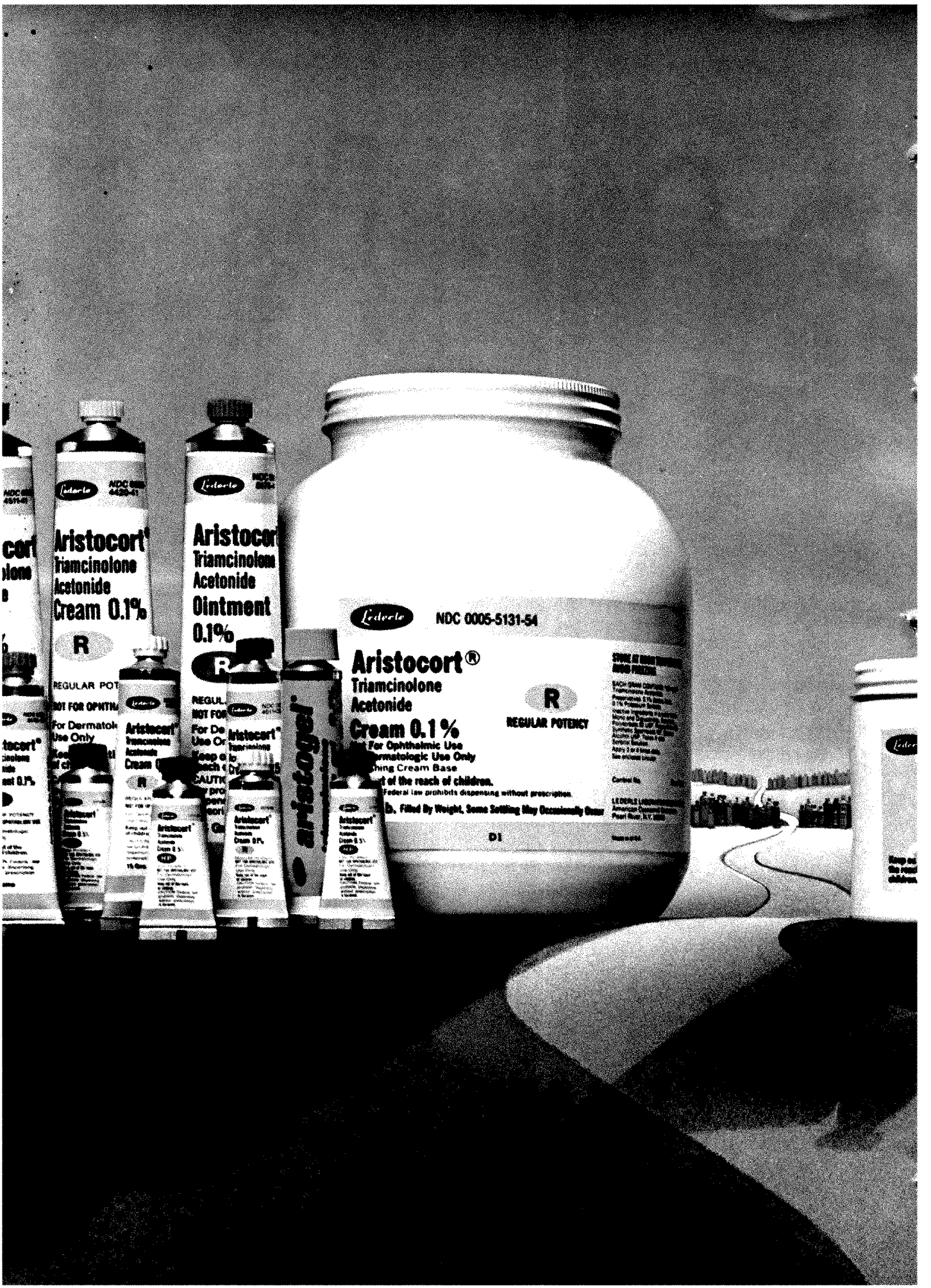
Aristocort
Triamcinolone
Acetonide
Cream 0.1%
R
Aristocort
Triamcinolone
Acetonide
Ointment
0.1%
R
Lederle
NDC 0005-5131-54
Aristocort®
Triamcinolone
Acetonide
R
REGULAR POTENCY
Cream 0.1%
For Ophthalmic Use
Federal law prohibits dispensing without prescription.
aristogel


<antocert®
0.5%
Aristocort
Aristocort
Aristocort

For Skin Without Water

Neutrogena® Dry Skin products are specially formulated to supplement surface fats and aid in the retention of moisture.

- Neutrogena® Dry-Skin Soap contains humectants, lubricants, and emollients to soften and moisturize, and is nonirritating to sensitive skin.
- Neutrogena® Rainbath® Dry Skin Bath Gel is lipid-free, cleanses with a rich lather without the drying effect of ordinary soap, and leaves skin soft and smooth. Available both scented and unscented.
- Neutrogena® Hand Cream is a heavy-duty formula containing a special blend of naturally occurring oils and glycerin, and is a useful adjunct in steroid-responsive hand dermatoses.[1]

1. Data on file, Medical Dept., Neutrogena Corp.

Neutrogena®

Dedicated to Sensitive Skin Care

Neutrogena Corp.
5755 West 96th Street
Los Angeles, California 90045

Now available! The latest information on self-assessment programs.

The new edition of the AMA's DIRECTORY OF SELF-ASSESSMENT PROGRAMS FOR PHYSICIANS is now available. It lists programs sponsored by all major specialty societies, on 21 topics.

Each program is listed by topic and sponsor and includes sites and times of tests, content, format, time required, method of scoring, aids to learning, fees and whom to write.

To order your copy of the Directory, ($1 ea.) write: Order Dept. OP-414, American Medical Association, 535 N. Dearborn St., Chicago, Ill. 60610.



For Skin Plagued by Acne

Neutrogena® Acne products aid in drying while they clean and degrease acne-plagued skin.

- Neutrogena® Acne-Cleansing Soap gently cleanses and degreases the skin, and does not interfere with topical or systemic acne treatment.
- Neutrogena® Acne-Drying Gel combines antisepsis with astringency, contains 47% active drying agents, is perfume-free, can be applied under or over makeup, and is imperceptible on the skin.

Neutrogena®
Dedicated to Sensitive Skin Care

Neutrogena Corp.
5755 West 96th Street
Los Angeles, California 90045

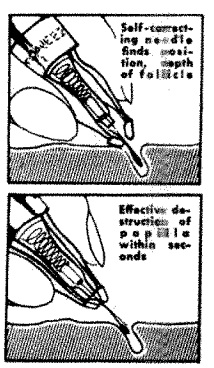

Perma Tweez®

ELECTROLYSIS FOR PERMANENT HAIR REMOVAL

Clinical study (copy on request) proves safety and efficacy of laity self-use electrolysis. Study shows chin and even axilla can be self-treated effectively through use of mirror. This permanent hair remover features the only patented self-correcting needle in existence. Battery operated instrument sterilizes itself when current flows. No-puncture safety feature also helps prevent infection.

Thousands of units sold to physicians for such varied application as removal of inverted eyelashes to cosmetic use.

PERMA TWEEZ & ATTACHMENT **$22.45**

☐ Invoice after 30 days

☐ Check enclosed

30 DAY FREE TRIAL EXAMINATION
(MAY BE RETURNED WITH NO OBLIGATION)

GENERAL MEDICAL CO., Dept. D-86
1935 Armacost Ave
West Los Angeles, CA 90025

DR _____
STREET _____
C/S _____ ZIP _____

Review Article

Lupus Band Test

Eugene W. Monroe, MD

• **The lupus band test (LBT) is a direct immunofluorescent technique for demonstrating a band of localized immunoglobulins at the dermal-epidermal junction in the skin of patients with lupus erythematosus (LE). Studies have shown immunoglobulins and complement at the dermal-epidermal junction in systemic (involved and uninvolved skin) and in discoid (involved skin only) LE. It is essential that the appropriate skin site be selected for biopsy; ie, involved or uninvolved skin, light-exposed or light-protected skin. The proper location of the biopsy site is determined by whether the LBT is intended for diagnostic or prognostic purposes. From a diagnostic standpoint, the LBT is a very sensitive and specific test for LE. In addition, this procedure has considerable value as a prognostic test for a patient with an established diagnosis of LE.**

(*Arch Dermatol* 113:830-834, 1977)

In 1963 Burnham et al,[1] using direct immunofluorescent techniques, demonstrated a band of localized immunoglobulins at the dermal-epidermal junction in the skin of patients with discoid (involved skin only) and systemic (involved and uninvolved skin) lupus erythematosus (LE). This immunofluorescent technique has become known as the lupus band test (LBT). In 1964 Cormane[2] demonstrated that certain patients with systemic LE had a band of immunoglobulins at the dermal-epidermal junction of visibly normal skin. Subsequently, several other studies[3-16] have shown immunoglobulins and complement at the dermal-epidermal junction in systemic and in discoid LE.

Three patterns of immunoglobulin deposition at the dermal-epidermal junction have been observed by various investigators.[9,13] A homogeneous or solid band of well-demarcated, bright fluorescence is seen mostly in chronic atrophic or hyperkeratotic skin lesions. A pattern of multiple, short, closely set, bright threads or fibrils is seen in more acute erythematous, edematous lesions, and occasionally, in clinically normal skin. A stippled band consisting of multiple small round points of fluorescence is the type most commonly seen in the clinically normal skin of systemic LE patients.

The frequency of the various immunoglobulin classes present in the subepidermal deposits varies with reports from different investigators. Several studies have shown that IgG represents the predominant immunoglobulin in the bands.[3,4,9] Other studies have shown IgM to be predominant.[17,18] In a recent study, Gilliam[19] found that approximately 80% of the patients with subepidermal staining had IgG at the dermal-epidermal junction and an equal number had IgM. The most frequent combination was IgG and IgM. Occasionally, IgA was found but always in combination with IgG. The importance of these data is that in performing the LBT, antiserum directed against both IgG and IgM must be used or a large number of false-negative test results will occur.

Other immunopathologic investigations have shown dermal-epidermal deposition of complement (C3 and C4) in involved and uninvolved systemic LE skin, suggesting involvement of the classical complement cascade.[8-10,17,18] More recent investigations have also demonstrated deposition of properdin or C3 proactivator, or both, in involved and uninvolved systemic LE skin, suggesting activation of the alternative complement pathway.[17,18,20,21] To what extent the classical and alternative pathways of complement activation are involved in the production of these skin lesions must still be resolved.

Some studies[22-25] have been performed to clarify the nature of the immunoglobulin deposits present at the dermal-epidermal junction in patients with LE. Acid buffer eluates from the skin of LE patients have disclosed both antinuclear and antibasement membrane properties of the deposited antibodies. However, circulating basement membrane antibodies have not been demonstrated in patients with LE.

The LBT is a very useful tool for the physician. This procedure has value as both a diagnostic and a prognostic test. The purpose for which the LBT is

Accepted for publication June 3, 1976.

From the Department of Dermatology, University of Michigan Medical School, Ann Arbor.

Reprint requests to Milwaukee Medical Clinic, 3003 W Good Hope Rd, Milwaukee, WI 53209 (Dr Monroe).

Table 1.—Lupus Band Test in Patients With Lupus Erythematosus (LE)

Type Skin in Patients	Systemic LE (%)	Discoid LE (%)
Involved	176/189 (93)[26]	257/274 (94)[26]
Uninvolved, light protected	94/193 (49)[26] 47/87 (55)[19]	0/62 (0)[26] 0/27 (0)[19]

Table 2.—Lupus Band Test in Normal Skin of ANA-Positive Disease Patients*

Diseases	References			
	1970[14]	1974[31]	1975[19]	1975[26]
Drug-induced LE	0/2	1/18	0/7	—
Rheumatoid arthritis	0/7	0/9	1/10	0/20
Scleroderma	0/7	0/1	0/12	0/45
Dermatomyositis	0/2	0/2	0/10	0/11
Mixed Connective Tissue Disease	. . .	(3/6)[47]	. . .	. . .

*ANA indicates antinuclear antibody; LE, lupus erythematosus.

intended, for example, diagnosis or prognosis, will dictate the proper location of the biopsy site. It should be stressed that when one refers to the LBT, he must specify the exact site of the biopsy—whether it is involved or uninvolved or light-exposed or light-protected skin. This is critical as results will vary in the same person depending on the site selected for the biopsy.

DIAGNOSTIC VALUE OF LBT

The value of the LBT as a diagnostic tool is well established. Its primary use is in diagnosing LE in patients with cutaneous lesions. Approximately 90% to 95% of the patients with systemic or discoid LE have a positive LBT in involved skin.[26,27] Thus, the test in involved skin is a very sensitive indicator of LE; ie, there are few false-negative test reactions.

The specificity of the LBT is also very high in differentiating LE from other cutaneous disorders that are clinically similar; ie, there are few false-positive test findings. Dermal-epidermal fluorescence is almost always negative in the following conditions: polymorphic light eruption,[7,10,14,15,28] benign lymphocytic infiltrates of Jessner,[10,26,29,30] lymphocytoma cutis,[15,26] lichen planus,[14,15,26,31] seborrheic dermatitis,[14,15,26] contact dermatitis,[14,15,26] drug eruptions,[26] psoriasis,[14,15,26] sarcoid,[14,26] pseudopelade,[26] morphea,[26] vitiligo,[26] idiopathic vasculitis,[14,15,31] and purpura.[31]

Some of the diseases that have had isolated reports of positive dermal-epidermal immunofluorescence reactions are indicated in the following tabulation.

Bullous pemphigoid[26,32]
Cutaneous porphyria[8,26,33]
Dermatitis herpetiformis[26,34]
Cicatricial pemphigoid[37]
Pemphigus erythematosus[26,38]
Hypocomplementemic vasculitis[26]
Anaphylactoid purpura[39]
Facial telangiectasia[26,35,36]
Rosacea[26,35,36]
Polymorphous light eruption[26,40]
Benign lymphocytic infiltrates[9]
Lepromatous leprosy[26,41,42]
Amyloidosis[26]
Primary biliary cirrhosis with amyloidosis[19]
Autoimmune thyroiditis[43]
Cold agglutinin syndrome[43]
Chronic biological false-positive reactions for syphilis reactions[43]
Phenobarbital-induced bullae[31]
Drug-induced LE[31,44,45]
Scleroderma[7,36]
Dermatomyositis[20,16,46]
Rheumatoid arthritis[19]
Mixed connective tissue disease[47]

Two of these diseases, bullous pemphigoid and cutaneous porphyria, usually have positive immunofluorescence.[26] However, other clinical and laboratory data should easily distinguish them from LE. In bullous pemphigoid the homogeneous band is often tubular in appearance with a dark center and brighter, sharply demarcated margins. In contrast, the band in LE tends to be wider and more solidly homogeneous.[14] In addition, bullous pemphigoid usually has circulating antibodies directed against the epithelial basement membrane and a negative antinuclear antibody (ANA).[32] In cutaneous porphyrias, fluorescence of the dermal-epidermal junction is usually much less intense than that found in the dermal blood vessels—exactly the reverse of the usual situation in LE. In addition, complement is rarely found in the band.[8,26,33] In dermatitis herpetiformis, the diagnostic immunofluorescent finding is the deposition of IgA at the dermal-epidermal junction, predominantly at the tips of the dermal papillae.[26,34] Studies have shown the frequent presence of dermal-epidermal junction fluorescence in the lesions of patients with rosacea and patients with facial telangiectasia, either essential in origin or those accompanying systemic scleroderma.[26,35,36] In lesions of lepromatous leprosy, dermal-epidermal fluorescence, predominantly of an IgM type, is often present.[26,41,42] Similar deposits were also found in clinically normal but histologically abnormal lepromatous leprosy skin.[42]

Two conditions that may be confused with lupus clinically, polymorphous light eruption and Jessner benign lymphocytic infiltrates, have had a few rare reports of dermal-epidermal fluorescence.[9,26,40] However, most large studies have shown consistently negative LBT findings in patients with polymorphous light eruptions[7,10,14,15,28] and Jessner lymphocytic infiltrates.[10,26,29,30] The immunofluorescent findings in drug-induced LE, scleroderma, dermatomyositis, rheumatoid arthritis, and mixed connective tissue disease will be discussed under the subject of other ANA-positive diseases. We believe, from reviewing all available data, direct immunofluorescence of involved skin is, in general, more sensitive and specific in differentiating LE from most conditions than is a routine histopathologic study of a biopsy specimen.[26]

The second diagnostic value of the LBT is in the differential diagnosis of systemic from discoid LE. Whereas both usually have positive direct immunofluorescence in involved skin, only systemic LE has positive immunofluorescence in clinically normal

light-protected skin (Table 1). Approximately 50% of systemic LE patients have positive LBTs in uninvolved light-protected skin.[19,26] No cases of positive LBT reactions have been reported in the normal skin of patients with discoid LE.[19,26,27]

The third diagnostic value of the LBT occurs in making a diagnosis of systemic LE in patients without cutaneous lesions. When cutaneous lesions are absent, most authors suggest that biopsies be made of sun-exposed skin, such as the dorsal forearm. The incidence of positive LBT results in uninvolved, sun-exposed skin of systemic LE patients is somewhere between 50% (the incidence in normal light-protected skin) and 95% (the incidence in involved skin). In the experience of Jablonska and Chorzelski[10] about 80% of these patients have positive LBTs in normal skin from the dorsal forearm.

The differentiation of systemic LE from other connective tissue diseases is sometimes quite difficult because their clinical and serologic pictures often overlap. A fourth diagnostic value of the LBT occurs in the diagnosis of SLE from these other antinuclear-antibody (ANA) positive diseases. As Table 2 shows, the specificity of the LBT in this group of diseases is quite high. Dermal-epidermal complexes are rarely found in patients with procainamide hydrochloride- or hydralazine hydrochloride-induced LE.[31,44,45] In scleroderma[7,36] and dermatomyositis[10,16,46] only rare cases of positive immunofluorescence have been reported, and these have been basically confined to areas of vascular lesions of the telangiectatic type. For example, in one study[36] where four patients with scleroderma had positive immunofluorescent reactions in facial telangiectatic lesions, all had negative immunofluorescence in indurated lesions without telangiectasia. A recent report indicated that three of six patients with the mixed connective tissue disease syndrome had positive immunofluorescence in clinically normal light-exposed skin.[47] This study casts some doubt on the validity of using sun-exposed, clinically normal skin to confirm a diagnosis of LE. Until a large study is completed, which analyzes the results of LBTs in clinically normal, light-exposed skin of other connective tissue diseases, it might be prudent to perform a biopsy on light-protected as well as light-exposed normal skin for diagnostic purposes.[48] An interesting immunofluorescent finding in patients with the mixed connective tissue disease is the frequent presence of a thready, intraepidermal nuclear-staining pattern, which appears to be associated with high titers of antibody to extractable nuclear antigen.[19] This pattern may prove to be of diagnostic value for the mixed connective tissue disease syndrome.

Table 3.—Lupus Band Test and Renal Disease

Study	Biopsy Site (Uninvolved Skin)	Results
Burnham & Fine (1971)[15]	Light protected	LBT result positive: renal disease increased three times
Caperton et al (1972)[50]	Light exposed	No relationship
Grossman et al (1974)[51]	Light protected	No relationship
Gilliam et al (1974-1975)[19,55]	Light protected	LBT result positive: 84% severe; 23% mild
Dantzig et al (1975)[49]	Light protected	LBT result positive: 83% severe; 19% mild
Gilliam & Pennebaker (1976) (oral communication)	Light protected	Poorer prognosis with IgG than IgM alone

PROGNOSTIC VALUE OF LBT

Although the diagnostic value of the LBT is well accepted, its prognostic significance is more controversial. The first critical point is that all biopsy specimens taken for prognostic purposes must come from clinically normal, light-protected skin such as the medial flexor forearm, medial upper arm, or buttocks. Several studies have clearly shown that direct immunofluorescence from uninvolved, light-protected skin correlates with laboratory measurements that have been associated with disease activity and poorer prognosis—hypocomplementemia,[15,19,31,49] elevated titers of antinative-DNA antibodies,[19] and peripheral pattern ANA.[15,19] The presence of leukopenia[49] and LE cells[15,49] also appears to be increased in patients with LBT-positive reactions. The frequency of positive ANA reactions does not correlate with cutaneous immunofluorescence.[19,49]

The correlation of a positive LBT finding in uninvolved skin with general clinical disease activity in systemic LE has been shown in several studies.[15,19,31] In addition, a recent study by Schrager and Rothfield[18] has attempted to correlate general clinical disease activity with the deposition of a particular immunoglobulin class in the skin. These authors have shown that a statistically significant correlation exists between deposits of IgA in the dermal-epidermal junction of nonlesional skin and clinical disease activity. They found that IgA was absent in all nonlesional (sun-exposed) skin from 16 patients with clinical remission, while it was present in 7 of 23 patients with active disease.

The correlation of LBT findings with renal involvement remains a very debatable subject, as shown in Table 3. In 1968 Pohle and Tuffanelli[7] suggested a possible relationship between renal involvement and the presence of immunoglobulin deposits in normal-appearing skin of systemic LE patients. In 1971 Burnham and Fine[15] substantiated this relationship by reporting a correlation between immunoglobulin deposition in the skin and the presence of renal involvement. They found kidney involvement three times more frequently in patients with LBT-positive findings than in those with negative results. However, their study did not include histologic classification of the renal lesions.

In contrast, Caperton et al[50] observed no relationship between the LBT and the presence of renal disease in 29 patients followed up during a one-year period. On the basis of renal biopsy specimens from 12 patients, they also concluded that there was no

relationship between the renal pathology and the result of the LBT. Of great importance, however, is the fact that these investigators did a biopsy of light-exposed skin, whereas Burnham et al examined skin from light-protected sites.[51]

Grossman et al[31] studied 26 patients with systemic LE and found that 78% of the patients with active renal disease had LBT-positive results, but that 41% of the patients without renal disease also had positive staining. This difference was not statistically significant and these investigators concluded that the LBT could not be correlated with specific organ system involvement. Although biopsy specimens in this study were taken from light-protected skin, renal activity was determined by study of the urinary sediment, not by renal biopsy.

Comprehensive studies by Gilliam et al[19,52] present the best evidence for a correlation between positive LBT findings and renal disease. These investigators found that 18 of 26 patients (70%) with renal disease had LBT-positive results as compared with 5 of 16 patients (31%) without renal disease. More impressive were their findings in 32 patients who had renal biopsies performed. Previous studies[53,54] have clearly shown that there are different types of renal disease in systemic LE, with the prognosis of the renal disease dependent upon the type of glomerulitis present. Gilliam et al[19,52] found positive LBT results in 16 of 19 patients (84%) with the diffuse proliferative or membranous glomerulonephritis, the most severe forms of lupus renal disease. On the other hand, only 3 of 13 (23%) patients with positive findings had focal proliferative glomerulonephritis (a mild form of lupus renal disease) or normal kidney biopsy specimens. Thus, a clear correlation was demonstrated between a positive LBT result and the severe histopathologic forms of renal disease.

Gilliam et al[52] also showed that four of nine patients with LBT-positive findings who initially had no clinical or laboratory evidence of renal disease subsequently developed overt renal disease after an average period of four months, suggesting that the LBT may have predictive value in this regard. In contrast, none of 11 patients with initial negative skin biopsy sections later developed renal involvement during an average follow-up period of 16 months. Also, in all instances in which an immunoglobulin of a particular class was present in the skin, it was found in the simultaneous kidney biopsy as well. This further suggests a relationship between the LBT and renal disease.

Finally, Dantzig et al[14] have shown a correlation between a positive LBT finding and the more severe forms of lupus nephritis. These investigators found that 5 of 6 (83%) of the patients with membranous or diffuse proliferative glomerulonephritis had positive LBT results, while only 3 of 16 (19%) of the patients with focal proliferative glomerulonephritis or normal kidney biopsy sections had positive results of a skin biopsy.

Recent preliminary data by J. N. Gilliam, MD, and J. Pennebaker, MD, (oral communication, April 1976) suggest another possible prognostic use for the LBT. They analyzed the course of LE patients as a function of the type of immunoglobulin class present in the immunofluorescent band at the dermal-epidermal junction. They found that disease activity, the severe histopathologic forms of nephritis, and mortality are greater in those patients who have IgG alone or in combination with any other immunoglobulin, rather than IgM only deposited in the skin.

Studies seeking a relationship between a positive LBT reaction and specific organ system involvement other than renal disease have been unsuccessful.[19,31,52] No correlation has been shown to exist between a positive LBT finding and active skin lesions, CNS involvement, arthritis, serositis, or vasculitis.

Finally, in the future, the LBT may have a value as a possible monitor of the effect of various therapies. Gilliam et al[19,55] have shown that 13 of 17 (76%) patients with LBT-positive results who were taking prednisone (average dose of 24 mg/day) still had positive reactions after four months of treatment. Other studies have also shown that prednisone therapy does not substantially alter the LBT.[7,12,15] On the other hand, Gilliam[19,55] showed that only one of nine (11%) patients with LBT-positive findings receiving cyclophosphamide (average dose, 1.8 mg/kg/day) and prednisone (average dose, 24 mg/day) still had a positive reaction after four months of treatment. These data suggest that immunosuppressive drugs, by eliminating the presence of immune complexes, which certainly play a causative role in the development of renal lesions, may be useful therapeutic agents. Further studies in this area would certainly be of value.

COMMENT

The LBT is extremely useful in the evaluation of a patient with possible LE. The procedure is a very sensitive and specific diagnostic method for discerning LE. In addition, it has much value as a prognostic tool in a patient with an established diagnosis of LE. Finally, two points of caution should be mentioned. First, in performing and interpreting these tests, one must be careful to perform a biopsy at the appropriate skin site; ie, involved or uninvolved or light-exposed or light-protected skin. Second, it should be kept in mind that the LBT is a laboratory procedure. This, like all laboratory tests, should be used in conjunction with clinical findings and other serologic and immunopathologic data in arriving at a final medical decision.

References

1. Burnham TK, Neblett TR, Fine G: The application of the fluorescent antibody technique to the investigation of lupus erythematosus and various dermatoses. *J Invest Dermatol* 41:451-456, 1963.

2. Cormane RH: "Bound" globulin in the skin of patients with chronic discoid lupus erythematosus and systemic lupus erythematosus. *Lancet* 1:534-535, 1964.

3. Cormane RH, Ballieux RE, Kalsbeek GL, et al: Classification of immunoglobulins in the dermo-epidermal junction in lupus erythematosus. *Clin Exp Immunol* 1:207-212, 1966.

4. Tan EM, Kunkel HG: An immunofluorescent study of the skin lesions in systemic lupus erythematosus. *Arthritis Rheum* 9:37-46, 1966.

5. Ten Have-Opbroek AAW: Demonstration of immunoglobulins and complement in the skin of patients with lupus erythematosus. *Acta Dermatol Venereol* 46:68-71, 1966.

6. Kalsbeek GL, Cormane RH: The occurrence of immunoglobulins in the dermo-epidermal junction of the skin in lupus erythematosus and

related syndromes. *Dermatologica* 135:205-215, 1967.

7. Pohle EL, Tuffanelli DL: Study of cutaneous lupus by immunohistochemical methods. *Arch Dermatol* 97:520-526, 1968.

8. Baart de la Faille-Kuyper EH, Cormane RH: The occurrence of certain serum factors in the dermo-epidermal junction and vessel walls of the skin in lupus erythematosus and other (skin) diseases. *Acta Dermatol Venereol* 48:578-588, 1968.

9. Burnham TK, Fine G: The immunofluorescent "band" test for lupus erythematosus: I. Morphologic variations of the band of localized immunoglobulins at the dermo-epidermal junction in lupus erythematosus. *Arch Dermatol* 99:413-420, 1969.

10. Chorzelski T, Jablonska S, Blaszczyk M: Immunopathologic investigations in lupus erythematosus. *J Invest Dermatol* 52:333-338, 1969.

11. Kay DM, Tuffanelli DL: Immunofluorescent techniques in clinical diagnosis of cutaneous disease. *Ann Intern Med* 71:753-762, 1969.

12. Percy JS, Smyth CJ: The immunofluorescent skin test in systemic lupus erythematosus. *JAMA* 208:485-488, 1969.

13. Tuffanelli DL, Kay D, Fukuyama K: Dermo-epidermal junction in lupus erythematosus. *Arch Dermatol* 99:652-662, 1969.

14. Burnham TK, Fine G, Neblett TR: Immunofluorescent "band" test for lupus erythematosus: II. Employing skin lesions. *Arch Dermatol* 102:42-50, 1970.

15. Burnham TK, Fine G: The immunofluorescent "band" test for lupus erythematosus: III. Employing clinically normal skin. *Arch Dermatol* 103:24-32, 1971.

16. Nesbitt LT, Gum OB: Direct cutaneous immunofluorescent test in lupus erythematosus. *South Med J* 66:991-997, 1973.

17. Jordon RE, Schroeter AL, Winkelmann RK: Dermo-epidermal deposition of complement components and properdin in systemic lupus erythematosus. *Br J Dermatol* 92:263-271, 1975.

18. Schrager MA, Rothfield NF: Clinical significance of serum properdin levels and properdin deposition in the dermo-epidermal junction in systemic lupus erythematosus. *J Clin Invest* 57:212-221, 1976.

19. Gilliam JN: The significance of cutaneous immunoglobulin deposits in lupus erythematosus and NZB/NZW F1 hybrid mice. *J Invest Dermatol* 65:154-161, 1975.

20. Rothfield N, Ross HA, Minta JO, et al: Glomerular and dermal deposition of properdin in systemic lupus erythematosus. *N Engl J Med* 287:681-686, 1972.

21. Provost TT, Tomasi TB: Evidence for complement activation via the alternate pathway in skin diseases: I. Herpes gestationis, systemic lupus erythematosus, and bullous pemphigoid. *J Clin Invest* 52:1779-1783, 1973.

22. Thivolet J, Beyvin AJ, LeMot J: Elution des anticorps fixes in vivo au hiveau de la peau au cours du pemphigus, de la pemphigoide bulleuse et du lupus erythemateux. *Lyon Medicale* 227:241-245, 1972.

23. Landry M, Sams WM: Basement-membrane antibodies in two patients with systemic lupus erythematosus. *Lancet* 1:821-822, 1972.

24. Landry M, Sams WM: Systemic lupus erythematosus: Studies of the antibodies bound to skin. *J Clin Invest* 52:1871-1880, 1973.

25. Wierzchowiecki MO, Quismorio FP, Friou GJ: Immunoglobulin deposits on skin in systemic lupus erythematosus. *Arthritis Rheum* 18:77-82, 1975.

26. Tuffanelli DL: Cutaneous immunopathology: Recent observations. *J Invest Dermatol* 65:143-153, 1975.

27. Schrager MA, Rothfield NF: The lupus band test, in *Clinics in Rheumatic Disease*. London, WB Saunders Co, vol 1, No. 3, 1975, pp 597-611.

28. Fisher DA, Epstein JH, Kay DN, et al: Polymorphic light eruption and lupus erythematosus: Differential diagnosis by fluorescent microscopy. *Arch Dermatol* 101:458-461, 1970.

29. Barthelmes H, Sonnischen N: Differential diagnostische untersuchungen Zwischen lupus erythematodes chronicus discoides und lymphocutarer infiltration Jessner-Kanof mit hilfe der immunofluoresenz histologie. *Arch Klin Exp Dermatol* 232:384-397, 1968.

30. Rothfield NF, March CF: Lupus erythematosus, in Fitzpatrick T, Arndt K, Clark W, et al (eds): *Dermatology in General Medicine*. New York, McGraw-Hill Book Co Inc, 1971, pp 1493-1518.

31. Grossman J, Callerame ML, Condemi JJ: Skin immunofluorescence studies on lupus erythematosus and other antinuclear-antibody-positive diseases. *Ann Intern Med* 80:496-500, 1974.

32. Jordon RE, Beutner EH, Witebsky E, et al: Basement zone antibodies in bullous pemphigoid. *JAMA* 200:751-756, 1967.

33. Epstein JH, Tuffanelli DL, Epstein WL: Cutaneous changes in the porphyrias: A microscopic study. *Arch Dermatol* 107:689-698, 1973.

34. Chorzelski TP, Beutner EH, Jablonska S, et al: Immunofluorescence patterns in dermatitis herpetiformis and its differentiation from bullous pemphigoid. *J Invest Dermatol* 56:373-380, 1971.

35. Baart de la Faille H, Baart de la Faille-Kuyper EH: Immunofluorescent studies of the skin in rosacea. *Dermatologica* 139:49-54, 1969.

36. Jablonska S, Chorzelski T, Maciejowska E: The scope and limitations of the immunofluorescence method in the diagnosis of lupus erythematosus. *Br J Dermatol* 83:242-247, 1970.

37. Bean SF, Waisman M, Michel B, et al: Cicatricial pemphigoid: Immunofluorescent studies. *Arch Dermatol* 106:195-199, 1972.

38. Chorzelski T, Jablanska S, Blaszczyk M: Immunopathologic investigations in the Senear-Usher syndrome. *Br J Dermatol* 80:211-217, 1968.

39. Ullman S, Halberg P, Nielsen B, et al: Deposits of immunoglobulins and complement in the dermo-epidermal junction of patients with anaphylactoid purpura. *Acta Dermatol Venereol* 55:359-362, 1975.

40. Jablonska S, Chorzelski TP: Lupus erythematosus, in Fry L, Seah PP (eds): *Immunologic Aspects of Skin Disease*. New York, John Wiley & Sons Inc, 1974, pp 66-152.

41. Bullock WE, Callerame ML, Palmer BJ: Immunohistologic alteration of skin and ultrastructural changes of glomerular basement membrane in leprosy. *Am J Trop Med Hyg* 23:78-83, 1973.

42. Quismorio FP, Rea TH, Levan NE, et al: Immunoglobulin deposits in lepromatous leprosy skin: Presence of deposits in apparently uninvolved skin and occurrence of serum antiepithelial antibodies. *Arch Dermatol* 111:331-334, 1975.

43. Johansson EA, Lassus A, Salo OP: Occurrence of antinuclear factors and immunoglobulins bound to the dermo-epidermal junction in patients with chronic biological false positive (CBFP) reactions for syphilis. *Acta Dermatol Venereol* 52:196-200, 1972.

44. Baart de la Faille-Kuyper EH: In vivo nuclear localization of immunoglobulins in clinically normal skin in systemic and procainamide-induced lupus erythematosus. *Neth J Med* 17:58-65, 1974.

45. Ullman S, Wiik A, Kobayasi T, et al: Drug-induced lupus erythematosus syndrome. *Acta Dermatol Venereol* 54:387-390, 1974.

46. Winkelmann RK, Jordan RE, DeMoragas JM: Immunofluorescent studies of dermatomyositis. *Dermatologica* 145:42-47, 1972.

47. Levitin PM, Weary PE, Giuliano VJ: The immunofluorescent "band" test in mixed connective tissue disease. *Ann Intern Med* 83:53-55, 1975.

48. Burnham TK: "Band" test in connective tissue disease. *Ann Intern Med* 83:909-910, 1975.

49. Dantzig PI, Maura J, Rayhanzadeh S, et al: The significance of a positive cutaneous immunofluorescence test in systemic lupus erythematosus. *Br J Dermatol* 93:531-536, 1975.

50. Caperton EM, Bean SF, Dick FR: Immunofluorescent skin test in systemic lupus erythematosus: Lack of relationship with renal disease. *JAMA* 222:935-937, 1972.

51. Burnham TK: Immunofluorescent test for lupus erythematosus: Relation to renal disease. *JAMA* 223:798-799, 1973.

52. Gilliam JN, Cheatum DE, Hurd ER, et al: Immunoglobulin in clinically uninvolved skin in systemic lupus erythematosus: Association with renal disease. *J Clin Invest* 53:1434-1440, 1974.

53. Pollack VE, Pirani CL, Schwartz FD: The natural history of the renal manifestations of systemic lupus erythematosus. *J Lab Clin Med* 63:537-550, 1964.

54. Baldwin DS, Lowenstein J, Rothfield NF, et al: The clinical course of the proliferative and membranous forms of lupus nephritis. *Ann Intern Med* 73:929-942, 1970.

55. Gilliam JN, Hurd ER, Ziff M: The effect of treatment on the lupus band test. *Clin Research* 22:327A, 1974.

Solar Simulator Tests Demonstrate Superior Substantivity*

SUPER SHADE LOTION [5% PABA] for SUN SENSITIVE PATIENTS

Superior in "Wash Off" Resistance and Cosmetic Elegance to The Leading "PABA" Formula

Super Shade Sun Blocking Lotion by COPPERTONE gives maximum sunburn protection for patients who enjoy the sun yet need the maximum filtering of the sun's ultraviolet rays. Super Shade has these advantages:

- WASH OFF RESISTANCE. The superior substantivity of Super Shade enables it to resist removal by perspiration and swimming. Reapplied as directed, it gives all day protection. Super Shade lets your patient stay in the sun 10 times longer without burning than with no protection.
- COSMETIC ELEGANCE: Super Shade is a white, creamy, non-greasy lotion. Unlike clear products, users can see where Super Shade has been applied. It permits an even uniform coverage with no gaps or unprotected areas.
- HELPS PREVENT SUN DAMAGE that may cause premature wrinkling, aging of the skin and skin cancer when used regularly as directed.

Active Ingredient: Para-Aminobenzoic Acid 5%. Alcohol 60%.

Sun Sensitive Patients Will Appreciate Your Recommendation of Super Shade.

Desquam-X®

5 or 10% Benzoyl Peroxide 6% Polyoxyethylene Lauryl Ether

the topical side of C. acnes control

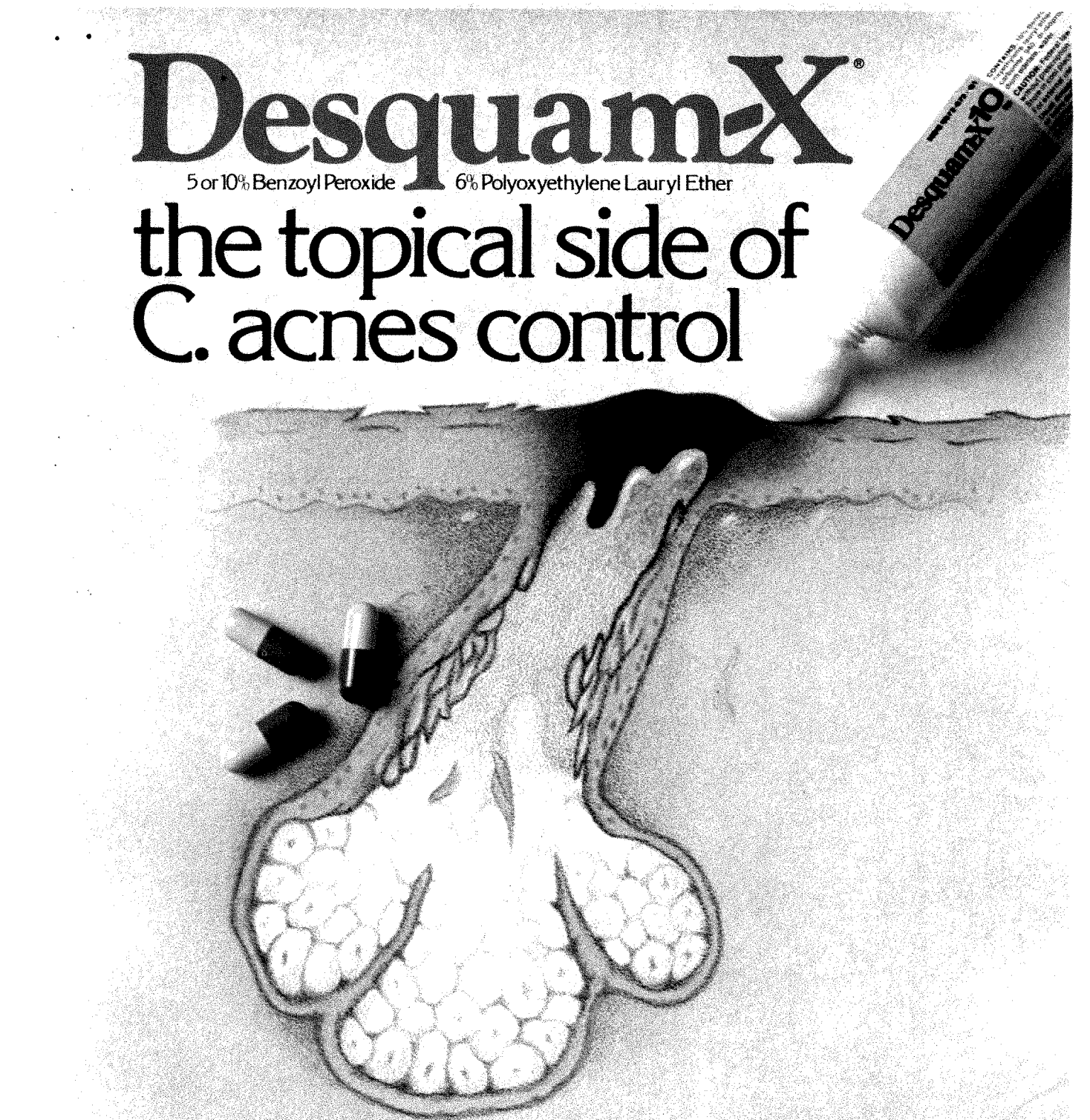

Desquam-X5®

Desquam-X10®

CONTENTS: Desquam-X 5 contains 5% Benzoyl Peroxide, 6% polyoxyethylene lauryl ether, 37% ethyl alcohol, carbomer 940, di-isopropanolamine, disodium edetate and water.

Desquam-X 10 contains 10% Benzoyl Peroxide, 6% polyoxyethylene lauryl ether, 37% ethyl alcohol, carbomer 940, di-isopropanolamine, disodium edetate and water.

INDICATION: A topical aid for the control of acne vulgaris.

ACTION: Provides the desirable drying and desquamation needed in the topical treatment of acne. Desquam-X has been demonstrated to have anti-bacterial effects, especially against Corynebacterium acnes.

DIRECTION FOR USE: After washing as instructed, rub Desquam-X into affected areas twice daily. In fair-skinned individuals or under excessively dry atmospheric conditions it is suggested that therapy be initiated with one application daily. The desired degree of drying and peeling can be obtained by modification of the dosage schedule.

CONTRAINDICATIONS: Not to be used in patients known to be sensitive to any ingredient of Desquam-X.

PRECAUTIONS: Avoid contact with eyes and mucous membranes. For external use only. Keep this and all medication out of the reach of children.

NOTE: May bleach colored fabrics.

HOW SUPPLIED: Plastic tubes 1.5 oz. (42.5 gm.)

CAUTION: Federal law prohibits dispensing without prescription.

WESTWOOD
PHARMACEUTICALS INC
Buffalo, New York 14213
In Canada, Belleville, Ontario K8N1E2

©1975 W. P. Inc.

Short Reports

Segmental Neurofibromatosis

Robert M. Miller, MD, Robert S. Sparkes, MD

Neurofibromatosis (von Recklinghausen disease) is an autosomal-dominant disorder with a frequency of about 1 in 3,000.[1] It is characterized by abnormal cutaneous pigmentation and by numerous tumors that develop in association with elements of both the CNS and peripheral nervous system. The pigmented spots are known as café au lait spots; the tumors are neurofibromas. Both manifestations tend to be multiple and widely distributed over the body; and because the manifestations affect the skin, these problems are initially brought to the attention of the dermatologist. However, there has been relatively little attention paid in the dermatological literature to segmental cases of the disorder. We are reporting two such instances to emphasize the limited clinical manifestations and their possible implications.

Report of Cases

CASE 1.—A 15-year-old girl sought help for the treatment of acne. Examination results also disclosed multiple pigmented macules in her right axilla (Crowe sign). Several larger café au lait spots were found limited to a small area on the skin of the right side of the trunk. The lowest café au lait spot was 2 cm above and to the right of the umbilicus. There were none above the shoulder. On the right side of her back, there was one soft nodule, which proved to be a neurofibroma on biopsy. The remainder of the results of the physical examination revealed an intelligent girl who was healthy in other respects. Her mother stated that the axillary freckling and café au lait spots were present since birth. The neurofibroma, although not exactly known was estimated to be a couple of years old. She had one older brother and one older sister. The sister and parents were examined by one of us (R.M.M.) and were found to have no evidence of café au lait spots or neurofibromas. The brother, grandparents, aunts and uncles were questioned by the patient's parents by telephone after explicit instructions. They all denied axillary freckles, café au lait spots or nodules resembling neurofibromas.

CASE 2.—A 61-year-old woman had had many freckles in her left axilla and a few larger café au lait spots on her trunk since birth. During the past few years, she had developed soft-domed, 1-cm nodules on her left arm, left back, and the left base of the neck. Results of examination showed that all lesions were limited to the left side of the body. The lowest café au lait macule was 4 cm above and to the left of the umbilicus; the highest was on the back at the level of the axilla. Several nodules extended up the left arm from the wrist. There were a few on the neck and one on the back. Biopsy of a typical nodule revealed a neurofibroma. The patient had a son and a daughter, neither of whom had café au lait spots or neurofibromas. No definite history was available regarding siblings or parents, although she did not believe there was any family history of neurofibromatosis. Her general physical health was good; she was an intelligent, active woman.

Comment

These two patients showed relatively localized manifestations of neurofibromatosis with negative family histories. Although the café au lait spots and neurofibromas usually are distributed widely over the body in this disorder, we believe that these patients do have a form of neurofibromatosis because of the clinical appearance of the lesions and the biopsy confirmation of neurofibromas. It is tentatively concluded that they had "segmental neurofibromatosis." This form of the disorder may not be rare. Because we examined these two patients in a private-practice office within a short period of time, we conclude that segmental neurofibromatosis is not rare.

Four instances of similar manifestations were reported by Crowe et al.[1] The neurofibromas were limited to the extremities in two cases: the right sacral area in one and the back in the other. Café au lait spots were present in only two cases (one spot in each). The siblings and parents were free of the disease, as were the six children of the four patients. The authors assigned the term "sectorial" to these limited manifestations, and believed that somatic mutation may have been the basis for the limited distribution. They suggested that this distribution of manifestations may be relatively easy to observe with this disorder because of the skin involvement. Diekmann et al[2] described a 9-year-old girl with localized neurofibromatosis, including hypertrophy of the clitoris and the urogenital tract. Café au lait spots were present. Nicholls[3] described two cases. The first patient was a 64-year-old woman with mediastinal neurofibromata. There were five small neurofibromas in the skin area corresponding segmentally to the site of the lesion. The second patient was an 11-year-old girl who had café au lait patches and freckles affecting the right trunk and leg in the area of the skin supplied by the eleventh thoracic to the second sacral nerve roots; however, no neurofibromas were noted. Sava et al[4] described a 9-year-old girl with lipoma of the right buttocks, segmental hypertrophy of the right buttocks and thigh, radiologically significant body hypertrophy, and a pale, coffee-colored stain on the right buttocks. A very abnormal density of the nerve fibers was found in the lipoma, with notable perineural thickening and proliferation resembling a schwannoma.

From the Veterans Administration Wadsworth Hospital Center, Los Angeles (Dr Miller) and the Divisions of Dermatology (Dr Miller) and Medical Genetics, (Dr Sparkes), University of California at Los Angeles School of Medicine.

Reprint requests to Dermatology Service, Veterans Administration Wadsworth Hospital Center, Los Angeles, CA 90073 (Dr Miller).

If it is assumed that these segmental cases are due to mutation at the same genetic locus as the more generalized inherited cases of neurofibromatosis, one has to ask why the manifestations are limited in their distribution. The unilateral and segmental pattern is in keeping with the distribution of nerves in the body. The negative family history for the disorder in the families indicates that the disorder has probably originated in the affected person and has not been inherited. In none of the segmental cases so far noted is there any apparent transmission of the disorder from the affected person to a child, although it is too early to be certain of this in younger patients, as in the 15-year-old girl we described in this report. As suggested by Crowe et al,[1] the most probable explanation is a somatic mutation that affected a single cell early in embryonic development and, through subsequent cell division, involved a number of progeny cells leading to the limited distribution in the patients. The relatively high gonadal or gametic mutation rate (1×10^{-4}) that has been suggested for this disorder[1] raises the possibility of a relatively unstable, highly mutable gene that might also be susceptible to increased mutation in somatic cells.

Other possible explanations also have to be considered. For example, the patchy occurrence of the tumors and the café au lait spots in the fully manifest variety, as well as in the limited distribution variety, may have the same mechanism. Although the explanation for this is not known in the fully expressed variety, there are other instances, such as in the Waardenburg syndrome, where there are spotty manifestations. To account for this distribution, as well as similar manifestations in other mammals, so-called pattern loci have been described. But this does not give further insight as to the mechanism involved. It may be possible also that there is a position effect occurring due to an unrecognized shift of genes in some cells from the active state to an inactive state in other cells, or vice-versa. And finally, there could be some unrecognized nongenetic factor that determines manifestation in one area of the body, but not in another.

References

1. Crowe FW, Schull WJ, Neel JV: *A Clinical, Pathological and Genetic Study of Multiple Neurofibromatosis.* Springfield, Ill, Charles C Thomas Publisher, p 181, 1956.
2. Diekmann L, Huther W, Pfeiffer RA; Ungewahnliche Erscheninungsformen der Neurofibromatose (von Recklinghausensche Krankheit) in Kindesalter. *Z Kinderheilkd* 101:191-222, 1967.
3. Nicholls EM: Somatic variation and multiple neurofibromatosis. *Hum Hered* 19:473-479, 1969.
4. Sava P, Mourat M, Carbillet JP, et al: A propos d'un Cas de Neurofibromatose avec Hypertrophie Segmentaire d'un Membro. *Sem Hop Paris* 51:1121-1127, 1975.

Pancreatic Carcinoma With Dissemination to Umbilicus and Skin

Anup K. Chakraborty, MD; Atigadda N. Reddy, MD; Saul J. Grosberg, MD; Simon Wapnick, MD

Careful examination of the umbilical area may at times yield unexpected clues to the diagnosis and the pathologic origin of intra-abdominal disease. Metastases from the pancreas may implant on the umbilicus. The mode of distribution of umbilical and paraumbilical implants in our patient with pancreatic carcinoma was most eye-compelling, and forms the substance of this report.

From the Gastrointestinal Section, Department of Medicine (Drs Chakraborty, Reddy, and Grosberg), and the Department of Surgery (Dr Wapnick), Veterans Administration Hospital, Brooklyn, NY, and State University of New York Downstate Medical Center, Brooklyn.

Reprint requests to Gastroenterology Section, 800 Poly Pl, Brooklyn, NY 11209 (Dr Grosberg).

Report of a Case

A 62-year-old man was admitted to the hospital for shortness of breath and for swelling of the abdomen and legs. Results of physical examination were consistent with congestive heart failure. In addition, a firm, irregular, 3 × 4-cm node adherent to the overlying skin was palpable in the right axilla.

The abdomen was distended; shifting dullness and fluid wave were present. On digital examination, a rectal shelf was felt. The umbilicus was protuberant and was preempted by a nodular, tender, bluish-pink mass that was irregular in contour and outline. Distributed in a straight line at an angle of 45° from the umbilical mass anteriorly and superiorly to the right subcostal area was a group of satellite lesions that was approximately 1.5 cm in diameter. These were also hard, irregular in outline and contour, and slightly tender. They were connected to one another and to the right axillary node by tender, cord-like structures lying subcutaneously. No bruits or venous hums were heard over these lesions (Figure).

The following procedures were productive in delineating the nature of the lesion and its probable site of origin.

Biopsy specimens of the right axillary node and of the subcutaneous nodules showed metastatic adenocarcinoma. Celiac angiography showed entrapment and irregular narrowing of the branches of the celiac axis, as well as extrinsic compression of the splenic and portal veins (consistent with the presence of a mass in the body of the pancreas). Gastroduodenoscopy showed intraluminal protrusion of the medial wall of the descending duodenum, with mucosal congestion and scattered areas of superfi-

cial ulceration (consistent with invasive disease). Results of examination of the peritoneal fluid showed it to be an exudate in which atypical cells were seen. A scan of the liver with technetium Tc 99m sulfur colloid and gallium citrate 67 was interpreted as showing the presence of malignant neoplasm in the left lobe of the liver. We were drawn to the conclusion on the basis of the data submitted that the patient had a carcinoma of the pancreas that had seeded the abdominal cavity and liver.

Comment

The umbilical area represents the site of predilection for metastases from a host of intra-abdominal malignant neoplasms, the most common of which are the stomach, colon, kidney, ovary, biliary tree, and pancreas, as well as the female breast.[1-3] Although the exact modes of spread to the umbilicus are unknown, hematogenous and lymphatic spread and spread by contiguity have been implicated. Pancreatic carcinomas are known to rapidly metastasize to the lymphatic system by permeation, embolization, and retrograde spread in the presence of lymphatic obstruction.[4]

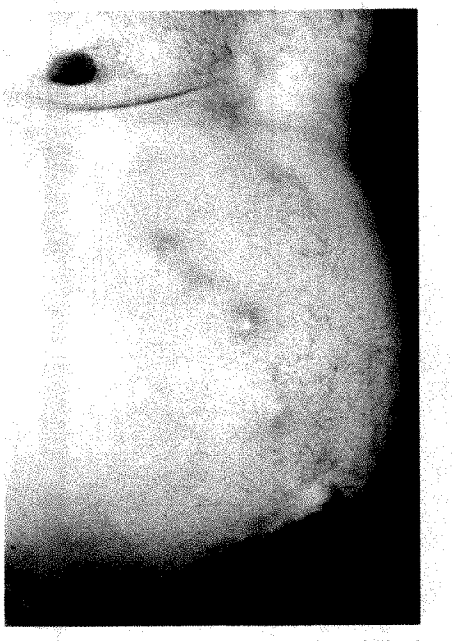

Abdomen showing ascites and umbilical and abdominal wall metastases.

In our patient the cord-like structures felt between the subcutaneous nodules most probably represent the thickened lymphatics permeated by the tumor cells. The same cord-like structures were readily traceable to the right anterior axillary nodes. These nodes normally drain the anterior abdominal wall up to the level of the umbilicus.

The clinical appearance of metastatic disease must be distinguished from endometriosis of the umbilicus, primary carcinoma of the umbilicus, benign umbilical granulomas caused by buried hairs and occasionally from infection. The finding of umbilical and skin metastases renders the primary malignant neoplasm inoperable. Our patient will receive protocol chemotherapy.

References

1. Lombardi LE, Parsons L: Carcinoma of the umbilicus metastatic from carcinoma of the stomach. *Ann Intern Med* 22:290-293, 1945.
2. Schiebel HM, Cleaver HD, Jackson JS: Metastatic carcinoma of the umbilicus. *JAMA* 157:1489-1490, 1955.
3. Clements AB: Metastatic carcinoma of the umbilicus. *JAMA* 150:556-559, 1952.
4. Glover RP, Waugh JM: The retrograde lymphatic spread of carcinoma of rectosigmoid region: Its influence in surgical procedures. *Surg Gynecol Obstet* 82:434-448, 1946.

Contact Dermatitis Caused by ECG Electrode Jelly

Ralph J. Coskey, MD

A 4-year-old boy was seen because of contact dermatitis that resulted from the use of an ECG electrode jelly (Cambridge). Patch tests proved that gum tragacanth in the jelly was responsible for the eruption. This agent is found in many different products, including foods, troches, cosmetics, toothpastes, and textile sizings.

Report of Case

A 4-year-old boy was seen on March 23, 1976 because of persistent dermatitis on his chest and extremities. He had developed the eruption two months previously, shortly after an ECG had been taken. The eruption was confined to the areas where the electrode jelly had been used for contact between the skin and the electrodes.

A diagnosis of contact dermatitis was made. The eruption resolved after topical treatment with steroids. Patch tests were performed, and the patient was found to be allergic to the electrode jelly and one of its constituents, gum tragacanth (Table). The commercially prepared jelly also contained sodium chloride, washed sand, glycerin, oil of pine (one part in 10,000), and water.

Comment

In a review of the literature of the last 13 years, I found two reports describing either allergic contact dermatitis or irritation from ECG electrode jelly. Thus, contact dermatitis from the antibacterial agent parachlorometaxylenol contained in an ECG paste (Redux) was recently reported in three cases.[1] Marked excoriation from electrode jelly applied to the skin in long-term (several hours) monitoring of the electrical activity of the heart also has been reported.[2]

In the case of my patient, gum tragacanth was the ingredient that caused the dermatitis. Tragacanth is used to suspend heavy insoluble powders, as an excipient for tablets and to impart consistency to troches. It also is used in the preparation of emulsions and emulsifying agents and

From the Dermatology Department, Wayne State University School of Medicine, Detroit.
Reprint requests to 23133 Orchard Lake Rd, Farmington, MI 48024 (Dr Coskey).

Patch Tests		
Material	Concentration and Vehicle	Results
Commercial electrode jelly (Cambridge)	As is	+
Pine oil	As is	–
Pine oil in olive oil	1:10,000	–
Gum tragacanth	1% aqueous solution	+
Glycerin	As is	–
Nickel sulfate	5% aqueous solution	–
Mercaptobenzothiazole Mix*	1%	–
Thiuram Mix*	1%	–
Naphthal Mix*	1%	–
Purified Protein Derivative Mix*	0.6%	–
Carba Mix*	3%	–

*From the National Program of Dermatology 1975 patch test kit. Ingredients were as follows: Mercaptobenzothiazole Mix, 0.25% mercaptobenzothiazole, 0.25% cyclohexylbenzothiazyldisulfide, 0.25% morpholinylmercaptobenzothiazole; Thiuram Mix, 0.25% tetramethylthiuram disulfide, 0.25% tetramethylthiuram monosulfide; 0.25% tetraethylthiuram disulfide, 0.25% dipentamethylenethiuram disulfide; Naphthal Mix, 0.5% phenyl-β-naphthylamine, di-β-naphthyl-p-phenylenediamine; Carba Mix, 1% 1,3-diphenylguanidine, 1% bis (diethyldithiocarbamato) zinc, bis (dibutyldithiocarbamato) zinc.

may be found in foods, candies, adhesives, cosmetics, toothpastes, depilatories, and other topical agents. In addition, it is used in textile sizing, textile printing, and dyeing with insoluble color lakes.[3,4]

There have been very few reports of allergy due to gum tragacanth. Feinberg and Schoenkerman[5] described a patient who had an eczematous eruption of the hands who had used a lotion with gum tragacanth. This patient had a marked reaction from tragacanth. Brown and Crepea[6] described a man with asthma and generalized urticaria that they attributed to gum tragacanth found in a tripelennamine tablet (Pyribenzamine). Gelfand[7] reported the cases of ten patients who developed one or more of the following symptoms: rhinitis, gastrointestinal symptoms, urticaria, cough, angioneurotic edema and/or asthma after ingestion of one or more of the following gums—tragacanth, karaya, and arabic.

My patient had been exposed to gum tragacanth in many foods, and has not developed allergic symptoms. Thus, he appears to only be allergic to the agent topically.

Timothy Pegnim of Cambridge Instrument Co, provided the ingredients of the electrode jelly.

References

1. Storrs FJ: Para-chloro-meta-xylenol allergic contact dermatitis in seven individuals. *Contact Dermatitis* 1:211-213, 1975.
2. Cox JM, Beltrame E: A non-irritating jelly for long-term electrocardiographic monitoring. *Anaesthesia* 24:267-268, 1969.
3. Fisher AA: *Contact Dermatitis*, ed 2. Philadelphia, Lea & Febiger Publishers, 1973, pp 172-173.
4. Stecher PG, Windholz M, Leahy DS, et al (eds): *Merck Index of Chemicals and Drugs*, ed 7. Rahway, NJ, Merck & Co, 1960, p 1055.
5. Feinberg SM, Schoenkerman BS: Karaya and related gums as causes of atopy. *Wis Med J* 39:734, 1940.
6. Brown EB, Crepea SB: Allergy (asthma) to ingested gum tragacanth. *J Allergy* 18:214-215, 1947.
7. Gelfand HH: Vegetable gums by ingestion in the etiology of allergic disorders. *J Allergy* 20:311-321, 1949.

KENALOG® SPRAY
Triamcinolone Acetonide Aerosol N.F.

DESCRIPTION: Kenalog Spray (Triamcinolone Acetonide Aerosol N.F.) provides 3.3 mg. triamcinolone acetonide per 50 grams in an isopropyl palmitate vehicle with alcohol (4.7%) and propellants.

INDICATIONS: Kenalog Spray (Triamcinolone Acetonide Aerosol N.F.) is indicated for relief of the inflammatory manifestations of corticosteroid-responsive dermatoses.

CONTRAINDICATIONS: Topical steroids are contraindicated in viral diseases of the skin, such as vaccinia and varicella, and in patients with a history of hypersensitivity to any product component. This preparation is not for ophthalmic use. Topical steroids should not be used when circulation is markedly impaired.

WARNINGS: Usage in Pregnancy— Although topical steroids have not been reported to have an adverse effect on the fetus, the safety of their use during pregnancy has not been absolutely established; therefore, they should not be used extensively on pregnant patients, in large amounts, or for prolonged periods of time.

PRECAUTIONS: Administer suitable antifungal or antimicrobial therapy if infection exists; if there is not a prompt, favorable response, discontinue the corticosteroid until the infection has been adequately controlled. Discontinue the drug and institute appropriate therapy if irritation develops. If extensive areas are treated or if the occlusive technique is used, the possibility exists of increased systemic absorption of the corticosteroid and suitable precautions should be taken. When used about the face, the eyes should be covered and inhalation of the spray avoided.

ADVERSE REACTIONS: The following local adverse reactions have been reported with topical corticosteroids either with or without occlusive dressings: burning sensations, itching, irritation, dryness, folliculitis, secondary infection, skin atrophy, striae, miliaria, hypertrichosis, acneform eruptions, maceration of the skin and hypopigmentation; contact sensitivity to a particular dressing material or adhesive may occur occasionally. Some patients (particularly those with very dry skin or dry lesions) may find the cooling effect of the spray objectionable or complain of a transient burning or stinging sensation.

For full prescribing information, consult package insert.

HOW SUPPLIED: Kenalog Spray (Triamcinolone Acetonide Aerosol N.F.) is available in spray dispenser cans of 50 and 150 g. with adapter.

SQUIBB®

©1977 E.R.Squibb & Sons, Inc. 327-503

ANOTHER CASE FOR KENALOG®
TRIAMCINOLONE ACETONIDE

"INTRACTABLE" SCALP PSORIASIS

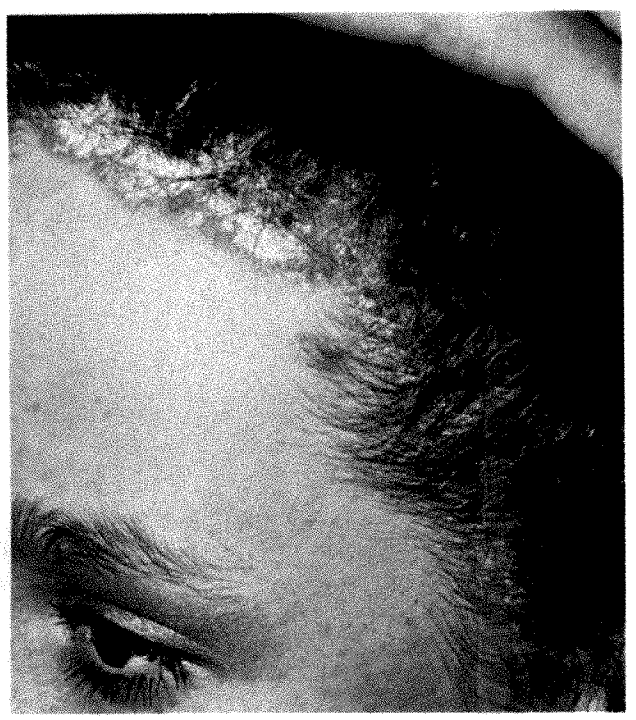

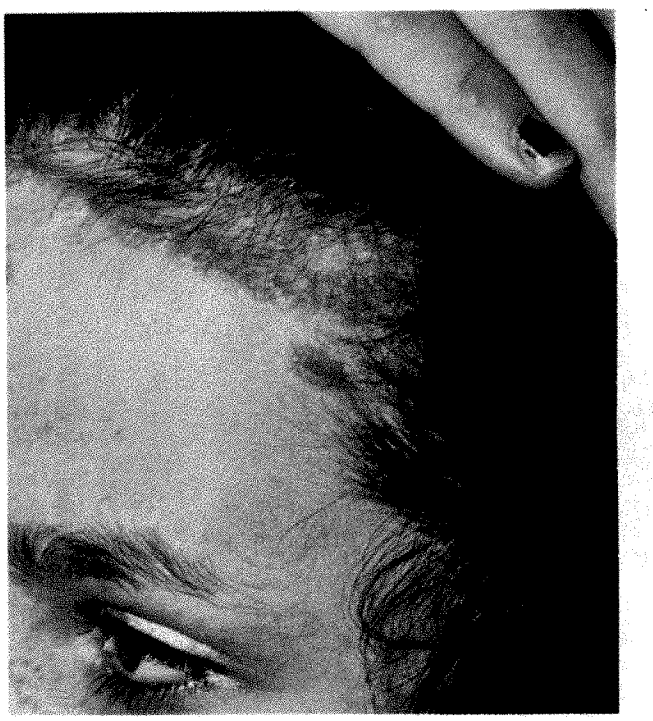

MARCH 4, 1977

A 15-year-old patient complaining of severe, intractable psoriasis of the scalp. Previous therapy with tar shampoo, keratolytic agents and fluorinated topical steroids had been unsuccessful. Because prior topical agents had been difficult to apply, Kenalog® Spray b.i.d. was prescribed.

Patient reported that pruritus had been relieved promptly. Marked improvement observed at this time: absence of scales, decrease in erythema and central clearing of plaques. Patient continuing on Kenalog® Spray b.i.d.
Case history on file at Squibb Institute for Medical Research.

AFTER 1 WEEK

A CASE FOR KENALOG® SPRAY

TRIAMCINOLONE ACETONIDE AEROSOL N.F.

See adjacent column for brief summary

Acne illustrated by artist.

VECTRIN Capsules, 100 mg
(minocycline HCl capsules, USP)
Brief Summary of Prescribing Information

Indicated in severe acne as adjunctive therapy. Consult package insert for complete prescribing information.

Contraindication: Hypersensitivity to any tetracycline.

Warnings: When need for intensive treatment outweighs potential dangers, perform renal and liver function tests before and during therapy; also follow serum concentrations. In renal impairment, usual doses may lead to excessive accumulation and liver toxicity. Under such conditions, use lower total doses, and, in prolonged therapy, determine serum levels. The use of tetracyclines during tooth development (last half of pregnancy, infancy, and childhood to the age of 8 years) may cause permanent discoloration of the teeth (yellow-gray-brown). This is more common during long-term use but has been observed following repeated short-term courses. Enamel hypoplasia has also been reported. Tetracyclines, therefore, should not be used in this age group unless other drugs are not likely to be effective or are contraindicated. Photosensitivity manifested by an exaggerated sunburn reaction has been observed in some individuals taking tetracyclines. Advise patients apt to be exposed to direct sunlight or ultraviolet light that such reaction can occur, and discontinue treatment at first evidence of skin erythema. Studies with minocycline HCl indicated that photosensitivity did not occur. However, reports have been received. In patients with significantly impaired renal function, the antianabolic action of tetracycline may cause an increase in BUN leading to azotemia, hyperphosphatemia, and acidosis. **CNS side effects:** (light-headedness, dizziness, vertigo) have been reported, may disappear during therapy, and always disappear rapidly when drug is discontinued. Caution patients who experience these symptoms about driving vehicles or using hazardous machinery while taking this drug. **Pregnancy:** In animal studies, tetracyclines cross the placenta, are found in fetal tissues, and can have toxic effects on the developing fetus (often related to retardation of skeletal development). Embryotoxicity has been noted in animals treated early in pregnancy. The safety of minocycline HCl for use during pregnancy has not been established. **Newborns, infants, and children:** All tetracyclines form a stable calcium complex in any bone-forming tissue. Prematures, given oral doses of 25 mg/kg every six hours, demonstrated a decrease in fibula growth rate reversible when drug was discontinued. Tetracyclines

PD-JA-1463-2-P (1-76)

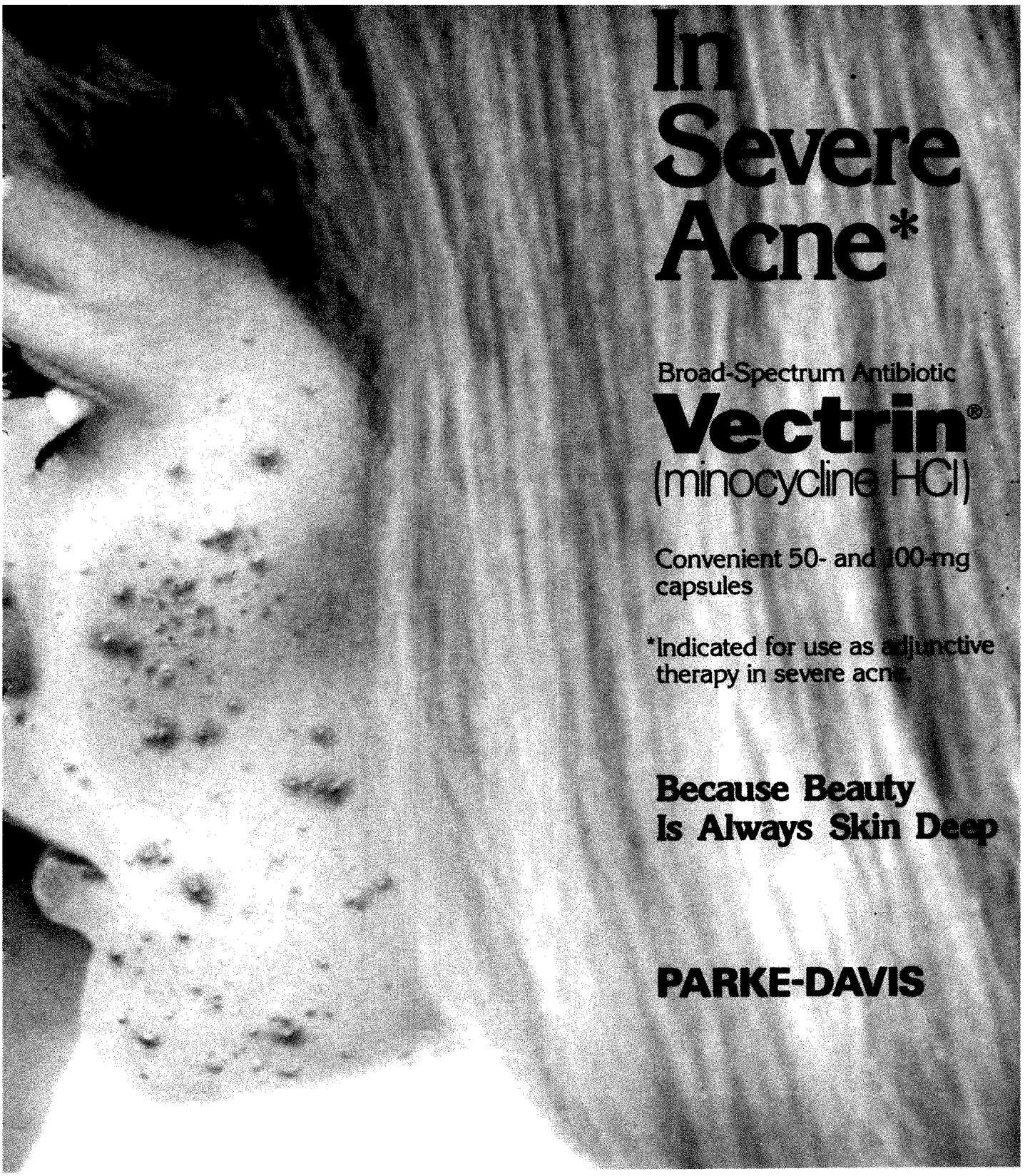

In Severe Acne*

Broad-Spectrum Antibiotic

Vectrin®

(minocycline HCl)

Convenient 50- and 100-mg capsules

*Indicated for use as adjunctive therapy in severe acne.

Because Beauty Is Always Skin Deep

PARKE-DAVIS

are present in the milk of lactating women who are taking a drug in this class.

Precautions: Use may result in overgrowth of non-susceptible organisms, including fungi. If superinfection occurs, antibiotics should be discontinued and appropriate therapy instituted. In venereal diseases when coexistent syphilis is suspected, darkfield examination should be done before treatment is started and blood serology repeated monthly for at least four months. Patients on anticoagulant therapy may require downward adjustment of such dosage. Test for organ system dysfunction (eg, renal, hepatic, and hemopoietic) in long-term use. Treat all group A beta-hemolytic streptococcal infections for at least 10 days. Avoid giving tetracycline in conjunction with penicillin.

Adverse Reactions: GI: Anorexia, nausea, vomiting, diarrhea, glossitis, dysphagia, enterocolitis, inflammatory lesions (with monilial overgrowth) in anogenital region. **Skin:** Maculopapular and erythematous rashes. Exfoliative dermatitis (uncommon). Photosensitivity is discussed above. (See Warnings.) **Renal toxicity:** Rise in BUN, dose-related. (See Warnings.) **Hypersensitivity reactions:** Urticaria, angioneurotic edema, anaphylaxis, anaphylactoid purpura, pericarditis, exacerbation of systemic lupus erythematosus. In young infants, bulging fontanels have been reported following full therapeutic dosage; disappearing rapidly when drug was discontinued. **Blood:** Hemolytic anemia, thrombocytopenia, neutropenia, eosinophilia. **CNS:** (See Warnings.) When given over prolonged periods, tetracyclines may produce brown-black microscopic discoloration of thyroid glands; no abnormalities of thyroid function studies are known to occur.

NOTE: Concomitant therapy: Antacids containing aluminum, calcium, or magnesium impair absorption; do not give to patients taking oral tetracycline. Studies to date indicate that absorption of VECTRIN (minocycline hydrochloride) is not notably influenced by foods and dairy products.

Full prescribing information available upon request.

PARKE, DAVIS & COMPANY
Detroit, Michigan 48232

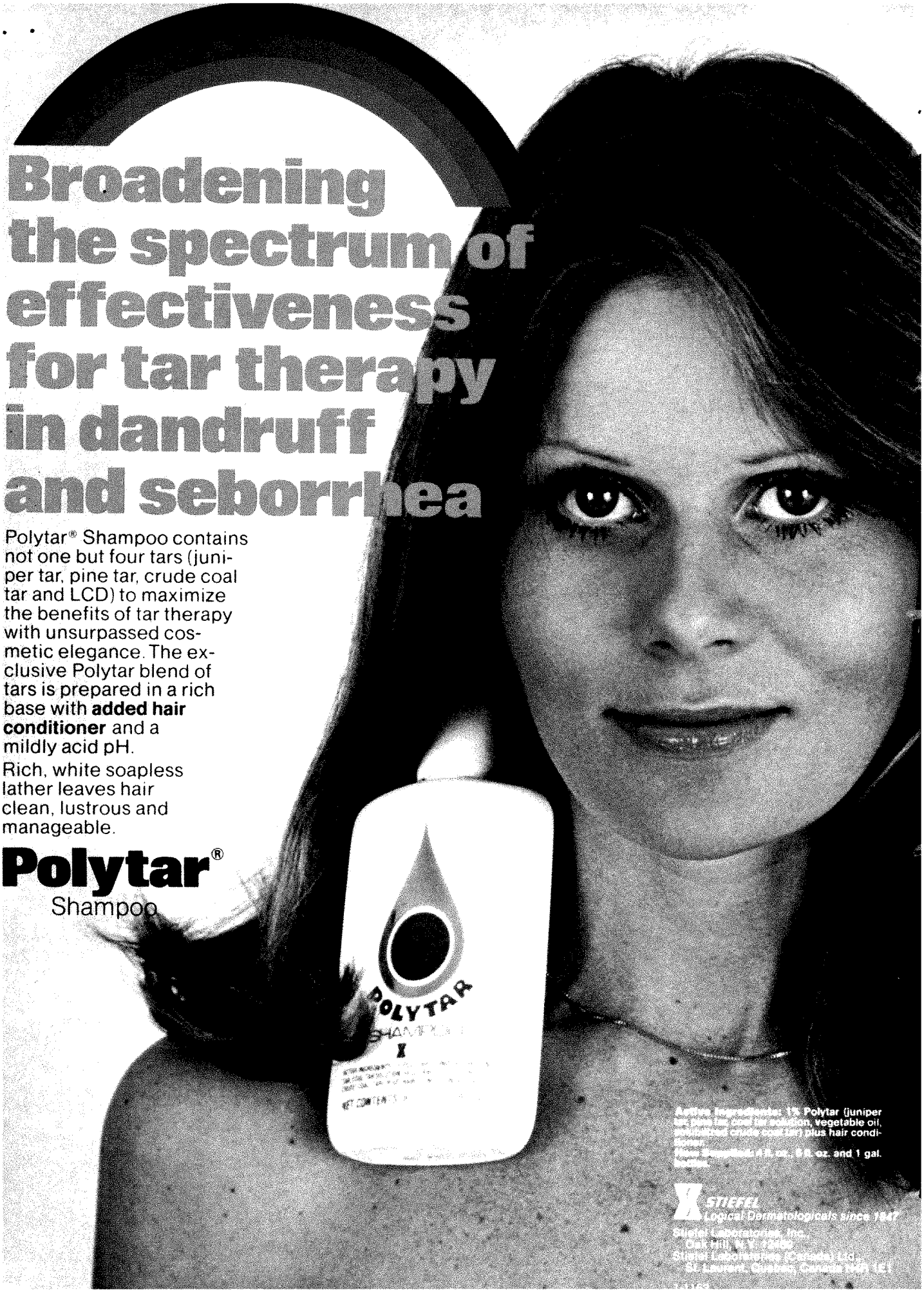
Broadening the spectrum of effectiveness for tar therapy in dandruff and seborrhea
Polytar® Shampoo contains not one but four tars (juniper tar, pine tar, crude coal tar and LCD) to maximize the benefits of tar therapy with unsurpassed cosmetic elegance. The exclusive Polytar blend of tars is prepared in a rich base with **added hair conditioner** and a mildly acid pH.
Rich, white soapless lather leaves hair clean, lustrous and manageable.
Polytar®
Shampoo

Active Ingredients: 1% Polytar (juniper tar, pine tar, coal tar solution, vegetable oil, sulfonated crude coal tar) plus hair conditioner.
Now Supplied: 4 fl. oz., 8 fl. oz. and 1 gal. bottles.
STIEFEL
Logical Dermatologicals since 1847
Stiefel Laboratories, Inc.
Oak Hill, N.Y. 12459
Stiefel Laboratories (Canada) Ltd.
St. Laurent, Quebec, Canada H4R 1E1

Psoriasis and Bullous Pemphigoid

To the Editor.—Bullous pemphigoid was described as a distinct clinical entity by Lever[1] in 1953 and has been reported to have occurred with several autoimmune diseases, ie, systemic lupus erythematosus (SLE),[2] polymyositis,[3] and rheumatoid arthritis.[4] It has also been occasionally reported with other cutaneous diseases: Kaposi sarcoma,[5] lichen planus,[6] and pemphigus.[7]

We report here on a patient with psoriasis in whom bullous pemphigoid developed after ultraviolet exposure.

Report of a Case.—A 59-year-old man was hospitalized in June 1975 with a six-month history of psoriasis. Two weeks before admission he had a generalized psoriatic flare that evolved into an exfoliative erythroderma. Past medical history was unremarkable. Physical examination revealed generalized erythroderma, with distinct psoriatic plaques on the elbows, knees, legs, back, and chest. Laboratory studies were as follows: hemoglobin, 13.6 gm/100 ml; hematocrit, 42.9%; total leukocyte count 9.6%, with 25% band forms, 40% polymorphonuclear leukocytes, 18% eosinophils, 1% basophils, 12% lymphocytes, and 4% monocytes. Results from urine analysis were normal. Results from stool tests for occult blood were normal three times; a chest x-ray film was normal; ECG was normal; and 12-factor automated chemical analysis had normal parameters.

The patient was started on a Goeckerman regimen. He received daily tar baths, followed by graduated exposure to ultraviolet light (UVL) (UV-B). Seven days after the institution of UVL therapy, a generalized bullous eruption developed over the patient's entire body.

Immunofluorescence studies disclosed the presence of IgG and C3 on the skin basement membrane zone (BMZ). A serum anti-BMZ antibody titer of 40 was also noted. Ultraviolet light and tar therapies were discontinued; wet dressings and topical steroids were instituted. In view of his psoriasis, the patient was not given steroids for systemic effect. After 15 days of intense topical therapy, the psoriasis had improved and new blisters no longer developed.

The patient remained blisterfree for one month. Repeat direct immunofluorescence again revealed IgG and C3 on the BMZ and an anti-BMZ serum titer was 40. The patient was given azathioprine, 100 mg/day. His blisters gradually disappeared during a period of approximately five weeks.

He has had no recurrence of blisters during the past nine months. All previous sites have healed, leaving hyperpigmented macular areas. Indirect immunofluorescence studies now fail to demonstrate BMZ serum antibodies. Direct immunofluorescence studies still demonstrate weak pure IgG BMZ deposition. The azathioprine has been reduced from 100 to 50 mg/day. The psoriasis is well controlled at present.

Cram et al[8] have shown that UVL exposure of normal-appearing skin of patients with bullous pemphigoid can produce fresh lesions with typical histological and immunohistochemical changes. We think this patient's clinical course may represent the same phenomenon.

A. Razzaque Ahmed, MD
Norman W. Winkler, MD, PhD
Buffalo, NY

Nonproprietary Name and Trademark of Drug

Azathioprine—*Imuran.*

1. Lever WF: Pemphigus. *Medicine* 32:1-123, 1953.
2. Jordon RE, Muller SA, Hale WL, et al: Bullous pemphigoid associated with systemic lupus erythematosus. *Arch Dermatol* 99:17-25, 1969.
3. Bullous pemphigoid with polymyositis and co-existing contact dermatitis, SOCIETY TRANSACTIONS. *Arch Dermatol* 94:672, 1966.
4. Lillicrap DA: Rheumatoid arthritis and pemphigoid. *Proc R Soc Med* 56:921-922, 1963.
5. Bullous pemphigoid and Kaposi's sarcoma, SOCIETY TRANSACTIONS. *Arch Dermatol* 101:690-691, 1970.
6. Stingl G, Holubar K: Coexistence of lichen planus and bullous pemphigoid *Br J Dermatol* 93:313-320, 1975.
7. Chorzelski TP, Maciejowsk. E, Jablonska S, et al: Coexistence of pemphigus and bullous pemphigoid. *Arch Dermatol* 109:849-853, 1974.
8. Cram DL, Fukuyama K: Immunohistochemistry of ultraviolet-induced pemphigus and pemphigoid lesions. *Arch Dermatol* 106:819-824, 1972.

Dapsone-Induced Neuropathy

To the Editor.—In regard to the article by Fredericks et al (ARCHIVES 112:1158-1160 1976), the case of sulfone neuropathy conforms to those previously reported. Neuropathy was confined to motor nerves and appeared only after prolonged high-dose therapy. We describe here a case that demonstrates features of sulfone neuropathy not usually seen, ie, occurrence after low-dose treatment, and sensory nerve involvement.

Report of a Case.—A 25-year-old man had been in good health except for severe cystic acne vulgaris of 2½ years' duration. Initial treatment elsewhere was with prednisone, 20 mg daily for two years, without significant improvement. Six months before admission he consulted us; prednisone therapy had been recently discontinued and he was now treated with 1 gm of tetracycline and 500 mg of erythromycin daily. He showed only slight improvement, and three months later sulfone therapy was begun. Results of a RBC glucose-6-phosphate dehydrogenase test were normal. Initial dosage was 50 mg daily, and this was increased to 200 mg daily during a two-week period. The patient was maintained on a regimen of erythromycin and tetracycline. However, after receiving dapsone therapy for 6½ weeks he noted difficulty in walking, and after eight weeks he could no longer stand on his toes.

Examination of the skin revealed acne cysts, erythematous papules, and pustules on the face, back, and chest. There was considerable scarring in these areas. Large striae were present on all extremities. Results of physical examination were otherwise normal except for the neurological findings that showed an abnormal gait with dragging of both feet. Ankle jerks were absent bilaterally. Moderate weakness was observed in the gastrocnemius, anterior, and posterior tibialis muscles bilaterally; considerable weakness was present in the flexor and extensor halluces longus and in the digitorum longus. On sensory examination, there was loss of vibratory sense in the feet, with greater involvement in the toes than in the ankles. Pinprick and position senses were normal. No motor or sensory abnormalities were noted in the upper extremities. Electrodiagnostic studies revealed a motor axonal neuropathy in the lower extremities.

Laboratory investigation revealed no abnormalities except for moderate anemia and reticulocytosis secondary to sulfone administration.

One week after dapsone therapy was discontinued, there was a definite increase in muscle strength. After six weeks, sensory and motor function had continued to improve although it had not completely returned to normal.

Comment.—This patient illustrates several interesting features of dapsone-induced peripheral neuropathy. First, severe weakness developed after our patient received a low total dose of dapsone (only 7.7. gm). Furthermore, the daily dose regimen of 200 mg is lower than in any case previously reported. Second, the neuropathy appeared after only 6½ weeks of dapsone therapy; in only one other

case has it developed so rapidly. Third, a sensory loss as well as a motor deficit in the lower extremities occurred in our patient. Of the eight reported cases, only two have had both sensory and motor involvement.[1,2]

LOUIS K. GEHLMANN, MD
WILLIAM C. KOLLER, MD
FREDERICK D. MALKINSON, MD, DMD
Chicago

Nonproprietary Name and Trademark of Drug

Dapsone—*Avlosulfon.*

1. Wyatt EH, Stevens JC: Dapsone induced peripheral neuropathy. *Br J Dermatol* 86:521-523, 1972.

2. du Vivier A, Fowler T: Possible dapsone induced peripheral neuropathy in dermatitis herpetiformis. *Proc R Soc Med* 67:439-440, 1974.

Bi-Directional Isomorphism: Co-existence of Psoriasis Vulgaris and Familial Benign Chronic Pemphigus

To the Editor.—We wish to report on the co-existence in two patients, found to be first cousins, of psoriasis vulgaris and familial benign chronic pemphigus (FBCP).

Report of Cases.—Case 1.—A woman aged 44 who came to us in 1961 with a maculopapular erythema of the axillae, perineum, natal cleft, and sub-mammary region for six years, and dry scaly psoriasis elsewhere, was regarded as having infected flexural psoriasis. After four months' treatment, she was clear. Ten years later she was referred again and after three months' treatment her lesions settled. She was referred by a third practitioner 11 months later, with a rash in the groins, and with blisters for the first time. This time the skin lesions did not respond to outpatient treatment and she was admitted to hospital for biopsy that showed a suprabasal acantholytic cleft with no dyskeratosis, and "villous" budding of the basal layer, diagnostic of FBCP. The flexures have been kept under control with occasional dilute potassium permanganate bathing and magenta paint. She now has no lesions of FBCP and the only manifestations of psoriasis are finger-nail pits and a plaque on one knee.

Case 2.—A woman aged 47, came to us in 1971 with a 40-year history of mild but widespread psoriasis that never needed hospital treatment, but that was more difficult to manage during the past four years in that some flexural lesions were painful and exudative. She showed extensive chronic psoriasis with moist flexural lesions with pustulation similar to incipient pustular psoriasis (Zumbusch). She had arthralgia of some fingers, but clinical examination was normal. The psoriasis responded satisfactorily to tar preparations and dithranol. On discharge home, her lesions were controlled with tar ointment for the glabrous lesions and potassium permanganate bathing, magenta paint, and fluocinolone acetonide 0.025% (Synalar) cream to the flexures. On admission again in October 1971, with widespread scaling psoriatic plaques and moist inflamed lesions in the intertriginous areas, pustules on the neck were noted. The psoriasis responded to routine measures and was controlled for 18 months, but on readmission in April 1973, with extensive chronic psoriasis and troublesome flexural lesions, she also had extensive nail pitting and onycholysis and psoriatic arthropathy in several interphalangeal joints. She was treated satisfactorily as before. A few months later, it was realized that she was the first cousin of the woman in case report 1 (Fig 1). A biopsy specimen from a vesicular plaque on the chest wall confirmed the diagnosis of FBCP (Fig 2). Both conditions have been kept under control since, using topical steroid/anti-microbial creams and the measures already mentioned.

Comment.—Several investigators have shown that various factors provoke characteristic lesions in FBCP. Haber and Russell[1] reported on two sisters with FBCP, observing that the sites of predilection could be accounted for by friction, moisture, and warmth; in one, lesions with typical histologic findings developed after the application of leukoplast to normal skin on the trunk.

Burns et al[2] showed that application of cultured *Candida Albicans* to previously uninvolved skin was successful in producing lesions of FBCP. Long-wave ultraviolent light rays

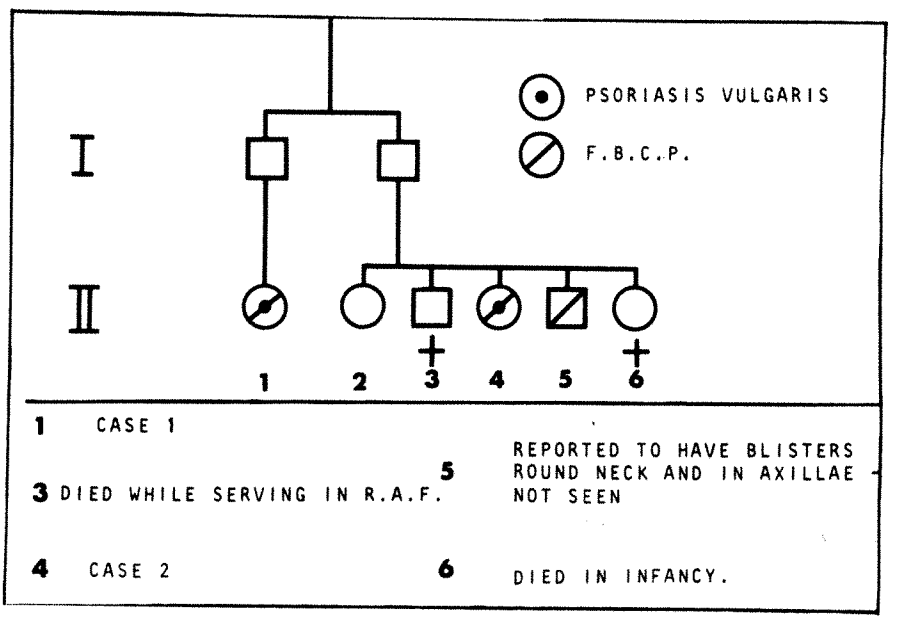

Fig 1.—Pedigree to show relationship between patients in cases 1 and 2.

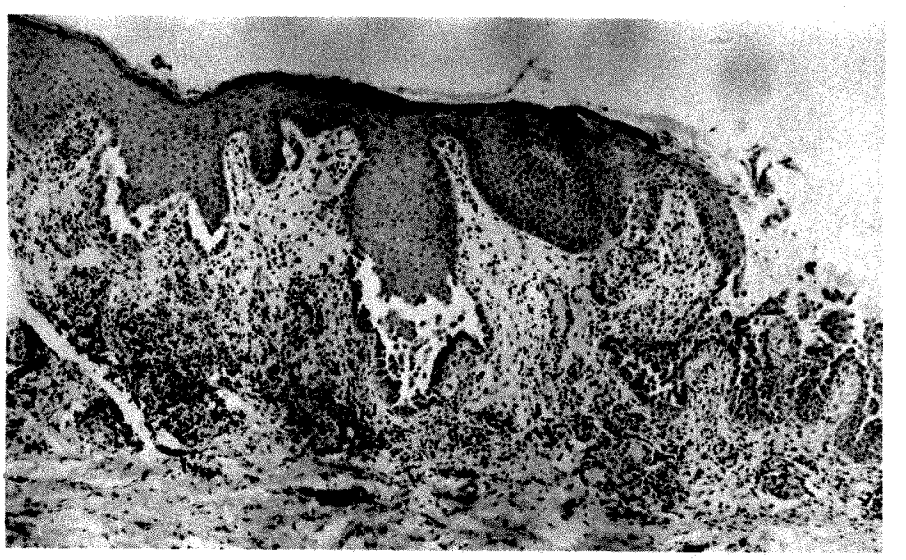

Fig 2.—Histology of vesicular area of psoriatic plaque on anterior chest wall of patient in case 2, showing typical suprabasal cleft formation and acantholysis of familial benign chronic pemphigus.

have also been shown to produce acantholysis[3] in patients known to have FBCP and in some of their relatives. That the lesions of FBCP can be an expression of isomorphism is supported by the case of Izumi et al[4] where injury with liquid nitrogen, hydration under polythene occlusion, and a positive patch test to neomycin sulfate, induced clinical and histological FBCP. Chorzelski[5] reported two cases of FBCP in which he induced acantholysis by carbon dioxide-freezing a burn at 60 C, by application of disinfectant, and by experimental staphylococcal infection. One of the subjects in their case reports had eczema and was known to be sensitive to sticking plaster, which could induce acantholysis; the other had psoriasis and demonstrated acantholytic features of FBCP in a psoriatic plaque. There has been only one other report[6] of two cases in which a clinical diagnosis of psoriasis was made and a later diagnosis of FBCP after biopsy of exudative lesions. Our second case provides a striking example of a patient in whom the lesions of FBCP occurred on nonflexural sites, preceded by typical psoriasis.

We report the cases to draw attention to the diagnostic difficulties that may occur when two conditions exhibiting isomorphism coexist in the same patient and to support the view that the sites of the lesions in FBCP can be determined by that phenomenon.

Since this article was submitted for publication, we have read of similar difficulties experienced by two other clinicians in the management of a 67-year-old female patient (ARCHIVES 112:1571-1574, 1976).

J. D. BOXLEY, MA, MB, B Chir, MRCP†
J. P. H. BYRNE, MA, MB, MRCP (I), MRCP
R. SUMMERLY, MB, ChB, FRCP, FRCPE
Stoke-on-Trent, England

†Dr Boxley died March 5, 1977.

1. Haber H, Russell B: Sisters with familial benign chronic pemphigus. *Proc R Soc Med* 43:558-560, 1950.
2. Burns RA, Reed WB, Swatek FE, et al: Familial benign chronic pemphigus: Induction of lesions by *Candida albicans*. *Arch Dermatol* 96:254-258, 1967.
3. Cram DL, Muller SA, Winkelmann RK: Ultraviolet-induced acantholysis in familial benign chronic pemphigus: Detection of the forme fruste. *Arch Dermatol* 96:636-641, 1967.
4. Izumi AK, Shmunes E, Wood MG: Familial benign chronic pemphigus: The role of trauma including contact sensitivity. *Arch Dermatol* 104:177-181, 1971.
5. Chorzelski T: Experimentally induced acantholysis in Hailey's benign pemphigus. *Dermatologica* 124:21-30, 1962.
6. Morales A, Livingood CS, Furman, H: Familial benign chronic pemphigus. *Arch Dermatol* 93:324-328, 1966.

Syncope Associated With Liquid Nitrogen Therapy

To the Editor.—Although experienced dermatologists are aware of the possibility of syncope as a complication of liquid nitrogen therapy for warts, this problem needs further emphasis.

Report of Cases.—Three patients recently fainted in our clinic. Two of the patients, both teenagers, fainted after five warts on their hands were treated with liquid nitrogen. One abruptly slumped, bruising his left temple and cutting his chin on a nearby sink. This patient had fainted once previously, at the age of 12, while visiting his brother in the hospital. The third patient, in his twenties, fainted just as the liquid nitrogen was brought into the treatment room. None of the patients had previously been treated with liquid nitrogen. All the patients were treated in the morning and had not eaten breakfast. All were seated in a chair for the cryosurgery when they fainted. Two of the patients fainted precipitously, before the physician could adequately assist them. One lost consciousness within a few seconds of feeling faint; the other did not report any ill feeling before fainting.

Comment.—Liquid nitrogen application to warts produces pain and emotional stress. For the same reasons, other forms of dermatologic surgery are performed in the recumbent position. We believe that this precaution should be taken with cryosurgery. This is especially important if the patient has not eaten breakfast or has many warts and a history of previous syncope.

ALLEN M. EPSTEIN, MD
JEROME L. SHUPACK, MD
New York

Carcinoma Occurring in Rhinophyma

To the Editor.—Rhinophyma, a glandular hyperplastic type of acne rosacea, has been reported to be associated with carcinoma.[1-5] We are reporting a case with basal and basosquamous carcinoma that provides morphologic evidence that the neoplasm arose directly from the rhinophyma.

Report of a Case.—A 65-year-old man first noted a slight swelling of his nose in 1956. In 1967 he had a small pigmented lesion excised from his nose that he stated was benign. The diagnosis of rhinophyma was made in 1973 because of excessive sebaceous activity and the presence of multiple cysts along the dorsum and tip of the nose and malar eminences. He had a chronic malodorous discharge from his nose but did not note any frank episode of infection.

In June 1975, biopsy of the rhinophyma at another hospital revealed basal cell carcinoma. He was then referred to Oakland Veterans Administration Hospital for further surgical treatment.

Physical examination showed a patient with considerably oily facial skin and with scattered epidermal cystic lesions over his malar prominences and periorbital regions. The patient's nose showed a large, bulbous rhinophyma of the tip that extended from the upper lateral, medial malar, and the lateral malar cartilages. It had deeply pitted follicles that readily exuded a creamy white material on pressure. A small scar was present at the site where the previous biopsy specimen had been taken. There was no gross evidence of tumor. The rhinophyma and basal cell carcinoma were surgically excised at the Oakland Veterans Administration Hospital.

Microscopic examination revealed typical features of rhinophyma. There was chronic inflammation, fibrosis, and dilated follicles with outward-extending hyperplastic finger-like projections. The cellular morphology of these projections ranged from no to severe dysplasia, to carcinoma in situ (Fig 1) and to carcinoma of basal and basosquamous types (Fig 2). Solar elastosis also was evident.

Comment.—Even though basal cell carcinoma occurs commonly on the nose, Acker and Helwig[6] consider the incidence of this tumor in cases of rhinophyma to be so high that a causal relationship must obtain. By means of the χ^2 table, the distribution of basal cell carcinoma in their patients with rhinophyma was compared to a large reported study of basal cell carcinoma without rhinophyma. They found a greater preponderance of basal cell carcinoma on the nose in patients with rhinophyma and considered that basal cell carcinoma will develop in greater than 5% of patients with rhinophyma.

The present report supports Helwig's statistical information and provides morphologic evidence that basal cell carcinoma arises directly from rhinophyma. In Papillary buds arising from dilated follicles, we found a spectrum of changes ranging from hyperplasia, to dysplasia, to carcinoma in situ, to invasive carcinoma. We consider this to provide a morphogenetic pathway for the development of basal cell carcinoma in rhinophyma. These finger-like projections, formed of basal cells, are a well-known feature of rhinophyma that occurs in 60% of these cases[6] but to our knowledge this case represents the first evidence for malignant transformation of these projections.

Chronic inflammation, a feature of

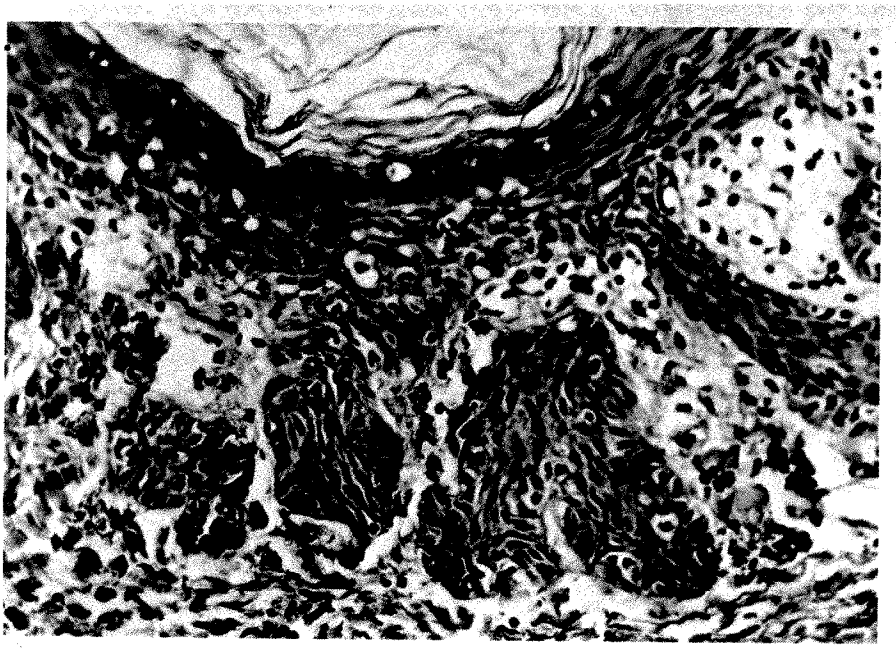

Fig 1.—There are finger-like projections extending from dilated follicle showing severe dysplasia and focal carcinoma in situ (hematoxylin-eosin, original magnification ×400).

Fig 2.—Basal cell carcinoma arising from dilated follicle (hematoxylin-eosin, original magnification ×80).

rhinophyma, may be related to the development of carcinoma. Squamous cell carcinomas are associated with chronic ulcers, chronic osteomyelitis, and burn scars.[5] Although basal cell carcinomas are not usually associated with chronic inflammatory processes, it is of interest that the tumor in the present case was partially basosquamous. Basal cell carcinomas, however, are sometimes associated with scars,[7] and the presence of fibrosis in rhinophyma may be a contributing factor.

We consider it unlikely that the tumor in this case is related to solar radiation, despite the presence of solar elastosis. Most skin carcinomas arise in sun-damaged skin,[5] as with the nose, and it has been postulated that sun exposure and sebaceous glands interact synergistically to generate basal cell carcinomas.[8] However, actinic radiation penetrates only superficially, and the tumor in this case arose deep to the solar elastosis from dilated follicles.

DANIEL B. BRUBAKER, DO
RICHARD H. HELLSTROM
Pittsburgh

1. Wende GW, Bentze CA: Rhinophyma: A pathological analysis of five separate tumors occurring in the same patient. *J Cutan Dis* 22:447-460, 1904.
2. Novy FG Jr: Rhinophyma with carcinomatous degeneration. *Arch Dermatol Syph* 22:270-273, 1930.
3. Eisenklam D: Case of carcinomatous degeneration with remarks on treatment. *Wien Klin Wochenschr* 44:1407-1409, 1931.
4. Rees TD: Basal cell carcinoma in association with rhinophyma. *Plast Reconstr Surg* 16:282-287, 1953.
5. Lever WF, Lever GS: *Histopathology of the skin.* Philadelphia, J B Lippincott Co, 1975, p 476.
6. Acker DW, Helwig EB: Rhinophyma with carcinoma. *Arch Dermatol* 95:250-254, 1967.
7. Margolis MH: Superficial multicentric basal cell epithelioma arising in thermal burn scar. *Arch Dermatol* 102:474-476, 1970.
8. Graham PK, McGavran MH: Basal cell carcinomas and sebaceous glands. *Cancer* 17:803-806, 1964.

Acquired Zosteriform Cavernous Hemangiomas: Brief Clinical Observation

To the Editor.—We were prompted to submit the following case report because of an extremely unusual distribution pattern of cavernous hemangiomas. We have been unable to find a similar example of such a patient in our search through the recent English literature. We would also like to suggest a potential hazard of the simple punch biopsy technique for deep dermal or subcutaneous nodules.

Report of a Case.—A 62-year-old man was admitted to Michael Reese Medical Center, Chicago, for the evaluation of progressive arthralgias and arthritis. During this admission, a dermatological consultation was obtained for the evaluation of large, multiple, nodular lesions of his trunk. The nodules were first noted 30 years ago. The lesions had been completely asymptomatic and had not varied in color or size. He denied a family history of similar lesions. His medical history and review of systems were noncontributory.

Physical examination revealed a well-developed man in moderate discomfort from diffuse arthralgias. Examination of the skin of the trunk revealed multiple, firm, freely movable, variably sized and shaped, deep dermal and subcutaneous nodules. They were flesh colored and arranged in a zosteriform pattern over the T-8 and T-9 dermatomes extending from the paraspinal to the midclavicular area (Fig 1).

Significant laboratory studies revealed a

normochromic anemia, a Westergren ESR of 114 mm/hr (normal for men, 0 to 20 mm/hr), and an antinuclear antibody titer of 1:1,280 with a speckled and homogeneous pattern. A chest roentgenogram revealed mild cardiomegaly and multiple small calcifications in the soft tissues lateral to the left rib cage. An upper and lower gastrointestinal series and a proctoscopic examination were normal.

One of the nodules on the lateral trunk was excised in toto. Hematoxylin-eosin sections revealed a moderately well-circumscribed fibrous and vascular nodule in the subcutis. Within the nodule were irregularly dilated and variously sized tortuous vascular channels containing RBC, and fibrinous material (Fig 2). The walls of the vascular channels varied from thick, muscular, and fibrous to thin and dilated ones lined with a single layer of endothelial cells. In some areas, there was a proliferation of small capillary-sized vessels, each vessel separated by thin strips of a collagenous stroma. Surrounding the hemangioma was fibrous wall that extended and partially replaced surrounding subcutaneous fat. Hemosiderin pigment was noted in small amounts throughout the collagenous stroma. The calcifications seen on chest x-ray film were not found on histological examination.

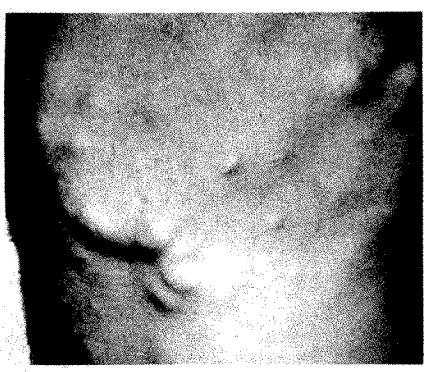

Fig 1.—Nodular cavernous hemangiomas in dermatome distribution involving chest wall of left side.

Comment.—To obtain an accurate differential diagnosis of zosteriform lesions of the skin and subcutis, one can classify them into vascular and nonvascular categories. The most commonly occurring vascular lesions known to present in a unilateral or dermatome distribution are nevus flammeus,[1,2] unilateral telangiectasias,[3-5] angiokeratoma corporis circumscriptum, and angioma serpiginosum.[2] These lesions can be readily distinguished from those of our patient on clinical morphology alone. Maffucci's hemangiomatosis can be eliminated from the differential diagnosis because of the absence of dyschondroplasia and noticeable bone deformities on roentgenographic and physical examinations. Of the common nonvascular lesions that may occur in a linear or dermatome pattern, one should consider those of congenital origin (eg, Darier-White disease and unilateral epidermal nevi) and of acquired origin (eg, lichen planus, herpes zoster, and lichen striatus). These can also be differentiated by their clinical morphology.

Nodular unilateral or dermatome lesions that cannot be easily differentiated solely on clinical morphology include multiple lipomas, neurofibromas,[6] leiomyomas, blue rubber bleb nevi,[7] lymphangioma cavernosum, vascular hamartomas,[1,7] and metastatic tumors. To differentiate these lesions from those of our patient requires a tissue biopsy.

Several observations can be made from the findings from this patient. First, one should now consider in the diagnostic possibilities of unilateral or dermatome lesions the entity zosteriform cavernous hemangiomas. Second, individuals found to have such vascular tumors in one area should be carefully evaluated for similar lesions in other sites. This is especially important in patients with hepatomegaly, gastrointestinal bleeding, seizures, or bone pain. In addition, the roentgenographic findings of soft tissue calcifications in a dermatome area may be suggestive but are not pathognomonic of zosteriform cavernous hemangiomas.

Dermatologists presented with unknown nodules in the skin are almost reflexly inclined to use a punch biopsy on such lesions. We would simply suggest, in the light of our case, that some caution be used under such circumstances.

DAVID M. STEINWAY, DO
DAVID F. FRETZIN, MD
Chicago

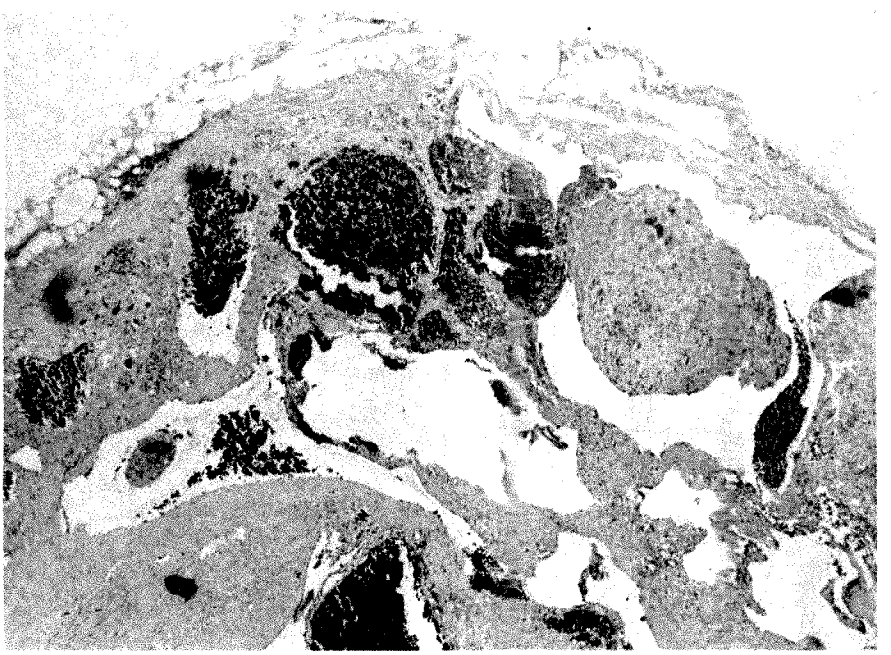

Fig 2.—Subcutaneous cavernous hemangiomas showing irregularly dilated and variously sized vascular channels containing RBCs (hematoxylin-eosin, original magnification ×40).

1. Fitzpatrick TB, Arndt KA, Clark WH, et al: *Dermatology in General Medicine*. New York, McGraw-Hill Book Co, 1971, pp 533-549.
2. Lever WF: *Histopathology of the Skin, ed 4*. Philadelphia; JB Lippincot Co, 1967, pp 1093-1110.
3. Aram H, Solomon LM: Linear telangectasias. *Acta Derm Venereol* 50:302-304, 1970.
4. Selmanowitz VJ: Unilateral nevoid telangiectasia. *Ann Intern Med* 73:87-89, 1970.
5. Cunliffe WJ, Dodman B, Butterworth MJ: Unilateral spider nevi. *Br J Dermatol* 87:51-52, 1972.
6. Crowe FW, Schull WJ, Neel JV: *A Clinical Pathological and Genetic Study of Multiple Neurofibromatosis*. Springfield, Ill, Charles C Thomas Publisher, 1956, p 26.
7. Fretzin DF, Potter B: Blue rubber bleb Nevus. *Arch Intern Med* 116:924-929, 1965.

Double-Blind Trial of 1% Clotrimazole Cream and Whitfield Ointment in the Treatment of Pityriasis Versicolor

To the Editor.—We have recently completed a double-blind trial of clotrimazole (Lotrimin, [Canesten (Br)]) compared with benzoic and salicylic acid (Whitfield) ointment in the treatment of pityriasis versicolor. Clotrimazole is a tritylimidazole deriva-

tive with a wide spectrum of antifungal activity including in vitro fungistatic activity against Malassezia furfur.[1] One percent clotrimazole cream is as effective as Whitfield ointment and more acceptable to the patient. Culture of Malassezia furfur showed a constant and persistent sensitivity to clotrimazole, suggesting its suitability for treatment of relapse. Clinical assessment of hypopigmented lesions at follow-up is not as reliable a test of cure as microscopy of scrapings.

Method.—During a two-year period, all patients seen in the skin department and found to be positive for Malassezia furfur on microscopy of skin scrapings were included in the trial. The patients were allotted at random to treatment with Whitfield ointment (3% salicylic acid and 6% benzoic acid in an emulsifying base) or 1% clotrimazole cream. Neither the clinician nor the patient knew which preparation was being used. All patients were instructed to apply the preparation twice daily to the affected areas for four weeks. Patients were assessed at four and eight weeks and at the end of the trial. Scrapings were cultured on pityrosporum agar, composed of malt extract, 36 gm; peptone (mycological), 6 gm; ox-bile, 20 gm; polysorbate (Tween) 80, 10 ml; Oxoid Agar No. 1, 10 gm; glycerol, (BDH) 5 ml; distilled water to 1 liter. Chloramphenicol (50 μg/ml) and cycloheximide (400 μg/ml) were also added. Cultures were incubated at 30 C for up to five days. Yeasts were identified morphologically and by their inability to grow on Sabourand dextrose agar. Sensitivity to clotrimazole was performed in which a stock solution of 10 mg/ml clotrimazole in ethanol was prepared and diluted in pityrosporum agar to give final concentrations of 6.25, 5.0, 2.5, 1.25, and 0.625 μg/per milliliter, respectively. Control plates with and without ethanol and without clotrimazole were included in each series.

Results.—Forty-five patients entered the trial. The 31 who completed eight weeks' treatment and surveillance gave a history of pityriasis versicolor varying from three months to ten years. More than 75% were 20 to 28 years old. No patient had been treated for pityriasis versicolor in the previous three months. Four weeks' treatment with either clotrimazole cream (14 patients) or Whitfield ointment (17 patients) was equally effective in curing pityriasis versicolor, 80% of the patients being mycologically clear four weeks after the end of the treatment. There was no statistically significant difference between the efficiency of the two preparations (χ^2 test with Yates correction). Burning and/or irritation was twice as common with Whitfield ointment and was noted by six patients. No other side effect occurred.

All isolates of Malassezia furfur were sensitive to clotrimazole, with a mean inhibitory concentration of 2.5 to 5.0 μg/ml.

This trial was started in 1973 since then other reports have demonstrated the clinical efficacy of clotrimazole in the treatment of pityriasis versicolor.[2,3] In a double-blind trial of 1% clotrimazole cream and Whitfield ointment in 32 patients with pityriasis versicolor, there was no statistically significant difference in response.[4] Whitfield ointment and sodium thiosulfate solution have long been used in the treatment of pityriasis versicolor and recently selenium sulfide detergent suspension has been advocated.[5-7] Vigorous application of selenium sulphide, however, runs the risk of causing toxic effects as a result of systemic absorption.[8] Complete cure has been claimed using repeat treatment with selenium sulfide every three months.[9] Repeat treatment is perhaps advisable after use of any topical agent. Clotrimazole would seem especially suitable for this because we have demonstrated that no resistance develops to it with persistent infection.

The attendance at long-term follow-up in this trial was low, preventing a meaningful analysis of relapse rates. Clinical assessment of patients with hypopigmented lesions at follow-up was not a reliable criterion of infection. Such lesions were not all positive mycologically, suggesting that hypopigmentation is a postinfective and postinflammatory phenomenon. Mycology should, therefore, be performed as a test of cure in these cases.

ROGER CLAYTON, MB, MRCP
ANTHONY DU VIVIER, MB, MRCP
MICHAEL SAVAGE
London

Drs M. Feiwel and L. Fry allowed us to study their patients and Dr R. R. Davies provided the laboratory in which the mycological studies were performed.

Dr C. S. Good of Bayer laboratories supplied the medicaments and assistance throughout the study.

Nonproprietary Names and Trademarks of Drugs

Clotrimazole.—*Gyne-Lotrimin, Lotrimin.*
Cycloheximide.—*Actidione.*
Benzoic and salicylic acid ointment.—*Whitfield ointment.*

1. Pempel M, Bartmann K: Experimental studies on the antimycotic action of clotrimazole (Canesten in vitro and after local application in vivo. *Drugs Made in Germany* 15:103, 1972.

2. Poleman G: Clinical experience in the local treatment of dermato-mycoses with Canesten (R), clinical excerpts *Med Mycol* 27:1183, 1973.

3. Gip L: The topical therapy of pityriasis versicolor with clotrimazole. *Postgrad Med J* 50(suppl 1):59-60, 1974.

4. Clayton YM, Connor B: Comparison of clotrimazole cream, Whitfield's ointment and Nystatin ointment for the topical treatment of ringworm infections, pityriasis versicolor, erythrasma and candidiasis. *Br J Dermatol* 89:297-303, 1973.

5. Robinson HM Jr, Yaffe SN: Selenium sulfide in the treatment of pityriasis versicolor. *JAMA* 162:113-114, 1956.

6. Leven NE: Selenium sulfide suspension in the treatment of tinea versicolor. *Arch Dermatol* 75:128-129, 1957.

7. Albright SD II, Hitch JM: Rapid treatment of tinea versicolor with selenium sulfide. *Arch Dermatol* 93:460-462, 1966.

8. Ransome JW, Scott NM Jr: Selenium sulfide intoxication. *N Engl J Med* 264:384-385, 1961.

9. Hersle K: Selenium sulfide treatment of tinea versicolor. *Acta Derm Venerol* 51:476-478, 1971.

Ferrous Iron and Porphyria Cutanea Tarda

To the Editor.—In recent studies ferrous iron has been implicated in the pathogenesis of porphyria cutanea tarda (PCT) because of its inhibition of uroporphyrinogen decarboxylase and uroporphyrinogen III cosynthetase.[1,2] Taljaard et al[3] suggested that beneficial effects of chloroquine treatment may be related to reduction in a specific pool of liver iron. These authors demonstrated increased urinary iron excretion in several patients with PCT who were treated with chloroquine sulfate. Since we have not found any other reports concerning urinary iron excretion in patients with PCT, we would like to describe briefly an additional case.

Report of Case.—In March 1976, a 60-year-old woman consulted us with an eight-month history of blisters developing over the dorsa of the hands after sunlight exposure. She subsequently noted some tightening of the skin over the arms and neck. In the past six weeks she had noted no new blisters. The patient reported that her urine appeared darker than usual and had a foul odor. She was taking no medications.

Physical examination revealed numerous erythematous, slightly atrophic areas over the dorsa of the hands and fingers at sites of previous blister formation. Milia were numerous. No vesicles or bullae were found. Diffuse, hypopigmented, indurated plaques of scleroderma-like changes were present over the arms, nape, upper chest, and lateral areas of the face. The urine showed intense coral-red fluorescence under the Wood lamp. Results from later studies in the hospital showed no abnormalities. Results of liver function studies and a liver scan were normal, as were serum iron levels and serum iron-binding capacity. Urinary uroporphyrin excretion was 2,240 μg for 24 hours (normal, 40 to 160 μg). The diagnosis of PCT was made. Hydroxychloroquine (Plaquenil) sulfate was given orally at a dose of 100 mg every

Urinary Porphyrin and Iron Excretion in a Patient		
Date	Uroporphyrin, μg/24 hr	Iron, mEq/Liter
3/21	2,249	88
3/23	1,720	110
3/29	2,106	244
4/19	2,818	720
6/30	388	160

other day. Therapy was initiated on March 26, 1976, and the urinary excretion of uroporphyrins and iron was measured repeatedly (Table). On April 21, the dose was increased to 200 mg every other day and then to 200 mg daily on June 24. The patient's hand lesions cleared and therapy was discontinued on Aug 20, 1976.

Comment.—Interestingly, the level of this patient's urinary excretion of iron increased and then decreased after hydroxychloroquine administration, as urinary porphyrin excretion often does. Although the increase in the level of urinary iron excretion with hydroxychloroquine therapy does not finally implicate iron in the pathogenesis of the disease nor diminished iron load in its treatment response, it does provide a possible explanation for the success of hydroxychloroquine-chloroquine therapy.

RONALD D. WISE, MD
FREDERICK D. MALKINSON, MD, DMD
Chicago

1. Kushner JP, Lee GR, Nacht S: The role of iron in the pathogenesis of porphyria cutanea tarda: An in vitro model. *J Clin Invest* 51:3044-3051, 1972.
2. Kushner JP, Steinmuller DR, Lee GR: The role of iron in the pathogenesis of porphyria cutanea tarda: II. Inhibition of uroporphyrinogen decarboxylase. *J Clin Invest* 56:661-667, 1975.
3. Taljaard JJF, Shanley BC, Stewart-Wynne EG, et al: Studies on low dose chloroquine therapy and the action of chloroquine in symptomatic porphyria. *Br J Dermatol* 87:261-273, 1972.

Congenital Disseminate Organoid Tumors

To the Editor.—We recently had the opportunity to observe a newborn infant with distinctive generalized organoid tumors that appeared to represent poorly differentiated attempts at hair formation.

Report of a Case.—A 3,416-gm full-term male infant was born with milia-like papules present everywhere on the body surface except the palms and soles. Normal hair was present in normal concentration and distribution. There were metatarsus varus of the left ankle and pectus excavatum. The rest of the physical examination was normal. At five days after birth the infant experienced respiratory distress followed by low-grade fever and diarrhea. Progressive cardiopulmonary distress ended life at the 44th day. Values for all urine, stool, blood, spinal fluid, and skin cultures were negative. At autopsy, endocardial fibroelastosis in the outflow tract of the heart was found. Extensive pleomorphic inflammatory cell infiltrates were present in the media of the aorta. The pancreas contained foci of lymphocytic aggregations.

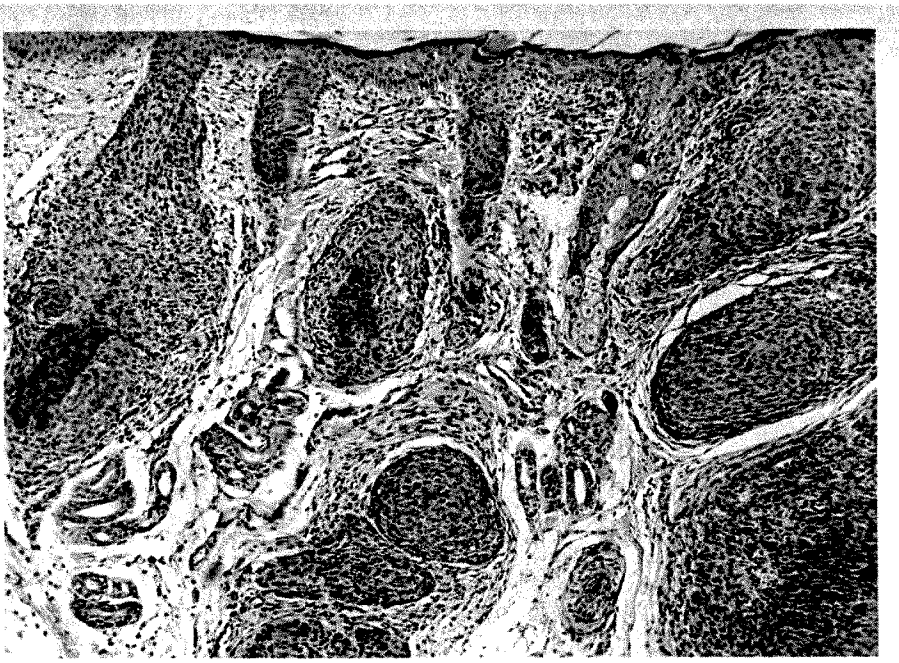

Groups of follicular units in dermis (×30).

Several skin biopsy specimens obtained before death contained single or multiple groups of poorly differentiated epidermoid cells in the mid-dermis. Most of the cells were grouped in globular masses and consisted of large vesicular cells admixed evenly with smaller dark cells. Eosinophilic hyalinized PAS-staining fibrillar material was found within these cellular groups. Occasionally, the epidermoid cells assumed a whorl formation (Fig). Within some of the masses, some basaloid cells tended to form buds.

The abnormal configurations were found either entirely within the dermis or connected to the epidermis. The dermal collagen contained an increase in fibrocytes.

Comment.—The congenital and disseminated nature of this adnexal tumor seems to be unique. The lesions numbered in the hundreds and consisted of scattered or closely set 1- to 2-mm milioid papules on the face, arms, trunk, and extremities.

Because the basaloid cells assumed bud formation, their orientation was perpendicular to the epidermis and the vesicular cells within the tumoral masses assumed a whorl-like pattern; we believe the tumors represented attempts at hair follicle formation. The presence of two cell types, clearer larger cells and smaller dark cells with fibrillar PAS and eosinophilic material, supports the broader diagnosis of organoid tumor.

Basal cell hamartomas with follicular infundibulum differentiation and plate-like basal cell proliferation were described by Mehregan and Butler[1] and Johnson and Hookerman[2] in a 52-year-old man with periorbital syringoma-like tumors. Our patient's tumor differed by its containing varying degrees of differentiation of the entire follicular structure, by its presence at birth, and by its widespread nature.

A rare form of trichoepithelioma (also a hair follicle hamartoma)[3,4] associated with alopecia in adults may be distributed in a disseminate manner. However, these contain globules of undifferentiated cells that form epithelial tracts, lobules, or a lace-like network of cells.

We believe diffuse congenital organoid tumors in infancy are another example of the varied form organoid tumors may assume.

LAWRENCE M. SOLOMON, MD
ANA M. ENG, MD
Chicago

1. Mehregan AH, Butler JD: A tumor of follicular infundibulum: Report of a case. *Arch Dermatol* 83:924-927, 1961.
2. Johnson WC, Hookerman BJ: Basal cell hamartoma with follicular differentiation. *Arch Dermatol* 105:105-106, 1972.
3. Brown AC, Crounse RG, Winkelmann RK: Generalized hair follicle hamartoma: Associated with alopecia, aminoaceduria and myasthenia-gravis. *Arch Dermatol* 99:478-493, 1969.
4. Trichoepithelioma with hair loss and myaesthenia gravis, SOCIETY TRANSACTIONS *Arch Dermatol* 97:221, 1968.

Trioxsalen Bath and Ultraviolet Light Treatment of Psoriasis

To the Editor.—Eighteen light-tolerant patients with widespread psoriasis were treated with 15 minutes of a 37 C warm bath with 50 mg of trioxsalen in 100 liters of water. The trioxsalen added was dissolved in 100 ml of 70% alcohol. Immediately after the bath, the skin was irradiated with a set of lamps for ten to 300 seconds at a distance of 60 cm.[1] The lamp gives 0.8M W/sq cm of ultraviolet (UV)-B and 13M W/sq cm of UV-A. The treatment was given five days per week. One arm was left for treatment with coal tar bath, UV light, and stiff dithranol paste.[2] After two to five weeks, the psoriasis had almost or completely healed on the trioxsalen-treated skin. The arm treated with the Ingram regimen[2] healed slower in nine patients, faster in one, and at the same rate in the others. It is possible that the light dose used in the Ingram regimen was too low. When comparing the effects it is essential that each method is used under optimal conditions. The light-sensitizing effect of the bath is even initially stronger and disappears more rapidly than after application of a local trioxsalen alcohol solution. The risk for accidental sunlight reactions is therefore less. The bath has the advantage over oral psoralen treatment in that it gives stronger sensitization with shorter treatment times and minimizes the risk for the internal side effects.

T. Fischer, MD
L. Juhlin, MD
Upsala, Sweden

1. Fischer T, Juhlin L: Behandling av psoriasis med UV-ljus tjära och psoralen. *Lakartidningen* 72:4511-4514, 1975.
2. Ingram JT: Approach to psoriasis. *Br Med J* 2:591-594, 1953.

Drs Fischer and Juhlin have presented an interesting and apparently effective method of treatment for psoriasis. However, this approach must be considered, potentially, quite dangerous in most areas of the United States, where exposure to the sun is available following the psoralen emersion. As noted by Arora and Willis, photosensitization by topically applied psoralen compounds persists at least 24 hours after exposure (Arch Dermatol *112:327-332, 1976). This potential for photosensitization may last even longer. Thus, this therapy regimen should be considered with a great deal of caution.*—Ed.

Benign Chronic Bullous Dermatosis of Childhood

To the Editor.—Prystowsky and Gilliam (*Arch Dermatol* 112:837-838, 1976) described a case that they labeled as "benign chronic bullous dermatosis of childhood," in which IgA was found deposited in a linear pattern along the dermoepidermal junction. The authors cited "the absence of a granular immunofluorescent pattern" as one factor that "excluded" the diagnosis of dermatitis herpetiformis. Since linear deposition of IgA at the dermoepidermal junction may be seen in 12% of biopsy specimens taken from adults with dermatitis herpetiformis,[1] this particular finding by no means excludes this diagnosis. As the authors point out, there is much confusion regarding the nosology of bullous diseases in childhood. The interesting finding of Prystowsky and Gilliam adds to this confusion.

David A. Voron, MD
Arcadia, Calif

1. Seah PP, Fry L: Immunoglobulins in the skin in dermatitis herpetiformis and their relevance in diagnosis. *Br J Dermatol* 92:157-166, 1975.

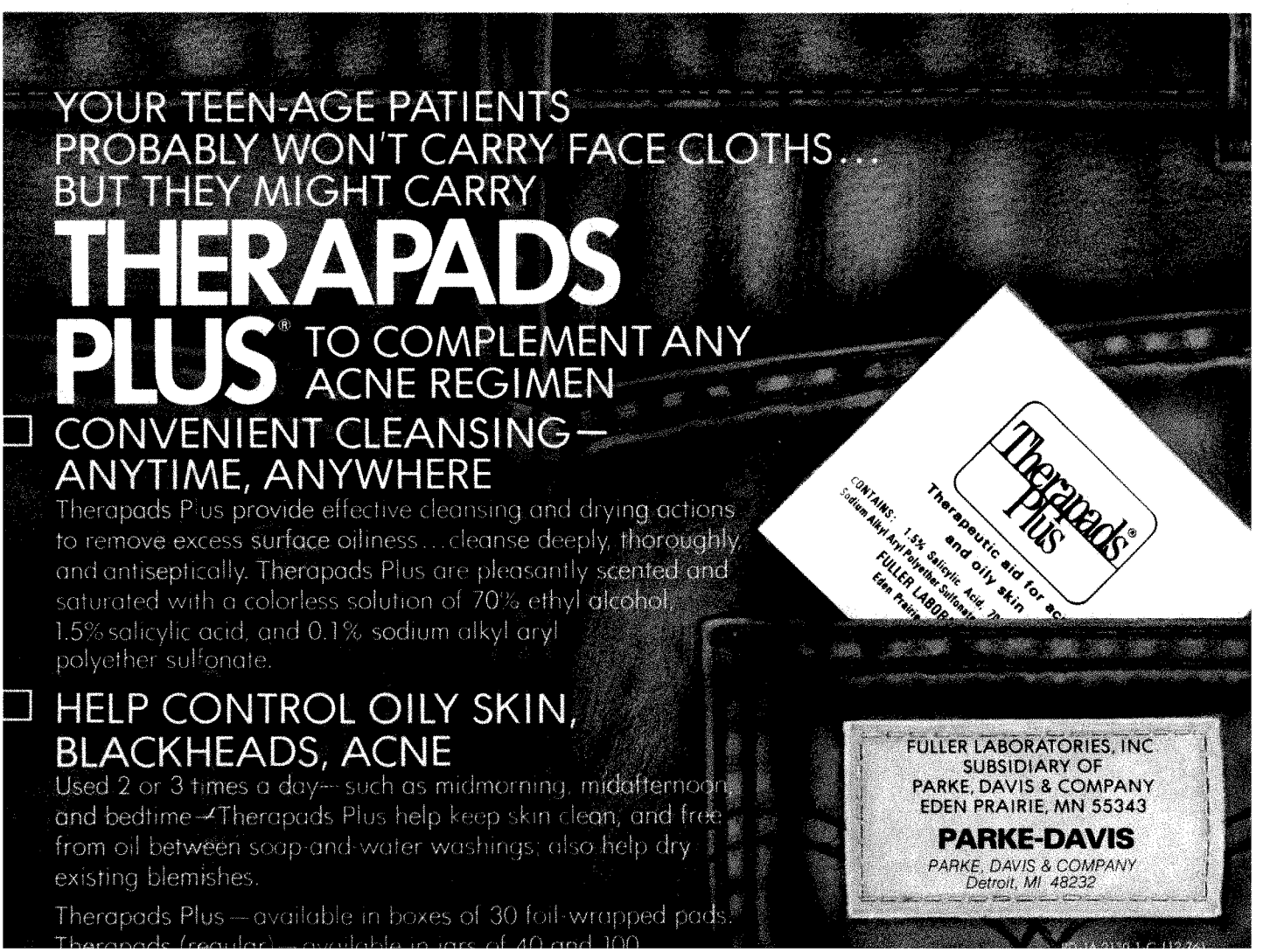



Bee-sting Allergy

Phadebas RAST® provides an accurate means of documenting IgE mediated allergic sensitivity to stinging insects.

Phadebas RAST®

the *in vitro* alternative

Pharmacia Diagnostics AB
Uppsala, Sweden

Pharmacia Diagnostics

Argentina Laboratorios Dr. Gador y Cia , S.A.C.I. Casilla de Correo 4641 BUENOS AIRES. **Australia** Pharmacia (South Seas) Pty. Ltd. P.O. Box 175 Cnr Talavera&Khartoum Roads NORTH RYDE N.S.W. 2113 **Austria** Pharmacia Gesellschaft m.b.H. Rathausplatz 4 A-1010 WIEN. Schoeller-Pharma G.m.b.H. Postfach 103 A-1111 WIEN. **Belgium** S.A. Pharmacia Belga N.V. Bld. Gen. Jacqueslaan 26 B-1050 BRUSSELS. **Brazil** Emprêsa Medimex importação e Comércio Ltda. Rua Cardoso Marinho, 40 Caixa Postal 33-ZC-00 RIO DE JANEIRO. **Canada** Pharmacia (Canada) Ltd. 2044 boul. St. Régis Blvd. DOVAL, Québec H9P 1H6. **Denmark** Pharmacia AS, Herredsvejen DK-3400 HILLERØD. **Finland** Pharmacia OY Alexandersgatan 48 A SF-HELSINGFORS 10. **France** Pharmacia France S.A. Rue de Marly Parly 2 F-78150 LE CHESNAY. **German Federal Republic** Deutsche Pharmacia GmbH Munziner Strasse 9 Postfach 5480 D-7800 FREIBURG 1. **Great Britain** Pharmacia (G.B.) Ltd. Paramount House 75 Uxbridge Road LONDON W5 5SS. **Greece** G.A. Kambanis Imports-Exports-Representations 3 Iridanou Street ATHENS 612. **Italy** Importex Chimici Farmaceutici S.p.A. P.O. Box 467 Via Flavia 122/124 I-34100 TRIESTE. **Mexico** Internacional Cientifica, S.A. Apartado 66-558 Zona 12 MEXICO 8 D.F. **The Netherlands** Gist-Brocades N.V. Diagnostics Dept. P.O. Box 324 Fridastraat 7–9 RIJSWIJK (Z H) 2109. **Norway** Norsk Pharmacia A/S Postboks 2005 Grünerløkka OSLO 5. **Portugal** J.A. Baptista D'Almeida Lda. Apartado 1339 LISBOA 1. **South Africa** Keatings Medical Industries (Pty) Ltd. P.O. Box 256 JOHANNESBURG 2000 R.S.A. **Spain** Atom Paseo del Monte 34 BARCELONA 12. **Sweden** Pharmacia Norden AB Diagnostic Dept. Box 159 751 04 UPPSALA 1. **Switzerland** Pharmacia-pdf-(Schweiz) A.G. 214 Seefeldstrasse CH-8034 ZUERICH. **USA** Pharmacia Diagnostics Division of Pharmacia Inc. 800 Centennial Avenue PISCATAWAY, New Jersey 08854. **Other countries** Pharmacia Diagnostics AB Box 17 S-751 03 UPPSALA 1, Sweden.

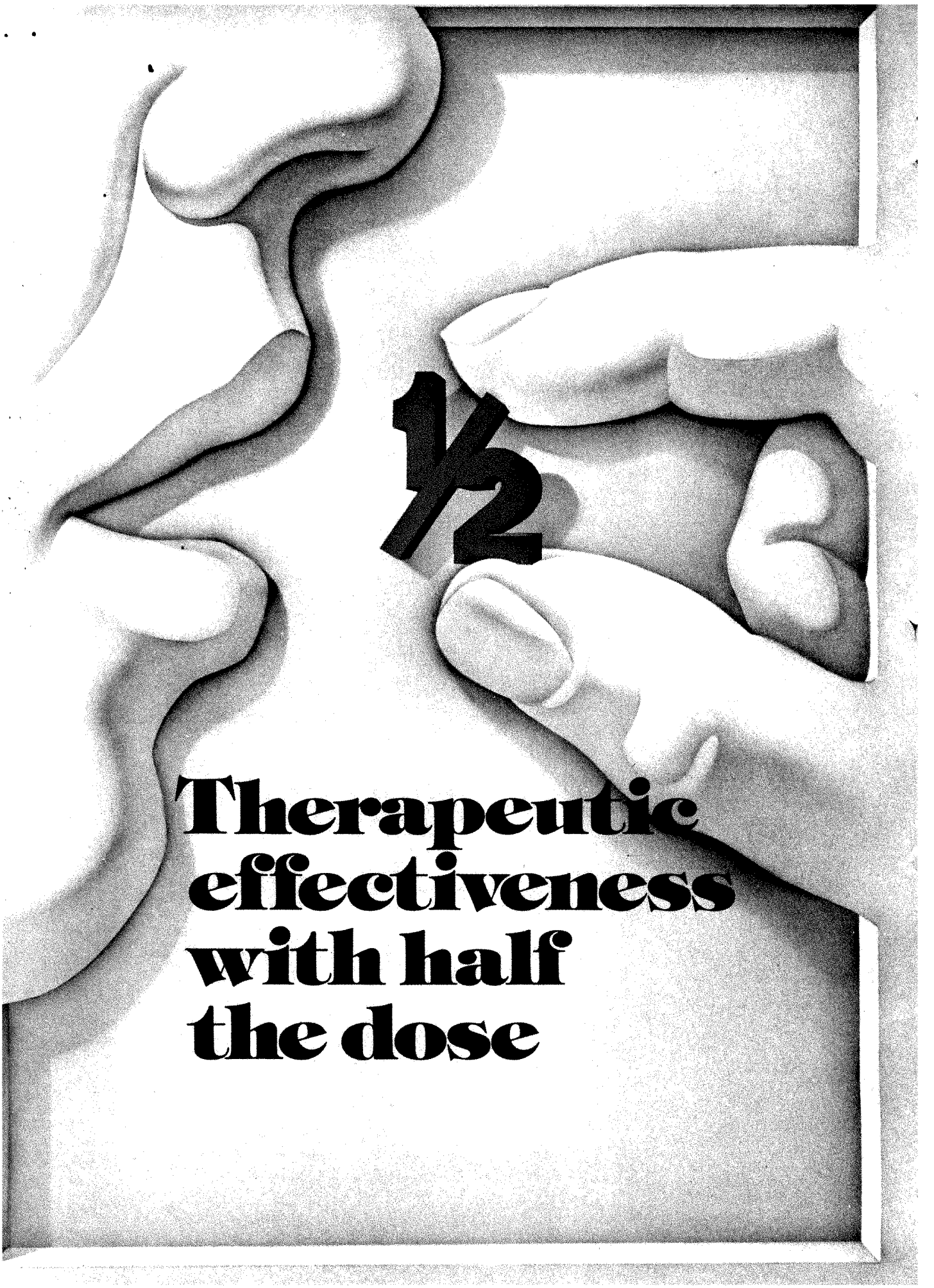
½
Therapeutic effectiveness with half the dose

Schering

Once-a-day dosage

NEW Fulvicin® P/G*

brand of griseofulvin [ultramicrosize], USP

(specially processed) **125 mg. tablets**

***"P/G" means a new polyethylene glycol system for enhanced absorption –**

A 250 mg. daily dose (two 125 mg. tablets) of new FULVICIN P/G can replace 500 mg. of griseofulvin (microsize), USP. This is made possible by a special process in which the ultramicrosize griseofulvin crystals are partly dissolved in polyethylene glycol and dispersed through the tablet matrix for enhanced absorption.

Patient convenience –

FULVICIN P/G can be prescribed as two 125 mg. tablets once a day. Compliance is further assured by the easy-to-swallow size of the tablets.

Patient savings –

FULVICIN P/G is up to 35 per cent less expensive per dose than all microsize griseofulvin formulations.**

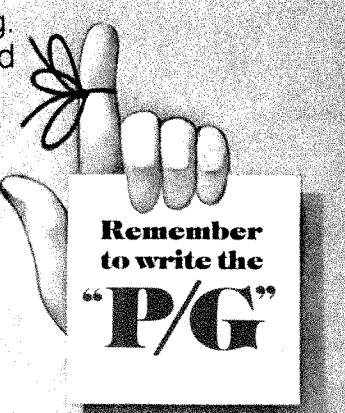

**Based on list-price comparison.

See Clinical Considerations section on following page.

COPYRIGHT ©1977, SCHERING CORPORATION. ALL RIGHTS RESERVED. SLS-703

Schering

NEW P/G
Fulvicin P/G
griseofulvin [ultramicrosize], USP
(specially processed) 125 mg. tablets

ical Considerations: INDICATIONS FULVICIN P/G Tablets are indicated the treatment of ringworm infections of the skin, hair and nails, namely, a corporis, tinea pedis, tinea cruris, tinea barbae, tinea capitis, tinea uum (onychomycosis) when caused by one or more of the following genera ungi: *Trichophyton rubrum, Trichophyton tonsurans, Trichophyton menta phytes, Trichophyton interdigitalis, Trichophyton verrucosum, Trichophyton gnini, Trichophyton gallinae, Trichophyton crateriform, Trichophyton sulph um, Trichophyton schoenleini, Microsporum audouini, Microsporum canis, rosporum gypseum, and Epidermophyton floccosum.* Note: Prior to rapy, the type of fungi responsible for the infection should be identified. The of this drug is not justified in minor or trivial infections which will respond to ical agents alone. Griseofulvin is not effective in the following: Bacterial ections, Candidiasis (Moniliasis), Histoplasmosis, Actinomycosis, Sporo hosis, Chromoblastomycosis, Coccidioidomycosis, North American Blas lycosis, Cryptococcosis (Torulosis), Tinea versicolor, and Nocardiosis. NTRAINDICATIONS This drug is contraindicated in patients with porphyria, atocellular failure, and in individuals with a history of hypersensitivity to eofulvin. WARNINGS *Prophylactic Usage.* Safety and efficacy of griseofulvin prophylaxis of fungal infections have not been established. *Animal icology.* Chronic feeding of griseofulvin, at levels ranging from 0.5-2.5% of diet, resulted in the development of liver tumors in several strains of mice ticularly in males. Smaller particle sizes result in an enhanced effect. Lower dosage levels have not been tested. Subcutaneous administration of tively small doses of griseofulvin once a week during the first three weeks of has also been reported to induce hepatomata in mice. Although studies in er animal species have not yielded evidence of tumorogenicity, these studies e not of adequate design to form a basis for conclusions in this regard. In acute toxicity studies, orally administered griseofulvin produced hepato ular necrosis in mice, but this has not been seen in other species. turbances in porphyrin metabolism have been reported in griseofulvin ted laboratory animals. Griseofulvin has been reported to have a hic-ne like effect on mitosis and cocarcinogenicity with methylcholanthrene utaneous tumor induction in laboratory animals. *Usage in Pregnancy.* The ty of this drug during pregnancy has not been established. *Animal roduction Studies.* It has been reported in the literature that griseofulvin found to be embryotoxic and teratogenic on oral administration to pregnant Pups with abnormalities have been reported in the litters of a few bitches ted with griseofulvin. Additional animal reproduction studies are in gress. Suppression of spermatogenesis has been reported to occur in rats investigation in man failed to confirm this. PRECAUTIONS Patients on onged therapy with any potent medication should be under close ervation. Periodic monitoring of organ system function, including renal atic, and hematopoietic, should be done. Since griseofulvin is derived from cies of penicillin, the possibility of cross sensitivity with penicillin exists. ever, known penicillin-sensitive patients have been treated without culty. Since a photosensitivity reaction is occasionally associated with eofulvin therapy, patients should be warned to avoid exposure to intense ural or artificial sunlight. Should a photosensitivity reaction occur, lupus hematosus may be aggravated. Griseofulvin decreases the activity of arin type anticoagulants so that patients receiving these drugs concomi ly may require dosage adjustment of the anticoagulant during and after eofulvin therapy. Barbiturates usually depress griseofulvin activity, and comitant administration may require a dosage adjustment of the antifungal nt. ADVERSE REACTIONS When adverse reactions occur, they are most monly of the hypersensitivity type, such as skin rashes, urticaria, and rarely, lonecrotic edema, and may necessitate withdrawal of therapy and ropriate countermeasures. Paresthesias of the hands and feet have been rted rarely after extended therapy. Other side effects reported occasionally oral thrush, nausea, vomiting, epigastric distress, diarrhea, headache, gue, dizziness, insomnia, mental confusion, and impairment of performance outine activities. Proteinuria and leukopenia have been reported rarely. inistration of the drug should be discontinued if granulocytopenia occurs. n rare, serious reactions occur with griseofulvin; they are usually associated high dosages, long periods of therapy, or both.

05231 JANUARY 1977

more complete details, consult package insert or Schering literature lable from your Schering Representative or Professional Services Depart-t, Schering Corporation, Kenilworth, New Jersey 07033.

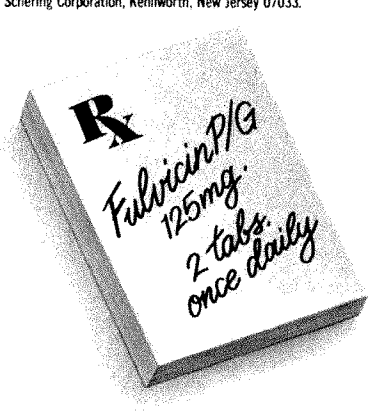

Society Transactions

The Society Proceedings are edited by Dr Harry L Arnold, Jr, Straub Clinic, Honolulu, HI 96813. Transactions and photographs should be sent, in duplicate, directly to him.

MICHIGAN DERMATOLOGICAL SOCIETY
November 1975

Amir H. Mehregan, MD, Recorder

Recurrent Digital Fibrous Tumor of Childhood. Presented by RALPH J. COSKEY, MD.

This 14-month-old girl was first seen because of skin-colored nodular lesions involving the fourth and fifth toes of the right foot. These were first noted at age 6 months and have increased in size. They were both excised at age 10 months but recurred two months later. A new lesion has appeared in the past month involving the third toe of the same foot.

Histopathologic examination by Dr A. H. Mehregan reports massive proliferation of elongated and spindle-shaped fibroblasts and collagenous tissue forming intersecting bundles. The elastic fibers are absent within the tumor area. Phosphotungstic acid-hematoyxlin stain demonstrates numerous round dense bodies in the cytoplasm of proliferating fibroblasts characteristic of the recurrent digital fibrous tumor of childhood (Figure).

Discussion

H. RAHBARI, MD: Among various forms of juvenile fibromatoses, the recurrent digital fibrous tumor of childhood shows distinctive clinical and histologic findings.[1] There are 21 published cases of this condition consisting of ten boys, ten girls, and one person of unknown gender. In 12 the patients' lesions were on the fingers and in eight on the toes. One child had lesions both on the fingers and toes. Nine patients had single lesions and 12 had multiple ones. In seven instances, the lesions were present at birth. This growth is notable for its unresponsiveness to surgical treatment and its tendency for recurrence. It is histologically differentiated from other types of fibrous tumors by the presence of round bodies 3 μ in diameter in the cytoplasm of fibroblasts. With Mallory's trichrome stain, these bodies appear red against collagen that stains blue and with phosphotungstic acid-hematoxylin the round bodies stain deep purple and are easily recognized. The possibility of the viral nature of the dense bodies was raised because of the positive staining with methyl green-pyronine that suggested the presence of RNA. Viral culture studies and electron microscopy, however, failed to support this hypothesis.[2] The round intracellular bodies are most likely accumulated abnormal by-products of metabolically deranged fibroblasts or are possibly related to the abnormal fibrillar protein covering of elastin.

RICHARD HARRELL, MD: In one case of this type I injected the lesion with steroid solution. The lesion has flattened but has not yet completely resolved.

1. Reye RDK: Recurring digital fibrous tumor of childhood. *Arch Pathol* 80:228-231, 1965.
2. Mehregan AH, Nabai H, Matthews JE: Recurring digital fibrous tumor of childhood. *Arch Dermatol* 106:375-378, 1972.

Lamellar Ichthyosis. Presented by KATHERINE TAYLOR, MD.

This 29-year-old man has had dry skin since infancy. He is the only member in his family who is affected, with three normal siblings. There is a thick and coarse scale covering the entire skin surface giving a parchment-like quality. The palms and soles are greatly hyperkeratotic and he has difficulty grasping with his fingers. The conjunctivae are injected and both eyes exhibit ectropions. There is also diffuse hair loss on the scalp. Histologic sections show mild thickening of the epidermis with hypergranulosis and adherent orthokeratotic hyperkeratosis. The dermis shows a mild perivascular round cell infiltrate.

Discussion

KATHERINE TAYLOR, MD: We have treated this patient and another patient with X-linked recessive ichthyosis with

Proliferation of elongated fibroblasts and collagenous fibers forming intersecting bundles (hematoxylin-eosin, × 225). Inset shows fibroblasts with round intracytoplasmic bodies (phosphotungstic acid-hematoxylin, × 800).

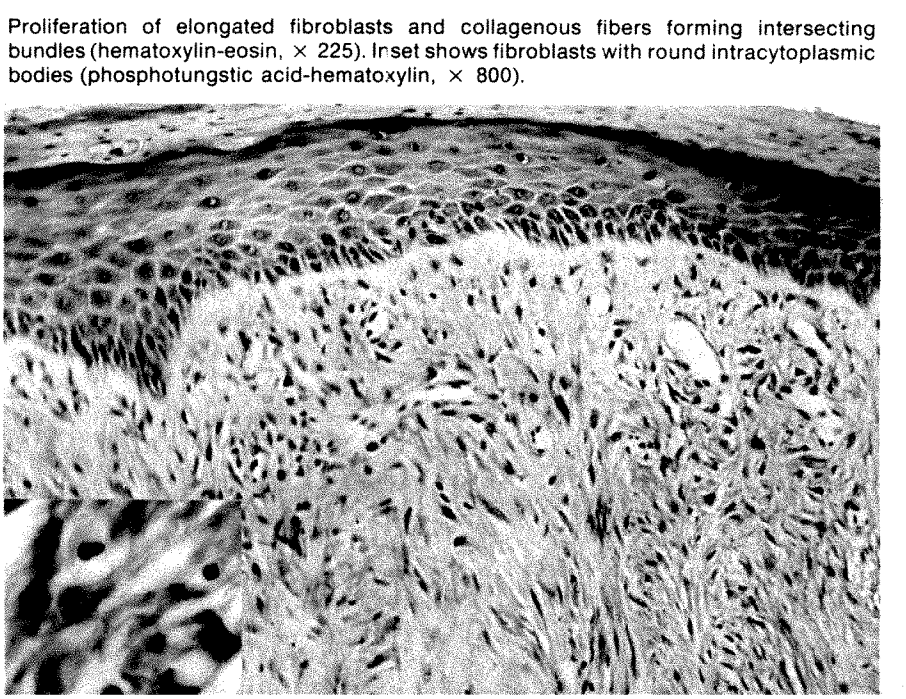

topical application of 5% lactic acid in an emulsion of equal parts of a water-miscible ointment base and water (Eucerin cream) for a period of six months. In the patient with X-linked recessive ichthyosis the results were dramatic in less than two weeks. The patient presented today experienced at least 50% improvement. Thus far we have not observed any untoward reaction to the topical medication.

Earl Rudner, MD: I tried lactic acid cream on a patient with ichthyosis hystrix, which is histologically similar to the epidermolytic hyperkeratosis. There was no beneficial response.

CHICAGO DERMATOLOGICAL SOCIETY
Feb 20, 1974

David F. Fretzin, MD, Recorder

Porokeratosis in a Patient With Psoriasis.

Presented by JOHN WEISS, MD; JAMES PEDERSON, MD; ANA ENG, MD

This 54-year-old man first noticed silvery scaling on his knees and elbows 20 years ago and was told he had psoriasis. He has been treated with various topical preparations, including steroids and tars. Two years ago, more bothersome and less responsive lesions began to develop that were more localized and keratotic than previous ones. Approximately one year ago another, morphologically different, lesion began to develop. This lesion is flat and symptomatic and has been unresponsive to therapy. There is no family history of similar skin problems. He has had Laennec cirrhosis and esophageal varices since 1960.

Examination of his skin shows a generalized, mild erythema. Diffuse, heavy scaling is noted on the scalp, dorsums of the hands and feet, and the legs. Numerous keratotic, conical, nodular lesions are most prominent on the extremities. A distinctly different, more numerous lesion is noted in a generalized distribution. This lesion has a well-defined keratotic, and slightly raised border. The central portion is erythematous, flat, and, without scale. All nails are dystrophic. Mucous membranes are not involved. Laboratory studies showed elevated SGOT, lactic dehydrogenase, serum alkaline phosphatase, and serum bilirubin levels. The complete blood cell count, BUN, serum uric acid levels and results of urinalysis were within normal limits. A biopsy specimen of a flat lesion with a well-defined keratotic border was found to be consistent with porokeratosis.

Topical steroids alone and in combination with keratolytics, including retinoic acid solution, have failed to alter the lesions.

Discussion

RICHARD WINKELMANN, MD: The patient has had cirrhosis for a minimum of five years and has had bleeding esophageal varices. This is an important background fact. He has a 20-year history of a psoriatic process that is said to be absent now and a two-year history of a rapidly and extensively progressive, keratosquamous, and nodular disease that has involuted into some unusual lesions. This patient presents a number of morphologically speculative problems.

SIDNEY BARSKY, MD: I thought he had psoriasis plus some small areas of porokeratosis. Histologically, one of the two slides was consistent with psoriasis and the other suggested porokeratosis with a prominent cornoid lamellae. I do not think the patient has disseminated actinic porokeratosis for he has porokeratotic lesions on covered areas. The relationship between these two diseases is not clear.

ANA ENG, MD: I diagnosed this case as one of porokeratosis of Mibelli by histopathological examination before seeing the patient clinically. However, the clinician at the time disagreed. This was when the patient showed only the verruca-like, fleshy growths on his extremities (Fig 1, arrow 1). After a few months, the typical lesions of porokeratosis of Mibelli developed (Fig 1, arrow 2). He also showed small, confluent erythematous papules on his extremities, back, and chest (Fig 1, arrow 3). A biopsy specimen of these papules showed the histopathological features of psoriasis, which on serial sections merged into areas showing cornoid lamellae. Figure 2 (arrows) shows the cornoid lamella seen in a keratotic lesion. This feature is present uniformly on multiple biopsy specimens and is typified by columns of parakeratosis, beneath which are perinuclear vacuolar changes of the cells in the granular layer. In warts, one may find parakeratotic layers of cells and vacuolated granular cells, but the columns of parakeratotic cells are not as sharply demarcated from adjacent normal epidermis as in porokeratosis. The parakeratotic cells in porokeratosis extend deeply in a V-shaped manner into the underlying prickle cell layer. The gross configuration and the epidermal changes of keratoacanthoma are absent.

Fig 1.—Different clinical variants of porokeratosis of Mibelli. Arrow 1 indicates verruca-like fleshy growths; arrow 2, typical lesions of porokeratosis of Mibelli; arrow 3, small confluent erythematous papules.

Fig 2.—Cornoid lamella (arrows) as typical histological feature of porokeratosis of Mibelli.

Ways to help allergy patients avoid "a bad day at the office"

Your allergy patients who are office workers may spend a quarter of their adult life in a hostile environment — from an allergen standpoint. Here are suggestions that might, with the help of an understanding employer, lessen the allergic burden.

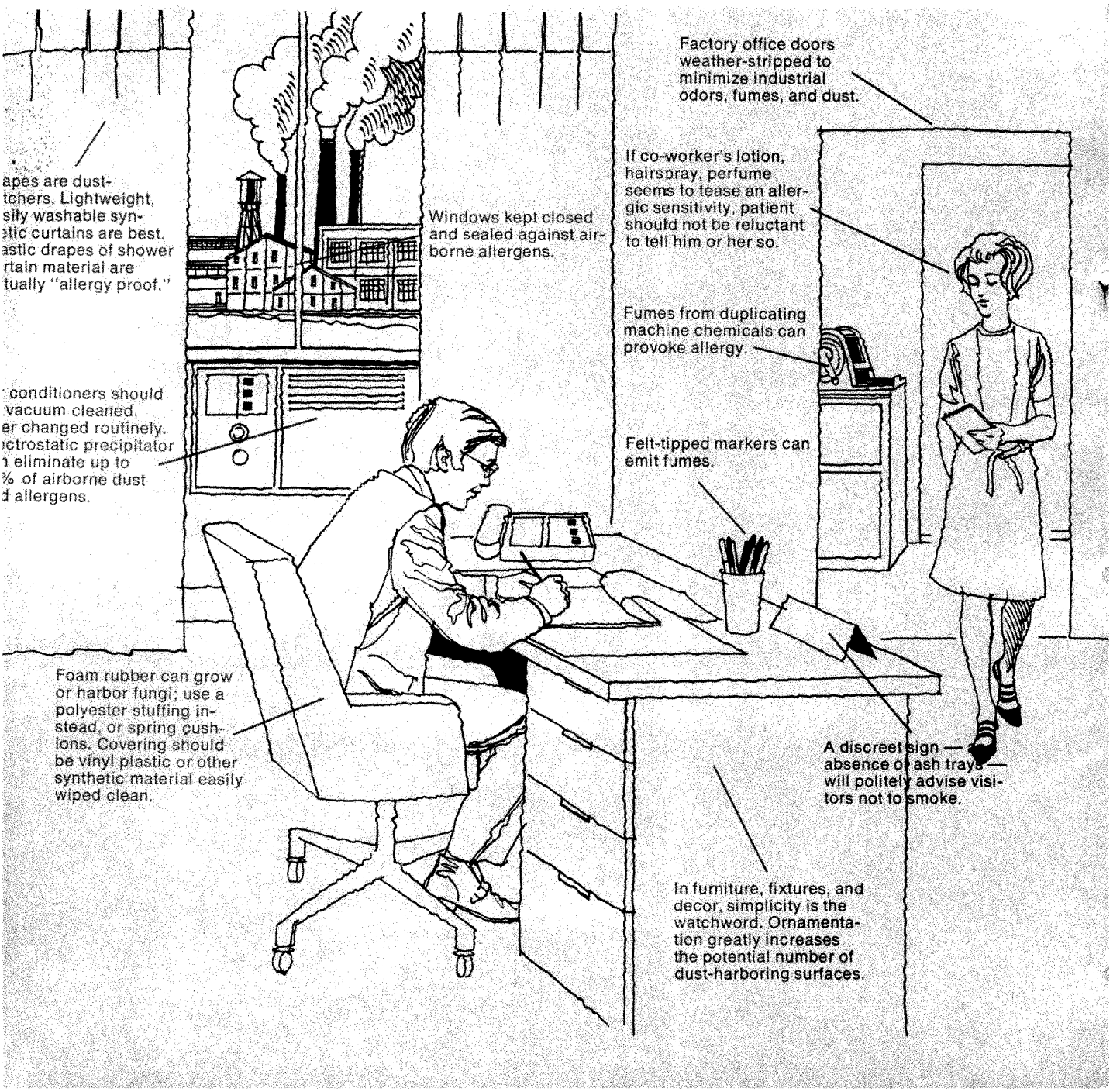

All measures to minimize exposure can be helpful. Still, allergic symptoms may occur and an antihistamine will be needed to bring these reactions under control. Dimetane Extentabs keep working for 10-12 hours, are economical, and are likely to produce good results in stubborn as well as routine cases, usually without drowsiness or overstimulation.

DIMETANE Extentabs®

(BROMPHENIRAMINE MALEATE, NF 8 mg. and 12 mg.)

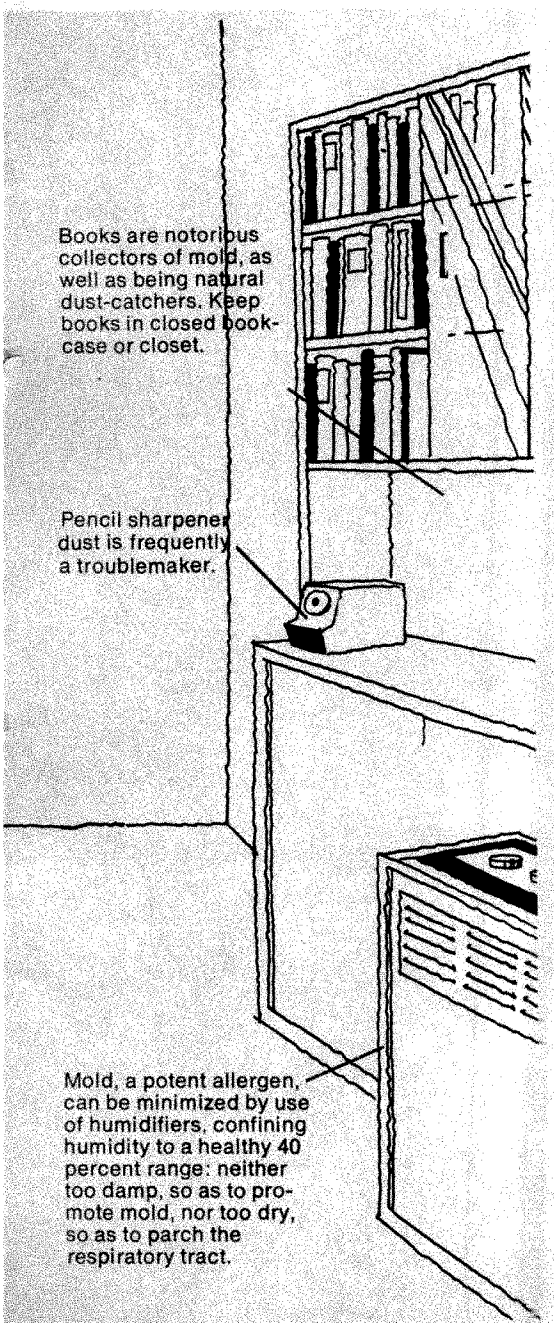

Indications: Perennial and seasonal allergic rhinitis; vasomotor rhinitis; allergic conjunctivitis due to inhalant allergens and foods; mild, uncomplicated allergic skin manifestations of urticaria and angioedema; amelioration of allergic reactions to blood or plasma; dermatographism; as therapy for anaphylactic reactions *adjunctive* to epinephrine and other standard measures after the acute manifestations have been controlled. **Contraindications:** *Use in Newborn or Premature Infants.* This drug should **not** be used in newborn or premature infants. *Use in Nursing Mothers.* Because of the higher risk of antihistamines for infants generally and for newborns and prematures in particular, antihistamine therapy is contraindicated in nursing mothers. *Use in Lower Respiratory Disease.* Antihistamines should NOT be used to treat lower respiratory tract symptoms including asthma. Antihistamines are also contraindicated in the following conditions: hypersensitivity to brompheniramine maleate and other antihistamines of similar chemical structure; monoamine oxidase inhibitor therapy (see Drug Interaction section). **Warnings:** Antihistamines should be used with considerable caution in patients with: narrow angle glaucoma; stenosing peptic ulcer; pyloroduodenal obstruction; symptomatic prostatic hypertrophy; bladder neck obstruction. *Use in Children.* In infants and children, especially, antihistamines in **overdosage** may cause hallucinations, convulsions, or death. As in adults, antihistamines may diminish mental alertness in children. In the young child, particularly, they may produce excitation. *Use in Pregnancy.* Experience with this drug in pregnant women is inadequate to determine whether there exists a potential for harm to the developing fetus. *Use with CNS Depressants.* Dimetane has additive effects with alcohol and other CNS depressants (hypnotics, sedatives, tranquilizers, etc.). *Use in Activities Requiring Mental Alertness.* Patients should be warned about engaging in activities requiring mental alertness, such as driving a car or operating appliances, machinery, etc. *Use in the Elderly (approximately 60 years or older).* Antihistamines are more likely to cause dizziness, sedation, and hypotension in elderly patients. **Precautions:** As with other antihistamines, Dimetane has an atropine-like action and, therefore, should be used with caution in patients with: history of bronchial asthma; increased intraocular pressure; hyperthyroidism; cardiovascular disease; hypertension. **Drug Interactions:** MAO inhibitors prolong and intensify the anticholinergic (drying) effects of antihistamines. **Adverse Reactions:** The most frequent adverse reactions are italicized: *General:* Urticaria, drug rash, anaphylactic shock, photosensitivity, excessive perspiration, chills, dryness of mouth, nose, and throat. *Cardiovascular System:* Hypotension, headache, palpitations, tachycardia, extrasystoles. *Hematologic System:* Hemolytic anemia, thrombocytopenia, agranulocytosis. *Nervous System: Sedation, sleepiness, dizziness, disturbed coordination,* fatigue, confusion, restlessness, excitation, nervousness, tremor, irritability, insomnia, euphoria, paresthesias, blurred vision, diplopia, vertigo, tinnitus, acute labyrinthitis, hysteria, neuritis, convulsions. *G.I. System: Epigastric distress,* anorexia, nausea, vomiting, diarrhea, constipation. *G.U. System:* Urinary frequency, difficult urination, urinary retention, early menses. *Respiratory System: Thickening of bronchial secretions,* tightness of chest and wheezing, nasal stuffiness. **Overdosage:** Antihistamine overdosage reactions may vary from central nervous system depression to stimulation. Stimulation is particularly likely in children. Atropine-like signs and symptoms – dry mouth; fixed, dilated pupils; flushing; and gastrointestinal symptoms may also occur. *If vomiting has not occurred spontaneously,* the patient should be induced to vomit. This is best done by having him drink a glass of water or milk after which he should be made to gag. Precautions against aspiration must be taken, especially in infants and children. *If vomiting is unsuccessful,* gastric lavage is indicated within 3 hours after ingestion and even later if large amounts of milk or cream were given beforehand. Isotonic and ½ isotonic saline is the lavage solution of choice. *Saline cathartics,* as milk of magnesia, by osmosis draw water into the bowel and therefore, are valuable for their action in rapid dilution of bowel content. *Stimulants* should **not** be used. Vasopressors may be used to treat hypotension. **Dosage and Administration:** DOSAGE SHOULD BE INDIVIDUALIZED ACCORDING TO THE NEEDS AND THE RESPONSE OF THE PATIENTS. *Adults:* One to two 4 mg tablets three or four times a day. One Extentab (8 or 12 mg) every eight to twelve hours or twice daily. Two to four teaspoonfuls of elixir three or four times a day. *Children over six.* One 4 mg tablet three or four times a day. One Extentab (8 or 12 mg) every twelve hours. One or two teaspoonfuls of elixir three or four times a day. *Children under six.* 0.5 mg of brompheniramine maleate per kg of body weight per 24 hours, or 15 mg per M^2 per 24 hours, divided into 3-4 doses.

A·H·ROBINS

A. H. ROBINS COMPANY RICHMOND, VA 23220

JQ15A 1800

Books

Medical Mycology, Chester W. Emmons, PhD, Chapman H. Binford, AB, MD, John P. Utz, MD, et al, 592 pp, with 554 illus, $19.50, Lea & Febiger, 1977.

The third edition of *Medical Mycology* by Emmons et al continues in the scholarly approach of the first editions and adds to the previous volumes. Not only is there an increase in pages but there are also additional illustrations and figures. The index is complete, cross-referenced, and easy to use. A substantial bibliography follows each chapter. The color plates are beautiful and one only wishes there were more of them. A new chapter on common contaminants, with clear illustrations, should prove useful to most medical mycology laboratories. An entire chapter has been devoted to phaeomycotic cysts, a poorly understood clinical entity to many workers in this discipline. The added table on "serologic, immunologic and skin tests in mycoses" summarizes nicely the available tests and indicates their usefulness. The additional information on new modalities of therapy for the mycoses is surely essential to all specialists in this field. In summary, this text is up to date, lucid, concise, and encompasses all aspects of medical mycology. It is especially pertinent today with the large number of immunosuppressed patients in whom complications develop because of pathogens as well as what were once considered to be contaminants. The text has a multispecialist appeal and will continue to be a valuable source of reference for dermatologists, internists, mycologists, surgeons, and researchers.

PAUL H. JACOBS, MD
Stanford, Calif

Enfermedades de la Boca: Semiologia, Patologia, Clinica y Terapeutica de la Mucosa Bucal, vol 3, by Julio Diaz, Luis Oscar Villapol, Ruben Berdichesky, Jorge Abulafia, and Juana Schneiderman, 973 pp, illus, Buenos Aires, Editorial Mundi, 1976.

This, the third volume of this encyclopedic treatise on diseases of the mouth, was to be the last volume. However, the authors tell us in the introduction that a fourth volume will be needed to finish this monumental undertaking. There has been some repetition, but this does not detract greatly from the overall value of the texts to date. The third volume complements the previous two works, and together they should serve as a complete primer and atlas of oral diseases.

The third volume is 973 pages long (exclusive of index) and is divided into eight chapters that cover primary diseases of the various oral structures, malformation and dysplasias, congenital and hereditary malformations and dysplasias, metabolic diseases with oral manifestations, connective tissue disorders, endocrine diseases, facial and cephalic neuralgias, psychiatric disorders, and blood disorders.

The book is generously endowed with charts and clinical photographs, which generally are of superior quality in selection. The bibliographies are reasonably extensive, although not selective, and sufficiently up to date. In particular, the chapter on primary diseases of the oral tissues was excellent. For example, the discussion on the various types of cheilitis is the most extensive and most expertly done of any I have read, and it bridges the gap between the old and new only as an expert clinician, such as Grinspan, could have done. The same is true for the discussion of the various types of glossitis and disorders of the gingivae, which are discussed equally expertly and make the book worth buying for this reason alone.

There was considerable waste of valuable space given over to preliminary general discussions of problems, such as basic genetics, and unnecessary theoretical considerations of disorders such as systemic lupus erythematosus, diabetes mellitus, and hyperlipidemia, among others. However, since the book is also intended for a wide readership, including dentists, this was probably considered prudent. Yet it does detract from the scientific merit of the book and extends the length of this treatise unnecessarily.

These volumes are a must for medical libraries and for those physicians particularly interested or working in this area. They will be most valuable for dentists, oral pathologists, and dermatologists. I would recommend to the authors that, rather than make further additions to these volumes, they revise the earlier volumes so that the texts will continue to be a source book of information of diseases of the mouth.

SIGFRID A. MULLER, MD
Rochester, Minn

DESCRIPTION

Synalar® (fluocinolone acetonide) has the chemica
6α, 9α-difluoro-16α-hydroxyprednisolone-16, 17-acetc

Synalar® Solution 0.01%—contains 0.01% fluocinolon
acetonide in propylene glycol with citric acid.

Synalar® Ointment 0.025%—contains 0.025% fluocin
acetonide in white petrolatum.

Synalar-HP® Cream—contains 0.2% fluocinolone ac
in a water-washable aqueous base of stearyl alcoh
alcohol, mineral oil, propylene glycol, sorbitan mon
stearate, polyoxyethylene sorbitan monostearate ar
citric acid, with methylparaben and propylparaben
preservatives.

Synemol™ (fluocinolone acetonide) has the chemicc
6α, 9α-difluoro-16α-hydroxyprednisolone-16, 17-aceto

The vehicle is a water-washable aqueous emollient
stearyl alcohol, cetyl alcohol, mineral oil, propylene
sorbitan monostearate, polyoxyethylene sorbitan mc
stearate and citric acid.

INDICATIONS

For relief of the inflammatory manifestations of cortic
steroid-responsive dermatoses.

CONTRAINDICATIONS

Topical steroids are contraindicated in vaccinia anc
varicella.

Topical steroids are contraindicated in those patient
history of hypersensitivity to any of the components o
preparation.

Synalar-HP Cream should not be used on infants up
years of age.

PRECAUTIONS

If irritation develops, the product should be discontin
appropriate therapy instituted.

In the presence of an infection the use of an approp
antifungal or antibacterial agent should be instituted
favorable response does not occur promptly, the cort
steroid should be discontinued until the infection has
adequately controlled.

If extensive areas are treated or if the occlusive techn
used, the possibility exists of increased systemic absor
of the corticosteroid and suitable precautions should
taken.

Although topical steroids have not been reported to h
adverse effect on pregnancy, the safety of their use ir
pregnant females has not absolutely been establishe
Therefore, they should not be used extensively on pre
patients, in large amounts, or for prolonged periods c

Topical steroids are not for ophthalmic use.

Synalar-HP Cream should not be used for prolonged p
and the quantity per day should not exceed 2 g of
formulated material.

ADVERSE REACTIONS

The following local adverse reactions have been repo
with topicalcorticosteroids: burning, itching, irritation,
dryness, folliculitis, hypertrichosis, acneform eruptions,
hypopigmentation.

Synalar Cream and Ointment, Synemol Cream.

The following may occur more frequently with occlusi
dressings than without such therapy: maceration of th
secondary infection, skin atrophy, striae, miliaria.

HOW SUPPLIED

Synalar® (fluocinolone acetonide)
Cream 0.025%—15, 60 g tubes; 120, 425 g jars.
Cream 0.01%—15, 45, 60 g tubes; 120, 425 g jars.
Ointment 0.025%—15, 60 g tubes; 425 g jars.
Solution 0.01%—20, 60 cc plastic squeeze bottles.
Synalar-HP® (fluocinolone acetonide) 0.2% Cream—5
tubes.
Synemol™ (fluocinolone acetonide)
Cream 0.025%—15, 60 g tubes.

These preparations are available on prescription only.

SYNTEX
SYNTEX LABORATORIES, INC.
PALO ALTO, CALIFORNIA 94304

INFLAMMATION OF
CONTACT DERMATITIS

SOLVED

SYNALAR® TOPICALS
(FLUOCINOLONE ACETONIDE)

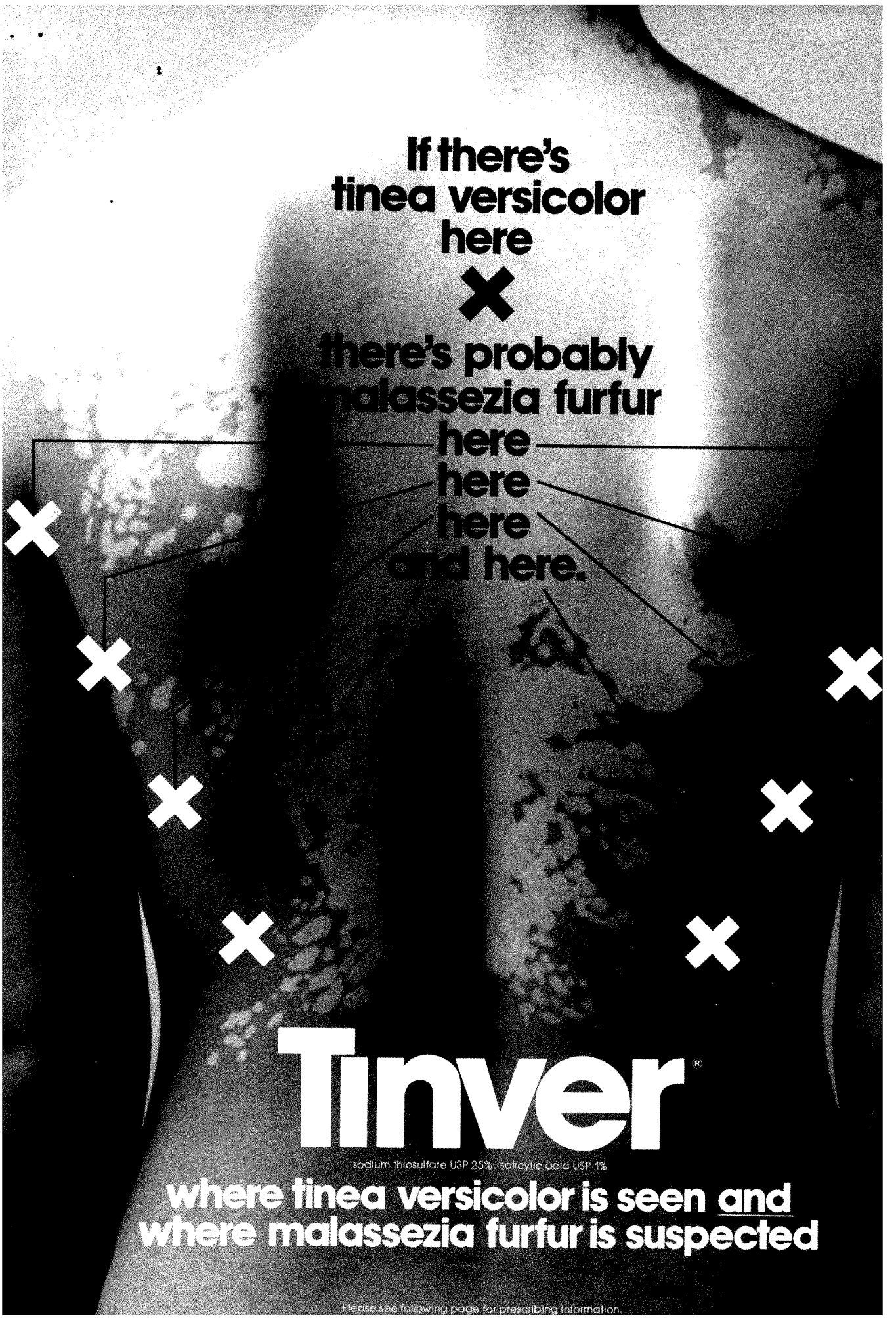
If there's
tinea versicolor
here
there's probably
malassezia furfur
here
here
here
and here.
Tinver®
sodium thiosulfate USP 25%, salicylic acid USP 1%
where tinea versicolor is seen and
where malassezia furfur is suspected
Please see following page for prescribing information.

DESCRIPTION:
Sodium thiosulfate 25%, salicylic acid 1%, isopropyl alcohol NF 10%, propylene glycol USP, menthol USP, disodium edetate, colloidal alumina, and purified water.

INDICATIONS:
For topical use in the treatment of tinea versicolor (Malassezia furfur infection).

PRECAUTIONS:
If signs of irritation or sensitivity develop, discontinue use. Do not use on or about the eyes.

ADMINISTRATION:
Thoroughly wash, rinse and dry the affected areas before application of medication. Apply a thin film of lotion to all affected areas and other susceptible areas twice a day. Although diagnostic evidence of the disease may disappear in a few days, it is advisable to continue treatment for a much longer period. Clothing should be boiled to prevent reinfection.

HOW SUPPLIED:
6 fl. oz. plastic dispenser bottles.

CAUTION:
U.S. Federal law prohibits dispensing without prescription.

Barnes-Hind Pharmaceuticals, Inc.
895 Kifer Road
Sunnyvale, California 94086

Tinver®

sodium thiosulfate USP 25%, salicylic acid USP 1%



News and Notes

The Patch Test Clinic.—The fourth annual Patch Test Clinic will be held during the Academy of Dermatology meeting in Dallas in December 1977. Residents and physicians in practice are requested to work up cases for presentation at the Clinic Symposium, where they will be discussed by a panel of experts and the presenter. The following three categories of presentations are to be considered: (1) the most instructive case; (2) the most thoroughly worked up case; and (3) the most unusual case. Awards to honor achievement will be given to winners in these three categories.

Those interested should submit a history and photomicrographs of the clinical lesions as well as patch test results of as many cases as you wish to submit in each of the three categories to: William L. Epstein, MD, Department of Dermatology, UCSF, San Francisco, CA 94143. Prepare now for the deadline of Nov 1, 1977.

Flaps.—The American Society for Dermatologic Surgery announces a course entitled "Dermatologic Surgery—Flaps." The course will be held at the University of California Medical Center, San Francisco, Oct 22 through 23, 1977. The course moderator will be Theodore Tromovitch, MD. For further information write to Extended Programs in Medical Education, University of California School of Medicine, San Francisco, CA 94143.

Position Open: Assistant Research Biochemist.—This position is open in the Department of Dermatology. Qualifications are as follows: postdoctoral experience and publications demonstrating productivity in biochemical oncology. Applicant must be competent in radioisotopic techniques, tissue culture of pigment cells, cell fractionation, and isolation and identification of metabolites by high pressure liquid chromatography. Also, must be familiar with electron microscopy and electronprobe x-ray microanalysis.

Effective Date of Appointment: July 1, 1977 through Dec 31, 1979. Address applications, including curriculum vitae, to: Dr Scott Blois, Blo 400, Room A-16, University of Ca fornia San Francisco, San Francisc CA 94143. An Equal Opportunity Affirmative Action employer.

Hair Transplant Symposium.—Th American Society for Dermatolog Surgery and the American Acaden of Facial Plastic and Reconstructi Surgery are sponsoring the Annu Hair Transplant Symposium an Workshop, Feb 10 and 11, 1978 in H Springs, Ark. The course moderat will be D. Bluford Stough III, MD. F further information write to Stou Dermatology and Cutaneous Surge Clinic, Doctor's Park, Hot Spring AR 71901.

Pediatric Dermatology Symposium This three-day symposium to be he at Stanford (Calif) University on Se 14-16, 1977, will focus on dermatolog problems observed in children, inclu ing viral, bacterial, fungal, and par sitic diseases, psoriasis, atopic derm titis, poison oak, warts, moles, e This is an American Medical Assoc tion-accredited postgraduate semin For information, contact Paul Jacobs, MD, Department of Dermat ogy, Stanford University Medi Center, Stanford, CA 94305, or pho (415) 497-6101.

General Meeting.—The American S ciety for Dermatologic Surgery w hold a general membership meeti Dec 4, 1977 in Dallas. Details will announced in the society's newslett or interested parties may write Daniel E. Gormley, MD, ASDS sec tary, 210 S Grand Ave, Suite 3 Glendora, CA 91740.

ASDS Annual Meeting.—The Am ican Society for Dermatologic Surg will hold its fourth annual Clinical a Scientific Meeting March 30 to Ap 2, 1978 at Vacation Village in S Diego. The course moderator will Theodore Tromovitch. For reservat information write to Mr. Rob Brown, The Incentive Co, 2207 Che nut St, Philadelphia, PA 19103.

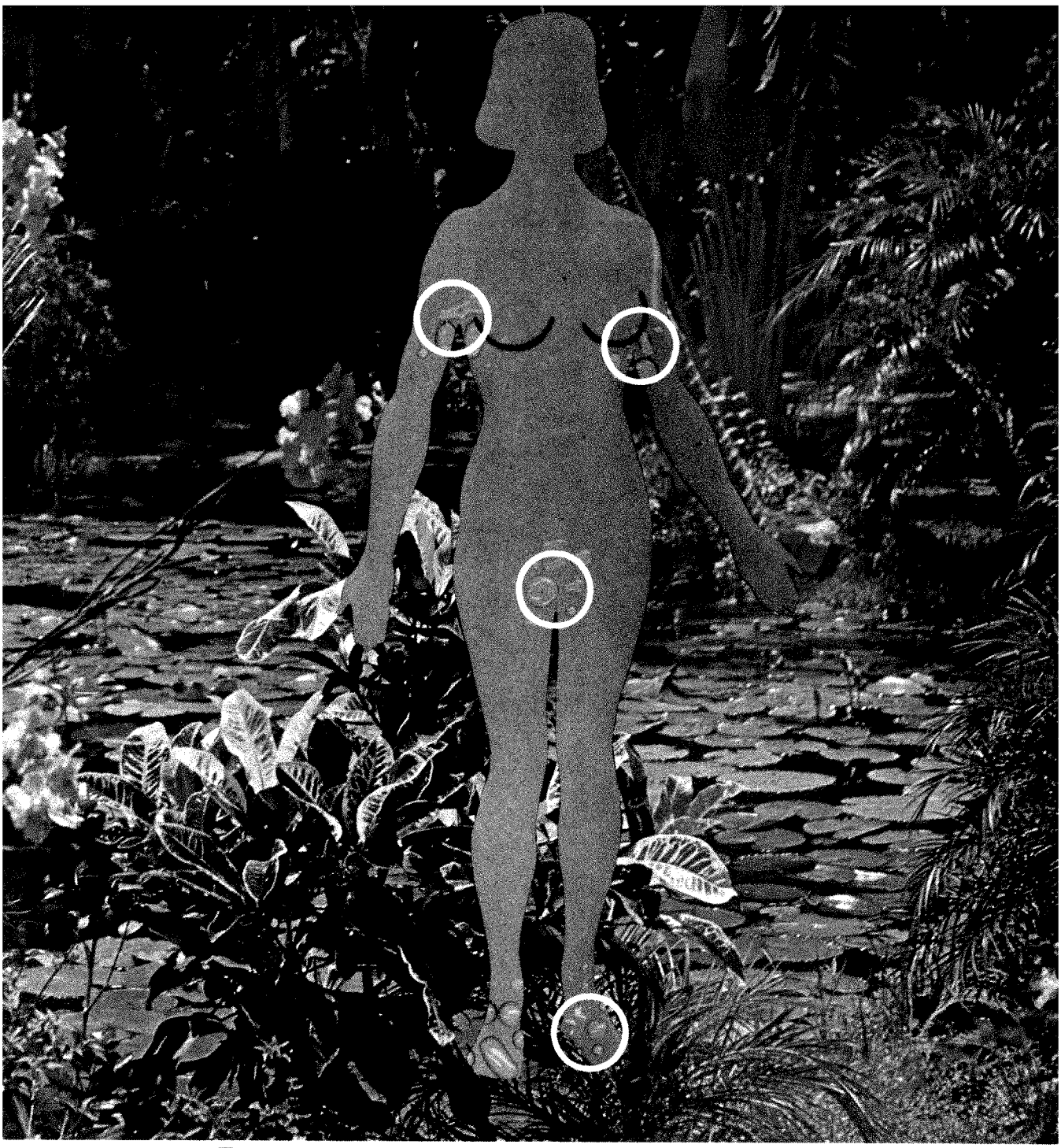

Dry Out the Damp Spot

with Super Absorbent

ZeaSORB®

A dry climate around your patient

ZeaSORB's unique formulation absorbs 2.6 times its weight in moisture...
25% to 100% more absorbent than five leading powders...

Active ingredients: Microporous cellulose 45%*, p-chloro-m-xylenol 0.5%, aluminum dihydroxy allantoinate 0.2%. Contains no starch or boric acid.

Supply: ZeaSORB is available in 2 oz. plastic dispenser bottles and 8 oz. shaker top cans.

Directions: Dust ZeaSORB freely wherever indicated.

Stiefel's brand of a patented ultra-absorptive cellulose derivative. U.S. Pat. Nos. 2890151, 3278383.

STIEFEL
Logical Dermatologicals since 1847

Stiefel Laboratories, Inc.,
Oak Hill, N.Y. 12460
Stiefel Laboratories (Canada) Ltd.,
St. Laurent, Quebec, Canada H4R 1E1

AZTEC® SUNSCREEN LOTION.

Protects better becau
it stays on longer.
Even after swimming.

Almost all professional sunscreen products protect against overexposure to the sun. Aztec does it with two complementary sunscreening agents for full coverage in the critical 280-315 nm range.

Maintaining protection during activity is another matter altogether. Swimming, perspiration, even toweling can easily wipe other lotions away, leaving your sun-sensitive patients exposed.

Only Aztec contains a patented acrylate polymer base which forms an umbrella-like matrix on the skin. This matrix holds both sunscreening agents on the skin for maximum protection...inhibits the loss of protection caused by swimming, evaporation or wiping away.



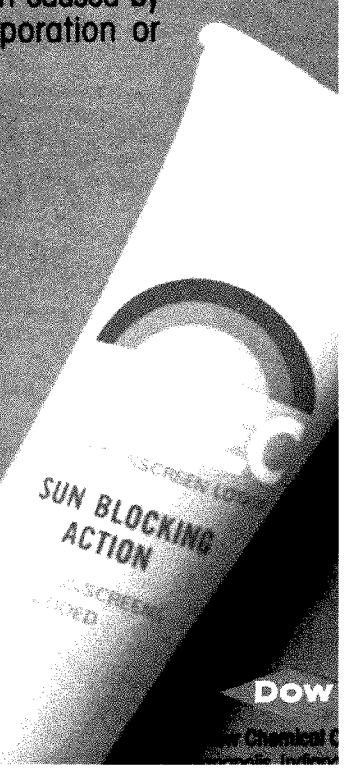

®Trademark of The Dow Chemical Company

For your professional recommendation.

AZTEC® SUNSCREEN LOTION.

Protects better, even after swimming.

HOECHST-ROUSSEL PHARMACEUTICALS INCORPORATED

Announces a New topical fluorinated corticosteroid in a Unique Emollient Cream Base

NEW TOPICORT (DESOXIMETASON

THE SPECIALLY DEVELOPED, PRESERVATIVE-FREE BASE COMBINES THE EMOLLIENCE OF AN OINTMENT WITH THE COSMETIC ACCEPTABILITY OF A CREAM IN A WATER-IN-OIL EMULSION.

Well-documented efficacy and safety: Anti-inflammatory, antipruritic, vasoconstrictive Topicort (desoximetasone) has been demonstrated safe and effective in relieving the inflammatory manifestations of corticosteroid-responsive dermatoses.

Worldwide clinical experience: For up to 4 years, Topicort (desoximetasone) has been marketed by Hoechst in over 30 foreign countries. Extensive clinical trials in the United States, conducted by 23 investigators under a wide variety of climatic conditions, confirm the many years of worldwide experience.

A wide range of conditions in corticosteroid-responsive dermatoses: Topicort (desoximetasone) is useful on wet as well as dry lesions, in both acute and chronic cases, with a profile of adverse reactions similar to that seen with other topical corticosteroids.

Emollient Cream 0.25%

Available: 15-gram tubes.
In corticosteroid-responsive dermatoses
Convenient B.I.D. dosage.

Please consult full prescribing information on following page.

0710

TOPICORT®(desoximetasone) EMOLLIENT CREAM 0.25%

Description: Topicort® (desoximetasone) Emollient Cream 0.25% contains the active synthetic corticosteroid desoximetasone. The chemical name of desoximetasone is 9α - fluoro - 11β, 21 - dihydroxy - 16α - methylpregna - 1,4 - diene-3,20-dione. The chemical structure is:

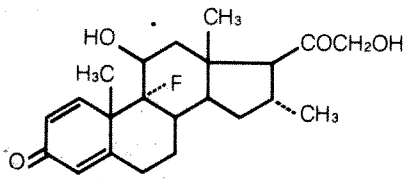

Each gram of Topicort® (desoximetasone) Emollient Cream 0.25% contains 2.5 mg desoximetasone in an emollient cream consisting of isopropyl myristate, cetylstearyl alcohol, white petrolatum, mineral oil, lanolin alcohol and purified water.

Actions: Topicort® (desoximetasone) Emollient Cream is primarily effective because of its anti-inflammatory, antipruritic and vasoconstrictive actions.

Indications: Topicort® (desoximetasone) Emollient Cream is indicated for the relief of inflammatory manifestations of corticosteroid-responsive dermatoses.

Contraindications: Topical steroids are contraindicated in vaccinia, varicella and in those patients with a history of hypersensitivity to any of the components of the preparation. This preparation is not for ophthalmic use.

Precautions: If local infection exists, suitable concomitant antimicrobial or antifungal therapy should be administered. If a favorable response does not occur promptly, application of the corticosteroid should be discontinued until the infection is adequately controlled.

Although systemic side effects associated with absorption of topical corticosteroid preparations are rare, their possible occurrence must be kept in mind when these preparations are used over large areas or for an extended period of time, or if occlusive technique is used.

If irritation or sensitization develops, the preparation should be discontinued and appropriate therapy instituted.

Although topical steroids have not been reported to have an adverse effect on pregnancy, the safety of their use during pregnancy has not been absolutely established; therefore, they should not be used extensively on pregnant patients, in large amounts, or for prolonged periods of time.

Adverse Reactions: The following local adverse reactions have been reported with topical corticosteroids: burning, itching, irritation, striae, skin atrophy, secondary infection, dryness, folliculitis, hypertrichosis, acneform eruptions and hypopigmentation. The following may occur more frequently with occlusive dressings: maceration of the skin, secondary infection, skin atrophy, striae, and miliaria.

Dosage and Administration: Apply a thin film of Topicort® (desoximetasone) Emollient Cream 0.25% to the affected skin areas twice daily. Rub in gently.

How Supplied: Topicort® (desoximetasone) Emollient Cream 0.25% is supplied in 15-gram tubes.

HOECHST-ROUSSEL
PHARMACEUTICALS INCORPORATED
SOMERVILLE, NEW JERSEY 08876

INDEX TO ADVERTISERS

A

Abbott Laboratories 710-711
Ayerst Laboratories 732-733

B

Barnes-Hind Pharmaceuticals 862-863
Burroughs Wellcome Company 709

C

Ciba Pharmaceuticals 734-735
Coppertone 835
Cryenco 729

D

Dermik Laboratories 707, 718-719
Doak Pharmacal Company 736
Dorsey Laboratories 713, 723-724
Dow Pharmaceuticals 865

G

General Medical Company 829

H

Herbert, G.S., Laboratories, Division of Allergan Pharmaceuticals 726
Hoechst-Roussel Pharmaceuticals 866-868

L

Lederle Laboratories, Division of American Cyanamid Company 826-827

N

Neutrogena Corporation 828-829

O

Owen Laboratories, Inc. ..... 3rd Cover

P

Parke-Davis & Company 720-721, 842-843, 852
Pharmacia Diagnostics 853
Purdue Frederick Company 737

R

Riker Laboratories, Inc. 722
Robins, A.H., Company 858-859
Roche Laboratories, Division of Hoffmann-LaRoche, Inc. 730-731

S

Schering Corporation 715, 854-856
Squibb, E.R., & Sons, Inc. 738-739, 840-841
Stiefel Laboratories, Inc. 727, 844, 864
Syntex Laboratories, Inc. 716-718, 860-861

T

Texas Pharmacal Company 728-729

W

Westwood Pharmaceuticals, Inc. 2nd Cover, 725, 740, 836, 4th Cover

While every precaution is taken to insure accuracy, we cannot guarantee against the possibility of an occasional change or omission in the preparation of this index.

This is a pabafilm™ stain.

Pabafilm™: The non-staining sunscreen
(amyl dimethyl PABA)

PreSun® for proven sunscreen protection

(5% PABA LOTION/GEL)

helps protect against premature aging of skin and skin cancer caused by the sun

©1977, W.P. Inc.

WESTWOOD
PHARMACEUTICALS INC.
Buffalo, New York 14213

2.12.7

Published by the American Medical Association

July 1

archives of Dermatology

Dermatology Manpower Requirements . . . 903

Actinic Cheilitis . . . 906

Acute Panniculitis . . . 909

Pemphigus Antibody . . . 923

Histiocytic Medullary Reticulosis . . . 927

Mycophenolic Acid and Psoriasis . . . 930

Cutaneous Coccidioidomycosis . . . 933

Tropical Rat Mite Dermatitis . . . 937

Volume 113 Numbe

Complete Contents . . . 870

Pemphigus Vegetans . . . 942

Follicular Atrophoderma . . . 9

Psuedomonal Balanitis . . . 95

Congenital Sensory Neuropathy . . . 954

AMA AMERICAN MEDICAL ASSOCIATION

CONTEMPORARY AND EFFECTIVE

For seborrhea oleosa and the oily hair and scalp associated with acne

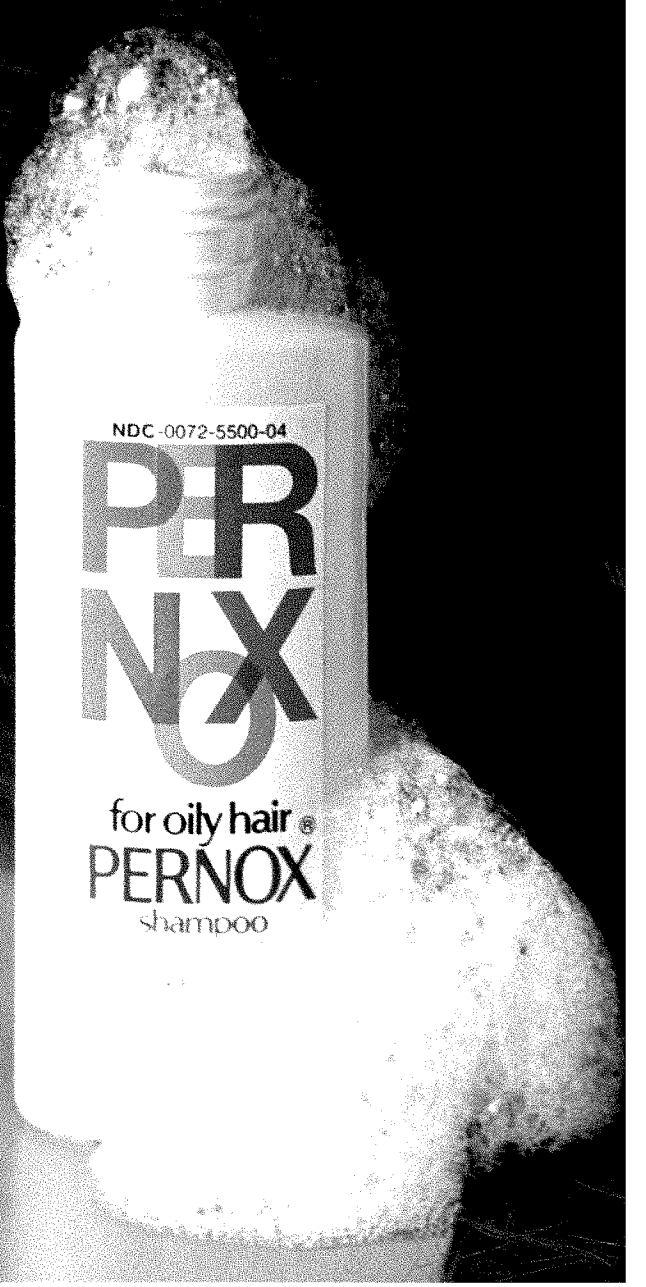

- Thorough cleansing of oily hair and scalp.
- Leaves patients' hair soft, manageable, fresh smelling.
- Elegant herbal scented shampoo.
- A special formulation designed to cleanse and condition oily hair.
- Its pH of 5.5 is gentle to the scalp.
- Can be used as often as necessary, preferably every day, to keep hair looking fresh and healthy.
- CONTAINS NO FORMALDEHYDE.

Supplied: 4 oz. and 8 oz. plastic bottles.

Pernox Shampoo® is adjunctive therapy especially formulated for oily scalps associated with acne.

WESTWOOD
PHARMACEUTICALS INC.
Buffalo, New York 14213

Inflammatory manifestations of psoriasis and atopic dermatitis...

Effectiveness demonstrated in only 8 days*

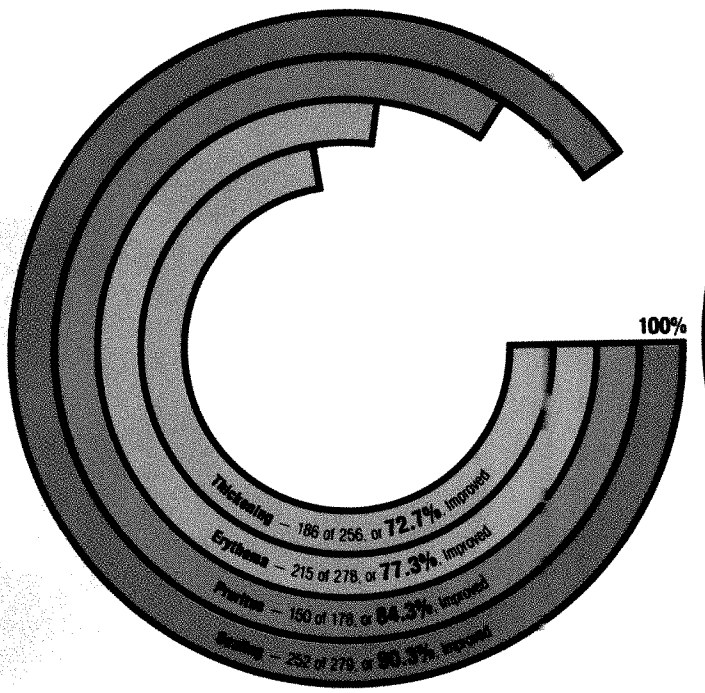



Psoriasis

In a study of 279 psoriatic patients

Atopic Dermatitis

In a study of 162 atopic dermatitis patie

Cordran® (Flurandrenolide)

Description: Cordran® (flurandrenolide, Dista) is a potent corticosteroid intended for topical use. **Actions:** Cordran is primarily effective because of its anti-inflammatory, antipruritic and vasoconstrictive actions. **Indications:** For relief of the inflammatory manifestations of corticosteroid-responsive dermatoses. **Contraindications:** Topical corticosteroids are contraindicated in vaccinia and varicella and in patients with a history of hypersensitivity to any of their components. **Precautions:** If irritation develops, the product should be discontinued and appropriate therapy instituted. In the presence of an infection, an appropriate antifungal or antibacterial agent should be used. If a favorable response does not occur promptly, the corticosteroid should be discontinued until the infection has been adequately controlled. If extensive areas are treated or if the occlusive technique is used, there is a possibility of increased systemic absorption of the corticosteroid, and suitable precautions should be taken. Although topical corticosteroids have not been reported to have an adverse effect on pregnancy, the safety of their use on pregnant women has not been absolutely established. Therefore, they should not be used extensively, in large amounts, or for prolonged periods of time on pregnant patients. These products not for ophthalmic use. **Adverse Reactions:** The following local adverse reactions have been reported with topical corticosteroid formulations: acneform eruptions, burning, dryness, folliculitis, hypertrichosis, hypopigmentation, irritation, itching. The following may occur more frequently with occlusive dressings: maceration of the skin, miliaria, secondary infection, skin atrophy, striae. **Administration and Dosage:** For moist lesions, a small quantity of the cream or lotion should be rubbed gently into the affected areas two to three times a day. For dry, scaly lesions, the ointment is applied in a thin film to affected areas two or three times daily.

Cream, Ointment, and Lotion Cordran®, 0.05%
flurandrenolide

Cream and Ointment Cordran, 0.025%

*Data on file at Dista Products Company.

DISTA **Dista Products Company**
Division of Eli Lilly and Company
Indianapolis, Indiana 46206

200136
Additional information available to the profession on request.

UNIVERSITY OF MEDICINE & DENTISTRY OF N.J. LIBRARY

Cream
Cordran®
Flurandrenolide

Efficacy is its strength

Archives of DERMATOLOGY
Copyright © 1977 by the AMERICAN MEDICAL ASSOCIATION

VOL 113, NO. 7 July 1977

ORIGINAL CONTRIBUTIONS

National Dermatology Manpower Requirements
Melvin Krasner, David L. Ramsay, MD, MEd, New York 903

Treatment of Lip Keratoses (Actinic Cheilitis) With Topical Fluorouracil
Ernst Epstein, MD, San Francisco 906

Acute Panniculitis
Lars Förström, MD, R. K. Winkelmann, MD, PhD, Rochester, Minn 909

Intrauterine Herpes Simplex Infections
James M. Komorous, MD; Clayton E. Wheeler, MD; Robert A. Briggaman, MD; Ivor Caro, MB, BCh, FF Derm, Chapel Hill, NC 918

Pemphigus Antibody Action on Skin Explants
Jau-Shyong Deng, MD, Taipei, Taiwan; Ernst H. Beutner, PhD; Suyu Shu, PhD, Buffalo; Tadeusz P. Chorzelski, MD, Warsaw 923

Tumor Cell Characterization of Histiocytic Medullary Reticulosis
Bernard N. Robinowitz, MD; Shiro Noguchi, PhD; Wilma F. Bergfeld, MD, Cleveland 927

Mycophenolic Acid in the Treatment of Psoriasis
Rosalie Marinari, MD; Raul Fleischmajer, MD; Alan H. Schragger, MD; Albert L. Rosenthal, MD, Philadelphia 930

CASE REPORTS

Primary Cutaneous Coccidioidomycosis
Gary F. Carroll, MD; Leanor D. Haley, PhD; June M. Brown, Atlanta 933

Tropical Rat Mite Dermatitis
Maj Ernest N. Charlesworth, MC, USAF, Capt Robert W. Clegern, BSC, USAF, San Antonio, Tex 937

Human Essential Fatty Acid Deficiency
Phyllis Skolnik, MD; William H. Eaglstein, MD; Vincent A. Ziboh, PhD, Miami 939

Pemphigus Vegetans of Hallopeau
Christopher G. Nelson, MD; Prapand Apisarnthanarax, MD, Galveston, Tex; Samuel F. Bean, MD, Houston; J. Fred Mullins, MD, Galveston, Tex 942

Pigmented Basal Cell Cancer Masquerading as Superficial Spreading Malignant Melanoma
Michael J. Fellner, MD, James M. Katz, MD, New York 946

Follicular Atrophoderma and Basal Cell Carcinomas
Peter Viksnins, MD, Alan Berlin, DO, Danville, Pa 948

Pseudomonal Balanitis
John W. Petrozzi, MD, Alexander Erlich, MD, Philadelphia 952

(Continued on page 872)

EDITORIAL BOARD

Chief Editor
John H. Epstein, MD
450 Sutter Street
San Francisco 94108

Assistant Chief Editor
Kimie Fukuyama, MD
San Francisco

Assistant Chief Editor
Denny L. Tuffanelli, MD
San Francisco

Donald C. Abele, MD
Augusta, Ga.

Harry L. Arnold, Jr, MD
Honolulu

Walter C. Lobitz, Jr, MD
Portland, Ore

Frederick D. Malkinson, MD
Chicago

Sigfrid A. Muller, MD
Rochester, Minn

W. Mitchell Sams, Jr, MD
Chapel Hill, NC

John S. Strauss, MD
Boston

Morris Waisman, MD
Tampa, Fla

Gerald D. Weinstein, MD
Miami

This is a pabafilm™ stain.

Pabafilm™: The non-staining sunscreen
(amyl dimethyl PABA)

CONTENTS—Continued

Congenital Sensory Neuropathy
John R. Person, MD; Roy S. Rogers III, MD; K. Hable Rhodes, MD, Rochester, Minn 954

HISTORICAL REVIEW

Hutchinson's *Archives of Surgery* Revisited
Robert Jackson, MD, FRCP(C), Ottawa 961

REGULAR DEPARTMENTS

Short Reports 969

Bullous Pemphigoid A. Razzaque Ahmed, MD; T. Ming Chu, PhD; Thomas T. Provost, MD, Buffalo . . . **Permanent Anonychia After Stevens-Johnson Syndrome** Birgitte Wanscher, MD, Jens Thormann, MD, Copenhagen

Society Transactions 976

Letters to the Editor 982

A Substitute for Chloroform in Prescriptions J. Walter Wilson, MD, Los Angeles . . . **Schistosomiasis of Spinal Cord and Skin** Norma Saxe, MB, CHB, FF Derm, (SA); Walter Gordon, MD, FRCP, Cape Town, South Africa; Margaret Gray Wood, MD, Philadelphia . . . **Transient Acantholytic Dermatosis in South Africa** Peter Lane, MRCP (EDIN), Durban, South Africa . . . **Jejunoileal Bypass and Psoriasis** Joseph M. Porres, MD, Minneapolis . . . **Allergic Contact Dermatitis to Herbicides** Donald L. Iden, MD, Arnold L. Schroeter, MD, Rochester, Minn . . . **Treatment With Penicillamines** Arthur N. Ward, MD, Smithfield, Pa; Charles J. McDonald, MD, Providence, RI . . . **Bits of Bicentennial Dermatology** Leon Goldman, MD, Cincinnati . . . **Nonvenereal (?) Sclerosing Lymphangitis of the Penis** Thomas S. Saunders, MD, Portland, Nicholas J. Fiumara, MD, MPH, Boston . . . **Atypical Fibroxanthoma** Howard S. Yaffee, MD, Cambridge, Mass, Lt Col Detlef K. Goette, MD, MC, San Francisco . . . **Peculiar Persistent Pruritic Affection of the Skin** Ira Leo Schamberg, MD, Elkins Park, Pa . . . **Isoniazid-Induced Pellagra** J. S. Comaish, MD, Mary Cooper, MD, Newcastle upon Tyne, England . . . **Treatment of *Mycobacterium marinum* Infections With Minocycline** Norman A. Lockshin, MD, Silver Spring, Md . . . **Congenital Pigment Formation** Grange S. Coffin, MD, Berkeley, Calif . . . **Tetracycline-Resistant Granuloma Inguinale** Robert J. Pariser, MD, Miami . . . **Betamethasone and Its Derivatives** C. G. Sparkes, PhD, London

News and Notes 993

Books 994

Index to Advertisers 1000

Instructions for Authors ..... see June 1977, p 714

SUBSCRIPTION RATES: The yearly rate of the ARCHIVES OF DERMATOLOGY is as follows: United States and US Possessions, one year, $18; two years, $28; all other countries, one year, $28; two years, $38. Special yearly price to residents, interns and medical students in the United States and US Possessions, $9.

THE ARCHIVES OF DERMATOLOGY is published monthly by the American Medical Association, 535 N Dearborn St, Chicago, IL 60610, and is an official publication of the Association. Second-class postage paid at Chicago and at additional mailing office.



Selsun®
(SELENIUM SULFIDE LOTION, U.S.P.)

Brief Summary

Contains:
Selenium sulfide, 2½%, w/v; l
tonite; lauric diethanolamide; et
ene glycol monostearate; titan
dioxide; amphoteric—2; sod
lauryl sulfate; sodium phosp
(monobasic); glyceryl mon
cinoleate; citric acid; captan;
fume; and water.

Indications:
For the treatment of dandruff
seborrheic dermatitis of the sca

Contraindications:
Should not be used by pati
allergic to any of its component

Warnings:
Safety for use on infants has
been established.

Precautions:
Cutaneous sensitization of
scalp or adjacent areas has b
reported; if sensitivity reacti
should occur, discontinue u
Chemical conjunctivitis may re
if product enters the eyes. Do
use when acute inflammation
exudation is present as an incre
in absorption may occur.

Adverse Reactions:
As with other shampoos, oilin
or dryness of the hair and sc
may occur following use; th
have been occasional reports of
increase in the amount of nor
hair loss. Hair discoloration n
occur; can be avoided or min-
imized by thorough rinsing.

703

Announcing Selsun.

What?

New Selsun®

(SELENIUM SULFIDE LOTION, U.S.P.)

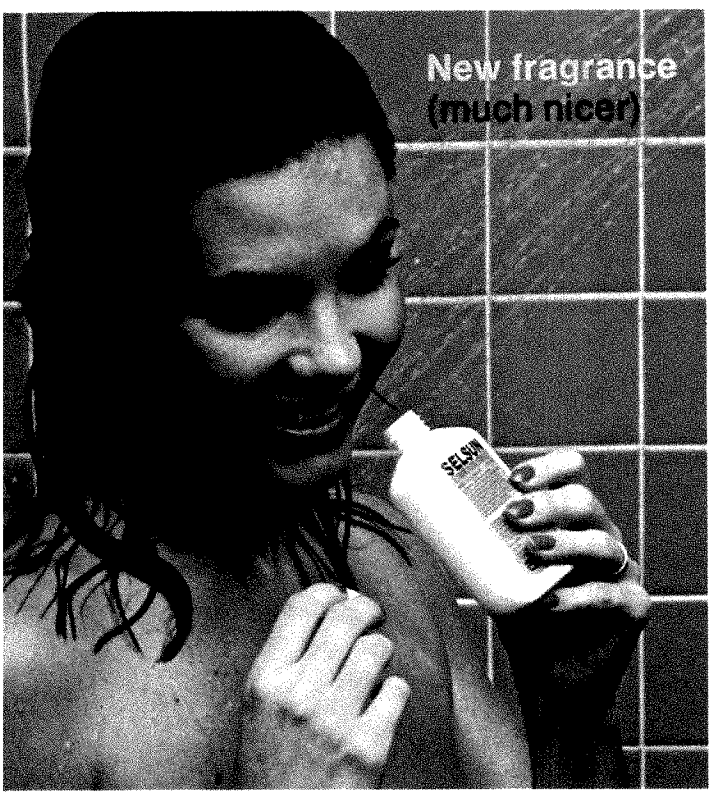

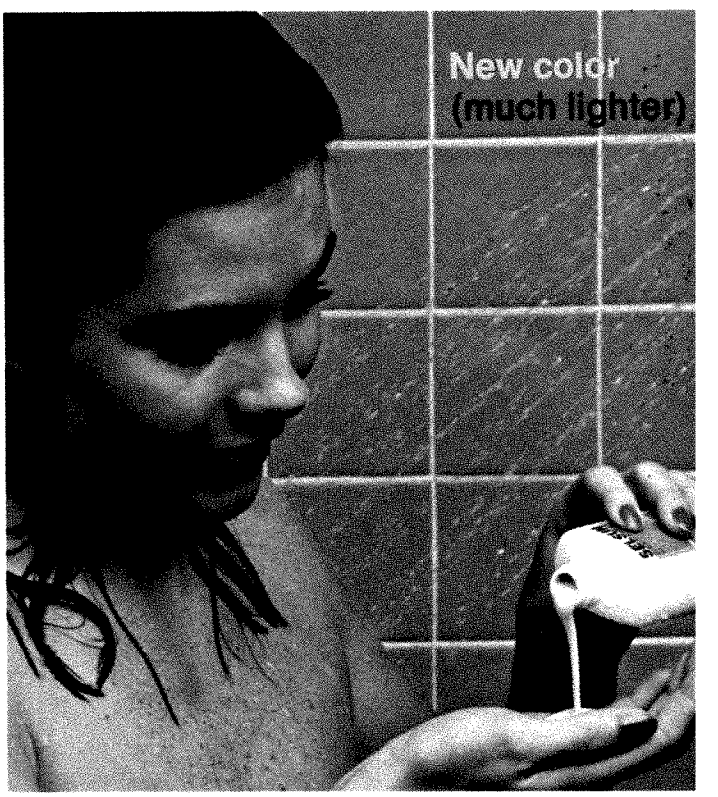

Please see opposite page for Brief Summary.

Archives of Dermatology

James H. Sammons, MD
Executive Vice-President

Thomas F. Hannon
Group Vice-President,
Publishing Operations

William R. Barclay, MD
Group Vice-President,
Scientific Publications

Norman D. Richey
Director, Publication
Production Division

John T. Baker
Director, Marketing Division

Helen R. Mazur
Acting Fulfillment Manager

John T. Baker, General Sales Manager; **Robert Corcoran,** Eastern Sales Manager; **Fred Bauman, Richard M. Johnson,** Eastern Sales Representatives; **William J. Healy,** Midwest Sales Representative; **Thomas J. Carroll,** West Coast/Northern Sales Representative

PUBLICATION STAFF

Offices: 535 N Dearborn St
Chicago, IL 60610

William R. Barclay, MD, Director
Scientific Publications Division

Robert W. Mayo, Executive Editor

Marlene M. Hinsch, Production Manager

Editorial Processing Manager: Diana A. Morgan

Copy Editing: Rosanne Schulenberg (Supervisor), Rae Usinger

Proofreading: Lorraine L. Kruse (Supervisor), Patricia Coyne, Helen Grzeskiewicz, Elizabeth Petrikenas, Dorothy Troy

Production Supervisors: Julia Bero (Layout), Thomas J. Handrigan (Illustrations), Marlene M. Hinsch (Editorial), James P. Bagniewski (Advertising)

Art and Senior Production Assistants: Betty Frigerio, Linda Gilbert, Floriana Hayes, Shirley Latronica, Deborah Orent, Donna Pender, Nancy Keyes, Susan Routhier, JoAnne Weiskopf

Production Assistants: Karen Branham, E. Linda Eisenberg, Anna Goins, Lucille Kuznicki

Manuscript Records: Mary Paino

Indexing: Phyllis H. McLaren (Supervisor), Jane P. Mauldin, Helen F. Topel

Please address communications concerning accepted or published communications to: AMA Specialty Journals, 535 N Dearborn St, Chicago, IL 60610.

Conditions for Acceptance of Color Illustrations

Illustrations in full color are accepted for publication in ARCHIVES OF DERMATOLOGY if the editor believes that color will add significantly to the published manuscript.

When color illustrations are accepted, the American Medical Association will pay part of the expense of reproduction and printing, the remainder to be borne by the author or the institution with which he is affiliated. After deducting AMA's contribution, the author's share is $275 for up to six square finished illustrations. Additional illustrations and special effects, such as outlining, opaquing, or surprinting, will be billed to the author at cost.

Color transparencies must be submitted for evaluation. Do not send color prints unless accompanied by original transparencies. If transparencies are mounted in frames or glass, the material should be carefully packed in gauze and sent with the manuscript in a separate container or between two pieces of pressboard.

Advertising and Subscription Information

ADVERTISING OFFICES: 535 N Dearborn St, Chicago, IL 60610, Area Code 312, 751-6000; and 600 Third Ave, New York, NY 10016, Area Code 212-867-6640.

ADVERTISING PRINCIPLES: Each advertisement in this issue has been reviewed and complies with the principles governing advertising in AMA scientific publications. A copy of these principles is available on request.

CHANGE OF ADDRESS: Please notify the publisher at least six weeks in advance, including both old and new address, and a mailing label taken from the most recent copy. Include your new zip code number.



"Adolescents especially, may suffer severe loss of self-esteem in our appearance-conscious society as a result of their acne. Some may be more seriously affected emotionally than others and withdraw from normal social interaction."[1]

Help Prevent Both Psychic...And Physical Scarring!

BENZAGEL®

(5% or 10% benzoyl peroxide, 6% polyoxyethylene lauryl ether)

and your counselling are BASIC to Successful Topical Therapy

"Results...Subjective and objective clinical results with this form of therapy were impressive. A rapid improvement could be seen within two weeks...Cysts, pustules and papules decreased in numbers, with a simultaneous reduction of accompanying inflammation. The distinct decline of oily conditions was dramatic."[2]

5 BENZAGEL® ACNE GEL & 10 BENZAGEL® ACNE GEL

Description: 5% or 10% benzoyl peroxide, 6% polyoxyethylene lauryl ether and 40% alcohol in an astringent gel containing colloidal magnesium aluminum silicate, hydroxypropyl methylcellulose, citric acid, fragrance and purified water.

Action: Provides drying, desquamative and antiseptic activity.

Indication: An aid in the treatment of acne.

Dosage and Administration: Wash affected areas prior to application. Apply once or more daily or as directed by physician.

Contraindications: Should not be used by patients having known sensitivity to either benzoyl peroxide or polyoxyethylene lauryl ether.

Precautions: For External Use Only. Not for ophthalmic use. Keep away from eyes and mucosae. Very fair individuals should begin with a single application at bedtime allowing overnight medication. May bleach colored fabrics. Keep this and all other medications out of the reach of children.

Caution: Federal law prohibits dispensing without prescription.

How Supplied: Plastic tubes, 1½ oz. and 3 oz.

REFERENCES:

1. Reisner, R.: The Rational Therapy of Acne, Cutis, Vol. 17, March, 1976, pg. 528.
2. Kuflik, E.: Benzoyl Peroxide Gel in Acne Therapy, Cutis, Vol. 17, January, 1976, pg. 175-177.

Dermik

Dermik Laboratories, Inc.
Fort Washington, Pa. U.S.A. 19034

AZTEC® SUNSCREEN LOTION.



Protects better because it stays on longer. Even after swimming.

Almost all professional sunscreen products protect against overexposure to the sun. Aztec does it with two complementary sunscreening agents for full coverage in the critical 280-315 nm range.

Maintaining protection during activity is another matter altogether. Swimming, perspiration, even toweling can easily wipe other lotions away, leaving your sun-sensitive patients exposed.

Only Aztec contains a patented acrylate polymer base which forms an umbrella-like matrix on the skin. This matrix holds both sunscreening agents on the skin for maximum protection...inhibits the loss of protection caused by swimming, evaporation or wiping away.

emark of The Dow Chemical Company

r your professional recommendation.

AZTEC® SUNSCREEN LOTION.

otects better, even after swimming

When patient acceptar

sebu

is the a

Tar is effective therapy, but it l
shampoos look like tar and, wor

Sebutone® provides tar t
with unique patient acc

- Itching usually stops after the first shampoo.
- It has a clean, fresh odor patients will like.
- It is a rich, lathering shampoo with a pleasant color.
- It contains the first chemically and biologically standardized tar, developed by Westwood.
- Sebutone's tar is bioassayed to insure therapeutic activity from batch to batch.
- Available in both lotion and cream.
- In addition to 0.5% Westwood® Tar, Sebutone contains 2% sulfur and 2% salicylic acid, for increased effectiveness.
- Wood's light shows that microfine particles remain on the scalp for up to three days to provide sustained antiseborrheic action.

sebutone

Substantive therapy...p

Available—Sebutone in 4 and 8 oz. b

WESTI
PHARMACEU
Buffalo, Nev

©1977, W. P. Inc.

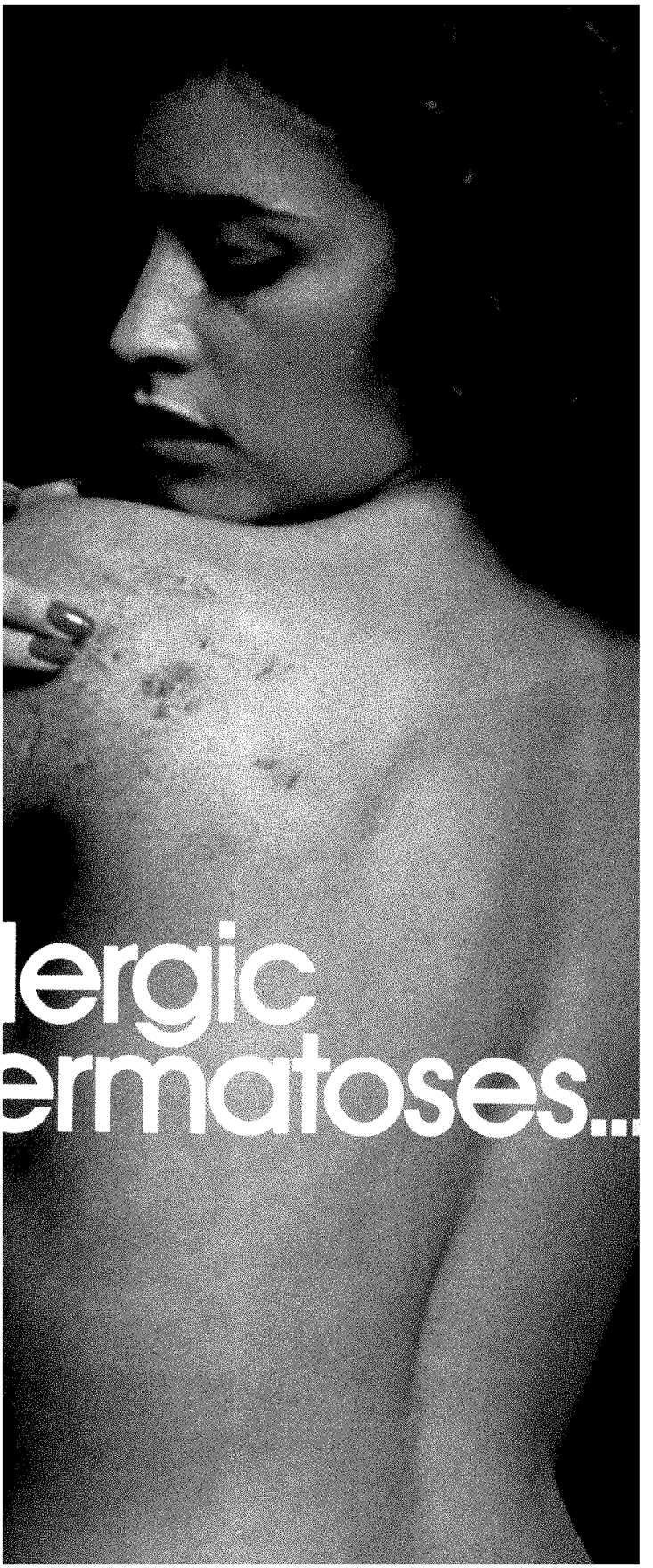
lergic
ermatoses...

rat, and rabbit, induced fetal abnormalities in the rat at doses substantially above the human therapeutic range. Clinical data in human beings are inadequate to establish safety in early pregnancy. Until such data are available, hydroxyzine is contraindicated in early pregnancy.

Precautions: Hydroxyzine may potentiate the action of central nervous system depressants such as meperidine and barbiturates. In conjunctive use, dosage for these drugs should be reduced. Because drowsiness may occur, patients should be cautioned against driving a car or operating dangerous machinery.

Adverse Reactions: Drowsiness may occur; if so, it is usually transitory and may disappear in a few days of continu therapy or upon dosage reduction. Dryness of the mouth may occur with higher doses. Involuntary motor activity, including rare instances of tremor and convulsions, has been reported, usually with higher than recommended dos

Supply: Tablets, containing 10 mg, 25 mg, or 50 mg hydroxyzine hydrochloride, 100's and 500's; Tablets, containin 100 mg, 100's; Syrup, containing 10 mg per teaspoonful (5 ml) and ethyl alcohol 0.5% v/v, pint bottles.

Before prescribing or administering, see package circular.

with strong emotional overlay

the cause can be obscure

Factors precipitating allergic dermatoses with strong emotional overlay, which can range from allergens to anxiety, can be difficult to identify.

successful treatment often includes

Atarax® (hydroxyzine HCl)

TABLETS: 10 mg, 25 mg, 50 mg, and 100 mg

- rapid antianxiety action
- demonstrated antihistaminic activity

ROERIG Pfizer
A division of Pfizer Pharmaceuticals

THE ONLY WAY TO END THE EPIDEMIC IS OVER HER DEAD BODY.

Kill the female itch mite (*sarcoptes scabiei*) and you've stopped the current scabies epidemic. Because when she burrows deep into the stratum corneum, she defies diagnosis and resists removal by surface-acting medications and cleansers. Her success has been making headlines around the country—with reports of scabies outbreaks in rural and suburban areas as well as in the cities.

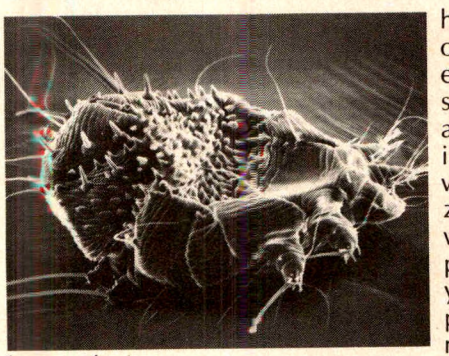

A quick and simple diagnosis. Scabies can mimic a number of dermatological conditions,[1-3] such as urticaria, furunculosis and dermatitis—as well as syphilis with which it may coexist. But there's an almost foolproof way to recognize it. Even in the absence of the fierce nocturnal itching[3] and the lesion distribution characteristic of the disease (hands, wrists and elbows in 9 out of 10 cases),[1] a quick microscopic look can confirm your scabies diagnosis.

To demonstrate the itch mite, look for an unscratched, inhabited burrow (wherever the patient says he itches at that very moment is a likely spot). Use a strong light, a magnifying glass and a surgical blade to which a drop of mineral oil is added. Scrape several sites. Transfer the material to a slide, cover and examine under low power magnification.[1,3,4] (If you don't spot any parasites in egg, larvae or adult stages, look for their red fecal compactions. They can be just as diagnostic.)

Kwell: penetrating action to kill mites, their eggs and larvae. Once you've found scabies, there's a positive way to eradicate it. Kwell (1% gamma benzene hexachloride) Lotion or Cream. It penetrates to reach the scabietic burrows, kills the female mites and, of course, the less tenacious males, as well as their eggs and any larvae that may have hatched. In fact, Kwell works so consistently and well against scabies that it has been the most widely prescribed scabicide for three decades.

Nearly 100% effective. The clinical record of Kwell has never been surpassed by any other pediculicide. It is "nearly 100% effective,"[1] and often works with a single application (a second or third application may be made at weekly intervals, if needed). Your patients will appreciate the low risk of sensitization and irritation.[5,6] And you will appreciate that Kwell works so predictably that it serves to confirm your diagnosis of scabies. Not many pharmaceutical preparations can match *that* record of dependability.

Contraindications: Kwell is contraindicated in individuals who develop hypersensitivity to the product or to any of its components.

Precautions: If accidental ingestion occurs, prompt institution of gastric lavage will rid the body of large amounts of the toxicant. However, since oils favor absorption, saline cathartics for intestinal evacuation should be given rather than oil laxatives.

Central nervous system manifestations can be antagonized by the administration of pentobarbital or phenobarbital in sufficiently large doses to the limit of their therapeutic effectiveness. It is not desirable to depress the patient to the point of hypnosis. However, persons poisoned with stimulants may tolerate large doses of barbiturate without undue depression and with great benefit. Intravenous calcium gluconate may be used in conjunction with the barbiturates. Epinephrine should not be used because ventricular fibrillation may result.

If accidental contact with eyes occurs, flush with water. If irritation or sensitization occurs, discontinue the product and consult physician.

Adverse Reactions: Eczematous eruptions due to sensitization of this product have been reported.

Available on prescription as Kwell Lotion in 2 and 16 fl. oz. bottles, and as Kwell Cream in 2 oz. and 1 lb. jars. See package insert for complete prescribing information.

References: 1. *Patient Care* 7:94, Nov. 1, 1973. 2. Stankler, L.: *Practitioner 210*:803, June 1973. 3. Domonkos, A.N. (ed.): Andrews' Diseases of the Skin: Clinical Dermatology, ed. 6, Philadelphia, W. B. Saunders Company, 1971, pp. 511-513. 4. Muller, G., *et al: Arch. Dermatol. 107*:70, Jan. 1973. 5. James, B.H.E.: *Br. Med. J. 1*:178, Jan. 15, 1972. 6. Sollman, T.: A Manual of Pharmacology, ed. 8, Philadelphia, W. B. Saunders Company, 1957, p. 178.

SEM Courtesy of J. M. Rawer, M.D., Columbus, Ohio.

Reed & Carnrick / Kenilworth, New Jersey 07033

Cream/Lotion

KWELL® gamma benzene hexachloride

THE SCABICIDE OF CHOICE.

An unsurpassed standard of therapy

PSORIASIS
The Capricious Dermatosis

LIDEX® (fluocinonide) 0.05%
A Stabilizing Influence

Psoriasis. Mere mention of the word can make an afflicted patient cringe. And, because of the capricious, unpredictable nature of the disease, the patient rarely knows where or when it will recur.

Obviously, the goal is control. And, though varied treatment modalities are available today, none offers universal

fficacy for all patients, all of the time.

Yet, very often a highly effective topical teroid, like Lidex, (fluocinonide) can elp stabilize psoriasis.

Lidex. A highly effective topical steroid vith anti-inflammatory, vasoconstrictive, ntipruritic actions.

100% dissolved for optimal penetration, important in stages that exhibit thickened, scaly lesions.

Totally free of preservatives.

Available in cream, ointment, and Topsyn® (fluocinonide) gel.

SYNTEX

SYNTEX LABORATORIES, INC.
PALO ALTO, CALIFORNIA 94304

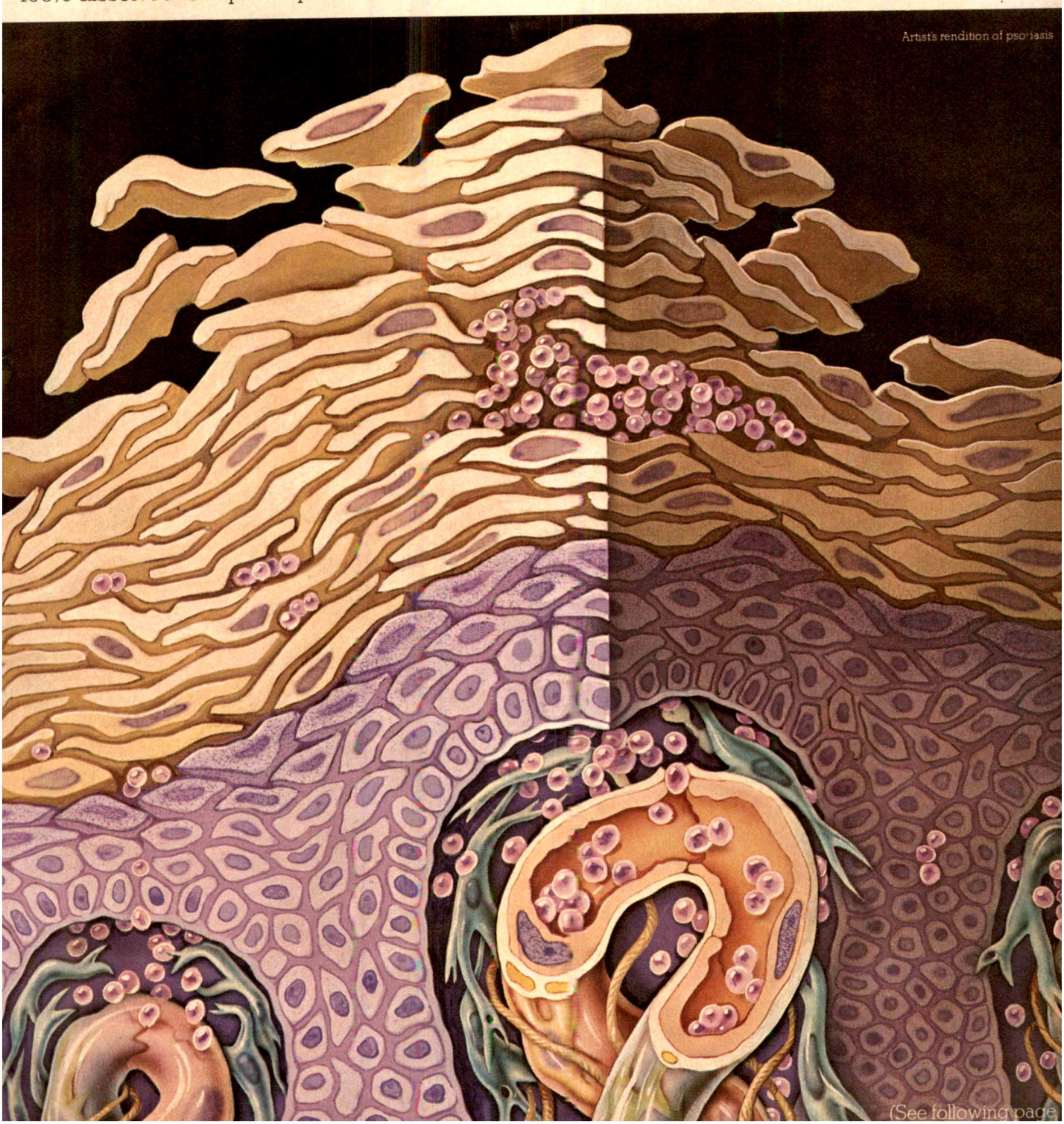

Artist's rendition of psoriasis

(See following page)

LIDEX® (fluocinonide)
0.05% Cream and Ointment

TOPSYN® (fluocinonide)
0.05% Gel

Summary of prescribing information

Description

LIDEX cream 0.05%, LIDEX ointment 0.05% and TOPSYN gel 0.05% contain the active compound fluocinonide. Fluocinonide, which is the 21-acetate ester of fluocinolone acetonide, has the chemical formula 6α, 9α, -difluoro-11β, 16α, 17α, 21-tetrahydroxypregna-1,4-diene-3, 20-dione, cyclic 16, 17-acetal with acetone 21-acetate. LIDEX cream contains fluocinonide in FAPG® cream, a specially formulated cream base consisting of stearyl alcohol, polyethylene glycol 6000, propylene glycol, 1, 2, 6-hexanetriol and citric acid. This white cream vehicle is greaseless, non-staining, anhydrous and completely water miscible. The base provides emollient and hydrophilic properties. In this formulation, the active ingredient is totally in solution.

LIDEX ointment contains fluocinonide in a specially formulated ointment base consisting of Amerchol CAB (mixture of sterols and higher alcohols), white petrolatum, propylene carbonate and propylene glycol. It provides the occlusive and emollient effects desirable in an ointment. In this formulation the active ingredient is totally in solution.

TOPSYN gel contains fluocinonide in a specially formulated gel base consisting of propylene glycol, propyl gallate, disodium edetate, and Carbopol 940 (carboxypolymethylene) with NaOH and/or HCL added to adjust the pH. This clear, colorless, thixotropic vehicle is greaseless, non-staining and completely water miscible. In this formulation, the active ingredient is totally in solution.

Indications

LIDEX cream and ointment and TOPSYN gel are intended for the relief of inflammatory manifestations of corticosteroid responsive dermatoses.

Contraindications

Topical steroids are contraindicated in vaccinia and varicella. Topical steroids are contraindicated in those patients with a history of hypersensitivity to any of the components of the preparation.

Precautions

If irritation develops, the cream, ointment or gel should be discontinued and appropriate therapy instituted. In the presence of an infection the use of an appropriate antifungal or antibacterial agent should be instituted.

If a favorable response does not occur promptly, the corticosteroid cream, ointment or gel should be discontinued until the infection has been adequately controlled.

If extensive areas are treated, the possibility exists of increased systemic absorption and suitable precautions should be taken.

Although topical steroids have not been reported to have an adverse effect on pregnancy, the safety of their use in pregnant females has not absolutely been established. Therefore, they should not be used extensively on pregnant patients, in large amounts or for prolonged periods of time.

LIDEX® (fluocinonide) cream and ointment and TOPSYN® (fluocinonide) gel are not for opthalmic use.

Adverse reactions

The following local adverse reactions have been reported with topical corticosteroids:

burning	folliculitis
itching	acneform eruptions
irritation	hypopigmentation
dryness	striae
secondary infection	skin atrophy

Dosage and administration

A small amount should be gently massaged into the affected area three or four times daily, as needed.

How supplied

LIDEX 0.05% Cream—15 g 30 g and 60 g tubes.
LIDEX 0.05% Ointment—15 g 30 g and 60 g tubes.
TOPSYN Gel 0.05% 15 g and 60 g tubes.

SYNTEX
SYNTEX LABORATORIES, INC
PALO ALTO, CALIFORNIA 94304

Ti y'r i re the 75-76 red and blue books

Profile of Medical Practice
Socioeconomic Issues of Health

Invaluable for anyone needing a quick, authoritative reference to vant data on the U.S. health care delivery system, these unique cations are compiled annually by the AMA Center for Health Se Research & Development.

The Red book, PROFILE OF MEDICAL PRACTICE, presents from the AMA Physician Masterfile and the Periodic Survey of sicians describing characteristics of medical practice such as zation of physicians' services; physicians' net income, expe fees; and other selected practice characteristics. It also inc essays on issues affecting the practice of medicine.

The Blue book, SOCIOECONOMIC ISSUES OF HEALTH, inc data on characteristics of the U.S. population; the health care ery system; medical education and licensure. Also included ar says on relevant health issues of general interest.

Quantities are limited so order yours today!

Order Dept., AMA, 535 N. Dearborn St., Chicago, Ill. 60610

Please send me the publications below in the quantities indicated. My check for $_____ , made payable to the AMA, is enclosed. (Previous editions of the Red and Blue Books available upon request.)

_____ PROFILE OF MEDICAL PRACTICE, OP-463, $4.50 ea.

_____ SOCIOECONOMIC ISSUES OF HEALTH, OP-462, $4.50 ea.

_____ set(s) $8.50 ea. S/J

Name _____

Address _____

City _____

State _____ Zip _____

All soaps for dry
kin are not alike...
especially Oilatum®
atum Soap is an old dry skin cleanser with an exciting
concept!
e there are several newer cleansers now available, most
tain hydrogenated oils, lanolin or mineral oil to provide
olliency.
w evidence[1], reported in the British Journal of Derma-
gy, suggests that a formula rich in linoleic acid "rapidly
tored to normal the abnormally high rates of transepi-
al water loss."
Oilatum Soap's pure vegetable oil is rich in this same
leic acid!
ditionally, Oilatum Soap is available in two forms—scented
unscented. Most dry skin cleansers don't offer you
choice... one which assumes considerable importance
en you have to consider the problem of patient
sitivity to perfumes.
STIEFEL
ogical Dermatologicals since 1847
el Laboratories, Inc.,
k Hill, N.Y. 12460
Laboratories (Canada) Ltd.,
Laurent, Quebec, Canada H4R 1E1
STIEFEL
ottey, C.; Hartop, P. J.; Black, J. G. and McCormack, J. I.: The
pair of impaired epidermal barrier function in rats by the cuta-
ous application of linoleic acid. Brit. J. Derm., 94, 13-21, 1976

Contains nothing that will interfere with or aggravate your acne regimen.

No sulfur, no salicylic acid, no medication, no perfume. Acne-Aid® Detergent Soap means gentle cleaning, *pure and simple.*

You can recommend it with even your most aggressive therapeutic measures, such as tretinoin or PanOxyl®... where many medicated soaps may be contraindicated.

STIEFEL
Logical Dermatologicals since 1847

Stiefel Laboratories, Inc.,
Oak Hill, N.Y. 12460
Stiefel Laboratories (Canada) Ltd.,
St. Laurent, Quebec, Canada H4R 1E1

we proudly announce publication of

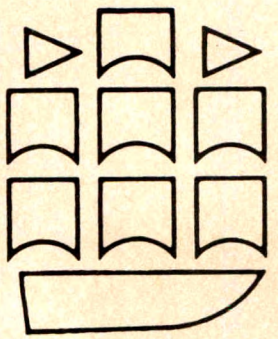

Recent Advances in Dermatology, No. 4

Edited by **Arthur Rook** MD FRCP

This handsome new volume provides from the literature of the past decade practical, selective and critical reviews dealing with the laboratory and clinical aspects of diseases commonly found in dermatological practice.

Contents

Preface
Contributors
Opportunism and Skin Infections/J.A. Savin, W. C. Nobel
The Sexually Transmitted Diseases/R.D. Catterall
Arthropods and the Skin/Brian Bagnall, Arthur Rook
Tropical Skin Diseases in Temperate Climates/R.R. M. Harman
Sweat Glands and Their Disorders/Katherine Grice/Julian Verbov
Leg Ulcers/Robin D.G. Peachey
Common Baldness and Alopecia Areata/Arthur Rook
Tumours of the Skin/John H. Epstein, Richard W. Sagebiel, Richard C. Connors, Bernard Ackerman
Tropical Therapy/A.W. McKenzie, D.S. Wilkinson
Ionising Radiation in Benign Dermatoses/Neville Rowell
Drug Reactions/Ashley Levantine, John Almeyda
Index

1977. 352 pages 29 halftone and 11 line illustrations; charts; biblio.
ISBN 0 443 01318 7 LC 76-41899 $27.50

If you have Book No. 3 of this series, here is No. 4 to complement it.

Forthcoming

Malignant Melanoma of the Skin and Mucous Membrane

by **Gerald W. Milton** MBBS FRCS FRACS

This book will offer expert guidance to those confronted with a patient presenting this problem. Probably more than any other clinician in the world, Milton has topnotch experience of the diagnosis and treatment of this condition.

approx. 200 pp., 6-page color section
due Aug./Sept. 1977 ISBN 0 443 01422 1 $29.00

Of related interest

Nursing Procedures for Skin Diseases

by **Eileen Huckbody** SRN RFN RCNT

Offers specialized instruction on remedial procedures covering varied aspects of nursing skin diseases. Useful to nurses studying dermatology, working in wards with skin patients and in the community, particularly among the aged, where skin changes often present difficult problems. Skin afflictions in school children and skin allergies arising within occupational environments are also covered.

1977. 135 pp. 26 halftone illustrations
ISBN 0 443 01538 4 LC 76-41737 spiral bound $7.50

Churchill Livingstone
Medical Division of **Longman Inc.**
19 West 44th St.
New York, NY 10036
Phone (212) 354-3166

Please send:

- ☐ Rook: **Recent Advances in Dermatology, No. 4** (013187) $27.50
- ☐ Milton: **Malignant Melanoma of the Skin and Mucous Membrane** (014221) $29.00
- ☐ Huckbody: **Nursing Procedures for Skin Diseases** (015384) $7.50

Please note my standing order for each new volume as published:

- ☐ **Recent Advances in Dermatology**

Name (Pls. Print) _____ Signature _____

Address Include City, State & Zip Code (Pls. Print) _____

Mode of Payment:

☐ Check enclosed for $_____* (NY residents, please add applicable sales tax.) Please make Check payable to Longman Inc.

☐ Charge (all orders subject to credit approval)
☐ American Express ☐ BankAmericard
☐ Master Charge

Expire Date _____

Account No. _____

Interbank No. (Master Charge Only.) _____

*There will be no shipping and handling charges on prepaid orders. Prices are subject to change without notice.

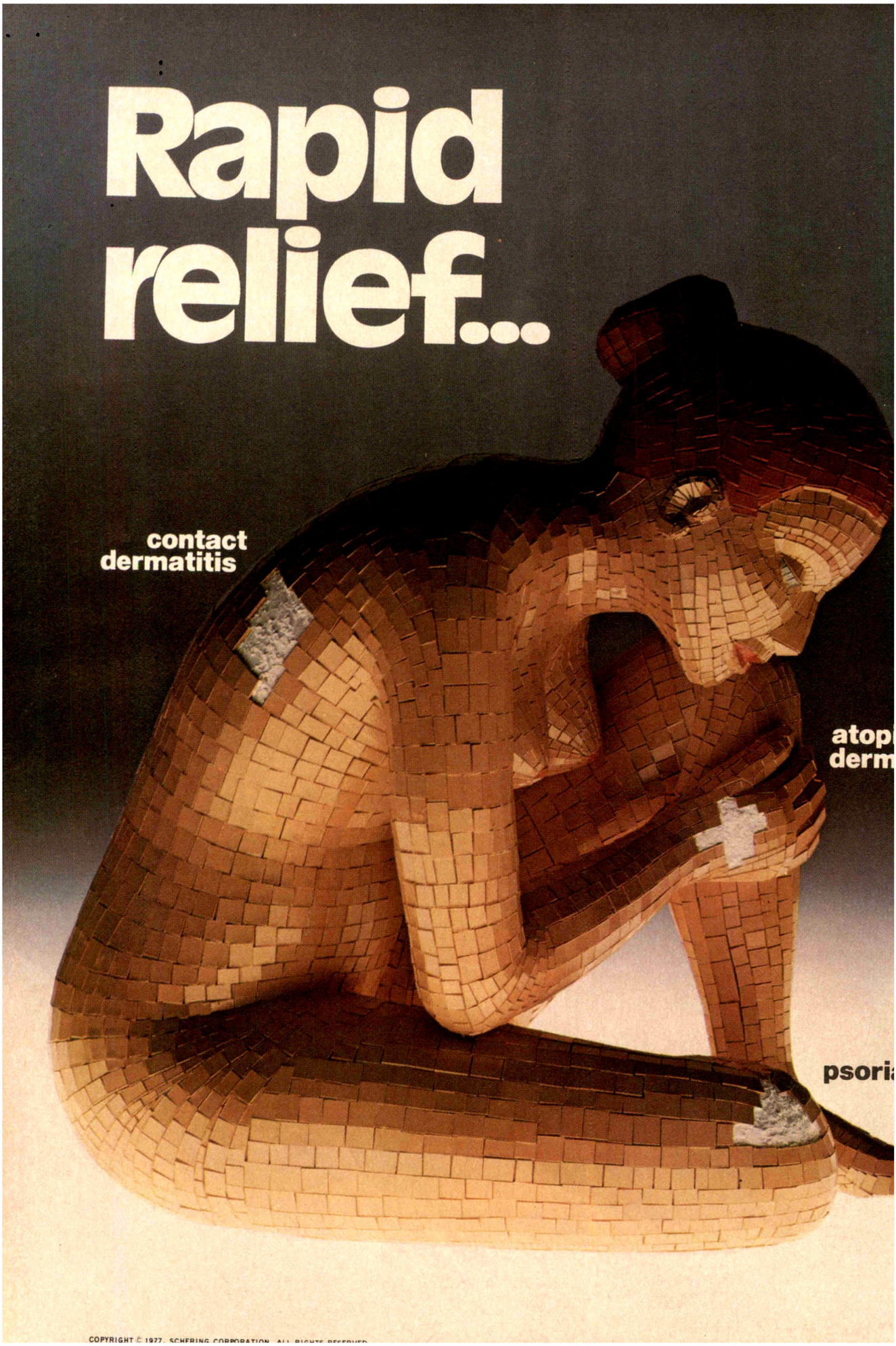

COPYRIGHT © 1977, SCHERING CORPORATION, ALL RIGHTS RESERVED

Schering

b.i.d. Diprosone®

brand of
betamethasone dipropionate
Cream 0.05%
(Potency expressed as betamethasone)

Twice a day for prompt relief of corticosteroid-responsive dermatoses

In contact dermatitis

90% of patients showed marked or moderate improvement in seven days*
34 of 38 contact dermatitis patients responded to therapy.

In atopic dermatitis

86% of patients showed marked or moderate improvement in seven days*
133 of 155 atopic dermatitis patients responded to therapy.

In psoriasis

62% of patients showed marked or moderate improvement in only seven days*
116 of 188 psoriasis patients responded to therapy.

Additional benefits:

- Rapid onset of response.
- Economy and convenience of b.i.d. dosage.
- Occlusive dressings infrequently needed.
- Sensitivity is rare.
- Choice of convenient package sizes—in 15 Gm. and moneysaving 45 Gm. tubes.

Diprosone® brand of betamethasone dipropionate
Cream 0.05%/Ointment 0.05%

Clinical Considerations:

DESCRIPTION DIPROSONE is betamethasone dipropionate (9-fluoro-11β, 17,21-trihydroxy-16β-methylpregna-1,4-diene-3,20-dione 17,21-di propionate). Each gram of DIPROSONE **Cream** 0.05% contains 0.64 mg. betamethasone dipropionate (equivalent to 0.5 mg. betamethasone) in a hydrophilic, emollient cream consisting of purified water, mineral oil, white petrolatum, polyethylene glycol 1000 monocetyl ether, cetostearyl alcohol, phosphoric acid, and monobasic sodium phosphate with 4-chloro-*m*-cresol as preservative. Each gram of DIPROSONE **Ointment** 0.05% contains 0.64 mg. betamethasone dipropionate (equivalent to 0.5 mg. betamethasone) in an ointment base of mineral oil and white petrolatum. **CONTRAINDICATIONS** DIPROSONE **Cream** and **Ointment** are contraindicated in vaccinia and varicella. Topical steroids are contraindicated in those patients with a history of hypersensitivity to any of the components of such preparations. **PRECAUTIONS** If irritation develops with the use of DIPROSONE **Cream** or **Ointment,** treatment should be discontinued and appropriate therapy instituted. In the presence of an infection, the use of an appropriate antifungal or antibacterial agent should be instituted. If a favorable response does not occur promptly, the corticosteroid should be discontinued until the infection has been adequately controlled. If extensive areas are treated or if the occlusive technique is used, the possibility exists of increased systemic absorption of the corticosteroid and suitable precautions should be taken. Although topical steroids have not been reported to have an adverse effect on pregnancy, the safety of their use in pregnant females has not been absolutely established. Therefore, they should not be used extensively on pregnant patients, in large amounts or for prolonged periods of time. DIPROSONE **Cream** and **Ointment** are not for ophthalmic use. **ADVERSE REACTIONS** The following local adverse reactions have been reported with topical corticosteroids: burning; itching; irritation; dryness; folliculitis; hypertrichosis; acneiform eruptions; hypopigmentation. The following may occur more frequently with occlusive dressings than without such therapy: maceration of the skin; secondary infection; skin atrophy; striae miliaria. **DOSAGE AND ADMINISTRATION** Apply a thin film of DIPROSONE **Cream** to the affected skin areas twice daily, in the morning and at night. Clinical studies of DIPROSONE have indicated that applications twice a day are generally adequate. Apply a small quantity of DIPROSONE **Ointment** to the affected skin areas twice daily, in the morning and at night.

APRIL 197

For more complete details, consult package insert or Schering literature available from your Schering Representative or Professional Services Department, Schering Corporation, Kenilworth, New Jersey 07033.

*Data in files of Headquarters Medical Research Division, Schering Corporation.

Also available for prescribing flexibility

b.i.d. Diprosone® Ointment 0.05%
brand of betamethasone dipropionate

SLS-7

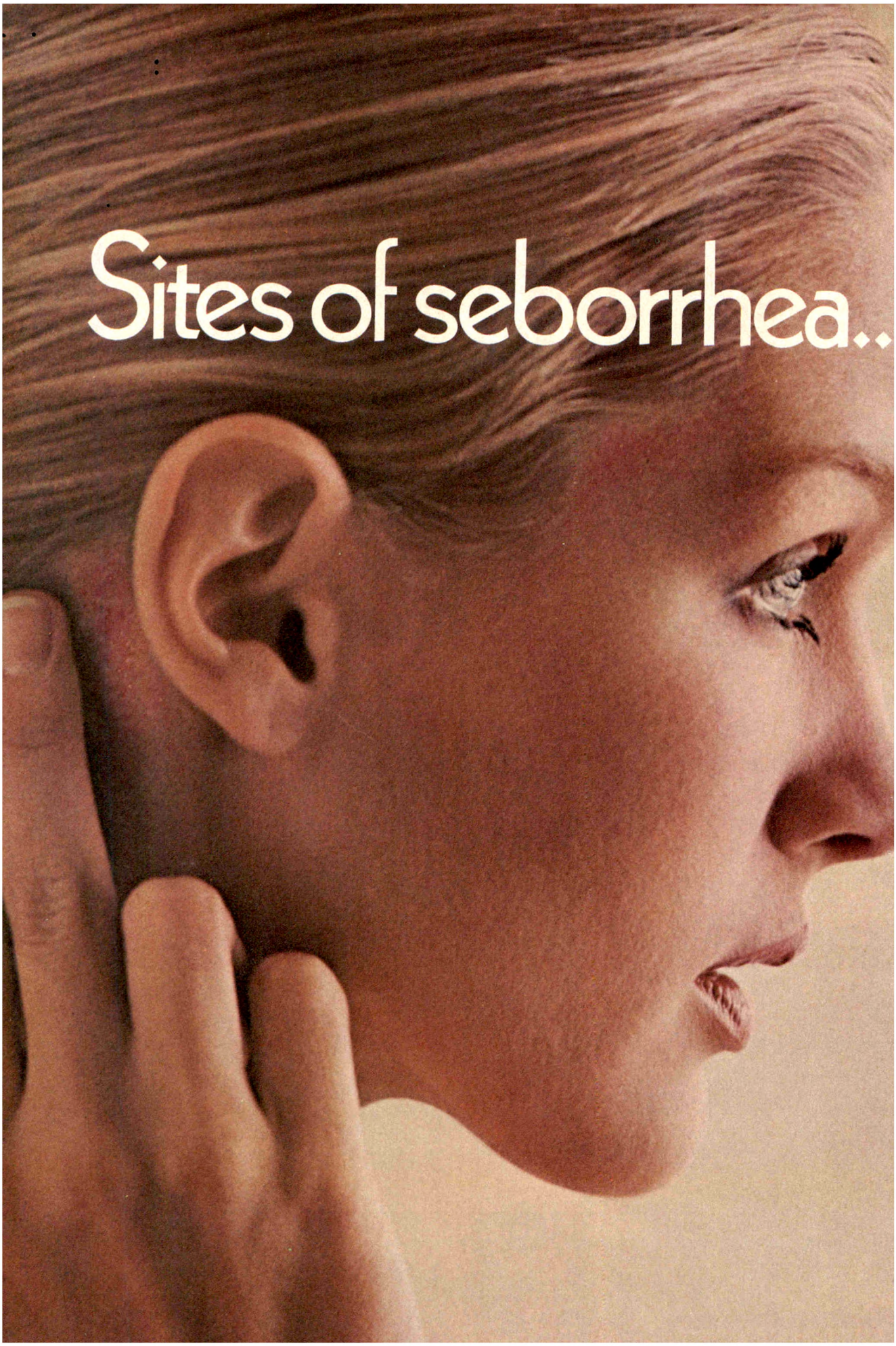
Sites of seborrhea..

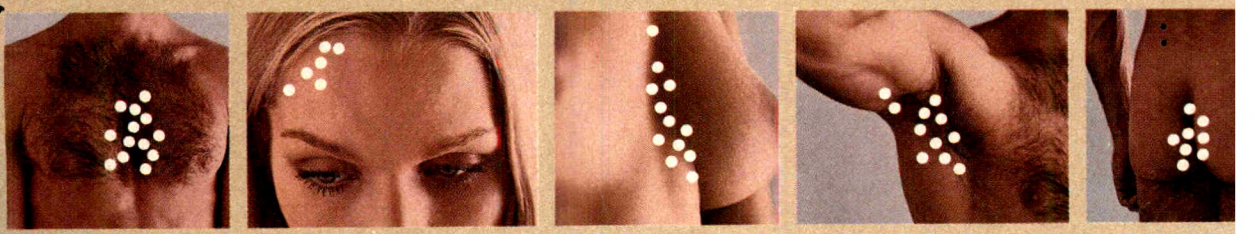

spots for Uticor (betamethason benzoat

a highly effective topical steroid in a special base

UTICORT contains the fluorinated corticosteroid ester — betamethasone benzoate 0.025% — in a s formulated, clear, self-liquefying gel base to increase steroid activity.
Patients with seborrheic dermatitis treated with UTICORT improved 86% in an average of 11.6

liquefies on application for better surface contact

UTICORT is especially valuable in the treatment of seborrheic dermatitis on hairy areas of the

cosmetically acceptable

UTICORT dries to a clear film and can be used confidently on either smooth or hairy skin area Moreover, it is greaseless, nonstaining, and nonsticky.

preservative free

Contains no parabens or other potentially sensitizing preservatives.

MEDICINE LIBRARY

Brief summary of prescribing information

INDICATIONS. Uticort Gel (betamethasone benzoate) is intended for relief of the inflammatory manifestations of corticosteroid-responsive dermatoses.

CONTRAINDICATIONS. Topical steroids are contraindicated in viral diseases of the skin, such as varicella and vaccinia. Topical steroids are contraindicated in patients with a history of sensitivity to any of the components of the preparation.

This preparation is not for ophthalmic use.

PRECAUTIONS. If irritation develops, the gel should be discontinued and appropriate therapy instituted. In the presence of an infection, the use of appropriate antifungal or antibacterial agents should be instituted. If a favorable response does not occur promptly, the corticosteroid should be discontinued until the infection has been adequately controlled.

If extensive areas are treated, or if the occlusive technique is used, the possibility exists of increased systemic absorption of the corticosteroid,

Although topical steroids have not been reported to have effect on pregnancy, the safety of their use in pregnant fem absolutely been established. Therefore, they should not be sively on pregnant patients, or in large amounts, or for prolon of time.

Due to the alcohol content of the vehicle, Uticort Gel (bet benzoate) may cause mild, transient stinging without irritatio excoriated skin.

ADVERSE REACTIONS. The following local adverse reaction reported with topical corticosteroids: burning sensations, it tion, dryness, folliculitis, secondary infection, skin atrophy, s trichosis, acneform eruptions, and hypopigmentation.

DOSAGE AND ADMINISTRATION. Apply to affected areas times daily as needed.

HOW SUPPLIED. N 0071-3025 Uticort Gel is supplied in 15 tubes.

ROCHE

Roche Laboratories announces an additional therapeuti application for Efudex® 5% Cream fluorouracil/Roche

now indicated for superficial basal cell carcinoma

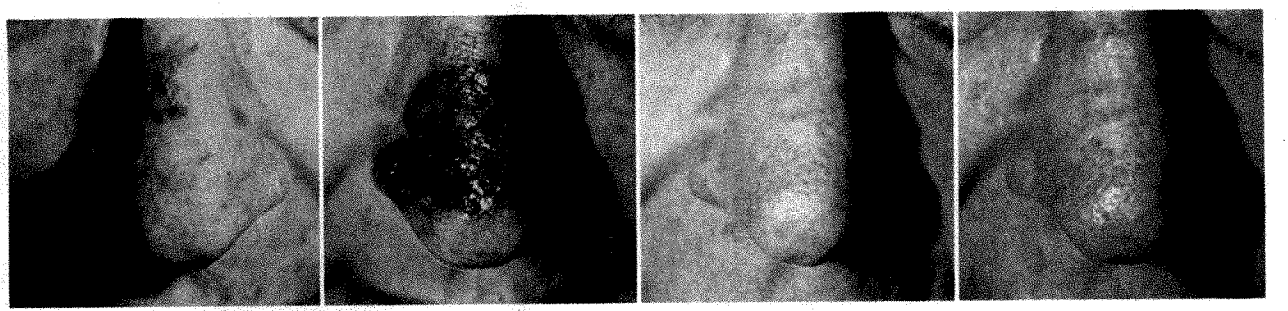

8/8/69
Before treatment a superficial, scaly, slightly excoriated lesion was present. Biopsy revealed the lesion to be a superficial basal cell carcinoma.

9/25/69
After 7 weeks of treatment with Efudex (fluorouracil) 5% Cream, lesion site is clearly delineated, markedly erythematous; surrounding skin shows no reaction to medication. Treatment terminated.

12/10/70
Follow-up approximately 14 months after treatment; healing has occurred with minimal scarring.

4/18/74
Patient has been followed continuously since treatment. **No evidence of recurrence.**

Efudex (fluorouracil) 5% Cream is recommended as an effective topical alternative to surgery for multiple lesions and difficult treatment sites.

A proven cytotoxic agent that exerts a marked effect on cells that grow more rapidly.

Cosmetically gratifying results, with minimal or no scarring. No systemic toxicity. Normal tissue rarely affected. Convenient, economical b.i.d. application.

Prolonged exposure to ultraviolet light may accelerate reaction to medication. If an occlusive dressing is used, there may be an increase in the incidence of inflammatory reactions in the adjacent normal skin.

An exclusive Roche formulation

Efudex® 5% Cream
fluorouracil/Roche

Before prescribing, please consult complete product information, a summary of which follows:
Indications: Multiple actinic or solar keratoses; superficial basal cell carcinomas when conventional methods are impractical (5% strength only).
Contraindications: If occlusive dressing is used, may increase inflammatory reactions in adjacent normal skin. Avoid prolonged exposure to ultraviolet rays. Safe use in pregnancy not established.
Precautions: If applied with fingers, wash hands immediately. Apply with care near eyes, nose and mouth. Solar keratoses failing to respond should be biopsied; perform follow-up biopsies in superficial basal cell carcinoma.
Adverse Reactions: Local—pain, pruritus, hyperpigmentation and burning at application site most frequent; also dermatitis, scarring, soreness, tenderness, suppuration, scaling and swelling. Also reported—insomnia, stomatitis, irritability, medicinal taste, photosensitivity, lacrimation, telangiectasia, leukocytosis, thrombocytopenia, toxic granulation and eosinophilia.
Dosage and Administration: *Actinic or solar keratosis*—apply sufficient quantity to cover lesions, twice daily. Usual length of therapy is 2 to 4 weeks. *Superficial basal cell carcinomas*—apply sufficient quantity **(only 5% strength recommended)** to cover lesions, twice daily. Continue treatment for at least 3 to 6 weeks, but possibly as long as 10 to 12.
How Supplied: Solution, 10-ml drop dispensers containing 2% or 5% fluorouracil on a weight/weight basis. Cream, 25-Gm tubes containing 5% fluorouracil in a vanishing cream base.

ROCHE

Roche Laboratories
Division of Hoffmann-La Roche Inc
Nutley, New Jersey 07110

what's best for the care of dry, or premature aging or wrinkled skin... DUE TO EPIDERMAL DEHYDRATION?

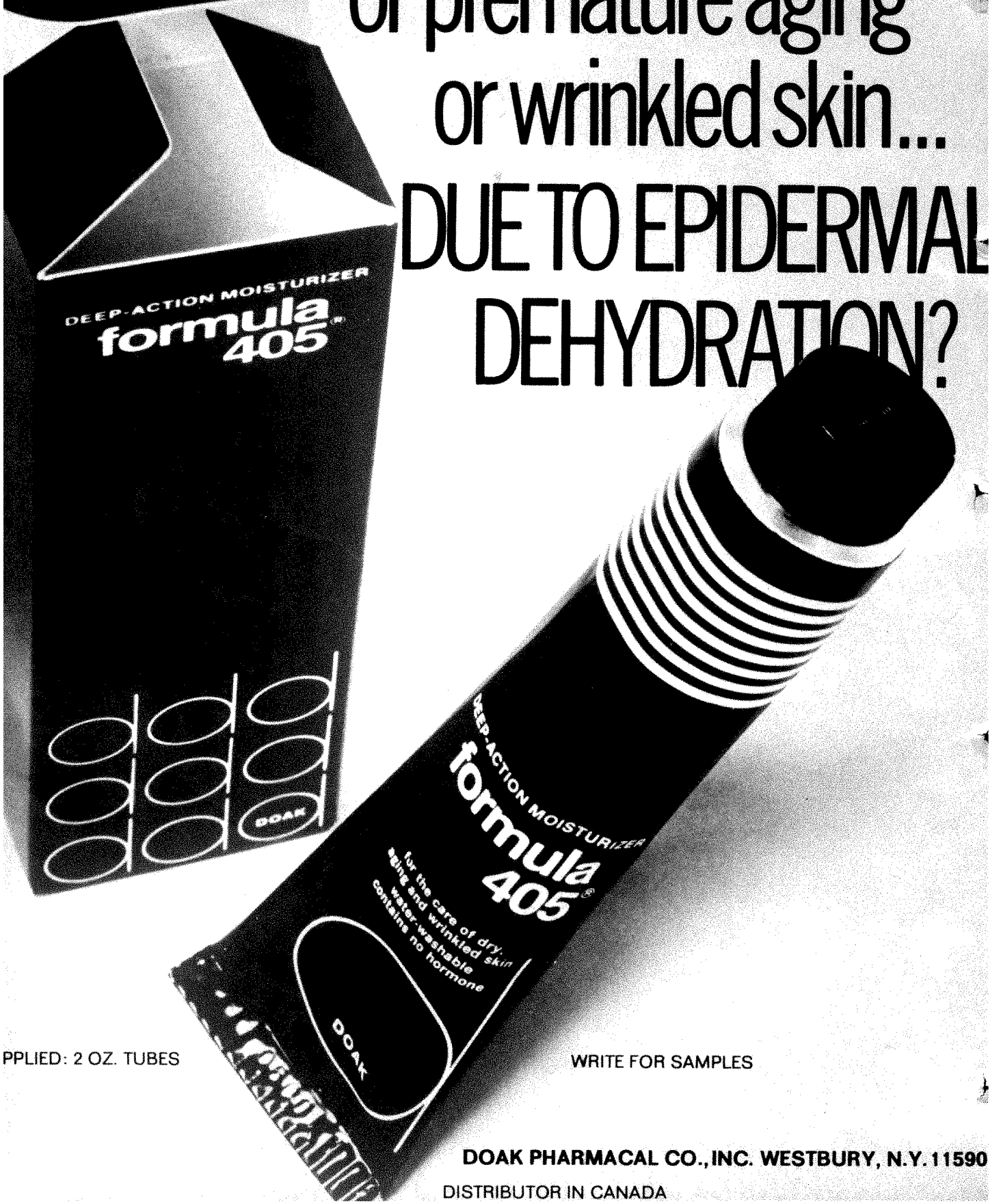

PPLIED: 2 OZ. TUBES

WRITE FOR SAMPLES

DOAK PHARMACAL CO., INC. WESTBURY, N.Y. 11590

DISTRIBUTOR IN CANADA



Bee-sting Allergy

Phadebas RAST® provides an accurate means of documenting IgE mediated allergic sensitivity to stinging insects.

Phadebas RAST®

the *in vitro* alternative

Pharmacia Diagnostics AB
Uppsala, Sweden

Pharmacia Diagnostics

Argentina Laboratorios Dr. Gador y Cia., S.A.C.I. Casilla de Correo 4041 BUENOS AIRES. **Australia** Pharmacia (South Seas) Pty. Ltd. P.O. Box 175 Cnr Talavera&Khartoum Roads NORTH RYDE N.S.W. 2113 **Austria** Pharmacia Gesellschaft m.b.H. Rathausplatz 4 A-1010 WIEN. Schoeller-Pharma G.m.b.H. Postfach 103 A-1111 WIEN. **Belgium** S.A. Pharmacia Belga N.V. Bld. Gen. Jacqueslaan 26 B-1050 BRUSSELS. **Brazil** Emprêsa Medimex Importação e Comércio Ltda. Rua Cardoso Marinho, 40 Caixa Postal 33-ZC-00 RIO DE JANEIRO. **Canada** Pharmacia (Canada) Ltd. 2044 boul. St. Régis Blvd. DOVAL, Québec H9P 1H6. **Denmark** Pharmacia AS, Herredsvejen DK-3400 HILLERØD. **Finland** Pharmacia OY Alexandersgatan 48 A SF-HELSINGFORS 10. **France** Pharmacia France S.A. Rue de Marly Parly 2 F-78150 LE CHESNAY. **German Federal Republic** Deutsche Pharmacia GmbH Munziner Strasse 9 Postfach 5480 D-7800 FREIBURG 1. **Great Britain** Pharmacia (G.B.) Ltd. Paramount House 75 Uxbridge Road LONDON W5 5SS. **Greece** G.A. Kambanis Imports-Exports-Representations 3 Iridanou Street ATHENS 612. **Italy** Importex Chimici Farmaceutici S.p.A. P.O. Box 467 Via Flavia 122/124 I-34100 TRIESTE. **Mexico** Internacional Cientifica, S.A. Apartado 66-558 Zona 12 MEXICO 8 D.F. **The Netherlands** Gist-Brocades N.V. Diagnostics Dept. P.O. Box 324 Frijdastraat 7–9 RIJSWIJK (Z H) 2109. **Norway** Norsk Pharmacia A/S Postboks 2005 Grünerløkka OSLO 5. **Portugal** J.A. Baptista D'Almeida Lda. Apartado 1339 LISBOA 1. **South Africa** Keatings Medical Industries (Pty) Ltd. P.O. Box 256 JOHANNESBURG 2000 R.S.A. **Spain** Atom Paseo del Monte 34 BARCELONA 12. **Sweden** Pharmacia Norden AB Diagnostic Dept. Box 159 751 04 UPPSALA 1. **Switzerland** Pharmacia-pdf-(Schweiz) A.G. 214 Seefeldstrasse CH-8034 ZUERICH. **USA** Pharmacia Diagnostics Division of Pharmacia Inc. 800 Centennial Avenue PISCATAWAY, New Jersey 08854. **Other countries** Pharmacia Diagnostics AB Box 17 S-751 03 UPPSALA 1, Sweden.

For Skin Without Water

Neutrogena® Dry Skin products are specially formulated to supplement surface fats and aid in the retention of moisture.

- Neutrogena® Dry-Skin Soap contains humectants, lubricants, and emollients to soften and moisturize, and is nonirritating to sensitive skin.
- Neutrogena® Rainbath® Dry Skin Bath Gel is lipid-free, cleanses with a rich lather without the drying effect of ordinary soap, and leaves skin soft and smooth. Available both scented and unscented.
- Neutrogena® Hand Cream is a heavy-duty formula containing a special blend of naturally occurring oils and glycerin, and is a useful adjunct in steroid-responsive hand dermatoses.[1]

1. Data on file, Medical Dept., Neutrogena Corp.

Neutrogena®
Dedicated to Sensitive Skin Care

Neutrogena Corp.
5755 West 96th Street
Los Angeles, California 90045

LENOX HILL HOSPITAL
Announces a Symposium on

TUMORS OF THE EYELIDS, ORBIT AND OCULAR ADNEXAE

October 27, 28, 29, 1977

This Symposium will be devoted to the diagnosis, pathogenesis and treatment of tumors of the eyelids and orbit, emphasizing basal cell carcinoma of the eyelids. The course will be presented by outstanding ophthalmologists, ophthalmic plastic surgeons, plastic surgeons, x-ray therapists, dermatologists, immunotherapists, cryosurgeons and pathologists.

The format will consist of lectures, panel discussions, surgical films and videotapes of surgery.

THE FACULTY WILL INCLUDE:
Albert Hornblass, M.D., Course Director
Edgar Berry, M.D.
Charles Beyer, M.D.
Jackson Coleman, M.D.
Anthony Domonkis, M.D.
Andrew Ferry, M.D.
Paul Henkind, M.D.
Crowell Beard, M.D.
Henry Gougelman, M.D.
Lazlo Bird, M.D.
Morris Leider, M.D.
David Soll, M.D.
Byron Smith, M.D.
Perry Robins, M.D.
Michael Tenner, M.D.
Seamus Lynch, M.D.
Stephen Trokel, M.D.
and others

TUITION:

Practitioners	$200.00
Residents	$75.00

FOR FURTHER INFORMATION WRITE TO:
Department of Ophthalmology
Lenox Hill Hospital
100 East 77th Street
New York, New York 10021

This activity is acceptable for 21 credit hours in Category I

Enjoy a Hawaiian Holiday— Surf, Sun and CME



AMA's Regional CME Sheraton-Waikiki Honolulu, Hawaii Oct. 31-Nov. 4, 1977

Write:
Dept. of Meeting Services
American Medical Association
535 N. Dearborn St.
Chicago, Ill. 60610

For Skin Plagued by Acne

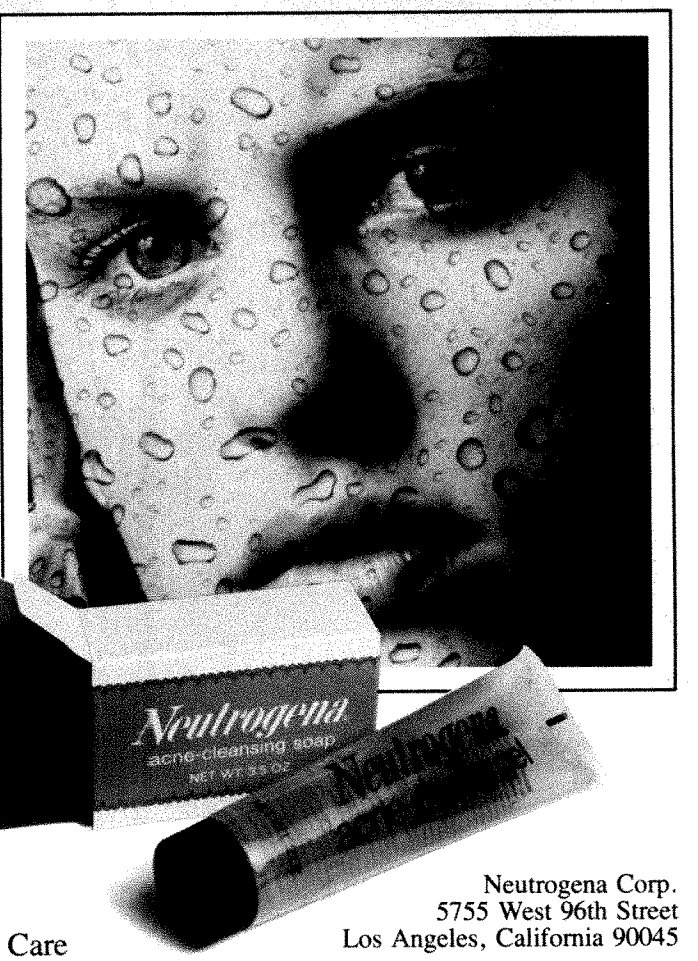

Neutrogena® Acne products aid in drying while they clean and degrease acne-plagued skin.

- Neutrogena® Acne-Cleansing Soap gently cleanses and degreases the skin, and does not interfere with topical or systemic acne treatment.
- Neutrogena® Acne-Drying Gel combines antisepsis with astringency, contains 47% active drying agents, is perfume-free, can be applied under or over makeup, and is imperceptible on the skin.

Neutrogena®
Dedicated to Sensitive Skin Care

Neutrogena Corp.
5755 West 96th Street
Los Angeles, California 90045

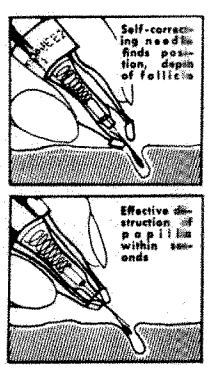

Perma Tweez®

ELECTROLYSIS FOR PERMANENT HAIR REMOVAL

Clinical study (copy on request) proves safety and efficacy of laity self-use electrolysis. Study shows chin and even axilla can be self-treated effectively through use of mirror. This permanent hair remover features the only patented self-correcting needle in existence. Battery operated instrument sterilizes itself when current flows. No-puncture safety feature also helps prevent infection.

Thousands of units sold to physicians for such varied application as removal of inverted eyelashes to cosmetic use.

PERMA TWEEZ & ATTACHMENT **$22.45**

☐ Invoice after 30 days

☐ Check enclosed

30 DAY FREE TRIAL EXAMINATION
(MAY BE RETURNED WITH NO OBLIGATION)

GENERAL MEDICAL CO., Dept. D-87
1935 Armacost Ave
West Los Angeles, CA 90025

DR _____
STREET _____
C/S _____ ZIP _____

CHARLES C THOMAS • PUBLISHER

CRYOSURGICAL ADVANCES IN DERMATOLOGY AND TUMORS OF THE HEAD AND NECK *edited by* **Setrag A. Zacarian,** *Boston Univ., Boston, Massachusetts. Forewords by* **John G. Bellows** *and* **Edward Krull.** *(11 Contributors)* This treatise is a most comprehensive review of cryosurgery for management of benign and malignant tumors of the skin, oral cavity, and head and neck. The fundamentals of cryogenesis, the development of the cryolesion, temperature monitoring, double freeze-thaw cycles and the pathogenesis of cryonecrosis are all reviewed in depth. The selection of various cryosurgical instruments and their respective applications and limitations are frankly discussed. Experimental data and supportive evidence in the area of cryoimmunology are explored and fully outlined. The contributors, all pioneers and outstanding professionals in their respective areas, guide the clinician through the laboratory aspects of cryosurgery, from the carefully controlled animal studies to the vast clinical experiences of tumor cryosurgery. They outline the cryosurgical management of patients with acne, benign lesions, and common and advanced skin cancers as well as the rare lentigo maligna. The less common but significant and difficult area of eyelid tumors is thoroughly discussed, clearly delineating the preservation of the lacrimal duct from freezing. The current success in the management of trichiasis with cryosurgery is also examined. *'77, 296 pp. (7 x 10), 473 il. (122 in color), 31 tables, $33.00.*

THE ULTRASTRUCTURE OF COLLAGEN: Its Relation to the Healing of Wounds and to the Management of Hypertrophic Scar *edited by* **J. J. Longacre.** *(35 Contributors)* Ever since the earliest recorded writings of man, scar has been a word with unpleasant connotations related to mutilation, disfigurement and loss of function. However, if it were not for the final conversion of granulation tissue into mature scar, no wound would heal firmly. These natural forces must be harnessed and made beneficial to man. This text relates the ultrastructure of collagen to the healing of wounds and the surgical management of hypertrophic scar and includes advanced knowledge on causation, treatment and prevention of hypertrophic scarring. A few of the topics discussed include wound sepsis, the basis of the histological demonstration of tension in collagen, burn contractures and keloids, the relation of collagen metabolism and hypertrophic scars, collagen degradation in normal and abnormal tissues, distribution of oxygen and its significance in healing tissue, the role of environmental factors on connective tissue cell metabolism, scanning and transmission electron microscopic studies, and behavior of scar tissue through its evolution with and without surgery. *'76, 537 pp. (6 3/4 x 9 3/4), 537 il., 28 tables, $41.50*

THE DOCTOR'S LAWYER: A Legal Handbook for Doctors *by* **Marc J. Lane,** *Chicago Bar Association, Chicago.* This handbook can help any doctor in maximizing opportune legal situations and in avoiding the obvious and not-so-obvious pitfalls of his practice and of life in general. A concise, common sense analysis of one legal concept introduces each chapter. Then, in checklist or outline form, the topic is logically developed. Without having to wade through pages of prose, the doctor can discover, for example, if the cost of traveling to an educational seminar is tax deductible, whether he should lease his laboratory equipment or buy it outright, and whether or not he should go into partnership. *'74, 112 pp. (8 1/2 x 11), 6 il., 5 tables, $12.75*

SKIN SURGERY (4th Ed.) *edited by* **Ervin Epstein** *and* **Ervin Epstein, Jr.,** *both of the Univ. of California Medical School. (45 Contributors)* Forty-five prominent authorities in such fields as dermatology, surgery and plastic surgery have contributed their expertise to this greatly expanded Fourth Edition. Over 150 new pages and more than 400 new illustrations have been added to bring this book up-to-date and in line with the rapidly growing interest in the field. The original five sections have been retained, but the format within these sections has been completely revamped and revised to accommodate new developments in cold steel surgery, electrosurgery, special procedures and special locations of disease. In addition, three new sections have been added which focus on chemosurgery, cryosurgery and investigative surgical therapy of the skin. A sampling of specific topics includes anesthesia, medicolegal problems, tattoo removal, eyelid surgery, and do-it-yourself instruments. The depth and clarity of this book make it a must for anyone involved or interested in surgery of the skin. *'77, 864 pp. (7 x 10), 1081 il. (19 in color), 37 tables, $98.75*

DERMATOPHYTES IN HUMAN SKIN, HAIR AND NAILS *by* **James T. Sinski,** *Univ. of Arizona, Tucson.* This book will aid dermatologists, medical technologists, microbiology students and laboratory administrators who are concerned with the microscopic examination of human skin, hair and nails for possible dermatophyte infection. This photographic essay is concerned with the typical, as well as the atypical morphology of fungi in human skin, nails and hair, with emphasis being placed on the differentiation of causal organisms as they are seen in clinical materials. The depiction of a number of artifacts seen during these examinations is also included since these may be confused with fungal elements. A number of choices of equipment for acquiring and storing a sample are given based on the site of the human body to be sampled, the funds available for equipment, and the physical characteristics of the laboratory. Practical suggestions for the processing of a specimen for microscopic examination are given, including reagents and equipment used. *'74, 64 pp. (6 3/4 x 9 3/4), 35 il., $7.95*

NAIL DISEASES In Internal Medicine *by* **Pietro de Nicola,** *Univ. of Pavia, Pavia, Italy, and* **Mario Morsiani** *and* **Giorgio Zavagli,** *both of the Univ. of Ferrara, Ferrara, Italy.* Anatomy, histology, embryology, chemical composition and histochemistry of the nail are presented in a short introductory chapter. The principal part of the book is concerned with the clinical aspects of nail disorders, including the most relevant nail symptoms. A clear description is presented of all nail symptoms, most of which are not well known and deserve consideration in clinical practice. Original illustrations, most of which are color plates, are particularly helpful in the description of nail symptoms and disorders. *'74, 128 pp., 18 il. (8 in color), $10.50*

BEHAVIORAL SCIENCE IN CLINICAL MEDICINE *by* **Stewart Wolf,** *Univ. of Texas, Galveston, and* **Helen Goodell,** *Cornell-New York Hospital Medical Center, New York.* The importance of understanding the patient before practice, diagnosis and treatment can be effective is illustrated in this text. The authors discuss behavioral science in the context of human ecology, man's needs and expectations, the significance of medical education, the cultivation of the individual, values, and fulfillment. *'76, 256 pp., 22 il., $14.50*

Orders with remittance sent, on approval, postpaid

301-327 East Lawrence Avenue • Springfield • Illinois • 62717

ECLIPSE®

(3% glyceryl PABA and 3% octyl dimethyl PABA)

For your patients

who can't-or won't-stay out of the sun.

For some, it's occupation. For others, the social desirability of a tan. Whatever the reason, many of your patients may be spending more time in the sun than you'd like.

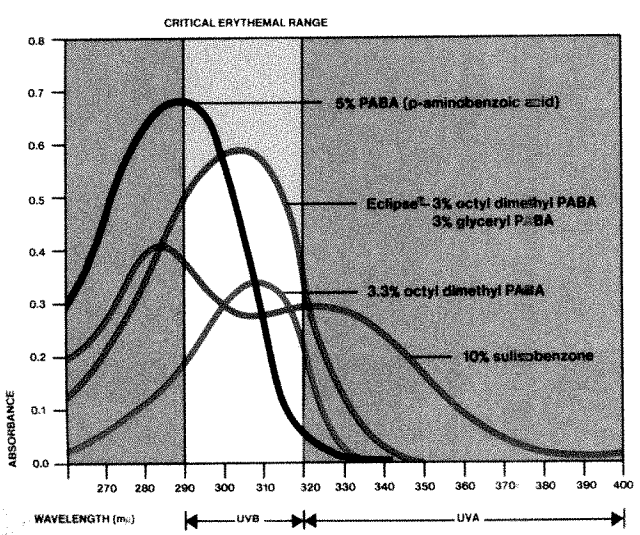

Unique Eclipse formulation combines two PABA derivatives for maximum UVB absorption.

They need Eclipse—a highly effective sunscreen that works immediately upon application, resists wash-off, and contains our exclusive Aquacare® base to help relieve sun and wind-dried skin.

Can other sunscreens do all that? Take a minute to read the labels: we're confident you'll recommend Eclipse.

- Absorbs more than 99% of erythemogenic solar UVB.
- Spreads smoothly and predictably for even protection.
- Permits slow tanning.
- Resists wash-off; protects after swimming or sweating.
- Formulated in Aquacare® to relieve sun and wind-dried skin.

Herbert Laboratories
Dermatology Division of
Allergan Pharmaceuticals
Irvine, CA 92713 U.S.A.

Send us this coupon today and we'll send you a way to slash your claims reporting costs and time

S/J

Return Order Blank To:
American Medical Association
535 North Dearborn
Chicago, Illinois 60610
(312) 751-6000

Type of form		Quantity—in orders of:		Price Including Handling and Postage
☐ Single Form (One page pads of a hundred)	OP-407	1,000	☐	$ 18.50
		5,000	☐	78.00
		10,000	☐	138.00
☐ Two Forms (Original and one carbon)	OP-408	1,000	☐	28.00
		5,000	☐	112.00
		10,000	☐	210.00
☐ Continuous Form (Original and one carbon) (For Computer Printers)	OP-409	1,000	☐	28.00
		5,000	☐	112.00
		10,000	☐	210.00

TOTAL _____

Name _____

Street Address _____

City _____ State _____ Zip _____

Check or money order must accompany this order and be made payable to the American Medical Association.

The Official AMA Uniform Health Insurance Claim Form

Accepted by Medicare, Commercial Carriers, many Blue Shield Plans, and many states for Medicaid.

Developed by the AMA in cooperation with carriers, government agencies, and other groups, this form is the most current and most widely used claim reporting form available. It significantly reduces the time and cost of claims reporting. **Note:** A number of private firms are marketing an outdated, more expensive version of this form. To be certain you are using the most current and acceptable form to third party insurers, we encourage you to use the official AMA form. Order today.

HALOG® CREAM (Halcinonide Cream 0.1%)

Each gram of Halog Cream (Halcinonide Cream 0.1%) contains 1 mg. halcinonide (0.1%) in a cream base.

INDICATIONS: This product is intended for topical application for adjunctive therapy and symptomatic relief of inflammatory manifestations of acute and chronic corticosteroid responsive dermatoses.

CONTRAINDICATIONS: Topical steroids are contraindicated in vaccinia, varicella, and in those patients with a history of hypersensitivity to any of the components of the preparation. This preparation is not for ophthalmic use.

PRECAUTIONS: *General*—If local infection exists, suitable concomitant antimicrobial or antifungal therapy should be administered. If a favorable response does not occur promptly, application of the corticosteroid should be discontinued until the infection is adequately controlled. Although systemic side effects associated with absorption of topical corticosteroid preparations are rare, their possible occurrence must be kept in mind when these preparations are used over large areas or for an extended period of time. If irritation or sensitization develops, the preparation should be discontinued and appropriate therapy instituted. Although topical steroids have not been reported to have an adverse effect on pregnancy, the safety of their use during pregnancy has not been absolutely established; therefore, they should not be used extensively on pregnant patients, in large amounts, or for prolonged periods of time.

Occlusive Dressing Technique—The use of occlusive dressing increases the percutaneous absorption of corticosteroids; their extensive use increases the possibility of systemic effects. For patients with extensive lesions it may be preferable to use a sequential approach, occluding one portion of the body at a time. The patient should be kept under close observation if treated with the occlusive technique over large areas and over a considerable period of time. Occasionally, a patient who has been on prolonged therapy, especially occlusive therapy, may develop symptoms of steroid withdrawal when the medication is stopped. Thermal homeostasis may be impaired if large areas of the body are covered. Use of the occlusive dressing should be discontinued if elevation of the body temperature occurs. Occasionally, a patient may develop a sensitivity reaction to a particular occlusive dressing material or adhesive and a substitute material may be necessary. If infection develops, discontinue the use of the occlusive dressing and institute appropriate antimicrobial therapy.

ADVERSE REACTIONS: The following local adverse reactions have been reported with topical corticosteroids: burning, itching, irritation, striae, skin atrophy, secondary infection, dryness, folliculitis, hypertrichosis, acneform eruptions, and hypopigmentation. The following may occur more frequently with occlusive dressings: maceration of the skin, secondary infection, skin atrophy, striae, and miliaria. Contact sensitivity to a particular dressing material or adhesive may occur occasionally (see PRECAUTIONS).

For full prescribing information, consult package insert.

HOW SUPPLIED: In tubes of 15 and 60 g. and in jars of 240 g. (8 oz.).

SQUIBB® The Priceless Ingredient of every product is the honor and integrity of its maker.™

© 1977 E.R. Squibb & Sons, Inc. 357-503

Pruritus relieved "within 24 hours"

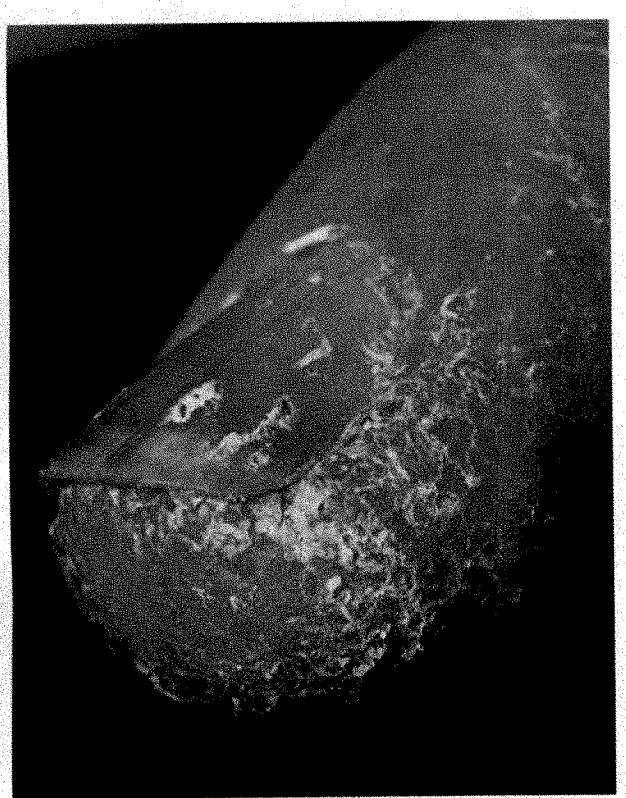

Eczematoid Dermatitis

Condition of six months' duration. Patient complaining of acute itching and soreness of finger. Examination revealed erythematous, eroded, fissured, scaling and crusted dermatitis. KOH test negative for fungal hyphae; no other skin involvement or history of skin problems.

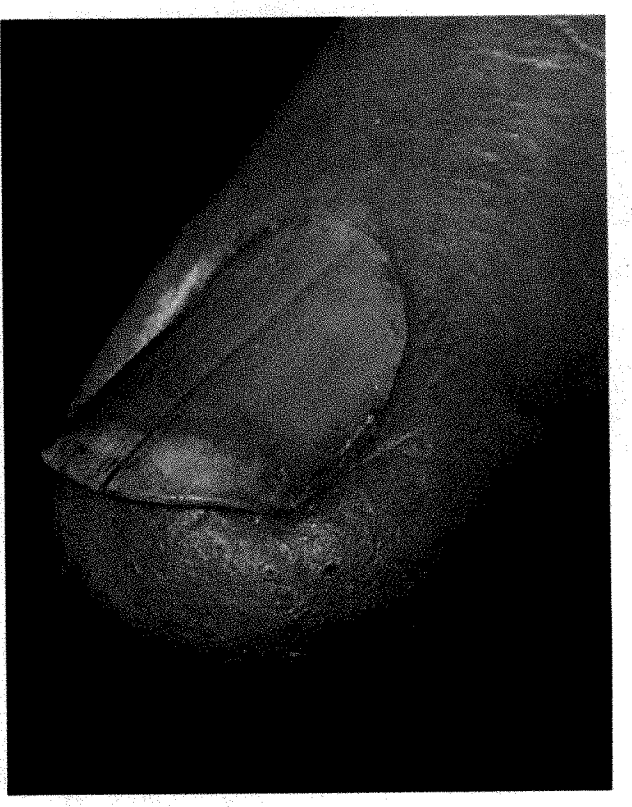

After 1 week

Halog 0.1% Cream applied twice daily. Patient reported pruritus relieved within 24 hours after first application of cream. Examination showed essentially complete resolution of dermatitis. Halog Cream discontinued and patient discharged.

Case history on file at Squibb Institute for Medical Research.

after Halog® Cream b.i.d

Halcinonide Cream 0.1%

See adjacent SQUIBB® column for brief summary.

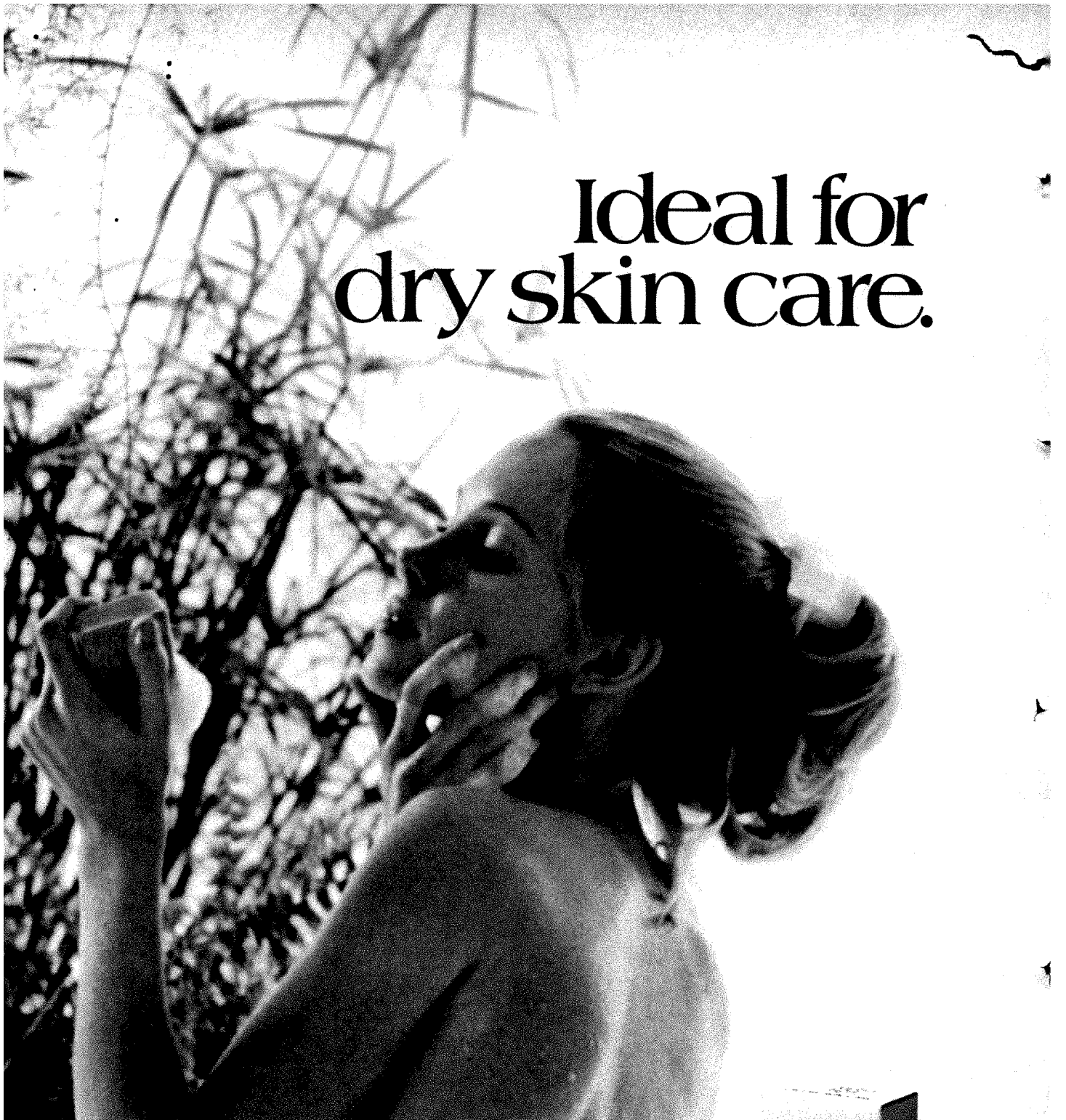

Ideal for dry skin care.

For dry skin care on a day-to-day basis, consider the soothing, softening, nondetergent cleansing properties of Alpha Keri Soap.

- Excellent cleansing properties eliminate harshness and irritation
- Contains Alpha Keri® therapeutic bath oil to soothe and soften skin
- Rich lather and delicate scent create outstanding patient acceptance

Alpha Keri® soap

The soothing, smoothing detergent-free cleanser

WESTWOOD
PHARMACEUTICALS INC.
Buffalo, New York 14213

In Canada, Belleville, Ontario K8N5E9

National Dermatology Manpower Requirements

The Experience of Prepaid Group Practices

Melvin Krasner, David L. Ramsay, MD, MEd

• Ten prepaid group health plans across the country were surveyed as part of an effort to estimate the need for dermatologists in the United States. Although generalizing the experiences of prepaid group practices to the general population is at best an imprecise approach, the dramatic shortage suggested by the data cannot be completely ascribed to the method used. Whereas the average ratio in the surveyed plans was 2.8 dermatologists per 100,000 subscribers, there are only about 1.9 dermatologists providing patient care per 100,000 persons in the general population. The difference between prepaid plan subscribers and the general population in annual visits to dermatologists is even more dramatic: 193 per 1,000 subscribers compared to 84 per 1,000 population.

(*Arch Dermatol* 113:903-905, 1977)

The physician staffing experience of prepaid group health plans (PGP) is often used as a basis for projecting national patient care requirements for physician specialists.[1,2] This approach has the appeal of being fairly simple, yet, as a reflection of functioning health care systems, it embodies a measure of reliability absent from theoretical methods. The prepaid plans are presumed to provide quality medical care sufficient to meet all the needs of their membership, and thus serve as possible models for the nation as a whole under conditions of free access to care.

Nonetheless, a number of important weaknesses are inherent in this approach, although appropriate modification can mitigate some of the shortcomings.[3] The principal problems with extrapolating from the experiences of group health plans are the following: (1) The behavior of physicians and patients is substantially influenced by the financial and administrative organization of prepaid plans, making generalization to other settings inappropriate. (2) The demographic and socioeconomic profile of the membership of prepaid plans generally differs from that of the American population as a whole. (3) Some medical services for enrollees are obtained outside the plan and the need for these services is not reflected in the plan's staffing pattern. (This fact also raises questions about quality and access.)

The effects of the last two factors can be estimated, and projections of specialty requirements can be adjusted accordingly. The first problem, however, encompasses a number of complex relationships that must be understood before specialty staffing patterns can be generalized to other organizational settings. Prepaid practices may exert administrative control or supervision over physician recruitment and behavior; even in the absence of controls, the economic incentives present in prepaid practices are completely different from those in other practice arrangements.[4] The effect of prepayment on patient utilization for preventive, diagnostic, or therapeutic care is another important consideration. Nonmonetary rationing of medical services through excessive waiting time, inaccessability of specialty care, or other barriers to access may also play an important role. Also, the functional overlap among specialties leaves an opportunity for varying specialty staffing patterns even when providing a similar mixture of services.

It has also been argued that the large-scale organization of prepaid group practices, by virtue of efficiencies directly related to size, permits greater productivity;[5] this assertion has been challenged, however, and the existence of such a relationship remains unclear at present.[6]

SURVEY OF PREPAID PLANS

The American Academy of Dermatology Manpower Study, as a small part of a comprehensive assessment of the need for and availability of dermatologic care in the United States, recently conducted a survey of dermatologists' staffing patterns among a number of major PGPs across the country. In addition, information on the volume of visits for dermatologic problems, number and type of auxiliary personnel, and related subjects was elicited in the

Accepted for publication Sept 23, 1976.

From the American Academy of Dermatology Manpower Study, Department of Dermatology, New York University School of Medicine, New York.

Reprint requests to 560 First Ave, New York, NY 10016 (Dr Ramsay).

Dermatologic Care and Staffing at Ten Prepaid Group Health Plans

Name of Plan	Enrollees	Visits	Visits per 1,000 Enrollees	Full-Time Equivalent Dermatologists per 100,000 Enrollees	Visits per Full-Time Equivalent Dermatologist
Hawaii Permanente	101,766	21,306*	209	2.3	7,040
Community Health Care Center	15,570	1,954	125	2.6	4,885
Group Health Association Washington, DC	95,555	11,848	124	2.8	4,388
Southern California Permanente	270,000	45,223	167	2.4†	6,957
Ohio Permanente	92,000	11,658	127	2.5	5,069
Northern California Permanente	1,240,000	259,196	209	3.0	7,005
Rhode Island Group Health Association	16,000	2,600	163	1.8†	8,667
Marshfield Clinic	21,029	3,930	187	2.6	7,860
Health Insurance Plan	740,000	81,400	110	1.2†	9,044
Yale Health Plan	20,063	6,193	305	5.0	6,193

*Includes 4,881 visits made to acne clinic independently conducted by specially trained clinic assistant. These visits excluded from Visits per Full-Time Equivalent Dermatologist.

†Full time equivalence is assumed at 220 days per year and seven hours per day. Figures may not correspond perfectly because of rounding. The data presented involved limited extrapolation on the basis of information provided by the group plans.

Academy survey. It was hoped that this information would help explain the wide variation in dermatologist-to-subscriber ratios identified in the past and would suggest a method for meaningful generalization from PGPs. A summary of the findings is presented in the Table.

The substantial variation in dermatologist-to-enrollee ratios among the plans indicates the need for caution in generalizing the specialty staffing pattern of a single PGP or a group of PGPs to other settings. Particularly outstanding is the experience of the Yale University Health Plan, where the equivalent of 1 full-time dermatologist is required to handle 20,000 enrollees or 5 dermatologists per 100,000. This plan is unusual because of the unique subscriber population it serves. More than half of its enrollment is in the 15- to 29-year age group, and, according to the information obtained in the national Health Interview Survey, this group appears to have a relatively high utilization rate for dermatologic care. Among individuals aged 17 to 24 years, 2.4% seek dermatologic care, as compared to 1.5% for all age groups combined.[7] Educational level also appears to have a positive influence on utilization, and this factor is probably operative here as well.

At the other end of the continuum, the Health Insurance Plan of Greater New York reports only 1.2 dermatologists per 100,000 enrollees. The data show that this low ratio is maintained by heavy physician workloads as well as a low utilization rate. Some observers have attributed the latter to a lack of ready access to specialists[8]; they present data for an aged population showing four times as much utilization under conditions of complete access.

Although it appears that highly trained auxiliary personnel play an important role in providing dermatologic care in some PGPs, initial review of the information on ancillary personnel in the PGPs did not provide a satisfactory explanation of the inter-PGP variation in dermatologist-to-population ratio or dermatologist productivity.

By omitting the extreme observations, ie, the Yale Health Plan and HIP, a simple mean of 2.5 dermatologists per 100,000 enrollees is obtained. The weighted average, based on the number of subscribers in each plan, is 2.8 dermatologists per 100,000 enrollees. In an effort to generalize the PGP experience to the nation as a whole, federal analysts in a study of medical specialty manpower applied an additive adjustment of 0.3 dermatologists per 100,000 persons to compensate for age and income differences between PGP subscribers and the general population and an additional 0.5 dermatologists per 100,000 to offset the greater productivity realized in group practices.[3] Recent data assembled by the American Medical Association, however, reveal that large group practices do not necessarily achieve the highest levels of productivity.[9] Therefore, it appears that a more conservative adjustment of 0.4 dermatologists per 100,000 population (based on the 0.3 age-income factor and an 0.1 productivity factor) would be appropriate. Based upon the weighted average of 2.8 dermatologists per 100,000 population described above, the national need would then be approximately 3.2 dermatologists per 100,000 population.

According to a recent tabulation of AMA data, there were 3,416 dermatologists principally involved in patient care in the United States in March 1976, a recent survey by the American Board of Dermatology found that there were 768 residents in dermatology training programs in this country (Clarence S. Livingood, MD, written communication from American Board of Dermatology to the General Accounting Office, July 23, 1976). In addition, the American Academy of Dermatology Manpower Study identified 139 dermatologists involved in patient care who were missing from the AMA data. Also found missing were 79 dermatologists whose professional activity could not be determined. If half, or 40, of this latter group and about 35 osteopathic dermatologists are assigned to the

patient care category, an estimate of 3,630 dermatologists primarily active in providing patient care is derived. Relating this figure to the American population of 215 million yields a figure of 1.7 dermatologists per 100,000 persons. Since dermatology residents provide a substantial amount of patients care, it may be preferable to include them, in which case the dermatologist-to-population ratio would be 2.0 per 100,000. However, if residents are assumed to provide only half as much care as the average practicing dermatologist, the corresponding ratio would be 1.9 dermatologists per 100,000 persons. Comparing any of these figures with national requirements based on group health plan statistics indicates a national deficit of more than 2,000 dermatologists.

Another basis for measuring the availability and utilization of care is the number of visits made to dermatologists. Recent data from the National Ambulatory Medical Care Survey show that there were approximately 15.7 million office visits to dermatologists per year (May 1973 through April 1974), or 73 per 1,000 population.[10] Based on information from the National Health Interview Survey,[11] this number is appropriately increased to 84 visits per 1,000 population to allow for dermatologic patient care provided outside of private physicians' offices (eg, clinics or company health units). When comparing the present national average of 84 visits to dermatologists per 1,000 population with an average of 193 dermatologist visits per 1,000 enrollees in the surveyed group practice plans (again omitting the two extreme observations), it is evident that, if the demand experienced in these plans were to be realized nationally, there may be a greater than twofold increase in patient demand for services.

COMMENT

In summary, the information on PGPs would indicate a need for a substantial increase in the number of dermatologists in the United States if free access to care were instituted. However, a final cautionary note is in order. The fact that one cannot easily make adjustments for many of the unique features of PGPs that affect specialty manpower needs and the fact that there is wide variation in staffing among the PGPs themselves (even after extreme values are omitted) cast considerable doubt on the validity and reliability of this approach. Only by detailed analysis of the patient care, organization, and other characteristics of prepaid group practices that would identify and measure the effects discussed earlier would the effectiveness of PGP staffing patterns as a tool in planning medical specialty services for the nation be improved. Such analysis is clearly beyond the scope of the present study, but comprehensive investigation of this subject is definitely needed and should be encouraged.

Another limiting feature is using PGPs as a model for future manpower requirements is that they form a static reference point that does not provide for possible changes in the pattern of a dermatologist's services. If, for example, similar to the British experience, dermatology becomes a referral-based specialty, the needs for dermatologists would be substantially less than at present, whereas if dermatologists are called upon in any national scheme to render all primary care in dermatology, the manpower estimates based upon PGP experiences would far understate the need for additional dermatologists.

The manpower-analysis approach based on PGP experience (as well as most other planning methods) is also static in the sense that it embodies all other characteristics of dermatology practice unique to this point in time, such as the current state of scientific knowledge, existing therapeutic methods, and major population features that determine levels of demand. Although these structural characteristics are not expected to change dramatically in the near future, long-run projections may be greatly affected by such change.

The manpower study group is aware of the serious limitations of extrapolating the PGP data for national planning and this report is only presented as one of the many facets of analysis being undertaken by this group to better understand the need for dermatology manpower.

This study was supported by contract 231-75-0021 from the Division of Medicine, Bureau of Health Manpower, Health Resources Administration, Department of Health, Education, and Welfare.

References

1. *Health Manpower Perspective: 1967*, Public Health Service publication No. 1667. Washington, DC, Bureau of Health Manpower, 1967, p 75.

2. Mason HR: Manpower needs by specialty. *JAMA* 219:1621-1626, 1972.

3. *The Distribution of Medical Specialty Manpower*, Resource Analysis Staff report No. 74-192, Washington, DC, Bureau of Health Resources Development, 1974, p 55.

4. Pineault R: The effect of prepaid group practice on physicians' utilization behavior. *Med Care* 14:121-136, 1976.

5. Fein R: *The Doctor Shortage: An Economic Diagnosis*. Washington, DC, Brookings Institution, 1967, pp 94-102.

6. Bailey RM: Economics of scale in medical practice, in *Empirical Studies in Health Economics*. Baltimore, Johns Hopkins Press, 1970, pp 255-273.

7. *Characteristics of Patients of Selected Types of Medical Specialists and Practitioners: United States: July 1963-June 1964*. Washington, DC, Public Health Service, National Center for Health Statistics, 1966, series 10, No. 28, pp 29-31.

8. Scitovsky AA, Snyder NM: *Medical Care Use by a Group of Fully Insured Aged*, publication No. (HRA) 75-3129. Washington, DC, National Center for Health Services Research, Government Printing Office, 1975.

9. Warner J, Aherne P: *Profile of Medical Practice*. Chicago, American Medical Association, 1974, p 182.

10. *The National Ambulatory Medical Care Survey: 1973 Summary, United States, May 1973-April 1974*, publication No. (HRA) 76-1772. Vital and Health Statistics series 13, No. 21, Rockville, Md, National Center for Health Statistics, 1975.

11. *Physician Visits: Volume and Interval Since Last Visit, United States—1971*, publication No. (HRA) 75-1524. Vital and Health Statistics series 10, No. 97, Rockville, Md, National Center for Health Statistics, 1975.

Treatment of Lip Keratoses (Actinic Cheilitis) With Topical Fluorouracil

Ernst Epstein, MD

• **Topical (5-fluorouracil [5-FU]) as a 5% solution was used to treat isolated actinic keratoses of the lips as well as diffuse actinic damage of the lower lip. Although producing considerable temporary discomfort, final results proved excellent, with recurrences in only two of 12 patients treated. Preliminary biopsy of suspicious infiltrated areas is mandatory, as is careful follow-up to ensure complete healing. Topical fluorouracil is an alternative to surgical excision of the vermilion border of the lip in those patients with severe diffuse actinic damage of the lips.**

(*Arch Dermatol* 113:906-908, 1977)

Topical administration of fluorouracil has proved to be an elegant method of destroying actinic keratoses of the face.[1-4] Since fluorouracil selectively destroys actinically damaged cells, it removes facial keratoses with cosmetic results generally superior to destructive modalities, such as surgery, liquid nitrogen, curettage, or electrodesiccation. When topical fluorouracil is used on the face, patients are usually instructed to avoid applying it to the lips because of the possibility of severe irritation. The manufacturers advise that fluorouracil be used "with care" about the mouth.

Actinic keratoses on the lips are fairly common; I have found that they are effectively destroyed by treatment with topical fluorouracil. Discussions with dermatologic colleagues showed that others have found fluorouracil effective in the treatment of isolated actinic keratoses of the lips, as well as the diffuse actinic lip damage known as chronic actinic cheilitis. While successful fluorouracil therapy of lip keratoses has received mention in some papers,[4,5] others have warned against using fluorouracil on the lips.[1,2] To my knowledge, there are no publications detailing the results of topical fluorouracil in keratoses of the lips. This report describes my four-year experience with topical fluorouracil in treating actinic lip keratoses.

MATERIALS AND METHODS

Fluorouracil was used as a commercially available 5% solution since preliminary studies suggested that it acted more rapidly than the 5% cream formulation. The patients were instructed to apply the 5% fluorouracil solution sparingly three (or sometimes four) times a day to the entire vermilion area of the lip with their fingertips, taking care to avoid the mucosa. Patients were seen after one week; based on the degree of reaction, they were instructed when to stop applying the fluorouracil. Photographs were taken before,

Fig. 1.—Case 9. Recurrent eroded actinic keratosis in a 56-year-old man that had been previously excised by a plastic surgeon.

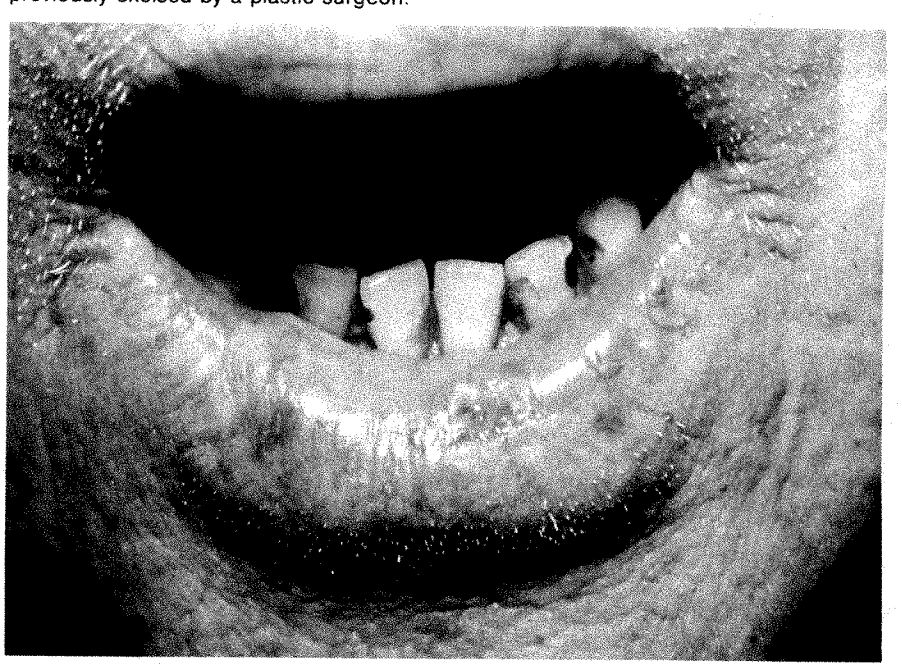

Accepted for publication Oct 6, 1976.

From the Department of Dermatology, University of California Medical Center, San Francisco.

Reprint requests to 36 S EL Camino Real, San Mateo, CA 94401 (Dr Epstein).

during, and after treatment, using color transparencies and a one to two reproduction ratio.

The aim of treatment was to produce a thorough erosion of the affected area. With completion of treatment, patients were asked to use white petrolatum (petroleum jelly) as desired for its soothing and lubricating effect on the raw and fissured lips. In a few patients, 1% hydrocortisone ointment was used. No other medications were used.

REPORT OF CASES

A 55-year-old man (case 9) was examined in December 1974 with a 5-mm diameter superficial erosion of the mid lower lip present 18 months (Fig 1). Two years earlier, a histologically proved actinic keratosis had been excised at this site by a plastic surgeon, but it recurred six months after surgery. The patient was directed to apply a 5% fluorouracil solution four times daily to the eroded area and a surrounding small margin. Figure 2 shows the effect produced after eight days. The fluorouracil treatment was continued for a total of 13 days, after which there was prompt healing (Fig 3) without any recurrence in the 16-month follow-up period.

A 56-year-old man (case 7) was seen in December 1970 for an erosion on the right side of his lower lip at the site of a squamous cell carcinoma treated with X-ray therapy 20 years earlier. The erosion was excised, the pathology report describing "hyperkeratosis with premalignant cytologic alteration." After surgery, the lip healed uneventfully, but the patient returned one year later with a new area of superficial lip ulceration. This second erosion cleared with liquid nitrogen freezing. However, in October 1972, the patient had multiple new lip keratoses; these were treated with a 13-day course of 5% fluorouracil solution applied three times daily to the entire lower lip. A month later the lip had healed. For nearly one year after the fluorouracil treatment, the lip remained well, but the development of additional keratoses in October 1973 led to a second course of fluorouracil applied four times daily for 12 days. After this second treatment, the patient remained free of lip keratoses up to the present (29 months).

Fig 2.—Case 9. Appearance after eight days of treatment with 5% fluorouracil solution applied four times daily.

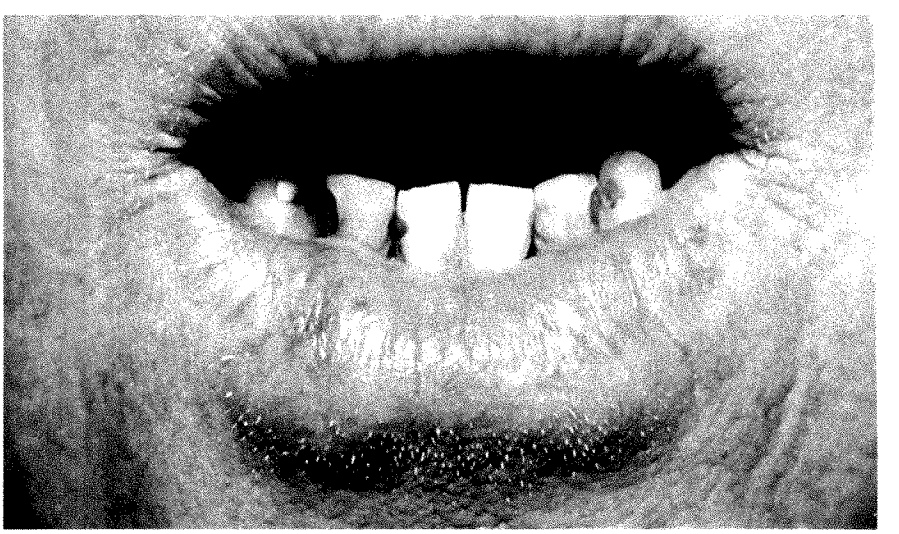

Fig 3.—Case 9. Result four weeks after completion of a 13-day course of treatment with topical fluorouracil.

RESULTS

The results in 12 patients (8 men, 4 women) treated during the years 1972 through 1975 are detailed in Table 1. Two patients had recurrences; one (case 1) had one small keratosis apparent 38 months after fluorouracil therapy. This lesion responded to liquid nitrogen destruction. The other patient with a recurrence (case 7 described previously) received a second course of topical fluorouracil. The mean age of these 12 patients was 56 years (range, 36 to 73 years). The lesion occurred on the lower lip of ten patients, and on the upper lip of two. Six patients underwent biopsies. Three had prior lip cancer while seven had prior skin cancers elsewhere. In four patients, isolated lesions were treated, while in eight the entire lip was treated. The mean length of therapy was 12 days (range, nine to 15 days), and the mean length of follow-up was 22 months (range, two to 48 months).

COMMENT

In view of the role of sunlight, it is not surprising that the lower lip was involved in the majority of cases. That men outnumbered women in these

Treatment and Follow-Up Data on 12 Patients Whose Lip Keratoses Were Treated With Topical Fluorouracil

	Case No.*											
	1	2	3	4	5	6	7	8	9	10	11	12
Sex	M	M	M	F	M	F	M	F	M	M	M	F
Age, yr	57	54	71	42	73	66	58	44	55	55	56	36
Upper or lower lip	L	L	L	U	L	L	L	U	L	L	L	L
Fluorouracil treatment of entire or part of lip	E	E	P	P	E	E	E	P	P	E	E	E
Biopsy performed	+	0	0	0	+	0	+	+	+	+	0	0
Prior lip carcinoma	0	0	+	0	0	0	+	0	0	+	0	0
Previous other skin cancer	+	0	0	+	+	0	0	+	+	+	+	0
Length of fluorouracil therapy in days	15	11	14	10	9	12	13, 12†	9	13	13	11	9
Follow-up, months	48	2	41	44	22	21	41	6	16	7	6	7
Recurrence	+	0	0	0	0	0	+	0	0	0	0	0

*L indicates lower lip; U, upper lip; E, entire lip; P, part of the lip; +, yes; 0, no.
†Patient 7 had two courses of treatment with fluorouracil applied to his lower lip.

series is probably a tribute to the protective effects of lipstick. Lip keratoses are the result of sun damage, and it is important that nine of the 12 patients had had skin cancers. Two patients had only had lip cancers, a third patient had a previous lip cancer plus skin cancers elsewhere, while an additional six patients had only had skin cancers at sites other than the lip.

The problem of lip carcinoma raises the issue of biopsies. Half of the patients had biopsies performed, and if there is a suspicion of malignancy in that the keratosis is infiltrated, deeply ulcerated, or persistent, preliminary biopsy is mandatory. Since squamous cell carcinoma of the lower lip has the potential of metastasizing, it requires surgery or radiation. Those patients treated without biopsy because of multiple or superficial lesions should be followed up carefully to ensure that healing is complete. If topical fluorouracil therapy is not successful in completely eradicating a lesion, it must be biopsied.

The only side effect encountered was lip discomfort. The effect of fluorouracil became evident three to four days after the start of treatment when tender erosions appeared, and after one week of treatment, the lip was usually sore. During the latter stages of treatment, some patients complained of considerable discomfort and required mild analgesics at bedtime. Usually ten to 13 days of treatment produced a brisk erosion. Healing was complete two or three weeks after stopping the fluorouracil treatment. Several patients had applied the fluorouracil too generously and had developed erosions of the adjacent lip mucosa. These mucosal ulcerations healed uneventfully. Although some patients complained bitterly of discomfort during treatment, all were delighted with the final results. In a few patients, hydrocortisone ointment was prescribed for treatment of erosions once fluorouracil therapy had been completed. However, plain white petrolatum seemed equally effective in providing symptomatic relief during healing.

No systemic side effects were observed, and none were expected, since even if the entire applied dose were absorbed, it would represent only a minute fraction of the therapeutic dose of intravenous fluorouracil. The safety of topical fluorouracil has been documented in many studies.[1-5] The mechanism of action, biochemistry, and cutaneous effects of fluorouracil are not discussed in this communication, since they have been thoroughly covered by others.[6-8]

While topical fluorouracil proved an effective way of destroying isolated lip keratoses, its greatest usefulness seemed to be in those patients with widespread actinic damage and multiple or recurrent keratoses. Conventional destructive methods, while capable of removing existing keratoses, do not prevent new ones, and the traditional approach to the problem of the severe, chronic actinically damaged lower lip has been excision of the entire vermilion border of the lip. While excision of the vermilion border is an effective treatment, it alters the sensory ability and the appearance of the lower lip. Topical fluorouracil not only removes existing keratoses, but also delays the formation of new lesions. It appears that topical fluorouracil therapy represents a medical alternative to surgical treatment of the diffusely actinically damaged lip.

Nonproprietary Name and Trademarks of Drug

Fluorouracil—*Flouroplex, Efudex.*

References

1. Dillaha CJ, Jansen GT, Honeycutt WM, et al: Further studies with topical 5-fluorouracil. *Arch Dermatol* 92:410-417, 1965.
2. Richards RN: The use of topical 5-fluorouracil in actinic keratoses. *Can Med Assoc J* 105:1314-1315, 1971.
3. Spira M, Freeman R, Arfai P, et al: Clinical comparison of chemical peeling, dermabrasion and 5-FU for senile keratoses. *Plast Reconstr Surg* 46:61-66, 1970.
4. Hansen DA: Use of 5-fluorouracil 5% ointment (Efudex) in treatment of senile keratoses. *S Afr Med J* 45:1347-1348, 1971.
5. Klein E: Tumors of skin. *NY State J Med* 68:886-899, 1968.
6. Heidelberger C, Ansfield FJ: Experimental and clinical use of fluorinated pyrimidines in cancer chemotherapy. *Cancer Res* 23:1226-1243, 1963.
7. Eaglstein WH, Weinstein GD, Frost P: Fluorouracil: Mechanism of action in human skin and actinic keratoses: I. Effect on DNA synthesis in vivo. *Arch Dermatol* 101:132-139, 1970.
8. Goette DK: Erythroplasia of queyrat: Treatment with topically administered flourouracil. *Arch Dermatol* 110:271-273, 1974.

Acute Panniculitis

A Clinical and Histopathologic Study of 34 Cases

Lars Förström, MD, R. K. Winkelmann, MD, PhD

• Thirty-four patients had histopathologic findings of acute panniculitis. 15 had clinical findings of erythema nodosum; 6 had infectious lesions; and 5 had Weber-Christian-like conditions with recurrent febrile suppurative or nonsuppurative nodular eruptions; 3 of the 5 had amylase and lipase enzyme abnormalities with or without pancreatic disease. Five additional patients had acute panniculitis that would be termed "erythema induratum" or "nodular vasculitis" by most clinicians, and the subsequent pathologic findings and courses were consistent with this view. Two patients had limited, traumatic panniculitis, forming a distinctive group but trauma was a factor in lesion formation in all groups, and one patient had vasculitis. Whereas acute panniculitis, with or without fat necrosis, may be associated with many inflammatory syndromes of the skin and subcutaneous tissue and may rarely occur in all, the most common relationship is with erythema nodosum in its most acute forms.

(*Arch Dermatol* 113:909-917, 1977)

Acute panniculitis describes the infiltration of fat lobules with masses of polymorphonuclear leukocytes, and it is often accompanied by necrosis of the white cells, as well as variable necrosis of the fat cells. The dermatopathologist occasionally can classify his findings only in terms of the descriptive diagnosis of acute panniculitis. The pathology report that suggests a severe disease may confuse the clinician, whose patient has short-lived inflammatory nodules of the skin and subcutaneous tissue. Experienced dermatologists can associate such reports with traumatic panniculitis, but most cases are not traumatic in origin. Some authors consider acute panniculitis as the first stage of Weber-Christian disease, but true Weber-Christian disease, if it exists, is a very rare and ill-defined syndrome. Our review of cases of acute panniculitis forms the basis of the present report and indicates that acute panniculitis is most often associated with erythema nodosum and that other causes such as infection and trauma are less common.

Accepted for publication Sept 23, 1976.

From the Department of Dermatology, Mayo Clinic and Mayo Foundation, Rochester, Minn.

Reprint requests to Section of Publications, Mayo Clinic, 200 First St SW, Rochester, MN 55901 (Dr Förström).

SERIES AND METHODS

A review of the biopsy specimen files of the Department of Dermatology at the Mayo Clinic revealed 34 cases with the histopathologic findings of acute panniculitis for which adequate clinical information and follow-up were available. When the biopsy specimen was taken, the ages of the patients averaged 46 years and ranged from 8 to 74 years. Of the 34 patients, 25 were women and nine were men. The mean duration of the disease was 3.5 years (range four days to 45 years), and the mean duration of the individual nodules was three weeks (range four days to four months).

The patients' records were reviewed, and the later course of the disease was analyzed on follow-up visits and by questionnaires. Hematoxylin-eosin and resorcin-fuchsin-Giemsa stained slides were available for study, and multiple sections were observed. When indicated, polaroscopy and ultraviolet fluorescent study of sections were done for the detection of foreign material.

All lesions showed infiltrates of predominantly polymorphonuclear cells involving fat lobules; in some lesions, the entire lobule was replaced by inflammatory cells. In some sections, this acute reaction was intermingled with lymphocytes and a few histiocytes. Fat necrosis sometimes occurred, and often there was necrosis of the cellular infiltrate itself.

RESULTS

According to history and clinical findings, the cases could be grouped into the following six categories: erythema nodosum (15 cases), skin infections (6 cases), erythema induratum (5 cases), traumatic panniculitis (2 cases), Weber-Christian-like syndromes (5 cases), and vasculitis (1 case).

Erythema Nodosum

Clinical Data.—The 15 patients in this group had red, tender nodules occurring mostly on the anterior

Table 1.—Acute Panniculitis in Erythema Nodosum

Case	Sex, Age (yr)	Disease Duration	Nodule		Remarks
			Duration, wk	Location	
1	F,56	2 mo	4-8	Pretibial, calf	Chronic ulcerations, colitis
2	F,62	6 yr	8	Pretibial	. . .
3	F,40	7 yr	2	Buttocks, upper arms, thighs	Sarcoidosis
4	F,71	3 wk	3	Pretibial	Chronic lymphatic leukemia
5	M,50	1¼ wk	. . .	Arms, legs	. . .
6	M,8	1 mo	. . .	Pretibial	. . .
7	F,26	2 yr	1-2	Elbows, hands, knees	. . .
8	F,32	4 mo	1	Legs, thighs	Fever
9	M,10	2 yr	1-2	Arms, legs	Arthralgias, fever
10	F,49	5 yr	. . .	Calves, buttocks, arm	. . .
11	F,42	6 mo	1	Trunk, elbow	. . .
12	F,44	1½ yr	1	Legs, arms, buttocks abdomen, thigh	. . .
13	F,56	6 yr	1-2	Legs, thighs	Arthralgias, Raynaud's phenomenon
14	M,17	1 wk	. . .	Arms, legs	Fever
15	F,20	6 wk	6	Extremities, buttocks	Sarcoidosis, fever

Fig 1.—Acute panniculitis in erythema nodosum. Diffuse replacement of fat lobule with polymorphonuclear leukocytes, with microcyst formation (hematoxylin-eosin, left, original magnification ×64; right, original magnification ×250).

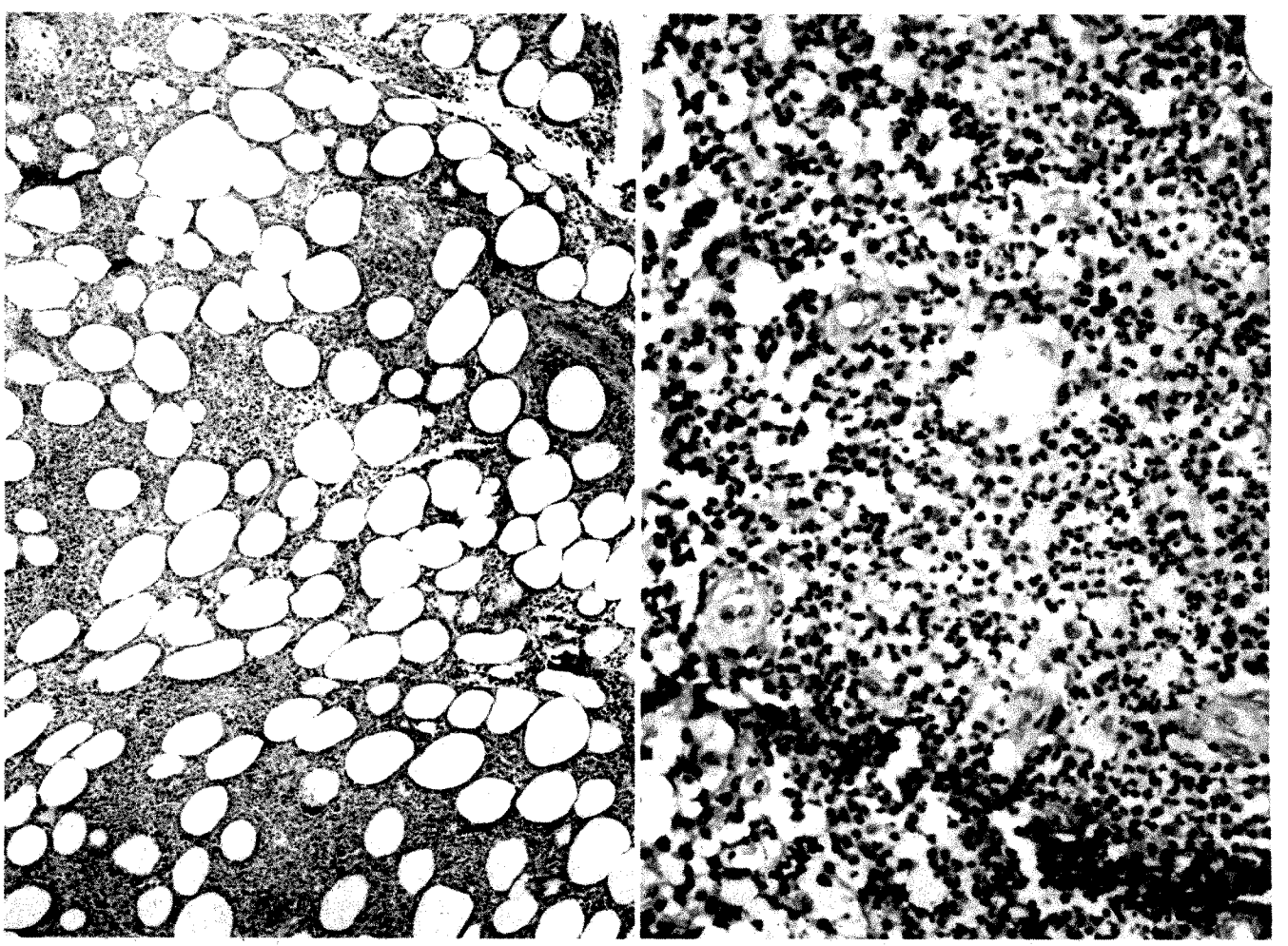

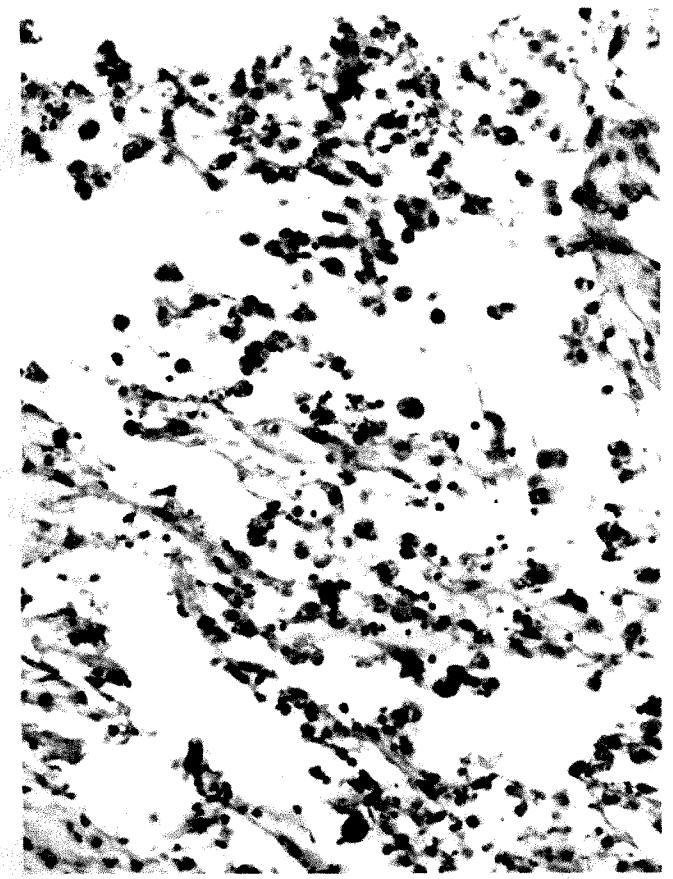

Fig 2.—Pseudomalignant cells in erythema nodosum and sarcoidosis. These large hyperchromatic mononuclear cells occasionally are observed in areas of intense fat cell destruction by panniculitis (hematoxylin-eosin, original magnification × 250).

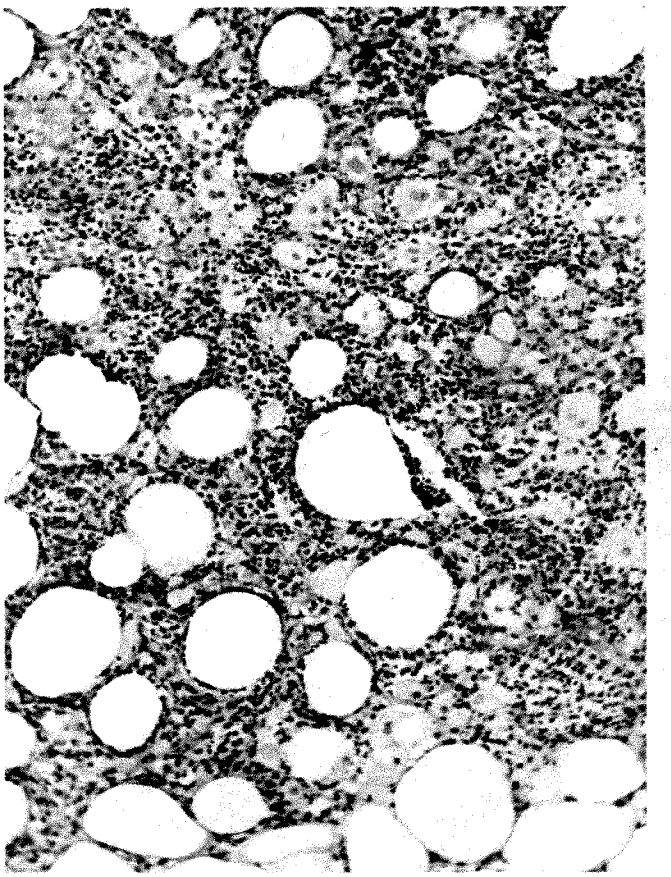

Fig 3.—Polymorphonuclear leukocytes and lipophagic cells in erythema nodosum and sarcoidosis. Various stages of lipoblast proliferation and differentiation are observed in the infiltrate (hematoxylin-eosin, original magnification × 160).

Table 2.—Acute Panniculitis With Erythema Induratum (Nodular Vasculitis)

Case	Sex, Age (yr)	Disease Duration, yr	Nodule		Remarks
			Duration, mo	Location	
16	F,60	5	2	Calves	Suppuration scars
17	F,33	5	1	Lower legs	Suppuration
18	F,46	1.5	1	Calves	Fluctuation
19	F,63	45	2-3	Lower legs	Depression scars
20	F,58	10	1½	Lower legs	. . .

aspects of the legs, often on the thighs, buttocks, and upper extremities, and occasionally on the trunk and abdominal skin (Table 1). Eleven of the patients were women, and the mean age of the group was 38 years. One of the patients, who had crops of nodules (five or six at a time), reported that several of the nodules had occurred after local trauma. Six patients had the disease less than three months. The cases that caused diagnostic problems were the six with recurrent episodes lasting two to seven years. Generally, the duration of the individual nodules was two to three weeks (range one week to eight weeks). In two patients, arthralgia developed, and only three were febrile. These signs and symptoms were unrelated to associated diseases. Two patients had the nodular eruption after having had a sore throat; one had ulcerative colitis; two had sarcoidosis; and one had chronic leukemia.

Laboratory and Reontgenographic Findings.—The erythrocyte sedimentation rate (ESR) was slightly elevated (21 to 40 mm/hr) in seven of the 15 patients, but in three, it was high (55, 69, and 120 mm/hr). Only two patients had leukocyte counts higher than 10,900/cu mm; one of these had chronic lymphatic leukemia. The antistreptolysin O titer (ASO) was moderately elevated (333 units) in one patient who had no history of sore throat. In another patient, a culture from the throat showed growth of streptococci of the viridans group. The chest roentgenograms were normal for all but the two patients with sarcoidosis, and these showed hilar adenopathy and nodular infiltrates. Cultures of nodules from six patients were negative for bacteria, acid-fast organisms, and fungi.

Histopathologic Findings.—Biopsy specimens showed acute panniculitis with a predominantly polymorphonuclear cell infiltrate (Fig 1). Often, there was necrosis of the cellular infiltrate itself and some secondary necro-

Table 3.—Acute Recurrent Panniculitis (Weber-Christian-Like Syndromes)

Case	Sex, Age (yr)	Disease Duration, mo	Lesion		Fever	Remarks
			Duration, wk	Location		
21*	M,47	24	4	Legs, trunk	Yes	...
22*	M,63	12	...	Anterior lower legs	Yes	Pancreatic carcinoma
23*	F,55	8	2	Thighs, buttocks	Yes	Mesenteric adenitis
24†	F,46	14	4-6	Buttocks, extremities	Yes	...
25†	F,43	48	4	Buttocks	...	Postinjection panniculitis

*With enzymes.
†Without enzymes.

sis of the fat. The acute panniculitis was principally focal, occurring in the periphery of the fat lobules in relation to the vessels, but in some of the lesions, the whole fat lobule was replaced by masses of polymorphonuclear leukocytes. Hemorrhage was an almost constant feature, and in some of the patients, it was extensive. Phlebitis was not a significant feature in the multiple sections studied. One of the patients had a mixed cell infiltrate in some areas of the specimen with foci of necrosis and, adjacent to the necrotic area, large pseudomalignant mononuclear cells (Fig 2). One patient (case 15) with erythema nodosum and sarcoidosis had acute panniculitis with proliferative lipophagic cells similar to so-called second stage of Weber-Christian disease (Fig 3).

Skin Infections

Clinical Data.—This group consisted of six patients, two of whom had fever. Three patients, one with pericholangiolitic hepatitis, had infectious skin lesions secondary to pruritus and excoriation. One patient had abscesses on his right hand and thigh secondary to contact dermatitis due to neomycin sensitivity. One patient had infected varicose ulcers of the legs. The last patient in this group, a 13-year-old boy, had skin lesions of macules, papules, and pustules on his arms, legs, and trunk for one week, until he died of pneumonia and staphylococcal sepsis. Three of the patients were men, and three were women. If the 13-year-old boy were excluded from this group, the mean age would be 66 years (range 57 to 74 years). The disease lasted from one week to six months.

Laboratory and Roentgenographic Findings.—The patients had elevated ESR that exceeded 40 mm/hr in all but one case; the boy with staphylococcal sepsis had an ESR of 82 mm/hr. Only two patients had elevated leukocyte counts. Urinalysis showed no abnormalities except for the boy with pneumonia sepsis who had hematuria. Culture of biopsy specimens showed growth of pathogenic bacteria in the four patients in whom it was performed. Two patients had *Pseudomonas aeruginosa* cultured, and one patient had *Micrococcus pyogenes*. Culture of the biopsy specimen from the septic patient showed many *Staphylococcus aureus* organisms, as did blood cultures.

Histopathologic Findings.—Biopsy specimens showed acute panniculitis with focal or large areas of necrosis. One of the specimens showed marked vascular proliferation of granulation tissue in the fat lobules. Two of the patients had histopathologic features similar to those seen in a patient with sterile panniculitis in whom amylase and lipase were found in the skin.[1] In a biopsy specimen from a lesion secondary to pruritus and scratching, there was a marked pseudoepitheliomatous hyperplasia. The patient with sepsis had, in addition to acute panniculitis, a similar cellular infiltrate in the dermis, with small foci of necrosis.

Erythema Induratum (Nodular Vasculitis)

Erythema induratum is defined as a chronic and recurrent tuberculous delayed hypersensitivity reaction involving the vessels of the legs. The histologic feature is usually a tuberculoid granuloma with caseation necrosis. Nontuberculous erythema induratum is a convenient equivalent term for nodular vasculitis.

Clinical Data.—The five patients in this group had chronic red to bluish nodules on their lower legs, particularly on the calves (Table 2). Ulceration of one or several nodules occurred in two patients (cases 16 and 17); in another (case 18), the nodules showed fluctuation, and one patient (case 19) had lesions that left depressions on healing. One patient (case 20) with nodular vasculitis had no ulcerations or scars. One patient (case 19) had suffered from pleurisy on four different occasions and pericarditis on one occasion. The father of patient 17 had died of tuberculosis when the patient was 6 years old. In this diagnostic group, the disease had lasted from 1.5 to 45 years, the average being 11 years. The individual nodules lasted from four weeks to three months and healed with scarring. All the patients were women, and their ages averaged 52 years (range 33 to 63 years).

Patient 16 had isoniazid treatment for nine months without apparent improvement. Patient 17 was cured during 12 months of isoniazid treatment. Patient 18 developed new lesions in spite of treatment with isoniazid and para-aminosalicylic acid for seven months. Patient 19 was lost to follow-up. Patient 20 was not treated with antituberculous therapy.

Laboratory and Roentgenographic Findings.—All the patients had elevated ESR, the highest value being 96 mm/hr in one hour. All patients had normal leukocyte counts. Two (cases 16 and 19) were reactive to intra-

dermal testing with 1 tuberculin unit of purified protein derivative (PPD), and two (cases 17 and 20) were reactive to 5 tuberculin units; this test was not done in case 18. All five patients had normal urine. Chest roentgenograms showed evidence of disease only in case 19—the right apex showed thickening of the pleura. Culture of biopsy specimens from the nodules revealed no growth of bacteria, *Mycobacterium tuberculosis*, or *Brucella* organisms, or fungi. Culture of sputum for *M tuberculosis* was negative in the two cases in which it was performed.

Histopathologic Findings.—One patient (case 16) had acute panniculitis with masses of polymorphonuclear cells invading the fat lobules, as did two others (cases 17 and 20) in whom there was additionally extensive secondary fat necrosis. In case 18, although the predominant feature was that of acute panniculitis, careful search revealed small areas of granulomatous panniculitis. Subsequent biopsy specimens showed only granulomatous features, typical of erythema induratum with caseation necrosis. In case 19, the acute polymorphonuclear leukocyte infiltrate was intermingled with lymphocytes, and there was phlebitis similar to erythema nodosum.

Acute Weber-Christian-Like Syndromes With Enzyme and Nonenzyme Panniculitis

These five patients (two men and three women) had recurrent febrile, inflammatory, subcutaneous masses that sometimes were associated with suppuration.

Clinical Data.—Four of the five were febrile with the development of the nodules. Three patients (cases 21, 22, and 23) had generalized nodules. Although the syndrome of recurring nodules extended from eight months to four years, individual nodules lasted only two to six weeks (Table 3). Three patients (cases 21, 22, and 23) developed suppuration and ulceration, and two (cases 23 and 24) had depressed residual change in the subcutaneous tissue. Pancreatic disease or enzymes (lipase and amylase) in the blood, urine, and skin were found in a patient with pancreatic carcinoma (case 22), in a previously reported patient with amylase and lipase in the inflamed skin (case 21),[1] and in a patient with lipase in the drainage from the lesions (case 23). Two patients (cases 21 and 23) had normal pancreatic function and structure at autopsy and laparotomy, respectively.

Case 21 was of a 47-year-old man who had painful subcutaneous nodules scattered over the body for three years at two separate periods, with a free interval of nine months. Each time, the activation of the disease was preceded by a sore throat and fever. The onset of the nodules was accompanied by nausea and malaise. The individual nodules subsided within one to three weeks, without ulceration or scarring except for two nodules that ruptured spontaneously, draining liquified material. However, new lesions continued to develop, particularly on areas likely to suffer minor trauma, that is, over bony prominences. He died with pericarditis and infarction of the terminal ileum, as well as infarction of the right kidney. Autopsy showed a normal pancreas, both grossly and microscopically. This patient has been described in detail previously.[1]

Case 22 was a 63-year-old man whose chief complaint was gradual onset of gastric distress that had lasted for six months. When examined, he had had severe, generalized, abdominal pain for one hour, three to four times a day. He had lost 5.4 kg. Laparotomy revealed a hard, nodular lesion, approximately 5 cm in size, within the neck of the pancreas. Needle biopsy from the pancreas showed adenocarcinoma grade 2.

The day after laparotomy the patient developed chills and a temperature of 40 C (104 F), which were considered to be the result of urinary infection. One week later, there was sudden onset of dyspnea, circulatory collapse, and shock. A clinical and roentgenographic diagnosis of lobar pneumonia was made, and *S aureus* was isolated from sputum. Treatment with vancomycin hydrochloride and later with chloramphenicol resulted in improvement within five days. Forty days after admission, tender, red nodules suddenly appeared on his legs. The nodules occurred in linear distribution bilaterally over the inner and extensor aspects of both legs. The nodules became fluctuant and drained 160 ml of chocolate-colored purulent material. Culture of the material for organisms was negative. The skin lesions involuted with injections of adrenocortcotropin (40 units/day). The patient died after having been hospitalized for 56 days. Postmortem examination revealed pancreatic carcinoma and diffuse pancreatitis with extensive necrosis.

Case 23, a 55-year-old woman with chronic symptomatic cholecystitis, had a three-month history of tender, liquifying, and draining nodules of the thighs and buttocks. After the lesions had healed, a depression in the subcutaneous tissue was observed. Each crop of nodules occurred with fever and malaise. No history compatible with factitial panniculitis was obtained. On two occasions, fluid drainage from lesions showed lipase (36 units/ml). Two biopsied lesions were grossly hemorrhagic and necrotic, but lipase and amylase were not found. Histologically, acute panniculitis was observed. Cholecystectomy revealed a normal pancreas and mesenteric adenitis.

The two patients who were without abnormal enzyme values had localized inflammatory nodules of acute panniculitis.

Case 24, a 46-year-old woman, had nodules for 14 months after having had a sore throat. Lesions occurred both on the extremities and on the trunk, with predisposition for pressure sites. She had fever during the time that a new crop of nodules developed. The nodules were red and tender. There was no ulceration or suppuration, but when they healed, the lesions left depressions.

Case 25, a 43-year-old woman, had dermatitis of the hand for which she received a corticosteroid injection ten days before the onset of the nodules. She had also received intramuscular injections of pain relievers in her hips for severe headaches. The first red and tender nodules developed on her arms, where no injections had been given. These nodules healed after one month without ulceration or suppuration. For 4 years, nodules appeared on her buttocks, from which the biopsy specimens were taken, and these showed acute panniculitis.

Laboratory and Roentgenographic Findings.—The ESR was slightly elevated in cases 21, 22, 23, and 24, and in case 25, it was 81 mm/hr. None of the patients had leukocytosis. The serum amylase levels were normal in all four patients in whom the enzyme was measured, and the urinary amylase level was elevated fivefold in case 21. In case 22, there was an increase in serum amylase activity from 160 to 3,000 units/100 ml (normal up to 507

Fig 4.—Polymorphonuclear leukocytes with necrosis in acute panniculitis and pancreatic carcinoma. Small focus lipophagic proliferation is observed in left center (hematoxylin-eosin, original magnification ×160).

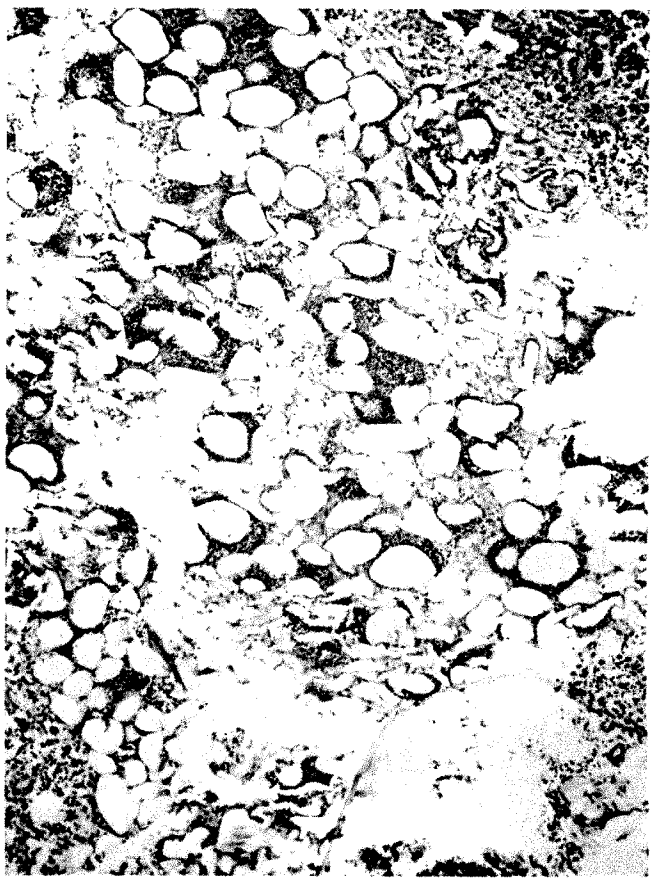

Fig 5.—Necklaces of polymorphonuclear leukocytes about fat cells in traumatic panniculitis. Focal fat necrosis is observed (hematoxylin-eosin, original magnification ×64).

units/100 ml). Cultures of the lesions for bacteria, fungi, and acid-fast organisms were negative.

Histopathologic Findings.—Cases 21 and 22 showed focal acute panniculitis. Case 21 also showed fat necrosis, liquefaction, and microcysts. Case 22 showed mild lipoblastic proliferation also (Fig 4). In case 24 particularly, the septa were affected by masses of polymorphonuclear cells. There was extensive hemorrhage in case 23. The biopsy specimen from case 25 revealed acute panniculitis and fat necrosis.

Traumatic Panniculitis

We define this as a syndrome of erythematous nodules that occur on minor trauma and have the histologic features of acute panniculitis.

Clinical Data.—This group consisted of two patients. One was a 44-year-old woman who fell and lacerated her scalp, for which she was given a tetanus toxoid injection. One week later, a red, tender, hot infiltration developed at the injection site, and after another week, a similar lesion developed on the upper anterior aspect of her thigh, a site of unknown trauma. One month later, two similar but linear lesions developed over the right lumbar area after the patient had been horseback riding. Finally, she struck the medial aspect of her left arm on a cupboard door, a minor blow, and nine days later, a tender, red, hot area appeared at the site of the trauma. There was no fever or other constitutional symptoms with any of the lesions. She had had hives in the past at least once a year. Except for an eruption after taking a sulfa drug, no sensitivities were known.

Examination showed several inflammatory subcutaneous lesions. A red-violaceous macule, 5 by 4 cm in size, was present in the lower deltoid area of the left arm at the site of the original tetanus injection. There was a round, tender, subcutaneous nodule, about 3 cm in diameter, near the upper border of the lesion. The entire area was warmer than the surrounding skin. There was an indurated subcutaneous linear lesion, 6 × 2 cm in size; another similar lesion, 4 × 2 cm in size, was seen parallel and horizontally over the lumbar area. Both lesions showed hyperpigmentation. On the site of the trauma (from striking the cupboard door), the medial aspect of her upper right arm, she had a red, infiltrated, tender, subcutaneous mass that was 10 cm in diameter. The right upper anterior aspect of her thigh had an irregular 2-cm area of lipoatrophy, with a central subcutaneous induration. Otherwise, she was in good general health.

The other patient was a 36-year-old woman who had a five-year history of recurrent nodules on the extremities. The nodules occurred during the winter months only. The first episode of nodules appeared over the elbows and was accompanied by fever and malaise. She visited a physician, who treated her with cortisone. The lesions cleared without any residua over a period of two to three weeks. The next episode occurred two years later and consisted of three or four nodules, which were 3 to 8 cm in diameter and located on her thighs and arms. At first, the lesions were red and tender. Later, they diminished in size and lost their color. Again, she was treated with cortisone. Since then the lesions recurred

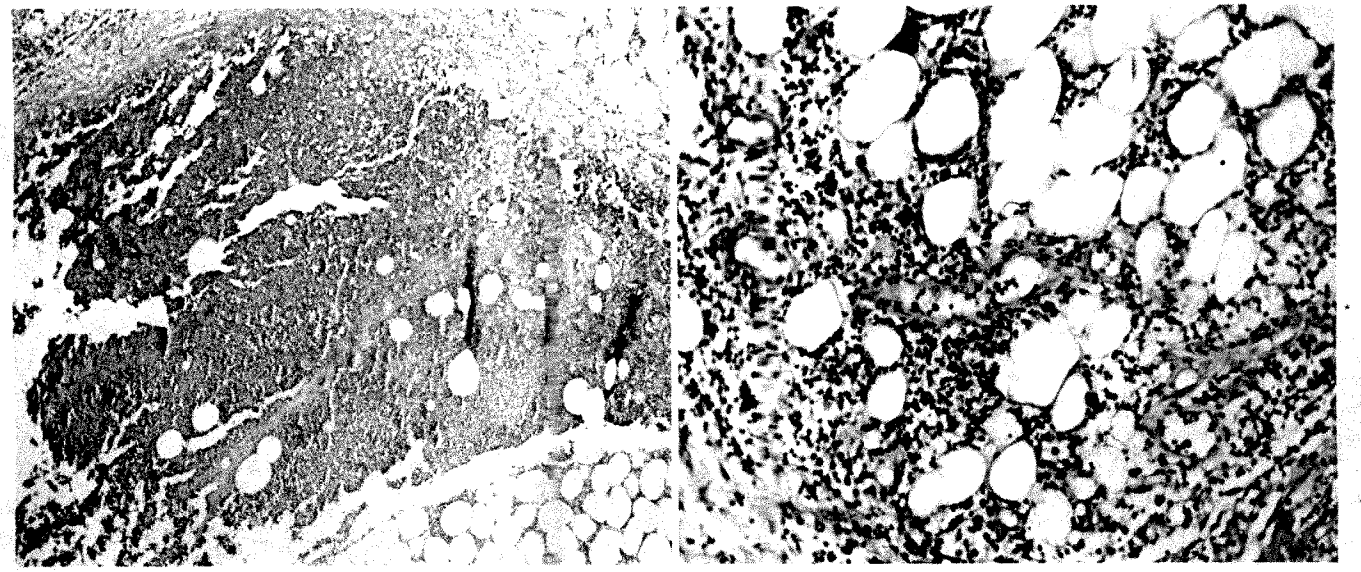

Fig 6.—Left, Acute panniculitis and necrosis in traumatic panniculitis. Right, Peripheral masses of polymorphonuclear leukocytes in fat lobule. Capillary vessels show secondary hyalinization (hematoxylin-eosin, left, original magnification ×64; right, original magnification ×160).

each winter, the episodes lasting weeks to several months. On three occasions, she had the lesions opened by a physician, and one drained spontaneously after trauma. Her local physician took a biopsy specimen, which he interpreted as being compatible with Weber-Christian disease. Thus, the patient was referred to our clinic. She left her home using crutches because a nodule on her left ankle was still draining purulent material after being incised. When she arrived at our clinic, there were hot, red, subcutaneous plaques at the circumference of the axillae due to the trauma of using the crutches.

Examination revealed a subcutaneous nodule that was 2 × 8 cm, along the medial aspect of her right arm, and several nodules at the circumference of the axillae. There was no color change of overlying skin. The posterior aspects of her thighs showed several red and tender nodules, 1 to 2 cm in diameter. Her general health was not changed. Marked improvement with healing or involution of all lesions occurred with bed rest.

Laboratory and Roentgenographic Findings.—The ESR was 45 mm/hr in one patient and 51 mm in the other. Both patients had normal leukocyte and differential counts. In the second patient, the hemoglobin value was 10.1 gm/100 ml; the lupus erythematosus clot test was negative; results of serum electrophoresis were normal; and the ASO titer was 250 Todd units. Both patients had normal serum amylase and lipase levels. Urinalysis revealed no abnormalities, and the chest roentgenograms revealed only slight cardiac enlargement in the first patient. Roentgenograms of the ankle were normal in the second patient. Culture of the pus from the incision site of the ankle showed growth of *P aeruginosa*. Cultures of biopsy specimens were negative for bacteria, *M tuberculosis*, *Brucella*, and fungi in both patients.

Histopathologic Findings.—The first patient had polymorphonuclear cells that were often arranged around cystic spaces in the fat (Fig 5); the lipophagic cells were few. The second patient had marked fat necrosis in addition to the polymorphonuclear leukocytes (Fig 6).

Vasculitis

A 46-year-old woman with regional enteritis (Crohn disease) had had lesions of cutaneous periarteritis nodosa on her lower extremities for four years. She had no signs or symptoms of infection. Focal or "starburst" livedo was prominent. Nodules on the livedo were suggestive of erythema nodosum. This patient was reported in detail in order to emphasize the vascular cutaneous lesions in Crohn's disease.[2] Biopsy specimens of the skin revealed acute panniculitis and no evidence of vascular inflammation until the entire lesion had been serially sectioned.

COMMENT

Erythema Nodosum

In many countries, erythema nodosum is not routinely studied by histopathologic examination. Furthermore, most studies of the histopathologic features of erythema nodosum have excluded cases in which the histologic findings have not fitted clearly defined limits accepted by the particular author. Probably for these reasons, the polymorphous nature of erythema nodosum histology, as described by us,[3] has not been fully recognized.

In most cases, erythema nodosum presents histopathologically as a vascular and septal inflammation characterized by a cellular infiltrate that is predominantly lymphocytic. Signs of thrombophlebitis are observed in 40% of cases.[4] Hemorrhage as a consequence of the phlebitis is common and should be recognized as a characteristic feature of erythema nodosum. Although emphasized by Miescher[5] in his classic description of the histologic features of erythema nodosum, the occurrence of hemorrhage has not gained much attention in more recent literature. It can occur as septal hemorrhage or as hemorrhage in the subcutaneous fat lobules.

In addition to the "typical" septal inflammation with phlebitis and hem-

orrhage, the spectrum of changes in erythema nodosum includes a true panniculitis of acute polymorphonuclear or subacute lymphocytic or rarely even chronic granulomatous type.[6] In our series of acute panniculitis, almost one half the cases were clinically typical examples of erythema nodosum, confirmed by follow-up. The necrosis sometimes seen apparently is not usually extensive enough to cause ulceration or scarring. Any individual feature may be predominant in a given area of a biopsy specimen so that multiple sections are necessary to recognize the variations in type and location of the pathologic process.

The observation of acute panniculitis in erythema nodosum has been made before, but it has not been emphasized in relation to clinical studies. Montgomery et al[7] stated in 1945 that erythema nodosum may show a relatively acute infiltration with atrophy and necrosis of the fat in the subcutaneous tissue. The case of acute benign panniculitis described by Turpin and Bocquet[8] probably was of erythema nodosum and is similar to many of our cases. More recently, Montgomery[9] described erythema nodosum in terms of an infiltration of polymorphonuclear leukocytes, although occasionally lymphocytes predominate. He found no constant findings, and he speculated whether there was a specific histologic picture for erythema nodosum. Likewise, Borrie and Stansfeld[10] concluded that, pathologically, erythema nodosum cannot be sharply separated from other examples of nodular vasculitis. Still later, Fine and Meltzer[11] observed foci of acute inflammation in one area and granulomatous inflammation in other areas of the same biopsy sections. They regarded this combination of acute and chronic inflammation as particularly characteristic of "chronic erythema nodosum."

Acute panniculitis is a descriptive histopathologic term whose features may be found at some time in most inflammation of the subcutaneous tissue. By simply expanding our range of diagnosis slightly to include cases with short-lived red nodules whether or not they are generalized, febrile, chronically recurrent, or suppurative, we find that two of the patients with Weber-Christian-type syndrome (cases 24 and 25), one with erythema induratum, and one with nodular vasculitis, and the two patients with traumatic panniculitis, could be considered to have acute panniculitis of erythema nodosum. Excluding the six patients with infection on the basis of clinical observation and culture, we find that 21 of the 28 patients with possible histopathologic acute panniculitis might be considered to have erythema nodosum.

Erythema Induratum

The typical histopathologic findings in erythema induratum include a granulomatous, tuberculoid infiltrate with vascular changes and areas of caseation necrosis. Although polymorphonuclear leukocytes have been reported to occur as components of the mixed cell infiltrate,[12] surprisingly five of our patients with acute panniculitis had clinical features generally known as being those of erythema induratum. We consider this diagnosis a distinct clinical entity, the cause of which sometimes can be tuberculous but generally is unknown (nodular vasculitis). The unresponsiveness of the disease to antituberculous treatment in two of three treated patients suggests a nontuberculous cause. In the future, more attention must be given to the age of the nodules biopsied because, in their evolution, even lesions of erythema induratum can develop a stage of acute panniculitis.

Acute Panniculitis With or Without Enzyme Changes (Weber-Christian-Like Panniculitis)

Since the classic description by Ungar,[13] histopathologists have associated acute panniculitis with the first stage of Weber-Christian disease.[14] However, the nosology of the Weber-Christian syndrome is at present very inexact[15,16]; several reports have included cases of erythema nodosum, acute traumatic panniculitis, and lupus panniculitis. Factitial panniculitis often presents histologically as acute panniculitis,[17-19] and several cases of Weber-Christian disease have on thorough examination seemed to have a factitial origin[17,20] or to be associated with enzyme abnormalities.[1,21-24] The demonstration of lipocyte proliferation in the second stage of Weber-Christian syndrome in some cases of erythema nodosum further emphasizes the lack of specificity of the histology of this entity. The further and final stage of fibrosis in Weber-Christian disease is nonspecific.

In our series, all of the cases of acute panniculitis and enzyme changes might earlier have been labeled Weber-Christian disease. Such cases may represent the only distinctive panniculitis syndrome that is equivalent to the description of Weber-Christian disease. Although the enzymes in serum, urine, and tissue may be related to the etiology of the process, they may only be markers of the tissue destruction. The destruction may be pancreatic or visceral as well as cutaneous, and the enzymes may be related to both visceral or cutaneous lesions.

Traumatic Panniculitis

The response of the subcutaneous tissues to mechanical trauma, insufficient in degree to cause immediate macroscopic injury, has been minimally studied. However, adipose tissue is extremely fragile, and even slight trauma may induce lesions.[25] Factitial panniculitis is one form of physically induced panniculitis. Jipp[26] reported traumatic fat necrosis, a necrotic inflammatory process occurring as nodules in the breasts following bleeding in the skin, after treatment with anticoagulants. Korting[18] found acute panniculitis with predominance of polymorphonuclear leukocytes and eosinophils to occur in nodules provoked by a "knock," a condition that he called nonfebrile suppurating Weber-Christian disease. Sarkany and Macmillan[27] proposed the name "recurrent, nonscarring, pressure panniculitis" for nodules appearing after local pressure and histologically showing acute panniculitis without vasculitis.

In two of the patients in the present series, we classified the panniculitis as traumatic because ordinary, minor trauma provoked the lesions. Probably other agents, so far unknown, may

have made the subcutaneous fat abnormally susceptible to "normal" trauma. In one of the patients, the seasonal appearance suggested a variant of erythema nodosum, and perhaps this is how the condition should be classified.

In our series of acute panniculitis, the role of trauma was not limited to the two patients classified as having traumatic panniculitis. Local trauma also preceded the development of several of the nodules in one patient with erythema nodosum and in one of the patients with the enzyme-panniculitis syndrome. Two additional patients with the enzyme-panniculitis syndrome and the patient with Crohn's disease and cutaneous periarteritis nodosa had predominance of lesions on locations likely to be traumatized, that is, bony prominences. In fact, the predisposition of the nodules for the anterior surface of the legs in erythema nodosum may be explained partly on the basis of the effect of minor trauma.

Vasculitis

The occurrence of vaculitis in the subcutaneous tissue is frequently associated with panniculitis. The panniculitis frequently is acute, angiocentric, and destructive, with infiltration of polymorphonuclear leukocytes and eosinophils. In all cases of acute inflammation, secondary hyalinization of the blood vessels can be observed, but in vasculitis, it is pervasive and also is found in the dermis where leukocytoclasia and vascular necrosis are more easily distinguished. In the spectrum of panniculitis associated with vascular inflammation, granulomas and lymphoproliferative features also may be found. The one case of vasculitis in our series illustrates that large, muscular, vessel inflammation also can be found with acute panniculitis.

CONCLUSIONS

This review of the special pathologic features of fat has revealed that most, if not all, inflammation of fat, whatever its cause, may have an acute inflammatory phase. All such lesions must be cultured and also studied for foreign materials and enzymes. The clinical pattern of the disease is most important in deciding the nature and prognosis of the nodular inflammatory process. Weber-Christian disease as an entity is rapidly being replaced by better described disease processes. Factitial panniculitis, traumatic panniculitis, panniculitis with enzyme changes, and connective tissue disease panniculitis are new syndromes that were once called "Weber-Christian disease." Erythema nodosum is the commonest form of clinical presentation of the histopathology of acute panniculitis, but even granulomatous erythema induratum may have a phase of acute panniculitis.

Nonproprietary Name and Trademark of Drug

Vancomycin—*Vancocin.*

References

1. Förström L, Winkelmann RK: Acute, generalized panniculitis with amylase and lipase in skin. *Arch Dermatol* 111:497-502, 1975.
2. Solley GO, Winkelmann RK, Rovelstad RA: Correlation between regional enterocolitis and cutaneous polyarteritis nodosa: Two case reports and review of the literature. *Gastroenterology* 69:235-239, 1975.
3. Winkelmann RK, Förström L: New observations in the histopathology of erythema nodosum. *J Invest Dermatol* 65:441-446, 1975.
4. Lofgren S: Erythema nodosum: Studies on etiology and pathogenesis in 185 adult cases. *Acta Med Scand* 174(suppl):9-197, 1946.
5. Miescher G: Zur Histologie des Erythema nodosum. *Acta Derm Venereol (Stockh)* 27:447-468, 1947.
6. Förström L, Winkelmann RK: Granulomatous panniculitis in erythema nodosum. *Arch Dermatol* 111:335-340, 1975.
7. Montgomery H, O'Leary PA, Barker NW: Nodular vascular diseases of the legs: Erythema induratum and allied condtions. *JAMA* 128:335-341, 1945.
8. Turpin R, Bocquet L: Panniculite aiguë bénigne. *Sem Hop Paris* 35:1793-1796, 1959.
9. Montgomery H: *Dermatopathology.* New York, Harper & Row Publishers, 1967, vol 2, pp 675-680.
10. Borrie P, Stansfeld A: Cutaneous vasculitis, in MacKenna RMB (ed): *Modern Trends in Dermatology,* ed 3. London, Butterworth & Co, 1966, pp 167-195.
11. Fine EM, Meltzer HD: Chronic erythema nodosum. *Arch Dermatol* 100:33-38, 1969.
12. Pavlik F, Kellner G, Till R: Reaktiv-nodöse prozesse in den unterschenkeln. *Z Haut Geschlechtskr* 48:11-24, 1973.
13. Ungar H: Relapsing febrile nodular inflammation of adipose tissue (Weber-Christian syndrome): Report of a case with autopsy. *J Pathol Bacteriol* 58:175-185, 1946.
14. Lever WF: Nodular nonsuppurative panniculitis (Weber-Christian disease): Report of a case in which an infiltrate of polymorphonuclear leukocytes represented the earliest lesion. *Arch Dermatol* 59:31-35, 1949.
15. Albrectsen B: The Weber-Christian syndrome, with particular reference to etiology: A description of eight cases of panniculitis. *Acta Derm Venereol (Stockh)* 40:474-484, 1960.
16. MacDonald A, Feiwel M: A review of the concept of Weber-Christian panniculitis with a report of five cases. *Br J Dermatol* 80:355-361, 1968.
17. Förström L, Winkelmann RK: Factitial panniculitis. *Arch Dermatol* 110:747-750, 1974.
18. Korting GW: Afebrile, suppurative Pfeifer-Weber-Christiansche Erkrankung mit Herdprovozierbarkeit durch Schlag und körpereigene Streptokokkenvakzine. *Dermatol Wochenschr* 133:521-528, 1956.
19. Parks DL, Perry HO, Muller SA: Cutaneous complications of pentazocine injections. *Arch Dermatol* 104:231-235, 1971.
20. Ackerman AB, Mosher DT, Schwamm HA: Factitial Weber-Christian syndrome. *JAMA* 198:731-736, 1966.
21. Duperrat B, Gaquière A, Bismuth V: Maladie de Weber Christian à déterminations multiples: Cutanées, mésentériques et osseuses. *Bull Mem Soc Med Hop Paris* 114:1235-1240, 1963.
22. Warter J, Storck D, Grosshans E, et al: Syndrome de Weber-Christian associe a un deficit en alpha-1-antitrypsine: Enquete familiale. *Ann Med Interne* 123:877-882, 1972.
23. De Graciansky P: Weber-Christian syndrome of pancreatic origin. *Br J Dermatol* 79:278-283, 1967.
24. Pavlik F: Pfeifer-Weber-Christian'sche Krankheit bei Pseudocyste des Pankreas. *Z Haut Geschlechtskr* 48:337-343, 1973.
25. Baumgartner W, Riva G: Pannikulitis, die herdförmige Fettgewebsentzündung. *Helv Med Acta* 14(suppl):7-69, 1945.
26. Jipp P: Subcutane Fettgewebsnekrosen nach Antikoagulantien-therapie. *Chirurg* 33:481-485, 1962.
27. Sarkany I, Macmillan AL: Recurrent nonscarring pressure panniculitis. *Proc R Soc Med* 62:1279, 1969.

Intrauterine Herpes Simplex Infections

James M. Komorous, MD; Clayton E. Wheeler, MD;
Robert A. Briggaman, MD; Ivor Caro, MB, BCh, FF Derm

• Most dermatologists are familiar with the manifestations of neonatal herpes simplex infections. Few, however, are acquainted with the concept of intrauterine herpes simplex infections.

This article describes two additional cases of intrauterine herpes simplex infections with congenital malformations. Common features included intrauterine growth retardation, microcephaly, encephalitis, chorioretinitis, psychomotor retardation, and recurrent, grouped, cutaneous vesicles. Seven similar cases with congenital malformations are reviewed as well as cases of intrauterine herpes simplex infection without congenital malformations.

We propose that intrauterine herpes simplex infections be termed "early" when there is evidence of disturbed embryogenesis or "late" when congenital malformations are less specific or inapparent. We further suggest that the spectrum of intrauterine infections is similar to that of neonatally acquired infections.

(*Arch Dermatol* 113:918-922, 1977)

Herpes simplex infections in the newborn represent uncommon yet well-recognized entities that were first documented by Batignani in 1934[1] and Hass in 1935.[2] Since then, numerous reports and reviews on the topic have appeared, the most recent being those of Nahmias et al in 1970[3] and Hanshaw in 1973.[4] It is generally agreed that most neonatal infections may be acquired either by ascending infection from the mother's genital area to the in utero infant after premature rupture of the membranes or by transvaginal spread to the infant during delivery. It is much less well appreciated that intrauterine infections have also been reported. This article describes two additional cases of intrauterine herpes simplex infection with associated malformations and discusses the spectrum of in utero infections in terms of both time of acquisition and severity.

REPORT OF CASES

CASE 1.—A girl was born Jan 21, 1969, at North Carolina Memorial Hospital (NCMH) to a 19-year-old, gravida 2, para 2 woman at 36½ weeks' gestation. The pregnancy was unremarkable except for a history suggestive of herpes progenitalis in the first trimester. After an uneventful five-hour labor, the baby was delivered transvaginally. The two-minute Apgar score was 10. On physical examination the weight was 1,932 gm, length 43 cm, and head circumference 28.5 cm, all less than the tenth percentile for the gestational age. There was a good cry and suck reflex and normal neurologic function. Microcephaly was present with overlapping of the coronal sutures, along with an abnormal right macula and minimal, healed chorioretinitis of the left eye.

On the fourth hospital day, numerous flat, grouped pustules were noted over the trunk, arms, and legs (Fig 1). A Tzanck preparation from those lesions showed multinucleated giant cells and intranuclear inclusion bodies. A skin biopsy specimen of a pustule on the left forearm showed changes compatible with herpes simplex, and material from pustules on the chest, left thigh, foot, and arm induced a cytopathologic effect (CPE) in HeLa cell cultures characteristic of herpes simplex type 2. Attempts to isolate virus from the infant's mouth, throat, anus, vagina, and nares were unsuccessful. A sample of cord blood had a neutralizing antibody titer of 1:128 for herpes simplex type 2.

Results of complete blood count (CBC) and urinalysis were normal as was chest x-ray film. A skull x-ray film demonstrated a small calvaria with overriding sutures. Results of chemical analyses of the blood were within normal limits except for an elevated indirect bilirubin level compatible with neonatal jaundice. On Jan 29, the quantitative IgM was 17 mg/100 ml, and on Feb 13, it was 32 mg/100 ml. The cerebral spinal fluid (CSF) had an elevated protein level of 226 mg/100 ml, glucose of 54 mg/100 ml, and RBC count of 3/cu mm and no WBCs. The child had serum neutralizing antibody titers suggestive of a herpes simplex type 2 infection (Table 1). Other serologic studies showed nonreactive maternal and cord blood for syphilis, an infant rubella hemagglutination inhibition (HI) titer of 1:320 on Jan 29 and Feb 18, and a maternal rubella HI titer of 1:320 on Feb 17. On Jan 29, the infant cytomegalovirus titer was less than 1:8, and the toxoplasma titer was negative.

The child required tube feedings in the

Accepted for publication Jan 13, 1977.

From the Department of Dermatology, North Carolina Memorial Hospital, Chapel Hill.

Reprint requests to Department of Dermatology, North Carolina Memorial Hospital, Chapel Hill, NC 27514 (Dr Wheeler).

premature nursery for the first week. New vesiculopustular herpetic skin lesions appeared throughout the hospital stay. Otherwise, she remained well, gaining to 2,310 gm without a change in head circumference, and was discharged on Feb 18.

She was observed closely thereafter in the pediatric and dermatology clinics where sequential sera were obtained for herpes simplex titers from the child and mother (Table 1). The maternal rubella HI titer on July 1, 1969, persisted at 1:320, whereas the infant's titer declined to 1:40 on May 6 and to 1:10 on July 1. On July 1, at 4 months of age, her weight, length, and head circumference were all less than the third percentile. She manifested severe psychomotor retardation, poor head control, opisthotonos, spastic quadriparesis, and bilateral nystagmus, but was able to blink her eyes in response to light and sound. On March 19, 1971, at 25 months of age, the child was admitted to NCMH because of dehydration. Vesicular lesions were noted on the neck, with a Tzanck preparation again showing multinucleated giant cells and intranuclear inclusion bodies. On April 13, at 27 months of age, she demonstrated marked microcephaly (head circumference 40.7 cm), growth retardation (weight 5,680 gm, length 69 cm), and psychomotor retardation. Ophthalmologic examination showed inability to follow light, bilateral healed chorioretinitis, and bilateral optic atrophy. Skull films showed microcephaly, a chest x-ray film showed diffuse bilateral infiltrates, and an electroencephalogram was grossly abnormal. The child was subsequently lost to follow-up.

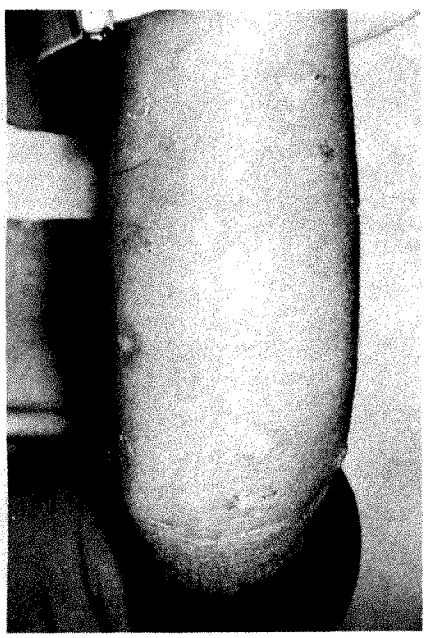

Fig 1.—Case 1 at the time of diagnosis. Grouped, vesiculopustular lesions on the left arm in various stages of evolution.

Table 1.—Neutralizing Antibody Titers* for Type 1 and Type 2 Herpes Simplex Virus

Sample and Date	Type 1 Titer	Type 2 Titer
Case 1		
Patient's serum		
Jan 28, 1969	512-1,024	1,024
Feb 17, 1969	512	1,024-2,048
April 13, 1971	256-512	2,048-4,096
Mother's serum		
Feb 5, 1969	128-256	128-256
May 6, 1969	128-256	256-512
April 13, 1971	64-128	128-256
Father's serum		
April 13, 1971	32-64	64-128
Case 2		
Patient's serum		
July 23, 1975	256-512	1,024-2,048
Jan 28, 1976	512-1,024	1,024-2,048
Patient's CSF		
July 23, 1975	32-64	32-64
Mother's serum		
July 23, 1975	128-256	512-1,024
Jan 28, 1976	256-512	512-1,024

*Neutralizing antibody titer is the reciprocal of the serum dilution that neutralized 50% of the herpes virus sample.

Case 2.—A boy was born at another hospital on July 21, 1975, to a 16-year-old, primigravida woman at 39 weeks' gestation. The birth weight was 2,450 gm (less than the tenth percentile). The pregnancy was uncomplicated except that the mother had an upper respiratory infection in the first trimester and noted her first episode of a perioral "fever blister" in the third trimester. No vaginal lesions were noted at the time of delivery. The mother's sister had recurrent herpes on one buttock; history pertaining to the father was unremarkable. At delivery oligohydramnios was noted, and the infant had an Apgar score of 6, poor suck, and a rash predominantly on the right side of the body. The child was transferred to NCMH on July 23 because of hypothermia and paroxysms of left-sided twitching and seizure-like activity. On admission he was lethargic, with a height of 49.5 cm (65th percentile) and head circumference of 32 cm (15th percentile). The fontanelles were flat with overlapping of the sutures, and there was positive transillumination over both frontal areas. He had a weak suck, weak cry, and was hypotonic with bilateral positive Babinski reflexes. His eyes were deeply recessed in the orbits, and microphthalmia was present. The pupils were normal and reacted to light, and "doll's eye" responses were intact. Ophthalmoscopic examination

Fig 2.—Anterior view of patient 2 at 48 hours after delivery. Erythematous, scaly, eroded, vesiculopustular eruption was confluent over the right side of the trunk and right upper extremity.

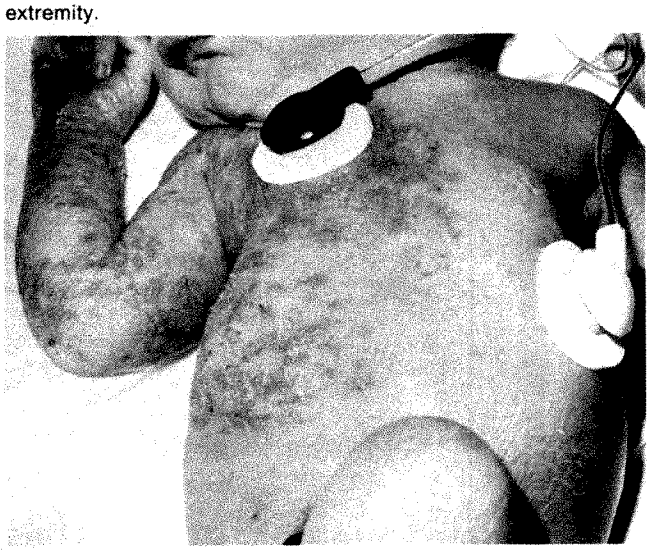

Fig 3.—Posterior view of patient 2 at 48 hours after delivery.

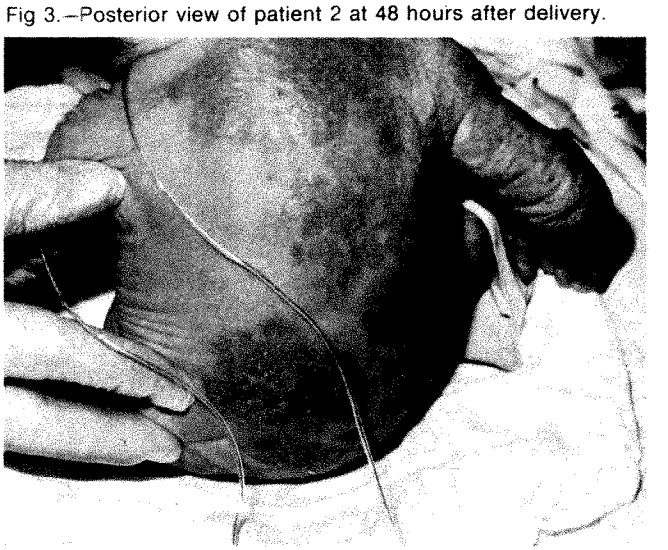

showed bilateral cobweb opacities at the plane of the posterior lens capsule and bilateral, white retinal masses thought to represent retinal dysplasia or scars. The liver edge was 1 cm below the right costal margin, but there was no splenomegaly. Skin examination revealed an ichthyotic appearance of the hands and feet and an erythematous, scaly, eroded, vesiculopustular eruption, which was confluent over the upper right arm and right side of the trunk with patches on the right shoulder, right axilla, right ear, nasolabial areas, cheeks, and both legs (Fig 2 and 3). A Tzanck preparation of blister fluid from the right axilla revealed acantholytic balloon cells, multinucleated giant cells, and intranuclear inclusion bodies. On the fifth hospital day blister fluid from vesicles in the right axilla and right upper back produced a CPE in HeLa cell cultures compatible with herpes simplex type 2. Viral cultures of the urine and CSF were negative. Serum obtained from the child on admission revealed neutralizing antibody titers consistent with a herpes simplex type 2 infection (Table 1). The mother's serum also demonstrated a herpes type 2 response. Rubella cytomegalovirus and toxoplasma titers were not elevated, and a serologic test for syphilis was nonreactive.

Results of CBC and platelet count were normal as was chest x-ray film. Chemical analyses of the blood gave normal results except for an SGOT of 99 IU and an elevated indirect bilirubin level compatible with physiologic, neonatal jaundice. Quantitative immunoglobulin determinations on admission demonstrated an elevated IgM of 34 mg/100 ml. The CSF had an elevated protein level of 210 mg/100 ml, glucose of 39 mg/100 ml, RBC count of 30/cu mm, and WBC count of 8/cu mm. Urine was unremarkable except for some unusual cells of possible embryonic connective tissue origin, but with no evidence of inclusion bodies. Skull films showed overriding of the sutures, and an EEG was abnormal with decreased voltage.

The child was treated with oxacillin sodium and kanamycin sulfate until the fourth day when all bacterial cultures were negative. The hospital stay was uneventful except for constant lethargy and temperature instability. He was transferred in an infant incubator to another hospital on Aug 4.

He was seen again on Sept 25, 1975, at 2 months of age, with recurrent, grouped vesicles on the trunk, possible deafness, and persistent temperature instability. The head circumference was 35 cm and he weighed 3,865 gm, below the third and tenth percentiles, respectively. He was lethargic and hypotonic and had hypopigmented areas with atrophy, scarring, and milia on the trunk, neck, and right arm. Skull films showed no calcifications. Ophthalmologic examination revealed inability to follow light and bilateral microcornea, microphthalmia, posterior synechias, posterior lenticular haziness, white vitreous masses, and chorioretinal scars.

The child was last seen on Jan 28, 1976, at 6 months of age. The head circumference was 39 cm (less than the third percentile), and he weighed 7,730 gm. The mother again described the intermittent appearance of grouped vesicles on the right side of his trunk, his inability to follow light or moving objects, and temperature instability. During the physical examination there were myoclonic jerking motions of his head and trunk as well as alternating flaccidity and rigidity of all of the extremities. Serum obtained from the infant and mother showed persistence of the herpes simplex type 2 titers, suggesting a chronic infection. The family was subsequently lost to follow-up.

VIRUS ISOLATION AND SEROLOGIC TESTS

In each case herpes simplex virus was isolated on HeLa cell cultures and identified as type 2 by the characteristic CPE produced by this virus. The virus in case 1 was also identified as type 2 by neutralization with anti-type 2 and anti-type 1 herpes simplex rabbit serum. Neutralization antibody tests were performed according to a previously described standard method.[5] The neutralization antibody titers were expressed as the reciprocal of the dilution of serum that neutralized 50% of the virus sample.

COMMENT

It is our opinion that these two infants represent the eighth and ninth documented cases of in utero herpes simplex infection with associated congenital malformations. Common features of their clinical presentations and subsequent courses are intrauterine growth retardation, microcephaly, encephalitis, chorioretinitis, psychomotor retardation, and recurrent, grouped, cutaneous vesicles. In addition, case 2 had seizures, microphthalmia, cloudy posterior lenses, persistent temperature instability, and immature connective tissue cells in the urine. The last two findings have not been previously described with intrauterine herpes infections, although urine sediment from the patient described by Florman and associates[6] contained cells with intranuclear "owl eye" inclusion bodies. In both of our cases, the diagnosis was made by the characteristic herpetic skin lesions, positive Tzanck preparations, induction of typical changes in HeLa cell cultures by material obtained from vesicular lesions, and elevated herpes simplex type 2 neutralizing antibodies in serum from the infant and mother soon after birth. Viral cultures from the infant's CSF, urine, mouth, nares, and anus were negative in each case. In case 1 the maternal and infant sera showed a notable rubella titer; however, the maternal titer remained elevated while the child's titer gradually decreased to within normal limits within five months, indicating only passive transfer of antibody. The infant's persistently elevated herpes simplex type 2 titers, however, indicated a chronic, ongoing viral infection. In case 2 the serum IgM was elevated, suggesting an in utero infection. Unfortunately, this finding is nonspecific, and the determination of specific IgM herpes virus antibodies, such as done by Nahmias et al[7] with the indirect immunofluorescent technique, was not performed.

Intrauterine Herpes Simplex Infections With Congenital Malformations

The first reports of possible in utero herpes simplex infections with congenital malformations were made by Schaffer and Avery in 1965[8] and South et al in 1969.[9] Florman and associates in 1973[6] reviewed four additional cases, including the first case of herpes simplex type 1 infection. They summarized the spectrum of anomalies, which included microcephaly, intracranial calcifications, diffuse brain damage, chorioretinitis, retinal dysplasia, microphthalmia, and a vesicular rash. Also in 1973, Montgomery and associates[10] reported a seventh case with the additional congenital anomalies of patent ductus arteriosus and short digits. The clinical and laboratory findings of those seven patients along with our two additional patients are summarized in Table 2. It is likely that there have been other cases of intrauterine herpes infection with congenital malformation that have not been recognized as such because of the lack of viral isolation, unavailability of serologic studies, or the similarity to congenital cytomegalovirus infections, as suggested by Florman and associates.[6] Hanshaw, for instance, knew of an infant with microcephaly, extensive cerebral calcifications, a vesicular rash, and a negative cytomegalovirus titer, but there was no viral isolation attempted (written communication, Oct 30, 1975).

Table 2.—Incidence of Clinical and Laboratory Findings in Nine Cases of Intrauterine Herpes Simplex Infection With Associated Congenital Malformations

	Reference of Each Case*									
Signs and Symptoms	8	9	3	3	3	5	10	Case 1	Case 2	Total
Temperature instability									X	1
Microphthalmia	X	X							X	3
Chorioretinopathy		X	X	X			X	X	X	6
Cloudy lenses		X							X	2
Microcephaly	X	X			X	X		X	X	6
Psychomotor retardation	X	X	X		X	X	X	X	X	8
Seizures		X				X			X	3
Spastic quadriplegia						X		X		2
Periventricular or cortical intracranial calcifications	X	X				X				3
Intrauterine growth retardation						X	X	X	X	4
Rash at birth or shortly thereafter	X	X	X	X	X		X	X	X	8
Cardiac abnormalities							X			1
Limb abnormalities							X			1
Hepatosplenomegaly						X				1
Pneumonitis						X				1
Laboratory Findings										
Herpes simplex type 1 isolation						X				1
Herpes simplex type 2 isolation	X	X	X	X	X		X	X	X	8
Elevated CSF protein	X	X	X		X	X		X	X	7
Elevated serum IgM at birth						X			X	2
Abnormal urinary sediment						X			X	2
Thrombocytopenia						X				1
History of first trimester herpes progenitalis		X	X	X	X			X		5

*Schaffer and Avery[6]; South et al[9]; Murphy, cited in Nahmias and associates[3]; Rubio, cited in Nahmias and associates[3]; Alford, cited in Nahmias and associates[3]; Florman et al[8]; and Montgomery et al.[10]

Pathogenesis of Congenital Malformations

The time of infection is difficult to ascertain by the severity of the clinical findings alone and almost impossible without a well-documented episode of infection in the mother or the presence of specific congenital malformations. Although a history suggestive of first trimester herpes progenitalis was reported in five of the nine cases, there was no such history in the remaining four, including our second case. Unlike the rubella virus that infects the embryo during embryogenesis, ie, during the critical first eight weeks of pregnancy, with resultant nuclear cataracts, hearing loss, and cardiac anomalies,[11] the congenital anomalies associated with the intrauterine herpes infections have generally been less specific. Anomalies such as microphthalmia, chorioretinopathy, microcephaly, and intracranial calcifications are not due to primary disturbances of organogenesis, but rather are teratogenic sequelae to disturbances of normally formed organs that may occur anytime after the first eight weeks to late in the third trimester.[11] Except for the case reported by Montgomery and associates[10] with cardiac and digital anomalies, congenital malformations determined during embryogenesis have not been documented. Alford states that it takes four to six weeks for microcephaly to appear in extrauterine life after sufficient brain destruction. Extrapolating from this observation he estimated that his case of in utero infection occurred approximately five weeks before delivery (written communication, Sept 15, 1975).

Early and Late Intrauterine Herpes Simplex Infections

We propose, therefore, that intrauterine herpes simplex infections be termed "early" when there is substantial evidence of infection during the first eight weeks of gestation or "late" when congenital malformations are less specific or inapparent, suggesting infection between eight weeks of gestation and term. We consider our two cases examples of late intrauterine infection because there were no congenital malformations in these infants that would indicate herpetic infection during embryogenesis.

Evidence of early intrauterine herpes simplex infections in humans is quite limited. We have already discussed the case reported by Montgomery and associates.[10] Naib et al[12] have shown an apparent relationship between genital herpes infection during the first four months of pregnancy and an increased abortion rate. Boué and Loffredo[13] isolated herpes virus type 2 from a spontaneous abortion at five weeks' gestation, and Goldman[14] more recently reported herpetic inclusions in the endometrium after dilatation and curettage for a missed abortion. Nahmias recently stated,[15] however, that in his experience the virus was isolated from fetal membranes, rather than fetal tissue, and postulated that abortions are usually produced by indirect effects of the virus.

In addition to the nine cases of intrauterine herpes simplex infections with associated congenital malformations reported herein, there is other evidence of late intrauterine infections. Witzleben and Driscoll in 1965,[16] Sieber et al in 1966,[17] and Blanc in 1968[18] described the presence of placental lesions in four infected newborn infants. Recently, Altshuler[19] reported a case of neonatal herpes simplex with necrotizing chorioamnionitis and postulated ascending infection with transamniotic spread in the presence of intact fetal membranes. Further evidence of late intrauterine infection includes recovery of herpes virus from the placenta and/or cord blood,[20,21] the development of the disease in infants who had intact fetal membranes and were delivered by cesarean section,[20,22] and numerous cases with the presence of herpetic lesions at birth.[23-28] In almost all of these cases, there was no known maternal herpetic disease at delivery or well-documented history of herpetic infection during pregnancy; therefore, the time of intrauterine infection could not be determined.

Animal Models

Animal studies support the concept of intrauterine herpes simplex infections. Transplacental herpes infections have been demonstrated by Biegeleisen et al and again by Middel-

kamp et al in rabbit fetuses[29-31] and by Ferm and Low in hamster fetuses.[32] In none of these experimental models were congenital anomalies produced. However, Heath et al[33] demonstrated central nervous system damage, a small brain, growth retardation, and eye and auditory anomalies in chick embryos inoculated with herpes simplex virus.

Comparison of Intrauterine and Neonatal Herpes Simplex Infections

It is interesting to compare the spectrum of intrauterine herpes simplex infections to neonatal infections. It is most likely that intrauterine infections are secondary to maternal viremia and transplacental spread as with other viral infections. Most intrauterine infections reported have been due to herpes simplex type 2, similar to the findings in neonatal infections.[7] Congenital abnormalities such as microcephaly, chorioretinitis, intracranial calcifications, and psychomotor retardation as seen in late intrauterine infection have all been described after chronic herpes infections acquired in the neonatal period.[3,4,34,35] This would indicate simply an earlier onset of infection with the in utero cases, not necessarily a different pathogenesis. The spectrum of clinical disease seen in cases of late intrauterine herpes infection without malformations is also similar to that of neonatally acquired infections. This spectrum has ranged from fatal disseminated disease with hepatoadrenal necrosis, encephalitis, fever, pneumonia, and vesicular eruptions,[16,17,20-23,26] to recovery with recurrent vesicular eruptions, neurologic and ophthalmic sequelae,[23,24,27,28] to recurrent vesicular eruptions without detectable sequelae.[25,27,28]

Conclusion

Although there is evidence that the severity of the infection and the degree and number of congenital malformations is related to the time of onset and duration of the intrauterine disease in congenital rubella and cytomegalovirus infections,[11,36] evidence for this relationship with intrauterine herpes simplex infections is less clear. It is our impression that herpes simplex virus can infect the fetus at any time during pregnancy, as well as the neonatal period, with severity ranging from abortion, congenital malformations, severe infection without malformations, to mild disease with few sequelae, and perhaps even to subclinical infections. Perhaps the severity of intrauterine infections and the sequelae may well be related to as yet undetermined immune mechanisms[37] or other unknown factors, in addition to the time and duration of infection.

Cytomegalovirus, rubella virus, and toxoplasma titers were obtained at the North Carolina State Laboratory.

References

1. Batignani A: Conjunctivite da virus erpetico in neonato. *Boll Ocul* 13:1217-1220, 1934.
2. Hass GM: Hepato-adrenal necrosis with intranuclear inclusion bodies: Report of a case. *Am J Pathol* 11:127-142, 1935.
3. Nahmias AJ, Alford CA, Korones SB: Infection of the newborn with herpesvirus hominis. *Adv Pediatr* 17:185-226, 1970.
4. Hanshaw JB: Herpesvirus hominis infections in the fetus and the newborn. *Am J Dis Child* 126:546-555, 1973.
5. Wheeler CE: Further studies on effect of neutralizing antibody upon course of herpes simplex infections in tissue culture. *J Immunol* 84:394-403, 1960.
6. Florman AL, Gershon AA, Blackett PR, et al: Intrauterine infection with herpes simplex virus: Resultant congenital malformations. *JAMA* 225:129-132, 1973.
7. Nahmias AJ, Dowdle WR, Josey WE, et al: Newborn infection with herpesvirus hominis types 1 and 2. *J Pediatr* 75:1194-1203, 1969.
8. Schaffer AJ, Avery ME: *Diseases of the Newborn*, ed 3. Philadelphia, WB Saunders Co, 1971, p 656.
9. South MA, Tompkins WAF, Morris CR, et al: Congenital malformation of the central nervous system associated with genital type (type 2) herpesvirus. *J Pediatr* 75:13-18, 1969.
10. Montgomery JR, Flanders RW, Yow MD: Congenital anomalies and herpesvirus infection. *Am J Dis Child* 126:364-366, 1973.
11. Warkany J: *Congenital Malformations*. Chicago, Year Book Medical Publishers Inc, 1971.
12. Naib ZM, Nahmias AJ, Josey WE, et al: Association of maternal genital herpetic infection with spontaneous abortion. *Obstet Gynecol* 35:260-263, 1970.
13. Boué A, Loffredo V: Avortement cause par le virus de l'virus de l'herpes type 2: Isolement du virus a partir de culture de tissue zygotiques. *Presse Med* 78:103-106, 1970.
14. Goldman RL: Herpetic inclusions in the endometrium. *Obstet Gynecol* 36:603-605, 1970.
15. Nahmias AJ: Delay can be deadly in neonatal herpes. *Infect Dis* 5:6-14, 1975.
16. Witzleben CL, Driscoll SG: Possible transplacental transmission of herpes simplex infection. *Pediatrics* 36:192-199, 1965.
17. Sieber OF Jr, Fulginiti VA, Brazie J, et al: In utero infection of the fetus by herpes simplex virus. *J Pediatr* 69:30-34, 1966.
18. Blanc WA: The future of antepartum morphologic studies, in Adamsons K (ed): *Diagnosis and Treatment of Fetal Disorders*. New York, Springer-Verlag, 1968.
19. Altshuler G: Pathogenesis of congenital herpesvirus infection. *Am J Dis Child* 127:427-429, 1974.
20. Gagnon A: Transplacental inoculation of fatal herpes simplex in the newborn. *Obstet Gynecol* 31:682-684, 1968.
21. Patrizi G, Middelkamp J, Reed C: Fine structure of herpes simplex virus. *Am J Clin Pathol* 49:325-341, 1968.
22. Bird T, Ennis JE, Wort AJ, et al: Disseminated herpes simplex in newborn infants. *J Clin Pathol* 16:423-431, 1963.
23. Torphy DE, Ray CG, McAlister R, et al: Herpes simplex virus infection in infants: A spectrum of disease. *J Pediatr* 76:405-408, 1970.
24. Mitchell JE, McCall FC: Transplacental infection by herpes simplex virus. *Am J Dis Child* 106:207-209, 1963.
25. Guha DK, Rashmi A, Khanduja PC: In utero infection of the fetus by herpes simplex virus. *Indian J Pediatr* 35:484-486, 1968.
26. Strawn EY, Scrimenti RJ: Intrauterine herpes simplex infection. *Am J Obstet Gynecol* 115:581-582, 1973.
27. Pettay O, Leinikki P, Donner M, et al: Herpes simplex virus infection in the newborn. *Arch Dis Child* 47:97-103, 1972.
28. Hovig DE, Hodgman JE, Mathies AW, et al: Herpesvirus hominis (simplex) infection in the newborn: With recurrences during infancy. *Am J Dis Child* 115:438-444, 1968.
29. Biegeleisen JZ Jr, Scott LV: Transplacental infection of fetuses of rabbits with herpes simplex virus. *Proc Soc Exp Biol Med* 97:411-412, 1958.
30. Biegeleisen JZ Jr, Scott LV, Joel W: Further evidence of fetal infection with herpes simplex virus. *Am J Clin Pathol* 27:289-293, 1962.
31. Middelkamp JN, Reed CA, Patrizi G: Placental transfer of herpes simplex virus in pregnant rabbits. *Proc Soc Exp Biol Med* 125:757-760, 1967.
32. Ferm VJ, Low RJ: Herpes simplex infection in the pregnant hamster. *J Pathol Bacteriol* 89:295-300, 1965.
33. Heath HD, Shear HH, Imagawa DT, et al: Teratogenic effects of herpes simplex, vaccinia, influenza-A (NWS), and distemper virus infections on early chick embryos. *Proc Soc Exp Biol Med* 92:675-682, 1956.
34. Nahmias AJ, Hagler WS: Ocular manifestations of herpes simplex in the newborn (neonatal ocular herpes). *Int Ophthalmol Clin* 12:191-213, 1972.
35. Eyster EF, Margolis MT: Progressive cortical calcification in a newborn: Report of a case. *Neuroradiology* 2:115-118, 1971.
36. Monif GRG, Egan EA II, Held B, et al: The correlation of maternal cytomegalovirus infection during varying stages in gestation with neonatal involvement. *J Pediatr* 80:17-20, 1972.
37. Cramer DV, Kunz HW, Gill TJ III: Immunologic sensitization prior to birth. *Am J Obstet Gynecol* 120:431-439, 1974.

Pemphigus Antibody Action on Skin Explants

Kinetics of Acantholytic Changes and Stability of Antigens in Tissue Cultures of Normal Monkey Skin Explants

Jau-Shyong Deng, MD; Ernst H. Beutner, PhD; Suyu Shu, PhD; Tadeusz P. Chorzelski, MD

• The pathogenic effect of the intercellular antibodies of pemphigus was studied by using organ culture of monkey skin. Skin explants that were grown on sera with intercellular antibody titers of 320 or greater fixed these antibodies within one day as demonstrated by direct immunofluorescence for IgG. None of the control sera gave such staining patterns. Following the binding of intercellular antibodies, characteristic histologic changes appeared, notably separation of individual epidermal cells and acantholysis. These histologic changes became more marked in two to five days. During this period, the bound antibodies and the intercellular antigens decreased and disappeared. These temporal relationships of immunofluorescence and histologic findings suggest that pemphigus antibodies play a role in the induction of acantholysis.

(*Arch Dermatol* 113:923-926, 1977)

Accepted for publication Nov 17, 1976.

From the Department of Dermatology, National Taiwan University, Taipei (Dr Deng), the Department of Microbiology, State University of New York, Buffalo (Drs Beutner and Shu), and the Department of Dermatology, Warsaw Academy of Medicine, Poland (Dr Chorzelski).

Reprint requests to Department of Microbiology, State University of New York, Buffalo, NY 14214 (Dr Beutner).

Since the original description of the intercellular antibodies of pemphigus,[1] numerous studies have been reported concerning their clinical significance[2] and their role in the pathogenesis of the disease.[3] Specifically, pemphigus antibodies can passively transfer the disease[4-6] and appear to induce lesion formation after ultraviolet (UV) irradiation.[7] Using an organ culture system in which normal skin is incubated in sera containing pemphigus antibodies, Michel and Ko demonstrated acantholytic changes in the skin explants.[8] Our results confirm these findings and indicate that this system provides a good model with which to study the pathogenetic role of pemphigus antibodies in the development of pemphigus lesions. The purpose of this study is to detail findings on the kinetics of acantholytic changes and the stability of antigens in monkey skin explants.

SUBJECTS AND METHODS

Sera from five patients with pemphigus vulgaris were studied. These had titers of intercellular antibodies in the range of 320 to 1,280 on sections of fresh monkey esophagus. A normal serum and sera of 20 patients with various connective tissue diseases served as controls. The latter had high titers of antinuclear antibodies (ANA). (Details of findings with sera containing high titers of ANA will be reported elsewhere.)[9]

Methods of Organ Culture

Skin explants were taken from the abdominal wall of Asian *Macaca ira* monkeys immediately after they were killed. Before removal of skin, the hair was cut, and the skin was cleaned with 70% alcohol solution and dried with sterile cotton. The excised skin strips were then washed in a balanced salt solution that contained 100 μg/ml of neomycin hydrochloride. A keratotome was used to cut skin explants at a thickness of about 0.5 mm. Skin explants measuring 2 × 2 mm were grown at 31 C on 1 ml of pemphigus sera or control sera; each of these sera contained 100 μg/ml of neomycin, and a modified raft technique was used,[10,11] ie, explants were supported on wax-rimmed lens paper. Media were changed daily. Explants were removed after one to five days and processed for routine histologic study or immunofluorescence staining.

Immunofluorescence Staining

Explants were quick frozen in liquid nitrogen, cut 4 μ in a cryostat, and processed for immunofluorescence staining or stored at −80 C. Indirect immunofluorescence staining was performed with a conjugate that was prepared from a goat antiserum to human IgG with antibodies to both heavy and light chains and with the following characteristics: (1) total protein (P), 10.9 mg/ml; (2) fluorescein (F), 54.8 μg/ml; (3) antibody protein (AB), 2.85 mg/ml; and (4) molar F/P ratio 2.1.[12] To remove the anti-IgG antibodies, a portion of the conjugate was absorbed with 3.5 mg/

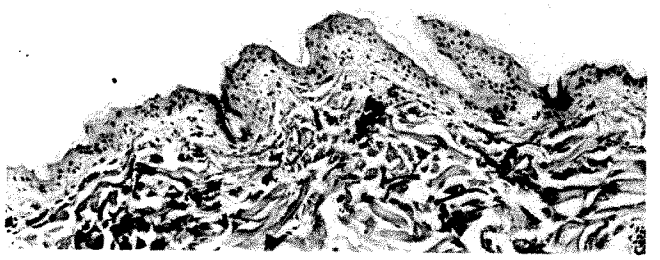

Fig 1.—Monkey skin on normal human serum after three days appears normal. There is little parakeratosis or thickening of horny cell layer. Epidermal cells seem to increase in size and stain more lightly (hematoxylin-eosin, ×100).

Fig 2.—Monkey skin in pemphigus serum after three days develops advanced suprabasal acantholysis involving both marginal and central portions of explant (hematoxylin-eosin, ×100).

Histologic Changes in Organ Culture of Skin in Pemphigus and Normal Human Sera

Time, Days	Histological Changes of Organ Culture	
	Pemphigus Serum	Normal Human Serum
1	Separation of individual epidermal cells and minimal acantholysis near margin of explant	Normal histologic structure
2	Acantholysis in marginal zone sometimes with separation of epidermis in central zone of skin	Essentially normal histologic structure
3	Advanced acantholysis, minimal parakeratosis, sometimes with separation of keratinized layers or vacuolation	Usually normal histologic structure, sometimes with separation of keratinized layers and vacuolation, also minimal parakeratosis
4	Advanced acantholysis, parakeratosis, and thickening of horny layers	Parakeratosis and thickening of horny layers
5	Advanced acantholysis and sloughing off of epidermis	Parakeratosis and thickening of horny layers
Special histologic changes	Acantholysis	Parakeratosis

ml of human IgG. Both unabsorbed and absorbed conjugate preparations were diluted 1:128 with phosphate-buffered saline that contained 4% bovine serum albumin for use in immunofluorescence. For the unabsorbed conjugate, this resulted in an AB concentration of 100 μg/ml. The degree of saturation of the intercellular antigen in organ culture was checked by indirect immunofluorescence with the same pemphigus serum in which explants were cultured.

RESULTS

Skin explants cultured with normal human sera or sera with ANA for one day underwent no detectable changes. By two days, only minimal histologic changes appeared, while after three days early parakeratotic changes could be seen (Fig 1). When the skin was maintained in organ culture for a longer period, thickening of the horny cell layers and parakeratosis became pronounced.

Skin explants maintained on pemphigus sera showed characteristic histologic changes. After one to two days, suprabasal separation developed in the epidermis, particularly at the periphery of the explants. Explants maintained on pemphigus sera for three to four days developed suprabasal acantholytic lesions (Fig 2). Pemphigus sera induced changes that resembled those seen in human pemphigus lesions prior to the appearance of inflammatory cells. The Table compares the histologic changes seen in explants grown on pemphigus and normal sera.

The binding of pemphigus antibodies to the intercellular areas of skin explants were shown by direct immunofluorescence for IgG deposits. While explants grown on normal sera had no intercellular deposits of IgG (Fig 3), those grown on pemphigus sera for one day gave positive direct immunofluorescence staining of the intercellular substance (Fig 4). Each of the five pemphigus sera produced positive direct immunofluorescence staining of the intercellular areas and suprabasal acantholytic lesions. In contrast, none of the 21 control sera produced either positive direct immunofluorescence staining patterns or histopathologic changes.

The time sequence of the appearance and disappearance of these reaction patterns is shown in the top of Fig 5. Direct immunofluorescence staining of the intercellular substance was the strongest on days 1 and 2, declined progressively on days 3 and 4, and disappeared thereafter. However, the titer of pemphigus antibodies in the medium remained constant since the medium was changed daily. The formation of intraepithelial lesions became more marked after maximal reactivity of the pemphigus antibodies had been reached, ie, in 48 to 72 hours.

Simultaneous indirect immunofluorescence for the disappearance of the intercellular antigens was performed on skin explants maintained on normal human sera for varying periods of time (Fig 5, bottom). These

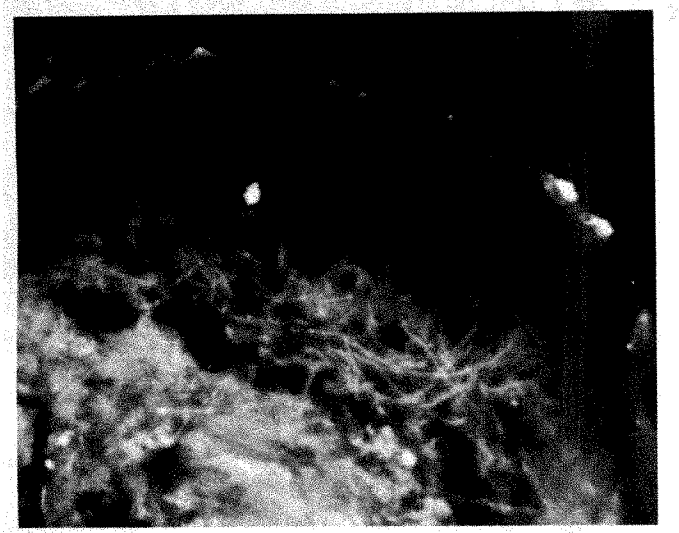

Fig 3.—Direct immunofluorescence staining for IgG deposition in epidermis of explant on normal human serum after one day reveals no staining in intercellular areas of epidermis. This serves as negative control (×400).

Fig 4.—Direct immunofluorescence staining of monkey skin in pemphigus serum for one day shows staining in intercellular spaces of epidermis. This indicates that pemphigus antibodies have diffused into tissue and reacted with intercellular antigens (×100).

Fig 5.—Interrelationship between histological change, intensity of immunofluorescent-bound (IF) pemphigus antibodies (top), relative pemphigus antigen reactivity (bottom), and time interval of organ culture.

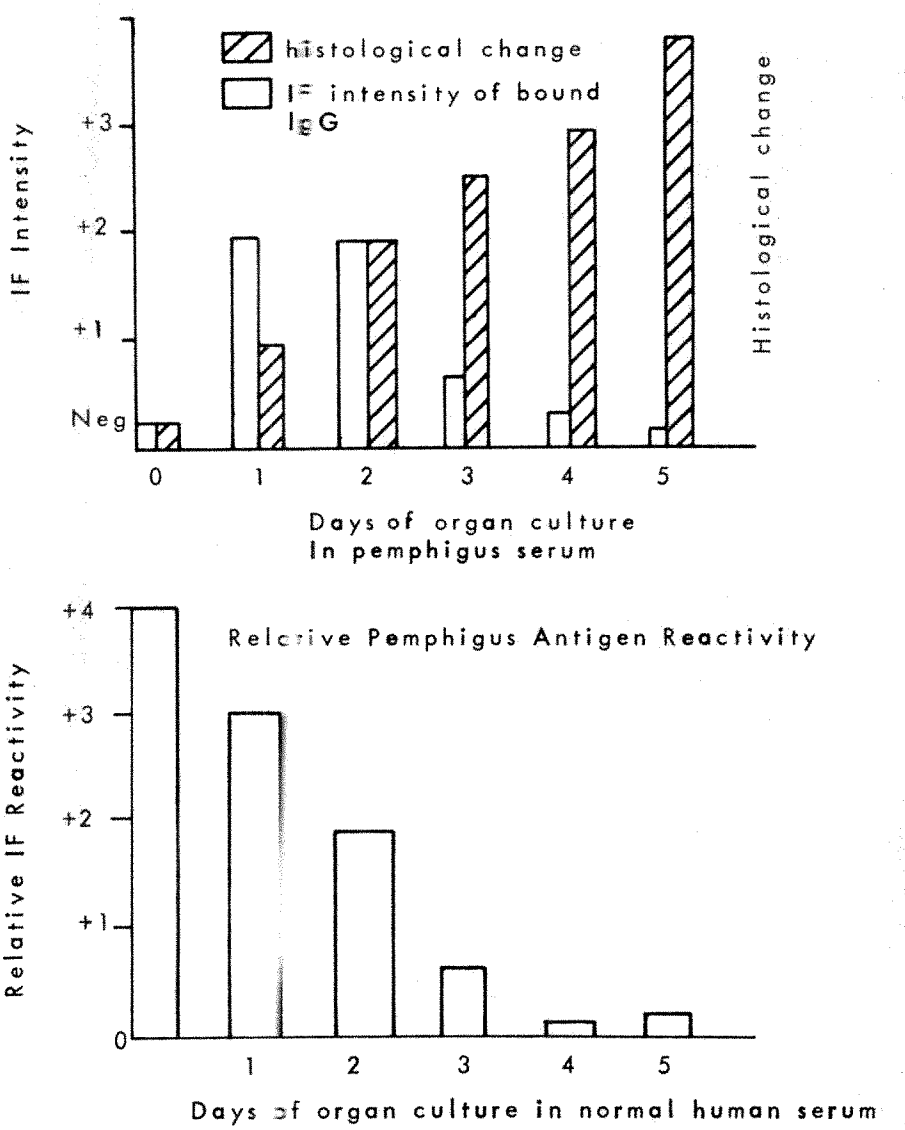

tests, which were performed with a single dilution of a pemphigus serum that gave a 4+ reaction on uncultured skin, showed a progressive decrease in the intensity of indirect immunofluorescence staining from day 0 to day 3. By the fourth and fifth days in organ culture, the reaction was essentially negative, which indicated that the loss in pemphigus antigens occurred in skin explants maintained in culture. The loss in pemphigus antigen concentrations between days 2 and 4 paralleled the loss of organ culture-bound pemphigus antibodies in that time span and gave an explanation for the latter.

To gain a more quantitative measure of the rate of antigen loss in organ culture, separate studies were performed in which full titrations with three pemphigus sera were carried out on skin explants maintained on a normal serum for varying periods of time. Again skin explants cultured on normal serum for one to two days exhibited a progressive decrease in relative titers. After three days in culture, only one of the three sera still gave a measurable immunofluorescence staining titer, and on the fourth day, all three sera gave nega-

tive reactions.

While indirect immunofluorescence on explants grown on normal sera gave a measure of the rate of pemphigus antigen loss and direct immunofluorescence on explants grown on pemphigus sera gave a qualitative measure of the organ culture reactivity of pemphigus antibodies, indirect immunofluorescence on the latter explants was needed to determine the degree of antigen saturation. Since a comparable intensity of staining was obtained in indirect and direct immunofluorescence on days 1 through 4, it appears that the organ culture reactions of pemphigus antibodies with explants saturate the intercellular antigens.

Interestingly, an explant of clinically normal skin from a pemphigus patient with in vivo-bound pemphigus antibodies grown on normal serum developed acantholysis in organ culture; however, the patient from whom the explant was taken developed no lesions in the vicinity of the biopsy site or elsewhere on the skin. It may be that the failure to develop intercellular antigen in culture renders explants more susceptible to the effects of pemphigus antibodies and that the continued synthesis of intercellular antigen in vivo gives some protection against bulla formation.

COMMENT

Explants of monkey skin grown on sera containing pemphigus antibodies developed intraepidermal changes that appeared analogous to those seen in human pemphigus lesions. These findings confirm the report of Michel and Ko[8] on the cytopathic effect of pemphigus antibodies on human skin explants. Our data show the sequence of events, as follows: (1) The pemphigus antibodies saturate the intercellular antigen on the first day in culture. (2) While some early histologic changes appear in an occasional explant grown on pemphigus serum for 24 hours, the characteristic suprabasal acantholytic changes usually do not appear until the second or third day in culture. By that time, a marked decrease in the amount of intercellular antigen is evident in indirect immunofluorescence and the expected decrease in the corresponding fixation of pemphigus antibodies can be shown by direct immunofluorescence staining. (3) On days 4 and 5, the intercellular antigen is completely gone, and the explants grown on pemphigus sera exhibit fully developed lesions.

In principle, this organ culture system provides a remarkably simple experimental model for studies on the immunopathology of the human disease. Although skin explants are subject to various biological changes, including immunologic, biochemical, and histologic modifications,[10,11] that may cause questions in interpretation, the present study and previous reports[8,10,11,13] indicate that these changes are predictable when explants are maintained under appropriate conditions.

Schiltz and Michel[14] have recently shown that the IgG fraction of pooled pemphigus sera induced acantholytic changes in skin explants in the absence of complement, and that pemphigus antibodies effectively blocked the incorporation of RNA and protein by the suprabasal cells but did not affect the basal cells. The latter could explain the failure of explants grown on pemphigus sera to develop the parakeratosis seen in explants grown on normal sera.

While these organ culture studies together with the passive transfer studies[4-6] and the studies on UV induction by Cram[7] and by T.P. Chorzelski, MD (unpublished data, November 1973) point to a pathogenic role of pemphigus antibodies, it should be stressed that a model system based on the production in animals of the entire spectrum of immunologic phenomena seen in human pemphigus is still needed to obtain definite proof of the autoimmune cause of this disease. In effect, organ culture studies such as the ones considered in the present study should eventually be reproduced with sera from animals with pemphigus. Such sera would, naturally, be expected to have pemphigus antibodies that could bind in vivo and in organ culture.[15]

This study was supported by a grant from the Summerhill Foundation and by a postdoctoral fellowship of the China Medical Board of New York, Inc.

Halyna Kostushko and Sharon Spicer provided technical assistance.

References

1. Beutner EH, Jordon RE: Demonstration of skin antibodies in sera of pemphigus vulgaris patients by indirect immunofluorescent staining. *Proc Soc Exp Biol Med* 117:505-510, 1964.

2. Chorzelski TP, Jablonska S, Beutner EH: Clinical significance of pemphigus antibodies, in Beutner EH, Chorzelski TP, Bean SF, et al (eds): *Immunopathology of the Skin: Labeled Antibody Studies*. Stroudsburg, Pa, Dowden Hutchinson & Ross Inc, 1973, pp 25-34.

3. Beutner EH, Chorzelski TP: Experimental studies on autosensitization in bullous diseases and on transfer of pemphigus, in Beutner EH, Chorzelski TP, Bean SF, et al (eds): *Immunopathology of the Skin: Labeled Antibody Studies*. Stroudsburg, Pa, Dowden Hutchinson & Ross Inc, 1973, pp 330-353.

4. Wood GW, Beutner EH, Chorzelski TP: Studies in immunodermatology: II. Production of pemphigus-like lesions by intradermal injection of monkeys with Brazilian pemphigus foliaceus sera. *Int Arch Allergy Appl Immunol* 42:556-564, 1972.

5. Holubar K, Chorzelski TP, Gauto M, et al: Studies in immunodermatology: III. Induction of intraepithelial lesions in monkeys by intramucosal injections of pemphigus antibodies. *Int Arch Allergy Appl Immunol* 44:631-643, 1973.

6. Chorzelski TP, Beutner EH, Jarzabek M: Passive transfer of pemphigus to experimental animals, proceedings. *Int Arch Allergy Appl Immunol* 39:106, 1970.

7. Cram DL: Photoinduction of lesions in patients with pemphigus and bullous pemphigoid, in Beutner EH, Chorzelski TP, Bean SF, et al (eds): *Immunopathology of the Skin: Labeled Antibody Studies*. Stroudsburg, Pa, Dowden Hutchinson & Ross Inc, 1973, pp 44-54.

8. Michel B, Ko CS: Effect of pemphigus or bullous pemphigoid sera and leucocytes on normal human skin in organ culture: An in vitro model for the study of bullous diseases. *J Invest Dermatol* 62:541-542, 1974.

9. Shu S, Provost T, Corxdale MB, et al: Nuclear deposits of immunoglobulins in skin of patients with systemic lupus erythematosus. *Clin Exp Immunol* 27:238-244, 1977.

10. Sarkany I, Grice K, Caron GA: Organ culture of adult human skin. *Br J Dermatol* 77:65-76, 1965.

11. Levine M: The growth of adult human skin in vitro. *Br J Dermatol* 86:481-490, 1972.

12. Beutner EH, Nisengard RJ: Defined immunofluorescence in clinical immunopathology, in Beutner EH, Chorzelski TP, Bean SF, et al (eds): *Immunopathology of the Skin: Labeled Antibody Studies*. Stroudsburg, Pa, Dowden Hutchinson & Ross Inc, 1973, pp 197-247.

13. Reaven EP, Cox AJ: Organ culture of human skin. *J Invest Dermatol* 44:151-156, 1965.

14. Schiltz J, Michel B: Production of epidermal acantholysis in normal human skin in vitro by the IgG fraction from pemphigus serum. *J Invest Dermatol* 67(pt 2):254-260, 1976.

15. Milgrom F, Witebsky E: Autoantibodies and autoimmune disease. *JAMA* 181:706-716, 1962.

Tumor Cell Characterization of Histiocytic Medullary Reticulosis

Bernard N. Robinowitz, MD; Shiro Noguchi, PhD; Wilma F. Bergfeld, MD

• Tumor cells from a 10-year-old boy with suspected histiocytic medullary reticulosis were examined and were found to have receptor sites for complement, the ability to phagocytize latex beads, and the electron microscopical picture of immature histiocytes. These findings strongly support the diagnosis of histiocytic medullary reticulosis. This disorder and the method of examination of the tumor cells are discussed.

(*Arch Dermatol* 113:927-929, 1977)

In 1939, Scott and Robb-Smith[1] described four cases of a rapidly fatal malignancy of histiocytes they called histiocytic medullary reticulosis (HMR). They also included six cases from the literature. Since that time, approximately 84 cases have been reported.[2] The clinical features of the disease include hepatosplenomegaly, lymphadenopathy, anemia, fever, pancytopenia, or leukocytosis; the median survival is less than six months. The histiocytic infiltrate in the liver and lymphoid system is characterized by erythrophagocytic histiocytes with cytologic atypia. Cline and Golde[3] reported that these histiocytes most closely resemble the immature type A macrophage and that HMR is likely to be a variant of well-differentiated reticulum cell sarcoma.

In this communication, we describe the electron microscopy of this tumor as well as the presence of receptor sites for complement on the tumor cell surface, and we report that isolated tumor cells phagocytize latex beads and have no detectable IgG on their cell surface.

PATIENTS AND METHODS

A 10-year-old boy was examined (M.J. Freeman et al, unpublished data), and the diagnosis was established by his clinical course and by examining hematoxylin-eosin-stained sections of material from splenectomy, lymph nodes, liver, and skin biopsy specimens.

A biopsy specimen for electron microscopy and cell function studies was obtained from a skin tumor on the knee. A portion of the biopsy specimen was placed in 5% gluteraldehyde for 24 hours, was postfixed in osmium tetroxide, was dehydrated in ethyl alcohol, and was embedded in epoxy resin. A 1-μ section was cut with a glass knife and was stained with paragon multiple stain. Suitable areas were chosen for electron microscopy, and thin sections were made with a diamond knife. The sections were stained with uranyl acetate followed by lead citrate and were examined by electron microscopy.

The remainder of the biopsy specimen was shredded in Hanks balanced salt solution (HBSS) with a scalpel blade. The cell suspension and tissue debris were separated by gravity (15 minutes), and the cells were washed. From this, 3 million cells were obtained. The percentage of the isolated tumor cells forming erythrocyte

Fig 1.—Skin tumor, atypical histiocytic infiltrate with mitotic figures consistent with histiocytic medullary reticulosis (hematoxylin-eosin, ×100).

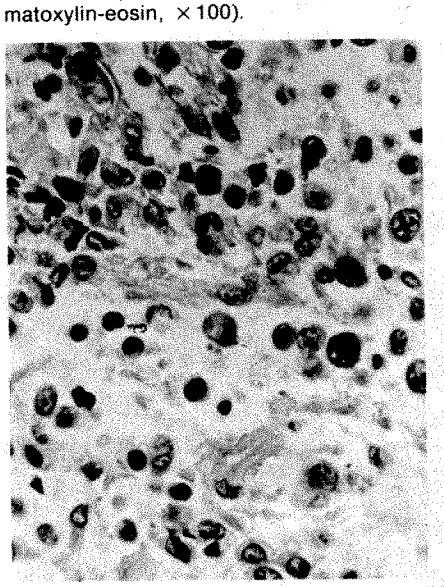

Accepted for publication Nov 24, 1976.

From the Departments of Dermatology (Drs Robinowitz and Bergfeld), Immunopathology (Dr Noguchi), and Pathology (Dr Bergfeld), Cleveland Clinic.

Reprint requests to Department of Dermatology, Cleveland Clinic, 9500 Euclid Ave, Cleveland, OH 44106 (Dr Bergfeld).

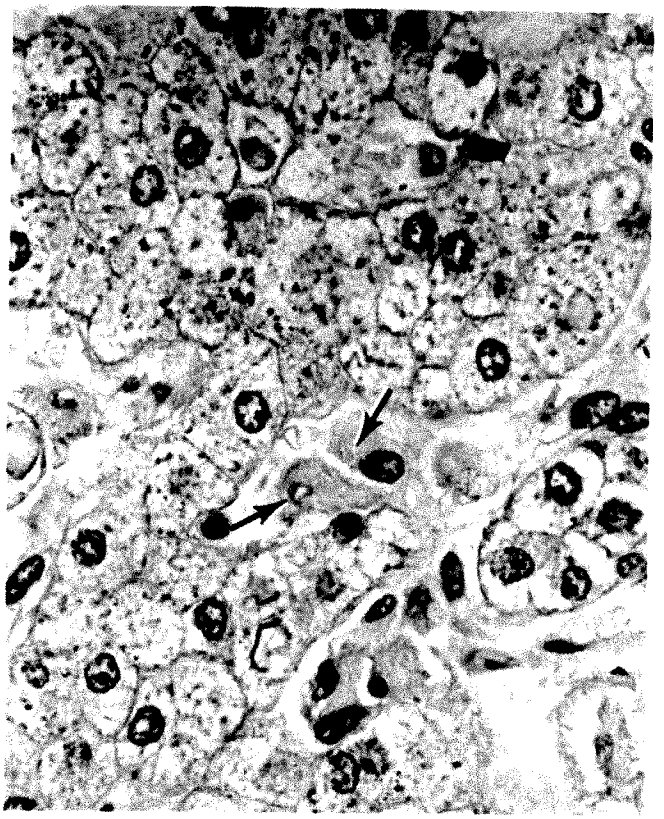

Fig 2.—Histiocytic erythrophagia, skin tumor histiocytic medullary reticulosis (arrows) (hematoxylin-eosin, ×200).

Fig 3.—Tumor cell and tissue (×21,200).

Fig 4.—Tumor cells forming erythrocyte antibody complement rosettes 30 minutes after incubation with latex beads. Note three ingested latex beads (×21,200).

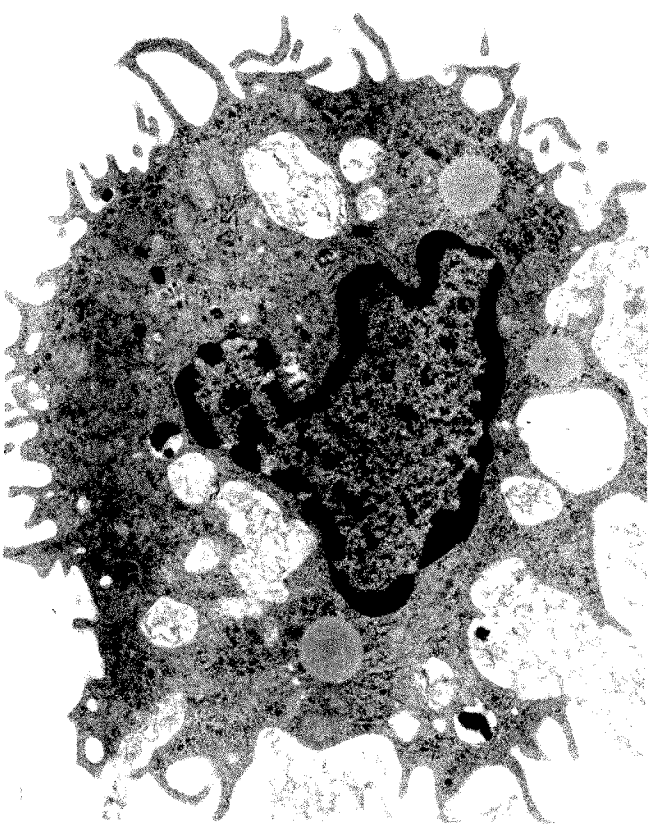

Fig 5.—Tumor cells forming erythrocyte antibody complement rosettes 30 minutes after incubation with latex beads. Note ingestion of tissue debris and latex beads (×14,300).

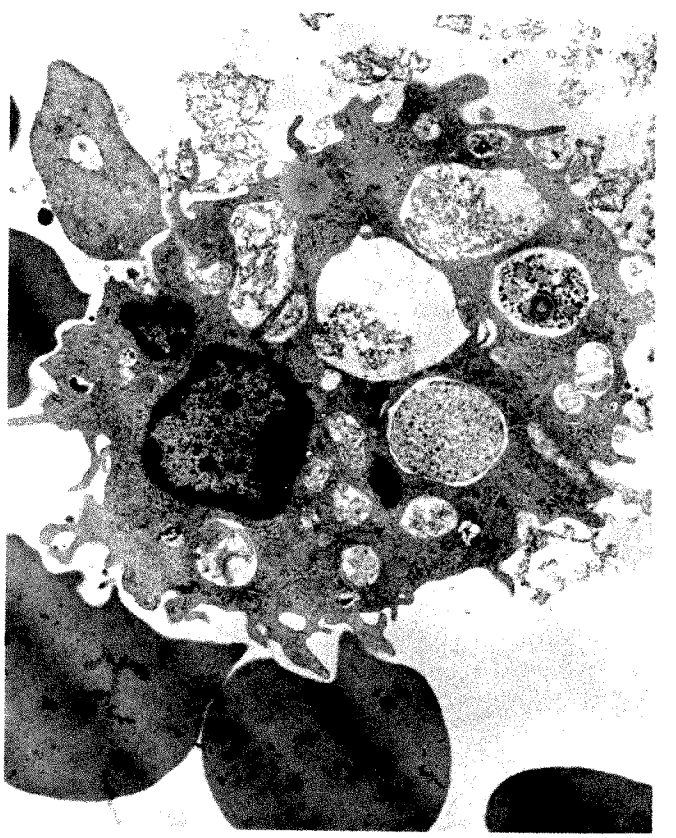

rosettes was determined by the method of Jondal et al,[4] and the percentage of tumor cells forming erythrocyte antibody complement (EAC) rosettes was determined by the method of Pincus et al.[5]

Phagocytosis was studied by adding 0.1 ml of a suspension of latex beads (0.81 μ) in HBSS to 1 ml (1 × 10 B cells per milliliter) tumor cells forming EAC rosettes, and then the mixture was incubated for 30 minutes at 37 C. After 30 minutes, these cells were placed in 5% gluteraldehyde for 24 hours. The cells were spun down to form a pellet and were stained, embedded, and examined as described for the tissue sections.

Tumor cell phagocytosis of latex beads (0.81 μ) was observed by adding a 0.1-ml suspension of the latex beads to 1 ml (1 × 10 B cells per milliliter) of tumor cells in HBSS, and the cells were observed under phase-contrast microscopy. The determination of tumor cells surface immunoglobulin was performed by staining with polyvalent antihuman immunoglobulins labeled with fluorescence.

RESULTS

By light microscopy, we noted that the ulcerated skin tumor (Fig 1) on the left knee was composed of large masses of normal and atypical histiocytes with focal areas of necrosis and acute and chronic inflammation. The atypical histiocytes displayed large pleomorphic vesicular nuclei with abnormal clamping of chromatin material. Within these nuclei were large nucleoli and an occasional mitotic figure. The nucleocytoplasmic ratio was approximately 1:1, and there were numerous large binucleated histiocytes. Serial sections of the tumor mass showed rare histiocytic erythrophagia within the skin tumor (Fig 2). This erythrophagia was also noted on multiple biopsy specimens of the visceral organs (M.T. Freeman et al, unpublished data).

By electron microscopy we noted that the tumor cells (Fig 3) were large histiocytes with a nucleocytoplasmic ratio of 1:1. The cytoplasm was that of an active cell with numerous ribosomes and polyribosomes and a variable amount of rough endoplasmic reticulum. The number of mitochondria within the cells also varied from few in some cells to many in others. The Golgi apparatus was well developed and was most commonly seen near the invaginated portion of the nucleus. Occasional vesicles, lysosomes, and vacuoles were noted in the cell's cytoplasm.

The shape of the nuclei varied from oval to half-moon. They commonly had one infolding and were without nuclear bridges or blebs. All nuclei had a large eccentrically placed nucleolus and a large amount of euchromatin with a rim of heterochromatin just beneath the nuclear membrane. Multiple nuclei were noted within some cells.

Sixty percent of the tumor cells formed spontaneous rosettes with EAC. No erythrocyte rosettes were formed. By electron microscopy, the tumor cells forming EAC rosettes were noted to have ingested latex beads (Fig 4 and 5), and large amounts of tissue debris were present in the tumor cell suspension. The tumor cells were filled with vacuoles, and lysosomes were filled with this tissue debris.

With the phase-contrast microscope, the isolated tumor cells were noted to be actively phagocytizing latex beads after 30 minutes of incubation at 37 C. No surface IgG was detected on the tumor cell surface.

COMMENT

The biopsy sections of the ulcerated skin tumor showed malignant histiocytosis with histiocytic erythrophagia. These findings were diagnostic of HMR. Again, similar findings of histiocytic erythrophagia were seen in the samples of tissue from lymph nodes, spleen, liver, and bone marrow.

On electron microscopy the HMR tumor cells appeared to be immature histiocytes. The nuclei appeared pleomorphic, and they had a large abnormal nucleolus that was suggestive of malignancy. The tumor cells appeared to be metabolically active, with numerous mitochondria, polyribosomes, and rough endoplasmic reticulum. These cells resembled the type 3 reticulum cell sarcoma described by Mori and Lennert,[6] differing only in having more lipid-filled vacuoles than reticulum cell sarcoma cells.

The description of erythrophagocytosis of the cells of HMR and the previous description of starch phagocytosis by giant peripheral blood histiocytes in a case of HMR prompted our study of tumor cell phagocytosis. The isolated tumor cells were noted to phagocytize latex beads actively and were shown to be actively phagocytizing tissue debris. The debris was surrounded by pseudopod projections of the histiocytes, forming a membrane-limited intracytoplasmic vacuole. The phagocytic ability of these tumor cells indicated that functionally HMR belongs to the macrophage line, and in accordance with the hypothesis of Cline and Golde,[3] the HMR appears to be a tumor of well-differentiated, tissue-fixed macrophagia (histiocyte).

Macrophages have a receptor on their surface membranes for complement.[7] We have demonstrated that the HMR cell has retained its complement receptor, thus, strengthening the view that HMR is a histiocytic tumor.

Finally, description of a complement receptor on the HMR cell surface suggests that in HMR, antibody-coated RBCs and complement are involved, possibly in erythrophagocytosis.

References

1. Scott RB, Robb-Smith AHT: Histiocytic medullary reticulosis. *Lancet* 2:194-198, 1939.
2. Abele DC, Griffin TB: Histiocytic medullary reticulosis: Report of two cases and review of the literature. *Arch Dermatol* 106:319-329, 1972.
3. Cline MJ, Golde DW: A review and reevaluation of the histiocytic disorders. *Am J Med* 55:49-60, 1973.
4. Jondal M, Holm G, Wigzell H: Surface markers on human T and B lymphocytes: A large population of lymphocytes forming nonimmune rosettes with sheep red blood cells. *J Exp Med* 136:207-215, 1972.
5. Pincus S, Bianco C, Nussenzweig V: Increased proportion of complement-receptor lymphocytes in the peripheral blood of patients with chronic lymphocytic leukemia. *Blood* 40:303-310, 1972.
6. Mori Y, Lennert K: *Electron Microscopic Atlas of Lymph Node Cytology and Pathology.* New York, Springer-Verlag, 1969, pp 32-33.
7. Griffin FM Jr, Bianco C, Silverstein SC: Characterization of the macrophage receptor for complement and demonstration of its functional independence from the receptor for the Fc portion of immunoglobulin G. *J Exp Med* 141:1269-1277, 1975.

Mycophenolic Acid in the Treatment of Psoriasis

Long-Term Administration

Rosalie Marinari, MD; Raul Fleischmajer, MD; Alan H. Schragger, MD; Albert L. Rosenthal, MD

• **Thirty five patients with psoriasis (plaque type 26, guttate 3, pustular 4, and erythrodermic 2) were treated with oral mycophenolic acid for a period ranging from 52 to 104 weeks. The average follow-up was 89 weeks, and the dose schedule ranged from 2,400 to 7,200 mg daily. Excellent response was noted in 20 patients, good in 13 patients, and poor in 2. The most common clinical side effects were in the gastrointestinal tract, namely, diarrhea, nausea, abdominal cramps, and soft stools. A high incidence of herpes simplex, herpes zoster, and a flu-like syndrome was noted. Laboratory abnormalities consisted of mild blood hemoglobin reduction, one case of leukopenia (3,900 WBCs per cubic millimeter), two cases with thrombocytopenia and mild elevation of alkaline phosphatase. Mycophenolic acid appears as a promising drug for the treatment of severe psoriasis.**

(*Arch Dermatol* 113:930-932, 1977)

The use of antimetabolites in the treatment of severe, recalcitrant psoriasis or psoriasis associated with psoriatic arthritis is well documented in the literature. Since Gubner[1] described the use of aminopterin sodium in psoriasis in 1951, several new chemotherapeutic agents have been suggested or tried in the treatment of this disease. Methotrexate[2] gradually replaced aminopterin as the folic acid antagonist used in psoriasis. Azaribine[3] was tried as early as 1964 in psoriasis, but due to serious side effects, it was removed from the market in 1976. Hydroxyurea,[4,5] was introduced around 1970 and Stein et al[6] found it particularly effective for the treatment of pustular psoriasis.

The limiting factor in the use of any of the above drugs in psoriasis is their significant systemic toxicity. This includes adverse reactions on the gastrointestinal, hematologic, and central nervous systems. There have been reports of fatalities. Thus, the search for new antimetabolites where safety parallels efficacy has continued.

The rationale for the use of metabolic inhibitors in the hyperplastic state of psoriasis is well documented.[7] Mycophenolic acid is an antimetabolite that interfers with the synthesis of purine precursors of RNA and DNA. It probably blocks the reaction of inosine-5-monophosphate to xanthosine-5-monophosphate to guanosine-5-monophosphate.[8]

Mycophenolic acid is rapidly glucuronized in the liver after oral administration and is excreted by the kidney within 24 hours.[9] Only those cells that contain the enzyme glucuronidase appear to be susceptible to the inhibitory effects of the drug (Fig 1). Early tissue culture studies have shown that while free mycophenolic acid inhibits mitosis, glucuronized mycophenolic acid does not since it cannot penetrate cell membranes.[8] Thus, tissues such as the epidermis, the epithelial linings of the gastrointestinal and urinary tracts and certain tumors are susceptible to the antiproliferative effect of mycophenolic acid.[10]

Jones et al[11] have recently reported the results of their preliminary 12 week efficacy studies and double blind crossover studies are now in progress. The purpose of our report is to present toxicity and efficacy data on a two-year study with oral mycophenolic acid in the treatment of psoriasis.

SUBJECTS AND METHODS

Thirty-five patients, 13 females and 22 males, with severe psoriasis (Fig 2), resistent to conventional topical modalities were treated with oral mycophenolic acid after giving informed consent. The patients ranged in age from 15 to 75 with a mean age of 44 years. The average duration of their disease was 18½ years, and 21 patients had been treated previously with methotrexate; some for as long as nine years. All therapy given for systemic effect was stopped at least one month prior to treatment with mycophenolic acid. Twenty-six patients had the plaque type of psoriasis, three had guttate psoriasis, four

Accepted for publication Dec 27, 1976.

From the Division of Dermatology, Department of Medicine, Hahnemann Medical College and Hospital, Philadelphia.

Reprint requests to 245 N 15th St, Philadelphia, PA 19102 (Dr Fleischmajer).

pustular psoriasis, and two, erythrodermas. Mycophenolic acid was dispensed in 400 mg capsules, and the dosage schedule varied from 2,400 to 7,200 mg daily, divided into equal amounts given every 8 or 12 hours. The dose was adjusted for every patient according to clinical response and toxicity. With high doses, almost all patients experienced adverse reactions, primarily diarrhea, but these side effects could be reversed by either stopping or lowering the dose of the drug. Many patients developed tolerance to the drug and were able to continue treatment at higher dosage schedules. The maintenance dose was about 4,000 mg daily.

The scoring of the severity of involvement was based on the percentage of body involved and on severity scores. Before treatment and at each successive visit, patients received a score on severity of erythema, scaling, and skin induration. Each of these factors were graded from 0 to 6 (0 indicates absent; 1, trace; 2, mild; 3, mild to moderate; 4, moderate; 5, moderate to severe; and 6, severe). The "total" severity score was the sum of the scores of three individual involved areas. Prior to treatment, the mean severity score was 62 (range 33 to 80), and the mean extent of body area involved was 36% (range 4 to 97).

These factors were followed and recorded for each patient at weekly intervals for eight weeks, biweekly for eight weeks, and monthly thereafter. Follow-up time ranged from 52 to 104 weeks, with an average of 89 weeks.

The following laboratory studies were performed on each patient visit: 12-factor automated blood chemical analysis (calcium, inorganic phosphorus, glucose, BUN, uric acid, cholesterol, total protein, albumin, total bilirubin, alkaline phosphatase, lactic dehydrogenase, SGOT), complete blood cell count, platelet count, and urinalysis. A complete eye examination was performed prior to treatment and at 28 and 52 weeks. Male subjects submitted semen analysis periodically during the first 16-week treatment period.

On each visit, patients were questioned about adverse reactions from a checklist, and the severity and duration of these adverse reactions were recorded.

RESULTS

The therapeutic response was as follows: complete clearing, 20; definite improvement except for mild residual erythema and/or small patches of activity, 13; and slight or no improvement, 2 (Fig 3). Symptomatic relief of pruritus was noted in the first two weeks of therapy, however, significant objective improvement of the lesions occurred at six to eight weeks with maximum effect usually by 12 weeks. Table 1 summarizes the data on response to therapy as measured by severity scores and percentage of body involved. The severity at 89 weeks is slightly higher than that at 52 weeks, which reflects some resistance to the drug following its prolonged administration.

The major clinical adverse reactions are listed in Table 2. Soft and frequent bowel movements, diarrhea sometimes associated with cramps, or rectal tenderness were the most common complaints. The frequency and severity of diarrhea was dose dependent and usually occurred in those patients receiving 3,600 to 4,800 mg daily. The onset of the diarrhea took place during the first through third week after initiation of treatment and usually consisted of four to five daily

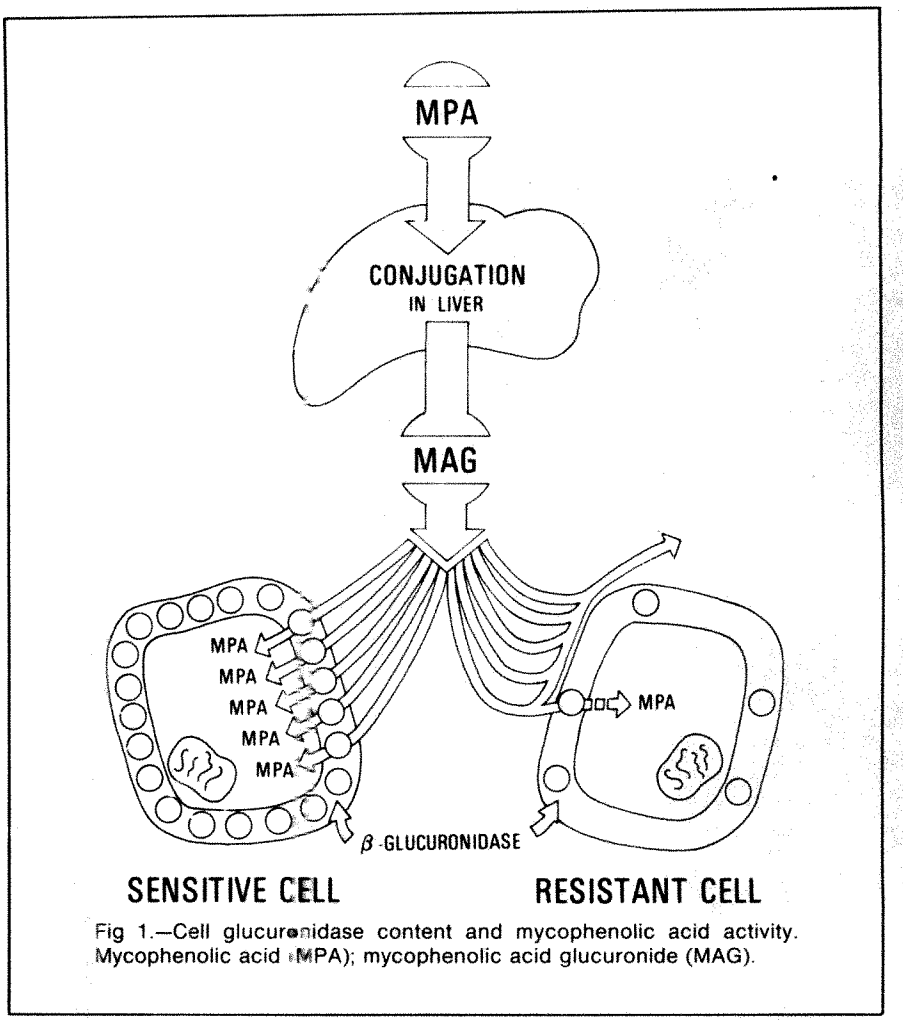

Fig 1.—Cell glucuronidase content and mycophenolic acid activity. Mycophenolic acid (MPA); mycophenolic acid glucuronide (MAG).

Fig 2.—Psoriasis vulgaris before treatment.

Fig 3.—Psoriasis vulgaris two months after treatment with mycophenolic acid.



Table 1.—Response to Mycophenolic Acid Therapy

	% Body Involvement	Severity Score
Before treatment	36.90*	62.20*
After 52 weeks	12.13 ± 2.89†	13.60 ± 2.51
After 89 weeks	11.48 ± 2.91	15.74 ± 2.92

*Mean of 35 cases.
†Standard error of the mean.

Table 2.—Adverse Reactions to Mycophenolic Acid (35 Cases)

	No.	%
Soft stools*	21	60
Diarrhea	19	54
Flu-like syndrome	17	48
Cramps	16	46
Nausea	15	43
Weakness	12	34
Insomnia	12	34
Anal tenderness	11	31
Herpes simplex	9	26
Vomiting	7	20
Anorexia	7	20
Dysuria	7	20
Herpes zoster	2	5.7

*Two to four bowel movements per day throughout entire treatment.

Table 3.—Laboratory Data

	Mycophenolic Acid		
	Start	End	% Change
Bilirubin, mg/100ml	0.48*	0.54*	+12.50
Alkaline phosphatase, units/100ml	68.53	66.55	−2.89
Lactic dehydrogenase, units	168.50	143.60	−14.78
SGOT, units	29.47	26.76	−9.20
Hemoglobin, gm/100ml	14.20	13.22	−6.90
WBCs, /cu mm	8,006	6,785	−15.25
Platelets, /cu mm	323,100	281,400	−12.91

*Mean of 35 cases.

bowel movements. All patients were advised that if diarrhea occurred and persisted for more than 24 hours, they should discontinue the drug for 48 hours, by which time the diarrhea usually was controlled. Then, they were placed on a lower dose schedule. We had one patient who developed diarrhea at a dosage of 3,600 mg/day. This patient continued mycophenolic acid therapy in spite of her diarrhea for five days at which time the diarrhea became bloody. The mycophenolic acid was discontinued. The patient was hospitalized and treated with fluid replacement, and no transfusions were found necessary. The sigmoidoscopy was interpreted as a "toxic colitis." At present, this patient is on mycophenolic acid therapy and doing well at a dose of 4,800 mg/day. At high dosage levels, some patients complained of a "weak, tired feeling," but as the drug was continued, these symptoms disappeared. Insomnia was not an infrequent complaint especially if a large dose was taken before retiring.

We had two cases with herpes zoster and nine patients with herpes simplex. In each patient, the viral infection ran a normal course, with complete recovery. Seventeen patients complained of a flu-like syndrome (about two episodes per patient) usually associated with a low grade fever, malaise, and myalgias, a nonproductive cough, and sometimes diarrhea that would last seven to ten days. The flu-like syndrome occurred after six months of therapy and only during the winter season. The high incidence of viral infections raises the question about the effect of mycophenolic acid on delayed hypersensitivity and immunity.

Routine laboratory studies performed revealed no significant abnormalities (Table 3). A reduction in hemoglobin of 1 to 2 gm/100 ml was noted in 13 patients, but none became frankly or symptomatically anemic. A mild leukopenia was seen in one patient (WBC, 3,900/cu mm), and two patients developed a thrombocytopenia (110,000 and 120,000 platelets/cu mm). A mild increase in alkaline phosphatase was noted in four patients. Jones et al[11] reported one case of leukopenia (WBC, 1,200/cu mm) and two cases of thrombocytopenia (66,000 and 90,000 platelets per cubic millimeter), in which all values promptly returned to normal when mycophenolic acid was discontinued and we had a similar experience.

COMMENT

Mycophenolic acid appears to be a safe and effective modality for the treatment of severe, recalcitrant psoriasis in its various clinical forms. The treatment regimen is a continuous one since once the drug is stopped, a relapse takes place within one to four weeks. The most common side effect is in the gastrointestinal tract and is dose related. Interestingly, many patients will develop a tolerance to this adverse reaction and then be able to maintain higher doses without problems.

Increased susceptibility to viral infections with mycophenolic acid is of interest since such a side effect was not reported with other antimetabolites used in the treatment of psoriasis. There does not appear to be any significant liver or kidney toxicity. However, studies are in progress where liver biopsies were performed before and during treatment.

This study suggests that because of its safety and efficacy, mycophenolic acid represents an encouraging alternative in the chemotherapy of severe, recalcitrant psoriasis.

Nonproprietary Names and Trademarks of Drugs

Azaribine—*Triazure.*
Hydroxyurea—*Hydrea.*

References

1. Gubner R: Effect of "aminopterin" on epithelial tissue. *Arch Dermatol* 64:688-699, 1951.
2. Rees RB, Bennett JH: Methotrexate vs aminopterin. *Arch Dermatol* 83:970-972, 1961.
3. Turner RW, Calabresi P: The effect of triacetyl azauridine on psoriasis. *J Invest Dermatol* 43:551-557, 1964.
4. Yarbro J: Hydroxyurea in psoriasis. *Lancet* 2:846-847, 1969.
5. Leavell U, Yarbro J: Hydroxyurea—a new treatment for psoriasis. *Arch Dermatol* 102:144-150, 1970.
6. Stein KM, Shelley WB, Weinberg RA: Hydroxyurea in the treatment of pustular psoriasis. *Br J Dermatol* 85:81-85, 1971.
7. Van Scott EJ, Ekel T: Kinetics of hyperplasia in psoriasis. *Arch Dermatol* 88:373-381, 1963.
8. Sweeney MJ, Hoffman DH, Esterman MA: Metabolism and biochemistry of mycophenolic acid. *Cancer Res* 32:1803-1809, 1972.
9. Lintrup J, Hyltoft-Peterson P, Knudtzons, et al: Metabolic studies in man with mycophenolic acid (NSC-129185), a new antitumor agent. *Cancer Chemother Rep* 56:229-235, 1972.
10. Mesirow SH, Stoughton RB: Demonstration of beta-glucuronidase in human skin. *J Invest Dermatol* 23:315-316, 1954.
11. Jones EL, Epinette WW, Hackney VC, et al: Treatment of psoriasis with oral mycophenolic acid. *J Invest Dermatol* 65:537-542, 1975.

Primary Cutaneous Coccidioidomycosis

A Review of the Literature and a Report of a New Case

Gary F. Carroll, MD; Leanor D. Haley, PhD; June M. Brown

• A 31-year-old woman working in the laboratory with the mycelial phase of *Coccidioides immitis* developed a firm, raised, erythematous lesion on the left index finger. A biopsy specimen of the lesion grew a white mold that proved to be *C immitis*.

A sinus tract communicating with the lesion and extending into the proximal phalanx developed. The expressed pus was positive for the tissue form of *C immitis* by potassium hydroxide and periodic acid-Schiff stains and fluorescent-antibody techniques. The sinus tract was irrigated with an aqueous solution of amphotericin B (Fungizone). The tract closed and the lesion decreased in size. Healing was completed in ten weeks.

Primary cutaneous disease must be distinguished from disseminated disease with cutaneous manifestations. In the majority of cases, primary disease heals spontaneously whereas disseminated disease usually requires systemic treatment with amphotericin B.

(*Arch Dermatol* 113:933-936, 1977)

Accepted for publication March 18, 1976.

From the Department of Health, Education, and Welfare, Public Health Service, Center for Disease Control, Atlanta.

Reprint requests to Department of Medicine, Infectious Diseases Section, Louisiana State University Medical Center, 1542 Tulane Ave, New Orleans, LA 70112 (Dr Carroll).

Before 1937 many authorities held that the majority of cases of systemic coccidioidomycosis resulted from direct inoculation of the skin with *Coccidioides immitis*, which produced localized cutaneous lesions and later spread via blood and lymph system to the viscera. This opinion was accepted because the first clinical lesion was frequently located on the skin, often at a site of recent trauma. In 1937 Dickerson,[1] and in 1938 Dickerson and Gifford,[2] outlined the natural history and pathogenesis of the disease. They demonstrated conclusively that the respiratory tract was the usual port of entry and that cutaneous lesions were, with few exceptions, the result of dissemination from a primary pulmonary focus. These authors also pointed out that most primary cases either escaped clinical recognition or were benign and associated with spontaneous recovery, permanent specific immunity, and lasting skin sensitivity.

Primary cutaneous coccidioidomycosis does occur, but it is rare. To our knowledge, only 17 authentic cases have been reported, all between 1926 and 1965.

Reports of the two earliest cases[3,4] were published before the work of Dickerson and Gifford and were not well documented in terms of present laboratory sophistication; nevertheless, the data seem to warrant the interpretation of the disease as cutaneous in origin.

In 1952 Curtis[5] briefly described a case that was later reported in considerable detail by Harrell and Honeycutt[6] in a review of 12 cases of coccidioidomycosis.

In 1953 Wilson et al[7] reviewed the clinical, pathologic, and serologic characteristics of primary cutaneous coccidioidomycosis and reported a new case of their own. To clearly distinguish primary cutaneous infection from disseminated disease with cutaneous manifestations, they formulated criteria that should be met before determining that the skin was the port of entry in a particular case. The most helpful of these criteria are listed as follows.

1. No history of significant pulmonary disease immediately preceding the appearance of the lesion.
2. History suggestive of inoculation through a break in the skin at the site of the first clinical lesion.
3. Short incubation period between inoculation and lesion—one to three weeks.
4. Lesion should resemble a chancre—a relatively painless, firmly indurated nodule with central ulceration—rather than an abscess.
5. Lymphangitis and lymphadenopathy should develop but only in the region of drainage.
6. Precipitins to coccidioidin should develop; complement-fixing antibodies

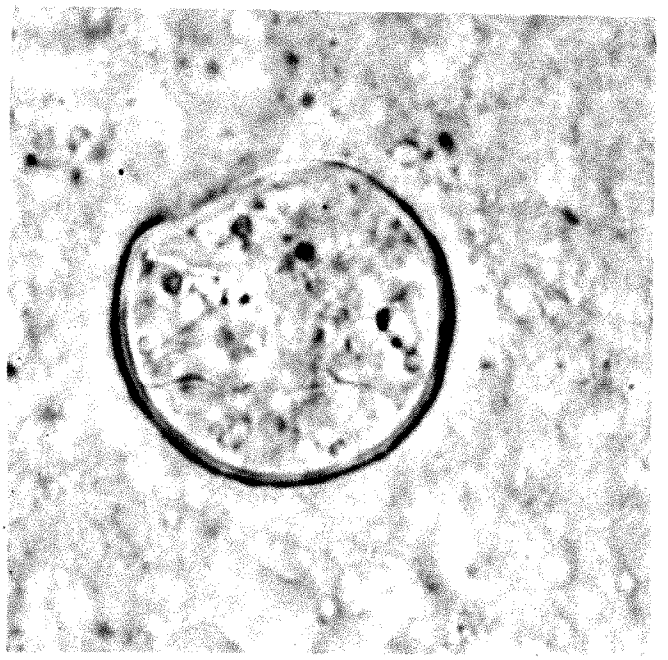

Fig 1.—Material expressed from sinus tract extending into proximal phalanx, left index finger. Note lone mature spherule filled with endospores (potassium hydroxide, original magnification ×1,000).

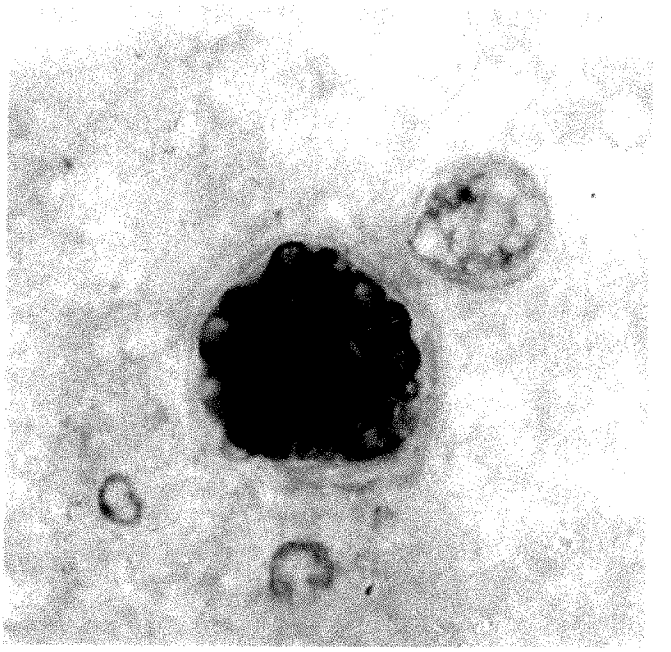

Fig 2.—Same material as in Fig 1. Note immature and mature spherules with endospores (periodic acid-Schiff stain, original magnification ×1,000).

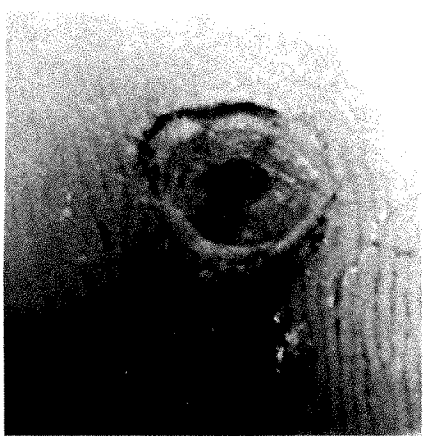

Fig 3.—Left index finger immediately after eschar removal. Sinus tract opens in center of lesion at proximal interphalangeal joint, with edema of proximal phalanx.

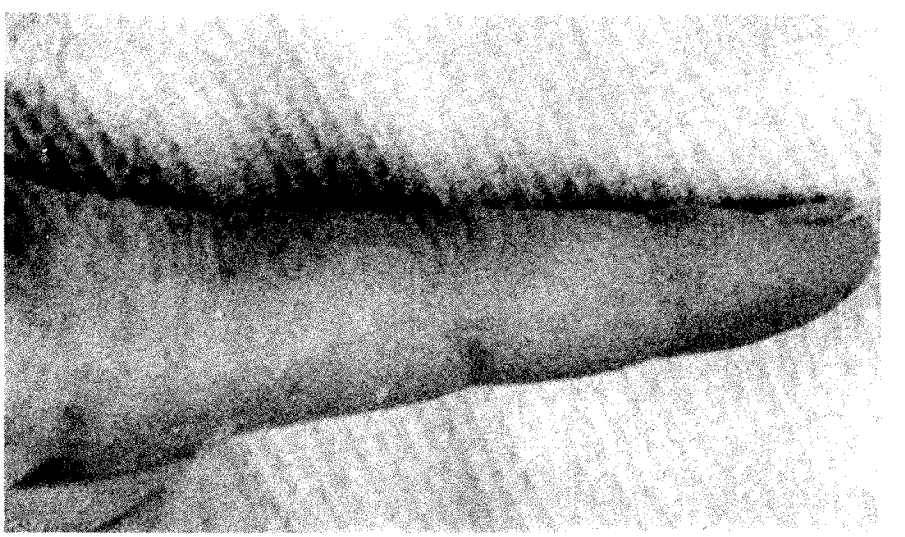

Fig 4.—Left index finger ten weeks after onset of illness. Note reduced edema at proximal phalanx, closure of sinus tract, and healing of lesion.

should be absent or present only in low titer.

7. Response to intracutaneous coccidioidin should convert from negative to positive and increase in reactivity.

Two cases of primary cutaneous disease in laboratory workers were reported in 1956 and 1959 by Trimble and Douchette[8] and Wright et al,[9] respectively. In 1961 Tiggert[10] described a case of laboratory infection in a previously immune individual, and in 1964 Sorensen and Cheu[11] reported a similar case. In 1964 Overholt and Hornick[12] reported three cases, all in laboratory workers, one of whom possessed previously acquired immunity.

In 1963 Goodman and Shabarum[13] reported a case of primary cutaneous disease in a black farm worker in Maricopa County, Ariz. Levan and Huntington[14] in 1965 described two cases in Filipino agricultural workers in the vineyards of the San Joaquin Valley, Calif. Also in 1965 Winn[15] reported primary cutaneous disease in three children, who were residents of the endemic California area.

Of these 17 cases of primary cutaneous coccidioidomycosis, 15 remained localized and 2 underwent dissemination.[3,15] The first of these dissemi-

Table 1.—Results of Intradermal Tests With Coccidioidin During Illness

Weeks After Onset of Illness	Antigen Dilution 1:100	1:10
2	0	NT
5	0	NT
7	+	NT
10	+	+ + + +
12	0	NT
14	0	NT
18	0	NT

*Thirty-six and fourty-eight-hour reading reactions: zone of induration < 5 mm indicated by 0; 5.0 to 7.5 mm, +; > 12.5 mm, + + + +; and test not done, NT.

Table 2.—Results of Serologic Tests for Antibodies to *Coccidioides immitis*

Test	Weeks After Onset of Illness 2	4	6	12	15	18
Latex agglutination	+	+	0	0	0	0
Precipitins	0	0	0	0	0	0
Complement fixation	0	0	0	0	0	0

nated infections occurred in 1926, long before the development of specific therapy. The second patient, reported in 1965, was treated with systemic amphotericin B. Both patients recovered. A third patient,[11] a Filipino farm worker, received intravenously given amphotericin B in the absence of dissemination because of the greater risk of this type of infection in Filipinos than in the general population.

In this article, we report a new case of primary cutaneous coccidioidomycosis acquired in the laboratory.

REPORT OF A CASE

A 31-year-old white woman, a graduate student, assisted in the inoculation of mice with a mycelial suspension of *C immitis* on Nov 15, 1974. On Nov 22, she performed autopsies on these mice, removing the liver and spleen, and made homogenates of these organs with Ten Broeck homogenizers. She does not recall any overt trauma either immediately preceding or during these procedures, and there was no contamination of the area by spillage.

She vaguely recalls acquiring a small splinter somewhere on her hands on or around Dec 16 while entering a cold room where media were stored. She does not recall the exact location of the splinter; she immediately removed it, and the lesion apparently healed without a trace.

On Dec 23 she first noted a raised lesion on the left index finger. It increased in size over a week's time, and she first sought medical advice on Dec 30.

There was no history of fever, malaise, or recent respiratory symptomatology. Past history was unremarkable. She had not lived or traveled in any of the southwestern states endemic for coccidioidomycosis or in Latin America. The coccidioidin skin test result had been negative in August 1974.

Examination on Dec 30 revealed a firm, raised, erythematous lesion on the lateral aspect of the left index finger overlying the proximal interphalangeal joint. There was mild erythema and edema of the proximal phalanx but no lymphangitis or lymphadenopathy.

On the following day, an excisional biopsy was performed, and tissue was submitted for histopathology and culture. Histopathologic examination demonstrated chronic inflammatory reaction; fungal cells were not noted with special stains. The homogenized specimen grew a pure culture of white mold that did not manifest the typical sporulation of *C immitis*. The tissues of the mice and guinea pigs inoculated with a suspension of this culture contained, at autopsy, spherules characteristic of *C immitis*.

On Jan 6, 1975 the proximal phalanx was noted to have increased in erythema, edema, and tenderness, and therefore, the eschar that had formed over the biopsy site was removed and pus was expressed from a sinus tract that extended into the proximal phalanx. This material was positive for the tissue form of *C immitis* by potassium hydroxide and periodic acid-Schiff stains and fluorescent-antibody techniques (Fig. 1 and 2).

A chest roentgenogram, complete blood count, and erythrocyte sedimentation rate were within normal limits. Roentgenograms of the left hand were unremarkable, except for soft tissue swelling of the index finger. Figure 3 shows the appearance of the lesion immediately after the eschar was removed. Results of skin tests and serologic evaluations throughout the course of illness are shown in Tables 1 and 2.

On Jan 9 the sinus tract was cannulated with a 21-gauge blunt needle through the opening at the proximal interphalangeal joint and irrigated with 10 ml of an aqueous solution of amphotericin B (Fungisone), containing 2 mg/ml.

The finger remained edematous, with minimal tenderness, for the next two to three weeks. At various times during this period, small (2 to 4 mm), erythematous, evanescent nodules of considerable tenderness suddenly appeared around the opening of the sinus tract. They persisted for a day or two, then disappeared as rapidly as they had appeared. At no time did the patient develop lymphangitis or lymphadenopathy, and repeated roentgenograms of the chest and left hand remained unremarkable.

With closure of the sinus tract, erythema and edema gradually subsided throughout the next four to six weeks. The finger appeared as shown in Fig 4 (taken ten weeks after the onset of illness).

COMMENT

In considering cutaneous lesions due to *C immitis*, the best policy is to assume that, unless there is convincing evidence to the contrary, such lesions are associated with disseminated disease. Extrapulmonic lesions are, in almost all cases, the result of dissemination from a primary pulmonary focus. This focus may be so insignificant that it is not detectable on roentgenographic examination, or it may have already healed by the time the disease had disseminated.

The ability to distinguish primary cutaneous disease from cutaneous lesions associated with disseminated disease is essential in management. The great majority of patients with primary disease note healing to be spontaneous without treatment, although local therapy is occasionally applied. However, even these local measurements are usually not necessary. Disseminated disease, on the other hand, usually requires immediate systemic treatment with amphotericin B.

As Wilson et al[7] and other authors[13] emphasized, primary cutaneous disease has similarities with primary pulmonary disease and differs from disease manifested by cutaneous lesions associated with dissemination in two important features: skin sensitivity and serologic response.

In primary disease (pulmonary or cutaneous), skin sensitivity to intracutaneous injection of coccidioidin usually converts from negative to

positive in the first few weeks after infection and should increase in reactivity unless immunity does not develop. On the other hand, disseminated cutaneous lesions are more often associated with decreasing or absent skin reactivity. Thus, a patient with cutaneous lesions due to *C immitis* and persistently negative skin test results is probably suffering from disseminated disease.

In general, serologic studies are most helpful in distinguishing primary disease from disseminated disease. The latex agglutination and precipitin tests[16] are useful in detecting IgM antibodies that appear early in the disease process.[17] Latex agglutination shows positive results one to two weeks after primary infection, persists two to four weeks, and becomes negative. Precipitins appear in the third to sixth week of illness, may remain positive in high titer for 6 to 8 weeks, and are absent by 12 to 16 weeks. On the other hand, complement-fixing antibodies are of the IgG type,[17] appearing in the eighth to tenth week of illness and increasing in titer as disease progresses. In general, the magnitude of the complement-fixation titer is related to the severity of the infection, the amount of tissue involved, and the gravity of the prognosis. With the exception of coccidioidal meningitis, serum complement-fixation titers greater than 1:16 often indicate extensively disseminated disease.

Thus, the serum of a patient in the early stages of primary disease (pulmonary or cutaneous) would be expected to be positive by latex agglutination and precipitin test results. The complement-fixation test usually demonstrates negative findings; occasionally they may be positive, but only in titers less than 1:16. In contrast, the serum of a patient with cutaneous lesions associated with disseminated disease would lack latex-agglutinating and precipitating antibodies but should demonstrate high-titered fixation of complement.

We believe that our patient represents an indisputable case of primary cutaneous coccidioidomycosis. This patient had direct contact with *C immitis*, and although no history of accidental self-inoculation can be obtained, there was ample opportunity, especially during autopsy of the mice, for this to occur. The incubation period is compatible with and the appearance of the lesion is typical of primary cutaneous disease. Results of serologic studies and intracutaneous tests are compatible with primary rather than disseminated disease. Failure to develop constitutional symptomatology and lymphangitis or localized lymphadenopathy, or both, and to demonstrate precipitins and increasing skin sensitivity is perhaps related to the immediate and aggressive surgical and local chemotherapeutic intervention.

Leo Kaufman, PhD, directed the serologic tests performed in this study.

References

1. Dickerson EC: Coccidioides infection: Part I. *Arch Intern Med* 59:1029-1052, 1937.
2. Dickerson EC, Gifford M: Coccidioides infection: Part II. *Arch Intern Med* 62:853-871, 1938.
3. Guy WH, Jacob FM: Granuloma coccidioides. *Arch Dermatol Syphilol* 16:308-311, 1927.
4. Imerman SW, Imerman CP: Granuloma coccidioides, primary cutaneous lesion: Treatment with the actual cautery: Report of a case. *Southwest Med* 17:18-21, 1933.
5. Curtis AC: Coccidioidomycosis, primary inoculation. *Arch Dermatol Syphilol* 65:365-366, 1952.
6. Harrell ER, Honeycutt WM: Coccidioidomycosis: A traveling fungus disease. *Arch Dermatol* 87:98-106, 1963.
7. Wilson JW, Smith CE, Plunkett OA: Primary cutaneous coccidioidomycosis: Criteria for diagnosis and report of a case. *Calif Med* 79:233-239, 1953.
8. Trimble JA, Douchette J: Primary cutaneous coccidioidomycosis. *Arch Dermatol* 74:405-410, 1956.
9. Wright ET, Newcomer VD, Nelson NH: Primary inoculation coccidioidomycosis. *Arch Dermatol* 79:118-120, 1959.
10. Smith CE, Pappagianis D, Levine HB, et al: Human coccidioidomycosis. *Bacteriol Rev* 25:314-315, 1961.
11. Sorensen RH, Cheu SH: Accidental cutaneous coccidioidal infection in an immune person. *Calif Med* 100:44-47, 1964.
12. Overholt EL, Hornick RB: Primary cutaneous coccidioidomycosis. *Arch Intern Med* 114:149-153, 1964.
13. Goodman DH, Shabarum B: Primary cutaneous coccidioidomycosis: Visible classic demonstration of delayed hypersensitivity. *Ann Intern Med* 59:84-90, 1963.
14. Levan NE, Huntington RW: Primary cutaneous coccidioidomycosis in agriculture workers. *Arch Dermatol* 92:215-220, 1965.
15. Winn WA: Primary cutaneous coccidioidomycosis: Reevaluation of its potentiality based on study of three new cases. *Arch Dermatol* 92:221-228, 1965.
16. Kaufman L: Serology: Its value in the diagnosis of coccidioidomycosis, cryptococcosis, and histoplasmosis. Proceedings-International Symposium on Mycoses. Scientific Publication, Pan American Health Organization 205:96-100, 1970.
17. Pappagianis D, Lindsey NJ, Smith CE, et al: Antibodies in human coccidioidomycosis: Immunoelectrophoretic properties. *Proc Soc Exp Biol Med* 118:118-122, 1965.

Tropical Rat Mite Dermatitis

Maj Ernest N. Charlesworth, MC, USAF, Capt Robert W. Clegern, BSC, USAF

• We had a patient with dermatitis caused by the bite of *Ornithonyssus bacoti* (Hirst), commonly referred to as the tropical rat mite. The bite of this mite resulted in a severely pruritic papular dermatitis in our patient. Accurate identification of the mite indicated the presence of rat infestation.

(*Arch Dermatol* 113:937-938, 1977)

Dermatologists are keenly aware of problems associated with mites, particularly when the preferred host is man, as is the case with *Sarcoptes scabiei* of the hominis variety. Man is also vulnerable to less frequently recognized forms of dermatitis caused by mites parasitic on various animals. A case report of a patient with an annoying dermatitis caused by the bites of the tropical rat mite, *Ornithonyssus bacoti* (Hirst), is presented.

Accepted for publication April 27, 1976.

From the Division of Dermatology, Department of Medicine, Wilford Hall USAF Medical Center (Dr Charlesworth); and the Entomology Section of the USAF School of Aerospace Medicine (Dr Clegern), Brooks Air Force Base, San Antonio, Tex. Dr Charlesworth is now with the Dermatology Service, Keesler Air Force Base, Biloxi, Miss.

The opinions expressed herein are those of the authors and do not necessarily represent the views of the USAF or the Department of Defense.

Reprints not available.

REPORT OF A CASE

A 69-year-old woman came to the dermatology clinic complaining of a pruritic dermatitis of four weeks' duration. This pruritic eruption was temporarily associated with her becoming aware of an infestation of small "bugs" throughout her house. She related that they seemed to be more numerous in the vicinity of her bedroom windowsill and in an adjacent bathroom. She first became aware of this infestation when placing bird food on an outer windowsill, sustaining an uncomfortable bite from a small "bug" on several occasions.

On physical examination, the patient showed discrete papules scattered over her breasts, shoulders, and arms (Fig 1 and 2). The primary lesion consisted of a 1- to 2-mm papule with a 2-mm halo of erythema. No central punctum, vesicle, pustule, or an associated urticarial component was noted in any of her lesions. There were neither excoriations nor burrows noted. The papules were more numerous in the area where the brassiere made tightest contact with the skin. The remainder of the physical examination was unremarkable.

Treatment of the patient was directed toward symptomatic relief with the application of 0.5% camphor in a hydrophilic lotion. In addition, she was given 10 mg of hydroxyzine hydrochloride every six hours as needed for pruritus. This treatment gave her good relief of the pruritus but did not prevent the development of new lesions.

Specimens the patient collected from her body two days prior to coming to the clinic were still motile. Preliminary microscopic examination disclosed a mite with morphologic characteristics similar to a bird mite, but similar also to other mites infesting other hosts. The mite was subsequently examined by the Agricultural Research Service, US Department of Agriculture; it was interpreted and identified as *O bacoti* or the tropical rat mite (Fig 3).

The patient was informed of the identification of the mite, and it was recommended that she have the house professionally exterminated for rats. She contracted a professional exterminator who confirmed the presence of rat nests in the attic. Within one month after the house was exterminated, she noted no further problem with either mites or a dermatitis.

COMMENT

The tropical rat mite, *O bacoti*, has been found as an ectoparasite on many rodents, but the brown Norway (*Rattus norvegicus*) and the black roof rat (*R rattus*) are the primary host species.[1] Although the mite relies on the rat for its blood meal, under certain circumstances, man may become a victim of the mite's bite. The first case report of *O bacoti* as a cause of human dermatitis was in 1913 in Australia.[2] Since recognition of the mite in this country in 1923 as a cause of dermatitis, there have been many reports from various countries.[3-12]

The mites are yellow to dark red,

Fig 1.—Papular eruption over breasts and inframammary region.

Fig 2.—Close-up view of several papules on erythematous base.





Fig 3.—Characteristic feature of tropical rat mite (×98).

depending on how recently the mite has fed. Both the male and female take their blood meals from the rodent as their preferred host. The female mite varies in size between 0.75 mm to 1.40 mm with the male somewhat smaller, and often they can be seen with the naked eye when crawling. The mite life cycle in the rat population has five stages: egg, larva, protonymph, deutonymph, and adult.[13-15] The larvae have three pairs of legs while the other stages have four pairs. The engorged female lays up to 100 eggs, which hatch into nonfeeding larvae. The larva then transforms into a protonymph, which requires a blood meal. The nonfeeding deutonymph follows, which subsequently develops into the adult form. The entire life cycle can take as little as 11 to 13 days under optimum conditions; however, the protonymph stage alone may survive to 43 days.[16] Engorged adult mites live an average of two weeks after feeding, but a few may survive eight or nine weeks.[17] It would thus appear that several weeks would have to elapse after rat extermination before the mite population would no longer pose a threat to humans.

Humans are usually bitten when the normal rat host is not available to the mite. This frequently occurs following rat extermination or some other cause of rat attrition. When the rat host is not available, *O bacoti* is capable of traveling several hundred feet in search of a blood meal. It is in this setting that man will most likely be bitten by the mite. The bite will induce a nonspecific dermatitis, usually consisting of small papules that tend to be more concentrated in areas covered by tight-fitting garments. The bite is frequently accompanied by mild pain at the site that precedes the pruritic dermatitis. Some patients may demonstrate an urticarial component to the dermatitis.[18] The lesions require no specific treatment and resolve when the rodent source of mites is eliminated. Because the character of the lesions is nonspecific, a differential diagnosis should include scabies, chigger bites, lice, bedbugs, grain, cheese, and fowl mites, dermatitis herpetiformis, and neurotic excoriations.

In addition to the discomfort of skin lesions, there is a possibility that *O bacoti* may be capable of transmitting disease. Although there is no documented report of human disease being contracted from this mite, there are experimental data that suggest it may be a potential disease vector. Murine typhus has been passed in the laboratory from rats to guinea pigs using *O bacoti* as the vector.[4,19] This mite has been shown to transmit rickettsial pox[20] and tularemia[21,22] from mouse to mouse. Plague, Coxsackie virus, and Q fever have also been shown to be transmissible to laboratory animals with *O bacoti* as the vector.[23-25] Despite the laboratory potential for disease transmission, *O bacoti* is currently of doubtful importance as a vector of human disease.

We believe that the proper identification of the mite causing this irritating dermatitis is important. The presence of mites are indicative of a rat-infested environment and proper identification allows the physician to advise the patient in eliminating the cause.

Westwood Pharmaceuticals, Inc, Buffalo, NY, provided assistance in the cost of reproduction of the color photographs used in this study.

References

1. Fairburn EA, Frain-Bell W: *Bdellonysus bacoti* causal agent of cutaneous disease. *Br J Dermatol* 68:350-354, 1956.

2. Cleland JB: Injuries and disease of man in Australia attributable to animals. *J Trop Med* 16:43-47, 1913.

3. Bishopp FG: *The Rat Mite Attacking Man.* US Department of Agriculture, 1923, vol 294, pp 1-4.

4. Shelmire B, Dove W: The tropical rat mite, *Liponyssus bacoti* Hirst, 1914: Cause of a skin eruption of man, and a possible vector of endemic typhus fever. *JAMA* 96:579-584, 1931.

5. Riley WA: Rat mite dermatitis in Minnesota. *Minn Med* 23:423-424, 1940.

6. Weber LF: Rat mite dermatitis. *JAMA* 114:1442, 1940.

7. Anderson CR: Rat mite dermatitis: Acariasis caused by tropical rat mite, *Liponyssus bacoti* Hirst, 1914. *Arch Dermatol Syphilogr* 50:90-95, 1944.

8. Hetherington GW, Holder WR, Smith EB: Rat mite dermatitis. *JAMA* 215:1499-1500, 1971.

9. Haggard CN: Rat mite dermatitis in children. *Pediatrics* 15:322-324, 1955.

10. Dowlati Y, Maguire HC: Rat mite dermatitis: A family affair. *Arch Dermatol* 101:617-618, 1970.

11. Wainschel J: Rat mite bite. *JAMA* 216:1864, 1971.

12. Lamb KP: The tropical rat mite, *Bdellonyssus bacoti* (Hirst, 1913) attacking man in New Zealand. *NZ Med J* 51:320-322, 1952.

13. Bertram DS, Unswarth K, Gordon RM: Biology and maintenance of *Liponyssus bacoti* Hirst 1913, and investigation into its role as vector of *Litomosoides carinii* to cotton rats and white rats, together with some observation on infection in white rats. *Ann Trop Med* 40:228-254, 1946.

14. Skaliy P, Hayes WJ: The biology of *Liponyssus bacoti* (Hirst 1913) *Am J Trop Med* 29:750-772, 1949.

15. Baker EW, Evans TM, Gould DJ, et al: *A Manual of Parasitic Mites of Medical or Economic Importance*, technical publication. New York, National Pest Control Assoc, Inc, 1956, pp 22-26.

16. Sudd JA: Laboratory studies of adult female *Bdellonysus bacoti* (Hirst, 1916). *Ann Trop Med Parasitol* 46:158-164, 1952.

17. Scott JA: Longevity of tropical rat mites without food. *J Parasitol* 35:434-435, 1949.

18. Rook A: Papular urticaria. *Pediatr Clin North Am* 8:817-833, 1961.

19. Dove WE, Shelmire B: Tropical rat mites, *Liponyssus bacoti* Hirst: Vectors of endemic typhus. *JAMA* 97:1506-1510, 1931.

20. Philip CB, Hughes LE: The tropical rat mite, *Liponyssus bacoti*, as an experimental vector of Rickettsial pox. *Am J Trop Med* 28:697-705, 1948.

21. Hopla CE: Experimental transmission of tularemia by the tropical rat mite. *Am J Trop Med* 31:768-782, 1951.

22. Petrov VG: On the role of the mite *Ornithonyssus bacoti* Hirst as a reservoir and vector of the agent of tularemia. *Parazitologiya* 1:7-14, 1971.

23. Yamada S: Observations on a house-infesting mite (*Liponyssu nagayol*) which attacks human beings, rats and other domestic mammals with brief notes of experiments regarding the possibility of plague transmission by means of this mite. *Far East Assoc Trop Med Trans* 2:358-372, 1932.

24. Schwab MR, Allen R, Sulkin SE: The tropical rat mite (*Liponyssus bacoti*) as an experimental vector of Coxsackie virus. *A J Trop Med Hyg* 1:982-986, 1952.

25. Zemskaya AA, Pchelkina AA: Experimental infection of the bird mite (*Dermanyssus gallinae*) and the rat mite *Ornithonyssus bacoti* with the causal agent of Q fever. *Dakl Hald Nauk SSSR* 101:391-392, 1955.

Human Essential Fatty Acid Deficiency

Treatment by Topical Application of Linoleic Acid

Phyllis Skolnik, MD; William H. Eaglstein, MD; Vincent A. Ziboh, PhD

• An essential fatty acid (EFA) deficiency developed in a 19-year-old man who was being maintained on a long-term regimen of fat-free, intravenous hyperalimentation fluids. The EFA deficiency was reversed after 21 days by daily, topical application of linoleic acid to the patient's skin. The ratio of eicosatrienoic acid (20:3, n-9) to eicosatetraenoic acid (20:4, n-6) decreased to normal levels in the skin and serum with clinical improvement of the EFA deficiency syndrome. The cutaneous manifestations (scalp dermatitis, alopecia, and depigmentation of hair) were reversed with continued, topical application of safflower oil, which contains 60% to 70% linoleic acid.

(*Arch Dermatol* 113:939-941, 1977)

Essential fatty acid (EFA) deficiency has been described in rats, mice, dogs, swine, and humans.[1-3] The essentiality of a polyenoic acid is that the double bonds must have cis-configuration as in linoleic acid and arachidonic acid. Arachidonic acid is three to five times as effective as linoleic acid in promoting growth. However, linoleic acid is the essential fatty acid that can be most easily obtained from the diet in preventing EFA deficiency.

Rats, dogs, mice, and pigs that were fed EFA-deficient diets developed eczema, dry, scaling skin, tail necrosis, renal edema, and sterility.[1] Infants who were fed low-fat diets developed thrombocytopenia, dry, scaling skin, or dermatitis; they gained weight slowly, and their bodies had a poor ability to heal wounds.[2] In addition to these clinical signs, EFA-deficient animals and humans have an abnormally high serum concentration of the fatty acid eicosatrienoic acid (20:3, n-9) and a low serum concentration of arachidonic acid (eicosatetraenoic acid, 20:4, n-6). The increased 20:3/20:4 ratio is diagnostic of EFA deficiency.[4]

In a well-controlled study, Prottey and co-workers[5] demonstrated in three cases that the cutaneous application of sunflower-seed oil (rich in linoleic acid), but not olive oil, reversed the effects of EFA deficiency caused by chronic malabsorption and it increased the levels of epidermal linoleic acid.

With the increased use of long-term, parenteral nutrition, many patients may develop EFA deficiency. Supplementation of their diets with linoleic acid is, therefore, imperative. Since a previous study from our laboratory showed that topical prostaglandin E_2 (PGE_2) cleared scaly skin lesions of EFA-deficient rats,[6] we investigated the effect of topical applications of linoleic acid, which is an endogenous precursor of arachidonic acid, prostaglandin E_1 (PGE_1), and PGE_2 on the skin of a patient who was being fed fat-free fluids by intravenous hyperalimentation.

METHODS

The patient was a 19-year-old man with severe, inflammatory bowel disease, who had had a colectomy following a sudden perforation of his transverse colon. After receiving fat-free fluids by intravenous hyperalimentation for four months postoperatively, he developed dermatitis of the scalp and eyebrow areas, a diffuse scalp and eyebrow alopecia, and a lightening of his remaining scalp hair (Fig 1). He still required intravenous hyperalimentation because of an abdominal wall defect and bowel-to-skin fistulas.

The intravenous hyperalimentation fluids contained the essential and nonessential amino acids, dextrose, and water, all in varying concentrations. Multivitamins that were added to the intravenous fluids included ascorbic acid, vitamin A, vitamin D (ergocalciferol), thiamine hydrochloride, riboflavin (as 5-phosphate), pyridoxine, niacinamide, dexpanthenol, and vitamin E (dl-alpha tocopherol acetate). The patient had been receiving these substances prior to and after development of the cutaneous manifestations of EFA deficiency.

Five milliliters of venous blood and one 4-mm skin punch biopsy specimen were taken from the left thigh at each of three different times and analyzed for the determination of fatty acids. The blood and skin specimens were obtained before treatment and at seven and 14 days after treatment. The patient was treated topically with 150

Accepted for publication April 28, 1976.
From the Department of Dermatology, University of Miami School of Medicine, Florida.
Reprints not available.

Fig 1.—Patient before topical essential fatty acid supplementation.

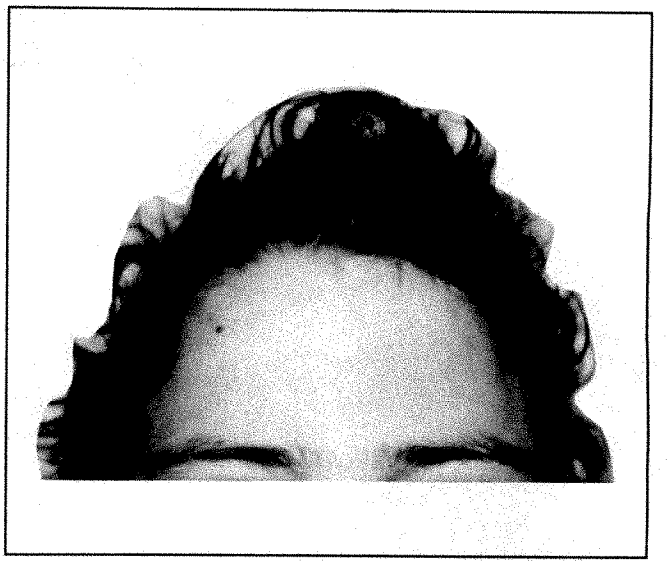

Fig 2.—Patient after three months of topical therapy. Note regrowth and pigmentation of hair.

mg of linoleic acid, which was carefully rubbed into the skin of his right thigh once a day for 21 days. Topical treatment with safflower oil (containing approximately 60% to 70% linoleic acid) replaced the linoleic acid applications to the right thigh after three weeks.

Analysis of Fatty Acids

The skin biopsy specimens were homogenized rapidly in chloroform:methanol, 2:1 (v/v) and the total lipids were extracted according to the procedure described by Folch et al.[7] The same method was used to extract the lipids from the serum. The total lipids from serum and skin were transesterified by refluxing under nitrogen for two hours with a 5% solution of hydrochloric acid in methanol. The methyl esters of the fatty acids were analyzed by gas-liquid-chromatography with a hydrogen flame ionization detector. The methyl esters were identified by internal standards of reference methyl esters of fatty acids (purity 95% to 99%). Quantification of fatty acid peaks was by triangulation.

Effects of Ultraviolet Light (UV-B) on Skin

The patient's response to ultraviolet light (UVL) irradiation was tested before and after topical linoleic acid therapy. Two sun tubes (major emission 290 to 320 nm; intensity, 2,000 $\mu W/cm^2$ at 10 cm) were used to irradiate 1 × 2-cm rectangular areas of the patient's left, volar forearm for various times at 30-second intervals. The minimal erythema dose (MErD), which is defined as: the minimum dose of UVL necessary to produce erythema 24 hours after irradiation, was determined.

RESULTS

After three weeks of topical therapy with linoleic acid, the scaling dermatitis of the patient's scalp resolved. Regrowth and repigmentation of his scalp and eyebrow hair occurred after three months of topical therapy (Fig 2). The topical safflower oil therapy was continued for the period during which the patient was maintained on intravenous hyperalimentation fluids, because his fistulous bowel disease prevented oral intake of solid foods and fluids.

The ratios of eicosatrienoic acid (20:3, n-9) to eicosatetraenoic acid (20:4, n-6) in the sera and skin specimens are shown in the Table. The ratio of the 20:3/20:4 fatty acids in the serum and the skin on admission into the hospital was increased greatly, demonstrating a clear case of EFA deficiency. After two weeks of topical treatment with linoleic acid, the ratio of these fatty acids was decreased to normal level in the skin. Although the ratio was still high in the serum, a notable drop had occurred from the pretreatment value. The MErD was the same and within normal range both before and after three months of linoleic acid therapy.

Cutaneous Application of Linoleic Acid

	20:3 to 20:4 Fatty Acid Ratio*	
Day	Serum	Skin
0	2.0	1.6
7	1.5	1.0
14	0.8	0.4

*Ratio of 20:3/20:4 > 0.4 denotes essential fatty acid deficiency syndrome.[4]

COMMENT

Our findings showed that a 19-year-old man who had been maintained on a long-term regimen of fat-free, intravenous hyperalimentation fluids developed signs of EFA deficiency. In addition to the cutaneous lesions, we found a marked increase in the ratio of 20:3/20:4 fatty acids in the patient's skin and serum. After three weeks of topical treatment with linoleic acid, the improvement of the dermatitis was parallel with a return to normal level of the 20:3/20:4 fatty acid ratio in the skin. A prominent decrease in this ratio also occurred in the serum (Table). These results indicate that linoleic acid was absorbed percutaneously and metabolized systemically to arachidonic acid (20:4, n-6). Percutaneous absorption of linoleic acid by EFA-deficient patients in whom correction of the cutaneous signs and the serum fatty acid ratio levels has taken place has been reported.[5-8] Correction of the skin 20:3/20:4 fatty acid ratio at sites distant from the linoleic acid applications has not been previously reported. The mechanism of action of

linoleic acid in reversing the skin signs of EFA deficiency is unknown. It is interesting, however, that Ziboh and Hsia[6] reported the clearing of scaly lesions in the skin of EFA-deficient rats with topical PGE_2. Since linoleic acid is an endogenous precursor of PGE_2, the possibility that the prostaglandins or their intermediates are involved in the reversal of the cutaneous signs associated with EFA deficiency is likely and deserves further study.

Of particular interest in this study is the repigmentation and growth of new scalp and eyebrow hair by the patient after several months of daily topical treatment with safflower oil. An analogous "browning" of normally black hair has been reported in EFA-deficient hooded rats.[9] These observations suggest that a relationship might exist between pigmentation, hair growth, linoleic acid, and its metabolites. Prostaglandins have been reported to disperse melanosomes in black goldfish[10] and to darken frog skin.[11] Further studies are necessary to elucidate possible relationships.

Since the E series prostaglandins are reported to be important mediators of UVL-induced redness,[12-15] it is surprising that the patient's MErD was normal before correction of his EFA deficiency. While EFA-deficient, the patient had reduced EFA precursors of PGE and an elevated skin concentration of eicosatrienoic acid (20:3, n-9), which is an inhibitor of prostaglandin synthesis.[16]

Our findings illustrate the need to supply linoleic acid to patients whose sole source of nutrition is fat-free fluids by intravenous hyperalimentation. Linoleic acid supplementation may also be necessary for patients suffering from fat malabsorption. Topical application of safflower oil is an effective and inexpensive method of dietary supplementation.

References

1. White A, Handler P, Smith E: *Principles of biochemistry.* New York, McGraw-Hill Book Co Inc, 1968, pp 1010-1011.
2. Caldwell MD, Jonsson HT, Otherson HB Jr: Essential fatty acid-deficiency in an infant receiving prolonged parenteral alimentation. *J Pediatr* 81:894-898, 1972.
3. Riella MC, Broviac JW, Wells M, Scribner BH: Essential fatty acid-deficiency in human adults during total parenteral nutrition. *Ann Intern Med* 83:786-789, 1975.
4. Holman RT: The ratio of trienoic:tetraenoic acids in tissue lipids as a measure of essential fatty acid requirement. *J Nutr* 70:405-410, 1960.
5. Prottey C, Hartop PJ, Press M: Correction of the cutaneous manifestations of essential fatty acid-deficiency in man by application of sunflower-seed oil to the skin. *J Invest Dermatol* 64:228-234, 1975.
6. Ziboh VA, Hsia SL: Effects of prostaglandin E_2 on rat skin: Inhibition of sterol ester biosynthesis and clearing of scaly lesions in essential fatty acid-deficiency. *J Lipid Res* 13:458-467, 1972.
7. Folch J, Lees M, Sloane Stanley GH: A simple method for the isolation and purification of total lipides from animal tissues. *J Biol Chem* 226:497-509, 1957.
8. Press M, Hartop PJ, Prottey C: Correction of essential fatty-acid deficiency in man by the cutaneous application of sunflower-seed oil. *Lancet* 1:597-599, 1974.
9. Sinclair HM: Essential fatty acids and the skin. *Br Med Bull* 14:258-262, 1958.
10. Abramowitz J, Charvin W: *In vitro* effects of prostaglandins upon melanosome dispersion in the skin of black goldfish. *Prostaglandins* 4:805-818, 1973.
11. Peaslee MH: Frog skin darkening effect of prostaglandins E_1, E_2 and $F_{2\alpha}$. *Am Zool* 11:651, 1971.
12. Greaves MW and Sondergaard J: Pharmacologic agents released in ultraviolet inflammation studied by continuous skin perfusion. *J Invest Dermatol* 54:365-367, 1970.
13. Mathur GP, Gandhi VM: Prostaglandin in human and albino rat skin. *J Invest Dermatol* 58:291, 1972.
14. Snyder DS, Eaglstein WH: Intradermal anti-prostaglandin agents and sunburn. *J Invest Dermatol* 62:47, 1974.
15. Eaglstein WH: Prostaglandins and ultraviolet erythema. *Cosmetics and Perfumery* 90:25-28, 1975.
16. Ziboh VA, Vanderhoek JY, Lands WEM: Inhibition of sheep vesticular gland oxygenase by unsaturated fatty acids from skin of essential fatty acid-deficient rats. *Prostaglandins* 5:233-239, 1974.

Pemphigus Vegetans of Hallopeau

Immunofluorescent Studies

Christopher G. Nelson, MD; Prapand Apisarnthanarax, MD; Samuel F. Bean, MD; J. Fred Mullins, MD

• Immunofluorescent techniques were used in the study of tissue from a patient with pemphigus vegetans of Hallopeau. The findings were typical of pemphigus, confirming the propriety of classifying this entity as a benign variant of pemphigus, rather than a disease of purely microbial etiology. The question is raised whether other types of vegetating pyodermas actually are separate diseases or represent a spectrum of pemphigus with the clinical appearance dependent on the patient's immunity to his disease. Immunofluorescent studies are proposed as a basis for classification.

(*Arch Dermatol* 113:942-945, 1977)

In 1889, Henri Hallopeau, MD, described a new skin disease characterized by polycyclic eruptions of pustules that gave way to eruptive firm pink papillomas which in turn progressively flattened and changed to dark brown patches which later faded.[1] His patient had involvement of widespread areas of skin and mucous membrane; the disease ran a benign course without pyrexia or systemic manifestations. He gave it the name "dermatitis pustulous chronic in foyers (centers) with eccentric progression."

Almost since the first report of this disease, its etiology has been subject to controversy. In 1898, Hallopeau[2] reported five more cases and shortened the name to pyodermite vegetante. A few months later, because of the development of bullae and a fatal outcome in one case, he became convinced that his disease was nothing more than a variant of pemphigus vegetans of Neumann.[3] He was followed in this opinion by many others.

Shortly after the turn of the century, Gaucher[4] postulated an infectious etiology for this disorder, and this opinion, too, gained a large following.

Today, much confusion still exists as to proper classification of the Hallopeau disorder—is it a relatively benign type of pemphigus (pemphigus vegetans of Hallopeau) or an idiosyncratic reaction to a cutaneous infection (pyoderma vegetans of Hallopeau) or are there perhaps two (or more) separate diseases?

In the last ten years, immunofluorescent techniques have been used to demonstrate circulating antibodies against epidermal components in pemphigus, and new insight has been gained into the pathophysiology of this group of diseases.

We had the opportunity to use immunofluorescent techniques in the study of a case of the Hallopeau rare disorder.

REPORT OF A CASE

A 70-year-old man was admitted to the University of Texas Medical Branch Dermatology service for evaluation of papillomatous lesions that had been waxing and waning in various flexural areas for the past year. Initially, the lesions involved only the inguinal areas, but later spread to the axillae, umbilicus, and nape of the neck. The primary lesions were reportedly papules and pustules; he denied the presence of bullae at any time. Over the same time period, the patient had developed extensive erosions inside the mouth, with a resultant 18-kg weight loss due to inability to eat because of pain. The patient had been treating his lesions by

Accepted for publication March 26, 1976.

From the Department of Dermatology, University of Texas Medical Branch, Galveston, Tex (Drs Nelson, Apisarnthanarax, and Mullins), and the Department of Dermatology, Baylor College of Medicine, Houston (Dr. Bean).

Reprint requests to Department of Dermatology, University of Texas Medical Branch, Galveston, TX 77550 (Dr Nelson).

frequent washing with soap and water, followed by dusting with an antibiotic powder. The past medical and family histories were noncontributory, as was the social history and review of systems.

Physical examination revealed a thin, chronically ill-appearing man with pertinent findings confined to the skin and oral mucosa. There were numerous verrucous papules, nodules, and tumors varying in size from a few millimeters to several centimeters in the inguinal folds, perineum, umbilicus, both axillae, and nape of the neck (Fig 1 and 2) There were two similar lesions, 5 mm in diameter, in the right antecubital fossa. The lesions varied in hue from flesh colored to erythematous, and some were crusted and purulent. The oral mucous membranes showed extensive erosions with some white plaque-like areas on the tongue, buccal mucosa, and gingivae.

On admission, CBC was normal except for an eosinophil count of 15%. Serum albumin was at the lower limits of normal, and there was a slight polyclonal increase of gamma globulin. The serologic test for syphilis was nonreactive, and the antinuclear antibody test was negative. Erythrocyte sedimentation rate was 32, and values for serum calcium, phosphorus, cholesterol, glucose, BUN, uric acid, creatinine, bilirubin, alkaline phosphatase, lactic dehydrogenase (LDH), SGPT, chloride, SGOT, carbon dioxide, potassium, and sodium were all normal.

Chest x-ray film, intravenous pyelogram, and upper gastrointestinal series were all normal. Barium enema showed diverticulosis without evidence of diverticulitis. Proctoscopic examination results were normal.

On admission, therapy with systemic and topical antibiotics was initiated. Several days later, when the skin biopsy was found to be typical of pemphigus vegetans, the entire regimen was discontinued, and a regimen of oral prednisone, 40 mg daily, and triamcinolone acetonide spray to the cutaneous lesions was started. His oral lesions were treated symptomatically with viscous lidocaine.

Almost immediately after the institution of this regimen, the vegetating lesions took on a dark violaceous color and began to regress. The oral lesions likewise showed dramatic response, and the eosinophil count returned to normal. The dose of prednisone was gradually tapered as the lesions continued to improve until the dose reached 15 mg/day, when there was a reappearance of the oral erosions. These promptly resolved when the steroid dose was adjusted upwards to 20 mg/day.

The patient was discharged on 20 mg of prednisone daily and thrice-daily application of triamcinolone acetonide spray to the small number of regressing lesions that remained.

In eight months of follow-up care, the vegetating cutaneous lesions have disappeared completely, leaving hyperpigmentation that is fading slowly. The patient is being maintained on prednisone, alternating 5 mg and 10 mg daily. At one point, he discontinued this medication and had a subsequent prompt return of his oral erosions. Reinstitution of the therapy was followed by their regression. Likewise, attempts to further lower his maintenance dose have resulted in reappearance of oral erosions.

MATERIALS AND METHODS

A verrucous nodule was excised for light microscopic examination, fixed in 10% formaldehyde solution (formalin), and stained with hematoxylin and eosin.

A similar verrucous nodule was excised for direct immunofluorescent studies. Biopsies were repeated one month after beginning treatment for both light microscopic and immunofluorescent study.

Tissue for indirect immunofluorescent studies was monkey esophagus.

The tissue obtained was quick frozen in liquid nitrogen and stored at a temperature of −20 C. Sections were cut in a cryostat at 4μ to 6μ and used within one week.

Commercially prepared fluorescein conjugated goat antihuman IgG, IgA, IgM, and BIC-globulin (C3) were used (Hyland Laboratories, Costa Mesa Calif). The molar fluorescein to protein ratio (F/P) and antibody concentration of the conjugates and dilutions used were as follows: IgG, F/P ratio, 3.5, 1.9 mg Ab/ml, diluted to a concentration of 50 μg/ml; IgA, F/P ratio 2.8, 0.8 mg Ab/ml diluted to a concentration of 100 μg/ml; IgM, F/P ratio 2.5, 0.3 mg Ab/ml diluted to a concentration of 100 μg/ml; and BIC globulin, F/P ratio 3.1, 1.2 gm Ab/ml, diluted to 50 μg/ml.

Standard direct and indirect immunofluorescent staining procedures were used as described by Beutner et al.[5] The control sera consisted of pemphigus vulgaris serum, bullous pemphigoid serum, normal human serum, and normal saline.

All studies were repeated one month after beginning treatment with prednisone.

RESULTS

Light Microscopic Studies

Hyperkeratosis, parakeratosis, and keratotic plugging of the hair follicles were present. There were marked acanthosis, papillomatosis, and considerable downward proliferation of the epidermis. Intraepidermal abscesses composed almost entirely of eosinophils were present in the acanthotic epidermis (Fig 3). Numerous acantholytic cells, appearing as single as well as clusters of rounded epidermal cells, were also seen within the abscesses (Fig 4). The dermis revealed a pronounced inflammatory infiltrate composed of an admixture of lymphoid cells, histiocytes, eosinophils, and a few neutrophils. The upper dermis showed moderate edema.

One month after initiation of the steroid regimen, a marked reduction in the amount of hyperkeratosis, acanthosis, and papillomatosis was seen, as well as the disappearance of the intraepidermal abscesses.

Direct Immunofluorescent Studies

Deposits of IgG were demonstrated in the intercellular substance throughout the epidermis. No IgA, IgM, or C3 was demonstrated. In addition, a striking picture was produced by fluorescence of the intraepidermal abscesses, which because of staining of the eosinophils and borders of the acantholytic cells, appeared to "light up" in comparison to the surrounding tissue (Fig 5). This staining was observed with anti IgG, but not with anti IgA, IgM, or C3.

One month after starting systemic steroids, direct immunofluorescence could no longer be demonstrated.

Indirect Immunofluorescent Studies

Using fluorescein conjugated antihuman IgG, intercellular antibodies to a titer of 1:20 were demonstrated on monkey esophagus. One month after initiation of steroids, this titer had dropped to zero.

COMMENT

Almost immediately after its introduction late in the 19th century, controversy began to develop around Hallopeau's new disease entity. Hudelo, Wickham, Brocq and Laredde still considered the disease a simple variant of dermatitis herpetiformis.[3] Kaposi and Herxheimer[3] argued that this was a deviation of pemphigus,

while Neumann, Neisser and Köbner[3] still regarded it as a separate entity because of the proliferative character (often with large vegetations), the localization, the peripheral progression, and the favorable prognosis. After one of his patients developed bullae and died, Hallopeau himself finally admitted in 1898[3] that his dermatosis was nothing more than a pustular variant of pemphigus vegetans that had been reported by Neumann in 1876. Neumann's disease was characterized by the formation of bullae that extended and coalesced, and on the floor of which papillomatous growths appeared. The disease often involved the mouth, and the course was fulminant and fatal.[6]

In a clinical lecture in 1906, Gaucher[4] affirmed a microbial etiology for what he called the "disease of Hallopeau," and the reports of several new cases with characteristic clinical and laboratory findings again gave the disease status as a separate entity. Later, other authorities[7-10] reaffirmed that cutaneous infections could give rise to papillomatous proliferations and the term "pyoderma vegetans" came into common usage.

Many authors,[11-14] including Hallopeau himself, continued to consider Hallopeau's original entity related to pemphigus vegetans of Neumann, or at least hypothesizing it as a type of pemphigus.

Brunsting and Underwood,[15] in 1949, reported five cases of pyoderma vegetans associated with ulcerative colitis and found some correlation between control of the colitis and control of the skin lesions. In addition, each of their patients was noted to have oral or nasal mucous membrane involvement. McCarthy[16] applied the term pyostomatitis vegetans to three cases reported by him which involved primarily the oral cavity. Current authorities[17] state that mucous membrane involvement is common in pyoderma vegetans.

In 1966, Stone and Mullins[18] described two patients with pemphigus vulgaris who developed lesions clinically and histologically typical of pemphigus vegetans at the site of chronic *Candida albicans* infections. They suggested pemphigus vegetans

Fig 1.—Multiple verrucous nodules in groin and umbilicus.

Fig 2.—Verrucous nodules in left axilla.

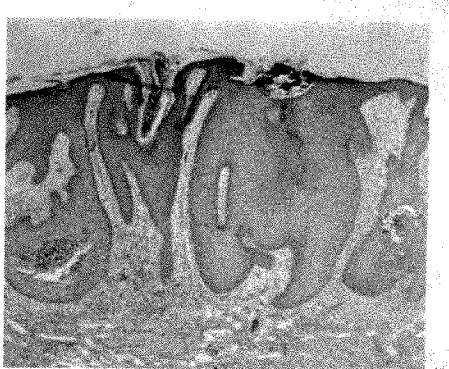

Fig 3.—Histologic section of nodule showing hyperkeratosis, follicular plugging, papillomatosis, marked acanthosis with intraepidermal abscess formation, and a chronic dermal inflammatory infiltrate (hematoxylin-eosin, original magnification ×25).

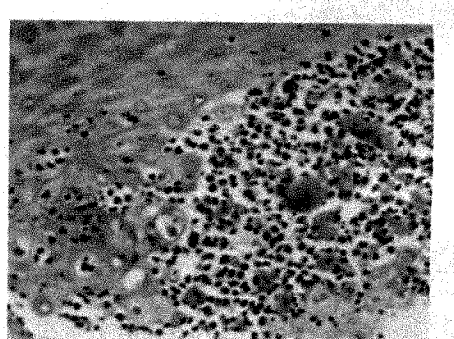

Fig 4.—Close-up view of intraepidermal abscess on left in Fig 3 showing numerous eosinophils and acantholytic cells (hematoxylin-eosin, original magnification ×250).



Fig 5.—Direct immunofluorescent staining of intraepidermal abscess. Note fluorescent staining of intercellular substance of epidermal cells near edges (anti-human IgG original magnification ×450).

may be the method by which patients with pemphigus respond to chronic infectious processes.

Our patient presents a clinical picture typical of Hallopeau's original description of his disease—the progressive multiple eruptions of pustules, later giving way to eruptive papillomatous lesions. Oral lesions were likewise present. The benign course of the disease in our patient, as well as his eosinophilia and skin biopsy findings, leave no doubt that this is, indeed, an example of Hallopeau's rare disorder.

Our findings of direct and indirect immunofluorescent studies typical of pemphigus confirm the findings of Ouimet et al[19] in a similar case. We believe our case is only the second to be so studied.

These findings confirm the opinion of those who believe pyoderma vegetans of Hallopeau belongs nosologically with pemphigus. Because the disease has a benign course and fails to produce bullae, we believe that it should be separated from pemphigus vegetans of Neumann and be recognized as a distinct entity—pemphigus vegetans of Hallopeau.

Whether pemphigus vegetans of Hallopeau is also separate and distinct from pyoderma vegetans remains unanswered. Both diseases share similar clinical features, including vegetating cutaneous lesions and mucous membrane involvement. In addition, common histopathologic features include hyperkeratosis, acanthosis with intraepidermal abscess formation, and a chronic dermal inflammatory infiltrate. It has been written[17-20] that the two entities may be separated on the basis that pyoderma vegetans may show fewer eosinophils and acantholytic cells in the intraepidermal abscesses than pemphigus vegetans.

Since eosinophils and acantholytic cells may be seen within the intraepidermal abscesses in both diseases, we propose that any differentiation must be made by immunofluorescent studies. Pemphigus vegetans of Hallopeau will have immunofluorescent findings typical of pemphigus; pyoderma vegetans should not. It is possible that many or all cases reported in the past as pyoderma vegetans actually were pemphigus vegetans, and the clinical appearance and course depended on the patient's immunity to his disease. Thus, a spectrum could exist from frank pemphigus vulgaris through pemphigus vegetans of Neumann, pemphigus vegetans of Hallopeau and on to the benign vegetating pyodermas.

The immunofluorescent techniques needed to properly categorize these diseases are now at hand. Future studies should be done to put this diverse group of disorders in the proper perspective.

Mario Dobrkovsky, MD, helped in translating references.

Texas Pharmacal Co, San Antonio, helped share the cost of the color reproductions.

References

1. Hallopeau H: *Congrès International de Dermatologie et de Syphiligraphic tenu à Paris (1° session).* Paris, G Masson, 1889, pp 344-362.

2. Hallopeau H: "Pyodermite vegetante", ihre beziehungen zur dermatitis herpetiformis und dem pemphigus vegetans. *Arch Dermatol Syph* 43:289-306, 1898.

3. Hallopeau H: Zweite mittheilung uber "pyodermite vegetante" (suppurative form der Neumannschen krankheit). *Arch Dermatol Syph* 45:323-328, 1898.

4. Darier J: *A Textbook of Dermatology,* Pollitzer S (ed-trans). Philadelphia, Lea and Febiger, 1920, p 244.

5. Beutner EH, Chorzelski TP, Jordon RE: *Autosensitization in Pemphigus and Bullous Pemphigoid.* Springfield, Ill, Charles C Thomas Publisher, 1970.

6. Nanta A, Bazek A: Formes cliniques des pyodermites vegetantes. *Ann Dermatol Syph* 8:609-623, 1937.

7. Gaucher PCE, Malloizel L: Maladie de Hallopeau (pyodermite vegetante). *Ann Dermatol Syph* 7:953-955, 1906.

8. Milian G: Pyodermite vegetante (maladie de Hallopeau). *Rev Franc Dermatol Venereol* 3:209-217, 1927.

9. Hudelo L: *Nouvelle Pratique Dermatologique,* ed 4. Paris, G Masson, 1936, p 450.

10. Degos R, Carteaud A: Pyodermite vegetante d'Hallopeau. *Ann Dermatol Syph* 80:254-262, 1953.

11. Brocq L: *Precis-atlas de Pratique Dermatologique.* Paris, Doin, 1920.

12. Darier J: *Precis de Dermatologie.* Paris, G Mason, 1928.

13. Riecke E: *Jadassohn's Handbuch, Haut u Geschlechtskrankheiten.* Berlin, J Springer, 1931, p 419.

14. Kumer L: *Arzt u Zieler's Haut u Geschlechtskrankheiten,* ed 3. Berlin, Urban und Schwarzenberg, 1934, p 407.

15. Brunsting LA, Underwood LJ: Pyoderma vegetans in association with chronic ulcerative colitis. *Arch Dermatol Syph* 60:161-172, 1949.

16. McCarthy FP: Pyostomatitis vegetans. *Arch Dermatol Syph* 60:750-764, 1949.

17. Rook A, Roberts SOB: Bacterial infections, in Rook A: *Textbook of Dermatology.* Oxford, England, Blackwell Scientific Publications, 1972, pp 526-527.

18. Stone OJ, Mullins JF: Vegetative lesions in pemphigus. *Derm Int* 5:137-140, 1966.

19. Ouimet G, Menard A, Trudeau J: Immunofluorescence dans la pyodermite vegetante de Hallopeau. *Union Med Can* 102:1,699-1,701, 1973.

20. Montgomery H: *Dermatopathology.* New York, Harper & Row, 1967, p 154.

Pigmented Basal Cell Cancer Masquerading as Superficial Spreading Malignant Melanoma

Michael J. Fellner, MD, James M. Katz, MD

• A 49-year-old woman of Spanish descent had a pigmented lesion on the thigh present for many years, which enlarged recently. The lesion showed notching and black, brown, and blue colors that led to the initial diagnosis of superficial spreading malignant melanoma. Results of skin biopsy disclosed the lesion was a basal cell epithelioma with large amounts of melanin in the dermis. This report illustrates the importance of considering pigmented basal cell epithelioma in the differential diagnosis of superficial spreading malignant melanoma.

(*Arch Dermatol* 113:946-947, 1977)

The differential diagnosis of deeply pigmented lesions includes malignant melanoma. In addition to the multiplicity of colors, which has been well described,[1] notching has been cited as a feature of both lentigo malignant melanoma and superficial spreading malignant melanoma. Pigmented basal cell cancer is distinguished from melanoma by the presence of a round, raised, pearly border. The following describes a differential diagnosis in which these two entities, which usually are easily differentiated clinically, posed a difficult problem.

Accepted for publication April 27, 1976.

From the Department of Dermatology, New York Medical College and Bird S. Coler Hospital, New York.

Reprint requests to Department of Dermatology, Bird S, Coler Hospital, Roosevelt Island, New York, NY 10044 (Dr Fellner).

REPORT OF A CASE

A 49-year-old Spanish woman who had a long history of a mole on the right medial aspect of the right thigh complained of an enlargement of the lesion during the past six months. The patient's previous medical history was unremarkable and she denied any symptomatology other than enlargement of the lesion.

On physical examination, the lesion (Fig 1) measured 2.5 × 2 cm, and it appeared as an irregularly shaped, hyperpigmented lesion with variation in color, ranging from black to brown to blue, with a serpiginous raised border. Pigment spillage was apparent and the lesion was notched. There was no enlargement of femoral or popliteal lymph nodes. The patient had an olive to tan complexion, dark black hair, and brown eyes.

The clinical impression was superficial spreading melanoma. Basal cell epithe-

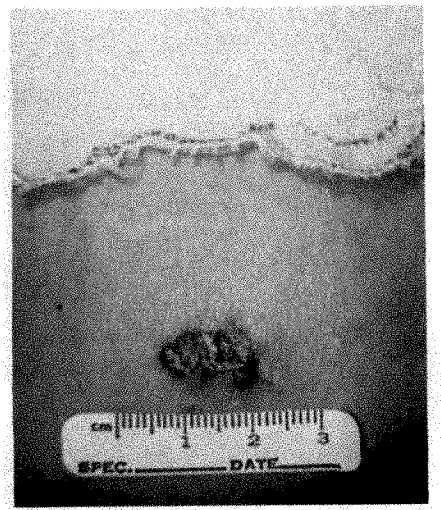

Fig 1.—Lesion showing gray irregular marking, notching, surrounding erythema, pigment spillage, ulcerative crusting, and subtle raised border extending beyond black lesion.

Fig 2.—Massive deposits of pigment within cells in papillary dermis and epidermis.

lioma of the pigmented variety was also considered as part of the differential diagnosis but was considered less likely. An excisional biopsy was done.

Results of the histologic examination showed hyperkeratosis with extension of melanin pigment into the horny layer of the epidermis. The stratum germinativum was heavily pigmented with irregular basalioma cells extending into the dermis. At low-power magnification (Fig 2), large amounts of pigment and basalioma cells showed some resemblance to superficial spreading melanoma. At high-power magnification (Fig 3), basalioma cells were



Fig 3.—Invasion of epidermis by masses of amorphous material with dark pigment and basalioma cells in dermis.

Fig 4.—Hyperkeratosis and "church spire" appearance in epidermis with massive deposition of pigment within epidermal cells.

seen clearly, and the diagnosis was pigmented basal cell epithelioma.

COMMENT

In 1975 a total of 5,538 tumor specimens that had been obtained from biopsies were studied histologically and reviewed for diagnostic accuracy in malignant melanoma. In this group three cases of basal cell cancers were found by histologic examination that had been diagnosed clinically as malignant melanoma, an incidence of less than 0.1%, indicating the rarity of this situation. The diagnosis of malignant melanoma in these three patients finally proved to be pigmented basal cell cancer, similar to the findings in our case. The reverse, diagnosing pigmented basal cell cancer and subsequently finding malignant melanoma, occurred in six patients.

An unusual aspect of this lesion was the striking clinical resemblance to superficial spreading melanoma, as described by Mihm et al,[1] with the variation in color, especially the gray intermixed with black and brown, as well as the notching. In addition, this occurred on the thigh of a Spanish woman with relatively dark skin, eyes, and hair, and was on a covered area of the body, the upper thigh. The location favored superficial spreading melanoma rather than basal cell epithelioma. The histology showed similarities to superficial spreading melanoma. The massive amount of pigment deposition were unusual for basal cell cancer.

The clinical diagnosis of basal cell cancer has been reported with an accuracy that ranges to a 25% error in diagnosis.[2,3] Pigmented basal cell cancer should be included in the differential diagnosis of malignant melanoma.

Westwood Pharmaceuticals, Buffalo, NY, assumed the cost of the color reproductions and reprints for this study.

References

1. Mihm MC, Fitzpatrick TB, Brown ML, et al: Early detection of primary cutaneous malignant melanoma. *N Engl J Med* 289:989-996, 1973.

2. Kopf AW, Mintzis M, Bart RS: Diagnostic accuracy in malignant melanoma. *Arch Dermatol* 111:1291-1292, 1975.

3. Freeman RG, Knox JM: Clinical accuracy in diagnosis of skin tumors. *Geriatrics* 18:546-551, 1963.

Follicular Atrophoderma and Basal Cell Carcinomas

The Bazex Syndrome

Peter Viksnins, MD, Alan Berlin, DO

• **Seven members of one family had a rare, inherited syndrome of follicular atrophoderma, basal cell carcinomas, and localized anhidrosis. Associated findings in some subjects were generalized hypohidrosis and "eczema" involving the face shortly after birth. This syndrome shows dominant inheritance, possibly x-linked. Follicular atrophoderma is an important skin manifestation, as it has been associated in all reported cases with other systemic or cutaneous abnormalities.**

(*Arch Dermatol* 113:948-951, 1977)

The syndrome we are describing consists of the following four components: (1) follicular atrophoderma; (2) basal cell carcinomas; (3) localized anhidrosis and/or generalized hypohidrosis; and (4) hypotrichosis. This syndrome was initially presented by Bazex et al, in 1964,[1] and subsequently published under the title of "Follicular Atrophoderma, Basal Cell Carcinomas and Hypotrichosis."[2] He and associates described six affected members of one family. All of these patients had hypotrichosis, although this was not seen in any of our patients. Some of these patients also had a generalized hypohidrosis and anhidrosis of the face. To our knowledge, no other reports of patients with this syndrome have appeared in the literature.

Detailed case histories of our two initial cases are presented. The pertinent findings in the additional cases are summarized in tabular form (Table). Their relationships are shown in the pedigree (Fig 1). Information regarding the grandfather (I 1) of the probands was obtained from his three daughters (II 3, 5, and 6) and one of his sons (II 1). The father of the probands was not examined.

Accepted for publication March 2, 1976.

From the Department of Dermatology, Geisinger Medical Center, Danville, Penn. Dr. Berlin is now in private practice in Flint, Mich.

Reprint requests to Chairman, Department of Dermatology, Geisinger Medical Center, Danville, PA 17821 (Dr Viksnins).

REPORT OF CASES

Case 1 (III 5).—A 22-year-old male college student came to use for treatment of multiple lesions on the face (Fig 2 through 4). He gave a history of having had eight or nine previous facial lesions diagnosed as "skin cancers" after surgical excision. One lesion had been treated with x-irradiation and one more recently with fluorouracil. He found that the fluorouracil caused considerable inflammation but did not result in complete resolution of the lesion. Multiple new lesions had developed on his face during the past year. He was aware of an unusual skin pattern present on the dorsum of the hands and feet as well as the elbows. According to his mother, this type of skin was common in the family and was present at birth. He stated that he sweated normally in all body areas except on the cheeks and chin. He found that even when working out in the gym, he did not develop any drops of sweat on the cheeks or chin. He felt that he burned easily on exposure to sunlight, and for this reason, he frequently had used a sunscreen preparation.

Past Medical History.—The patient's mother stated that immediately after birth, he had developed an erythematous, scaling eruption on the ears and the skin behind the ear. This had been diagnosed as "eczema" and cleared spontaneously in a matter of months. There was no history of any other skin disorder, in particular, no history of pigmentary abnormalities. He had the usual childhood diseases and had not been treated for any significant illness. Three years previously, he had normal lumbosacral x-ray films after an examination for low back pain. History was negative for any musculoskeletal disorders, swelling or cysts along the mandible, soft tissue tumors, seizure disorders, or any psychological problems. Review of systems was entirely negative except for myopia.

Examination.—No abnormalities were noted except for the skin findings. The patient had medium to dark brown hair with a fair complexion and numerous freckles. Atrophic white scars marked the sites of previous basal cell carcinoma surgery. Eight suspicious lesions on the face were noted. These papular lesions ranged in size from 2 to 5 mm. Four were lightly pigmented with fine overlying telangiectasias; two were flesh-colored, and two showed slight erythema and scaling.

The skin on the dorsum of both hands extending to the proximal phalanges showed a "multiple ice-pick mark" pattern. An identical pattern was noted on the dorsum of both feet and both elbows. The skin in the affected areas, when picked up between the fingers, showed a considerable accentuation of the normal skin creases. The individual lesions had the appearance of exaggerated follicular funnels. Only a few terminal hairs were noted in the involved areas but multiple scattered fine vellus hairs were present. Hair growth and distribution appeared normal in all other areas. There were no nail abnormalities, palmo-plantar pits, or keratoderma. Albright sign (dimpling of a knuckle due to a shortened metacarpal bone) was absent.

Laboratory Results.—Roentgenograms of the skull, mandible, and chest showed no abnormalities. Values for the following were within the normal range: CBC, urinalysis, BUN, creatinine, uric acid, phosphorus, calcium, glucose, cholesterol, total protein, total bilirubin, SGOT, lactic dehydrogenase, and alkaline phosphatase. Chromosome studies on leukocytes (25 cells counted) showed no structural or numerical abnormalities.

Treatment.—Eight facial lesions were removed under local anesthesia by parallel excision and curettage. A 4-mm punch biopsy was taken from a follicular lesion on the left elbow.

Case 2. (III 6).—A 24-year-old man (brother of case 1) developed multiple facial lesions at age 19 (Fig 5). Initially, he noted two lesions, one in the right infraorbital area and one on the right side of the nose. The former was surgically excised, and he was told that it was a skin cancer. The latter lesion had been clinically successfully treated with fluorouracil. Four new lesions had developed on his face over the last one to two years. He stated that the skin pattern on his hands, feet, and elbows was identical to that of his brother. According to his mother, the skin pattern was present at birth. He stated that he sweated normally in all areas including the face. He was able to tolerate sunlight well and frequently worked out-of-doors for longer periods.

Past Medical History.—The patient's mother stated that immediately after birth, he developed a severe eczema involv-

Summary of Findings and Past Medical History

Case No.	Age/Sex	Basal Cell Carcinomas of the Face, Approximate Number of Total Lesions	Age at Onset, yr	Follicular Atrophoderma, Location	Hypohidrosis Generalized	Anhidrosis Above Neck	Facial Eczema Soon After Birth	Other Medical Conditions
1 (III5)	22/M	16	15	Dorsum hands, dorsum feet, elbows	—	+ (Face, except forehead	(Mild—ears only)	None
2 (III6)	24/M	5	19	Dorsum hands, dorsum feet, elbows	—	—	Severe	Hay fever
3 (II 3)	57/F	15	16	Dorsum hands, dorsum feet, elbows	—	+	Severe	Scoliosis
4 (II 5)	55/F	8	22 or 23	Dorsum hands, dorsum feet, elbows	—	+	Uncertain	Diabetes mellitus
5 (II 6)	50/F	3	26	Dorsum hands, elbows	+	+	Uncertain	Rheumatoid arthritis
6 (III7)	20/F	None to date	. . .	Dorsum hands, elbows	+	+	Severe	Hay fever
7 (III8)	21/M	None to date	. . .	Dorsum hands, elbows	+	+	None	Hay fever and acne vulgaris

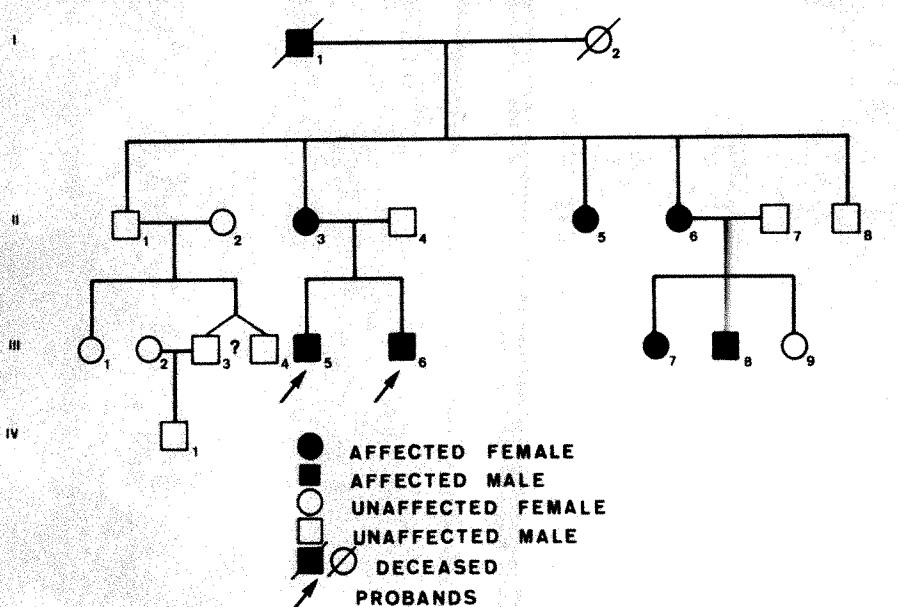

Fig 1.—Pedigree.

ing only the face. This eruption cleared during the first year of life. He had the usual childhood diseases and had not been treated for any significant illnesses. He gave a history of hay fever manifested by seasonal rhinorrhea, conjunctivitis, and sneezing. He also had multiple episodes of poison ivy. There was no history of pigmentary abnormalities, musculoskeletal problems, swelling or cysts along the mandible, soft tissue tumors, seizure disorders, or psychological problems. Review of systems was entirely negative.

Examination.—No abnormalities were noted except for the skin findings. The patient had light-to-medium brown hair, a moderately fair complexion, and multiple freckles. Scattered milia were noted on the face, especially on the right side of the nose in the area of previous fluorouracil therapy. Four lesions in the central facial area warranted surgical removal. These were all 2 to 4 mm, lightly-pigmented papules without telangiectasias. The skin changes on the dorsum of both hands, both feet, and both elbows were identical to those in case 1. Hair growth and distribution were normal in all areas. There were no nail abnormalities, palmar or plantar pits, or keratoderma. Albright sign was absent.

Laboratory Results.—Chromosome studies on leukocytes (25 cells counted) showed no structural or numerical abnormalities.

Treatment.—The four lesions were removed from the face under local anesthesia by parallel excision and curettage. A 4-mm, punch biopsy was taken from a follicular lesion on the dorsum of the left hand.

HISTOPATHOLOGICAL FINDINGS

Case 1.—Seven of the eight lesions removed from the face proved to be basal cell carcinomas. Islands of basaloid cells showing prominent peripheral palisading were seen in the dermis as well as budding from the epidermis. Biopsy of a follicular lesion from the left elbow did not show any abnormalities. The epidermis and dermis were normal. In multiple sections through the block, two small hair-containing follicles of the vellus type were seen. Sebaceous glands were present and normal in structure. Elastic fibers (Verhoeff stain) were normal in structure and quantity on light microscopy.

Case 2.—Three of the four lesions removed from the face proved to be basal cell carcinomas. One of these lesions showed considerable differentiation towards hair follicles and could not be histologically distinguished from a trichoepithelioma. The fourth lesion was an intradermal nevus. The biopsy of a follicular lesion from the dorsum of the left hand showed no abnormalities of the epidermis or dermis. One small, hair-containing follicle of the vellus type was seen. The sebaceous gland associated with this follicle was normal in structure. Elastic fibers (Verhoeff stain) were normal in structure and quantity on light microscopy.

COMMENT

The distinctive clinical picture of

Fig 2.—Hands (case 1). Multiple "ice-pick mark" pattern with exaggerated follicular funnels.

Fig 3.—Elbows (case 1).



Fig 4.—Face (case 1). Multiple pigmented papules that are histologically basal cell carcinomas.

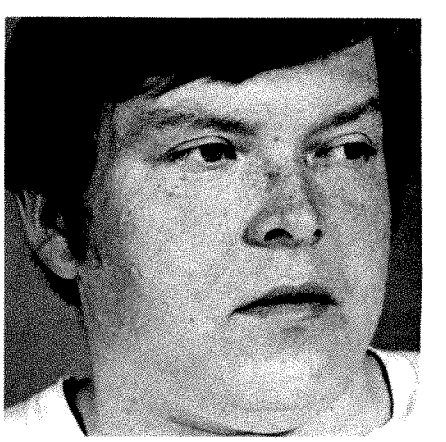

Fig 5.—Face (case 2). Pigmented papules and milia.

follicular atrophoderma should not be confused with any other entity. The skin lesions (Fig 2, 3, and 6) have been variously described as ice-pick marks,[3] dimples, which make the skin look vermiculate,[4] and depressions in the skin in a funnel shape around the pilosebaceous orifices.[2] We suggest the term "multiple ice-pick marks" to describe multiple lesions in one area, and the term "exaggerated follicular funnels" to describe individual lesions. In all seven of our patients, these follicular lesions were confined with remarkable regularity to the dorsum of the hands and the elbows. Bazex et al[2] described lesions not only on the hands, feet, and elbows, but also on the face. In the cases presented by Bazex et al[2] and in our current series, there was no history of preceding inflammatory skin disease involving any of the affected areas. The mother of patients 1 and 2 gave emphatic support to her observation of the skin changes in her newborn sons. Our other five subjects and those of Bazex et al[2] have had the lesions of follicular atrophoderma recognized early in life, but there is no certainty about the congenital nature of these lesions.

Despite the striking clinical appearance of the follicular lesions, no consistent histologic picture of follicular atrophoderma has emerged. Although no definite histologic abnormalities were noted in our biopsies, previous reports have mentioned absence of the hair follicle below the sebaceous gland level,[1] a normal pilosebaceous structure with flattening of the epidermis at the base of the pit,[2] and questionable edema and atrophy of the hair follicle with focal epidermal atrophy.[5]

As noted by Bazex et al,[2] the term "follicular atrophoderma" is not appropriate since there is neither clinical nor histologic evidence of definite atrophy of either the dermis or epidermis. Rather, the follicular ostium seems deeper and more lax than is usually seen; however, this term has become established in the literature. We also did not find any evidence of atrophy of either the epidermis or dermis. We found small superficial vellus type hair follicles that appeared normal in structure on light microscopy. No abnormalities of the elastic fibers were noted.

Basal cell carcinomas developed on the face between the ages of 15 and 26 in five of our seven subjects. The lesions are clinically indistinguishable from nevocellular nevi (Fig 4 and 5). Most common on the central facial area and eyelids, these basal cell carcinomas are morphologically and histologically identical to the lesions seen in the nevoid basal cell carcinoma syndrome (Gorlin syndrome).[3] Cases 6 and 7, ages 20 and 21, have not yet developed any basal cell carcinomas. The number of new lesions seems to decrease after age 30. None of the abnormalities associated with the nevoid basal cell carcinoma were seen in our cases except for scoliosis in case 3 and multiple milia in case 2. Skeletal abnormalities were sought but not

Fig 6.—Hands (case 2).

found. None of our patients had palmar or plantar pits or a positive Albright sign.

Anhidrosis involving the entire face and head was present in five subjects. Even after considerable physical exertion, these patients have not observed sweat formation above the neck. One patient had anhidrosis localized to the face with sparing of the forehead. In only one subject was sweating normal in all areas of the body. Generalized hypohidrosis of moderate degree was reported in three patients. Unfortunately, we did not have the opportunity to verify this finding by objective testing.

The fourth component of this syndrome, hypotrichosis, was not observed in any of our patients. We did find that the areas involved by follicular atrophoderma showed scattered fine vellus hairs and very few terminal hairs. Bazex et al[2] found hypotrichosis in all six of his subjects with varying degrees of alopecia in the scalp and eyebrow areas. The hair shafts were thin, lusterless, and chestnut colored. Body hair was thin and replaced by a down.

The lesions of follicular atrophoderma are of particular significance in that there has been only one case reported in the literature of follicular atrophoderma as an apparently isolated defect.[4] However, this patient also had keratosis pilaris and punctate keratoderma of the palms and soles. Other reported cases excluding those described by Bazex et al and our present series have been associated with the cutaneous and systemic abnormalities of Conradi disease. This rare multisystem syndrome is thought to be inherited as an autosomal recessive. According to Tasker et al,[5] the constant signs of this syndrome are saddle nose deformity, hypertelorism, frontal bossing, high-arched palate, short neck, and short stature with a diagnostic, radiologic hallmark of epiphyseal stippling seen during the first year of life. In fact, the term follicular atrophoderma was coined by Miescher[6] to describe the characteristic skin lesions seen in a 7-year-old girl with Conradi disease. In Conradi disease, the lesions of follicular atrophoderma seem to follow an inflammatory skin eruption present at birth. In the case reported by Bodian,[7] the follicular lesions appeared at about the age of 7 months. It is interesting that in our subjects, a skin eruption diagnosed as eczema was also present at birth or within the first few days of life. Although its exact nature is unclear, this dermatitis was definitely limited to the face and did not involve the areas of follicular atrophoderma. It is also likely that the lesions of follicular atrophoderma were present at birth in our subjects.

Nevoid basal cell carcinoma syndrome, Conradi disease, and the Bazex syndrome are separate entities; however, similarities among these entities exist. It is interesting to note that frontal bossing, hypertelorism, and a broad nasal root are constant signs in Conradi disease.[8] These same abnormalities have also been associated with the nevoid basal cell carcinoma syndrome.[9] Follicular atrophoderma, hypotrichosis, and areas of alopecia are associated with Conradi disease as well as the Bazex syndrome.

Analysis of the pedigree (Fig 1) of the Bazex syndrome clearly shows a pattern of dominant inheritance. Our findings would be compatible with an x-linked dominant pattern in that all daughters of the affected male subject were affected and none of his sons. The fact that no male-to-male transmission was seen in the pedigree published by Bazex et al[2] would also support an x-linked dominant pattern. However, in view of the small number of reported cases, the more common autosomal dominant pattern cannot be excluded. Future follow up of the affected male progeny would help clarify this point.

We have described seven additional cases of a rare, dominantly inherited syndrome consisting of follicular atrophoderma, basal cell carcinomas, localized anhidrosis and/or generalized hypohidrosis, and hypotrichosis. This syndrome may be related to both Conradi disease and the nevoid basal cell carcinoma syndrome.

References

1. Bazex A, Dupre A, Christol B: Genodermatose complexe de type indetermine associant une hypotrichose, un etat atrophodermique generalise et des degenerescences cutanees multiples (epitheliomas-baso cellulaires). *Bull Soc Fr Dermatol Syphiligr* 71:206, 1964.
2. Bazex A, Dupre A, Christol B: Atrophodermie folliculaire, proliferations baso-cellulaires et hypotrichose. *Ann Dermatol Syphiligr* 93:241-254, 1966.
3. Braun-Falco O, Marghescu S: Uber eine systematisierte follikulare atrophodermie mit keratosis palmoplantaris dissipata und keratosis follicularis. *Hautarzt* 18:13, 1967.
4. Ollendorff-Curth H: Follicular atrophoderma and pseudopelade associated with chondrodystrophia calcificans congenita. *J Invest Dermatol* 13:233-247, 1949.
5. Tasker WG, Mastri AR, Gold AP: Chondrodystrophia calcificans congenita (dysplasia epiphysalis punctata). *Am J Dis Child* 119:122-127, 1970.
6. Miescher G: Atypische chondrodystrophie, typus morguino, kombiniert mit follikulare atrophodermie. *Dermatologica* 89:38-40, 1944.
7. Bodian EL: Skin manifestations of Conradi's disease. *Arch Dermatol* 94:743-748, 1966.
8. Gorlin RJ, Goltz RW: Multiple nevoid basal cell epitheliomas, jaw cysts and bifid rib: A syndrome. *N Engl J Med* 262:908-912, 1960.
9. Berlin NI, et al: Clinical staff conference: Basal cell nevus syndrome. *Ann Intern Med* 64:403-421, 1966.

Pseudomonal Balanitis

John W. Petrozzi, MD, Alexander Erlich, MD

• **Significant ecologic changes in the cutaneous flora during treatment may present a challenge both diagnostically and therapeutically. The development of an erosive balanitis due to *Pseudomonas aeruginosa* presented an example of such a microbiologic shift in the case reported. The eruption developed during treatment with topical antibacterial, antifungal, and corticosteroid agents. The sudden exacerbation of any balanitis while under treatment should alert the physician to the possibility of superinfection.**

(*Arch Dermatol* 113:952-953, 1977)

The following case discloses an infrequently reported cause of balanitis—*Pseudomonas aeruginosa*. The development of this potentially threatening infection during the course of treatment with various topical antibacterial, antifungal, and corticosteroid agents emphasizes the need to keep ecological principles in mind when dealing with cutaneous infections.

REPORT OF A CASE

A sexually active, 29-year-old man reported to the Philadelphia Veterans Administration (VA) Hospital on repeated occasions because of various penile eruptions, initially with scabies. Except for a few persistent nodules on the scrotum, he responded well to gamma benzene hexachloride lotion. Thereafter, several mollusca contagiosa appeared on the penile shaft. These were curetted without difficulty.

While using betamethasone valerate cream to the scabetic nodules he developed a few condylomata acuminata on the penile shaft. These responded to full-strength trichloroacetic acid with complete healing.

A few weeks later he was seen by his doctor, with pruritic superficial erosions on the glans penis. No preceding vesicles were recounted. A cream containing triamcinolone acetonide, neomycin sulfate, gramicidin, and nystatin (Mycolog) was used over a two-week period without benefit. He was then given amphotericin B lotion, again without response. Finally, idochlorhydroxyquin 3% hydrocortisone 1% cream was administered. However, while using the cream he suddenly developed the explosive onset of a painful, deep erosive balanitis (Figure). He continued to be treated with numerous topical steroid creams, with progression of the balanitis. Finally, cultures were taken at the Philadelphia VA Hospital, which revealed a heavy growth of *P aeruginosa* sensitive to gentamicin. Cool saline compresses and gentamicin sulfate cream afforded 50% improvement within a week. At that time a circumcision was performed at the patient's request, and further healing was completed over the following week. The patient was never febrile and did not manifest any systemic symptoms during the course of his disease.

Laboratory tests showed the following to be normal: complete and differential blood cell counts, urinalysis results, six- and 12-factor automated blood chemistry studies, two-hour postprandial blood glucose levels, chest roentgenogram, and VDRL test results.

COMMENT

This case discloses a diverse group of penile lesions that are frequently encountered in the sexually active male, ie, scabies, mollusca contagiosa, condylomata acuminata, and a balanitis.

The common causes of balanitis are trauma, contact irritant, or allergic dermatitis and infection. Other diseases that must be considered include plasma cell balanitis, Reiter syn-

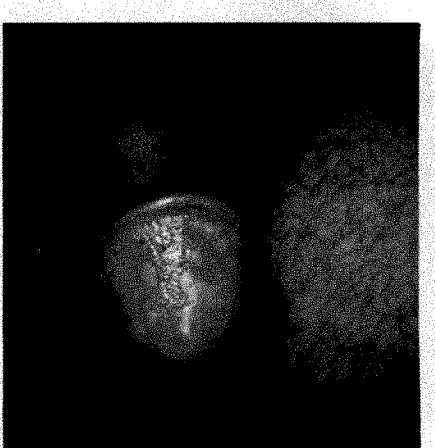

Erythema, maceration, and erosive changes on glans penis.

Accepted for publication May 17, 1976.

From the Department of Dermatology, School of Medicine, University of Pennsylvania, and the Veterans Administration Hospital, Philadelphia.

Reprint requests to Department of Dermatology, Veterans Administration Hospital, University and Woodland Avenues, Philadelphia, PA 19104 (Dr Petrozzi).

drome, Behçet syndrome, erythema multiforme, cicatricial pemphigoid, fixed drug reactions, erythroplasia of Queyrat, and other malignant disorders.

Of the infectious agents, *Candida albicans* and herpes simplex are the most commonly encountered sources. However, syphilis, chancroid, and tuberculosis as well as amebic, trichomonal, staphylococcal, fusospirochetal, streptococcal, and gonococcal organisms can produce a balanitis. Surprisingly, a review of the literature revealed little mention of *Pseudomonas* as a cause of balanitis.

Our patient was under treatment for several weeks, with little improvement in his balanitis. However, the sudden, explosive exacerbation of the balanitis signaled a notable change in the course of his disease. Important was the fact that it occurred while he was being treated with topical steroids, antibacterial agents, and anticandida preparations. This is similar to the experience with several dermatologic entities.

In Gram-negative folliculitis, acne patients undergoing long-term treatment with systemic antibiotics suddenly develop recalcitrant pustules and deep nodules due to resistant *Proteus* and *Aerobacter-Klebsiella* organisms that have replaced the previous bacterial flora.[1] Not infrequently in these cases, there are explosive eruptions when antibiotics are changed or administered.

In the treatment of Hailey-Hailey disease, similar problems develop. Prolonged antibacterial treatment leads to superinfection with *Candida*, and vice versa. Hidradenitis suppurativa and "athlete's foot" yield the same problems.[2]

We think that the use of topical steroid, antibacterial, and anticandida agents in this case led to colonization with *P aeruginosa*, which subsequently became invasive, leading to a severe erosive balanitis. The enhanced colonization of *Pseudomonas* after removal of the Gram-positive flora has been well demonstrated by Taplin et al.[3] Since *Pseudomonas* may be an occupant of the lower bowel in 1% of the nonhospitalized population, fecal contamination is the likely source of infection in this case.

The severity of the balanitis reflects the ability of *Pseudomonas* to produce potent exotoxin as well as proteolytic, elastolytic, lipolytic, and collagenolytic enzymes.[5] The destructive cutaneous effect of chronic *Pseudomonas* infection was evident in the case of severe otitis externa recently described in the dermatology literature by Petrozzi and Warthan.[6] Fortunately, since we were dealing with a healthy patient and the eruption was still of recent onset, a beneficial response could be obtained with topical measures.

The lack of prior communications dealing with pseudomonal balanitis may reflect the rarity of such an occurrence, inadequate diagnosis, or simply a failure of reporting it. We describe our case to increase clinical awareness of this entity, particularly since early diagnosis is essential in light of the potential destructiveness of this organism. In view of the many genital diseases being encountered today by dermatologists and the frequent use of topical steroids, antibiotics, and anticandida agents, any case of severe unresponsive balanitis should receive proper microbiologic study to eliminate *Pseudomonas* as the source of infection.

Schering Corp, Bloomfield, NJ, provided the grant that allowed reproduction of the color photograph.

Nonproprietary Names and Trademarks of Drugs

Amphotericin B—*Fungizone.*
Gentamicin sulfate—*Garamycin.*

References

1. Fulton JE Jr, McGinley K, Leyden J, et al: Gram-negative folliculitis in acne vulgaris. *Arch Dermatol* 98:349-353, 1968.
2. Leyden JJ, Marples RR: Ectologic principles and antibiotic therapy in chronic dermatoses. *Arch Dermatol* 107:208-211, 1973.
3. Taplin O, Zaias N, Rebell G: Environmental influences on the microbiology of the skin. *Arch Environ Health* 2:546-550, 1965.
4. Wysocki JP, Grant S, McGarity G, et al: The role of wounds in the epidemiology of nosocomial infections due to *Pseudomonas aeruginosa*. *Invest Urol* 11:370-373, 1974.
5. Hall JH, Callaway JL, Tindall JP, et al: *Pseudomonal aeruginosa* in dermatology. *Arch Dermatol* 97:312-324, 1968.
6. Petrozzi JW, Warthan TL: Malignant external otitis. *Arch Dermatol* 110:258-260, 1974.

Congenital Sensory Neuropathy

Report of an Atypical Case

John R. Person, MD; Roy S. Rogers III, MD; K. Hable Rhodes, MD

• **An otherwise normal 11-year-old boy had greatly reduced acral pain and temperature sensation with associated trophic damage. The disorder was present at birth, and there was no family history of similar problems. The patient also exhibited complete anhidrosis. The case may be an "overlap" between what has been termed as hereditary sensory neuropathy (HSN) type 2 and type 4.**

(*Arch Dermatol* 113:954-957, 1977)

The onset of an acquired peripheral neuropathy is usually obvious to the adult patient who can perceive the change and verbalize his problem. The onset of many of the hereditary sensory neuropathies (HSNs), however, is at birth. The patient usually has recurrent acral skin ulcers and a history of repeated injuries that may progress to substantial deformity before the correct diagnosis is made. When the trophic damage is mild and largely cutaneous, it is common for these patients to be examined by a dermatologist.

We report a case of congenital sensory neuropathy, which was encountered recently at the Mayo Clinic. Although typical in presentation, the case differs in some respects from previously reported cases.

Accepted for publication May 3, 1976.

From the Mayo Clinic and Mayo Foundation, Rochester, Minn.

Reprint requests to c/o Section of Publications, Mayo Clinic, 200 First Street SW, Rochester, MN 55901 (Dr Person).

REPORT OF A CASE

A healthy-appearing, 11-year-old boy was seen initially in this clinic in August 1975 with a history of hyperkeratotic fingers and toes, and intermittent, nonpainful, and poorly healing ulcers of the same areas. He had been the product of a normal spontaneous vaginal delivery and had seemed to be normal at birth. He had been entirely healthy otherwise, but was described by his mother as unathletic and clumsy. His intelligence and progress in school were normal. Numerous evaluations had centered previously on an infectious or immunologic cause for the recurrent ulcerations, but none had been found. The patient had received various systemic antibiotics and topical preparations for the recurrent, infected ulcers. In summer 1975, a dermatologist in the patient's hometown detected a probable neurologic deficit in pain perception in the acral extremities and suggested that the patient's hands and feet be vigorously protected. Three months later the patient came to this clinic.

Initial examination showed a well-developed and well-nourished boy in no distress. His weight was 39.5 kg, his height was 147 cm, and his blood pressure was 90/50 mm Hg. The fingers and toes were hyperkeratotic and slightly fissured, and a healing 1-cm ulcer was noted on one finger (Fig 1 and 2). Decreased acral pain perception but normal touch perception was found.

The patient was examined in the Department of Dermatology, where the ulcer and hyperkeratosis were thought to be entirely consistent with neurotrophic damage. Results of a potassium hydroxide test of scales were negative for the presence of superficial fungi.

The patient was seen in the Department of Neurology, where examination demonstrated loss of superficial pain and, to a lesser extent, temperature in an acral distribution, including the hands, wrists, feet, and ankles. Pain sensation was minimal in the digits, but gradually increased as testing proceeded proximally, becoming normal at the levels of the midthighs and antecubital fossae. Results of the neurologic examination were otherwise noncontributory.

A detailed family history did not reveal any Jewish ancestry or consanguinity; a dubious revelation indicated that a maternal great-grandfather had been "sickly" and "had to protect his hard hands." The patient had one normal brother.

The following laboratory tests gave results within the normal ranges: ESR (Westergren method), cholesterol, triglycerides, serum protein electrophoresis, complete blood cell count, platelet count, SGOT, total hemolytic complement, serum IgE, and urinalysis. Values for serum alkaline phosphatase and serum phosphate were elevated but were consistent with normal bone growth. A 24-hour specimen of urine tested for amino acids was largely within normal limits. Results of a CSF examination showed normal values for glucose, protein, and cell counts; the VDRL test for syphilis on the CSF was negative.

Fig 1.—The patient's hands.

A roentgenogram of the chest showed a congenital dysplastic first left rib, and a roentgenogram of the cervical portion of the spinal column did not show any evidence of abnormality. Destruction of the left second middle and all distal phalanges, with soft tissue swelling of the right third digit, was evident on roentgenograms of the hands, and those of the feet showed resorption of the distal phalanges of the right foot, with soft tissue swelling of the first three digits.

Electromyography showed normal motor conduction in the right arm and leg, but sensory studies showed small amplitude-evoked responses to orthodromic and antidromic stimulation of the ulnar and median nerves. Response latency and conduction velocity were normal. Sural nerve responses were minute distally. Results of a needle examination of two distal muscles were normal. The interpretation was "consistent with a sensory peripheral neuropathy. The fact that sensory conduction velocity and distal latencies are normal would favor axonal involvement rather than demyelination."

Sweat testing showed complete anhidrosis. Results of audiometric testing were within the normal range. A sural nerve biopsy specimen showed depletion of fibers on which regeneration could not be ruled out, but no obvious qualitative abnormalities were present.

Quantitative sensory testing was performed and showed the affected areas to be borderline-normal in touch discrimination, in the second percentile in temperature discrimination, and below the second percentile in pain discrimination. Pain perception, however, was present in all areas tested. Compound action-potential testing showed a small but well-developed A-alpha and a reduced C-fiber potential; no A-gamma potential was present.

Testing of the patient's brother and parents showed normal pain, temperature, and touch discrimination normal electromyograms; and normal results of sweat tests. The patient's paternal aunt showed mild abnormalities in thermal discrimination, which were thought to be the result of the hurried nature of that particular examination; the other sensory modalities were within the normal ranges.

The patient and his parents were counseled at length in the necessity for scrupulous local care, avoidance of trauma, and aggressive treatment of infections of the hands and feet. The techniques suggested have been recommended by the Public Health Service Hospital in Carville, La, for use in the treatment of lepromatous neuropathy.[1]

Fig 2.—The patient's feet.

COMMENT

The congenital sensory radiculopathies and neuropathies are a diverse and confusing group of disorders (Table). The first cases probably were reported in 1852 by Nélaton,[2] who noted the occurrence of perforating foot ulcers in several members of one family. Many cases have been re-

Congenital and Hereditary Sensory Neuropathies

Type	Hereditary Sensory Radicular Neuropathy[6-13]	Nonprogressive Sensory Radicular Neuropathy[19]	Congenital Sensory Neuropathy[14-18]	Familial Dysautonomia[20]	Congenital Sensory Neuropathy with Anhidrosis[23-26]	Present Case
Ohta's classification	HSN type 1	None	HSN type 2	HSN type 3	HSN type 4	...
Onset	Second decade	Birth	Birth	Birth	Birth	Birth
Course	Progressive	Nonprogressive	May progress	May improve	Progressive	?
Heredity	Autosomal dominant	? (sporadic)	Autosomal recessive	Autosomal recessive	Autosomal recessive	?
Intelligence	Normal	Normal	Normal	Often retarded	Often retarded with delayed motor development	Normal
Distribution of sensory loss	Distal	Distal	Distal	Generalized	Generalized	Distal
Pain	↓↓*	↓↓	↓*	↓	↓↓	↓↓↓*
Temperature	↓↓↓	↓↓	↓	±†	↓	↓↓
Touch	↓	↓↓	↓↓	Normal	Normal	Normal
Tendon reflexes in affected areas	↓	↓	Rarely ↓	↓	↓	Normal
Sweating	Normal	Normal	Normal	↑‡	Absent	Absent
Flare to histamine	Absent	Normal	Absent	Absent	Absent	Not tested
Pathologic findings	Loss of ganglion cells and unmyelinated fibers	Loss of myelinated fibers	Loss of myelinated fibers	Demyelination of posterior columns	Absent sensory fibers in Lissauer's tract	Loss of myelinated and unmyelinated fibers
Miscellaneous	Possible deafness	Hypotonia at birth		Absent fungiform and circumvallate papillae, drooling, decreased lacrimation	Possible fever	

* One arrow indicates decreased somewhat; two arrows, decreased substantially; and three arrows, decreased severely.
† Indicates may or may not be affected.
‡ Arrow indicates increased somewhat.

ported[3-5] since that time, but most have lacked the pathologic and physiologic studies now considered appropriate. Hicks[6] reported one of the most extensive series of cases in 1922. He described ten members in a family of 34 members, spanning four generations, who had shooting pains in the legs, deafness, and perforating ulcers on the feet, which progressed to foot deformity. In affected areas, loss of temperature sensation exceeded loss of pain, and touch was least affected. Involvement of the lower extremities was more extensive than that of the upper extremities. The disorder became evident in the second decade or later and was inherited as an autosomal dominant.

A family with similar disorders was described by Thévenard[7] in 1942, and the disorder has occasionally been referred to as Thévenard syndrome. In 1951, Denny-Brown[8] studied, at autopsy, an affected member of the family reported by Hicks. He found primary degeneration of the dorsal root ganglia with unmyelinated fibers more seriously affected than myelinated fibers. He termed the disorder "hereditary sensory radicular neuropathy."

Although the disorder is a radiculopathy, clinical differentiation of it and of a peripheral neuropathy may be impossible. Motor involvement is variable but usually is mild; the peroneal muscles are affected most commonly. Deafness has not been a feature[7-13] except in the cases reported by Hicks.[6] Ohta and his associates[14] referred to this disorder as HSN type 1 to distinguish it from the recessively inherited sensory neuropathy that they studied in a large Quebec kinship and termed HSN type 2. In the latter cases the onset was a birth, lancinating pains were absent, and sensory loss was generalized but accentuated acrally. Loss of touch was greater than that of pain and temperature, and there was no motor involvement. A peripheral nerve biopsy specimen showed an almost total absence of myelinated fibers in the affected areas. The cases of Winkelmann et al,[15] of Johnson and Spalding,[16] of Heller and Robb,[17] and of Schoene et al[18] probably were of this type.

Other authors have described a recessively inherited sensory loss, present from birth, associated with generalized anhidrosis. Fever may be a prominent symptom. The patients usually are retarded and, at autopsy, have shown an absence of primary sensory nerves in Lissauer's tract and dorsal root ganglia. Pain perception is absent, temperature perception is reduced, and touch is normal. Skin biopsy specimens show normal-appearing sweat glands, and sural nerve biopsy specimens show normal myelination. Ohta et al[14] refer to this disorder as HSN type 4.

Ogden and his colleagues[19] have described a recessive or perhaps nonfamilial radicular neuropathy, which differs from HSN type 1 in its inheritance, its presence at birth, and its lack of progression. It is also the

only one of the hereditary neuropathies to show a normal "flare" response to intradermal histamine administration. Biopsy specimen of an affected nerve shows a loss of myelinated fibers.

Familial dysautonomia, first described by Riley and his associates,[20] is a recessively inherited disorder, which is present at birth, and occurs with increased incidence among Jews. The patients are usually retarded and they exhibit drooling, defective lacrimation, and acrocyanosis. Erythematous mottling usually occurs with heat or emotional stress. A generalized reduction in pain perception is often reported and temperature sensation may be reduced; with time, these sensations may become more normal. Sweating is increased. Fungiform and circumvallate papillae are absent from the tongue. At autopsy, demyelination of the posterior columns and dorsal root fibers is found.[21] Ohta et al[14] refer to dysautonomia as HSN type 3.

These neuropathic disorders are to be distinguished from various other conditions.[8,13,15] In congenital indifference to pain, the patient from birth can perceive painful stimuli but does not interpret them as unpleasurable. Autopsy studies, in such cases, have not shown any obvious anatomic defects.[22] In asymbolia, a lesion of the parietal lobe is responsible for an acquired indifference. Hysteria or psychic states can occur similarly. In syringomyelia, the arms and hands are unresponsive to pain and temperature, but other sensations are intact, muscle atrophy is present, and the lower extremities are spared. The onset is in young adulthood. The disorder is caused by a fluid-filled cavity in the central gray matter of the spinal cord, which interferes with discussating fibers in the cord. The cause of syringomelia is unknown and it is rarely familial. Also to be differentiated are the hereditary chronic interstitial neuritis of Déjérine-Sottas disease, which involves both motor and sensory function and results in palpably enlarged nerves, and the various acquired peripheral neuropathies of toxic, infectious, or metabolic origin.

Our case does not fit readily into any of the described syndromes, but it probably is best classified as an "overlap" between congenital sensory neuropathy (HSN type 2) and congenital sensory neuropathy with anhidrosis (HSN type 4).

Quantitative sensory testing was performed in the laboratory of Dr Peter James Dyck.

References

1. Trautman JR, Enna CD: Leprosy, in Tice F (ed): *Practice of Medicine*. New York, Harper & Row Publishers Inc, 1971, vol 3, pp 1-38.
2. Nélaton A: Affection singulière des os du pied. *Gaz Hop* 25:13, 1852.
3. Bruns: Familialer symmetrischer Gangrän und Arthropathie an den Füssen, möglicherweise beruhend auf familiärler Syringomyelie im Lumbosacralmarke. *Neurol Zentralbl* 22:599-602, 1903.
4. Schultze F: Familiär auftretendes Malum Perforans der Füsse (familiäre lumbale Syringomyelie?). *Dtsch Med Wochenschr* 43:545-547, 1917.
5. Smith EM: Familial neurotrophic osseous atrophy: A familial neurotrophic condition of the feet with anesthesia and loss of bone. *JAMA* 102:593-595, 1934.
6. Hicks EP: Hereditary perforating ulcer of the foot. *Lancet* 1:319-321, 1922.
7. Thévenard A: L'acropathie ulcéro-mutilante familiale. *Rev Neurol (Paris)* 74:193-212, 1942.
8. Denny-Brown D: Hereditary sensory radicular neuropathy. *J Neurol Neurosurg Psychiatry* 14:237-252, 1951.
9. Mandell AJ, Smith CK: Hereditary sensory radicular neuropathy. *Neurology (Minneap)* 10:627-630, 1960.
10. Pallis C, Schreeweiss J: Hereditary sensory radicular neuropathy. *Am J Med* 32:110-118, 1962.
11. Teppeiner J: Familiäre Akroosteolyse mit trophischen Hautgeschwüren. *Wien Klin Wochenschr* 76:523-526, 1964.
12. Dyck PJ, Kennel AJ, Magal IV, et al: A Virginia kinship with hereditary sensory neuropathy, peroneal muscular atrophy, and pes cavus. *Mayo Clin Proc* 40:685-694, 1965.
13. Moschella SL, Wire GE: Sensory radicular neuropathy of the hereditary type: A case report. *Arch Dermatol* 94:449-453, 1966.
14. Ohta M, Ellefson RD, Lambert EH, et al: Hereditary sensory neuropathy type II: Clinical, electrophysiologic, histologic, and biochemical studies of a Quebec kinship. *Arch Neurol* 29:23-37, 1973.
15. Winkelmann RK, Lambert EH, Hayles AB: Congenital absence of pain: Report of a case and experimental studies. *Arch Dermatol* 85:325-338, 1962.
16. Johnson RH, Spalding JMK: Progressive sensory neuropathy in children. *J Neurol Neurosurg Psychiatry* 27:125-130, 1964.
17. Heller IH, Robb P: Hereditary sensory neuropathy. *Neurology (Minneap)* 5:15-29, 1955.
18. Schoene WC, Asbury AK, Åström KE, et al: Hereditary sensory neuropathy: A clinical and ultrastructural study. *J Neurol Sci* 11:463-487, 1970.
19. Ogden TE, Robert F, Carmichael EA: Some sensory syndromes in children: Indifference to pain and sensory neuropathy. *J Neurol Neurosurg Psychiatry* 22:267-276, 1959.
20. Riley CM, Day RL, Greeley DMcL, et al: Central autonomic dysfunction with defective lacrimation: I. Report of five cases. *Pediatrics* 3:468-478, 1949.
21. Fellner MJ: Manifestations of familial autonomic dysautonomia: Report of a case, with an analysis of 125 cases in the literature. *Arch Dermatol* 89:190-195, 1964.
22. Magee KR: Congenital indifference to pain: An anatomicopathologic study. *Arch Neurol* 9:635-640, 1963.
23. Gillespie JB, Perucca LG: Congenital generalized indifference to pain (congenital analgia). *Am J Dis Child* 100:124-126, 1960.
24. Swanson AG, Buchan GC, Alvord EC Jr: Anatomic changes in congenital insensitivity to pain: Absence of small primary sensory neurons in ganglia, roots, and Lissauer's tract. *Arch Neurol* 12:12-18, 1965.
25. Pinsky L, DiGeorge AM: Congenital familial sensory neuropathy with anhidrosis. *J Pediatr* 68:1-13, 1966.
26. Vassella F, Emrich HM, Kraus-Ruppert R, et al: Congenital sensory neuropathy with anhidrosis. *Arch Dis Child* 43:124-130, 1968.

SOLBAR®

Shuns UVB and UVA —

SOLBAR®

Contains Water Insoluble Benzophenones.

Aids in Preventing
Wrinkling, Freckling and Drying
due to overexposure to the sun.

PERSŌN & COVEY INC.
GLENDALE, CALIF. 91201

NOCIN Minocycline HCl
al and Intravenous Brief Summary
ntraindications: Hypersensitivity to any tetracycline.
arnings: Intravenous use, particularly in pregnancy, in daily ıses exceeding 2 grams has been associated with deaths rough liver failure. When need for intensive treatment outeighs potential dangers, perform renal and liver function tests ıfore and during therapy; also follow serum concentrations. In nal impairment, usual doses may lead to excessive accumulaon and liver toxicity. Under such conditions, use lower total ıses, and, in prolonged therapy, determine serum levels. This ızard is of particular importance in I.V. use in pregnant or ıstpartum patients with pyelonephritis. In such cases, the blood vel should not exceed 15 mcgm/ml, and liver function tests ıould be made at frequent intervals. Do not prescribe other cyclines during tooth development (last half of pregnancy, infancy and childhood to the age of 8 years) may cause permanent discoloration of the teeth (yellow-gray-brown). This is more common during long-term use but has been observed following repeated short-term courses. Enamel hypoplasia has also been reported. Tetracyclines, therefore, should not be used in this age group unless other drugs are not likely to be effective or are contraindicated. Photosensitivity manifested by an exaggerated sunburn reaction has been observed in some individuals taking tetracyclines. Advise patients apt to be exposed to direct sunlight or ultraviolet light that such reaction can occur, and discontinue treatment at first evidence of skin erythema. Studies to date indicate that photosensitivity is rarely reported with MINOCIN *Minocycline HCl*. In patients with significantly impaired renal function, the antianabolic action of tetracycline may cause an acidosis. CNS side effects (lightheadedness, dizziness, vertigo) have been reported, may disappear during therapy, and always disappear rapidly when drug is discontinued. Caution patients who experience these symptoms about driving vehicles or using hazardous machinery while taking this drug. **Pregnancy:** In animal studies, tetracyclines cross the placenta, are found in fetal tissues, and can have toxic effects on the developing fetus (often related to retardation of skeletal development). Embryotoxicity has been noted in animals treated early in pregnancy. **Newborns, infants and children:** All tetracyclines form a stable calcium complex in any bone-forming tissue. Prematures, given oral doses of 25 mg./kg. every 6 hours, demonstrated a decrease in fibula growth rate, reversible when drug was discontinued. Tetracyclines are present in the milk of lactating women who are taking a drug in this class

Staph infection: Skin deeper

When the patient is penicillin-hypersensitive, when bacteriologic testing shows *Staph. aureus* to be resistant or the infection has proved unresponsive, MINOCIN *Minocycline HCl* may be an effective alternative.* Clinical studies have demonstrated satisfactory response in 156 of 173 simple or mixed skin and soft tissue infections due to staphylococci.

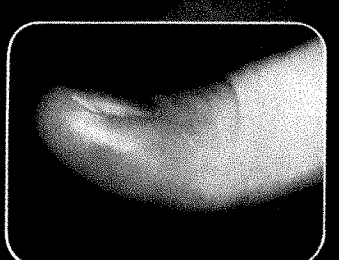

Actual patient photograph after 7 days of MINOCIN.

MINOCIN®
MINOCYCLINE HCl

CAPSULES 50 mg and 100 mg
SYRUP 50 mg/5 cc
INTRAVENOUS 100 mg/vial

100 or 200 mg initially, 50 mg *q.i.d.* or 200 mg initially, 100 mg *b.i.d.*

*Tetracyclines are not the drugs of choice in the treatment of any type of staphylococcal infection. MINOCIN is indicated for treatment of *Staphylococcus aureus* skin and soft tissue infections only when bacteriologic tests indicate appropriate susceptibility to the drug.

MINOCIN Minocycline HCl
Oral and Intravenous Brief Summary (continued)
organisms, including fungi. If superinfection occurs, institute appropriate therapy. In venereal diseases when coexistent syphilis is suspected, darkfield examination should be done before treatment is started and blood serology repeated monthly for at least four months. Patients on anticoagulant therapy may require downward adjustment of such dosage. Test for organ system dysfunction (*e.g.*, renal, hepatic and hemopoietic) in long-term use. Treat all group A beta-hemolytic streptococcal infections for at least 10 days. Avoid giving tetracycline in conjunction with penicillin.
Adverse Reactions: GI: (with both oral and parenteral use) anorexia, nausea, vomiting, diarrhea, glossitis, dysphagia, enterocolitis, inflammatory lesions (with monilial overgrowth) in anogenital dermatitis (uncommon). Photosensitivity is discussed above ("Warnings"). **Renal toxicity:** rise in BUN, dose-related (see "Warnings"). **Hypersensitivity reactions:** urticaria, angioneurotic edema, anaphylaxis, anaphylactoid purpura, pericarditis, exacerbation of systemic lupus erythematosus. In young infants, bulging fontanels have been reported following full therapeutic dosage, disappearing rapidly when drug was discontinued. **Blood:** hemolytic anemia, thrombocytopenia, neutropenia, eosinophilia. **CNS:** (see "Warnings"). When given in high doses, tetracyclines may produce brown-black microscopic discoloration of thyroid glands; no abnormalities of thyroid function studies are known to occur. **NOTE: Concomitant therapy:** Antacids containing aluminum, calcium, or magnesium impair absorption; do not give to patients taking oral minocycline. Studies to date indicate that absorption of MINOCIN *Minocycline HCl* is not notably influenced by

CNS side effects including lightheadedness, dizziness, or vertigo have been reported with MINOCIN. Patients who experience these symptoms should be cautioned about driving vehicles or using hazardous machinery while on minocycline therapy.

Lederle
LEDERLE LABORATORIES
A Division of American Cyanamid Compar

Historical Review

Hutchinson's *Archives of Surgery* Revisited

Robert Jackson, MD, FRCP(C)

• **I present a brief review of Hutchinson's *Archives of Surgery*. I have listed most of his well-known and not-so-well-known early clinical descriptions. To this list can be added descriptions of Peutz-Jegher syndrome, lipomelanic reticulosis, telangiectatic lupus erythematosus, temporal arteritis, and recurrent herpes simplex on the thigh and buttocks.**

The characteristics of Hutchinson's writing are the use of catchy, descriptive terms, his use of patients' names for diseases, his belief in the effectiveness of illustrations, superb clinical observation but faulty conclusions, and a lack of humor. Seventy-two years after his death, there is still much that can be learned about clinical disease from Hutchinson.

(*Arch Dermatol* 113:961-964, 1977)

Jonathan Hutchinson
Born at Selby July 23rd 1828
Died at Haslemere June 23rd 1913
A Man of Hope and Forward Looking Mind
Tombstone, Sir Jonathan Hutchinson
St Bartholomew Churchyard
Haslemere, England

One may wonder why another paper is needed on Sir Jonathan Hutchinson (Fig 1). His medical bibliography totals almost 1,200 items, and there have been numerous personal and scientific articles published on his life and scientific reports.[1-3] However, the writings of this most amazing man are a gold mine of clinical information, and, like any mine, have to be continually worked in order that one may extract everything of value from them.

The source for the content of this paper is mainly the 11 volumes of Hutchinson's *Archives of Surgery*, published between 1889 and 1900.[4] I use the possessive Hutchinson's correctly—he wrote every word himself. These volumes form the heart of his medical bibliography.

The purpose of this article is to point out several early descriptions of clinical disease that can be found in these 11 volumes. These early descriptions have not generally been accredited to Hutchinson. Identification of priority in medicine is usually a difficult and not too profitable pursuit. However, Hutchinson's technique of observation and description of these conditions is so neat that it needs to be repeatedly held up as an example in this very complex medical world of what can be learned by simple clinical observation and clear, lucid, short description. In addition to a reproduction of some of his probable "firsts," some general comments are made on his technique of observing and recording, and on his personal life and accomplishments.

DESCRIPTIONS OF CLINICAL CONDITIONS

Many descriptions of clinical conditions have been found in Hutchinson's writings. Some of these are probably firsts, but even if they are not, his excellent writing and drawings and prominence in medical circles of the time have made these descriptions worthy of note.

Well Known

Arsenical keratoses and cancer
Atrophic balanitis (balanitis xerotica obliterans)
Chiropomphylx
Dermatitis gangrenosa infantum (gangrenous varicella or vaccinia)
Hilliard lupus (verrucous lupus erythematosus)
Hutchinson triad of congenital syphilis:
- Screwdriver-shaped notched upper central incisors
- Interstitial keratitis
- Eighth nerve deafness

Hutchinson freckle (lentigo maligna)
Hutchinson recurrent summer eruptions (prurigo aestivalis, hydroa vacciniforme)
Idiopathic calcinosis of the scrotum

Accepted for publication May 21, 1975.
From the Department of Dermatology, Ottawa Civic Hospital and the University of Ottawa, Ontario, Canada.

Reprint requests to 1081 Carling Ave, Suite 508, Ottawa K1Y 4G2, Ontario, Canada (Dr Jackson).



Fig 1.—Color caricature of Jonathan Hutchinson at age of 62 by "Spy" (Sir Leslie Ward). (From *Vanity Fair*, Sept 27, 1890)

Fig 2.—Famous Howard twins. (From *Archives of Surgery*, vol VII, 290, 1896, plate CXLI)

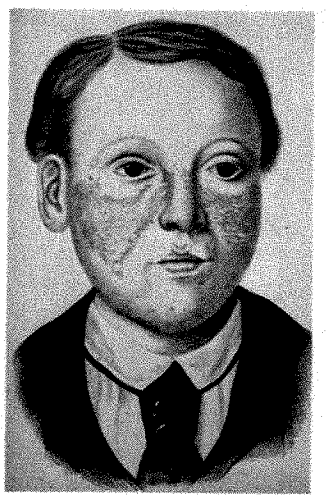

Fig 4.—Telangiectatic lupus erythematosus, the "most superficial type of lupus erythematosus". (From *Archives of Surgery*, vol IV, 384, 1892, plate LXXIV)

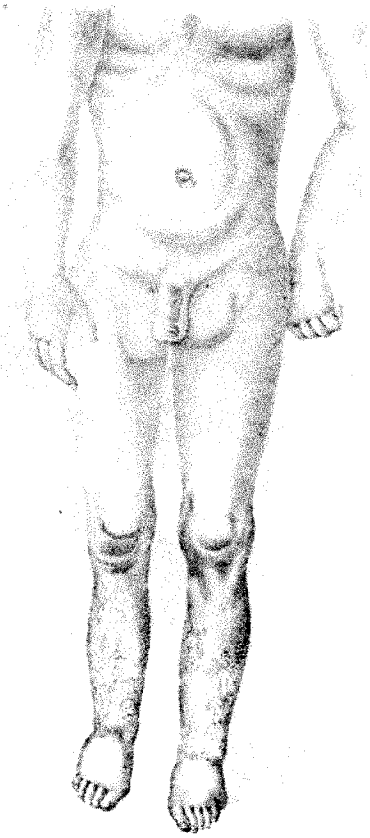

Fig 3.—Hebra's bubo. (From *Archives of Surgery*, vol VII, 377, 1896, plate CLXI)

Infective angioma (angioma serpiginosum)
Melanotic whitlow (malignant melanoma of nail bed)
Mortimer malady (sarcoidosis)
Solid edema of the face (following erysipelas)
Vaccination syphilis
Zoster following trivalent arsenic

Not So Well Known

References are to volume and page number in Hutchinson's Archives of Surgery.

Eczema with liability to bronchitis and asthma (I-160)
Molluscum contagiosum spread in Turkish baths (I-179)
Keloid in vaccination scars (I-197)
Absence of gland implication in rodent ulcer (I-210)
Genital herpes simplex (I-350)
Fixed drug (chloral) (I-plate I)
Lupus lymphaticus (lymphangioma circumscriptum (I-plate XVI))
Tobacco amblyopia (II-151)
Diphtheritic polyneuritis (II-380)
Facial hemiatrophy (III-29)
Acroscleroderma (III-35, X-164)
Phagedenic syphilis (III-105)
Vanilla eczema (IV-49)
Hutchinson freckle (lentigo maligna) of buccal mucosa (IV-61) and prepuce (V-160)
Hives from parsley (IV-78)
Erysipeloid carcinoma (IV-220)
Enlargement of palatal glands (stomatitis nicotina) (IV-263)
Glossitis of the sides of the tongue from amalgam used in filling teeth (IV-318)
Egg "poisoning" (hives) (V-363)
Progeria (VI-140)
Fordyce disease of the lip (VII-195)
Recurrent attacks of labial herpes simplex followed by erythema multiforme (VII-226)
Eczema cancer (extra mammary Paget) (IX-240)
Acne keloid nape of neck (X-232)

PROBABLE FIRSTS

More recently, keratoacanthoma[7] and toxic epidermal necrolysis[8] have been found in his writings. I wish now to illustrate a few more probable "firsts" of Hutchinson.

In many of these, the "first" clinical description has been assigned to other investigators. References to these publications are included in the subtitles.

Peutz-Jegher Syndrome (1921,[10] 1949[11])

Hutchinson clearly illustrated the pigmentation of and about the lips and on the buccal mucosa in twin 9-year old sisters (Fig 2). McKusick[9] and Ingram[8] report that one of the twins was later proved to have polyposis of the small intestine.

Lipomelanotic Reticulosis (Dermatopathic Lymphadenitis, 1932[12])

Under the title of "Hebra's Bubo: the Bubo of Prurigo," Hutchinson describes "soft, flabby enlargement of the glands in Scarpa's triangle, which is met with in chronic cases of prurigo nous eruptions in the legs"[13] (Fig 3).

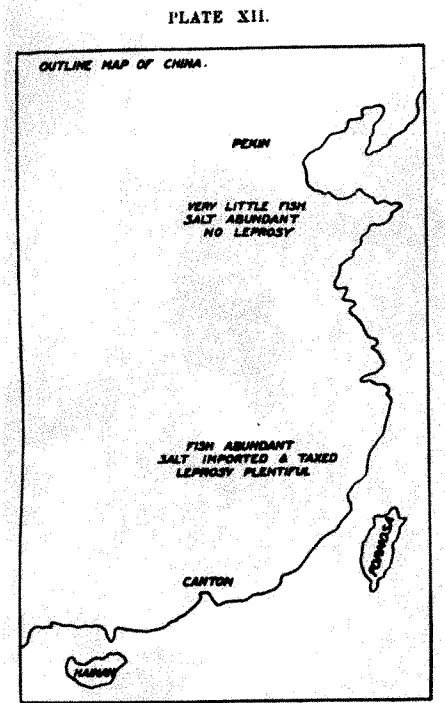

Fig 5.—Outline map of China to show suggested relationship of fish, salt, and taxes. (From *On Leprosy and Fish Eating: A Statement of Facts and Explanations*)

Fig 6.—Physician's dress when visiting plaque patients. "The figure represented is that of a physician equipped for visiting patients ill with the plague. He is enwrapped in a habit which completely protects his body and he wears a mask for his face. The mask has a nose of enormous length destined to contain oderiferous substances supposed to be disinfectant." Hutchinson obtained this from a Venetian physician. It came from a manuscript dating about 1750. (From *Archives of Surgery*, vol X, 380, 1899)

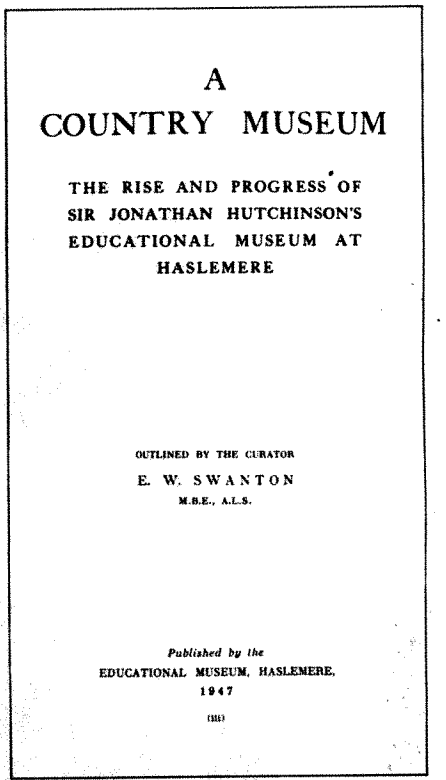

A
COUNTRY MUSEUM

THE RISE AND PROGRESS OF SIR JONATHAN HUTCHINSON'S EDUCATIONAL MUSEUM AT HASLEMERE

OUTLINED BY THE CURATOR
E. W. SWANTON
M.B.E., A.L.S.

Published by the
EDUCATIONAL MUSEUM, HASLEMERE,
1947

Fig 7.—Title page of text *A Country Museum*. Museum was founded and built by Hutchinson in 1895.

"As is well known, common eczema but rarely causes gland enlargements. I suspect that the scratching which pruriginous eruptions provoke has much to do in causing lymphatic irritation."

Telangiectatic Lupus Erythematosus (1903[14])

This unusual variety of discoid lupus erythematosus is not adequately described in present-day textbooks. There is no marked change in the epidermis, except for a persistent circumscribed redness, which close inspection shows to be due to telangiectatic blood vessels (Fig 4). The forehead, flush areas of face, upper part of the chest, and upper part of the back are the sites commonly affected. The eruption may remain for years without change. Evidence of systemic disease is lacking. Rarely, a fine epidermal atrophy may be present.

Temporal Arteritis (1934[15])

The subject of this case was an old man named Rumbold, the father is a well-remembered beadle at the London Hospital College thirty years ago. He was a tall, fine-looking man, rather thin, and quite bald. He had been a gentleman's servant, having lived in the family of the Earl of Dundonald, and he had, I believe, suffered from gout. At the time that I saw him he was living with his son near to the London Hospital College. He was upwards of eighty, and almost in his dotage. I was asked to see him because, as I was told, he had had red "streaks on his head" which were painful and prevented his wearing his hat. As I have said, he was bald, and his scalp was thin. The "red streaks" proved on examination to be his temporal arteries, which on both sides were found to be inflamed and swollen. The streaks extended from the temporal region almost to the middle of the scalp, and several branches of each artery could be distinctly traced. The condition was nearly symmetrical. During the first week that he was under my observation pulsation could be feebly detected in the affected vessels, but it finally ceased; the redness then subsided, and the vessels were left impervious cords. At no time was any gangrene of the skin of the scalp threatened. The old gentleman lived, I believe, several years after this without any other manifestation of arterial disease.[16]

Recurrent Herpes on the Thigh and Buttock

Of this patient, Mr. F—, my notes under date March 1880, record: He has had four attacks of herpes on the right buttock. He now shows me his fourth eruption, three long oval groups of abortive vesicles sloping down the buttock. He thinks that he feels rather ill whenever it comes, and the right leg feels weak and there is some tenderness in the inguinal region of right side. He never had herpes on the penis, and he never had ordinary shingles. His first attack of herpes was a year or more ago, and he has had three since last Christmas. He had syphilis two years ago.[17]

Sir Jonathan Hutchinson and His Writings

Hutchinson's writings have several characteristics. First was his ability to pick descriptive terms that were accurate and would be remembered. Examples are the "apple jelly" nodule of lupus vulgaris, the "screwdriver" central incisor peg teeth, and the "ground glass" cornea of congenital syphilis.

Second was his tendency to use the name of a patient for a condition that he did not understand. Examples are Mabey malady (terminal phalanx arthritis [acroarthritis] in association with recurring attacks of iritis), Penmann disease (hydroa aestivale), Mortimer malady (sarcoidosis), and Branford legs (erythema induratum). He believed that by doing so he would not prejudice subsequent thought and investigation of a newly recognized condition.

Third was his belief in the effectiveness of illustrations. All were hand drawn, mostly by Edwin Burgess and Mabel Green. They admirably supplemented his short, lucid clinical descriptions.

Fourth, there is the general summation that his clinical observations were valid but that his conclusions were often faulty. The best example of this is his long-standing and rigid belief that "the cause of the malady known as true leprosy is the eating of fish in a state of commencing decomposition".[17] How this idea got into his head, and why it stayed there, would be a most interesting story.

In his text *On Leprosy and Fish Eating*,[18] he gives the following three reasons as to why he did not look for the Hansen bacillus in the decomposing fish. First, he had the "assured conviction that the general facts were overwhelmingly conclusive and that they needed only to be clearly set forth." Second, he assumed that others would look for the bacillus in fish. "A third and perhaps the most influential reason for my individual neglect of microscopic search in the incriminated fish, has been a deep distrust of the negative conclusion." He even tied in the availability of salt used in curing fish (and hence preventing decomposition) as being related to the incidence of leprosy (Fig 5). He traveled to many parts of the world to get supporting information on fish-eating habits. However, as the contemporary American dermatologist William Pusey said (cited by Ingram[6]), all he ever proved was that rotting fish was eaten all over the world.

Another example of his incorrect conclusions was his belief that alopecia areata was a modified ringworm, or at any rate, a sequela of that disease.[19] He keeps stating and looking for evidence of its parasitic origin, despite the fact that all his microscopic examinations for fungal products were negative.

Finally, it must be said that he was a prim, humorless man. Nowhere in his most extensive writings (including letters and the opinions of those who knew him) was there ever any indication that he had a sense of humor. His lectures and writings were fascinating, dramatic, and informative—but not funny. He had an interest in the odd, unusual, and bizarre (Fig 6).

It is not surprising that with his able inquisitive mind he had many other interests. One of his favorites was the Medical Graduates College and Polyclinic. This was a series of 50 lectures and demonstrations that he gave in the 1890s and early 1900s for an annual fee of one guinea. Any medical man could attend. With the current resurgence of postgraduate or continuing medical education, it is humbling to realize that Hutchinson was doing this three quarters of a century ago. His other interest was the Haslemere Educational Museum, which he built and set up himself (Fig 7). Its purpose was to show general scientific information of all sorts with a special orientation to children. Work with this museum occupied many of his final years.

References

1. Hutchinson H: *Jonathan Hutchinson: Life and Letters*. London, William Heinemann, 1946.
2. McLeary JE, Farber EM: Dermatological writings of Sir Jonathan Hutchinson. *Arch Dermatol Syphilol* 65:130-136, 1952.
3. McKusick VA: The clinical observations of Jonathan Hutchinson. *Am J Syph Gon Ven Dis* 36:101-126, 1952.
4. Wales AE: Sir Jonathan Hutchinson, 1828-1913. *Br J Vener Dis* 39:67-86, 1963.
5. Nelson CT: Jonathan Hutchinson on vaccination syphilis. *Arch Dermatol* 99:529-535, 1969.
6. Ingram JT: My hero—Sir Jonathan Hutchinson. *London Hospital Gazette* 73:7-12, 1970.
7. Hutchinson J: *Archives of Surgery*. London, J. and A. Churchill, vol I to V, 1889-1893; London, West, Newman & Co, vol VI-XI, 1895-1900.
8. Hutchinson J: The crateriform ulcer (acute epithelial cancer), in *Archives of Surgery*. vol I, 241, 1889.
9. Jackson R: Sir Jonathan Hutchinson on toxic epidermal necrolysis: An historical note. *Br J Dermatol* 91:469-472, 1974.
10. Peutz JLA: Very remarkable case of familial polyposis of mucous membrane of intestinal tract and nasopharynx and accompanied by peculiar pigmentation of skin and mucous membranes. *Ned Tijdschr Geneeskd* 10:134-146, 1921.
11. Jeghers H, McKusick VA, Katz KH: Generalized intestinal polyposis and melanin spots of the oral mucosa, lips and digits. *N Engl J Med* 241:993, 1005, 1031-1036, 1949.
12. Pautrier LM, Woringer F: Note preliminaire sur un tableau histologique particulier de lesions ganglionnaires accompagnant des eruptions dermatologique generalisees, prurigineuses, de type cliniques differents. *Bull Soc Fr Dermatol Syphilol* 39:947, 1932.
13. Hutchinson J: Hebra's bubo, the bubo of prurigo, in *Archives of Surgery*. vol VII, 377-378, 1896.
14. Radcliffe-Crocker H: *Diseases of the Skin, Their Description, Pathology, Diagnosis and Treatment*, ed 3. Philadelphia, P Blakiston's Sons & Co, 1903, p 819.
15. Horton BT, Magath TB, Brown GE: Arteritis of the temporal vessels: A previously undescribed form. *Arch Intern Med* 53:400, 1934.
16. Hutchinson J: Diseases of the arteries, in *Archives of Surgery*. vol I, 325, 1889.
17. Hutchinson J: Group of cases in which herpes recurred repeatedly on the thigh and buttock, in *Archives of Surgery*. vol IX:127, 1898.
18. Hutchinson J: *On Leprosy and Fish-Eating: A Statement of Facts and Explanations*. London, Archibald Constable & Co, Ltd, 1906.
19. Hutchinson J: On alopecia areata and its relation to ringworm, in *Archives of Surgery*. vol IV: 289-304, 1892.

Schering

When it's all you want, it's all they get.

pure and simple

Chlor-Trimeton® 12mg.

brand of

chlorpheniramine maleate, USP

brand of

Repetabs® Tablets, repeat-action tablets

Available on prescription only.

Also available:
Chlor-Trimeton®
8 mg. Repetabs®
Injection 100 mg./ml.
and 10 mg./ml.

Copyright © 1977 Schering Corporation. All rights reserved.

SWW-9340

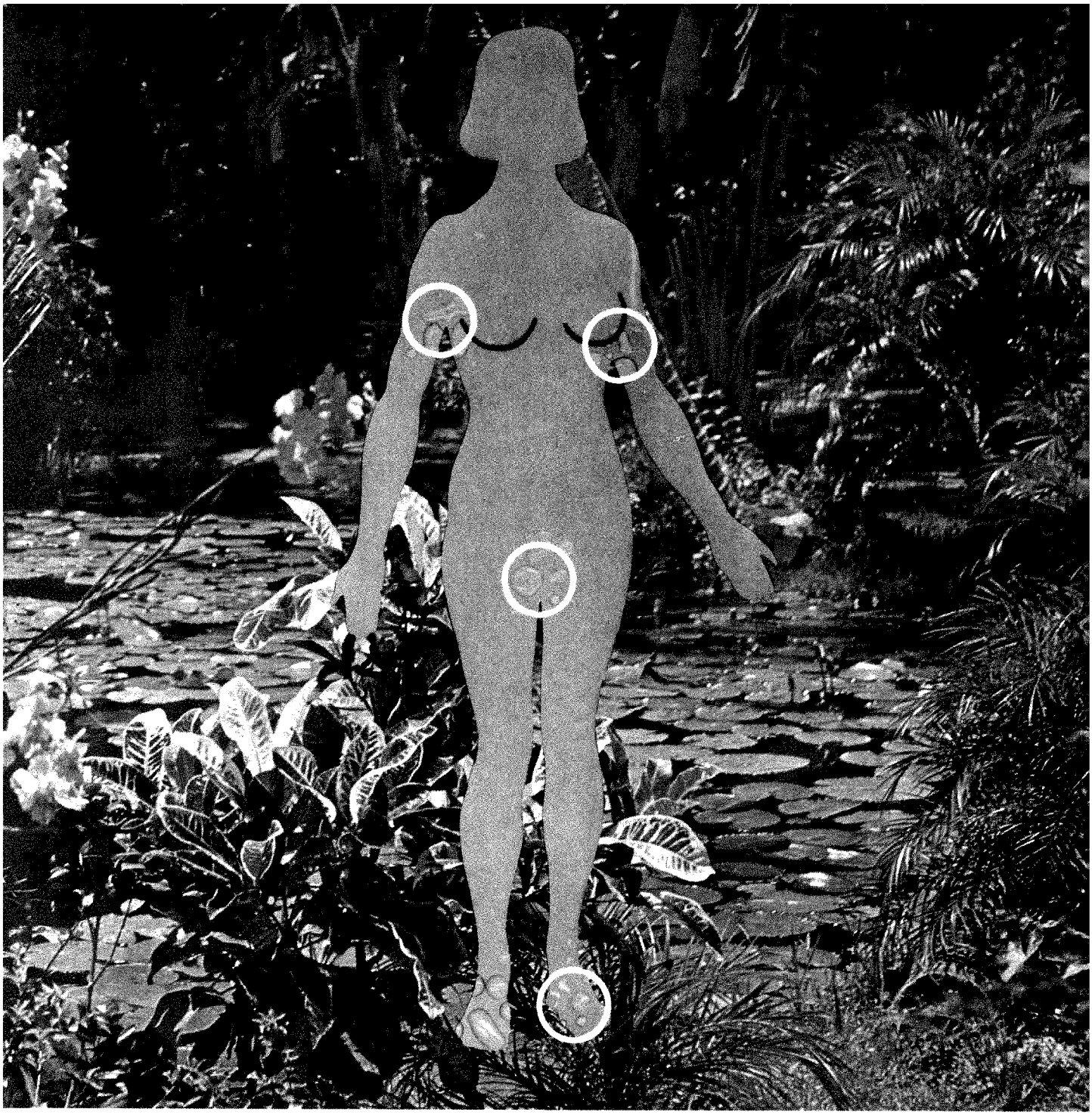

Dry Out the Damp Spots

ZeaSORB's unique formulation absorbs 2.6 times its weight in moisture...
25% to 100% more absorbent than five leading powders...

with Super Absorbent

ZeaSORB®

A dry climate around your patient

Active ingredients: Microporous cellulose 45%,* p-chloro-m-xylenol 0.5%, aluminum dihydroxy allantoinate 0.2%. Contains no starch or boric acid.

Supply: ZeaSORB is available in 2 oz. plastic dispenser bottles and 8 oz. shaker top cans.

Directions: Dust ZeaSORB freely wherever indicated.

*Stiefel's brand of a patented ultra-absorptive cellulose derivative. U.S. Pat. Nos. 2890151, 3278383.

STIEFEL
Logical Dermatologicals since 1847

Stiefel Laboratories, Inc.,
Oak Hill, N.Y. 12460
Stiefel Laboratories (Canada) Ltd.,
St. Laurent, Quebec, Canada H4R 1E1

1-1161

An excellent blend of clinical efficacy and cosmetic acceptance. Now indicated for seborrheic dermatitis.

Obviously, efficacy is foremost in your mind when you recommend a therapeutic shampoo. And efficacy, coupled with cosmetic acceptability, usually guarantees a successful therapeutic course.

That's why Head & Shoulders is so highly regarded in the treatment of dandruff.

Clinically effective

For years, Head & Shoulders has proved effective in the treatment of dandruff—whether for initial therapy or long-term control. And now, research shows that Head & Shoulders is effective in the treatment of seborrheic dermatitis.*

Cosmetically pleasing

Head & Shoulders lathers well, has a pleasant odor and appearance, and need not be left on the scalp for an extended period of time. Also, it leaves hair clean, manageable, and attractive.

Head & Shoulders®

You'll like it for its therapeutic benefits. Your patients will like it for its cosmetic appeal.

*Orentreich, N.: A clinical evaluation of two shampoos in the treatment of seborrheic dermatitis. J. Soc. Cosmet. Chem. 23:189 (March 3) 1972.

Solar Simulator Tests Demonstrate Superior Substantivity

SUPER SHADE LOTION [5% PABA] for SUN SENSITIVE PATIENTS

Superior in "Wash Off" Resistance and Cosmetic Elegance to The Leading "PABA" Formula

Super Shade Sun Blocking Lotion by COPPERTONE gives maximum sunburn protection for patients who enjoy the sun yet need the maximum filtering of the sun's ultraviolet rays. Super Shade has these advantages:

- WASH OFF RESISTANCE. The superior substantivity of Super Shade enables it to resist removal by perspiration and swimming. Reapplied as directed, it gives all day protection. Super Shade lets your patient stay in the sun 10 times longer without burning than with no protection.
- COSMETIC ELEGANCE: Super Shade is a white, creamy, non-greasy lotion. Unlike clear products, users can see where Super Shade has been applied. It permits an even uniform coverage with no gaps or unprotected areas.
- HELPS PREVENT SUN DAMAGE that may cause premature wrinkling, aging of the skin and skin cancer when used regularly as directed.

Active Ingredient: Para-Aminobenzoic Acid 5%. Alcohol 60%.

Sun Sensitive Patients Will Appreciate Your Recommendation of Super Shade.

Bullous Pemphigoid

Clinical and Serologic Evaluation for Associated Malignant Neoplasms

A. Razzaque Ahmed, MD; T. Ming Chu, PhD; Thomas T. Provost, MD

Bullous pemphigoid (BP) has been reported in association with malignant neoplasms of the urinary tract, lung, genitalia, breast, pancreas, gastrointestinal (GI) tract, skin, and lymphoreticular system.[1] The course of BP usually does not parallel the course of the malignant neoplasm. The malignant neoplasm may be evident at the onset of BP or present as an incidental finding at postmortem examination.[2]

Carcinoembryonic antigen (CEA) levels greater than 2.5 ng/ml have been reported in serum samples from patients with pancreatic, colonic, rectal, gastric, mammary, and cervical malignant neoplasms, and in some leukemias.[3] The presence of CEA correlates with a high incidence of proved malignant neoplasms and is an early indicator of clinically unrecognized recurrence.[4]

The purpose of this study was to determine the incidence of a malignant neoplasm in a large number of patients with BP using clinical as well as serologic evaluation.

Subjects and Methods

Thirty-three patients with BP were studied. All of the patients had the typical clinical disease, subepidermal bullae on routine histopathologic features, and demonstrated the presence of immunoglobulins and/or the third component of complement at the dermal-epidermal junction of peribullous skin. These 33 patients (15 women, 18 men) ranged in age from 45 to 93 years (mean, 72.3 years). These patients have been followed up by routine physical examination every six months for a period ranging from one to five years (mean, 3.2 years). Initial examination included the following laboratory studies; CBC, differential, urinalysis, SMA-12, stool for occult blood, and chest roentgenograms. Carcinoembryonic antigen assay was performed using a radioimmunoassay using a zirconyl phosphate gel.[5] A total of 76 serum samples consisting of the initial as well as the most recent sample, were analyzed.

Results

No gross evidence of malignant neoplasms was observed in these 33 patients. Eleven of these patients have died, and three autopsies have been performed. In one patient, a microscopic adenocarcinoma of the colon was detected. The serum of this patient was negative for CEA. No malignant neoplasm was observed at autopsy in the other two patients.

A level of 2.5 ng/ml or greater is considered a positive CEA determination. One of our patients had a level of 4.4 ng/ml. This patient, however, had a detailed examination in the hospital including upper GI series, barium enema, and repeated stool examination for occult blood. No evidence of malignant neoplasms was detected, and he remained asymptomatic 18 months later. The rest of the 75 serum samples were negative for CEA.

Comment

The incidence of proved malignant neoplasm in our bullous pemphigoid patient population is one of 33 (3.0%). The incidence of malignancy in New York, excluding New York City, for 33 persons with a mean age of 72 years, observed for three years as determined by extrapolating the International Union Against Cancer (UICC) tables[6] is 4.2%. If we assume the elevated CEA represents an unrecognized cancer, this would give two malignant neoplasms in 33 patients. The 95% confidence level for an annual incidence of malignancy is 0% to 5%. The incidence rate in our series is, at most, 2.0% per year. Therefore, we conclude that in our patients with bullous pemphigoid there is no increase in the incidence of malignant neoplasms. Recently, Stone and Schroeter[1] failed to demonstrate that patients with bullous pemphigoid compared with age-matched controls have a substantial increased incidence of malignant disease. The results of our study support their conclusions.

From the Departments of Dermatology, State University of New York at Buffalo School of Medicine (Drs Ahmed and Provost), and Diagnostic Immunology, Roswell Park Memorial Institute (Dr Chu), Buffalo. Dr Ahmed is now with the University of California at Los Angeles School of Medicine.

Reprint requests to Department of Dermatology, State University of New York at Buffalo School of Medicine, 50 High St, Buffalo, NY 14203 (Dr Provost).

This study was supported in part by National Institutes of Health grant No. Pol AM 16593-03 and Research Contract CB-33858 from the National Cancer Institute.

References

1. Stone SP, Schroeter AL: Bullous pemphigoid and associated malignant neoplasms. *Arch Dermatol* III:991-994, 1975.

2. Cormia FE, Domenkos AN: Cutaneous reactions to internal malignancies. *Med Clin North Am* 49:655-680, 1965.

3. Hansen MJ, Snyder JJ, Muller E, et al: CEA assay: A laboratory adjunct in management of cancer. *Hum Pathol* 15:139-147, 1974.

4. Chu TM, Holyoke ED, Murphy GP: Carcinoembryonic antigen: Current clinical status. *NY State J Med* 74:1388-1393, 1974.

5. Chu TM, Reynoso G: Evaluation of a new radioimmunoassay method for CEA in plasma using zirconyl phosphate gel. *Clin Chem* 18:918-922, 1972.

6. Doll R, Payne P, Waterhouse J: *International Union Against Cancer: Cancer Incidence in Five Continents*. New York, Springer-Verlag, 1966.

Permanent Anonychia After Stevens-Johnson Syndrome

Birgitte Wanscher, MD, Jens Thormann, MD

Loss of nails with scarring that leads to anonychia may occur on a congenital basis, as in the nail-patella syndrome and the dystrophic epidermolysis bullosa, or on an acquired basis, as seen after severe trauma, as well as in the case of impaired peripheral circulation, in lichen planus, and in bullous drug eruptions.[1] Any drugs that induce bullae can cause nail changes or nail loss due to destruction of the nail matrix.[1]

To our knowledge, hitherto nothing has been written about the nail changes in Stevens-Johnson syndrome. Therefore, we will present such a case report of a patient with permanent nail loss.

Report of a Case

A 29-year-old man was admitted to the dermatology department April through July 1971 with a fulminant attack of Stevens-Johnson syndrome.

Physical examination results showed suppurative conjunctivitis on both eyes and edema and redness of the eyelids. On the lips and around the nostrils, severe crusting and oozing was found. In the mouth, denuded, edematous, and red areas were seen. All over the body and the extremities, erythema multiforme lesions appeared, some of them with bullae. The skin of the hands showed confluent bullae and small bullae immediately proximal to the nails of some of the fingers and on the fingertips. The patient was treated systemically with betamethasone (Celestone) for 2½ months, cyproheptadine hydrochloride (Periactin), tetracycline hydrochloride, erythromycin stearate (Abboticine), and various topical preparations. The cause of the disease was considered to be tablets that contained 0.1 mg of belladonna alkaloid malates, 0.3 mg of ergotamine tartrate, and 20 mg of phenobarbital (Bellergal) which, for two months, had been the treatment of hyperhidrosis.

In November 1975, the patient was readmitted to the hospital to clarify the cause of his Stevens-Johnson syndrome. On this admission, the patient reported that, after discharge, all the nails of his fingers and toes were shed, and that no regrowth had occurred. The absence of nails had caused little trouble.

Results of physical examination of the nails showed cicatricial anonychia and pterygium. On the proximal halves of some of the nail beds, slightly keratinized epithelium was found. Only the fifth left toenail showed an almost normal nail plate. The peripheral circulation was unimpaired. No treatment was given, because the nails remained unchanged for four years. No biopsy specimen was taken.

Comment

The nail anomaly found in our case has been reported as a consequence of lichen planus of the nails.[1-4] Lichen planus may even be confined only to the nails without involvement of skin and mucous membranes, but it rarely involves all the nails.[3,4] The immediate course in the present case with shedding of all nails indicates that the patient's cicatricial anonychia was due to the Stevens-Johnson syndrome.

Zaias and Alvarez[5] have shown that the nail plate is solely produced by the nail matrix and receives no contribution from the proximal nail fold and the nail bed. The scarring is, therefore, caused by destruction of the matrix. In our patient, we found pterygium formation, which is also due to destruction of the nail matrix and fusion of the epithelium of the dorsal nail fold with the nail bed.[5]

Several recent reports concerning the treatment of nail dystrophy with intralesional administration of triamcinolone acetonide using a needleless injector (Port-O-Jet or Dermojet) have appeared,[6] and promising results have been obtained in the treatment of lichen planus.[6] However, when the nail changes, especially the pterygium formation, have lasted for more than a year or when the nails show severe destructive dystrophy, no response has been found. Apart from the systemic corticosteroid treatment that this patient received in the immediate phase, no treatment of the nails was attempted because the condition had been present for four years. However, perhaps injections of a corticosteroid suspension through the posterior nail fold to the matrix ought to be tried early to prevent the permanent anonychia.

From the Department of Dermatology, Rigshospital, Copenhagen.

Reprints not available.

References

1. Samman PD: *The Nails in Disease*, ed 2, London, William Heinemann Medical Books Ltd, 1972, pp 61-65, 91.

2. Zaias N: The nail in lichen planus. *Arch Dermatol* 101:264-271, 1970.

3. Cornelius CE, Shelly WB: Permanent anonychia due to lichen planus. *Arch Dermatol* 96:434-435, 1967.

4. Marks R, Samman PD: Isolated nail dystrophy due to lichen planus. *Trans St John's Hosp Derm Soc* 58:93-97, 1972.

5. Zaias N, Alvarez J: The formation of the primate nail plate: An autoradiographic study in squirrel monkey. *J Invest Dermatol* 51:120-136, 1968.

6. Abell E, Samman PD: Intradermal triamcinolone treatment of nail dystrophies. *Br J Dermatol* 89:191-197, 1973.

IN SKIN INFECTIONS, WHERE CLEANLINESS REQUIRES MORE THAN SOAP

BETADINE® Skin Cleanser

Degerms as it cleanses

ıtients can use BETADINE Skin Cleanser to degerm and cleanse face, hands and body, gently and thoroughly—ırticularly when it is essential to prevent autoinoculation of new sites, as may be the case in infected acne pimples.

BETADINE Skin Cleanser, with its rich, golden lather, provides these advantages:

- Prompt, broad-spectrum microbicidal action—kills both gram-positive and gram-negative bacteria (including antibiotic-resistant strains), fungi, viruses, protozoa and yeasts.
- Maintains microbicidal activity in the presence of blood, pus and serum.
- Virtually nonirritating to skin and mucosa.*
- Nonstaining to skin and natural fabrics.

Supplied: 4 fl. oz. plastic bottles.

*In the rare instance of local irritation or sensitivity, discontinue use by the individual.

Purdue Frederick © COPYRIGHT 1976, THE PURDUE FREDERICK COMPANY

NORWALK, CONN. 06856 A8196 172076



anti-
inflammatory
antifungal
antipruritic
antibacterial

Clear choice

When dermatoses become infected with bacteria or fungi, plain topical steroids are generally not the recommended therapeutic choice.

A clear choice, however, is Vioform®-Hydrocortisone. With its unique four-way action, it supplies the kind of comprehensive treatment many common dermatoses* require.

*This drug has been evaluated as possibly effective for these indications. See brief prescribing information.

Vioform®-Hydrocortisone
(iodochlorhydroxyquin and hydrocortisone)

INDICATIONS
Based on a review of this drug by the National Academy of Sciences-National Research Council and/or other information, FDA has classified the indications as follows:
"Possibly" effective: Contact or atopic dermatitis; impetiginized eczema; nummular eczema; infantile eczema; endogenous chronic infectious dermatitis; stasis dermatitis; pyoderma; nuchal eczema and chronic eczematoid otitis externa; acne urticata; localized or disseminated neurodermatitis; lichen simplex chronicus; anogenital pruritus (vulvae, scroti, ani); folliculitis; bacterial dermatoses; mycotic dermatoses such as tinea (capitis, cruris, corporis, pedis); moniliasis; intertrigo. Final classification of the less-than-effective indications requires further investigation.

CONTRAINDICATIONS
Hypersensitivity to Vioform-Hydrocortisone, or any of its ingredients or related compounds; lesions of the eye; tuberculosis of the skin; most viral skin lesions (including herpes simplex, vaccinia, and varicella).

WARNINGS
This product is not for ophthalmic use.
In the presence of systemic infections, appropriate systemic antibiotics should be used.

Usage in Pregnancy
Although topical steroids have not been reported to have an adverse effect on pregnancy, the safety of their use in pregnant females has not been established. Therefore, they should not be used extensively on pregnant patients in large amounts or for prolonged periods of time.

PRECAUTIONS
May prove irritating to sensitized skin in rare cases. If this occurs, discontinue therapy. May stain.
If used under occlusive dressings or for a prolonged period, watch for signs of pituitary-adrenal axis suppression.
May interfere with thyroid function tests. Wait at least one month after discontinuance of therapy before performing these tests. The ferric chloride test for phenylketonuria (PKU) can yield a false-positive result if Vioform is present in the diaper or urine.
Prolonged use may result in overgrowth of nonsusceptible organisms requiring appropriate therapy.

ADVERSE REACTIONS
Few reports include: Hypersensitivity, local burning, irritation, pruritus. Discontinue if untoward reaction occurs. Rarely, topical corticosteroids may cause striae at site of application when used for long periods in intertriginous areas.

DOSAGE
Apply a thin layer to affected areas 3 or 4 times daily.

HOW SUPPLIED
Cream, 3% iodochlorhydroxyquin and 1% hydrocortisone in a water-washable base containing stearyl alcohol, cetyl alcohol, stearic acid, petrolatum, sodium lauryl sulfate, and glycerin in water; tubes of 5 and 20 Gm. *Ointment*, 3% iodochlorhydroxyquin and 1% hydrocortisone in a petrolatum base; tubes of 20 Gm. *Lotion*, 3% iodochlorhydroxyquin and 1% hydrocortisone in a water-washable base containing stearic acid, cetyl alcohol, lanolin, propylene glycol, sorbitan trioleate, polysorbate 60, triethanolamine, methylparaben, propylparaben, and perfume Flora in water; plastic squeeze bottles of 15 ml. *Mild Cream*, 3% iodochlorhydroxyquin and 0.5% hydrocortisone in a water-washable base containing stearyl alcohol, cetyl alcohol, stearic acid, petrolatum, sodium lauryl sulfate, and glycerin in water; tubes of ½ and 1 ounce. *Mild Ointment*, 3% iodochlorhydroxyquin and 0.5% hydrocortisone in a petrolatum base; tubes of 1 ounce.
C75-38 Rev. 7/75

Consult complete product literature before prescribing.

CIBA Pharmaceutical Company
Division of CIBA-GEIGY Corporation
Summit, New Jersey 07901

2/7853 17

Vioform®-Hydrocortisone
(iodochlorhydroxyquin and hydrocortisone)

The most widely prescribed form... 20-Gm Cream



CIBA

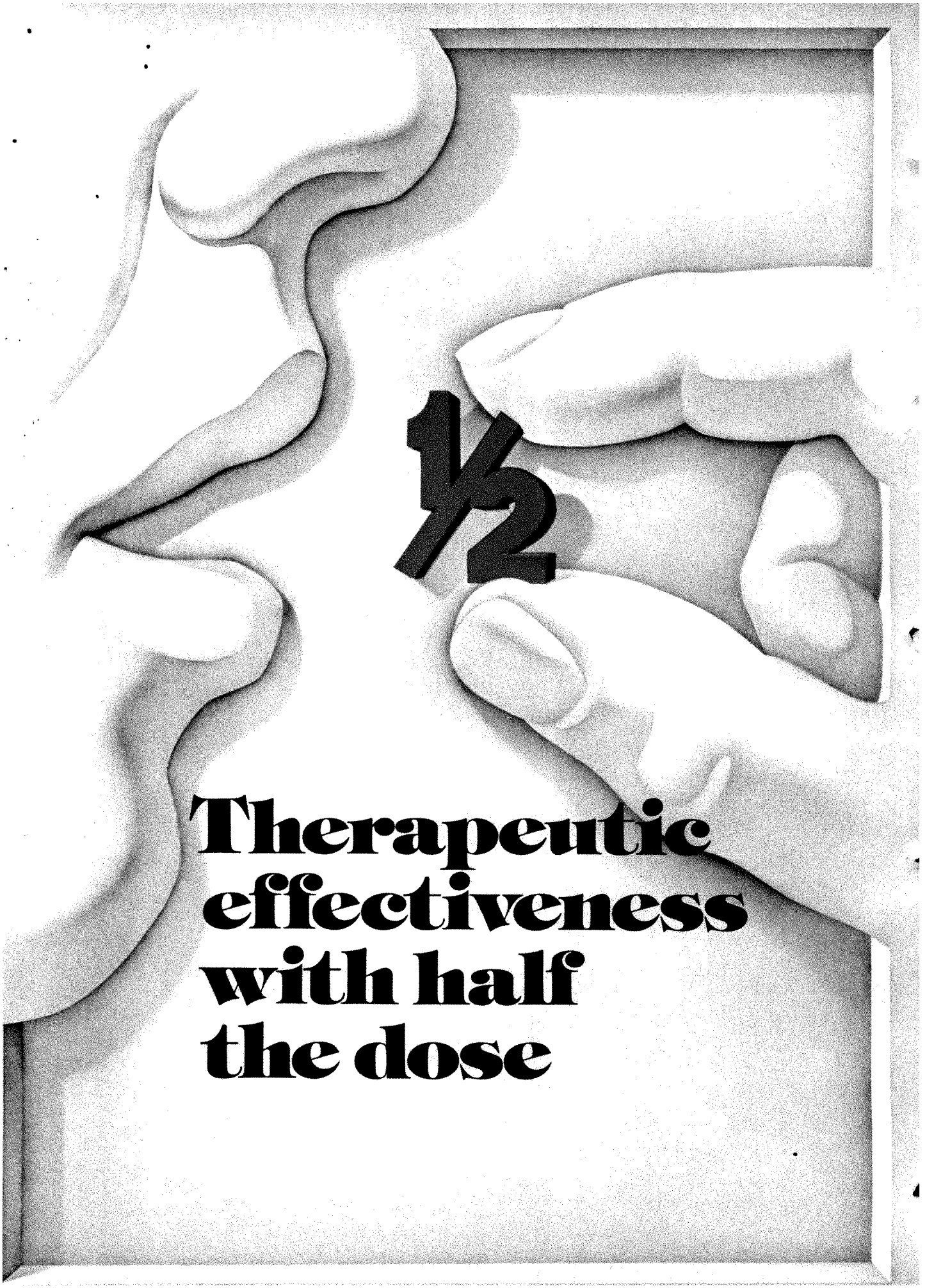
½
Therapeutic effectiveness with half the dose

Schering

Once-a-day dosage

NEW Fulvicin® P/G*

brand of griseofulvin [ultramicrosize], USP

(specially processed) **125 mg. tablets**

*"P/G" means a new polyethylene glycol system for enhanced absorption –

A 250 mg. daily dose (two 125 mg. tablets) of new FULVICIN P/G can replace 500 mg. of griseofulvin (microsize), USP. This is made possible by a special process in which the ultramicrosize griseofulvin crystals are partly dissolved in polyethylene glycol and dispersed through the tablet matrix for enhanced absorption.

Patient convenience –

FULVICIN P/G can be prescribed as two 125 mg. tablets once a day. Compliance is further assured by the easy-to-swallow size of the tablets.

Patient savings –

FULVICIN P/G is up to 35 per cent less expensive per dose than all microsize griseofulvin formulations.**

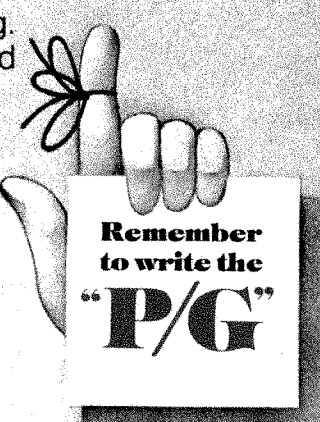

**Based on list-price comparison.

See Clinical Considerations section on following page...

COPYRIGHT © 1977, SCHERING CORPORATION. ALL RIGHTS RESERVED. SLS-703

Schering

NEW P/G
Fulvicin®
griseofulvin [ultramicrosize], USP
(specially processed) 125 mg. tablets

Clinical Considerations: INDICATIONS FULVICIN P/G Tablets are indicated for the treatment of ringworm infections of the skin, hair, and nails, namely: tinea corporis, tinea pedis, tinea cruris, tinea barbae, tinea capitis, tinea unguium (onychomycosis); when caused by one or more of the following genera of fungi: *Trichophyton rubrum, Trichophyton tonsurans, Trichophyton mentagrophytes, Trichophyton interdigitalis, Trichophyton verrucosum, Trichophyton megnini, Trichophyton gallinae, Trichophyton crateriform, Trichophyton sulphureum, Trichophyton schoenleini, Microsporum audouini, Microsporum canis, Microsporum gypseum,* and *Epidermophyton floccosum*. Note: Prior to therapy, the type of fungi responsible for the infection should be identified. The use of this drug is not justified in minor or trivial infections which will respond to topical agents alone. Griseofulvin is not effective in the following: Bacterial infections, Candidiasis (Moniliasis), Histoplasmosis, Actinomycosis, Sporotrichosis, Chromoblastomycosis, Coccidioidomycosis, North American Blastomycosis, Cryptococcosis (Torulosis), Tinea versicolor, and Nocardiosis. **CONTRAINDICATIONS** This drug is contraindicated in patients with porphyria, hepatocellular failure, and in individuals with a history of hypersensitivity to griseofulvin. **WARNINGS** *Prophylactic Usage*: Safety and efficacy of griseofulvin for prophylaxis of fungal infections have not been established. *Animal Toxicology*: Chronic feeding of griseofulvin, at levels ranging from 0.5-2.5% of the diet, resulted in the development of liver tumors in several strains of mice, particularly in males. Smaller particle sizes result in an enhanced effect. Lower oral dosage levels have not been tested. Subcutaneous administration of relatively small doses of griseofulvin once a week during the first three weeks of life has also been reported to induce hepatomata in mice. Although studies in other animal species have not yielded evidence of tumorogenicity, these studies were not of adequate design to form a basis for conclusions in this regard. In subacute toxicity studies, orally administered griseofulvin produced hepatocellular necrosis in mice, but this has not been seen in other species. Disturbances in porphyrin metabolism have been reported in griseofulvin-treated laboratory animals. Griseofulvin has been reported to have a colchicine-like effect on mitosis and cocarcinogenicity with methylcholanthrene in cutaneous tumor induction in laboratory animals. *Usage in Pregnancy*: The safety of this drug during pregnancy has not been established. *Animal Reproduction Studies*: It has been reported in the literature that griseofulvin was found to be embryotoxic and teratogenic on oral administration to pregnant rats. Pups with abnormalities have been reported in the litters of a few bitches treated with griseofulvin. Additional animal reproduction studies are in progress. Suppression of spermatogenesis has been reported to occur in rats, but investigation in man failed to confirm this. **PRECAUTIONS** Patients on prolonged therapy with any potent medication should be under close observation. Periodic monitoring of organ system function, including renal, hepatic, and hematopoietic, should be done. Since griseofulvin is derived from species of penicillin, the possibility of cross-sensitivity with penicillin exists, however, known penicillin-sensitive patients have been treated without difficulty. Since a photosensitivity reaction is occasionally associated with griseofulvin therapy, patients should be warned to avoid exposure to intense natural or artificial sunlight. Should a photosensitivity reaction occur, lupus erythematosus may be aggravated. Griseofulvin decreases the activity of warfarin-type anticoagulants so that patients receiving these drugs concomitantly may require dosage adjustment of the anticoagulant during and after griseofulvin therapy. Barbiturates usually depress griseofulvin activity, and concomitant administration may require a dosage adjustment of the antifungal agent. **ADVERSE REACTIONS** When adverse reactions occur, they are most commonly of the hypersensitivity type, such as skin rashes, urticaria, and rarely, angioneurotic edema, and may necessitate withdrawal of therapy and appropriate countermeasures. Paresthesias of the hands and feet have been reported rarely after extended therapy. Other side effects reported occasionally are oral thrush, nausea, vomiting, epigastric distress, diarrhea, headache, fatigue, dizziness, insomnia, mental confusion, and impairment of performance of routine activities. Proteinuria and leukopenia have been reported rarely. Administration of the drug should be discontinued if granulocytopenia occurs. When rare, serious reactions occur with griseofulvin, they are usually associated with high dosages, long periods of therapy, or both.

10705231 JANUARY 1977

For more complete details, consult package insert or Schering literature available from your Schering Representative or Professional Services Department, Schering Corporation, Kenilworth, New Jersey 07033.

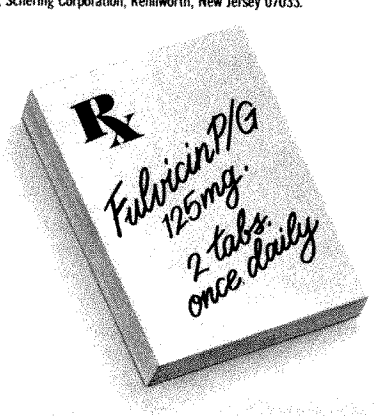

Society Transactions

The Society Proceedings are edited by Dr Harry L. Arnold, Jr, Straub Clinic, Honolulu, HI 96813. Transactions and photographs should be sent, in duplicate, directly to him.

PHILADELPHIA DERMATOLOGICAL SOCIETY
Jan 17, 1975

Waine C. Johnson, MD, Recorder

Wilson's Disease and Penicillamine-Induced Anetoderma. Presented by Lt Comdr WILLIAM DAVIS, MC, USN.

A 15-year-old boy and his 13-year-old brother are presented. The 15-year-old patient had a diagnosis of Wilson's disease established after an episode of hepatitis in the spring of 1970. Laboratory screening of the family revealed the brother to have decreased ceruloplasm and increased copper levels. Both patients have been treated with penicillamine, 1.0 to 1.5 gm daily, since the summer of 1970. Both patients for the past two years have shown circumscribed plaques of hemorrhagic milia and scarring of the skin of the elbows and knees. The younger patient has had atrophic lesions of the axillae and neck for about one year. Both patients appear somewhat pale but do not show organomegaly or Kaiser-Fleischer rings. Both have scarred, hemorrhagic areas with numerous 1- to 5-mm milia located over the elbows and knees. The younger patient has central confluent and peripherally sharply demarcated 5- to 15-mm light blue, atrophic macules involving the axillae and sides of the neck. A liver biopsy specimen from the younger patient showed copper 157 μg/gm, and that from the older patient showed 210 μg/gm (normal range, <100 μg/gm). A 24-hour urine specimen on the older patient showed copper, 1,123 μg/liter (normal value, 20 to 50 μg/liter). A skin biopsy specimen from the knee of the younger boy showed milia and scarring. A biopsy specimen from his right axilla revealed an absence of elastic tissue by special staining with the Hart's elastic tissue stain; a biopsy specimen from the axilla of the 15-year-old showed normal skin.

Discussion

COMDR C ROBERT CHARLES, MC USN: The effects of penicillamine therapy are varied; those described in the literature include allergic eruptions, desquamation, hemorrhagic or pemphigus-like bullae, friability, discoloration, epidermal inclusion cysts, cutis hyperelastica, cheilosis, glossitis, stomatitis, vulvar ulcerations, and elastosis perforans serpiginosa. The younger of the two siblings presented today has yet another complication of penicillamine therapy, that of anetoderma. To our knowledge, this complication has yet to have been described in the literature although it is my understanding that Dr Margaret Wood of the University of Pennsylvania saw an almost identical case of penicillamine-induced anetoderma at the Cleveland Clinic several years ago.

The pathogenesis of the anetoderma in this case could be related to copper deficiency resulting from penicillamine chelation or to direct penicillamine effects on elastin. Copper is required for the formation of stable cross-links between lysine residues, and severe copper deficiency may be associated with structural abnormalities of elastic tissue. In Wilson's disease, which is characterized by chronic toxic reaction to copper, however, a direct effect of penicillamine on elastic tissue seems more likely. Elastic tissue, like collagen, involves the participation of aldehydes to form stable cross-links. Penicillamine can react nonenzymatically with aldehydes to form thiazolidine compounds, thus impairing the formation of such stable cross-links. In a similar fashion, penicillamine also has profound effects on collagen, producing an accumulation of soluble collagen via a block in the formation of insoluble collagen and an accelerated turnover of preformed insoluble collagen. These changes in collagen are no doubt responsible for many of the other cutaneous effects of penicillamine therapy, including inclusion cyst, friability and delay in wound healing.

Nonproprietary Name and Trade Name of Drug

Penicillamine—*Cuprimine.*

Parapsoriasis en Plaques. Presented by MATTHEW OLIVO, MD, LT STEPHEN DAMM, MC, USN.

A 53-year-old man was initially seen in 1968 with a one-year history of an asymptomatic eruption about the waist and on the buttocks. Physical examination at this time revealed scaling erythematous patches, with areas of telangiectasia involving the hips, lower abdomen, and back. He was treated with fluocinolone acetonide cream 0.1% with some improvement.

Discussion

DONALD BAXTER, MD: I think the patient now has mycosis fungoides. Patients of this type initially have scaly, yellowish to red lesions that may show mild atrophy or slight infiltration. When you follow-up with serial biopsy specimens over several years, you begin to get a picture that histologically is fairly typical of mycosis fungoides. The recent biopsy specimen does not show significantly atypical cells, but there are lymphocytes within the epidermis and an occasional small collection of these is present. These would be acceptable as Pautrier microabscesses.

EUGENE J VAN SCOTT, MD: The lesions are clinically compatible with the cases in which mycosis fungoides evolves. Our problem frequently is in obtaining confirmation histologically of a diagnosis of mycosis fungoides. Early diagnosis and treatment is, in my opinion, important in mycosis fungoides as it is in cancer in general.

HARRY J HURLEY, MD: I believe the emphasis on the telangiectatic element or the poikilodermatous change as a clinical feature strongly suggesting mycosis fungoides is important. Once the lesions of parapsoriasis have acquired this additional poikilodermatous feature, clinically we can consider the disease to be mycosis fungoides.

SAMUEL L. MOSCHELLA, MD: The lesions are clinically and histologically consistent with early mycosis fungoides. Since the patient is asymptomatic, the question of whether or not to treat him arises. Does one cure early mycosis fungoides by intensive topical treatment with mechlorethamine hydrochloride or by intensive therapy with the electron beam? From our experience so far, I am not optimistic and think that our therapy for mycosis fungoides is still palliative. We are probably capable of reducing the morbidity of the disease, but I question our capacity to affect its final prognosis or duration. Although mechlorethamine is an excellent form of therapy, we have the problem of sensitization in our patients despite following the recommended initial course of therapy to induce tolerance.

DR VAN SCOTT: We now have data on about 100 cases. At least 50% of the patients in these cases are free of disease and a number of these, after five years, have had their therapy discontinued with no recurrence, so we can begin to think in terms of cure. It is easier to effect a cure in the early stages. It is a rule in treating neoplasms to treat them while they are a small problem.

DONALD PIROZZI, MD: I would like to ask Dr Van Scott the incidence of sensitization in patients given weekly injections to induce tolerance.

DR VAN SCOTT: We have been very successful. In approximately 70 cases in which we have given 200 μg of mechlorethamine hydrochloride in weekly injections before topical therapy, only about 10% have become allergic.

HERBERT GOLDSCHMIDT, MD: You would not want to use teleroentgen therapy with soft x-rays because the patient shows relatively small areas of involvement. I would start him on the Van Scott regime with mechlorethamine and if he did not respond or if he should become sensitized, I would then consider radiation treatment.

DR MOSCHELLA: In our limited experience, treating early cases of mycosis fungoides with electron beam therapy using doses of 2,700 to 3,000 rads, the results have been disappointing. The four patients treated experienced a severe immediate dermatitis and later radiodermatitis. All experienced relapse within six months. There is a considerable reluctance by the radiotherapist to pursue this form of treatment because of the relatively poor results and the resulting permanent change to the skin that prevents further beam therapy for several years.

DR PIROZZI: Does the fact that there is no pruritus disturb anyone? The British have described a condition, xanthoerythroderma perstans, or chronic superficial dermatitis, that they believe does not represent parapsoriasis and does not eventuate into mycosis fungoides. It is completely asymptomatic and appears similar clinically to the features seen in this case. I wonder if this patient's condition could represent xanthoerythroderma perstans?

DR OLIVO: I have known this patient for about eight years. For the most part, the lesions have been essentially unchanged and asymptomatic. In the past six months to a year, reticulated patches and slightly atrophic and scaly areas of the buttocks have developed. Now that we have the opinion of the pathologists that the lesions are those of mycosis fungoides, we will proceed to treat the patient.

Multiple Pilomatrixomas. Presented by MATTHEW OLIVO, MD, LT STEPHEN DAMM, MC, USN.

A 35-year-old woman has had acne vulgaris for about 20 years. Occasionally cysts had developed in the axillae. Eighteen months ago she noticed cysts appearing on the dorsum of her left arm and shortly thereafter, two similar hard lesions developed on the right arm and one lesion below the left ear. Physical examination revealed four very firm, irregular, nontender nodules located on the right and left forearms and beneath the left ear. Two fluctuant cysts were also present in the axillae. A biopsy specimen from one of the arm lesions was reported as a pilomatrixoma.

Discussion

WAINE C JOHNSON, MD: The histology was characteristic of pilomatrixoma (calcifying epithelioma of Malherbe), with typical-appearing shadow cells and basalophilic cells and areas of ossification. This latter feature is seen in about 20% of the pilomatrixomas. Pilomatrixomas tend to occur in the younger age group; about one half of the patients reported in the literature have been younger than 20 years of age. The unusual aspect in this patient is the occurrence of multiple lesions. Of 228 patients reported by Drs Forbis and Helwig (ARCHIVES 83:606-618, 1961), only seven patients had multiple tumors and only one had as many as four tumors.

HOECHST-ROUSSEL PHARMACEUTICALS INCORPORATED

Announces a New topical fluorinated corticosteroid in a Unique Emollient Cream Base

NEW TOPICORT (DESOXIMETASONE)

THE SPECIALLY DEVELOPED, PRESERVATIVE-FREE BASE COMBINES THE EMOLLIENCE OF AN OINTMENT WITH THE COSMETIC ACCEPTABILITY OF A CREAM IN A WATER-IN-OIL EMULSION.

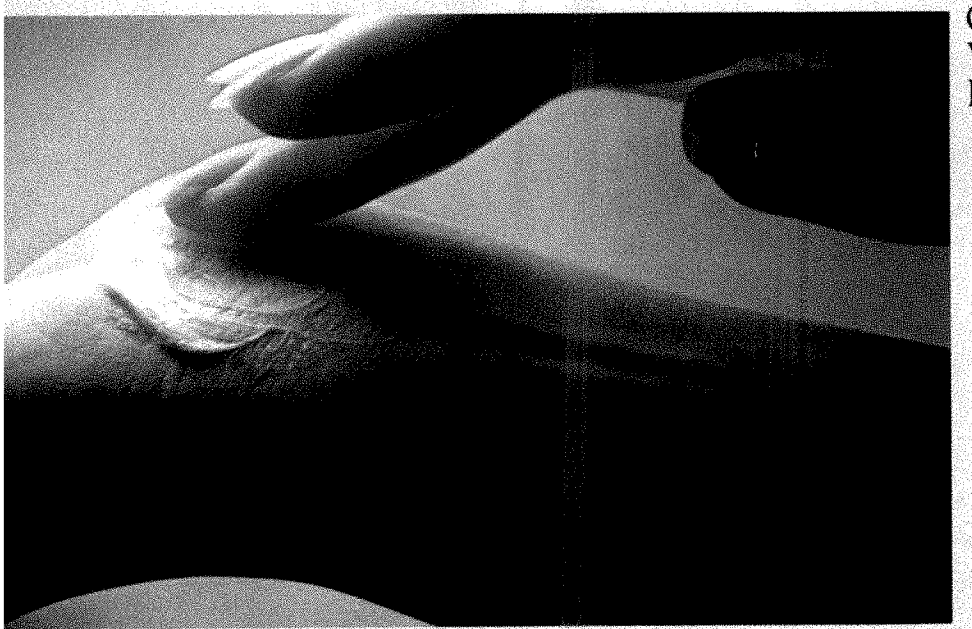

Well-documented efficacy and safety: Anti-inflammatory, antipruritic, vasoconstrictive Topicort (desoximetasone) has been demonstrated safe and effective in relieving the inflammatory manifestations of corticosteroid-responsive dermatoses.

Worldwide clinical experience: For up to 4 years, Topicort (desoximetasone) has been marketed by Hoechst in over 30 foreign countries. Extensive clinical trials in the United States, conducted by 23 investigators under a wide variety of climatic conditions, confirm the many years of worldwide experience.

A wide range of conditions in corticosteroid-responsive dermatoses: Topicort (desoximetasone) is useful on wet as well as dry lesions, in both acute and chronic cases, with a profile of adverse reactions similar to that seen with other topical corticosteroids.

Emollient Cream

0.25%

Available: 15-gram tubes.
In corticosteroid-responsive dermatoses
Convenient B.I.D. dosage.

Please consult full prescribing information on following page.

071033-677

TOPICORT® (desoximetasone) EMOLLIENT CREAM 0.25%

Description: Topicort® (desoximetasone) Emollient Cream 0.25% contains the active synthetic corticosteroid desoximetasone. The chemical name of desoximetasone is 9α - fluoro - 11β, 21 - dihydroxy - 16α - methylpregna - 1,4 - diene-3,20-dione. The chemical structure is:

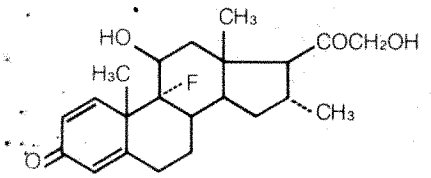

Each gram of Topicort® (desoximetasone) Emollient Cream 0.25% contains 2.5 mg desoximetasone in an emollient cream consisting of isopropyl myristate, cetylstearyl alcohol, white petrolatum, mineral oil, lanolin alcohol and purified water.

Actions: Topicort® (desoximetasone) Emollient Cream is primarily effective because of its anti-inflammatory, antipruritic and vasoconstrictive actions.

Indications: Topicort® (desoximetasone) Emollient Cream is indicated for the relief of inflammatory manifestations of corticosteroid-responsive dermatoses.

Contraindications: Topical steroids are contraindicated in vaccinia, varicella and in those patients with a history of hypersensitivity to any of the components of the preparation. This preparation is not for ophthalmic use.

Precautions: If local infection exists, suitable concomitant antimicrobial or antifungal therapy should be administered. If a favorable response does not occur promptly, application of the corticosteroid should be discontinued until the infection is adequately controlled.

Although systemic side effects associated with absorption of topical corticosteroid preparations are rare, their possible occurrence must be kept in mind when these preparations are used over large areas or for an extended period of time, or if occlusive technique is used.

If irritation or sensitization develops, the preparation should be discontinued and appropriate therapy instituted.

Although topical steroids have not been reported to have an adverse effect on pregnancy, the safety of their use during pregnancy has not been absolutely established; therefore, they should not be used extensively on pregnant patients, in large amounts, or for prolonged periods of time.

Adverse Reactions: The following local adverse reactions have been reported with topical corticosteroids: burning, itching, irritation, striae, skin atrophy, secondary infection, dryness, folliculitis, hypertrichosis, acneform eruptions and hypopigmentation. The following may occur more frequently with occlusive dressings: maceration of the skin, secondary infection, skin atrophy, striae, and miliaria.

Dosage and Administration: Apply a thin film of Topicort® (desoximetasone) Emollient Cream 0.25% to the affected skin areas twice daily. Rub in gently.

How Supplied: Topicort® (desoximetasone) Emollient Cream 0.25% is supplied in 15-gram tubes.

HOECHST-ROUSSEL
PHARMACEUTICALS INCORPORATED
SOMERVILLE, NEW JERSEY 08876

JAMA

for the developments your specialty journal doesn't cover.

JAMA is one of the world's most respected medical journals.

Each weekly issue contains authoritative original contributions featuring the latest clinical developments in research, diagnosis, and treatment.

In addition, JAMA brings you editorials, question and answer columns, news of medical meetings, abstracts of key articles from other journals in the U.S. and abroad, plus letters and reviews of books and films.

Start your JAMA subscription coming today!

	U.S. & Poss.	All Other Countries
☐ 104 issues	$50	$75
☐ 52 issues	$30	$50

(Payment must accompany order. Make check or money order payable to JAMA.)

Name _____

Address _____

City _____ State _____ Zip _____

Return to: Circulation and Records Department
American Medical Association
S/J 535 North Dearborn Street, Chicago, Ill. 60610

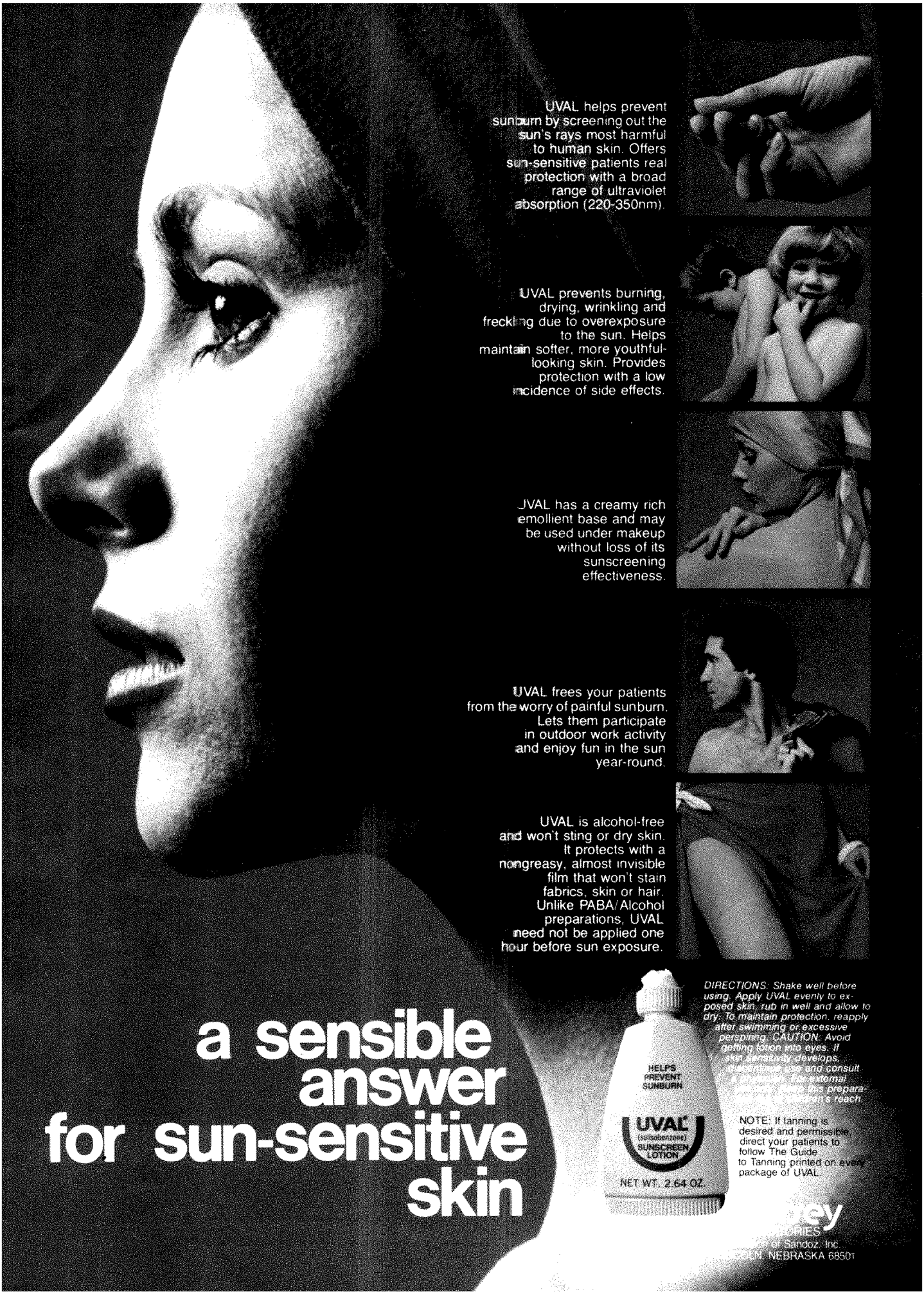
UVAL helps prevent sunburn by screening out the sun's rays most harmful to human skin. Offers sun-sensitive patients real protection with a broad range of ultraviolet absorption (220-350nm).
UVAL prevents burning, drying, wrinkling and freckling due to overexposure to the sun. Helps maintain softer, more youthful-looking skin. Provides protection with a low incidence of side effects.
UVAL has a creamy rich emollient base and may be used under makeup without loss of its sunscreening effectiveness.
UVAL frees your patients from the worry of painful sunburn. Lets them participate in outdoor work activity and enjoy fun in the sun year-round.
UVAL is alcohol-free and won't sting or dry skin. It protects with a nongreasy, almost invisible film that won't stain fabrics, skin or hair. Unlike PABA/Alcohol preparations, UVAL need not be applied one hour before sun exposure.
a sensible answer for sun-sensitive skin
HELPS PREVENT SUNBURN
UVAL (sulisobenzone) SUNSCREEN LOTION
NET WT. 2.64 OZ.
DIRECTIONS: Shake well before using. Apply UVAL evenly to exposed skin, rub in well and allow to dry. To maintain protection, reapply after swimming or excessive perspiring. CAUTION: Avoid getting lotion into eyes. If skin sensitivity develops, discontinue use and consult a physician. For external use only. Keep this preparation out of children's reach.
NOTE: If tanning is desired and permissible, direct your patients to follow The Guide to Tanning printed on every package of UVAL.
ey
ORIES
of Sandoz, Inc.
OLN, NEBRASKA 68501

Letters to the Editor

A Substitute for Chloroform in Prescriptions

To the Editor.—I have just recently learned that the Food and Drug Administration has issued a ban on the use of chloroform in prescriptions. Several letters from dermatologists have already been received asking me to suggest a substitute for it in the prescription advocated in the article that I contributed to the ARCHIVES on the treatment of paronychia and onycholysis (92:726-730, 1965).

I recommended highly the technique of "absolute, continuous dryness" accomplished in general by avoidance of water, including liquid food materials, lotions, and ointments. Only of secondary importance medication with thymol was suggested because of its antibiotic efficacy against all fungi and bacteria. Chloroform was selected as the solvent vehicle because it is nonpolar (not miscible with water) and of specific gravity much more than water. It was the favorite of Hiram Miller (as well as Howard Morrow long before him), and they used 5% chrysarobin dissolved in it. They attributed its benefit to its ability to "float" water out of the interstices because of its high specific gravity. (The abstract of my article did not mention chloroform at all.)

If dermatologists cannot use chloroform in the future, it will indeed be difficult to duplicate the previous formula completely. I first thought of carbon tetrachloride, but it has already been banned for many purposes because of toxicity higher than that of chloroform. To find a substance equally heavy, all hydrocarbons are ruled out at once, because all have less than 1.0 specific gravities.

Halogenated hydrocarbon liquids do have high specific gravities and could be considered if the boiling points are high enough. Possibilities are trichloroethane (either methyl chloroform or vinyl chloride) or methyl iodide. Bromoform would create even more objections than chloroform.

However, I think the factor of "high specific gravity floating water out of crevices" has been overemphasized. I believe that either ethyl or isopropyl alcohol would serve adequately in spite of their specific gravities of less than water (about 0.8). For this particular purpose, they would need to be in the "absolute" form, to avoid the water contained in the usual 95% ethyl or the 70% isopropyl preparations so widely used.

J. WALTER WILSON, MD
Los Angeles

We suggest the use of 1% to 4% thymol, according to the concentrations suggested in Dr Wilson's original article in the "absolute" ethyl alcohol base.—ED.

Schistosomiasis of Spinal Cord and Skin

To the Editor.—In their article "Schistosomiasis: Paraplegia and Ectopic Skin Lesions as Admission Symptoms," which appeared in the May 1976 ARCHIVES (112:690-695), the authors, Wood et al, state that they were unable to find a case report of ectopic cutaneous schistosomiasis that occurred together with spinal cord involvement. We would like to draw the attention of the authors, and that of your readers, to our publication: "Schistosomiasis of Spinal Cord and Skin," (*S Afr Med J* 49(2):57-58, 1975).

Our patient was fortunate in receiving treatment in time to help her recover from her paralysis, and this stresses the importance of early diagnosis and treatment.

NORMA SAXE, MB, CHB, FF Derm (SA)
WALTER GORDON, MD, FRCP
Cape Town, South Africa

In Reply.—Our article was submitted to the ARCHIVES on Jan 14, 1975, prior to the publication of the paper by Drs Saxe and Gordon. The final proof of our paper was returned to the ARCHIVES' editor on March 15, 1975, at which time it did not occur to me to again research the literature. The subsequent delay until publication in May 1976 (16 months following submission of the paper, and 14 months following acceptance of the paper) is beyond my responsibility.

I certainly regret that I failed to see the article that was written by Drs Saxe and Gordon. They are to be congratulated on their early diagnosis and successful treatment.

MARGARET GRAY WOOD, MD
Philadelphia

Transient Acantholytic Dermatosis in South Africa

To the Editor.—A fair-haired, 63-year-old man, whose occupation was a builder, had had an intensely itching rash on his back of two months' duration. His work caused him to be in the sun for much of the day, and he also had many actinic keratoses on his face and arms.

On examination, he had a red, maculopapular rash on the back that resembled pityriasis rosea. The rash was slightly scaly. The individual lesions, however, seemed unusually firm. At the time, I was convinced of the diagnosis of pityriasis rosea and did a skin biopsy. The histologic characteristics showed hyperkeratosis with focal parakeratosis. The epidermis also showed suprabasal clefts and vesicles. Within the vesicles there were shrunken, distorted acantholytic cells. There were no corps ronds. As a result of the clinical history and the histologic findings, a diagnosis of transient acantholytic dermatosis was made. The following blood values were obtained: hemoglobin, 13.0 gm/100 ml; WBCs 6,900/cu mm: eosinophils, 2%; ESR, 15/min. A VDRL test for syphilis was negative.

The following therapeutic regimen was begun: clobetasol propionate cream (British, no US equivalent) three times daily; pyrilamine maleate, 50 mg three times daily; and trimeprazine, 10 mg nightly.

One month later, the rash on the back had improved, but there had been an eruption of new lesions around the shoulders and a few on the chest. He mentioned that the cortisone cream did not help the pruritus, but that the antihistamine tablets did. One month later, his skin was quite clear and he had no pruritus.

The patient had all the main features mentioned by Grover in his original description of transient acantholytic dermatosis.[1] The patient was male, 63 years of age, the eruption followed exposure to the sun, and the condition was transient and lasted approximately three months.

When I was in New York in August 1976, Grover reviewed the slide of this patient's skin biopsy specimen. A. Bernard Ackerman also reviewed the slide at New York Medical Center. They both believed that the scaliness of the lesions was unusual, but that otherwise it seemed to be a typical case of transient acantholytic dermatosis.

PETER LANE, MRCP (EDIN)
Durban, South Africa

1. Grover RW: Transient acantholytic dermatosis. *Arch Dermatol* 101:426-434, 1970.

Jejunoileal Bypass and Psoriasis

To the Editor.—The LETTER TO THE EDITOR by Nowlin and associates (*Arch Dermatol* 112:1465, 1976) has prompted us to report the following case.

Report of a Case.—In 1967, a 44-year-old woman developed plaques covered with slivery scales on her legs, sacrum, and abdomen. This eruption was diagnosed as psoriasis and treated topically with steroids. Later, similar lesions appeared over the scalp, eyelids, cheeks, chest, shoulders, back, groin, and nails. She was hospitalized in 1972 and in 1973, and treated with a modified Goeckerman technique. Excellent but short-lived control of the condition was obtained.

In 1974, the patient underwent a jejunoileal bypass for obesity: her weight decreased from 122 to 77 kg after one year, and to 68 kg after two years. Shortly after her surgery, she began to notice improvement of her psoriasis and, of her own accord, discontinued application of her psoriasis medication. This improvement had continued up to this report, and has included her nails. The only remaining lesions are 2-cm patches on both shins and vague arthritic aches. This patient is now considered to have a protein deficiency that resulted from her surgery, as evidenced by her total serum protein level of 4.4 gm/100 ml (normal, 6.35 ± 0.52 gm/100 ml) and her serum albumin level of 1.96 gm/100 ml (normal, 3.73 ± 0.42 gm/100 ml).

Comment.—This report points to an effect of jejunoileal bypass opposite to that described by Nowlin et al. It would be of interest to know whether this patient developed any type of nutritional deficiency. Whether this contradiction reflects differences in HLA antigens, type of nutritional deficiency, or other factors among psoriatic patients is an intriguing question. Further investigation of this point may shed some light on the pathogenesis of psoriasis in general.

JOSEPH M. PORRES, MD
Minneapolis

Allergic Contact Dermatitis to Herbicides

To the Editor.—Since Spencer's original article in 1966[1] on herbicide dermatitis, little has been written on the sensitizing potentials of herbicides. Indeed, the exact incidence of contact dermatitis to herbicides remains unknown.

During the past 24 months, we have patch-tested 22 patients suspected of having herbicide-induced allergic contact dermatitis. They were tested for all or part of a "herbicides tray" consisting of ten herbicides. These herbicides were all of 1% concentration (commercial source) in petrolatum and were applied for 24 hours. The patch tests were then read at 24, 48, and often at 72 hours after application. The herbicides selected for administration were these: amiben, atrazine, Bladex, Dyfonate, Furadan, Lasso, Lorox, Ramrod, 2-4-D Weed Killer, and Treflan. All patients had a history of exposure to one or more herbicides.

Results.—The only positive or irritant reactions occurred with Ramrod and Lasso, plus one questionable reaction to Treflan at 72 hours. Of the 17 patients patch-tested to Ramrod, seven had positive reactions and five had irritant reactions. Only two of the seven patients with positive tests could directly implicate Ramrod and gave a history of using it. Among the 21 patients patch-tested to Lasso, five had positive results and one had an irritant reaction. Only two of the five patients with positive tests had a direct history of Lasso use.

Comment.—Ramrod and Lasso surpass the eight other herbicides tested, both in irritancy and in their sensitizing potentials. Patients were predominantly farmers who had simultaneous exposure to many herbicides. Despite ample warning on the labels provided by the manufacturer that indicated the possibility of skin irritation and sensitization, many of the patients admitted to careless or accidental contamination of skin or clothing without any attempt to remove the offending agent immediately. One of us has observed a patient for several years. This farmer is so highly sensitized to Ramrod that he develops a generalized airborne contact dermatitis each spring when his neighbors use this product.

Both Ramrod and Lasso are used in the pre-emergence and early post-emergence growth cycle of crops and have similar spectrums of weed control and crop tolerance. Ramrod (propachlor) (2-chloro-*N*-isopropylacetanilide) is used for the control of most annual grasses and certain broadleaf weeds. Resistant crops include corn, sorghum, soybeans, other legume crops, fruit trees, and many ornamentals.[2] Lasso (alchlor) (2-chloro-2',6'-diethyl - *N* - [methoxymethyl]acetanilide) is also used to control most annual grasses and certain broadleaf weeds and yellow nutsedge. Tolerant crops include corn soybeans, peanuts, cotton, woody fruits, and certain ornamentals.[3]

We suggest, for patch testing, the use of lower concentrations of Ramrod and Lasso in the future, perhaps 0.5%, 0.25%, or 0.1%, to reduce the number of irritant reactions. The irritancy of these two herbicides may well contribute to their sensitizing ability. The fact that both Ramrod and Lasso are acetanilides suggests that this moiety may be the sensitizing fraction. The fact that both contain chloride moieties may contribute as well. Spencer found that Randox, Randox-T, and Ramrod all contain chloroacetyl groups, which were stated to be quite reactive.[1] He suggested but could not confirm cross-sensitization among Randox, Randox-T, and Ramrod. Randox-T is no longer marketed (F. R. Johannsen, PhD, Monsanto Co, written communication). We found three patients who reacted to both Ramrod and Lasso. This suggests the possibility of cross-sensitization, but the small size of our group and the fact that not all patients were tested to both herbicides makes it impossible for us to confirm this.

Rasmussen and Cole[4] state that "The chief problem with propachlor (Ramrod), alachlor (Lasso), atrazine, and Treflan is contact dermatitis." We concur that allergic contact dermatitis to Ramrod and Lasso exists, but we cannot draw any conclusion about its incidence. Large amounts of these herbicides apparently are used. It may be that only a small fraction of users develop an allergic contact dermatitis. The possibility also exists that those who have become sensitized have violated normal precautions and put themselves at unnecessary risk.

Physicians who treat agriculturists should be aware of the possibility of acute allergic contact dermatitis from Ramrod and Lasso. They will then be in a position to advise their patients to avoid further contact with these agents and thus prevent future disability from a potentially chronic occupational dermatosis.

DONALD L. IDEN, MD
ARNOLD L. SCHROETER, MD
Rochester, Minn

1. Spencer MC: Herbicide dermatitis. *JAMA* 198:1307-1308, 1966.
2. *Herbicide Handbook of the Weed Science Society of America*, ed 3. Champaign, Ill, Weed Science Society of America, 1974, pp 331-333.
3. *Herbicide Handbook of the Weed Science Society of America*, ed 3. Champaign, Ill, Weed Science Society of America, 1974, pp 8-11.
4. Rasmussen RW, Cole GA: The spectrum of agricultural medicine. *Minn Med* 59:536-539, 1976.

Treatment With Penicillamines

To the Editor.—As I read the "Comment" section of the case report of

Drs Campo and McDonald, which was entitled "Treatment of Acrodermatitis Enteropathica With Zinc Sulfate" (*Arch Dermatol* 112:687-689, 1976), an interesting thought occurred to me. The physicians point out that among many other treatments, penicillamines have been used for treatment. That being the case, and if their theory is correct, the penicillamine-treated babies should have gotten worse, since penicillamine is a nonselective chelator and it would, therefore, surely have chelated the zinc in an already presumably zinc-deficient baby. I hope that we hear from the penicillamine-users as to whether their patients did get worse, because it would be excellent indirect evidence of the correctness of the theory of Drs Campo and McDonald.

In my own experience, there was a child with Wilson's disease who, on long-term penicillamine therapy, developed a very severe dermatitis that responded very nicely to oral zinc sulfate therapy. Perhaps someday we will refer to congenital and induced acrodermatitis enteropathica.

As an additional item of thought, might not acrodermatitis enteropathica also be a dependency disease much like pyridoxine-dependent convulsive disorder or vitamin D-resistant rickets, such that the usual amount of zinc in the diet does not prevent disease, but in marked excess, it does? Since zinc is a well-known coenzyme in several enzyme systems, much as are pyridoxine and vitamin D, I think this theory at least deserves investigation.

ARTHUR N. WARD, MD
Smithfield, Pa

In Reply.—I have read with interest the letter from Dr Ward, and I have very few comments to make other than to indicate that our reference to the use of penicillamine in the treatment of acrodermatitis described regrowth of hair during penicillamine treatment. There was also a comment that the accompanying dermatitis initially cleared but then recurred to a rather great extent within several weeks after the treatment was begun.

This, to my knowledge, is the only reference to the treatment of acrodermatitis enteropathica with penicillamine. I agree that the administration of penicillamine to a patient with acrodermatitis may, in fact, exacerbate that disease; however, we have no reference material to which we can refer that would confirm our impression.

I also agree that as we learn more about the metabolism of zinc in the skin, we will find that there are a large number of zinc-deficiency dermatoses that until this time have, in all probability, gone unnoted and also undiagnosed.

CHARLES J. MCDONALD, MD
Providence, RI

In Reply.—I found Dr McDonald's reply fascinating—particularly his remark, ". . . we will find that there are a large number of zinc-deficiency dermatoses that until this time have, in all probability, gone unnoted and also undiagnosed." This letter comes then, as a "reply to a reply" because of several new ideas that I have.

First, I had a patient with a silvery, lichenified, pink lesion on each elbow that, though I unfortunately did not perform a biopsy on either, looked to me like classical psoriasis. Based on my appreciation of Dr McDonald's rationale in using zinc for acrodermatitis enteropathica, I thought to myself, in effect: "She's got a psoriasiform lesion—two small areas with no evidence of systemicity," (if I may coin a word along with, hopefully, a helpful idea). "Therefore, since psoriasis is a disease on which an origin has not been agreed (if it is even known), why not try zinc sulfate for treatment?"

Quaintly, the patient's lesions did heal! (I've tried zinc since—with failure, in all honesty—but I wonder, have others tried zinc for diagnosed psoriasis, atopic dermatitis, acne, and other such disorders?) I had given my patient a prescription for 250 mg of zinc sulfate daily, although I realize that this was about 15 times the minimum daily requirement (MDR) of zinc. I also, of course, warned her to discontinue usage of the medication if she vomited or if she felt nauseous, since this would be the earliest sign of zinc toxicity. Might the dosage, however, have been carried higher in a nonresponder based on the consideration of this as a possible zinc *dependency* disease (cf, hypophosphatemic vitamin-resistant rickets, which is of sex-linked, inherited origin and often requires 100 to 1,000 or more times the usual MDR of vitamin D to produce a response)?

A second thought that came to mind was: since penicillamine produced hair growth in patients with acrodermatitis, might it (or some other chelator) not help male pattern baldness? Perhaps such baldness is a holandrically-inherited propensity to over-absorb zinc and therefore, to lose hair. Of course, in bald men (such as myself) who happen to be allergic to penicillin, demercaprol, edetate, or potassium sulfide could be tried.

Finally, I wonder if topical steroids might not exert their favorable effect on skin by driving sodium ions into the systemic circulation and thereby selecting against *Staphylococcus aureus*. In a sense, these steroids may increase the skin's bacterial competition, since *Staphylococcus* bacteria are well known to flourish in high sodium concentrations (and even in the ocean). Might this not also implicate high sodium ion concentration in acne vulgaris, which arises in adolescents, who differ from children in that they have more hormone production and therefore, more sodium in their facial and thoracic perspiration? I've tried putting teenagers with severe, comedomatous acne on very low sodium diets, with some success clinically. I've also tried the "familial granulomatosis" regime, which consists of high doses of iodine and ascorbic acid, since acne is, at times, sort of a facial model of this disease; I perform neutral blue toluidine studies also, on occasion.

The relevance of all this to zinc is that one of the medicines that is used to treat acne is zinc oxide, which sometimes helps! Maybe sodium and zinc, as metallic ions, compete with each other on the skin in some unknown way. If this is so, a more soluble (ie, more ionic) zinc salt, such as zinc sulfate or zinc chloride, should be tried on the skin of acne sufferers.

ARTHUR N. WARD, MD
Smithfield, Pa

Bits of Bicentennial Dermatology

To the Editor.—With all the current popularity of exhibits of colonial medicine as part of Bicentennial reviews, it is of interest to add some bits of dermatology.

First, Indian medicine; the chief dermatological problem was, of course, the epidemics of smallpox acquired from the white man.[1] Many of the herbs used by the Indians were later incorporated into the pharmacopeia.[2] Boils and superficial wounds were treated with the roots of the tobacco plant. Rothman, many years later, used an infusion of tobacco for the treatment of recalcitrant pustular dermatitis of the hands. Snake root (*Aristolochia serpentaria*) and lion's heart (prenanthese reubincunda) were used for snake bites.[2] Celandine (balsam, jewelweed, touch-me-not, snapweed, lady's earrings) that was popular with the Indians is used today

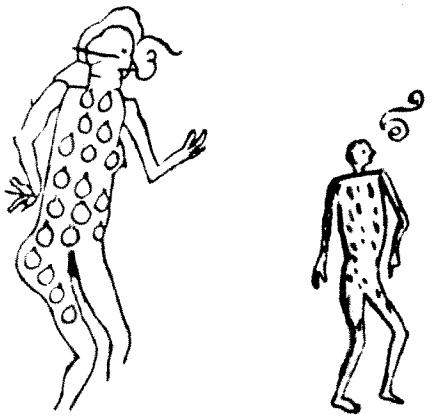

Fig 1.—Rock painting, portrayal of smallpox among Indians from Colorado and Dakota, 1779-1780.



Fig 2.—Probable epidermal cysts: Amos Morrow (reprinted from Goldman.[5]).



Fig 3.—Portrait of Nathaniel Allen, 1763 showing details of hairy nevi.

among farmers for the treatment of poison ivy dermatitis. A great variety of herbs were used in the treatment of venereal disease by the Indians. These were more effective with gonorrhea than with syphilis. The *Gazette of Williamsburg* also detailed some interesting remedies for the treatment of venereal diseases during the colonial period. It is perhaps not well known that Corlett, one of the early dermatologists of Cleveland, established a special room in the Allen Memorial Library in Cleveland for Indians and Indian Medicine. In lower Canada, the medical officers in 1782 were using mercury for syphilis, and the government issued pamphlets in regard to mercury therapy. This was one of the early evidences of public health measures for the control of venereal disease.

In regard to the physicians, Benjamin Rush included mercurial ointments in his medicine case and discussed skin diseases in his *Practice of Medicine*. He also taught that the skin was nonabsorptive. Reuben Mussey, in Cincinnati in 1838, proved that the skin was absorptive by putting his entire body in a tub of madder. Preston[3] indicates that for days afterwards he passed red dye in his urine. None of the other physicians of that period, Josiah Bartlett, Lyman Hall, or Matthew Thornton, wrote about skin diseases. Dr Richard Allison, a surgeon of the Fifth Pennsylvania Regiment during the Revolutionary War and the first physician in the Cincinnati area, wrote about the need for supplies and a hospital and not about dermatology, although he helped in the severe smallpox epidemic in Cincinnati in 1793.

Benjamin Franklin[4] evidently did not use his famed electric shock therapy for the treatment of his own recurrent eczema that he acquired in his 80s. This dermatitis covered his entire body except his hands and face. A flare of his severe gout once cleared his eczema briefly. Also, at times, warm baths helped.



Fig 4.—Jonathan Dwight I (1743-1831) with filiform warts. Last decade 18th century.

Franklin, also, was treated by Sir John Pringle. It is of interest that Sir John Pringle wanted Franklin to "electrify" the epileptic daughter of the Duke of Ancaster. Franklin's remark about his gout could well be applied to his eczema. He said, "People who live long and who will drink the cup of life to the very bottom must expect to meet with some of the usual dregs."

The portrayal of skin lesions by colonial artists during that period has also shown some interesting samples. Four examples have been collected. Figure 1 is an Indian rock painting depicting smallpox. Figure 2 is of Amos Morrow[5] with scalp lesions (epidermal cysts), 1795. His portrait was presented as a case for diagnosis at the Cincinnati Dermatological Society. Figure 3 is a portrait of Nathaniel Allen with two hairy nevi. Jonathan Dwight with the extensive filiform warts of the face is seen in Fig 4.

These are interesting examples of the realism of the American painters of that period. Skin diseases of that period and later were described in much greater detail by Daniel Drake[6] in his famed books in 1815 and 1850.

LEON GOLDMAN, MD
Cincinnati

Beatrix Rumford, Director and Barbara Luck, Registrar of the Abby Aldrich Rockefeller Folk Collection of Williamsburg, helped in the collection of several of these examples. Lisabeth M. Holloway, Curator, Historical Collections Library of the College of Physicians of Philadelphia reviewed the publications about skin diseases in colonial dermatology.

Figure 1 is reprinted with the permission of K. F. Wellmann. Figure 2, by Charles Peale Pock, is reprinted with the permission of the Abby Aldrich Rockefeller Folk Art Collection of Williamsburg. Figure 3, by John Singleton Copley, is reprinted with the permission of the Honolulu Academy of Arts, Frank C. Atherton Memorial Fund Purchase, 1976 (4376.1). Figure 4 is a gift of Barbara Mercer Adam and Charlotte Adam Coate to the Metropolitan Museum of Art, and is reprinted with the museum's permission.

1. Wellmann KF: Medizinische und paramedizinische Bezuge in indianischen Felsbildern Nordamerikas. *Dtsch Med Wochenschr* 99:307-311, 1974.

2. Moore RG: Indian remedies. *Ohio State Med J* 71:661, 1975.

3. Preston RH: *History of Dermatology of Cincinnati*. Read before the Central States Dermatological Association, May 10, 1969.

4. Bell WJ Jr: *The Colonial Physician and Other Essays*. New York, Science History Publication, 1975.

5. Goldman L: Scalp lesions in early American art. *NY State J Med* 72:222, 1972.

6. Goldman L: Dermatology of Daniel Drake. *Int J Dermatol* 14:676-687, 1975.

Nonvenereal (?) Sclerosing Lymphangitis of the Penis

To the Editor.—The use of the adjective "nonvenereal" by Fiumara to describe sclerosing lymphangitis of the penis seems in error (*Arch Dermatol* 111:902-903, 1975). The lesion is associated with (or related to) sexual (venereal) acts *in every instance.* Why use nonvenereal to designate something clearly venereal?

THOMAS S. SAUNDERS, MD
Portland

In Reply.—The venereal history of the three patients in my report was clearly stated. Earlier reports stressed the nonvenereal nature, and until the studies of additional patients are accomplished the common nomenclature was used. My personal opinion is that sclerosing lymphangitis of the penis is acquired sexually.

NICHOLAS J. FIUMARA, MD, MPH
Boston

Atypical Fibroxanthoma

To the Editor.—In the August 1976 issue of the ARCHIVES (112:1155-1157), Goette and Odom present a case report entitled "Atypical Fibroxanthoma Masquerading as Pyogenic Granuloma." In their presentation they make several strong statements that add to their argument, with which I must take issue.

The future of a lesion that bears this diagnosis is not at all certain, and as they point out, "It has no characteristic morphological features that permit a diagnosis on clinical grounds alone, and, therefore, necessitates a biopsy for diagnosis." They go on:

> In order that unnecessary radical surgical procedures be avoided, it is imperative that clinical and histological aspects of every lesion that receives a serious consequential diagnosis be analyzed critically to avoid grave pitfalls of judgement clinically, histologically, and most important, therapeutically.

I am afraid that despite every scrutiny given by experts, these tumors can and do kill. Goette and Odom noted several reports in their article. I think it is wiser to point out that the entire concept of the nosology of "pseudotumors" begins with a misnomer. These are tumors whose destinies are not exactly predictable, despite their usual benignity. This is illustrated in the case of my patient.

My patient was a 62-year-old man with a lump on the back that was diagnosed as "pseudosarcomatous fasciitis," "angiosarcoma," "atypical dermatofibrosarcoma," and by Dr R.V.P. Hutten, as "atypical fibroxanthoma." Because of several postoperative recurrences, the patient received electron-beam therapy at Memorial Hospital in New York. However, he died of invasive fibrosarcoma of the lung. Schreiber's patient, a 43-year-old woman with "pseudosarcomatous fasciitis," met a similar fate.[1]

Until the immunologists work us out of the corner that we have painted ourselves into, rational therapy will continue to be empirical, based on the unlikely possibility of a dire end. It is an utter delusion to believe that we understand the clinical or pathological basis of whatever we finally agree to call this entity.

HOWARD S. YAFFEE, MD
Cambridge, Mass

1. Yaffee HS: Masked fibrosarcomas. *Cutis* 6:1353, 1970.

In Reply.—Dr Yaffee's comments pertaining to "pseudotumors," probably meaning *pseudomalignancies,* are generally applicable to the concept of pseudomalignancies, and we do not claim to have illusions about understanding any one or all of them. His unfortunate experience with a case of metastasizing fibrosarcoma points out the important fact that dermatologists should have a thorough knowledge of the histopathology and clinical manifestations of these tumors. The diversity of histological diagnoses that were rendered in his case points out the unfamiliarity of many a pathologist with these entities.

As Dr Yaffee certainly knows, a fibrosarcoma does not qualify as a pseudomalignancy. Misnomer or not, the fact remains that our statements about atypical fibroxanthoma (AFX) in particular, are substantiated by over 200 cases that are recorded in the literature. As pointed out in our article, two cases metastasized, and close follow-up examinations were recommended in all cases of AFX. In our opinion, the occasional, exceptional case does not detract from the fact that AFX generally is a condition with a histologically malignant appearance and a benign clinical course, or as some have called it, a pseudomalignancy.

LT COL DETLEF K. GOETTE, MD, MC
San Francisco

Peculiar Persistent Pruritic Affection of the Skin

To the Editor.—Itch, the prime dermatologic symptom, wears many faces. I have observed over the years a number of patients complaining of a peculiar type of itching that, to my knowledge, has not appeared in the dermatologic literature. When the patients are persuaded to describe the itching, several clear-cut characteristics emerge. The itch is momentary, attacks only a small area, and is relieved by a single scratch or pinch. The area in which the itch occurs is usually centripetal. It may be localized, as on one side of the back, the face or the perianum, or widespread areas of skin may be involved. If a social situation precludes scratching, the itch abates during a period of a few minutes, but often recurs in the same site a short time later. The condition usually affects older patients and usually is chronic. There is no evidence of dermatitis, and topical therapy is ineffective.

The spontaneous temporally and spatially localized character of the itch suggests that it is mediated via the delta fibers of A-class nerves, rather than the C fibers that conduct diffuse itching.[1] As to origin, I have no clue.

Alliteration using the letter P has been popular with dermatologists over the years.[2-5] Electing to follow this tradition I have chosen to name this entity, "peculiar persistent pruritic affection of the skin."

IRA LEO SCHAMBERG, MD
Elkins Park, Pa

1. Lorincz AL: Neurophysiologic reactions of the skin: Pathophysiology of pruritus, in Fitzpatrick TB (ed): *Dermatology in General Practice.* New York, McGraw-Hill Book Co Inc, 1971.
2. Schamberg JF: A peculiar progressive pigmentary disease of the skin. *Br J Dermatol* 13:1, 1901.
3. Ackerman AB, Kornberg R: Pearly penile papules: Acral angiofibromas. *Arch Dermatol* 108:673-675, 1973.
4. Schlappner OLA, Wood MG, Gerstein W, et al: Painful and nonpainful piezogenic pedal papules. *Arch Dermatol* 106:729-733, 1972.
5. Bendl BJ: Painful pigmented prosthesis pressure papules. *Cutis* 17:954-957, 1976.

Isoniazid-Induced Pellagra

To the Editor.—In a communication on the subject of isoniazid-induced pellagra,[1] we mentioned preliminary evidence that rats receiving isoniazid showed evidence of increased epidermal lipid biosynthesis. This result was of interest first because isoniazid, as an antagonist of the hypocholesterolemic agent niacin, might be expected if anything to stimulate lipid and especially sterol biosynthesis. Second, increased levels of total epidermal lipogenesis and of sterol biosynthesis relative to other lipids are found in lesions of psoriasis and lichen simplex[2]

Present Results With Higher Doses of Isoniazid		
Group	Epidermal Lipogenesis (dpm* 3-mm Biopsy Specimen)	Sterols (% of Total Lipid Labeling)
Controls (N = 8)	6,620 ± 380	6.22 ± 0.69
Isoniazid-treated, 20 mg/kg/day for 8 wk (N = 8)	7,010 ± 630	4.93 ± 0.46
Isoniazid-treated 40 mg/kg/day for 8 wk (N = 7)	5,420 ± 540	5.50 ± 0.40

*dpm indicates disintegrations per minute.

and it seemed possible that a similar change might accompany isoniazid-induced hyperkeratosis.

When, however, our preliminary results were checked using larger groups of animals and higher doses of isoniazid, we were unable to substantiate the initial conclusion. Our present results (Table) are as follows (mean ± SEM).

The rats used were intact females aged eight to ten weeks at the start of the experiment and they were maintained on a standard breeding diet (Oxoid) ad libitum. Epidermal lipogenesis from tagged with carbon 14 glucose was measured as previously described.[3] Apart from showing no evidence of altered lipid metabolism, the epidermis from isoniazid-treated rats was histologically normal and there was no increase in the number of cell layers in the stratum corneum measured after alkali swelling.[4] These results are consistent with our failure to reproduce the cutaneous symptoms of pellagra by topical application of isoniazid in normally nourished individuals.[1] It seems possible that the induction of a pellagra-like syndrome by isoniazid requires a poor nutritional status in addition to the metabolic antagonism of niacinamide by the drug.

J. S. Comaish, MD
Mary Cooper, MD
Newcastle upon Tyne, England

Nonproprietary Name and Trademarks of Drug

Isoniazid—*Hyzyd, Niconyl, Nydrazid.*

1. Comaish JS, Felix RH, McGrath H: Topically applied niacinamide in isoniazid-induced pellagra. *Arch Dermatol* 112:70-72, 1976.
2. Cooper MF, McGrath H, Shuster S: Epidermal lipogenesis in psoriasis and lichen simplex. *Br J Dermatol* 94:369-378, 1976.
3. Cooper MF, Thody AJ, Shuster S: Hormonal regulation of cutaneous lipogenesis: Effects of hypophysectomy, posterior-hypophysectomy and α-melanocyte-stimulating hormone treatment. *Biochem Biophys Acta* 360:193-204, 1974.
4. Christophers E, Kligman AM: Visualization of the cell layers of the stratum corneum. *J Invest Dermatol* 42:407-410, 1964.

Treatment of *Mycobacterium marinum* Infections With Minocycline

To the Editor.—Two cases of *Mycobacterium marinum* infections were successfully treated with minocycline hydrochloride (Minocin). Loria reported his experience with this drug in 1976.[1] Prior to that, Dr E. Epstein remarked in the SOCIETY TRANSACTIONS that he knew of four cases that were successfully treated with minocycline.[2] Kim treated and cured six cases of *M marinum* with tetracycline, which patients took over a two- to three-month period.[3]

Report of Cases.—CASE 1.—A 50-year-old man had a four-year history of nonhealing granulomas on the lower aspect of his right leg. The lesion previously had been treated with penicillin without response. A punch biopsy showed a granuloma, and culture of the tissue at room temperature grew a photochromagen that was identified as *M marinum.* He was treated with 100 mg of minocycline hydrochloride twice a day and showed complete healing of the lesions after eight weeks. He was occasionally bothered with dizziness and a lightheaded feeling during the course of his therapy.

CASE 2.—A 61-year-old woman developed three deep, slightly tender nodules on the lower aspect of her right leg. One of the lesions spontaneously drained a purulent material. She was treated with cloxacillin sodium monohydrate for four weeks, without any change in the lesions. After confirmation of a *M marinum* infection by biopsy and culture, she was treated with 100 mg of minocycline hydrochloride twice a day. Within one week after minocycline therapy was started, there was improvement of all of the nodules. By the end of four weeks, the dosage was reduced to 50 mg twice daily because of dizziness. On this lower dose, the dizziness disappeared. After six weeks of therapy, almost all of the lesions had completely cleared.

Comment.—Both patients most likely obtained their infections in the Chesapeake Bay.[4,5] The first patient has a home at the edge of the bay and the second patient frequently sails on the bay. Although neither patient could recall any specific trauma to his or her leg, both were exposed to the Chesapeake Bay waters on many occasions.

From these two cases, as well as from the previously reported cases, it would seem that minocycline, tetracycline, or any other of the tetracycline derivatives would be the treatment of choice in *M marinum* infections.

Norman A. Lockshin, MD
Silver Spring, Md

1. Loria PR: Minocycline hydrochloride treatment for atypical acid-fast infection. *Arch Dermatol* 112:517-519, 1976.
2. Cutaneous *Mycobacterium marinum* infection, SOCIETY TRANSACTIONS. *Arch Dermatol* 110:984, 1974.
3. Kim R: Tetracycline therapy for atypical mycobacterial granuloma. *Arch Dermatol* 110:299, 1974.
4. Zeligman I: *Mycobacterium marinum* granuloma: A disease acquired in the tributaries of the Chesapeake Bay. *Arch Dermatol* 106:26-31, 1972.
5. Cott RE, Carter DM, Sall T: Cutaneous disease caused by atypical mycobacteria. *Arch Dermatol* 95:259-268, 1967.

Congenital Pigment Formation

To the Editor. This figure shows an 8-month-old infant who has a congenital pigment formation in the shape of a deer track. It is not a nevus in the usual sense of the word, but seems to be outlined by the pale ventral median stripe and by a medial extension of the familiar pigment-border that is often found on the arm. The baby's

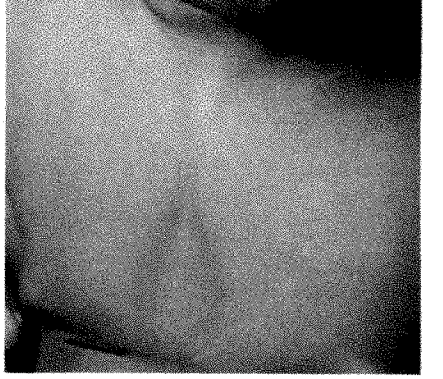

family history is not available, so we have no unsuperstitious explanation of the anomaly. Although I have seen several clear and definite deer tracks and many vague and imperfect ones in pediatric practice, I have neither heard of a name for this mark nor read a description of it; and my favorite dermatologist could not say much more. We would appreciate information from your staff; and if any mystery remains, we hope that you can publish the photograph for comment from your readers.

Grange S. Coffin, MD
Berkeley, Calif

Tetracycline-Resistant Granuloma Inguinale

To the Editor.—I have observed a case of granuloma inguinale in which prolonged treatment with 2 gm of oral tetracycline hydrochloride per day failed to produce clinical or microbiologic response.

Report of a Case.—A 40-year-old man was admitted to the University of Miami Dermatology service on Sept 6, 1975, for treatment of extensive granuloma inguinale. Ten years prior to admission, he developed a nodule on his left upper inner thigh that later ulcerated and enlarged. He had received numerous courses of oral antibiotics, mostly tetracyclines, but always stopped therapy before healing was complete. His medical follow-up was sporadic. On admission, he had a beefy-red, granular, eroded lesion involving the left upper inner thigh, left inguinal area, base of the scrotum, and the intergluteal and perianal areas. Its border was heaped up and serpiginous. Crush preparations of tissue from the lesion stained with Wright-Giemsa and Warthin-Starry stain showed numerous Donovan bodies in large mononuclear cells. Biopsy specimens of the lesion showed the inflammatory changes of granuloma inguinale and confirmed the presence of Donovan bodies.

Treatment consisted of sitz baths, compresses, and oral tetracycline hydrochloride (500 mg four times a day) taken on an empty stomach and administered by the nursing staff. This treatment was continued throughout his 38-day hospitalization. Ingestion and absorption of tetracycline was confirmed by bright-yellow fluorescence of the patient's urine under Wood's light as compared with control urine. During the hospitalization, the lesion became less purulent and foul-smelling, but showed only minimal signs of healing. Repeat biopsies and crush preparations on the 30th day of hospitalization showed persistence of an active inflammatory process typical of granuloma inguinale and the presence of Donovan bodies. Oral sulfisoxazole (1 gm, four times a day) was begun on the 31st hospital day, and the tetracycline treatment was continued. By the 38th day, signs of healing were noted, and biopsy specimens showed diminution of the inflammatory process and the absence of Donovan bodies. Crush preparations, likewise, showed no Donovan bodies. The patient insisted on continuing his treatment as an outpatient and was discharged, but failed to return for follow-up.

Comment.—Tetracycline is considered the treatment of choice for granuloma inguinale. Although failure of tetracycline in treating this disease has been suggested,[1,2] most patients received low doses or short periods of treatment. The present case demonstrates that under optimal conditions (ie, hospitalization, supervised drug administration in acceptable doses for a prolonged interval), clinical and microbiologic resistance to tetracycline can occur in granuloma inguinale. Repeated inadequate courses of tetracycline therapy may have fostered the emergence of resistant organisms in this patient.

ROBERT J. PARISER, MD
Miami

1. Robinson RCV, Elmendorf DF, Zheutlin HEC: Aureomycin in the treatment of granuloma inguinale. *Am J Syph* 33:389-396, 1949.

2. Greenblatt RB, Barfield WE, Dienst RB, et al: A five-year study of antibiotics in the treatment of granuloma inguinale. *Am J Syph* 36:186-191, 1952.

Betamethasone and Its Derivatives

To the Editor.—May I draw your attention to a confusing nomenclature in the article entitled "Multicenter Trial Analysis: Fluocinonide and Betamethasone Gel in Psoriasis" (*Arch Dermatol* 112:1729-1733, 1976). The corticosteroid under study was betamethasone benzoate, and it is correctly referred to just once in the summary, once in the text, and in the figures. However, in the title and on most of the occasions in the text, it is referred to as betamethasone. Betamethasone benzoate, like betamethasone valerate, is an ester derived from betamethasone (alcohol), and all three substances have different biological properties. Betamethasone is a highly active anti-inflammatory corticosteroid when given systemically, but has little activity when applied to the skin. On the other hand, the two esters have a relatively low level of systemic activity but are highly active when applied topically. Further, considerable differences in activity can be seen between various esters derived from the same parent alcohol and betamethasone benzoate does not have the same properties as the valerate or other esters of betamethasone.[1]

In view of these differences, and with the growing understanding of the importance for clinicians to know exactly which topical corticosteroid they are using and to be fully acquainted with its strength,[2] it is important to consistently use the correct nomenclature. This is especially true in a field where there is such a large number of active principles with remarkably similar names.

C. G. SPARKES, PHD
London

1. Phillipps GH: Locally active corticosteroids: Structure activity relationships, in Wilson LC, Marks R (eds): *Mechanisms of Topical Corticosteroid Activity*. Edinburgh, Churchill Livingstone, 1976, pp 1-18.

2. Champion RH, Goldin D: Clinical aspects of topical therapy. *Pharm J* 218:328-330, 1975.

DESCRIPTION

Synalar® (fluocinolone acetonide) has the
6α, 9α-difluoro-16α-hydroxyprednisolone-1

Synalar® Solution 0.01%—contains 0.01% fl
acetonide in propylene glycol with citric

Synalar® Ointment 0.025%—contains 0.02
acetonide in white petrolatum.

Synalar-HP® Cream—contains 0.2% fluoci
in a water-washable aqueous base of ste
alcohol, mineral oil, propylene glycol, sorl
stearate, polyoxyethylene sorbitan monos
citric acid, with methylparaben and prop
preservatives.

Synemol™ (fluocinolone acetonide) has th
6α, 9α-difluoro-16α-hydroxyprednisolone-1

The vehicle is a water-washable aqueous
stearyl alcohol, cetyl alcohol, mineral oil,
sorbitan monostearate, polyoxyethylene
stearate and citric acid.

INDICATIONS

For relief of the inflammatory manifestatio
steroid-responsive dermatoses.

CONTRAINDICATIONS

Topical steroids are contraindicated in vc
varicella.

Topical steroids are contraindicated in th
history of hypersensitivity to any of the con
preparation.

Synalar-HP Cream should not be used or
years of age.

PRECAUTIONS

If irritation develops, the product should b
appropriate therapy instituted.

In the presence of an infection the use of
antifungal or antibacterial agent should
favorable response does not occur prom
steroid should be discontinued until the in
adequately controlled.

If extensive areas are treated or if the occ
used, the possibility exists of increased sys
of the corticosteroid and suitable precau
taken.

Although topical steroids have not been re
adverse effect on pregnancy, the safety
pregnant females has not absolutely bee
Therefore, they should not be used extens
patients, in large amounts, or for prolonge

Topical steroids are not for ophthalmic us

Synalar-HP Cream should not be used for
and the quantity per day should not exce
formulated material.

ADVERSE REACTIONS

The following local adverse reactions hav
with topicalcorticosteroids: burning, itchin
dryness, folliculitis, hypertrichosis, acneform
hypopigmentation.

Synalar Cream and Ointment, Synemol C

The following may occur more frequently
dressings than without such therapy: mac
secondary infection, skin atrophy, striae, n

HOW SUPPLIED

Synalar® (fluocinolone acetonide)
Cream 0.025%—15, 60 g tubes; 120, 425 g
Cream 0.01%—15, 45, 60 g tubes; 120, 425
Ointment 0.025%—15, 60 g tubes; 425 g jc
Solution 0.01%—20, 60 cc plastic squeeze
Synalar-HP® (fluocinolone acetonide) 0.2
tubes.
Synemol™ (fluocinolone acetonide)
Cream 0.025%—15, 60 g tubes.

These preparations are available on pres

SYNTEX
SYNTEX LABORATORIES, INC.
PALO ALTO, CALIFORNIA 94304

INFLAMMATION OF
CONTACT DERMATITIS

SOLVED

SYNALAR® TOPICALS

New fast way with spray
for contact dermatitis control

New Diprosone® Aerosol 0.1%
brand of
betamethasone dipropionate (Potency expressed as betamethasone)

Rapid improvement of moderate to very severe contact dermatitis signs/symptoms*

	Per cent of patients improved†		
	Pruritus 129 patients	**Erythema 129 patients**	**Vesiculation 77 patients**
After 3 days	85%	78%	82%
After 7 days	92%	93%	94%

*Improvement is defined as a reduction of signs or symptoms. †Data in files of Headquarters Medical Research Division, Schering Corporation.

- Easily penetrates hairy areas...convenient for hard-to-reach sites.
- Cools and soothes hot, oozing, itching lesions.
- Cosmetically elegant...invisible, odorless, stainless.

Diprosone is also available in cream, ointment, and lotion.

COPYRIGHT © 1977, SCHERING CORPORATION. ALL RIGHTS RESERVED. SLS-846

See Clinical Considerations section on opposite page...

Schering

New Diprosone®

brand of
betamethasone
dipropionate

Aerosol 0.1%

Clinical Considerations: INDICATIONS DIPROSONE Aerosol is indicated solely for the adjunctive topical management for the relief of inflammatory manifestations of acute contact dermatitis. DIPROSONE Aerosol has not been shown to be effective in any steroid-responsive dermatosis other than contact dermatitis. **CONTRAINDICATIONS** DIPROSONE Aerosol is contraindicated in vaccinia and varicella. Topical steroids are contraindicated in those patients with a history of hypersensitivity to any of the components of such preparations. DIPROSONE Aerosol is also contraindicated for use under occlusive dressings. **WARNINGS** Keep away from eyes or other mucous membranes. Use only as directed; intentional misuse by deliberately concentrating or inhaling the contents can be harmful or fatal. Avoid freezing of the tissue by not spraying for more than three seconds, at a distance of not less than six inches. Contents under pressure. Do not puncture. Do not use or store near heat or open flame. Exposure to temperatures above 120° Fahrenheit may cause bursting. Never throw container into fire or incinerator. Keep out of reach of children. **PRECAUTIONS** If irritation develops with the use of DIPROSONE Aerosol, treatment should be discontinued and appropriate therapy instituted. In the presence of an infection, the use of an appropriate antifungal or antibacterial agent should be instituted. If a favorable response does not occur promptly, the corticosteroid should be discontinued until the infection has been adequately controlled. If extensive areas are treated, the possibility exists of increased systemic absorption of the corticosteroid and suitable precautions should be taken. Although topical steroids have not been reported to have an adverse effect on pregnancy, the safety of their use in pregnant females has not been absolutely established. Therefore, they should not be used extensively on pregnant patients, in large amounts or for prolonged periods of time. DIPROSONE Aerosol is not for ophthalmic use. **ADVERSE REACTIONS** The following local adverse reactions have been reported with topical corticosteroids: burning; itching; irritation; dryness; folliculitis; hypertrichosis; acneiform eruptions; hypopigmentation; maceration of the skin; secondary infection; skin atrophy; striae; miliaria.

1079105 MARCH 1977

Aerosol Packaged by Aerosol Techniques, Inc.
Armstrong Laboratories Division
West Roxbury, MA 02132

For more complete details, consult package insert or Schering literature available from your Schering Representative or Professional Services Department, Schering Corporation, Kenilworth, New Jersey 07033.

How are you keeping up with happenings in your specialty?

Keep up-to-date with an AMA Specialty Journal. Month after month, it will bring you articles on original research, news of medical significance, and comments on current events in the specialty field of your interest.

Start an AMA Specialty Journal coming today.

- ☐ American Journal of Diseases of Children
- ☐ Archives of Dermatology
- ☐ Archives of General Psychiatry
- ☐ Archives of Internal Medicine
- ☐ Archives of Neurology
- ☐ Archives of Ophthalmology
- ☐ Archives of Otolaryngology
- ☐ Archives of Pathology and Laboratory Medicine
- ☐ Archives of Surgery

	U.S. & Poss.	All Other Countries
☐ 24 issues.....	$28.00	$38.00
☐ 12 issues.....	$18.00	$28.00

Payment must accompany all orders. Make checks payable to the American Medical Association.

Name _____

Address _____

City _____ State _____ Zip _____

Return to: Subscription Department, AMA
535 North Dearborn St., Chicago, Ill. 60610

S/J

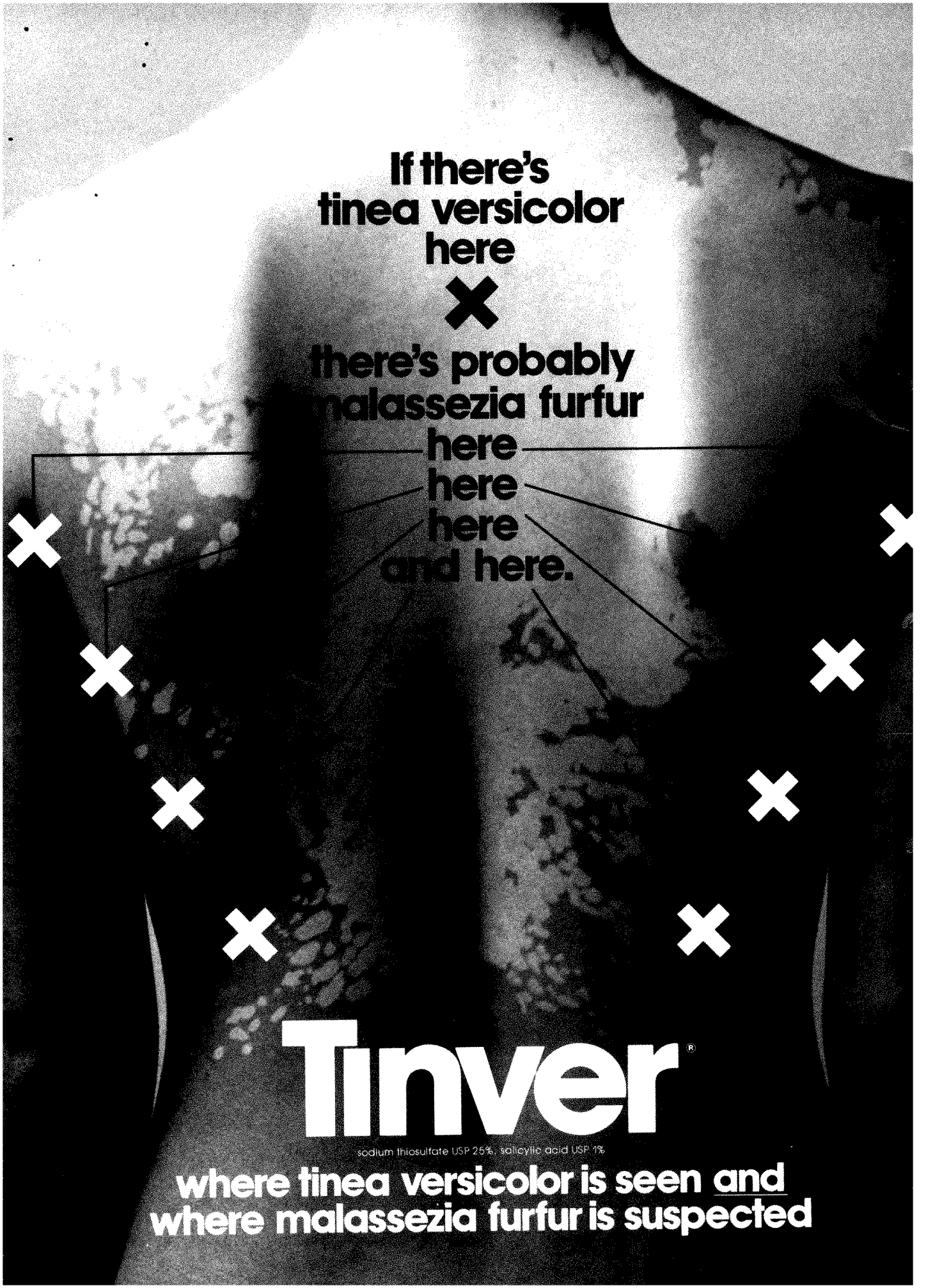
If there's
tinea versicolor
here
there's probably
malassezia furfur
here
here
here
and here.
Tinver®
sodium thiosulfate USP 25%, salicylic acid USP 1%
where tinea versicolor is seen and
where malassezia furfur is suspected

DESCRIPTION:
Sodium thiosulfate 25%, salicylic acid 1%, isopropyl alcohol NF 10%, propylene glycol USP, menthol USP, disodium edetate, colloidal alumina, and purified water.

INDICATIONS:
For topical use in the treatment of tinea versicolor (Malassezia furfur infection).

PRECAUTIONS:
If signs of irritation or sensitivity develop, discontinue use. Do not use on or about the eyes.

ADMINISTRATION:
Thoroughly wash, rinse and dry the affected areas before application of medication. Apply a thin film of lotion to all affected areas and other susceptible areas twice a day. Although diagnostic evidence of the disease may disappear in a few days, it is advisable to continue treatment for a much longer period. Clothing should be boiled to prevent reinfection.

HOW SUPPLIED:
6 fl. oz. plastic dispenser bottles.

CAUTION:
U.S. Federal law prohibits dispensing without prescription.

Barnes-Hind Pharmaceuticals, Inc.
895 Kifer Road
Sunnyvale, California 94086

Tinver®

sodium thiosulfate USP 25%, salicylic acid USP 1%



News and Notes

Dermal Pathology.—The nineteenth annual course in "Dermal Pathology" sponsored by The University of Texas Health Science Center at Houston, Division of Continuing Education, and The University of Texas System Cancer Center, M. D. Anderson Hospital and Tumor Institute at Houston and co-sponsored by the American Society of Dermatopathology, will be held August 21-26, 1977. During this 5½-day course, emphasis will be given to a review of the basic concepts of dermal pathology, including histology and anatomy, electron microscopy, histochemistry, inflammatory dermatoses, granulomatous dermatoses, reticuloendothelial and alterative dermatoses, and nevi and neoplasms. The course is designed primarily for pathologists and dermatologists. The curriculum will be similar to that of previous courses which have been held in Houston, at the Skin and Cancer Hospital of Temple University in Philadelphia, and the University of California at Irvine. This will be the sixth time that the course will have been held in Houston. In addition to the didactic presentations, emphasis will be given to microscopical slide study and self-evaluation examinations. This continuing medical education offering meets the criteria for 38 credit hours in category I of the Physician's Recognition Award of the American Medical Association.

For further information please write to the Office of the Director, The University of Texas Health Science Center at Houston, Division of Continuing Education, PO Box 20367, Houston, TX 77025.

Scholarship Program for Dermatologic Surgery.—The American Society for Dermatologic Surgery announces its Third Annual Scholarship Program to emphasize the scope and importance of surgery in dermatology and to disseminate surgical knowledge and training in our specialty. A number of grants of variable amounts and for variable periods of time will be awarded to defray some or all of the expenses of such training. Applicants must be in an approved dermatology residency training program and finish the surgical elective at least six months before the completion of the residency; or be a full-time faculty member in an approved dermatology program; or be actively involved in a dermatology training program in some other capacity. Surgical training in teaching institutions and private practices are acceptable. Other proposals for obtaining training suggested by the candidates will be considered. Applications, subject to the approval of the training director, should be submitted by Oct 31, 1977. Scholarship awards will be announced at the American Society for Dermatologic Surgery meeting at the American Academy of Dermatology in December.

For further information and applications, please write to Edward A. Krull, MD, Department of Dermatology, Henry Ford Hospital, Detroit, MI 48202.

New Officers.—At the 97th Annual Meeting of the American Dermatological Association in Phoenix, Ariz, March 19-24, 1977, the following officers were elected: president, Rudolf L. Baer, MD; vice president, Hermann Pinkus, MD; treasurer, Richard L. Dobson, MD; board of directors, Harry J. Hurley, MD.

Clinical Trials Methods.—The National Institutes of Health is sponsoring a "National Conference on Clinical Trials Methodology" to be held Oct 3-4, 1977, in the Masur Auditorium, the Clinical Center, National Institutes of Health in Bethesda, Md. This meeting is intended to bring together scientists involved in the design and conduct of clinical trials who come from a variety of disciplines, ie, clinical medicine, statistics, epidemiology, and who work in a variety of disease areas. The conference agenda includes many of the complex and unresolved issues inherent in the conduct of clinical trials—when and how to stop a trial, incentives to attract effective clinical trial investigators, patient recruitment, quality assurance of clinical data, ethical problems, and communication among investigators. No registration or notification of planned attendance is required. Additional information may be obtained by writing to Dr Robert Gordon, Building 1, Room 134, National Institutes of Health, Bethesda, MD 20014.

Books

Psychophysiological Aspects of Skin Disease, Major Problems in Dermatology series, vol 8, ed 1, F. A. Whitlock, MD, 248 pp, with illus, $18, Philadelphia, WB Saunders Co, 1976.

Psychophysiological Aspects of Skin Disease, which is from the series *Major Problems in Dermatology,* is a well-written, readable monograph. The first part of the book is a historical perspective of the subject. Inadequately controlled and biased studies are dissected in an attempt to extract information that may help the reader gain a perspective of the subject. Clinical experience more than scientific investigation was used to formulate the conclusions of these studies.

The first chapters are cumbersome reading because of painstaking reviews of the literature. Brief discussions of psychologic, physiologic, and hypnotic tools used to construct many recent psychophysiologic theories will be useful especially to the naive reader.

The second half of the book deals with specific skin disorders, with an introductory literature review and then a subsequent assessment of present interpretations. The inability of investigators to control their studies and remove their bias is again emphasized. Too much text, however, is devoted to this historical autopsy. Many methods for dealing with patients having urticaria, atopic dermatitis, anogenital pruritus, acne vulgaris, rosacea, hair problems, and self-inflicted dermatoses will be useful for the practicing dermatologist. In addition, a perspective of the possible benefits and problems of psychotherapeutic intervention is given.

The outstanding contribution of this book is to help dispel many unwarranted labels certain dermatological conditions have worn. Skin disease frequently has psychological components, but invalid prejudices make the clinician and researcher much less helpful.

STEPHEN Z. SMITH, MD
Louisville

Microvascular Injury, by Terence J. Ryan, 418 pp, 170 illus, $29.50, Philadelphia, WB Saunders Co, 1976.

Microvascular Injury cannot be recommended as light reading, reposing comfortably between *The Doonesbury Chronicles* and *Jaws.* Nor may its virtues be honestly extolled to the "bottom-line" clinician, whose interest in a disease process begins and ends with the prescription pad. It should, however, receive enthusiastic endorsement from the curious dermatologist who is anxious to clarify the often turbid exposition of microvascular pathology. And, of course, it certainly belongs on the shelf (the section with the thinnest veneer of dust) of any investigator who is attempting serious work in the field.

This book, like all books, is limited by the range of the author's personal interests; fortunately, the range of Terence Ryan's interest in vascular events is broad. The author and his contributors (M.W. Kanan and G.W. Cherry) carefully review the history, pathophysiology, diagnosis, and treatment of vasculitis. Yet, in Ryan's words, "This book is about injury to the small blood vessels of the skin," and not about vasculitis per se. Indeed, the authors have undertaken a courageously broad analysis of microvascular injury following a wide variety of unpleasant stimuli and have attempted to relate the process of vascular injury to a complex interplay of physiology and inflammation. If they have not always succeeded, we must recall the enormity of their self-appointed task.

Throughout this book, the authors have laudably (and successfully) attempted to vitiate the tyranny of jargon, to excise awkward morphological descriptions, and to make cutaneous microvascular pathology understandable to both the dermatologist and the nondermatologist. The emphasis here is consistently on the understanding of the pathophysiology of complicated microvascular aberrations and their relationship to clinical (largely dermatological) disease. Descriptive terminology has thus been stripped and cleaned in what seems to me a thoroughly reasonable fashion.

Every reviewer is entitled to sporadic outbursts of favoritism. My favorite chapters in this book were "Coagulation and Fibrinolysis" and "The Localization of Granulomatous Diseases and Vasculitis," and, since they conform only vaguely to my special vascular enthusiasms, I still lay claim to relative objectivity. If I were to criticize any chapter, it would be the one entitled "The Management of Vasculitis," and the deficiencies there seem to be those of the art, not of the authors. This is a useful book; I doubt that it will come out in "paperback," so order it now.

JOHN E. WOLF, JR, MD
Houston

KENALOG® SPRAY
Triamcinolone Acetonide Aerosol N.F.

DESCRIPTION: Kenalog Spray (Triamcinolone Acetonide Aerosol N.F.) provides 3.3 mg triamcinolone acetonide per 50 grams in an isopropyl palmitate vehicle with alcohol (4.7%) and propellants.

INDICATIONS: Kenalog Spray (Triamcinolone Acetonide Aerosol N.F.) is indicated for relief of the inflammatory manifestations of corticosteroid-responsive dermatoses.

CONTRAINDICATIONS: Topical steroids are contraindicated in viral diseases of the skin, such as vaccinia and varicella, and in patients with a history of hypersensitivity to any product component. This preparation is not for ophthalmic use. Topical steroids shou not be used when circulation is markedly impaired.

WARNINGS: Usage in Pregnancy– Although topical steroids have not been reported to have an adverse effect on the fetus, the safety of their use during pregnancy has not been absolutely established; therefore, they should not be used extensively on pregnant patients, in large amounts, or for prolonged periods of time.

PRECAUTIONS: Administer suitable antifungal or antimicrobial therapy if infection exists; if there is not a prompt, favorable response, discontinue the corticosteroid unti the infection has been adequately controlled Discontinue the drug and institute appropriate therapy if irritation develops. If extensive areas are treated or if the occlusive techniqu is used, the possibility exists of increased systemic absorption of the corticosteroid anc suitable precautions should be taken. When used about the face, the eyes should be covered and inhalation of the spray avoided.

ADVERSE REACTIONS: The following local adverse reactions have been reported with topical corticosteroids either with or without occlusive dressings: burning sensations, itching, irritation, dryness, folliculitis, secondary infection, skin atrophy, striae, miliaria, hypertrichosis, acneform eruptions, maceration of the skin and hypopigmentation; contact sensitivity to a particular dressing material or adhesive may occur occasionally. Some patients (particularly those with very dry skin or dry lesions) may find the cooling effect of the spray objectionable or complain of a transient burning or stinging sensation.

For full prescribing information, consult package insert.

HOW SUPPLIED: Kenalog Spray (Triamcinolone Acetonide Aerosol N.F.) is available in spray dispenser cans of 50 and 150 g. with adapter.

SQUIBB®

©1977 E.R.Squibb & Sons, Inc. 327-503

ANOTHER CASE FOR KENALOG®
TRIAMCINOLONE ACETONIDE

"INTRACTABLE" SCALP PSORIASIS

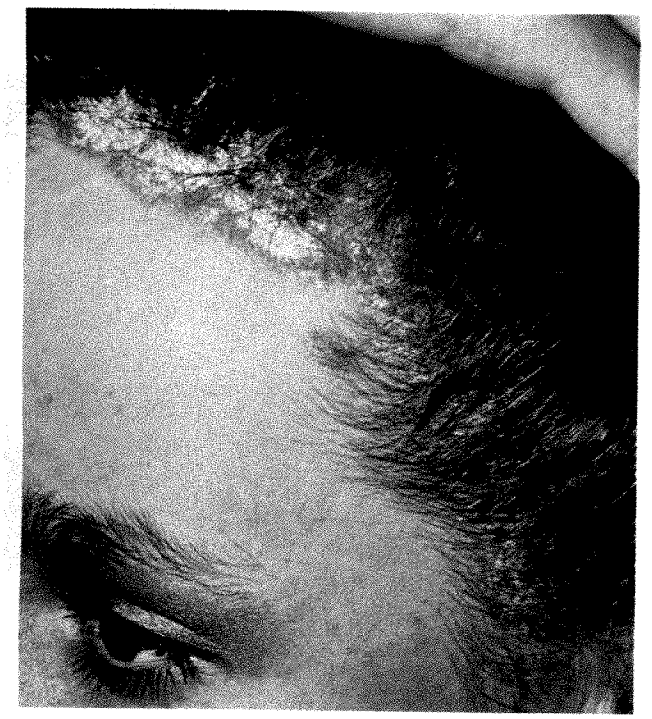

MARCH 4, 1977

A 15-year-old patient complaining of severe, intractable psoriasis of the scalp. Previous therapy with tar shampoo, keratolytic agents and fluorinated topical steroids had been unsuccessful. Because prior topical agents had been difficult to apply, Kenalog® Spray b.i.d. was prescribed.

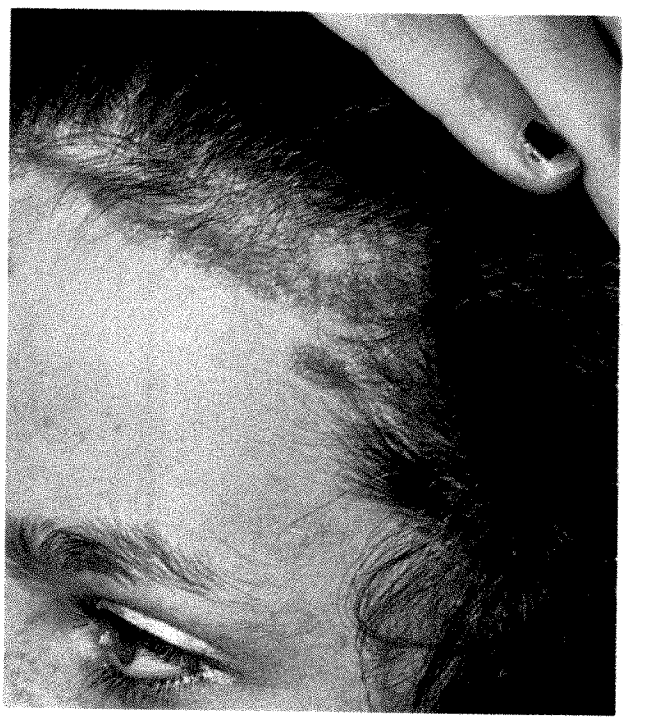

AFTER 1 WEEK

Patient reported that pruritus had been relieved promptly. Marked improvement observed at this time: absence of scales, decrease in erythema and central clearing of plaques. Patient continuing on Kenalog® Spray b.i.d.
Case history on file at Squibb Institute for Medical Research.

A CASE FOR KENALOG® SPRAY

TRIAMCINOLONE ACETONIDE AEROSOL N.F.

See adjacent column for brief summary.

Acne illustrated by artist.

VECTRIN Capsules, 100 mg
(minocycline HCl capsules, USP)
Brief Summary of Prescribing Information

Indicated in severe acne as adjunctive therapy. Consult package insert for complete prescribing information.

Contraindication: Hypersensitivity to any tetracycline.

Warnings: When need for intensive treatment outweighs potential dangers, perform renal and liver function tests before and during therapy; also follow serum concentrations. In renal impairment, usual doses may lead to excessive accumulation and liver toxicity. Under such conditions, use lower total doses, and, in prolonged therapy, determine serum levels. The use of tetracyclines during tooth development (last half of pregnancy, infancy, and childhood to the age of 8 years) may cause permanent discoloration of the teeth (yellow-gray-brown). This is more common during long-term use but has been observed following repeated short-term courses. Enamel hypoplasia has also been reported. Tetracyclines, therefore, should not be used in this age group unless other drugs are not likely to be effective or are contraindicated. Photosensitivity manifested by an exaggerated sunburn reaction has been observed in some individuals taking tetracyclines. Advise patients apt to be exposed to direct sunlight or ultraviolet light that such reaction can occur, and discontinue treatment at first evidence of skin erythema. Studies with minocycline HCl indicated that photosensitivity did not occur. However, reports have been received. In patients with significantly impaired renal function, the antianabolic action of tetracycline may cause an increase in BUN leading to azotemia, hyperphosphatemia, and acidosis. **CNS side effects:** (light-headedness, dizziness, vertigo) have been reported, may disappear during therapy, and always disappear rapidly when drug is discontinued. Caution patients who experience these symptoms about driving vehicles or using hazardous machinery while taking this drug. **Pregnancy:** In animal studies, tetracyclines cross the placenta, are found in fetal tissues, and can have toxic effects on the developing fetus (often related to retardation of skeletal development). Embryotoxicity has been noted in animals treated early in pregnancy. The safety of minocycline HCl for use during pregnancy has not been established. **Newborns, infants, and children:** All tetracyclines form a stable calcium complex in any bone-forming tissue. Prematures, given oral doses of 25 mg/kg every six hours, demonstrated a decrease in fibula growth rate, reversible when drug was discontinued. Tetracyclines

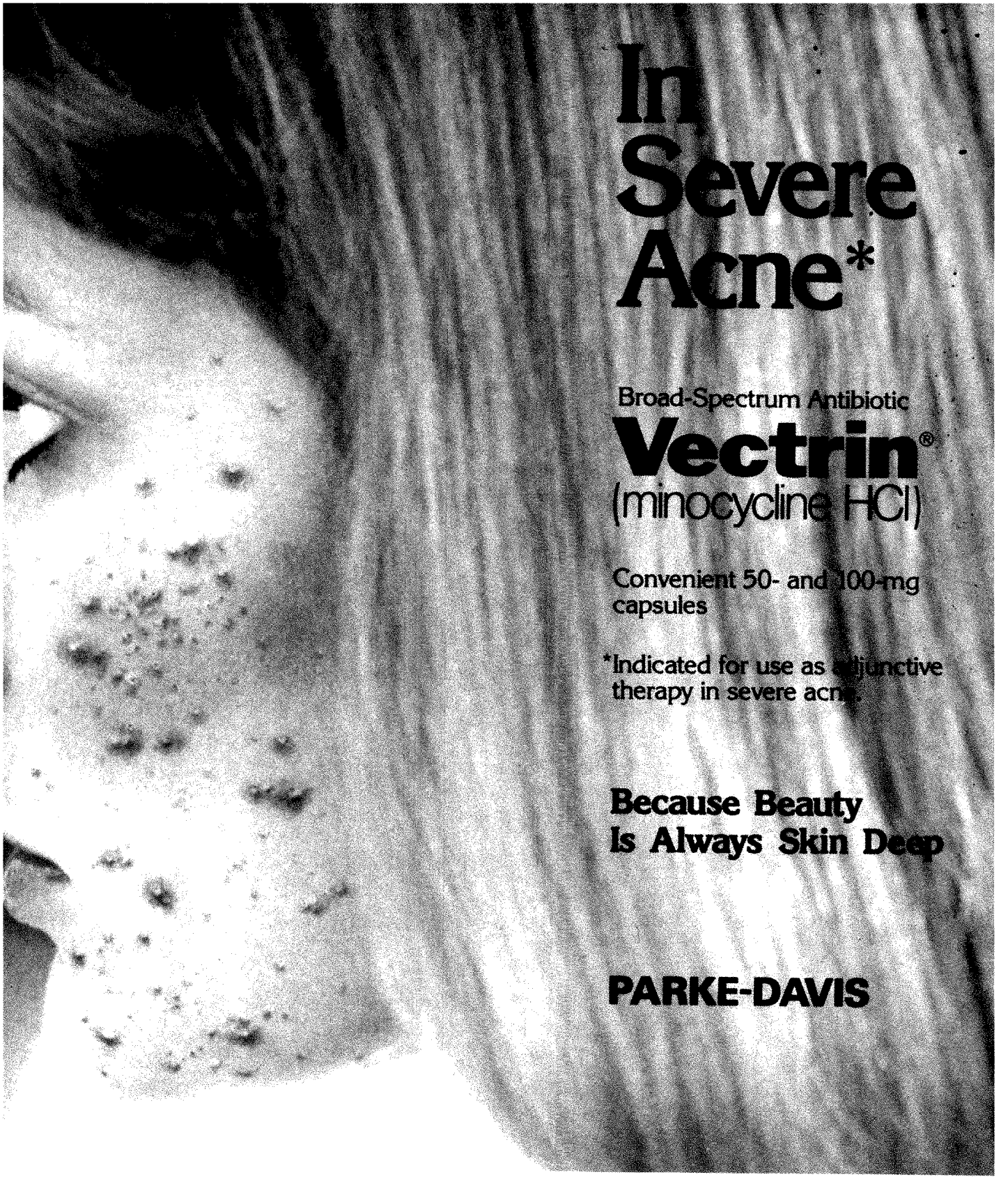

In Severe Acne*

Broad-Spectrum Antibiotic

Vectrin®

(minocycline HCl)

Convenient 50- and 100-mg capsules

*Indicated for use as adjunctive therapy in severe acne.

Because Beauty Is Always Skin Deep

PARKE-DAVIS

are present in the milk of lactating women who are taking a drug in this class.

Precautions: Use may result in overgrowth of non-susceptible organisms, including fungi. If superinfection occurs, antibiotics should be discontinued and appropriate therapy instituted. In venereal diseases when coexistent syphilis is suspected, darkfield examination should be done before treatment is started and blood serology repeated monthly for at least four months. Patients on anticoagulant therapy may require downward adjustment of such dosage. Test for organ system dysfunction (eg, renal, hepatic, and hemopoietic) in long-term use. Treat all group A beta-hemolytic streptococcal infections for at least 10 days. Avoid giving tetracycline in conjunction with penicillin.

Adverse Reactions: GI: Anorexia, nausea, vomiting, diarrhea, glossitis, dysphagia, enterocolitis, inflammatory lesions (with monilial overgrowth) in anogenital region. **Skin:** Maculopapular and erythematous rashes. Exfoliative dermatitis (uncommon). Photosensitivity is discussed above. (See Warnings.) **Renal toxicity:** Rise in BUN, dose-related. (See Warnings.) **Hypersensitivity reactions:** Urticaria, angioneurotic edema, anaphylaxis, anaphylactoid purpura, pericarditis, exacerbation of systemic lupus erythematosus. In young infants, bulging fontanels have been reported following full therapeutic dosage, disappearing rapidly when drug was discontinued. **Blood:** Hemolytic anemia, thrombocytopenia, neutropenia, eosinophilia. **CNS:** (See Warnings.) When given over prolonged periods, tetracyclines may produce brown-black microscopic discoloration of thyroid glands; no abnormalities of thyroid function studies are known to occur.

NOTE: Concomitant therapy: Antacids containing aluminum, calcium, or magnesium impair absorption; do not give to patients taking oral tetracycline. Studies to date indicate that absorption of VECTRIN (minocycline hydrochloride) is not notably influenced by foods and dairy products.

Full prescribing information available upon request.

PARKE, DAVIS & COMPANY
Detroit, Michigan 48232

Gets to deep fungal infections

Actual photograph of tinea unguium infection (onychomycosis).
Note typical worm-eaten appearance of fingernail destroyed by fungus.

when topicals can't.

Potent, systemic fungistat

GRISACTIN provides the antifungal activity needed to control tinea infections, including onychomycosis, that invade the dermis and deeper regions. Systemic action penetrates where topical action often fails.

GRISACTIN is effective against a wide range of fungi: *Trichophyton rubrum, T. mentagrophytes, T. tonsurans, T. interdigitalis, T. verrucosum, T. megnini, T. gallinae, T. crateriform, T. sulphureum, T. schoenleini, Microsporum canis, M. audouini, M. gypseum,* and *Epidermophyton floccosum.*

Peak serum levels are usually produced in about four hours with a single 500 mg. tablet. To meet the requirements of different patients—depending on body weight, age, severity, and location of infection—dosage is easily individualized with 125 mg. and 250 mg. capsules, and 500 mg. tablets.

Grisactin® 500

BRAND OF

griseofulvin (microsize) TABLETS

BRIEF SUMMARY
(For full prescribing information, see package circular.)

Grisactin®
brand of
griseofulvin (microsize)

Indications: Griseofulvin is indicated for the treatment of ringworm infections of the skin, hair, and nails, namely: *Tinea corporis, Tinea pedis, Tinea cruris, Tinea barbae, Tinea capitis, Tinea unguium* (onychomycosis) when caused by one or more of the following genera of fungi: *Trichophyton rubrum, T. tonsurans, T. mentagrophytes, T. interdigitalis, T. verrucosum, T. megnini, T. gallinae, T. crateriform, T. sulphureum, T. schoenleini, Microsporum audouini, M. canis, M. gypseum, Epidermophyton floccosum.*
NOTE: Prior to therapy, the type of fungi responsible for the infection should be identified.
The use of this drug is not justified in minor or superficial infections which will respond to topical agents alone.
Griseofulvin is *not* effective in the following: Bacterial infections, candidiasis (moniliasis), histoplasmosis, actinomycosis, sporotrichosis, chromoblastomycosis, coccidioidomycosis, North American blastomycosis, cryptococcosis (torulosis), *Tinea versicolor,* nocardiosis.

Contraindications: This drug is contraindicated in patients with porphyria, hepatocellular failure, and in individuals with a history of hypersensitivity to griseofulvin.

Warnings: *Prophylactic Usage*—Safety and efficacy of griseofulvin for prophylaxis of fungal infections has not been established.
Animal Toxicology—Chronic feeding of griseofulvin, at levels ranging from 0.5-2.5% of the diet, resulted in the development of liver tumors in several strains of mice, particularly in males. Smaller particle sizes result in an enhanced effect. Lower oral dosage levels have not been tested. Subcutaneous administration of relatively small doses of griseofulvin, once a week, during the first three weeks of life has also been reported to induce hepatomata in mice. Although studies in other animal species have not yielded evidence of tumorigenicity, these studies were not of adequate design to form a basis for conclusions in this regard.
In subacute toxicity studies, orally administered griseofulvin produced hepatocellular necrosis in mice, but this has not been seen in other species. Disturbances in porphyrin metabolism have been reported in griseofulvin-treated laboratory animals. Griseofulvin has been reported to have a colchicine-like effect on mitosis and cocarcinogenicity with methylcholanthrene in cutaneous tumor induction in laboratory animals.
Usage in Pregnancy—The safety of this drug during pregnancy has not been established.
Animal Reproduction Studies—It has been reported in the literature that griseofulvin was found to be embryotoxic and teratogenic on oral administration to pregnant rats. Pups with abnormalities have been reported in the litters of a few bitches treated with griseofulvin. Additional animal reproduction studies are in progress.
Suppression of spermatogenesis has been reported to occur in rats, but investigation in man failed to confirm this.

Precautions: Patients on prolonged therapy with any potent medication should be under close observation. Periodic monitoring of organ system function, including renal, hepatic, and hematopoietic, should be done.
Since griseofulvin is derived from a species of Penicillium, the possibility of cross-sensitivity with penicillin exists; however, known penicillin-sensitive patients have been treated without difficulty.
Since a photosensitivity reaction is occasionally associated with griseofulvin therapy, patients should be warned to avoid exposure to intense natural or artificial sunlight. Should a photosensitivity reaction occur, lupus erythematosus may be aggravated.
Griseofulvin decreases the activity of warfarin-type anticoagulants so that patients receiving these drugs concomitantly may require dosage adjustment of the anticoagulant during and after griseofulvin therapy.
Barbiturates usually depress griseofulvin activity and concomitant administration may require a dosage adjustment of the antifungal agent.

Adverse Reactions: When adverse reactions occur, they are most commonly of the hypersensitivity type such as skin rashes, urticaria, and rarely, angioneurotic edema, and may necessitate withdrawal of therapy and appropriate countermeasures. Paresthesias of the hands and feet have been reported rarely after extended therapy. Other side effects reported occasionally are oral thrush, nausea, vomiting, epigastric distress, diarrhea, headache, fatigue, dizziness, insomnia, mental confusion, and impairment of performance of routine activities.
Proteinuria and leukopenia have been reported rarely. Administration of the drug should be discontinued if granulocytopenia occurs.
When rare, serious reactions occur with griseofulvin, they are usually associated with high dosages, long periods of therapy, or both.

Dosage and Administration: Accurate diagnosis of the infecting organism is essential. Medication must be continued until the infecting organism is completely eradicated as indicated by appropriate clinical or laboratory examination. General measures in regard to hygiene should be observed to control sources of infection or reinfection. Concomitant use of appropriate topical agents is usually required, particularly in treatment of *tinea pedis.*
Dosage should be individualized, depending on age and severity of infection. *Adults*—0.5 Gm. daily (125 mg. q.i.d., 250 mg. b.i.d., or 500 mg./day). *Children*—10 mg./kg. daily is usually adequate (from 30 to 50 lb., 125 mg. to 250 mg. daily; over 50 lb., 250 mg. to 500 mg. daily, in divided doses).

How Supplied: GRISACTIN [griseofulvin (microsize)]—No. 442—GRISACTIN 125, each capsule contains 125 mg., in bottles of 100 and 500. No. 443—GRISACTIN 250, each capsule contains 250 mg., in bottles of 100 and 500. No. 444—GRISACTIN 500, each tablet (scored) contains 500 mg., in bottles of 60.

Ayerst

Ayerst Laboratories
New York, N.Y. 10017

7719

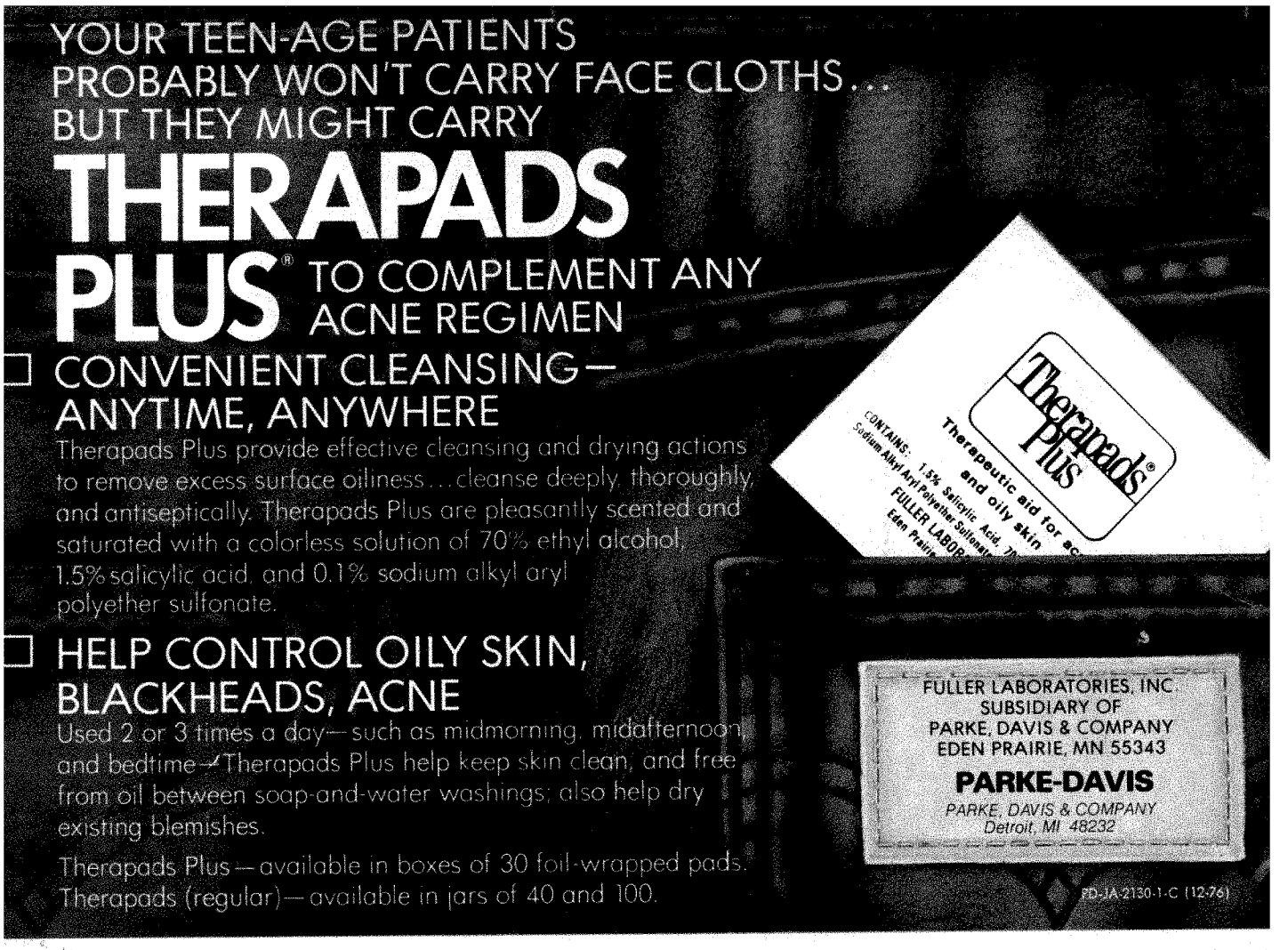

INDEX TO ADVERTISERS

A

Abbott Laboratories 872-873
Ayerst Laboratories 998-999

B

Barnes-Hind Pharmaceuticals 992-993

C

Churchill Livingstone, Publishers 887
Ciba Pharmaceuticals 972-973
Coppertone 968

D

Dermik Laboratories ..... 875, 3rd Cover
Dista Products Company 869
Doak Pharmacal Company 894
Dorsey Laboratories 981
Dow Pharmaceuticals 876

G

General Medical Company 897

H

Herbert, G.S., Laboratories, Division of Allergan Pharmaceuticals 899
Hoechst-Roussel Pharmaceuticals 978-980

L

Lederle Laboratories, Division of American Cyanamid Company 959-960
Lenox Hill Hospital 896

N

Neutrogena Corporation 896-897

O

Owen Laboratories, Inc. 871

P

Parke-Davis & Company 890-891, 996-997, 1000
Person & Covey, Inc. 958
Pharmacia Diagnostics 895
Procter & Gamble Company 967
Purdue Frederick Company 971

R

Reed & Carnrick 880-881
Roche Laboratories, Division of Hoffmann-LaRoche, Inc. 892-893
Roerig, J.B., Company Division of Pfizer, Inc. 878-879

S

Schering Corporation 888-889, 965, 974-976, 990-991
Squibb, E.R., & Sons, Inc. 900-901, 994-995
Stiefel Laboratories, Inc. 885-886, 966
Syntex Laboratories, Inc. 882-884, 988-989

T

Thomas, Charles C., Publisher 898

W

Westwood Pharmaceuticals, Inc. ..... 2nd Cover, 877, 902, 4th Cover

While every precaution is taken to insure accuracy, we cannot guarantee against the possibility of an

When the fluorinated steroid is gone–

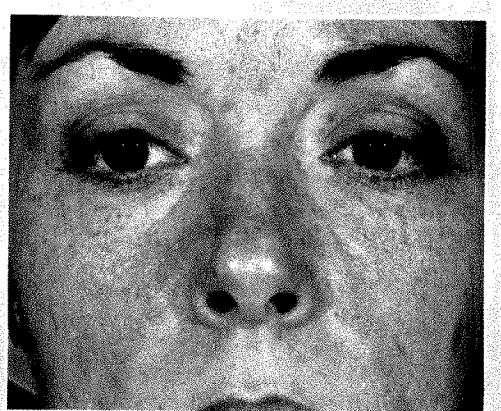

Problems such as striae, or dermal atrophy leading to telangiectasia and fragility, especially on the face, in the groin, anal or axillary areas may be the result.

Consider Starting with Hytone® 2.5% (hydrocortisone)

For rapid control of the majority of inflammatory dermatitides seen in office practice.

Followed by–Hytone® 1% or 0.5%

for maintenance therapy and ultimate control– especially on the face or in children.

Hytone®–the conservative but effective approach

HYTONE® CREAM (hydrocortisone)

DESCRIPTION: Hydrocortisone 2½%, 1% and ½% in a water-washable cream containing purified water, propylene glycol, isopropyl myristate, cholesterol and related sterols, cetyl alcohol, sorbic acid, glyceryl monostearate, polysorbate 60, sorbitan monostearate and polyoxyl 40 stearate. ACTIONS: Topical corticosteroids are effective primarily because of their anti-inflammatory, antipruritic, and vasoconstrictive actions. INDICATIONS: For relief of the inflammatory manifestations of corticosteroid-responsive dermatoses. CONTRAINDICATIONS: In viral diseases of the skin such as varicella and vaccinia and in patients with a history of hypersensitivity to any component. Not for ophthalmic use. Topical steroids should not be used when circulation is markedly impaired. WARNING: Should not be used extensively, in large amounts, or for prolonged periods in pregnancy. PRECAUTIONS: If irritation develops, the product should be discontinued and appropriate therapy instituted. In the presence of an infection, the use of appropriate antifungal or antibacterial agents should be instituted. If a favorable response does not occur promptly, the corticosteroid should be discontinued until the infection has been adequately controlled. If extensive areas are treated or if the occlusive technique is used, the possibility exists of increased systemic absorption of the corticosteroid and suitable precautions should be taken. ADVERSE REACTIONS: The following local adverse reactions have been reported with topical corticosteroids, either with or without occlusive dressings: burning sensations, itching, irritation, dryness, folliculitis, secondary infection, skin atrophy, striae, hypertrichosis, acneform eruption and hypopigmentation. DOSAGE AND ADMINISTRATION: Apply to affected areas 3 or 4 times daily. HOW SUPPLIED: Cream 2½%—Tubes ½ oz. and 1 oz. Cream 1% and ½%—Tube 1 oz. and Jar 4 oz. CAUTION: Federal law prohibits dispensing without prescription.

Dermik

Dermik Laboratories, Inc.
Fort Washington, Pa. 19034

PreSun® for proven sunscreen protection

(5% PABA LOTION/GEL)



helps protect against premature aging of skin and skin cancer caused by the sun

©1977, W.P. Inc.

WESTWOOD
PHARMACEUTICALS INC.
Buffalo, New York 14213

Published by the American Medical Association

August 1977

Arch.
8.11.77

archives of Dermatology

Bullous Pemphigoid . . . 1043

Photochemotherapy . . . 1047

Keratinizing Dermatoses . . . 1052

Allergic Dermatitis to Fluorouracil . . . 1058

Physician Utilization . . . 1062

Mycobacterium marinum Infections . . . 1067

Herpes Gestationis . . . 1069

Volume 113 Number 8

Complete Contents . . . 1002

Leukocytoclastic Angiitis . . . 1073

Cutaneous Infarction . . . 1075

Eruptive Nevocytic Nevi . . . 1080

Eosinophilic Fasciitis . . . 1092

Xanthoma Disseminatum . . . 1094

CONTEMPORARY AND EFFECTIVE

For seborrhea oleosa and the oily hair and scalp associated with acne

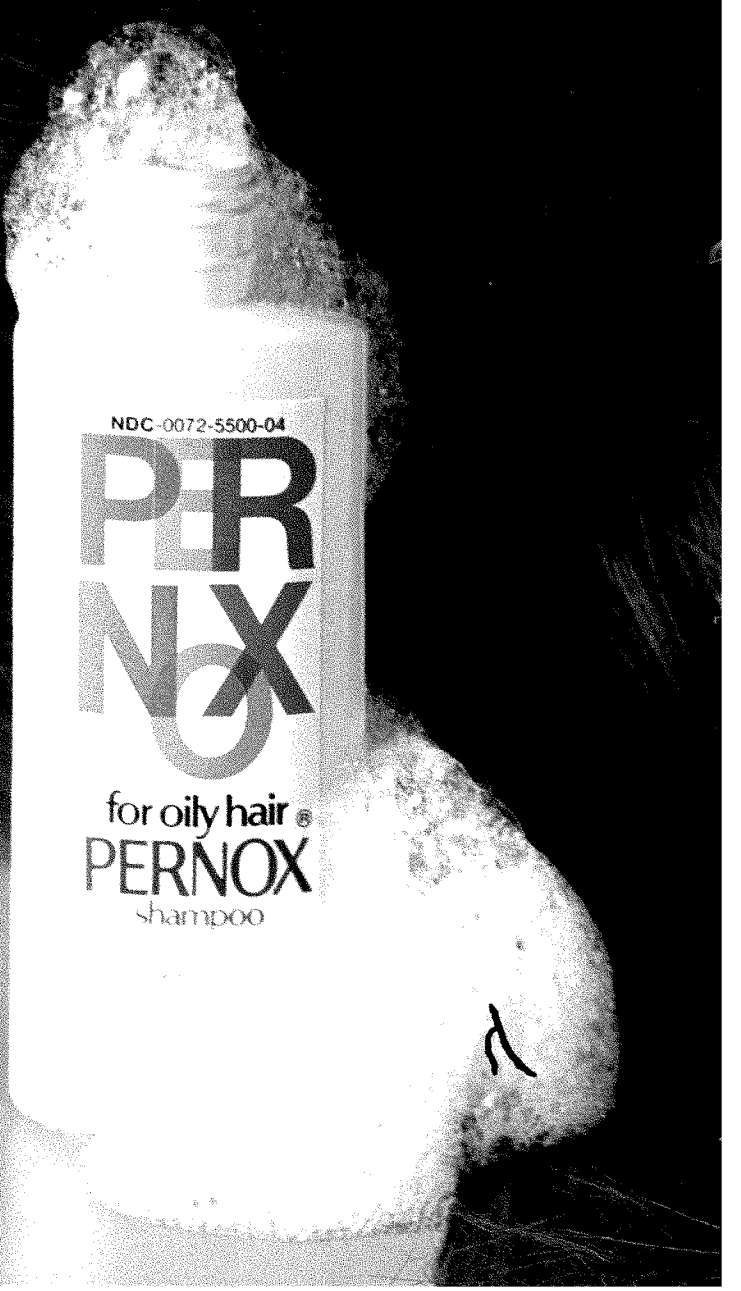

- Thorough cleansing of oily hair and scalp.
- Leaves patients' hair soft, manageable, fresh smelling.
- Elegant herbal scented shampoo.
- A special formulation designed to cleanse and condition oily hair.
- Its pH of 5.5 is gentle to the scalp.
- Can be used as often as necessary, preferably every day, to keep hair looking fresh and healthy.
- CONTAINS NO FORMALDEHYDE.

Supplied: 4 oz. and 8 oz. plastic bottles.

Pernox Shampoo® is adjunctive therapy especially formulated for oily scalps associated with acne.

WESTWOOD
PHARMACEUTICALS INC.
Buffalo, New York 14213

© 1977 W.P. INC.

ECLIPSE®

(3% glyceryl PABA and 3% octyl dimethyl PABA)

For your patients

who can't-or won't-stay out of the sun.

For some, it's occupation. For others, the social desirability of a tan. Whatever the reason, many of your patients may be spending more time in the sun than you'd like.

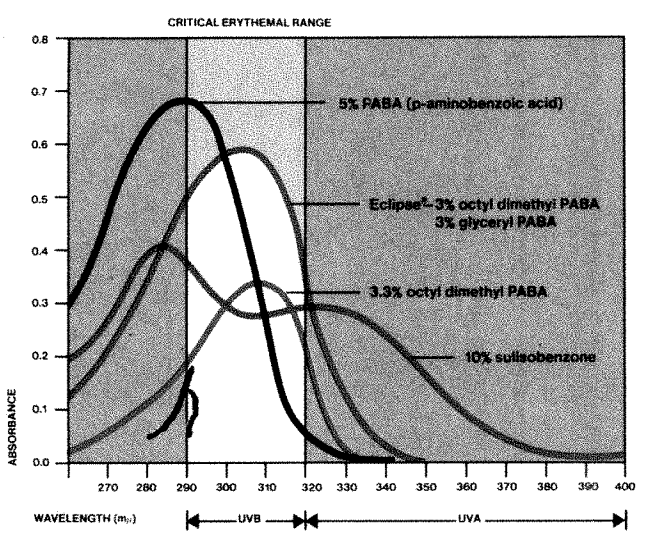

Unique Eclipse formulation combines two PABA derivatives for maximum UVB absorption.

They need Eclipse—a highly effective sunscreen that works immediately upon application, resists wash-off, and contains our exclusive Aquacare® base to help relieve sun and wind-dried skin.

Can other sunscreens do all that? Take a minute to read the labels: we're confident you'll recommend Eclipse.

- Absorbs more than 99% of erythemogenic solar UVB.
- Spreads smoothly and predictably for even protection.
- Permits slow tanning.
- Resists wash-off; protects after swimming or sweating.
- Formulated in Aquacare® to relieve sun and wind-dried skin.



Herbert Laboratories
Dermatology Division of
Allergan Pharmaceuticals
Irvine, CA 92713 U.S.A.

Archives of DERMATOLOGY
Copyright © 1977 by the AMERICAN MEDICAL ASSOCIATION

VOL 113, NO. 8 August 1977

ORIGINAL CONTRIBUTIONS

Bullous Pemphigoid
A. Razzaque Ahmed, MD; John C. Maize, MD; Thomas T. Provost, MD, Buffalo, NY 1043

Photochemotherapy for Mycosis Fungoides
Henry H. Roenigk, Jr, MD, Cleveland 1047

Keratinizing Dermatoses
Sigfrid A. Muller, MD, Rochester, Minn; Richard W. Belcher, MD, Cleveland; Nancy B. Esterly, MD, Chicago; Jon C. Lochner, MD; James S. Miller, MD; Henry Roenigk, Jr, MD, Cleveland; Lester Weissman, MD, Nutley, NJ 1052

Defective Monocyte Chemotaxis in Mycosis Fungoides
Larry E. Seitz, MD; Loren E. Golitz, MD; William L. Weston, MD; John E. Aeling, MD; Roberta D. Dustin, Denver 1055

Allergic Contact Dermatitis to Topical Fluorouracil
Lt Col Detlef K. Goette, MC, USA, Lt Col Richard B. Odom, MC, USA, San Francisco 1058

Utilization of Physician Services for Dermatologic Complaints
Robert S. Stern, MD, Boston; Marie-Louise Johnson, MD, PhD, New York; James DeLozier, MD, Rockville, Md
Editorial comment by Philip C. Anderson, MD, Columbia, Mo 1062

***Mycobacterium marinum* Infections Treated With Tetracycline**
Allan K. Izumi, MD, Honolulu; C. William Hanke, MD, Cleveland; Michiko Higaki, MT (ASCP), Honolulu 1067

CASE REPORTS

Immunopathologic Study of Herpes Gestationis in Mother and Infant
Allan Katz, MD; Joe O. Minta, PhD; John W. P. Toole, MD; Walter Medwidsky, MD, FRCP(C), Toronto 1069

Leukocytoclastic Angiitis in Subacute Bacterial Endocarditis
Sheldon Rubenfeld, MD, Kyung-Whan Min, MD, Houston 1073

Cutaneous Infarction
Barnett S. Kramer, MD; Alfred D. Hernandez, MD; Robert L. Reddick, MD; Arthur S. Levine, MD, Bethesda, Md 1075

Systemic Argyria Secondary to Topical Silver Nitrate
Jay P. Marshall II, MD, Richard P. Schneider, MD, Nashville, Tenn 1077

Eruptive Nevocytic Nevi After Severe Bullous Disease
Alfred W. Kopf, MD, New York; Charles Grupper, MD, Paris; Rudolf L. Baer, MD, New York; John C. Mitchell, MD, Vancouver, British Columbia 1080

Eczema Herpeticum Caused by Herpesvirus Type 2
Paul G. Hazen, MD, R. Bennett Eppes, MD, Cleveland 1085

Graft-Versus-Host Reaction
Antoinette F. Hood, MD; Nicholas A. Soter, MD; Joel Rappeport, MD; Irma Gigli, MD, Boston 1087

Eosinophilic Fasciitis
Ronald E. Krauser, MD, Ralph J. Tuthill, MD, Portsmouth, Va 1092

Xanthoma Disseminatum
Maurice A. Mishkel, MD; W. Peter Cockshott, MD; Darius J. Nazir, PhD; Donald Rosenthal, MD; William P. Spaulding, MD; Alun Wynn-Williams, MD, Hamilton, Ontario 1094

(Continued on page 1004)

EDITORIAL BOARD

Chief Editor
John H. Epstein, MD
450 Sutter Street
San Francisco 94108

Assistant Chief Editor
Kimie Fukuyama, MD
San Francisco

Assistant Chief Editor
Denny L. Tuffanelli, MD
San Francisco

Donald C. Abele, MD
Augusta, Ga.

Harry L. Arnold, Jr, MD
Honolulu

Walter C. Lobitz, Jr, MD
Portland, Ore

Frederick D. Malkinson, MD
Chicago

Sigfrid A. Muller, MD
Rochester, Minn

W. Mitchell Sams, Jr, MD
Chapel Hill, NC

John S. Strauss, MD
Boston

Morris Waisman, MD
Tampa, Fla

Gerald D. Weinstein, MD
Miami

The cosmetically acceptable infection fighter

NEOSPORIN®G Cream

(polymyxin B-neomycin-gramicidin)

Each gram contains Aerosporin® brand Polymyxin B Sulfate 10,000 units; neomycin sulfate 5 mg (equivalent to 3.5 mg neomycin base); gramicidin 0.25 mg. Inactive ingredients: liquid petrolatum, white petrolatum, purified water, propylene glycol, polyoxyethylene polyoxypropylene compound, emulsifying wax, and 0.25% methylparaben as preservative.

NEOSPORIN®G Cream
(polymyxin B-neomycin-gramicidin)

When topical infection invades hairy areas, facial skin or intertriginous areas, Neosporin®G Cream provides broad antibacterial coverage. It contains three antibiotics that combat virtually all pathogenic bacteria found topically.*

These antibiotics are seldom used systemically, so the patient is spared the possibility of sensitization to those antibiotics which might later be required systemically.

Smooth vanishing cream base leaves no greasy residue on skin, no stains on fabric.

Wellcome / **Burroughs Wellcome Co.**
Research Triangle Park
North Carolina 27709

*INDICATIONS: Based on a review of this drug by the National Academy of Sciences—National Research Council and/or other information, FDA has classified the indications as follows: "Possibly" effective: For topical administration for the treatment of the listed localized infections or for suppressive therapy in such conditions: • primary pyodermas (impetigo, ecthyma, sycosis vulgaris, paronychia) • secondary infected dermatoses (eczema, herpes, and seborrheic dermatitis) • traumatic lesions (inflamed or suppurating as a result of bacterial infection).

Final classification of the less-than-effective indications requires further investigation.

CONTRAINDICATIONS: Not for use in the eyes or in the external ear canal if the eardrum is perforated. This product is contraindicated in those individuals who have shown hypersensitivity to any of its components.

WARNING: Because of the potential hazard of nephrotoxicity and ototoxicity due to neomycin, care should be exercised when using this product in treating extensive burns, trophic ulceration and other extensive conditions where absorption of neomycin is possible. In burns where more than 20 percent of the body surface is affected, especially if the patient has impaired renal function or is receiving other aminoglycoside antibiotics concurrently, not more than one application a day is recommended.

When using neomycin-containing products to control secondary infection in the chronic dermatoses, such as chronic otitis externa or stasis dermatitis, it should be borne in mind that the skin in these conditions is more liable than is normal skin to become sensitized to many substances, including neomycin. The manifestation of sensitization to neomycin is usually a low grade reddening with swelling, dry scaling and itching; it may be manifest simply as failure to heal. During long-term use of neomycin-containing products, periodic examination for such signs is advisable and the patient should be told to discontinue the product if they are observed. These symptoms regress quickly on withdrawing the medication. Neomycin-containing applications should be avoided for that patient thereafter.

PRECAUTIONS: As with other antibacterial preparations, prolonged use may result in overgrowth of nonsusceptible organisms, including fungi. Appropriate measures should be taken if this occurs.

ADVERSE REACTIONS: Neomycin is a not uncommon cutaneous sensitizer. Articles in the current literature indicate an increase in the prevalence of persons allergic to neomycin. Ototoxicity and nephrotoxicity have been reported (see Warning section).

HOW SUPPLIED: Tube of 15 g.

Complete literature available on request from Professional Services Dept. PML.

CONTENTS—Continued

Congenital Cutaneous Candidiasis
Nathan Rudolph, MB, BCh; Arshad A. Tariq, MB, BS; Mario R. Reale, MD; Philip K. Goldberg; Philip J. Kozinn, MD, Brooklyn, NY 1101

Sporotrichoid Leishmaniasis
Stanley Spier, MD, FRCP(C); Maria Medenica, MD; Shirley McMillan, MA; Christopher Virtue, MD, Chicago 1104

Epithelioid Sarcoma
Norma Saxe, MB, Jan B. C. Botha, MD, Cape Town, South Africa 1106

SPECIAL ARTICLE

Choosing Dermatologic Instruction for Students in Family Practice
Richard M. Caplan, MD, Roger I. Ceilley, MD, Iowa City 1113

IN MEMORIAM

William B. Reed, MD, 1924-1976
William L. Epstein, MD; Denny L. Tuffanelli, MD; John H. Epstein, MD, San Francisco 1119

REGULAR DEPARTMENTS

Short Reports 1121

HLA in Bullous Pemphigoid A. Razzaque Ahmed, MD; Elias Cohen, PhD; Leslie E. Blumenson, PhD; Thomas T. Provost, MD, Buffalo . . . **Cutaneous Myiasis Due to *Dermatobia hominis*** Lt Col E. Dale Everett, MC, USA; Lt Col Richard L. DeVillez, MC, USA; Lt Col Charles W. Lewis, MC, USA, Fort Sam Houston, Tex . . . **Skin Eruption Caused by Ethambutol** Jagjit S. Pasricha, MD, PhD, Amrinder J. Kanwar, MD, New Delhi . . . **Hair Follicle Involvement in Bullous Pemphigoid** Thomas F. Downham II, MD, Thomas A. Chapel, MD, Detroit

Letters to the Editor 1128

Treatment of Lentigo Maligna Michael A. Gromet, MD, San Francisco . . . **Treatment for Acne** Ina Levenson, MD, Milwaukee . . . **Simultaneous Occurrence of Goodpasture's Syndrome and Follicular Mucinosis** Frank J. Jonelis, MD, San Francisco . . . **Immunotherapy of Leprosy** Ramon M. Fusaro, MD, PhD, Omaha . . . **Bands in Cellular Blue Nevus** A. Bourlond, MD, Louvain, Belgium; Jag Bhawan, MD; Lee M. Edelstein, MD, Worcester, Mass . . . **Insect Sting Kit** Claude A. Frazier, MD, Asheville, NC . . . **Urticaria Due to *Clonorchis sinensis*** Ralph J. Coskey, MD, Detroit . . . **Accidental Intraocular Injection With Dermojet Syringe** Henry T. Perry, MD; Bruce T. Cohn; Jack Stanley Nauheim, MD, East Meadow, NY . . . **Nevi in Leprosy** Ronald J. Barr, MD, David C. Herzlinger, MD, Irvine, Calif . . . **Familial Localized Scleroderma (Morphoea)** Mehr Taj, MB, MRCP, DCH, Ashfaq Ahmad, MB, MRCP, FAAP, DCH, Peshawar, Pakistan . . . **Hereditary Syringomas** Howard P. Baden, MD, Boston . . . **Cantharidin Treatment of Warts at Home** E. William Rosenberg, MD; Rex A. Amonette, MD; J. Harvey Gardner, MD, Memphis . . . **Skin Closures** Samuel J. Stegman, MD, Theodore A. Tromovitch, MD, San Francisco

Society Transactions 1137

Books 1146

News and Notes 1150

Index to Advertisers 1154

Instructions for Authors 1011

SUBSCRIPTION RATES: The yearly rate of the ARCHIVES OF DERMATOLOGY is as follows: United States and US Possessions, one year, $18; two years, $28; all other countries, one year, $28; two years, $38. Special yearly price to residents, interns and medical students in the United States and US Possessions, $9.

THE ARCHIVES OF DERMATOLOGY is published monthly by the American Medical Association, 535 N Dearborn St, Chicago, IL 60610, and is an official publication of the Association. Second-class postage paid at Chicago and at additional mailing office.

Selsun®
(SELENIUM SULFIDE LOTION, U.S.P.) ℞

Brief Summary

Contains:
Selenium sulfide, 2½%, w/v; bentonite; lauric diethanolamide; ethylene glycol monostearate; titanium dioxide; amphoteric—2; sodium lauryl sulfate; sodium phosphate (monobasic); glyceryl monoricinoleate; citric acid; captan; perfume; and water.

Indications:
For the treatment of dandruff and seborrheic dermatitis of the scalp.

Contraindications:
Should not be used by patients allergic to any of its components.

Warnings:
Safety for use on infants has not been established.

Precautions:
Cutaneous sensitization of the scalp or adjacent areas has been reported; if sensitivity reactions should occur, discontinue use. Chemical conjunctivitis may result if product enters the eyes. Do not use when acute inflammation or exudation is present as an increase in absorption may occur.

Adverse Reactions:
As with other shampoos, oiliness or dryness of the hair and scalp may occur following use; there have been occasional reports of an increase in the amount of normal hair loss. Hair discoloration may occur; can be avoided or minimized by thorough rinsing.

ABBOTT
7033184

Announcing Selsun.

What?

New Selsun®

(SELENIUM SULFIDE LOTION, U.S.P.)

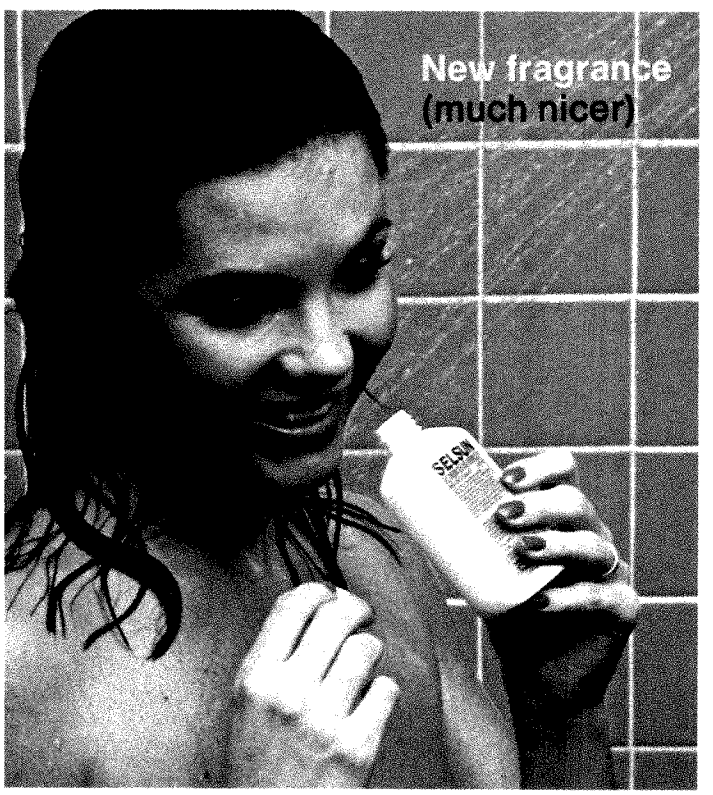

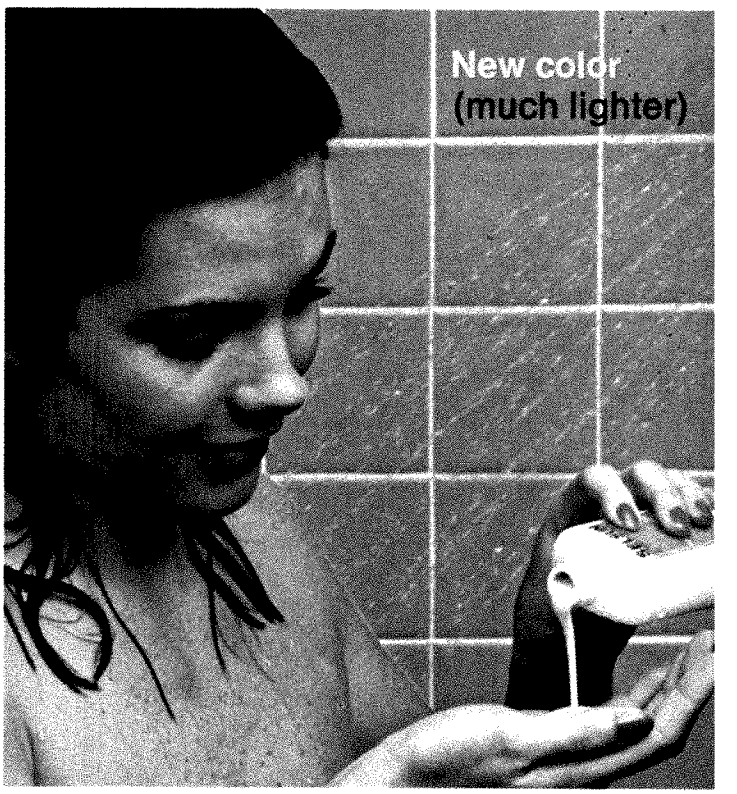

Please see opposite page for Brief Summary

Archives of Dermatology

James H. Sammons, MD
Executive Vice-President

Thomas F. Hannon
Group Vice-President,
Publishing Operations

William R. Barclay, MD
Group Vice-President,
Scientific Publications

Norman D. Richey
Director, Publication
Production Division

John T. Baker
Director, Marketing Division

Helen R. Mazur
Acting Fulfillment Manager

John T. Baker, General Sales Manager; **Robert Corcoran,** Eastern Sales Manager; **Fred Bauman, Richard M. Johnson,** Eastern Sales Representatives; **William J. Healy,** Midwest Sales Representative; **Thomas J. Carroll,** West Coast/Northern Sales Representative

PUBLICATION STAFF

Offices: 535 N Dearborn St
Chicago, IL 60610

Robert W. Mayo
Executive Editor and Director,
Scientific Publications Division

Sandra Williamson
Administrative Assistant

Marlene M. Hinsch, Production Manager

Editorial Processing Manager: Diana A. Morgan

Copy Editing: Rosanne Schulenberg (Supervisor), Paula Glitman, Patti Narret, Kathy Swartz

Proofreading: Lorraine L. Kruse (Supervisor), Patricia Coyne, Helen Grzeskiewicz, Elizabeth Petrikenas, Dorothy Troy

Production Supervisors: Julia Bero (Layout), Thomas J. Handrigan (Illustrations), Marlene M. Hinsch (Editorial), James P. Bagniewski (Advertising)

Art and Senior Production Assistants: Betty Frigerio, Linda Gilbert, Floriana Hayes, Shirley Latronica, Deborah Orent, Donna Pender, Nancy Keyes, Susan Routhier, JoAnne Weiskopf

Production Assistants: Karen Branham, E. Linda Eisenberg, Anna Goins, Dannie Kendrick, Lucille Kuznicki

Manuscript Records: Mary Paino

Indexing: Phyllis H. McLaren (Supervisor), Jane P. Mauldin, Helen F. Topel

Please address communications concerning accepted or published communications to: AMA Specialty Journals, 535 N Dearborn St, Chicago, IL 60610.

Conditions for Acceptance of Color Illustrations

Illustrations in full color are accepted for publication in ARCHIVES OF DERMATOLOGY if the editor believes that color will add significantly to the published manuscript.

When color illustrations are accepted, the American Medical Association will pay part of the expense of reproduction and printing, the remainder to be borne by the author or the institution with which he is affiliated. After deducting AMA's contribution, the author's share is $275 for up to six square finished illustrations. Additional illustrations and special effects, such as outlining, opaquing, or surprinting, will be billed to the author at cost.

Color transparencies must be submitted for evaluation. Do not send color prints unless accompanied by original transparencies. If transparencies are mounted in frames or glass, the material should be carefully packed in gauze and sent with the manuscript in a separate container or between two pieces of pressboard.

Advertising and Subscription Information

ADVERTISING OFFICES: 535 N Dearborn St, Chicago, IL 60610, Area Code 312, 751-6000; and 600 Third Ave, New York, NY 10016, Area Code 212-867-6640.

ADVERTISING PRINCIPLES: Each advertisement in this issue has been reviewed and complies with the principles governing advertising in AMA scientific publications. A copy of these principles is available on request.

CHANGE OF ADDRESS: Please notify the publisher at least six weeks in advance, including both old and new address, and a mailing label taken from the most recent copy. Include your new zip code number.

AZTEC® SUNSCREEN LOTION.

Protects better because it stays on longer. Even after swimming.

Almost all professional sunscreen products protect against overexposure to the sun. Aztec does it with two complementary sunscreening agents for full coverage in the critical 280-315 nm range.

Maintaining protection during activity is another matter altogether. Swimming, perspiration, even toweling can easily wipe other lotions away, leaving your sun-sensitive patients exposed.

Only Aztec contains a patented acrylate polymer base which forms an umbrella-like matrix on the skin. This matrix holds both sunscreening agents on the skin for maximum protection...inhibits the loss of protection caused by swimming, evaporation or wiping away.

New measures of response in psoriasis patients

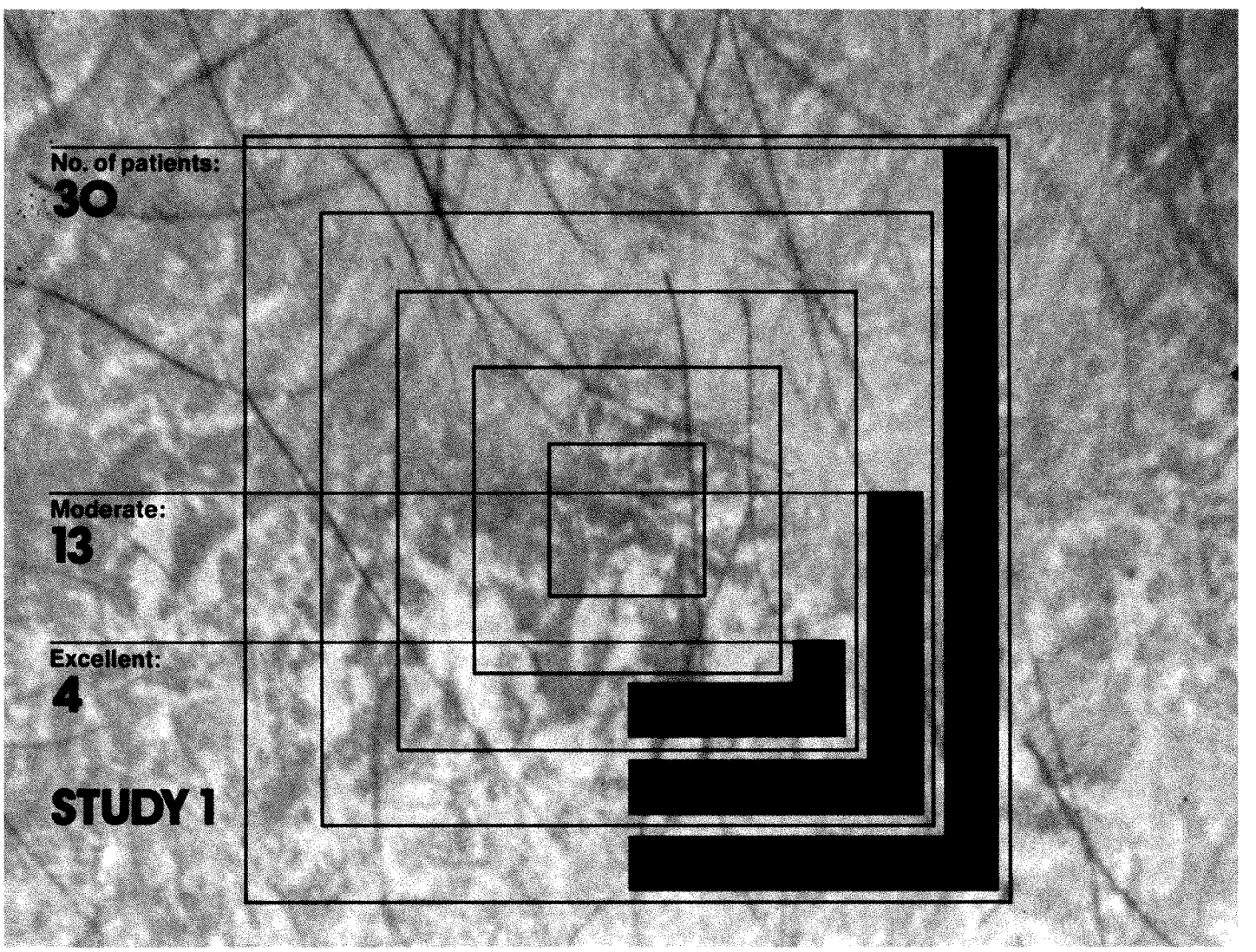

ARISTOCORT-A (Triamcinolone Acetonide 0.1%) Cream was applied t.i.d. without occlusion for 14 days, by a total of 60 patients with psoriasis, in 2 similar studies.*

The % of moderate or excellent response was 57% in Study 1 and 50% in Study 2. A combined overall response rate of 90% was achieved if 22 patients showing slight response are included.*

■ Overall patient acceptance of the Cream in both these studies was high, when evaluated against 10 criteria.

Data on file. Lederle Laboratories. Dept. of Medical Research

New studies show 50-57% moderate or excellent response in 14 days

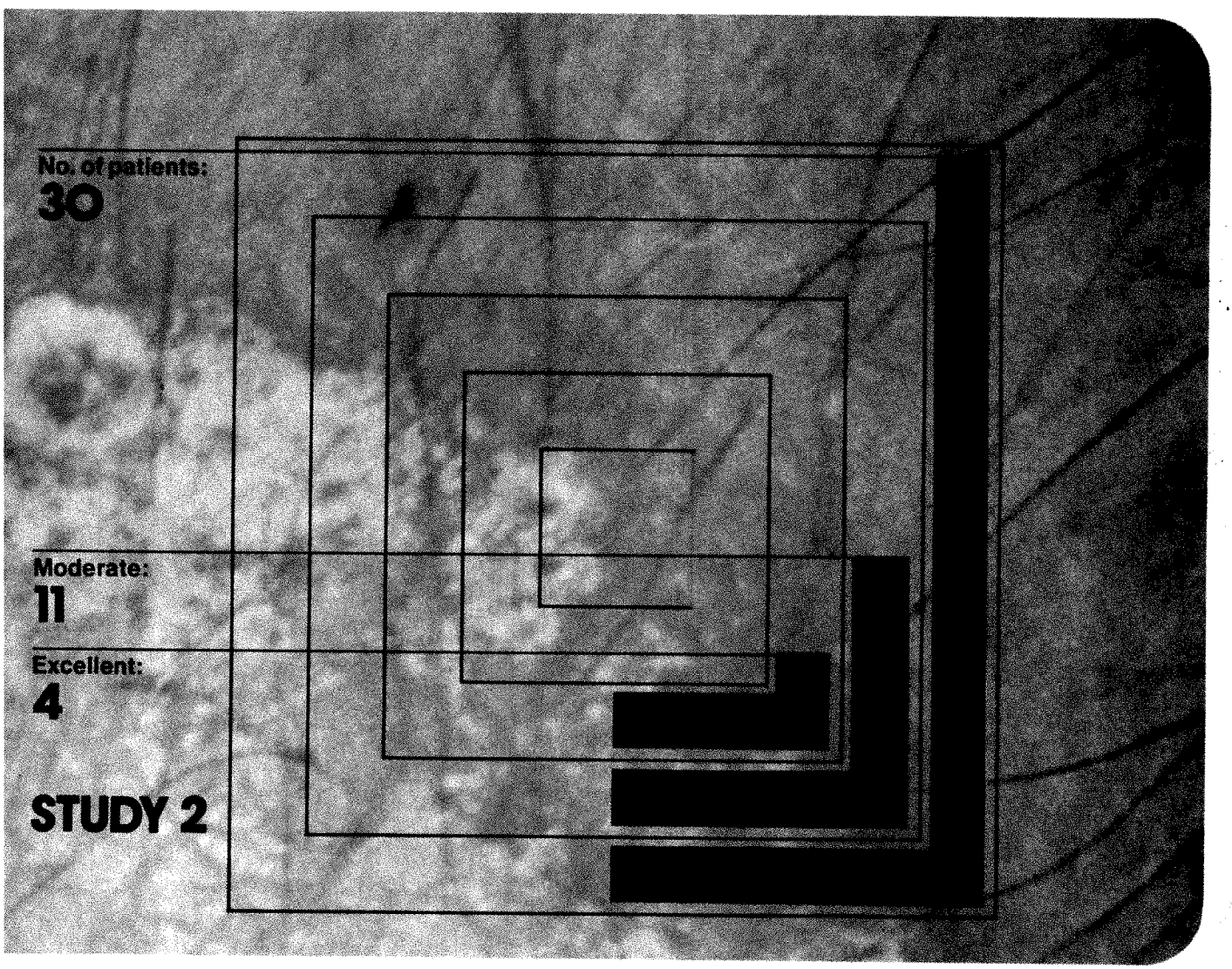

Aristocort®-A

TRIAMCINOLONE ACETONIDE 0.1% Cream

with AQUATAIN™ Hydrophilic Base

See following page for prescribing information.

Large size packages

save money when treating chronic and/or extensive dermatoses



CREAM 0.025%
(Quarter Strength)
75 Gm. tubes



OINTMENT 0.1%
(Regular Potency)
75 Gm. tubes

Also available: 15 Gm. tubes of ARISTOCORT A Cream—0.025%, 0.1% and 0.5%—and ARISTOCORT A Ointment, 0.1% and 0.5%.

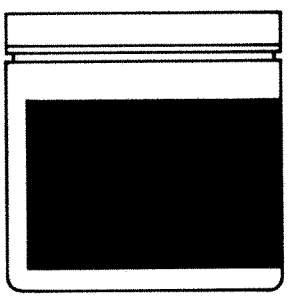

CREAM 0.1%
(Regular Potency)
75 Gm. tubes
½ lb. jars

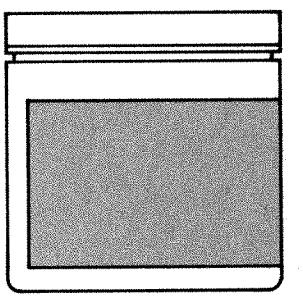

CREAM 0.5%
(High Potency)
½ lb. jars

INDICATIONS: For relief of inflammatory manifestations of corticosteroid-responsive dermatoses.

CONTRAINDICATIONS: Viral skin diseases, such as varicella and vaccinia; hypersensitivity to any component (not for ophthalmic use); when circulation is markedly impaired.

WARNINGS: Safety of use in pregnancy has not been absolutely established. Do not use extensively, in large amounts, or for prolonged periods of time in pregnant patients.

PRECAUTIONS: If irritation develops, discontinue use and institute appropriate therapy. In infections, use appropriate antifungal or antibacterial agents; if a favorable response does not occur promptly, discontinue the corticosteroid until the infection is adequately controlled. If extensive areas are treated or the occlusive technique is used, increased systemic absorption of the corticosteroid may occur; take suitable precautions.

ADVERSE REACTIONS: (local) Burning sensations, itching, irritation, dryness, folliculitis, secondary infection, skin atrophy, striae, hypertrichosis, acneform eruption and hypopigmentation.

ARISTOCORT A CREAM: Each gram of ARISTOCORT A contains 0.25 mg. (0.05%), 1 mg. (0.1%) or 5 mg. (0.5%) of the highly active steroid, Triamcinolone Acetonide (a derivative of triamcinolone) in AQUATAIN, a specially formulated base composed of emulsifying wax NF, isopropyl palmitate, glycerin USP, sorbitol solution USP, lactic acid, 2% benzyl alcohol and purified water. AQUATAIN is non-staining, water-washable, paraben-free, spermaceti-free and has a light texture and consistency.

ARISTOCORT A OINTMENT: Each gram of ARISTOCORT A Ointment contains 1 mg. (0.1%) or 5 mg. (0.5%) of the highly active steroid, Triamcinolone Acetonide (a derivative of triamcinolone) in a specially formulated base composed of emulsifying wax NF, white petrolatum, and propylene glycol. In addition, the 0.1% Ointment contains Tenox II and lactic acid.

Lederle

LEDERLE LABORATORIES,
A Division of American Cyanamid Company
Pearl River, New York 10965

066-7

Aristocort®-A

TRIAMCINOLONE ACETONIDE with AQUATAIN™ Hydrophilic Base 0.1% Cream

A free measure for lesions
Ask your Lederle Representative for a complimentary supply.

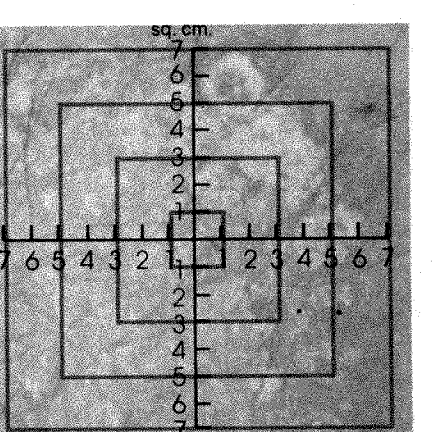

Instructions for Authors

Send manuscripts by first-class mail to the Chief Editor, John H. Epstein, MD, 450 Sutter St, San Francisco, CA 94108. Manuscripts are received with the understanding that they are not under simultaneous consideration by another publication. Accepted manuscripts become the permanent property of the ARCHIVES and may not be published elsewhere without permission from the publisher (AMA).

Author Responsibility.—All accepted manuscripts are subject to copy editing. The author will receive an edited typescript rather than galley proofs for approval. The author is responsible for all statements in his work, including changes made by the copy editor.

Designate one author as correspondent and provide his address and telephone number. Order reprints at the time the typescript is returned after editorial processing. Specify address to which requests for reprints should be sent.

Manuscript Preparation.—Submit an original typescript and two high-quality copies of the entire manuscript. All copy (including references, legends, and tables) must be typed double-spaced on 22 × 28-cm (8½ × 11-inch), heavy-duty white bond paper. Ample margins should be provided.

Refer to patients by number (or, in anecdotal reports, by fictitious given names). Real names or initials should not be used in the text, tables, or illustrations.

Titles.—Titles should be short, specific, and clear. They should not exceed 42 characters per line, including punctuation and spaces, and be limited to two lines, if possible. The title page should include the full names and academic affiliations of all authors, the address to which requests for reprints should be sent, and, if the manuscript was presented at a meeting, the name of the organization, place, and date on which it was read.

Style of Writing.—The style of writing should conform to acceptable English usage and syntax. Slang, medical jargon, obscure abbreviations, and abbreviated phrasing are to be avoided.

Informed Consent.—Manuscripts reporting the results of experimental investigations of human subjects must include a statement to the effect that informed consent was obtained after the nature of the procedure(s) had been fully explained.

Abstract.—Provide an abstract (135-word maximum) of the article, including statements of the problem, method of study, results, and conclusions. The abstract replaces the summary.

References.—List references in consecutive numerical order (not alphabetically). Once a reference is cited, all subsequent citations should be to the original number. All references must be cited in the text or tables. Unpublished data and personal communications should not be listed as references. References to journal articles should include (1) author, (2) title, (3) journal name (as abbreviated in *Index Medicus*), (4) volume number, (5) inclusive page numbers, and (6) year, in that order. References to books should include (1) author(s), (2) chapter title (if any), (3) editor (if any), (4) title of book, (5) city of publication, (6) publisher, and (7) year. Volume and edition numbers, specific pages, and name of translator should be included when appropriate. The author is responsible for the accuracy and completeness of the references and for their correct text citation.

Metrication.—All measurements must be in metric units. English units may also be given parenthetically if the measurements were originally done in English units.

Illustrations.—Use only those illustrations that clarify and augment the text. Submit illustrations in duplicate, unmounted and unrimmed. Do not send original artwork. Send high-contrast glossy prints (not photocopies). Figure number, name of senior author and arrow indicating "top" should be typed on a gummed label and affixed to the back of each illustration. All lettering must be legible after reduction to column size. Artwork submitted for publication may be relettered to achieve uniformity of lettering style throughout the journal. Magnification and stain should be provided when pertinent. Illustrations should preferably be in a proportion of 12.5 × 18 cm (5 × 7 inches).

An experienced medical illustrator should be employed whenever possible for the preparation of all artwork. Template lettering or preset type is preferred to hand-lettered labels. If halftone artwork with labels is submitted, affix type and leaders to a clear acetate overlay registered to the base drawing. Labels and leaders should be applied directly to the drawing board surface if the artwork consists only of line ink technique.

Illustrations in full color are accepted for publication if the editors believe that color will add significantly to the published manuscript. The ARCHIVES will pay part of the expense of reproduction and printing color illustrations, the remainder to be borne by the author or his sponsor. After deducting the ARCHIVES contribution, the author's share is $275.00 for up to six square-finished illustrations that can be arranged on a one-page layout. Any additional illustrations or special effects will be billed to the author at cost. Positive color transparencies (35 mm preferred) must be submitted for an evaluation. Do not send color prints unless accompanied by original transparencies. All transparencies should be carefully packed and sent with the manuscript.

Legends.—Legends should be typed double-spaced, beginning on a separate sheet of paper. Length should be limited to a maximum of 40 words.

Photographic Consents.—A letter of consent must accompany all photographs of patients in which a possibility of identification exists. It is not sufficient to cover the eyes to mask identity.

Acknowledgments.—Illustrations from other publications must be acknowledged. Include the following when applicable: author(s), title of article, title of journal or book, volume number, page(s), month, and year. The publisher's permission to reprint should be submitted to the ARCHIVES after the manuscript has been formally accepted.

Statistical Review.—Manuscripts containing statistical evaluations should include the name and affiliation of the statistical reviewer.

Tables.—Each table should be typed double-spaced, including all headings, on a separate sheet of 22 × 28-cm (8½ × 11-inch) paper. Do not use larger size paper. If a table must be continued, use a second sheet and repeat all heads and stubs. Each table must have a title.

New fast way with spray
for contact dermatitis control

New Diprosone® Aerosol 0.1%
brand of
betamethasone dipropionate (Potency expressed as betamethasone)

Rapid improvement of moderate to very severe contact dermatitis signs/symptoms*

	Per cent of patients improved†		
	Pruritus 129 patients	**Erythema 129 patients**	**Vesiculation 77 patients**
After 3 days	**85%**	**78%**	**82%**
After 7 days	**92%**	**93%**	**94%**

*Improvement is defined as a reduction of signs or symptoms. †Data in files of Headquarters Medical Research Division, Schering Corporation.

- Easily penetrates hairy areas...convenient for hard-to-reach sites.
- Cools and soothes hot, oozing, itching lesions.
- Cosmetically elegant...invisible, odorless, stainless.

Diprosone is also available in cream, ointment, and lotion.

COPYRIGHT © 1977, SCHERING CORPORATION. ALL RIGHTS RESERVED. SLS-846

See Clinical Considerations section on opposite page...

Schering

New Diprosone®

brand of
betamethasone
dipropionate
Aerosol 0.1%

Clinical Considerations: INDICATIONS DIPROSONE Aerosol is indicated solely for the adjunctive topical management for the relief of inflammatory manifestations of acute contact dermatitis. DIPROSONE Aerosol has not been shown to be effective in any steroid-responsive dermatosis other than contact dermatitis. **CONTRAINDICATIONS** DIPROSONE Aerosol is contraindicated in vaccinia and varicella. Topical steroids are contraindicated in those patients with a history of hypersensitivity to any of the components of such preparations. DIPROSONE Aerosol is also contraindicated for use under occlusive dressings. **WARNINGS** Keep away from eyes or other mucous membranes. Use only as directed; intentional misuse by deliberately concentrating or inhaling the contents can be harmful or fatal. Avoid freezing of the tissue by not spraying for more than three seconds, at a distance of not less than six inches. Contents under pressure. Do not puncture. Do not use or store near heat or open flame. Exposure to temperatures above 120° Fahrenheit may cause bursting. Never throw container into fire or incinerator. Keep out of reach of children. **PRECAUTIONS** If irritation develops with the use of DIPROSONE Aerosol, treatment should be discontinued and appropriate therapy instituted. In the presence of an infection, the use of an appropriate antifungal or antibacterial agent should be instituted. If a favorable response does not occur promptly, the corticosteroid should be discontinued until the infection has been adequately controlled. If extensive areas are treated, the possibility exists of increased systemic absorption of the corticosteroid and suitable precautions should be taken. Although topical steroids have not been reported to have an adverse effect on pregnancy, the safety of their use in pregnant females has not been absolutely established. Therefore, they should not be used extensively on pregnant patients, in large amounts or for prolonged periods of time. DIPROSONE Aerosol is not for ophthalmic use. **ADVERSE REACTIONS** The following local adverse reactions have been reported with topical corticosteroids: burning; itching; irritation; dryness; folliculitis; hypertrichosis; acneiform eruptions; hypopigmentation; maceration of the skin; secondary infection; skin atrophy; striae; miliaria.

11079105 MARCH 1977

Aerosol Packaged by Aerosol Techniques, Inc.
Armstrong Laboratories Division
West Roxbury, MA 02132

For more complete details, consult package insert or Schering literature available from your Schering Representative or Professional Services Department, Schering Corporation, Kenilworth, New Jersey 07033.

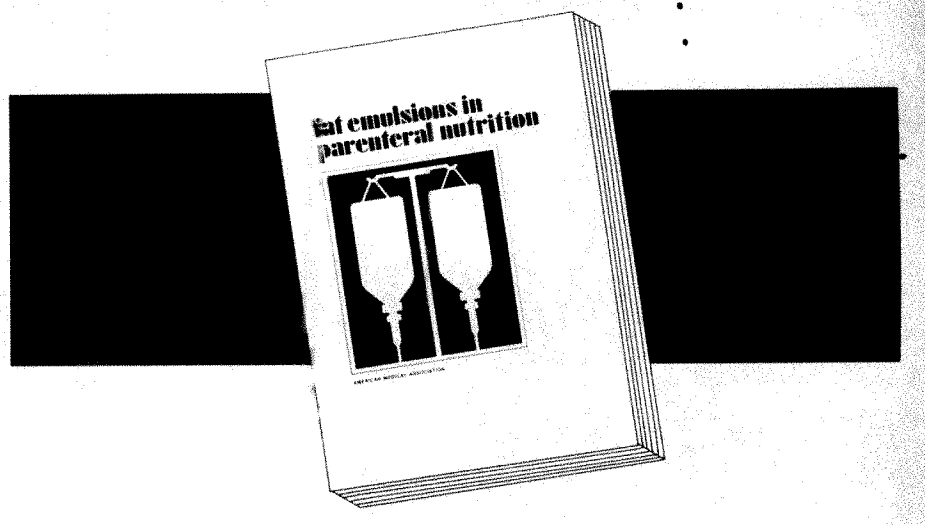

FDA soon to approve fat emulsions for clinical use!
Prepare yourself with this new AMA book...

Fat Emulsions in Parenteral Nutrition

A digest of the latest important research findings

FAT EMULSIONS IN PARENTERAL NUTRITION, the proceedings of the June, 1975 meeting sponsored by the Department of Foods and Nutrition and the Nutrition Advisory Group of the AMA, will provide you with a review of experimental and clinical studies and discussions of problems encountered with the use of fat emulsions.

Divided into three sections, the book covers the metabolism of fatty acids and function of essential fatty acids with information on EFA deficiency; fat as an energy source; and the pathophysiology with discussions on side effects, interrelations with other nutrients, and the current status of products available.

To avoid potential problems and to become thoroughly acquainted with the intricacies of this about-to-be-approved nutritional supplement, every hospital physician, nurse and pharmacist should make this publication required reading.

Order Dept. OP-140, AMA, 535 N. Dearborn St., Chicago, Ill. 60610

Please send _____ copy(ies) of FAT EMULSIONS IN PARENTERAL NUTRITION, OP-140, $7 in U.S. and U.S. Possessions, $7.50 elsewhere.

Name _____

Institution _____

Address _____

City _____ State _____ Zip _____

Remittance, made payable to AMA, must accompany order. S/J

Gets to deep fungal infections

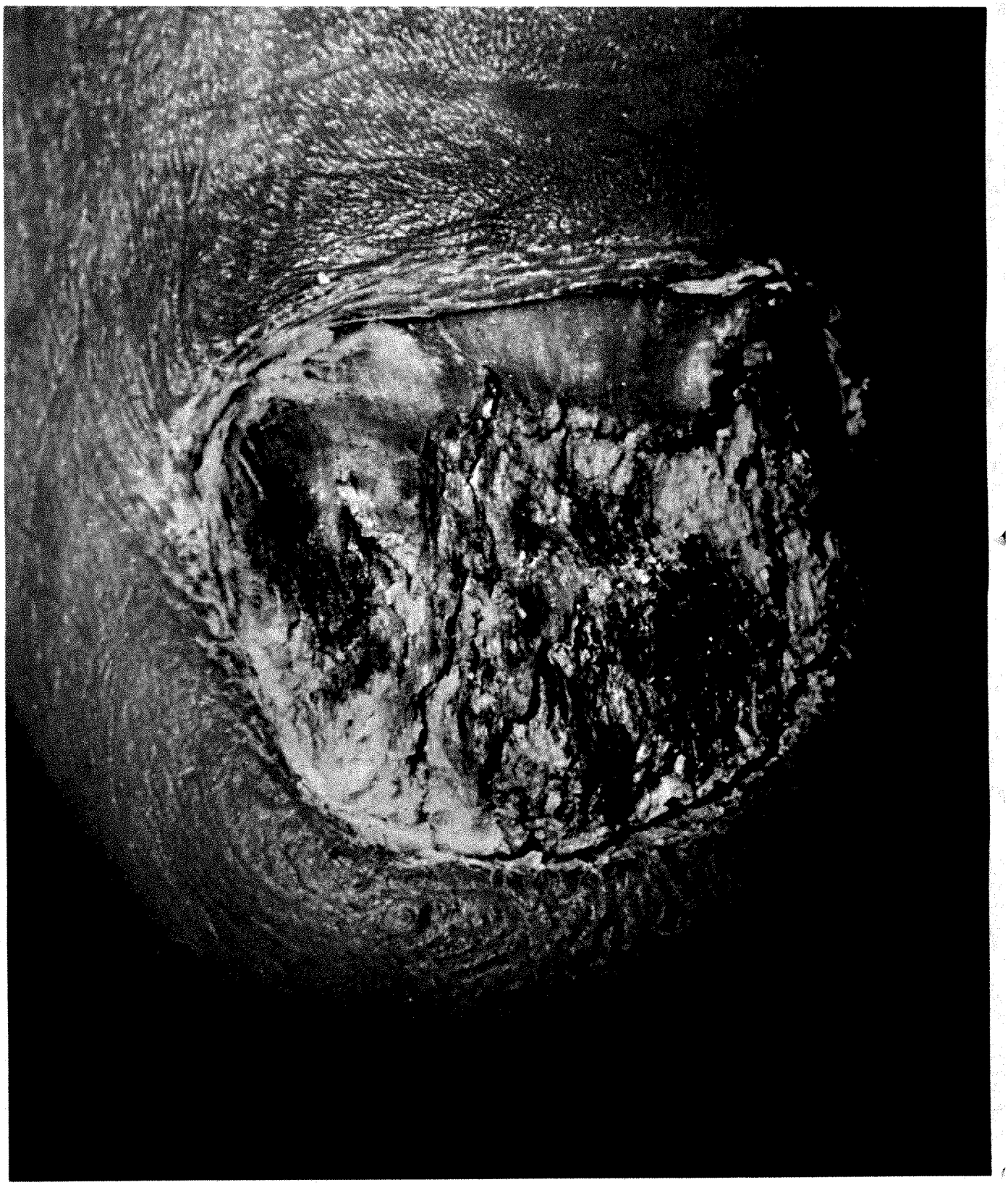

Actual photograph of tinea unguium infection (onychomycosis).
Note typical worm-eaten appearance of fingernail destroyed by fungus.

when topicals can't.

Potent, systemic fungistat

GRISACTIN provides the antifungal activity needed to control tinea infections, including onychomycosis, that invade the dermis and deeper regions. Systemic action penetrates where topical action often fails.

GRISACTIN is effective against a wide range of fungi: *Trichophyton rubrum, T. mentagrophytes, T. tonsurans, T. interdigitalis, T. verrucosum, T. megnini, T. gallinae, T. crateriform, T. sulphureum, T. schoenleini, Microsporum canis, M. audouini, M. gypseum,* and *Epidermophyton floccosum.*

Peak serum levels are usually produced in about four hours with a single 500 mg. tablet. To meet the requirements of different patients—depending on body weight, age, severity, and location of infection—dosage is easily individualized with 125 mg. and 250 mg. capsules, and 500 mg. tablets.

Grisactin® 500

BRAND OF

griseofulvin (microsize) TABLETS

BRIEF SUMMARY
(For full prescribing information, see package circular.)

Grisactin®
Brand of
Griseofulvin (microsize)

Indications: Griseofulvin is indicated for the treatment of ringworm infections of the skin, hair, and nails, namely: *Tinea corporis, Tinea pedis, Tinea cruris, Tinea barbae, Tinea capitis, Tinea unguium* (onychomycosis) when caused by one or more of the following genera of fungi: *Trichophyton rubrum, T. tonsurans, T. mentagrophytes, T. interdigitalis, T. verrucosum, T. megnini, T. gallinae, T. crateriform, T. sulphureum, T. schoenleini, Microsporum audouini, M. canis, M. gypseum, Epidermophyton floccosum.*
NOTE: Prior to therapy, the type of fungi responsible for the infection should be identified.
The use of this drug is not justified in minor or trivial infections which will respond to topical agents alone.
Griseofulvin is *not* effective in the following: Bacterial infections, candidiasis (moniliasis), histoplasmosis, actinomycosis, sporotrichosis, chromoblastomycosis, coccidioidomycosis, North American blastomycosis, cryptococcosis (torulosis), *Tinea versicolor,* nocardiosis.
Contraindications: This drug is contraindicated in patients with porphyria, hepatocellular failure, and in individuals with a history of hypersensitivity to griseofulvin.
Warnings: *Prophylactic Usage*—Safety and efficacy of griseofulvin for prophylaxis of fungal infections has not been established.
Animal Toxicology—Chronic feeding of griseofulvin, at levels ranging from 0.5-2.5% of the diet, resulted in the development of liver tumors in several strains of mice, particularly in males. Smaller particle sizes result in an enhanced effect. Lower oral dosage levels have not been tested. Subcutaneous administration of relatively small doses of griseofulvin, once a week, during the first three weeks of life has also been reported to induce hepatomata in mice. Although studies in other animal species have not yielded evidence of tumorigenicity, these studies were not of adequate design to form a basis for conclusions in this regard.
In subacute toxicity studies, orally administered griseofulvin produced hepatocellular necrosis in mice, but this has not been seen in other species. Disturbances in porphyrin metabolism have been reported in griseofulvin-treated laboratory animals. Griseofulvin has been reported to have a colchicine-like effect on mitosis and cocarcinogenicity with methylcholanthrene in cutaneous tumor induction in laboratory animals.
Usage in Pregnancy—The safety of this drug during pregnancy has not been established.
Animal Reproduction Studies—It has been reported in the literature that griseofulvin was found to be embryotoxic and teratogenic on oral administration to pregnant rats. Pups with abnormalities have been reported in the litters of a few bitches treated with griseofulvin. Additional animal reproduction studies are in progress.
Suppression of spermatogenesis has been reported to occur in rats, but investigation in man failed to confirm this.
Precautions: Patients on prolonged therapy with any potent medication should be under close observation. Periodic monitoring of organ system function, including renal, hepatic, and hematopoietic, should be done.
Since griseofulvin is derived from a species of Penicillium, the possibility of cross-sensitivity with penicillin exists; however, known penicillin-sensitive patients have been treated without difficulty.
Since a photosensitivity reaction is occasionally associated with griseofulvin therapy, patients should be warned to avoid exposure to intense natural or artificial sunlight. Should a photosensitivity reaction occur, lupus erythematosus may be aggravated.
Griseofulvin decreases the activity of warfarin-type anticoagulants so that patients receiving these drugs concomitantly may require dosage adjustment of the anticoagulant during and after griseofulvin therapy.
Barbiturates usually depress griseofulvin activity and concomitant administration may require a dosage adjustment of the antifungal agent.
Adverse Reactions: When adverse reactions occur, they are most commonly of the hypersensitivity type such as skin rashes, urticaria, and rarely, angioneurotic edema, and may necessitate withdrawal of therapy and appropriate countermeasures. Paresthesias of the hands and feet have been reported rarely after extended therapy. Other side effects reported occasionally are oral thrush, nausea, vomiting, epigastric distress, diarrhea, headache, fatigue, dizziness, insomnia, mental confusion, and impairment of performance of routine activities.
Proteinuria and leukopenia have been reported rarely. Administration of the drug should be discontinued if granulocytopenia occurs.
When rare, serious reactions occur with griseofulvin, they are usually associated with high dosages, long periods of therapy, or both.
Dosage and Administration: Accurate diagnosis of the infecting organism is essential. Medication must be continued until the infecting organism is completely eradicated as indicated by appropriate clinical or laboratory examination. General measures in regard to hygiene should be observed to control sources of infection or reinfection. Concomitant use of appropriate topical agents is usually required, particularly in treatment of *tinea pedis.*
Dosage should be individualized, depending on age and severity of infection. *Adults*—0.5 Gm. daily (125 mg. q.i.d., 250 mg. b.i.d., or 500 mg./day). *Children*—10 mg./kg. daily is usually adequate (from 30 to 50 lb., 125 mg. to 250 mg. daily; over 50 lb., 250 mg. to 500 mg. daily, in divided doses).
How Supplied: GRISACTIN [griseofulvin (microsize)]—No. 442—GRISACTIN 125, each capsule contains 125 mg., in bottles of 100 and 500. No. 443—GRISACTIN 250, each capsule contains 250 mg., in bottles of 100 and 500. No. 444—GRISACTIN 500, each tablet (scored) contains 500 mg., in bottles of 60.

Ayerst

Ayerst Laboratories
New York, N.Y. 10017

7719

Rapid relief...

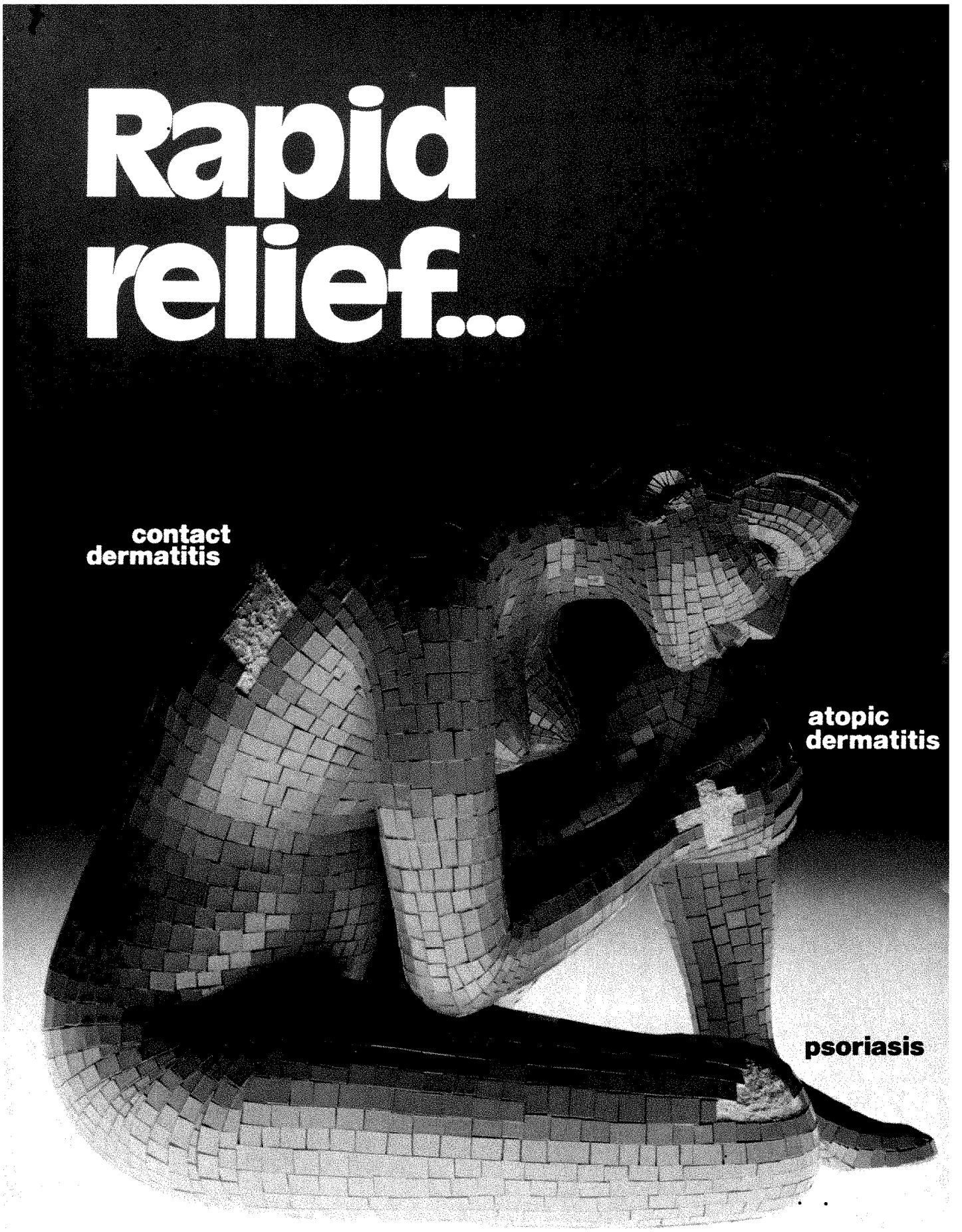

COPYRIGHT © 1977, SCHERING CORPORATION. ALL RIGHTS RESERVED.

b.i.d.
Diprosone®
brand of
betamethasone dipropionate
Cream 0.05%
(Potency expressed as betamethasone)

Twice a day for prompt relief of corticosteroid-responsive dermatoses

In contact dermatitis

90% of patients showed marked or moderate improvement in seven days*
34 of 38 contact dermatitis patients responded to therapy.

In atopic dermatitis

86% of patients showed marked or moderate improvement in seven days*
133 of 155 atopic dermatitis patients responded to therapy.

In psoriasis

62% of patients showed marked or moderate improvement in only seven days*
116 of 188 psoriasis patients responded to therapy.

Additional benefits:

- Rapid onset of response.
- Economy and convenience of b.i.d. dosage.
- Occlusive dressings infrequently needed.
- Sensitivity is rare.
- Choice of convenient package sizes—in 15 Gm. and moneysaving 45 Gm. tubes.

Diprosone® brand of betamethasone dipropionate
Cream 0.05%/Ointment 0.05%

Clinical Considerations:

DESCRIPTION DIPROSONE is betamethasone dipropionate (9-fluoro-11β, 17,21-trihydroxy-16β-methylpregna-1,4-diene-3,20-dione 17,21-dipropionate). Each gram of DIPROSONE **Cream** 0.05% contains 0.64 mg. betamethasone dipropionate (equivalent to 0.5 mg. betamethasone) in a hydrophilic, emollient cream consisting of purified water, mineral oil, white petrolatum, polyethylene glycol 1000 monocetyl ether, cetostearyl alcohol, phosphoric acid, and monobasic sodium phosphate with 4-chloro-*m*-cresol as preservative. Each gram of DIPROSONE **Ointment** 0.05% contains 0.64 mg. betamethasone dipropionate (equivalent to 0.5 mg. betamethasone) in an ointment base of mineral oil and white petrolatum. **CONTRAINDICATIONS** DIPROSONE **Cream** and **Ointment** are contraindicated in vaccinia and varicella. Topical steroids are contraindicated in those patients with a history of hypersensitivity to any of the components of such preparations. **PRECAUTIONS** If irritation develops with the use of DIPROSONE **Cream** or **Ointment,** treatment should be discontinued and appropriate therapy instituted. In the presence of an infection, the use of an appropriate antifungal or antibacterial agent should be instituted. If a favorable response does not occur promptly, the corticosteroid should be discontinued until the infection has been adequately controlled. If extensive areas are treated or if the occlusive technique is used, the possibility exists of increased systemic absorption of the corticosteroid and suitable precautions should be taken. Although topical steroids have not been reported to have an adverse effect on pregnancy, the safety of their use in pregnant females has not been absolutely established. Therefore, they should not be used extensively on pregnant patients, in large amounts or for prolonged periods of time. DIPROSONE **Cream** and **Ointment** are not for ophthalmic use. **ADVERSE REACTIONS** The following local adverse reactions have been reported with topical corticosteroids: burning; itching; irritation; dryness; folliculitis; hypertrichosis; acneiform eruptions; hypopigmentation. The following may occur more frequently with occlusive dressings than without such therapy: maceration of the skin; secondary infection; skin atrophy; striae; miliaria. **DOSAGE AND ADMINISTRATION** Apply a thin film of DIPROSONE **Cream** to the affected skin areas twice daily, in the morning and at night. Clinical studies of DIPROSONE have indicated that applications twice a day are generally adequate. Apply a small quantity of DIPROSONE **Ointment** to the affected skin areas twice daily, in the morning and at night.

APRIL 1976

For more complete details, consult package insert or Schering literature available from your Schering Representative or Professional Services Department, Schering Corporation, Kenilworth, New Jersey 07033.

*Data in files of Headquarters Medical Research Division, Schering Corporation

Also available for prescribing flexibility

b.i.d. Diprosone® Ointment 0.05%
brand of betamethasone dipropionate

SLS-710

Ways to help allergy patients avoid "a bad day at the office"

Your allergy patients who are office workers may spend a quarter of their adult life in a hostile environment – from an allergen standpoint. Here are suggestions that might, with the help of an understanding employer, lessen the allergic burden.

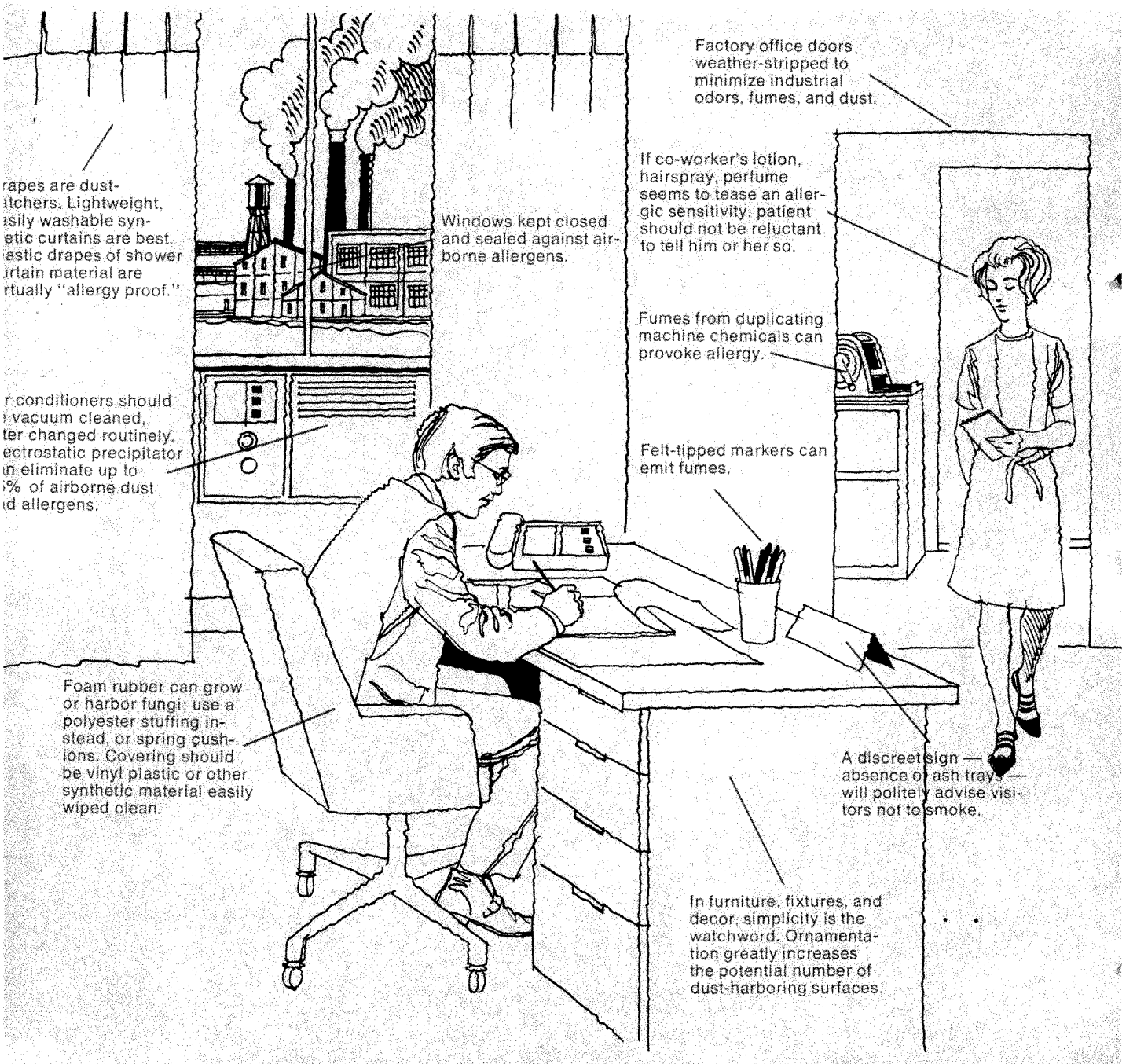

All measures to minimize exposure can be helpful. Still, allergic symptoms may occur and an antihistamine will be needed to bring these reactions under control. Dimetane Extentabs keep working for 10-12 hours, are economical, and are likely to produce good results in stubborn as well as routine cases, usually without drowsiness or overstimulation.

DIMETANE Extentabs®

(BROMPHENIRAMINE MALEATE, NF 8 mg. and 12 mg.)

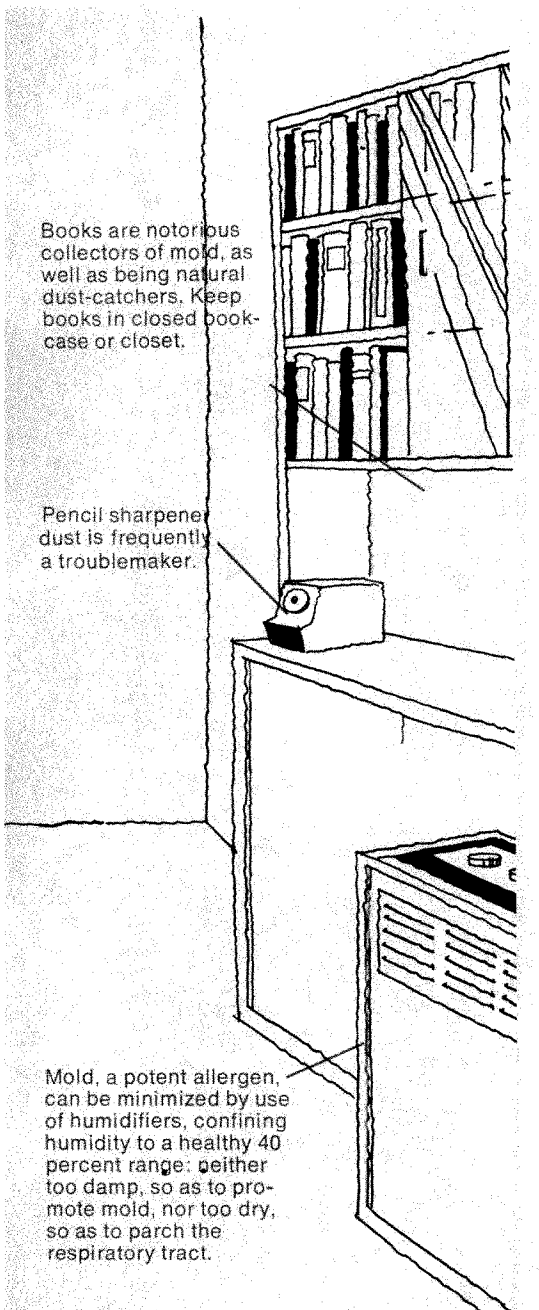

Indications: Perennial and seasonal allergic rhinitis; vasomotor rhinitis; allergic conjunctivitis due to inhalant allergens and foods; mild, uncomplicated allergic skin manifestations of urticaria and angioedema; amelioration of allergic reactions to blood or plasma; dermatographism; as therapy for anaphylactic reactions *adjunctive* to epinephrine and other standard measures after the acute manifestations have been controlled. **Contraindications:** *Use in Newborn or Premature Infants.* This drug should **not** be used in newborn or premature infants. *Use in Nursing Mothers.* Because of the higher risk of antihistamines for infants generally and for newborns and prematures in particular, antihistamine therapy is contraindicated in nursing mothers. *Use in Lower Respiratory Disease.* Antihistamines should NOT be used to treat lower respiratory tract symptoms including asthma. Antihistamines are also contraindicated in the following conditions: hypersensitivity to brompheniramine maleate and other antihistamines of similar chemical structure; monoamine oxidase inhibitor therapy (see Drug Interaction section). **Warnings:** Antihistamines should be used with considerable caution in patients with: narrow angle glaucoma; stenosing peptic ulcer; pyloroduodenal obstruction; symptomatic prostatic hypertrophy; bladder neck obstruction. *Use in Children.* In infants and children, especially, antihistamines in **overdosage** may cause hallucinations, convulsions, or death. As in adults, antihistamines may diminish mental alertness in children. In the young child, particularly, they may produce excitation. *Use in Pregnancy.* Experience with this drug in pregnant women is inadequate to determine whether there exists a potential for harm to the developing fetus. *Use with CNS Depressants.* Dimetane has additive effects with alcohol and other CNS depressants (hypnotics, sedatives, tranquilizers, etc.). *Use in Activities Requiring Mental Alertness.* Patients should be warned about engaging in activities requiring mental alertness, such as driving a car or operating appliances, machinery, etc. *Use in the Elderly (approximately 60 years or older).* Antihistamines are more likely to cause dizziness, sedation, and hypotension in elderly patients. **Precautions:** As with other antihistamines, Dimetane has an atropine-like action and, therefore, should be used with caution in patients with: history of bronchial asthma; increased intraocular pressure; hyperthyroidism; cardiovascular disease; hypertension. **Drug Interactions:** MAO inhibitors prolong and intensify the anticholinergic (drying) effects of antihistamines. **Adverse Reactions:** The most frequent adverse reactions are italicized: *General:* Urticaria, drug rash, anaphylactic shock, photosensitivity, excessive perspiration, chills, dryness of mouth, nose, and throat. *Cardiovascular System:* Hypotension, headache, palpitations, tachycardia, extrasystoles. *Hematologic System:* Hemolytic anemia, thrombocytopenia, agranulocytosis. *Nervous System: Sedation, sleepiness, dizziness, disturbed coordination,* fatigue, confusion, restlessness, excitation, nervousness, tremor, irritability, insomnia, euphoria, paresthesias, blurred vision, diplopia, vertigo, tinnitus, acute labyrinthitis, hysteria, neuritis, convulsions. *G.I. System: Epigastric distress,* anorexia, nausea, vomiting, diarrhea, constipation. *G.U. System:* Urinary frequency, difficult urination, urinary retention, early menses. *Respiratory System: Thickening of bronchial secretions,* tightness of chest and wheezing, nasal stuffiness. **Overdosage:** Antihistamine overdosage reactions may vary from central nervous system depression to stimulation. Stimulation is particularly likely in children. Atropine-like signs and symptoms – dry mouth; fixed, dilated pupils; flushing; and gastrointestinal symptoms may also occur. *If vomiting has not occurred spontaneously,* the patient should be induced to vomit. This is best done by having him drink a glass of water or milk after which he should be made to gag. Precautions against aspiration must be taken, especially in infants and children. *If vomiting is unsuccessful,* gastric lavage is indicated within 3 hours after ingestion and even later if large amounts of milk or cream were given beforehand. Isotonic and ½ isotonic saline is the lavage solution of choice. *Saline cathartics,* as milk of magnesia, by osmosis draw water into the bowel and therefore, are valuable for their action in rapid dilution of bowel content. *Stimulants* should **not** be used. Vasopressors may be used to treat hypotension. **Dosage and Administration:** DOSAGE SHOULD BE INDIVIDUALIZED ACCORDING TO THE NEEDS AND THE RESPONSE OF THE PATIENTS. *Adults:* One to two 4 mg tablets three or four times a day. One Extentab (8 or 12 mg) every eight to twelve hours or twice daily. Two to four teaspoonfuls of elixir three or four times a day. *Children over six.* One 4 mg tablet three or four times a day. One Extentab (8 or 12 mg) every twelve hours. One or two teaspoonfuls of elixir three or four times a day. *Children under six.* 0.5 mg of brompheniramine maleate per kg of body weight per 24 hours, or 15 mg per M^2 per 24 hours, divided into 3-4 doses.

A·H·ROBINS

A. H. ROBINS COMPANY, RICHMOND, VA 23220

10154 1800

anti-
inflammatory
antifungal
antipruritic
antibacterial

Clear choice

When dermatoses become infected with bacteria or fungi, plain topical steroids are generally not the recommended therapeutic choice.

A clear choice, however, is Vioform® Hydrocortisone. With its unique four-way action, it supplies the kind of comprehensive treatment many common dermatoses* require.

*This drug has been evaluated as possibly effective for these indications. See brief prescribing information.

Vioform®-Hydrocortisone
(iodochlorhydroxyquin and hydrocortisone)

INDICATIONS
Based on a review of this drug by the National Academy of Sciences-National Research Council and/or other information, FDA has classified the indications as follows:
"Possibly" effective: Contact or atopic dermatitis; impetiginized eczema; nummular eczema; infantile eczema; endogenous chronic infectious dermatitis; stasis dermatitis; pyoderma; nuchal eczema and chronic eczematoid otitis externa; acne urticata; localized or disseminated neurodermatitis; lichen simplex chronicus; anogenital pruritus (vulvae, scroti, ani); folliculitis; bacterial dermatoses; mycotic dermatoses such as tinea (capitis, cruris, corporis, pedis); moniliasis; intertrigo. Final classification of the less-than-effective indications requires further investigation.

CONTRAINDICATIONS
Hypersensitivity to Vioform-Hydrocortisone, or any of its ingredients or related compounds; lesions of the eye; tuberculosis of the skin; most viral skin lesions (including herpes simplex, vaccinia, and varicella).

WARNINGS
This product is not for ophthalmic use.
In the presence of systemic infections, appropriate systemic antibiotics should be used.

Usage in Pregnancy
Although topical steroids have not been reported to have an adverse effect on pregnancy, the safety of their use in pregnant females has not been established. Therefore, they should not be used extensively on pregnant patients in large amounts or for prolonged periods of time.

PRECAUTIONS
May prove irritating to sensitized skin in rare cases. If this occurs, discontinue therapy. May stain.
If used under occlusive dressings or for a prolonged period, watch for signs of pituitary-adrenal axis suppression.
May interfere with thyroid function tests. Wait at least one month after discontinuance of therapy before performing these tests. The ferric chloride test for phenylketonuria (PKU) can yield a false-positive result if Vioform is present in the diaper or urine.
Prolonged use may result in overgrowth of nonsusceptible organisms requiring appropriate therapy.

ADVERSE REACTIONS
Few reports include: Hypersensitivity, local burning, irritation, pruritus. Discontinue if untoward reaction occurs. Rarely, topical corticosteroids may cause striae at site of application when used for long periods in intertriginous areas.

DOSAGE
Apply a thin layer to affected areas 3 or 4 times daily.

HOW SUPPLIED
Cream, 3% iodochlorhydroxyquin and 1% hydrocortisone in a water-washable base containing stearyl alcohol, cetyl alcohol, stearic acid, petrolatum, sodium lauryl sulfate, and glycerin in water; tubes of 5 and 20 Gm. *Ointment*, 3% iodochlorhydroxyquin and 1% hydrocortisone in a petrolatum base; tubes of 20 Gm. *Lotion*, 3% iodochlorhydroxyquin and 1% hydrocortisone in a water-washable base containing stearic acid, cetyl alcohol, lanolin, propylene glycol, sorbitan trioleate, polysorbate 60, triethanolamine, methylparaben, propylparaben, and perfume Flora in water; plastic squeeze bottles of 15 ml. *Mild Cream*, 3% iodochlorhydroxyquin and 0.5% hydrocortisone in a water-washable base containing stearyl alcohol, cetyl alcohol, stearic acid, petrolatum, sodium lauryl sulfate, and glycerin in water; tubes of ½ and 1 ounce. *Mild Ointment*, 3% iodochlorhydroxyquin and 0.5% hydrocortisone in a petrolatum base; tubes of 1 ounce.
C75-38 Rev. 7/75

Consult complete product literature before prescribing.

CIBA Pharmaceutical Company
Division of CIBA-GEIGY Corporation
Summit, New Jersey 07901

2/7853 17

Vioform®-Hydrocortisone
(iodochlorhydroxyquin and hydrocortisone)

The most widely prescribed form... 20-Gm Cream

CIBA

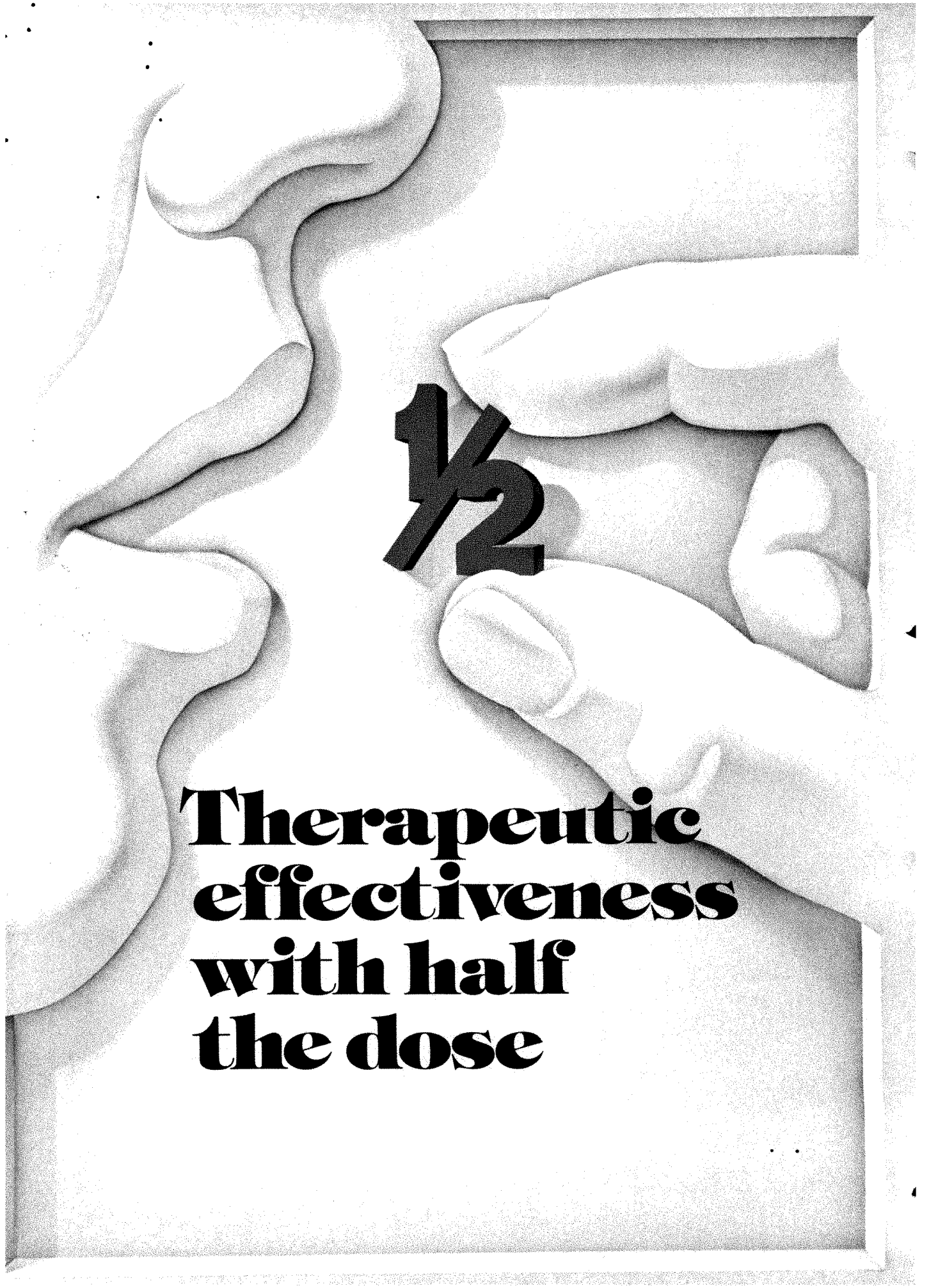
½
Therapeutic effectiveness with half the dose

Schering

Once-a-day dosage

NEW Fulvicin® P/G*

brand of griseofulvin [ultramicrosize], USP

(specially processed) **125 mg. tablets**

*"P/G" means a new polyethylene glycol system for enhanced absorption –

A 250 mg. daily dose (two 125 mg. tablets) of new FULVICIN P/G can replace 500 mg. of griseofulvin (microsize), USP. This is made possible by a special process in which the ultramicrosize griseofulvin crystals are partly dissolved in polyethylene glycol and dispersed through the tablet matrix for enhanced absorption.

Patient convenience –

FULVICIN P/G can be prescribed as two 125 mg. tablets once a day. Compliance is further assured by the easy-to-swallow size of the tablets.

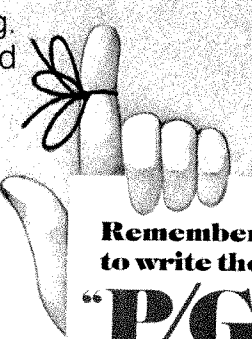

Remember to write the "P/G"

Patient savings –

FULVICIN P/G is up to 35 per cent less expensive per dose than all microsize griseofulvin formulations.**

**Based on list-price comparison.

See Clinical Considerations section on following page...

COPYRIGHT © 1977, SCHERING CORPORATION. ALL RIGHTS RESERVED. SLS-703

Schering

NEW P/G Fulvicin® P/G

griseofulvin [ultramicrosize], USP

(specially processed) **125 mg. tablets**

Clinical Considerations: INDICATIONS FULVICIN P/G Tablets are indicated for the treatment of ringworm infections of the skin, hair, and nails, namely: tinea corporis, tinea pedis, tinea cruris, tinea barbae, tinea capitis, tinea unguium (onychomycosis) when caused by one or more of the following genera of fungi: *Trichophyton rubrum, Trichophyton tonsurans, Trichophyton mentagrophytes, Trichophyton interdigitale, Trichophyton verrucosum, Trichophyton megnini, Trichophyton gallinae, Trichophyton crateriform, Trichophyton sulphureum, Trichophyton schoenleini, Microsporum audouini, Microsporum canis, Microsporum gypseum,* and *Epidermophyton floccosum*. Note: Prior to therapy, the type of fungi responsible for the infection should be identified. The use of this drug is not justified in minor or trivial infections which will respond to topical agents alone. Griseofulvin is not effective in the following: Bacterial infections, Candidiasis (Moniliasis), Histoplasmosis, Actinomycosis, Sporotrichosis, Chromoblastomycosis, Coccidioidomycosis, North American Blastomycosis, Cryptococcosis (Torulosis), Tinea versicolor, and Nocardiosis. **CONTRAINDICATIONS** This drug is contraindicated in patients with porphyria, hepatocellular failure, and in individuals with a history of hypersensitivity to griseofulvin. **WARNINGS** *Prophylactic Usage*: Safety and efficacy of griseofulvin for prophylaxis of fungal infections have not been established. *Animal Toxicology*: Chronic feeding of griseofulvin, at levels ranging from 0.5-2.5%, of the diet, resulted in the development of liver tumors in several strains of mice, particularly in males. Smaller particle sizes result in an enhanced effect. Lower oral dosage levels have not been tested. Subcutaneous administration of relatively small doses of griseofulvin once a week during the first three weeks of life has also been reported to induce hepatomata in mice. Although studies in other animal species have not yielded evidence of tumorogenicity, these studies were not of adequate design to form a basis for conclusions in this regard. In subacute toxicity studies, orally administered griseofulvin produced hepatocellular necrosis in mice, but this has not been seen in other species. Disturbances in porphyrin metabolism have been reported in griseofulvin-treated laboratory animals. Griseofulvin has been reported to have a colchicine-like effect on mitosis and cocarcinogenicity with methylcholanthrene in cutaneous tumor induction in laboratory animals. *Usage in Pregnancy*: The safety of this drug during pregnancy has not been established. *Animal Reproduction Studies*: It has been reported in the literature that griseofulvin was found to be embryotoxic and teratogenic on oral administration to pregnant rats. Pups with abnormalities have been reported in the litters of a few bitches treated with griseofulvin. Additional animal reproduction studies are in progress. Suppression of spermatogenesis has been reported to occur in rats, but investigation in man failed to confirm this. **PRECAUTIONS** Patients on prolonged therapy with any potent medication should be under close observation. Periodic monitoring of organ system function, including renal, hepatic, and hematopoietic, should be done. Since griseofulvin is derived from species of penicillin, the possibility of cross sensitivity with penicillin exists, however, known penicillin-sensitive patients have been treated without difficulty. Since a photosensitivity reaction is occasionally associated with griseofulvin therapy, patients should be warned to avoid exposure to intense natural or artificial sunlight. Should a photosensitivity reaction occur, lupus erythematosus may be aggravated. Griseofulvin decreases the activity of warfarin-type anticoagulants so that patients receiving these drugs concomitantly may require dosage adjustment of the anticoagulant during and after griseofulvin therapy. Barbiturates usually depress griseofulvin activity, and concomitant administration may require a dosage adjustment of the antifungal agent. **ADVERSE REACTIONS** When adverse reactions occur, they are most commonly of the hypersensitivity type, such as skin rashes, urticaria, and rarely, angioneurotic edema, and may necessitate withdrawal of therapy and appropriate countermeasures. Paresthesias of the hands and feet have been reported rarely after extended therapy. Other side effects reported occasionally are: oral thrush, nausea, vomiting, epigastric distress, diarrhea, headache, fatigue, dizziness, insomnia, mental confusion, and impairment of performance of routine activities. Proteinuria and leukopenia have been reported rarely. Administration of the drug should be discontinued if granulocytopenia occurs. When rare, serious reactions occur with griseofulvin, they are usually associated with high dosages, long periods of therapy, or both.

10705231 JANUARY 1977

For more complete details, consult package insert or Schering literature available from your Schering Representative or Professional Services Department, Schering Corporation, Kenilworth, New Jersey 07033.

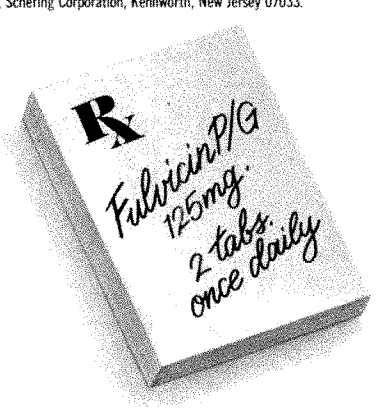

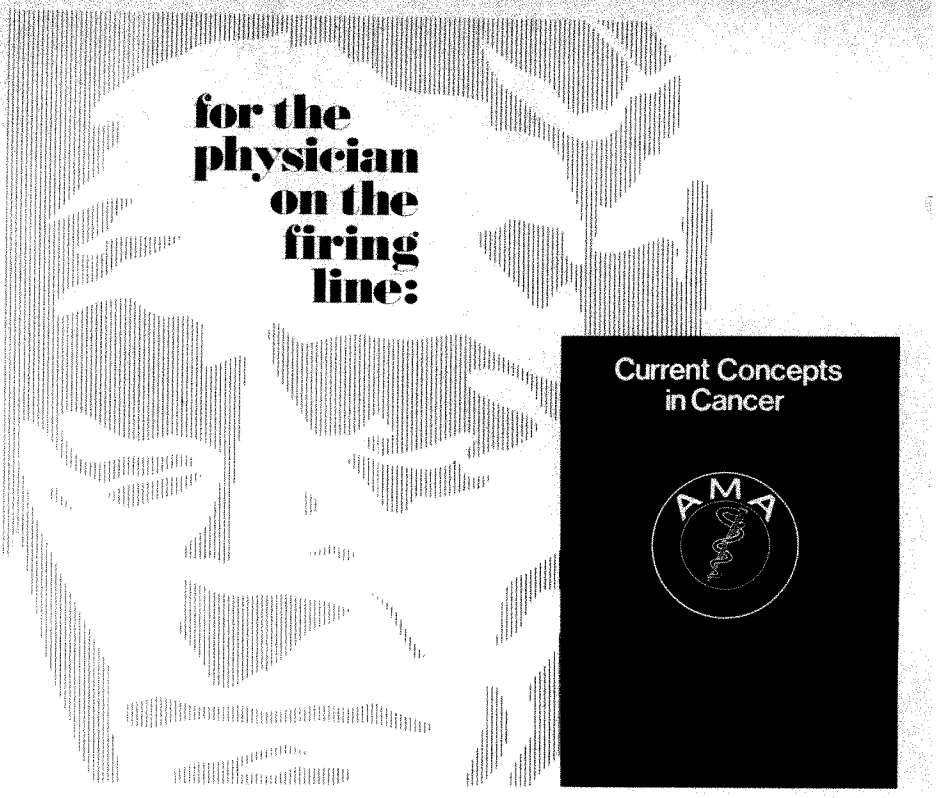

A valuable guide to diagnostic and therapeutic procedures for the cancer patient

Current Concepts in Cancer

While national attention focuses on cancer through specialized cancer centers, physicians are aware that the majority of cancer patients are treated in office practices. For most practicing physicians, cancer treatment is not a research objective, but a very practical problem in patient management.

Current Concepts in Cancer, a compilation of articles originally published in the *Journal of the American Medical Association,* is designed to be a guide for the practitioner in the choice of diagnostic and therapeutic procedures for many types of malignancies. It presents an objective interdisciplinary view by MDs outstanding in their respective fields, emphasizing principles of diagnosis and surgical, radiotherapeutic, and chemotherapeutic treatment.

Make this important resource a part of your reference file. Order your copy today.

American Medical Association S/J
535 North Dearborn Street
Chicago, Illinois 60610

Please send me _____ copy(ies) of **Current Concepts in Cancer** (OP-281). Price is $10 per copy. Please enclose your remittance with order.

Please Print

Name _____

Address _____

City _____ State _____ Zip _____

MINOCIN Minocycline HCl
Oral and Intravenous Brief Summary
Contraindications: Hypersensitivity to any tetracycline.
Warnings: Intravenous use, particularly in pregnancy, in daily doses exceeding 2 grams has been associated with deaths through liver failure. When need for intensive treatment outweighs potential dangers, perform renal and liver function tests before and during therapy, also follow serum concentrations. In renal impairment, usual doses may lead to excessive accumulation and liver toxicity. Under such conditions, use lower total doses, and, in prolonged therapy, determine serum levels. This hazard is of particular importance in I.V. use in pregnant or postpartum patients with pyelonephritis. In such cases, the blood cyclines during tooth development (last half of pregnancy, infancy and childhood to the age of 8 years) may cause permanent discoloration of the teeth (yellow-gray-brown). This is more common during long-term use but has been observed following repeated short-term courses. Enamel hypoplasia has also been reported. Tetracyclines, therefore, should not be used in this age group unless other drugs are not likely to be effective or are contraindicated. Photosensitivity manifested by an exaggerated sunburn reaction has been observed in some individuals taking tetracyclines. Advise patients apt to be exposed to direct sunlight or ultraviolet light that such reaction can occur, and discontinue treatment at first evidence of skin erythema. Studies to date indicate that photosensitivity is rarely reported with MINOCIN acidosis. CNS side effects (lightheadedness, dizziness, vertigo) have been reported, may disappear during therapy, and always disappear rapidly when drug is discontinued. Caution patients who experience these symptoms about driving vehicles or using hazardous machinery while taking this drug. **Pregnancy:** In animal studies, tetracyclines cross the placenta, are found in fetal tissues, and can have toxic effects on the developing fetus (often related to retardation of skeletal development). Embryotoxicity has been noted in animals treated early in pregnancy. **Newborns, infants and children:** All tetracyclines form a stable calcium complex in any bone-forming tissue. Prematures, given oral doses of 25 mg./kg. every 6 hours, demonstrated a decrease in fibula growth rate, reversible when drug was discontinued. Tetracy-

taph infection:
kin deeper

hen the patient is penicillin-
persensitive, when bacterio-
gic testing shows *Staph. aureus*
be resistant or the infection has
oved unresponsive, MINOCIN
***inocycline HCl* may be an effective**
ternative.* Clinical studies have
monstrated satisfactory response
156 of 173 simple or mixed
in and soft tissue
fections due
staphylococci.

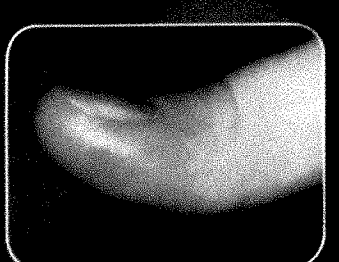

Actual patient photograph
after 7 days of MINOCIN.

MINOCIN®
MINOCYCLINE HCl

CAPSULES 50 mg and 100 mg
SYRUP 50 mg/5 cc
INTRAVENOUS 100 mg/vial

100 or 200 mg initially, 50 mg *q.i.d.*
or 200 mg initially, 100 mg *b.i.d.*

tracyclines are not the drugs of choice in the treatment
any type of staphylococcal infection. MINOCIN is indi-
ted for treatment of *Staphylococcus aureus* skin and soft
sue infections only when bacteriologic tests indicate
propriate susceptibility to the drug

OCIN Minocycline HCl
l and Intravenous Brief Summary (continued)
anisms, including fungi. If superinfection occurs, institute
ropriate therapy. In venereal diseases when coexistent syphi-
s suspected, darkfield examination should be done before
atment is started and blood serology repeated monthly for at
t four months. Patients on anticoagulant therapy may require
nward adjustment of such dosage. Test for organ system
function (e.g., renal, hepatic and hemopoietic) in long-term
Treat all group A beta-hemolytic streptococcal infections for
east 10 days. Avoid giving tetracycline in conjunction with
cillin.
erse Reactions: GI: (with both oral and parenteral use): anorex-
dermatitis (uncommon). Photosensitivity is discussed above
("Warnings"). **Renal toxicity:** rise in BUN, dose-related (see
"Warnings"). **Hypersensitivity reactions:** urticaria, angioneurotic
edema, anaphylaxis, anaphylactoid purpura, pericarditis, exacer-
bation of systemic lupus erythematosus. In young infants, bulging
fontanels have been reported following full therapeutic dosage;
disappearing rapidly when drug was discontinued. **Blood:** hemoly-
tic anemia, thrombocytopenia, neutropenia, eosinophilia. **CNS:**
(see "Warnings"). When given in high doses, tetracyclines may
produce brown-black microscopic discoloration of thyroid glands;
no abnormalities of thyroid function studies are known to occur.
NOTE: Concomitant therapy: Antacids containing aluminum, calci-
um, or magnesium impair absorption; do not give to patients
taking oral minocycline. Studies to date indicate that absorption

CNS side effects including light-headedness, dizziness, or vertigo have been reported with MINOCIN. Patients who experience these symptoms should be cautioned about driving vehicles or using hazardous machinery while on minocycline therapy.

LEDERLE LABORATORIES

wash it. dry it. peel it.

Fostex,® the flexible therapeutic acne wash that degreases, dries, and peels. Easily integrated with all topical or systemic therapy for acne Grades I, II, and III. Convenient and economical Fostex Liquid and Cream are also effective anti-seborrheic shampoos for oily scalps associated with acne. Available as Fostex Cream in 4½ oz. jars, Fostex Cake in 3¾ oz. bars, and Fostex Liquid in 5 oz. plastic bottles.

Fostril,® the flesh-tinted drying and peeling lotion that conceals as it heals. Adaptable to Grades I, II, or III acne, Fostril is available in 1 oz. plastic tubes.

Transact,® the transparent medicated acne gel. A thin film of Transact will dry the oiliest of skin and is ideal for acne on chest, shoulders, and back. Greaseless, nonstaining, with a fresh clean fragrance. In 1 oz. plastic tubes.

WESTWOOD
PHARMACEUTICALS INC.
Buffalo, New York 14213
In Canada, Belleville, Ontario K8N 1E2

An effective tool for superficial basal cell

2/6/70—Before treatment a 3.0 cm lesion was present behind left ear. Biopsy revealed it to be a superficial basal cell carcinoma. Treatment with Efudex (fluorouracil) 5% Cream was begun.

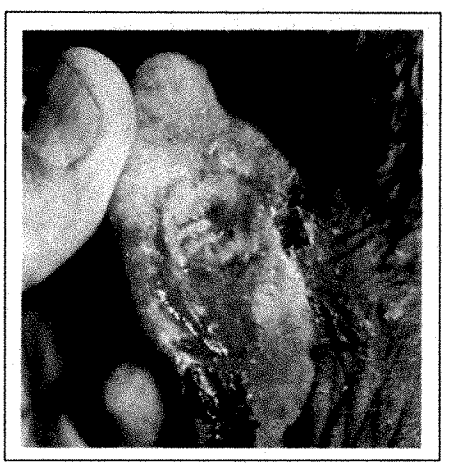

5/1/70—After 11 weeks' therapy, lesion site was necrotic and escharified; surrounding skin showed minimal inflammation. Treatment was terminated 4/24/70.

9/10/70—Area completely healed; posttreatment biopsy revealed no further carcinoma.

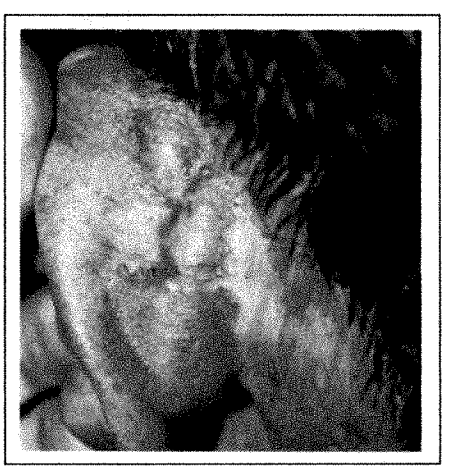

6/15/72—Patient 25 months posttreatment. No evidence of recurrence.

Management of superficial basal cell carcinoma is often complicated by multiple lesions which extend over large areas of the body. Until now, primary treatment has been surgery or radiation therapy. However, these modalities may be followed by scarring and disfigurement.

Topical chemotherapy with Efudex (fluorouracil) 5% is a valuable alternative when conventional methods are impractical. For example, it is an effective agent for the concurrent treatment of superficial lesions over large areas of the body, or for use on difficult treatment sites.

Although during treatment with Efudex the lesion and some of the surrounding skin may become inflamed and blistered temporarily, final results are cosmetically gratifying, with minimal or no scarring.

Efudex 5% Cream offers the dermatologist:

- An effective topical alternative to surgery for multiple lesions and difficult treatment sites.
- Cosmetically gratifying results, with minimal or no scarring. No systemic toxicity.
- Convenient, economical b.i.d. application. Apply with care near eyes, nose and mouth; wash hands immediately afterward if applied with fingers.

Efudex® 5% Cream
fluorouracil/Roche
An exclusive Roche formulation
Also available as 5% Efudex Solution

Before prescribing, please consult complete product information, a summary of which follows:

Indications: Multiple actinic or solar keratoses; superficial basal cell carcinomas when conventional methods are impractical (5% strength only).

Contraindications: If occlusive dressing is used, may increase inflammatory reactions in adjacent normal skin. Avoid prolonged exposure to ultraviolet rays. Safe use in pregnancy not established.

Precautions: If applied with fingers, wash hands immediately. Apply with care near eyes, nose and mouth. Solar keratoses failing to respond should be biopsied; perform follow-up biopsies in superficial basal cell carcinoma.

Adverse Reactions: Local—pain, pruritus, hyperpigmentation and burning at application site most frequent; also dermatitis, scarring, soreness, tenderness, suppuration, scaling and swelling. Also reported—insomnia, stomatitis, irritability, medicinal taste, photosensitivity, lacrimation, telangiectasia, leukocytosis, thrombocytopenia, toxic granulation and eosinophilia.

Dosage and Administration: *Actinic or solar keratosis*—apply sufficient quantity to cover lesions, twice daily. Usual length of therapy is 2 to 4 weeks. *Superficial basal cell carcinomas*—apply sufficient quantity (only 5% strength recommended) to cover lesions, twice daily. Continue treatment for at least 3 to 6 weeks, but possibly as long as 10 to 12.

How Supplied: Solution, 10-ml drop dispensers containing 2% or 5% fluorouracil on a weight/weight basis. Cream, 25-Gm tubes containing 5% fluorouracil in a vanishing cream base.

ROCHE

Roche Laboratories
Division of Hoffmann-La Roche Inc.
Nutley, New Jersey 07110

You don't have to ask your patients to sacrifice their skin to effectively treat their acne.



Use Persa-Gel.

A clinical test* shows Persa-Gel to be as effective as tretinoin cream in the lowering of the lesion count (pustules, papules and comedones), on unselected patients, **without** excessive erythema and peeling.

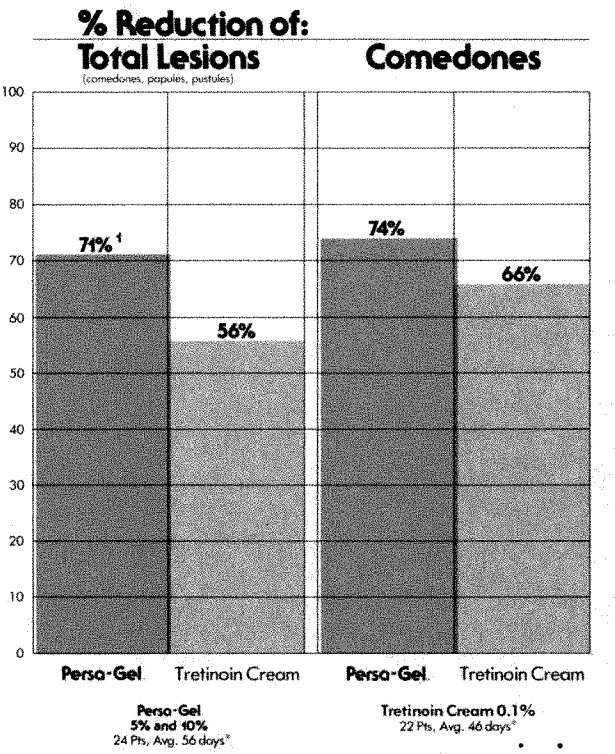

*Data on file, Texas Pharmacal Company.
See next page for full prescribing information.

Persa-Gel™
(BENZOYL PEROXIDE)

Unique Acetone Gel 5% and 10%

TPC
TEXAS PHARMACAL COMPANY
San Antonio, Texas 78296

Unique acetone base enhances stability and cosmetic acceptability.

Two and one-half year dating
No refrigeration required

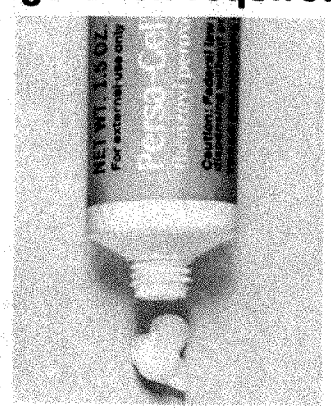

CAUTION: Federal law prohibits dispensing without prescription.
DESCRIPTION: Persa-Gel™ 5% contains 5% benzoyl peroxide; Persa-Gel™ 10% contains 10% benzoyl peroxide; in a gel base containing acetone, carboxyvinyl polymer, triethanolamine, sodium lauryl sulfate, propylene glycol and purified water.
ACTIONS: Benzoyl peroxide is primarily effective because of its drying, peeling and antiseptic action.
INDICATION: For adjunctive topical therapy of acne vulgaris.
CONTRAINDICATIONS: Benzoyl peroxide is contraindicated in patients with acute inflammation and in patients with a history of hypersensitivity to any of the components of the preparation.
PRECAUTIONS: If excessive irritation develops, discontinue use and institute appropriate therapy. After the reaction clears, treatment may often be resumed with less frequent applications. Avoid contact with eyes, eyelids, lips and other mucous membranes, and anterior neck. May bleach hair and colored fabrics.
ADVERSE REACTIONS: Allergic contact dermatitis and severe erythema with crusting have been reported with topical benzoyl peroxide.
DOSAGE AND ADMINISTRATION: Persa-Gel™ (benzoyl peroxide) should be applied thinly to cover affected area after cleansing with non-medicated soap and water or a degreaser. Initial application once daily before bedtime is recommended, increasing to twice daily as tolerance develops. Feelings of warmth and stinging and slight erythema may be noted initially. It is advisable to initiate therapy with Persa-Gel™ 5% shifting to the use of Persa-Gel™ 10% after 3 or 4 weeks, or earlier if tolerance to the 5% has been determined. Therapeutic results are usually seen within 2 weeks with continued improvement therafter.
HOW SUPPLIED: Persa-Gel™ 5% 1.5 oz. tubes
(NDC0064-8610-31)
Persa-Gel™ 10% 1.5 oz. tubes
(NDC0064-8600-31)

Persa-Gel™
(BENZOYL PEROXIDE)
Unique Acetone Gel 5% and 10%

TPC
TEXAS PHARMACAL COMPANY
San Antonio, Texas 78296

LENOX HILL HOSPITAL
Announces a Symposium on

TUMORS OF THE EYELIDS, ORBIT AND OCULAR ADNEXAE

October 27, 28, 29, 1977

This Symposium will be devoted to the diagnosis, pathogenesis and treatment of tumors of the eyelids and orbit, emphasizing basal cell carcinoma of the eyelids. The course will be presented by outstanding ophthalmologists, ophthalmic plastic surgeons, plastic surgeons, x-ray therapists, dermatologists, immunotherapists, cryosurgeons and pathologists.

The format will consist of lectures, panel discussions, surgical films and videotapes of surgery.

THE FACULTY WILL INCLUDE:
Albert Hornblass, M.D., Course Director
Edgar Berry, M.D.
Charles Beyer, M.D.
Jackson Coleman, M.D.
Anthony Domonkis, M.D.
Andrew Ferry, M.D.
Paul Henkind, M.D.
Crowell Beard, M.D.
Henry Gougelman, M.D.
Lazlo Bird, M.D.
Morris Leider, M.D.
David Soll, M.D.
Byron Smith, M.D.
Perry Robins, M.D.
Michael Tenner, M.D.
Seamus Lynch, M.D.
Stephen Trokel, M.D.
and others

TUITION:

Practitioners	$200.00
Residents	$75.00

FOR FURTHER INFORMATION WRITE TO:
Department of Ophthalmology
Lenox Hill Hospital
100 East 77th Street
New York, New York 10021

This activity is acceptable for 21 credit hours in Category I

Sojourn in the Ozarks for sports, scenery and CME

AMA's Regional CME Tan-Tar-A Golf and Tennis Resort Osage Beach, Missouri Sept. 16-18, 1977

Write:
Dept. of Meeting Services
American Medical Association
535 N. Dearborn St.
Chicago, Ill. 60610

HOECHST-ROUSSEL PHARMACEUTICALS INCORPORATED

Announces a New topical fluorinated corticosteroid in a Unique Emollient Cream Base

NEW TOPICORT®
(DESOXIMETASONE)

THE SPECIALLY DEVELOPED, PRESERVATIVE-FREE BASE COMBINES THE EMOLLIENCE OF AN OINTMENT WITH THE COSMETIC ACCEPTABILITY OF A CREAM IN A WATER-IN-OIL EMULSION.

Well-documented efficacy and safety: Anti-inflammatory, antipruritic, vasoconstrictive Topicort (desoximetasone) has been demonstrated safe and effective in relieving the inflammatory manifestations of corticosteroid-responsive dermatoses.

Worldwide clinical experience: For up to 4 years, Topicort (desoximetasone) has been marketed by Hoechst in over 30 foreign countries. Extensive clinical trials in the United States, conducted by 23 investigators under a wide variety of climatic conditions, confirm the many years of worldwide experience.

A wide range of conditions in corticosteroid-responsive dermatoses: Topicort (desoximetasone) is useful on wet as well as dry lesions, in both acute and chronic cases, with a profile of adverse reactions similar to that seen with other topical corticosteroids.

Emollient Cream 0.25%

Available: 15-gram tubes.
In corticosteroid-responsive dermatoses
Convenient B.I.D. dosage.

Please consult full prescribing information on following page.

071083-677

TOPICORT®(desoximetasone) EMOLLIENT CREAM 0.25%

Description: Topicort® (desoximetasone) Emollient Cream 0.25% contains the active synthetic corticosteroid desoximetasone. The chemical name of desoximetasone is 9α - fluoro - 11β, 21 - dihydroxy - 16α - methylpregna - 1,4 - diene-3,20-dione. The chemical structure is:

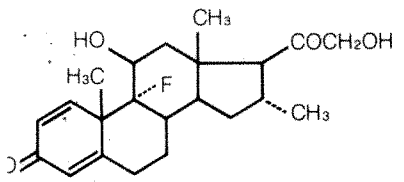

Each gram of Topicort® (desoximetasone) Emollient Cream 0.25% contains 2.5 mg desoximetasone in an emollient cream consisting of isopropyl myristate, cetylstearyl alcohol, white petrolatum, mineral oil, lanolin alcohol and purified water.

Actions: Topicort® (desoximetasone) Emollient Cream is primarily effective because of its anti-inflammatory, antipruritic and vasoconstrictive actions.

Indications: Topicort® (desoximetasone) Emollient Cream is indicated for the relief of inflammatory manifestations of corticosteroid-responsive dermatoses.

Contraindications: Topical steroids are contraindicated in vaccinia, varicella and in those patients with a history of hypersensitivity to any of the components of the preparation. This preparation is not for ophthalmic use.

Precautions: If local infection exists, suitable concomitant antimicrobial or antifungal therapy should be administered. If a favorable response does not occur promptly, application of the corticosteroid should be discontinued until the infection is adequately controlled.

Although systemic side effects associated with absorption of topical corticosteroid preparations are rare, their possible occurrence must be kept in mind when these preparations are used over large areas or for an extended period of time, or if occlusive technique is used.

If irritation or sensitization develops, the preparation should be discontinued and appropriate therapy instituted.

Although topical steroids have not been reported to have an adverse effect on pregnancy, the safety of their use during pregnancy has not been absolutely established; therefore, they should not be used extensively on pregnant patients, in large amounts, or for prolonged periods of time.

Adverse Reactions: The following local adverse reactions have been reported with topical corticosteroids: burning, itching, irritation, striae, skin atrophy, secondary infection, dryness, folliculitis, hypertrichosis, acneform eruptions and hypopigmentation. The following may occur more frequently with occlusive dressings: maceration of the skin, secondary infection, skin atrophy, striae, and miliaria.

Dosage and Administration: Apply a thin film of Topicort® (desoximetasone) Emollient Cream 0.25% to the affected skin areas twice daily. Rub in gently.

How Supplied: Topicort® (desoximetasone) Emollient Cream 0.25% is supplied in 15-gram tubes.

HOECHST-ROUSSEL
PHARMACEUTICALS INCORPORATED
SOMERVILLE, NEW JERSEY 08876

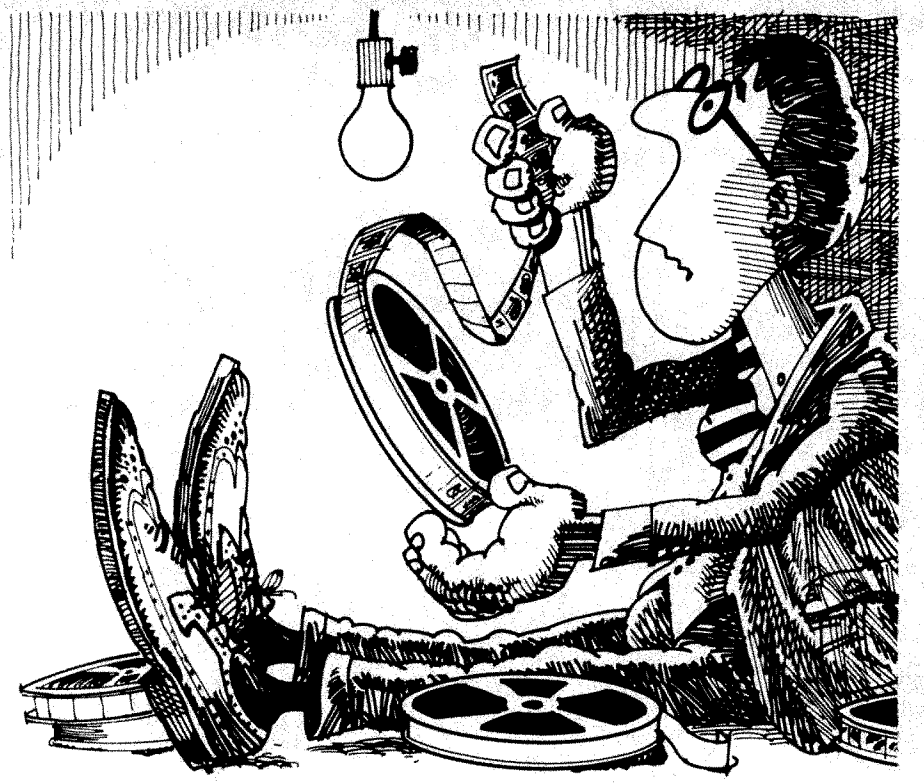

a quick reference to the AMA's large collection of medical films

and its yours free with the coupon below

You'll find nearly 100 pages of medical motion picture titles and descriptions in this new catalog—well over 300 titles and many of them brand new! All are available on loan basis for a slight service charge.

Reserve your copy today—supply is limited.

S/J



American Medical Association
535 N. Dearborn St.
Chicago, Ill. 60610
ATTN: Dept. of Audio Visual
Self Learning Programs.

Please send me your catalog:
AMA Medical Health Film Library 1976 when it's ready.

Name _____

Title _____

Organization _____

Address _____

City _____

State/Zip _____

When Griseofulvin is indicated...

TINEA PEDIS*

TINEA UNGUIUM*



TINEA CRURIS*

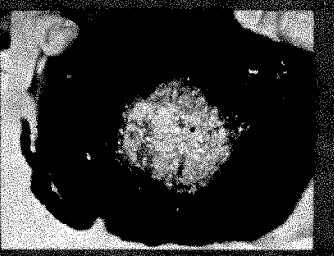

TINEA CAPITIS*

*Also *Tinea barbae* and *Tinea corporis* when caused by fungi from genera known to be sensitive to griseofulvin.

Gris-PEG®
(griseofulvin ultramicrosize) Tablets 125 mg
offers effective therapy with 1/2 the dose.†

- Can be taken on an empty stomach
- Absorption nearly complete without fatty meals
- Reduced cost for patients
- Once-a-day or b.i.d. dosage

†250 mg of Gris-PEG® provides plasma levels equivalent to those obtained with 500 mg microsize griseofulvin. This improved absorption permits the oral intake of half as much griseofulvin but there is no evidence, at this time, that this confers any significant clinical difference in regard to safety or efficacy.



Dorsey LABORATORIES
Division of Sandoz, Inc.
LINCOLN, NEBRASKA 68501

Gris-PEG®
(griseofulvin ultramicrosize) Tablets 125 mg
The ½ dose griseofulvin.

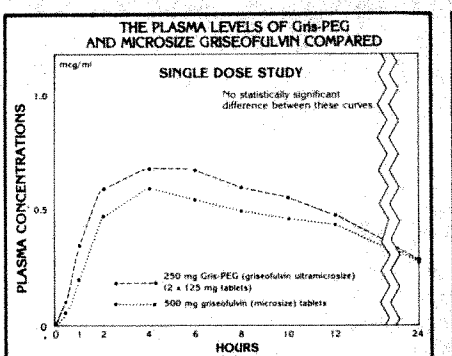

Based on a single dose double-blind bioavailability study conducted in 24 human volunteers comparing the average griseofulvin (microsize) and Gris-PEG plasma levels. There is no significant difference between peak plasma levels, times to peak, and areas under the curve. Gas chromatographic assay.

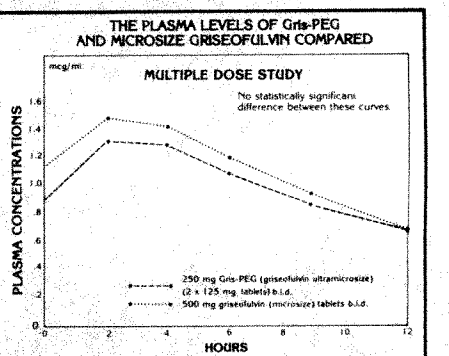

Based on a double-blind multiple dose steady state crossover bioavailability study conducted in 17 human volunteers comparing the average griseofulvin (microsize) and Gris-PEG plasma levels obtained on days 9, 11 and 13. There is no significant difference between times to peak, peak plasma levels, and areas under the curve. Gas chromatographic assay.

DESCRIPTION

Griseofulvin is an antibiotic derived from a species of *Penicillium*.

Gris-PEG is an ultramicrocrystalline solid-state dispersion of griseofulvin in polyethylene glycol 6000.

Gris-PEG Tablets differ from griseofulvin (microsize) tablets USP in that each tablet contains 125 mg of ultramicrosize griseofulvin biologically equivalent to 250 mg of microsize griseofulvin.

ACTION

Microbiology: Griseofulvin is fungistatic with *in vitro* activity against various species of *Microsporum*, *Epidermophyton* and *Trichophyton*. It has no effect on bacteria or other genera of fungi.

Human Pharmacology: The peak plasma level found in fasting adults given 0.25 g of Gris-PEG occurs at about four hours and ranges between 0.37 to 1.6 mcg/ml.

Comparable studies with microsize griseofulvin indicated that the peak plasma level found in fasting adults given 0.5 g occurs at about four hours and ranges between 0.44 to 1.2 mcg/ml.

Thus, the efficiency of gastrointestinal absorption of the ultramicrocrystalline formulation of Gris-PEG is approximately twice that of conventional microsized griseofulvin. This factor permits the oral intake of half as much griseofulvin per tablet but there is no evidence, at this time, that this confers any significant clinical differences in regard to safety and efficacy.

Griseofulvin is deposited in the keratin precursor cells and has a greater affinity for diseased tissue. The drug is tightly bound to the new keratin which becomes highly resistant to fungal invasions.

INDICATIONS

Gris-PEG (griseofulvin ultramicrosize) is indicated for the treatment of the following ringworm infections:

Tinea corporis (ringworm of the body)
Tinea pedis (athlete's foot)
Tinea cruris (ringworm of the thigh)
Tinea barbae (barber's itch)
Tinea capitis (ringworm of the scalp)
Tinea unguium (onychomycosis, ringworm of the nails)

when caused by one or more of the following genera of fungi:

Trichophyton rubrum
Trichophyton tonsurans
Trichophyton mentagrophytes
Trichophyton interdigitalis
Trichophyton verrucosum
Trichophyton megnini
Trichophyton gallinae
Trichophyton crateriform
Trichophyton sulphureum
Trichophyton schoenleini
Microsporum audouini
Microsporum canis
Microsporum gypseum
Epidermophyton floccosum

NOTE: Prior to therapy, the type of fungi responsible for the infection should be identified.

The use of the drug is not justified in minor or trivial infections which will respond to topical agents alone.

Griseofulvin is *NOT* effective in the following:

Bacterial infections
Candidiasis (Moniliasis)
Histoplasmosis
Actinomycosis
Sporotrichosis
Chromoblastomycosis
Coccidioidomycosis
North American Blastomycosis
Cryptococcosis (Torulosis)
Tinea versicolor
Nocardiosis

CONTRAINDICATIONS

This drug is contraindicated in patients with porphyria, hepatocellular failure, and in individuals with a history of sensitivity to griseofulvin.

WARNINGS

Prophylactic Usage: Safety and Efficacy of Griseofulvin for Prophylaxis of Fungal Infections Has Not Been Established.

Animal Toxicology: Chronic feeding of griseofulvin, at levels ranging from 0.5 to 2.5% of the diet, resulted in the development of liver tumors in several strains of mice, particularly in males. Smaller particle sizes result in an enhanced effect. Lower oral dosage levels have not been tested. Subcutaneous administration of relatively small doses of griseofulvin, once a week, during the first three weeks of life has also been reported to induce hepatomata in mice. Although studies in other animal species have not yielded evidence of tumorigenicity, these studies were not of adequate design to form a basis for conclusions in this regard.

In subacute toxicity studies, orally administered griseofulvin produced hepatocellular necrosis in mice, but this has not been seen in other species. Disturbances in porphyrin metabolism have been reported in griseofulvin treated laboratory animals. Griseofulvin has been reported to have a colchicine-like effect on mitosis and cocarcinogenicity with methylcholanthrene in cutaneous tumor induction in laboratory animals.

Usage in Pregnancy: The safety of this drug during pregnancy has not been established.

Animal Reproduction Studies: It has been reported in the literature that griseofulvin was found to be embryotoxic and teratogenic on oral administration to pregnant rats. Pups with abnormalities have been reported in the litters of a few bitches treated with griseofulvin. Additional animal reproduction studies are in progress. Suppression of spermatogenesis has been reported to occur in rats, but investigation in man failed to confirm this.

PRECAUTIONS

Patients on prolonged therapy with any potent medication should be under close observation. Periodic monitoring of organ system function, including renal, hepatic and hematopoietic, should be done.

Since griseofulvin is derived from species of *Penicillium* the possibility of cross sensitivity with penicillin exists; however, known penicillin-sensitive patients have been treated without difficulty.

Since a photosensitivity reaction is occasionally associated with griseofulvin therapy, patients should be warned to avoid exposure to intense natural or artificial sunlight. Should a photosensitivity reaction occur, lupus erythematosus may be aggravated.

Griseofulvin decreases the activity of warfarin-type anticoagulants so that patients receiving these drugs concomitantly may require dosage adjustment of the anticoagulant during and after griseofulvin therapy.

Barbiturates usually depress griseofulvin activity and concomitant administration may require a dosage adjustment of the antifungal agent.

ADVERSE REACTIONS

When adverse reactions occur, they are most commonly of the hypersensitivity type such as skin rashes, urticaria, and rarely, angioneurotic edema, and may necessitate withdrawal of therapy and appropriate countermeasures. Paresthesias of the hands and feet have been reported rarely after extended therapy. Other side effects reported occasionally are oral thrush, nausea, vomiting, epigastric distress, diarrhea, headache, fatigue, dizziness, insomnia, mental confusion, and impairment of performance of routine activities.

Proteinuria and leukopenia have been reported rarely. Administration of the drug should be discontinued if granulocytopenia occurs.

When rare, serious reactions occur with griseofulvin, they are usually associated with high dosages, long periods of therapy, or both.

DOSAGE AND ADMINISTRATION

Accurate diagnosis of the infecting organism is essential. Identification should be made either by direct microscopic examination of a mounting of infected tissue in a solution of potassium hydroxide or by a culture on an appropriate medium.

Medication must be continued until the infecting organism is completely eradicated as indicated by appropriate clinical or laboratory examination. Representative treatment periods are—*tinea capitis*, 4 to 6 weeks; *tinea corporis*, 2 to 4 weeks; *tinea pedis*, 4 to 8 weeks; *tinea unguium*—depending on rate of growth—fingernails, at least 4 months; toenails, at least 6 months.

General measures in regard to hygiene should be observed to control sources of infection or reinfection. Concomitant use of appropriate topical agents is usually required particularly in treatment of *tinea pedis*. In some forms of athlete's foot, yeasts and bacteria may be involved as well as fungi. Griseofulvin will not eradicate the bacterial or monilial infection.

An oral dose of 250 mg of Gris-PEG (griseofulvin ultramicrosize) is biologically equivalent to 500 mg of griseofulvin (microsized) USP (see ACTION Human Pharmacology).

Adults: A daily dose of 250 mg will give a satisfactory response in most patients with *tinea corporis*, *tinea cruris* and *tinea capitis*. One 125 mg tablet twice per day or two 125 mg tablets once per day is the usual dosage. For those fungal infections more difficult to eradicate such as *tinea pedis* and *tinea unguium*, a divided daily dose of 500 mg is recommended. In all cases, the dosage should be individualized.

Children: Approximately 5 mg per kilogram (2.5 mg per pound) of body weight per day is an effective dose for most children. On this basis the following dosage schedule for children is suggested: Children weighing over 25 kilograms (approximately 50 pounds) 125 mg to 250 mg daily; children weighing 15-25 kilograms (approximately 30 to 50 pounds) 62.5 mg to 125 mg daily; children 2 years of age and younger, dosage has not been established.

Dosage should be individualized, as is done for adults. Clinical experience with griseofulvin in children with *tinea capitis* indicates that a single daily dose is effective. Clinical relapse will occur if the medication is not continued until the infecting organism is eradicated.

HOW SUPPLIED

Gris-PEG (griseofulvin ultramicrosize) Tablets (white) differ from griseofulvin microsized tablets (USP) in that each tablet contains 125 mg of ultramicrosize griseofulvin, biologically equivalent to 250 mg of microsized griseofulvin. Two 125 mg tablets of Gris-PEG are biologically equivalent to 500 mg of microsized griseofulvin. In bottles of 100 and 500 scored, film-coated tablets.

Dorsey LABORATORIES
Division of Sandoz, Inc. • LINCOLN, NEBRASKA 68501



Bee-sting Allergy

Phadebas RAST® provides an accurate means of documenting IgE mediated allergic sensitivity to stinging insects.

Phadebas RAST®

the *in vitro* alternative

Pharmacia Diagnostics AB
Uppsala, Sweden

Pharmacia Diagnostics

Argentina Laboratorios Dr. Gador y Cía., S.A.C.I. Casilla de Correo 4041 BUENOS AIRES. **Australia** Pharmacia (South Seas) Pty. Ltd. P.O. Box 175 Cnr Talavera&Khartoum Roads NORTH RYDE N.S.W. 2113 **Austria** Pharmacia Gesellschaft m.b.H. Rathausplatz 4 A-1010 WIEN. Schoeller-Pharma G.m.b.H. Postfach 103 A-1111 WIEN. **Belgium** S.A. Pharmacia Belga N.V. Bld. Gen. Jacqueslaan 26 B-1050 BRUSSELS. **Brazil** Emprêsa Medimex Importação e Comércio Ltda. Rua Cardoso Marinho, 40 Caixa Postal 33-ZC-00 RIO DE JANEIRO. **Canada** Pharmacia (Canada) Ltd. 2044 boul. St. Régis Blvd. DOVAL, Québec H9P 1H6. **Denmark** Pharmacia AS, Herredsvejen DK-3400 HILLERØD. **Finland** Pharmacia OY Alexandersgatan 48 A SF-HELSINGFORS 10. **France** Pharmacia France S.A. Rue de Marly Parly 2 F-78150 LE CHESNAY. **German Federal Republic** Deutsche Pharmacia GmbH Munziner Strasse 9 Postfach 5480 D-7800 FREIBURG 1. **Great Britain** Pharmacia (G.B.) Ltd. Paramount House 75 Uxbridge Road LONDON W5 5SS. **Greece** G.A. Kambanis Imports-Exports-Representations 3 Iridanou Street ATHENS 612. **Italy** Importex Chimici Farmaceutici S.p.A. P.O. Box 467 Via Flavia 122/124 I-34100 TRIESTE. **Mexico** Internacional Cientifica, S.A. Apartado 66-558 Zona 12 MEXICO 8 D.F. **The Netherlands** Gist-Brocades N.V. Diagnostics Dept. P.O. Box 324 Frijdastraat 7–9 RIJSWIJK (Z H) 2109. **Norway** Norsk Pharmacia A/S Postboks 2005 Grünerløkka OSLO 5. **Portugal** J.A. Baptista D'Almeida Lda. Apartado 1339 LISBOA 1. **South Africa** Keatings Medical Industries (Pty) Ltd. P.O. Box 256 JOHANNESBURG 2000 R.S.A. **Spain** Atom Paseo del Monte 34 BARCELONA 12. **Sweden** Pharmacia Norden AB Diagnostic Dept. Box 159 751 04 UPPSALA 1. **Switzerland** Pharmacia-pdf-(Schweiz) A.G. 214 Seefeldstrasse CH-8034 ZUERICH. **USA** Pharmacia Diagnostics Division of Pharmacia Inc. 800 Centennial Avenue PISCATAWAY, New Jersey 08854. **Other countries** Pharmacia Diagnostics AB Box 17 S-751 03 UPPSALA 1, Sweden.

For Skin Without Water

Neutrogena® Dry Skin products are specially formulated to supplement surface fats and aid in the retention of moisture.

- Neutrogena® Dry-Skin Soap contains humectants, lubricants, and emollients to soften and moisturize, and is nonirritating to sensitive skin.
- Neutrogena® Rainbath® Dry Skin Bath Gel is lipid-free, cleanses with a rich lather without the drying effect of ordinary soap, and leaves skin soft and smooth. Available both scented and unscented.
- Neutrogena® Hand Cream is a heavy-duty formula containing a special blend of naturally occurring oils and glycerin, and is a useful adjunct in steroid-responsive hand dermatoses.[1]

1. Data on file, Medical Dept., Neutrogena Corp.

Neutrogena®
Dedicated to Sensitive Skin Care

Neutrogena Corp.
5755 West 96th Street
Los Angeles, California 90045

---

for the part-time occupational physician...

an invaluable quick reference guide to occupational dermatoses

The AMA's new guide, *Occupational Dermatoses*, is an invaluable aid for physicians working part-time in occupational health programs.

It provides a ready reference for specific information on the causes, diagnosis, prevention, and treatment of occupational skin diseases. It also discusses management of prolonged and recurrent dermatoses, medico-legal aspects, and provides extensive references.

To order your copy ($1 ea.) of *Occupational Dermatoses, OP-108,* write: Order Dept., American Medical Association, 535 N. Dearborn St., Chicago, Ill. 60610.



For Skin Plagued by Acne



Neutrogena® Acne products aid in drying while they clean and degrease acne-plagued skin.

- Neutrogena® Acne-Cleansing Soap gently cleanses and degreases the skin, and does not interfere with topical or systemic acne treatment.
- Neutrogena® Acne-Drying Gel combines antisepsis with astringency, contains 47% active drying agents, is perfume-free, can be applied under or over makeup, and is imperceptible on the skin.

Neutrogena®
Dedicated to Sensitive Skin Care

Neutrogena Corp.
5755 West 96th Street
Los Angeles, California 90045

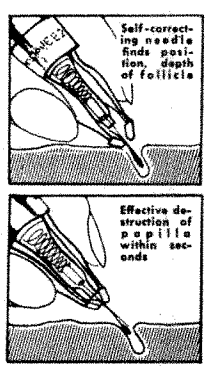

Perma Tweez®

ELECTROLYSIS FOR PERMANENT HAIR REMOVAL

Clinical study (copy on request) proves safety and efficacy of laity self-use electrolysis. Study shows chin and even axilla can be self-treated effectively through use of mirror. This permanent hair remover features the only patented self-correcting needle in existence. Battery operated instrument sterilizes itself when current flows. No-puncture safety feature also helps prevent infection.

Thousands of units sold to physicians for such varied application as removal of inverted eyelashes to cosmetic use.

PERMA TWEEZ & ATTACHMENT **$22.45**

☐ Invoice after 30 days

☐ Check enclosed

30 DAY FREE TRIAL EXAMINATION

(MAY BE RETURNED WITH NO OBLIGATION)

GENERAL MEDICAL CO., Dept. D-88
1935 Armacost Ave
West Los Angeles, CA 90025

DR _____
STREET _____
C/S _____ ZIP _____

They're in... the 75-76 red and blue books

Profile of Medical Practice
Socioeconomic Issues of Health!

Invaluable for anyone needing a quick, authoritative reference to relevant data on the U.S. health care delivery system, these unique publications are compiled annually by the AMA Center for Health Services Research & Development.

The Red book, PROFILE OF MEDICAL PRACTICE, presents data from the AMA Physician Masterfile and the Periodic Survey of Physicians describing characteristics of medical practice such as utilization of physicians' services; physicians' net income, expenses, fees; and other selected practice characteristics. It also includes essays on issues affecting the practice of medicine.

The Blue book, SOCIOECONOMIC ISSUES OF HEALTH, includes data on characteristics of the U.S. population; the health care delivery system; medical education and licensure. Also included are essays on relevant health issues of general interest.

Quantities are limited so order yours today!

Order Dept., AMA, 535 N. Dearborn St., Chicago, Ill. 60610

Please send me the publications below in the quantities indicated. My check for $_____ , made payable to the AMA, is enclosed. (Previous editions of the Red and Blue Books available upon request.)

_____ PROFILE OF MEDICAL PRACTICE, OP-463, $4.50 ea.

_____ SOCIOECONOMIC ISSUES OF HEALTH, OP-462, $4.50 ea.

_____ set(s) $8.50 ea. S/J

Name _____

Address _____

City _____

State _____ Zip _____

HALOG® CREAM (Halcinonide Cream 0.1%)

Each gram of Halog Cream (Halcinonide Cream 0.1%) contains 1 mg. halcinonide (0.1%) in a cream base.

INDICATIONS: This product is intended for topical application for adjunctive therapy and symptomatic relief of inflammatory manifestations of acute and chronic corticosteroid responsive dermatoses.

CONTRAINDICATIONS: Topical steroids are contraindicated in vaccinia, varicella, and in those patients with a history of hypersensitivity to any of the components of the preparation. This preparation is not for ophthalmic use.

PRECAUTIONS: *General*—If local infection exists, suitable concomitant antimicrobial or antifungal therapy should be administered. If a favorable response does not occur promptly, application of the corticosteroid should be discontinued until the infection is adequately controlled. Although systemic side effects associated with absorption of topical corticosteroid preparations are rare, their possible occurrence must be kept in mind when these preparations are used over large areas or for an extended period of time. If irritation or sensitization develops, the preparation should be discontinued and appropriate therapy instituted. Although topical steroids have not been reported to have an adverse effect on pregnancy, the safety of their use during pregnancy has not been absolutely established; therefore, they should not be used extensively on pregnant patients, in large amounts, or for prolonged periods of time.

Occlusive Dressing Technique—The use of occlusive dressing increases the percutaneous absorption of corticosteroids; their extensive use increases the possibility of systemic effects. For patients with extensive lesions it may be preferable to use a sequential approach, occluding one portion of the body at a time. The patient should be kept under close observation if treated with the occlusive technique over large areas and over a considerable period of time. Occasionally, a patient who has been on prolonged therapy, especially occlusive therapy, may develop symptoms of steroid withdrawal when the medication is stopped. Thermal homeostasis may be impaired if large areas of the body are covered. Use of the occlusive dressing should be discontinued if elevation of the body temperature occurs. Occasionally, a patient may develop a sensitivity reaction to a particular occlusive dressing material or adhesive and a substitute material may be necessary. If infection develops, discontinue the use of the occlusive dressing and institute appropriate antimicrobial therapy.

ADVERSE REACTIONS: The following local adverse reactions have been reported with topical corticosteroids: burning, itching, irritation, striae, skin atrophy, secondary infection, dryness, folliculitis, hypertrichosis, acneform eruptions, and hypopigmentation. The following may occur more frequently with occlusive dressings: maceration of the skin, secondary infection, skin atrophy, striae, and miliaria. Contact sensitivity to a particular dressing material or adhesive may occur occasionally (see PRECAUTIONS).

For full prescribing information, consult package insert.

HOW SUPPLIED: In tubes of 15 and 60 g. and in jars of 240 g. (8 oz.).

SQUIBB® The Priceless Ingredient of every product is the honor and integrity of its maker.™

© 1977 E.R. Squibb & Sons, Inc. 357-503

Pruritus relieved "within 24 hours"

Eczematoid Dermatitis

Condition of six months' duration. Patient complaining of acute itching and soreness of finger. Examination revealed erythematous, eroded, fissured, scaling and crusted dermatitis. KOH test negative for fungal hyphae; no other skin involvement or history of skin problems.

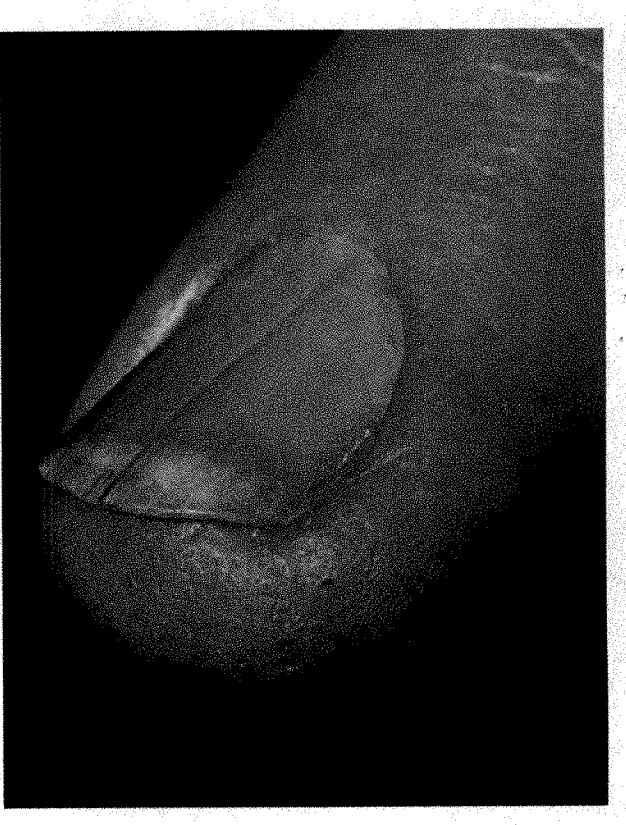

After 1 week

Halog 0.1% Cream applied twice daily. Patient reported pruritus relieved within 24 hours after first application of cream. Examination showed essentially complete resolution of dermatitis. Halog Cream discontinued and patient discharged.

Case history on file at Squibb Institute for Medical Research.

after Halog® Cream b.i.d

Halcinonide Cream 0.1%

See adjacent **SQUIBB®** column for brief summary.

Pernox® Can Improve an Acne Lesion in Two Days

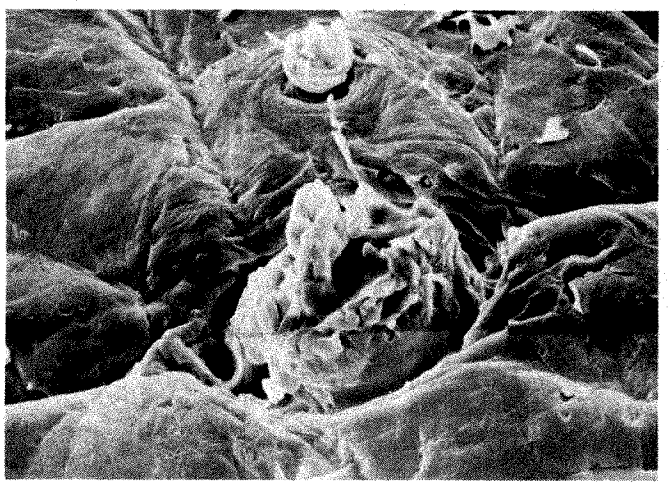

BEFORE TREATMENT: Comedo plugged with keratinous debris. (Scanning electron microscopy courtesy of Structure Probe Inc.)

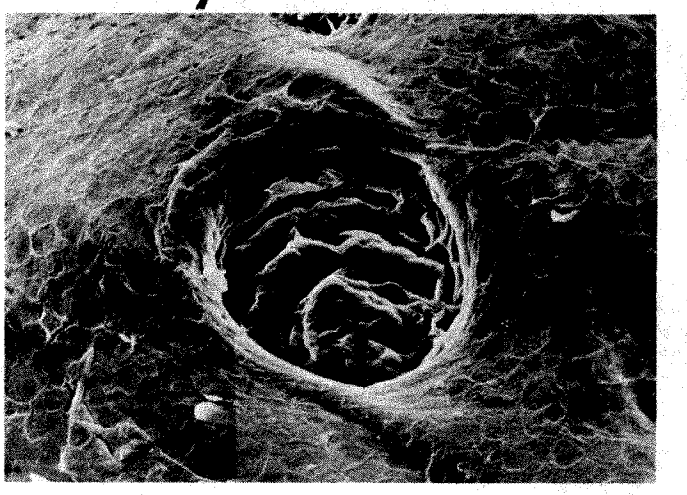

AFTER 2 DAYS (Two one-minute Pernox® Scrub washes daily): Depth of orifice indicates removal of plug in large central comedo.

When we formulated Pernox® Scrub, we had a goal in mind. Make it abradant . . . a harsh word, yet make it smooth for acne skin. Pernox accomplishes just that.

Washing varies from patient to patient. You determine the regimen by frequency of washing and the amount of water used during the wash.

Patients respond to Pernox rapidly, often noticing improvement after the first wash. The unique combination of ingredients in Pernox emulsifies oil and dries affected areas, contributing to this success.

Two pleasant forms, regular and lemon-scented scrub and lemon-scented lotion offer you a choice for your patients' therapy.

Pernox . . . an acne regimen formulated to give you more than you're now getting from your present acne scrub.

PERNOX®

Scrub/Lotion

Lathering Scrub Cleanser for Acne

Pernox Scrub, Regular and Lemon-Scented in 2 and 4 oz. plastic tubes.

New Lemon-Scented Pernox Lotion in 6 oz. bottles.

The Abradant of Choice

WESTWOOD
PHARMACEUTICALS INC.
Buffalo, New York 14213

©1977, W.P. Inc.

Bullous Pemphigoid

Clinical and Immunologic Follow-up After Successful Therapy

A. Razzaque Ahmed, MD; John C. Maize, MD; Thomas T. Provost, MD

• Thirty-six patients with bullous pemphigoid (BP) have been periodically evaluated for four years. This study demonstrates that BP may occur in a transient predominantly localized form that remits spontaneously, and most BP patients after successful therapy remain in prolonged clinical remission. In this study, all patients with active or recurrent disease had IgG and/or C3 basement membrane zone (BMZ) deposition. Serum anti-BMZ antibodies was an inconstant feature. In most instances, clinical remission of BP was associated with disappearance of BMZ Ig and C3 deposition and serum BMZ antibodies. Fluorescein-conjugated, antihuman C3 appears to be a more sensitive immunoreagent than antihuman, class specific, immunoglobulin antisera in detecting positive BMZ staining in BP. Combined therapy with azathioprine plus prednisone appears to be superior to prednisone alone in the treatment of BP.

(*Arch Dermatol* 113:1043-1046, 1977)

Lever, in 1953,[1] described bullous pemphigoid (BP) and differentiated it from pemphigus vulgaris. Jordon et al[2] demonstrated the presence of basement membrane zone (BMZ) antibodies and their specificity for BP. Others have confirmed these observations and have demonstrated the deposition of various immunoglobulin and complement components as well as components of the alternative complement pathway along the BMZ.[3-9] However, their pathogenetic role has yet to be proved. For example, a number of authors have observed a lack of correlation between BP disease activity and serum antibody titers.[5,10,11] In addition, after infusion of high titer BP serum, monkeys demonstrated BMZ IgG deposition but failed to develop either clinical or histological disease resembling BP.[12]

Lever emphasized that BP may be a relatively benign disease capable of spontaneous remission. Brennan and Montgomery[13] reported 15 of 22 untreated BP patients in remission for 8 to 30 years supporting Lever's contention.[14] Rook and Waddington[15] subsequently reported 38 untreated BP patients in clinical remission ranging from one to five years. Stevenson, in 1960,[16] reported that of 62 BP patients treated with steroids, 25 were in full remission and required no maintenance therapy. Church,[17] however, that same year reported that only four of 36 BP patients treated with steroids were in full remission.

We decided to evaluate the therapeutic response of BP patients and the possible pathogenetic role of immunoglobulins and complement by the following: (1) clinical observation of BP patients after successful therapy; (2) correlation of the presence of in vivo bound immunoglobulins and complement and serum BMZ antibodies with clinical disease activity; and (3) determination of the fate of in vivo bound and circulating BMZ antibody after successful therapy.

PATIENTS AND METHODS

Thirty-six patients have been included in this study. Sixteen were men (45%) and 20 were women (55%). Thirty-two were white (82%) and 4 were black (12%). All patients were hospitalized initially. The patients had classic clinical disease, ie, subepidermal, tense bullae arising on inflamed or normal-appearing skin.

The extent of the patient's disease was classified into one of the following four groups depending on the number of lesions: 1+, < 20 lesions; 2+, 20 to 40 lesions; 3+, 40 to 60 lesions; and 4+, > 60 lesions.

Fourteen patients were treated with prednisone alone. The initial dose ranged from 40 to 180 mg/day (mean, 70 mg). Fifteen patients were treated with azathioprine, 1.5 mg/kg of body weight/day, (mean, 100 mg daily), plus prednisone, initially 40 to 240 mg/day (mean, 60 mg). Before therapy, all patients had a complete blood count, urinalysis, chest roentgenogram, blood glucose, BUN, bilirubin determination, as well as stool examinations for occult blood, ova, and parasites. The patients receiving azathioprine had a bimonthly CBC. The patients were treated until clinical remission occurred and their serum and skin failed to demonstrate BMZ antibodies or C3 deposition. The patients' records were then evaluated for length of hospitalization (equated here with time to control disease), mean steroid maintenance dose, complications, and duration of therapy. All patients were thereafter examined clinically and immunologically at four- to six-month intervals.

Specific immunofluorescent studies were conducted during the initial and subsequent follow-up examinations. Direct immunofluorescent examination of the peribullous normal-appearing skin was performed with standard immunofluorescent techniques as previously described.[8] Monospecific antisera, as judged by immunoelectrophoresis and/or gel double diffusion, specific for IgA, IgG, IgM, IgE, IgD, and C3 were employed. The antisera were made in our laboratory or were purchased commercially. The specificities of the antisera have been previously described.[8] Fluorescein-conjugated goat antihuman IgD antiserum was purchased commercially. All antisera demonstrated specific staining as judged either by absorption with purified myeloma protein or with blocking experiments employing a sandwich technique with unlabelled, class specific antiimmunoglobulin antisera.

Indirect immunofluorescent studies were employed using previously described standard techniques, ie, fluorescein-conjugated rabbit anti-human IgG with monkey esophagus and, at times, normal human skin as a substrate to determine serum basement membrane antibodies.[8] In addition, the patients' sera were examined in the Erie County Laboratories for various autoantibodies against nuclear components, smooth muscle, gastric parietal cells, mitochondria, and adrenal and thyroid glands employing standard immunofluorescent techniques.

Biopsy specimens of peribullous and

Accepted for publication Nov 8, 1976.

From the Department of Dermatology, EJ Meyers Memorial Hospital, Buffalo General Hospital and Veterans Administration Hospital, State University of New York at Buffalo, School of Medicine, Buffalo. Dr Ahmed is now with the UCLA School of Medicine, Los Angeles.

Reprint requests to Buffalo General Hospital, 100 High St, Buffalo, NY 14203 (Dr Provost).

Table 1.—Clinical Data

Clinical Category	No. of Patients	Age of Onset, yr		Length of Time (Days) to Control Initial Blistering Disease		Follow-up Period, mo	No. of Patients With Recurrence
		Mean	Range	Mean	Range		
Mild +	7	78	43-92	15	10-37	8-30 Mean 22	0
Moderate + +	12	74	57-92	23	18-49	9-40 Mean 31	3
Moderately severe + + +	6	71	49-82	33	22-47	8-36 Mean 25.6	2
Severe + + + +	11	66	46-90	40	26-57	14-45 Mean 26	2

Table 2.—Immunopathological Studies: Initial Direct Immunofluorescence Results of Perilesional Skin*

Reagent	Positive Staining
IgA	7
IgM	12
IgG	32
IgD	4
IgE	5
C3	36

*Total number of patients: 36.

Table 3.—Immunopathological Studies: Initial Indirect Immunofluorescence Results

Category	No. of Patients	Negative Titer	Neat Titer	No. of Patients (%) Positive	Ab Titer Mean	Range
Mile +	7	1	2	4 (55)	80	10-640
Moderate + +	12	3	...	9 (75)	40	10-1,280
Moderately severe + + +	6	1	...	5 (82)	20	10-640
Severe + + + +	11	2	2	7 (63)	80	10-5,120

Table 4.—Follow-up Data on Immunofluorescent Studies When Patients Clinically Free of Disease

No. of Patients	Clinical Category				Length of Follow-Up, mo	Treatment		Immunofluorescent Studies	
	1+	2+	3+	4+		On	Off	Direct	Indirect
2	2	...	...	...	8-30 Mean 22.5	...	2	Negative	Negative
22	...	10	3	9	6-45 Mean 23	6	16	Negative	Negative
5	...	...	3	2	8-14 Mean 10	3	2	Positive	Negative
3	1	2	...	...	4-10 Mean 8	...	3	Negative	Positive

normal skin were obtained using a 4 mm punch. Normal skin from the extensor forearm was obtained at four to six monthly intervals when the patients were clinically free of disease and therapy had been discontinued.

A total of 117 biopsies have been performed on these 36 patients. One hundred thirty-one serum specimens have been examined for BMZ antibodies.

RESULTS

The clinical data of these patients are presented in Table 1. All seven patients with 1+ disease had localized involvement. In six patients, the disease was limited predominantly to one extremity. The seventh patient had only scalp involvement. All of these patients remitted on topical therapy alone (wet dressings and 0.1% triamcinolone acetonide cream). There were no recurrences in this group.

All patients with 2+, 3+, and 4+ activity had generalized disease. Three patients were noted to have oral lesions that healed without sequelae after therapy. Also, 12 patients had significant pruritus that was controlled with hydroxyzine hydrochloride. In general, the more extensive the bullous eruption, the longer the period of time for initial control of the blistering disease.

Seven patients had recurrences. Four patients had more than one recurrence. Each recurrence reproduced the clinical picture of the initial episode. The interval between recurrences was highly variable ranging from six weeks to 20 months and did not correlate with clinical severity or duration of initial disease.

No autoantibodies to nuclei, smooth muscle, adrenal, thyroid, and mitochondria were noted.

Table 2 contains results of the initial direct immunofluorescent examinations. There was no apparent relation between extent of clinical disease and class or number of classes of immunoglobulin BMZ deposition. The IgG and C3 were the most common immunoreactants detected along the BMZ. The C3 was observed in four initial examinations in the apparent absence, as judged by immunofluorescent techniques, of BMZ immunoglobulin deposition. This phenomenon occurred early in the initial disease and was not related to clinical severity. Subsequent biopsies performed two to three weeks later in two patients demonstrated IgG BMZ deposition. A similar immunofluorescent observation of C3 BMZ deposition in the apparent absence of Ig deposition was found in five additional instances during recurrence of bullous pemphigoid.

The IgD was seen in four patients and IgE in five. The IgD, IgE, IgA, and IgM deposition always occurred in association with IgG.

Eleven of the 36 patients initially had either no demonstrable serum BMZ antibody, or if noted, was present only in undiluted (neat) serum (Table 3). There was no correlation between the absence of serum anti-BMZ antibody and clinical disease activity.

The fates of BMZ antibody deposition and serum BMZ antibody after therapy are displayed in Table 4. Sixteen patients, off all therapy, have been free of serologic and immunohistologic evidence of BP for a mean period of 23 months. Six additional patients being treated are free of disease with no serologic or direct immunofluorescent evidence of BMZ antibody or C3 deposition.

Five patients, free of disease for a mean of ten months, have persistent

Table 5.—Treatment

Treatment Group	No. of Patients	Clinical Category				Dose of Prednisone, mg/Day			
		1+	2+	3+	4+	Initial Dose, mg/Day	Duration of Initial Dose /Day	Maintenance Dose, mg/Day	Duration Maintenance, wk
Steroids	14	...	12	2	...	30-180 Mean 60	6-60 Mean 20	5-30 Mean 30	4-40 Mean 21
Steroids and azathioprine	15	...	...	4	11	40-240 Mean 70	10-60 Mean 21	10-60 Mean 35	4-24 Mean 16

pure IgG BMZ deposition but no serum BMZ antibody. Two have not had therapy for at least 12 months.

Three patients, disease-free and not being treated, persist in displaying serum IgG BMZ antibodies but direct immunofluorescence of normal skin failed to demonstrate in vivo C3 and immunoglobulin BMZ deposition.

Twelve patients with 2+ (moderate) and two patients with 3+ (moderately severe) disease were treated with prednisone alone (Table 5). Patients classified as having very severe disease (11 patients with 4+ disease) and four patients with 3+ disease received a combination of azathioprine and prednisone. The prednisone maintenance dose and length of time on treatment were less in those patients treated with the combined therapy than in the group of BP patients with milder disease that received prednisone alone.

COMMENT

In this paper, we confirm Lever's observations on the heterogeneous nature of BP.[11] During a prolonged observation of BP patients before the availability of corticosteroids, Lever noted 11 BP patients with localized disease who remitted spontaneously.[14] The seven patients with a predominantly localized disease (1+) included in our series all displayed classic indirect and/or direct immunofluorescent findings of BP. Once in the hospital, the localized bullous disease rapidly responded to topical steroids and wet dressings. Results of follow-up serologic examination and direct immunofluorescence of the skin were available in only three (Table 4), but clinical follow-up results in the other four reveals no evidence of BP.

There was no correlation between the extent of the disease and the antibody titer, a finding that has been observed previously.[10] Thirty percent of our patients' initial sera had either no detectable serum BMZ antibodies, or if present, the titer was neat (undiluted serum). Most laboratories would report the three neat sera noted in our series as negative for BMZ antibodies. Follow-up examination of these patients two to three weeks later generally demonstrated a detectable serum BMZ antibody titer. The reason for the failure to detect the serum BMZ antibody initially may be related to the fact that early in the disease, all the antigenic determinants on the BMZ may not be occupied. In a sense, these unoccupied antigenic sites absorb out the serum antibody. It is likely that once the antigenic sites on the BMZ are occupied, the serum antibody titer rises and becomes detectable.

This study also demonstrates the value of fluorescein-conjugated anti-human C3 as a diagnostic reagent. In nine instances (four initial disease and five with recurrent episodes), C3 BMZ deposition was noted in the apparent absence of Ig deposition. In two of three patients tested, we were unable to demonstrate Clq or C4 staining. One patient demonstrated Clq staining. Subsequent examination of biopsy specimens of two additional patients taken three weeks later demonstrated IgG BMZ deposition. Surprisingly, six patients demonstrating only C3 deposition along the BMZ had detectable serum antibodies (mean titer 40). We cannot explain this apparent discrepancy between serum and skin BMZ antibody detection. Our general experience indicates that a direct immunofluorescent examination of perilesional skin is a superior diagnostic procedure to serum antibody determination. On the other hand, the ease in detecting C3 in the apparent absence of Ig BMZ deposition, as judged by immunofluorescent technique, is most likely explained by the fact that one IgM and two IgG molecules are capable of activating hundreds of C3 molecules at the site of an antigen-antibody reaction.[18]

All patients when examined initially or during subsequent recurrences of their BP had IgG and/or C3 BMZ deposition. During recurrence, we could demonstrate a serum anti-BMZ antibody in 50% of patients. Again these patients were examined early in their recurrence, which in view of our previous results (see above), probably explains the low incidence of detectable serum antibodies.

Our most significant observation, however, is that 16 of our patients with generalized disease have, after therapy, remained in prolonged clinical remission and without serologic or direct immunofluorescent evidence of BMZ antibodies. Five of these patients have been observed for at least 36 months; five for 18 months; four for 12 months; and two for 6 months.

Five patients persist in demonstrating pure IgG BMZ deposition after prolonged therapy given for a systemic effect. Two of these patients have not had therapy for at least 12 months. The reason for the persistence of IgG deposition is unknown. This may represent delayed catabolism of IgG but this seems unlikely because of the duration of the persistence. On the other hand, the IgG BMZ deposition could represent a subclinical immunologic assault on the basement membrane that may, with time, either abate or result in formation of new bullae. These patients remain under observation.

Three patients clinically free of disease have persisted in displaying serum BMZ antibodies without direct, immunofluorescent evidence of Ig or C3 in normal skin. These antibodies are easily detected with monkey esophagus but are difficult to detect when homologous or autologous skin is employed as a substrate. The titer of these antibodies on autologous skin is 20 compared to 80 on monkey esophagus. The reason for the discrepancy between the presence of serum antibodies in these patients in the absence of direct immunofluorescent evidence of BMZ Ig deposition is

unknown. Perhaps the in vitro techniques provide a more favorable milieu for the low titer serum antibody to react with the human basement membrane than is present in the in vivo setting. Alternatively, or perhaps related to this observation, may be the weak avidity of these BMZ antibodies for human BMZ antigen(s).

The IgD and IgE BMZ deposition was noted in a small percentage of our patients. Similar observations have been previously noted.[8-19] Three of the five patients with IgE basement membrane deposition demonstrated serum IgE antibasement membrane antibodies in weak titers.[2-6] The IgD serum antibasement membrane antibodies were found in a neat titer in one of the four patients demonstrating IgD basement membrane staining.

This study suggests that the combined use of prednisone with azathioprine (1.5 mg/kg of body weight) is of benefit in treating BP. Our data indicate that not only may the length of therapy be reduced (in our series 30%) but that the maintenance dose of prednisone may be substantially lowered (50%).

The steroid-sparing effect of the combined use of prednisone and azathioprine appears to be of real benefit in the prolonged steroid treatment of an elderly patient. To date, employing the combination of azathioprine (1.5 mg/kg of body weight/day) and prednisone as described in the study, we have not had any serious side effects due to either the prednisone or azathioprine.

On the other hand, in half of the 14 patients treated with high doses of prednisone alone, side effects either secondary to or partially attributable to the steroids were noted. Two deaths occurred in this group; one secondary to massive gastrointestinal bleeding, the other secondary to a gram negative septicemia. Four patients developed depression or psychosis. Mild gastrointestinal bleeding, steroid-induced diabetes mellitus, and osteoporosis were noted in individual patients.

Other investigators, however, have noted toxicity with azathioprine.[20,21] Our lack of side effects may be explained, at least in part, by the relatively low dose (1.5 mg/kg of body weight) employed in our study compared to the 2.5 mg/kg of body weight by others.

Admittedly, our experience with this combined therapy is preliminary and has not been subjected to the scrutiny of a double-blind control, but our observations suggest that the combined therapeutic effect of low doses of azathioprine and prednisone are additive but their toxicity is not.

Finally, it must be emphasized that during a prolonged evaluation all patients with BP (initial or recurrent disease) had positive immunofluorescence along the perilesional BMZ. We believe that the pure C3 deposition, noted in nine instances (four during initial disease, five during recurrent disease), is secondary to an immunologic reaction. This is supported by the subsequent ability to demonstrate IgG BMZ deposition (two to three weeks later). This pure C3 BMZ deposition is similar to the findings noted in herpes gestationis in which C3 is often noted along the BMZ in the apparent absence, as judged by immunofluorescent techniques, of other complement components and immunoglobulins.[22,23] Unlike the herpes gestationis patients, the serum of these BP patients lacking antibasement antibodies failed to deposit C3 on normal human skin or monkey esophagus. Jordon et al[23] and Katz et al,[24] however, have provided evidence that the serum factor in herpes gestationis capable of depositing C3 along the BMZ frequently in the absence of demonstrable BMZ antibodies is an avid complement fixing IgG anti BMZ antibody, which may be present in the serum in such low quantities as to frequently escape detection by routine immunofluorescent techniques.

We, therefore, feel that the consistent findings of IgG and/or C3 at the site of pathology in all patients with active or recurrent BP provides supporting, but by no means conclusive evidence, for a role of Ig and C in the pathogenesis of bulla formation in this disease.

This investigation was supported by Public Health Research grant R01 AM 16593-03 from the National Institute of Arthritis and Metabolic Diseases.

Christine Perpetus, Gail Raimondo, and Marilyn Fitzsimmons gave technical assistance.

Marvin Winer, MD, Hans Kipping, MD, Paul Weinmann, MD, Howard Stoll, MD, and Frank Hoak, MD, referred their patients for this study.

Nonproprietary Name and Trademark of Drug

Azathioprine—*Imuran.*

References

1. Lever WF: Pemphigus. *Medicine* 32:1-123, 1953.
2. Jordon RE, Beutner EH, Witebsky E, et al: Basement zone antibodies in bullous pemphigoid. *JAMA* 200:751-756, 1967.
3. Chorzelski T, Jablonska S, Blaszcsyk M: Autoantibodies in pemphigoid. *Dermatologica* 136:325-334, 1968.
4. Jordon RE, Trifthauser CT, Schroeter AL: Direct immunofluorescence studies of pemphigus and pemphigoid. *Arch Dermatol* 103:486-491, 1971.
5. Jordon RE, Sams WM Jr, Beutner EH: Complement immunofluorescent staining in bullous pemphigoid. *J Lab Clin Med* 74:548-556, 1969.
6. Cormane RH, Szabo E: Immunopathology of skin in pemphigoid. *Br J Dermatol* 83:435-445, 1970.
7. Beutner EH, Jordon RE, Chorzelski TP: Immunopathology of pemphigus and pemphigoid. *J Invest Dermatol* 51:65-80, 1968.
8. Provost TT, Tomasi TB Jr: Immunopathology of bullous pemphigoid. *Clin Exp Immunol* 18:193-200, 1974.
9. Jordon RE, Schroeter AL, Good RA, et al: Complement system in bullous pemphigoid. *Clin Immunol Immunopathol* 3:307-314, 1975.
10. Sams WM Jr, Jordon RE: Correlation of pemphigoid and pemphigus antibody titers with disease activity. *Br J Dermatol* 84:7-13, 1971.
11. Peck SM, Osserman KE, Weiner LB, et al: Studies in bullous disease. *N Engl J Med* 279:951-958, 1968.
12. Sams WM Jr, Gleich GJ: Failure to transfer bullous pemphigoid with serum from patients. *Proc Soc Exp Biol Med* 136:1027-1031, 1971.
13. Brennan JG, Montgomery H: Pemphigus and other bullous dermatoses: Correlation of clinical and pathological findings: *J Invest Dermatol* 211:349-363, 1953.
14. Lever WF: *Pemphigus and Pemphigoid.* Springfield, Ill, Charles C Thomas Publisher, 1965.
15. Rook A, Waddington E: Pemphigus and pemphigoid. *Br J Dermatol* 64:425-438, 1953.
16. Stevenson CJ: Treatment in bullous dermatoses with corticosteroids, drugs and corticotrophin. *Br J Dermatol* 72:11-19, 1960.
17. Church R: Pemphigoid treated with corticosteroids. *Br J Dermatol* 72:434-441, 1960.
18. Ruddy S, Gigli I, Austen KF: The complement system of man. *N Engl J Med* 287:489-495, 545-549, 592-596, 1972.
19. Cormane RH, Giannetti A: IgD in various dermatoses: Immunofluorescence studies. *Br J Dermatol* 84:523-533, 1971.
20. Greaves MW, Burton JL, Marks J, et al: Azathioprine in treatment of bullous pemphigoid. *Br Med J* 1:144-145, 1971.
21. Van Dijk TJA, Van Velde JL: Treatment of pemphigus and pemphigoid with azathioprine. *Dermatologica* 147:179-185, 1973.
22. Provost TT, Tomasi TB Jr: Evidence for complement activation via the alternate pathway in skin diseases: I. Herpes gestationis, systemic lupus erythematosus, and bullous pemphigoid. *J Clin Invest* 52:1779-1787, 1973.
23. Jordon RE, Heine KG, Tappeiner G, et al: The immunopathology of herpes gestationis: Immunofluorescence studies and characterization of "HG factor". *J Clin Invest* 57:1426-1433, 1976.
24. Katz SI, Hertz KC, Yaoita H: Herpes gestationis. Immunopathology and characterization of HG factor. *J Clin Invest* 57:1434-1441, 1976.

Photochemotherapy for Mycosis Fungoides

Henry H. Roenigk, Jr, MD

• **Twelve cases of cutaneous mycosis fungoides (MF) with erythroderma, plaques, and tumors were treated with photochemotherapy. Methoxsalen followed two hours later by ultraviolet light (UVA) resulted in clinical clearing of skin lesions in seven patients with plaque stage MF and one patient with erythrodermic MF. Four patients with both plaque and tumor stage MF showed clearing of plaques but not the tumors. Phototherapy units consisted of boxes with 16 to 64 UVA lights. The mean number of treatments to clear was 17.4. The mean total dose to clear was 134.8 joules. The mean dose of maintenance UVA was 5.6 joules/sq cm. Histopathologic clearing of mycosis fungoides was demonstrated with the clinical clearing.**

(*Arch Dermatol* 113:1047-1051, 1977)

Mycosis fungoides (MF) is a form of malignant lymphoma that arises in the skin and over many years steadily progresses to plaques and tumors. Autopsy findings often reveal significant visceral involvement at time of death.[1] The premycotic stage is characterized by scaly erythematous patches that clinically resemble nonspecific eczemas, psoriasis, or parapsoriasis. When skin lesions reach the plaque and tumor stage in the skin, the clinical and histologic diagnosis is more evident.

Therapy of MF is controversial. The course of MF varies from either a long-term chronic process to early mortality. This variability in the natural course of the disease makes evaluation of therapy difficult. Staging of the disease[2,3] is important in deciding if therapy should be confined to skin lesions or given for systemic effect to irradicate visceral involvement. Topical approaches to therapy include corticosteroids,[4] nitrogen mustard painting,[5-7] and electron beam irradiation.[8]

Methoxsalen has been used for systemic effect for the treatment of vitiligo for over 20 years.[9] Parrish et al[10] reported successful treatment of psoriasis combining oral methoxsalen given for systemic effect and a high intensity longwave (320 to 390 mm) ultraviolet light (UVA) system. Our studies,[11] using several different phototherapy units in 168 patients with psoriasis, have confirmed the effectiveness of this therapy.

The present study describes the beneficial effect of photochemotherapy with methoxsalen and UVA in patients with MF.

SUBJECTS AND METHODS

Twelve patients, eight women and four men, aged 27 to 82 years, with clinical cutaneous lesions of MF were studied. The diagnosis was confirmed histologically on repeated skin biopsies. All biopsy specimens were reviewed and confirmed by the pathology panel of the MF cooperative study.[12]

Complete evaluation of all patients included routine laboratory studies, microscopic examination of bone marrow biopsy specimens, roentgenograms of upper and lower gastrointestinal tract, intravenous pyelogram, liver scan, brain scan, lymphangiograms, and lymph node biopsies. Laparotomy staging was done in one patient. Only patients with no detectable visceral lesions of MF were entered into the therapy.

Ten-milligram capsules of methoxsalen

Accepted for publication Dec 10, 1976.

From the Department of Dermatology, Cleveland Clinic, Cleveland.

Reprint requests to Department of Dermatology, Northwestern University Medical School, Chicago, IL 60611 (Dr. Roenigk).

Table 1.—Phototherapy Units Used for Photochemotherapy of MF

Phototherapy Unit	Manufacturer	No.	Bulb Manufacturer	Reflector	Intensity, mW/sq cm (After 200 hrs Operation)*
PUVA-16	Environmental Chambers	16	GE	External-Alzak	2.5
PUVA-36	Environmental Chambers	36	GE	External-Alzak	3.1
PUVA-48	National Biological Corp	48	GE	External-Alzak	4.5
PUVA-64	GTE Sylvania	64	Sylvania	Internal in bulb	9.5

*Intensity measured in the center of the chamber.

were given according to the method of Parrish et al[10] based on patient body weight as follows: up to 50 kg of body weight, 20 mg; 51 to 65 kg, 30 mg; 66 to 80 kg, 40 mg; and over 80 kg, 50 mg. Most of the patients were taking 40 mg of methoxsalen. Patients were instructed to take the methoxsalen two hours before their scheduled light therapy.

Phototherapy units utilized the following two different light bulbs: General Electric blacklight (F 72 T12 BL H0) and Sylvania (Parrish et al).[10] Both lamps emit a continuous spectrum of long UVA in the range of 320 nm to 400 nm with a peak emission between 350 and 380 nm. Both lamps are 72 inches long and units were developed with various numbers of bulbs. Sylvania lamps have an internal reflector system and the General Electric units utilize external reflectors. Table 1 compares the phototherapy units used in this study. Each unit has a timer and meter for hours of operation. Output of the units was measured with an international light 254 photometer and 700 research radiometer calibrated at 360 nm (Table 1).

Initial exposure times of patients to longwave UVA were based on the degree of pigmentation before therapy, history of ability to tan, and the type of phototherapy units to be used. Exposure times were increased with each treatment depending on patient response, evidence of erythema, and type of phototherapy unit used. Initial UVA dose was between 1.5 to 3 joules/sq cm. Dosage of phototherapy was recorded in both minutes and joules per square centimeter. Exposure times were increased at each treatment by at least 0.5 joules/sq cm or more depending on presence of erythema. Ultraviolet light blocking goggles were worn over the eyes during therapy and UVA blocking sunglasses for five hours after therapy.

Once the MF lesions had cleared completely, the patient was placed on a maintenance schedule. The UVA exposure (joules/sq cm) during maintenance was the same as the patient's last treatment during the clearing phase. Photochemotherapy was usually given every 48 hours (three times a week) during clearing. Maintenance was either once or twice per week or every other week (Table 2).

Table 2.—Follow-up of Mycosis Fungoides Treated With Photochemotherapy

Patient	Maintenance Dose, Joules/sq cm	Frequency	Follow-up, mo
MF Cleared			
1	7	Weekly	12
2	5	Every 2 wk	15
3	5.5	Every 2 wk	10
6	5.5	Weekly	18
7	2.5	2 X Wk	11
8	5	2 X Wk	15
9	3	Every 2 wk	14
11	5	2 X Wk	5
Mean	4.5		12.5
SD	±1.03		
Plaque lesions cleared, tumor lesion unresponsive			
4	11.5	2 X Wk	12
5	7.5	2 X Wk	10
10	4	3 X Wk	PUVA Stopped
11	6	3 X Wk	PUVA Stopped
12	6	3 X Wk	PUVA Stopped
Mean	7.0		
SD	±1.3		

Table 3.—Mycosis Fungoides Previous Therapy

Case No.	Therapy Prior to PUVA	Response
1	Topical nitrogen mustard Superficial x-ray	Cleared, sensitized Resolved large plaques
2	None	. . .
3	None	. . .
4	Topical nitrogen mustard Electron beam and bleomycin	Cleared, sensitized Fair remission
5	Methoxsalen Topical nitrogen mustard Superficial x-ray	Fair Cleared Tumors resolved
6	Methoxsalen	Fair
7	Topical nitrogen mustard Superficial x-ray	Cleared, sensitized Good
8	None	. . .
9	Topical nitrogen mustard Methoxsalen	Good Fair
10	Topical steroids	Poor
11	Electron beam ×7	Poor response in later courses
12	None	

Photographs and skin biopsies from identical locations were taken before and after therapy with photochemotherapy to evaluate results.

Eight of the 12 patients had received other therapy previously for MF with topical corticosteroids, mechlorethamine, superficial x-ray, electron beam, and chemotherapy (Table 3). Four patients had no prior therapy.

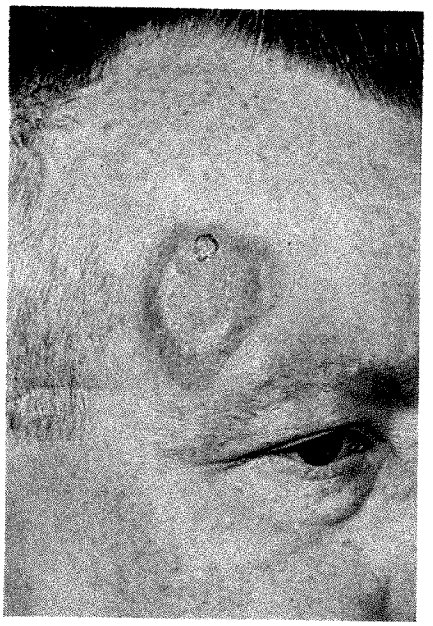

Fig 1.—Case 1, plaque-like lesions of MF before PUVA.

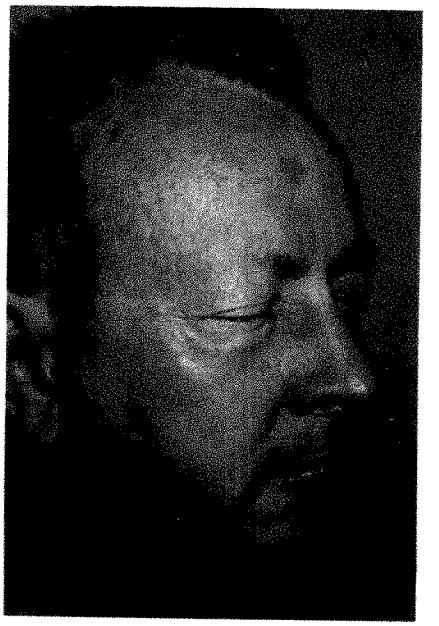

Fig 2.—Case 1, clearing of plaque lesions of MF of face after PUVA therapy.

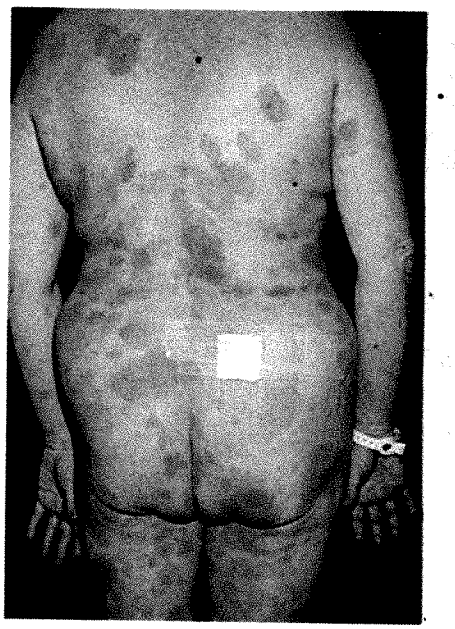

Fig 3.—Case 2, plaque-like lesions MF over back before PUVA therapy.

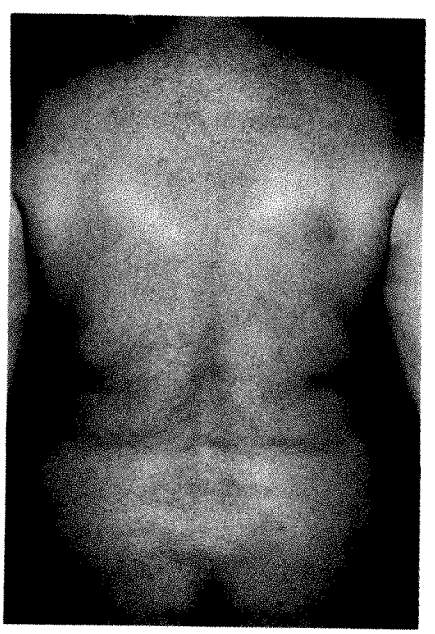

Fig 4.—Case 2, clearing of all plaque-like lesions of MF after PUVA therapy.

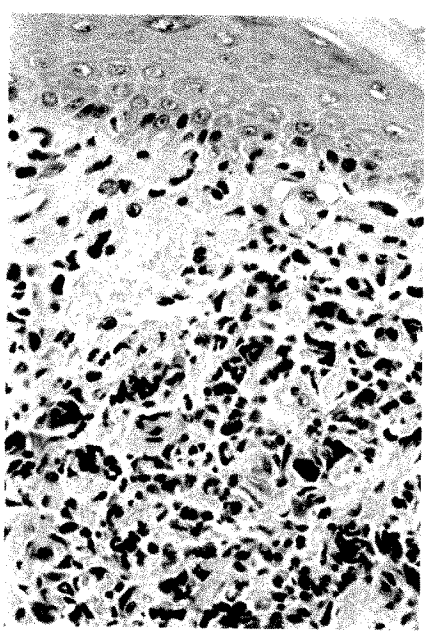

Fig 5.—Case 4, skin biopsy specimen before PUVA therapy compatible with MF (hematoxylin-eosin, original magnification ×40).

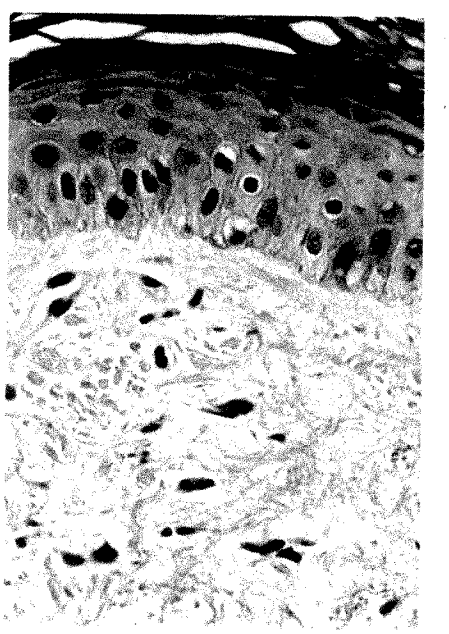

Fig 6.—Case 4, skin biopsy specimen after PUVA therapy showing the atypical dermal infiltrate is cleared (hematoxylin-eosin, original magnification ×40).

RESULTS

Seven patients (cases 1 (Fig 1 and 2), 2 (Fig 3 and 4), 3, 6, 8, 9, and 11) had plaque-type MF and had the best response to PUVA (Table 4). All of them cleared their MF with a mean total dose of 134.8 joules (Table 4). They have subsequently been placed on maintenance therapy, and all have remained clear with a mean maintenance dose of UVA of 5.6 joules/sq cm (Table 4). Average follow-up of the cleared patient is greater than one year. Patient 8 had erythroderma and was difficult to control because of the erythema from UVA. She is now maintained on 5 joules/sq cm of methoxsalen-UVA (PUVA)-16 twice per week. As the lesions cleared, a deep tan developed in all patients.

Four patients (cases 4, 5, 10, 11) had both plaque and tumor lesions. The plaque lesions in all four patients responded to PUVA. Cases 4 and 5

Table 4.—Mycosis Fungoides-PUVA

Case No.	Age, yr	Stage of MF	PUVA	No. of Treatments to Clear	Total Joules to Clear	Maintenance (Weekly) min, Joules/sq cm	Comment
1	50	Plaque	PUVA-48	30	261	32, 6	...
2	51	Plaque	PUVA-16	12	51	30, 5	...
3	27	Plaque	PUVA-16	19	114	30, 5	...
4	82	Plaque and tumor	PUVA-64	40	449	23, 11.5	Tumor on nose needed deep x-ray
5	55	Plaque and tumor	PUVA-48	22	148	19, 7.5	Tumor lesions not clear
6	56	Plaque	PUVA-64	20	124	18, 7	Aging of skin
7	47	Erythroderma	PUVA-16	16	84	16, 2.5	Cleared
8	58	Plaque	PUVA-16	13	59	30, 5	Switch to mustard painting and flared; cleared after 38 PUVA treatments
9	77	Plaque	PUVA-16	10	38	19, 3	Carcinoma of the colon
10	67	Plaque and tumor	PUVA-24	12	51	24, 4	Tumor lesions not resolved; Randomized to electron beam
11	49	Plaque	PUVA-24	18	104	30, 5	Cleared
12	78	Plaque and tumor	PUVA-36	...	...	...	Randomized to electron beam and chemotherapy because internal MF; skin lesion resolved
Mean				17.4	134.8	24.6, 5.6	
SD				±2.23	±8.17	± 21.7, ± 1.20	

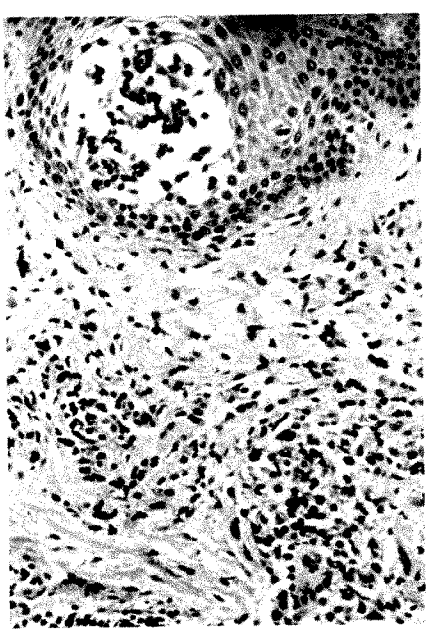

Fig 7.—Case 8, skin biopsy specimen before PUVA compatible with MF large pustular abscess in the epidermis and atypical dermal infiltrate (hematoxylin-eosin, original magnification ×20).

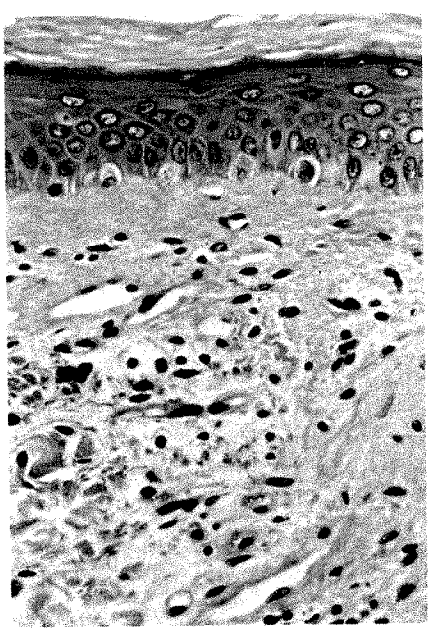

Fig 8.—Case 8, skin biopsy specimen after two months of PUVA, abscess and atypical dermal infiltrate is cleared (hematoxylin-eosin, original magnification ×20).

required deep x-ray therapy to isolated tumor lesions that showed no response to PUVA. The plaques of MF in case 10 were clearing but the patient was randomized in the MF cooperative study because of tumor lesions. Case 12 was initially treated and responded to PUVA at an outside institution. After complete examination at Cleveland Clinic, he was found to have visceral involvement with MF and was subsequently randomized in the MF cooperative study to electron beam and chemotherapy.

Patients were treated with various phototherapy units (Table 4). The number of minutes per treatment at time of clearing varied with the phototherapy unit used (PUVA-16 takes longer to give 5 joules/sq cm than does PUVA-64). The average maintenance treatment was 5.6 joules/sq cm.

Histological sections of skin from plaques before and after PUVA confirm the clinical clearing of lesions in all patients (Fig 5 through 8).

COMMENT

Because of the chronicity of MF and its unpredictable course, treatment must be individualized. Although, Van Scott and Winters[13] have advocated an aggressive approach with topical mechlorethamine hydrochloride. Fuks et al[8] have presented data that intensive early electron beam therapy may be curative. Bluefarb[14] recommended a conservative approach with topical corticosteroids and UVA exposure in mild cases. Chemotherapy following therapeutic outlines used for Hodgkin's disease have not increased survival of patients with MF.[1]

Photochemotherapy has become a new method of controlling severe generalized psoriasis.[10] Two large cooperative studies in the United States are presently evaluating this therapy and its possible adverse reactions.

Gilchrest et al[15] have treated nine patients in various stages of MF using methoxsalen and the Sylvania phototherapy unit. Case 6 is one of their cases and has been followed by Cleveland Clinic for the past year. This report of 11 additional cases that have responded confirms the short-term effectiveness of this new therapy in MF. We used methoxsalen in a similar dosage to Gilchrest et al[15] but utilized various phototherapy units with both General Electric and Sylvania light sources (Table 1).

Mycosis fungoides in the plaque stage responds best to photochemotherapy. Seven patients in our series who only had plaque stage mycosis fungoides responded and cleared completely. Follow-up for greater than one year (Table 2) shows they remain clear if maintenance therapy is continued. None of them have developed tumors or symptoms of visceral involvement. Patients with both plaque and tumor stage MF showed a good response in plaques only. The tumors were not responsive to photochemotherapy, and several of our patients in this group required other therapy to control tumors.

Skin biopsy specimens taken from identical plaque lesions of MF before and after photochemotherapy confirm the clearing of plaque lesions. Even lesions with abnormal lymphocytes deep in dermis and Pautrier abscesses in epidermis resolved with photochemotherapy. The histological clearing of deep dermal lymphocytes confirms the depth of penetration of UVA (Fig 5 through 8).

The mechanism of action of photochemotherapy in clearing lesions of MF is not completely understood. Methoxsalen is a furocoumarin derivative and a potent photosensitizer with an action spectrum in the long ultraviolet wave light range (320 to 400 nm). Methoxsalen-induced damage is related to the formation of photoproducts between the chemical and pyrimidine bases of the cellular DNA.[16,17] Epstein and Fukuyama[18] have shown that the phototoxic reaction induced by methoxsalen and UVA inhibits semiconservative premitotic DNA synthesis in mammalian epidermis but caused minimal depression of RNA formation. This depression of DNA synthesis is the presumed rationale for its effect on the rapidly proliferating epidermis in psoriasis.

Musajo et al[19] demonstrated that irradiation with UVA and methoxsalen inhibited tumor transmitting capacity of Ehrich ascites tumor cells. They indicated the tumor inhibition may be due to inhibition of DNA and RNA synthesis.[17] Similar tumor inhibiting effects have been reported with methoxsalen and UVA in several different tumor systems.[20] A similar effect on DNA synthesis and to a lesser extent, RNA synthesis, may be the explanation for the clinical and histological improvement seen in MF exposure to methoxsalen and UVA.

Because of the complications that can occur from other forms of therapy presently used for MF, photochemotherapy seems to offer an alternative approach that is effective and safe. Continuous maintenance photochemotherapy in the plaque stage may keep mycosis fungoides in remission.

Nonproprietary Name and Trademarks of Drug

Methoxsalen—*8-MOP, Oxsoralen.*

References

1. Epstein EH, Levin DL, Croft JD, et al: Mycosis fungoides: Survival, prognostic features, response to therapy and autopsy findings. *Medicine* 15:61, 1972.
2. Haynes HA, VanScott EJ: Therapy of mycosis fungoides. *Prog Dermatol* 3:1, 1968.
3. Griem ML, Moran EM, Fergason DJ, et al: Staging procedures in mycosis fungoides. *Br J Cancer* 31:362-367, 1975.
4. Farber EM, Zackheim HS, McClintock RP, et al: Treatment of mycosis fungoides with various strengths of fluocinolone acetonide cream. *Arch Dermatol* 97:165, 1968.
5. Haserick JR, Richardson JH, Grant DJ: Remission of lesion on mycosis fungoides following topical application of nitrogen mustard. *Cleve Clin Q* 26:144-147, 1959.
6. Roenigk HH Jr, Haserick JR: Mycosis fungoides treated with topical applications of nitrogen mustard, in Waisman M (ed): *Pharmaceutical Therapeutics in Dermatology.* Springfield, Ill, Charles C Thomas Publisher, 1968.
7. VanScott EJ, Kalmenson JD: Complete remissions of mycosis fungoides lymphoma induced by topical nitrogen mustard (HN_2). *Cancer* 32:18-29, 1973.
8. Fuks ZY, Bagshaw MA, Farber EM: Prognostic signs and the management of the mycosis fungoides. *Cancer* 32:1385-1396, 1973.
9. Fitzpatrick TB, Arnot KA, Elmofty AM, et al: Hydroquinone and psoralen in the therapy of hypermelanosis and vitiligo. *Arch Dermatol* 93:589-600, 1966.
10. Parrish JA, Fitzpatrick TB, Tannenbaum L, et al: Photochemotherapy of psoriasis with oral methoxsalen and longwave ultraviolet light. *N Engl J Med* 291:1207-1210, 1974.
11. Roenigk HH Jr, Martin J: *Photochemotherapy for psoriasis—Comparison of phototherapy systems. Cutis,* to be published.
12. Lamberg SI, Diamond EL, Lorincz AL, et al: The mycosis fungoides cooperative study group. *Arch Dermatol* 111:457-459, 1975.
13. VanScott EJ, Winters PL: Response of mycosis fungoides to intensive external treatment with nitrogen mustard. *Arch Dermatol* 102:507-514, 1970.
14. Bluefarb SM: Treatment of mycosis fungoides, in Waisman M (ed): *Pharmaceutical Therapeutics in Dermatology.* Springfield, Ill, Charles C Thomas Publisher, 1968, pp 83-86.
15. Gilchrest BA, Parrish JA, Tannenbaum L, et al: Oral methoxsalen photochemotherapy of mycosis fungoides. *Cancer* 38:683-689, 1976.
16. Pathak MA, Kramer DM: Photosensitization of skin in vivo by furocoumasins (psoralens). *Biochem Biophys Acta* 195:197-206, 1969.
17. Musajo L, Bordin F, Baccichetti F, et al: Psoralen-thymine C_4-cycloadduct formed in the photoinactivator with psoralens of Ehrlich ascites tumor cells. *Rend Accad Naz Lincei* 43:442-447, 1967.
18. Epstein JH, Fukuyama K: Effects of 8-methoxypsoralen-induced phototoxic effects on mammalian epidermal macromolecular synthesis in vivo. *Photochem Photobiol* 21:325-330, 1975.
19. Musajo L, Visentini P, Baccichetti F, et al: Photoinactivation of Ehrlich ascites tumor cells obtained with skin-photosensitizing furocoumarins. *Experientia* 23:335-336, 1967.
20. Musajo L, Rodighiero G, Caporale G, et al: Photoreactions between skin–photosensitizing furocoumarins and nucleic acid, in Fitzpatrick T. B. (ed): *Sunlight and Man.* Tokyo, University of Tokyo Press, 1974, pp 369-387.

Keratinizing Dermatoses

Combined Data From Four Centers on Short-Term Topical Treatment With Tretinoin

Sigfrid A. Muller, MD; Richard W. Belcher, MD; Nancy B. Esterly, MD; Jon C. Lochner, MD; James S. Miller, MD; Henry Roenigk, Jr, MD; Lester Weissman, MD

• In four medical centers, 40 patients with keratinizing dermatoses were treated with topical tretinoin (vitamin A acid) 0.1% cream and salicylic acid 2% cream in a short-term, double-blind study. Tretinoin was the more effective treatment for several of the keratinizing dermatoses with the exception of palmar-plantar hyperkeratosis, for which it was not effective in the concentration and method of application used. The most striking clinical responses occurred in patients with lamellar ichthyosis and ichthyosis vulgaris. Local adverse reactions—chiefly pruritus, erythema, burning, excoriation, and irritation—were not severe and could be controlled by modification of the treatment regimen.

(*Arch Dermatol* 113:1052-1054, 1977)

Vitamin A preparations, both systemic and topical, have been administered for years for hyperkeratotic skin disorders. In the early 1960s, topical preparations of tretinoin (retinoic acid, vitamin A acid) were first reported effective in decreasing scale formation in the ichthyosiform dermatoses.[1,2] However, no further publications concerning their topical application appeared until 1968, when Frost and Weinstein[3] described the effects of various forms of vitamin A, including vitamin A acid cream in strengths ranging from 0.1% to 0.3%, in patients with ichthyosiform dermatoses or psoriasis. Fulton et al[4] reported the successful treatment of two patients with Darier's disease by application of a tretinoin 1% lotion under occlusion, and Schuppli and Ziegler[5] treated one patient with congenital ichthyosiform erythroderma and obtained good results. Subsequently, occasional papers, usually case reports, have appeared on the efficacy of tretinoin in the treatment of such chronic dermatoses as palmar-plantar hyperkeratosis, lamellar ichthyosis, psoriasis, ichthyosis vulgaris, and Darier's disease.[6-17] Considerable differences in formulation of medication, concentration of vitamin A acid, method and frequency of application, and duration of treatment can be noted in these reports.

A multiclinic study was initiated in which an identical protocol was used at four medical centers. In these double-blind studies, patients with hyperkeratotic skin disorders were treated with identically paired medications—a tretinoin 0.1% cream and a salicylic acid 2% cream, the latter being selected as a safe nonspecific irritant. The results were analyzed as a single, multiclinic study. The data from patients with the same disease were pooled and analyzed.

MATERIALS AND METHODS

A total of 44 patients with ichthyosis or bilateral and symmetric localized hyperkeratotic skin disease participated in these double-blind studies. Nineteen were male and 25 were female subjects; their ages ranged from 2 to 70 years (27 were less than 21 years old). Nine were black, the remainder white. For each patient, comparable sites of involvement were designated as site 1 and site 2. One site was treated with tretinoin 0.1% cream and the other with an identical-appearing salicylic acid 2% cream. Each tube also contained the following: distilled water, propylene glycol, stearyl alcohol, petrolatum, isopropyl palmitate, polyoxyl 40 stearate, cetyl alcohol, stearic acid, beeswax, methylparaben, (butylated hydroxyanisole) (BHA), (butylated hydroxytoluene) (BHT), propylparaben, and disodium sequestrene. Each medication, coded by patient number and site number, was applied to the designated area as a thin film once or twice daily for a period of 12 weeks, unless improvement suggested a reduced schedule, after which the code was broken. Patients were seen weekly by the principal investigator for evaluation, and overall improvement in scaling and erythema was recorded as none, slight, moderate, or good (scored 0 through 3).

Local or systemic side effects were detected by clinical examination and laboratory studies. Baseline values were established for routine hematologic studies, urinalysis, BUN, SGOT or SGPT, cholesterol, blood glucose, alkaline phosphatase, and serum bilirubin. These tests were repeated once every two weeks for the first four weeks and monthly thereafter.

For statistical tests of the results of therapy, each patient's daily improvement score for each treated area was recorded at every visit, and the average scores were calculated for the 12-week period by taking the sum of the daily scores and determining the mean. The mean improvement score of all patients was determined for

Accepted for publication Dec 27, 1976.

From the Departments of Dermatology, Mayo Clinic, Rochester, Minn (Dr Muller); Cleveland Metropolitan General Hospital (Drs Belcher and Lochner) and Cleveland Clinic (Drs Roenigk and Miller), Cleveland; the College of Medicine, University of Illinois, Chicago (Dr Esterly); and the Department of Clinical Pharmacology, Hoffmann-La Roche Inc, Nutley, NJ (Dr Weissman).

Reprint requests to Department of Clinical Pharmacology, Hoffman-La Roche, Inc, Nutley, NJ 07110 (Dr Weissman).

Table 1.—Mean Improvement Scores of 28 Patients With Congenital Ichthyosis and Hyperkeratosis

Diagnosis	No. of Patients	Mean Improvement Score	
		Vitamin A Acid	Salicylic Acid
Pityriasis rubra pilaris	1	1.60	1.00
Darier's disease	2	1.00	0.67
		2.00	1.50
Ichthyosis vulgaris (t = 3.86 P = .01)	6	2.20	0.60
		(Mean 1.87 ± 0.19)	(Mean 0.61 ± 0.26)
		1.36	1.64
		2.55	1.09
		1.33	0.13
		1.83	0.00
		1.95	0.20
X-linked ichthyosis	2	3.00	3.00
		1.83	0.75
Epidermolytic hyperkeratosis	2	1.50	0.36
		2.42	0.31
Lamellar ichthyosis (t = 5.01 P = .001)	15	1.72	1.46
		(Mean 2.14 ± 0.13)	(Mean 0.80 ± 0.23)
		2.14	0.09
		1.29	0.00
		2.04	0.38
		2.30	0.00
		2.63	0.09
		2.73	0.73
		2.45	2.18
		2.05	0.09
		1.86	2.32
		2.80	0.00
		2.00	0.00
		1.88	0.00
		1.25	2.00
		3.00	1.67

Fig 1.—Lamellar ichthyosis of upper extremities. Lesion has cleared on subject's left side after treatment with tretinoin. Salicylic acid cream (control), on subject's right side, was ineffective.

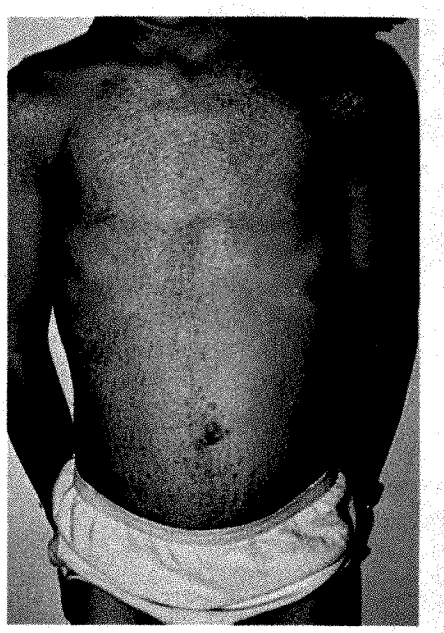

Fig 2.—Lamellar ichthyosis. Clearing has occurred on subject's left side after treatment with tretinoin. Control side patient's right was unimproved.

each medication, and the significance of the difference between the scores was obtained by the one-tailed Student's t-test.

RESULTS

Forty of the 44 patients completed 12 weeks of therapy. Four patients were dropped from the study and their data were not included in the results because the treatment period was too short for adequate evaluation of drug efficacy. Among the 12 patients with palmar-plantar hyperkeratosis, lesions of only three patients treated with tretinoin and only two treated with salicylic acid improved clinically even to a slight degree. The mean improvement score for each medication also indicated less than slight improvement, and no significant statistical difference between the two medications was detected.

For patients with ichthyosis vulgaris and lamellar ichthyosis (Table 1), the therapeutic effect of tretinoin 0.1% cream, represented by mean scores of 1.87 and 2.14, respectively, showed that tretinoin cream was definitely superior to salicylic acid 2% cream, which had mean scores of 0.61 and 0.80, respectively. The clinical difference in response of the paired treatment sites was particularly striking in the patients with lamellar ichthyosis, as shown in Fig 1 and 2.

Although all patients with lamellar ichthyosis responded most dramatically, there was also some response in patients with other ichthyosiform dermatoses, that is, ichthyosis vulgaris and X-linked ichthyosis.

Systemic reactions were absent in all 44 patients, and no significant abnormalities were detected by laboratory tests. Five patients in one clinic had elevated baseline levels of SGOT, but none of these values increased significantly during treatment, and in two patients, the values actually decreased.

Adverse reactions to therapy were restricted to local effects (Table 2) and occurred in all types of lesions treated with tretinoin 0.1% cream. The most common untoward effects were erythema, pruritus, and irritation. Fifty-nine reactions occurred in 29 of the 44 patients; 53 occurred in 26 of the 30 patients with a congenital ichthyosiform dermatosis. Local reactions were more frequently noted in sites treated with tretinoin (59 sites) than in those treated with salicylic acid (8 sites). The salicylic acid cream did not exacerbate any of the skin disorders treated.

Of the four patients dropped from the study, two did not complete the course of treatment because of exacerbation of a preexisting atopic dermatitis; they had been admitted to the study for treatment of concurrent ichthyosis vulgaris. The association of these two conditions is well documented.[18] Another patient had an impetiginized eczematous eruption at

Table 2.—Number of Adverse Reactions and Their Relation to Therapy

Reaction	Vitamin A Acid	Salicylic Acid	Drug Relationship			
			Vitamin A Acid		Salicylic Acid	
			Probable	Possible	Probable	Possible
Pruritus	15	2	15		2	
Erythema	16		16			
Burning	5		5			
Excoriation	5	1	5		1	
Tingling	1	1	1		1	
Urticaria*	1			1		
Irritation	10	1	10		1	
Blistering	1		1			
Impetiginous dermatitis†	1	1				
Eczematous eruption	1			1		
Skin tenderness	1		1			
Flare-up of atopic dermatitis	2	2	2		2	
Total	**59**	**8**	**56**	**2**	**7**	

*Diagnosis questionable.
†Remote drug relationship.

both treatment sites. Therefore, the reaction could not be attributed to either tretinoin or salicylic acid. The fourth patient, who had mild acquired ichthyosis, was dropped from the study at his request after erythema developed, and he believed that treatment was making his skin condition worse.

COMMENT

Topical application of tretinoin 0.1% cream proved to be an effective short-term treatment for ichthyotic disorders, particularly lamellar ichthyosis and ichthyosis vulgaris. Too few patients with Darier's disease and pityriasis rubra pilaris were treated to permit any conclusions except that further trials should be done in these conditions. It did not improve palmar-plantar hyperkeratosis. (It is of interest that among the 12 patients with palmar-plantar hyperkeratosis who showed little or no response to tretinoin, only two topical irritative reactions were reported, both in the same patient.) This contrasts with the remarkable improvement reported in one case of keratoderma of the palms and soles by Heiss and Gross,[7] who used 0.3% tretinoin ointment on the palms and soles. It is possible that we would have observed a therapeutic effect if a stronger concentration of tretinoin had been used.

Statistical evaluation of the clinical responses demonstrated significant differences between the two medications that favored tretinoin in ichthyotic disorders. Improvement of all lesions treated with tretinoin was rated slight to good, whereas 17 of 28 sites (60%) treated with salicylic acid did not improve. These responses are reflected in the mean improvement score (Table 1).

Fifty-six local reactions occurred with tretinoin at treated sites and were regarded as probably attributable to the medication. The reactions were mild to moderate in degree and could be controlled easily by decreasing the frequency of application. Although described as adverse reactions, the irritant effects may be related to the pharmacologic action of tretinoin and may be contributing to the desired therapeutic response, as suggested by other studies.[4,13]

In this short-term study, tretinoin has been shown to be beneficial, and this confirms the data previously reported. It remains to be determined how useful tretinoin will be in the long-term management of patients with keratinizing disorders, because it is likely that the medication will usually need to be used indefinitely.

This investigation was supported by a grant from Hoffman-La Roche, Inc.

Nonproprietary Name and Trademark of Drug

Tretinoin—*Retin-A*.

References

1. Beer P: Untersuchungen über die Wirkung der Vitamin-A-Säure. *Dermatologica* 124:192-195, 1962.
2. Stüttgen Von G: Zur Lokalbehandlung von Kertosen mit Vitamin-A-Säure. *Dermatologica* 124:65-80, 1962.
3. Frost P, Weinstein GD: Topical vitamin A acid for scaling dermatoses, abstracted. *Clin Res* 16:255, 1968.
4. Fulton JE Jr, Gross PR, Cornelius CE III, et al: Darier's disease: Treatment with topical vitamin A acid. *Arch Dermatol* 98:396-399, 1968.
5. Schuppli R, Ziegler G: Erythrodermie ichthyosiforme congenitale. *Dermatologica* 137:335, 1968.
6. Goldsmith LA, Baden HP: Management and treatment of ichthyosis. *N Engl J Med* 286:821-823, 1972.
7. Heiss HB, Gross PR: Keratosis palmaris et plantaris treatment with topically applied vitamin A acid. *Arch Dermatol* 101:100-103, 1970.
8. Mirrer E, McGuire J: Lamellar ichthyosis: Response to retinoic acid (tretinoin): A case report. *Arch Dermatol* 102:548-551, 1970.
9. Plewig G, Wolff HH, Braun-Falco O: Lokalbehandlung normaler und pathologischer menschlicher Haut mit Vitamin-A-Säure: Klinisch, histologische und elektronemikroskopische Untersuchungen. *Arch Klin Exp Dermatol* 239:390-413, 1971.
10. Frost P, Weinstein GD: Topical administration of vitamin A acid for ichthyosiform dermatoses and psoriasis. *JAMA* 207:1863-1868, 1969.
11. Schumacher A, Stüttgen G: Vitamin-A-Säure bei Hyperkeratosen, epithelialen Tumoren und Akne: Orale und lokale Anwendung. *Dtsch Med Wochenschr* 96:1547-1551; 1563-1564, 1971.
12. Schuppli R, Ziegler G: Morbus Darier. *Dermatologica* 137:343, 1968.
13. Standlee TL, Tindall JP: Clinical trials with topical vitamin A acid. *South Med J* 64:1497-1502, 1971.
14. Thomson J, Milne JA: The use of retinoic acid in congenital ichthyosiform erythroderma. *Br J Dermatol* 81:452-455, 1969.
15. Goette DK: Zosteriform keratosis follicularis cleared with topically applied vitamin A acid. *Arch Dermatol* 107:113-114, 1973.
16. Hesbacher EN: Zosteriform keratosis follicularis treated topically with tretinoin. *Arch Dermatol* 102:209, 1970.
17. Günther SH: Vitamin A acid in treatment of polyplantar keratoderma. *Arch Dermatol* 106:854, 1972.
18. Krueger GG, Molk L, Kahn G: Exacerbation of atopic dermatitis. *Arch Dermatol* 105:405-406, 1972.

Defective Monocyte Chemotaxis in Mycosis Fungoides

Larry E. Seitz, MD; Loren E. Golitz, MD; William L. Weston, MD; John E. Aeling, MD; Roberta D. Dustin

• Monocyte-macrophage function was studied in 14 patients with histologically confirmed mycosis fungoides. Three component parts of the monocyte-macrophage system were examined. Monocyte bacterial phagocytosis and bacterial killing were normal. However, a defect in directional mobility (chemotaxis) was found in patients with mycosis fungoides ($P < .0025$) when compared to 35 healthy controls. Defective chemotaxis was present regardless of disease stage or therapy. This defect in monocyte chemotaxis represents a previously unrecognized immune deficiency and may help explain the frequent infections found in patients with mycosis fungoides.

(*Arch Dermatol* 113:1055-1057, 1977)

Mycosis fungoides is a lymphoma that is first manifest in the skin and later may invade visceral organs. It has a variable clinical course of one to many years and is characterized by its progression through three clinical stages. The last two stages, the plaque and tumor stage, are frequently complicated by cutaneous bacterial infections that may lead to septicemia, the major cause of death.[1-4]

This association with frequent infections led previous investigators to study immune responses such as lymphocyte function in patients with mycosis fungoides. Despite extensive studies, no consistent defect of the lymphocyte system was uncovered. Therefore, we chose to investigate another aspect of immunity, the function of the monocyte-macrophage system. We report the results of quantitative assays of monocyte-macrophage function in 14 patients with mycosis fungoides.

Accepted for publication Sept 10, 1976.

From the Department of Dermatology, University of Colorado School of Medicine, Denver.

Reprint requests to Department of Dermatology, University of Colorado School of Medicine, 4200 E 9th Ave, Denver 80220 (Dr Seitz).

SUBJECTS AND METHODS

Fourteen patients were selected from the mycosis fungoides clinic at the University of Colorado Medical Center. All were registered with the National Mycosis Fungoides Cooperative Group and were diagnosed histologically as having mycosis fungoides by the national pathology panel. The patients were representative of all three stages of the disease and had their disease for periods of time ranging from a few months to 35 years. Seven of the patients had undergone x-ray therapy, including conventional and electron beam therapy, and six had received chemotherapy, either topically, systemically, or both. Five had received only topical steroids. Concomitant therapy did not exclude patients from this study. The two patients with stage 3 mycosis fungoides were lymphopenic (less than 1,000 lymphocytes/cu mm).[5] Two of the 14 patients (No. 1 and 11 on the Table) had cutaneous infections at the time of the study. Thirty-five controls (mean age, 35.2 years) were selected from healthy young adults. The majority of these were studied concomitantly with patients with mycosis fungoides. Three component parts of the monocyte-macrophage system were investigated. This included chemotaxis, bacterial phagocytosis, and bacterial-killing power. All assays were performed on suspensions of monocytes obtained from heparinized peripheral venous blood and separated on ficoll-hypaque gradients.[6] Monocyte phagocytosis and killing were measured as the ability to ingest and kill *Staphylococcus aureus* 502A using the modified methods of Tan et al.[7]

Chemotaxis was measured by the method described previously[8] using micro-

Summary of Data on Patients With Mycosis Fungoides

Patient/Age, yr Duration of Disease, yr	Stage	Previous Therapy*	Current Therapy*	WBC	Absolute Lymphocytes Count	Phagocytosis, % EB†	Killing, % IB‡	Chemotaxis, % Cells Responding
1/66/6	III	None	NH_2 Conv x-ray	3,200	736	11	1	5.0
2/47/1	Remission	Conv x-ray	. . .	5,200	1,664	18	0	3.8
3/61/8	I	MTX, E-beam, DNCB	Steroids	7,150	2,065	15	1	5.4
4/71/1	II	None	Steroids, NH_2	7,900	1,501	8	0	7.6
5/60/3	I	Conv x-ray, steroids	Steroids	6,400	1,088	43	1	2.4
6/51/one half	I	Steroids	Steroids	5,800	1,102	25	1	3.9
7/58/20	II	E-beam, NH_2, steroids	Steroids	5,000	1,350	58	5	4.5
8/56/one half	I	Steroids	Steroids	10,000	2,500	126	7	3.9
9/55/5	I	Steroids	Steroids	ND§	ND	ND	ND	3.0
10/60/2	II	NH_2, steroids	NH_2, steroids	ND	ND	ND	ND	5.1
11/58/3	III	E-beam, photon, NH_2, urea	None	3,000	750	ND	ND	4.6
12/58/11	I	Steroids	Steroids	7,400	1,035	8	5	2.2
13/39/1	I	Systemic Ster, conv x-ray	Steroids	8,000	2,000	21	11	1.0
14/67/5	I	None	Steroids	3,400	1,849	ND	ND	1.4

*Conv x-ray indicates conventional superficial x-ray; MTX, methotrexate; E-beam, electron beam x-ray; DNCB, dinitrochlorobenzene; Steroids, topical steroid unless otherwise stated; NH_2, nitrogen mustard; Photon, total body photon x-ray beam; Urea, topical carmustine; Systemic Ster, steroids given by parenteral or oral administration.

†% EB indicates percent of extracellular bacteria surviving.

‡% IB indicates percent of intracellular bacteria surviving.

§ND indicates not done.

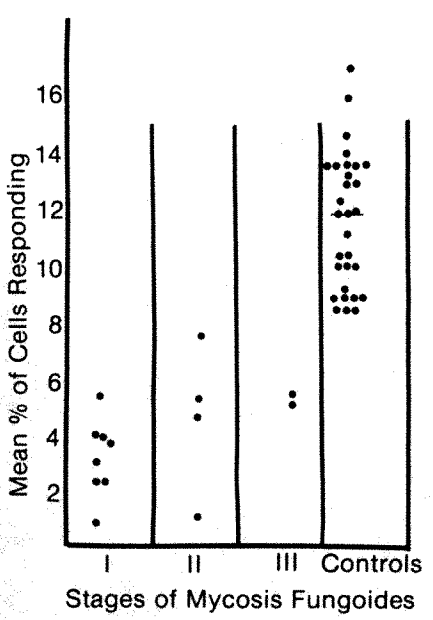

Scattergram of monocyte chemotaxis in patients with mycosis fungoides and controls. Mycosis fungoides, mean 4.3 ± 3.4 with control mean of 11.6 ± 6.0.

chemotaxis plastic chambers that were separated into two compartments by a sandwich of two Millipore filters. An 8.0-μ filter was placed on top and a 0.45-μ filter was placed below that permitted counting of any cells that passed completely through the upper filter and were, therefore, trapped by the lower filter. A standard chemotactic attractant used in this assay was a 10% solution of pooled AB negative human serum in RPMI-1640 tissue culture media activated with *Escherichia coli* lipopolysaccharide endotoxin type 0111:B4 at 200 μg/ml for 30 minutes at 37 C. This amount of endotoxin has been found to be the most effective in activating the C5a component of the complement system.[6] Aliquots of 0.5 ml of endotoxin-activated serum were stored and frozen at −70 C. Attractants were added to the lower chamber and 0.25 ml of a concentration of 1×10^6 monocytes/ml (250,000 monocytes) was added to the upper compartment. All assays were performed in triplicate. Chambers were incubated at 37 C with 5% carbon dioxide and 100% humidity for five hours. After incubation, the filters were removed and fixed in absolute methanol and rinsed in distilled water. Filters were stained using hematoxylin and bluing agents and then dehydrated in a standard fashion and cleared with xylene. After mounting on a slide and allowing to dry overnight, the filters were examined at ×430. Ten fields were counted. The cells on the upper surface of the 8.0-μ filter (cells that did not migrate) were compared to those migrating through the filter (including those within the filter) plus those that passed through the 8.0-μ filter and were entrapped on the surface of the 0.45-μ filter. The results were expressed as the percentage of total cells migrating using the formula: 100 × total number of cells migrating/total number of cells migrating and not migrating.

RESULTS

Monocyte phagocytosis and killing of *S aureus* 502A was normal in nine of the ten patients studied (Table). Phagocytosis expressed as percentage extracellular bacteria surviving (% EB) was 18.5 ± 6.2 (mean ± SD) for the control group and 33.3 ± 15.9 (mean ± SD) for patients with mycosis fungoides ($P = .20$). Bactericidal activity expressed as percentage intracellular bacteria surviving (% IB) was 2.0 ± 0.9 (mean ± SD) for the control group and 3.2 ± 1.5 (mean ± SD) for patients with myco-

sis fungoides ($P = .50$). One subject had evidence of poor bacterial phagocytosis (126% EB) (Table).

Thirteen of fourteen patients with mycosis fungoides demonstrated defective cellular chemotaxis of their mononuclear leukocytes. The mean of this group of patients was 4.3 ± 3.4 (mean $\pm$ SD) with a control of 11.6 ± 6.0 (mean ± 2 SD). This was significantly depressed ($P = .0025$) when compared to the 35 controls by χ^2 analysis (Figure). Only one of these 14 patients with mycosis fungoides demonstrated chemotaxis values within 2 SD of normal controls.

COMENT

Previous investigations of the immune system in mycosis fungoides have focused on lymphocyte number and function. Most recently, Tan et al[7] published their findings of B and T cell function in 19 patients. They found no evidence of immune suppression even in those who had the disease for many years. Their studies included quantitation of B cells in the peripheral blood and an attempt to find these cells in the skin tumors. Also normal were serum immunoglobulin levels, except for a slightly elevated IgE value. Serum complement components C3 and C4 were normal. T cell function as measured by lymphocyte transformation and reaction in mixed lymphocyte culture was normal.

Investigation of immune status in mycosis fungoides by Blaylock et al[8] also revealed relatively normal immunological responses. Evaluation of B cell function revealed a normal anamnestic response to an *E coli* antigen and normal levels of circulating immunoglobulins. Quantitative serum assays for IgM and IgG were normal, whereas the serum IgA level was frequently elevated. Delayed hypersensitivity as measured by a battery of nine skin test antigens and the ability to sensitize to dinitrochlorobenzene were similarly found to be normal. The development of contact sensitivity to topical nitrogen mustard in many patients with mycosis fungoides is additional evidence of the competence of this aspect of their cell-mediated immunity.[9,10] Clendenning[11] reported that all 14 of the patients he studied with mycosis fungoides retained the ability to reject a homograft and to accept autografts until the terminal stage of their disease. Conflicting evidence was reported by Rostenberg and Bluefarb[12] who found a decreased number of positive delayed skin tests in patients with mycosis fungoides and concluded that there was a general depression of delayed-type hypersensitivity.

The demonstration of normal immune response in the studies of Blaylock[8] and Tan et al[7] may reflect the selection of cases with patients with early mycosis fungoides because an absolute lymphopenia in the peripheral blood is a well-documented event in advanced mycosis fungoides. Lymphopenia was present in 45% of the 132 patients with tumor stage mycosis fungoides reported by Fuks et al,[13] in 76% of the 165 patients with mycosis fungoides reported by Cyr et al,[14] and in all four patients reported by Edelson et al.[15]

Despite the failure to detect an immunological defect in prior studies of patients with mycosis fungoides, there is considerable clinical evidence that infection is a major difficulty in these patients. All 34 patients in the study by Casazza et al[1] and all 17 patients in the study by Block et al[2] had skin infections. Infections of tissues other than skin were also common. Seventy-five percent of Casazza et al's[1] 34 patients, and 67% of the patients reported by Epstein et al[3] had extracutaneous infections, most notably bacterial pneumonia.[1-4] Although *Pseudomonas* and *S aureus* are the most frequently found pathogens, unusual organisms and opportunistic bacteria are also frequently found and accounted for eight of 21 cases of septecemia in one series.[9] Opportunistic pathogens, such as disseminated herpes simplex,[1] *Candida albicans*,[1-3] *Aspergillus*,[4] toxoplasmosis,[4] and the virus agent of multifocal leukoencephalopathy[16] have been demonstrated in mycosis fungoides as in other conditions with impaired host defenses.

Despite the apparent differences in immune response when comparing Tan et al's[7] patients with mycosis fungoides with those with Hodgkin[17] disease, the incidence of infection, the types of microorganisms involved, the time of onset of infections, the number of infectious episodes per patient, and the incidence of septicemia are virtually identical in both diseases. The same infection data are also found in patients with lymphosarcoma and reticulum cell sarcoma.[17] We speculated that a defect in the monocyte-macrophage system was a possible explanation for this contradiction. Our finding of depressed monocyte chemotaxis in 13 of 14 patients with mycosis fungoides represents a newly recognized in vitro immunologic defect in this disease. Since attraction of monocytes to tissue sites is an important host defense against invading microorganisms, faulty chemotaxis may partially explain the frequent infections in such patients.

Defective monocyte chemotaxis in mycosis fungoides occurs regardless of the stage of the disease, regardless of the presence or absence of therapy, and despite preservation of normal monocyte phagocytosis and bactericidal activity. A selective defect in directional mobility of monocyte-macrophages occurs in mycosis fungoides and may be a useful marker for this disease.

References

1. Casazza AR, Duvall CP Carbone PP: Infection in lymphoma. *JAMA* 197:710-716, 1966.
2. Block JB, Edgecomb J, Eisen A, et al: Mycosis fungoides: Natural history and aspects of its relationship to other malignant lymphomas. *Am J Med* 34:228-235, 1963.
3. Epstein EH Jr, Levin DL, Croft JD Jr, et al: Mycosis fungoides: Survival, prognostic features, response to therapy, and autopsy findings. *Medicine* 51:61-72, 1972.
4. Reed RJ, Cummings CE: Malignant reticulosis and related conditions of the skin. *Cancer* 19:1231-1247, 1966.
5. Valentine WN: The leukopenic state and agravulocytosis, in Beeson PB, McDermott W (eds): *Textbook of Medicine*. Philadelphia, WB Saunders Co, 1975, p 1528.
6. Weston WL, Dustin RD, Hecht SK: Quantitative assays of monocytemacrophage function in man. *J Immunol Methods* 8:213-222, 1975.
7. Tan RSH, Butterworth CM, McLaughlin H, et al: Mycosis fungoides—a disease of antigen persistence. *Br J Dermatol* 91:607-616, 1974.
8. Blaylock WJ, Clendenning WE, Carbone PP, et al: Normal immunologic reactivity in patients with the lymphoma mycosis fungoides. *Cancer* 19:233-236, 1966.
9. Ratner AC, Waldorf DS, VanScott EJ: Alterations of lesions of mycosis fungoides lymphoma by direct imposition of delayed hypersensitivity reactions. *Cancer* 21:83-88, 1968.
10. Waldorf DS, Haynes HA, VanScott EJ: Cutaneous hypersensitivity and desensitization to mechlorethamine in patients with mycosis fungoides lymphoma. *Ann Intern Med* 67:282-289, 1967.
11. Clendenning WE, VanScott EJ: Skin autografts and homografts in patients with the lymphoma mycosis fungoides. *Cancer Res* 25:1844-1850, 1965.
12. Rostenberg A, Bluefarb SM: Cutaneous reactions in the lymphoblastomas. *Arch Dermatol* 69:195-205, 1954.
13. Fuks ZY, Bagshaw MA, Farber EM: Prognostic signs and the management of the mycosis fungoides. *Cancer* 32:1385-1395, 1973.
14. Cyr DP, Geokas MC, Worsley GH: Mycosis fungoides: Hematologic findings and terminal course. *Arch Dermatol* 94:558-573, 1966.
15. Edelson RL, Kirkpatrick CH, Shevach EM, et al: Perferential cutaneous infiltration by neoplastic thymus-derived lymphocytes. *Ann Intern Med* 80:685-692, 1974.
16. Caldwell I, Dayan AD: Mycosis fungoides and progressive multifocal leukoencephalopathy. *Br J Dermatol* 82:176, 1970.
17. Aisenberg AC: Hodgkin's disease: Prognosis, treatment and etiologic and immunologic considerations. *N Engl J Med* 270:508-514, 565-570, 617-622, 1964.

Allergic Contact Dermatitis to Topical Fluorouracil

Lt Col Detlef K. Goette, MC, USA, Lt Col Richard B. Odom, MC, USA

• We designed a prospective and retrospective study to determine the incidence of allergic contact dermatitis to topical application of fluorouracil. Intracutaneous and epicutaneous skin tests of various fluorouracil concentrations were given to patients who were to be treated with the drug for actinic keratoses (group A) and to patients who had previously been treated with fluorouracil for actinic keratoses (group B). Six patients in group B had allergic contact dermatitis to topical fluorouracil. The common clinical characteristic of the six patients was a severe pruritic eruption at the site of fluorouracil application. Allergic contact dermatitis should be suspected in the presence of severe pruritus or a severe eczematous response in patients treated with topical fluorouracil.

(*Arch Dermatol* 113:1058-1061, 1977)

Recently, we reported[1] two cases of allergic contact dermatitis to topical fluorouracil in patients treated for actinic keratoses of the face. Because a significant number of patients developed a vigorous reaction during this treatment, we wondered about the incidence of allergic contact dermatitis to fluorouracil. Such a reaction would be extremely difficult to differentiate from the well-known irritancy from topical application of fluorouracil. Therefore, we designed a prospective and retrospective study to determine the incidence of allergic contact dermatitis by means of intracutaneous and epicutaneous skin tests in patients who were to be treated and in those patients who had been previously treated with fluorouracil for actinic keratoses of the face, scalp, arms, and hands.

Accepted for publication Nov 22, 1976.

From the Dermatology Service, Department of Medicine, Letterman Army Medical Center, Presidio of San Francisco, Calif.

The opinions or assertions contained herein are the private views of the authors and are not to be construed as official or as reflecting the views of the Department of the Army or the Department of Defense.

Reprint requests to Technical Publications Editor, Letterman Army Medical Center, Presidio of San Francisco, CA 94129 (Dr Goette).

MATERIALS AND METHODS

Group A (Prospective Study)

Group A consisted of 35 patients who had never been treated with topical fluorouracil (fluorouracil virgins) for actinic keratoses. All of these patients were tested intracutaneously on the left forearm with the following concentrations of fluorouracil in sterile water: 50 mg/ml; 25 mg/ml; and 10 mg/ml. The intracutaneous injection consisted of 0.1 ml of each strength of fluorouracil. The test sites were read after 48 hours and observed for a period of six days. Only 12 of the 35 patients had epicutaneous skin tests before treatment. These tests were done on their backs or on the inner aspect of the upper arm with 1%, 5%, and 10% concentrations of fluorouracil in petrolatum. Forty-eight hours later, all 35 patients were questioned regarding any reactions at any test sites. They were questioned about erythema, papules, vesicles, itching, and burning. If any of these reactions were noted, the patient was seen by one of the physicians the same day. Patients were requested to observe the test sites for a total of six days for any other reactions.

If no reactions had occurred, the patient started applications of 1% fluorouracil in propylene glycol twice daily to the face or a 5% fluorouracil cream to the scalp, forearm and/or the hands for 3 to 5 weeks (4 weeks average). Posttreatment testing also was done intracutaneously and epicutaneously in all 35 patients. Within three to eight weeks after completion of the treatment, all patients were tested intracutaneously with the same concentrations of freshly prepared fluorouracil solutions that were made each week. Simultaneously, epicutaneous tests were performed with 1%, 5%, and 10% concentrations of fluorouracil. The intracutaneous and epicutaneous tests were read and recorded at 48 and 72 hours.

Group B (Retrospective Study)

Group B consisted of 35 patients who had been treated for actinic keratoses with topical fluorouracil (fluorouracil experienced) in the preceding three months to three years, on one or more occasions. All patients received intracutaneous tests as described for group A. Twenty of the 35 patients had epicutaneous skin tests done in addition to the intracutaneous tests. The procedure for reading the tests was the same as described for group A.

Five of the fluorouracil-experienced patients were retreated and at the conclusion of treatment were retested in the fashion described for group A.



Fig 1.—Reaction 48 hours after intracutaneous injections of 0.1 ml of 50 mg/ml (top), 25 mg/ml (center), and 10 mg/ml (bottom) of fluorouracil in patient 6. (Skin markings at reaction sites are erroneous. Markings should read 5 mg/.1 ml, 2.5 mg/.1 ml, and 1 mg/.1 ml).

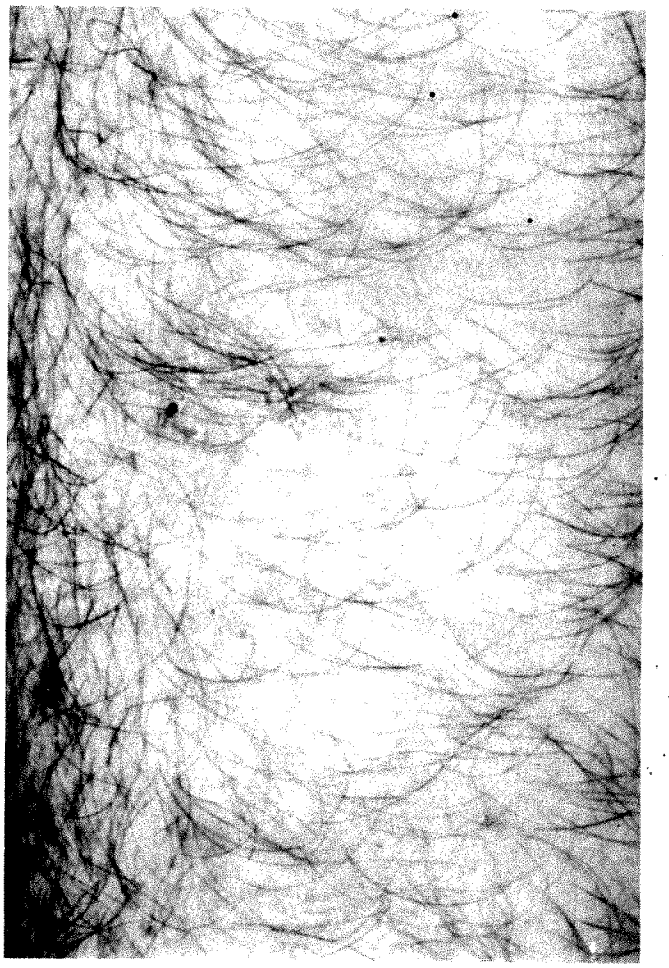

Fig 2.—Spontaneous flare of previously negative intracutaneous fluorouracil test sites two weeks after initiating a second course of topical fluorouracil for actinic keratoses of face (patient 5).

RESULTS

Group A

Of the 35 patients tested intracutaneously before fluorouracil treatment, one person reacted with asymptomatic, macular erythema at the testing sites. Of the 12 patients tested epicutaneously before treatment, none had any reactions to the patch tests.

Group B

Of the 35 patients tested intracutaneously, six reacted with patches of erythematous induration, papules, and minute vesicles (Fig 1). Pruritus was intense. All six patients reacting to intracutaneously injected fluorouracil had 3+ to 1+ epicutaneous reactions as outlined in the Table. Two patients (1 and 5 in the Table) experienced a moderate to severe pruritic, widespread dermatitis during fluorouracil treatment, while two other patients (2 and 6 in Table 1) noted a moderate local flare reaction. Patient 2 (Table) experienced similar reactions on the chin. The dermatitis was caused by the patient's nervous rubbing with her fluorouracil-treated hand on her chin. Patient 5 (Table), who developed fluorouracil sensitivity during a second course of treatment, had two to three intracutaneous test sites, initially negative, that flared two weeks after the onset of fluorouracil application to the face (Fig 2). The severity of the facial eruption necessitated interruption of therapy. Of the 29 remaining members of group B, two developed nonspecific, flat, asymptomatic, erythematous patches at the intracutaneous test sites not matched by any reaction at the epicutaneous level, while the rest of the sites were negative for both tests.

Histology

Biopsy specimens were taken from the intracutaneous test sites of patients 1 and 2 (Table), and in patient 1 (Table) a biopsy was done on an epicutaneous skin test specimen also. All three specimens demonstrated essentially similar findings; the epidermis showed mild spongiosis and round cell exocytosis. The papillary and upper dermal vessels revealed a mild to moderate perivascular infiltration with lymphocytes, histiocytes, and occasional eosinophils (Fig 3). These findings are consistent with allergic contact dermatitis but not compatible with an irritant dermatitis.

COMMENT

Topical fluorouracil therapy is considered the treatment of choice for diffuse actinic keratoses and erythroplasia of Queyrat[2] and has been used for the treatment of Bowen's disease,[3] actinic cheilitis, superficial basal cell carcinoma, and squamous cell carcinoma.[4]

Results of Intracutaneous and Epicutaneous Skin Tests With Fluorouracil, Group B (Six Patients)

Patient No.	Skin Tests: Intracutaneous Reaction, mm 5.0 mg	2.5 mg	1.0 mg	Epicutaneous Reaction, +s 10%	5%	1%	Reactions: Pruritus	Flare	Widespread	Biopsy	Courses of Fluorouracil
1	25	18	15	...	...	2	Severe	Absent	Severe	Yes	2 (1%)*
2	18	23	22	3	3	2	Moderate	Moderate	Absent	Yes	2 (1%; 5%)
3	25	12	15	3	2	1	Severe	Absent	Absent	...	1 (5%)
4	18	12	8	3	2	(1)	Severe	Absent	Absent	...	2 (5%)
5	18	16	9	1	3	...	Severe	Absent	Moderate	...	2 (5%)
6	27	21	17	3	3	...	Severe	Moderate	Absent	...	2 (1%)

*Numbers in parentheses indicate percentage of fluorouracil in preparation.

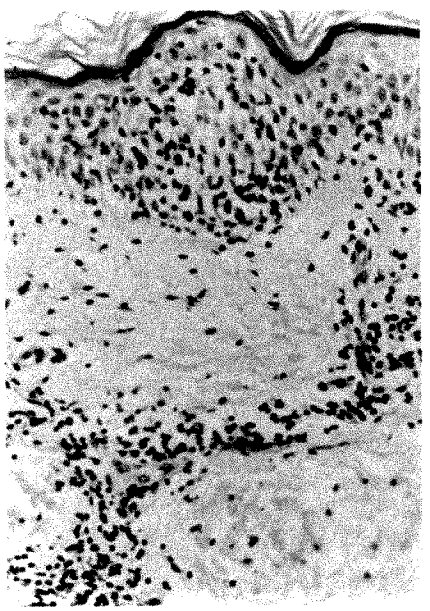

Fig 3.—Biopsy specimen of intracutaneous fluorouracil reaction site (patient 1) demonstrating epidermal spongiosis, exocytosis, papillary edema, and a moderately dense perivascular round cell inflammatory infiltrate (hematoxylin-eosin, original magnification ×100).

Topical fluorouracil usually elicits a moderate to severe irritation at the diseased site with symptoms and signs of burning, itching, stinging, erythema, and scaling often aggravated by exposure to direct sunlight. Disease-free fluorouracil-treated skin usually remains clinically normal, although Zelickson et al[5] have discovered mild histological and ultramicroscopical changes. Side effects to topical fluorouracil other than irritancy are rare, but allergic contact dermatitis to fluorouracil, or its vehicle, or preservatives therein, has been noted. Sams,[6] in 1968, reported four cases of contact dermatitis to fluorouracil preparations. In two of his cases, he elicited a positive reaction to the vehicle; in one case, to propylene glycol, and in the other to both the wool wax and to alcohol esters of the aquaphor base. In the remaining two cases, he obtained eczematous reactions to fluorouracil and not to the vehicles in the patch tests. Sams'[6] article seems to be the first to point out the possibility of allergic sensitization to topically applied fluorouracil preparations.

In 1975, Mansell et al[7] described the development of delayed hypersensitivity reactions in patients treated with topical fluorouracil (5% to 20% creams) for cutaneous malignancies. They studied 25 patients retrospectively and were able to elicit positive responses in 17 patients (68%) after intracutaneous testing with serially diluted concentrations of fluorouracil (50 mg/ml to 0.4 mg/ml of sterile preservative-free water). In a prospective series of 15 patients tested in like manner, they found that 11 patients (73%) developed sensitization to fluorouracil during the treatment. They eliminated the possibility of an irritancy reaction to fluorouracil mostly on a histological basis. Epicutaneous skin tests were not done in their series.

Comparing the incidence of induction of delayed hypersensitivity to fluorouracil of approximately 70% in Mansell's series[7] to that of 0.6% in Sams' series,[6] a marked discrepancy becomes apparent. While Mansell et al[7] relied exclusively on intracutaneous skin tests, Sams[6] performed only epicutaneous skin tests to fluorouracil.

We believed that the combination of intracutaneous and epicutaneous tests in varying strengths of fluorouracil to fluorouracil-virgin and fluorouracil-experienced groups might allow a more accurate evaluation of the subject of allergic contact dermatitis to fluorouracil.

The absence of any reactions in group A (fluorouracil virgins) on challenge after initial intracutaneous injections and after three to five weeks of 1% or 5% fluorouracil topical preparations rules out any possibility of allergic sensitization or irritant reaction. The asymptomatic, macular patches of erythema at the sites of the initial injections of fluorouracil in four patients in groups A and B were interpreted as irritant phenomena. However, the preceding erythema was not necessary for the development of hyperpigmentation; it was observed in several individuals in whom erythema did not develop at intracutaneous injection sites. Similar erythema and subsequent hyperpigmentation had been observed previously, especially after administration of fluorouracil and bleomycin[8] given for systemic effect.

The fact that none of the patients in group A showed any reactions to intracutaneous and epicutaneous skin tests after three to five weeks of topical fluorouracil therapy is in stark contrast to the report of Mansell et al[7] of development of sensitivity to fluorouracil in 73% of their group of prospective patients. An explanation for the obvious discrepancy may be found in the fact that Mansell et al[7] were treating their patients for precancerous conditions and basal cell and squamous cell carcinomas with 5% to 20% topical fluorouracil. The patients may have been treated for longer periods with higher concentrations of fluorouracil that caused greater absorption and probably higher sensitization. This observation may account for the fact that five of our six cases of fluorouracil sensitivity occurred in patients who had received two courses of fluorouracil (group B). The repetitive insult led to further antigen exposure, thus enhancing the chance of development of sensitization. All six patients in our group B had a severe irritant reaction to fluorouracil before the signs of allergic contact dermatitis became prominent.

Despite the allergic reaction, all patients had excellent therapeutic results from topical fluorouracil. In view of the high incidence of allergic contact dermatitis in the Mansell et al[7] series, one could consider immunological mechanisms a factor in the therapeutic response of premalignant conditions. However, the overall incidence of 8.6% allergic contact dermatitis in our study indicates that the development of delayed hypersensitivity is not a prerequisite for an adequate therapeutic response.

Additionally, the occurrence of a widespread pruritic dermatitis in nontreated areas of the skin in two patients supports the hypothesis of increased absorption and hematogenous dissemination of the allergen with elicitation of allergic contact dermatitis in distant sites. This allergic dermatitis differs from the dermatitis confined to mostly sun-exposed areas in patients receiving fluorouracil therapy for systemic effect for carcinomatosis. The systemically administered fluorouracil apparently eradicates actinic keratoses in these patients with the appearance of an irritant dermatitis similar to that seen after topical application of fluorouracil. Such an observation was initially reported by Falkson and Schulz[8] in 1962 and later by Omura and Torre[9] in 1969.

The following criteria may be useful for the differentiation of an allergic from an irritant contact dermatitis to topical fluorouracil: (*a*) development of a severely pruritic eczematous eruption at the site of contact with a topical fluorouracil preparation; (*b*) development of a widespread pruritic dermatitis away from the treated area during fluorouracil treatment or the occurrence of a flare phenomenon at a site previously exposed to the drug; (*c*) development of a positive epicutaneous skin test reaction to preservative-free test materials of fluorouracil in concentrations of 5% or 10%; (*d*) development of a pruritic indurated erythema with papules or vesicles at the site of the intracutaneous injections (0.1 ml injections of 50 mg/ml, 25 mg/ml, and 10 mg/ml of fluorouracil in sterile water); (*e*) excellent correlation of the intracutaneous and epicutaneous reactions; and (*f*) compatible histological findings.

The development of a severely pruritic eczematous dermatitis at the site of fluorouracil application in a fluorouracil-experienced patient, should alert the clinician to the possibility of an acute allergic contact dermatitis to the drug. The simple testing methods outlined in this article will readily confirm or negate this diagnosis.

Since acceptance of this article, we have seen an additional patient who developed widespread allergic contact dermatitis to fluorouracil during his third course of treatment over a five-year period. Also, he experienced a flare phenomenon of his dermatitis when skin-tested in the above-described fashion.

Nonproprietary Name and Trademarks of Drug

Fluorouracil—*Efudex, Fluoroplex.*

References

1. Goette DK, Odom RB: Allergic contact dermatitis to topically applied 5-fluorouracil. *Arch Dermatol* 113:196-198, 1977.
2. Goette DK, Carson T: Erythroplasia of Queyrat: Treatment with topical 5-fluorouracil. *Cancer* 38:1498-1502, 1976.
3. Jansen GT, Dillaha CT, Honeycutt WM: Bowenoid conditions of the skin: Treatment with topical 5-fluorouracil. *South Med J* 69:185-188, 1967.
4. Klein E, Stoll HL, Milgrom H, et al: Tumors of the skin: XLI. Topical 5-fluorouracil for epidermal neoplasms. *J Surg Oncol* 3:331-349, 1971.
5. Zelickson AS, Mottaz J, Weiss LW: Effects of topical fluorouracil on normal skin. *Arch Dermatol* 111:1301-1306, 1975.
6. Sams WM: Untoward response with topical fluorouracil. *Arch Dermatol* 97:14-22, 1968.
7. Mansell PW, Litwin MS, Ichinose H, et al: Delayed hypersensitivity to 5-fluorouracil following topical chemotherapy of cutaneous cancers. *Cancer Res* 35:1288-1294, 1975.
8. Falkson G, Schulz EJ: Skin changes in patients treated with 5-fluorouracil. *Br J Dermatol* 74:229-236, 1962.
9. Omura EF, Torre D: Inflammation of actinic keratoses due to systemic fluorouracil therapy. *JAMA* 208:150-151, 1969.

CORRECTION

Typographical Error.—In the article "Leukocyte Migration Inhibition Assay (LIF) in Nickel Contact Dermatitis," which appeared in the December issue of the ARCHIVES (112:1741-1744, 1976), line 14 of column 3 on page 1742 should have read "tubes. All but approximately 5 mm. . ."

Utilization of Physician Services for Dermatologic Complaints

The United States, 1974

Robert S. Stern, MD; Marie-Louise Johnson, MD, PhD; James DeLozier, MD

• The National Ambulatory Medical Care Survey provides data on the "who," "for what complaint," and "to whom" for office visits to office-based physicians. In 1974, complaints referable to the skin accounted for 44 million physicians visits. This represents 7% of the 634 million visits to physician offices made during this period. Dermatologists accounted for 34% of all visits for skin complaints. General and family practitioners accounted for 40% of such encounters. Office visits prompted by dermatologic complaints were frequently less than 16 minutes long. Each office-based dermatologist accounted for an average of 5,600 patient visits per year. According to the dermatologist's diagnosis, 31% of these visits were prompted by acne; warts accounted for an additional 8%.

(*Arch Dermatol* 113:1062-1066, 1977)

This report presents data about office visits for dermatologic complaints in the United States in 1974. It is based on provisional data generated by the National Ambulatory Medical Care Survey (NAMCS) and provides information of the characteristics of patients coming to physicians' offices for care of dermatologic complaints. In addition, the survey provides comparisons of the type of patients seen by various specialists, the direction of physician visits, and physician follow-up plans. This information gives a clearer picture of the "who," "for what," and "to whom" with respect to physician visits motivated by dermatologic illness in this country. When analyzed with information on the prevalence of dermatologic disease that will be available as a result of the National Center for Health Statistics Health and Nutrition Examination Survey, better determination of the magnitude of unmet needs for dermatologic services will be possible.

Accepted for publication Nov 10, 1976.

From the Center for Community Health and Medical Care and Department of Dermatology, Harvard Medical School, Boston (Dr Stern); the Department of Dermatology, New York University School of Medicine, New York (Dr Johnson); and the National Center for Health Statistics, Department of Health, Education and Welfare, Rockville, Md (Dr DeLozier).

Reprint requests to Department of Dermatology, Beth Israel Hospital, 330 Brookline Ave, Boston 02215 (Dr Stern).

METHODS

The NAMCS, described in detail elsewhere, is an ongoing effort to collect information relating to ambulatory visits to a national sample of office-based physicians.[1] A randomly selected, geographically proportional sample of physicians in "office-based, patient care practices" was selected for monitoring. A total of 3,581 such physicians drawn from a universe of 184,386 physicians identified as being office-based cooperated in the 1974 data collection.

Each participating physician was visited prior to the period of data collection by NAMCS staff for thorough instruction in the use of data forms. During a randomly assigned seven-day period, each physician maintained a log of all office visits and completed encounter forms (Figure) on a systematic sample of patients.

The 3,581 participating physicians completed encounter forms for a total of 61,158 visits during 1974. These NAMCS data allowed an estimate of total 1974 physician office visits in the United States of 634 million. The analysis of data where dermatologic complaints were the principal stated reason for physician visits to any practitioner and all visits to a dermatologist provided a clearer picture of the "who," "for what," and "to whom" of the demand for medical care for dermatologic complaints. This analysis has been carried out with the full cooperation of the National Center for Health Statistics. To facilitate this analysis we developed a dermatologically oriented grouped classification for the NAMCS Symptom Classification (Table 1).[1]

RESULTS: VISITS FOR DERMATOLOGIC COMPLAINTS

Total

During 1974, a total of 44 million visits were made to office-based physicians for complaints referable to the skin. This represents 7% of the estimated 634 million visits to office-based physicians during this time. Visits for dermatologic complaints exceeded the number of visits prompted by the most common symptomatic problems seen in office practice, including "problems of the lower extremity" (26 million visits, 1973 and 1974) and throat soreness (21 million visits in 1973 and 1974), as well as the combined total of visits for pregnancy and routine gynecologic examinations (39 million in 1973 and 1974).[2]

Sex Distribution

Women accounted for 60% (26 million) of all visits for skin complaints. This percentage was the same as the proportion of all ambulatory visits made by women. To correct for the greater female population in the United States, age- and sex-specific rates of visits per year were calculated (Table 2). Except for the group under 15 years old, women more frequently attended a physician for a dermatologic complaint than did men. For

ASSURANCE OF CONFIDENTIALITY—All information which would permit identification of an individual, a practice, or an establishment will be held confidential, will be used only by persons engaged in and for the purposes of the survey and will not be disclosed or released to other persons or used for any other purpose.

A № 048512

1. DATE OF VISIT Mo / Day / Yr

PATIENT RECORD

NATIONAL AMBULATORY MEDICAL CARE SURVEY

2. DATE OF BIRTH Mo / Day / Yr

3. SEX
1 ☐ FEMALE
2 ☐ MALE

4. COLOR OR RACE
1 ☐ WHITE
2 ☐ NEGRO/BLACK
3 ☐ OTHER
4 ☐ UNKNOWN

5. PATIENT'S PRINCIPAL PROBLEM(S) COMPLAINT(S), OR SYMPTOM(S) THIS VISIT *(In patient's own words)*
a. MOST IMPORTANT
b. OTHER

6. SERIOUSNESS OF PROBLEM IN ITEM 5a *(Check one)*
1 ☐ VERY SERIOUS
2 ☐ SERIOUS
3 ☐ SLIGHTLY SERIOUS
4 ☐ NOT SERIOUS

7. HAVE YOU EVER SEEN THIS PATIENT BEFORE?
1 ☐ YES 2 ☐ NO
If YES, for the problem indicated in ITEM 5a?
1 ☐ YES 2 ☐ NO

8. MAJOR REASON(S) FOR THIS VISIT *(Check all major reasons)*
01 ☐ ACUTE PROBLEM
02 ☐ ACUTE PROBLEM, FOLLOW-UP
03 ☐ CHRONIC PROBLEM, ROUTINE
04 ☐ CHRONIC PROBLEM, FLARE-UP
05 ☐ PRENATAL CARE
06 ☐ POSTNATAL CARE
07 ☐ POSTOPERATIVE CARE → (Operative procedure)
08 ☐ WELL ADULT/CHILD EXAM
09 ☐ FAMILY PLANNING
10 ☐ COUNSELING/ADVICE
11 ☐ IMMUNIZATION
12 ☐ REFERRED BY OTHER PHYS/AGENCY
13 ☐ ADMINISTRATIVE PURPOSE
14 ☐ OTHER (Specify)

9. PHYSICIAN'S PRINCIPAL DIAGNOSIS THIS VISIT
a. DIAGNOSIS ASSOCIATED WITH ITEM 5a ENTRY
b. OTHER SIGNIFICANT CURRENT DIAGNOSES *(In order of importance)*

10. DIAGNOSTIC/THERAPEUTIC SERVICES ORDERED/PROVIDED THIS VISIT *(Check all that apply)*
01 ☐ NONE
02 ☐ LIMITED HISTORY/EXAM
03 ☐ GENERAL HISTORY/EXAM
04 ☐ CLINICAL LAB. TEST
05 ☐ BLOOD PRESSURE CHECK
06 ☐ EKG
07 ☐ HEARING TEST
08 ☐ VISION TEST
09 ☐ ENDOSCOPY
10 ☐ OFFICE SURGERY
11 ☐ DRUG PRESCRIBED
12 ☐ X-RAY
13 ☐ INJECTION
14 ☐ IMMUNIZATION/DESENSITIZATION
15 ☐ PHYSIOTHERAPY
16 ☐ MEDICAL COUNSELING
17 ☐ PSYCHOTHERAPY/THERAPEUTIC LISTENING
18 ☐ OTHER (Specify)

11. DISPOSITION THIS VISIT *(Check all that apply)*
1 ☐ NO FOLLOW-UP PLANNED
2 ☐ RETURN AT SPECIFIED TIME
3 ☐ RETURN IF NEEDED, P.R.N.
4 ☐ TELEPHONE FOLLOW-UP PLANNED
5 ☐ REFERRED TO OTHER PHYSICIAN/AGENCY
6 ☐ RETURNED TO REFERRING PHYSICIAN
7 ☐ ADMIT TO HOSPITAL
8 ☐ OTHER (Specify)

12. DURATION OF THIS VISIT *(Time actually spent with physician)*
_____ MINUTES

HRA-34-2
REV. 8-74

DEPARTMENT OF HEALTH, EDUCATION AND WELFARE
PUBLIC HEALTH SERVICE
HEALTH RESOURCES ADMINISTRATION
NATIONAL CENTER FOR HEALTH STATISTICS

O.M.B. #68-S72106
EXPIRATION DATE 12/31/75

Encounter form.

dermatologic complaints, the difference in the sex-specific rate of visits is greatest in the adolescent-early adult group (15-24 years old). In this age group, females attended a physician 45% more frequently than men. Among patients 25 years old and over, the women's rate of visits for dermatologic complaints was less than 10% greater than that for men. This can be compared to the substantially higher rates of total physician visits by women in the adult years (Table 2).

Age

The percentage of total physician visits accounted for by dermatologic complaints was greatest in younger patients. The rate varied from a high of 11% in the group aged 15 to 24 years to only 5% of all visits to a physician among patients 45 years old and over being for a dermatologic complaint.

In addition to having its greatest relative importance as a reason for a physician visit in the 15- to 24-year-old age group, the absolute rate of visits for such complaints was also greatest in this group. Women in this age group were more than half-again as likely to seek advice for a dermatologic complaint than were women in any other age group. While the rate for males was also highest in the adolescent group, it never exceeded by more than 25% the visit rate by men in other age groups.

Complaint Category

When grouped according to our complaint classification scheme, individual complaint (Table 1) categories accounted for 15% to 34% of all visits for dermatologic complaints. There was substantial variation in the sex ratio of visits for each complaint (Table 3). For example, while men comprised 59% of visits for allergic and irritant conditions affecting the skin (category 2, Table 1), men accounted for only 24% of acne visits. Substantial variation between males and females in frequency of physician visits was confined to three age and complaint categories: (1) adolescent (age 15 to 24) acne, (2) childhood (less than age 15) injury and infection, and (3) adolescent (age 15 to 24) allergic and irritant skin complaints. Visit rates for remaining categories are similar between men and women.

While male and female visit rates per thousand population are similar for patients age 45 and over, the number of women in this age group is larger. As a result, women were seen in 56% of the 13.2 million visits by patients 45 and over who had dermatologic complaints.

UNIVERSITY OF MICHIGAN LIBRARY

Table 1.—Dermatologic Complaint Classification

Complaint Categories	NAMCS Code	Partial Listing of Component Complaints
Acne	100	
Infectious disorders and wounds	106,116	Athlete's foot, boils, ringworm, bites, blisters, bruises
Allergic and irritant	112,113	Hives, photosensitivity, poison ivy, diaper rash, itching, pain, ulcers, sores
Morphologic changes	104,109,110, 115,120	Discoloration of pigmentation, wrinkles, bumps, nodules, lesions, moles
All other	108,111,122, 124,126,130	Warts, calluses, corns, symptoms referable to hair and nails including brittleness, breaking, falling out

Table 2.—Annual Rate of Office Visits* by Age According to Type of Complaint

	No. of Visits per Thousand Persons per Year								
	Total Patients	Male	Female	Male	Female	Male	Female	Male	Female
Complaint All visits	Patients 3,072	2,272 (under 15 yr)	2,107	1,762 (15-24 yr)	3,348	2,252 (24-44 yr)	4,024	3,568 (45+ yr)	4,478
All visits for dermatologic complaints	214	218	183	226	327	181	200	203	215
Acne	21	†	†	47	99	†	†	†	†
Allergy	73	86	90	63	92	53	62	66	72
Infection & injury	47	75	34	50	47	58	†	47	41
Morphologic change	52	†	†	†	60	47	61	74	75
Other dermatologic complaints	21	†	†	†	†	†	†	†	†

*Rates are the number of office visits per thousand noninstitutionalized population. For example, 1,905,000 visits "for acne" are estimated for 19,257,000 women aged 15 to 24 years, yielding a rate of 99 visits per thousand population for this complaint category.

†Estimate smaller than that required for establishment of confidence limits (less than 800,000 visits estimated).

Table 3.—Number and Percentage Distribution of Office Visits by Sex According to Type of Dermatologic Complaint and for All Complaints

Complaint	No. of Visits, Millions	Sex	
		Male*	Female*
All dermatologic complaints	44.1	40	60
Acne	4.2	24	76
Allergy and irritant	15.1	45	55
Infection and injury	9.6	59	41
Morphologic change	9.7	44	56
Other dermatologic complaints	5.5	46	54

*Percentage distribution.

Table 4.—Percent Distribution of Length of Office Visit by Type of Complaint

Complaint	Length of Visits, min*		
	5 or less	6 to 15	16+
All visits	17	59	24
Dermatologic complaints			
All dermatologic complaints	21	64	15
Acne	13	76	11
Allergy and irritant	24	66	10
Infection and injury	27	57	16
Morphologic change	15	65	20

*Quantity indicated by percentage distribution.

Specific Complaints

The most frequent patient skin complaint leading to a physician visit was "allergic skin reaction" (10.2 million visits). Other specific complaints leading to large numbers of encounters included acne (4.4 million), warts (2.6 million), and skin moles (1.0 million).

Physicians diagnosed warts as the principal reason for the visit in 3.5 million encounters. Thus, more than one third of patients coming for wart treatment did not indicate specific knowledge of the nature of their skin growth.

Duration of Visits

Visits for dermatologic complaints were, on the average, shorter than visits for all medical complaints. Dermatologic visits lasted 15 minutes or less in 85% of cases, and 21% of dermatologic visits lasted five minutes or less. Only 76% of visits for all complaints took 15 minutes or less. Notable for frequent short visits (as defined by actual physician contact time with patients) were visits prompted by allergic and irritant dermatoses (Table 4).

Procedures and Drugs

Visits for dermatologic complaints frequently involved surgical procedures and the use of drugs, both prescription and over-the-counter preparations. For instance, 70% of visits for acne involved prescription of a drug and 20% of such visits over-the-counter medications. With the exception of visits related to warts, 75% which were treated surgically, on the average the rate of writing a prescription was approximately 70%. This was a substantially higher prescription-writing rate than the 55% rate for all visits to general practitioners and internists.

Visits by Physician Specialty

General and family practitioners, internists, and pediatricians together accounted for 52% of the visits for dermatologic complaints, which numbered 44 million or 7% of all office-based physician visits (Table 5). Of the 4.2 million visits for acne, 85% were seen by dermatologists. Dermatologists saw 47% of patients with complaints referable to morphologic changes of the skin. Acute conditions, such as allergic skin reactions, irritation, and swelling of the skin, were seen more often by physicians other than dermatologists (Table 6).

Practitioners other than dermatologists who see a large number of patients with specific skin complaints were general and family practitioners, pediatricians, and internists. The percentage of total visits to each of these specialties that were initiated for skin complaints is 6.8%, 5.8%, and 3.2%, respectively.

Visits to Dermatologists

Of the 18 million office visits to dermatologists in 1974, 85% were prompted by specific dermatologic

complaints. The remaining visits were for administrative reasons, routine follow-up examinations, or for nondermatologic complaints, which, in the NAMCS classification, included visits for venereal diseases not accompanied by skin findings.

Based on NAMCS data and the American Medical Association *Distribution of Physicians* in office-based practice, it appeared that dermatologists averaged about 5,600 patient visits in 1974, a number equal to that of general practitioners (Table 7).

Other data available from the NAMCS survey showed that 65% of visits to dermatologists were follow-up visits, a proportion close to that found for all physicians (62%). However, dermatologists followed up a higher proportion of patients with allergic and irritant complaints and with morphologic changes (53% and 56%) than did other physicians (31% and 38%). In general, dermatologists scheduled return visits more frequently (72%) than did other physicians (60%). Dermatologists' highest rate of return visits was for patients with acne; 85% were given appointments to return.

Thirty-five percent of visits to dermatologists were first visits to that physician for a particular complaint. This percentage parallels the 38% of all visits that are the first contact with a given physician for the presenting problem. Dermatologists have a higher percentage of visits made by new patients (26%) than do general and family practitioners (12%), internists (13%), or pediatricians (9%).

Table 5.—Number and Percentage Distribution of Office Visits by Physician Specialty

Complaint	No. of Visits, Millions	Physician Specialty*		
		Dermatologists	General Family Practice	All Other Physicians
All visits	634.0	2.8	41.5	55.7
All dermatologic complaints	44.1	34	40	25
Acne	4.2	86	†	†
Allergy	15.1	30	41	29
Morphologic change	9.7	47	29	24
Injury and infection	9.6	†	62	38
Other dermatologic complaints	5.5	31	27	42

*Quantity indicated by percentage distribution.
†Estimate less than number required to establish confidence limits.

Table 6.—Number and Percentage Distribution of Office Visits by Type of Physician

Complaint (NAMCS Code)		No. of Visits, Millions	Type of Physician Seen	
			Dermatologists	Other Physicians
Acne	(100)	4.4	86	14
Warts	(111)	2.6	42	58
Allergic skin reactions	(112)	10.2	29	71
Skin irritation	(113)	4.8	34	66
Swelling or mass of skin	(115)	6.1	28	72

*Quantity indicated by percentage distribution.

Table 7.—Number and Percentage Distribution of Visits to Physicians in Office Practice by Type of Specialty

Physician Specialty	Office Visits All Complaints		Physicians in Office-Based Practice		
	Visits, Millions	Percent Distribution	No. Thousands	Percent Distribution	Office Visits per Physician per Year, Thousands
Dermatology	18	2.8	3.2	1.6	5.6
General practice	263	41.5	47.2	23.7	5.6
Surgery	129	20.3	48.5	24.4	2.7
Internal medicine	69	10.8	32.2	16.2	2.1
Pediatrics	52	8.2	12.9	6.5	4.0
Obstetrics/gynecology	51	8.0	14.7	7.4	3.5
Other	53	8.3	40.5	20.3	1.3
Total	**635**	**100.0**	**199.1**	**100.0**	...

COMMENT

The profile of the "average" dermatologist provided by the NAMCS was that of a busy practitioner who in a 48-week working year of five days per week saw 23 to 30 patients daily in his office.[3] The actual time that the dermatologist spent with patients—on the average, 19 to 20 hours per week—is comparable to that spent by the general practitioner with his patients. The most frequent complaints handled by the dermatologist, in descending order of frequency, were acne, chronic lesions and tumefactions of the skin, allergic dermatitis, and contact dermatitis. Approximately seven of ten patients were given a written prescription; some surgical procedure was performed on three of ten patients. The NAMCS study documented that primary care physicians were major providers of dermatologic care. Curiously, acne, a ubiquitous condition, was not as frequently a precipitating reason for visits to these physicians as were other conditions and diseases of the skin.

The profiles of the dermatologist and the primary care practitioner in reference to providing care for patients with skin complaints were intuitively reasonable. The quantitative estimates provided in this study were subject to limitations of interpretation. Errors due to variations occurring by chance ascribable to the size of the sample can be estimated, and when reasonable confidence limits were exceeded, no data inferences have been made.[3] Other limitations, such as the nonresponse rate (26% of all physicians, 16% of dermatologists contacted) due to physicians' refusal to cooperate in the study or the noninclusion of some office-based physicians in the AMA and American Osteopathic Association listings were

not considered to have seriously distorted the data.[2] The larger sample of physicians and the greater number of patient encounters that will become available as the survey continues will provide more reliable and detailed estimates. The NAMCS data conformed in general, by diagnosis and type of physician seen, to data provided by the National Disease and Therapeutic Index (1968 and 1969) cited by the National Program for Dermatology study.[3]

However impressive the reported volume of visits due to complaints of the skin may be, the present demand for care is moderated by financial factors. For example, the percentage of adolescents consulting a physician for acne is at least three times greater for individuals from families with an income exceeding $15,000 than for members of low-income families.[4] Diminishing financial barriers with extended third-party coverage, as in a program of national health insurance, will increase demand substantially. For example, only 1.4 million patients are accounted for in the NAMCS study by the conservative estimate of three visits per year by a patient with acne. This in only one fifth of the nine million Americans with acne, according to preliminary survey information.[5] Estimates in the range of an increase of 75% in the overall utilization of health services with full insurance coverage have been made.[6] Further, with full coverage, patients with skin complaints may choose to consult dermatologists directly. With demand potentially exceeding supply, some rationing of the dermatologist's services coupled with increased utilization of primary care physicians and other substitute skills may become necessary.

The present study does not provide information on the quality of care given to patients with skin complaints by dermatologists and other physicians. The minimal dermatologic preparation of medical students and residents in other specialties poses serious questions about their level of diagnostic and therapeutic adequacy. A major task for the discipline of dermatology is to augment the education of other physicians so they can recognize and treat common dermatologic conditions and, where indicated, recognize the need for dermatologic consultation. Within the field of dermatology itself there is a need to determine more precisely what knowledge and skills are crucial and to ensure that dermatologists maintain a satisfactory level of performance.

Another unanswered question is the extent to which dermatologists' practices are oriented toward cosmetic care such as hair transplants and dermabrasion. A determination of the extent and appropriateness of such practices is needed for specialty planning manpower needs.[7]

The NAMCS study provides useful estimates of present demand for the relief of dermatologic complaints. In its present stage, it is not comprehensive enough to identify populations at high risk, such as occupational groups, and it does not analyze differences in the efficiency or outcome of different practitioner's treatment of skin disease. The NAMCS does, however, complement other efforts, most notably the Health and Nutrition Examination Survey, which will describe with some precision the extent and nature of skin disease in the US population and the individual variation in the utilization of medical service for its relief.

As an ongoing data collection effort, the NAMCS data base is constantly expanding. In addition, proposed revisions of the encounter forms should provide more specific information on chronicity of disease, physician diagnostic and treatment services, and prescribing habits. When available, this information will provide a basis for comparison of the actual services rendered by physicians with different specialties for discrete dermatologic conditions.

This investigation was supported in part by a Fellowship Grant by the Dermatology Foundation to Dr Stern.

Todd M. Frazier, MS, pointed out the availability of the data used in this paper and reviewed the manuscript. These data were made available by the National Center for Health Statistics, which, acting on the recommendations of the NAMCS Advisory Committee, has encouraged users of survey data to request special tabulations addressed to specific problems as we have.

References

1. National Center for Health Statistics: *National Ambulatory Medical Care Survey: Background and Methodology, United States.* Vital and Health Statistics Series II, No. 61. US Department of Health, Education, and Welfare, Public Health Service, 1974.

2. National Center for Health Statistics: *The National Medical Care Survey: 1973 Summary, United States, May 1973-April 1974.* Vital and Health Statistics Series XIII, No. 21. US Department of Health, Education, and Welfare, Public Health Service, 1975.

3. Joint Committee on Planning for Dermatology: *National Program for Dermatology.* American Academy of Dermatology, 1969.

4. National Center for Health Statistics: *Health Attitudes and Behavior of Youths 12-17 Years: Dermographic and Socioeconomic Factors.* US Department of Health, Education, and Welfare, Public Health Service, 1975.

5. Johnson ML: Burden of Dermatologic Disease in the United States. Read before the annual meeting of the American Dermatologic Association, Honolulu, April 2, 1974.

6. Newhouse J. Phelps C, Schwartz W: Policy options and the impact of national health insurance. *N Engl J Med* 290:1345-1359, 1974.

7. Fahs IJ, Lynch FW, Ward RD, et al: Dermatologists in the United States, 1968 through 1973. *Arch Dermatol* 112:235-242, 1976.

Editorial Comment

The largest and, I hope, insurmountable obstacle to the prompt government ownership of the medical care system in the United States is the expectation that our government bureaucracy would surely bungle the job. An even worse disaster for elected politicians than bungling the postal service or the welfare administration or the auto safety legislation or the energy crisis or the Department of Defense purchasing would be fouling the voluntary health care system. Most knowledgeable men of power, in and out of government, will never risk supporting federal ownership or direction of medicine *unless* the private physicians hopelessly bungle the job themselves. Our principal defense against the major intrusion of government into dermatology is to manage our specialty not merely well, but in a sophisticated, progressive, and very humane fashion. The first rule is this: All citizens with any skin diseases are our responsibility ultimately.

To manage our specialty expertly, we need to know precisely what our task is and what resources we can and cannot use. Stern et al have done a fine preliminary study of some of these problems. They have described where our patients go for their care and for which disorders. Because less than one third of dermatology is done by specialists, we see the importance of our members' participating in continuing education programs in every state of the nation. Many skin disorders are not medically complex, apparently not requiring the care of a specialist, but to assure the best results some supervision is appropriate. How is that to be achieved in private practice? In the same way, what is the best and most economical means for all patients to receive high-quality care for their acne? As Stern et al show, all patients with skin complaints cannot see the dermatologist; he is already working a 48-hour week. Furthermore, that highly trained dermatologist is needed to diagnose and treat more complex disorders, and use special technical facilities, such as for minor surgery or for patch testing. We alone can solve this problem properly.

Many other crucial questions raised by this communication are yet to be answered, concerning the quality of care, proper pricing, rehabilitation, disease prevention, and more. The more detailed data from the National Health Survey may solve some problems and raise some more. We can say that although we are now far superior to the federal bunglers, we have only started on the difficult road to managing our specialty properly and serving our patients expertly.

PHILIP C. ANDERSON, MD
Columbia, Mo

Mycobacterium marinum Infections Treated With Tetracycline

Allan K. Izumi, MD; C. William Hanke, MD; Michiko Higaki, MT (ASCP)

• Five cases of *Mycobacterium marinum* skin infections were successfully treated with 2 gm of tetracycline hydrochloride daily for periods from four to 12 weeks. In each case, the isolated *M marinum* was sensitive in vitro to tetracycline at levels from 25 to 50 μg/ml. Tetracycline is recommended as treatment for extensive or sporotrichoid *M marinum* infections.

(*Arch Dermatol* 113:1067-1068, 1977)

Treatment for *Mycobacterium marinum* infections are numerous. Surgical curettement and electrodesiccation and excision are the most popular methods of treatment, since the majority of these infections are small and localized. Chemotherapeutic measures are usually reserved for the more extensive and sporotrichoid varieties but are hampered because of the known resistance of this bacillus to antituberculous drugs. However, a variety of chemotherapeutic measures are described. Johnson[1] reported his success with streptomycin sulfate and potassium iodide. Barrow and Hewitt[2] successfully treated a case with co-trimoxazole and sulfamethoxazole. Wolinsky et al[3] and Van Dyke and Lake[4] used a combination of ethambutol, isoniazid, and rifampin. Kim[5] briefly reported his success with tetracycline hydrochloride. Loria[6] recently described his success with minocycline hydrochloride.

Thus far, the results of chemotherapy have been difficult to evaluate because of the natural tendency of this infection to spontaneously heal, usually within one to two years. The purpose of this study was to present our experience with the use of tetracycline and to correlate this with in vitro sensitivity studies.

SUBJECTS AND METHODS

Five male patients were examined from 1972 to 1975 (Table 1). Three had localized tuberculoid granulomas over the finger or hand. One patient had a sporotrichoid granuloma involving his hand and elbow. One patient had an extensive granuloma over the entire knee and upper thigh. Each patient had been aware of his lesion ranging from three months to 20 years. Four of these patients had not received prior treatment. A 4-mm punch biopsy was obtained from each patient. The biopsy specimen was immediately bisected. One half of the specimen was sent to pathology (hematoxylin-eosin and acid-fast stains) and the other one half placed in 1 ml of sterile water and sent to Leahi Hospital for culture. In vitro sensitivity studies were set up against streptomycin isoniazid, *p*-aminosalicylic acid, ethambutol, rifampin, and tetracycline (Table 2).

For comparision several atypical *Mycobacterium* strains (group I-IV), obtained from Hawaii's State Department of Health, were also tested against tetracycline in vitro (Table 3).

Each patient was placed on regimens of tetracycline at a dose of 2 gm daily. This dose was maintained for an average of 8.5 weeks, with a range of 4 to 12 weeks. The criteria for resolution was complete flattening and clearing of the granuloma. In case 4, a repeat biopsy specimen and culture were obtained to confirm the granuloma's resolution. Four-month to eight-month follow-up studies on each patient were done to confirm that the granuloma had not recurred.

RESULTS OF IN VITRO TESTING

The results of the in vitro sensitivity studies of the *M marinum* isolates from these five patients are summarized in Table 2. All isolates were resistant to *p*-aminosalicylic acid at levels of 10 to 100 μg/ml. These isolates were also resistant to isoniazid, showing only growth suppression at levels of 5 and 10 μg/ml in one isolate each. There was a modest growth suppression to streptomycin at 100 μg/ml in three isolates, ethambutol at 2 to 8 μg/ml, and rifampin at 0.1 to 1.0 μg/ml. The isolates were not suppressed by tetracycline until levels of 25 μg/cc were reached. All isolates were suppressed at levels of tetracycline from 25 to 50 μg/ml.

Results of in vitro sensitivity studies against other atypical *Mycobacterium* strains are also summarized in Table 3. Except for *M flavescens*, *M smegmatis*, and *M phlei*, all other strains were resistant to tetracycline.

COMMENT

Mycobacterium marinum (*balnei*) is a Runyon group I photochromogen *Mycobacterium*. Linell and Norden[7] originally described the bacteriologic characteristics of this bacillus as the following: (1) growth on Lowenstein-Jensen media at 31 C, but not at 37 C; (2) conversion from cream-colored colonies to yellow-orange colonies in 10 to 21 days after light exposure; and (3) failure to grow in guinea pigs.

In vitro antimicrobial sensitivity

Table 1.—Patient Summary

Patient No.	Age, yr/ Sex	Duration of Lesion	Clinical Site	Treatment Period, Weeks	Follow-up Period, mo
1	52, M	3 mo	Dorsum hand	10	6
2	60, M	6 mo	Index finger	9	6
3	44, M	1 yr	Finger	4	6
4	35, M	20 yr	Knee-thigh	12	8
5	59, M	6 mo	Sporotrichoid-hand and elbow	8	4

Accepted for publication Nov 3, 1976.

From the Department of Medicine, Division of Dermatology, John A. Burns School of Medicine of the University of Hawaii (Dr Izumi), and the Leahi Hospital, Laboratory Division (Mr Higaki), Honolulu. Dr Hanke is now with the Department of Dermatology, The Cleveland Clinic.

Read before the Joint Scientific Meeting of the Texas-Hawaii Dermatological Society, Honolulu, Oct 27, 1974.

Reprint requests to 848 S Beretania St, Suite 307, Honolulu, HI 96813 (Dr Izumi).

Table 2.—In Vitro Sensitivity Studies to *M Marinum* Isolates

In Vitro Drugs, μg/ml	M Marinum Isolates 1	2	3	4	5
Streptomycin					
10	+1*	0	+1	0	+2
100	0	...	0	...	0
Isonizaid					
0.1	+3	+3	+3	+3	+3
1.0	+3	+3	+3	+3	+2
5.0	+3	0	+1	+1	+1
10.0	+3	...	...	0	+1
p-Aminosalicylic acid					
10	+3	+3	+3	+3	+3
100	+3	+1	+1	+1	+3
Ethambutol					
2	+1	0	+3	0	0
4	0	...	+3	...	...
8	...	...	0	...	...
Rifampin					
0.1	0	+3	+3	0	+2
0.5	...	+1	+1	...	+1
1.0	...	0	0	...	0
Tetracycline					
6.0	+3	+2	+3	+3	+3
12.0	+2	+1	+3	+3	+3
25.0	0	0	+2	+3	+2
50.0	...	...	0	0	0

* +1 indicates 50-100 colonies per plate; +2, 100-200 colonies per plate; +3, 200-500 colonies per plate; and +4, >500 colonies per plate.

Table 3.—In Vitro Sensitivity Studies to Atypical *Mycobacterium* Against Tetracycline

Atypical Mycobacteria Groups	In Vitro Tetracycline (concentrate), μg/ml 0	6	12	25	50	100
Group I						
M kansasii	+3*	+3	+3	+3	+2	+1
Group II						
M scrofulaceum	+3	+3	+3	+3	+3	+2
M flavescens	+3	+3	+1	0		
Group III						
M avium-intracellular complex	+3	+3	+3	+3	+3	+3
M xenopi	+3	+3	+3	+3	+2	+1
M friviale (V)	+3	+3	+3	+3	+2	+1
Group IV						
M fortuitum 1	+3	+3	+3	+3	+3	+3
M fortuitum 2	+3	+3	+3	+3	+3	+3
M fortuitum 3	+3	+3	+3	+3	+3	+3
M smegmatis	+3	+3	+1	0		
M phlei	+3	+3	+3	+1	0	

* +1 indicates 50-100 colonies per plate; +2, 100-200 colonies per plate; +3, 200-500 colonies per plate; and +4, >500 colonies per plate.

studies against *M marinum* have consistently shown that it is relatively resistant to isoniazid, streptomycin, neomycin sulfate, *p*-aminosalicylic acid, penicillin, chloramphenicol (Chloromycetin), and thiosemicarbazone.[3,4,7-9] However, it is partially sensitive to rifampin, ethionamide, vancomycin hydrochloride, ethambutol, streptomycin, cycloserine, and tyrothricin.[3,4,7,8]

There have been relatively few reports concerning the in vitro antimicrobial effects of tetracycline on *M marinum*. Linell and Norden[7] reported that *M marinum* was resistant to "physiologic doses" of chlortetracycline hydrochloride (Aureomycin/all forms) and oxytetracycline (Terramycin), but they did not define the concentration. Knox et al[10] briefly commented that the isolated *M marinum* organism was resistant to tetracycline in vitro, but again, they did not define that level. Kim[5] noted that two out of six cases were resistant to tetracycline in vitro at 100 μg/cc. All of his cases, however, did respond to tetracycline.

All of our isolates of *M marinum* were sensitive to tetracycline in vitro at levels of 25 to 50 μg/ml. A limited survey of other atypical mycobacteria indicated that all were resistant to tetracycline, except for *M flavescens, M smegmatus,* and *M phlei.* We are unable to explain the in vitro resistance of *M marinum* to tetracycline reported by Kim.[5]

Tetracycline and minocycline, a semisynthetic derivative of tetracycline, have both been reported to be clinically effective against *M marinum* infections.[5,6] Based on our correlated in vitro antimicrobial studies, we believe that this is a direct antimicrobial effect.

Tetracycline is recommended as the treatment of choice for extensive or sporotrichoid varieties of *M marinum* infections. Small localized *M marinum* infections should probably be treated locally by surgical excision, curettement, electrodesiccation, or cryosurgery. Our treatment program consisted of 2 gm of tetracycline daily for at least two to four months.

James T. Swift, MD, provided clinical data and laboratory material for case 5.

Nonproprietary Names and Trademarks of Drugs

Tetracycline hydrochloride—*Achromycin, Bicycline, Panmycin, Polycycline, Steelin, Tetracyn.*
Rifampin—*Rifadin, Rimactane.*
Ethionamide—*Trecator-SC.*
Cycloserine—*Oxamycin, Seromycin.*
Vancomycin—*Vancocin.*

References

1. Johnson HM: Dihydrostreptomycin and potassium iodide in the treatment of *Tuberculosis verrucosa* cutis. *J Invest Dermatol* 15:61-66, 1950.
2. Barrow GI, Hewitt M: Skin infections with *Mycobacterium marinum* from a tropical fish tank. *Br Med J* 2:505-506, 1971.
3. Wolinsky E, Gomez F, Zimpfer F: Sporotrichoid *Mycobacterium marinum* infection treated with rifampin—ethambutol. *Am Rev Respir Dis* 105:964-967, 1972.
4. Van Dyke JJ, Lake KB: Chemotherapy for aquarium granuloma. *JAMA* 233:1380-1381, 1975.
5. Kim R: Tetracycline therapy for atypical mycobacterial granuloma. *Arch Dermatol* 110:299, 1974.
6. Loria PR: Minocycline hydrochloride treatment for atypical acid-fast infection. *Arch Dermatol* 112:517-519, 1976.
7. Linell F, Norden A: *Mycobacterium balnei*: A new acid-fast bacillus occuring in swimming pools and capable of producing skin lesions in humans. *Acta Tuber Scand* 73:1-84, 1954.
8. Schaefer WB Davis CL: A bacteriologic and histopathologic study of skin granuloma due to *Mycobacterium balnei*. *Am Rev Respir Dis* 84:837-844, 1961.
9. Adams RM, Remington JS, Steinberg J, et al: Tropical fish aquariums: A source of *Mycobacterium marinum* infections resembling sporotrichosis. *JAMA* 211:457-461, 1970.
10. Knox J, Gever SG, Freeman RG: Atypical acid-fast organism infection of the skin. *Arch Dermatol* 84:386-391, 1961.

Immunopathologic Study of Herpes Gestationis in Mother and Infant

Allan Katz, MD; Joe O. Minta, PhD; John W.P. Toole, MD; Walter Medwidsky, MD, FRCP(C)

• In vivo bound C3 was demonstrated by immunofluorescence in lesions of both maternal and infant skin in an immunopathologic study of herpes gestationis. Immunoglobulins and other complement components of both classical and alternative pathways were not found. The serum was also negative for circulating antibody to basement membrane of skin. Maternal serum had a factor present that was able to deposit C3 from fresh normal serum onto the basement membrane zone of skin.

Hemolytic complement titrations showed a decrease of CH_{50} levels in serum of both classical and alternative pathways in the mother and the classical pathway in the infant, with a decrease of C2 and C4 in both.

To our knowledge, this is the first report of a decrease in serum complement components in herpes gestationis and indicates that complement may not be activated locally.

(*Arch Dermatol* 113:1069-1072, 1977)

Herpes gestationis (HG) is a rare vesiculobullous dermatitis of pregnancy first described by Bunel in 1811[1] and named by Milton in 1872.[2] Russell and Thorne[3] estimated the incidence to be 1 in 3,000 to 4,000 deliveries; however, Kolodny[4] stated the incidence was closer to 1 in 10,000 deliveries.

In recent years an immunologic mechanism has been implicated in the pathogenesis of HG. Provost and Tomasi demonstrated in vivo bound C3, C5, and properdin in the basement membrane zone of skin by immunofluorescence.[5] Also, a factor was detected in the serum (HG factor) that was capable of depositing C3 along the basement membrane zone of normal human skin. This factor has recently been shown to be a thermostable IgG.[6,7] Bushkell et al demonstrated in vivo bound IgG as well as Clq, C3, and properdin in a patient with an IgG basement membrane antibody in both serum and blister fluid.[8] There have been several reports of in vivo bound IgA as well.[9,10]

With respect to HG occurring in the infant, Rimbaud et al found IgG fixation in the basal layer of skin without circulating antibodies in serum.[11] There was no mention, however, of complement staining. In vivo fixation of C3 and C4 without IgG has been reported in both normal skin of an infant who did not have the lesions of HG,[6] as well as in lesional skin.[12] In several recent studies the HG factor was also shown to be present in cord serum.[6,7]

The following report of HG occurring in a mother and infant describes studies on skin and serum and documents a decrease in serum complement activity of both the classical and alternative pathways.

REPORT OF A CASE

A 39-year-old, para 4, gravida 8, Rh-positive woman was hospitalized Nov 20, 1975, at 37 weeks' gestation with hypertension, edema, and proteinuria.

At three months' gestation the patient developed a widespread pruritic urticarial vesiculobullous eruption. Biopsy results showed subepidermal bullae consistent with herpes gestationis. She was treated with prednisone, 20 mg/day, which was maintained throughout pregnancy. This controlled the pruritus, however, scattered bullae confined to the distal extremities still persisted.

A similar eruption appeared in the last trimester of her preceding full-term pregnancy in 1969. This had been treated with orally given dexamethasone, but a biopsy was not carried out. The healthy infant was noted to have a transient erythematous rash that was not further investigated.

Past history included a spontaneous abortion in the first trimester in February 1975, a full-term delivery in 1963, a spontaneous abortion in the first trimester in 1962, full-term normal deliveries in 1961 and 1960, and a first trimester abortion in 1959.

A diagnosis of chronic persistent hepatitis confirmed by liver biopsy was made in 1973.

The patient was delivered of a full-term female infant on Nov 21, 1975. She was maintained on a regimen of prednisone, 20 mg/day, until Nov 27, when the dose was reduced to 15 mg/day. Two days later an exacerbation of her skin condition developed with erythematous papules, vesicles, and bullae most severe in the periumbilical region, back, and limbs. This responded to an increase in the dose of prednisone to 30 mg/day started on Dec 3. Results of a second biopsy showed subepidermal bullae

Accepted for publication Dec 15, 1976.

From the Department of Pathology, Toronto Western Hospital (Dr Katz) and University of Toronto (Drs Katz and Minta); and the Department of Dermatology, University of Toronto (Dr Toole) and St Michael's Hospital (Dr Medwidsky).

Reprint requests to Department of Pathology, Toronto Western Hospital, 399 Bathurst St, Toronto, Canada M5T 2S8 (Dr Katz).

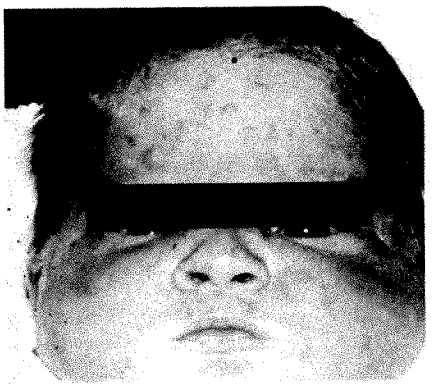

Fig 1.—Papulovesicular rash on forehead of infant.

consistent with HG. Pertinent laboratory findings were as follows: peripheral blood eosinophilia, 1,152/cu mm; erythrocyte sedimentation rate, 108 mm/hr; and albumin/globulin ratio, 3.8/3.5 gm/100 ml in serum.

The baby was noted to have an erythematous rash at birth that involved the face, abdomen, and distal extremities by 6 days of age. It consisted of polycyclic erythematous papules studded with vesicles (Fig 1). Biopsy results showed subepidermal bullae with numerous eosinophils, consistent with HG (Fig 2). The eruption subsided throughout a period of one week.

METHODS

Four-millimeter punch biopsies of bullous lesions and adjacent skin were performed on mother and baby. One portion of tissue was fixed in 10% buffered formaldehyde solution followed by Brazil solution.[14]

The rest of the tissue was snap frozen in liquid nitrogen and stored at −70 C until used. Four-micron sections were cut in a cryostat at −20 C and immunofluorescent staining was done on both unfixed tissue and tissue fixed in acetone for ten minutes. Fluorescein conjugates were prepared from purified antibodies to rabbit antihuman IgG (RAHIgG), sheep antihuman IgM (SAHIgM), and sheep antihuman IgA (SAHIgA) by previously described methods[14] for direct immunofluorescent staining[15] of skin biopsy specimens. All conjugates gave single lines when tested with normal human serum and monoclonal proteins by immunoelectrophoresis and double diffusion in agar. For the demonstration of C3, conjugated antiserum to human C3 produced in goats (GAHC3) was purchased (Meloy Laboratories, Springfield, Mass). Controls for C3 staining included the following: (1) the use of surgical specimens of normal human skin; (2) blocking of specific staining by incubation of sections with unconjugated antihuman C3 (purchased from Meloy Laboratories) followed by conjugated antihuman C3; and (3) prior absorption of the conjugate by purified human C3 prepared by the method of Müller-Eberhard et al.[16] A detailed description of these conjugates is given in Table 1.

The indirect immunofluorescent method[15] was used in an attempt to demonstrate Clq, C5, properdin, and factor B in biopsy specimens of mother's and baby's skin. The details of the methods used to prepare rabbit antisera to human Clq, properdin, and factor B have been reported elsewhere.[17-19] Goat antiserum to human C5 was purchased from Kent Laboratories, Vancouver, BC (lot 1100Dl). Fluorescein-conjugated sheep antirabbit IgG (SARIgG) and rabbit antigoat IgG (RAGIgG) were prepared by the above methods[14] for the staining of biopsy specimens by the indirect immunofluorescent method with the corresponding rabbit and goat antisera to human complement components. Details of these conjugates are also given in Table 1.

The sera of both mother and baby were tested by the indirect method for the presence of a circulating IgG antibody localized to the basement membrane zone of normal human group O skin obtained at surgery. Serum was used undiluted and at dilutions of 1/5 and 1/10 followed by the application of RAHIgG conjugated globulin.

The in vitro complement binding test[20] was performed in an attempt to demonstrate HG factor in the serum of mother and baby. Briefly, sera were applied undiluted and diluted 1/4 and 1/8 to cryostat sections of unfixed normal human group O skin. Following washing, the sections were incubated with a 1/10 dilution of fresh

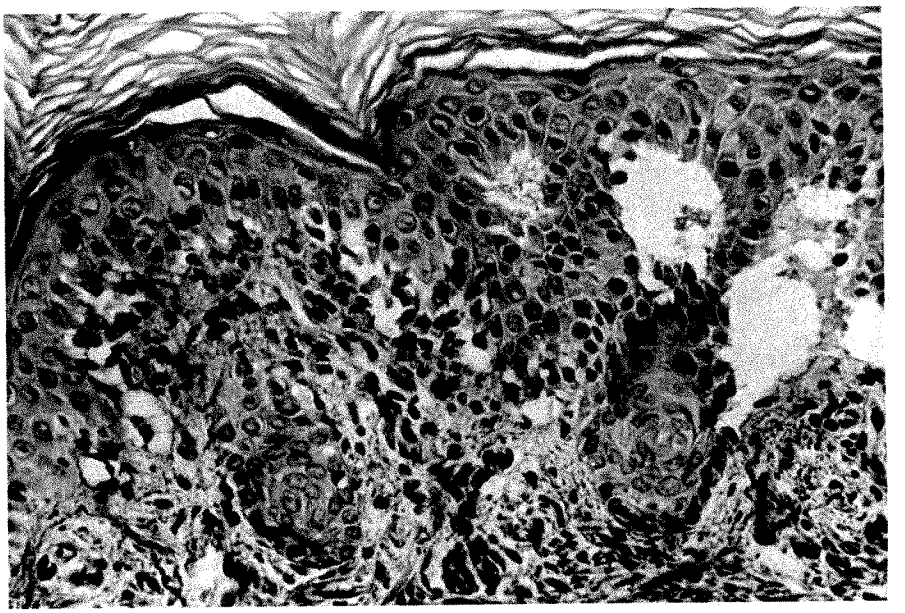

Fig 2.—Skin biopsy specimen from infant showing spongiosis, bulla formation with inflammatory infiltrate in base (hemalum-phloxine-saffron, original magnification ×250).

Table 1.—Characteristics of Conjugates Used in Immunofluorescent Staining

Conjugate*	Fluorescein/Protein Ratio, M	Protein Concentration, mg/ml	Antibody Concentration, mg/ml	Dilution Used
RAHIgG	1.5	10	0.7	1/10
SAHIgM	1.5	10	1.2	1/12
SAHIgA	1.5	10	0.8	1/8
GAHC3	1.4	8.9	0.6	1/10 1/15
SARIgG	2	10	...	1/8
RAGIgG	2	10	...	1/8

*Rabbit antihuman IgG indicated by RAHIgG; sheep antihuman IgM, SAHIgM; sheep antihuman IgA, SAHIgA; goat antihuman C3, GAHC3; sheep antirabbit IgG, SARIgG; and rabbit antigoat IgG, RAGIgG.

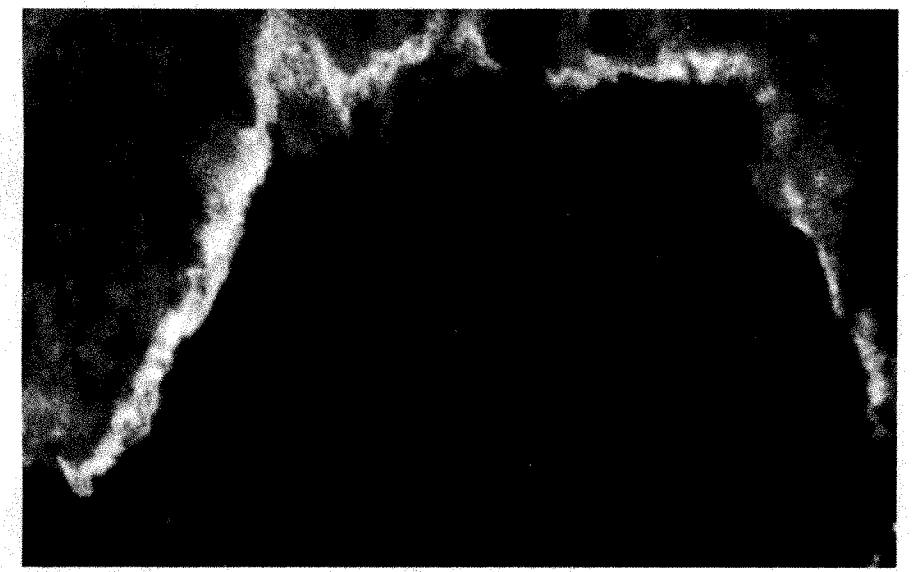

Fig 3.—In vivo bound C3 in continuous pattern on basement membrane zone of infant skin (original magnification ×160).

Table 2.—Complement Titrations on Serum-CH_{50} Units*

Specimen	Classical Pathway	Alternative Pathway	C2	C4
Normal adult serum	72	14	1,150	14,000
Mother's serum A (Dec 1)	18	4.5	398	1,160
Mother's serum B (Dec 3)	51	8.8	767	12,000
Normal cord serum	35	6.7	610	5,210
Baby's serum (Dec 5)	10	5.1	354	1,820

*Normal range in our laboratory; classical pathway, 60 to 90 CH_{50} units; alternative pathway, 12 to 18 CH_{50} units.

normal human group O serum (which was a source of complement), rinsed again, then followed by the application of fluorescein-conjugated antihuman C3 or C4 at dilutions of 1/4 and 1/8. Controls included the use of conjugates alone, substitution of buffer in place of mother's and baby's sera, and the use of sera from two pregnant women who did not have skin disease.

For in vitro properdin binding, rabbit antihuman properdin serum was used undiluted followed by conjugated SARIgG.

Complement Assays

All serum samples were stored at −75 C until used. Total hemolytic complement activity (CH_{50}) was determined, according to the method of Kabat and Mayer,[21] using sensitized sheep erythrocytes. The integrity of the alternative pathway in serum was assayed by measuring its ability to hemolyse unsensitized rabbit red blood cells as described by Platts-Mills and Ishizaka.[22]

The hemolytic assay of C2 was performed by a one-step method using C2 deficient human serum.[23] The C4 hemolytic titrations were carried out by a modification of the one-step functional assay of C4 using C4-deficient guinea pig serum, as described by Gaither et al.[24] Essentially, 0.25 ml of normal or patient's serum diluted from 1/400 to 1/32,000 in veronal-buffered dextrose saline (0.084 μ) containing calcium ions, magnesium ions, and gelatin[25] was added to 0.25 ml of C4-deficient guinea pig serum (diluted 1/40) and 0.5 ml of sensitized erythrocytes (5×10^8 cells/ml). After incubation at 37 C for 60 minutes, the unlysed cells were sedimented and the serum dilution required for 50% lysis determined.[21]

RESULTS

Immunofluorescence

Direct immunofluorescent staining showed in vivo bound C3 in a continuous pattern along the basement membrane zone of the epidermis in both mother's and baby's skin (Fig 3) at conjugate dilutions of 1/10 and 1/15. The intensity of staining was decreased by blocking with unconjugated anti-C3 and staining was abolished by prior absorption of the conjugate with purified human C3. Negative results were obtained for IgG, IgM, IgA, Clq, C4, C5, properdin, and factor B in both maternal and infant skin.

Circulating antibodies of the IgG class to the basement membrane zone of normal human skin were not detected in either mother's or baby's serum by the indirect immunofluorescent method.

The in vitro complement-binding test disclosed the presence of a factor in two samples of maternal serum (sample A taken Dec 1 and B Dec 3) to a dilution of 1/8 that bound C3 from fresh normal human serum along the basement membrane zone of normal human skin. No C3 binding was observed with a single sample of infant's serum taken Dec 5. Negative results were also noted for C4 and properdin binding with both samples of maternal serum as well as with infant's serum.

Complement Studies

Table 2 summarizes the results of selected complement titrations on patients' and normal serum. As shown in the Table, mother's serum A had a substantially depressed total hemolytic complement activity. Both C2 and C4 titres determined by functional assays were also correspondingly decreased. Whereas the classical total hemolytic activity and C4 titre in serum B approached normal levels, the C2 titre was subnormal. To evaluate the integrity of the alternative complement pathway, the efficiency of patients' serum in hemolysing unsensitized rabbit erythrocytes in the presence of magnesium ion ethylene glycol bis tetraacetic acid was compared to that of normal serum. The results show that the alternative pathway hemolytic activity in mother's serum A was remarkably lower than in serum B and normal serum. The titre in serum B was about 63% of normal.

The classic and alternative pathways of hemolysis, the C2 and C4 titres of normal cord serum, were

about 30% to 50% of normal adult values. The alternative pathway hemolytic activity in the baby's serum was comparable to that of normal cord serum. However, the C2 and C4 titres as well as the classic pathway hemolytic activity were appreciably lower than in normal cord serum.

COMMENT

The finding of in vivo bound C3 in skin of both mother and infant in the present study and in a previous one,[12] as well as the demonstration of HG factor in cord blood,[6,7] is suggestive of passive transfer of the disease from mother to infant.

We were unable to demonstrate in vivo deposition of other complement components apart from C3 of either the classical or alternative pathways as reported by others.[5,6,8] Reasons for this difference may be related to variable concentrations of complement components, their transient presence in the basement membrane zone, or to the relative insensitivity of the method used.

This study clearly demonstrates a decrease in serum complement activity of both classical and alternative pathways and suggests that complement activation may not be occurring only locally at the site of blister formation. The decrease would appear to be real, as both the classical and alternative pathways as well as C2 and C4 activity were affected. Our results are at variance with previous reports[6,9] that failed to demonstrate decrease in CH_{50} levels and C3 concentration in serum. Although the technique of radial immunodiffusion used to measure C3 concentration does not indicate functional activity, unlike the method used in this study, the reason for this discrepancy is not known. As maternal complement levels were lowest when the dose of steroids was reduced, it is unlikely that complement depression was merely a nonspecific effect of steroid therapy.

The in vivo fixation of IgG as well as Clq, C3, C5, properdin, and factor B in skin in HG[6,8] is also consistent with activation of both the classical and alternative complement pathways. The circulating (HG) factor that is able to deposit C3 and other components of the classical complement system from fresh serum along the basement membrane zone has recently been shown to be IgG.[6,7] When C2-deficient serum or magnesium ion EGTA-treated serum was used as a complement source, no in vitro binding of C3 was seen, suggesting complement activation via the classical pathway.[7] A possible explanation for the above findings is that the alternative pathway is being activated secondarily to classical pathway activation through the C3b amplification mechanism.[26]

Circulating IgG antibody to skin has also been detected in bullous pemphigoid. This together with in vivo fixation of IgG, Clq, C3, C4, C5, properdin, and factor B in the skin in bullous pemphigoid[5] is suggestive of a relationship to HG. Also, HG factor inhibited the staining of basement membrane zone of normal human skin by fluorescein-conjugated globulin from a bullous pemphigoid serum.[7]

The importance of immunoglobulin and complement deposition in the skin in HG together with the demonstration of a circulating antibody to basement membrane is not known. Such antibodies have not as yet been shown to be pathogenic and may arise secondarily to tissue damage. Similarly, the possible role of changes in pregnancy, such as hormonal alterations, in the pathogenesis of HG is not known.

Dr Minta is a research scholar of the Canadian Heart Foundation, Toronto.

The C4-deficient guinea pigs were provided by Michael Frank, MD, National Institutes of Health.

References

1. Bunel JBH: Essai sur le pemphigus. Paris, 1811, National Library of Medicine, Surgeon General's Catalogue, First Series, Vol 2.

2. Milton JL: *The Pathology and Treatment of Diseases of the Skin*. London, Robert Hardwicke, 1872.

3. Russell B, Thorne NA: Herpes gestationis. *Br J Dermatol* 69:339-357, 1957.

4. Kolodny RC: Herpes gestationis: A new assessment of incidence, diagnosis and fetal prognosis. *Am J Obstet Gynecol* 104:39-45, 1969.

5. Provost TT, Tomasi TB Jr: Complement activation via the alternate pathway in skin disease: I. Herpes gestationis systemic lupus erythematosus and bullous pemphigoid. *J Clin Invest* 52:1779-1787, 1973.

6. Katz SI, Hertz KC, Yaoita H: Herpes gestationis: Immunopathology and characterization of the HG factor. *J Clin Invest* 57:1434-1441, 1976.

7. Jordon RE, Heine KG, Tappeiner G, et al: The immunopathology of herpes gestationis: Immunofluorescence studies and characterization of "HG factor." *J Clin Invest* 57:1426-1433, 1976.

8. Bushkell LL, Jordon RE, Goltz RW: Herpes gestationis: New immunologic findings. *Arch Dermatol* 110:65-69, 1974.

9. Kocsis M, Larsen ET, Husby G, et al: Immunofluorescence studies in herpes gestationis. *Acta Dermatovener* 55:25-29, 1975.

10. Heid E, Maleville J, Basset A: Etude de deux cas d'herpes gestationis en immunofluorescence. *Soc Fr Dermatol Syphiligr* 80:10-11, 1973.

11. Rimbaud P, Jean R, Bonnet H, et al: Herpes gestationis: Eruption bulleuse chez le nouveau-ne. *Bull Soc Fr Dermatol Syphiligr* 78:419-425, 1971.

12. Chorzelski TP, Jablonska S, Beutner EH, et al: Herpes gestationis with identical lesions in the newborn. *Arch Dermatol* 112:1129-1131, 1976.

13. Lynch MJ, Raphael SS, Mellor LD et al: *Medical Laboratory Technology and Clinical Pathology*, ed 2. Philadelphia, WB Saunders Co, 1969, p 994.

14. Beutner EH, Sepulveda MR, Barnett EV: Quantitative studies of immunofluorescent staining. *Bull WHO* 39:587-606, 1968.

15. Coons AH, Kaplan MG: Localization of antigen in tissue cells: II. Improvements in a method for the detection of antigen by means of fluorescent antibody. *J Exp Med* 91:1-13, 1950.

16. Müller-Eberhard HJ, Nilsson U, Aronsson T: Isolation and characterization of two β_1-glycoproteins of human serum. *J Exp Med* 111:201-215, 1960.

17. Assimeh SN, Bing DH, Painter EH: A simple method for the isolation of the subcomponents of the first component of complement by affinity chromatography. *J Immunol* 113:225-234, 1974.

18. Minta JO, Lepow IH: Solid phase radioimmunoassay of properdin. *Fed Proc* 31:787, 1972.

19. Minta JO: Changes in the immunochemistry of highly purified properdin in human serum. *J Immunol* 114:1415-1421, 1975.

20. Jordon RE, Sams WM Jr, Beutner EH: Complement immunofluorescent staining in bullous pemphigoid. *J Lab Clin Med* 74:548-556, 1969.

21. Kabat EA, Mayer MM: *Complement and Complement Fixation: Experimental Immunochemistry*, ed 2. Springfield, Ill, Charles C Thomas Publisher, 1961.

22. Platts-Mills TAE, Ishizaka K: Activation of the alternate pathway of human complement by rabbit cells. *J Immunol* 113:348-358, 1974.

23. Gelfand EW, Clarkson JE, Minta JO: Selective deficiency of the second component of complement in a patient with anaphylactoid purpura. *Clin Immunol Immunopathol* 4:269-276, 1975.

24. Gaither TA, Alling DW, Frank MM: A new one-step method for the functional assay of the fourth component (C4) of human and guinea pig complement. *J Immunol* 113:574-583, 1974.

25. Rapp HJ, Borsos J: *Molecular Basis of Complement Action*. New York, Appleton-Century-Crofts, 1970.

26. Müller-Eberhard HJ, Götze O: C3 proactinator convertase and its mode of action. *J Exp Med* 135:1003-1008, 1972.

Leukocytoclastic Angiitis in Subacute Bacterial Endocarditis

Sheldon Rubenfeld, MD, Kyung-Whan Min, MD

• The case of a patient who had palpable purpura on his lower extremities due to *Lactobacillus*-caused subacute bacterial endocarditis is reported. Histologic examination of the purpuric lesions demonstrated a leukocytoclastic angiitis. It is postulated that purpuric and other cutaneous lesions of subacute bacterial endocarditis are related to circulating immune complexes.

***(Arch Dermatol* 113:1073-1074, 1977)**

Skin lesions are often very helpful in making the diagnosis of subacute bacterial endocarditis (SBE). Petechiae, splinter hemorrhages, Osler nodes, and Janeway lesions are commonly described, but purpura has rarely been noted.

The pathogenesis of the cutaneous manifestations of SBE has been attributed to embolic phenomenon, altered capillary permeability, and immunologic or hypersensitivity reactions. We describe a patient with leukocytoclastic angiitis caused by SBE.

REPORT OF A CASE

A 40-year-old man was admitted to the Houston Veteran's Administration Hospital because of red spots on his legs. Two-and-one-half months prior to admission he had noted migratory polyarthralgias and weakness. Five weeks prior to admission, red spots appeared on the patient's legs that cleared in ten days but reappeared on the day of admission. During the previous two weeks he had noted daily fevers, drenching night sweats, dyspnea on walking three blocks, and paroxysmal nocturnal dyspnea without orthopnea, edema, or chest pain.

Physical examination revealed a pale, nervous, and slightly obese man in no acute distress. His temperature was 37.6 C; pulse rate, 110 beats per minute and regular; blood pressure, 146/90 mm Hg; and his respirations were 22/min. The skin showed multiple palpable purpuric lesions (Fig 1) on the anterior and posterior aspects of the legs. Funduscopic examination revealed three white exudates partially surrounded by hemorrhage. A systolic thrill was felt at the apex, and auscultation revealed a grade 4/6 holosystolic murmur and a third heart sound. The spleen was palpated 6 cm below the left costal margin.

Pertinent laboratory data included the following values: hematocrit, 25%, hemoglobin, 8.3 gm/100 ml, and a leukocyte count of 7,800/cu mm. The reticulocyte count was 0.8% and the platelet count was 302,000/cu mm. The RBCs were normochromic and normocytic with a rare fragmented RBC. Prothrombin time was 12 seconds with control of 12.3 seconds; partial thromboplastin time was 28.3 seconds with control of 28.1 seconds. The template bleeding time was 6.5 minutes (normal is less than 7 minutes), and the whole blood clot retraction was 74% (normal is 40% to 94%). Fibrinolysin and cryoglobulin tests were negative, as were direct and indirect Coombs tests; the plasma fibrinogen value was 370 mg/100 ml (normal is 160 to 415 mg/100 ml). The antistreptolysin 0 titer and antinuclear antibody titers were negative. Rheumatoid factor was positive 1:2,560 and the C3 level was 59 mg/100 ml (normal is 70 to 150 mg/100 ml). The BUN level was 21 mg/100 ml, serum creatinine clearance was 63 ml/min, and urinalysis results revealed proteinuria with RBCs too numerous to count. Chest film showed marked cardiomegaly; an echocardiogram demonstrated abnormal motion of the anterior and posterior leaflets of the mitral valve, with smudging of the anterior leaflet suggestive of vegetations.

The patient spiked fevers up to 39.1 C. One week after admission, six of 12 blood cultures grew a pleomorphic Gram-variable rod that was sensitive to penicillin and was later identified as *Lactobacillus*. Each day 24 million units of aqueous penicillin G potassium were administered intravenously, and the patient defervesced with resolution of the purpuric lesions during the next eight to ten days.

A biopsy specimen of the purpuric skin lesions showed small, dermal arterioles infiltrated by polymorphonuclear leukocytes with generalized disruption of the arterial walls and scattered nuclear debris (nuclear dust) within the exudate (Fig 2). Extravasated erythrocytes were also present. Gram stains of the skin biopsy sections failed to reveal any microbiological agents in the vascular lesions. Immunofluorescent staining on the fresh-frozen section of the skin biopsy specimen for human IgG and C were not revealing.

COMMENT

Purpuric lesions have only rarely been noted in patients with SBE. Weber[1] reported the first such case in 1910, in a patient who had a bleeding tendency manifested by bleeding gums and epistaxis. A causative organism was neither isolated in the blood nor found at autopsy. In 1912, Osler[2] described a patient with streptococcal SBE, purpuric skin lesions, and bleeding gums. Libman and Friedberg[3] noted seven such cases in their 1941 monograph, but many large reviews[4,5] of SBE since that time have failed to mention purpura as a manifestation of SBE.

Horwitz and Silbert[6] in 1968, however, reported two cases of streptococcal SBE with purpura, normal bleeding and coagulation times, normal platelet counts, and a negative tourniquet test. This report clearly ruled out coagulopathy as the cause of the purpura, but the pathogenesis of these as well as other cutaneous lesions in SBE remains obscure.

Merklen[7] considered damage to blood vessels rather than septic emboli as the mechanism for purpura in SBE. In 1936, Cornil et al[8] suggested that Osler nodes were a local response to protein from bacteria in the heart valve. In 1960, Howard[9] noted biopsy studies of Osler nodes which demonstrated perivasculitis in many tiny vessels beneath the Malpighian layers without evidence of emboli or bacteria. He considered these lesions to be allergic reactions to the causative organisms. In 1974, Weinstein and Schlesinger[10] attributed the classic peripheral signs of SBE to an allergic

Accepted for publication June 7, 1976.

From the Baylor College of Medicine, Houston, and the Department of Pathology, the Veterans Administration Hospital, Houston (Dr Min).

Reprint requests to Department of Pathology, Veterans Administration Hospital, 2002 Holcombe Blvd, Houston TX 77030 (Dr Min).

Fig 1.—Palpable purpuric lesions of leukocytoclastic angiitis on lower extremities of patient with subacute bacterial endocarditis.

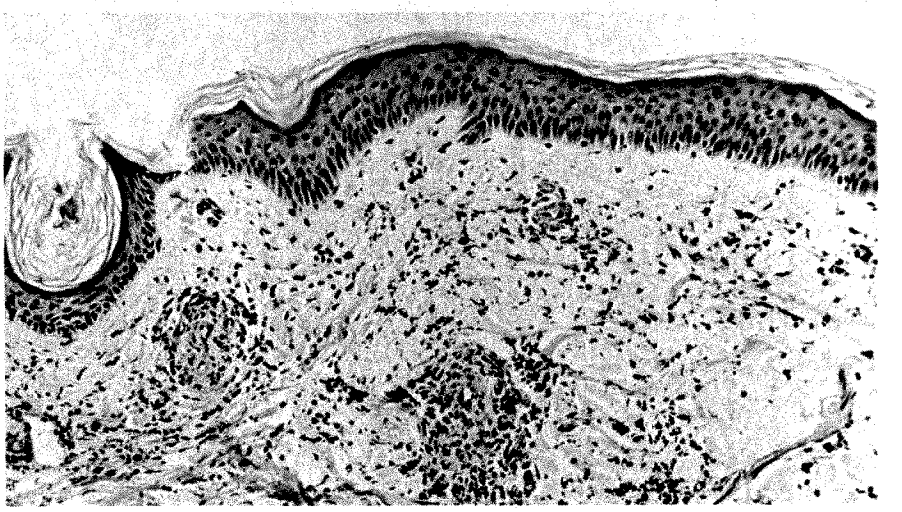

Fig 2.—Biopsy specimen of purpuric skin lesion. Dermal arterioles infiltrated by polymorphonuclear leukocytes. Nuclear debris and extravasated red blood cells are present in perivascular areas (hematoxylin-eosin, ×150).

vasculitis involving small arteries.

Williams and Kunkel[11,12] and others[13-15] have demonstrated various immunologic phenomena in endocarditis such as IgM anti-IgG antibodies (Rheumatoid factor), hypocomplementemia and high titers of agglutinating, complement-fixing, and opsonizing antibodies specific for the causative organism. Gutman et al[16] demonstrated γ-globulin and C in the glomerular basement membrane of patients with endocarditis, and concluded that the diffuse proliferative glomerulonephritis associated with SBE is probably caused by circulating antigen-antibody complexes.

The typical patient with leukocytoclastic angiitis[17] has palpable purpura that persist for one to four weeks and are localized to the lower extremities, and a compatible histological picture on biopsy specimens. In several large-scale studies on leukocytoclastic angiitis[18,19] an association with endocarditis was not found. The lesion of leukocytoclastic angiitis is identical to that of the Arthus reaction and to experimental serum-sickness produced by the trapping of antigen-antibody complexes within vessel walls. Although IgG and C have been seen in the skin lesions of many patients with leukocytoclastic angiitis,[20] failure to demonstrate immune complexes in the purpuric lesions of our patient does not detract from the hypothesis of an immunologic origin since removal of immune complexes occurs within 18 hours in the cutaneous vessels of guinea pigs in which an Arthus reaction was produced.[21] Biopsies of the skin lesions of our patient were performed several days after admission.

The depressed serum level of C3 and the evidence of renal involvement further suggest that our patient had an immune-complex disease, and that the purpuric lesions were a manifestation of trapping of antigen-antibody complexes arising as a consequence of his SBE. This lends support to the concept of an immunologic phase of SBE.[22] Further immunologic investigations of other cutaneous manifestations of SBE are warranted.

References

1. Weber FP: Chronic purpura of two years duration connected with malignant endocarditis, wrongly supposed to be connected with splenic anemia. *Br J Dermatol* 22:37-43, 1910.
2. Osler W: Chronic infectious endocarditis with an early history like splenic anemia. *Interstate Med J* 19:103-107, 1912.
3. Libman E, Friedberg CK: *Subacute Bacterial Endocarditis*. New York, Oxford University Press, p 74, 1941.
4. Lerner PI, Weinstein L: Infective endocarditis in the antibiotic era. *N Engl J Med* 274:199-206, 259-266, 323-331, 1966.
5. Pankey GA: Subacute bacterial endocarditis at the University of Minnesota Hospital, 1939 through 1959. *Ann Intern Med* 55:550-561, 1961.
6. Horwitz LD, Silbert R: Subacute bacterial endocarditis presenting as purpura. *Arch Intern Med* 120:483-486, 1967.
7. Merklen P: Endocardites secondaires des cardiaques avec purpura. *Presse Med* 37:727-728, 1929.
8. Cornil L, Mosinger M, Jouve A-X: Contribution a l'etude histologique du nodule d'Osler. *Ann Anat Pathol* 13:675-686, 1936.
9. Howard EJ: Osler's nodes. *Am Heart J* 59:633-634, 1960.
10. Weinstein L, Schlesinger JJ: Pathoanatomic, pathophysiologic and clinical correlation in endocarditis. *N Engl J Med* 291:832-837, 1122-1126, 1974.
11. Williams RC Jr, Kunkel HG: Rheumatoid factor, complement and conglutinin aberrations in patients with subacute bacterial endocarditis. *J Clin Invest* 41:666-675, 1962.
12. Williams RC Jr, Kunkel HG: Rheumatoid factors and their disappearance following therapy in patients with subacute bacterial endocarditis. *Arthritis Rheum* 5:126, 1962.
13. Laxdal T, Messner RP, Williams RC Jr, et al: Opsonic, agglutinating and complement-fixing antibodies in patients with subacute bacterial endocarditis. *J Lab Clin Med* 71:638-653, 1968.
14. Messner RP, Laxdal T, Quie PG, et al: Rheumatoid factors in subacute bacterial endocarditis—bacterium, duration of disease or genetic predisposition? *Ann Intern Med* 68:746-756, 1968.
15. Quie PG, Messner RP, Williams RC Jr: Phagocytosis in subacute bacterial endocarditis: localization of the primary opsonic site to Fc fragment. *J Exp Med* 128:553-570, 1968.
16. Gutman RA, Striker GE, Gilliland BC, et al: The immune complex glomerulonephritis of bacterial endocarditis. *Medicine (Baltimore)* 51:1-25, 1972.
17. Braverman IM: *Skin Signs of Systemic Disease*. Philadelphia, WB Saunders Co, 1970, pp 207-226.
18. Winkelmann RK, Ditto WB: Cutaneous and visceral syndromes of necrotizing or "allergic" angiitis: a study of 38 cases. *Medicine (Baltimore)* 43:59-89, 1964.
19. McCombs RP: Systemic "allergic" vasculitis. *JAMA* 194:1059-1064, 1965.
20. Stringa SG, Bianchi C, Casala AM, et al: Allergic vasculitis Gougerot-Ruiter syndrome. *Arch Dermatol* 95:23-27, 1967.
21. Cream JJ, Bryceson ADM, Ryder G: Disappearance of immunoglobulin and complement from the Arthus reaction and its relevance to studies of vasculitis in man. *Br J Dermatol* 84:106-109, 1971.
22. Cordeiro A, Costa H, Laginha F: Immunologic phase of subacute bacterial endocarditis: A new concept and general considerations. *Am J Cardiol* 16:477-481, 1965.

Cutaneous Infarction

Manifestation of Disseminated Mucormycosis

Barnett S. Kramer, MD; Alfred D. Hernandez, MD; Robert L. Reddick, MD; Arthur S. Levine, MD

• We describe the second reported case of cutaneous infarction as a manifestation of disseminated mucormycosis. The lesion, which closely resembled ecthyma gangrenosum, occurred in a leukemic patient who was on a regimen of broad-spectrum antibiotics. In this case as in the only other reported case, *Mucor pusillus* was the cause.

***(Arch Dermatol* 113:1075-1076, 1977)**

With the routine use of potent cytotoxic agents and broad-spectrum antibiotics in the practice of oncology, fatal deep mycoses have become increasingly frequent.[1,2] Laboratory confirmation of a deep mycosis is often difficult,[3] and physical signs may therefore be of particular value. Cutaneous infarction is not well known as a component of a disseminated mucormycosis.

REPORT OF A CASE

A 20-year-old, nondiabetic woman was admitted to the National Cancer Institute (NCI) in August 1975 for treatment of the third relapse of acute lymphoblastic leukemia (first diagnosed in September 1973). Reinduction therapy was initially attempted with asparaginase (L-asparaginase), vincristine sulfate, daunorubicin, and prednisone. The treatment was complicated by a bacterial, upper respiratory tract infection and by otitis media, which were treated successfully with oral sulfisoxazole and erythromycin stearate. The leukemia did not respond to the reinduction attempt, and the patient was then admitted to the Institute for one week of treatment with high-dose thioguanine, cyclophosphamide (Cytoxan), cytarabine, and methyl-CCNU (semustine) (TEAM). Her peripheral granulocyte count was less than 500 cu mm on days 4 to 28 following the inception of the TEAM regimen. Because of persistent fever of unknown origin, she was given cephalothin sodium, gentamicin sulfate, disodium carbenicillin, and daily WBC transfusions on days 8 to 26. By day 35 granulocytopenia and fever had remitted, but the patient remained in relapse, and a second course of TEAM at higher dosage was administered. Profound granulocytopenia and recurrent fever were present from day 50 until death. During this time, she received continuous broad-spectrum antibiotics and, on days 65 to 80, she received daily WBC transfusions for an apparent infection of the left cheek. The latter resolved, but spiking fevers persisted.

On day 117, an exquisitely painful 2 × 2.5-cm macular erythematous lesion appeared on the upper-abdomen without antecedent skin trauma. A chest film (normal one week earlier) showed infiltrates in the right lung with a small area of cavitation. The purpuric skin lesion enlarged to 9 × 8 cm during the next four days, with a nonblanching ring of surrounding erythema and a central area of vesiculation and necrosis (Fig 1). Biopsy specimens taken of the advancing erythematous ring and purpuric edge were culture-negative, although a few hyphae were noted on wet-crush preparations. The cavitary pneumonia progressed, and the patient died on day 121, 24 hours after she developed a left hemiparesis. All premortem and postmortem blood cultures were negative for bacteria and fungus.

At autopsy, leukemia was found in the bone marrow, liver, and spleen. Hemorrhagic infarction of the lungs, liver, right kidney, and brain was evident. Total occlusion of many vessels throughout these organs (including the superior saggital sinus) by broad, irregularly walled, nonseptate fungal hyphae of the type that are consistent with mucor, was evident on histologic sections (Fig 2). Culture of pulmonary tissue revealed *Mucor pusillus*.

Results of histopathologic examination of the skin lesion revealed thromboses of dermal blood vessels by mucor and necrosis of the overlying epidermis. Fungi were also present in the necrotic epidermis, morphologically similar to those found in other tissues.

COMMENT

Mucormycosis is almost uniformly fatal in the compromised host, and is usually diagnosed using postmortem material. It has been reported to involve nearly every organ, but premortem diagnosis is often difficult because of the inaccessibility of tissue necessary for biopsy or culture.[1] Isolation from blood is rare, positive CSF cultures have never been reported, and current serologic tests are of no value in diagnosis.[2] Skin lesions, although rare, may be of considerable importance since they might permit early recognition and treatment of disseminated infection. In patients who may achieve a remission of their underlying cancer, early treatment of the complicating mycosis would be of obvious value.

Localized subcutaneous phycomycosis is seen almost exclusively in cases in Indonesia and Africa; it is a well-described, self-limited, painless, mycetoma that occurs in noncompromised hosts; and it may resolve without definitive therapy.[4,5] How-

Accepted for publication Oct 22, 1976.

From the Pediatric Oncology, Pathology, and Dermatology Branches of the National Cancer Institute, Bethesda, Md.

Reprint requests to Pediatric Oncology, Pathology, and Dermatology Branches, National Cancer Institute, Building 10, Room 3B-12, Bethesda, MD 20014 (Dr Levine).

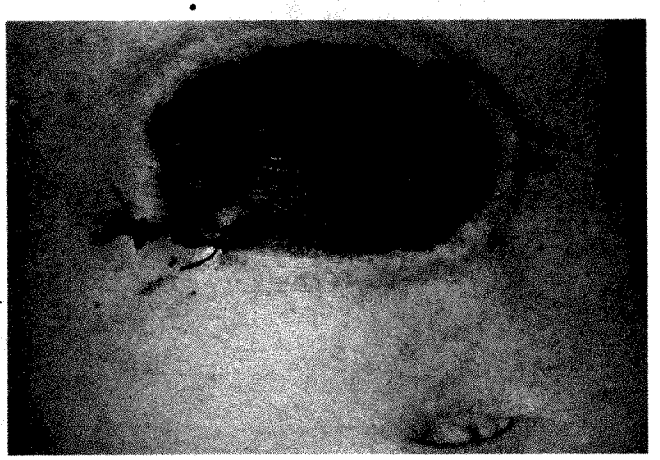

Fig 1.—Cutaneous involvement of skin by *Mucor pusillus*. Central macular area contains numerous bullae; lesion is surrounded by thin, erythematous rim separate from main lesion. Sutures mark sites of previous biopsies.

Fig 2.—Skin section near edge of lesion with subepidermal collections of fluid; nonseptate right angle branching hyphae of *Mucor pusillus* epithelium and dermis; small vessels within deep dermis were occluded by hyphae (PAS, ×275).

ever, there has been only one previous report of cutaneous infarction as a manifestation of disseminated mucormycosis.[6] Both in our case and in the earlier one, skin infarction and pain were prominent manifestations; and the lesion was very similar in appearance to ecthyma gangremosum.

Veliath et al have recently reported a case of disseminated mucormycosis in which the portal of entry was presumed to be a skin ulcer.[7] In that case, the ulcer was present for at least 15 days before the clinical and roentgenographic signs indicated pulmonary dissemination and infarction. In addition, there is a question as to whether the fungus found in the skin ulcer was a superinfection of a preexisting ulcer. However, it was believed certain that the skin manifestations did not arise as a result of a disseminated pulmonary lesion.

It is interesting that cutaneous infarction as a manifestation of disseminated mucormycosis is rare, especially in view of the marked propensity of this organism to cause widespread thromboses. The skin may be relatively uninvolved in phycomycetes infections. Large inocula of *Absidia* spores have been injected intravenously in more than 600 mice.[8,9] Although fungal lesions and thromboses were found in multiple organs, only one skin lesion was described—a subcutaneous granuloma with no cutaneous infarction. It is also of note that in the only previously reported case of cutaneous infarction in disseminated mucormycosis, *M pusillus* was identified, as it was in our case.[6] It may be that this particular species of phycomycetes has a propensity to produce cutaneous lesions.

Nonproprietary Names and Trademarks of Drugs

Asparaginase—*Crasnitin.*
Cephalothin sodium—*Keflin.*
Gentamicin sulfate—*Garamycin.*
Vincristine sulfate—*Oncovin.*

References

1. Meyer RD, Armstrong D: Mucormycosis—changing status. *CRC Crit Rev Clin Lab Sci* 4:421-451, 1973.
2. Meyer RD, Rosen P, Armstrong D: Mycomycosis complicating leukemia and lymphoma. *Ann Intern Med* 77:871-879, 1972.
3. Koneman EW, Truell JE: Diagnosis of pulmonary fungus infections. *Geriatrics* 29:99-106, 1974.
4. Baker RD, Seabury JH, Schneidou JD Jr: Subcutaneous and cutaneous mucormycosis and subcutaneous phycomycosis. *Lab Invest* 11(11):1091-1102, 1962.
5. Joe LK, Eng NT, Tjokronegora S, et al: Phycomycosis (mucormycosis) in Indonesia—description of a case affecting the subcutaneous tissue. *Am J Trop Med Hyg* 9:143-148, 1960.
6. Meyer RD, Kaplan MH, Ong M, et al: Cutaneous lesions in disseminated mucormycosis. *JAMA* 225:737-738, 1973.
7. Veliath AJ, Rao R, Radhakrisha M, Prabhu M, et al: Cutaneous phycomycosis (mucormycosis) with fatal pulmonary dissemination. *Arch Dermatol* 112:509-512, 1976.
8. Smith JB, Jones RH: Localization and fate of *Absidia ramosa* spores after intravenous inoculation of mice. *J Comp Pathol* 83:49-55, 1973.
9. Eades SM, Corbel MJ: Metastatic subcutaneous zygomycosis following intravenous and intracerebral inoculation of *Absidia corymbifera* spores. *Sabouraudia* 13:200-203, 1975.

Systemic Argyria Secondary to Topical Silver Nitrate

Jay P. Marshall II, MD, Richard P. Schneider, MD

• **A case of generalized argyria secondary to topical silver nitrate use on the oral mucosa is described, and the nature and history of argyria reviewed. The patient has extreme pigmentation of her skin and abdominal viscera, as seen on physical examination, gastroduodenoscopy, and laparotomy. Her use of silver nitrate applicators was uncontrolled by her dentist and pharmacist, and the diagnosis of argyria was not made until 2½ years of heavy usage had passed. Avoidance of similar cases requires the careful scrutiny of silver-containing medicinal usage by all health practitioners and pharmacists. Although the systemic distribution of silver in both elemental and ionic forms can be linked with no systemic toxicity, the resultant pigmentation can be devastating to the patient.**

(*Arch Dermatol* 113:1077-1079, 1977)

Argyria results from exposure to silver salts or silver protein colloids and can closely mimick cyanosis, methemoglobinemia, metastatic melanoma with melanogenuria, and hemochromatosis.[1-3] This paper describes a patient with generalized argyria secondary to mucosal absorption of topically-applied silver nitrate and presents a brief review of the history of argyria.

REPORT OF A CASE

A 46 year-old white woman presented to St Thomas Hospital in December 1975 for evaluation of chronic abdominal pain. The patient was extremely pigmented and has been told in 1972 that she had argyria. She had first used silver-containing medications in 1970 when her dentist suggested the use of topical silver nitrate for bleeding gingiva secondary to poorly fitting dentures. In April 1970, she began using the applicators at the rate of three weekly without a prescription. In November 1971, a bluish discoloration appeared about the patient's nasal and glabellar areas. She continued to use the silver nitrate applicators and referred herself to a physician for evaluation of the pigmentation in July 1972. She was strikingly pigmented at that time and was originally felt to have cardiac cyanosis. That diagnosis proved false, and other studies, including porphyrin levels, serum iron studies, hemoglobin electrophoresis, and serum cortisol levels were normal. The only drug that could be implicated was silver nitrate. Skin biopsy specimens revealed a large amount of intracellular and extracellular pigment with the distribution and staining properties of silver. She was advised to discontinue her use of silver nitrate sticks.

In 1973, she had had an exploratory laparotomy with excision of a cystic duct remnant and an intraoperative liver biopsy. The biopsy specimen revealed silver pigment deposited in portal areas and around central veins (Fig 1). During the following two years, no substantive decrease in the skin pigment was noted. The

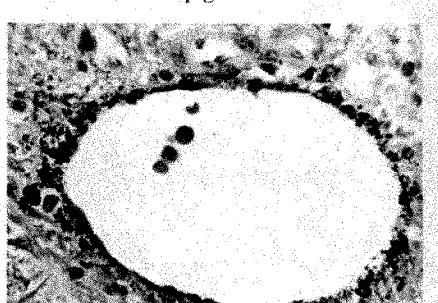

Fig 1.—Portal vein with pigmented granules surrounding vein wall (hematoxylin-eosin, original magnification ×400).

Accepted for publication Aug 31, 1976.

From the Gastroenterology Division, Department of Medicine, St Thomas Hospital, and the Gastroenterology Department, Vanderbilt University Medical School, Nashville, Tenn.

Reprint requests to Gastroenterology Division, St Thomas Hospital, 4220 Harding Rd, Nashville, TN 37202 (Dr Schneider).

patient continued to experience the abdominal pain noted prior to her first usage of silver nitrate and was referred to us for evaluation of this problem in December 1975.

On examination, she was a very deeply pigmented white woman with a slate grey hue to her skin (Fig 2 and 3). The pigmentation was most striking in the sun exposed areas, although present over the entire body. The nail lunulae were bluish with the rest of the nailbed a light grey. The pigment was totally confluent, giving the patient a noncaucasian appearance. The sclerae were grey, and the corneas revealed perilimbic brownish rings.

Due to her abdominal complaints, gastroscopy was performed. The entire esophagus, stomach, and duodenum had a faint greyish cast, and the stomach was inflammed secondary to poor gastric emptying as a sequella to previous gastric surgery. Reconstructive surgery was therefore performed with formation of a gastrojejunostomy and Roux-en-Y drainage. At operation, the patient's pancreas, stomach, hepatic capsule, spleen, intestines, and peritoneum were all discolored in a manner similar to the skin. The pancreas was by far the most pigmented and actually appeared "silver." Gastric biopsy (Fig 4) revealed deposition of silver granules in the connective tissue. Postoperatively, the patient improved and was discharged with only mild abdominal complaints.

Fig 2.—Patient's face demonstrating diffuse pigmentation.

Fig 3.—Patient's hands demonstrating pigmentation of skin and bluish-grey nail beds.

COMMENT

In ancient medicine, silver compounds were used largely for diseases of the nervous system due to the proposed relation between silver and the moon, and the belief that the insane were under the influence of the lunar deities. Angelus Sola, in 1647,[3] advocated internal use of silver nitrate in epilepsy, tabes, and chorea minor. De Fourcroy[4] reported the first case of argyria in 1791 in a Protestant minister in Hamburg with obstructive jaundice who had taken a solution of silver nitrate for several months and had eventually become "almost wholly black."[4] The prevalence of argyria increased until the late 19th century when the fear of silver toxicity decreased its use. Although Potter[5] attributed numerous maladies to argyria, present understanding is, however, that the systemic toxicity of silver is limited to pigmentation, except in acute silver poisoning where hemorrhagic, erosive intestinal lesions occur.[6] Systemic toxicity of silver is limited by its rapid binding to various active groups of proteins and the precipitation of silver chloride. Damage to the tissues only occurs when its ability to bind the silver locally is overwhelmed acutely by massive doses. The fatal oral dose is approximately 10 gm, although recovery has occurred after much larger doses.[7] Slow administration can result in huge amounts of the metal being stored in the body. The minimal oral dosage ingested to yield systemic argyria has been estimated to be 25 to 30 gm over a six-month period.[8] As is graphically demonstrated in this patient, the silver is diffusely distributed throughout the body with the highest concentrations occurring in the skin and connective tissues. The pigment may be silver sulfide, silver chloride, or the metallic silver, which results from the reduction of the silver salt within the tissues. This reduction is photoactivated, causing the skin to function in a manner similar to photographic film.[7] Silver also has a stimulatory effect on melanocytes, therefore adding to the increased pigmentation of the sun-exposed areas.[9]

The pigmentation of argyria is permanent. Local injections with 6% sodium thiosulfate solution and 1% potassium ferrocyanide intradermally can decrease silver concentrations in small areas.[10] The use of this is cumbersome and uncomfortable. Because the pigment is elemental silver, chelating agents such as dimercaprol and ethylenediaminetetracetic acid are ineffective.[7]

Localized argyria results from topical silver salts via either medicinal or occupational exposure. Buckley[9] reports a case of a duplicating machine operator who developed localized argyria of her hands from daily immersion in photographic developing solutions. Handling of silver metal by silversmiths and the oral suctioning of silver nitrate solutions in the preparation of silver beads are other causes of reported occupational argyria.[8,9]

As in this case, cyanotic heart disease is often an early consideration.[11,12] This diagnosis should be rapidly dispelled by history and laboratory evaluation. Corneal pigmentation resembling Kayser-Fleischer rings and azure lunulae, both present in this patient, were originally described by Whelton and Pope.[13] The extreme pigmentation of both skin and the abdominal organs seen in this patient has been described,[2,8,14] but no case of severe systemic argyria could be found that had been attributed solely to topical silver nitrate usage. Although argyria is listed as a complication of prolonged use of topical silver nitrate applicators, some manufacturers characterize this as "localized" argyria.

All silver-containing preparations are controlled and must be prescribed. Despite this, as demonstrated in this patient, the possible toxic effects of long-term silver use may be overlooked and indiscriminate use allowed.

Use of colloidal silver compounds such as mild silver protein (Argyrol) strong silver protein and (Protargol) for such varied indications as bladder irrigation, urethritis, nasal drops for cold prevention, mucosal ulcerations, cervicovaginitis, and conjunctivitis has been practiced. The use of silver arsphenamine in the early 20th century for the treatment of syphilis was associated with a significant incidence of at least localized argyria. In 1935, Gaul and Staud[15] reported 70 cases of argyria secondary to oral, intranasal, or pharyngeal use of organic and colloidal silver compounds. It appears that his series marked the end of widespread use of the silver colloid solutions as no subsequent reports have rivaled his in number of cases or frequency of detection. The current use of silver sulfadiazine in the treatment of burns must be carefully scrutinized to avoid excessive systemic absorption of silver from the wounds.

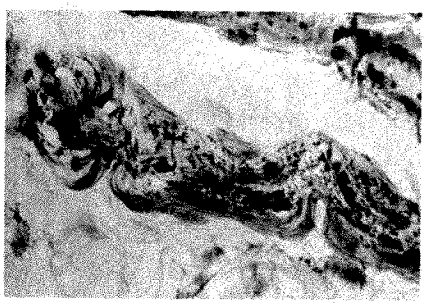

Fig 4.—Gastric biopsy with pigmented granules in connective tissue (hematoxylin-eosin, original magnification ×400).

In patients who ingest silver nitrate, marked argyremia may persist for months as demonstrated by spectography. This can be used diagnostically in the evaluation of possible argyria.[16] Histologically, the silver granules appear as small dark granules deposited diffusely in the tissue, with largest concentrations being in elastin, basal laminar areas of sweat glands, the epidermal membrane, and in connective tissue stroma throughout the body.[8,9,14] The particles average 300 A units in size with a calculated mass of 1.035×10^{-16} grams.[17] Spectroscopic examination of the biopsied tissue may be necessary to differentiate bismuth and silver in the skin.[10]

The impact of argyria on this patient is very significant. Her pigmentation, like that of the "blue man" of the Barnum and Bailey circus,[8] is extremely noticeable. Its presence causes her a great deal of embarrassment and anguish, and because of this, she has severely restricted her social activities and contacts with those outside her family.

References

1. Wintrobe MM, Thorn GW, Adams RD, et al (eds): *Harrison's Principles of Internal Medicine*. New York, McGraw-Hill Book Co, 1974, pp 276-279.
2. Ronchese F: Argyrosis and cyanosis-melanosis and cyanosis. *Arch Dermatol* 80:277-282, 1959.
3. Sola A: *Opera Medicochymica quae Extant Omnia; Frustulatim Hactenus Diversique Linguis Excusa, nunc in Unum Collecta Latinque Idiomate Edita*. Frankfurt, Germany, J Beyeri, 1647.
4. de Fourcroy AF (ed): *La Medicine Eclairee par les Sciences Physiques*. Paris, Buisson, 1791, p 342.
5. Potter SOL: *Handbook of Materia Medica, Pharmacy and Therapeutics, fourth edition*. Philadelphia, Blakiston, 1892, pp 115-116.
6. Hill WR, Pillsbury DM: *Argyria: The Pharmacology of Silver*. Baltimore, Williams & Wilkins, 1939.
7. Goodman LS, Gilman A: *Pharmacological Basis of Therapeutics*, ed 5. New York, MacMillan, 1975, pp 930-931.
8. Gettler AO, Rhoads CP, Weiss S: A contribution to the pathology of generalized argyria with a discussion of the fate of silver in the human body. *Am J Pathol* 3:631-652, 1927.
9. Buckley WR: Localized argyria. *Arch Dermatol* 88:531-539, 1963.
10. Stillians AW: Argyria. *Arch Dermatol Syphilol* 35:67-77, 1937.
11. Rich LL, Epinette WW, Nasser WK: Argyria presenting as cyanotic heart disease. *Am J Cardiol* 30:290-292, 1972.
12. Levine SA, Smith JA: Argyria confused with heart disease. *N Engl J Med* 226:682-684, 1942.
13. Whelton MJ, Pope FM: Azure lunules in argyria. *Arch Intern Med* 121:267-269, 1968.
14. Prose PH: An electron microscopic study of human generalized argyria. *Am J Pathol* 42:293-299, 1963.
15. Gaul LE, Staud AH: Clinical spectroscopy. *JAMA* 104:1387-1390, 1935.
16. Blumberg H, Carey TN: Argyemia: Detection of unsuspected and obscure argyria by the spectrographic demonstration of high blood silver. *JAMA* 103:1521-1524, 1934.
17. Buckley WR, Oster CF, Fassett DW: Localized argyria. *Arch Dermatol* 92:697-705, 1965.

Eruptive Nevocytic Nevi After Severe Bullous Disease

Alfred W. Kopf, MD; Charles Grupper, MD; Rudolf L. Baer, MD; John C. Mitchell, MD

• In two patients, hundreds of nevocytic nevi (melanocytic nevi) appeared in sites of severe bullous dermatoses that were considered to be toxic epidermal necrolysis and erythema multiforme exudativum, respectively. This phenomenon may result from benign melanocytic hyperplasia accompanying keratinocytic hyperplasia during the healing process of some of the denuded areas of the skin.

(*Arch Dermatol* 113:1080-1084, 1977)

About 1% to 4% of newborn white infants possess one or more pigmented nevi at birth.[1] During the first three decades of life, the average number of such moles increases to 30 or 40 per person.[2,3] Sometimes nevocytic nevi can be very numerous, very large (giant nevocytic nevi) or in zosteriform distribution. Usually, nevocytic nevi appear gradually in the early years of life as hyperpigmented and macular lentigines or as junction nevi; they are rather symmetrically distributed over the cutaneous surface.[4] In contrast to this usual course, the two patients presented in this report abruptly developed hundreds of nevocytic nevi in sites that had been previously involved by bullous dermatoses.

REPORT OF CASES

Case 1.—In June 1971, this 8-year-old white girl developed a severe eruption involving the skin, eyes, and nails (Color Fig 1). A diagnosis of Lyell's syndrome (toxic epidermal necrolysis) was made. The Stevens-Johnson type of erythema multiforme was considered in differential diagnosis. After subsidence of the acute manifestations, in January 1972, the patient had the following skin changes: mottled, faint, brownish, erythematous, coalescing patches over her trunk; an erosion in the right nostril; thinned finger nail plates; and an area of peculiar brownish-black hyperpigmentation on the anterior part of her left shoulder, within which were darker, buckshot-like macules as well as circinate and gyrate, dark brown lesions.

A biopsy, taken from a hyperpigmented area in her left axilla, showed nests of nevus cells at the dermal-epidermal junction. A histologic diagnosis of "junction nevus" was made.

Examination by an ophthalmologist in July 1971, showed severe photophobia and fibrosis of the conjunctivae and eyelids. Vision was 20/20 in the right eye and 20/50 in the left. The right lids exhibited trichiasis and marked keratinization of the margins extending onto the palpebral conjunctivae. A keratinized plaque was seen in the right lower fornix. There was developing symblepharon with filamentary bands between the lids at the canthi. The lower fornix was shrinking. The cornea was clear and the fundus negative. The left eye showed more severe symblepharon and conjunctival shrinkage. The cornea exhibited diffuse superficial punctate keratitis with filaments. The diagnosis was cicatricial phase of Lyell's syndrome with possible continuing activity.

The patient was again seen in April 1972, at which time she had many more pigmented lesions. Over the anterior aspect of her right shoulder, she had patches of brown, speckled, macular lesions. On the anterior aspect of her left shoulder, there were very many pinhead-sized, barely elevated, brownish papules (Color Fig 2). In her right axilla were numerous, deeply pigmented macular and slightly papular lesions (Color Fig 3). On the trunk, faint hyperpigmentation remained in the areas that had been involved during the acute phase of the bullous disease. There was very superficial scarring in a few of these areas. Both thumb and middle finger nail plates were thinned and dystrophic.

The patient was seen again in August 1972, April 1973, and November 1973, with only a very slight increase in the number of pigmented lesions (Color Fig 4). Light microscopy of specimens revealed nests of typical benign nevus cells at the dermal-epidermal junction and in the dermis (Color Fig 5). Junctional and intradermal nevus cells were readily demonstrated on plastic embedded (1-μ thick) sections (Color Fig 6).

Additional studies included electron microscopy (EM) of two punch biopsy specimens obtained under local anesthesia and fixed immediately for EM processing. One-micron thick sections were studied. Some melanocytes overlying intradermal nevocytes exhibited normal features, having long dendrites and normal melanosome synthesis with respect to number, size, and keratinocytic delivery. In the area of nevocytic hyperplasia (Figure), the epidermal melanocytes had few dendrites and were round in shape. Their melanosomal content was reduced. In the dermis, the nevus cells had short cytoplasmic processes. Macrophages were dispersed throughout the papillary and reticular dermis. Melanosomes resembled those seen in type B nevus cells or were round and contained dense vesicles and electron opaque structures. The nevus cells in the deep dermis had few melanosomes and some of these were round and irregularly stained.

Urinary melanogens were determined by the method of Rorsman-Rosengren.[5-7] Determinations of dihydroxyphenylalanine (DOPA), cysteinyl-DOPA, dopamine, and creatinine were made on two separate morning specimens. All these metabolites were within normal limits (Table).

When last examined elsewhere in February 1976, the eruptive nevocytic nevi remained virtually unchanged and rebiopsy of one of the axillary lesions again showed a benign compound nevocytic nevus.

Case 2.—In 1969, an 8-year-old white boy developed measles, followed by a widespread bullous eruption diagnosed as Stevens-Johnson syndrome (erythema multiforme exudativum). He was very ill at the time of the bullous eruption and had a stormy course in the hospital. Subsequently, he lost his hair and nails. Approximately six to eight weeks after this illness, multiple pigmented lesions were noted on the trunk in areas that had been involved by the bullous lesions. Virtually all of the lesions developed within a few months

Accepted for publication Sept 10, 1976.

From the Department of Dermatology, New York University School of Medicine, and the Oncology Section, Skin and Cancer Unit, New York University Medical Center, New York (Drs Kopf and Baer); Fondation Francaise Du Psoriasis, Paris (Dr Grupper); and the Division of Dermatology, University of British Columbia, Vancouver (Dr Mitchell).

Reprint requests to Skin and Cancer Unit, 562 First Ave, New York 10016 (Dr Kopf).

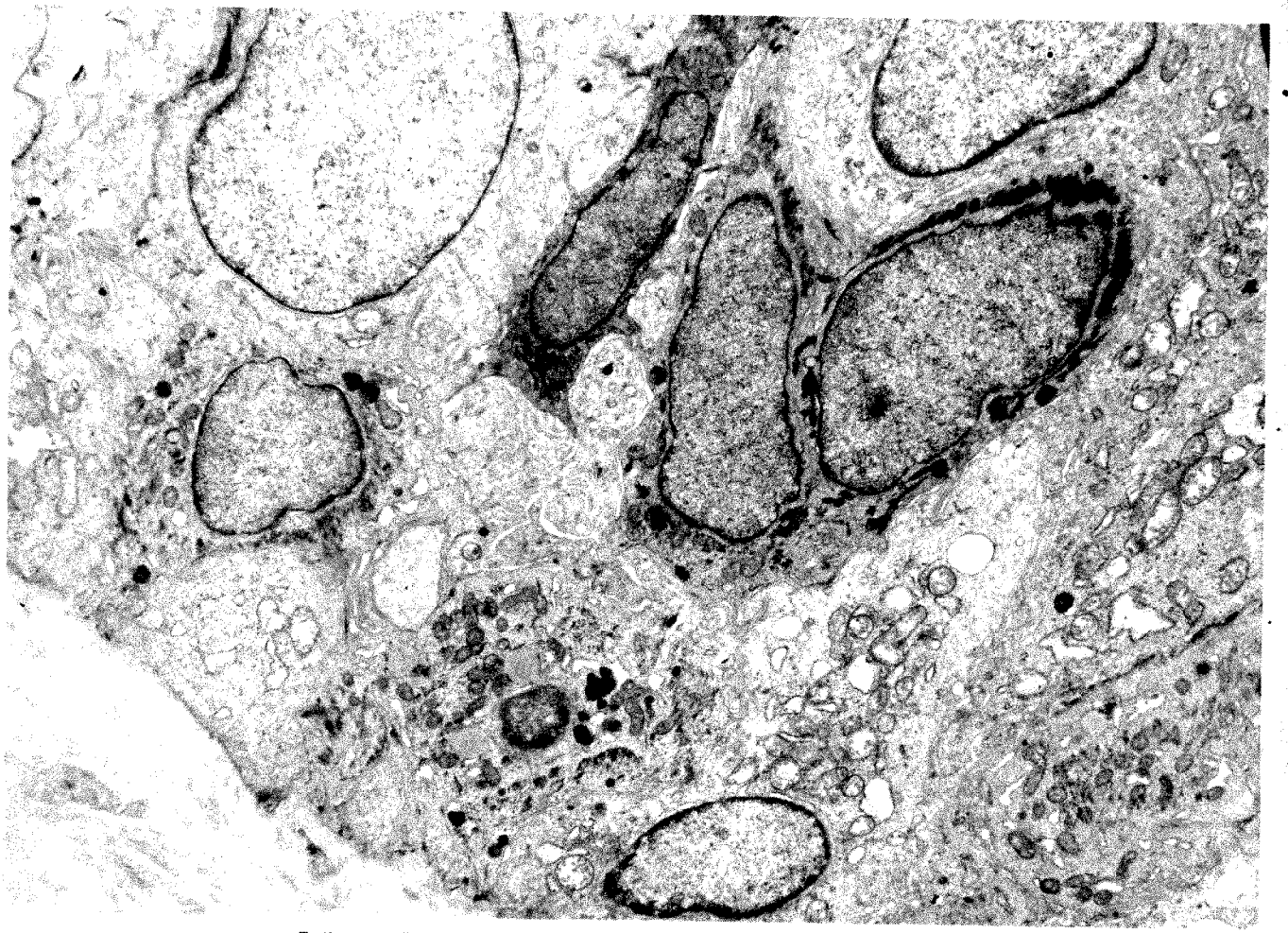

Patient 1. Electron photomicrograph of nest of junction nevus cells. Only a few keratinocytes (darker cells) remain in this area.

after the illness. Since their onset, the pigmented lesions have more or less remained stationary. When examined in August 1974, five years after the acute illness, he presented with corneal scarring, nail dystrophy, and eruptive nevi over a large area of his back (Color Fig 7).

Two biopsies of the pigmented lesions were performed. Biopsy 1 specimen had the features of a typical compound nevus (Fig 8). Except for some hyperpigmentation of the keratinocytes in the epidermis and an apparent increase in the number of clear cells (melanocytes) at the dermal-epidermal junction, the epidermis between the clusters of nevus cells was normal. The nevus cells at the dermal-epidermal junction formed classic theques of varying sizes. The nevus cells in the dermis were present in nests and cords of varying sizes and shapes. A considerable amount of pigment was present in these intradermal clusters of nevus cells. No mitoses were noted in the nevus cells, and their size and shape were typical of benign moles. No features of benign juvenile melanoma were noted. There was no inflammatory reaction surrounding the nests of nevus cells nor in any portions of the cutaneous biopsy. In summary, the findings were those of uncomplicated typical compound nevi.

The findings in biopsy 2 specimens were identical to those of biopsy 1 except that there was somewhat more pigment in the nevus-cell nests at the dermal-epidermal junction and that there was a sparse perivascular inflammatory infiltrate in patchy fashion in the dermis. Again, the histologic findings were those of a benign, compound nevocytic nevus.

COMMENT

The following constellation of findings seems to set apart these two patients from those with other types of nevocytic nevi: (1) hundreds of nevocytic nevi erupted over a relatively short period of time in an asymmetric fashion; (2) both patients were children (age 8); (3) both patients had developed a severe bullous dermatosis prior to the appearance of the eruptive nevus-cell nevi; (4) in both cases, histologic examination of more than one pigmented lesion showed benign, compound nevi; and (5) in both patients relatively long-term follow-up (four and six years) showed the condition to have reached a point of stability in terms of the number of lesions without tendency for spontaneous involution.

Several possibilities were considered in order to explain these unusual lesions. First, we considered the possibility that they represented disseminated benign juvenile melanoma[5]; but the histopathologic findings did not meet the criteria set forth for this type of neoplasm.[5] Secondly, the abrupt onset, number, and clinical appearance of the lesions made us consider malignant melanoma in a phase of satellite metastases. This





Fig 1

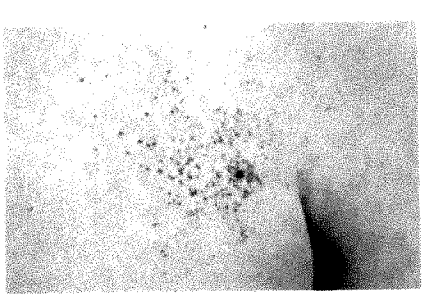

Fig 2

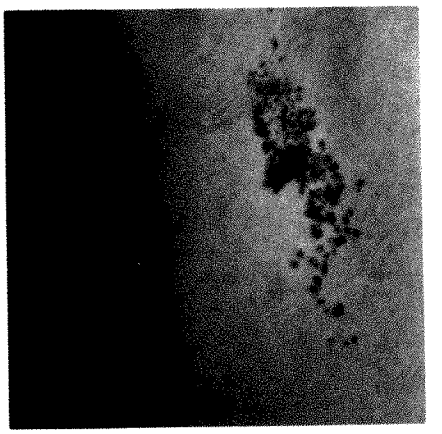

Fig 3

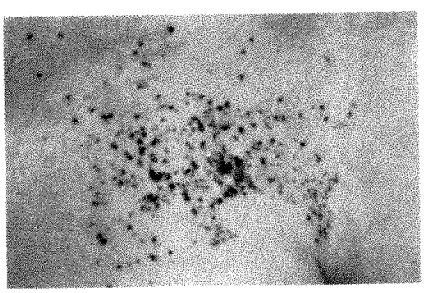

Fig 4

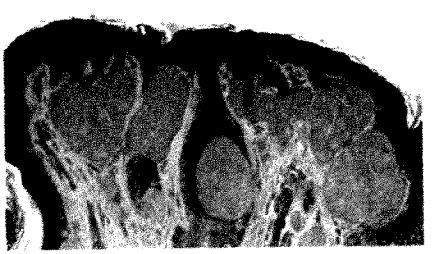

Fig 6

Fig 7

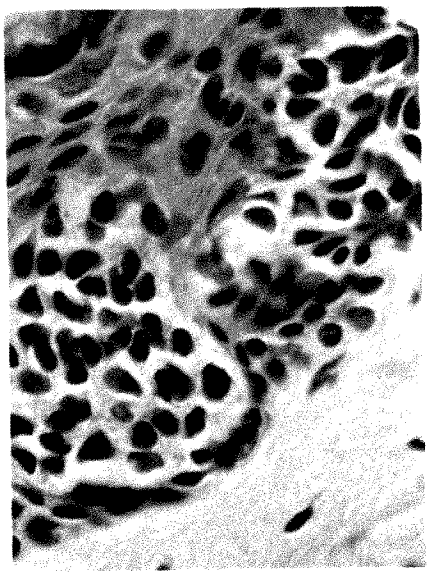

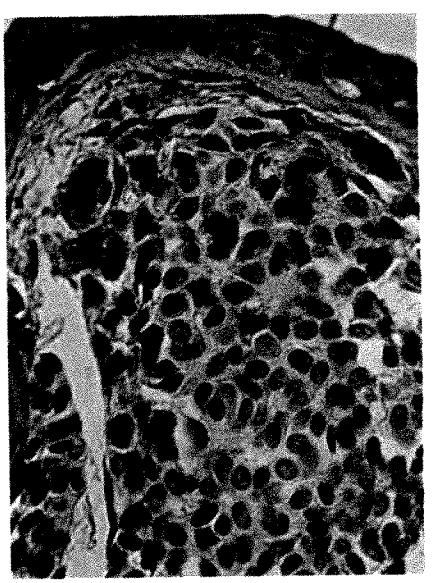

Fig 5

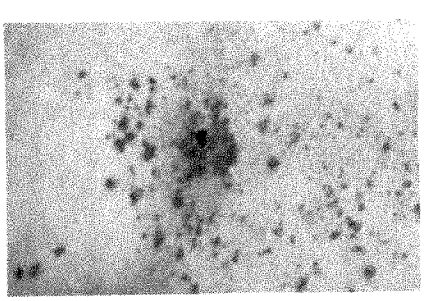

Fig 8

Fig 1.—Patient 1. Toxic epidermal necrolysis involving face (top), legs (center), and hands (bottom), June 1971.

Fig 2.—Patient 1. Ten months after onset of illness. Photo illustrates numerous nevocytic nevi on left thoracic area (April 4, 1972).

Fig 3.—Patient 1. Sixteen months after onset of illness. Note cluster of nevocytic nevi in the axilla (Oct 23, 1972).

Fig 4.—Patient 1. Twenty-nine months after onset of illness. Note little change in number, size or distribution of nevi on thoracic area (Nov 28, 1973).

Fig 5.—Patient 1. Photomicrographs showing nests of typical junctional and intradermal nevus cells (top, original magnification ×100; bottom, hematoxylin-eosin, original magnification × 40).

Fig 6.—Patient 1. One-micron thick sections of plastic embedded specimen. Note large nevus cell nests at the dermal-epidermal junction (original magnification ×10).

Fig 7.—Patient 2. Eruptive nevocytic nevi of back.

Fig 8.—Patient 2. Nests of benign junctional and dermal nevus cells (hematoxylin-eosin, original magnifications ×10).

Urinary Melanogens in Patient 1

Date	DOPA, mg/ml	Cysteinyl-DOPA, γ/ml	Dopamine, mg/ml	Creatinine, mg/ml	Ratio: Cysteinyl-DOPA Creatinine γ/ml × 10, mg/ml
12/4/74	0.00	0.024	0.48	2.25	1.07
12/12/74	0.02	0.027	0.28	1.90	1.42
Normal control	< 0.16	< 0.03	< 0.5	≃ 3	< 5

diagnosis was ruled out by the findings that the lesions were benign compound nevi and by the subsequent course that showed no further dissemination in four-year and six-year follow-ups, respectively.

To explain the phenomenon of eruptive nevocytic nevi in these two patients, we postulate that, during the re-epithelialization entailed in the healing process of the bullous eruptions, there was stimulation of widely disseminated melanocytes, each one of which had the potential for producing nevus cells. The fact that this condition was observed in young patients during their prime years of life for developing pigmented nevi[2] would favor this conjecture.

It is also known that nevus-cells or their precursors can be involved in the healing process after partial removal of moles. For example, after partial removal of giant nevus-cell nevi, it is not unusual to see hyperpigmented streaks coursing over the surface of the scars produced by the surgical procedures. Melanocytes can migrate along with epithelium as has been demonstrated in a number of studies.[10-12] Such melanocyte migration is associated with melanocyte multiplication.[13]

It is generally held that nevus cells are derived from dermal-epidermal melanocytes.[14] Thus, a failure of the usual control mechanisms regulating melanocytic proliferation (eg, by a melanocyte chalone)[15] could be considered as a possible explanation for the tremendous, albeit, temporary proliferation of nevus cells in our patients. Benign nevocytic nevi, after partial removal, can recur with clinical hyperpigmentation. Though some of the original lesions so treated were histologically shown to be intradermal nevi, the recurrent hyperpigmentations took on the histologic aspects of junction or compound nevi.[14,16] Such lesions can sometimes simulate malignant melanomas and the neologism "pseudomelanoma" has been proposed.[17] A concept of "seeded nevus cells" to explain recurrences of nevi after partial removal was suggested by Gougerot in 1947.[18] Schoenfeld and Pinkus[14] reported that in some instances, the melanocytes that produced recurrence of pigmentation in nevocytic nevi after incomplete removal appeared to be derived from nevus cells around hair roots. Since hair root melanocytes can migrate during wound healing,[13] an adnexal (pilar) source of melanocytes could have been responsible for the spotty "buckshot" distribution of nevi in our two patients.

Very little is known about the rapidity of the process of maturation of nevocytic nevi. We know that most such nevi removed in the first few decades of life have a significant component of junctional theques or nests; but that in nevi removed later in life, the cells are mostly intradermal in location.[4,19,20] Since this process of dropping off or "Abtropfung" is usually incomplete, most clinically typical intradermal nevi have some few remaining junctional theques.[21] The biopsies in our patients were done 6, 31, and 60 months after the abrupt onset of the nevi. All already showed intradermal elements; thus, at least under some circumstances, nevocytic nevi can develop a combination of junctional and intradermal elements in a relatively short time.

Since juvenile lentigines are considered to be precursors of nevocytic nevi, the eruptive nevocytic nevi reported here may be related to various syndromes of lentiginosis.[22] This similarity is especially true for the syndrome of lentiginosis profusa in which large numbers of lentigines develop in a short period of time in adolescents and young adults.[23-27] Crops of pigmented nevi can develop rapidly in adolescence and during pregnancy. They can also appear without any apparent hormonal influence as reported by Coskey[28] who collected and documented three cases of eruptive pigmented lesions (nevus and lentigo) in a two-year period. In clinical practice, it is not unusual to be consulted by patients who report a sudden appearance of numerous moles, but in our review of the literature, we were unable to find previous reports of eruptive, pigmented, nevocytic nevi following bullous dermatoses, as occurred in the patients reported here. In some cases of lentiginosis profusa[29] which were actually examples of widespread nevocytic nevi, partial or complete spontaneous disappearance of the pigmented lesions seems to have ensued. Such disappearance of lesions did not occur in our patients during the observation periods noted.

The precise pathogenesis of nevo-

cytic nevi is not known. The hypothesis suggested above, melanocytic seeding of some healing sites following bullous dermatoses, remains unproven. Perhaps the precursors of nevus cells are nevoblasts that are special melanocytes destined to give rise to a broad spectrum of morphologic types of nevocytic nevi,[30] including those of the eruptive variety. One has to explain further proliferation of the melanocytes by invoking theories such as those of clonal selection, pathogenic induction, and accidental mutation.[31] A local abundance of a nerve-growth factor from dermal neural structures could provide a local stimulus for melanocytic proliferation.[32] However, the seeding hypothesis leaves many questions unanswered, such as the following: Why is this phenomenon not observed more often? Why does it not occur after extensive cutaneous burns, after dermabrasions, or even after bullous *Rhus* dermatitis? Why has it not been reported following other types of bullous dermatoses such as epidermolysis bullosa? Why are the eruptive nevi localized to only a portion of the skin affected by the bullous disease?

The phenomenon of eruptive nevocytic nevi following bullous disease may result from the profound epidermal necrosis that occurred as a consequence of bulla formation and that called forth a burst of mitoses of epidermal keratinocytes. The ratio of keratinocytes to melanocytes is approximately 36 to 1,[33] and melanocytes must presumably proliferate along with keratinocytes to maintain this ratio of cells. Such orchestration must require very precise mechanisms to result in a perfect balance of recreated normal epidermal-melanin units. It is possible that the control mechanisms concerned with melanocytic proliferation went astray during the wound healing process so that an overabundance of pigment cells resulted leading to the formation of numerous nevocytic nevi.

Since these patients have been followed for only four and six years, respectively, the potential for malignancy in such cases is not known. In instances of giant nevocytic nevi, which also cover large areas of the skin, the possibility for malignant transformation is substantial.[34-36] Our patients have numerous nevocytic nevi, but the lesions are small and widely scattered rather than concentrated in the large plaques as occurs in giant nevocytic nevi.

We hope to continue to follow these patients and report at a later date any further developments.

Goodwin Breinin, MD, Chairman of the Department of Ophthalmology, New York University School of Medicine, performed the ophthalmic examinations on patient 1; J. P. Cesarini, MD, Laboratoire de Recherches sur les Tumeurs de la Peau Humaine, Foundation Ophtalmologique A de Rothschild, performed the electron microscopic examinations and interpretations; Dr Hewes, of the American Hospital in Paris, treated patient 1 in collaboration with C. Grupper, MD, when she presented with the acute phase of toxic epidermal necrolysis; Beltzer Garelly, MD, performed the light microscopy of patient 1; and William S. Wood, MD, examined the histologic material by light microscopy on patient 2.

The Rudolf L. Baer Foundation for Skin Diseases, Inc, aided in defraying the costs of preparation of the manuscript and publishing the color illustrations.

References

1. Walton RG, Jacobs AH, Cox AJ: Pigmented lesions in newborn infants. *Br J Dermatol* 95:389-396, 1976.

2. Nicholls EM: Development and elimination of pigmented moles, and the anatomical distribution of primary malignant melanoma. *Cancer* 32:191-195, 1973.

3. Stegmaier OC, Becker SW Jr: Incidence of melanocytic nevi in young adults. *J Invest Dermatol* 34:125-129, 1960.

4. Stegmaier OC: Life cycle of the nevus. *Mod Med* 31:79-91, 1963.

5. Rorsman H, Rosengren AM, Rosengren E: Determination of 5-S-cysteinyldopa in melanomas with a fluorimetric method. *Yale J Biol Med* 46:516-523, 1973.

6. Meunier M: *Interet du dosage de la 5-S-cysteinyldopa dans les urines des patients porteurs de melanome malin*, thesis, Paris, 1975.

7. Agrup G, Agrup P, Andersson T, et al: Urinary excretion of 5-S-cysteinyldopa in patients with primary melanoma or melanoma metastasis. *Acta Derm Venereol* 55:337-341, 1975.

8. Capetanakis J: Juvenile melanoma dissimenatum. *Br J Dermatol* 92:207-211, 1975.

9. Kopf AW, Andrade R: Benign juvenile melanoma, in *Year Book of Dermatology*. Chicago, Year Book Medical Publishers, 1966.

10. MacKenzie I, Rous R: The experimental disclosure of latent neoplastic changes in tarred skin. *J Exp Med* 73:391-416, 1941.

11. Billingham RF, Medawar PB: Pigment spread and cell heredity in guinea-pig skin. *Heredity* 2:29-47, 1948.

12. Bart RS, Kopf AW: Demonstration of dendritic bridges between migrant limbal melanocytes in the cornea of the guinea pig, in Riley V (ed): *Pigmentation: Its Genesis and Biologic Control*. New York, Appleton-Century-Crofts, 1972, pp 155-161.

13. Starrico RG: The melanocytes and the hair follicle. *J Invest Dermatol* 35:185-194, 1960.

14. Schoenfeld RJ, Pinkus H: The recurrence of nevi after incomplete removal. *Arch Dermatol* 78:30-35, 1958.

15. Mohr U, Althoff J, Kinzel V, et al: Melanoma regression induced by chalone. *Nature* 220:138-139, 1968.

16. Cox AJ, Walton RG: The induction of junctional changes in pigmented nevi. *Arch Pathol* 79:428-434, 1965.

17. Kornberg R, Ackerman AB: Pseudomelanoma: Recurrent melanocytic nevus following partial surgical removal. *Arch Dermatol* 111:1588-1590, 1975.

18. Gougerot H: Recidive des naevi, apres destruction, dans le meme type, dans la meme forme, dans la meme etundue. *Monde Med* 57:50, 1947.

19. Lund HZ, Stobbe GD: The natural history of the pigmented nevus: Factors of age and anatomic location. *Am J Pathol* 25:1117-1155, 1949.

20. Helwig EB: Malignant melanoma of the skin in man, in: *Conference on Biology of Cutaneous Cancer*, monograph No. 10. Bethesda, Md, National Cancer Institute, 1962, pp 287-295.

21. Kopf AW, Andrade R: A histologic study of the dermo-epidermal junction in clinically "intradermal" nevi, employing serial sections. *Ann NY Acad Sci* 100:200-220, 1963.

22. Rook A, Wilkinson DS, Ebling FJG: *Textbook of Dermatology*, ed 2. Oxford, England, Blackwell, 1972, p 1252.

23. Degos R, Carteaud A: Lentiginose profuse keratosique. *Ann Dermatol Syphiligr* 83:125, 1956.

24. Ebert MH: Multiple pigmented nevi: A study of the origin of the nevus cell. *Arch Dermatol* 37:1-21, 1938.

25. Sanderson KV: Eruptive telangiectatic cellular naevi. *Br J Dermatol* 72:302-307, 1960.

26. Selmanowitz VJ: Lentiginosis profusa (multiple lentigines syndrome). *Acta Derm Venereol* 51:387-393, 1971.

27. Zeigler EP, Becker SW: Generalized lentigo. *Arch Dermatol* 33:109-125, 1933.

28. Coskey RJ: Eruptive nevi. *Arch Dermatol* 111:1658, 1975.

29. Kiess O: Zur kasuistic des lentiginosis profusa. *Derm Wochenschr* 85:1729-1735, 1927.

30. Mishima Y: Melanocytic and nevocytic malignant melanomas: Cellular and subcellular differentiation. *Cancer* 20:632-649, 1967.

31. Whimster IW: The group behavior of pigment cells. *Trans St Johns Hosp Dermatol Soc* 57:57-86, 1971.

32. Schenkein I: The chemistry and biology of nerve growth factor, in Lajtha A (ed): *Handbook of Neurochemistry*. New York, Plenum Press, 1971, vol 5, pp 503-524.

33. Frenk E, Schelehorn JP: Zur morphologie der melanineinheit. *Dermatologica* 139:271-277, 1969.

34. Reed WB, Becker SW Sr, Becker SW Jr, et al: Giant pigmented nevi, melanoma and leptomeningeal melanocytosis. *Arch Dermatol* 91:100-119, 1965.

35. Kaplan EN: The risk of malignancy in large congenital nevi. *Plast Reconstr Surg* 53:421-428, 1974.

36. Honigsmann H, Wolff K, Konrad K: Systemische nevomatose: Tierfellnaevus, multiple eruptive naevi und nevuszellabsiedelungen in den lymphknoten. *Hautarzt* 25:547-555, 1974.

Eczema Herpeticum Caused by Herpesvirus Type 2

A Case in a Patient With Darier Disease

Paul G. Hazen, MD, R. Bennett Eppes, MD

• This, to our knowledge, is the first documented report of eczema herpeticum due to infection with herpesvirus hominis type 2. The virus was isolated from a patient with known Darier disease who developed Kaposi varicelliform eruption. Recent increases in the incidence of infection with type 2 herpes simplex as well as the high frequency of recurrence with this virus make this infection of potential significance in patients with preexisting cutaneous disease.

(*Arch Dermatol* 113:1085-1086, 1977)

Darier disease (hyperkeratosis follicularis) has been reported to be among the dermatoses susceptible to the sudden onset of a widespread vesicular eruption accompanied by high fever known as Kaposi varicelliform eruption. Both the vaccinia virus and the herpes simplex virus have been implicated, and the infections are referred to respectively as eczema vaccinatum and eczema herpeticum.

There are two types of herpes simplex virus that can be distinguished by clinical and laboratory criteria. Herpesvirus hominis type 1 is the virus most often responsible for perioral herpes infections, although other anatomic regions may be involved. Herpesvirus type 2 is frequently implicated in genital infections, eruptions of the hands, thighs, and buttocks and in infants with neonatal herpes infections, although it also can be found in other sites.[1] Type 1 and type 2 herpesvirus can be distinguished in vitro by their different growth patterns on chorioallantoic membrane of the chick embryo, by their different biochemical composition, and by specific serologic responses in the host.[2]

The purpose of this report is to present a patient with known Darier disease who developed Kaposi varicelliform eruption caused by the herpes simplex type 2 virus. To the best of our knowledge, this is the first report of eczema herpeticum in which the herpesvirus hominis type 2 virus has been isolated as the causative agent.

REPORT OF A CASE

A 26-year-old man with known Darier disease since age 6 was admitted to University Hospitals of Cleveland in August 1974, with a widespread vesicular eruption and high fever.

For many years the patient had had persistent hyperkeratotic papules on the mid-chest, back, upper arms, and legs. Previous skin biopsies had confirmed the diagnosis of Darier disease. The patient's father also had Darier disease.

Extensive vesiculation and crusting of forehead, neck, and ears due to infection with herpes simplex virus type 2.

One week before admission the patient noted a cluster of small blisters on the shaft of the penis. The lesions became pustular, and the patient developed moist and tender fissuring with crusting in the intertriginous areas of the groin. Four days later, multiple exudative and crusted lesions appeared on the ears, forehead, and chest. The patient developed chills, fever, and malaise and became toxic.

On admission, the patient appeared acutely ill. The temperature was 40 C. There were clusters of umbilicated vesicles on an erythematous base and extensive crusting on the neck, back, and forehead (Figure). Both pinnae showed a vesiculopustular eruption with crusting and marked edema. There were multiple superficial erosions of the penis and severe maceration and crusting of the genitocrural folds and presternal region. Multiple "dirty-brown," scaly papules were noted on the arms and legs.

The patient's past medical history included varicella in childhood and smallpox vaccinations without complication at the ages of 1, 5, and 12. The patient denied a history of "cold sores," herpes zoster, or previous genital lesions.

Results of laboratory studies were as follows: white blood cell count, 7,000/cu mm, with 72% polymorphonuclear leukocytes, 15% lymphocytes, 9% monocytes, and 4% eosinophils. The hematocrit value was 42%, and the erythrocyte sedimentation rate, 42 mm/hr. Serum glutamic oxaloacetic transaminase was 42 Henry units/100 ml (normal, > 25 units). Results of other liver function tests were within normal limits. Serum protein electrophoresis showed an increase in the α_2-globulin fraction. Chest roentgenogram was within normal limits. Skin, throat, and urine cultures demonstrated normal flora. VDRL was nonreactive.

Skin tests for *Trichophyton*, *Candida*, purified protein derivative, and mumps were negative at 48 hours. A Tzank smear of a chest vesicle demonstrated several multinucleated giant cells. Culture of an adjacent vesicle yielded a virus characterized as herpes simplex and subsequently identified as type 2 by the Communicable

Accepted for publication May 25, 1976.

From the Division of Dermatology, University Hospitals of Cleveland.

Reprint requests to Division of Dermatology, University Hospitals of Cleveland, 2065 Adelbert Rd, Cleveland, OH 44106 (Dr Hazen).

Disease Center in Atlanta. A biopsy specimen of an arm papule demonstrated suprabasilar separation with corps ronds and grains typical of Darier disease.

The axillae and groin remained moist and fissured after discharge. Skin biopsy specimens from the forearm, groin, and chest in July 1975 again demonstrated changes consistent with Darier disease.

The patient has continued to have approximately monthly episodes of grouped vesicles on an erythematous base occurring in clusters on the trunk. Another skin culture in May 1975 has again demonstrated herpes simplex virus type 2.

COMMENT

Eczema herpeticum, by definition, appears in patients with preexisting cutaneous disease. It generally appears as tiny umbilicated vesicles, often in an area of previous dermatitis, that gradually enlarge, coalesce, and progress to pustular and crusted stages. Erosions and fissuring accompanied by edema and purulent exudate are common. The patient's temperature is usually elevated and may remain so for several weeks. The patient may appear toxic, and involvement of internal organs including the liver, brain, gastrointestinal tract, lungs, and adrenals may occur. The mortality has been reported to be as high as 10% to 50%.[3]

Several groups of patients are more susceptible to severe herpetic infections. These include those patients with preexisting cutaneous disease; newborn infants, particularly if premature[4]; patients with severe malnutrition[5]; certain patients with associated infections such as measles[6]; those with underlying defects in cell-mediated immunity such as patients receiving immunosuppressive agents[7-9] and patients with congenital thymic defects such as thymic dysplasia or the Wiskott-Aldrich syndrome[10]; and those patients with underlying lymphomas.[7] In considering herpetic infections in patients with preexisting cutaneous disease, those patients with atopic dermatitis or neurodermatitis are most often affected, although eczema herpeticum has been reported as a complication of a variety of other cutaneous diseases including Darier disease, congenital ichthyosiform erythroderma, seborrheic eczema, and pemphigus.[3]

In all previous reports of eczema herpeticum in patients with Darier disease or other dermatoses, either herpes simplex type 1 was isolated or typing was not carried out. In 1961, Hitselberger and Burns[11] reported a patient with Darier disease who developed a generalized vesicular eruption after contact with a neighbor with a "cold sore" ten days previously. Although no virus was isolated, the skin biopsy specimen was consistent with a cutaneous viral infection and a Tzank smear demonstrated numerous multinucleated giant cells.

Fisher and Kibrick,[12] Doeglas and Moolhuysen,[13] von Weiss et al,[14] and Bleiberg and Klosk[15] have reported cases of Kaposi varicelliform eruption in which herpes simplex type 1 was suspected to be the causative agent. Von Weiss was able to culture herpes simplex, but typing was not done. Izumi and Goldschmidt[16] and Higgins and Crow[17] were also able to culture the herpes simplex virus from their patients; they were further able to identify it as type 1. Carney et al[18] reported a patient with Darier disease who recovered from eczema vaccinatum only to experience numerous vesicles over the anterior portion of the trunk nine months later. The eruption had been preceded ten days earlier by a blister in the genital region. The patient was otherwise asymptomatic and the vital signs were normal. Herpes simplex virus was cultured from one of the trunk vesicles. Typing was not performed.

Our patient is similar to the patient reported by Carney et al in that a vesicular eruption in the genital area preceded the onset of the more generalized process. Our patient, however, was febrile, appeared toxic, and had more extensive involvement.

Recent epidemiologic studies indicate a high incidence of genital herpes in the population and a significant risk of recurrence. Several reports indicate that herpes genitalis has become the predominate cause of vesiculoulcerative disease of the genitalia.[19,20] Herpes simplex virus type 2 has been isolated from the genitourinary tract of 15% of 190 asymptomatic males.[21] Moreover, 9% of private patients and 22% of public clinic patients have serologic evidence of prior herpesvirus type 2 infection.[20] This represents at least a several-fold increase in occurrence in the last 20 years.[19]

The increasing incidence of infection with herpesvirus type 2 and the tendency of this eruption to recur suggests that physicians should be alert for the complication of eczema herpeticum due to herpes simplex virus type 2 in any patient with preexisting cutaneous disease.

References

1. Rawls WE, Gardner HL: Herpes genitalis: Venereal aspects. *Clin Obstet Gynecol* 15:912-918, 1972.
2. Nahmias AJ, Roizman B: Infection with herpes-simplex viruses 1 and 2. *N Engl J Med* 289:667-674, 719-725, 781-789, 1973.
3. Wheeler CE, Abele DC: Eczema herpeticum, primary and recurrent. *Arch Dermatol* 93:162-171, 1966.
4. Nahmias AJ, Alford CA, Korones SB: Infection of the newborn with herpesvirus hominis. *Adv Pediatr* 17:185-226, 1970.
5. McKenzie D, Hansen JDL, Becker W: Herpes simplex virus infection: Dissemination in association with malnutrition. *Arch Dis Child* 34:250-256, 1959.
6. Kipps A, Becker W, Wainwright J, et al: Fatal disseminated herpes infection in children: Epidemiology based on 93 non-neonatal cases. *S Afr Med J* 41:647-651, 1967.
7. Casazza AR, Duvall CP, Carbone PP: Infection in lymphoma: Histology, treatment and duration in relation to incidence and survival. *JAMA* 197:710-716, 1966.
8. Montgomerie JZ, Becroft DMO, Croxson MC, et al: Herpes-simplex-virus infection after renal transplantation. *Lancet* 2:867-871, 1969.
9. Muller SA, Herrmann EC Jr, Winkelmann RK: Herpes simplex infection in hematologic malignancies. *Am J Med* 52:102-113, 1972.
10. St Geme JW Jr, Prince JT, Burke BA, et al: Impaired cellular resistance to herpes-simplex virus in Wiskott-Aldrich syndrome. *N Engl J Med* 273:229-234, 1965.
11. Hitselberger JF, Burns RE: Darier's disease: Report of a case complicated by Kaposi's varicelliform eruption. *Arch Dermatol* 83:425-429, 1961.
12. Fisher BK, Kibrick S: Primary herpes in adult with Darier's disease. *Arch Dermatol* 87:729-733, 1963.
13. Doeglas HMG, Moolhuysen TMGF: Kaposi's varicelliform eruption: Two cases caused by herpesvirus hominis infection complicating Darier's disease. *Arch Dermatol* 100:592-595, 1969.
14. Von Weiss JF, Kibrick S, Lever WF: Eczema herpeticum as complication of Darier's disease. *Ann Intern Med* 62:1293-1296, 1951.
15. Bleiberg J, Klosk E: Kaposi's varicelliform eruption superimposed on keratosis follicularis. *J Newark Beth Isr Hosp* 2:48, 1951.
16. Izumi A, Goldschmidt H: Herpes simplex infection complicating Darier's disease. *Arch Dermatol* 102:650-653, 1970.
17. Higgins PG, Crow KD: Recurrent Kaposi's varicelliform eruption in Darier's disease. *Br J Dermatol* 88:391-394, 1973.
18. Carney JF, Caroline NL, Nankervis GA, et al: Eczema vaccinatum and eczema herpeticum in Darier disease. *Arch Dermatol* 107:613-614, 1973.
19. Gardner HL, Kaufman RH: Herpes genitalis: Clinical features. *Clin Obstet Gynecol* 15:896-911, 1972.
20. Amstey MS: Genital herpesvirus infection. *Clin Obstet Gynecol* 18:89-100, 1975.
21. Centifanto YM, Drylie DM, Deardourff SL, et al: Herpesvirus type 2 in the male genitourinary tract. *Science* 178:318-319, 1972.

Graft-Versus-Host Reaction

Cutaneous Manifestations Following Bone Marrow Transplantation

Antoinette F. Hood, MD; Nicholas A. Soter, MD; Joel Rappeport, MD; Irma Gigli, MD

• The distinctive cutaneous changes that occur in both the acute and chronic forms of the graft-vs-host reaction (GVHR) are described in two living patients in whom the GVHR developed after bone marrow transplantation for aplastic anemia. In the skin, the mild form of the acute GVHR is recognized as a subtle macular erythema, and the severe form appears as erythematous papules and violaceous macules with scale. Skin biopsy specimens in both of the acute forms show vacuolar alterations of the epidermal basal-cell layer with a perivenular infiltrate of lymphocytes. The chronic GVHR evolves from generalized scaling to diffuse areas of sclerotic and atrophic skin with a curious reticulated hyperpigmentation, ulcerations, and alopecia. Histopathologic study shows collagenization of the dermis that can be correlated with the clinical sclerodermoid changes. Owing to its visibility, the skin offers a unique opportunity for the early recognition of the GVHR.

(*Arch Dermatol* 113:1087-1091, 1977)

Lymphocytic cells that are administered to an immunodeficient or immunosuppressed individual possess the capacity to react against recipient tissue antigens that are absent in the donor and that are not linked to the histocompatibility (HLA) or mixed leukocyte culture (MLC) loci. The immunologic competence of these cells forms the basis for the development of the graft-vs-host reaction (GVHR).[1,2] Although the GVHR has been described in immunodeficient patients who have received unirradiated blood products,[3,4] it is seen most frequently in patients that have received bone marrow transplants.[5] The GVHR has become one of the major impediments limiting the success of this therapeutic maneuver. The principal organs involved in the GVHR are the intestinal tract, the liver, and the skin; clinically distinguishable acute and chronic forms of the GVHR are recognized. The acute GVHR develops one to seven weeks after bone marrow transplantation and is characterized by fever, eosinophilia, diarrhea, hepatic dysfunction, and distinctive cutaneous changes. Mortality in the acute GVHR ranges from 44% to 90% and results from end organ failure, or, more commonly, associated infection.[6,7] The use of antithymocyte globulin (ATG) and sterile environments has reduced appreciably the mortality in an acute GVHR.[8] The chronic GVHR occurs months after bone marrow transplantation and may or may not be preceded by a clinically recognizable acute GVHR; the skin and the intestinal tract are commonly affected, and the liver is less frequently involved. Although the chronic GVHR is less frequent than the acute GVHR, it may become more frequent as patients receiving bone marrow transplants survive for longer time intervals. Morbidity and mortality of the chronic GVHR are uncertain at the present time.

Of the three organs commonly affected in a GVHR, the skin offers unique opportunities for observation and study of the emergence and progression of both gross and microscopic changes. Although the histopathologic changes of the GVHR have been documented,[7-11] detailed descriptions of the gross morphological findings of the lesions are lacking. In this report, the evolution of the distinctive cutaneous lesions in two living patients in whom GVHR developed following bone marrow transplantation is described and correlated with histopathologic features. In the first patient, an acute GVHR occurred that resolved after the administration of antithymocyte serum (ATS). In the second patient, a chronic GVHR developed that was characterized by evolution into striking generalized sclerodermoid changes with ulcerations and alopecia.

MATERIALS AND METHODS

Grafting Procedure

The donor in each instance was a sibling who was HLA identical and MCL nonreactive when compared with the patient. The patients were maintained in a protected environment with strict reverse isolation. Skin sterilization was obtained with daily applications of topically applied povidone-iodine (Betadine) ointment; gastrointestinal sterilization was obtained by means of a diet low in bacteria and a bowel preparation containing nystatin (Mycostatin), gentamicin sulfate, and vancomycin hydrochloride. Prior to bone marrow transplantation, the following immunosuppressive agents were administered: cyclophosphamide, 50 mg/kg/day for four days; procarbazine hydrochloride, 12.5 mg/kg/day for three days; and three doses of ATS. Thirty-six hours after the last administration of cyclophosphamide, the patients received an intravenous infusion of donor marrow with the day of infusion designated as day 0. In an attempt to prevent GVHR following bone marrow transplantation, methotrexate, 10 mg/sq m, was administered orally on days 1, 3, 6, 11, and weekly thereafter to day 62 in patient 1 and day 102 in patient 2.

Biopsy Specimens

Skin trephine biopsy specimens measuring 4 mm were obtained with use of lidocaine, fixed in 10% formaldehyde solution,

Accepted for publication June 2, 1976.

From the Departments of Dermatology and Medicine, Harvard Medical School, and the Divisions of Dermatology and Hematology, Department of Medicine, Peter Bent Brigham Hospital, Boston. Dr Gigli is now with New York University Medical Center.

Reprint requests to Division of Dermatology, Department of Medicine, Peter Bent Brigham Hospital, Boston, MA 02115 (Dr Soter).

Clinical and Histopathologic Features Observed During Evolution of the Chronic Cutaneous GVHR		
Days After Bone Marrow Transplantation	**Clinical Observations**	**Histopathologic Features**
35-49	Transient pruritic lesions; faint macular erythema of upper portion of back	ND*
88-98	Progressive scaling	Epidermal edema with prominent focal vacuolation and lymphocytic infiltration of the basal-cell layer; necrosis of individual epidermal cells; sparse perivenular infiltrate of lymphocytes in the dermis
113	Generalized scaling skin with prominent hyperkeratotic follicles; patchy hyperpigmentation over face and trunk; erythematous macules on back	As above plus collagenization of the papillary dermis
155	Discrete erythematous macules with scale on back; patchy hyperpigmentation	Vacuolar degeneration and necrosis of basal-cell layer; homogenization of papillary dermis
175-193	Reticulated hyperpigmentation surrounding smooth shiny atrophic hypopigmented skin over midback; edema and confluent erythema of palms and soles; mild alopecia of scalp	ND
249-291	Crusted erosions over trunk and extremities that resolved after the administration of antibiotics	ND
305-400	Fissures and large erosions on back; periungual erythema and telangiectases; generalized hair loss; bullae	Focal subepidermal bullae; atrophic epidermis with focal dyskeratosis; homogenization of dermis; sweat glands surrounded by collagen; and histiocytes containing melanin

*ND indicates not done.

embedded in paraffin, stained with hematoxylin-eosin, and examined with a light microscope.

RESULTS
Report of Patients

CASE 1.—A 28-year-old woman with idiopathic aplastic anemia of one month's duration had the following laboratory values on admission: hemoglobin, 8.9 gm/100 ml; hematocrit, 26.5%; WBC, 2,600/cu mm, with 28% neutrophils, 65% lymphocytes, 6% monocytes, and 1% eosinophils; platelet count, 4,000/cu mm; and reticulocytes, 0.4% (uncorrected). A bone marrow biopsy specimen showed an acellular marrow. After immunosuppression, 1.9×10^8 marrow cells per kilogram body weight obtained from the patient's histocompatible brother were administered intravenously on day 0. A bone marrow biopsy specimen obtained on day 16 showed an increase in all hematopoietic elements, and allogeneic engraftment was further documented by the demonstration of donor RBC markers and sex chromosome. The patient developed clinical and laboratory evidence of the GVHR in the following three organ systems: the gastrointestinal tract, liver, and skin. Diarrhea was noted on day 7; liver function test (LFT) results were abnormal between days 22 and 29 with increased bilirubin, alkaline phosphatase, and SGOT; and there were skin lesions on day 30.

The initial eruption was recognized as a faint, mottled macular erythema that blanched with the application of external pressure and that was noted initially on the upper portions of the trunk with gradual spread to include the entire trunk, face, and upper extremities. Between days 42 and 48, numerous nonblanching erythematous papules were observed on the upper and lower extremities accompanied by erythematous macules on the trunk; these lesions were replaced by discrete violaceous papules with evolution into macules with scale (Fig 1). The progression of the cutaneous eruption from the sixth to the ninth week following diarrhea was accompanied by continued nausea and vomiting, weight loss, and hepatomegaly with persistent elevation of the LFTs. Regimens of ATS (0.1 ml/kg of body weight) were administered on days 65, 68, and 70 following transplantation. After the first dose of ATS, the patient experienced fever, arthralgias, and hypocomplementemia with a low CH50 level, presumably the result of serum sickness. The ATS was discontinued after three doses; the diarrhea subsided, and the skin lesions faded, leaving residual postinflammation hyperpigmentation. The LFTs failed to improve after the administration of ATS; however, with continued elevation of her total bilirubin and alkaline phosphatase; an atypical cytomegalovirus was cultured from the urine, suggesting that the persistent liver disease was the result of viral hepatitis rather than the GVHR. The patient was discharged from the hospital on day 91 and has been followed up as an outpatient. Despite persistently abnormal LFTs, she remains clinically well with a good appetite, stable weight, and no recurrence of either diarrhea or skin lesions.

CASE 2.—A 25-year-old woman was hospitalized with a two-month history of aplastic anemia following exposure to benzene. Laboratory studies revealed the following values: hemoglobin, 10.4 gm/100 ml; hematocrit, 30.3%; reticulocytes, 0%; platelet count, 2,500/cu mm; and WBC, 2,600/cu mm with 2% neutrophils, 1% band forms, 88% lymphocytes, 5% atypical lymphocytes, 2% monocytes, and 2% metamyelocytes. A bone marrow biopsy specimen showed severe hypoplasia with depletion of all hematopoietic elements. After immunosuppression, 2.6×10^8 marrow cells per kilogram body weight, obtained from the patient's histocompatible sister were administered intravenously on day 0. Twelve days after transplantation, there was evidence of successful engraftment in the peripheral blood with the appearance of myeloid cells and nucleated erythrocytes. A bone marrow aspirate and biopsy specimen obtained on day 31 showed marked erythroid activity, normal myeloid activity, and adequate megakaryocytes. A RBC marker further substantiated successful engraftment. On day 35, the patient experienced evanescent pruritic skin lesions that were ascribed to the administration of ampicillin sodium for cystitis. The eruption persisted after the antibiotic was discontinued, and the patient developed fever and abnormal LFTs on day 45. These signs and symptoms subsided after the dose of methotrexate was increased from 10 to 15 mg/sq m weekly. When discharged on day 81, the patient was clinically well with good appetite, stable weight, and no diarrhea or skin lesions.

Over the next few months, however, the patient developed an inexorably progressive GVHR of the skin that appeared as generalized scaling, follicular hyperkeratosis, and patchy hyperpigmentation (Table). On day 133, several erythematous macules with scale were observed on the midback (Fig 2), and subsequently similar lesions appeared on the face and extremities. The individual lesions resolved, leaving a localized area of sclerotic, atrophic skin with a curious reticulated erythema and hyperpigmentation (Fig 3, right). The palms and soles appeared diffusely violaceous with scale; periungual erythema and telangiectases were observed. As the eruption progressed, the patient experienced increas-

Fig 1.—Severe acute GVHR (patient 1, day 52). Violaceous macules over an upper extremity.

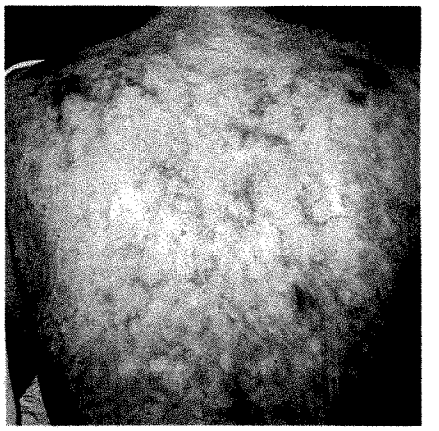

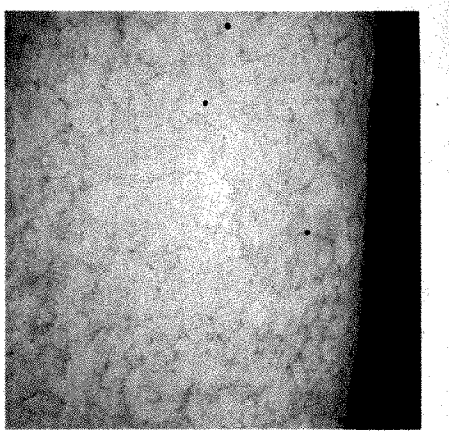

Fig 3.—Chronic GVHR (patient 2, day 326). Left, Extensive atrophy of skin with erythema and ulceration. Right, Detail of lower extremity showing curious reticulated hyperpigmentation.

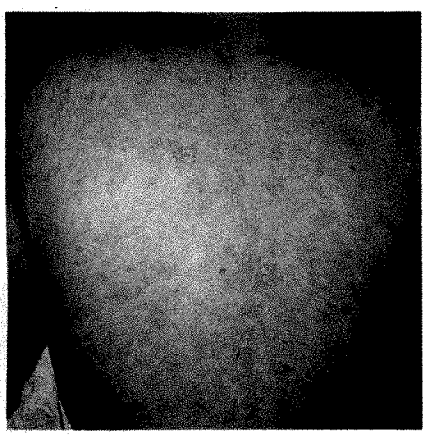

Fig 2.—Chronic GVHR (patient 2, day 155). Erythematous macules with scale are present lateral to midline.

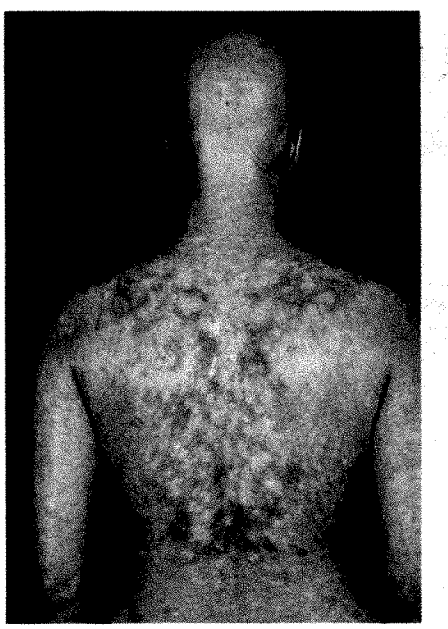

Fig 4.—Chronic GVHR (patient 2, day 398). Alopecia of scalp with extensive cutaneous ulceration.

ing "tightness" of her skin and decreased range of motion at the elbows, knees, and mouth. There was patchy erythema, reticulated hyperpigmentation, and superficial parchment-like wrinkling. Six months after transplantation, multiple superficial erosions with honey-colored crusts appeared over the trunk; these lesions, interpreted as impetigo, resolved after the administration of erythromycin for ten days. Several weeks later, focal areas of erythema were noted in previously altered skin of the back that evolved into large ulcerations (Fig 3, left). Antinuclear factor and lupus erythematosus (LE) cell preparations were negative on multiple occasions, and the patient denied a history of Raynaud's phenomenon, dysphagia, or constipation.

Neither the administration of prednisone and methotrexate nor the topical application of 0.1% betamethasone valerate cream was effective in altering the progression of the skin lesions. When the eruption became symptomatic enough to interfere with her normal activities, the patient was hospitalized, and ATS (0.1 ml/kg of body weight) was administered beginning on day 313. After the third dose of ATS, she experienced fever and arthralgias interpreted as serum sickness; the treatment was discontinued. Although there was a transient decrease in the erythema following the administration of ATS, the inexorable progression of the process remained unaltered. Thirteen months after the marrow transplantation, the patient's skin disease remained as the major clinical feature and therapeutic problem (Fig 4).

Histologic Findings

The faint macular erythematous lesions that appeared early in patient 1 were characterized by focal vacuolation of the epidermal basal-cell layer, focal extension of lymphocytes into the epidermis, and a sparse perivenular infiltrate of lymphocytes and histocytes in the upper portions of the dermis. The nonblanching papules in patient 1, violaceous macules with scale in both patients, and the erythematous macules appearing in previously affected skin in patient 2 showed intercellular edema of the epidermis, marked vacuolation of the basal-cell layer, dyskeratosis and necrosis of individual epidermal cells, so-called mummified cells,[1] a perivenular infiltrate of lymphocytes with focal extension into the epidermis, edema with fibrosis of the papillary dermis, and occasional focal extravasation of RBCs about venules (Fig 5). As the chronic cutaneous disease progressed in patient 2 to include atrophy, reticulated hyperpigmentation, and ulceration, a skin biopsy specimen exhibited thickening of the dermis with hypertrophic and closely packed collagen bundles that appeared hyalinized and brightly eosinophilic with fibrosis and with loss of hair follicles and persistence of sweat glands surrounded by collagen. There was hyperkeratosis, thinning of the epidermis, and a paucity of lymphocytes in the epidermis and about venules (Fig 6).

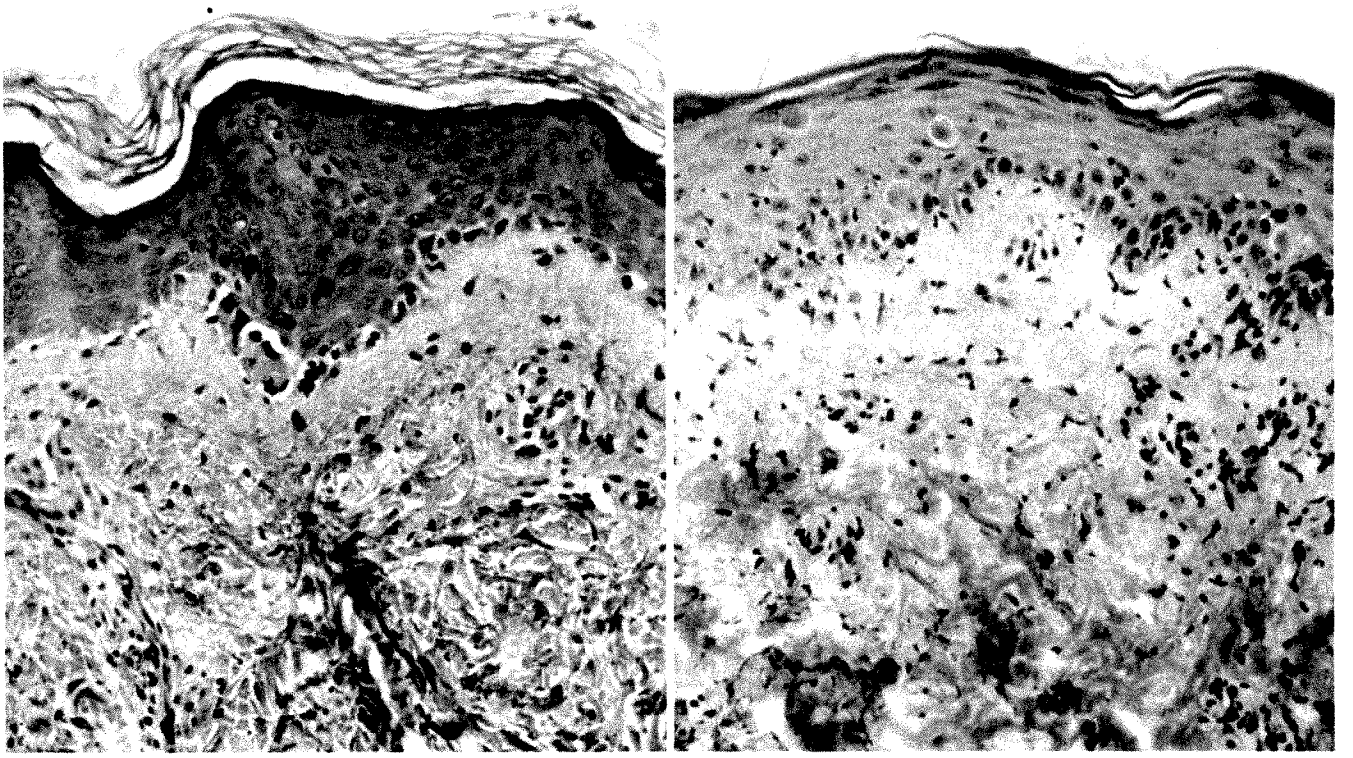

Fig 5.—Acute GVHR (patient 1, day 48). Left, Focal dyskeratosis and vacuolation of basal-cell layer of epidermis. Right, Epidermal intercellular edema; lymphocytic infiltration of both epidermis and dermis (left and right, hematoxylin-eosin, original magnification ×125).

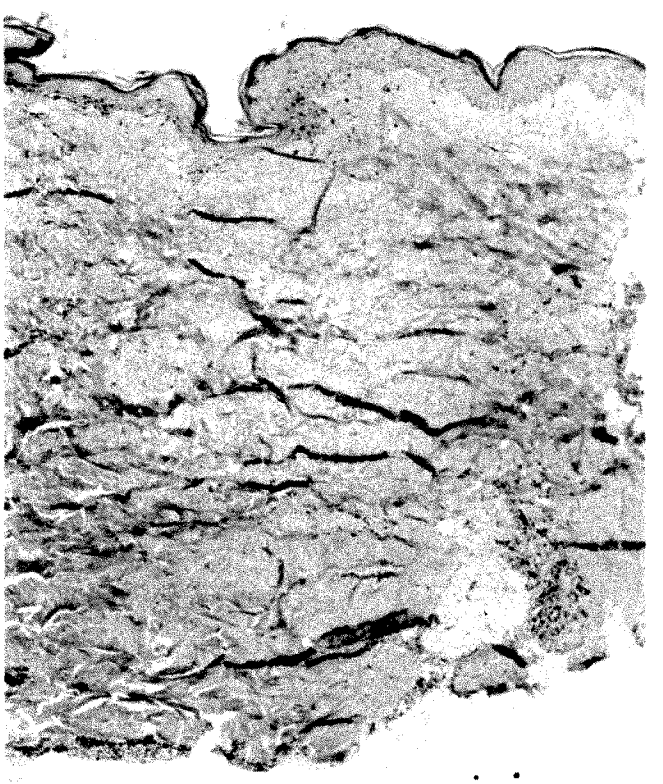

Fig 6.—Chronic GVHR (patient 2, day 302). Atrophic epidermis, collagenization of dermis with persistence of eccrine sweat gland, and paucity of infiltrate of lymphocytes (hematoxylin-eosin, original magnification, ×12.5).

COMMENT

Distinctive skin changes may be observed in the GVHR both in the acute and chronic forms, and the cutaneous changes associated with acute GVHR can be subdivided as mild and severe (florid) with respect to clinical description and course. The mild acute GVHR is characterized by an easily overlooked macular erythema that appears on the upper portion of the trunk, head, and neck and histologically shows focal vacuolar degeneration of the epidermal basal-cell layer with a sparse perivenular infiltrate of lymphocytes. This reaction corresponds to the grade I GVHR described in the Seattle classification (≦ 25% body surface involved, little or no visceral involvement).[6] Inasmuch as this form of the GVHR is observed in transplantation patients without sustained engraftment as well as in immunodeficient patients that have received nonirradiated blood products, the cells participating in the reaction are presumed to be the mature circulating lymphocytes administered in the marrow infusion. Mortality in a mild acute GVHR is similar to that in patients without a GVHR.[6] This form of the GVHR should be considered in the differential diagnosis of any cutaneous eruption developing in immunosuppressed patients receiving transfusions of blood rich in lymphocytes. Since the skin lesions are subtle and not all eruptions occurring in these patients are manifestations of the GVHR, drug-induced eruptions and viral exanthems should also be considered. Histopathologic examination of a skin biopsy specimen may be helpful in resolving the dilemma.

The severe or florid form of an acute GVHR was noted in patient 1 as nonblanching, erythematous papules and violaceous macules with scale that appeared on the extremities and trunk. On histologic examination, these lesions showed intercellular epidermal edema, vacuolar degeneration of the basal-cell layer, dyskeratosis and necrosis of epidermal cells, and a perivenular infiltrate of lymphocytes with extension into the epidermis. These observations correspond to the Seattle classification of grade II to III GVHR (≧ 25% body surface involved, mild to moderate visceral involvement).[6] Although the pathogenesis of the severe acute GVHR is unknown, since it occurs only in patients with successful bone marrow engraftment and can be terminated by ATS, it is probable that the process results from established and proliferating lymphocytes in the recipient. The mortality associated with severe GVHR (grade II-IV) is high (85%), owing to the patients' increased susceptibility to infections.[6] Although certain of the violaceous papules may clinically and histopathologically resemble lichen planus,[12,13] the lesions in the severe acute GVHR can be distinguished by their characteristic histopathologic features. In lichen planus, there is characteristically a dense infiltrate of mononuclear cells in the upper portion of the dermis; these cells may obscure the dermoepidermal junction. In the GVHR, the infiltrate in the dermis is sparse and disposed about venules. In addition to lichen planus, the histologic differential diagnosis includes LE, fixed-drug eruptions, and erythema dyschromicum perstans.[14]

The evolution of a chronic cutaneous GVHR in patient 2 was characterized by a progression from generalized scaling to diffuse sclerotic, atrophic skin with widespread ulcerations. The most striking histopathologic change was the progressive collagenization of the dermis that correlated clinically with the sclerodermoid changes; in addition there was a paucity of lymphocytes, and the epidermal changes were similar to those observed in the acute severe GVHR. The possibility of coexistent collagen-vascular diseases such as scleroderma and LE were considered but eliminated, owing to the absence of the criteria requisite for diagnosis. The similarity between the skin lesions of the chronic GVHR and those observed after external administration of electron-beam therapy and poikiloderma atrophicans vasculare, a premalignant harbinger of mycosis fungoides, is considerable.[7]

The incidence of a chronic GVHR following bone marrow transplantation is as yet unknown inasmuch as a substantial population of patients that are long-term survivors has not yet been accumulated. In reported patients, three of 20 individuals[5] that survived more than 100 days after engraftment developed a chronic GVHR. The pathogenesis of the chronic GVHR is unclear; owing to the delayed onset of the disease, it seems likely that the immunocompetent cells participating in the reaction are derived from the engrafted marrow and have differentiated within the recipient. The paucity of lymphocytes observed in the skin compared with the extensive changes of the epidermis and the dermis suggest that additional factors may be implicated.

This investigation was supported in part by Public Health Service grant 5 M01-RR-31-14 from the National Institutes of Health. Dr Soter is the recipient of National Research Service Award 1-F 32-AI 05240.

Martin C. Mihm, Jr, MD, and Joseph M. Corson, MD, interpreted the skin biopsy specimens. Robertson Parkman, MD, assisted in the preparation of this manuscript. Reproductions in color courtesy of Syntex Laboratories Inc, Palo Alto, Calif.

Nonproprietary Names and Trademarks of Drugs

Gentamicin sulfate—*Garamycin.*
Vancomycin—*Vancocin.*

References

1. Billingham RE: The biology of graft-versus-host reactions, in *The Harvey Lectures Series 62, 1966-1967.* New York, Academic Press, 1968, pp 21-78.

2. Elkins WL: Cellular immunology and the pathogenesis of graft versus host reactions. *Prog Allergy* 15:78-187, 1971.

3. Levin RH, Whang J, Tjio JH, et al: Persistent mitosis of transfused homologous leukocytes in children receiving antileukemia therapy. *Science* 142:1305-1311, 1963.

4. Parkman R, Mosier D, Umansky I, et al: Graft-versus-host disease after intrauterine and exchange transfusions for hemolytic disease of the newborn. *N Engl J Med* 290:359-363, 1974.

5. Thomas ED, Storb R, Clift RA, et al: Bone-marrow transplantation. *N Engl J Med* 292:832-843, 895-902, 1975.

6. Glucksberg H, Storb R, Fefer A, et al: Clinical manifestations of graft-versus-host disease in human recipients of marrow from HL-A-matched sibling donors. *Transplantation* 18:295-304, 1974.

7. Slavin RE, Santos GW: The graft-versus-host reaction in man after bone marrow transplantation: pathology, pathogenesis, clinical features, and implication. *Clin Immunol Immunopathol* 1:472-498, 1973.

8. Storb R, Gluckman E, Thomas ED, et al: Treatment of established human graft-versus-host disease by antithymocyte globulin. *Blood* 44:57-75, 1974.

9. Lerner KG, Kao GF, Storb R, et al: Histopathology of graft-vs-host reaction (GVHR) in human recipients of marrow from HL-A-matched sibling donors. *Transplant Proc* 6:367-371, 1974.

10. Slavin RE, Woodruff JM: The pathology of bone marrow transplantation, in Sommers SC (ed): *Pathology Annual.* New York, Appleton-Century-Crofts, 1974, vol 9, pp 291-344.

11. Krüger GRF, Berard CW, DeLellis RA, et al: Graft-versus-host disease: Morphologic variation and differential diagnosis in 8 cases of HL-A-matched bone marrow transplantation. *Am J Pathol* 63:179-202, 1971.

12. Touraine R, Revuz J, Dreyfus B, et al: Graft versus host reaction and lichen planus. *Br J Dermatol* 92:589, 1975.

13. Saurat JH, Didier-Jean L, Gluckman E, et al: Graft versus host reaction and lichen planus-like eruption in man. *Br J Dermatol* 92:591-592, 1975.

14. Soter NA, Wand C, Freeman RG: Ultrastructural pathology of erythema dyschromicum perstans. *J Invest Dermatol* 52:155-162, 1969.

Eosinophilic Fasciitis

Ronald E. Krauser, MD, Ralph J. Tuthill, MD

• A detailed evaluation of the clinical and histologic manifestations of eosinophilic fasciitis is described in a 22-year-old woman. Scleroderma-like skin involvement is associated with eosinophilia and hypergammaglobulinemia. Visceral and serologic manifestations of a generalized scleroderma are lacking. Results of a biopsy showed severe thickening of the deep fascia accompanied by an infiltration of lymphocytes and plasma cells. This syndrome must be differentiated from generalized scleroderma because eosinophilic fasciitis has a benign course and may benefit from systemic corticosteroid therapy.

(*Arch Dermatol* 113:1092-1093, 1977)

In 1974 Shulman reported an unusual scleroderma-like syndrome associated with hypergammaglobulinemia and eosinophilia.[1] Since then three additional articles have described similar patients.[2-4] Cutaneous involvement seems to occur mainly on the arms and legs, with a relative sparing of the face and hands. Visceral involvement is uniformly lacking and serologic evaluations are usually negative. We describe a patient with similar clinical features and provide a detailed analysis of the histopathologic changes that accompany this disorder.

REPORT OF A CASE

A 22-year-old woman was in good health until December 1974 when she developed intermittent swelling of her left hand, particularly on the volar aspect. Within the next month she noticed an inability to completely straighten the left elbow and the fingers of the left hand. No other extremities were affected. She specifically denied morning stiffness, fever, rashes, dysphagia, cough, shortness of breath, or symptoms suggestive of Raynaud phenomenon.

Results of the physical examination were unremarkable except for the left arm and hand. The skin from the shoulder to the wrist appeared tight and slightly thickened. Puckering or dimpling of the skin was noted on the medial aspect of the proximal forearm. There was no telangiectasia or palpable calcinosis. The left elbow lacked full extension by 10°. The left wrist was warm with mild swelling and tenderness. There was swelling of the tendon sheaths on the dorsum of the left hand. The metacarpophalangeal and proximal interphalangeal joints lacked full extension by 15°.

On laboratory evaluation, complete blood counts repeatedly showed 15% to 20% eosinophils. The total eosinophil count was 1,050/cu mm. A Wintrobe sedimentation rate was 10 mm/hr. Urinalysis, muscle enzyme test and biochemical screen determinations were normal. Fluorescent antinuclear antibody, latex fixation, and anti-DNA antibodies were negative on three occasions. Serum protein electrophoresis disclosed a mild hypergammaglobulinemia, which on quantitation proved to be of the IgG class. Roentgenograms of the hands, wrists, and chest, as well as esophageal manometric and pulmonary function test results were within normal limits.

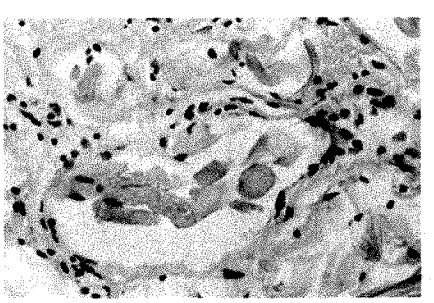

Fig 1.—Altered collagenous bundles of reticular dermis are more intensely eosinophilic, have crumpled appearance, and seem to lie in small lacuna with basophilic substance at periphery (hematoxylin-eosin stain, original magnification ×400).

An open biopsy of the skin and deep fascia of the proximal forearm was performed. On histologic examination the epidermis and papillary dermis were unremarkable. The mid-dermis showed spotty perivascular lymphocytic infiltrates. The deep reticular dermis disclosed discrete foci of fibrillation with both swelling and shrinking of collagenous bundles accompanied by increased basophilic ground substance and a mild lymphocytic infiltrate. Some of the altered collagenous bundles appeared to lie in lacunae or small cystic spaces (Fig 1). It was in the deep fascia, however, that the changes were most striking. This tissue showed centrally located foci of pale basophilic change that were so extensive that cystic changes were noted in one area (Fig 2). There were perivascular lymphocytic infiltrates and mild degenerative changes in the fat cells adjacent to the fascia. Evidence of new collagen formation, as shown by entrapment of lipocytes, was also present (Fig 3). In the areas of less involved deep fascia there were scattered, small blood vessels with plump endothelial cells and mild perivascular infiltrates. In other areas in which there was less myxomatous change, there were numerous plump spindle-shaped cells. No eosinophils and only rare plasma cells and mast cells (Giemsa stain) were seen. Alcian blue stain at pH 4.5 was strongly positive in the myxomatous areas but was negative at pH 0.5 in the same sites.

COMMENT

The presence of fascial inflammation and peripheral eosinophilia has led Rodnan and associates to suggest the term "eosinophilic fasciitis" be used to describe this syndrome.[2] As was the case in prior reports, our patient lacked telangiectasia, calcinosis, Raynaud phenomenon, and visceral manifestations associated with generalized scleroderma. Esophageal manometric findings, which are abnormal in almost 90% of patients with

Accepted for publication July 13, 1976.

From the Rheumatology Section (Dr Krauser) and Department of Pathology (Dr Tuthill), Naval Regional Medical Center, Portsmouth, Va.

Reprint requests to 30 S Valley Rd, Paoli, PA 19301 (Dr Krauser).

Fig 2.—Dense regular connective tissure shows microcystic change associated with perivascular lymphocytic inflammation in adjacent adipose tissue (hematoxylin-eosin stain, original magnification ×40).

Fig 3.—Evidence of new collagen formation with entrapment of lipocytes (hematoxylin-eosin stain, original magnification ×40).

generalized scleroderma,[3] have been uniformly normal in individuals with eosinophilic fasciitis. However, joint involvement with synovitis and early contractures of shoulders, elbows, and hands is a common feature of this syndrome. Not only are the clinical patterns of skin involvement unusual for both generalized and localized forms of scleroderma, but a relationship to strenuous exertion or trauma has been suggested in some patients. Our patient was a left-handed barber, and repeated microtrauma to her left arm could have possible etiologic implications. The natural course of the disease may lead to severe skin hardness and tightness in 6 to 12 months. In some instances dramatic improvement, including reversal of the cutaneous lesion, has been observed following systemic corticosteroid therapy.

The biopsy findings of eosinophilic fasciitis have been relatively consistent in all published cases. The predominant changes are deep with striking thickening of the deep fascia. Inflammation, often perivascular, is present in the deeper layers of the subcutaneous tissue and extends into the tendons and superficial muscle bundles. The inflammatory response is composed mostly of lymphocytes and plasma cells. Eosinophils are usually not present in significant numbers. Immunohistologic studies by Rodnan et al[2] in two cases have disclosed deposits of IgG and C_3 in the deep fascia and septa of underlying muscle.

The biopsy changes are difficult to correlate into a specific histologic diagnosis that relates to any well-recognized clinicopathologic entity. It appears that there is a primary change in collagen fibers with a multitude of secondary changes. The myxomatous change in the deep fascia is reminiscent of two other lesions: early ganglion formation in periarticular connective tissue[6-8] and cutaneous myxomas.[9] Both of these lesions have high correlation with minor trauma[9,10] such as might be suspected in our patient. Also, the earliest changes in cutaneous myxomas[9] show some similarities to the early changes in the deep reticular dermis of our patient. Excluded on clinical and histologic grounds are entities such as eosinophilic collagenosis, which shows foci of necrotic collagen surrounded by histiocytes, eosinophils, and extruded granules from the eosinophils.[11] Distinguishing eosinophilic fasciitis from linear scleroderma and morphea is difficult because these other disorders may also involve underlying structures such as deep fascia and skeletal muscle.[12-14] The early dermal changes in our patient and those described in early morphea[11,15] are similar, as was the case with early cutaneous myxomas. Eosinophilic fasciitis might be separated from localized scleroderma by the rather extreme degeneration of small collagen bundles associated with a microcystic myxomatous change. However, it is probably inappropriate to do so upon the examination of only a single clinical case.

Thus, eosinophilic fasciitis seems to possess some clinical, serologic, and histologic changes that may differentiate it from generalized and localized sclerodermas. It remains to be determined if this new disease is just part of the spectrum of scleroderma or in truth merits consideration as a distinct clinical entity.

References

1. Shulman LE: Diffuse fasciitis with hypergammaglobulinemia and eosinophilia: A new syndrome, abstracted. *J Rheum* 1 (suppl 1):46, 1974.
2. Rodnan GP, DiBartolomeo A, Medsger TA, et al: Eosinophilic fasciitis: Report of six cases of a newly recognized scleroderma-like syndrome, abstracted. *Clin Res* 23:443, 1975.
3. Caperton EM, Hathaway DE: Scleroderma with eosinophilia and hypergammaglobulinemia: The Shulman syndrome, abstracted. *Arth Rheum* 18:391, 1975.
4. Schumacher HR: A scleroderma-like syndrome with fasciitis, myositis, and eosinophilia. *Ann Intern Med* 84:49-50, 1976.
5. Garrett JM, Winkelmann RK, Schlegel JF, et al: Esophageal deterioration in scleroderma. *Mayo Clin Proc* 46:92-96, 1971.
6. Lichtenstein L: *Diseases of Bone and Joints.* St Louis, CV Mosby Co, 1975, pp 222-223.
7. Lichtenstein L: Tumors of synovial joints, bursae and tendon sheaths. *Cancer* 8:816-830, 1955.
8. McEvedy BV: Simple ganglia. *Br J Surg* 49:585-594, 1962.
9. Johnson WC, Graham JH, Helwig EB: Cutaneous myxoid cyst: Clinicopathologic and histochemical study. *JAMA* 191:15-20, 1965.
10. Ackerman LV, Rosai J: In *Surgical Pathology.* St Louis, CV Mosby Co, 1974, p 1083.
11. Reed RJ, Clark WH, Mihm MC: The cutaneous collagenoses. *Hum Pathol* 4:165-199, 1973.
12. Moschella SL, Pillsbury DM, Harley HJ, et al: *Dermatology.* Philadelphia, WB Saunders Co, 1975, p 934.
13. Eisen EZ: Scleroderma, in Fitzpatrick F (ed): *Dermatology in General Medicine.* New York, McGraw-Hill Book Co Inc, 1971, pp 1525-1532.
14. Christianson HB, Dorsey CS, O'Leary PA, et al: Localized scleroderma. *Arch Dermatol* 74:629-639, 1956.
15. O'Leary PA, Montgomery H, Ragsdale WE: Dermatohistopathology of various types of scleroderma. *Arch Dermatol* 75:78-87, 1957.

Xanthoma Disseminatum

Clinical, Metabolic, Pathologic, and Radiologic Aspects

Maurice A. Mishkel, MD; W. Peter Cockshott, MD; Darius J. Nazir, PhD;
Donald Rosenthal, MD; William P. Spaulding, MD; Alun Wynn-Williams, MD

• A 55-year-old man with the classical mucocutaneous lesions of xanthoma disseminatum has been followed up for a period of 13 years. The special features of this case, which make it unique, are as follows: (1) the availability of histologic data on multiple lesions for more than a ten-year period; (2) the progressive nature of the multiple osseous lesions; (3) the metabolic studies that show no evidence for accumulation of abnormal sterols in a xanthoma, the blood, or intestinal aspirate; (4) the development of hypothyroidism and symptoms or signs, or both, of an intracerebral and an intraspinal lesion; (5) the partial regression of the cutaneous symptoms and lesions while receiving clofibrate, in spite of progression of the mucous membrane and osseous lesions; and (6) the failure to develop diabetes insipidus to date.

(*Arch Dermatol* 113:1094-1100, 1977)

Xanthoma disseminatum (XD) is a rare dermatologic disorder of unknown cause that may be accompanied by systemic manifestations. Although the clinical picture may be very distinctive, there is still controversy about how many reported cases are examples of this disorder and whether or not there is an overlap with Hand-Schüller-Christian disease. A textbook of dermatology[1] states that there are fewer than 30 reported cases of XD.

Our patient has had a clinical follow-up for a period of 13 years with biopsies performed on skin and bone lesions. Information is given concerning the sterol composition of a xanthoma. We have shown that the disease is not characterized by an accumulation of cholestanol, as seen in cerebrotendinous xanthomatosis,[2] another normolipidemic disorder. This case is classic in most of its features in that the patient is a man who has no family history of the disorder, which commenced in his middle life. The cutaneous lesions are typical in their widespread nature, with particular emphasis on flexural involvement. The color of the lesions varies from yellow to mahogany-brown to purple. Mucous membrane involvement of the mouth and nose is a prominent feature but the patient has not developed diabetes insipidus to date. An unusual feature has been the slowly progressive involvement of bone, reminiscent of a reticuloendotheliosis, but the histology is similar to a case reported by Halprin and Lorincz.[3] Although the patient has been normolipidemic throughout the course of the disease, clofibrate (Atromid-S) therapy led to a definite decrease in size of the cutaneous lesions throughout a period of three years. The progressive nature of the mucous membrane and osseous lesions by contrast has not been affected. Subsequently, the patient became hypothyroid and developed a spastic paraparesis, but no cause for the latter has yet been found.

Accepted for publication Oct 28, 1975.

From the Departments of Medicine (Drs Mishkel, Nazir, and Spaulding), Radiology (Dr Cockshott), Dermatology (Dr Rosenthal), and Pathology (Dr Wynn-Williams), McMaster University, Hamilton, Ontario.

Read in part before the Atlantic Dermatological Conference, Toronto, 1967; and the Royal College of Physicians & Surgeons of Canada meeting, Edmonton, Alberta, Jan 26, 1973.

Reprint requests to HGH-McMaster Clinic, Hamilton General Hospital, Barton Street E, Hamilton L8L 2X2 Ontario (Dr Mishkel).

Fig 1.—Mucocutaneous xanthomatous nodules at both angles of mouth and on buccal mucous membranes.

Fig 2.—Collar of mahogany-brown elevated plaques involving neck.

Fig 3.—Right axilla showing diffuse involvement by purple-brown macules and more localized yellow infiltration in axillary flexures.

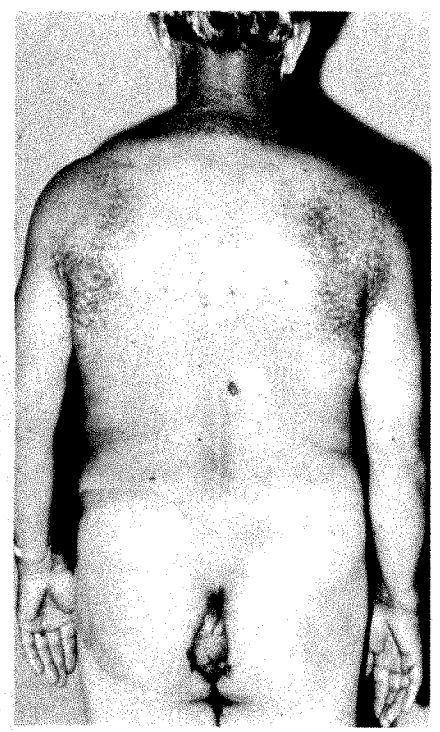

Fig 4.—Posterior aspect of body showing pigmented macular involvement of neck, areas extending up from axillae, and large sessile xanthomatous masses partially obstructing anal orifice.

REPORT OF A CASE

A 55-year-old Yugoslavian man came to the HGH-McMaster Lipid Research Clinic on Aug 18, 1969. Previously he had been seen by one of us (D.R.) in 1966 and a diagnosis of XD was made. The patient noted the appearance of orange-brown lesions on the face and neck in 1954. Initially, the lesions had waxed and waned, but particularly in the last few years, they had spread to other sites and increased in size and number. The lesions caused him concern because of the disfigurement, the tendency for the lesions to itch when he ate certain foods, and because of obstruction to passage of feces.

No family member had similar lesions. His father had died at 72 years from a heart attack, and his mother at 85 years of natural causes. Three sisters had died from infectious diseases and one brother was still alive in Yugoslavia. Except for the mucocutaneous lesions, the patient's only other complaints were of depression and early morning stiffness and aching in the shoulders and hips. In particular, he had no symptoms of vascular insufficiency (angina of effort or intermittent claudication), polyuria nor polydipsia, and no bone pain. His past history included recurrent urinary tract infections, cystoscopy, and subsequent prostatectomy. During a urologic investigation in 1962, some of the perineal lesions were removed, but these quickly recurred. The 13-year follow-up period dates from this time, for microscopic examination disclosed a polypoid xanthoma showing lipid-containing macrophages.

Prior to his first clinic visit he had been shown to be essentially normolipidemic. The laboratory values were as follows: plasma cholesterol, 190 mg/dl; triglyceride, 162 mg/dl (upper limit of normal, 250 and 150 mg/dl, respectively); and phospholipids, 180 mg/dl (normal range, 175 to 305 mg/dl). Results of an oral glucose tolerance test had been abnormal, with a fasting blood glucose level of 116 mg/dl, and blood glucose levels at one-half, one, and two hours of 158, 200, and 110 mg/dl, respectively. Another test performed a year later gave similar results. There was no glycosuria during either test. A routine roentgenogram of his pelvis (1969) showed cystic lesions in the region of the acetabulum but his serum alkaline phosphatase level was normal.

The physical examination showed a middle-aged man in a good state of nutrition. He weighed 61.2 kg (136 lb) and was 160 cm tall. His blood pressure was 110/70, and no abnormality was found in the cardiovascular system including the peripheral pulses. The liver and spleen were not palpable, there was no lymph node enlargement, and no bone tenderness. The only abnormalities found were restricted to mucocutaneous lesions. There was a minor bilateral corneal arc and a single red-brown pinguecula at the outer aspect of the right corneoscleral junction. Otherwise, the eyes were unaffected. There was a smooth, fleshy, yellow-red nodule approximately 1 cm in diameter at the lateral aspect of the right naris, and a smaller lesion on the left. Similar fleshy nodules were seen at the lateral aspects of the mouth, and these extended into the mouth, heaping up the mucous membranes (Fig 1). The nodules were pink or yellow and there were similar smaller lesions scattered over the face and forehead. The entire neck was surrounded by a collar of bosselated mahogany-brown elevated plaques, stretching from below the clavicles and the upper back to below the mandible and the hairline (Fig 2). Two butterfly-shaped areas, extending down the back into the axilla, the lateral chest wall, and up over the anterolateral aspects of the chest, were extensively involved with purple-brown macules. The axillary flexures were diffusely infiltrated with orange-yellow papules and plaques (Fig 3). The antecubital fossae were extensively involved with purple-brown papules and the umbilicus was encircled by a few similar lesions. Pigmented papular lesions were found in the groins, over the scrotum, and in the

popliteal fossa. The anal orifice was partially obstructed by large, sessile, yellow-brown masses (Fig 4).

The extensor surfaces, elbows, knees, and buttocks were spared. There were no tendon xanthomas on the dorsum of the hands and the Achilles tendons were not thickened. The palms of the hands showed no planar xanthomas or diffuse yellowing. The ocular fundi were normal.

Fasting plasma lipid tests showed a cholesterol level of 166 mg/dl and triglycerides, 74 mg/dl; lipoprotein electrophoresis was normal. Other normal biochemical findings included a BUN of 16 mg/dl; fasting blood glucose, 108 mg/dl; and serum uric acid, 6.0 mg/dl.

It was learned from the patient that his family physician had previously placed him on a regimen of clofibrate capsules, which had caused partial regression of his lesions and relieved the pruritic response to certain foods. Clofibrate had been stopped after one year, some six months prior to his clinic visit, because of the cost. The patient was given clofibrate again, 1 gm twice daily. This was continued for three years with one month's break to allow for metabolic studies.

RESULTS

Progress

The patient tolerated clofibrate very well. Within two months he put on 13.5 kg (30 lb) in weight, reached a maximum weight of 74.7 kg (166 lb), and then stabilized at 72 kg (160 lb). Within two months he stated that the pruritic response to pork, sugar, beer, and whisky had been greatly reduced. This symptom returned on temporary cessation of the drug. Within ten weeks of drug therapy, the patient noted a decrease in size of the lesions around the neck. This could not be verified with any certainty until at four months when the yellowing of the axilla was reduced, and more strikingly, the lesions around the neck were flattened considerably from a "cobblestone" appearance to a diffuse thickening of the skin. There was no change in the red-brown pigmentation. There was, however, actual progression of the mucosal lesions in the nose and at the angles of the mouth.

The fasting plasma lipid determinations and lipoprotein electrophoresis (on paper and agarose gel) were repeated more than ten times throughout the next three years, and results were always normal. The majority of cholesterol and triglyceride values were below 200 and 100 mg/dl, respectively.

Subsequent Investigations

The patient was admitted to the hospital July 1972 for removal of the lesions in the nose and mouth. Roentgenograms of the skull showed no abnormality, and in particular, the sella turcica was normal. Multiple cystic lesions in both acetabula, femoral necks, and the proximal phalanx of the right middle finger were essentially as seen in 1969. In addition, there were new cystic lesions in both ischial tuberosities and the left scaphoid bone. The results of serum calcium, phosphorus, alkaline phosphatase, BUN, electrolytes, and oral glucose tolerance test were normal. A complete blood cell count, including platelet count and sedimentation rate, was normal. An iliac crest aspiration showed a normal bone marrow, and in particular, there was no increase in plasma cells and no lipid-laden histiocytes seen. The determinations for serum total proteins, albumin, protein electrophoresis, and immunoelectrophoresis were normal.

The patient declined a bone biopsy of a cystic lesion, but in March 1973 he fell and dislocated his right shoulder. Roentgenograms showed cystic areas in the humerus, clavicle, coracoid process, and acromion. The shoulder was reduced while the patient was under general anesthesia, and an open biopsy of the acromion performed. The bursal tissue was yellow; this specimen and bone curettings from the acromion were examined histologically.

In August 1974 he was seen by another internist (W. B. S.). He was receiving no medication for the xanthomas but followed a low-fat diet and avoided alcohol (to prevent itchiness of the lesions). For the past several years pain in the shoulders, wrists, arms, and legs together with generalized weakness had forced him to stop working and he was limited to walking with a cane. For six weeks he had often complained of increasing difficulty with his balance, for he often felt dizzy. Physical examination was as before with the same cutaneous, buccal mucosal, and perineal lesions; however, in addition, the tongue was large, furrowed, and contained firm deposits. The legs were cold and no arterial pulses were palpable below the femoral arteries.

Laboratory investigations, including urinalysis, hemoglobin, white blood count, and blood film, sedimentation rate, serum electrolytes, BUN, creatinine, blood glucose, bilirubin, SGOT, SGPT, serum albumin, alkaline phosphatase, calcium, phosphorus, and uric acid were all normal. Fasting serum cholesterol level was 220 mg/dl and triglycerides, 67 mg/dl.

A skeletal roentgenographic survey showed widespread lesions. In summary, these were juxta-articular, marginal erosions combined with destructive lesions in trabecular bone, most severe at the hips and shoulders but seen to a lesser degree in the hands and elbows. A chest roentgenogram showed a nodule posteriorly overlying dorsal vertebrae 6 and 7 on the right side. The nodule appeared to be a soft tissue mass closely related to pleura. A bone scan was negative.

In November 1974 a diagnosis of hypothyroidism was made. The patient had noted increasing intolerance to cold for six months and for two years his voice had been lower-pitched and his skin felt drier. The thyroid gland was not enlarged and the serum thyroxine level was 2.0 μgm/dl (normal, 4 to 11 μgm/dl) and serum thyroid-stimulating hormone value, 140 μU/ml (normal, < 10 μU/ml). Cytoplasmic and colloid antibody test results were negative but the thyroglobulin tanned RBC antibodies were present in a titre of 1:40. Replacement treatment was given using levothyroxine sodium.

In December 1974 his wife described an episode of stiffening with tonic and clonic movements of the limbs, associated with unconsciousness, and lasting "all night." An EEG disclosed "mild and diffuse excess of slow activity . . . some minimal paroxysmal features during photo flash stimulation. No features to suggest the presence of a localized cortical lesion." Neurologic examination yielded signs of bilateral pyramidal tract disease with equal hyperactive

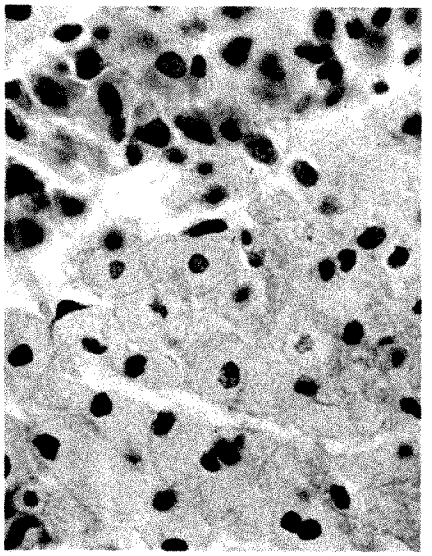

Fig 5.—Pale and denser histiocytes in skin biopsy section (hematoxylin-eosin, original magnification ×400).

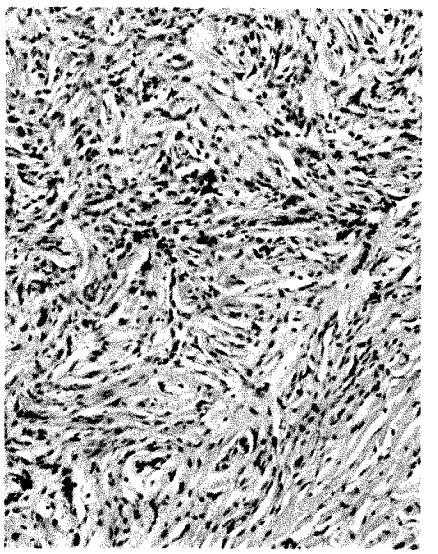

Fig 6.—Dermatofibromatous appearance (hematoxylin-eosin, original magnification ×150).

Fig 7.—Hemosiderin deposits in skin biopsy section. (Prussian blue stain, and hematoxylin-eosin, original magnification ×30).

tendon reflexes, bilateral Babinski responses, and generalized weakness of the limbs, more severe proximally.

A neurologic consultation confirmed bilateral pyramidal tract disease with increased deep reflexes, spasticity in the legs, and bilateral plantar extensor responses. In addition, there was a sensory level to pinprick and light touch at roughly T 11-12, and there was also diminished vibration and joint position sense in the lower limbs. An intramedullary lesion was suggested as the likely cause and a myelogram was performed but showed no significant abnormality. Examination of the CSF showed a protein level of 21 mg/dl, a glucose value of 60 mg/dl, and lymphocyte, 1/cu mm. A serum B_{12} level was normal, and a serum VDRL result was negative.

In order to explain the patient's paraparesis, in February 1975 a radioiodinated serum albumin brain scan and a computerized transaxial tomographic scan of the head were done; both were normal, there being no suggestion of a parasagittal lesion. He was treated symptomatically with diazepam, 2 mg three times a day, which significantly relieved the flexor spasms and spasticity. He was seen by Prof P. K. Thomas (London) who considered that an intraspinal xanthoma[4] had not been ruled out. The patient was last seen in December 1975 and there had been no significant change in his general or neurologic condition.

Biopsy Findings

Infiltrative xanthomatous lesions were prominent in all the biopsy material from skin, mucous membranes, bone, and bursal tissue. There were numerous histiocytes in the connective tissues (Fig 5). Many of these were pale, swollen cells containing doubly refractile lipid and a small central nucleus. Other histiocytes, however, had a denser, eosinophilic cytoplasm and varied in size and shape; their nuclei were larger and a few of these cells were large and multinucleate. Actual Touton cells were very rare. Mitotic activity was not a feature. Mingled with the histiocytes were fibrocytes and small blood vessels in variable numbers; some fields were richly collagenous (Fig 6). A minority of histiocytes contained iron and there were small extracellular deposits of iron (Fig 7). No recent hemorrhage was evident. There were no features of malignancy. The bony infiltrates resembled those seen in the skin and other tissues and did not present the characteristics of eosinophilic granuloma. The microscopic appearances are in best accordance with the very rare condition described as disseminated xanthosiderohistiocytosis by Halprin and Lorincz,[3] and alternatively described as XD. Lipid accumulations are associated with accumulations of histiocytes, which may also contain iron, and the condition is distinct from either hypercholesterolemic or hyperlipemic xanthomatoses.

Radiologic Aspects

The skeletal lesions were para-articular in distribution and intramedullary, affecting particularly the hips, shoulders, elbows, knees, and wrists. The bone foci were discrete, well-demarcated, usually rounded areas of bone destruction varying in size from 0.5 cm to as much as 2.5 cm (Fig 8). In the femoral necks, the oval foci were larger, being as much as 4 cm in length (Fig 9). In the hands, carpal deposits as well as an enchondroma in the proximal phalanx of the middle finger were present. A series of examinations were carried out in several institutions for a period of three years. These studies indicated a slight progression in size of deposits during this period of time. The skull and sella were normal.

This type of bone lesion is vaguely suggestive of deposits in bone such as are seen in amyloidosis and Gaucher's disease, but the severity is far greater than one expects. The lesions in the

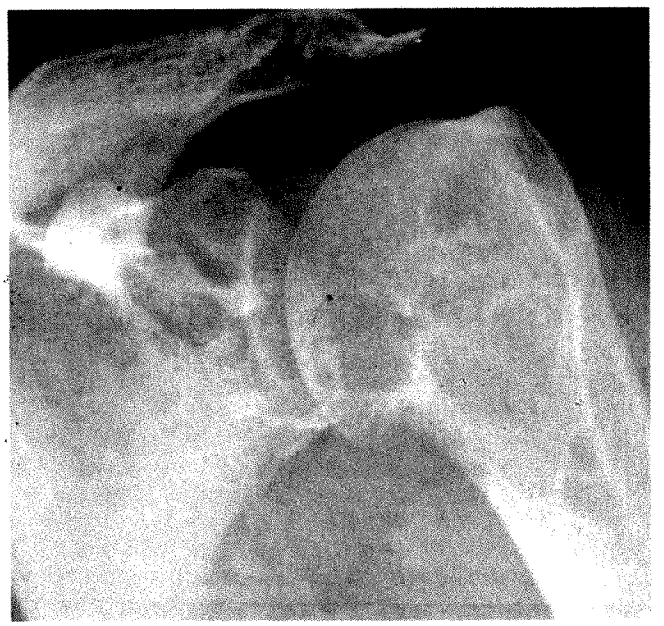

Fig 8.—Left shoulder showing cystic lesions, particularly in head of humerus.

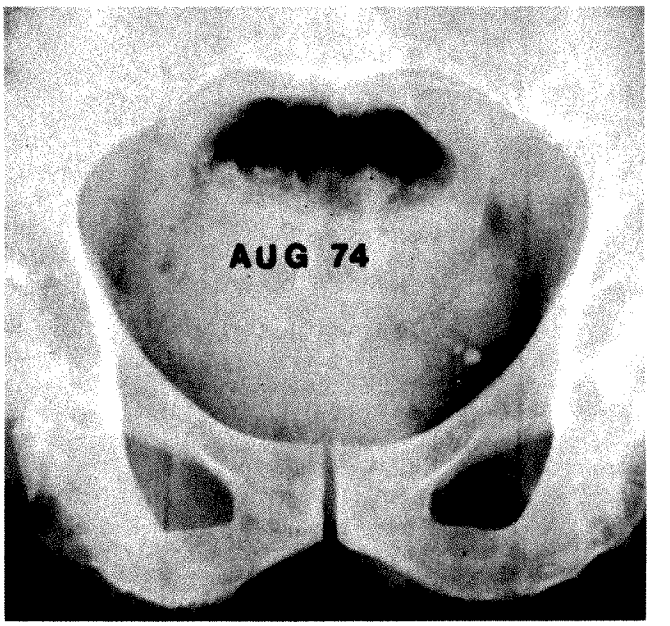

Fig 9.—Cystic lesions in pelvis and femoral necks.

shoulders and hips have features very similar to those recorded in reticulohistiocytosis (lipid arthropathy), but the lack of destructive lesions in the hand around the metacarpophalangeal joints and the interphalangeal joints excludes this possibility. If a single joint had been affected, villonodular synovitis would have to be considered.

These XD lesions are difficult to fit into a conventional diagnosis. In Hand-Schüller-Christian disease the lesions in tubular bones are usually in the shaft, and skull and rib lesions are common. The hands are rarely affected in contradistinction to this case. The well-defined edges, multiplicity of lesions, and chronicity are unlikely features of eosinophilic granuloma.

The parasynovial foci in bone is a different distribution pattern from that one normally sees in eosinophilic granuloma. There the lesions, in a person of the age of this patient, are related to the remaining sites of red marrow in bone. These naturally tend to be in the cancellous intramedullary bone at the proximal and distal ends of the long bones, flat bones, and in the spine. The histiocytic lesions of intramedullary origin extend toward the cortical margin from within. In this patient the lesions seem to be arising from the region of synovial attachment to bone in the para-articular areas; others are however intramedullary in the cancellous bone. Obviously by roentgenographic criteria alone, separation between XD and eosinophilic granuloma cannot be absolute. Lipoid granulomatosis, an entity described by Jaffe,[3] produces a sclerotic endosteal and medullary reaction to the cholesterol-laden cells.

Metabolic Studies

Hepatic cholesterol synthesis was studied while the patient received clofibrate and for a period without (performed in conjunction with H. Sodhi, MD, of Saskatoon). Approximately 100 μCi of acetate labeled with radioactive carbon 14 and 10 μCi of tritium-labeled mevalonate were injected intravenously and blood was taken at zero and two hours, and then every half hour for four hours total. The patient fasted for 12 hours prior to and throughout the test, and ten subjects with hyperlipoproteinemia (HLP) were simultaneously studied under the same conditions. Three had type IIA HLP, three type IIB HLP, three type III HLP, and one type IV HLP. All 11 patients were studied on two separate occasions, by the same technique. On the first occasion all had been receiving clofibrate, 2 gm/day, for a minimum of three months, while on the second occasion they had stopped the drug therapy for a minimum of two weeks. Measurement of incorporation of the two radioactive labels into plasma cholesterol showed that clofibrate inhibited cholesterol synthesis in the patient with XD to a degree (33%) comparable to that found in hyperlipidemic subjects (mean of 42% for ten patients, range 0% to 93%). The results indicate that clofibrate was effective in suppressing hepatic cholesterol synthesis in the patient with XD.

One of the yellow skin lesions was analyzed for its sterol content and this was compared with the composition of a tuberous xanthoma from a patient with hyperlipidemic xanthomatosis (type IIB hyperlipoproteinemia). The tuberous xanthoma had 50% more sterol content, but the major difference was that the sterol in XD was predominantly esterified (Table 1). Only a small percentage of the sterol in both biopsy specimens was in the form of cholestanol.

A recently well-delineated form of normolipidemic xanthomatosis is known as cerebrotendinous xanthomatosis (CTX). It is characterized by

the accumulation of a sterol, cholestanol, which is normally found in tissues in low concentrations. No increase in cholestanol was found in plasma, intestinal aspirate of bile, or a xanthoma from this patient (Table 2). Another metabolic abnormality found in CTX is a reduction in the primary bile acid, chenodeoxycholic acid in the biliary aspirate, but this abnormality was not found in the patient with XD (Table 3). Actually, the percentage of chenodeoxycholic acid was raised by more than 30% in this patient when compared to values for normal subjects, while the secondary bile acid, deoxycholic acid (formed from cholic acid), was considerably lower than in normal subjects.[2]

Table 1.—Comparison of Sterol Composition of a Xanthoma

Components	Xanthoma Disseminatum	Tuberous Xanthoma in Type IIB HLP*
Total sterol, mg/100 gm†	1,592	2,385
Free cholesterol, mg/100 gm	196	1,260
%	12.3	52.8
Ester cholesterol, mg/100 gm	1,391	1,110
%	87.4	46.5
Cholestanol, mg/100 gm	5	15
%	0.3	0.6

*Hyperlipoproteinemia indicated by HLP.
†All sterols expressed as mg/100 gm wet tissue weight.

Table 2.—Comparison of Sterol Composition of Plasma, Biliary Aspirate, and Xanthoma*

Tissue	Cholesterol (A)	Cholestanol (B)	Ratio B/A × 100 in XD	Ratio B/A × 100 in CTX†
Plasma, mg/dl	96.2	0.2	0.2	1.9
Biliary aspirate, mg/dl	177.0	2.5	1.4	3.7-10.6
Xanthoma, mg/100 gm	1,592	4.9	0.3	7.3-11.1

*Xanthoma disseminatum indicated by XD; cerebrotendinous xanthomatosis, CTX.
†Ratios found in cases of CTX by Salen.[2]

Table 3.—Comparison of Bile Acid Percentage Composition in Biliary Aspirate

Bile Acid	Xanthoma Disseminatum	Cerebrotendinous Xanthomatosis*	Normal*
Cholic	34	77-88	45
Chenodeoxycholic	59	3-11	43
Deoxycholic	3	0-7	12
Other	4	5-9	0-2

*Values found in cases of cerebrotendinous xanthomatosis and normal subjects by Salen.[2]

COMMENT

The term XD has been used loosely in the world literature so that confusion abounds. Most authors regard XD as a primary disorder of histiocytic proliferation with secondary accumulation of lipid, both intracellularly and extracellularly. The major point of disagreement is whether XD is a specific entity or if there is a consistent overlap with histiocytosis X, especially the Hand-Schüller-Christian (H-S-C) variant.

A composite picture is that of an adult man without a family history of the disease, who has multiple xanthomatous papules, nodules, and plaques, which are progressive in nature, distributed particularly in the flexor areas of the body, including axillae, antecubital fossae, periumbilical area, perineum, and genitalia. Mucosal lesions in the mouth and of the upper respiratory tract are characteristic and may lead to respiratory embarrassment.[1-6] Lesions in the perineum may interfere with defecation. Except for severe laryngeal involvement, the disease tends to run a chronic course and the lesions have been seen to regress spontaneously. Conjunctival or corneal involvement, or both, are not uncommon. If diabetes insipidus occurs, it usually is mild and may be transient so that continued therapy with vasopressin injection (Pitressin) becomes unnecessary.[7] Diabetes insipidus is thought to be due to the presence of meningeal xanthomas involving the hypothalamic-posterior pituitary axis. No reports of the use of clofibrate in this disease have been found, and a low-fat diet, radiotherapy, and steroid treatment do not have a convincing effect on the course of the disease.

In the typical case, no true differential diagnosis exists. Domonkos[7] believes that XD is not a manifestation of histiocytosis X and Beare,[8] and Allen[9] consider the histology of the two lesions to be different, but Allen considers them to be related.

Thannhauser and Magendantz[10] consider the first case of XD to be the one reported by Virchow[10] in 1871, entitled "Xanthelasma multiplex." Turner[6] in 1925 was the first to differentiate XD from other xanthomatous eruptions. The case described by Horsfall and Smith[1] was considered to be one of XD but it better fits H-S-C disease in a child. The cutaneous lesions were those of XD with involvement of bone, dura of the brain, pituitary, spinal cord, and the lungs. In view of the epileptic fit and the spastic paresis in our case, the xanthomatous lesion of the pons in the cases of Weidman and Schaffer[11] and Chiari[10] are relevant.

Altman and Winkelmann[12] described seven cases of XD and reviewed an additional 46 cases. They quoted Fleischmajer[13] in differentiating between XD and the H-S-C syndrome, as follows.

1. Xanthoma disseminatum usually occurs in adults, while the H-S-C syndrome primarily affects children.

2. Diabetes insipidus may be absent, mild, or transient in XD while it is one of the classic triad of the H-S-C syndrome.

3. Bone lesions are rarely associated with XD but our case bridges this very basic difference between the two syndromes. Involvement of the upper respiratory tract is frequently associated with XD.

4. Xanthoma disseminatum is

usually self-limited with a good prognosis, while the H-S-C syndrome usually is progressive and has a poor prognosis.

5. The histology of XD reveals a xanthomatous picture from the beginning, progressing in some areas to fibrosis. The histology of the H-S-C syndrome is that of a granuloma, although xanthomatous features frequently occur.

Altman and Winkelmann[12] noted that iron deposition was not a feature of their cases. When present, iron was found within histiocytes and giant cells. The case of Halprin and Lorincz[3] showed considerable accumulation of iron pigment granules within the histiocytes, and they proposed the new term xanthosiderohistiocytosis.

Little information is available about the sterol content of the xanthomas. Thannhauser and Magendantz[10] found that a lesion contained cholesterol, 4.6 mg/100 gm (dry weight) of which 80% was esterified. (This probably should have been expressed as 4.6 gm/100 gm). In three cases analyzed by Altman and Winkelmann,[12] the total cholesterol level was 4.6, 3.4, and 7.0 gm/100 gm (wet weight) as compared to 1.6 gm/100 gm (wet weight), with 87% esterified cholesterol in our case (Table 1). To our knowledge, this was the first attempt to find an accumulation of cholestanol.

Kalz et al[14] followed up a patient with XD for ten years and reported that orally taken steroid treatment did not stop the progression of the cutaneous lesions. Combined oral steroids and electrocoagulation prevented the lesions from relapsing once they were removed. Altman and Winkelmann[12] showed cases undergoing spontaneous remission, and they considered that there was no effective treatment for XD. The response to clofibrate in our case (by regression of cutaneous lesions once and cessation of pruritus on both occasions) might have been fortuitous. However, we have shown that clofibrate suppressed hepatic cholesterogenesis and local suppression of cholesterol synthesis may have been the mechanism involved. In spite of the improvement of the cutaneous lesions, those of the oral mucous membrane, in the perineum and the bone, increased in size.

All authors agree that XD should have normal plasma lipid levels, and Altman and Winkelmann[12] stressed that XD is not primarily a systemic disorder of lipid metabolism. The histologic appearance of the lesions suggests that the disease is basically a reactive histiocytic proliferation in which lipid accumulates as a secondary phenomenon. The proliferation of histiocytes, whether benign or more atypical, would suggest to us that XD is possibly a variant of the histiocytosis X group of disorders. Altman and Winkelmann[12] consider only one case, that of Gottron, as being acceptable as a case of typical H-S-C syndrome associated with typical XD.

Supported in part by grant 15-10 from the Ontario Heart Foundation, and by a grant from the Canadian Life Insurance Association, Toronto.

The clofibrate used in this study was supplied by Leighton Smith, MD, Ayerst Laboratories, Montreal.

References

1. Crocker AC: The histiocytosis syndromes, in Fitzpatrick TB, Arndt KA, Clark WH, et al (eds): *Dermatology in General Medicine*. New York, McGraw-Hill Book Co Inc, 1971, pp 1331-1332.

2. Salen G: Cholestanol deposition in cerebrotendinous xanthomatosis. *Ann Intern Med* 75:843-851, 1971.

3. Halprin KM, Lorincz AL: Disseminated xanthosiderohistiocytosis (xanthoma disseminatum). *Arch Dermatol* 82:171-182, 1960.

4. Horsfall FL, Smith WR: Lipoid granulomatosis: Defects in bones, exophthalmos and diabetes insipidus. *Q J Med* 4:37-51, 1935.

5. Jaffe HL: *Metabolic Degenerative and Inflammatory Disease of Bones and Joints*. Philadelphia, Lea & Febiger, 1972.

6. Turner AL: A case of xanthoma tuberosum with extensive distribution of the xanthomatous nodules on the mucous membrane of the respiratory tract. *J Laryngol* 40:249-252, 1925.

7. Domonkos AN: *Andrews' Diseases of the Skin*. Philadelphia, WB Saunders Co, 1971, pp 632-633.

8. Beare JM: Histiocytic proliferative disorders, in Rook A, Wilkinson DS, Ebling FJG (eds): *Textbook of Dermatology*. Oxford, Blackwell, 1972, vol 2, pp 1364-1378.

9. Allen AC: *The Skin: A Clinicopathological Treatise*. New York, Grune & Stratton Inc, 1967, pp 1053-1054.

10. Thannhauser SJ, Magendantz H: The different clinical groups of xanthomatous diseases. *Ann Intern Med* 2:1662-1746, 1938.

11. Weidman FD, Schaffer HW: Xanthoma of the skin and larynx: Associated with carcinoma of the stomach and regressive xanthoma of the pons. *Arch Dermatol Syphilol* 35:767-814, 1937.

12. Altman J, Winkelmann RJ: Xanthoma disseminatum. *Arch Dermatol* 86:582-596, 1962.

13. Fleischmajer: *The Dislipidoses*. Springfield, Ill, Charles C Thomas Publisher, 1960, p 509.

14. Kalz F, Hoffman MM, Lafrance A: Xanthoma disseminatum. *Dermatologica* 140:129-141, 1970.

Congenital Cutaneous Candidiasis

Nathan Rudolph, MB, BCh; Arshad A. Tariq, MB, BS; Mario R. Reale, MD; Philip K. Goldberg; Philip J. Kozinn, MD

• **Three newborn infants are described in whom a generalized maculopapular rash was observed at birth or soon after. The eruption rapidly became vesicular, and in one infant it became bullous, and was followed in each case by extensive desquamation. *Candida albicans* was demonstrated on direct smear and on culture from the skin vesicles, and evidence of an intrauterine infection with this organism was detected on histologic examination of the placenta in at least two of the cases. Agglutinating antibodies to *Candida* were present in the sera of all three infants, though these may have reflected transplacental passage of maternal antibody.**

***(Arch Dermatol* 113:1101-1103, 1977)**

Candidal infection of the newborn infant is manifest most often in the form of oral thrush and is acquired by the infant during passage through the mother's birth canal. However, a generalized candidal dermatitis that appears at or shortly after birth implies an intrauterine infection, and there have been only nine such authentic reports.[1-7] Three additional cases are now added.

Accepted for publication June 14, 1976.

From the Department of Pediatrics, Maimonides Medical Center and Downstate Medical Center, State University of New York, Brooklyn.

Reprint requests to Department of Pediatrics, Box 49, Downstate Medical Center, 450 Clarkson Ave, Brooklyn, NY 11203 (Dr Rudolph).

REPORT OF CASES

CASE 1.—A 3,260-gm male infant was delivered by low-forceps extraction to a 19-year-old primipara after 42 weeks of gestation. The infant's Apgar score was 9 at one minute. The mother had had recurrent urinary tract infections and required hospitalization during the eighth month of pregnancy, when she was found to have pyuria with *Escherichia coli*, enterococci, and yeasts that were identified on urine culture; she was discharged without specific therapy. At birth, the infant was active and in no distress. His abnormal physical findings were limited to the skin. A diffuse pinkish-red maculopapular eruption was present over the face, neck, front of chest, and arms with a few scattered lesions over the lower limbs. Twenty-four hours after delivery, the rash had become vesicular and had spread to the hands and feet (Fig 1). In some areas, especially the palms and soles, bullae subsequently developed, and some of the vesicles and bullae became pustular. By 4 days of age, eruption on the trunk and chest subsided but persisted on the palms and soles, where the lesions lasted for almost two weeks (Fig 2 and 3). The rash was followed by extensive desquamation.

The results of the infant's complete blood cell count (CBC), including his platelet count, were normal, as were the results of blood culture, CSF examination, and serum electrolyte determinations. At 2 days of age, a direct smear from the vesicles showed mycelia and yeasts that were identified as *Candida albicans* by culture. *Candida albicans* was also cultured from the umbilical stump, urine, and stool. At 3 days of age, immunoglobulin levels were as follows: IgG, 1,100 mg/100 ml; IgM, 10 mg/100 ml; and IgA, 15 mg/100 ml. At 14 days of age, immunoglobulin levels were as follows: IgG, 860 mg/100 ml and IgM, 24 mg/100 ml. At 28 days of age, immunoglobulin levels were as follows: IgG, 540 mg/100 ml and IgM, 24 mg/100 ml. Histologic examination of a PAS preparation of the umbilical cord and placenta showed an inflammatory process, karyorrhexis, and *Candida* on the umbilical cord and fetal surface of the placenta. Neither mother nor infant had constitutional manifestations of systemic disease. Results of specific immunologic tests for *Candida* in case 1 are shown in the Table. The infant's therapy consisted of nystatin cream applied locally three times daily for ten days and 200 mg of nystatin oral suspension four times daily for ten days because of *Candida* in the stool. The infant thrived and was discharged at the weight of 4,550 gm at 4 weeks of age.

CASE 2.—A 4,110-gm, full-term male infant was delivered by Cesarean section to a 21-year-old woman, para 0010 because of cephalopelvic disproportion. The mother had had a candidal vaginitis at 28 weeks of gestation that was not treated. Her membranes had ruptured 12 hours prior to delivery. The infant's Apgar score was 7 and 10 at one and five minutes, respectively. Twelve hours after delivery, a diffuse maculopapular rash was noted on the infant's face, chest, and extremities.

Fig 1.—Papulovesicular stage of eruption of congenital cutaneous candidiasis (patient 1).

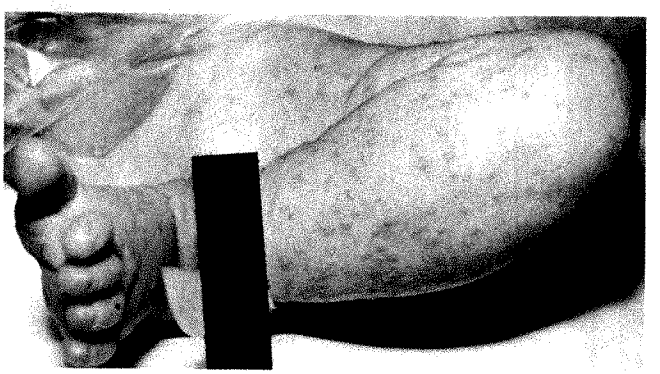

Fig 2.—Vesiculobullous candidal lesions on heel (patient 1).

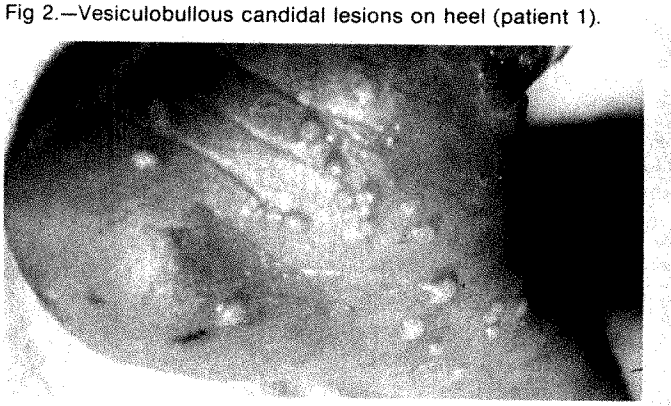

By 3 days of age, this rash had become vesiculopustular, and oral thrush was detected at 4 days of age. Desquamation commenced at 5 days of age and reached a peak by 9 days of age, after which gradual resolution occurred. The infant was afebrile throughout and manifested no constitutional signs of systemic disease. Positive smears and cultures for *Candida* were obtained from the skin lesions, mouth, and conjunctival sacs. Urine collected by bag yielded a growth of *Staphylococcus aureus* and *Candida*. The results of the infant's CBC, including his platelet count, were normal, as were the results of his serum electrolyte determinations; the result of the rapid plasma reagent test for syphilis was negative. At 6 days of age, immunoglobulin levels were as follows: IgG, 1,150 mg/100 ml; IgM, 30 mg/100 ml; and IgD, 1 mg/100 ml. The candidal dermatitis was treated with nystatin cream three times daily for ten days, and the oral thrush with 100,000 units of nystatin oral suspension every four hours after feeding for two weeks. He was discharged on the 18th day at the weight of 4,870 gm with normal physical findings.

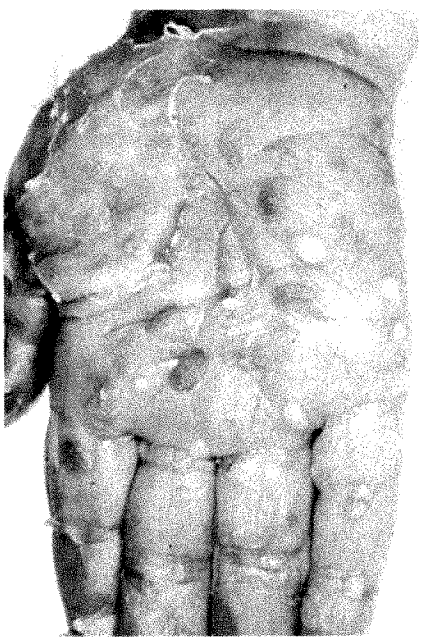

Fig 3.—Late clearing of bullous lesions on palm with commencing desquamation (patient 1).

The mother became febrile on the first postoperative day and fever persisted for six days. On the third postoperative day, small yellow vesicles appeared along her abdominal incision, and direct smear and cultures of material from these vesicles showed *C albicans*. She was treated with flucytosine (100/mg/kg/day) in four divided doses and with local applications of gentian violet. The fever subsided and the abdominal lesions cleared rapidly. She was discharged on the 13th postoperative day in good condition.

Histologic examination of the placenta showed the presence of an inflammatory process with karyorrhexis, and PAS staining showed *Candida* on the umbilical cord and fetal surface of the placenta. Results of specific immunologic tests for *Candida* in case 2 are shown in the Table.

Case 3.—A 2,270-gm female infant was born to a 22-year-old primipara by normal spontaneous delivery after 36 weeks of gestation. The mother's antepartum visits were irregular and no antepartum vaginal cultures were taken. Membranes ruptured two hours prior to delivery. The Apgar score was 9 at one minute. Three hours after delivery, a diffuse maculopapular rash was noted over the infant's face, chest, back, and extremities (Fig 4). This rash rapidly became vesicular. The lesions gradually dried and generalized desquamation occurred (Fig 5). On discharge at 2 weeks of age, the infant was thriving, and her skin was normal. At no time during her hospital stay was there fever or any other constitutional sign. A direct smear from the yellow vesicular fluid showed mycelia and yeasts that were confirmed as *C albicans* by culture. Urine obtained by suprapubic puncture yielded 5,000 colonies of *Candida* per milliliter. Results of the infant's CBC were normal. At 6 days of age, the infant's serum had an agglutinin titer for *Candida* of 1:320 and a negative precipitin test. Treatment consisted of local applications of nystatin cream. The mother's postpartum course was uneventful. Histologic examination of the umbilical cord and placenta showed inflammatory changes, but they were not stained specifically with PAS to demonstrate *Candida*.

COMMENT

A review of the known cases of congenital cutaneous candidiasis[1-7] indicates that this condition does not appear to be related to maternal age, parity, prematurity, type of delivery, duration of labor, or premature rupture of membranes. This fact is in contrast to the known correlation between the duration of rupture of membranes and neonatal bacterial infection.[8] In most of the previous cases, the rash was noted at birth or within 12 hours after delivery. However, in two cases with evidence of intrauterine infection of the fetal adnexae, the eruption appeared at 4 and 6 days of age, respectively.[6] The rash is diffuse and may involve the trunk, neck, face, and extremities. The lesions pass through macular, papular, vesicular, and pustular

Fig 4.—Early diffuse maculopapular and vesicular stage of candidal rash (patient 3).

Fig 5.—Extensive confluent desquamation on trunk (patient 3).

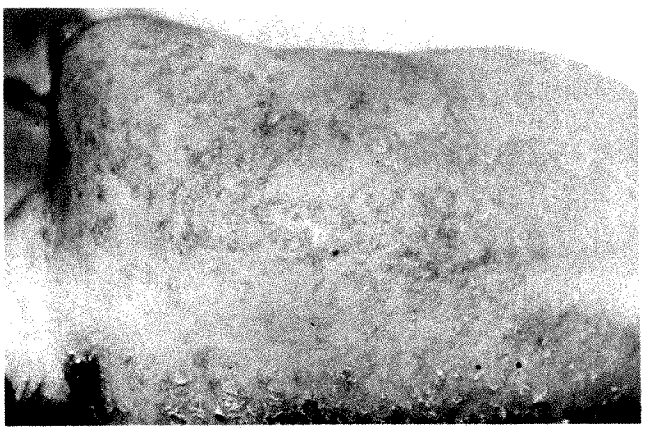

Immunologic Findings*					
		Agglutinin Titers for *Candida*		Precipitin Titers for *Candida*	
Patient	Date	Infant	Mother	Infant	Mother
1†	4/10/74	1:640	1:320	0	0
	4/22/74	1:320	. . .	0	. . .
	3/7/75	1:40	1:20	0	0
2‡	10/5/74	1:640	1:320	0	0
	10/11/74	1:320	1:320	0	1:4
	10/22/74	. . .	. . .	. . .	1:8
	11/5/74	. . .	. . .	. . .	1:4
	3/7/75	1:80	1:640	0	1:1

*Data from Taschdjian et al.[17]
†Patient 1 was born April 6, 1974.
‡Patient 2 was born Oct 1, 1974.

phases, and even bulla formation has been noted. Desquamation had been a prominent feature of the recuperative period. It is of interest that in only one of the reported cases (case 2) was oral thrush noted. The oral lesions observed in a case by Cabaniss et al[9] at 4 weeks of age were presumably due to a postnatal infection.

The course of the cutaneous infection is characterized by an absence of constitutional signs and normal WBC and platelet counts. However, since *Candida* was cultured from urine obtained by suprapubic puncture in case 3, it appears that asymptomatic systemic dissemination of the organism might occur. Cultures from the mouth and skin in our three cases were positive only in association with clinically obvious lesions, while positive cultures from the conjunctiva in case 2 were not associated with recognizable clinical disease of the conjunctiva. This fact might be explained by local tissue immunity of the conjunctival mucosa.[10] Immunoglobulin levels, where determined, were not altered, in contrast to the hypergammaglobulinemia and hypogammaglobulinemia reported in systemic candidiasis.[11]

The mechanism whereby infection of the fetus and fetal adnexae occurs has been the subject of much discussion.[8,12,13,14] The appearance of candidal dermatitis at, or shortly after birth, clearly points to intrauterine infection. Flamm[15] demonstrated that *Candida* cannot pass the placental barrier and indicated that ascending infection via the birth canal, with or without colonization of the fetal adnexae, is the probable route of invasion. This infection may be facilitated by clinical or subclinical rupture of membranes prior to the onset of labor.[13]

Gotz and associates[16] demonstrated that *Candida* has the ability to invade and penetrate intact chick chorioallantoic membranes, which suggests the possibility that the organism may also infect the amniotic sac through intact membranes. Negative blood cultures in cases 1 and 2 and the absence of precipitating antibodies tend to indicate that there was no hematogenous spread of the candidal infection in the fetus.[17]

Since cutaneous candidiasis may occur from two to seven days after exposure to the organism, the intrauterine infection in each of our patients must have occurred within the week prior to labor. Intrapartum infection of the skin acquired during passage through the birth canal is possible,[14] but this would then have resulted in the appearance of the rash at a later age, as would infection transmitted by infected nursery personnel.

The clinical picture of the candidal dermatitis may initially resemble erythema toxicum or a bacterial folliculitis. At a later stage, other vesiculobullous eruptions such as herpes, syphilis, varicella, bullous impetigo, and histiocytosis may need to be differentiated. The diagnosis is suggested by the clinical features of the condition as manifested by a progressive but generally benign course, by the characteristic desquamation, and by the absence of constitutional signs; it is confirmed by direct smear and culture from the vesicles. Although all three infants had high serum agglutinin titers for *Candida*, the diagnostic importance of this finding is not clear since it could reflect transplacental passage of maternal antibodies, rather than antibodies produced by the fetus. In addition, testing for the presence of precipitating antibodies, which are generally associated with systemic disease,[17] appears to be of little diagnostic value in this cutaneous infection, in spite of the widespread dermal involvement.

Nonproprietary Name and Trademark of Drug

Flucytosine—*Ancobon*.

References

1. Sonnenschein H, Clark HL, Taschdjian CL: Congenital cutaneous candidiasis in a premature infant. *Am J Dis Child* 99:81-85, 1960.
2. Sonnenschein H, Taschdjian CL, Clark DH: Congenital cutaneous candidiasis. *Am J Dis Child* 107:260-266, 1964.
3. Jahn CL, Cherry JD: Congenital cutaneous candidiasis. *Pediatrics* 33:440-441, 1964.
4. Dvorak AM, Gavaller B: Congenital systemic candidiasis. *N Engl J Med* 274:540-543, 1966.
5. Rhatigan RM: Congenital cutaneous candidiasis. *Am J Dis Child* 116:545-546, 1968.
6. Schirar A, Rendu C, Vielh JP, et al: Congenital mycosis. *Biol Neonate* 24:273-278, 1974.
7. Kam LA, Giacoia GP: Congenital cutaneous candidiasis. *Am J Dis Child* 129:1215-1218, 1975.
8. Blanc WA: Pathways of fetal and early neonatal infection: Viral placentitis, bacterial and fungal chorioamnionitis. *J Pediatr* 59:473-496, 1961.
9. Cabaniss WH Jr, Manley WF Jr, Swan RE: Cutaneous moniliasis in a premature infant. *J Pediatr* 50:480-483, 1957.
10. Kozinn PJ, Caroline L, Taschdjian CL: Conjunctiva contains factor inhibiting growth of *Candida albicans*. *Science* 146:1479-1480, 1964.
11. Kozinn PJ, Taschdjian CL, Seelig M, et al: Diagnosis and therapy of systemic candidiasis. *Sabouraudia* 7:98, 1969.
12. Kozinn PJ, Taschdjian CL, Wiener H: Incidence and pathogenesis of neonatal candidiasis. *Pediatrics* 21:421-429, 1958.
13. Benirschke K, Raphael SI: *Candida albicans* infection of the amniotic sac. *Am J Obstet Gynecol* 75:200-202, 1958.
14. Kozinn PJ, Taschdjian CL, Burchall JJ, et al: Transmission of P_{32} labelled *Candida albicans* to newborn mice at birth. *Am J Dis Child* 99:31-34, 1960.
15. Flamm H: *Die pränatalen Infektionen des Menschen*. Stuttgart, Germany, Georg Thiem, 1959, p 70.
16. Gotz H, Nasemann T, Sturde HC: Weitere untersuchungen über die praktische Verwendung des Chorionallantoistests zur Hefedifferenzierung. *Arch Klin Exp Dermatol* 203:582-597, 1956.
17. Taschdjian CL, Seelig MS, Kozinn PJ: Serological diagnosis of candidal infections. *CRC Crit Rev Clin Lab Sci* 4:19-59, 1973.

Sporotrichoid Leishmaniasis

Stanley Spier, MD, FRCP(C); Maria Medenica, MD; Shirley McMillan, MA; Christopher Virtue, MD

• American leishmaniasis that is acquired in Panama may appear clinically as a sporotrichoid eruption. When lesions reminiscent of sporotrichosis are encountered, a careful history of the patient's travels should be made, as well as a search for the organism of leischmaniasis in tissue smears, histopathological sections, and cultured media. We report the case of an American soldier stationed in Panama who had developed an ulcer on the dorsum of his right wrist, and nodules on his right forearm that were arranged in a linear pattern. The initial clinical impression was that of sporotrichosis, but on careful study of the patient's history, and after other appropriate investigations were made, it was discovered that the patient had leishmaniasis.

(*Arch Dermatol* 113:1104-1105, 1977)

American leishmaniasis acquired in Panama may appear clinically as ulcers together with nodules that are arranged in a linear configuration that follow the course of the lymphatic channels[1-3] and thus mimic the classical features of sporotrichosis. We treated a patient who had sporotrichoid leishmaniasis, and we document the case and underline the necessity of considering leishmaniasis in the face of a sporotrichoid eruption.

Accepted for publication May 19, 1976.

From the Department of Dermatology, the Abraham Lincoln School of Medicine, University of Illinois, Chicago.

Reprint requests to 5845 Cote des Neiges, Suite 290, Montreal, Quebec, Canada (Dr Spier).

REPORT OF A CASE

A 21-year-old man had enjoyed good health and had an unremarkable medical history. While stationed in Panama for 18 months with the US Army, he developed "raised red dots" on the back of his right wrist, on both forearms, and on his earlobes at the sites of recent sandfly bites. All the lesions except one healed after a few days. One lesion on the back of his right wrist steadily increased in size and eventually ulcerated. Approximately three weeks later, he developed nodules in a linear pattern on his right forearm.

We saw the patient approximately seven weeks following the initial appearance of the lesions, and at that time he had a superficial ulcer (3×2 cm) on the dorsum of his right wrist. The ulcer had an indurated, rolled border with surrounding erythema, and a purulent base (Fig 1). On the right forearm there were nontender nodules in a linear arrangement (Fig 2). The epitrochlear and axillary lymph nodes were not palpable. The results of the remainder of the physical examination were normal.

The following laboratory tests were performed, and the results were found to be negative or within normal limits: complete blood cell count (CBC); urinalysis; chest film; serum protein electrophoresis; ECG; blood chemistry studies (including liver function tests and BUN) using an automated multiple analysis system (SMA-12); VDRL; culture of biopsy specimen from the edge of the ulcer for deep fungus, including sporotrichosis; fungal immunodiffusion for *Sporotrichum* antigen (four different antigens), *Aspergillus* antigen (five different antigens), *Histoplasma* antigen, *Blastomyces* antigen, and *Candida* antigen; fixation tests for histoplasmosis, blastomycosis, and coccidioidomycosis; smears and culture of biopsy specimens for

Fig 1.—Ulcer on dorsum of right wrist with indurated, rolled border and surrounding erythema.

Fig 2.—Right forearm showing nodules in linear arrangement.

Fig 3.—Leishman-Donovan bodies seen mainly within the cytoplasm of histiocytes (Giemsa, original magnification ×1,000).

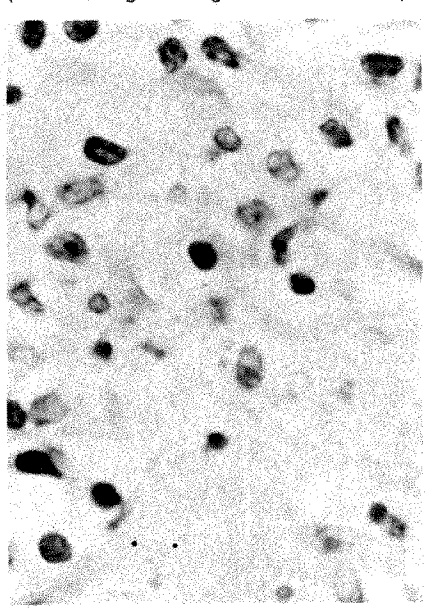

typical and atypical mycobacteria.

Two punch biopsy specimens (4 mm) were taken from the edge of the ulcer. Sections were stained with hematoxylin-eosin (HE), PAS, Giemsa, and Ziehl-Neelsen. The purulent exudate at the base of the ulcer was cultured for bacteria, and sensitivity studies were made. With HE and Giemsa stains, Leishman-Donovan bodies were clear and abundant, mainly within the cytoplasm of the histiocytes (Fig 3).

Culture of the biopsy specimen for leishmania organisms on Novy-MacNeal-Nicolle medium was not successful.

Coagulase-negative staphylococci were found, as were Herbicola-Lathyri. The patient was treated with erythromycin stearate taken orally, by cool tap water compresses, and topical bacitracin ointment.

The patient was then admitted to the hospital and treated with sodium antimony gluconate (Pentostam), 600 mg (intramuscular) daily, for ten days. Prior to the antimony therapy two of the nodules on the dorsum of the right forearm enlarged, became fluctuant, and produced a serous exudate. Within four weeks of completion of the antimony injections, all the lesions were completely healed. The patient experienced no side effects other than temporary T wave inversion of his ECG.

The following laboratory tests were performed during antimony treatment, and the results were found to be negative or within normal limits: CBC, urinalysis, chest film, blood chemistry studies (including liver function tests and BUN), and serum protein electrophoresis. Compared with ECG tracings done prior to therapy, the ECG taken during antimony treatment showed inverted T waves in leads V_2 and V_3.

A CBC was done following treatment and was found to be within normal limits. An ECG performed following treatment showed reversal of T wave inversion in leads V_2 and V_3.

COMMENT

The first case of cutaneous leishmaniasis in the Republic of Panama was reported by Darling in 1910. Since then, many cases of the disease have been reported among military personnel stationed in the Canal Zone.

As in the other types of leishmaniasis, the disease acquired in Panama is transmitted via an insect vector (the *Phlebotomus*, or sandfly).[3] Most Panamanian cases are acquired in the dry-season months of January and February.[1,2] Our patient acquired his disease at the beginning of the dry season.

American mucocutaneous leishmaniasis differs clinically from oriental sore in that in the former, the mucous membranes of the nose and throat are frequently affected—sometimes even causing severe mutilation or death.[4]

Leishmaniasis acquired in Panama differs from that acquired in South America in at least two respects. In the former there is infrequent involvement of mucous membranes[3,5,6] and the presence of palpable nodules in a linear arrangement along the lymphatics that drain the ulcer.[1-3] The resultant clinical picture is reminiscent of that seen in sporotrichosis.

It is therefore important to take a complete history, particularly in regard to the patient's travels and to the possibility of exposure to the vectors of leishmaniasis. One should, when it is appropriate, aggressively look for the organism in tissue smears, histopathological sections, and cultured media. The search for *S schenkii* should be done concurrently.

The diagnosis in the case of our patient was made by finding the nuclei and parabasal bodies, which were located chiefly inside histiocytes. The organisms were visable equally well with HE and with Giemsa stains.

Our patient responded to antimony therapy within a few days, with quick healing of the ulcer and the disappearance of all nodules—in contrast to the slow rate of spontaneous healing that usually requires several months or years.

References

1. Snow JS, Satulsky EM, Kean BH: American cutaneous leishmaniasis: Report of twelve cases from the Canal Zone. *Arch Dermatol* 57:90-101, 1948.
2. Kean BH: Cutaneous leishmaniasis on the Isthmus of Panama. *Arch Dermatol* 50:237-238, 1944.
3. Calero CM, Johnson CM: Cutaneous leishmaniasis in the Republic of Panama. *Am J Trop Med Hyg* 2:628-633, 1953.
4. Fox H: American (mucocutaneous) leishmaniasis in clinical tropical medicine, in Taylor Bercovitz Z (ed): *Clinical Tropical Medicine*. New York, Harper & Row Publishers Inc, 1944.
5. Shanbrom E, Minton R, Lester C, et al: Visceral manifestations of American mucocutaneous leishmaniasis. *Amer J Med* 20:145-152, 1956.
6. Walton BC, Person DA, Bernstein R: Leishmaniasis in the US military in the Canal Zone. *Amer J Trop Med Hyg* 17:19-24, 1968.

Epithelioid Sarcoma

A Distinctive Clinical Presentation

Norma Saxe, MB, Jan B. C. Botha, MB

• A case of epithelioid sarcoma occurred in an adult black man. The neoplasm recurred after 15 years in the form of multiple nodules and distinctive annular plaques. To our knowledge, this latter clinical manifestation has not been reported previously.

(*Arch Dermatol* 113:1106-1108, 1977)

Epithelioid sarcoma, a rare soft tissue neoplasm, was first described by Enzinger in 1970.[1] The histogenesis is uncertain, but ultrastructural studies suggest a synovial rather than a fibroblastic origin.[2-5] Although no age group is exempt, it usually occurs in young adults, predominantly males. Epithelioid sarcoma affects the soft tissues, manifesting as skin nodules and ulcers.[6-9] While it can occur at any site, it is most frequently found on the extremities.[1-5] The neoplasm grows slowly and may be present for months or years prior to treatment. The clinical course is characterized by frequent recurrences and late metastases, especially to the lungs and scalp.

We treated a patient with epithelioid sarcoma whose tumor recurred with multiple nodules and plaques consisting of an annular raised border with normal-appearing skin in the center. This distinctive clinical appearance has not been described previously, nor has any reference to epithelioid sarcoma appeared in the dermatologic literature, to the best of our knowledge, other than a brief reference.[10] and a case report.[11]

Accepted for publication May 10, 1976.

From the Departments of Dermatology and Pathology, Groote Schuur Hospital, Observatory, Cape Town, South Africa.

Reprint requests to Department of Pathology, University of Cape Town Medical School, Observatory, 7925, South Africa (Dr Botha).

REPORT OF A CASE

Clinical History

A 38-year-old African (black) man was referred to Groote Schuur Hospital in 1960 from an outlying area, following incomplete excision of a tumor on the dorsum of the right wrist. A histologic diagnosis of anaplastic squamous carcinoma had been made. A soft pectoral lymph node was present, but no bony or other evidence of metastatic spread was found. An axillary block dissection at the time failed to reveal any evidence of tumor, and radiotherapy was administered to the wrist lesion. In 1975, the patient was seen elsewhere with a recurrence of the lesion at the original site. A biopsy specimen was interpreted as an amelanotic melanoma, and the patient was again referred to Groote Schuur Hospital. On examination, he had a fungating tumor measuring 6.0 × 4.0 cm on the dorsum of the right wrist, as well as multiple nodules, some ulcerated, and annular plaques on both the flexor and extensor surfaces of the forearm (Fig 1). The individual plaques resembled such benign annular lesions as annular sarcoid, although there was no doubt as to the malignant nature of all the lesions. Apart from squamous carcinoma and malignant melanoma, other conditions considered in the clinical differential diagnosis included Kaposi's sarcoma and atypical fibroxanthoma arising in a previously irradiated area. Another biopsy was performed, followed by amputation of the forearm.

Pathologic Findings

The biopsy specimen showed the presence of a well circumscribed nest of cells

Fig 1.—Annular plaques and nodules on flexor surface of forearm.

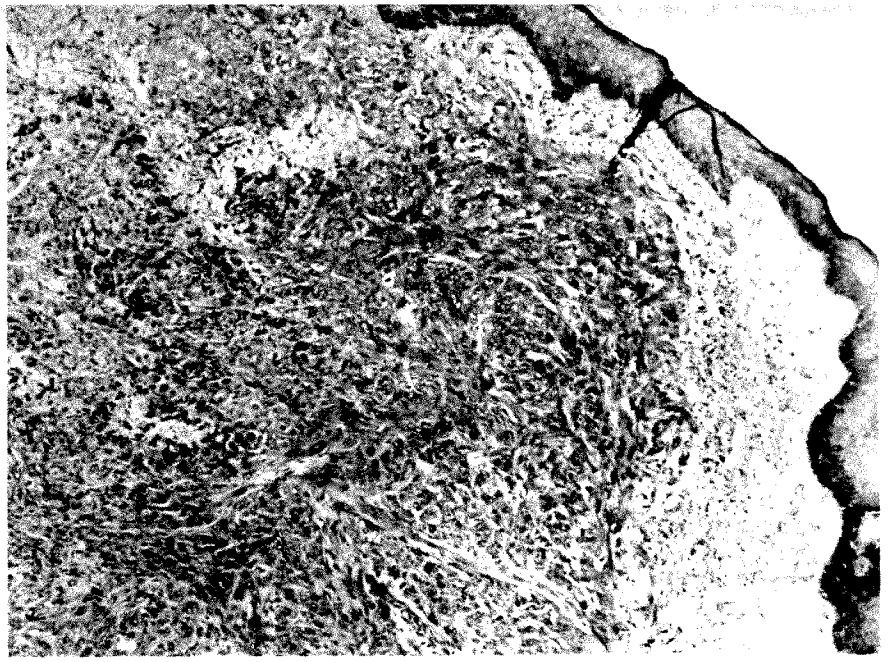

Fig 2.—Subepidermal location of tumor nodule (hematoxylin-eosin, original magnification ×40).

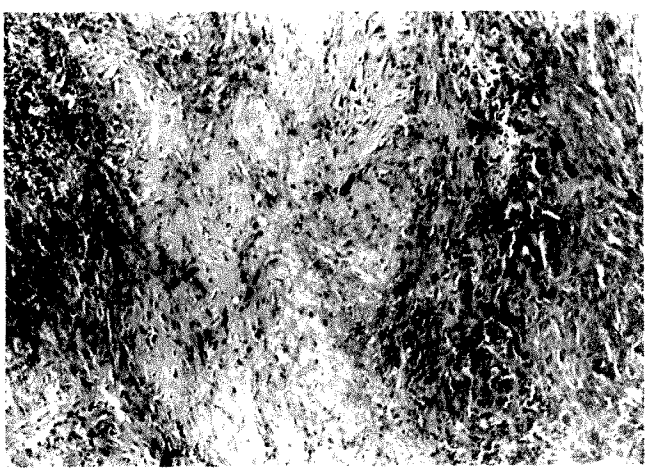

Fig 3.—Tumor nodule showing area of central degeneration (hematoxylin-eosin, original magnification ×40).



Fig 4.—Abundant lymphocytes along margin of tumor nodule (hematoxylin-eosin, original magnification ×100).

Fig 5.—Sheets of epithelioid cells with abundant cytoplasm and a single atypical mitotic figure (hematoxylin-eosin, original magnification ×800).

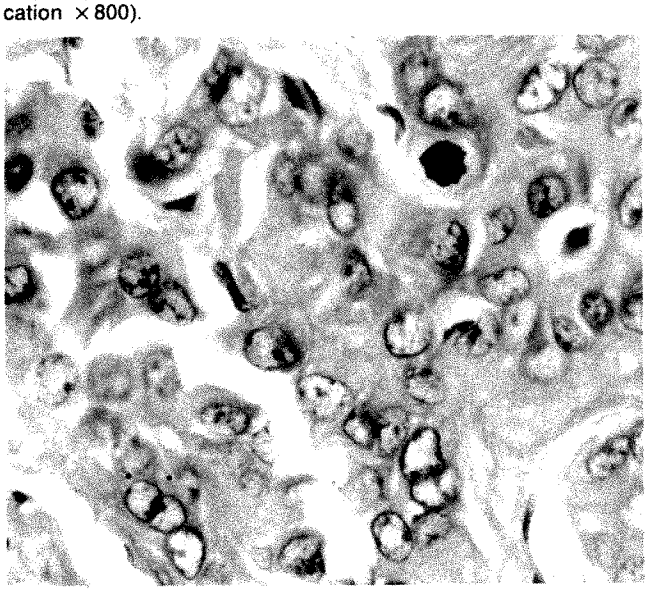

Fig 6.—Spindled neoplastic cells (hematoxylin-eosin, original magnification ×800).

Fig 7.—Annular plaques with central ulceration on left wrist of second patient.

situated in the dermis. The cells varied from spindle to epithelioid in appearance, had a moderately acidophilic cytoplasm, and contained numerous mitotic figures, some of which were atypical. The surrounding tissue showed a marked desmoplastic response, and, in areas, a prominent lymphocytic infiltrate. On the basis of the nodular configuration of the aggregates of malignant cells, and the appearances of the individual cells, a diagnosis of epithelioid sarcoma was made, despite the absence of areas of degeneration within the nests of cells.

Examination of tissue from the amputation specimen confirmed the diagnosis of epithelioid sarcoma. The characteristic microscopic features of this lesion—the nodular pattern, the acidophilia of the cytoplasm of the malignant cells, and the presence of central degeneration of many of the nodules—were all confirmed (Fig 2 and 3). The character of this latter degenerative process varied from frank necrosis to fibrosis and calcification. Many of the smaller tumor nodules appeared solid and showed little or no evidence of any degenerative change. Most of the tumor cells were arranged in discrete nodules, and a significant number of these showed the presence of a prominent lymphocytic infiltrate at the periphery. Where a marked desmoplastic response had been evoked, the margins of the neoplastic deposits were often ill-defined and the nodular pattern accordingly effaced.

Review of the slides originally identified as anaplastic squamous carcinoma and amelanotic malignant melanoma showed the microscopic appearances of epithelioid sarcoma (Fig 4 through 6).

COMMENT

Our patient's clinical course was that of tumor recurrence in the form of multiple nodules following a long asymptomatic period. Enzinger[1] found that recurrence usually occurred within six months after the initial surgery. Other authors state that the growth of this tumor is slow, although recurrences are frequent.[2] The presence of multiple nodules might suggest benign conditions such as sporotrichosis, clinically. Although no report has described annular plaques, such as occurred in our patient, Enzinger's only clinical illustration resembles this feature of our patient,[1] as does the description (not illustrated) of epithelioid sarcoma of the penis masquerading as Peyronie's disease.[12] This clinical appearance would therefore appear to be one of the characteristic lesions of epithelioid sarcoma.

Histologically, the occurrence of epithelioid cells in a nodular arrangement with central degeneration may mimic a benign granulomatous condition, particularly one of the palisading granulomas such as a granuloma annulare, necrobiosis lipoidica, or a rheumatoid nodule. Even when the malignant nature is recognized, it may be confused with other neoplasms such as malignant melanoma, synovial sarcoma, or poorly differentiated squamous carcinoma. The central degeneration is a typical feature, the diagnostic importance of which is emphasized in the literature, yet it may be absent in small nodules, as in the initial biopsy specimens of our patient. The diagnosis of epithelioid sarcoma may therefore have to be considered solely on the basis of the cellular morphological findings and configuration of the neoplastic mass.

The clinician's dilemma is not unlike that of the pathologist's in that the epithelioid sarcoma may both clinically and pathologically resemble a benign granulomatous condition. Enzinger, in fact, entitled this report "Epithelioid Sarcoma: A Sarcoma Simulating a Granuloma or a Carcinoma".[1] All 13 cases reported by Bryan et al[13] were misdiagnosed clinically.

A clinical awareness of the multifocal nodular or distinctive annular appearance of epithelioid sarcoma might enable the clinician to alert the pathologist to this possible diagnosis, thereby leading to adequate and prompt treatment.

Since this article was accepted for publication, we have seen a black woman, aged 43 years, referred from a distant area, with recurrent nodules and ulcers on the left wrist at the site of a tumor removed in October 1972. In view of the appearance of annular nodules with central ulceration (Fig 7), a clinical diagnosis of epithelioid sarcoma was made, which was confirmed histologically.

References

1. Enzinger FH: Epithelioid sarcoma: A sarcoma simulating a granuloma or a carcinoma. *Cancer* 26:1029-1041, 1970.
2. Fisher ER, Horvat B: The fibrocytic derivation of the so-called epithelioid sarcoma. *Cancer* 30:1074-1081, 1972.
3. Soule EH, Enriquez P: Atypical fibrous histiocytoma, malignant fibrous histiocytoma, malignant histiocytoma, and epithelioid sarcoma. *Cancer* 30:128-143, 1972.
4. Santiago H, Feinerman LK, Lattes R: Epithelioid sarcoma: A clinical and pathologic study of nine cases. *Hum Pathol* 3:133-147, 1972.
5. Gabbiani G, Fu YS, Kaye GI, et al: Epithelioid sarcoma: A light and electron microscopic study suggesting synovial origin. *Cancer* 30:486-499, 1972.
6. Heppenstall RB, Yvars MF, Chung SMK: Epithelioid sarcoma: two case reports. *J Bone Joint Surg* 54:802-806, 1972.
7. Nelson FR, Crawford BE: Epithelioid sarcoma: A case report. *J Bone Joint Surg* 54:798-801, 1972.
8. Piver MS, Tsukada Y, Barlow J: Epithelioid sarcoma of the vulva. *Obstet Gynecol* 40:839-842, 1972.
9. Jefferiss CD, Caldwell RA: Epithelioid sarcoma: Case report of a young musician's hand. *Hand* 6:208-210, 1974.
10. Lever WF, Lever GS: Tumors of fibrous tissues, in: *Histopathology of the Skin*. ed 5. Philadelphia, JB Lippincott Co, 1975, p 584.
11. Shelley WB: Epithelioid Sarcoma, in: *Consultations in Dermatology II*. Philadelphia, WB Saunders Co, 1974, p 70.
12. Moore SW, Wheeler JE, Hefter LG: Epithelioid sarcoma masquerading as Peyronie's disease. *Cancer* 35:1706-1710, 1975.
13. Bryan RS, Soule EH, Dobyns JH, et al: Primary epithelioid sarcoma of the hand and forearm. *J Bone Joint Surg* 56:458-465, 1974.

Schering

When it's all you want, it's all they get.



pure and simple

Chlor-Trimeton® 12mg.

brand of
chlorpheniramine maleate, USP
brand of
Repetabs® Tablets, repeat-action tablets

Available on prescription only.

Also available:
Chlor-Trimeton®
8 mg. Repetabs®
Injection 100 mg./ml.
and 10 mg./ml.

Copyright © 1977, Schering Corporation. All rights reserved.

SWW-9340

←→r the ne hell←→...

ACNAVEEN® BAR

Soothes and cleans sensitive skin, and helps bring their guards down...

Hiding their embarrassment compounds the misery. Incessant picking and rubbing of acne lesions often causes more irritation. Urge them to wash with soap-free ACNAVEEN® Bar, logical adjunctive therapy in whatever treatment you've chosen:

- 2% salicylic acid and 2% sulfur provide a peeling and drying effect.
- Aveeno Colloidal Oatmeal soothes the skin and reduces irritation.

ACNAVEEN® BAR: Special mild cleansing bar for acne.

Available in 3.5 oz. bars

Cooper Cooper Laboratories, Inc., Wayne, New Jersey 07470

...safe for your patients to use, ...effective and less traumatic than cryosurgery or curettage[1]

et remedies for warts are almost as ommon as warts themselves. How- ver, one specific formulation has gain clinically proven its value.

. B. Rees reported, *"My favorite wart emedy is . . . equal parts of salicylic cid and lactic acid in four parts of lexible collodion (Duofilm)".*[2]

Bunney and associates find the Duofilm ormula, used at home, at least as ffective as, and less traumatic than, ryotherapy and curettage.[1]

Arndt[3], in a double-blind controlled tudy of patients with multiple warts, onfirmed Bunney's findings.

Duofilm is safe and simple to use. pecial patient instruction pads and upplies of Duofilm for your treatment able are available on request.

Duofilm®

(Salicylic Acid, USP, 16.7% and Lactic Acid, USP, 16.7% in Flexible Collodion, USP)

for warts

omposition: Salicylic Acid, USP, 16.7% and Lactic Acid, USP, 6.7% in Flexible Collodion, USP.

dications: DUOFILM is indicated as a keratolytic agent for the re- oval of benign epithelial tumors such as common warts.

osage and Administration: Prior to the application of DUOFILM, ak the affected area in hot water for at least five minutes. Dry oroughly with a clean towel.

pply DUOFILM directly to the wart using the plastic applicator. Each op should be permitted to dry before re-application of the liquid. are should be taken to see that DUOFILM is not applied to the sur- unding skin. A Band-Aid® or similar bandage should then be plied lightly.

reatment should take place once daily and continue as directed by hysician.

ontraindications: Diabetics or patients with impaired blood circu- tion should not use DUOFILM. Do not use on moles, birthmarks or nusual warts with hair growing from them.

recautions: For external use only.

UOFILM is highly flammable and should be kept away from fire or ame. Keep bottle tightly capped when not in use. Store at con- olled room temperature.

spilled on mucous membranes or in eyes, flush with water, remove recipitated collodion, and flush with water for an additional 15 inutes.

eep this and all medication out of the reach of children.

ow Supplied: DUOFILM is available in ½ oz. bottles with plastic pplicators.

aution: Federal law prohibits dispensing without a prescription.

1. Bunney, M.H.; Nolan, M.W.; Williams, D.A.: An assessment of methods of treating viral warts by comparative treatment trials based on a standard design. *Brit. J. Derm.* **94**, 667, 1976.
2. Rees, R.B.: Post-graduate course in Dermatology, sponsored by Cleveland Clinic and U. of Cal., San Fran., Nov. 5-10, 1976, Maui, Hawaii.
3. Arndt, K.A.: Double-blind study of salicylic and lactic acid lotion in treating warts. Study on file at Stiefel Research Institute.

STIEFEL
Logical Dermatologicals since 1847

Stiefel Laboratories, Inc.,
Oak Hill, N.Y. 12460
Stiefel Laboratories (Canada) Ltd.,
St. Laurent, Quebec, Canada H4R 1E1

9-1085

Acne on back and shoulders—now within easy reach.

BUF BODY SCRUB provides "epidermabrasion"—the mechanical exfoliation of the outer layer of dead skin cells.

- thoroughly cleanses the skin and removes excess oil
- helps to loosen and remove comedones
- aids removal of coarse, rough skin of hyperkeratosis
- high patient acceptance of BUF-PUF documented by clinical studies

NEW BUF™ BODY SCRUB

A unique new product that features BUF-PUF® Nonmedicated Cleansing Sponge on a contoured, reusable handle.

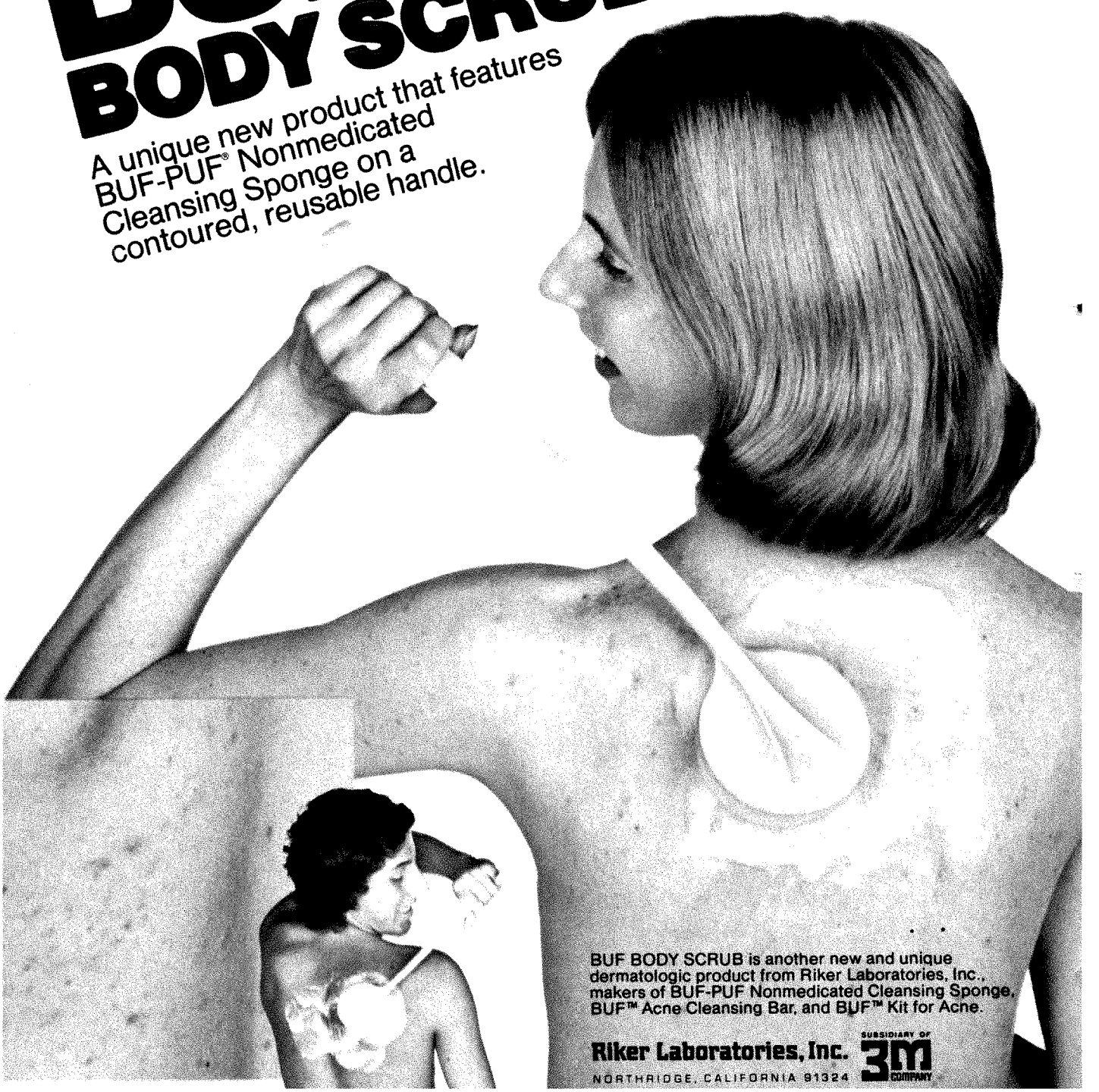

BUF BODY SCRUB is another new and unique dermatologic product from Riker Laboratories, Inc., makers of BUF-PUF Nonmedicated Cleansing Sponge, BUF™ Acne Cleansing Bar, and BUF™ Kit for Acne.

Riker Laboratories, Inc. SUBSIDIARY OF 3M COMPANY

NORTHRIDGE, CALIFORNIA 91324

Special Article

Choosing Dermatologic Instruction for Students in Family Practice

Richard M. Caplan, MD, Roger I. Ceilley, MD

• Sixty-three family practitioners responded to a special questionnaire designed to determine their judgment of what is most important to teach medical students and those residents headed toward careers in family practice. The ranking of emphases and specific diseases should be helpful to dermatologists responsible for the instruction.

(*Arch Dermatol* 113:1113-1115, 1977)

Deciding "what to teach" is a challenging problem for any conscientious teacher. For the dermatologist responsible for teaching cutaneous medicine to medical students and residents in nondermatologic disciplines, this problem may be compounded by the lack of personal experience with whatever is most important to the nondermatologist. Because of the current need for most academic institutions to foster careers and training efforts in primary care, dermatologic teachers should strive to prepare primary physicians for the cutaneous medicine they will ultimately practice.

Primary care is a concept with disputed definition, but *family practice* appears on all lists of "disciplines that provide primary care" and includes the largest number of practitioners. To help determine what objectives and content might be most suitable in the training of future family practitioners, a survey was conducted among family physicians attending a general refresher course for family physicians. This paper reports the findings and offers suggestions for planning the appropriate educational preparation for family physicians.

There is no generally accepted curriculum for all students of any given type, since circumstances and opinions are so varied among training centers. Even so, a general similarity exists within broad outlines, tempered by availability of time, space, personnel, case material, geography, and other local factors. Caplan and Solomon[1] have discussed educational objectives for dermatology and provided examples of many kinds that might be chosen. Yet it lies with the responsible teacher to identify his students' needs, which in turn are related to the learning sophistication, knowledge level, curricular obligations, and personal aspirations of the students. Further, any attempt at a universal educational prescription is muddled by what the instructor likes to teach, what the student likes and wants to learn, and what the public needs.

To approach the problem of what basic information should be taught medical students about ocular disorders, Spivey[2] conducted an extensive survey among practitioners and concluded that the collective opinion of nonophthalmologists was more appropriate in some particulars than the opinions of ophthalmologists. Academicians might offer justifications for modifying their approach and content away from the expressed desires of the learners, but the needs in actual practice or practice-to-be of their students should have high priority in guiding such decisions. Since no such information about student needs was known to us, we sought the opinion of one group that is a major educational target in most medical schools and teaching hospitals.

METHOD

A questionnaire was distributed to family physicians attending a refresher course for the family physician given at the University of Iowa in February 1975. The same instrument was distributed at a similar course given at the University of Oregon at about the same time.

The survey instrument asked the respondents to judge what they believed "most important to include in an educational program aimed at medical students

Accepted for publication July 23, 1976.

From the Department of Dermatology, University of Iowa College of Medicine, Iowa City.

Reprints not available.

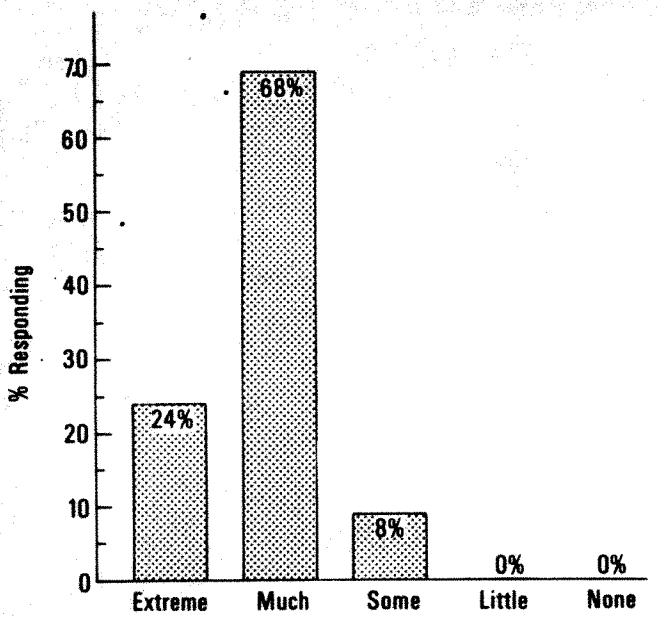

Fig 1.—Relative importance of skin problems in family practice.

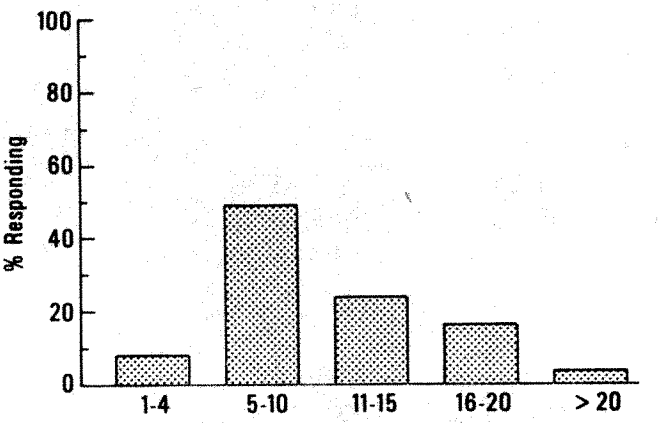

Fig 2.—Estimated percentage of family practice office visits that derive from cutaneous problems.

and residents headed toward careers in family practice." Not only were the respondents available to us, but they were practitioners whose presence at the refresher course was testimony to their concern for their own education and their patients' well being. Furthermore, those physicians had the experience to tell us what may be needed in day-to-day family practice.

The 63 respondents ranged from 5 to 45 years postgraduation from medical school. The great majority practiced in either Iowa or Oregon and most practiced in rural areas or small- to medium-sized cities.

The specific diseases mentioned in the questionnaire were derived largely from the list published by Caplan and Solomon.[1] That list had been derived from the collective wisdom of 99 dermatologists active in the Division of Education and Communication of the National Program for Dermatology. Our respondents were invited to list other conditions that they believed were important but that did not appear among the choices.

Additional questions sought an estimate of the relative importance of cutaneous problems in their practice, and their sense of priority about the general approach to instructional content.

The respondents were asked to assign a whole-number score of one to four to each item presented, with four representing the most important. The tally of scores for each item was determined in essentially the same manner that an academic grade-point is obtained: each value score was multiplied by the number of persons selecting it, all such products were summed, and the total was divided by the number responding. The final score (S) for each item is given by:

$$S = \frac{\Sigma N_1 + \Sigma 2N_2 + \Sigma 3N_3 + \Sigma 4N_4}{N}$$

where N is the total number responding on each item, and N_x is the number responding with each respective score of one to four.

RESULTS

The data from the 50 Iowa respondents and the 13 Oregon respondents were found to be so similar that the data were pooled. The numerical results from the combined respondents are shown beside the questionnaire items, arranged by decreasing score rather than the alphabetical sequence presented in the original questionnaire.

Each question invited additional suggestions from the respondent. A few verbal responses seemed to merit special consideration, and are listed beneath the numerical responses.

QUESTIONNAIRE RESPONSES

1. To what extent are skin problems an important part of family practice? (check one)
   a. Of extreme importance
   b. Of much importance
   c. Of some importance
   d. Of little importance
   e. Of no importance
   (See Fig 1)

2. Would you please estimate the percentage of office visits in your own practice that derive from cutaneous problems? (See Fig 2)

3. The following subject topics represent some *possibilities* for learning packages, which might consist of brief readings, audiotapes, and associated photographs or transparencies for projection. Please indicate your idea of the relative importance of including such a topic by ranking the items with a:
   1. Of too little importance–omit it
   2. Of some importance–include it if you have time and space
   3. Important–include
   4. Very important–a must

Score	Topic
3.71	Topically administered therapy
3.44	Discussion of virtues and hazards of over-the-counter products (soaps, shampoos, cosmetics, sunscreens, acne remedies, dermatitis remedies, etc)
3.34	Internally administered therapy
3.00	Principles of allergy and immunology as related to the skin
2.95	Percutaneous absorption
2.89	Basic dermatologic nomenclature
2.71	Eccrine glands and their activity
2.70	Sebaceous glands and their activity
2.53	The process of pigmentation
2.49	The process of keratinization
2.48	Brief presentation of cutaneous anatomy and physiology
2.00	Cutaneous microbiology

Additional suggestions deemed worthy of consideration by us include: Care of skin in summer and winter; external manifestations of sensitivity to foods, pollens, and drugs; and cutaneous surgical techniques.

4. Using the same rating system as in question 3, indicate your idea of how important it would be to include a discussion of the following diseases or disease groups.

Score	Disease or Disease Group
3.79	Contact dermatitis (allergic and irritant)
3.73	Premalignant lesions (actinic keratoses, leukoplakia, Paget disease, etc)
3.59	Eczema, atopic
3.57	Dermatophyte fungal infection
3.52	Basal cell carcinoma
3.51	Squamous cell carcinoma
3.49	Acne vulgaris
3.48	Stasis dermatitis and ulcer
3.41	Psoriasis
3.41	Verrucae
3.40	Urticaria
3.40	Erythema multiforme
3.40	Melanoma
3.38	Seborrheic dermatitis
3.38	Candidiasis
3.36	Nails, common disorders of
3.35	Pyoderma (includes impetigo, boils, cellulitis, erysipelas)
3.32	Herpes simplex
3.27	Herpes zoster
3.26	Erythema nodosum
3.25	Benign melanocytic nevi
3.24	Eczema, nummular
3.21	Viral exanthems
3.17	Tinea versicolor
3.15	Purpura
3.05	Seborrheic keratosis
3.03	Pityriasis rosea
3.00	Corns
2.98	Vitiligo
2.97	Photodermatitis
2.95	Acne rosacea
2.92	Hemangiomas
2.90	Alopecia (areata and male-pattern)
2.90	Syphilis
2.62	Mollusum contagiosum
2.60	Keloid
2.59	Ichthyosis
2.53	Drug eruptions
2.50	Milia

Additional suggestions deemed worthy of consideration by us include: miliaria; infestations; dry skin.

5. Using the same key, please indicate the importance, when discussing diseases in the list above, of initial factors:

Score	Factors
3.89	Diagnosis
3.87	Treatment
3.63	Differential diagnosis
3.46	Prognosis
3.32	Prevention
3.29	Cause
2.63	Pathogenesis

6. Other suggestions: (1) Provide clear statements of what should not be done; when to refer. (2) Use a problem-oriented approach. (3) Indicate how long it should take to resolve or improve specific diseases.

COMMENT

Medical educators should address the nation's health needs effectively and respond to public, professional, and governmental pressures for improvement in the quality and quantity of primary care service. Any dermatologist who teaches any level of medical student, primary care resident, primary care practitioner, or several types of practitioner-extenders, would be well-served to know the views of the intended learners. The instruction would become more welcome and valuable through the instructor's better knowledge of the practitioner's needs. Those needs, in turn, grow from the experience of actual clinical practice.

The questionnaire responses reported here were estimates and opinions, and were not data derived from audit of medical records or patients. Nonetheless, such estimates can provide useful guidelines for educational planning. The needs of trainees in other primary care disciplines (internal medicine, pediatrics, obstetrics and gynecology) cannot be safely inferred from this data derived from family physicians.

The traditional academician is likely to attempt to teach too much, because he is unwilling to label "relatively unimportant" certain topics of interest in his own research or practice. He is likely to give greater emphasis to basic science information or pathophysiology. Such emphasis is probably more appropriate at the level of medical students and dermatology residents. For nondermatologic residents and especially for practitioners, the emphasis on common problems and problem solving is what matters most. Diagnosis and treatment become paramount. A teacher may choose goals and content not of his student's liking, justifying to himself that "I know best what is important and what he should learn." Indeed, the right of a teacher to make such a judgement is a vital component of academic freedom. To be obliged to teach only prepackaged courses and explicit content mandated for all by some central educational authority, and thus exclude the variety and innovation of individual teachers who thoughtfully make carefully reasoned choices of content and method, would be disastrous to our educational system.

This study sought principally to help identify in what areas the teaching and learning of cutaneous medicine for family practice might be most effectively focused. How to teach most effectively and how to evaluate such effort are still other challenges for the conscientious teacher.

Frances Storrs, MD, administered the questionnaire at the University of Oregon.

References

1. Caplan R, Solomon L: Instructional objectives in dermatology. *Arch Dermatol* 104:345-351, 1971.

2. Spivey B: Ophthalmology for medical students: Content and comment. *Arch Ophthalmol* 84:368-375, 1970.

Acne illustrated by artist.

VECTRIN Capsules, 100 mg
(minocycline HCl capsules, USP)
Brief Summary of Prescribing Information

Indicated in severe acne as adjunctive therapy. Consult package insert for complete prescribing information.

Contraindication: Hypersensitivity to any tetracycline.

Warnings: When need for intensive treatment outweighs potential dangers, perform renal and liver function tests before and during therapy; also follow serum concentrations. In renal impairment, usual doses may lead to excessive accumulation and liver toxicity. Under such conditions, use lower total doses, and in prolonged therapy, determine serum levels. The use of tetracyclines during tooth development (last half of pregnancy, infancy and childhood to the age of 8 years) may cause permanent discoloration of the teeth (yellow-gray-brown). This is more common during long-term use but has been observed following repeated short-term courses. Enamel hypoplasia has also been reported. Tetracyclines, therefore, should not be used in this age group unless other drugs are not likely to be effective or are contraindicated. Photosensitivity manifested by an exaggerated sunburn reaction has been observed in some individuals taking tetracyclines. Advise patients apt to be exposed to direct sunlight or ultraviolet light that such reaction can occur, and discontinue treatment at first evidence of skin erythema. Studies with minocycline HCl indicated that photosensitivity did not occur. However, reports have been received. In patients with significantly impaired renal function, the antianabolic action of tetracycline may cause an increase in BUN leading to azotemia, hyperphosphatemia, and acidosis. **CNS side effects:** (light-headedness, dizziness, vertigo) have been reported, may disappear during therapy, and always disappear rapidly when drug is discontinued. Caution patients who experience these symptoms about driving vehicles or using hazardous machinery while taking this drug. **Pregnancy:** In animal studies, tetracyclines cross the placenta, are found in fetal tissues, and can have toxic effects on the developing fetus (often related to retardation of skeletal development). Embryotoxicity has been noted in animals treated early in pregnancy. The safety of minocycline HCl for use during pregnancy has not been established. **Newborns, infants, and children:** All tetracyclines form a stable calcium complex in any bone-forming tissue. Prematures, given oral doses of 25 mg/kg every six hours, demonstrated a decrease in fibula growth rate; reversible when drug was discontinued. Tetracyclines

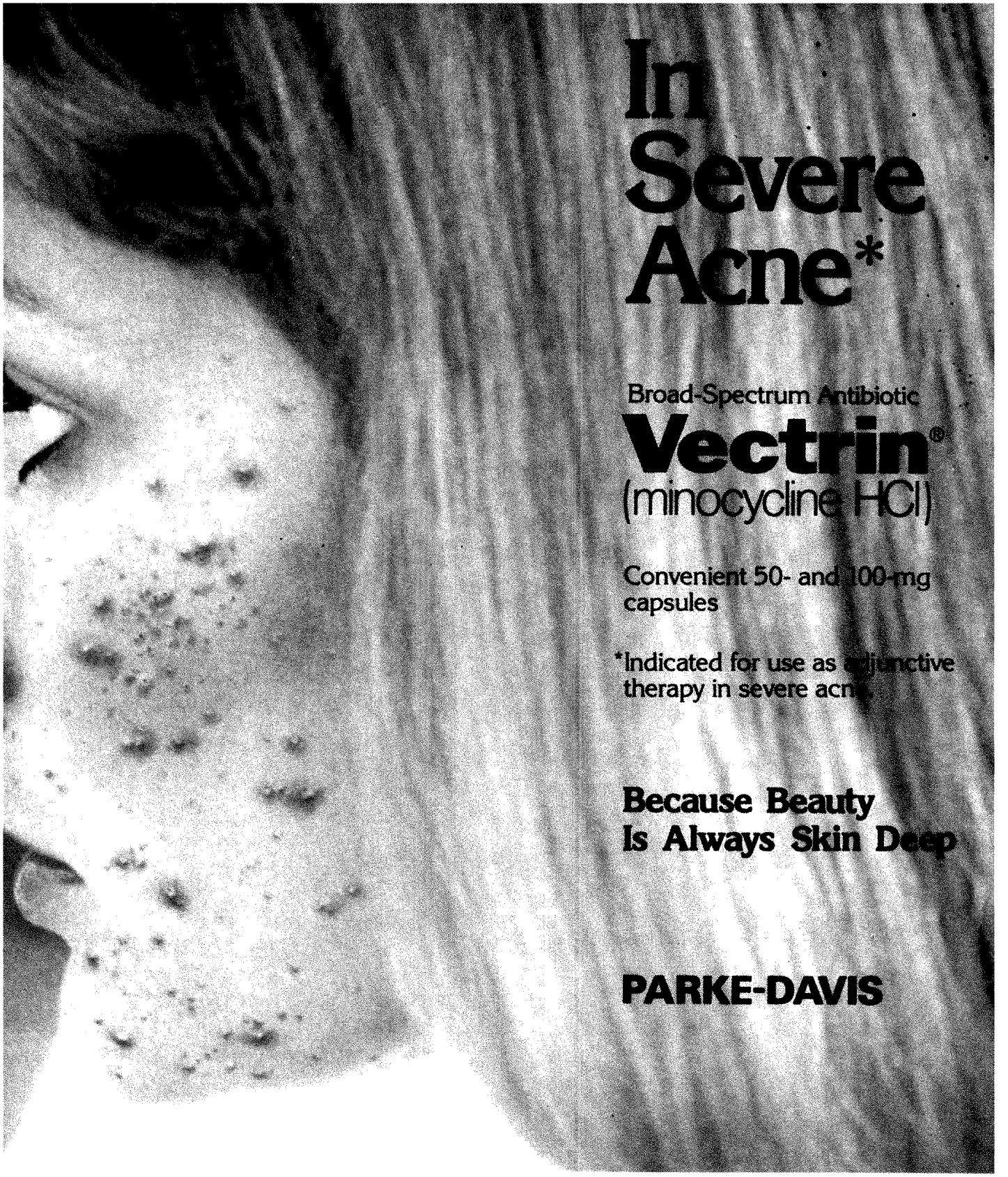
In Severe Acne*
Broad-Spectrum Antibiotic
Vectrin®
(minocycline HCl)
Convenient 50- and 100-mg capsules
*Indicated for use as adjunctive therapy in severe acne.
Because Beauty Is Always Skin Deep
PARKE-DAVIS

are present in the milk of lactating women who are taking a drug in this class.

Precautions: Use may result in overgrowth of non-susceptible organisms, including fungi. If superinfection occurs, antibiotics should be discontinued and appropriate therapy instituted. In venereal diseases when coexistent syphilis is suspected, darkfield examination should be done before treatment is started and blood serology repeated monthly for at least four months. Patients on anticoagulant therapy may require downward adjustment of such dosage. Test for organ system dysfunction (eg, renal, hepatic, and hemopoietic) in long-term use. Treat all group A beta-hemolytic streptococcal infections for at least 10 days. Avoid giving tetracycline in conjunction with penicillin.

Adverse Reactions: GI: Anorexia, nausea, vomiting, diarrhea, glossitis, dysphagia, enterocolitis, inflammatory lesions (with monilial overgrowth) in anogenital region. **Skin:** Maculopapular and erythematous rashes. Exfoliative dermatitis (uncommon). Photosensitivity is discussed above. (See Warnings.) **Renal toxicity:** Rise in BUN, dose-related. (See Warnings.) **Hypersensitivity reactions:** Urticaria, angioneurotic edema, anaphylaxis, anaphylactoid purpura, pericarditis, exacerbation of systemic lupus erythematosus. In young infants, bulging fontanels have been reported following full therapeutic dosage, disappearing rapidly when drug was discontinued. **Blood:** Hemolytic anemia, thrombocytopenia, neutropenia, eosinophilia. **CNS:** (See Warnings.) When given over prolonged periods, tetracyclines may produce brown-black microscopic discoloration of thyroid glands; no abnormalities of thyroid function studies are known to occur.

NOTE: Concomitant therapy: Antacids containing aluminum, calcium, or magnesium impair absorption; do not give to patients taking oral tetracycline. Studies to date indicate that absorption of VECTRIN (minocycline hydrochloride) is not notably influenced by foods and dairy products.

Full prescribing information available upon request.

PARKE, DAVIS & COMPANY
Detroit, Michigan 48232

Obviously, efficacy is foremost in your mind when you recommend a therapeutic shampoo. And efficacy, coupled with cosmetic acceptability, usually guarantees a successful therapeutic course.

That's why Head & Shoulders is so highly regarded in the treatment of dandruff.

Clinically effective

For years, Head & Shoulders has proved effective in the treatment of dandruff—whether for initial therapy or long-term control. And now, research shows that Head & Shoulders is effective in the treatment of seborrheic dermatitis.*

Cosmetically pleasing

Head & Shoulders lathers well, has a pleasant odor and appearance, and need not be left on the scalp for an extended period of time. Also, it leaves hair clean, manageable, and attractive.

Head & Shoulders®

You'll like it for its therapeutic benefits. Your patients will like it for its cosmetic appeal.

*Orentreich, N.: A clinical evaluation of two shampoos in the treatment of seborrheic dermatitis, J. Soc. Cosmet. Chem. 23:189 (March 3) 1972.

William B. Reed, MD
1924-1976

Bill Reed died unexpectedly on June 15, 1976, shortly before his 52nd birthday. He was a kind, generous physical and intellectual giant who spent much of his enormous energy and talent to further our specialty. He traveled widely, met unusual people, and made lasting friends. He had an uncanny knack for discerning the real from the fake, the innovative from the imitation, the fresh, forward thinker from the devious obstructionist. He delighted in discovering new young talent and helping those with interesting findings to bring it all together. He was harsh, opinionated, and vocal and a busybody. But more importantly he tied together the world of many thinking dermatologists and scientists through his personal communications system. He telephoned everywhere and at all hours. Once you learned his mumbled, half-sentence jargon, huge amounts of new information and ideas, as well as some opinions, were transmitted with each call or personal visit. He was constantly busy with a new research project or a new syndrome, or he was writing a paper or chapter on cutaneous genetic disorders. His broad experience, enormous intellect, and elephantine memory made his discussions of genetic problems at scientific meetings an awe-inspiring, educational experience. He prepared several "Bill Reed Horror Movies" that still prove to be diamond-in-the-rough teaching aids.

Bill was proud to be a dermatologist, proud to be a Norwegian of Pennsylvania Dutch extraction, and proud to have been trained at Columbia, Johns Hopkins and the Mayo Clinic. He also was proud of his friends, but he expected each of them to return his pride with excellence. When they did not match up he told them so in no uncertain terms. His father figure in dermatology was Louis Brunsting, and he was a disciple of the Paul O'Leary Mayo Clinic System. He spent much of his time at St Joseph's Hospital in Burbank, Calif, and enhanced the delivery of medical care there. At various times he was on the teaching staffs of most of the dermatology departments in southern California, most recently as a clinical professor of dermatology at the University of California at Irvine. He was an honorary or corresponding member of nine foreign societies. He published about 150 scientific papers in his short life, some of the best known of which concerned psoriasis and arthritis, ataxia, telangiectasia, melanomas and congenital nevi, xeroderma pigmentosum, and, of course, the Reed syndrome.

His private practice office, a small, converted house in downtown Burbank was a sight to behold it was always crowded, with people often waiting outside. Here he provided superb dermatological care. He was a father confessor to kids with acne; he knew he was considered an offbeat freak by many, and his compassion and understanding for the less fortunate was beautiful. They loved him as one who really could understand their problems, and they filled his office. He made house calls and transported patients to get proper appliances and to see experts. He even paid the expenses of some patients to consult experts in a different locality. His own medical fees were always minimal. He was the local dermatologist's expert in many areas.

He loved good music, especially operas. He often brought hard-to-get records to his foreign friends. He loved his niece and nephew, and he mostly loved humanity. None of his friends ever felt sorry for Bill, they truly admired and loved him for the so many wonderful things he stood for; Bill was himself, with no apologies. We will miss you Bill Reed, and only hope you are still the same, wherever you are.

WILLIAM L. EPSTEIN, MD
DENNY L. TUFFANELLI, MD
JOHN H. EPSTEIN, MD
SAN FRANCISCO

what's best for the care of dry, or premature aging or wrinkled skin... DUE TO EPIDERMAL DEHYDRATION?

PPLIED: 2 OZ. TUBES

WRITE FOR SAMPLES

DOAK PHARMACAL CO., INC. WESTBURY, N.Y. 1159

DISTRIBUTOR IN CANADA

HLA in Bullous Pemphigoid

A. Razzaque Ahmed, MD; Elias Cohen, PhD; Leslie E. Blumenson, PhD; Thomas T. Provost, MD

A possible genetic link has been suggested in several dermatologic diseases. An increased incidence of HLA-A10 and HLA-B13 has been reported in pemphigus vulgaris, HLA-B17 and HLA-B13 in psoriasis, and HLA-B5 in Behçet syndrome.[1] HLA-B8 has been reported in 70% to 88% of dermatitis herpetiformis cases and in 90% of adult celiac disease cases,[2] which is suggestive of a close association between these two diseases.

The purpose of this study was to determine the HLA phenotype frequencies in a group of white patients with bullous pemphigoid (BP).

Subjects and Methods

Nineteen white patients with BP were studied. All had typical clinical disease and subepidermal bullae and all demonstrated the presence of immunoglobulins and/or C3 along the basement membrane zone (BMZ) of peribullous skin, as previously described.[3]

HLA typing was performed by Amos microcytotoxicity tests[4] with the use of 70 anti-HLA antisera. Similar tests were performed on 60 controls matched for age, sex, race, and geographic area. Statistical analysis of the data was performed using χ^2 test and, when necessary, the Fisher exact test.[5]

From the Department of Dermatology, State University of New York at Buffalo, School of Medicine, Buffalo, NY (Drs Ahmed and Provost), and the Blood Bank Laboratory (Dr Cohen) and the Biostatistics Department (Dr Blumenson), Roswell Park Memorial Institute, Buffalo, NY. Dr Ahmed is now with the University of California at Los Angeles School of Medicine.

Reprint requests to Department of Dermatology, State University of New York at Buffalo, School of Medicine, 50 High St, Buffalo, NY 14203 (Dr Provost).

Results

No statistically significant increased incidence of HLA antigen was noted in patients with BP compared to the control group. The incidence of HLA-A3 was decreased among the patients, although the difference (5% vs 32%) was not statistically significant (Table). There was no correlation between HLA phenotypes and serum skin BMZ antibody titer. Three patients with IgD and IgE deposition on the BMZ had HLA-B12.

HLA Typing in Bullous Pemphigoid (BP)*

	No. (%) in 60 Controls	No. (%) in 19 BP Patients
HLA-A1	20	3
HLA-A2	50	5
HLA-A28	10	1
HLA-A3	32	5
HLA-A9	23	1
HLA-A23	2	0
HLA-A24	0	0
HLA-A10	12	2
HLA-Aw25	0	0
HLA-A26	0	0
HLA-A11	8	5
HLA-Aw33	5	5
HLA-A29	7	1
HLA-B5	15	1
HLA-Bw35	3	0
HLA-B7	25	1
HLA-Bw22	3	1
HLA-B27	10	2
HLA-B8	15	1
HLA-B12	35	3
HLA-B13	2	0
HLA-Bw40	22	2
HLA-B14	3	0
HLA-Bw15	7	2
HLA-Bw16	2	0
HLA-Bw17	17	5
HLA-B18	5	2
HLA-Bw21	0	0

*Since 28 antigens were surveyed, the probability level of the χ^2 test must be corrected to obtain the correct probability of obtaining a difference as large or larger (under the null hypothesis) as actually observed. This correction is obtained by multiplying the probability level by 28.

Comment

Histocompatible antigens present on the cell membrane of all nucleated cells are controlled by a single chromosomal region. In mice this region is termed the H2 locus and in man the HLA system. The HLA region is located on chromosome 6 and is composed of two loci termed A and B.[6]

In our study there was no statistically significant increase in the incidence of a specific HLA phenotype among 19 white patients with BP.

This study was supported in part by grant R01 AM 16593-03 from the National Institutes of Health, by grant CA-11987021 from the National Cancer Institute, and by the Juliet and Israel Cohen Memorial Research Fund.

References

1. Vladutiu AO, Rose NR: HL-A antigens with disease. *Immunogenetics* 1:305-328, 1974.
2. Katz SI, Falchuk ZM, Dahl NV, et al: HL-A-8 genetic link between dermatitis herpetiformis and gluten sensitive enteropathy. *J Clin Invest* 51:2977-2980, 1972.
3. Provost TT, Tomasi TB Jr: Immunopathology of bullous pemphigoid. *Clin Exp Immunol* 18:193-200, 1974.
4. Amos DB, Bashir R, Boyle W, et al: A simple microcytotoxicity test. *Transplantation* 7:220-223, 1969.
5. Snedecor GW, Cochran WG: *Statistical Methods*, ed 6. Ames, Iowa, Iowa State University Press, 1967.
6. Dausset J, Hors J: Some contributions of the HL-A complex to the genetics of human disease. *Transplant Rev* 22:44-73, 1975.

Cutaneous Myiasis Due to *Dermatobia hominis*

Lt Col E. Dale Everett, MC, USA; Lt Col Richard L. DeVillez, MC USA; Lt Col Charles W. Lewis, MC, USA

With the ease and frequency of worldwide travel, unfamiliar diseases are often encountered by the American physician. We would like to share two such cases that are infrequently reported in the United States.[1-3]

Report of Cases

Two middle-aged women traveled to Costa Rica in June 1976 on a three-week bird-watching expedition. During this time, they remained in good health, except for sustaining some insect bites. In early July, a few days after their return to the United States, one woman noted intense pruritus associated with small papules on the upper part of her back, and the other noted it on the proximal portion of her upper extremities. The papules gradually enlarged and formed nodules with small apertures. Both women were seen after two weeks of symptoms. One of the patients had extracted a "worm" from one of the lesions on her arm, which she brought with her (Fig 1). The other had applied a heavy cream to the lesion on her back. This latter patient had noticed considerable reduction in pruritus for about three days before being examined. One had seen a physician a few days earlier and had been given an antimicrobial agent for "infection."

Results of examination of the lesions disclosed erythematous, indurated, raised lesions that appeared to be healing. However, in one of the women a brightly erythematous nodule with an aperture was present. A small amount of seropurulent material was present, and a white structure could be seen to protrude and then disappear from the opening (Fig 2).

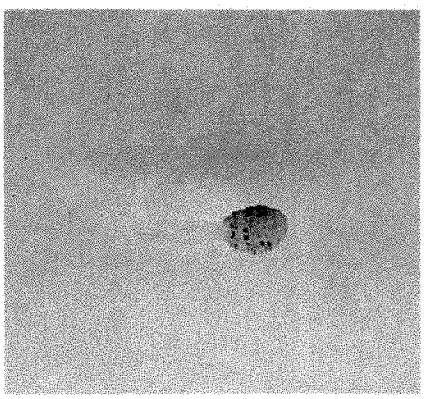

Fig 1.—Extracted larva of *Dermatobia hominis*. Concentric black rings around head are small barbs.

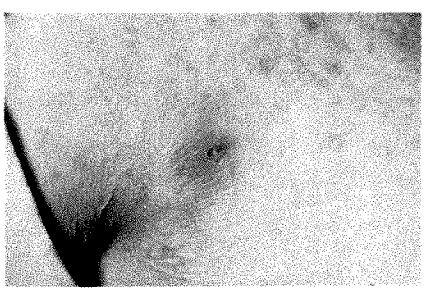

Fig 2.—Larval structure (white dot) protruding from lesion.

A biopsy specimen from the lesion on the back showed a superficial and deep polymorphous cellular infiltrate of histocytes, lymphocytes, and eosinophils, consistent with a benign reactive process due to parasitosis of the skin. The lesion with the active larva was incised, and the organism was removed.

Comment

Dermatobia hominis (human botfly, warble fly) is widely distributed throughout Central and South America. Man becomes an accidental host after being bitten by a mosquito that is carrying the eggs of the botfly on her abdomen.

Symptoms include pruritus, a gradually enlarging lesion, and pain. A seropurulent drainage from the punctum is common. If left alone, the larva gradually matures over a period of 50 to 100 days; it then exits from the host and drops to the ground where further maturation takes place. During the period of maturation in the host, the aperture in the skin remains open, allowing the organism to breathe.

Treatment has usually been incision and extraction of the larvae. Some may be squeezed out, but the barbed head makes this difficult. Occlusion of the punctum in the skin with pork fat has also been used, causing the larvae to migrate out of the skin to breathe.[1] The application of heavy cream to the lesion by one of our patients may have resulted in this phenomenon, since no organism was found.

Recognition of this unusual, but easily treated, disease is important. It allays the anxiety of the patient and, in one of our cases, would have saved the exposure to and expense of an antimicrobial agent.

References

1. Ruch DM: Botfly myiasis. *Arch Dermatol* 96:677-680, 1967.
2. Katz SI, Taylor R: Cutaneous myiasis. *South Med J* 64:759-760, 1971.
3. Iannini PB, Brandt D, LaForce FM: Furuncular myiasis. *JAMA* 233:1375-1376, 1975.

From the Infectious Disease Service, Brooke Army Medical Center, Fort Sam Houston, Tex.
Reprint requests to Infectious Disease Service, Brooke Army Medical Center, Fort Sam Houston, TX 78234 (Dr Everett).

Skin Eruption Caused by Ethambutol

Jagjit S. Pasricha, MD, PhD, Amrinder J. Kanwar, MD

Of all the drugs commonly used for the treatment of tuberculosis, streptomycin sulfate, isoniazid (isonicotinic acid hydrazide), aminosalicylic acid, and thiosemicarbazone are well known to produce skin eruptions,[1] but those due to ethambutol hydrochloride have been referred to only twice in the literature, to our knowledge. Jesiotr[2] reported one case of purpura due to ethambutol, while Kauppinen[3] listed another case without specifying the nature of the cutaneous eruption. In neither case, was the eruption confirmed to be caused by ethambutol. Enquiries from some of the pharmaceutical firms marketing this drug indicated that skin eruptions due to ethambutol have not been reported (Cyanamid India Ltd, June 30, 1976, and Fenochem Laboratories, July 8, 1976, written communications). We are reporting a patient who devel-

From the Department of Dermatology and Venereology, All India Institute of Medical Sciences, New Delhi.
Reprint requests to Department of Dermatology and Venereology, All India Institute of Medical Sciences, New Delhi-110016, India (Dr Pasricha).

oped a generalized erythematous macular and papular eruption that was later confirmed by the provocation test to be caused by ethambutol. This is important because ethambutol is a first-line antitubercular drug in some countries, and it has been reported to be remarkably free of side effects in humans.

Report of a Case

A 23-year-old woman with pulmonary tuberculosis was being treated with streptomycin injections, isoniazid, and aminosalicylate sodium. On Nov 9, 1975, she started having palpitation and tremors, for which treatment with streptomycin was stopped. On Nov 14, she received ethambutol and diphenhydramine hydrochloride, but two days later she developed a high fever, for which trimethoprim, sulphamethoxazole, and acetaminophen were given. On Nov 21, treatment with trimethoprim and sulphamethoxazole was stopped, and she was given promethazine hydrochloride. On Nov 22, she was given chloroquine in addition to ethambutol, isoniazid, aminosalicylate sodium, acetaminophen, and diphenhydramine. The next day she noticed the appearance of erythematous macular and papular lesions on her body, which soon became generalized. Treatment with all of the drugs was stopped. On Dec 1, she developed jaundice, for which she was given an injection of dexamethasone, cyproheptadine hydrochloride, and an antacid; she was referred to the hospital.

At the time of admission, she had diffuse erythema and scaling over the body with a few erythematous papules on the face and trunk. She was afebrile. She was treated with 40 mg of prednisolone daily. The skin lesions and jaundice cleared completely within two weeks.

Provocation Test

When treatment with corticosteroids had been withdrawn and the patient was free from all the lesions, provocation tests were undertaken with the drugs to find out the actual cause of the skin eruption. On Dec 23, she was given streptomycin sulfate (0.5 gm, intramuscularly), but there was no reaction. On the next day, she was given streptomycin sulfate (1.0 gm) without adverse effects. Since then she continued to receive streptomycin sulfate (1.0 gm) daily. On Dec 26, she was orally administered 500 mg of ethambutol hydrochloride. Within ten hours, the patient developed pruritic and erythematous papular lesions over the face and trunk. The eruption was treated with 20 mg of prednisolone daily. When the lesions subsided, the prednisolone was also tapered off. Subsequently, she was tested with isoniazid (50, 100, and 300 mg, respectively) on three consecutive days. She did not develop any reaction and therefore received streptomycin and isoniazid.

Comment

Allergic cutaneous eruptions can be caused by almost any drug, but some drugs produce allergic reactions more commonly than others. It is often presumed that the drug given last or the one that is known to produce such reactions most frequently, is the drug responsible for the reaction. Many times, as in our patient, this is not so. In an individual patient, any drug can be responsible for the reaction, and, therefore, it is always preferable to confirm the cause of the eruption.

At present, the most reliable method of discerning which drug is responsible for a skin eruption is the provocation method.[3] Of course, provocation must be avoided if the drug reaction is anaphylactoid in nature. Also, it may not be necessary if alternative drugs are available. However, the procedure is quite safe when the eruption is not of a severe or life-threatening nature.

Nonproprietary Names and Trademarks of Drugs

Ethambutol hydrochloride—*Myambutol.*
Trimethoprim—*Syraprim.*

References

1. Levantine A, Almeyda J: Cutaneous reactions to antituberculous drugs. *Br J Dermatol* 86:651-655, 1972.
2. Jesiotr M: Ethambutol in the treatment of 26 patients with chronic active pulmonary tuberculosis. *Tubercle* 50:54-55, 1969.
3. Kauppinen K: Cutaneous reactions to drugs with special reference to severe bullous mucocutaneous eruptions and sulphonamides. *Acta Derm Venereol Suppl* 68:1-89, 1972.

Hair Follicle Involvement in Bullous Pemphigoid

Thomas F. Downham II, MD, Thomas A. Chapel, MD

Immunofluorescence of biopsy specimens from patients with bullous pemphigoid almost invariably demonstrates localized immunoglobulins at the dermoepidermal junction adjacent to bullous lesions and in skin. Indirect immunofluorescence of serum samples from patients with bullous pemphigoid has demonstrated circulating antibodies localized to the basement membrane zone. Direct immunofluorescence has revealed IgG localized to the basement membrane zone. Indirect and direct complement staining methods have shown complement fixed to the basement membrane zone.

We report a case of bullous pemphigoid to emphasize that deep dermal hair follicles also may have localized immunoglobulins around the outer root sheath. This finding can confirm a diagnosis of bullous pemphigoid and the more typical involvement at the dermal-epidermal junction.

From the Department of Dermatology and Syphilology, Wayne State University, Detroit.
Reprint requests to Department of Dermatology and Syphilology, Scott Hall, 540 E Canfield, Detroit, MI 48201 (Dr Downham).

Report of a Case

An 80-year-old woman with adult onset diabetes and arteriosclerotic heart disease developed vesicles on her neck. Mildly pruritic vesicles and bullae later appeared on the extremities, trunk, and oral cavity.

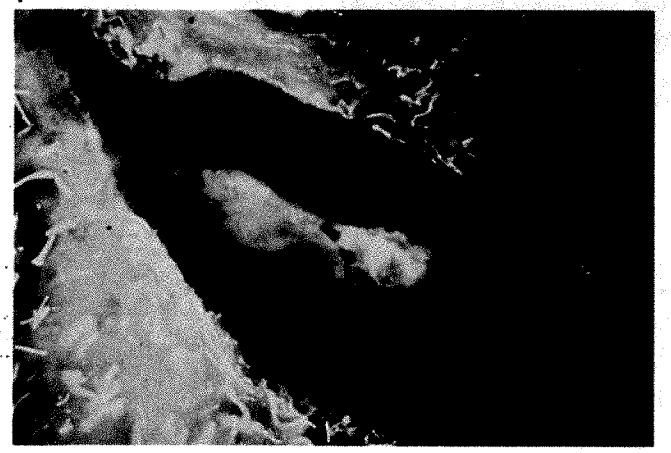

Fig 1.—Control slide of deep dermal hair follicle showing no immunofluorescence around hair follicle epithelium (×200).

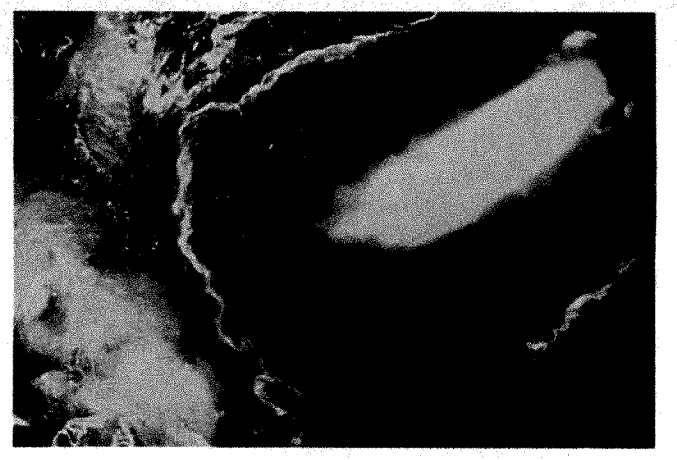

Fig 2.—Deposition of IgG is indicated by irregular fluorescent "band" around hair follicle epithelium (×200).

Biopsy findings were compatible with bullous pemphigoid.

Immunofluorescence studies showed deposition of IgG at the dermoepidermal junction adjacent to the bullous lesion and around the hair follicle epithelium of deep dermal hair follicles (Fig 1 and 2).

The patient was treated orally with prednisone, but aggravation of her diabetes forced discontinuation of the drug. Courses of methotrexate, cyclophosphamide (cytoxan), and prednisone were used subsequently, but exacerbations of her pemphigoid necessitated four hospitalizations during the next 17 months.

She was readmitted to the hospital for the fifth time, and was started on a regimen of 80 mg of prednisone every morning, insulin zinc suspension (Lente Insulin) on a sliding scale, hydroxyzine hydrochloride (25 mg three times daily), nystatin oral suspension (100,000 units four times daily), and 0.5% gentian violet to denuded blisters. Cyclophosphamide, 25 mg twice a day, was later added because of a poor therapeutic response.

Despite therapy new lesions appeared, and old lesions were slow to reepithelialize. The patient subsequently developed bilateral bronchopneumonia with septicemia, rectal bleeding, and congestive heart failure, and died.

Comment

According to Pinkus and Mehregan, the adult hair follicle is surrounded by two layers of optically different connective tissue: the dense fibrous root sheath and the hyaline membrane between ectodermal and mesodermal components. The hair follicle is surrounded also by an intricate net of elastic fibers that are more prominent in the area of the isthmus or middermal portion.[1]

Major studies using indirect immunofluorescence testing for specificity of bullous pemphigoid antigen where hair follicle epithelium was used as a substrate failed to mention the problems of autofluorescence of the hair follicle.[2,3] Burnham and Fine[4] and Rodrigue[5] emphasized the problem encountered when using human hairy skin for the detection of circulating bullous pemphigoid antibody, and stressed that the brightly fluorescent hair follicle connective tissue sheath had to be differentiated from the bullous pemphigoid "band." Therefore, use of hairy skin for indirect immunofluorescence of bullous pemphigoid sera should be approached with caution. Familiarization with the normal microanatomy of the pilary complex is essential.

Burnham and Weinberger[6] recently reported that patients with bullous pemphigoid and cicatricial pemphigoid almost invaribly demonstrate an immunofluoresent band of localized immunoglobulin at the dermoepidermal junction in skin and adjacent bullous lesions. A band around only deep dermal hair follicles in inflammatory lesions may also be present. Hair follicle involvement in bullous pemphigoid, may be as confirmatory as the band at the dermoepidermal junction, especially if the clinical manifestation is plaque-type bullous pemphigoid in contrast to the presence of bullous lesions.[6]

With direct immunofluorescence we have found that irregular fluorescent staining of the area around the follicle epithelium in deep dermal hair follicles was specific, while very regular linear bright-green fluorescence observed around the hair follicle was nonspecific. This irregular fluorescent staining is specific because it was not present in unstained controls.

This study was supported in part by the Detroit General Hospital Research Corporation and National Institutes of Health grant RR0534.

References

1. Pinkus H, Mehregan AH: *A Guide to Dermatohistopathology*, ed 2, New York, Appleton-Century Crofts, 1976, pp 33-36.

2. Chorzelski TP, Beutner EH: Factors contributing to occasional failures in laboratory diagnosis of bullous pemphigoid by indirect immunofluorescence. *Br J Dermatol* 86:111, 1972.

3. Wick G, Beutner EH: Quantitative studies of immunofluorescent staining: III. Comparison of different antigens in an indirect immunofluorescent staining system for human IgG, using the basement zone antibodies of bullous pemphigoid. *Immunology* 16:149, 1967.

4. Burnham TK, Fine G: Indirect cutaneous immunofluorescence. *Arch Dermatol* 105:52-58, 1972.

5. Rodrigue B: *Factors Influencing the Demonstration of Circulating Antibodies in Bullous Pemphigoid*, thesis. Wayne State University Graduate School, Detroit, 1972.

6. Burnham TK, Weinberger GI: False-negative immunofluorescent "band" in lesions of bullous and cicatricial pemphigoid. Read before the annual convention American Medical Association, Dallas, July 29, 1976.



"Adolescents especially, may suffer severe loss of self-esteem in our appearance-conscious society as a result of their acne. Some may be more seriously affected emotionally than others and withdraw from normal social interaction."[1]

Help Prevent Both Psychic...And Physical Scarring!

BENZAGEL®

(5% or 10% benzoyl peroxide, 6% polyoxyethylene lauryl ether)

and your counselling are BASIC to Successful Topical Therapy

"Results...Subjective and objective clinical results with this form of therapy were impressive. A rapid improvement could be seen within two weeks...Cysts, pustules and papules decreased in numbers, with a simultaneous reduction of accompanying inflammation. The distinct decline of oily conditions was dramatic."[2]

5 BENZAGEL® ACNE GEL & 10 BENZAGEL® ACNE GEL

Description: 5% or 10% benzoyl peroxide, 6% polyoxyethylene lauryl ether and 40% alcohol in an astringent gel containing colloidal magnesium aluminum silicate, hydroxypropyl methylcellulose, citric acid, fragrance and purified water.

Action: Provides drying, desquamative and antiseptic activity.

Indication: An aid in the treatment of acne.

Dosage and Administration: Wash affected areas prior to application. Apply once or more daily or as directed by physician.

Contraindications: Should not be used by patients having known sensitivity to either benzoyl peroxide or polyoxyethylene lauryl ether.

Precautions: For External Use Only. Not for ophthalmic use. Keep away from eyes and mucosae. Very fair individuals should begin with a single application at bedtime allowing overnight medication. May bleach colored fabrics. Keep this and all other medications out of the reach of children.

Caution: Federal law prohibits dispensing without prescription.

How Supplied: Plastic tubes, 1½ oz. and 3 oz.

REFERENCES:

1. Reisner, R.: The Rational Therapy of Acne, Cutis, Vol. 17, March, 1976, pg. 528.
2. Kuflik, E.: Benzoyl Peroxide Gel in Acne Therapy, Cutis, Vol. 17, January, 1976, pg. 175-177.

Dermik

Dermik Laboratories, Inc.
Fort Washington, Pa. U.S.A. 19034

The seven most important reasons to prescribe a topical antifungal. Right at your fingertips.

1 It is effective against the most prevalent fungal pathogens. MicaTin brand miconazole nitrate 2% offers exceptional effectiveness against the most difficult-to-treat pathogen—*Trichophyton rubrum*, and is equally effective against *Trichophyton mentagrophytes, Epidermophyton floccosum, Candida albicans* and *Malassezia furfur.*

2 It clears the most common fungal infections. MicaTin provides outstanding clinical and mycological efficacy in tinea pedis,* tinea corporis* and tinea cruris* as well as candidiasis and tinea versicolor.

3 It relieves symptoms quickly. Within 72 hours for the majority of patients. Within 1 to 2 weeks for virtually all patients.

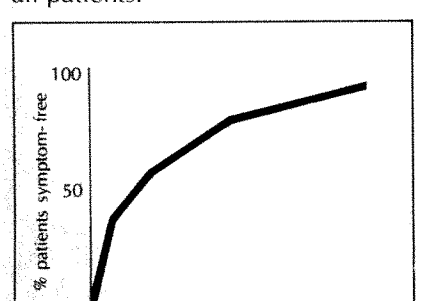

4 It demonstrates effectiveness in extensive studies. Clinical studies† demonstrate the outstanding success rate of MicaTin in the treatment of tinea pedis, tinea corporis and tinea cruris, when used with the recommended dosage of twice daily for one month. At the end of therapy, 88—94% of the patients were clinically clear.

The clinical studies of patients with candidiasis and tinea versicolor are equally impressive. Nine out of ten patients with candidiasis or tinea versicolor were clinically and mycologically clear within two weeks—the recommended duration of treatment.

Pathogen	Infection	Conversion KOH	Conversion Culture	Clinical Clearance or Improvement
Trichophyton rubrum	Tinea pedis	82%	86%	88%
Trichophyton mentagrophytes / *Epidermophyton floccosum*	Tinea corporis / Tinea cruris	93%	90%	94%
Candida albicans	Candidiasis†	92%	86%	88%
Malassezia furfur	Tinea versicolor	89%	—	92%

5 Its low relapse rate promises an outstanding chance of cure. To prove how effective MicaTin really is in keeping fungal infections clear, we evaluated these same patients one month later (median).† Of the 121 patients who were clear of tinea pedis, tinea corporis and tinea cruris at the end of treatment *and* were available for follow-up, 92% showed no clinical or mycological recurrence of the original infection.

And of the 34 patients cleared of cutaneous candidiasis *and* available for follow-up, 91% were still clear two weeks later (median).

6 It has a low incidence of side effects. Reports of "burning" sensation, irritation and maceration with MicaTin have been few and isolated. Naturally, it should not be used in patients with known hypersensitivity to any of its ingredients.

7 It is economically priced. The retail price of MicaTin is usually lower than that of other prescription antifungals.

Introducing new
MicaTin Lotion
brand miconazole nitrate 2%
12 ml. and 30 ml. bottles

MicaTin cream
brand miconazole nitrate 2%
new 85 g. (3 oz.) tube
and familiar 1 oz. and 15 g. sizes

Description: MicaTin brand miconazole nitrate cream 2% and lotion 2% each contain miconazole nitrate‡ 2%, formulated into a water miscible base consisting of pegoxol 7 stearate, peglicol 5 oleate, mineral oil, benzoic acid, and butylated hydroxyanisole.

Actions: Miconazole nitrate is a synthetic antifungal agent which inhibits the growth of the common dermatophytes, *Trichophyton rubrum, Trichophyton mentagrophytes,* and *Epidermophyton floccosum,* the yeast-like fungus, *Candida albicans,* and the organism responsible for tinea versicolor *(Malassezia furfur).*

Indications: For topical application in the treatment of tinea pedis (athlete's foot), tinea cruris, and tinea corporis caused by *Trichophyton rubrum, Trichophyton mentagrophytes,* and *Epidermophyton floccosum,* in the treatment of cutaneous candidiasis (moniliasis), and in the treatment of tinea versicolor.

Contraindications: MicaTin has no known contraindications.

Precautions: If a reaction suggesting sensitivity or chemical irritation should occur, use of the medication should be discontinued.

For external use only. Avoid introduction of MicaTin brand miconazole nitrate cream 2% and lotion 2% into the eyes.

Adverse Reactions: There have been isolated reports of irritation, burning, and maceration associated with application of MicaTin.

Dosage and Administration: Sufficient MicaTin cream should be applied to cover affected areas twice daily (morning and evening) in patients with tinea pedis, tinea cruris, tinea corporis, and cutaneous candidiasis and once daily in patients with tinea versicolor. It is preferable to use MicaTin lotion in intertriginous areas; if the cream is used, it should be applied sparingly and smoothed in well to avoid maceration effects.

Early relief of pruritus (first week) and early clinical improvement (one to two weeks) have been seen in treatment of infections caused by common dermatophytes. Even though clinical improvement may be seen fairly soon after treatment is begun, *Candida* infections should be treated for two weeks and dermatophyte infections for one month in order to reduce the possibility of recurrence. If a patient shows no clinical improvement after a month of treatment, the diagnosis should be redetermined. Patients with tinea versicolor usually exhibit clinical and mycological clearing after two weeks of treatment.

How Supplied: MicaTin brand cream 2% containing miconazole nitrate at 2% strength is supplied in 1 oz., 15 g., and 3 oz. tubes. MicaTin brand lotion 2% containing miconazole nitrate at 2% strength is supplied in polyethylene squeeze bottles in quantities of 12 and 30 ml.

*When infecting organisms are *Trichophyton rubrum, Trichophyton mentagrophytes* and *Epidermophyton floccosum.*

†Data for tinea pedis is based on 4 weeks' therapy in 138 patients; for tinea cruris and tinea corporis—4 weeks' therapy in 50 patients; for tinea versicolor—2 weeks' therapy in 38 patients; for candidiasis—2 weeks' therapy in 23 patients and 4 weeks' therapy in 20 patients. (There was no significant difference in effectiveness between the two candidiasis groups.) Data on file, Dermatological Division, Johnson & Johnson.

‡Chemical name: 1-[2,4-dichloro-β-[(2,4-dichlorobenzyl) oxy] phenethyl] imidazole mononitrate.

An ethical specific from the Dermatological Division of

Johnson & Johnson

New Brunswick, New Jersey 08903

© Johnson & Johnson 1977

MicaTin Cream/Lotion

BRAND miconazole nitrate 2%

It all adds up to confidence.

Letters to the Editor

Treatment of Lentigo Maligna

To the Editor.—A potentially valuable lesson can be gleaned from the experience of Kopf and coworkers[1] in the radiotherapy of lentigo maligna. One patient (case 14) in their series developed regional lymph node metastases from a lesion in which an incisional (punch) biopsy specimen showed only noninvasive lentigo maligna. This fact adds weight to the argument advanced by many that, when possible, complete but conservative excision of the lesion should be performed, not only to achieve accurate microstaging, but also to reduce the likelihood of recurrence, so commonly observed after ablative therapy. While the authors rightfully suggest that the primary tumor might have shown dermal invasion had multiple biopsy specimens been taken, they subsequently imply that the absence of clinically obvious papular or nodular components argues against such a possibility.

In tracing the origin of this oft-repeated axiom that a melanotic freckle without palpable nodularity is likely benign (ie, noninvasive), we must return to 1894, when Jonathan Hutchinson first described a small series of patients with lentigo melanosis.[2] Understandably, little was known of the histopathologic evolution of the disease at that time. Aided by the eloquent work of McGovern et al[3] and Clark et al[4] within the past decade, our understanding of the biologic behavior of melanoma has blossomed. If one examines its vertical growth phase, one finds that the earliest level of dermal invasion, level 2, displays a range of thickness from less than 0.3 to greater than 1.0 mm.[5] Surely, not all of the more superficially invasive lesions in this group are papular or nodular. This point is underscored by Clark and Mihm, who emphasize that "although lentigo maligna melanoma has characteristically raised areas, we have observed lesions that clinically appeared to be lentigo maligna but histologically were found to have definite foci of invasion. This flat variant of lentigo maligna (sic) that is only diagnosable histologically must be included in the differential diagnosis of these flat pigmented lesions."[6] Indeed, as evidenced by clinical data from patients with superficial spreading and lentigo maligna melanoma, flatness is far from a reliable clinical marker of benignancy, particularly in the earlier stages of invasion. According to unpublished data from the Melanoma Clinical Cooperative Group, absence of clinical elevation was a feature of 32 of 320 superficial spreading melanoma (10%), 3 of 17 lentigo maligna melanoma (18%), 18 of 74 all level 2 melanoma (24%), 15 of 63 level 2 superficial spreading melanoma (24%), and 2 of 3 level 2 lentigo maligna melanoma (67%).

To invoke the shibboleths of 80 years ago as a guide for the treatment of a disease with such grave potential leaves much to be desired. Until larger numbers are available for review, I believe that whenever feasible, all Hutchinson's freckles (especially including those without a palpably or visibly elevated component) should be subjected to surgical excision, subserial sectioning, and microscopic examination to determine if invasion has indeed supervened. As the authors suggest, the Melanoma Clinical Cooperative Group could be instrumental in providing the answers to this and other questions regarding the clinical expression of this problematic disease, particularly as it relates to its natural history and response to therapy.

A final note: In abandoning the Miescher technique of x-ray therapy in this setting, the authors express interest in the reports of other therapeutic modalities. Litwin and coworkers[7] have previously reported their experience with topical 5% fluorouracil (5-fluorouracil) in three patients with lentigo maligna. Interestingly, two of the patients had melanomas excised from within the melanotic freckle, one having developed after cessation of therapy. Since that time, all have remained free of disease for periods of up to 66 months postherapy, while an additional two patients similarly treated are also without recurrence (MS Litwin, oral communication, July 1976). While this modality may hold promise for effecting durable remissions in lentigo maligna, it is difficult at present to underwrite its routine use, when it appears that the very diagnosis on which its success rests, cannot , short of total excision, be made with reasonable surety.

MICHAEL A. GROMET, MD
San Francisco

1. Kopf AW, Bart RS, Gladstein AH: Treatment of melanotic freckle with x-rays. *Arch Dermatol* 112:801-807, 1976.
2. Hutchinson J: Lentigo-melanosis. *Arch Surg* (London) 5:253-256, 1893-1894.
3. McGovern VJ, Mihm MC, Bailly C, et al: The classification of malignant melanoma and its histologic reporting. *Cancer* 32:1446-1457, 1973.
4. Clark WH, Ainsworth AM, Bernardino EA, et al: The developmental biology of primary human malignant melanomas. *Semin Oncol* 2:83-103, 1975.
5. Wanebo HJ, Fortner JG, Woodruff J, et al: Selection of the optimum surgical treatment of stage I melanoma by depth of microinvasion. *Ann Surg* 182:302-315, 1975.
6. Clark WH, Mihm MC: Neoplasms of the melanocyte, in Fitzpatrick TB (ed): *Dermatology in General Medicine*. New York, McGraw-Hill Book Co, 1971, pp 491-511.
7. Litwin MS, Krementz ET, Mansell PW, et al: Topical chemotherapy of lentigo maligna with 5-fluorouracil. *Cancer* 35:721-733, 1975.

Treatment for Acne

To the Editor.—I must respond to the recent debate concerning the use of clindamycin in the treatment of moderately severe acne. For the past two years, I have been treating a number of patients with moderately severe acne resistant to tetracycline, minocycline, and various topical agents, with lincomycin hydrochloride monohydrate (Lincocin) (300 to 450 mg intramuscularly) at intervals of three to four weeks with improvement noted by both the patient and the doctor by the second or third injection. To date, there have been no side effects. I have also injected cystic acne lesions with triamcinolone hexacetonide (Aristospan) (5 mg/ml), diluted equal parts with lincomycin hydrochloride monohydrate with satisfactory resolution

of lesions and again no side effects. For many patients who have had months of painful acne nodules, lincomycin hydrochloride monohydrate has brought welcome relief. Before we throw out a useful treatment, perhaps a change in the method of administration may be all that is needed.

INA LEVENSON, MD
Milwaukee

Simultaneous Occurrence of Goodpasture's Syndrome and Follicular Mucinosis

To the Editor.—Both Goodpasture's syndrome and follicular mucinosis are uncommon or even rare conditions, both of obscure cause. We recently had the opportunity to study a patient with both conditions.

Report of a Case.—In July 1974, a 12-year-old girl developed hemoptysis and subsequently hematuria. She was hospitalized and thoroughly examined, and the diagnosis of Goodpasture's syndrome was confirmed by characteristic routine and immunofluorescence findings on lung and renal biopsy specimens, as well as by positive circulating antiglomerular basement membrane antibodies. She was treated with high doses of prednisone (60 to 100 mg daily), azathioprine (Imuran) (100 mg daily), as well as methyldopa (Aldomet), hydralazine hydrochloride, furosemide (Lasix), and potassium chloride. She did well, except for seizures due to hypertensive encephalopathy, and her prednisone was gradually tapered. In December, she developed a follicular eruption on her forehead and cheeks, which was believed to be steroid acne. This was treated with tretinoin (Retin-A) cream from April 1975 to June 1976. The treatment provided no relief, and the patient sought further dermatologic treatment in June. At that time she had innumerable firm, follicular papules, and only few comedones, over her forehead and cheeks. A biopsy specimen of a papule showed changes typical of follicular mucinosis. Direct immunofluorescence staining performed on an adjacent papule was entirely negative. By September the prednisone had been discontinued, while the other medications remained the same. The rash had almost entirely cleared by this time without any specific treatment.

Comment.—Goodpasture's syndrome is uncommon, and is said to have no cutaneous manifestations,[1] although a faint macular rash has been described.[2] In general, however, the patients are quite ill, and it is likely that all but the most obvious cutaneous manifestations would be ignored by patient and physician alike. Furthermore, as in our case, a follicular eruption on the face of a patient receiving steroids would probably be called steroid acne, without further investigation.

While the simultaneous occurrence of Goodpasture's syndrome and follicular mucinosis is probably coincidental, clinicians should be made aware of this association so that it can be looked for in future patients with Goodpasture's syndrome, as well as in other immunosuppressed patients who might otherwise be thought to have steroid acne. While the cause of follicular mucinosis is unknown, its occasional association with reticuloses, especially mycosis fungoides,[3] raises the question of the role of abnormal antigens, immunologic responsiveness, or other factors in bringing about the inflammation and subsequent deposition of mucin in the hair follicle. Goodpasture's syndrome is an autoimmune disease in which antiglomerular basement membrane antibodies, produced in response to an unknown stimulus, cause damage to the glomeruli[4,5] and possibly to the lungs.[6] Again the question is raised as to the possible role of this abnormality of antibody production in the development of follicular mucinosis.

Follicular mucinosis has been reported in association with reticuloses[3] and familial reticuloendotheliosis.[7] To my knowledge, this is the first report of its occurrence with Goodpasture's syndrome, an autoimmune disease.

FRANK J. JONELIS, MD
San Francisco

1. Rusby NL, Wilson C: Lung purpura with nephritis. *Q J Med* 29:501-512, 1960.
2. Gaensler EA, McCluskey RT: Case records of the Massachusetts General Hospital. *N Engl J Med* 294:944-951, 1976.
3. Emerson RW: Follicular mucinosis. *Br J Dermatol* 79:635, 1967.
4. Lerner RA, Glassock RJ, Dixon FJ: The role of anti-glomerular basement membrane antibody in the pathogenesis of human glomerulonephritis. *J Exp Med* 126:989-1004, 1967.
5. Unanue ER, Dixon FJ: Experimental allergic glomerulonephritis induced in the rabbit with heterologous renal antigens. *J Exp Med* 125:149-162, 1967.
6. Koffler D, Sandson J, Carr R, et al: Immunologic studies concerning the pulmonary lesions in Goodpasture's syndrome. *Am J Pathol* 54:293-305, 1969.
7. Freeman RG: Familial reticuloendotheliosis with eosinophilia and follicular mucinosis. *Arch Dermatol* 105:737-738, 1972.

Immunotherapy of Leprosy

To the Editor.—In reading the minutes[1] of the SOCIETY TRANSACTIONS in the August 1976 issue of the ARCHIVES, the reader is left suspended in one of the discussions on the immunotherapy of leprosy. The minutes alluded to some leprosy research by a "Korean physician"[2] in an obscure manner that invites inquiry.

In 1972, Lim et al[2] reported that repeated whole WBC transfusions given over approximately a three-month period substantially cleared patients with either lepromatous or tuberculoid leprosy. The clinical, bacteriologic, and histologic data all became normal soon after the end of the immunotherapy and remained normal. These results were recently confirmed in a communication[3] that also reiterates the previous failure of the use of transfer factor.[4]

RAMON M. FUSARO, MD, PHD
Omaha

1. Society Transactions. *Arch Dermatol* 112:1193-1194, 1976.
2. Lim SD, Fusaro R, Good RA: Leprosy VI: The treatment of leprosy patients with intravenous infusions of leukocytes from normal persons. *Clin Immunol Immunopathol* 1:122-139, 1972.
3. Saha K, Mittal MM, Maheshwari HB: Passive transfer of immunity into leprosy patients by transfusion of lymphocytes and by transfusion of Lawrence's transfer factor. *J Clin Microbiol* 1:279-288, 1975.
4. Bullock WE, Fields JR, Brandriss MW: An evaluation of transfer factor as immunotherapy for patients with lepromatous leprosy. *N Engl J Med* 287:1053-1059, 1972.

Bands in Cellular Blue Nevus

To the Editor.—Banded structure in cellular blue nevus presented by Bhawan and Edelstein in the ARCHIVES (112:1176-1177, 1976) warrants further comment.

Extensive investigation with the electron microscope on the relationship between blue nevus cells and nerves led me to believe that the blue nevus cells proliferate outside of the perineurium and do not invade the endoneurium. Even in the most tiny myelinated and unmyelinated fibers, devoid of perineurial sheath, the "fundamental architectural unit"[1] is respected, and degeneration of Schwann cells and axons takes place very late if ever. The picture published by Bhawan and Edelstein stresses this, and, as far as it is found repeatedly, represents an objective argument against the neural origin of blue nevus.

The "striated body," is quite common in normal tissues with immature collagen fibers (the so-called reticulin fibers) and especially in the central and peripheral nervous structures.[1] It is present too in tumors of the same, but lacks specificity. Experimental work by Carasso and collaborators[2] and by Luse and collaborators[3] proved it to be abnormal collagen fibril.

Collagen brought into solution may, in definite conditions, precipitate and organize into banded periodic structures (periodicity sway between 1,400 and 2,600 A). This makes at least speculative the hypothesis of actin and myosin-like material.

A. BOURLOND, MD
Louvain, Belgium

1. Bourlond A: *L'innervation Cutanée*. Paris, Masson, 1968, p 171.
2. Carasso A, Favard P, Oberlin A: Le callagéne in *Traité de Microscopie Électronique*. Paris, Magan Publishers, 1961, pp 1141-1174.
3. Luse S, Zopf D, Cox J: An electron microscopic study of in vitro and in vivo long-spacing collagen. *Anat Rec* 145:254-255, 1963.

In Reply.—Our experience on the relationship between cellular blue nevus and nerves is different from that of Dr Bourland. We have observed invasion of nerves by cellular blue nevus cells. In fact, a cell containing melanosomes, indistinguishable from the nevus cells present outside the nerve, can be seen in the Figure (close to the banded structure in black rectangle in the uppermost part of the electron micrograph).[1] This has also been reported by other workers, both in experimentally induced nevi in animals[2] and humans.[3]

In contrast to Dr Bourland's observations, ultrastructural evidence of degeneration of Schwann cells and axons was seen in almost every nerve within the cellular blue nevi of our three patients. Figure 1 in our report showed multiple layers of basement membrane surrounding a Schwann cell from a nerve within a cellular blue nevus. Such changes have been considered to result from repeated segmental demyelination and remyelination. They are described in a variety of human hypertrophic neuropathies and can be produced experimentally (unpublished data).

We did nothing more than speculate that banded structures may contain actin and myosin, and further stated that they are reported in a variety of tissues.[1] However, it has been shown quite clearly that these banded structures are different from native collagen or experimentally reconstituted long spacing collagen.[4]

JAG BHAWAN, MD
LEE M. EDELSTEIN, MD
Worcester, Mass

1. Bhawan J, Edelstein LM: Banded structures in cellular blue nevus. *Arch Dermatol* 112:1176-1177, 1976.
2. Nakai T, Rappaport H: A study of histogenesis of experimental melanotic tumors resembling cellular blue nevi: The evidence in support of their neurogenic origin. *Am J Pathol* 43:175-184, 1973.
3. Rodriguez HA, Ackerman LV: Cellular blue nevus clinicopathologic study of forty-five cases. *Cancer* 21:393-405, 1968.
4. Sun CN, White HJ: Extracellular cross-striated banded structures in human connective tissue. *Tissue Cell* 7:419-432, 1975.

Nerve within cellular blue nevus showing multiple layers of basement membrane (arrows) around myelinated fiber (×10,880).

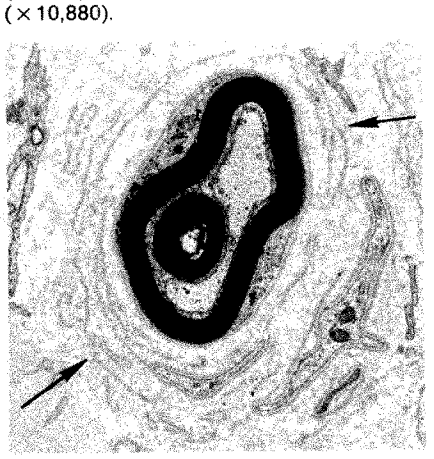

Insect Sting Kit

To the Editor.—I am convinced that lives now needlessly lost due to severe systemic reactions to insect stings could be saved. How? By a greater awareness of the possibility of such fatal reactions plus knowledge of the existence of an insect sting kit. The kit is an emergency first aid measure to stave off anaphylaxis. Because of my convictions, I am presently collecting and correlating data on the incidence of such fatalities.

I am especially interested in time lapse between sting and death, although information concerning the following would be helpful: (1) time sequence of symptoms; (2) previous reactions to insect stings; (3) medication on hand at time of sting; (4) type of medication; (5) type of insect; (6) number of stings; and (7) estimation as to whether or not a physician or hospital emergency room could have been reached in time to avoid a fatal outcome.

CLAUDE A. FRAZIER, MD
Asheville, NC

Urticaria Due to *Clonorchis sinensis*

To the Editor.—Intestinal parasites are a rare cause of urticaria.[1] I would like to report a case of urticaria probably due to infestation with *Clonorchis sinensis*.

Report of a Case.—A 54-year-old Oriental woman who lived in Michigan was seen on July 1, 1976, because of generalized urticaria. Her history was notable in that she had been in Hong Kong for one month and had only recently arrived home. She had a similar episode of urticaria when she was in Hong Kong four years previously.

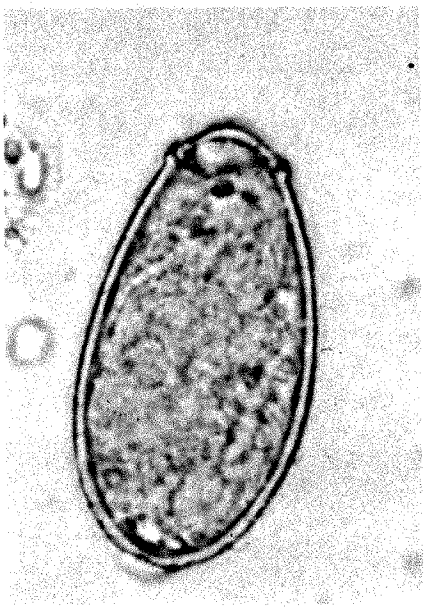

Typical egg of *Clonorchis sinensis*.

Laboratory studies were obtained at the time she was seen. The WBC count was 9,000/cu mm with a normal differential, except for 6% eosinophils. The hemoglobin, urinalysis, blood glucose, BUN, serum creatinine, serum bilirubin, SGOT, alkaline phosphatase, serum uric acid, serum cholesterol, serum calcium and phosphorus, serum protein, as well as albumin and globulin levels were all normal. Stools for ova and parasites were negative at first, but when repeated showed many eggs of *C sinensis* (Figure).

The patient was treated with 10 mg of hydroxyzine hydrochloride three times a day, and the eruption resolved in about ten days. Because of the tendency for *C sinensis* to spread to the liver, this woman was referred to a gastroenterologist. However, she neglected to see him because of a lack of symptoms.

Comment.—*Clonorchis sinensis* is also referred to as the Chinese liver fluke. Infestation with it is obtained by eating raw or undercooked fish that contain the encysted larvae. This parasite is endemic in Japan, Korea, China, and Viet Nam. After ingestion, affected persons may be asymptomatic or if they have a heavy infestation, they may have epigastric distress, malaise, anorexia, hepatomegaly, and jaundice. During this stage, eosinophilia may be present. Eggs are not found in the stool until after one month.

The fluke ascends the biliary tree from the duodenum or may go to the liver by the portal circulation. They mature in the bile ducts and may live there many years. Light infections may be symptomless, but heavier ones may result in "chronic cholangitis with inflammation of the biliary tree, proliferation of biliary epithelium and progressive portal cirrhosis."[2] As a late complication, cholangiocarcinoma may occur. There is a high incidence of this in Hong Kong in men after the fourth decade.

The diagnosis is made by finding the typical egg in the stool. Treatment is with chloroquine, but it may not be effective. In some instances of biliary obstruction, surgery may be needed to remove the flukes.[2,3]

Although *C sinensis* infection is not mentioned as a cause of urticaria in the text books I reviewed,[1-3] it probably was the cause in my patient's case. Clinicians should consider intestinal parasites as a possible cause of hives in patients who have recently returned from the Orient or Africa.

RALPH J. COSKEY, MD
Detroit

1. Katz HI: Anaphylactic syndromes, in Moschella SL, Pillsbury DM, Hurley HJ Jr (eds): *Dermatology*, ed 1. Philadelphia, WB Saunders Co, 1975, vol 1, pp 229-232.
2. Marsden PD: Hermaphroditic flukes, in Beeson PB, McDermott W (eds): *Textbook of Medicine*, ed 14. Philadelphia, WB Saunders Co, 1975, pp 518-519.
3. Markell EK, Voge M: *Medical Parasitology*, ed 3. Philadelphia, WB Saunders Co, 1971, pp 159-161.

Accidental Intraocular Injection With Dermojet Syringe

To the Editor.—Accidental intraocular injection of corticosteroids by a Dermojet syringe is a rare occurrence that has, to the best of our knowledge, not been reported previously. This letter reports the accidental intraocular injection of steroids by a dermatologist while treating psoriasis of the lids.

Report of a Case.—A 35-year-old man had an acute onset of pain and blurred vision of the right eye of four hours' duration. Earlier that day the patient had received a 0.1-ml injection of triamcinolone acetonide (40 mg/ml) administered to the right upper lid via a Dermojet syringe. Instantly the patient became aware of severe pain, decreased vision, and an abrupt onset of floaters. Vision was completely absent at first, but within minutes it returned, although still diminished. On examination later that day, visual acuity was 20/60 in the right eye and 20/20 in the left. Ocular tension was normal. On eversion of the right upper lid, a small area of hemorrhage was seen in the palpebral conjunctiva. The anterior segment was unremarkable in both eyes, and the left fundus was normal. The vitreous of the right eye contained many white particles of various sizes and shapes. The fundus could be seen around these particles, a small hole was present at the equatorial region of the fundus superotemporally, and there were scattered small retinal hemorrhages (Figure). The patient was treated with analgesics and mydriatics, and after one week the visual acuity in the right eye was 20/20. Many steroid particles remained in the vitreous overlying the retina, and the patient still complained of floaters. During the ensuing three-year period, the patient's visual acuity remained normal, and he was asymptomatic except for occasional floaters. Results of ocular examination were unremarkable, except for several residual steroid particles floating in the vitreous and a chorioretinal scar around the previous retinal hole in the right eye.

Comment.—The Dermojet syringe uses a high-velocity microspray in single doses of 0.1-ml to a depth of 2 to 5 mm without actual contact with the site of injection. At first impression it would seem that this depth of penetration could not be sufficient to penetrate the lid and ocular tissues. Yet there is no doubt that ocular penetration occurred through the closed upper lid.

Previous reports of accidental intraocular injection of steroids, using conventional syringes with various gauge needles, have led to severe decreases in visual acuity and even blindness.[1] If the patient retains good vision after the injection, the presence of a given amount of intraocular steroids may lead to other problems. Severe secondary glaucoma or steroid-induced cataract in susceptible patients may develop.[2] Although intraocular penetration is unlikely with the Dermojet syringe, in this day of medicolegal jurisprudence, discretion dictates avoidance of this type of injection around or into the eyelids and necessitates great care in administering any type of injection that might inadvertently enter the eye.

Fundus photograph of right eye three days after accidental intraocular injection showing intraocular steroid particles, with retinal and vitreous hemorrhage.

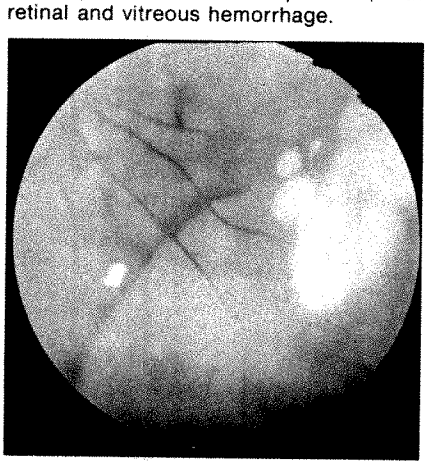

HENRY T. PERRY, MD
BRUCE T. COHN
JACK STANLEY NAUHEIM, MD
East Meadow, NY

1. Schlaegel TF Jr, Wilson FM: Accidental intraocular injections of depot corticosteroids. *Trans Am Acad Ophthalmol Otolaryngol* 78:847-855, 1975.
2. Havener WH: *Ocular Pharmacology*. St Louis, CV Mosby Co, 1970, pp 304-309, 311-312.

Nevi in Leprosy

To the Editor.—Indeterminant leprosy may be a difficult diagnosis to make due to the paucity of organisms in skin biopsy material. Observations on a recent case suggest that biopsy specimens of cellular nevi may facilitate diagnosis, since the organism has an affinity for nevus cells. We were unable to find any previous references to this effect; however, this observation is apparently well known to many leprologists (oral communication with Dr Samuel Moschella, Aug 27, 1976).

Report of a Case.—A 38-year-old man was seen in the dermatology clinic at University of California Irvine Medical Center with a two-year history of progressive numbness of the hands and feet. Results of physical examination showed multiple hypopigmented macules on the back, chest, and in the axilla. Multiple biopsy specimens were taken, fixed in a formaldehyde solution, and processed routinely, and sections were stained with hematoxylin-eosin and Fite-Faraco stains. The sections exhibited a mild perivascular inflammatory infiltrate composed of lymphocytes and histiocytes. There was some suggestion of perineural fibrosis. The Fite-Faraco stain exhibited rare acid-fast organisms that were found only on reexamination of the tissue. The sections were interpreted as indeterminant leprosy. The patient was administered dapsone. Five months later, the patient returned to the clinic and had an intradermal cellular nevus removed from the left side of his nose. The hematoxylin-eosin stained sections exhibited the microscopical features of an intradermal cellular nevus. To our surprise, the Fite-Faraco stain exhibited several acid-fast organisms that were not abundant, but were found without difficulty within the nevus. Unfortunately, a biopsy of normal skin was not performed.

Comment.—The discovery of *Mycobacterium leprae* within an otherwise

normal cellular nevus was not expected, but its occurrence seems reasonable due to the well-known affinity that the organism has for neural crest cells, particularly Schwann's cells. As previously stated, a biopsy should have been taken from normal skin at the time of the removal of the nevus, but the patient was unavailable. It is still unlikely that this finding was just a coincidence since, with the exception of lepromatous leprosy, organisms are not usually found in uninvolved skin. Although this represents only a single case, it is hoped that physicians who see many patients with leprosy will consider examining nevi when organisms may be difficult to find in skin lesions, which is frequently the case in indeterminant or tuberculoid varieties. Such a procedure is considerably less traumatic than nerve biopsies and possibly may prove to be just as useful.

RONALD J. BARR, MD
DAVID C. HERZLINGER, MD
Irvine, Calif

Familial Localized Scleroderma (Morphoea)

To the Editor.—Familial scleroderma is a rare condition; to our knowledge, only nine documented instances of the disease have been reported. This report adds one more family to the literature. Four children, three brothers and one sister, had clinically and histologically established localized scleroderma.

In 1953, Rees and Bennett[1] reported the first documented instance of localized scleroderma occurring in two members of the same family. In 1968, Burge and Perry[2] after reviewing the literature on familial scleroderma presented four more documented instances. In 1972, Szczepanski and Jakubowicz[3] reported another instance of localized scleroderma in two sisters. In 1975, Wuthrich et al[4] reported another two instances of localized scleroderma.

Report of Cases.—CASE 1.—In November 1975 a 15-year-old boy with morphoea involving all four limbs was examined. The lesions had started to develop 11 years previously and gradually increased in size. During the winter, he had symptoms of Raynaud's phenomenon.

Clinical examination of the affected areas revealed claw-like hands, with considerable tightening of the skin over the fingers that resulted in flexion deformities.

The skin over the fingers was shiny and smooth and could not be lifted. The skin over the dorsum of the hands was rough and hyperpigmented (Fig 1). The radial pulse was normal.

The feet were also severely affected; the right one was grossly deformed. The skin was rough and dry with hyperpigmentation. There was gross wasting of the small muscles of the feet, with contracture of the toes.

The tibial pulsation was normal on both sides and so were the sensations. There was no other obvious skin involvement. The rest of the physical examination showed him to be a well-built, intelligent adolescent.

Laboratory investigations gave the following values: hemoglobin, 10 gm/100 ml; WBCs, 8,150/cu mm: polymorphonuclear leukocytes, 75%, lymphocytes, 30%, monocytes, 2%; ESR, 32 mm Hg. The results of a lupus erythematosus (LE) cell test were negative, but the rheumatoid arthritis (RA) factor was positive. Results of urinalysis, chest roentgenogram, barium swallow, spine roentgenogram, and ECG were normal. A skin biopsy specimen showed a considerably thickened dermis with hypertrophic, closely packed collagen bundles; sebaceous glands and hair structure were completely absent.

CASE 2.—The 13-year-old sister of the boy in case 1 was seen at the same time with clinically typical lesions of morphoea that were almost-identical to those of her brother in case 1 (Fig 2).

Her symptoms started nine years previously and progressed gradually with the passage of time. However, Raynaud's phenomenon in this case was more severe than in case 1.

Laboratory investigations gave the following values: hemoglobin, 8 gm/100 ml; WBCs, 8,000/cu mm, polymorphonuclear leukocytes, 25%, lymphocytes, 75%, and eosinophils, 1%. Results from an LE cell test were negative; however, the RA factor was negative. Results from urinalysis, barium swallow, chest and spine roentgenograms and ECG were normal. A skin biopsy specimen showed hypertrophic section and closely packed collagen bundles. Most of the vessels in the dermis had considerable thickening of the wall with narrowing of their lumens and they were surrounded by few inflammatory cells.

Fig 1.—Skin over dorsum of hands was rough and hyperpigmented for patient in case 1.



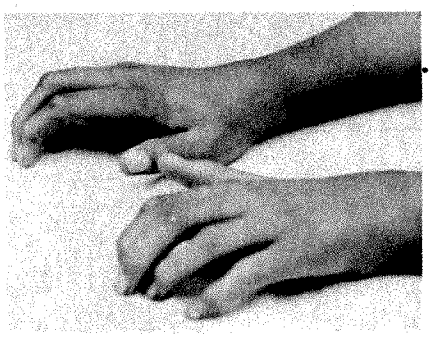

Fig 2.—Thirteen-year-old sister of patient in case 1 has clinically typical lesions of morphoea almost-identical to those seen in her brother in case 1.

CASE 3.—The 7-year-old brother of the patients in cases 1 and 2 was also examined at the same time. His symptoms started three years earlier with thickening of the skin over the fingers of both hands and knees. This progressed gradually and the lesions increased in size.

Clinical examination revealed tightness of the skin over the fingers of both hands that led to mild flexion deformity of the fingers. The skin over the knees was thick and hyperpigmented. Raynaud's phenomenon in this case was less noticeable.

Laboratory investigations gave the following values: hemoglobin, 8 gm/100 ml; WBCs, 10,300/cu mm, polymorphonuclear leukocytes, 75%, lymphocytes, 20%, monocytes, 1%, eosinophils, 1%. The ESR was 20 mm Hg. Results of an LE cell test were negative; the RA factor was negative. Results from urinalysis, chest and spine roentgenograms, barium swallow, and ECG were normal. A skin biopsy specimen showed sclerotic collagen in the dermis, with sweat glands bound down in the middermis.

CASE 4.—The 5-year-old brother of the aforementioned patients was seen at the same time. His symptoms started six months previously with thickening of the skin of proximal interphalangeal joints of both hands.

On examination, the skin was tight over the proximal interphalangeal joints with moderate induration but no discoloration. No lesions were present on any other parts of the body. Systemic examination did not reveal any other abnormality.

Laboratory investigations gave the following values: hemoglobin, 7.5 gm/100 ml; WBCs, 9,650/cu mm; neutrophils, 30%, lymphocytes, 69%, monocytes, 1%. The ESR was 15 mm Hg. Results of an LE cell test were negative; the RA factor was negative. Results from urinalysis, chest and spine roentgenograms, barium swallow, and ECG were normal. A skin biopsy specimen showed a considerably thickened dermis. Collagen bundles were hypertrophic, sclerotic, and closely packed.

Comment.—Nine other documented instances of localized scleroderma that have been published and the one reported here suggest hereditary predisposition in this disease, but obviously more work is needed to prove this factor.

Previous workers have shown that females have a greater predisposition for scleroderma developing than males, but in our four cases, there was a greater incidence in boys than in girls. The ratio was 3 boys:1 girl. Raynaud's phenomenon in scleroderma has been reported and the incidence is greater in females. In the brothers and sister of our four cases, this phenomenon was present in all, but the symptoms were more severe in the sister who was affected.

Christianson et al[5] found anomalies in the vertebral column in 32 of 68 patients with localized scleroderma. None of the patients in our cases had any abnormality in the vertebral column.

Several authors have found an increased incidence of positive antinuclear antibody factor in patients with scleroderma.

Recently, Hanson et al[6] reported an increased incidence of positive RA factor in children with focal scleroderma. In our cases, only the boy in case 1 has a positive RA factor.

MEHR TAJ, MB, MRCP, DCH
ASHFAQ AHMAD, MB, MRCP, FAAP, DCH
Peshawar, Pakistan

Dr Zaib-un-Nisa reported on the skin biopsy specimens and Mr Bhatti took the photographs.

1. Localized scleroderma in father and daughters, SAN FRANCISCO DERMATOLOGICAL SOCIETY. *Arch Dermatol* 68:360, 1953.
2. Burge KM, Perry HD, Stickler GB: "Familial" scleroderma. *Arch Dermatol* 99:681-687, 1969.
3. Szczepanski A, Jakubowicz K: Wsprawie rodzinnego wystepowania twardziny przegl. *Dermatol* 59:361-364, 1972.
4. Wuthrich RC, Henry HR, Willard DS: Localized scleroderma: A report of two families. *Arch Dermatol* 111:98-104, 1975.
5. Christianson HB, Dorsey CS, O'Leary PA, et al: Localized scleroderma: A clinical study of 235 cases. *Arch Dermatol* 74:629-639, 1956.
6. Hanson V, Drexler E, Kornreich H: Rheumatoid factor in children with focal scleroderma. *Pediatrics* 53:945-947, 1974.

Hereditary Syringomas

To the Editor.—There are a large number of epidermal appendage tumors of the skin, and they have been carefully classified according to clinical appearance, light and electron microscopical structure, and enzyme histochemistry.[1,2] Most of these tumors appear to be acquired and are representative of developmental defects, although disorders such as the basal cell nevus, trichoepithelioma, cylindroma, and steatocystoma multiplex have a genetic basis, and they are inherited in an autosomal dominant manner.[3] Of these disorders, however, in only the basal cell nevus syndrome is a second type of skin lesion—palmar keratoses and pits—observed. This report describes a patient with both syringomas of the face and palmar keratoses, whose mother had similar lesions.

Report of a Case.—The patient was a 65-year-old woman who requested removal of several lesions of the face that had developed when she was in her teens. She had also noted keratotic lesions of the palms at about the same time. Her mother had similar lesions. The patient was unaware of this condition in other family members, but she had no siblings or children. She denied having been given arsenic as medication or having been exposed to arsenical sprays.

The pertinent findings on physical examination were restricted to the skin. Multiple, yellowish papules, some of which had telangiectasia, were noted around the eyes, and numerous 1- to 2-mm keratotic papules were present on the palms. There was no raindrop-like pigmentation. Studies of biopsy specimens of three lesions from the face showed typical features of syringoma.

Comment.—The appearance of multiple syringomas is rather distinctive, and the correct diagnosis is usually made prior to histopathological study. In this case, some confusion arose because of the apparent hereditary nature of the disorder and its association with palmar lesions. This uncommon genetic basis has been described previously,[4] and subsequent to seeing this patient, I had observed two additional patients who had an affected parent, but no palmar lesions were noted in these cases.

The differential diagnosis in this case included a number of hereditary diseases in which keratotic lesions of the palms and soles occur (Table). In most of these diseases, cutaneous lesions may be observed in other areas; in basal cell nevus syndrome and lipoid proteinosis facial lesions are very common. The typical palmar lesions of the former disorder are circular pits with perpendicular sides and a reddened base that is formed by normal keratin; keratotic lesions are also observed. In the other disorders, a depression may be seen in the palmar lesions—a "pseudopit"—but the base is lined with greatly thickened stratum corneum.

HOWARD P. BADEN, MD
Boston

1. Lever WF: Pathogenesis of benign tumors of cutaneous appendages and of basal cell epithelioma: Benign tumors of cutaneous appendages. *Arch Dermat & Syph* 57:679-708, 1948.
2. Hashimoto K, Lever WF: Appendage tumors of the skin. Springfield, Ill, Charles C Thomas Publisher, 1968.
3. Sanderson KV: Tumours of the skin, in Rook A, Wilkinson DS, Ebling FJG (eds): *Textbook of Dermatology.* Oxford, England, Blackwell Scientific Publications, 1972, pp 1911-2007.
4. Reed WB: Genetische aspekte in der dermatologie. *Hautarzt* 21:8-16, 1970.

Keratotic Lesions in Genetic Diseases

Disease	Mode of Inheritance	Distinguishing Features
Keratosis punctata	AD*	Palmar and plantar lesions develop during first decade
Basal cell nevus syndrome	AD	Palmar lesions are pits without keratotic plugs; papules found on face; multiple anomalies of bone
Darier's disease	AD	Keratotic papules on trunk and head that show acantholysis on biopsy
Acrokeratosis verruciformis	AD	Keratotic lesions on dorsum of hands and feet
Epidermodysplasia verruciformis	AR†	Warts may be widespread on body
Pachyonychia congenita	AD	Subungual hyperkeratosis and mucous membrane involvement
Acrokeratoelastoidosis	AD	Yellowish papules on dorsum of feet and hands
Lipoid proteinosis	. . .	Ivory papules and plaques on face; mucous membranes are involved
Cutaneous papillomatosis	. . .	Pigmented keratotic lesions on trunk in various configurations

*AD, autosomal dominant.
†AR, autosomal recessive.

Cantharidin Treatment of Warts at Home

To the Editor.—Cantharidin treatment of warts has become increasingly popular since first suggested by Epstein and Kligman in 1958.[1] The presently available commercial preparation of cantharidin carries a package insert suggesting application by the physician and the use of occlusive tape dressing to enhance the drug's blistering effect. Because the proper application of small pieces of occluding tape can be time-consuming, and because office treatment usually requires one or more return office visits, we decided to investigate the use of cantharidin as a self-applied, home treatment for warts.

The cantharidin was supplied as a 0.7% solution in acetone-flexible collodion in specially sized, 2.5-ml applicator bottles for ease of self-application. A standard (green) food color was added to simplify the process of self-application. The patients (or their parents) were told to apply a small amount of the colored solution directly to the wart, allow it to dry, and then to cover the area with an ordinary cotton adhesive bandage. Patients were instructed to apply the agent daily until a blister appeared or the wart disappeared.

These directions deliberately omitted mention of the application of an occlusive tape over the wart. We recognized that omitting the occlusive tape might result in a less therapeutic effect. We felt, however, that this might be preferable because it was expected to simplify the process of application and produce fewer painful reactions.

We treated a total of 336 hand warts in 100 patients with this method. Of the warts, 158 were common and 178 were subungual or paronychial warts. Thirty of the 100 patients were children under the age of 12. None of the patients experienced pain, untoward blistering, or any other side effect. The treatment resulted in removal of 112 of 178 subungual or paronychial warts and 103 of 158 common warts (on hands and fingers). One patient with a wart on her palm developed a so-called fairy ring of tiny satellite warts after the original wart disappeared. These were treated by freezing with liquid nitrogen.

This treatment compares favorably with the results that were obtained by Bunney et al,[2] who used a preparation that contained one part salicylic acid, one part lactic acid, and four parts flexible collodion. That treatment was as good as any, such as cryosurgery or curettage, that might be given in the office.

We conclude that home treatment with 0.7% cantharidin solution, applied without the use of occlusive tape, is a safe, easy, and reasonably effective method for the treatment of warts and may be safely prescribed by the physician.

The cantharidin was supplied as Cantharone by the Ingram Pharmaceutical Co, San Francisco.

E. William Rosenberg, MD
Rex A. Amonette, MD
J. Harvey Gardner, MD
Memphis

1. Epstein WL, Kligman AM: Treatment of warts with cantharidin. *Arch Dermatol* 77:508-511, 1958.

2. Bunney MH, Nolan MW, Williams DA: An assessment of methods of treating viral warts by comparative treatment trials based on a standard design. *Br J Dermatol* 94:667-679, 1976.

Skin Closures

To the Editor.—We have been using the new Clearon Skin Closures by Ethicon in our office for several months. They are effective for holding wound edges together after suture removal and seem superior to Steri-Strips by 3M Company in their transparency. We feel it is important to see the wound edge when applying the strips, especially when strips are used in lieu of sutures.

At first, we used Hollister Medical Adhesive on the skin around the wound edge to increase the holding power of the tapes and the length of time the tapes would stay in place. This was the same technique we had used for the Steri-Strips. We quickly found that Clearon Skin Closures fell off in a day or two. On investigating the problem, it became apparent that there is a basic chemical incompatibility between the polyacrylic adhesive used in Clearon Skin Closures and the polysiloxane adhesive used in the Hollister Medical Adhesive.

Now we wipe the skin well with alcohol and allow it to dry before applying the Clearon Skin Closures. They adhere tightly and remain in place for seven to ten days without difficulty.

This letter is to advise our colleagues that these very practicable skin closures by Ethicon should not, in our opinion, be used with Hollister Medical Adhesive.

Samuel J. Stegman, MD
Theodore A. Tromovitch, MD
San Francisco

SYNALAR®
(fluocinolone acetonide)
CREAM 0.025%
CREAM 0.01%
OINTMENT 0.025%
SOLUTION 0.01%

Description Synalar (fluocinolone acetonide) has the chemical name 6α, 9α-difluoro-16α-hydroxyprednisolone-16, 17-acetonide.

The cream contains fluocinolone acetonide 0.25 mg./g. or 0.1 mg./g. in a water-washable aqueous base of stearic acid, propylene glycol, sorbitan monostearate and monooleate, polysorbate 60, purified water and citric acid with methylparaben and propylparaben as preservatives.

The ointment contains fluocinolone acetonide 0.25 mg./g. in a white petrolatum U.S.P. vehicle.

The solution contains fluocinolone acetonide 0.1 mg./g. in a water-washable base of propylene glycol with citric acid.

Indications For relief of the inflammatory manifestations of corticosteroid-responsive dermatoses.

Contraindications Topical steroids are contraindicated in vaccinia and varicella.

Topical steroids are contraindicated in those patients with a history of hypersensitivity to any of the components of the preparation.

Precautions If irritation develops, the product should be discontinued and appropriate therapy instituted.

In the presence of an infection the use of an appropriate antifungal or antibacterial agent should be instituted. If a favorable response does not occur promptly, the corticosteroid should be discontinued until the infection has been adequately controlled.

If extensive areas are treated or if the occlusive technique is used, the possibility exists of increased systemic absorption of the corticosteroid and suitable precautions should be taken.

Although topical steroids have not been reported to have an adverse effect on pregnancy, the safety of their use in pregnant females has not absolutely been established. Therefore, they should not be used extensively on pregnant patients, in large amounts, or for prolonged periods of time.

Synalar products are not for ophthalmic use.

Adverse reactions The following local adverse reactions have been reported with topical corticosteroids: burning, itching, irritation, dryness, folliculitis, hypertrichosis, acneform eruptions, hypopigmentation.

The following may occur more frequently with occlusive dressings than without such therapy: maceration of the skin, secondary infection, skin atrophy, striae, miliaria.

How Supplied
Synalar (fluocinolone acetonide)
Cream 0.025% — 15 and 60g. tubes and 120 and 425g. jars.
Cream 0.01% — 15, 45 and 60g. tubes and 120 and 425g. jars.
Ointment 0.025% — 15 and 60g. tubes and 425g. jars.
Solution 0.01% — 20cc. and 60cc. plastic squeeze bottles.

Also Available
Synalar-HP® (fluocinolone acetonide)
Cream 0.2% 5g. and 12g. tubes.

SYNTEX
SYNTEX LABORATORIES, INC.


AS USEFUL TODAY AS THE
DAY IT WAS INTRODUCED
SYNALAR
(FLUOCINOLONE
ACETONIDE)
See preceding page for summary
of prescribing information
SYNTEX

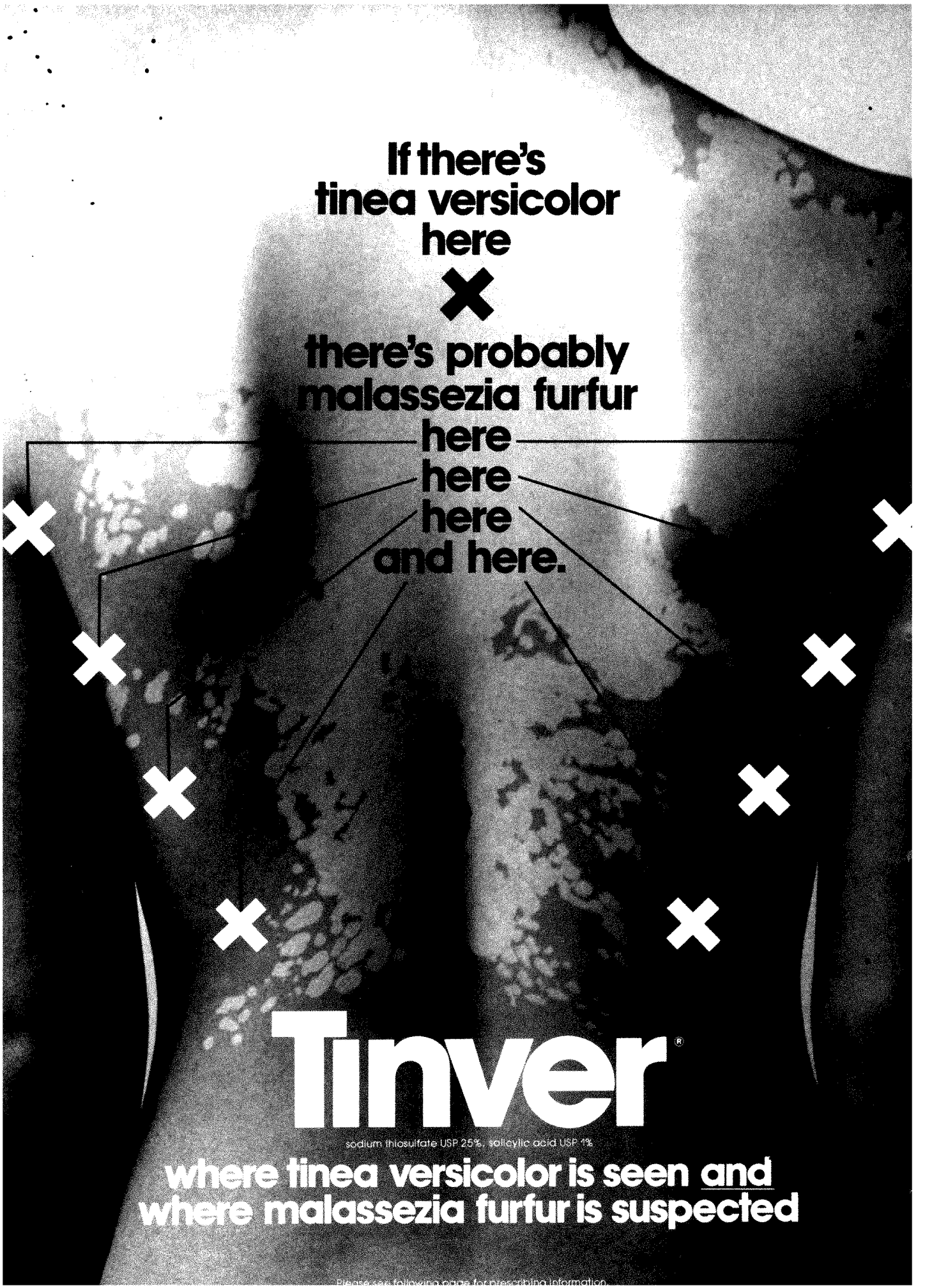
If there's
tinea versicolor
here
there's probably
malassezia furfur
here
here
here
and here.
Tinver®
sodium thiosulfate USP 25%, salicylic acid USP 4%
where tinea versicolor is seen and
where malassezia furfur is suspected
Please see following page for prescribing information.

DESCRIPTION:
Sodium thiosulfate 25%, salicylic acid 1%, isopropyl alcohol NF 10%, propylene glycol USP, menthol USP, disodium edetate, colloidal alumina, and purified water.

INDICATIONS:
For topical use in the treatment of tinea versicolor (Malassezia furfur infection).

PRECAUTIONS:
If signs of irritation or sensitivity develop, discontinue use. Do not use on or about the eyes.

ADMINISTRATION:
Thoroughly wash, rinse and dry the affected areas before application of medication. Apply a thin film of lotion to all affected areas and other susceptible areas twice a day. Although diagnostic evidence of the disease may disappear in a few days, it is advisable to continue treatment for a much longer period. Clothing should be boiled to prevent reinfection.

HOW SUPPLIED:
6 fl. oz. plastic dispenser bottles.

CAUTION:
U.S. Federal law prohibits dispensing without prescription.

Barnes-Hind Pharmaceuticals, Inc.
895 Kifer Road
Sunnyvale, California 94086

Tinver®

sodium thiosulfate USP 25%, salicylic acid USP 1%

Society Transactions

MICHIGAN DERMATOLOGICAL SOCIETY

September 1975

Amir H. Mehregan, MD, Recorder

Focal Dermal Hypoplasia. Presented by ROBERT LEE, MD.

The patient is a 1-month-old baby boy, the first child born of full-term pregnancy and an uncomplicated vaginal delivery. The examination at 3 days of age revealed a jaundiced baby with cutaneous lesions that have persisted. There are multiple oval and annular depressed areas over the face and trunk. The surface of the skin lesions appears atrophic and gives a button-hold type of feeling when palpated. The baby has recession of maxilla and cryptorchidism. There is some asymmetry of face and ears. The jaundice has gradually subsided.

Discussion

AMIR H. MEHREGAN, MD: Biopsy specimen shows definite dermal hypoplasia with the subcutaneous fat tissue situated close to the epidermis. The hypoplastic dermis shows a few telangiectatic capillaries. The network of elastic fibers is well organized. The findings support the clinical impression of focal dermal hypoplasia.[1]

L. LEE, MD: Focal dermal hypoplasia or Goltz-Gorlin syndrome is an autosomal or X-linked dominant congenital malformation characterized by cutaneous, soft tissue, ocular, and neuroskeletal manifestations.[2] Cutaneous changes consist of linear or patchy red streaking of the skin and areas of dermal hypoplasia with herniation of subcutaneous fat tissue and linear or reticular areas of dyschromia and telangiectasia. Fibroepithelial papillomas occur over the lips, in axilla or periumbilical regions, and may also involve buccal or genital mucosa. The scalp hair may be sparse or brittle. Fingernails and toenails may be absent or may show dystrophic changes. Soft tissue defects include asymmetry of the face and ears and auricular appendages. There is a defect in abdominal musculature, umbilical or inguinal hernia, and rectal prolapse. Ocular abnormalities are anophthalmia, aniridia, wide spacing of the eyes, strabismus, nystagmus, heterochromia, blue sclera, and irregularity of the pupils.

Skeletal defects are variable and may include short stature, microcrania, pointed

Duplicated terminal phalanx of great toe.

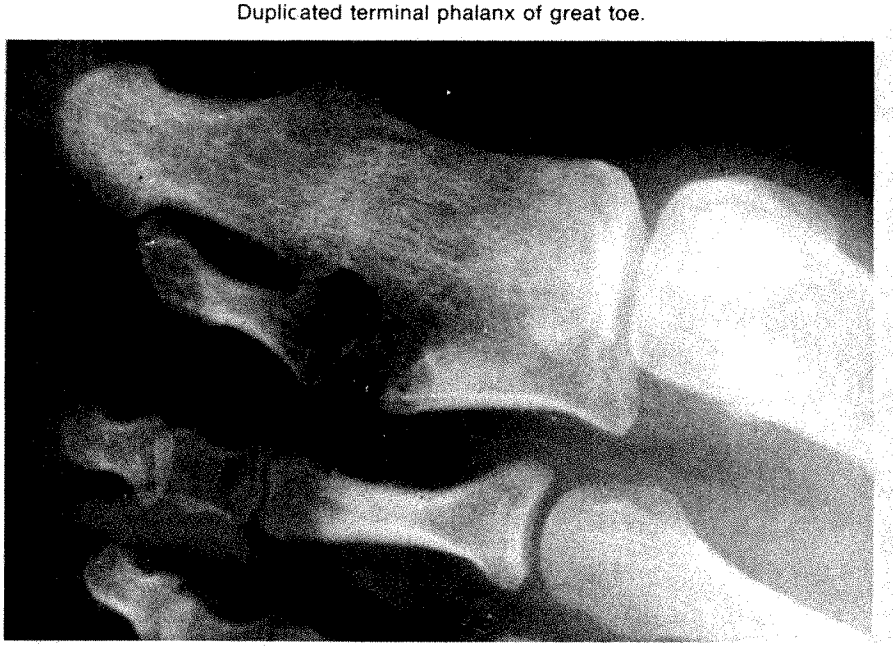

chin, and deviation of nasal septum in addition to the deformities of vertebral bones, bones of the hands and feet, and generalized osteoporosis. Oral and dental anomalies exist such as prognathism, underdevelopment of the mandible, microdontia or dysplasia of the teeth, developmental abnormalities of the tongue, and hypertrophy of the gums. This syndrome may also be complicated by mental deficiency and epileptiform seizures. There are 47 famale cases and three males with this syndrome that have been reported. The case presented is the fourth male infant with focal dermal hypoplasia showing cutaneous manifestations and characteristic histologic findings of this condition. The infant shows asymmetry of the face and ears, but other components of this syndrome have not yet been detected.

References

1. Goltz RW, Henderson RR, Hitch JM, et al: Focal dermal hypoplasia syndrome: A review of the literature and report of two cases. *Arch Dermatol* 101:1-11, 1970.
2. Goltz R: Focal dermal hypoplasia, in Bergsma D (ed): *Birth Defects Atlas and Compendium*. Baltimore, Williams & Wilkins Co, 1973, p 414.

Rubinstein—Taybi's Syndrome. Presented by JAMES STROUD, MD.

The patient is a 19-year-old woman with severe mental retardation. On physical examination considerably enlarged thumbs and toes were seen. The patient also has epileptic seizures and self-destructive tendencies marked by picking at herself and by the pulling of her nails. X-ray films of the toes show duplicated terminal phalanx of both great toes (Figure). The thumbs are similarly affected.

Discussion

JAMES STROUD, MD: This syndrome is characterized by broad terminal phalanges of the thumb and hallux, broad terminal phalanges of other fingers, and overlapping toes in association with varieties of facial abnormalities and mental deficiency.[1] In addition, there are often other skin changes such as nevus flammeus, hirsutism of the trunk and limbs, and changes in the dermatoglyphic pattern.

Reference

1. Rubinstein JH: Broad thumb-hallux syndrome, in Bergsma D (ed): *Birth Defects Atlas and Compendium*. Baltimore, Williams & Wilkins Co, 1973, p 218.

PHILADELPHIA DERMATOLOGICAL SOCIETY
May 16, 1975

Waine C. Johnson, MD, Recorder

Blue Rubber Bleb Syndrome. Presented by HERBERT A. LUSCOMBE, MD; YOUNG C. KAUH, MD; MARGERY A. SCOTT, MD.

A 17-year-old boy from Puerto Rico had skin lesions involving the arms, legs, feet, and genitalia since birth. Although they have occasionally become painful during the summer, they have generally remained asymptomatic and have increased in size only in proportion to his growth. The lesions do not show an increase in sweating. He denies melena but has had recurrent episodes of spontaneous epistaxis. His paternal grandfather had similar lesions, but nine siblings are unaffected. Dermatological examination revealed numerous elevated hemangiomas varying in color from dark blue to purple that involved the arms, trunk, feet, and penis. The lesions will empty completely on steady pressure. A complete blood count and platelet studies have been normal. No occult blood was found in the stool, and upper and lower gastrointestinal (GI) studies were normal. A biopsy specimen was reported as hemangioma.

Discussion

THOMAS BUTTERWORTH, MD: The term "blue rubber bleb nevus" was used by Bean to describe hemangiomas of skin that were compressible and that refilled fairly promptly on release of pressure and were associated with nocturnal pains, supralesional sweating, and melena from GI hemangiomas. The patient presented does not show all of the features described by Bean in that some of the angiomas were firm whereas others were soft and compressible; increased sweating was not seen; the growths are only occasionally painful and blood has not been found in the stools.

Multiple glomangiomas must be considered a diagnostic possibility in this case. They favor the extremities but may be widely scattered elsewhere. The solitary glomangioma is extremely painful, especially when found beneath the nail, whereas the multiple scattered lesions are usually not painful. Sweating and melena do not occur as a rule. We need the help of the dermatopathologist to make an exact diagnosis in this case.

HERBERT GOLDSCHMIDT, MD: Hereditary glomangiomas of the multiple type usually show a different clinical picture in that they are less conspicuous and are a very light blue in color. The histologic findings are usually diagnostic.

DONALD BAXTER, MD: Clinically, this patient's lesions looked very much like the familial glomangiomas that I have seen. They do not show herniations like the blue rubber bleb nevi usually do. However, the biopsy specimen shows changes of a hemangioma and does not show the features of a glomangioma. Perhaps another lesion should be excised.

WAINE C. JOHNSON, MD: The histology of a blue rubber bleb nevus is not entirely specific but shows features of a cavernous hemangioma with large vascular spaces and often will have a good bit of smooth muscle about the vascular spaces. The features seen in this patient's biopsy specimen are those of a cavernous hemangioma with a considerable amount of smooth muscle and would be consistent with a blue rubber bleb nevus. The histological features are not those of a glomangioma. I think the diagnosis depends on how you define the blue rubber bleb nevus syndrome as to whether or not intestinal vascular tumors and the other features mentioned have to be present. The possibility of intestinal lesions probably cannot be entirely ruled out, although there is no evidence of such lesions at this time. The possibility of bleeding from any internal lesions, if they are present, is of course the most significant concern for this patient.

Mycosis Fungoides and Sarcoidosis. Presented by YOUNG KAUH, MD; HERBERT A. LUSCOMBE, MD; J. MCFARLAND, MD.

A 47-year-old woman states that she was refused employment in 1966 because of an abnormal chest roentgenogram that was interpreted as sarcoidosis. A scalene node and a skin biopsy were performed and were interpreted as sarcoidosis. She was started on treatment of prednisone, 10 mg per day. In 1969, she had a liver biopsy specimen taken that was interpreted as being consistent with sarcoidosis. By 1971, she had disseminated skin lesions, and a biopsy specimen from one lesion was interpreted as sarcoidosis and that from another as chronic dermatitis. Between 1971 and 1974, her treatment included prednisone, chlorpropamide, and topical steroid creams. The skin lesions progressed, an exfoliative dermatitis developed, and as this cleared somewhat, eczematoid lesions were noted. She was treated with oral steroids for systemic effect and chlorambucil. The skin lesions were treated in 1975 with 2,000 rads of electron beam therapy and later with topical mechlorethamine hydrochloride (Mustargen).

Dermatological examination shows multiple plaques and tumors, some of which are ulcerated, involving most of the body surface. Skin tests to intermediate strength of purified protein derivative, mumps, *Candida*, and trichophytin antigens were negative. No Sézary cells were identified in the peripheral blood. The present treatment includes mechlorethamine, chlorpropamide, and antibiotic ointment.

Discussion

HAROLD ISRAEL, MD: This patient has had generalized sarcoidosis with characteristic pulmonary changes and granulomas demonstrated in skin, lymph node, and liver biopsy specimens. In 1974 when the large ulcerating nodules developed, I was concerned that there was a superimposed deep fungal infection. Skin biopsy specimens at that time showed mycosis fungoides and she was treated with radiation and mechlorethamine with considerable improvement. Two Kveim tests were performed and were negative although the reaction could have been suppressed because of steroids. In my experience, a positive Kveim test is seen in 60% to 80% of the patients with sarcoidosis.

A question that deserves consideration is whether patients with sarcoidosis are prone to having neoplasms develop because of their impaired delayed hypersensitivity

or altered immunity. In general, we have not been persuaded that patients with sarcoidosis show an increased incidence of neoplasms. Brincker and Wilbek[1] reported a possible increase in the association of sarcoidosis and Hodgkin's disease. An epidemiologic survey in Denmark of patients with sarcoidosis was cross-checked with the tumor registry, and a greater frequency of neoplasms (mostly lymphomas) was found in patients with sarcoidosis.[1] I am not completely convinced that their data are correct.

HERMAN BEERMAN, MD: I would like for Dr Israel to comment on the validity and significance of the Kveim test.

DR ISRAEL: There has been a recent outbreak of correspondence about the Kveim test.[2] Hurley et al[3] reported that their antigen is usually positive in sarcoidosis but is nonspecific in that patients with other diseases also show a positive reaction. I believe that many or most of the antigens available will give false-positive reactions. We had hopes of developing an in vitro equivalent measuring migration inhibition of lymphocytes from the affected patients, but this has not yet proved practical.

References

1. Brincker H, Wilbek E: The incidence of malignant tumors in patients with respiratory sarcoidosis. *Br J Cancer* 29:247-251, 1974.
2. Martin L: Practical problems with Kveim test. *N Engl J Med* 292:1407-1408, 1975.
3. Hurley TH, Sullivan JR, Hurley JV: Reaction to Kveim test material in sarcoidosis and other diseases. *Lancet* 1:494-496, 1975.

CHICAGO DERMATOLOGICAL SOCIETY
January 1975

David F. Fretzin, MD, Recorder

Dermatomyositis Sine Myositis. Presented by SIDNEY BARSKY, MD, RAYMOND W. VAHL, MD.

This 62-year-old woman was well until 18 months ago, when she noted progressive, erythematous, macular hyperpigmentation of her forehead and forearms. Two months previously, she had had a "flu-like" illness, with weakness of her arms and legs that persisted for three weeks. She relates "soreness of the flesh" and tenderness of her arms during that time that improved without treatment. She has since developed hyperpigmentation of the chest and back, and violaceous, papular lesions on the dorsums of the hands. She noted occasional warm sensations and a 15-pound weight loss in the past two months. Her medical history includes adult-onset diabetes and intermittent diastolic hypertension. Her current medications include: phenformin hydrochloride, tolbutamide, chlorthalidone, and methyldopa.

Results of physical examination show slight erythema of the palatal and pharyngeal mucosa. Her strength is normal in all muscle groups. A hyperpigmented, erythematous, macular eruption is present on her forehead, malar area, upper arms, and hands. There is violaceous, papular thickening over her knuckles and proximal interphalangeal joints, and periungual telangiectasia and tenderness with cuticular hyperkeratosis of the hands.

A skin biopsy specimen of the arm was consistent with the poikilodermatous changes of dermatomyositis. Immunofluorescence was negative for IgG, IgM, and complement in involved and uninvolved skin. Laboratory studies disclosed the following values: WBC, 4,200/cu mm; hemoglobin, 11.6 gm/100 ml, with a normal differential cell count; sedimentation rate, 29 mm/hr; fasting blood glucose, 220 mg/100 ml. The following tests were negative: urinalysis, antinuclear antibody, rheumatoid factor, cryoglobulins, and VDRL (test for syphilis). The EMG of her girdle muscles was normal. The SGOT, creatinine phosphokinase, aldolase, and urine creatinine levels were all within normal limits. The urine porphyrins were normal (24-hour determination). Evaluation for occult malignant neoplasms (upper and lower gastrointestinal [GI] tracts, gallbladder, intravenous pyelogram, and chest roentgenograms was unremarkable. Sputum and cervical cytologic findings were also normal.

The patient has had no further weakness or myalgias in the past two months. She has occasional pain of her shoulder joints. Her sedimentation rate remains elevated. Tenderness at the tips of the digits persists. Treatment consists of fluocinonide ointment (0.05%) to the erythematous and periungual areas and cool-water soaks for her hands.

Discussion

DR ROY S. ROGERS: This is a fascinating case of what looks like dermatomyositis without the myositis component. We have seen in the past week an interesting husband and wife from Montana with a similar picture, the classical eruption of dermatomyositis with no myopathic findings. They are ranchers and are exposed to a variety of chemicals, and I wonder if this patient has been exposed to some insecticide or potent chemical that could be playing a role in her curious disease. The biopsy specimen was consistent with the poikilodermatous changes seen in dermatomyositis: there is epithelial atrophy and liquefaction degeneration of the basal cell layer, incontinence of pigment, and dilated vessels. I did not notice the hyperkeratotic cuticular manifestations that Dr Samitz has emphasized, but she did have periungual and cuticular telangiectasias that would be consistent with any of the connective-tissue diseases. There was no evidence of malignant neoplasms in this patient. Patients with polymyositis and dermatomyositis seem to have a disorder of cell-mediated immunity in which the lymphocytes, probably T-lymphocytes, are responsible for attacking the muscles. Lymphotoxin (which is a product of T-lymphocytes) is generated by the lymphocytes attacking the muscles. In addition, muscle antigens, though crude in nature, have been shown to cause lymphocytes harvested from patients with these disorders to release lymphokines, such as the migration inhibition factor for macrophages. This would then lead one to wonder if we could study delayed hypersensitivity reactions to see if those are intact. If not, one would wonder about malignancy, since it has been reported that patients with dermatomyositis who have malignant neoplasms also have a profound diminution in circulating T cells, whereas they have the normal number of B cells.

DR FREDERICK MALKINSON: Although cases of dermatitis without myositis are well recognized, they are rare. I would make a plea for observation and continued study only, rather than submit her to any kind of systemic therapy. This treatment approach might have to be modified in the relatively rare cases where dermatitis is finally followed, months or years later, by the advent of muscle involvement.

Are these patients any more susceptible to malignant neoplasms than normal persons? Patients with polymyositis without the dermatitis seem to be much less susceptible to the development of cancer. Perhaps the inflammatory changes in the skin per se are the critical factors, reflecting an increased tendency to develop malignant neoplasms. There are so few patients with dermatomyositis without myositis that have been followed up long-term that this question is currently unsettled. I would not altogether rule out the possibility that malignant neoplasms might complicate this picture sooner or later, however.

DR MARIA MEDENICA: Patients with dermatomyositis and underlying malignant neoplasms usually have less-pronounced manifestations of myositis. Serum enzyme levels are slightly elevated, but the dermatitis is usually acute and much more widespread.

DR RICHARD WINKELMANN: I have never seen malignant neoplasms develop in a case of this kind, and we have followed up a number of similar cases. I believe that this falls into that same category as discoid lupus erythematosus. Most cases of discoid lupus erythematosus do not progress to more severe disease. We recognize them as strictly cutaneous, and we can, with our more-sophisticated techniques, narrow down a small number of indeterminate cases that need to be followed up with the question of systemic involvement. The same is true for periarteritis nodosa. I believe that if we do not find a serious disease at the time we see the patients in the full flower of the eruption, the chances are they will not develop it. We should recognize that it does indicate a better prognosis. I would corroborate what Dr Malkinson said about conservatism for these patients. Indomethacin has been our form of therapy for patients of this kind. I am not sure it is entirely necessary, but it has provided some antiinflammatory action for them.

DR MARVIN S. KAGEN: Chlorothiazide (Diuril) or hydrochlorothiazide (Hydrodiuril) can produce a lupus erythematosus-like

picture. I had a patient who was being treated for hypertension with a chlorothiazide who developed subacute systemic lupus erythematosus, which disappeared after stopping the drug. In this case, the woman is receiving chlorthalidone (Hygroton), and it may be a good idea to stop that medication to see if it would affect the picture. We know that a drug reaction can simulate any eruption, and maybe this is the first case of a dermatomyositis-like syndrome due to chlorthalidone. In early cases of dermatomyositis, the patient may have no symptoms except erythema on the neck, forehead, and eyelids, with erythematous papules appearing later on the fingers and hands. The serum enzyme levels may be elevated several weeks before weakness appears.

Multiple Subcutaneous *Pseudomonas* Abscesses. Presented by WILLIAM STORINO, MD, ASANEE LERTSBURAPA, BRUCE BENNIN, MD.

This 45-year-old woman's current problem began in June 1974, when she developed a low-grade fever and subcutaneous nodules in her axillae and perineal area. The lesions increased in number and size, and she was admitted to Cook County Hospital on July 7, 1974. She had a history of tuberculous osteomyelitis of the spine at the age of 1 year and three years ago had active pulmonary tuberculosis. She has intermittently received antituberculosis medications for most of her life. Two years ago, she was found to be diabetic and was treated with insulin. She has no evidence of diabetes now. There is also a past history of ethanolism. The patient has had various "allergic" reactions to penicillin, tetracycline, chlorpromazine (Thorazine), aspirin, and gentamicin sulfate.

Results of physical examination showed multiple, firm, movable subcutaneous nodules 3 to 5 cm in diameter (Figure). Most lesions were tender but not erythematous. The areas of predilection were the breasts, axillae, and perineum. The thighs and abdomen were also involved to a lesser extent, but the face was spared. She also had a palpable smooth liver, measuring 16 cm.

The following laboratory tests were normal: complete blood cell count; urinalysis; serum electrolytes; VDRL (test for syphilis); SGOT; SGPT; creatine phosphokinase; serum bilirubin; serum albumin; globulin; antinuclear, antimitochondrial, and anti-smooth-muscle antibodies; immunoglobulin electrophoresis; 17-OH corticosteroids and 17-ketosteroids; serum cortisol; cold agglutinins; EKG; upper GI tract series, intravenous pyelogram, fungal serologies; and a gallium scan. The following laboratory tests were abnormal: chest roentgenogram showed a right lower lobe calcified nodule. Barium enema showed diverticulosis. Cultures of purulent material and tissue from abscesses yielded *Pseudomonas aeruginosa* and were negative for fungi and mycobacteria. All blood cultures were negative. A battery of immunologic studies was within normal limits.

A biopsy specimen from a nodule showed a chronic inflammatory cell infiltrate in the dermis and subcutis. Intermixed were also foamy histiocytes and foreign-body giant cells. A few giant cells contained nondoubly refractile amorphous filaments in the cytoplasm.

Large subcutaneous cold abscess on anterior part of thigh.

The patient received a three-week course of gentamicin, achieving blood levels ten times above the minimal inhibitory concentration for *Pseudomonas*. The lesions improved, but never completely resolved. New lesions have continued to form, some healing spontaneously and others requiring incision and drainage. No evidence of visceral involvement or of any constitutional symptoms or signs has been found.

Discussion

DR WINKELMANN: This patient has had tuberculosis in the past, for which she has received multiple forms of therapy, including isoniazid, aminosalicylic acid, and streptomycin sulfate. It occurred to me that isoniazid is one of the drugs that can induce lupus erythematosus. I carefully examined this woman with abscesses and inflammatory disease of the subcutaneous tissue to see if there was evidence of a lupus panniculitis. I did not find any satisfactory evidence for that. She appeared chronically ill. The subcutaneous lesions were chronic with hemosiderosis pigmentation and a chronic fibrotic inflammatory reaction.

I wondered whether this might be one of those unusual factitial cases of panniculitis that Dr Forstrom and I reported in the ARCHIVES. *Pseudomonas* disease that I have seen has been associated with an acute, febrile, severely wasting illness, and I found this woman outside my experience. This was why I was looking for an alternative explanation for her problem. I would not be at all surprised if we found on biopsy some refractile material or some evidence that she has been injecting some of these areas, or some other explanation for her panniculitis. The histologic findings do not permit me to speculate on what other cause the panniculitis might be. If it were an acute panniculitis, many differential diagnostic possibilities would have to be considered. I was not happy with explaining this as a pyogenic infection of the subcutaneous tissue.

DR ALBERT SLEPYAN: I recall a recent patient in whom, after many months of observation, a diagnosis of nocardiosis was made by culturing old tissue containing a pocket of activity deep within the tissue. I suggest repeating the culture studies.

DR BRUCE BENNIN: The problem is how the abscesses are taking seed. Originally it was believed that there was some internal nidus. This possibility was evaluated, but no nidus was found—not surprising in light of the lack of constitutional symptoms of the patient. A second possibility was some immunodeficiency, but both cell-mediated and humoral immunity appear intact. A third possibility was self inoculation. We believed it would be difficult to inject pure *Pseudomonas* into multiple sites at various times, unless she had access to pure *Pseudomonas* cultures or withdrew material for injection from existing abscesses. She has been in the hospital for three months and has carefully been observed by the house staff and nurses. The possibility of placing a cast over the sites of predilection has been entertained; however, the lesions develop so slowly that it was believed that this was not practical.

The way they start out is not characteristic of most abscesses. However, cold abscesses, as in the Job's syndrome,[1] sometimes begin like this. The patient's IgE level was normal.[2] A fourth possibility was superinfection, as has been mentioned previously. There is no evidence to support this. A fifth possibility was that of primary cutaneous infection. Maibach and Kligman[3] described multiple cutaneous cold abscesses in children. These were of staphylococcal type, and were believed to be due to direct access through the eccrine sweat glands. Since many of our patient's lesions are in the area of apocrine gland concentration, some variant of this entity might be a possibility. We still do not know how the organisms gain access to the patient, nor do we know of any particular effective therapy. She is hypersensitive to most antibiotics. Even the most effective in vitro antibiotic apparently was not able to reach sufficient tissue levels to eradicate the organism. About 20 cultures of the *Pseudomonas* have shown the same antibiotic sensitivities. Typing is being done now to confirm whether organisms from all sites are identical. Cultures have also been made from various sites on the skin surface, nails, and stools to try and locate a similar organism, but these have been to no avail.

Nonproprietary Names and Trademarks of Drugs

Chlorpromazine—*Chlor-PZ, Cromedazine, Promachel, Thorazine.*
Chlorthalidone—*Hygroton.*
Fluocinonide—*Lidex, Topsyn.*
Gentamicin sulfate—*Garamycin.*
Methyldopa—*Aldomet.*
Phenformin hydrochloride—*DBI, DBI-TD, Meltrol.*

References

1. Davis SD, Schaller J, Wedgwood RJ: Job's syndrome. *Lancet* 1:1013-1015, 1966.
2. Hill HR, Ochs HD, Quie PG, et al: Defect in neutrophil granulocyte chemotaxis in Job's syndrome of recurrent "cold" staphylococcal abscesses. *Lancet* 2:617-619, 1974.
3. Maibach HI, Kligman AM: Multiple sweat gland abscesses. *JAMA* 174:140-142, 1960.

IN SKIN INFECTIONS, WHERE CLEANLINESS REQUIRES MORE THAN SOAP

BETADINE® Skin Cleanser

Degerms as it cleanses

Patients can use BETADINE Skin Cleanser to degerm and cleanse face, hands and body, gently and thoroughly—particularly when it is essential to prevent autoinoculation of new sites, as may be the case in infected acne pimples.

BETADINE Skin Cleanser, with its rich, golden lather, provides these advantages:

- Prompt, broad-spectrum microbicidal action—kills both gram-positive and gram-negative bacteria (including antibiotic-resistant strains), fungi, viruses, protozoa and yeasts.
- Maintains microbicidal activity in the presence of blood, pus and serum.
- Virtually nonirritating to skin and mucosa.*
- Nonstaining to skin and natural fabrics.

Supplied: 4 fl. oz. plastic bottles.

* In the rare instance of local irritation or sensitivity, discontinue use by the individual.

Purdue Frederick © COPYRIGHT 1976, THE PURDUE FREDERICK COMPANY

NORWALK, CONN. 06856 A8196 172075



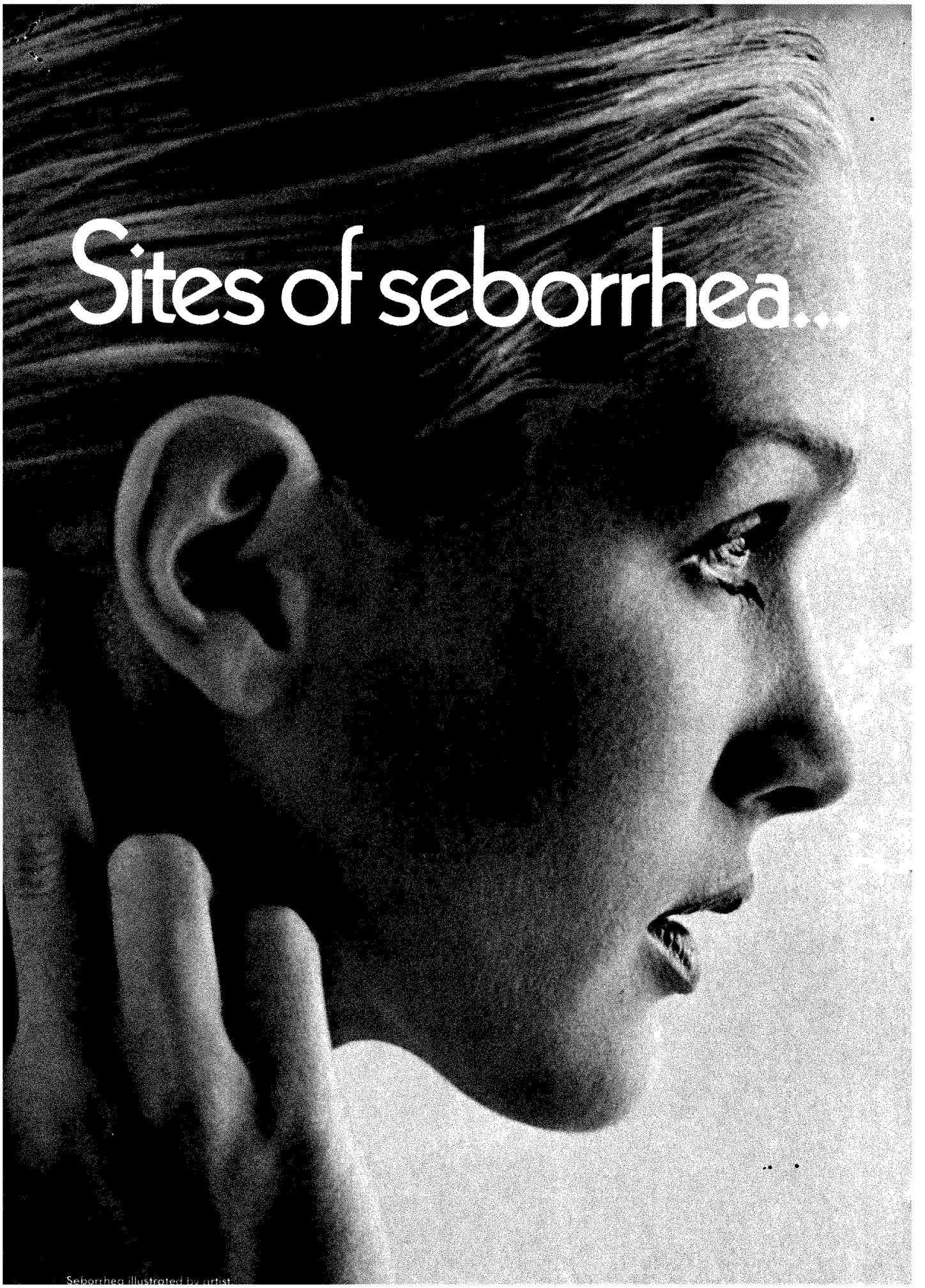
Sites of seborrhea...
Seborrhea illustrated by artist

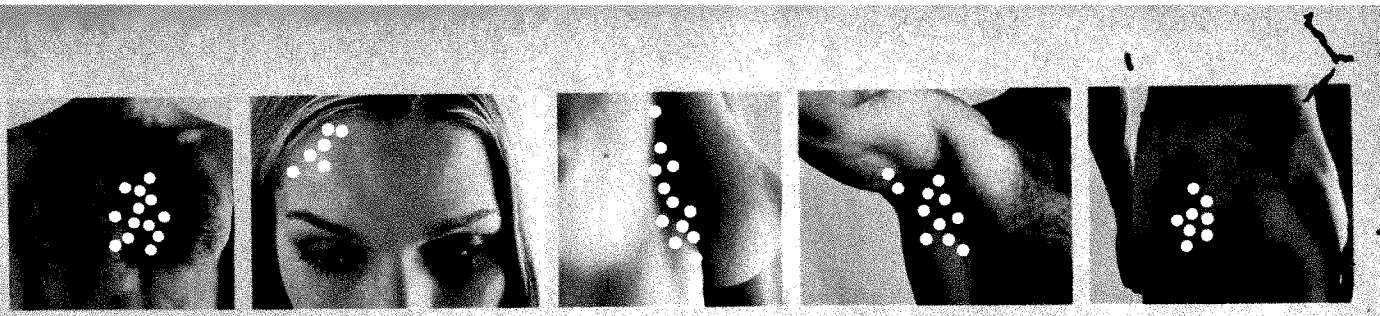

spots for

Uticort™

(betamethasone benzoate)

a highly effective topical steroid in a special base

UTICORT contains the fluorinated corticosteroid ester — betamethasone benzoate 0.025% — in a specially formulated, clear, self-liquefying gel base to increase steroid activity.
Patients with seborrheic dermatitis treated with UTICORT improved 86% in an average of 11.6 days.

liquefies on application for better surface contact

UTICORT is especially valuable in the treatment of seborrheic dermatitis on hairy areas of the body.

cosmetically acceptable

UTICORT dries to a clear film and can be used confidently on either smooth or hairy skin areas. Moreover, it is greaseless, nonstaining, and nonsticky.

preservative free

Contains no parabens or other potentially sensitizing preservatives.

Brief summary of prescribing information

INDICATIONS. Uticort Gel (betamethasone benzoate) is intended for relief of the inflammatory manifestations of corticosteroid-responsive dermatoses.

CONTRAINDICATIONS. Topical steroids are contraindicated in viral diseases of the skin, such as varicella and vaccinia. Topical steroids are contraindicated in patients with a history of sensitivity to any of the components of the preparation.

This preparation is not for ophthalmic use.

PRECAUTIONS. If irritation develops, the gel should be discontinued and appropriate therapy instituted. In the presence of an infection, the use of appropriate antifungal or antibacterial agents should be instituted. If a favorable response does not occur promptly, the corticosteroid should be discontinued until the infection has been adequately controlled.

If extensive areas are treated, or if the occlusive technique is used, the possibility exists of increased systemic absorption of the corticosteroid, and suitable precautions should be taken.

Although topical steroids have not been reported to have an adverse effect on pregnancy, the safety of their use in pregnant females has not absolutely been established. Therefore, they should not be used extensively on pregnant patients, or in large amounts, or for prolonged periods of time.

Due to the alcohol content of the vehicle, Uticort Gel (betamethasone benzoate) may cause mild, transient stinging without irritation if used on excoriated skin.

ADVERSE REACTIONS. The following local adverse reactions have been reported with topical corticosteroids: burning sensations, itching, irritation, dryness, folliculitis, secondary infection, skin atrophy, striae, hypertrichosis, acneform eruptions, and hypopigmentation.

DOSAGE AND ADMINISTRATION. Apply to affected areas two to four times daily as needed.

HOW SUPPLIED. N 0071-3025 Uticort Gel is supplied in 15-g and 60-g tubes.

Caution: Federal law prohibits dispensing without prescription.

PARKE-DAVIS

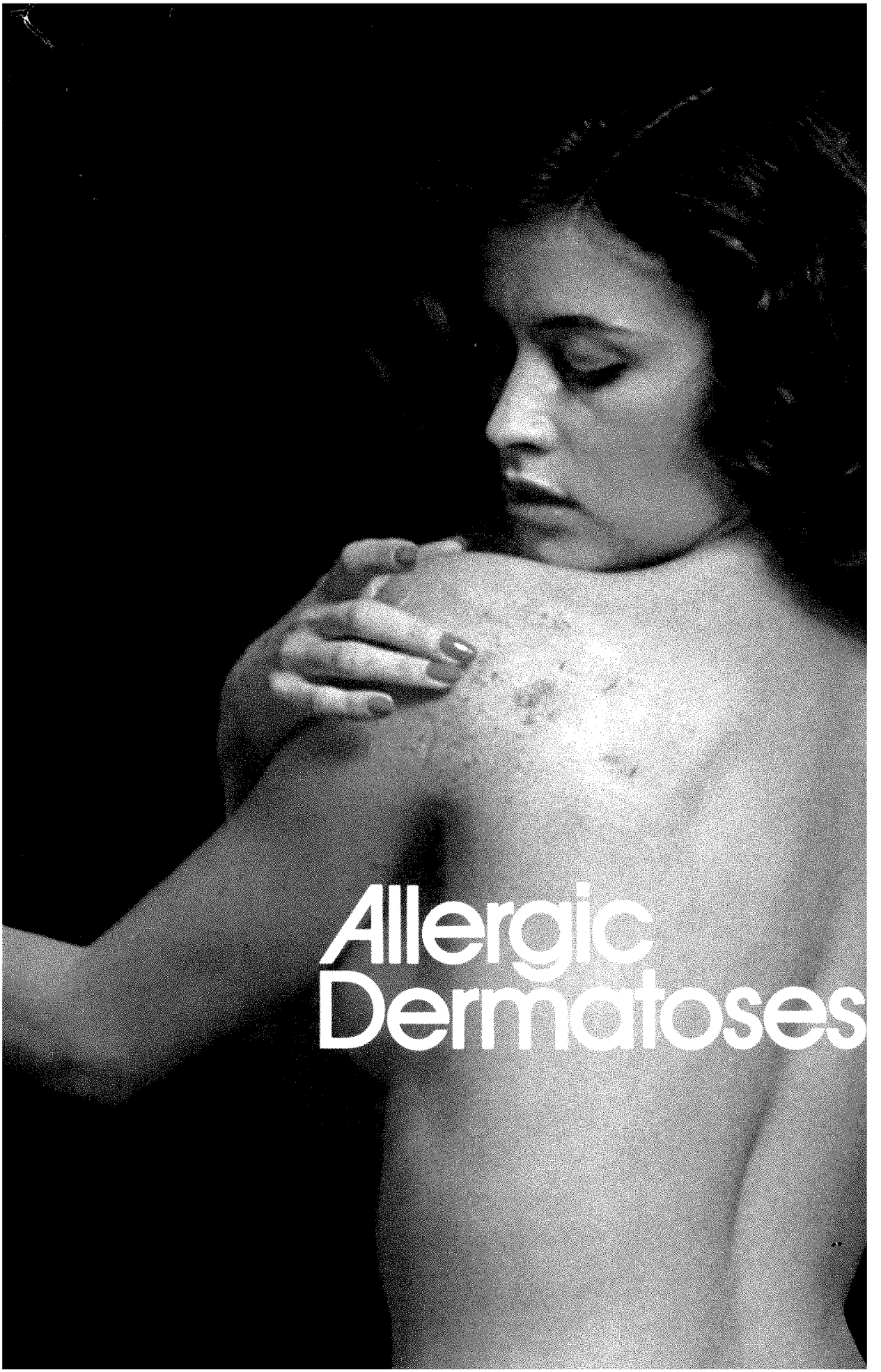
Allergic
Dermatoses

Contraindications: Hypersensitivity to hydroxyzine. Hydroxyzine, when administered to the pregnant [illegible] rat, and rabbit, induced fetal abnormalities in the rat at doses substantially above the human therapeutic range. Clinical data in human beings are inadequate to establish safety in early pregnancy. Until such data are available, hydroxyzine is contraindicated in early pregnancy.

Precautions: Hydroxyzine may potentiate the action of central nervous system depressants such as meperidine and barbiturates. In conjunctive use, dosage for these drugs should be reduced. Because drowsiness may occur, patients should be cautioned against driving a car or operating dangerous machinery.

Adverse Reactions: Drowsiness may occur; if so, it is usually transitory and may disappear in a few days of continued therapy or upon dosage reduction. Dryness of the mouth may occur with higher doses. Involuntary motor activity, including rare instances of tremor and convulsions, has been reported, usually with higher than recommended dosage.

Supply: Tablets, containing 10 mg, 25 mg, or 50 mg hydroxyzine hydrochloride, 100's and 500's; Tablets, containing 100 mg, 100's; Syrup, containing 10 mg per teaspoonful (5 ml) and ethyl alcohol 0.5% v/v, pint bottles.

Before prescribing or administering, see package circular.

with strong emotional overlay

the cause can be obscure

Factors precipitating allergic dermatoses with strong emotional overlay, which can range from allergens to anxiety, can be difficult to identify.

successful treatment often includes

Atarax® (hydroxyzine HCl)

TABLETS: 10 mg, 25 mg, 50 mg, and 100 mg

- rapid antianxiety action
- demonstrated antihistaminic activity

ROERIG Pfizer

A division of Pfizer Pharmaceuticals

New York, New York 10017

Books

Skin Surgery, ed 4, edited by Ervin Epstein, MD, and Ervin Epstein, Jr, MD, 839 pp, with illus, $98.75, Springfield, Ill, Charles C Thomas Publisher, 1976.

The fourth edition of *Skin Surgery*, like the third edition, is the premiere textbook on dermatologic surgery. Nearly every surgical aspect of our specialty is well covered in the clearly printed, easily read, 839 glossy pages of this quality book.

The subject matter has been reorganized to accentuate the increased importance of cryosurgery and chemosurgery. In this textbook, chemosurgery includes chemotherapy, chemical peels, and chemosurgery for microscopic controlled excision of cutaneous cancers. Important chapters have been added dealing with medico legal problems, maxilofacial prostheses, laser skin surgery, cryotherapy for acne, and local anesthetics. Two excellent new contributions are the "Diagnosis and Treatment of Surgical Emergencies" by Krull and Ande and "Skin Surgery of the Eyelids" by Beard. Nearly all of the chapters have been updated, including many good-quality photographs. However, a few surgically treated conditions were less well covered or deleted—conditions I think are not uncommonly encountered by the dermatologist: rhinophyma, hidradinitis suppurativa, and chondrodermatitis nodularis helicis.

One addition (prominently located in the prefice) that I consider inappropriate is the reprinting of "Max the Knife" by Ralph Leukart. This poem is clever and portrays every practicing physician's daily frustrations, but it does not belong in the introduction to this major and serious medical textbook. In the same vein, the last two chapters, "Gimmicks and Gadgets in Skin Surgery" and "Do It Yourself Instruments," detract from the major effort of this book and of our specialty in general.

One hundred dollars is a great deal of money for a textbook. To me, however, the value of the book justifies the price. A week-long seminar on skin surgery (at a far greater cost) could not cover the volume and scope of the material presented here. As I read the book, I graded each chapter. By my arbitrary scale, 75% of the chapters are good to excellent, with only a few chapters irrelevant or outdated.

The editors recognize the advantages and disadvantages of a multiauthored book and purposely did not delete opinions contrary to their own. Without excessive repetition, various opinions are presented on most subjects. Samuel Ayer's conservative views on chemical face peels for wrinkling is balanced by Thomas Bakers aggressive presentation. Many contributors present a historical viewpoint in their particular subjects, which adds to our understanding of the natural growth of dermatologic surgery and highlights our progress.

However, in several instances I would have been happier if the editors had editorialized more. For example, in the chapter "Deep Cryosurgery" by Andrew Gage, a surgeon, cryosurgery is recommended for treatment of recurrent cutaneous tumors. Most dermatologists know of the high second recurrence rate from the reapplication of a "blind" modality for recurrent tumors. Other contributors, careless with cure-rate statistics, were left unchallenged by the editors.

For the fifth edition of *Skin Surgery*, I hope the editors include more on skin closures and skin flaps, more on suture materials, and add the treatment of keloids. Until then, this excellent book is rightfully the keystone of skin surgery.

SAMUEL J. STEGMAN, MD
Burlingame, Calif

Cancer, Epidemiology and Prevention: Current Concepts, edited by David Schottenfeld, 574 pp, $46.41, Springfield, Ill, Charles C Thomas Publisher, 1975.

This volume brings into focus a number of aspects of the cancer problem, ranging from economic costs to immunologic parameters. As with all multiauthored books (there are 37 contributors), there is some unevenness to the presentations. However, over all it is well done. Perhaps the three chapters of most interest to the dermatologic community concern ionizing radiation, sunlight, and immunovirology. The review by Farrington Daniels Jr on sunlight and cancer is thorough and clearly presented. It is one of the highlights of the book. The chapter on immunovirology, by W.D. Winters and D.L. Morton, is also informative. In contrast, the section on ionizing radiation is somewhat less complete.

This book would not be of interest to dermatologists in general. However, it would be of value to those involved in the various aspects of cancer research. It certainly belongs in medical center libraries as an important reference volume.

JOHN H. EPSTEIN, MD
San Francisco

KENALOG® SPRAY
Triamcinolone Acetonide Aerosol N.F.

DESCRIPTION: Kenalog Spray (Triamcinolone Acetonide Aerosol N.F.) provides 3.3 mg. triamcinolone acetonide per 50 grams in an isopropyl palmitate vehicle with alcohol (4.7%) and propellants.

INDICATIONS: Kenalog Spray (Triamcinolone Acetonide Aerosol N.F.) is indicated for relief of the inflammatory manifestations of corticosteroid-responsive dermatoses.

CONTRAINDICATIONS: Topical steroids are contraindicated in viral diseases of the skin, such as vaccinia and varicella, and in patients with a history of hypersensitivity to any product component. This preparation is not for ophthalmic use. Topical steroids should not be used when circulation is markedly impaired.

WARNINGS: Usage in Pregnancy— Although topical steroids have not been reported to have an adverse effect on the fetus, the safety of their use during pregnancy has not been absolutely established; therefore, they should not be used extensively on pregnant patients, in large amounts, or for prolonged periods of time.

PRECAUTIONS: Administer suitable antifungal or antimicrobial therapy if infection exists; if there is not a prompt, favorable response, discontinue the corticosteroid until the infection has been adequately controlled. Discontinue the drug and institute appropriate therapy if irritation develops. If extensive areas are treated or if the occlusive technique is used, the possibility exists of increased systemic absorption of the corticosteroid and suitable precautions should be taken. When used about the face, the eyes should be covered and inhalation of the spray avoided.

ADVERSE REACTIONS: The following local adverse reactions have been reported with topical corticosteroids either with or without occlusive dressings: burning sensations, itching, irritation, dryness, folliculitis, secondary infection, skin atrophy, striae, miliaria, hypertrichosis, acneform eruptions, maceration of the skin and hypopigmentation; contact sensitivity to a particular dressing material or adhesive may occur occasionally. Some patients (particularly those with very dry skin or dry lesions) may find the cooling effect of the spray objectionable or complain of a transient burning or stinging sensation.

For full prescribing information, consult package insert.

HOW SUPPLIED: Kenalog Spray (Triamcinolone Acetonide Aerosol N.F.) is available in spray dispenser cans of 50 and 150 g. with adapter.

SQUIBB®

©1977 E.R.Squibb & Sons, Inc. 327-503

"INTRACTABLE" SCALP PSORIASIS

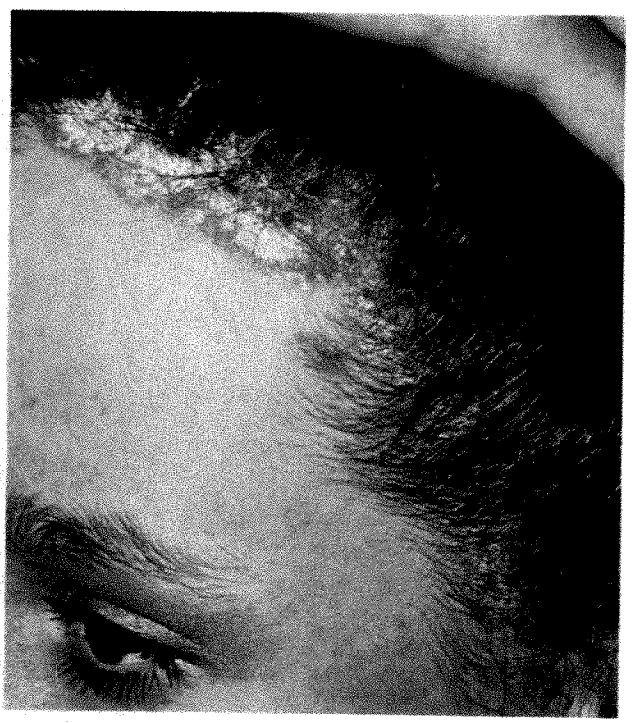

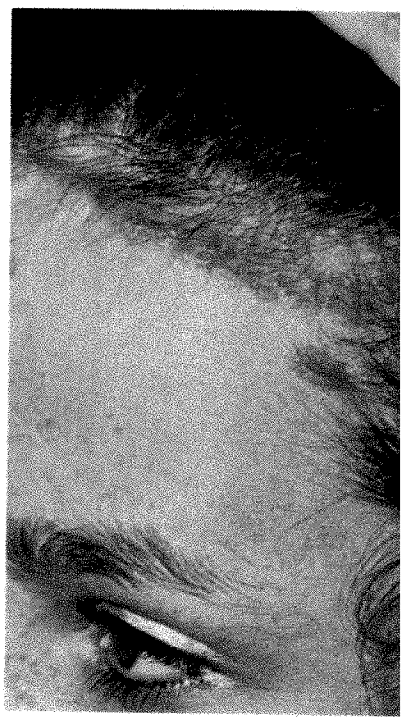

MARCH 4, 1977

A 15-year-old patient complaining of severe, intractable psoriasis of the scalp. Previous therapy with tar shampoo, keratolytic agents and fluorinated topical steroids had been unsuccessful. Because prior topical agents had been difficult to apply, Kenalog® Spray b.i.d. was prescribed.

Patient reported that pruritus had been relieved promptly. Marked improvement observed at this time: absence of scales, decrease in erythema and central clearing of plaques. Patient continuing on Kenalog® Spray b.i.d.
Case history on file at Squibb Institute for Medical Research.

AF

A CASE FOR KENALOG® SPRA

TRIAMCINOLONE ACETONIDE AEROSOL N.F.

See adjacent column for brief summary.

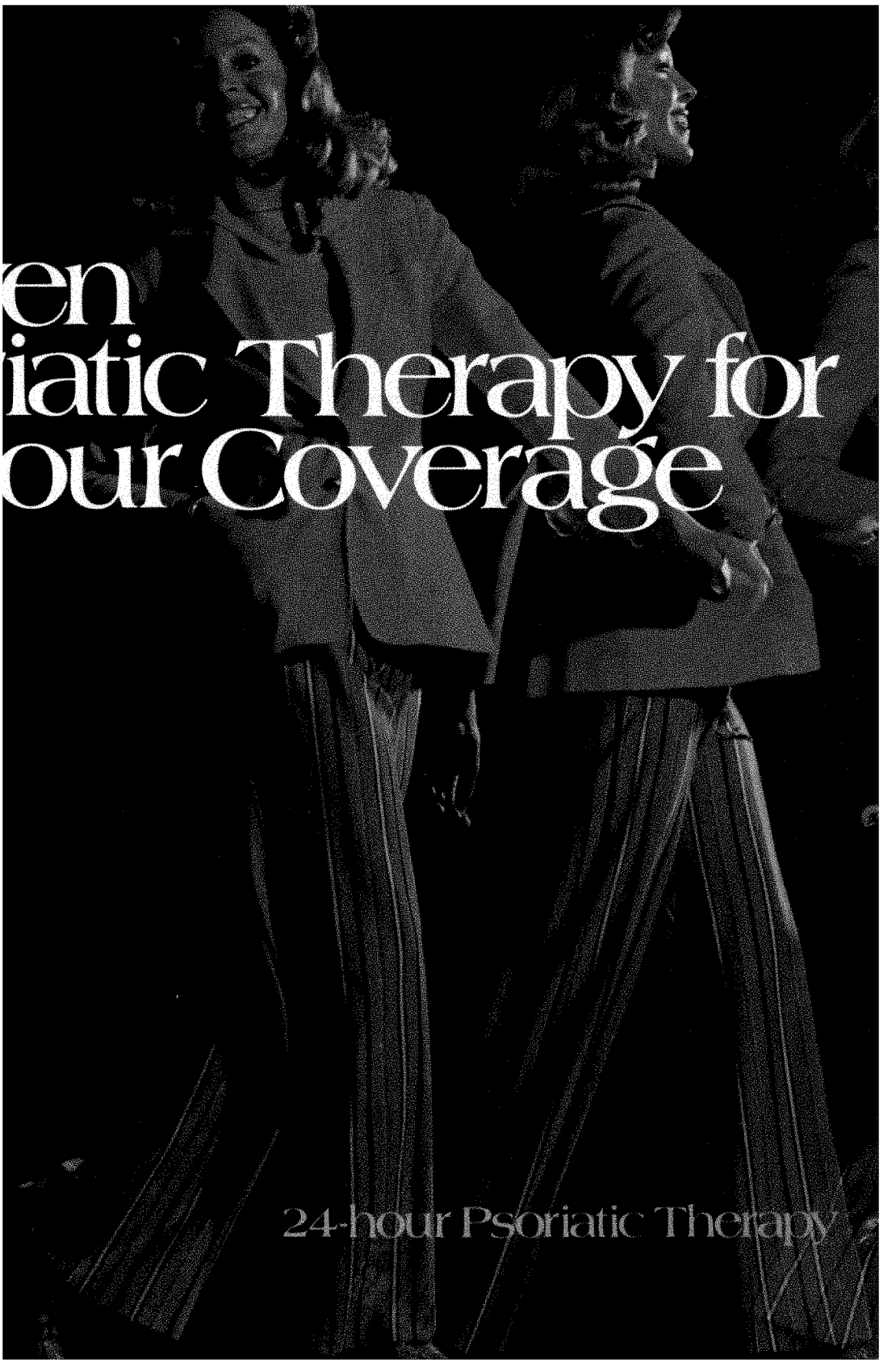
en
iatic Therapy for
our Coverage
24-hour Psoriatic Therapy

estar™

Therapeutic Tar Gel

Tar odor won't betray **estar** therapy. Proven **estar** Therapeutic Tar Gel is equivalent to 5% crude coal tar in everything but odor. No sticky, greasy residue to remain on the skin . . . proven therapy to control the formation of psoriatic scales and reduce itching with antipruritic action so that scratching is less likely.

The gel base enables the patient to apply **estar** evenly and smoothly. Tar therapy that doesn't smell like it . . . **estar** Therapeutic Tar Gel.

Balnetar®

Water-dispersible Emollient Tar

Change ordinary water into a psoriatic treatment for patients who bathe before bedtime. **Balnetar** can work through the night to provide keratoplastic, antieczematous, and antipruritic action. It lubricates and moisturizes the skin to relieve and help prevent excessive dryness while it softens and aids in the removal of scales and crusts. One to three capfuls of **Balnetar** added to a tub of warm water can extend the effect of **estar** Therapeutic Tar Gel to twenty-four hour tar therapy. The active ingredient in **Balnetar** treats the skin without staining it or the porcelain of the tub.

Sebutone®

Therapeutic Tar Shampoo

When psoriasis finds its way to the scalp, **Sebutone** can penetrate, soften, and remove scales, crusts, and excess oil with its chemically and biologically standarized tar. Microfine particles of tar remain on the scalp for up to three days (as shown with Wood's light) providing prolonged residual action. The fresh, clean fragrance and excellent cleansing properties of **Sebutone** make no other shampoo necessary when treating scalp psoriasis or any stubborn case of seborrhea or dandruff.

ith estar/Balnetar/Sebutone

Please see product information on next page.

WESTWOO
PHARMACEUTICALS
Buffalo, New York 14
In Canada, Belleville, Ontario K8

estar™
Therapeutic Tar Gel

Composition: Westwood® Tar (biologically equivalent to 5% Coal Tar USP) in hydro-alcoholic gel (29% alcohol).

Actions and Uses: A therapeutic aid in the treatment of psoriasis and other tar responsive dermatoses such as eczema (atopic dermatitis, lichen simplex chronicus, nummular eczema) and seborrheic dermatitis. **estar** is suitable for use in a modified Goeckerman regimen, either in the hospital or on an outpatient basis; it also can be used in follow-up treatment to help maintain remissions.

Contraindications: estar should not be applied to acutely inflamed skin or used by individuals who are known to be sensitive to coal tar.

Dosage and Administration:

Psoriasis:
The patient should massage **estar** into affected areas, once or twice per day or as directed by physician. Rub in well, allow the gel to remain for five minutes, and then remove excess by patting with tissues.

Chronic atopic dermatitis, Lichen simplex chronicus, Nummular eczema, and Seborrheic dermatitis:

One or two applications per day, as described above, are suggested. If dryness occurs, an emollient may be applied one hour after **estar.**

Caution: AFTER USING, PROTECT TREATED AREAS FROM SUNLIGHT UNLESS DIRECTED BY PHYSICIAN. DO NOT USE ON HIGHLY INFLAMED OR BROKEN SKIN. If used on the scalp, temporary discoloration of blond, bleached, or tinted hair may occur. If undue irritation develops or increases, discontinue use and consult physician. AVOID CONTACT WITH EYES. In case of contact, flush eyes with water.

Slight staining of clothing may occur. Standard laundry procedures will usually remove stains.

For complete prescribing information, see PDR.

SUPPLIED: 3 oz. plastic tube.

Balnetar®
Water-dispersible Emollient Tar

CONTAINS: WESTWOOD® TAR (Equivalent to 2.5% crude coal tar U.S.P.) mineral oil, and lanolin oil.

Balnetar is an important adjunct in the management of a wide range of dermatoses, including:

Atopic dermatitis
Psoriasis
Chronic eczematoid dermatitis
Eczematoid dermatitis
Seborrheic dermatitis

Suggested for use in modified Goeckerman regimen.

Directions:
Balnetar should always be used with water—either added to water or rubbed into wet skin.

Bath: Add 1 to 3 captuls to a tub of warm water. Do not use soap. Soak for 10 to 20 minutes. Pat dry. Frequency depends on nature and severity of condition.

Direct Application: Pat off excess with tissue or old towel to help minimize staining of clothing or linens.

Scalp Application: Mix 2 to 3 captuls with ¼ cup of water. Rub into scalp with fingertips. Apply once a day, preferably before bedtime. A therapeutic shampoo may be used the following morning.

Contraindication: Not indicated when acute inflammation is present.

CAUTION: If irritation persists, discontinue use and consult physician. In rare instances, temporary discoloration of blond, bleached, or tinted hair may occur. In rare cases, Balnetar may cause allergic irritations attributable to coal tar. Keep out of the reach of children. AVOID CONTACT WITH EYES.

PRECAUTION: After use of Balnetar, avoid exposure to sunlight unless otherwise directed by physician. GUARD AGAINST SLIPPING IN BATHTUB. TO AVOID STAINING, DO NOT USE IN FIBER GLASS BATHTUBS.

SUPPLIED: 8 fl. oz. plastic bottles.

Sebutone®
Therapeutic Tar Shampoo

CONTAINS: WESTWOOD® TAR (equivalent to 0.5% Coal Tar U.S.P.) sulfur 2% and salicylic acid 2% in SEBULYTIC® brand of unique penetrating surface-active combination of soapless cleaners and wetting agents.

CAUTION: If undue skin irritation develops or increases, discontinue use and consult physician. In rare instances, temporary discoloration of blond, bleached, or tinted hair may occur. For external use only. Keep out of the reach of children. AVOID CONTACT WITH EYES. IN CASE OF CONTACT, FLUSH EYES WITH WATER.

SUPPLIED: 4 and 8 oz. bottles and Sebutone Cream in 4 oz. tubes.

WESTWOOD
PHARMACEUTICALS INC.
Buffalo, New York 14213
In Canada, Belleville, Ontario K8N 1E2

News and Notes

Dermatopathology Fellowship.—The Dermatopathology Fellowship that will be offered at the New York University School of Medicine from 1979 to 1980, is designed to prepare dermatologists and pathologists for a career in dermatopathology within a medical center environment. This will be accomplished by full participation in an active dermatopathology laboratory that will function within a department of clinical dermatology.

The fellow will learn the optimal handling of specimens in the laboratory and will study microscopically the more than 200 skin specimens that are processed daily in the laboratory. The program will include attendance at clinical conferences in the Department of Dermatology and twice-weekly dermatopathology luncheon conferences where subjects of interest will be discussed in depth. In addition, the fellow will be actively involved in planning and presenting the weekly Dermatopathology Conference.

Stipend is $18,000. Dr A. Bernard Ackerman, Director of Dermatopathology, is in charge of this program and will serve as tutor and supervisor. For further information, contact A. Bernard Ackerman, MD, 562 First Ave, New York, NY 10016, or call (212) 679-3200, ext 2766.

Dermatologic Surgery Fellowship.—The Dermatology Department of the Cleveland Clinic Foundation announces a fellowship in dermatologic surgery. This is a 12-month program intended for persons who have completed three years of an approved dermatology residency program. A minimum of 50% of the fellow's time will be devoted to intensive training and experience in Mohs' chemosurgery, which will lead to eligibility for membership in the American College of Chemosurgery. The remainder of the fellow's time will be devoted to excisional surgery, dermabrasion, hair transplantation, and other surgical modalities. Didactic material includes surgical anatomy, the biology of wound healing, and dermatopathology. Considerable emphasis will be placed on the interdisciplinary approach to cutaneous surgical problems, with ample exposure to plastic surgery, ophthalmology, otorhinolaryngology, and radiation therapy. Furthermore, research in dermatologic surgery or a related basic science area will be encouraged.

A stipend commensurate with graduate level V training will be provided by the Cleveland Clinic Educational Foundation. The first available vacancy for this fellowship is Jan 1, 1978. Inquiries should be sent to Philip L. Bailin, MD, head, Section of Chemosurgery, Department of Dermatology, Cleveland Clinic Foundation, 9500 Euclid Ave, Cleveland, OH, 44106.

Seminar.—The American Society for Dermatologic Surgery announces a seminar on dermabrasion and chemical peel Sept 30 through Oct 2, 1977 in New Orleans. The course moderator will be George Farber, MD. For further information write to Dr Farber at 144 Elk Pl, Suite 1604, New Orleans, LA 70112.

Scleroderma Research Award for 1977.—The Monterey Bay Scleroderma Foundation announces its first $1,000 annual award for scleroderma research for 1977. The establishment of an award carries with it the hope that it will act as an incentive to study this chronic disabling disease.

The award is designed for the individual or group whose investigative work in this field has been outstanding. Names of applicants for the award, together with supporting data should be submitted for consideration by Dec 1, 1977. Results of the research must have been presented at a scientific medical meeting or published in a recognized medical journal.

The award recipient will be determined by a committee of five men. If in the committees' opinion, none of the applications reflect outstanding research, no award will be given for that year. Address all communications to Denny L. Tuffanelli, MD, Department of Dermatology, University of California School of Medicine, San Francisco, CA 94143.

Skin Tumor Seminar.—There will be a seminar titled "Tumors Involving the Skin" on April 12, 1978, organized by the Department of Dermatology of Roswell Park Memorial Institute (RPMI). The chairperson is Dr Ole Holtermann. For further information contact Ms Claudia Lee, Cancer Control, RPMI, 666 Elm St, Buffalo, NY 14263.

Reference Sera and Voluntary Proficiency Testing Programs for ANA and Other Tissue Antibodies.—A reference service established in 1975 through a nonprofit foundation, the International Service for Immunology Laboratories (ISIL), offers reference sera for (1) antinuclear antibodies; (2) smooth muscle and mitochondrial antibodies; (3) thyroid cell and thyroglobulin antibodies; and (4) pemphigus and pemphigoid antibodies. This service, which affords coded and uncoded reference sera, is being extended now to comply with another need of participating laboratories. That is, in addition to reference sera with known types and titers of antibodies that are available for a handling charge of $25, self-evaluation with coded sera can now be done by one of two methods. Either laboratories receive four to six coded sera on request (as before) or an annual "blind" evaluation is done. Since specimens of the first type tend to receive more than average attention, the results are open to question. For blind evaluations laboratories provide the ISIL ten to 20 copies of their "request slips" used for their routine test requests. Participating laboratories then receive serum samples with request slips on a prearranged basis. On reporting results of routine tests, they in turn receive an evaluation of their findings and, if indicated, some suggestions for adjustments and modifications of their methods.

For further information write to ISIL, Inc, 219 Sherman Hall, SUNY/Buffalo, Buffalo, NY 14214.

Mexican Board of Dermatology.—The Mexican Board of Dermatology was founded on Feb 26, 1974 in Mexico City and officially registered on Aug 26, 1974 at the Mexican National Academy of Medicine; its foundation was announced before the secretary of health and welfare on March 7, 1975. As with all other Mexican specialty boards, the aim of the Mexican Board of Dermatology is the improvement of its specialty in the country. On July 23, 1976, the Mexican Board of Dermatology awarded, without examination and on the basis of curricula vitae only, 139 diplomas to well-known and generally recognized dermatologists who had been practicing and teaching dermatology in Mexico for many years. On July 31, 1976, fifteen young dermatologists took the first written examination, and on Oct 22, 1976, they took the corresponding oral examination. Fourteen of them passed. This year, in July and October, respectively, the board will give the second written and oral examinations.

The creation of the Mexican Board of Dermatology represents a landmark in the organization and progress of dermatology in Mexico. The 15 members of the board are, as follows: Raul Aceves, MD; Miguel Ahumada, MD; Rafael Andrade, MD (president); José Barba-Rubio, MD; Luciano Domínguez, MD; Juventino Gonzáles, MD; Amado González, MD; Antonio González-Ochoa, MD; Pedro Lavalle, MD; Ernesto Macotela, MD (secretary-treasurer); Mario Magaña, MD; Jorge Peniche, MD; Ramón Ruiz-Maldonado, MD; Amado Saúl, MD; and Jorge Vega-Núñez, MD.

Practical Dermatopathology Symposium.—This two-day symposium sponsored by the Department of Dermatology, Stanford University Medical Center, will be held at the Holiday Inn in Palo Alto, Calif, on Oct 7 and 8, 1977. The course represents an approach to dermatopathology based on types of disease processes and recognition of which affords practical methods of reaching definitive diagnoses. Time will be devoted to oral mucosal lesions, mycology, and cutaneous ultrastructure, subjects not usually included in dermatopathology courses. Exercises using projected photomicrographs will provide opportunities for self-assessment and for discussion of subjects of interest to participants. American Medical Association-accredited postgraduate seminar. For information, contact: Paul H. Jacobs, MD, Department of Dermatology, Stanford University Medical Center, Stanford, CA 94305, or phone (415) 497-6101.

Research Training Fellowship Award.—The Society for Investigative Dermatology is pleased to announce that it will again offer Research Fellowship Awards. These are designed for individuals embarking on academic careers who wish to spend one or more years working primarily in basic research. This training must be obtained under the guidance of a sponsoring investigator. The Fellowships are not intended to support individuals who have substantial teaching and/or patient care commitments. The award will provide a stipend of $16,000 per year.

Applications may be obtained from: W. Mitchell Sams, Jr, MD, Secretary-Treasurer, The Society for Investigative Dermatology, Department of Dermatology, North Carolina Memorial Hospital, Chapel Hill, NC 27514. Deadline for submitting applications is Oct 15, 1977. Awards will be announced by Dec 15, 1977, and may commence any time between Jan 1 and July 1, 1978.

Workshop in Soft Tissue Surgery.—This workshop will be held Oct 7-9, 1977, in Dallas. The University of Texas Otolaryngology programs in conjunction with The American Academy of Facial Plastic and Reconstructive Surgery offer this intensive 2½-day workshop that will emphasize the basic principles and concepts in soft tissue surgery and their use in clinical situations. Didactic lectures, faculty panels, videotapes, and problem case solving sessions will be presented by a multidisciplined faculty. Laboratory periods will be conducted for practicing suture techniques, design of local skin flaps, and methods of scar camouflage. Tuition (includes $30.00 worth of instruments) is $110 for residents and $185 for practicing physicians. For information contact: Jack P. Gunter, MD, Course Coordinator, Office of Continuing Education, University of Texas Health Science Center at Dallas, 5323 Harry Hines Blvd, Dallas, TX 75235.

Fourth South African Dermatological Congress.—The Dermatological Group of the Medical Association of South Africa will hold its fourth congress in the Kruger National Park (Game Reserve), Aug 23 to 26, 1978. Principal speakers will be Dr Harry Arnold, from the United States, Professors Malcolm Greaves and Wilson Jones, from England, Dr Colin Ramsay, from Canada, and Dr Mali, from the Netherlands. In addition to topics on purely dermatological themes, there will be a symposium on skin diseases in and caused by animals, in which veterinarians who work in the game reserve will participate. Meeting times will be arranged so that there will be ample time for the viewing of wild game. For information contact the Congress Organizer, PO Box 6705, Johannesburg 2000, Republic of South Africa.

PSORIASIS
The Capricious Dermatosis

LIDEX® (fluocinonide) 0.05%
A Stabilizing Influence

Psoriasis. Mere mention of the word can make an afflicted patient cringe. And, because of the capricious, unpredictable nature of the disease, the patient rarely knows where or when it will recur.

Obviously, the goal is control. And, though varied treatment modalities are available today, none offers universal

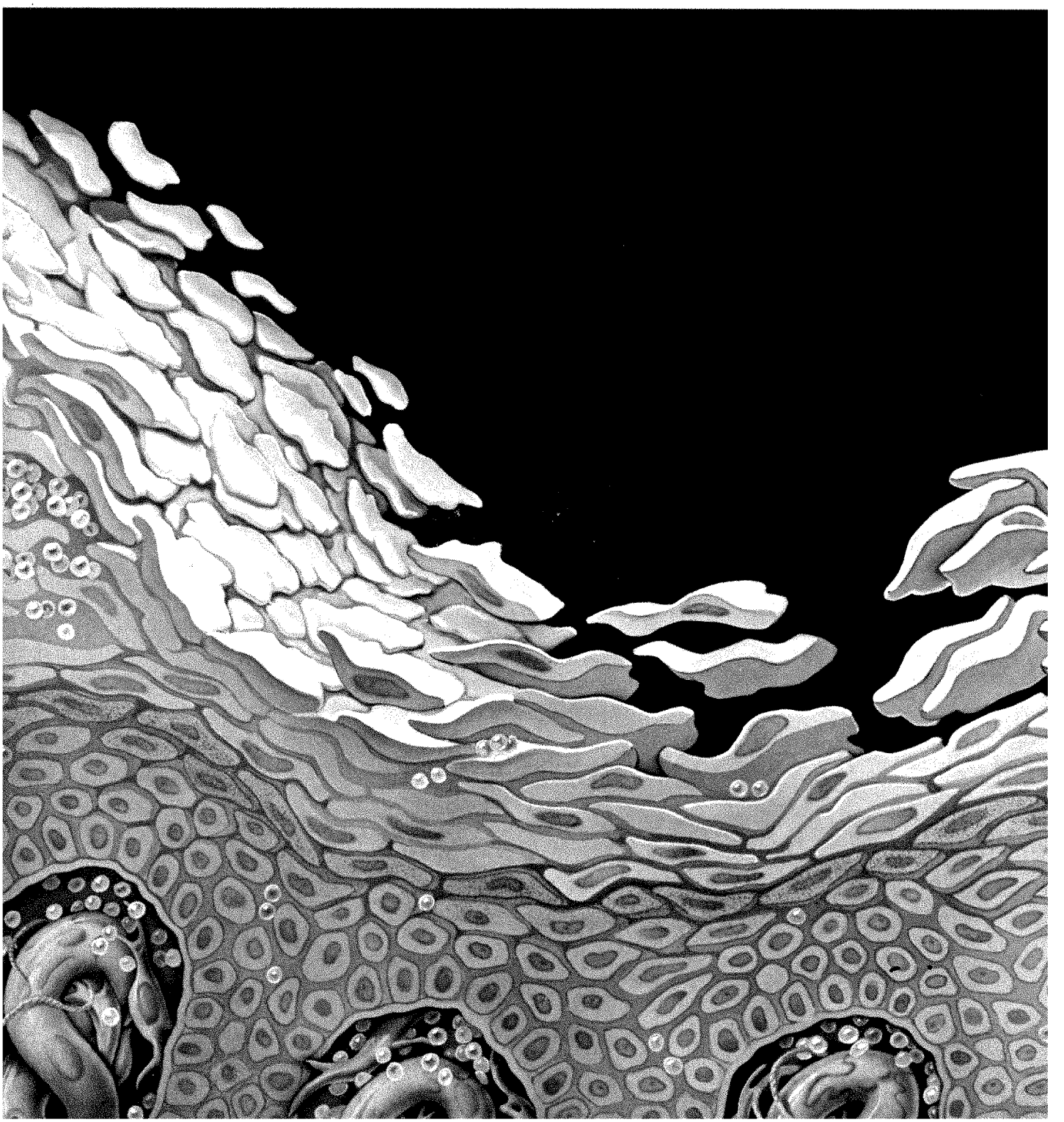

efficacy for all patients, all of the time.

Yet, very often a highly effective topical steroid, like Lidex, (fluocinonide) can help stabilize psoriasis.

Lidex. A highly effective topical steroid with anti-inflammatory, vasoconstrictive, antipruritic actions.

100% dissolved for optimal penetration, important in stages that exhibit thickened, scaly lesions.

Totally free of preservatives.

Available in cream, ointment, and Topsyn® (fluocinonide) gel.

SYNTEX

SYNTEX LABORATORIES, INC.
PALO ALTO, CALIFORNIA 94304



LIDEX® (fluocinonide)
0.05% Cream and Ointment

TOPSYN® (fluocinonide)
0.05% Gel

Summary of prescribing information

Description
LIDEX cream 0.05%, LIDEX ointment 0.05% and TOPSYN gel 0.05% contain the active compound fluocinonide. Fluocinonide, which is the 21-acetate ester of fluocinolone acetonide, has the chemical formula 6α, 9α, -difluoro-11β, 16α, 17α, 21-tetrahydroxypregna-1,4-diene-3, 20-dione, cyclic 16, 17-acetal with acetone 21-acetate. LIDEX cream contains fluocinonide in FAPG® cream, a specially formulated cream base consisting of stearyl alcohol, polyethylene glycol 6000, propylene glycol, 1, 2, 6-hexanetriol and citric acid. This white cream vehicle is greaseless, non-staining, anhydrous and completely water miscible. The base provides emollient and hydrophilic properties. In this formulation, the active ingredient is totally in solution.

LIDEX ointment contains fluocinonide in a specially formulated ointment base consisting of Amerchol CAB (mixture of sterols and higher alcohols), white petrolatum, propylene carbonate and propylene glycol. It provides the occlusive and emollient effects desirable in an ointment. In this formulation the active ingredient is totally in solution.

TOPSYN gel contains fluocinonide in a specially formulated gel base consisting of propylene glycol, propyl gallate, disodium edetate, and Carbopol 940 (carboxypolymethylene) with NaOH and/or HCL added to adjust the pH. This clear, colorless, thixotropic vehicle is greaseless, non-staining and completely water miscible. In this formulation, the active ingredient is totally in solution.

Indications
LIDEX cream and ointment and TOPSYN gel are intended for the relief of inflammatory manifestations of corticosteroid responsive dermatoses.

Contraindications
Topical steroids are contraindicated in vaccinia and varicella. Topical steroids are contraindicated in those patients with a history of hypersensitivity to any of the components of the preparation.

Precautions
If irritation develops, the cream, ointment or gel should be discontinued and appropriate therapy instituted. In the presence of an infection the use of an appropriate antifungal or antibacterial agent should be instituted.

If a favorable response does not occur promptly, the corticosteroid cream, ointment or gel should be discontinued until the infection has been adequately controlled.

If extensive areas are treated, the possibility exists of increased systemic absorption and suitable precautions should be taken.

Although topical steroids have not been reported to have an adverse effect on pregnancy, the safety of their use in pregnant females has not absolutely been established. Therefore, they should not be used extensively on pregnant patients, in large amounts or for prolonged periods of time.

LIDEX® (fluocinonide) cream and ointment and TOPSYN® (fluocinonide) gel are not for opthalmic use.

Adverse reactions
The following local adverse reactions have been reported with topical corticosteroids:

burning	folliculitis
itching	acneform eruptions
irritation	hypopigmentation
dryness	striae
secondary infection	skin atrophy

Dosage and administration
A small amount should be gently massaged into the affected area three or four times daily, as needed.

How supplied
LIDEX 0.05% Cream—15 g 30 g and 60 g tubes.
LIDEX 0.05% Ointment—15 g 30 g and 60 g tubes.
TOPSYN Gel 0.05% 15 g and 60 g tubes.

SYNTEX
SYNTEX LABORATORIES, INC.
PALO ALTO, CALIFORNIA 94304

INDEX TO ADVERTISERS

A

Abbott Laboratories 1004-1005
Ayerst Laboratories 1014-1015

B

Barnes-Hind Pharmaceuticals 1136-1137
Burroughs Wellcome Company 1003

C

Ciba Pharmaceuticals 1020-1021
Cooper Laboratories, Inc. 1110

D

Dermik Laboratories 1125
Doak Pharmacal Company 1120
Dorsey Laboratories 1035-1036
Dow Pharmaceuticals 1007

G

General Medical Company 1039

H

Herbert, G.S., Laboratories, Division of Allergan Pharmaceuticals 1001
Hoechst-Roussel Pharmaceuticals 1032-1034

J

Johnson & Johnson 1126-1127

L

Lederle Laboratories, Division of American Cyanamid Company 1008-1010, 1025-1026
Lenox Hill Hospital 1031

N

Neutrogena Corporation 1038-1039

O

Owen Laboratories, Inc. ..... 3rd Cover

P

Parke-Davis & Company 1116-1117, 1142-1143
Pharmacia Diagnostics 1037
Procter & Gamble Company 1118
Purdue Frederick Company 1141

R

Riker Laboratories, Inc. 1112
Robins, A.H., Company 1018-1019
Roche Laboratories, Division of Hoffmann-LaRoche, Inc. 1028-1029
Roerig, J.B., Company Division of Pfizer, Inc. 1144-1145

S

Schering Corporation 1012-1013, 1016-1017, 1022-1024, 1109
Squibb, E.R., & Sons, Inc. 1040-1041, 1146-1147
Stiefel Laboratories, Inc. 1111
Syntex Laboratories, Inc. 1134-1135, 1152-1154

T

Texas Pharmacal Company 1030-1031

W

Westwood Pharmaceuticals, Inc. 2nd Cover, 1027, 1042, 1148-1150, 4th Cover

While every precaution is taken to insure accuracy, we cannot guarantee against the possibility of an occasional change or omission in the preparation of this index.

This is a pabafilm™ stain.

Pabafilm™: The non-staining sunscreen
(amyl dimethyl PABA)

PreSun® for proven sunscreen protection

(5% PABA LOTION/GEL)

helps protect against premature aging of skin and skin cancer caused by the sun

©1977, W.P. Inc.

WESTWOOD
PHARMACEUTICALS INC.
Buffalo, New York 14213

HCR
3.12.77

Published by the American Medical Association

September 1977
Volume 113, Number 9

archives of Dermatology

PUVA Statement 1195

Topical Halcinonide and Betamethasone Valerate Effects on Plasma Cortisol ..... *E. C. Gomez, L. Kaminester, P. Frost* 1196

Mycophenolic Acid for Psoriasis ..... *W. S. Lynch, H. H. Roenigk, Jr* 1203

Spontaneous Regression of Plane Warts After Inflammation ..... *H. Tagami, M. Takigawa, A. Ogino, S. Imamura, S. Ofugi* 1209

Recovery Processes During Regression of Plane Warts ..... *M. Takigawa, H. Tagami, S. Watanabe, A. Ogino, S. Imamura, S. Ofugi* 1214

Flat Warts Undergoing Involution ..... *A. Berman, R. K. Winkelmann* 1219

Solar Urticaria Treatment by Inducing Tolerance to Artificial Radiation and Natural Light ..... *C. A. Ramsay* 1222

Atopic Dermatitis and Tuberculin Reactivity ..... *M. Uehara* 1226

Beta Carotene Therapy for Erythropoietic Protoporphyria and Other Photosensitivity Diseases *M. M. Mathews-Roth, M. A. Pathak, T. B. Fitzpatrick, L. H. Harber, E. H. Kass* 1229

Clotrimazole vs Haloprogin Treatment of Tinea Cruris ..... *J. V. VanDersarl, R. H. Sheppard* 1233

Immunosuppressants and Prednisone in Pemphigus Vulgaris ..... *W. F. Lever, G. Schaumburg-Lever* 1236

Multiple Osteolytic Lesions in a Patient With Mycosis Fungoides ..... *K. E. Greer, L. L. Legum, C. E. Hess* 1242

Bony Lesions in Systemic Mastocytosis ..... *S. Sostre, H. L. Handler* 1245

Nodular Primary Localized Cutaneous Amyloidosis ..... *T. A. Chapel, D. J. Birmingham, Y. E. Malinowski* 1248

Apocrine Cystadenoma of the Penile Shaft ..... *R. F. Powell, C. H. Palmer, E. B. Smith* 1250

Allergic Contact Dermatitis From Sunscreen Preparations Complicating Photodermatitis ..... *G. Thompson, H. Maibach, J. Epstein* 1252

Localized Mycosis Fungoides With Prominent Epidermotropism ..... *W. F. Lever* 1254

Metastatic Basal Cell Carcinoma ..... *G. R. Mikhail, L. P. Nims, A. P. Kelly, Jr, D. M. Ditmars, Jr, W. R. Eyler* 1261

Occupational Hazards From Deep Mycoses ..... *J. Schwarz, C. A. Kauffman* 1270

New Health Practitioners and Dermatology Manpower Planning ..... *M. Krasner, D. L. Ramsay, P. E. Weary, M-L. T. Johnson* 1280

AMA AMERICAN MEDICAL ASSOCIATION

LIBRARY

classic therapy

To effectively help control dandruff, remove excess oil and stop itching.

Sebulex®

Therapeutic Shampoo
Cream Therapeutic Shampoo

WESTWOOD
PHARMACEUTICALS INC.
Buffalo, New York 14213
In Canada, Belleville, Ontario K8N 1E2

When either Benzoyl Peroxide or Retinoic Acid can't solve the puzzle of pustular acne...

Sulfacet-R®

(10% sodium sulfacetamide,
5% microsize sulfur)

PENETRATES into the skin to exert its antibacterial activity.

CONTROLS pustular stages of acne and seborrhea quickly, safely... without unsightly desquamation.

SAFETY RECORD..."in thousands of patients during the past two decades, not a single instance of sensitivity has been observed."*

PROVIDES instant **"Social Confidence"** with the exclusive Dermik Color Blender,™ customized tinting to match individual patient skin tones.

*Olansky S: Old drug in a new system revisited. Cutis 19:852-854. June, 1977

Dermik

Dermik Laboratories, Inc.
Fort Washington, Pa., U.S.A. 19034

SULFACET-R® LOTION

DESCRIPTION—Sulfacet-R* Acne Lotion contains (as dispensed) sodium sulfacetamide 10% and microsize sulfur 5% in a flesh-tinted lotion of purified water, alkyl-aryl sulfonic acid salts, hydroxyethylcellulose, propylene glycol, xanthan gum, lauric myristic diethanolamide, polyoxyethylene laurate, cyclohexanediamine tetraacetic acid, butylparaben, methylparaben, silicone emulsion, talc, zinc oxide, titanium dioxide, attapulgite, iron oxides, pH buffers and 2-bromo-2-nitropropane-1, 3-diol.

ACTIONS—Provides keratolytic, peeling, drying and antiseborrheic action.

INDICATIONS—An aid in the treatment of acne vulgaris, acne rosacea and seborrheic dermatitis.

CONTRAINDICATIONS—This product is contraindicated for use by patients having known hypersensitivity to sulfonamides, sulfur or any other component of this preparation. Not to be used by patients with kidney disease.

PRECAUTIONS—For external use only. Keep away from eyes. If irritation develops, discontinue use and consult physician. Sensitivity to sodium sulfacetamide may occur. Therefore, caution and careful supervision should be observed when prescribing this drug for patients who may be prone to hypersensitivity to topical sulfonamides. Particular caution should be employed if areas of denuded or abraded skin are involved. Patients should be carefully observed for possible local irritation or sensitization during long term therapy. Occasionally, certain individuals may be sensitive to one or more components of this preparation. The object of this therapy is to achieve desquamation without irritation, but sodium sulfacetamide and sulfur can cause reddening and scaling of the epidermis. These side effects are not unusual in the treatment of acne vulgaris, but patients should be cautioned about the possibility. Keep out of the reach of children.

ADVERSE REACTIONS—Previous toxic reactions such as agranulocytosis, acute hemolytic anemia, purpura hemorrhagica, drug fever, jaundice and contact dermatitis indicates hypersensitivity to sulfonamides.

DIRECTIONS—Shake well before using. Apply a thin film 1 to 3 times daily with light massaging to blend in each application in accordance with the physician's directions. Each package contains a "Dermik Color Blender" which enables the patient to alter the basic shade of the lotion so that it matches the skin color exactly.

[Important to the Pharmacist—At the time of dispensing, add contents of vial* to the bottle. Shake well and/or stir with a glass rod to insure a uniform dispersion. Place expiration date of four (4) months on bottle label.]

*"Sulfa-Pak" vial contains 2.4 grams of sodium sulfacetamide.

HOW SUPPLIED—Bottle, 1 oz.

CAUTION—Federal law prohibits dispensing without prescription.

Archives of DERMATOLOGY

Copyright © 1977 by the AMERICAN MEDICAL ASSOCIATION

VOL 113, NO. 9 September 1977

EDITORIAL

PUVA Statement 1195

ORIGINAL CONTRIBUTIONS

Topical Halcinonide and Betamethasone Valerate Effects on Plasma Cortisol
Edward C. Gomez, MD, PhD; Lewis Kaminester, MD; Phillip Frost, MD, Miami Beach, Fla 1196

Mycophenolic Acid for Psoriasis
William S. Lynch, MD, Henry H. Roenigk, Jr, MD, Cleveland 1203

Spontaneous Regression of Plane Warts After Inflammation
Hachiro Tagami, MD; Masahiro Takigawa, MD; Atsuhiko Ogino, MD; Sadao Imamura, MD; Shigeo Ofugi, MD, Kyoto, Japan 1209

Recovery Processes During Regression of Plane Warts
Masahiro Takigawa, MD; Hachiro Tagami, MD, Kyoto, Japan; Susumu Watanabe, MD, Kurashiki, Japan; Atsuhiko Ogino, MD; Sadao Imamura, MD; Shigeo Ofugi, MD, Kyoto, Japan 1214

Flat Warts Undergoing Involution
Alexander Berman, MD, Milwaukee, Richard K. Winkelmann, MD, Rochester, Minn 1219

Solar Urticaria Treatment by Inducing Tolerance to Artificial Radiation and Natural Light
Colin A. Ramsay, MD, MRCP, London 1222

Atopic Dermatitis and Tuberculin Reactivity
Masami Uehara, MD, Kyoto, Japan 1226

Beta Carotene Therapy for Erythropoietic Protoporphyria and Other Photosensitivity Diseases
Micheline M. Mathews-Roth, MD; Madhu A. Pathak, MB, PhD; T. B. Fitzpatrick, MD, PhD, Boston; Leonard H. Harber, MD, New York; Edward H. Kass, MD, PhD, Boston 1229

Clotrimazole vs Haloprogin Treatment of Tinea Cruris
Maj Jules V. VanDersarl, MC, USAF, Sgt Robert H. Sheppard, Keesler AFB, Miss 1233

Immunosuppressants and Prednisone in Pemphigus Vulgaris
Walter F. Lever, MD, Gundula Schaumburg-Lever, MD, Boston 1236

CASE REPORTS

Multiple Osteolytic Lesions in a Patient With Mycosis Fungoides
Kenneth E. Greer, MD; Larry L. Legum, MD; Charles E. Hess, MD, Charlottesville, Va 1242

Bony Lesions in Systemic Mastocytosis
Maj Samuel Sostre, MC, USAF, Maj Harvey L. Handler, MC, USAF, Wright-Patterson Air Force Base, Ohio 1245

Nodular Primary Localized Cutaneous Amyloidosis
Thomas A. Chapel, MD; Donald J. Birmingham, MD; Yolanta E. Malinowski, MD, Detroit 1248

Apocrine Cystadenoma of the Penile Shaft
Ralph F. Powell, MD; Charles H. Palmer, MD; Edgar B. Smith, MD, Albuquerque, NM 1250

Allergic Contact Dermatitis From Sunscreen Preparations Complicating Photodermatitis
Greg Thompson, MD; Howard Maibach, MD; John Epstein, MD, San Francisco 1252

Localized Mycosis Fungoides With Prominent Epidermotropism
Walter F. Lever, MD, Boston 1254

REVIEW ARTICLES

Metastatic Basal Cell Carcinoma
George R. Mikhail, MD; Linda P. Nims, MD; Alexander P. Kelly, Jr, MD; Donald M. Ditmars, Jr, MD; William R. Eyler, MD, Detroit 1261

Occupational Hazards From Deep Mycoses
Jan Schwarz, MD, Carol A. Kauffman, MD, Cincinnati 1270

(Continued on page 1158)

EDITORIAL BOARD

Chief Editor
John H. Epstein, MD
450 Sutter Street
San Francisco 94108

Assistant Chief Editor
Kimie Fukuyama, MD
San Francisco

Assistant Chief Editor
Denny L. Tuffanelli, MD
San Francisco

Donald C. Abele, MD
Augusta, Ga.

Harry L. Arnold, Jr, MD
Honolulu

Walter C. Lobitz, Jr, MD
Portland, Ore

Frederick D. Malkinson, MD
Chicago

Sigfrid A. Muller, MD
Rochester, Minn

W. Mitchell Sams, Jr, MD
Chapel Hill, NC

John S. Strauss, MD
Boston

Morris Waisman, MD
Tampa, Fla

Gerald D. Weinstein, MD
Miami

...benzoyl peroxide gel from Owen

- Proven effective in reduction of total lesions
- Cosmetically elegant vehicle
- Promoted to dermatologists only

Description: benzac™ 5 contains benzoyl peroxide 5%, polyoxyethylene lauryl ether 6%, alcohol 30% (w/w), dimethicone, carbomer 940, di-isopropanolamine, citric acid, fragrance and purified water. benzac™ 10 contains benzoyl peroxide 10%, polyoxyethylene lauryl ether 6%, alcohol 30% (w/w), dimethicone, carbomer 940, di-isopropanolamine, citric acid, fragrance and purified water.

Actions: benzac™ is an effective aid in the topical treatment of acne vulgaris. benzac™ provides drying, desquamating action, and has been shown to have antibacterial effects against Propionibacterium (Corynebacterium) acnes.

Indications: An adjunctive topical therapy for the control of acne vulgaris.

Contraindications: Not to be used by patients having known sensitivity to benzoyl peroxide or any other ingredients of the preparation.

PRECAUTIONS: FOR EXTERNAL USE ONLY. Avoid contact with the eyes, eyelids, and other mucous membranes. May bleach hair and colored fabrics. **KEEP THIS AND ALL DRUGS OUT OF THE REACH OF CHILDREN.**

Dosage and Administration: After washing with a mild cleanser and water, apply once or twice daily. The degree of drying and peeling can be adjusted by modification of the dosage schedule.

How Supplied: benzac™ 5, 60 gram tubes benzac™ 10, 60 gram tubes

CAUTION: FEDERAL LAW PROHIBITS DISPENSING WITHOUT PRESCRIPTION.

Owen
Owen Laboratories, Dallas, Texas 75234
Division of Alcon Laboratories, Inc.

SPECIAL ARTICLE

New Health Practitioners and Dermatology Manpower Planning
Melvin Krasner; David L. Ramsay, MD, MEd; Peyton E. Weary, MD; Marie-Louise T. Johnson, MD, PhD, New York 1280

REGULAR DEPARTMENTS

Short Reports 1287

Search for a Causal Agent of Psoriasis by Seroepidemiologic Methods Joan J. Rayner, MS, Kendall O. Smith, PhD, San Antonio, Tex . . . **Basal Cell Carcinoma With Bony Metastases Producing Myelofibrosis** Rama M. Jager, MD; Leonard J. Weiner, MD; Robert S. Howell, MD, Louisville

Letters to the Editor 1294

Spread of Condyloma Acuminata to Infants and Children Frances J. Storrs, MD, Portland, Ore, Leon Goldman, MD, Cincinnati . . . **Malignant Melanoma in a Thermal Burn Scar** Gerald A. Gellin, MD, William L. Epstein, MD, San Francisco . . . **Pruritus in Secondary Syphilis** Burton Allyn, MD, New York . . . **Photochemotherapy in Erythrodermic Seborrhoic Dermatitis** Karin Birgit Dahl, MD, Flemming Reymann, MD, Copenhagen . . . **A Simple Permanent Mount of *Sarcoptes scabiei*** Leon Goldman, MD, Cincinnati . . . **Alopecia Areata and Vitiligo Associated With Down's Syndrome** Algie C. Brown, MD; Zbigniew L. Olkowski, MD, ScD; John R. McLaren, MD; Mike H. Kutner, PhD, Atlanta . . . **Weight Loss and Psoriasis** Frank W. Rosenberg, MD, Toronto . . . **An Unusual Contact Photosensitizing Reaction** Paul Lazar, MD, Highland Park, Ill . . . **Immunofluorescence Findings in Juvenile Bullous Disease** Roger Clayton, MB, MRCP, Michael Feiwel, MA, MB, FRCP, London . . . **Pain With Synoviomas** Vincent J. Derbes, MD; Herbert Ichinose, MD; Harry Hoerner, MD, New Orleans . . . **Cutaneous Reaction to Chlorambucil** L. G. Millard, MB, MRCP, S. M. Rajah, Leeds, England . . . **Cutaneous Leishmaniasis: Inefficacity of Treatment With Metronidazole** Asher Wahba, MD, Chaim Cohen, MD, Jerusalem . . . **Herpes Gestationis** Kurt S. Stenn, MD, New Haven, Conn; K. Hertz, MD; S. Katz, MD; J. Maize, MD; A. B. Ackerman, MD, Bethesda, Md . . . **The Presence of Benzocaine in Sunscreens Containing Glyceryl PABA (Escalol 106)** Alexander A. Fisher, MD, Woodside, Long Island, NY . . . **Frequency of Skin Lesions in Chronic Drinkers** Mark Rosset, MD, FRCP(C), Toronto . . . **'Stockbroker's Knee'** Daniel S. J. Choy, MD, New York . . . **Bone Involvement in Early Syphilis** Prof Gunnar Lomholt, Tromsoe, Norway . . . **Biting Insect Summary** Claude A. Frazier, MD, Asheville, NC . . . **Atopic Dermatitis Reactions to Methacholine** Stephen P. Stone, MD, Springfield, Ill . . . **Azaribine, Homocystinemia, and Thrombosis** Jerome L. Shupack, MD; Anthony J. Grieco, MD; Allen M. Epstein, MD; Claude Sansaricq, MD; Selma E. Snyderman, MD, New York . . . **Melanoma Treatment With Phenolic or Catecholic Compounds** David Paslin, MD, Daly City, Calif . . . **Minocycline and Thyroid Function** Thomas Gretzinger, MD, Fresno, Calif . . . **Zinc Sulfate and Axillary Perspiration Odor** Morton D. Scribner, MD, Arcadia, Calif . . . **Isolated Familial Benign Chronic Pemphigus** Donald E. Hazelrigg, MD, Leon J. Stoller, MD, Evansville, Ind . . . **Transient Bullous Eruption** David Weedon, FRCPA, Graeme Beardmore, FACD, Brisbane, Australia . . . **Propranolol Therapy** Morton D. Scribner, MD, Arcadia, Calif . . . **Suggested Sequence of Testing for Acne Patients Receiving Long-Term Tetracycline Therapy** Gordon C. Sauer, MD, Kansas City, Mo . . . **Elastosis Perforans Serpiginosa Associated With Penicillamine** Mark Abel, MD, Brick Town, NJ **Pilomatricoma** Harry L. Arnold, Jr, MD, Honolulu, Lawrence J. Gregg, MD, Tulsa, Okla

Society Transactions 1306

Books 1311

News and Notes 1314

Index to Advertisers 1322

Instructions for Authors 1162

SUBSCRIPTION RATES: The yearly rate of the ARCHIVES OF DERMATOLOGY is as follows: United States and US Possessions, one year, $18; two years, $28; all other countries, one year, $28; two years, $38. Special yearly price to residents, interns and medical students in the United States and US Possessions, $9.

THE ARCHIVES OF DERMATOLOGY is published monthly by the American Medical Association, 535 N Dearborn St, Chicago, IL 60610, and is an official publication of the Association. Second-class postage paid at Chicago and at additional mailing office.



Selsun®
(SELENIUM SULFIDE LOTION, U.S.P.) ℞

Brief Summary

Contains:
Selenium sulfide, 2½%, w/v; bentonite; lauric diethanolamide; ethylene glycol monostearate; titanium dioxide; amphoteric—2; sodium lauryl sulfate; sodium phosphate (monobasic); glyceryl monoricinoleate; citric acid; captan; perfume; and water.

Indications:
For the treatment of dandruff and seborrheic dermatitis of the scalp.

Contraindications:
Should not be used by patients allergic to any of its components.

Warnings:
Safety for use on infants has not been established.

Precautions:
Cutaneous sensitization of the scalp or adjacent areas has been reported; if sensitivity reactions should occur, discontinue use. Chemical conjunctivitis may result if product enters the eyes. Do not use when acute inflammation or exudation is present as an increase in absorption may occur.

Adverse Reactions:
As with other shampoos, oiliness or dryness of the hair and scalp may occur following use; there have been occasional reports of an increase in the amount of normal hair loss. Hair discoloration may occur; can be avoided or minimized by thorough rinsing.

ABBOTT
7093197

For the benefit of your patients

TRADITIONAL THERAPY

FOR DANDRUFF AND SEBORRHEIC DERMATITIS OF THE SCALP

HAS BEEN IMPROVED

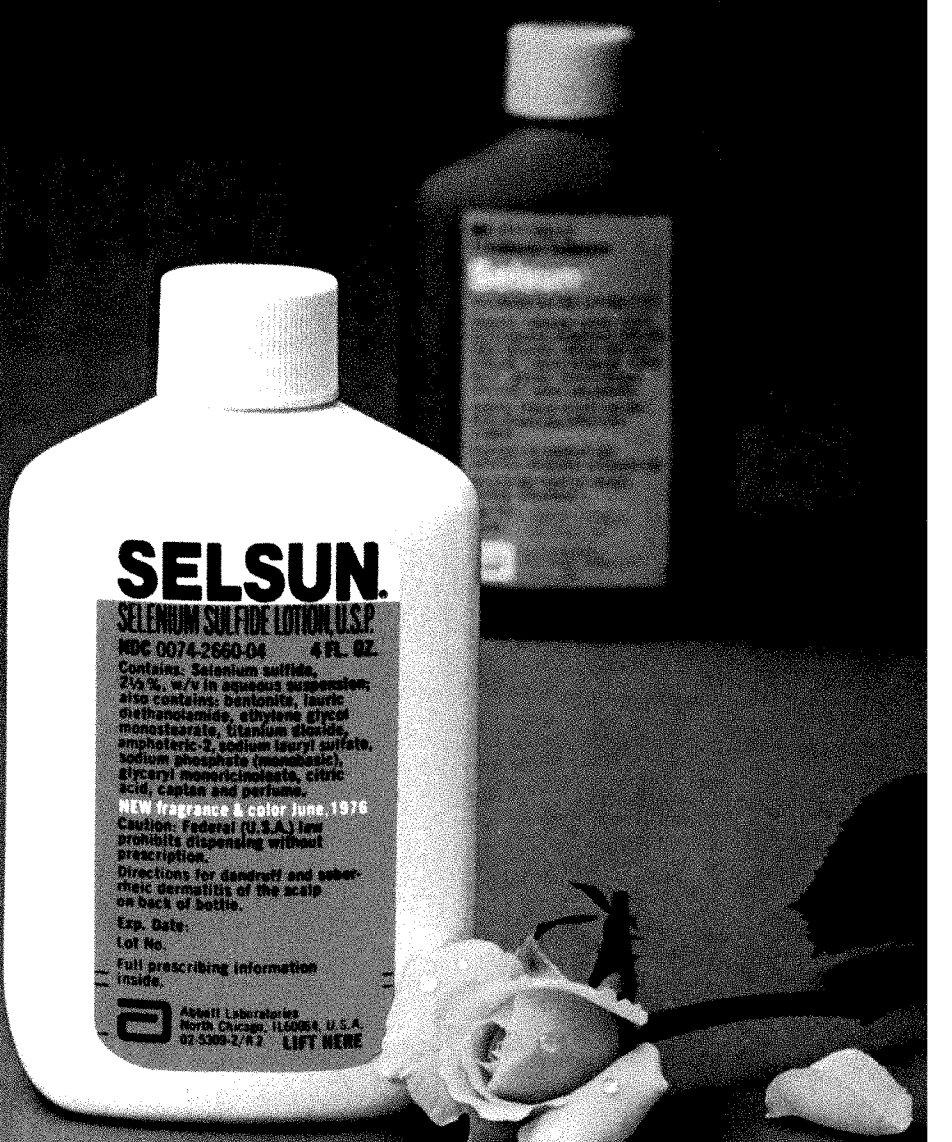

NEW FRAGRANCE
(much milder)

NEW COLOR
(much lighter)

NEW SUDSING
(much better)

SAME EFFICACY AND SAFETY

IMPROVED

Selsun® ℞

SELENIUM SULFIDE, LOTION, U.S.P.

Please see opposite page for Brief Summary

YOUR TEEN-AGE PATIENTS PROBABLY WON'T CARRY FACE CLOTHS... BUT THEY MIGHT CARRY

THERAPADS PLUS®

TO COMPLEMENT ANY ACNE REGIMEN

☐ CONVENIENT CLEANSING— ANYTIME, ANYWHERE

Therapads Plus provide effective cleansing and drying actions to remove excess surface oiliness... cleanse deeply, thoroughly, and antiseptically. Therapads Plus are pleasantly scented and saturated with a colorless solution of 70% ethyl alcohol, 1.5% salicylic acid, and 0.1% sodium alkyl aryl polyether sulfonate.

☐ HELP CONTROL OILY SKIN, BLACKHEADS, ACNE

Used 2 or 3 times a day—such as midmorning, midafternoon, and bedtime—Therapads Plus help keep skin clean, and free from oil between soap-and-water washings; also help dry existing blemishes.

Therapads Plus—available in boxes of 30 foil-wrapped pads. Therapads (regular)—available in jars of 40 and 100.



FULLER LABORATORIES, INC.
SUBSIDIARY OF
PARKE, DAVIS & COMPANY
EDEN PRAIRIE, MN 55343

PARKE-DAVIS

PARKE, DAVIS & COMPANY
Detroit, MI 48232

FD-JA-2130-1-C (12-76)

LENOX HILL HOSPITAL
Announces a Symposium on

TUMORS OF THE EYELIDS, ORBIT AND OCULAR ADNEXA

October 27, 28, 1977

This Symposium will be devoted to the diagnosis, pathogenesis and treatment of tumors of the eyelids and orbit, emphasizing basal cell carcinoma of the eyelids. The course will be presented by outstanding ophthalmologists, ophthalmic plastic surgeons, plastic surgeons, x-ray therapists, dermatologists, immunotherapists, cryosurgeons and pathologists.

The format will consist of lectures, panel discussions, surgical films and videotapes of surgery.

THE FACULTY WILL INCLUDE:
Albert Hornblass, M.D., Course Director
Crowell Beard, M.D.
Edgar Berry, M.D.
Charles Beyer, M.D.
Lazlo Biro, M.D.
Martin Bodian, M.D.
Norman C. Charles, M.D.
Jackson Coleman, M.D.
Anthony Domonkis, M.D.
Paul Henkind, M.D.
Seamus Lynch, M.D.
Perry Robins, M.D.
Robert Sagerman, M.D.
John Simonton, M.D.
Byron Smith, M.D.
David Soll, M.D.
Michael Tenner, M.D.
Stephen Trokel, M.D.
and others

TUITION:

Practitioners	$200.00
Residents	$75.00

FOR FURTHER INFORMATION WRITE TO:
Department of Ophthalmology
Lenox Hill Hospital
100 East 77th Street
New York, New York 10021

This activity is acceptable for 14 credit hours in Category I

It's a distressing, disabling and costly disease

And, now there's a monograph that looks at all aspects of the disease from recent epidemiological data to advisable therapeutic regimens. Morton's **Gonorrhea** discusses all the advances made since the mid-1960's and provides references. Emphasis is placed on the sound scientific routines of clinical examination, laboratory methods, epidemiological follow-up of sex contacts and control measures. Each individual chapter is complete with references. Remember when the question concerns gonorrhea, the answer's in our book!

By **R.S. Morton**, MD. Consultant Venereologist, Royal Infirmary, Sheffield. About 300 pp. Illustd. About $25.00. Just Ready

W.B. Saunders Company **West Washington Square, Philadelphia, Pa. 19105**

MORTON: Gonorrhea

Major Problems in Dermatology

9

Archives of Dermatology

James H. Sammons, MD
Executive Vice-President

Thomas F. Hannon
Group Vice-President,
Publishing Operations

William R. Barclay, MD
Group Vice-President,
Scientific Publications

Norman D. Richey
Director, Publication
Production Division

John T. Baker
Director, Marketing Division

Helen R. Mazur
Acting Fulfillment Manager

John T. Baker, General Sales Manager; **Robert Corcoran,** Eastern Sales Manager; **Fred Bauman, Richard M. Johnson,** Eastern Sales Representatives; **William J. Healy,** Midwest Sales Representative; **Thomas J. Carroll,** West Coast/Northern Sales Representative

PUBLICATION STAFF

Offices: 535 N Dearborn St
Chicago, IL 60610

Robert W. Mayo
Executive Editor and Director,
Scientific Publications Division

Sandra Williamson
Administrative Assistant

Marlene M. Hinsch, Production Manager

Editorial Processing Manager: Diana A. Morgan

Copy Editing: Rosanne Schulenberg (Supervisor), Paula Glitman, Patti Narret, Kathy Swartz

Proofreading: Lorraine L. Kruse (Supervisor), Patricia Coyne, Helen Grzeskiewicz, Elizabeth Petrikenas, Dorothy Troy

Production Supervisors: Julia Bero (Layout), Thomas J. Handrigan (Illustrations), Marlene M. Hinsch (Editorial), James P. Bagniewski (Advertising)

Art and Senior Production Assistants: Betty Frigerio, Linda Gilbert, Floriana Hayes, Shirley Latronica, Deborah Orent, Donna Pender, Nancy Keyes, Susan Routhier, JoAnne Weiskopf

Production Assistants: Karen Branham, E. Linda Eisenberg, Anna Goins, Dannie Kendrick, Lucille Kuznicki

Manuscript Records: Mary Paino

Indexing: Phyllis H. McLaren (Supervisor), Jane P. Mauldin, Helen F. Topel

Please address communications concerning accepted or published communications to: AMA Specialty Journals, 535 N Dearborn St, Chicago, IL 60610.

Conditions for Acceptance of Color Illustrations

Illustrations in full color are accepted for publication in ARCHIVES OF DERMATOLOGY if the editor believes that color will add significantly to the published manuscript.

When color illustrations are accepted, the American Medical Association will pay part of the expense of reproduction and printing, the remainder to be borne by the author or the institution with which he is affiliated. After deducting AMA's contribution, the author's share is $275 for up to six square finished illustrations. Additional illustrations and special effects, such as outlining, opaquing, or surprinting, will be billed to the author at cost.

Color transparencies must be submitted for evaluation. Do not send color prints unless accompanied by original transparencies. If transparencies are mounted in frames or glass, the material should be carefully packed in gauze and sent with the manuscript in a separate container or between two pieces of pressboard.

Advertising and Subscription Information

ADVERTISING OFFICES: 535 N Dearborn St, Chicago, IL 60610, Area Code 312, 751-6000; and 600 Third Ave, New York, NY 10016, Area Code 212-867-6640.

ADVERTISING PRINCIPLES: Each advertisement in this issue has been reviewed and complies with the principles governing advertising in AMA scientific publications. A copy of these principles is available on request.

CHANGE OF ADDRESS: Please notify the publisher at least six weeks in advance, including both old and new address, and a mailing label taken from the most recent copy. Include your new zip code number.

Instructions for Authors

Send manuscripts by first-class mail to the Chief Editor, John H. Epstein, MD, 450 Sutter St, San Francisco, CA 94108. Manuscripts are received with the understanding that they are not under simultaneous consideration by another publication. Accepted manuscripts become the permanent property of the ARCHIVES and may not be published elsewhere without permission from the publisher (AMA).

Author Responsibility.—All accepted manuscripts are subject to copy editing. The author will receive an edited typescript rather than galley proofs for approval. The author is responsible for all statements in his work, including changes made by the copy editor.

Designate one author as correspondent and provide his address and telephone number. Order reprints at the time the typescript is returned after editorial processing. Specify address to which requests for reprints should be sent.

Manuscript Preparation.—Submit an original typescript and two high-quality copies of the entire manuscript. All copy (including references, legends, and tables) must be typed double-spaced on 22 × 28-cm (8½ × 11-inch), heavy-duty white bond paper. Ample margins should be provided.

Refer to patients by number (or, in anecdotal reports, by fictitious given names). Real names or initials should not be used in the text, tables, or illustrations.

Titles.—Titles should be short, specific, and clear. They should not exceed 42 characters per line, including punctuation and spaces, and be limited to two lines, if possible. The title page should include the full names and academic affiliations of all authors, the address to which requests for reprints should be sent, and, if the manuscript was presented at a meeting, the name of the organization, place, and date on which it was read.

Style of Writing.—The style of writing should conform to acceptable English usage and syntax. Slang, medical jargon, obscure abbreviations, and abbreviated phrasing are to be avoided.

Informed Consent.—Manuscripts reporting the results of experimental investigations of human subjects must include a statement to the effect that informed consent was obtained after the nature of the procedure(s) had been fully explained.

Abstract.—Provide an abstract (135-word maximum) of the article, including statements of the problem, method of study, results, and conclusions. The abstract replaces the summary.

References.—List references in consecutive numerical order (not alphabetically). Once a reference is cited, all subsequent citations should be to the original number. All references must be cited in the text or tables. Unpublished data and personal communications should not be listed as references. References to journal articles should include (1) author, (2) title, (3) journal name (as abbreviated in *Index Medicus*), (4) volume number, (5) inclusive page numbers, and (6) year, in that order. References to books should include (1) author(s), (2) chapter title (if any), (3) editor (if any), (4) title of book, (5) city of publication, (6) publisher, and (7) year. Volume and edition numbers, specific pages, and name of translator should be included when appropriate. The author is responsible for the accuracy and completeness of the references and for their correct text citation.

Metrication.—All measurements must be in metric units. English units may also be given parenthetically if the measurements were originally done in English units.

Illustrations.—Use only those illustrations that clarify and augment the text. Submit illustrations in duplicate, unmounted and untrimmed. Do not send original artwork. Send high-contrast glossy prints (not photocopies). Figure number, name of senior author, and arrow indicating "top" should be typed on a gummed label and affixed to the back of each illustration. All lettering must be legible after reduction to column size. Artwork submitted for publication may be relettered to achieve uniformity of lettering style throughout the journal. Magnification and stain should be provided when pertinent. Illustrations should preferably be in a proportion of 12.5 × 18 cm (5 × 7 inches).

An experienced medical illustrator should be employed whenever possible for the preparation of all artwork. Template lettering or preset type is preferred to hand-lettered labels. If halftone artwork with labels is submitted, affix type and leaders to a clear acetate overlay registered to the base drawing. Labels and leaders should be applied directly to the drawing board surface if the artwork consists only of line ink technique.

Illustrations in full color are accepted for publication if the editors believe that color will add significantly to the published manuscript. The ARCHIVES will pay part of the expense of reproduction and printing color illustrations, the remainder to be borne by the author or his sponsor. After deducting the ARCHIVES contribution, the author's share is $275.00 for up to six square-finished illustrations that can be arranged on a one-page layout. Any additional illustrations or special effects will be billed to the author at cost. Positive color transparencies (35 mm preferred) must be submitted for an evaluation. Do not send color prints unless accompanied by original transparencies. All transparencies should be carefully packed and sent with the manuscript.

Legends.—Legends should be typed double-spaced, beginning on a separate sheet of paper. Length should be limited to a maximum of 40 words.

Photographic Consents.—A letter of consent must accompany all photographs of patients in which a possibility of identification exists. It is not sufficient to cover the eyes to mask identity.

Acknowledgments.—Illustrations from other publications must be acknowledged. Include the following when applicable: author(s), title of article, title of journal or book, volume number, page(s), month, and year. The publisher's permission to reprint should be submitted to the ARCHIVES after the manuscript has been formally accepted.

Statistical Review.—Manuscripts containing statistical evaluations should include the name and affiliation of the statistical reviewer.

Tables.—Each table should be typed double-spaced, including all headings, on a separate sheet of 22 × 28-cm (8½ × 11-inch) paper. Do not use larger size paper. If a table must be continued, use a second sheet and repeat all heads and stubs. Each table must have a title.

They're individuals...
(with individual skin problems)



Aristocort® lets you treat them that way!

Triamcinolone Acetonide

Versatility

A dosage form and strength for every patient...every type of indicated steroid-responsive dermatosis

Economy

A variety of sizes to meet all therapeutic needs and maximize economy

Experience

Fluorinated topical effectiveness—confirmed over almost 20 years of clinical use

Elegance

Cosmetically pleasing. Without sensitizers, such as parabens, phenol preservatives and lanolin.

Supplied as:

0.1% and 0.025% Creams: in 15 and 75 Gm. tubes and ½ and 5¼ lb. jars
0.5% Cream: in 15 Gm. tubes and ½ lb. jars
0.1% Ointment: in 15 and 75 Gm. tubes and ½ and 5¼ lb. jars
0.5% Ointment: in 15 Gm. tubes and ½ lb. jars
ARISTOGEL® Triamcinolone Acetonide Gel 0.1%: in 15 and 75 Gm. tubes.

Indications: For relief of inflammatory manifestations of corticosteroid-responsive dermatoses.
Contraindications: Viral skin diseases, such as varicella and vaccinia; hypersensitivity to any component (not for ophthalmic use); when circulation is markedly impaired.
Warnings: Safety of use in pregnancy has not been absolutely established. Do not use extensively, in large amounts, or for prolonged periods of time in pregnant patients.
Precautions: If irritation develops, discontinue use and institute appropriate therapy. In infections, use appropriate antifungal or antibacterial agents; if a favorable response does not occur promptly, discontinue the corticosteroid until the infection is adequately controlled. If [illegible] areas are treated or the occlusive technique is used, increased systemic absorption of the corticosteroid may occur; take suitable precautions.
Adverse Reactions: (local) Burning sensations, itching, irritation, dryness, folliculitis, secondary infection, skin atrophy, striae, hypertrichosis, acneform eruption and hypopigmentation.
Supplied: *Cream 0.5%*—Per Gm.: triamcinolone acetonide 5 mg., sorbic acid 0.1% and potassium sorbate 0.1% as preservatives; *Cream 0.1%*—Per Gm.: triamcinolone acetonide 1 mg., sorbic acid 0.1% and potassium sorbate 0.1% as preservatives; *Cream 0.025%*—Per Gm.: triamcinolone acetonide 0.25 mg., sorbic acid 0.1% and potassium sorbate 0.1% as preservatives; all potencies are in a water base of mono and diglycerides, squalane, polysorbate 80 USP, polysorbate 60, cetyl esters wax NF, stearyl alcohol USP, Tenox II, and sorbitol solution USP, *Ointment 0.5%*—Per Gm.: triamcinolone acetonide 5 mg.; inactive ingredient: white petrolatum; *Ointment 0.1%*—Per Gm.: triamcinolone acetonide 1 mg.; inactive ingredient: white petrolatum. *ARISTOGEL® GEL 0.1%*—Per Gm.: triamcinolone acetonide 1 mg., 1.8% benzyl alcohol as preservative; inactive ingredients in a water base: polysorbate 80 USP, polyoxyethylene (20) cetyl ether, glycerin USP, and citric acid USP.

003-7

Lederle

Lederle Laboratories
A Division of American Cyanamid Company
Pearl River, New York 10965

Four indications for Komed® HC Acne Lotion

Komed HC reduces inflammation as it keeps skin dry and desquamating with non-comedogenic sodium thiosulfate[1]

1.

When you wish to alternate severe acne medication with acne medication that will reduce erythema and irritation



2.

When severe acne medication has been effective and you want to maintain acne control with minimal irritation



3.

When you determine that initial use of severe acne medication is not indicated



4.

When reducing the inflammation associated with acne vulgaris is an important consideration



Besides its ability to reduce inflammation, patients appreciate the invisibility of Komed HC. It dries rapidly to a transparent film to be worn unseen or used as the base for makeup.

Contraindications Contraindicated for herpes simplex, chickenpox, smallpox, tuberculous ulcers and fungal infections.
Warning Although there have been no reports of topical steroids having adverse effects on pregnant patients, the safety of their use has not been established. Therefore, they should not be used extensively, in large amounts, or for prolonged periods of time during pregnancy.
For acne conditions not requiring the anti-inflammatory effects of hydrocortisone, KOMED lotion or KOMED MILD lotion are recommended.
Precautions If signs of irritation or sensitivity develop, discontinue use. If infections due to bacteria or fungi appear during therapy, appropriate measures should be taken. The anti-inflammatory action of hydrocortisone may mask the presence of infection. Do not use on or about the eyes.
Caution U.S. Federal law prohibits dispensing without a prescription.

[1]Mills OH Jr, Kligman AM "Is Sulphur helpful or harmful in acne vulgaris?" Br J Derm 86:620, 1972

"Suspensions and creams containing elemental sulphur were shown to be capable of inducing comedones in the rabbit ear and on human backs."

Komed® HC

(hydrocortisone acetate 0.5%, sodium thiosulfate 8%, salicylic acid 2%)

Barnes Hind Pharmaceuticals, Inc.
895 Kifer Road
Sunnyvale, California 94086

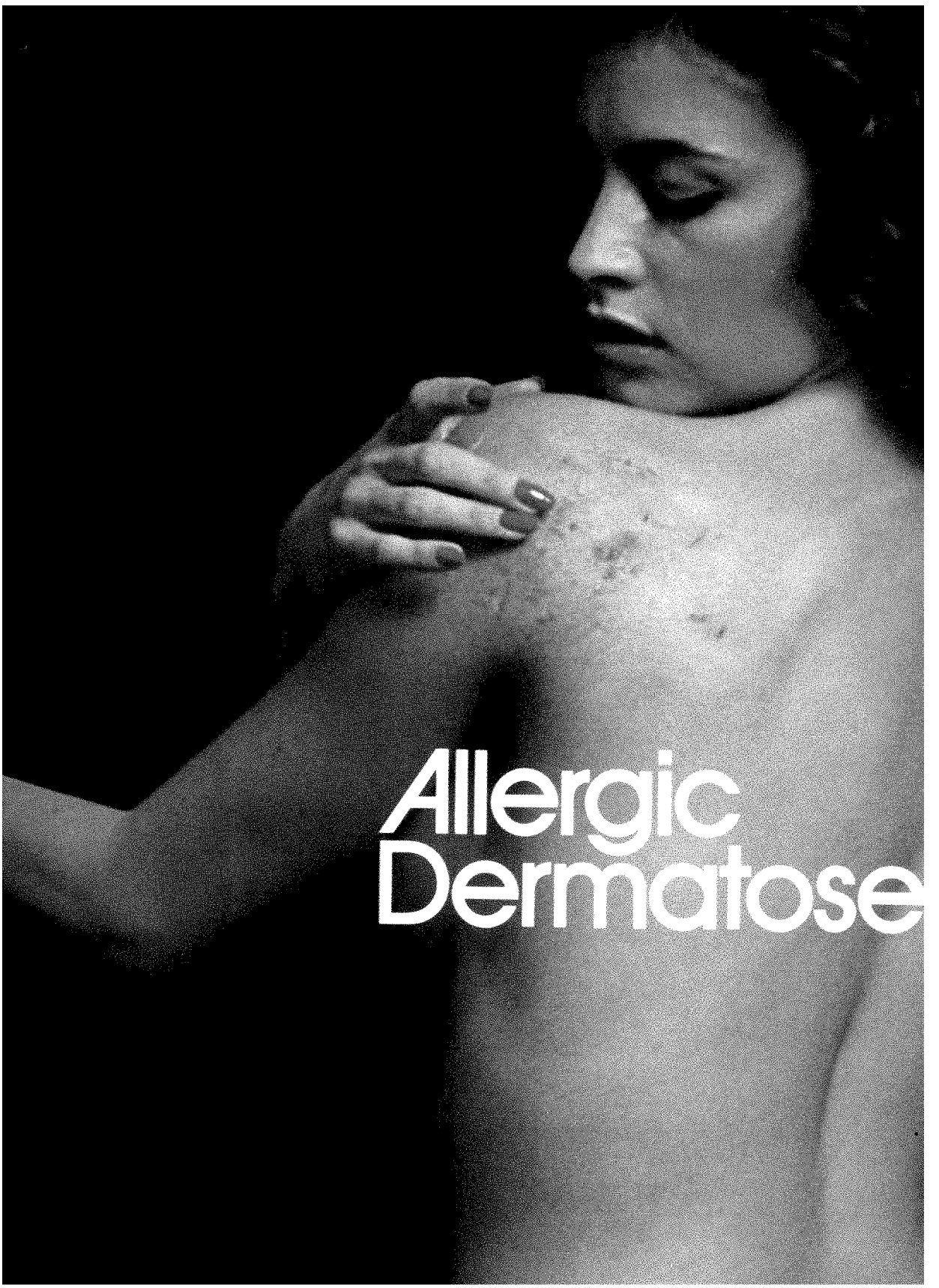
Allergic
Dermatose

rat, and rabbit, induced fetal abnormalities in the rat at doses substantially above the human therapeutic range. Clinical data in human beings are inadequate to establish safety in early pregnancy. Until such data are available, hydroxyzine is contraindicated in early pregnancy.

Precautions: Hydroxyzine may potentiate the action of central nervous system depressants such as meperidine and barbiturates. In conjunctive use, dosage for these drugs should be reduced. Because drowsiness may occur, patients should be cautioned against driving a car or operating dangerous machinery.

Adverse Reactions: Drowsiness may occur; if so, it is usually transitory and may disappear in a few days of continued therapy or upon dosage reduction. Dryness of the mouth may occur with higher doses. Involuntary motor activity, including rare instances of tremor and convulsions, has been reported, usually with higher than recommended dosage

Supply: Tablets, containing 10 mg, 25 mg, or 50 mg hydroxyzine hydrochloride, 100's and 500's; Tablets, containing 100 mg, 100's; Syrup, containing 10 mg per teaspoonful (5 ml) and ethyl alcohol 0.5% v/v, pint bottles.

Before prescribing or administering, see package circular.

with strong emotional overlay

the cause can be obscure

Factors precipitating allergic dermatoses with strong emotional overlay, which can range from allergens to anxiety, can be difficult to identify.

successful treatment often includes

Atarax®
(hydroxyzine HCl)

TABLETS: 10 mg, 25 mg, 50 mg, and 100 mg

- rapid antianxiety action
- demonstrated antihistaminic activity

ROERIG Pfizer

gets to deep fungal infec

when topicals can't.

Potent, systemic fungistat

GRISACTIN provides the antifungal activity needed to control tinea infections, including onychomycosis, that invade the dermis and deeper regions. Systemic action penetrates where topical action often fails.

GRISACTIN is effective against a wide range of fungi: *Trichophyton rubrum, T. mentagrophytes, T. tonsurans, T. interdigitalis, T. verrucosum, T. megnini, T. gallinae, T. crateriform, T. sulphureum, T. schoenleini, Microsporum canis, M. audouini, M. gypseum,* and *Epidermophyton floccosum.*

Peak serum levels are usually produced in about four hours with a single 500 mg. tablet. To meet the requirements of different patients—depending on body weight, age, severity, and location of infection—dosage is easily individualized with 125 mg. and 250 mg. capsules, and 500 mg. tablets.

Grisactin® 500

BRAND OF

griseofulvin (microsize) TABLETS

BRIEF SUMMARY
(For full prescribing information, see package circular.)

Grisactin®
Brand of
Griseofulvin (microsize)

Indications: Griseofulvin is indicated for the treatment of ringworm infections of the skin, hair, and nails, namely: *Tinea corporis, Tinea pedis, Tinea cruris, Tinea barbae, Tinea capitis, Tinea unguium* (onychomycosis) when caused by one or more of the following genera of fungi: *Trichophyton rubrum, T. tonsurans, T. mentagrophytes, T. interdigitalis, T. verrucosum, T. megnini, T. gallinae, T. crateriform, T. sulphureum, T. schoenleini, Microsporum audouini, M. canis, M. gypseum, Epidermophyton floccosum.*
NOTE: Prior to therapy, the type of fungi responsible for the infection should be identified.
The use of this drug is not justified in minor or trivial infections which will respond to topical agents alone.
Griseofulvin is *not* effective in the following: Bacterial infections, candidiasis (moniliasis), histoplasmosis, actinomycosis, sporotrichosis, chromoblastomycosis, coccidioidomycosis, North American blastomycosis, cryptococcosis (torulosis), *Tinea versicolor,* nocardiosis.
Contraindications: This drug is contraindicated in patients with porphyria, hepatocellular failure, and in individuals with a history of hypersensitivity to griseofulvin.
Warnings: *Prophylactic Usage*—Safety and efficacy of griseofulvin for prophylaxis of fungal infections has not been established.
Animal Toxicology—Chronic feeding of griseofulvin, at levels ranging from 0.5-2.5% of the diet, resulted in the development of liver tumors in several strains of mice, particularly in males. Smaller particle sizes result in an enhanced effect. Lower oral dosage levels have not been tested. Subcutaneous administration of relatively small doses of griseofulvin, once a week, during the first three weeks of life has also been reported to induce hepatomata in mice. Although studies in other animal species have not yielded evidence of tumorigenicity, these studies were not of adequate design to form a basis for conclusions in this regard.
In subacute toxicity studies, orally administered griseofulvin produced hepatocellular necrosis in mice, but this has not been seen in other species. Disturbances in porphyrin metabolism have been reported in griseofulvin-treated laboratory animals. Griseofulvin has been reported to have a colchicine-like effect on mitosis and cocarcinogenicity with methylcholanthrene in cutaneous tumor induction in laboratory animals.
Usage in Pregnancy—The safety of this drug during pregnancy has not been established.
Animal Reproduction Studies—It has been reported in the literature that griseofulvin was found to be embryotoxic and teratogenic on oral administration to pregnant rats. Pups with abnormalities have been reported in the litters of a few bitches treated with griseofulvin. Additional animal reproduction studies are in progress.
Suppression of spermatogenesis has been reported to occur in rats, but investigation in man failed to confirm this.
Precautions: Patients on prolonged therapy with any potent medication should be under close observation. Periodic monitoring of organ system function, including renal, hepatic, and hematopoietic, should be done.
Since griseofulvin is derived from a species of Penicillium, the possibility of cross-sensitivity with penicillin exists; however, known penicillin-sensitive patients have been treated without difficulty.
Since a photosensitivity reaction is occasionally associated with griseofulvin therapy, patients should be warned to avoid exposure to intense natural or artificial sunlight. Should a photosensitivity reaction occur, lupus erythematosus may be aggravated.
Griseofulvin decreases the activity of warfarin-type anticoagulants so that patients receiving these drugs concomitantly may require dosage adjustment of the anticoagulant during and after griseofulvin therapy.
Barbiturates usually depress griseofulvin activity and concomitant administration may require a dosage adjustment of the antifungal agent.
Adverse Reactions: When adverse reactions occur, they are most commonly of the hypersensitivity type such as skin rashes, urticaria, and rarely, angioneurotic edema, and may necessitate withdrawal of therapy and appropriate countermeasures. Paresthesias of the hands and feet have been reported rarely after extended therapy. Other side effects reported occasionally are oral thrush, nausea, vomiting, epigastric distress, diarrhea, headache, fatigue, dizziness, insomnia, mental confusion, and impairment of performance of routine activities.
Proteinuria and leukopenia have been reported rarely. Administration of the drug should be discontinued if granulocytopenia occurs.
When rare, serious reactions occur with griseofulvin, they are usually associated with high dosages, long periods of therapy, or both.
Dosage and Administration: Accurate diagnosis of the infecting organism is essential. Medication must be continued until the infecting organism is completely eradicated as indicated by appropriate clinical or laboratory examination. General measures in regard to hygiene should be observed to control sources of infection or reinfection. Concomitant use of appropriate topical agents is usually required, particularly in treatment of *tinea pedis.*
Dosage should be individualized, depending on age and severity of infection. *Adults*—0.5 Gm. daily (125 mg. q.i.d., 250 mg. b.i.d., or 500 mg./day). *Children*—10 mg./kg. daily is usually adequate (from 30 to 50 lb., 125 mg. to 250 mg. daily; over 50 lb., 250 mg. to 500 mg. daily, in divided doses).
How Supplied: GRISACTIN [griseofulvin (microsize)]—No. 442—GRISACTIN 125, each capsule contains 125 mg., in bottles of 100 and 500. No. 443—GRISACTIN 250, each capsule contains 250 mg., in bottles of 100 and 500. No. 444—GRISACTIN 500, each tablet (scored) contains 500 mg., in bottles of 60.

Ayerst

Ayerst Laboratories
New York, N.Y. 10017

7719

The American Retired Physicians Association:

Here's how it can help you plan—and have—a more rewarding retirement

The American Retired Physicians Association (ARPA) is the first and only national organization created specifically to serve the special needs and interests of retired, semi-retired, and soon-to-retire physicians and their spouses. It offers a wide variety of benefits that can significantly contribute to making your retirement everything you hoped for. They include:

- Group travel
- Insurance programs
- Discount information
- Retirement lifestyles
- Expert financial advice
- Opportunities for service
- Information resource bank
- Current medical news
- Bi-monthly *Newsletter*

To be eligible for membership, you must be a physician —or physician's widow—at least 55 years of age. Annual dues are only $20 for a voting member (MDs); $15 for a non-voting member (non-MD, widow-widower). For more information and/or to join, return this coupon today!

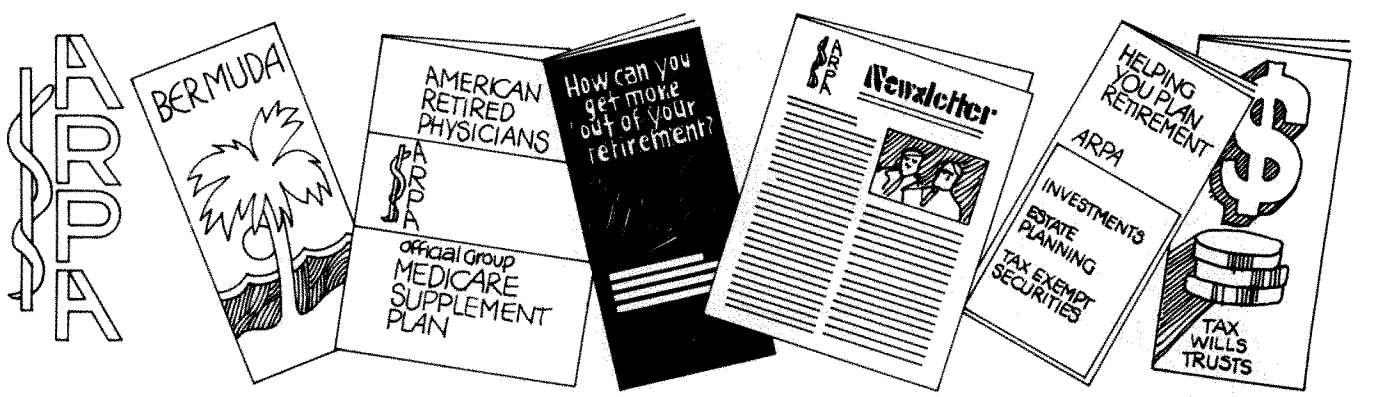

Membership Application

American Retired Physicians Association
536 North State Street
Chicago, Illinois 60610

Enroll me in ARPA

Annual Dues:
$20 MD Voting Member
$15 Non-voting member (Non-MD, widow or widower)

Name _____ Street _____
(Please print or type)

City _____ State _____ Zip _____ Date of Birth _____

Spouse _____ Widow _____ Widower _____

Retired from Practice _____ Part-Time Practice _____ Full-Time _____ Other _____

Specialty _____

Date _____ Signature _____

S/J

IS AQUACARE®/HP TOO MUCH FOR EVERYDAY DRY SKIN?

IF IT WEREN'T SO SAFE AND COSMETICALLY ELEGANT THE ANSWER MIGHT BE YES.

AQUACARE®/HP HYDRATES, SOFTENS AND SOOTHES CHRONIC, SCALING, PRURITIC CONDITIONS . . . WHETHER MILD OR SEVERE.

The keys to a more efficient medical practice

AMA Practice Management Publications

An efficient medical practice requires sound business management. By applying proven management techniques, you can improve the efficiency and profitability of your practice and--most important of all--have more time to devote to your patients.

These AMA Practice Management Publications, developed with the help of medical management consultants, are designed to provide you with the latest techniques and procedures in the management of your practice. Whether you are a new physician who must make immediate decisions about setting up your practice or an established physician who wants to increase the efficiency of your practice, these publications are an invaluable source.

TO ORDER: Write Order Department, American Medical Association, 535 N. Dearborn, Chicago, IL. 60610. Please specify title, OP number, and include payment with your order.

Publications

1 **The Business Side of Medical Practice** (OP-410) $2.00
Guide to basic management principles. Includes: deciding how to practice; selecting a location; setting up an office; financing; legal hurdles; insurance; mechanics of providing good medical service; billings and collections; human relations.

2 **Planning Guide for Physicians' Medical Facilities** (OP-439) $2.00
Provides guidelines and general principles to help you determine the criteria for selecting a medical office that best suits your needs. Includes: basic planning before building; office construction, inside and out; your office interior; office condominiums.

3 **Medicolegal Forms with Legal Anaysis** (OP-109) $1.25
Contains medicolegal forms, with legal analysis and citations of court decisions, for the more common interactions between patients and their physicians and hospitals, such as: consent and informed consent; patient's right to privacy; confidentiality of records; physician-patient relationship.

4 **Preparing a Patient Information Booklet** (OP-441) $.30
A guide for preparing a general information booklet for your patients on your specialty and type of practice.

5 **Talking with Patients** (OP-450) $.30
Provides proven psychological principles and specific examples on how to improve office-patient relations in telephone communications.

6 **Medical Collection Methods** (OP-448) $25.00
A "how to" cassette/workbook program designed to train medical assistants in the most effective collection techniques.
Extra Workbooks (OP-449) $2.00 each

7 **Professional Corporations in Perspective** (OP-102) $3.25
1977 publication which features: economic factors, advantages and disadvantages of incorporation; effect of ERISA on professional corporations; choosing a retirement plan; and managing a professional corporation.

8 **New Doctor's Kit** (OP-458) $10.00
Contains: **The Business Side of Medical Practice; Planning Guide for Physicians' Medical Facilities; AMA Publications Lists; Group Practice Guidelines; Current Procedural Terminology** order form; Uniform Health Insurance Claim Form; **Medicolegal Forms; Talking with Patients; Preparing a Patient Information Booklet;** AMA membership information; Placement Service; and bibliography on billing systems, recording keeping systems, etc.

9 **Group Practice Kit** (OP-457) $7.50
Contains: **Group Practice Guidelines; Professional Corporations in Perspective;** medicolegal reprints on such subjects as: professional liability, confidentiality, informed consent, etc.; samples of model legal agreements for a physician and employed associate, office sharing, medical partnerships, and forming a corporation.

wash it. dry it. peel it.

Fostex,® the flexible therapeutic acne wash that degreases, dries, and peels. Easily integrated with all topical or systemic therapy for acne Grades I, II, and III. Convenient and economical Fostex Liquid and Cream are also effective anti-seborrheic shampoos for oily scalps associated with acne. Available as Fostex Cream in 4½ oz. jars, Fostex Cake in 3¾ oz. bars, and Fostex Liquid in 5 oz. plastic bottles.

Fostril,® the flesh-tinted drying and peeling lotion that conceals as it heals. Adaptable to Grades I, II, or III acne, Fostril is available in 1 oz. plastic tubes.

Transact,® the transparent medicated acne gel. A thin film of Transact will dry the oiliest of skin and is ideal for acne on chest, shoulders, and back. Greaseless, nonstaining, with a fresh clean fragrance. In 1 oz. plastic tubes.

WESTWOOD
PHARMACEUTICALS INC.
Buffalo, New York 14213
In Canada, Belleville, Ontario K8N 1E2

Reservoirs of moisture

Each bath with Alpha Keri® Therapeutic Bath Oil is a reservoir of moisture for dry skin.

The addition of Alpha Keri in the bath helps skin store moisture for days. And feel soft, smooth, and supple in minutes. Between baths, a single application of Keri® Lotion instantly restores moisture to dry skin for hours.

See PDR for complete product information.

Alpha Keri®
Therapeutic Bath Oil

Keri® lotion
Skin Lubricant-Moisturizer

Help skin keep in touch with moisture

WESTWOOD
PHARMACEUTICALS INC.
Buffalo, New York 14213

©1976, W.P. Inc.

CONTEMPORARY AND EFFECTIVE

For seborrhea oleosa and the oily hair and scalp associated with acne



- Thorough cleansing of oily hair and scalp.
- Leaves patients' hair soft, manageable, fresh smelling.
- Elegant herbal scented shampoo.
- A special formulation designed to cleanse and condition oily hair.
- Its pH of 5.5 is gentle to the scalp.
- Can be used as often as necessary, preferably every day, to keep hair looking fresh and healthy.
- CONTAINS NO FORMALDEHYDE.

Supplied: 4 oz. and 8 oz. plastic bottles.

Pernox Shampoo® is adjunctive therapy especially formulated for oily scalps associated with acne.

WESTWOOD
PHARMACEUTICALS INC.
Buffalo, New York 14213

© 1977, W.P. INC.

Schering

When it's all you want, it's all they get.

pure and simple

Chlor-Trimeton® 12mg.

brand of
chlorpheniramine maleate, USP

brand of
Repetabs® Tablets, repeat-action tablets

Available on prescription only.

Also available:
Chlor-Trimeton®
8 mg. Repetabs®
Injection 100 mg./ml.
and 10 mg./ml.

Copyright © 1977 Schering Corporation. All rights reserved.

SWW-9340

New measures of response in psoriasis patients

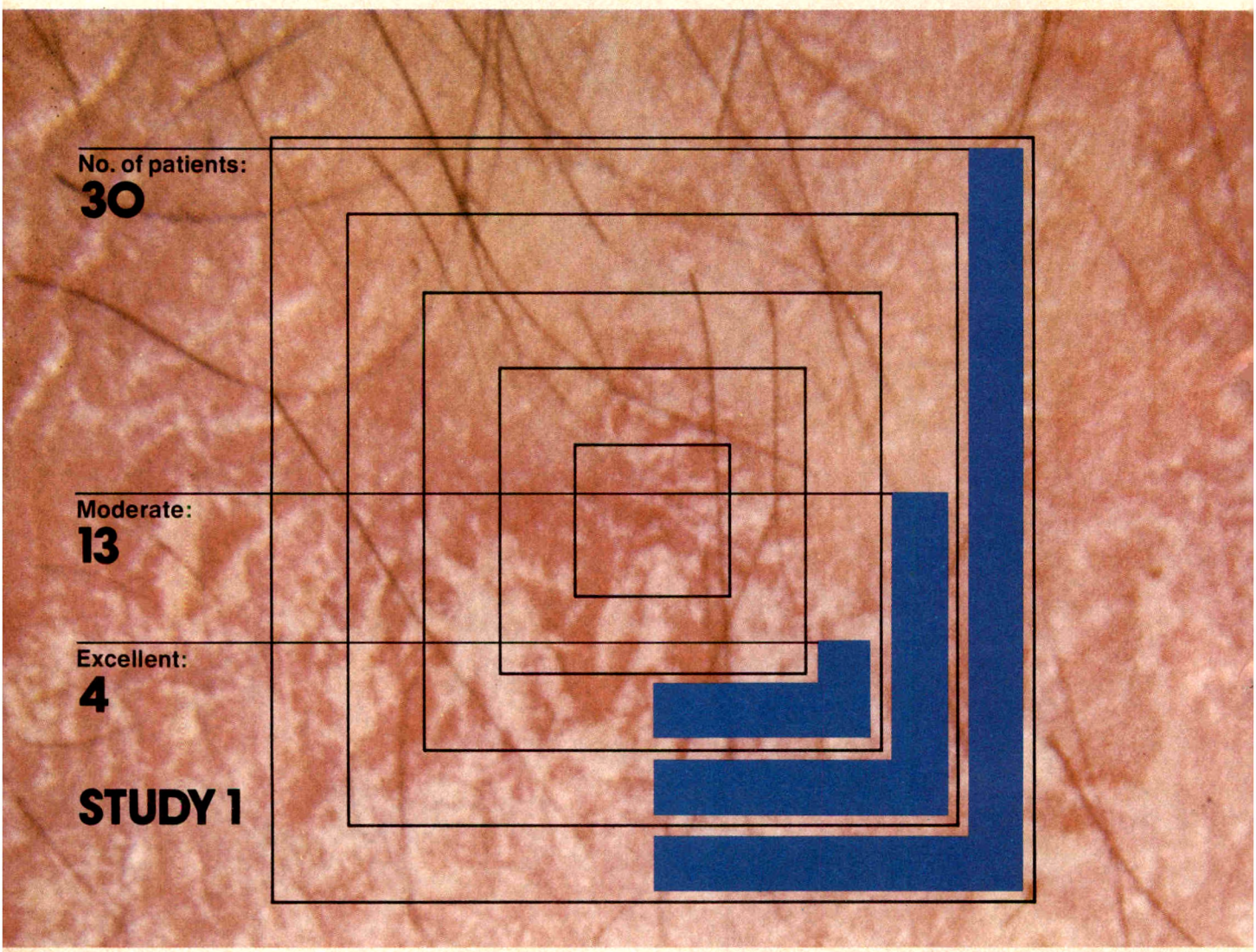

■ ARISTOCORT-A (Triamcinolone Acetonide 0.1%) Cream was applied t.i.d. without occlusion for 14 days, by a total of 60 patients with psoriasis, in 2 similar studies.*

■ The % of moderate or excellent response was 57% in Study 1 and 50% in Study 2. A combined overall response rate of 90% was achieved if 22 patients showing slight response are included.*

■ Overall patient acceptance of the Cream in both these studies was high, when evaluated against 10 criteria.

*Data on file, Lederle Laboratories, Dept. of Medical Research

New studies show 50-57% moderate or excellent response in 14 days

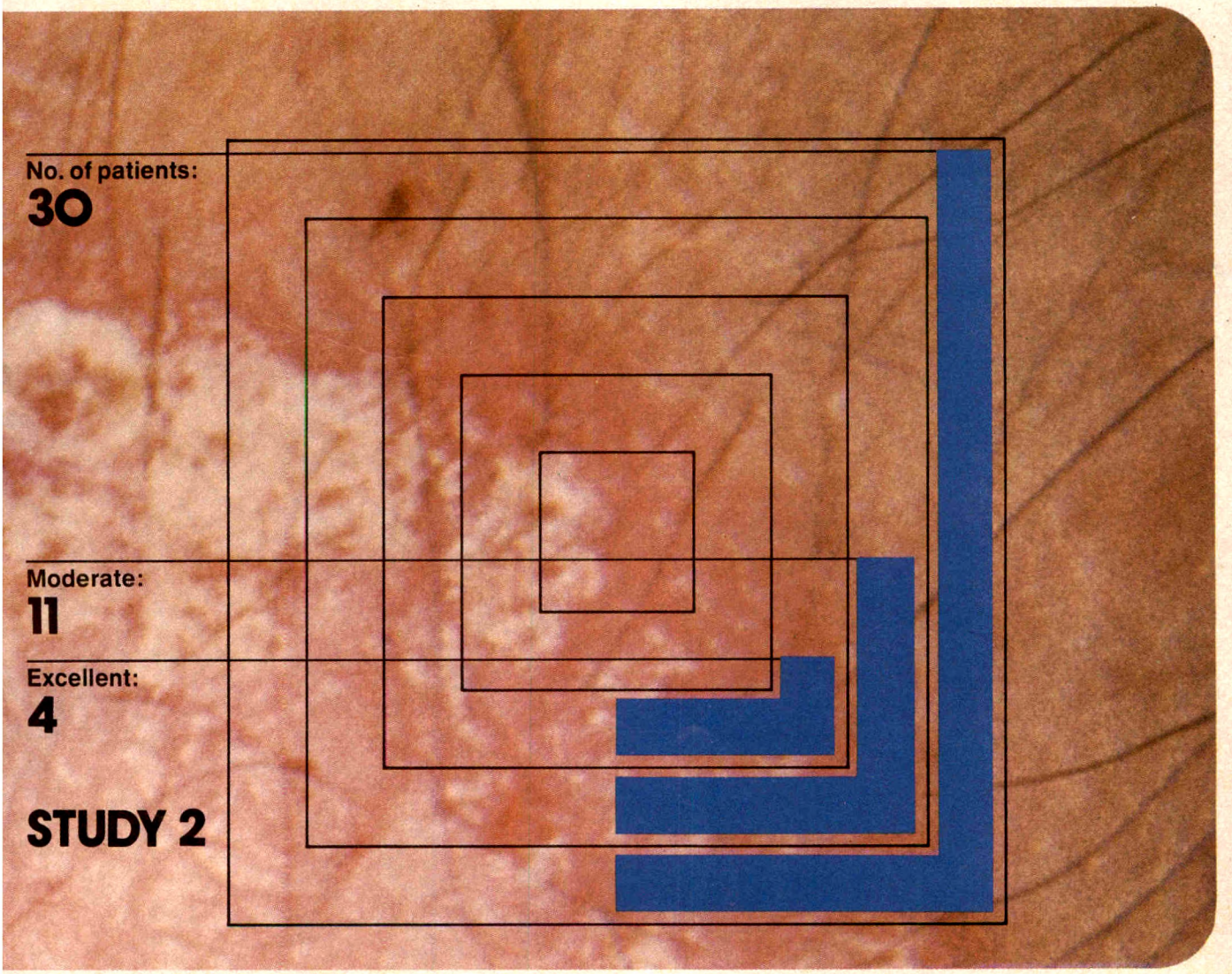

Aristocort®-A

TRIAMCINOLONE ACETONIDE

with AQUATAIN™ Hydrophilic Base

0.1% Cream

See following page for prescribing information.

Measures of Economy

Large size packages
save money when treating chronic and/or extensive dermatoses

CREAM 0.025%
(Quarter Strength)
75 Gm. tubes

OINTMENT 0.1%
(Regular Potency)
75 Gm. tubes

Also available: 15 Gm. tubes of ARISTOCORT A Cream—0.025%, 0.1% and 0.5%—and ARISTOCORT A Ointment, 0.1% and 0.5%.



CREAM 0.1%
(Regular Potency)
75 Gm. tubes
240 Gm. jars

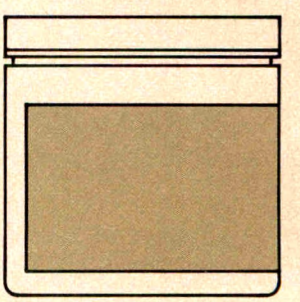

CREAM 0.5%
(High Potency)
240 Gm. jars

INDICATIONS: For relief of inflammatory manifestations of corticosteroid-responsive dermatoses.

CONTRAINDICATIONS: Viral skin diseases, such as varicella and vaccinia; hypersensitivity to any component (not for ophthalmic use); when circulation is markedly impaired.

WARNINGS: Safety of use in pregnancy has not been absolutely established. Do not use extensively, in large amounts, or for prolonged periods of time in pregnant patients.

PRECAUTIONS: If irritation develops, discontinue use and institute appropriate therapy. In infections, use appropriate antifungal or antibacterial agents; if a favorable response does not occur promptly, discontinue the corticosteroid until the infection is adequately controlled. If extensive areas are treated or the occlusive technique is used, increased systemic absorption of the corticosteroid may occur; take suitable precautions.

ADVERSE REACTIONS: (local) Burning sensations, itching, irritation, dryness, folliculitis, secondary infection, skin atrophy, striae, hypertrichosis, acneform eruption and hypopigmentation.

ARISTOCORT A CREAM: Each gram of ARISTOCORT A contains 0.25 mg. (0.025%), 1 mg. (0.1%) or 5 mg. (0.5%) of the highly active steroid, Triamcinolone Acetonide (a derivative of triamcinolone) in AQUATAIN, a specially formulated base composed of emulsifying wax NF, isopropyl palmitate, glycerin USP, sorbitol solution USP, lactic acid, 2% benzyl alcohol and purified water. AQUATAIN is non-staining, water-washable, paraben-free, spermaceti-free and has a light texture and consistency.

ARISTOCORT A OINTMENT: Each gram of ARISTOCORT A Ointment contains 1 mg. (0.1%) or 5 mg. (0.5%) of the highly active steroid, Triamcinolone Acetonide (a derivative of triamcinolone) in a specially formulated base composed of emulsifying wax NF, white petrolatum, and propylene glycol. In addition, the 0.1% Ointment contains Tenox II and lactic acid.

Lederle

LEDERLE LABORATORIES,
A Division of American Cyanamid Company
Pearl River, New York 10965

066-7R

Aristocort®-A
TRIAMCINOLONE ACETONIDE with AQUATAIN™ Hydrophilic Base
0.1% Cream

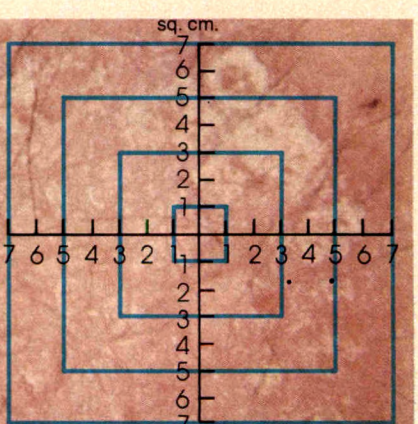

A free measure for lesions
Ask your Lederle Representative for a complimentary supply.

An excellent blend of clinical efficacy and cosmetic acceptance. Now indicated for seborrheic dermatitis.

Obviously, efficacy is foremost in your mind when you recommend a therapeutic shampoo. And efficacy, coupled with cosmetic acceptability, usually guarantees a successful therapeutic course.

That's why Head & Shoulders is so highly regarded in the treatment of dandruff.

Clinically effective

For years, Head & Shoulders has proved effective in the treatment of dandruff—whether for initial therapy or long-term control. And now, research shows that Head & Shoulders is effective in the treatment of seborrheic dermatitis.*

Cosmetically pleasing

Head & Shoulders lathers well, has a pleasant odor and appearance, and need not be left on the scalp for an extended period of time. Also, it leaves hair clean, manageable, and attractive.

Head & Shoulders®

You'll like it for its therapeutic benefits. Your patients will like it for its cosmetic appeal.

*Orentreich, N.: A clinical evaluation of two shampoos in the treatment of seborrheic dermatitis, J. Soc. Cosmet. Chem. 23:189 (March 3) 1972.

HOECHST-ROUSSEL PHARMACEUTICALS INCORPORATED

Announces a New topical fluorinated corticosteroid in a Unique Emollient Cream Base

NEW TOPICORT
(DESOXIMETASONE)

THE SPECIALLY DEVELOPED, PRESERVATIVE-FREE BASE COMBINES THE EMOLLIENCE OF AN OINTMENT WITH THE COSMETIC ACCEPTABILITY OF A CREAM IN A WATER-IN-OIL EMULSION.

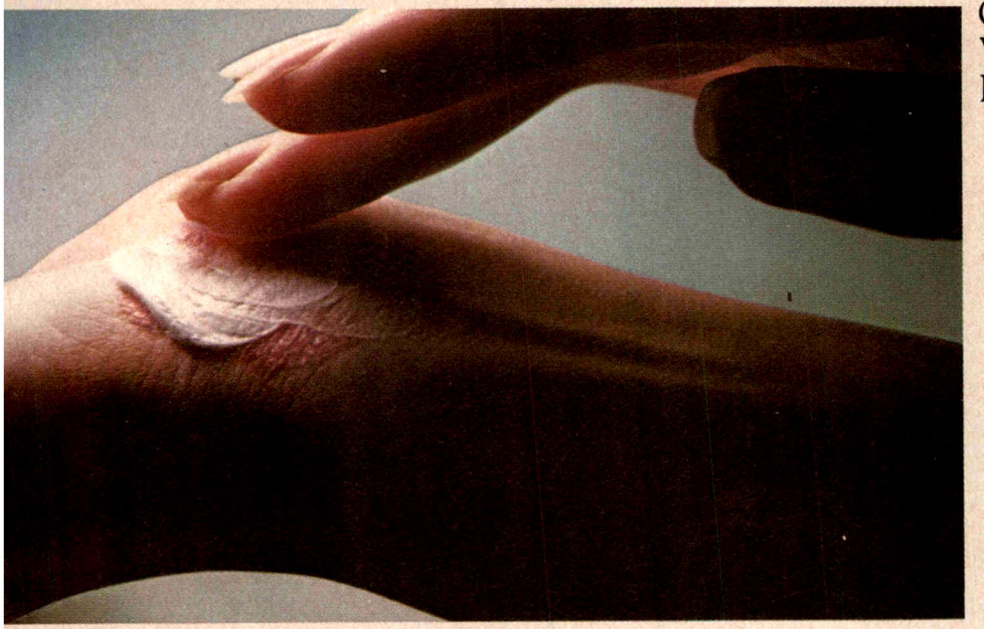

Well-documented efficacy and safety: Anti-inflammatory, antipruritic, vasoconstrictive Topicort (desoximetasone) has been demonstrated safe and effective in relieving the inflammatory manifestations of corticosteroid-responsive dermatoses.

Worldwide clinical experience: For up to 4 years, Topicort (desoximetasone) has been marketed by Hoechst in over 30 foreign countries. Extensive clinical trials in the United States, conducted by 23 investigators under a wide variety of climatic conditions, confirm the many years of worldwide experience.

A wide range of conditions in corticosteroid-responsive dermatoses: Topicort (desoximetasone) is useful on wet as well as dry lesions, in both acute and chronic cases, with a profile of adverse reactions similar to that seen with other topical corticosteroids.

Emollient Cream 0.25%

Available: 15-gram tubes.
In corticosteroid-responsive dermatoses
Convenient B.I.D. dosage.

Please consult full prescribing information on following page.

Q7103J-677

TOPICORT®(desoximetasone) EMOLLIENT CREAM 0.25%

Description: Topicort® (desoximetasone) Emollient Cream 0.25% contains the active synthetic corticosteroid desoximetasone. The chemical name of desoximetasone is 9α - fluoro - 11β, 21 - dihydroxy - 16α - methylpregna - 1,4 - diene-3,20-dione. The chemical structure is:

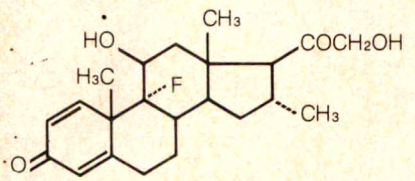

Each gram of Topicort® (desoximetasone) Emollient Cream 0.25% contains 2.5 mg desoximetasone in an emollient cream consisting of isopropyl myristate, cetylstearyl alcohol, white petrolatum, mineral oil, lanolin alcohol and purified water.

Actions: Topicort® (desoximetasone) Emollient Cream is primarily effective because of its anti-inflammatory, antipruritic and vasoconstrictive actions.

Indications: Topicort® (desoximetasone) Emollient Cream is indicated for the relief of inflammatory manifestations of corticosteroid-responsive dermatoses.

Contraindications: Topical steroids are contraindicated in vaccinia, varicella and in those patients with a history of hypersensitivity to any of the components of the preparation. This preparation is not for ophthalmic use.

Precautions: If local infection exists, suitable concomitant antimicrobial or antifungal therapy should be administered. If a favorable response does not occur promptly, application of the corticosteroid should be discontinued until the infection is adequately controlled.

Although systemic side effects associated with absorption of topical corticosteroid preparations are rare, their possible occurrence must be kept in mind when these preparations are used over large areas or for an extended period of time, or if occlusive technique is used.

If irritation or sensitization develops, the preparation should be discontinued and appropriate therapy instituted.

Although topical steroids have not been reported to have an adverse effect on pregnancy, the safety of their use during pregnancy has not been absolutely established; therefore, they should not be used extensively on pregnant patients, in large amounts, or for prolonged periods of time.

Adverse Reactions: The following local adverse reactions have been reported with topical corticosteroids: burning, itching, irritation, striae, skin atrophy, secondary infection, dryness, folliculitis, hypertrichosis, acneform eruptions and hypopigmentation. The following may occur more frequently with occlusive dressings: maceration of the skin, secondary infection, skin atrophy, striae, and miliaria.

Dosage and Administration: Apply a thin film of Topicort® (desoximetasone) Emollient Cream 0.25% to the affected skin areas twice daily. Rub in gently.

How Supplied: Topicort® (desoximetasone) Emollient Cream 0.25% is supplied in 15-gram tubes.

HOECHST-ROUSSEL
PHARMACEUTICALS INCORPORATED
SOMERVILLE, NEW JERSEY 08876

Announcing three important NEW changes in the ARCHIVES OF NEUROLOGY



New Focus
Look for more original articles of immediate clinical application . . . more case reviews of solid, "hands on" bedside experience—look for the NEW ARCHIVES OF NEUROLOGY to be more relevant to your practice.

New Face
Guiding the journal's new thrust is Maurice W. Van Allen, M.D., Chairman of the Department of Neurology at the University of Iowa School of Medicine, and a noted clinician, educator, researcher, lecturer, and medical writer.

New Facade
A unique modular, four-color design highlights the key articles in each issue.

The NEW ARCHIVES OF NEUROLOGY . . . NOW with articles of interest to ALL physicians who have indicated a concern for treatment of neurological disorders.

If you wish to subscribe, write: Circulation Dept., AMA, 535 N. Dearborn St., Chicago, IL. 60610, and enclose $18.00 for a 1-year subscription.

Sulfoxyl® Lotion Regular ℞
Sulfoxyl® Lotion Strong
Composition: Sulfoxyl Lotion Regular contains 5% benzoyl peroxide and 2% sulfur; Sulfoxyl Lotion Strong contains 10% benzoyl peroxide and 5% sulfur, each in a lotion base formulated with polyethylene glycol monostearate, stearic acid, glycerol monostearate, isopropyl palmitate, propylene glycol, zinc soap and purified water.
Indications: Use as a topical aid in the treatment of acne.
Dosage and Administration: After cleansing the skin, smooth Sulfoxyl Lotion gently into the affected areas, once daily for three days. If no discomfort is felt, frequency of application can then be increased to twice daily. The amount of drying and desquamation can be modified by adjusting the dosage schedule.
Contraindications: Patients with a known sensitivity to benzoyl peroxide, sulfur or any of the other formulation ingredients should not use these medications.
Precautions: For external use only. Avoid contact with eyes, mucous membranes and sensitive areas of the neck. Notify physician if excessive dryness or irritation occurs or increases.
Keep from heat.
Caution: Patients should be warned that these formulations may bleach colored linens, towels and apparel.
How Supplied: 1.0 ounce plastic bottles.
Caution: Federal law prohibits dispensing without prescription.

Benoxyl® 5 and 10 Lotion: Benoxyl 5 contains 5% benzoyl peroxide and Benoxyl 10, 10% benzoyl peroxide in a grease-free washable lotion base.
How Supplied: 1 oz. and 2 oz. plastic bottles.

PanOxyl® 5, PanOxyl® 10 ℞
Composition: PanOxyl 5 contains 5% Benzoyl Peroxide. PanOxyl 10 contains 10% Benzoyl Peroxide. PanOxyl 5 and PanOxyl 10 also contain 6% polyoxyethylene lauryl ether and 40% ethyl alcohol in a gel base formulated with colloidal magnesium aluminum silicate, hydroxypropylmethylcellulose, citric acid and purified water.
Action and Uses: The topical use of PanOxyl 5 and PanOxyl 10 provides therapeutic control of acne through drying and desquamative action, as well as providing antiseptic activity.
Indications: Use as an aid in the treatment of acne.
Dosage and Administration: Apply 1 or more times daily to affected areas. Washing the face with soap and water prior to application greatly enhances the efficacy of the medication.
Contraindications: Patients with a known sensitivity to Benzoyl Peroxide should not employ these medicatons.
Precautions: For external use only. Avoid contact with the eyes or mucosal membranes. Very fair individuals should always be started on a single application at bedtime, allowing the medication to remain on the skin overnight. PanOxyl may bleach colored fabrics.
How Supplied: 2 oz. and 4 oz. plastic tubes.
Caution: Federal law prohibits dispensing without prescription.

STIEFEL
Logical Dermatologicals since 1847
Stiefel Laboratories, Inc.,
Oak Hill, N.Y. 12460
Stiefel Laboratories (Canada) Ltd.,
St. Laurent, Quebec, Canada H4R 1E1

Three Dimensions of Acne Care

The widest range of benzoyl peroxide formulations gives you maximum therapeutic flexibility

New Sulfoxyl® Lotion

The drying and desquamating effects of sulfur added to benzoyl peroxide can be particularly valuable in acne complicated by excessive oiliness. "...Sulfur with benzoyl peroxide ...produces a greater keratolytic effect than either substance alone."[1] The exfoliative properties of sulfur can help benzoyl peroxide to penetrate deeper into sebaceous follicles.

Two Strengths:
Sulfoxyl® Lotion Regular (5% benzoyl peroxide and 2% sulfur) and Sulfoxyl® Lotion Strong (10% benzoyl peroxide and 5% sulfur) in a grease-free washable base.

Benoxyl® Lotion

A good way to start benzoyl peroxide therapy. Benzoyl peroxide alone has been described as "a triple action drug: (1) it suppresses *C. acnes* in vivo; (2) it is comedolytic and (3) it is a counter-irritant."[3]

Two Strengths
Benoxyl® 5 Lotion (5% benzoyl peroxide) and Benoxyl® 10 Lotion (10% benzoyl peroxide) in a grease-free washable base.

PanOxyl® Gel

"The most potent forms of benzoyl peroxide are the new alcohol gels such as PanOxyl. Once the gel is applied to the skin, the solvent evaporates and deposits a concentrated form of depot free-radical oxygen which...is capable of penetrating into the sebaceous follicles and suppressing the *C. acnes*. This topical agent is much more effective in suppressing the fatty acids and the bacterial counts than systemic tetracycline and also produces a more rapid clinical improvement... No new lesions usually appear after 3 weeks and after 2 months the patient is usually free of the acne problem."[2]

Two Strengths:
PanOxyl® 5 Gel (5% benzoyl peroxide) and PanOxyl® 10 Gel (10% benzoyl peroxide) in an alcohol gel base.

STIEFEL

Stiefel Laboratories, Inc., Oak Hill, New York 12460
Stiefel Laboratories (Canada) Ltd.
St. Laurent, Quebec, Canada H4R 1E1
Logical Dermatologicals since 1847

ee opposite page for prescribing information

Kirton, V. and Wilkinson, D.S.: *Practitioner*, **204**: 683, 1970
2. Fulton, J.E., Jr.: Acne Vulgaris. *Current Ther.* ed. Conn, H.F., 558-560, 1975
Fulton, J.E., Jr. et al. in *Acne Morphogenesis and Treatment*, Plewig, G. and Kligman, A.M., Springer-Verlag, 290-1, 1975

Contains nothing that will interfere with or aggravate your acne regimen.

No sulfur, no salicylic acid, no medication, no perfume. Acne-Aid® Detergent Soap means gentle cleaning, *pure and simple.*

You can recommend it with even your most aggressive therapeutic measures, such as tretinoin or PanOxyl®.. where many medicated soaps may be contraindicated.

STIEFEL
Logical Dermatologicals since 1847

Stiefel Laboratories, Inc.,
Oak Hill, N.Y. 12460
Stiefel Laboratories (Canada) Ltd.,
St. Laurent, Quebec, Canada H4R 1E1

The $25 investment that could save you from a malpractice suit

One in every 10 physicians now faces a malpractice suit, and 40% will lose their cases, according to a study by a major insurance company. And every fourth doctor can count on at least one malpractice suit during his career.



What you can do to protect yourself

If you know your legal obligations to your patients and are aware of the problem areas that can lead to potentially dangerous situations, you could significantly reduce the odds of a malpractice suit.

You get exactly that kind of vital information from THE CITATION, a twice monthly publication of the American Medical Association's Office of the General Counsel. The price: only $25 for a year's subscription of 25 issues.

Learn prevention from the experience of others

THE CITATION brings you summaries of actual malpractice cases involving claims of abandonment, negligence, mistaken diagnosis, therapeutic procedure, lack of consent, and many more. Each summary is a concise report of a case, including background, evidence, defense, and decision.

Here's what reading THE CITATION regularly can mean to you:

- Learning the problem areas and from the experience of others so you can avoid similar situations.
- Developing a keener insight into situations that can create trouble.
- Being aware of the kinds of medical cases for which you should seek consultation.
- Gaining a better understanding of the laws, and their applications to specific cases.

In addition, THE CITATION provides information on every kind of legal problem you can expect to encounter in your practice.

Can you afford to be without it?

The odds being what they are for a malpractice suit, the physician who doesn't know how to take every possible precaution is courting trouble. *Prevention* is the best possible defense against a malpractice suit; and THE CITATION is the *best* way to learn how to avoid the problem areas.

A one-of-a-kind publication

THE CITATION is the only publication, at any price, that provides comprehensive coverage, on a nationwide basis, of all areas of the law that have impact on the practice of medicine.

The wisest $25 investment you can make

When you think of the money, time, and aggravation THE CITATION could save you, $25 for a one year subscription is a very small price indeed. Take a minute right now to subscribe. Fill out the form below and send it, along with your payment, to the address indicated.

THE CITATION
535 N. Dearborn Street/Chicago, Ill. 60610

S/J

I enclose $_____ for _____ year(s) of THE CITATION. (Please send payment with order.)

1 year (25 issues): $25.00 2 years (50 issues): $48.00

Name _____

Address _____

City/State/Zip _____

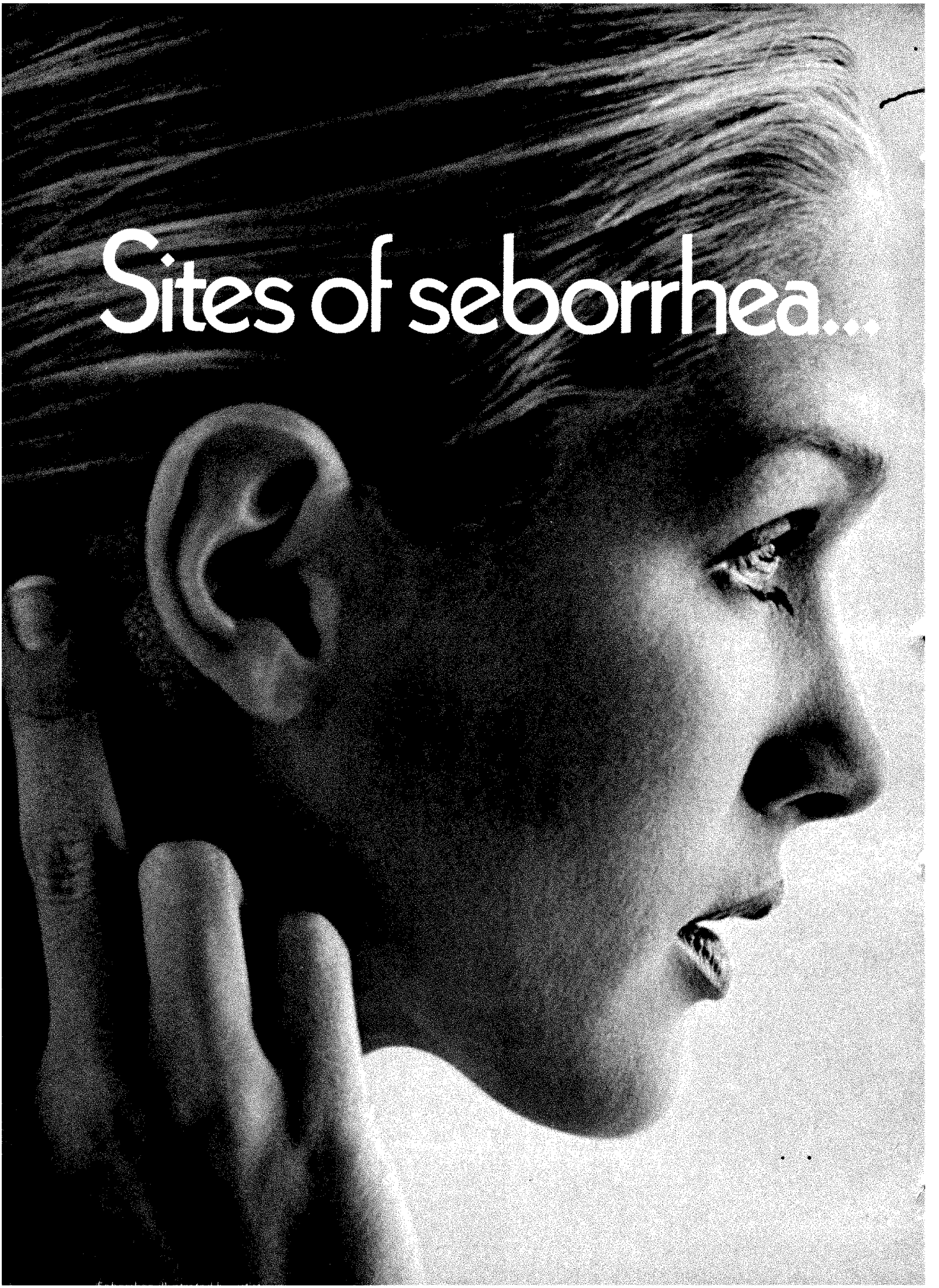
Sites of seborrhea...



spotsite

Uticort™

(betamethasone benzoate)

a highly effective topical steroid in a special base

UTICORT contains the fluorinated corticosteroid ester — betamethasone benzoate 0.025% — in a specially formulated, clear, self-liquefying gel base to increase steroid activity.

Patients with seborrheic dermatitis treated with UTICORT improved 86% in an average of 11.6 days.

liquefies on application for better surface contact

UTICORT is especially valuable in the treatment of seborrheic dermatitis on hairy areas of the body.

cosmetically acceptable

UTICORT dries to a clear film and can be used confidently on either smooth or hairy skin areas. Moreover, it is greaseless, nonstaining, and nonsticky.

preservative free

Contains no parabens or other potentially sensitizing preservatives.

Brief summary of prescribing information

INDICATIONS. Uticort Gel (betamethasone benzoate) is intended for relief of the inflammatory manifestations of corticosteroid-responsive dermatoses.

CONTRAINDICATIONS. Topical steroids are contraindicated in viral diseases of the skin, such as varicella and vaccinia. Topical steroids are contraindicated in patients with a history of sensitivity to any of the components of the preparation.

This preparation is not for ophthalmic use.

PRECAUTIONS. If irritation develops, the gel should be discontinued and appropriate therapy instituted. In the presence of an infection, the use of appropriate antifungal or antibacterial agents should be instituted. If a favorable response does not occur promptly, the corticosteroid should be discontinued until the infection has been adequately controlled.

If extensive areas are treated, or if the occlusive technique is used, the possibility exists of increased systemic absorption of the corticosteroid, and suitable precautions should be taken.

Although topical steroids have not been reported to have an adverse effect on pregnancy, the safety of their use in pregnant females has not absolutely been established. Therefore, they should not be used extensively on pregnant patients, or in large amounts, or for prolonged periods of time.

Due to the alcohol content of the vehicle, Uticort Gel (betamethasone benzoate) may cause mild, transient stinging without irritation if used on excoriated skin.

ADVERSE REACTIONS. The following local adverse reactions have been reported with topical corticosteroids: burning sensations, itching, irritation, dryness, folliculitis, secondary infection, skin atrophy, striae, hypertrichosis, acneform eruptions, and hypopigmentation.

DOSAGE AND ADMINISTRATION. Apply to affected areas two to four times daily as needed.

HOW SUPPLIED. N 0071-3025 Uticort Gel is supplied in 15-g and 60-g tubes.

Caution: Federal law prohibits dispensing without prescription.

PARKE-DAVIS

PARKE, DAVIS & COMPANY, Detroit, MI 48232



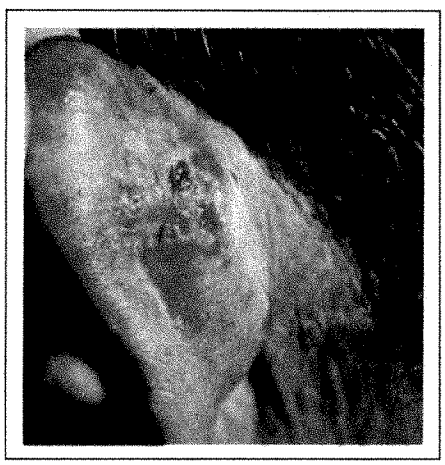

2/6/70—Before treatment a 3.0 cm lesion was present behind left ear. Biopsy revealed it to be a superficial basal cell carcinoma. Treatment with Efudex (fluorouracil) 5% Cream was begun.

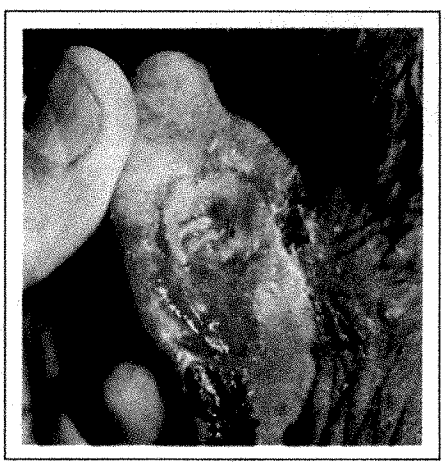

5/1/70—After 11 weeks' therapy, lesion site was necrotic and escharified; surrounding skin showed minimal inflammation. Treatment was terminated 4/24/70.

9/10/70—Area completely healed; posttreatment biopsy revealed no further carcinoma.

6/15/72—Patient 25 months posttreatment. No evidence of recurrence.

Management of superficial basal cell carcinoma is often complicated by multiple lesions which extend over large areas of the body. Until now, primary treatment has been surgery or radiation therapy. However, these modalities may be followed by scarring and disfigurement.

Topical chemotherapy with Efudex (fluorouracil) 5% is a valuable alternative when conventional methods are impractical. For example, it is an effective agent for the concurrent treatment of superficial lesions over large areas of the body, or for use on difficult treatment sites.

Although during treatment with Efudex the lesion and some of the surrounding skin may become inflamed and blistered temporarily, final results are cosmetically gratifying, with minimal or no scarring.

Efudex 5% Cream offers the dermatologist:

- An effective topical alternative to surgery for multiple lesions and difficult treatment sites.
- Cosmetically gratifying results, with minimal or no scarring. No systemic toxicity.
- Convenient, economical b.i.d. application. Apply with care near eyes, nose and mouth; wash hands immediately afterward if applied with fingers.

Efudex® 5% Cream
fluorouracil/Roche
An exclusive Roche formulation
Also available as 5% Efudex Solution

Before prescribing, please consult complete product information, a summary of which follows:

Indications: Multiple actinic or solar keratoses; superficial basal cell carcinomas when conventional methods are impractical (5% strength only).

Contraindications: If occlusive dressing is used, may increase inflammatory reactions in adjacent normal skin. Avoid prolonged exposure to ultraviolet rays. Safe use in pregnancy not established.

Precautions: If applied with fingers, wash hands immediately. Apply with care near eyes, nose and mouth. Solar keratoses failing to respond should be biopsied; perform follow-up biopsies in superficial basal cell carcinoma.

Adverse Reactions: Local—pain, pruritus, hyperpigmentation and burning at application site most frequent; also dermatitis, scarring, soreness, tenderness, suppuration, scaling and swelling. Also reported—insomnia, stomatitis, irritability, medicinal taste, photosensitivity, lacrimation, telangiectasia, leukocytosis, thrombocytopenia, toxic granulation and eosinophilia.

Dosage and Administration: *Actinic or solar keratosis*—apply sufficient quantity to cover lesions, twice daily. Usual length of therapy is 2 to 4 weeks. *Superficial basal cell carcinomas*—apply sufficient quantity (only 5% strength recommended) to cover lesions, twice daily. Continue treatment for at least 3 to 6 weeks, but possibly as long as 10 to 12.

How Supplied: Solution, 10-ml drop dispensers containing 2% or 5% fluorouracil on a weight/weight basis. Cream, 25-Gm tubes containing 5% fluorouracil in a vanishing cream base.

ROCHE

Roche Laboratories
Division of Hoffmann-La Roche Inc.
Nutley, New Jersey 07110



Let's dispense with unusual amenities.

Cryo-surgery is a highly specialized science and surgical skill. And of course liquid nitrogen storage is especially critical.

Cryenco Biostat® Model 350 LN_2 dispensing dewars are unsurpassed in the field for efficiency, durability and dependability.

Each Model 350 is hand-crafted with long-life stainless steel outer shell construction and a 2-year warranty.

Engineered for consistant service, Model 350 dispenses LN_2 conveniently and efficiently for dermatological use and boasts a working duration of up to 3 months, without a refill.

Engineering, service and design features all add up to a storage facility with truly unusual advantages. Write today for a free catalog or contact your local Cryenco representative.

Cryenco
A HELIX COMPANY

Sales Division / 11055 Leroy Drive
Denver, Colorado 80233 (303) 451-1031

KENALOG® SPRAY
Triamcinolone Acetonide Aerosol N.F.

DESCRIPTION: Kenalog Spray (Triamcinolone Acetonide Aerosol N.F.) provides 3.3 mg. triamcinolone acetonide per 50 grams in an isopropyl palmitate vehicle with alcohol (4.7%) and propellants.

INDICATIONS: Kenalog Spray (Triamcinolone Acetonide Aerosol N.F.) is indicated for relief of the inflammatory manifestations of corticosteroid-responsive dermatoses.

CONTRAINDICATIONS: Topical steroids are contraindicated in viral diseases of the skin, such as vaccinia and varicella, and in patients with a history of hypersensitivity to any product component. This preparation is not for ophthalmic use. Topical steroids should not be used when circulation is markedly impaired.

WARNINGS: Usage in Pregnancy— Although topical steroids have not been reported to have an adverse effect on the fetus, the safety of their use during pregnancy has not been absolutely established; therefore, they should not be used extensively on pregnant patients, in large amounts, or for prolonged periods of time.

PRECAUTIONS: Administer suitable antifungal or antimicrobial therapy if infection exists; if there is not a prompt, favorable response, discontinue the corticosteroid until the infection has been adequately controlled. Discontinue the drug and institute appropriate therapy if irritation develops. If extensive areas are treated or if the occlusive technique is used, the possibility exists of increased systemic absorption of the corticosteroid and suitable precautions should be taken. When used about the face, the eyes should be covered and inhalation of the spray avoided.

ADVERSE REACTIONS: The following local adverse reactions have been reported with topical corticosteroids either with or without occlusive dressings: burning sensations, itching, irritation, dryness, folliculitis, secondary infection, skin atrophy, striae, miliaria, hypertrichosis, acneform eruptions, maceration of the skin and hypopigmentation; contact sensitivity to a particular dressing material or adhesive may occur occasionally. Some patients (particularly those with very dry skin or dry lesions) may find the cooling effect of the spray objectionable or complain of a transient burning or stinging sensation.

For full prescribing information, consult package insert.

HOW SUPPLIED: Kenalog Spray (Triamcinolone Acetonide Aerosol N.F.) is available in spray dispenser cans of 50 and 150 g. with adapter.

SQUIBB®

©1977 E.R.Squibb & Sons,Inc. 327-503

ANOTHER CASE FOR KENALOG®
TRIAMCINOLONE ACETONIDE

"INTRACTABLE" SCALP PSORIASIS

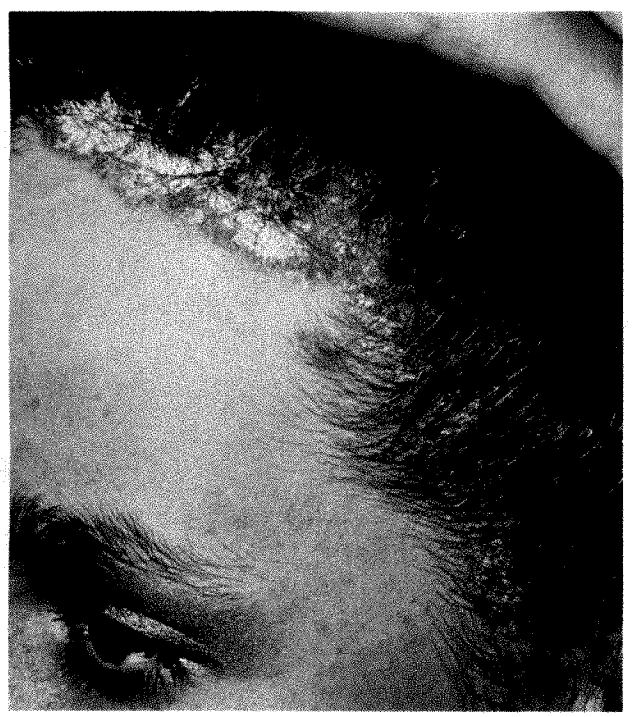

MARCH 4, 1977

A 15-year-old patient complaining of severe, intractable psoriasis of the scalp. Previous therapy with tar shampoo, keratolytic agents and fluorinated topical steroids had been unsuccessful. Because prior topical agents had been difficult to apply, Kenalog® Spray b.i.d. was prescribed.

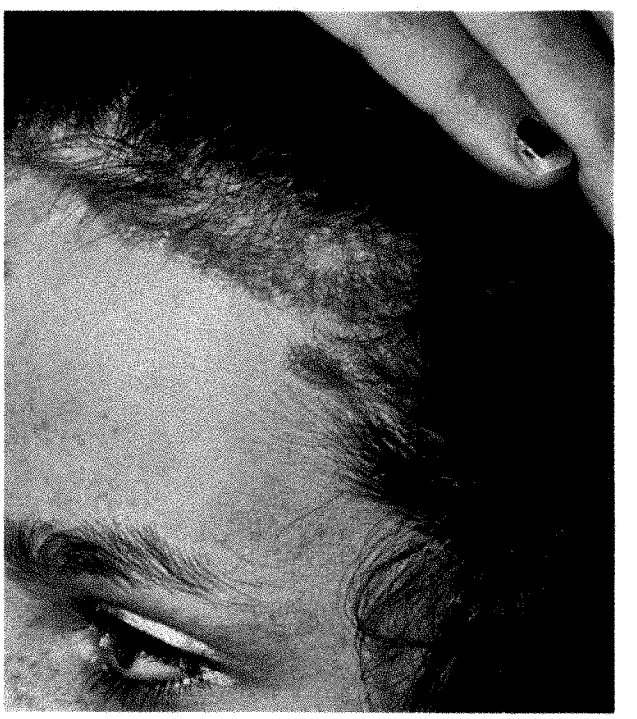

AFTER 1 WEEK

Patient reported that pruritus had been relieved promptly. Marked improvement observed at this time: absence of scales, decrease in erythema and central clearing of plaques. Patient continuing on Kenalog® Spray b.i.d.
Case history on file at Squibb Institute for Medical Research.

A CASE FOR KENALOG® SPRAY

TRIAMCINOLONE ACETONIDE AEROSOL N.F.

See adjacent column for brief summary.

For dry skin care on a day-to-day basis, consider the soothing, softening, nondetergent cleansing properties of Alpha Keri Soap.

- Excellent cleansing properties eliminate harshness and irritation
- Contains Alpha Keri® therapeutic bath oil to soothe and soften skin
- Rich lather and delicate scent create outstanding patient acceptance

Alpha Keri® soap

The soothing, smoothing detergent-free cleanser

WESTWOOD
PHARMACEUTICALS INC.
Buffalo, New York 14213

PUVA Statement

The Task Forces on Psoriasis and Photobiology of the American Academy of Dermatology (AAD) met in Chicago during the annual meeting of the academy, December 1976, to discuss PUVA therapy. The following statement was developed by these two task forces and accepted by the AAD Board of Directors. It was issued as a special notice at the AAD meeting and published in the AAD Bulletin.

A number of papers on PUVA therapy for psoriasis have appeared in the ARCHIVES *or are in press. In addition, the journal will continue to evaluate and accept manuscripts related to the scientific aspects of PUVA. However, the editors would like to emphasize that they are in complete agreement with the academy's position that is presented in the following statement.*—EDS.

The Psoriasis and Photobiology Task Forces of the American Academy of Dermatology make the following statement concerning PUVA therapy for psoriasis. Because of initial success of PUVA therapy, its use may become widespread before completion of investigative evaluation. The following considerations are unanswered:

1. Determination of the lowest effective irradiation dose to minimize potential long-term damage
2. Determination of maintenance irradiation requirements, with consideration of potential for chronic cutaneous changes
3. Evaluation of histopathological data that may be of prognostic importance
4. Determination of necessary protective measures to prevent ocular, as well as cutaneous, injury
5. Further observation to determine if the treatment may produce serious threats relating to carcinogenesis, including melanoma formation and malignancies of circulating blood elements

Therefore, this form of photochemotherapy cannot be recommended until the above questions have been evaluated by controlled analytical procedures.

Topical Halcinonide and Betamethasone Valerate Effects on Plasma Cortisol

Acute and Subacute Usage Studies

Edward C. Gomez, MD, PhD; Lewis Kaminester, MD; Phillip Frost, MD

• **The effect of topical application of halcinonide cream and betamethasone valerate cream on plasma cortisol was studied in an acute usage study as well as a subacute study, which more closely approximated common clinical usage. In the acute study, halcinonide cream caused a marked decrease in plasma cortisol, both with and without occlusion, in patients with extensive psoriasis, but only with occlusion in normal subjects. Betamethasone valerate cream decreased plasma cortisol levels in patients with extensive psoriasis when applied with occlusion and, to a lesser extent, without occlusion. In a double-blind subacute usage study without occlusion, two of 23 patients treated with halcinonide cream showed decreased plasma cortisol levels during the treatment period, while none of the 21 patients treated with betamethasone valerate cream showed such decreases. Three patients in the halcinonide group developed striae. Clinical response to halcinonide was superior to that with betamethasone valerate cream, but a similar number of patients were resistant to treatment with each medication.**

(*Arch Dermatol* **113:1196-1202, 1977**)

The effects of topical application of potent fluorinated adrenal corticosteroid preparations, with or without occlusion, have been well documented.[1,2] In the presence of an abnormal barrier to percutaneous absorption or with the increased percutaneous absorption produced by occlusion, sufficient absorption of a variety of corticosteroid preparations occurs to produce suppression of endogenous production of cortisol. Such studies have usually been acute usage experiments.[1-5] The extrapolation from these studies to the common, usually longer term use of corticosteroid preparations in clinical practice is less clear.

In the course of evaluating adrenal effects of a new and potent topical corticosteroid preparation, halcinonide cream, we have compared the effects obtained with such an acute usage protocol to those obtained with subacute usage protocol, which more closely approximated the usual clinical situation. This article reports the adrenal effects of halcinonide cream, 0.1%, and betamethasone valerate cream, 0.1%, when applied for five days with and without occlusion to both normal and diseased skin, in comparison to the effects of the same preparations when used on an outpatient basis over a four- to six-week period without occlusion.

Accepted for publication Nov 22, 1976.

From the Department of Dermatology, Mount Sinai Medical Center, Miami Beach. Dr Gomez is now with the Department of Dermatology, New York University Medical Center.

Reprint requests to Mount Sinai Medical Center, 4300 Alton Rd, Miami Beach, FL 33140 (Dr Frost).

SUBJECTS AND METHODS

Patient Selection

All patients were volunteers who, after an explanation of the protocol to be followed, signed an informed consent form

Table 1.—Relative Fluorescence of Cortisol, Halcinonide, and Betamethasone Valerate*

Compound	nmoles	Fluorescence Units†
Cortisol	4.9	21
	9.8	41
	19.6	75
Halcinonide	9.8	0
	19.6	0
Betamethasone valerate	9.8	0
	19.6	0

*Aliquots of 196 μM standard ethanolic solutions of the various corticosteroids were added to 4 ml of fluorescence reagent and incubated at room temperature for 30 to 60 minutes.[6]

†Fluorescence determined in fluorometrically, with use of excitation wavelength of 470 nm and emmission wavelength of 520 nm.

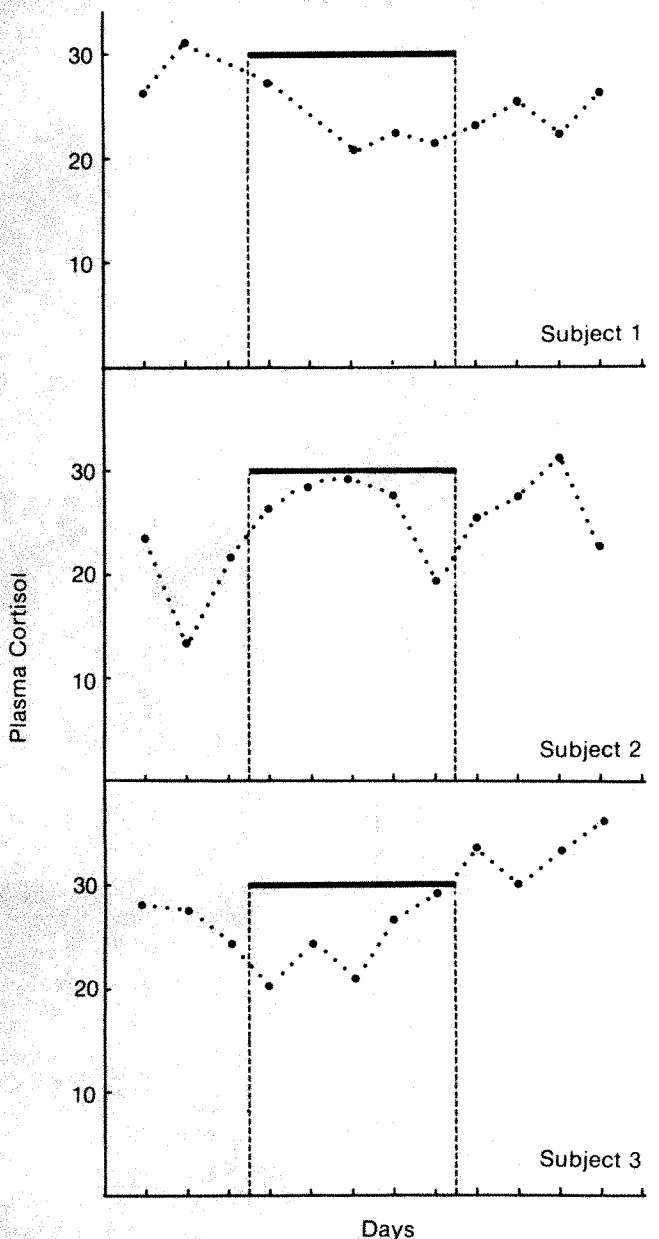

Fig 1.—Application of halcinonide cream, 0.1%, to normal subjects 1 through 3. Points in rectangle indicate values of plasma cortisol on mornings after treatment days.

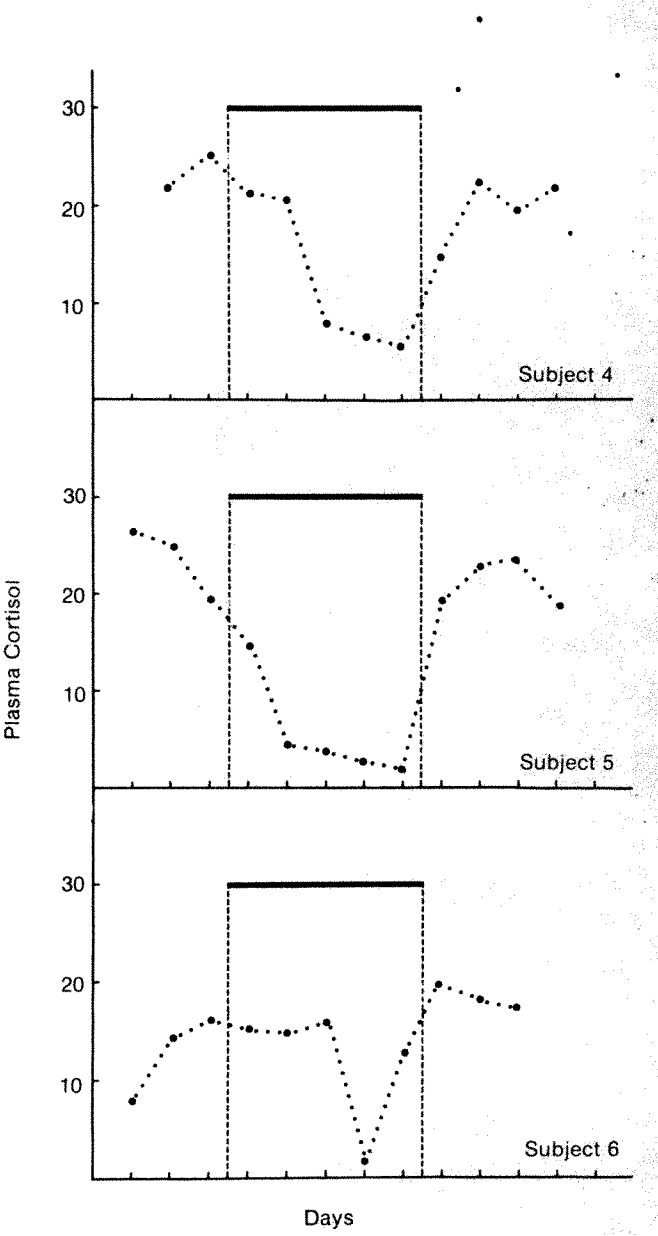

Fig 2.—Application of halcinonide cream, 0.1%, with occlusion, to normal subjects 4 through 6. Points in rectangle indicate values of plasma cortisol on mornings after treatment days.

that had been approved by the Research and Human Rights Committees of Mount Sinai Medical Center. One patient had atopic dermatitis; the other patients psoriasis.

Patients participating in the acute usage study had more than 30% of the total body surface involved and had not received systemically administered corticosteroids during the prior three months or topically administered corticosteroids during the previous month. Patients participating in the subacute usage study had at least 5% of the body surface involved and had not received systemically administered corticosteroids for the prior three months or topically administered corticosteroids for two weeks prior to beginning therapy. All patients in the acute usage study had normal pituitary-adrenal reserve as measured by a 24-hour oral metapirone test during the pretreatment period.

Experimental Design

Acute Usage Protocol.—The study was divided into a pretreatment period (days −4 to −1), a treatment period (days 1 to 5), and a post-treatment period (days 6 to 13). During the pretreatment period, a five-hour (100 gm) oral glucose tolerance test was done on day −4 and a metapirone test on day −3. Urine was collected daily to determine 17-hydroxysteroid and plasma cortisol levels. Specimens to determine blood glucose levels were taken two hours after breakfast on day −2.

During the treatment period, daily two-hour postprandial glucose determinations, plasma cortisol determinations, and 24-hour urine collections for urinalysis and 17-hydroxysteroid levels were performed.

During the post-treatment period, plasma cortisol determinations and 24-hour urine collections for urinalysis and 17-hydroxysteroid determinations were performed daily. Two-hour postprandial glucose determinations were done on days 6 and 11. The five-hour glucose tolerance test was repeated on day 10.

Fifteen grams of cream were applied to approximately 50% of the body twice daily at approximately 10 AM and 10 PM, by a nurse. When occlusion was indicated, the application of the cream was immediately followed by application of a plastic film held in place with tape and/or panty hose. The occlusive plastic film was left in place

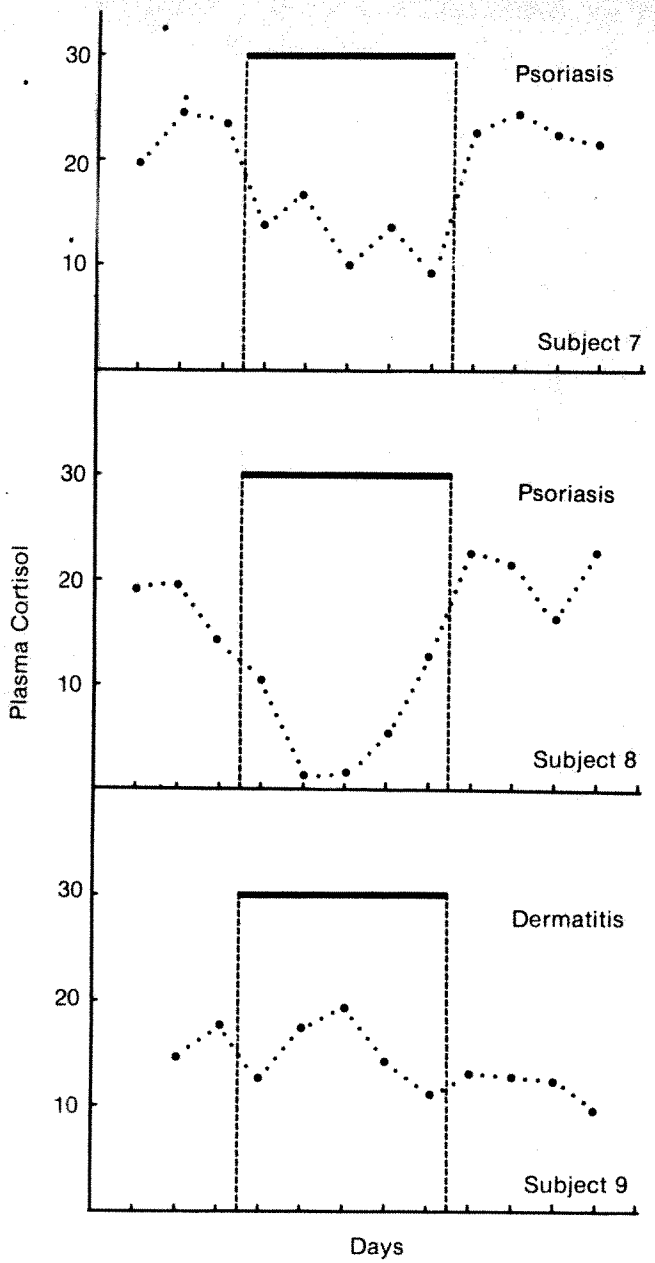

Fig 3.—Application of halcinonide cream, 0.1%, to subjects 7 through 9. Points in rectangle indicate values of plasma cortisol on mornings after treatment days.

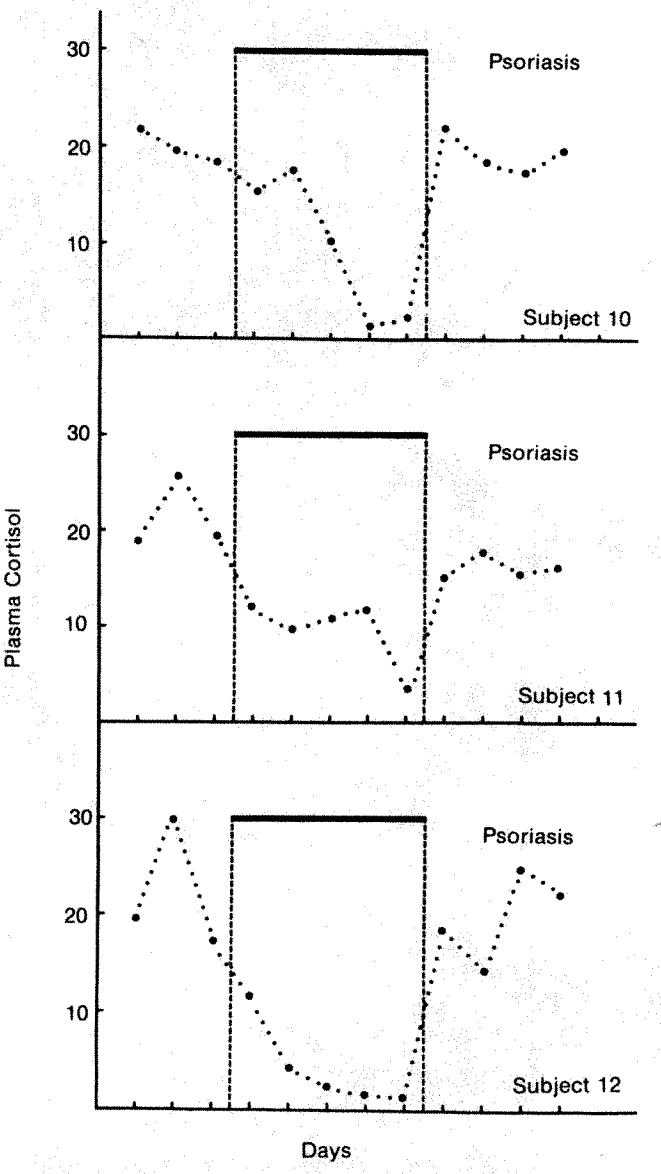

Fig 4.—Application of halcinonide cream, 0.1%, with occlusion, to subjects 10 through 12. Points in rectangle indicate values of plasma cortisol on mornings after treatment days.

for ten hours after each application and then removed for two hours to allow the patient to bathe and dry prior to the next application.

Subacute Usage Protocol.—This was a double-blind study comparing halcinonide cream, 0.1%, and betamethasone valerate cream, 0.1%, applied three or four times a day, without occlusion. Patients were examined at weekly intervals for four to six weeks. On the initial visit blood was drawn for hematologic studies, chemical analyses of the blood, and duplicate plasma cortisol determinations. At the weekly visits these studies were evaluated. Drugs were assigned according to a randomized schedule and were coded so that neither the investigator nor the patient was aware whether halcinonide cream or betamethasone valerate cream was used. To minimize the effect of diurnal variations of cortisol, patient visits were scheduled at the same time of day for each patient, but the time of day varied from patient to patient.

Cortisol and Steroid Excretion Measurements

Specimens for plasma cortisol determination were collected in tubes treated with heparin. Specimens were collected between 8 AM and 8:30 AM each day in the acute usage study. Twenty-four-hour urine specimens were collected from 8 AM each morning to 8 AM the following day and stored in a refrigerator until the analyses were to be done. Cortisol determinations were done by the method of Kitabchi and Kitchell.[6] To insure that the topical corticosteroids did not interfere with the fluorescence measurement of cortisol, the lack of reactivity of halcinonide and betamethasone valerate in this assay was confirmed (Table 1). The 17-hydroxycorticoid levels were determined by the method of Porter and Silber.[7]

RESULTS

Acute Usage Study

Application of Halcinonide Cream to Normal Skin.—Three normal subjects had halcinonide cream, 0.1%, applied to 50% of the body surface area,

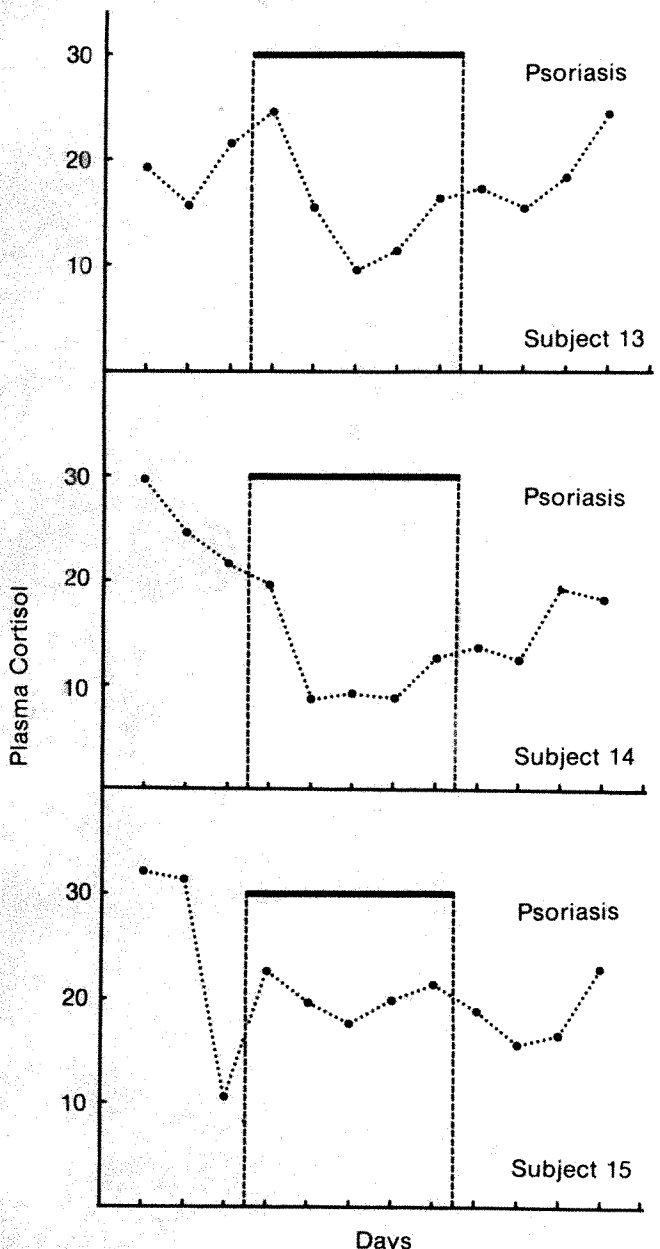

Fig 5.—Application of betamethasone valerate cream, 0.1%, to subjects 13 through 15. Points in rectangle indicate values of plasma cortisol on mornings after treatment days.

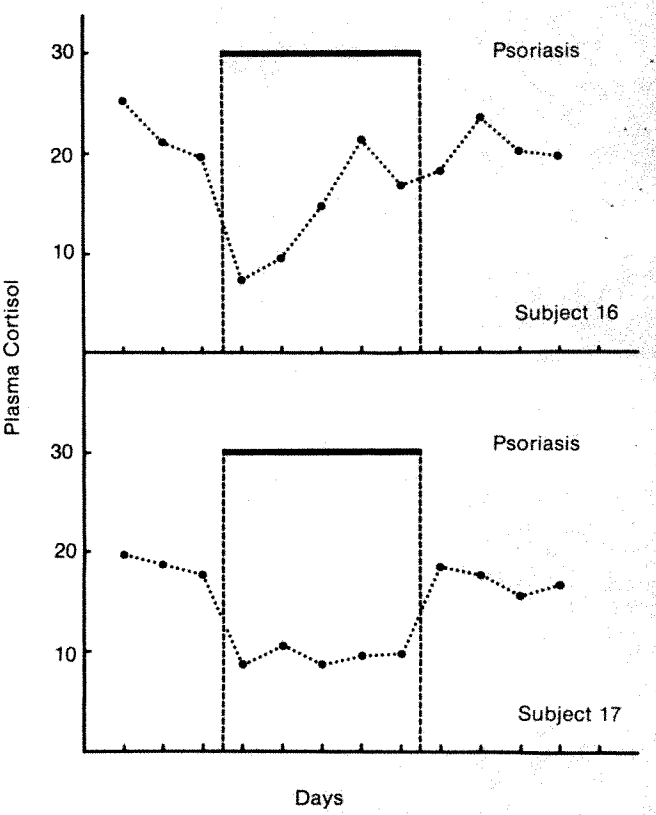

Fig 6.—Application of betamethasone valerate cream, 0.1%, with occlusion, to subjects 16 and 17. Points in rectangle indicate values of plasma cortisol on mornings after treatment days.

without occlusion, according to the acute usage protocol described above. Daily plasma cortisol determinations showed no evidence of adrenal suppression (Fig 1). Measurement of 17-hydroxysteroid excretion showed no evidence of adrenal suppression, except in subject 3, in whom 17-hydroxysteroid excretion was slightly lower on days 4, 5, and 6 than during the pretreatment days.

Three additional normal subjects had halcinonide cream, 0.1%, applied with occlusion, in a similar manner. Each of the subjects showed suppression of plasma cortisol during the treatment period (Fig 2). Subjects 4 and 5 showed progressive decrease in plasma cortisol until the morning after the final treatment. By the following morning, plasma cortisol levels in both of these patients had increased, indicating that the adrenal suppression was rapidly reversible. Subject 6 showed marked depression of plasma cortisol on only one of the treatment days. This value was definitely outside the normal range, but in view of the normal values found on the preceding and succeeding days, the possibility of a technical error must be considered.

Application of Halcinonide Cream to Diseased Skin.—Three subjects with widespread cutaneous involvement were treated with halcinonide cream, 0.1%, without occlusion. Two of the subjects had psoriasis and one had atopic dermatitis. The two subjects with psoriasis showed definite decreases of plasma cortisol on the mornings after treatment and a rapid increase to pretreatment values the days after the discontinuation of treatment (Fig 3). Subject 8 showed a marked decrease in plasma cortisol on the second morning after the initiation of treatment with a rise toward normal during the treatment period despite continued therapy. The rise in plasma cortisol during the treatment period was temporally related to an extremely rapid improvement in the patient's lesions. Subject 9, who had atopic dermatitis, showed no evidence of suppression of plasma cortisol during treatment.

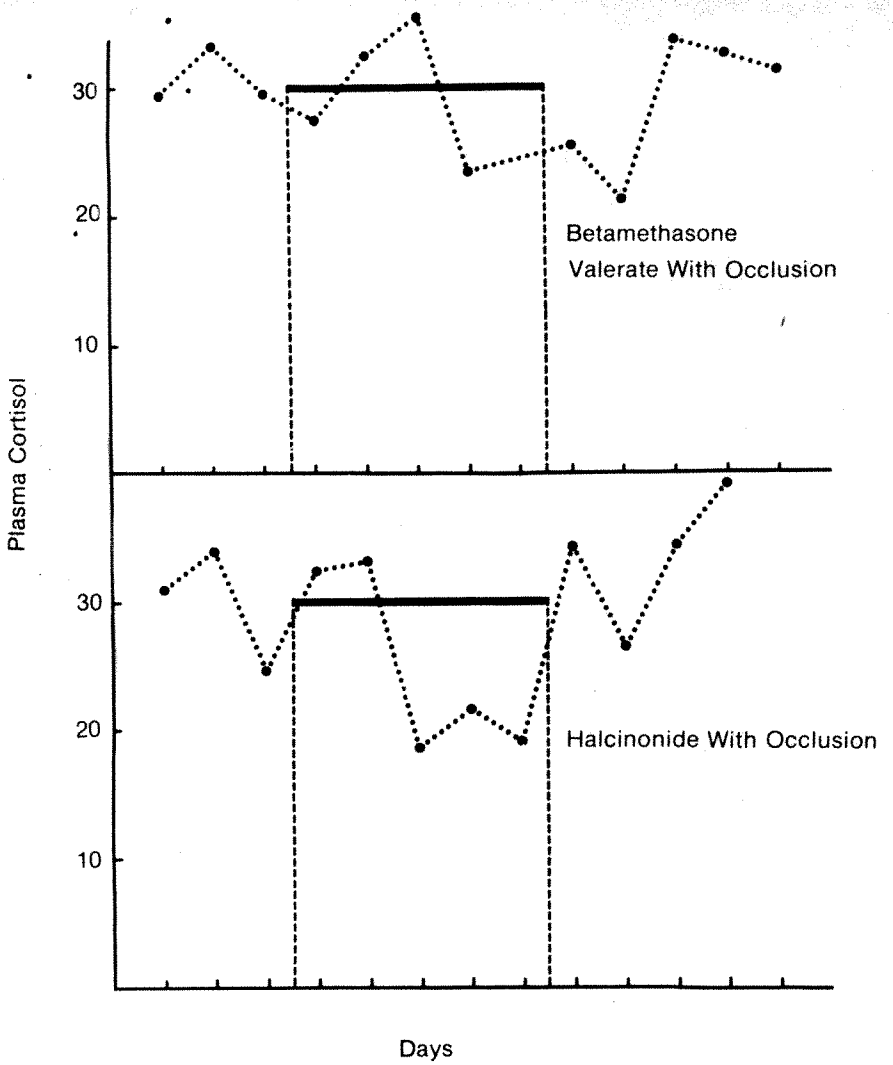

Fig 7.—Application of halcinonide cream, 0.1%, with occlusion and betamethasone valerate cream, 0.1%, with occlusion to subject 18. Points in rectangle indicate values of plasma cortisol on mornings after treatment days.

Three additional subjects with widespread psoriasis were treated with halcinonide cream, 0.1%, with occlusion (Fig 4). All three showed a marked decrease in plasma cortisol values, which persisted throughout the treatment period despite the clinical improvement of the skin lesions. After the discontinuation of treatment, the plasma cortisol values rose rapidly to the pretreatment level.

Application of Betamethasone Valerate Cream to Diseased Skin.—Three subjects with widespread psoriasis were treated with betamethasone valerate cream, 0.1%, without occlusion (Fig 5). Subject 13 showed a mild decrease in plasma cortisol values only during the middle of the treatment period, while subject 14 showed a mild decrease in plasma cortisol values during the treatment period, which persisted for two days after discontinuation of treatment.

Subject 15 showed no evidence of suppression during the treatment period. Three patients were treated with betamethasone valerate cream, 0.1%, with occlusion. Figure 6 shows the plasma cortisol values obtained for two of these patients. Both show a decrease in plasma cortisol during the treatment period. Subject 16 showed a rise in plasma cortisol despite continued therapy with occlusion, while subject 17 showed a persistent decrease in plasma cortisol until the termination of therapy. The third patient (subject 18) treated with betamethasone valerate cream, 0.1%, with occlusion, showed no evidence of adrenal suppression (Fig 7). This same patient was also treated with halcinonide cream, 0.1%, with occlusion, and again failed to show a suppression of plasma cortisol or 17-hydroxysteroid excretion during the treatment. Plasma cortisol in this patient was in the high normal range with some values above the normal range.

Effects on Glucose Metabolism.—Four of the subjects tested had abnormal results to pretreatment glucose tolerance tests. Of these only one of the subjects demonstrated abnormal glucose metabolism in the course of the study, and these data have been reported separately.[8]

Subacute Usage Protocol

Fifty-one outpatients between 9 and 76 years of age with psoriasis were treated with halcinonide cream, 0.1%, or betamethasone valerate cream, 0.1%, without occlusion, according to the double-blind subacute usage protocol described above. Of these patients, 44 patients completed four to six weeks of therapy. There were 31 male and 13 female patients. Involvement with psoriasis varied from approximately 5% (1/18) of the body surface to more than 50% (9/18) of the body surface. Of 44 patients completing the four to six weeks of therapy, nine had severe psoriasis, 26 moderate psoriasis, and nine mild psoriasis. Patients used between 225 and 900 gm of cream during the course of the study with an average usage of 472 gm.

A summary of the results of the study are shown in Table 2. Twenty-three of the patients completing the study were treated with halcinonide cream, 0.1%, and 21 were treated with betamethasone valerate cream, 0.1%. Of the patients treated with halcinonide cream, two showed mild, reversible adrenal suppression, and three developed striae. Of the patients treated with betamethasone valerate cream, none showed either adrenal suppression or striae formation.

Clinical response was graded at each visit and an overall clinical response assigned at the end of the study. Of the 23 patients treated with halcinonide cream, 13 had excellent responses. Only one of the 21 patients treated with betamethasone valerate cream had an excellent response. Both treatment groups had a similar number of patients who showed only fair or poor responses.

The plasma cortisol findings in the two patients showing adrenal suppression are shown in Fig 8. One patient was treated for four weeks with an excellent clinical response and showed a persisting decrease in plasma cortisol level as compared to the pretreatment and post-treatment values. Only 5% of the body surface was involved in this patient, much less than in many patients who showed no

Table 2.—Summary of Results of Subacute Usage Study

	Halcinonide	Betamethasone Valerate
No. of Patients	23	21
Adrenal suppression	2	0
Striae formation	3	0
Clinical response		
Excellent	13 (57%)	1 (4%)
Good	3 (13%)	12 (57%)
Fair	4 (17%)	6 (29%)
Poor	3 (13%)	2 (10%)

evidence of adrenal suppression. The second patient evidencing adrenal suppression was treated for six weeks with an excellent response and a moderate decrease in plasma cortisol values compared to pretreatment and post-treatment values. This patient also had a smaller percentage (10%) of the body surface involved than did other patients who did not show adrenal suppression. Neither patient developed any notable side effects during the study period.

All three patients developing striae were in the group treated with halcinonide cream. Two of the patients developed the striae at sites of natural occlusion, one near the axillae and the second in the intergluteal fold. The third patient developed a band of striae around the waist, exactly matching the area under a wide leather belt that he customarily wore.

COMMENT

The suppression of adrenal function by topically applied corticosteroid preparations is amply demonstrated in the dermatologic literature. Most studies have used patients with widespread involvement with psoriasis or other dermatoses known to have an abnormal barrier to percutaneous penetration and in many cases have used occlusion to augment penetration of the corticosteroid preparation. Such studies are now performed to evaluate the safety of new corticosteroid preparations prior to marketing. Since the routine use of corticosteroid preparations in dermatologic practice is much different from the use of such preparations in the studies reporting adrenal suppression, it is of interest to monitor corticosteroid effects on the adrenal pituitary axis under conditions more closely resembling actual clinical usage.

The studies described here indicate

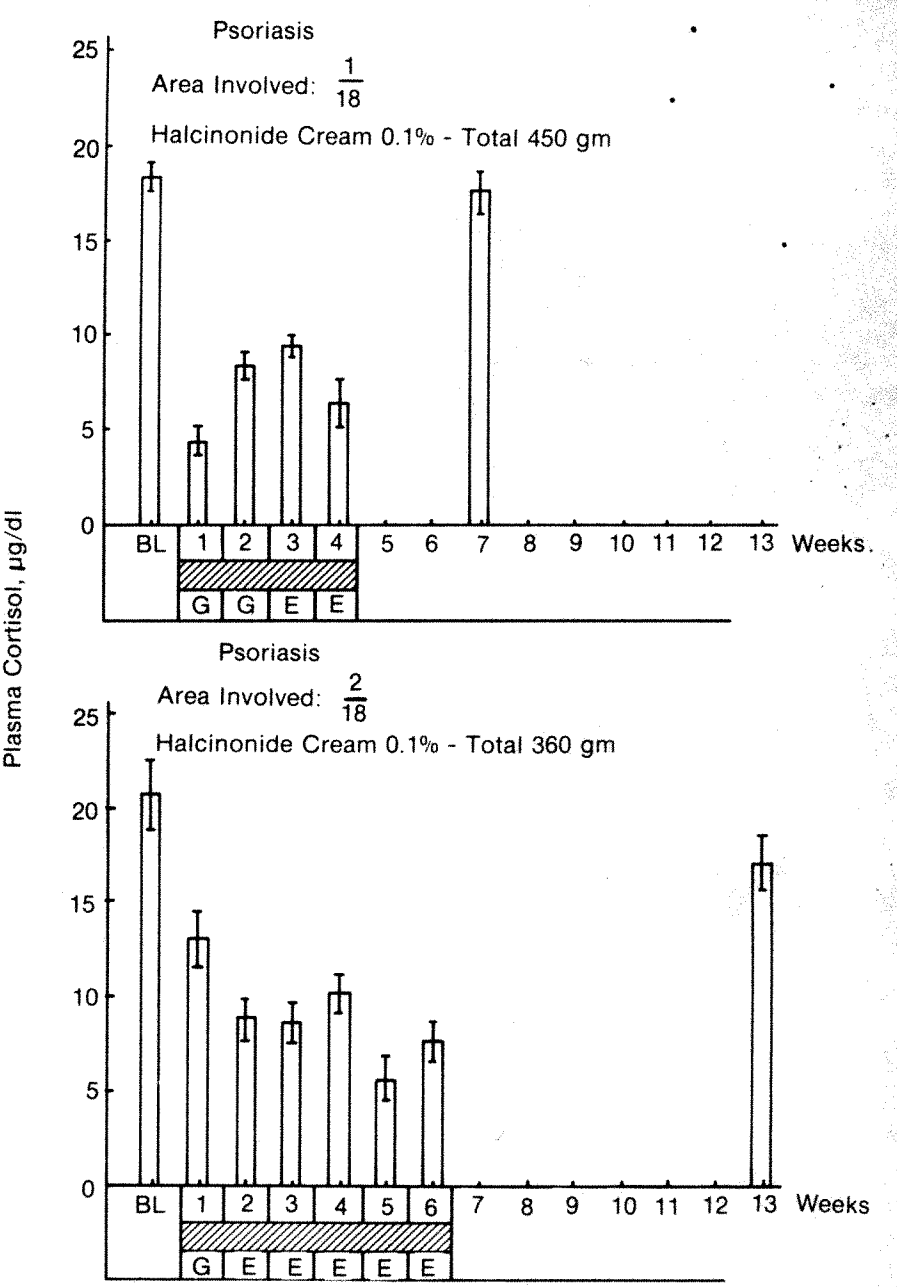

Fig 8.—Suppression of plasma cortisol of two subjects in subacute usage study. Shaded area indicates values while under treatment. BL indicates baseline or pretreatment specimen. Lower letters indicate grading of clinical response at each visit (G, good and E, excellent). Cortisol values are average of determinations on two separate specimens (indicated by brackets).

that halcinonide cream, like other recently introduced corticosteroid preparations, has a suppressive effect on the adrenal-pituitary axis, as measured by a decrease in plasma cortisol levels after topical application to patients with widespread psoriasis, with or without occlusion. In addition, application to normal skin also causes a decrease in plasma cortisol levels, provided the area of application is occluded with a plastic film. No evidence of adrenal effects was noted when halcinonide cream was applied to 50% of the body surface of normal individuals without occlusion.

Betamethasone valerate cream also caused suppression of the plasma cortisol level in individuals with widespread psoriasis, both with and without occlusion. One individual with widespread psoriasis did not show adrenal suppression with either betamethasone valerate cream or halcinonide cream applied under occlusion. This individual had a relatively high cortisol level, including many values above the upper limit of normal, and

may have abnormal adrenal function. One patient developed a temporary alteration of glucose metabolism while under treatment with halcinonide and has been reported elsewhere.[8]

In contrast to the findings with the acute usage protocol, only two of 44 patients completing the subacute usage study showed evidence of adrenal suppression, both patients being in the halcinonide group. Three patients who developed striae were also in the halcinonide group. The finding of more side effects in the halcinonide treatment group than in the betamethasone valerate treatment group is not surprising since the clinical evaluations in this study, as well as reports of others,[9] indicate that halcinonide cream is a more potent preparation than is the betamethasone valerate cream used for comparison.

The contrast between the acute usage study and the subacute usage study is striking. The data suggest that in routine clinical usage there is less adrenal suppression than would be expected from the acute usage studies. Assessment of pituitary-adrenal reserve might have revealed additional patients with effects from subacute usage, but the large number of patients involved precluded studies not easily performed on an outpatient basis.

The reliance solely on plasma cortisol values during the subacute usage study is not considered an important factor since the additional examination of 17-hydroxycorticoid excretion in the acute usage study yielded no additional information. Indeed, the difficulty of obtaining reliable 24-hour excretion values over a three-week period far exceeded the usefulness of these determinations. It is, of course, essential that the method used to determine plasma cortisol not measure the topical corticosteroids under study.

The potency of present-day preparations makes the performance of adrenal function tests of patients having widespread psoriasis during acute usage studies, with or without occlusion, of questionable value in the evaluation of new corticosteroid preparations. Most present-day steroids easily cause adrenal suppression in the majority of subjects so treated. More meaningful information can be obtained by studying subjects with an unaltered barrier, either with or without occlusion. Such studies would detect topical corticosteroid preparations having even greater potential for suppression of adrenal function, such as clobetasol proprionate ointment, which was recently reported to cause profound decrease in plasma cortisol when applied to normal subjects without occlusion.[10]

More recently, Carruthers et al[11] have studied clobetasol proprionate cream and ointment in normal subjects over a two-week period and found marked and persisting suppression of plasma cortisol during the treatment period, providing sufficient corticosteroid was applied (90 gm of preparation per week). Cortisol returned to normal on discontinuation of therapy. Patients under treatment for periods of ten weeks to 18 months with more than 50 gm per week also showed decreased plasma cortisol or reduced peak insulin stress test levels. Carruthers and associates also encountered a subject who showed no evidence of adrenal suppression at dosages causing suppression in other subjects (a situation similar to the patient in Fig 7). Their finding of diminished reserve on insulin stress is probably related to the prolonged periods of therapy and might have been overlooked in an acute usage study.

Long-term studies with patients having altered barriers are also logical in that they more closely approximate clinical usage and may provide some indication of additional side effects, such as striae formation, which would not be observed in short-term studies for the evaluation of acute effects or the determination of efficacy.

This investigation was supported in part by National Institutes of Health grant AM16232. E. R. Squibb and Sons provided the halcinonide cream (Halog) and betamethasone valerate cream (Valisone).

Nonproprietary Names and Trademarks of Drugs

Betamethasone valerate—*Valisone.*
Halcinonide—*Halog.*

References

1. Scoggins RB: Decrease of urinary corticosteroids following application of fluocinolone acetonide under occlusive dressing. *J Invest Derm* 39:473, 1962.

2. March C, Kerbel G: Adrenal function after application of topical steroids under occlusive plastic film. *JAMA* 187:676-678, 1964.

3. Gill KA, Baxter DL: Plasma cortisol suppression by steroid creams. *Arch Dermatol* 89:734-740, 1964.

4. Scoggins RB, Kliman RB: Percutaneous absorption of corticosteroid. *N Engl J Med* 273:831-840, 1965.

5. Carr RD, Baxter WM: Percutaneous absorption of corticosteroids: Adrenal corticol suppression with total body inunction. *Acta Dermatovenereol* 48:417-428, 1968.

6. Kitabchi AE, Kitchell LC: A simplified fluorometric method for determination of blood cortisol using phase separating filter paper. *Anal Biochem* 34:529-537, 1970.

7. Porter CC, Silber RH, cited by Gluck D (ed): *Methods of Biochemical Analysis,* vol 4. Interscience, 1957.

8. Gomez EC, Frost P: Induction of glycosuria and hyperglycemia by topical corticosteroid therapy. *Arch Dermatol* 112:1559-1562, 1976.

9. Leibeohn E, Bagatell FK: Halcinonide in the treatment of corticosteroid responsive dermatoses. *Br J Dermatol* 90:435-440, 1974.

10. Ortega E, Burdick KH, Segal EJ: Adrenal suppression by clobetasol proprionate. *Lancet* 1:1200, 1975.

11. Carruthers JA, August PJ, Staughton RCD: Observations on the systemic effect of topical clobetasol proprionate (Dermovate). *Br Med J* 4:203-204, 1975.

Mycophenolic Acid for Psoriasis

William S. Lynch, MD, Henry H. Roenigk, Jr, MD

• Mycophenolic acid is an antimetabolite used experimentally for the treatment of psoriasis. Thirty-eight patients were treated with mycophenolic acid. A double-blind, placebo-controlled study demonstrated the efficacy of mycophenolic acid ($P < .01$). A long-term safety study showed the occurrence of hematologic abnormalities, viral infections, and carcinoma. The position of mycophenolic acid in the therapeutic treatment of psoriasis must await the results of a multicenter cooperative study.

***(Arch Dermatol* 113:1203-1208, 1977)**

Despite continuous investigative efforts, the cause of psoriasis remains an enigma. In the past decade it has been confirmed that an increased epithelial proliferation explains many of the clinical and histologic features of a psoriatic lesion.[1,2] Because of this, various chemotherapeutic agents have been employed in resistant cases.[3] Theoretically, most of these compounds function by interrupting hyperkinetic cellular function.

Methotrexate has proved to be an invaluable agent for psoriasis, and psoriatic arthritis,[4,5] but substantial potential toxicity[5,6] has necessitated a continuing search for a safe and efficacious drug. Cyclophosphamide,[7] nitrogen mustard,[7] mercaptopurine,[7,8] thiguanosine,[9] fucidin,[10] azathioprine,[11] levodopa,[12] fenfluramine hydrochloride,[13] and psoralen plus UVA[14] are among the agents that have been or are being evaluated. Hydroxyurea[15,16] and azaribine[17,18] have also proved beneficial in controlled series, but have shown significant toxic side effects.

More recently, mycophenolic acid, an inhibitor of purine synthesis, has given encouraging results.[19] Of the 29 patients treated by Jones et al[19] in their initial clinical trial, one patient's condition cleared completely, 14 showed almost complete clearing, 13 exhibited definite improvement, and one did not respond. A cooperative study was subsequently designed to judge both the efficacy and long-term safety of orally given MPA in psoriasis. Ten medical centers and approximately 375 patients are participating in the study (written communication, E. L. Jones, MD, September 1976). Our preliminary report comprises a portion of this cooperative effort.

METHODS

Thirty-eight patients with psoriasis were enrolled in the study. All types of psoriasis were eligible (plaque, guttate, inverse, pustular, palmar-plantar, arthritic). The subjects must have been unable to control their skin condition with nonsystemic measures. All participants were fully informed as to possible adverse reactions, alternative treatment available, and the design of the study. Writen consent was obtained.

Exclusion from the study included the following: women of childbearing potential unless using adequate contraception; children under 12 years of age; patients who received methotrexate or other antimetabolic drugs in the previous four weeks; patients with a preexisting leukopenia (WBC, 3,500 cm mm); men planning conception; chronic alcoholics and persons exposed to toxic chemicals; patients with liver disease.

The investigation was divided into separate portions: (1) double-blind, placebo-controlled parallel study to judge efficacy; and (2) long-term follow-up study to judge safety.

Medications

Mycophenolic acid was supplied in 400-mg capsules. The placebo medication consisted of capsules identical in appearance to the active medication, but containing starch only. The medication was started initially at a dosage of 2,400 mg/day in two to three divided doses. Dosages were increased at a rate no faster than every week. The maximum dosage was 96 mg/kg/day. The dosage was adjusted to maintain the desired clinical response.

If an appreciable adverse reaction occurred, the drug was either temporarily discontinued or the dose was lowered. The therapy was interrupted temporarily if infection, fracture, surgery, infarction, thrombosis, vaccination, or hazardous medication affected the patient. A patient was released from the study protocol if a neoplasm was diagnosed. Concurrent medication, including topical therapy, was kept at a minimum. Close surveillance was maintained for a possible drug interaction.

Clinical and Laboratory Observations

All patients were observed as outpatients or inpatients in the Cleveland Clinic.

Accepted for publication Nov 24, 1976.

From the Cleveland Clinic Foundation.

Read in part before the Central State Dermatology Society meeting, Cleveland, May 18, 1975.

Reprint requests to Department of Dermatology, Northwestern University School of Medicine, 303 E Chicago Ave, Chicago, IL 60610 (Dr Roenigk).

Table 1.—Characteristics of Study Population Receiving Mycophenolic Acid	
No. patients	
Females	20
Males	18
Total	**38**
Average ages, yr (range)	
Females	46.8 (14-72)
Males	39.3 (13-72)
Previous therapy, No. patients	
Methotrexate	28
Azaribine	1
Hydroxyurea	1
Activity of Psoriasis, Initial Severity Score	
Average	43
Range	15-84
Initial Body Involvement, %	
Average	49.7
Range	6-76

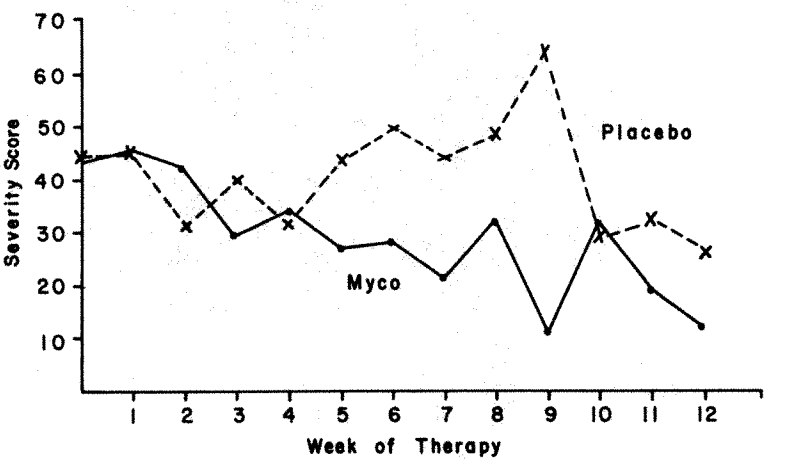

Fig 1.—Comparative severity scores of mycophenolic acid (Myco) and placebo.

Table 2.—Improvement in Severity Scores at 16 Weeks		
Improvement (%)*		**No. of Patients**
Excellent	(75-100)	13†
Good	(50-74)	11
Fair	(25-49)	2
Poor	(0-24)	5
Worse		1
Total		**32**

*Average time for significant response, 9.1 weeks.

†These were completely clear of involvement.

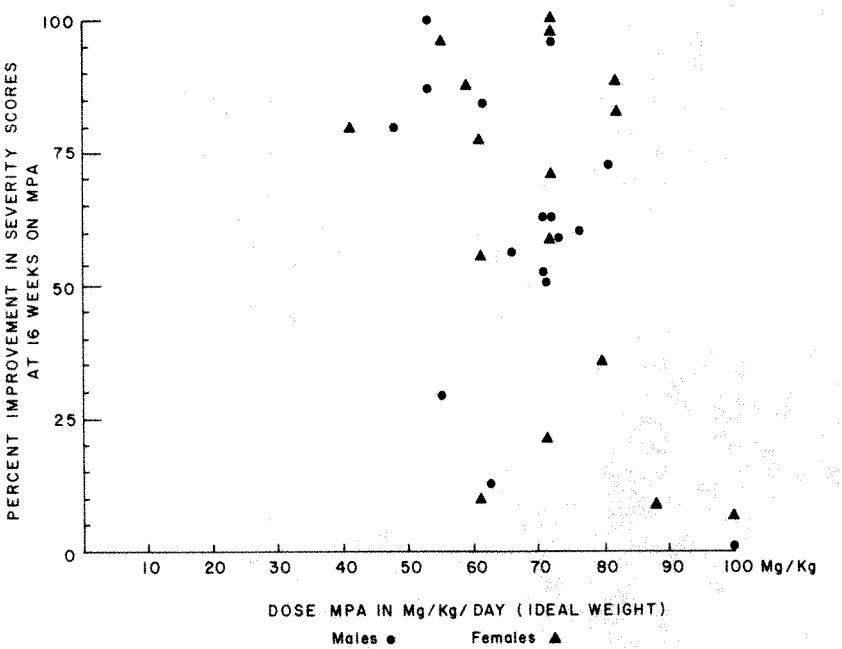

Fig 2.—Improvement in severity scores vs dosage (ideal weight) and sex. Mycophenolic acid indicated by MPA.

Initial evaluation included a detailed history and physical examination, including an ophthalmologic examination, and photographs. Patients were seen at weekly intervals for the first eight weeks, every other week for four weeks, then every four weeks. At each visit the severity of the disease was graded at six skin sites using the following scale of 0 to 6 for lesion thickness, scaling, and erythema: 0, absent; 1, trace; 2, mild; 3, mild to moderate; 4, moderate; 5, moderate to severe; and 6, severe. The maximum possible severity score was, therefore, 108. The percent of body area affected was recorded initially and at 12 weeks.

Interpretation of response to mycophenolic acid and placebo was done in the following manner: (1) Efficacy study: The mean severity scores of the mycophenolic acid-treated and the placebo-treated groups were evaluated at each visit and at the end of the 12 weeks. These data were then analyzed for statistical significance. (2) Safety study: Severity scores were tabulated at each visit. At 16 weeks the percent improvement in the individual severity score was calculated and placed into one of the following categories: excellent, 75% to 100%; good, 50% to 74%; fair, 25% to 49%; poor, 0 to 24%; and worse, condition flared.

Patients with psoriatic arthritis were graded on their subjective feelings, the amount of anti-inflammatory medication taken, grip strength, and/or the time it took to walk 14.9 meters (50 ft).

At each visit a complete blood count, platelet count, urinalysis, and automated chemical analyses profile were done. If symptoms or laboratory tests indicated, additional appropriate laboratory tests were performed.

The ophthalmic examination was repeated at 28 weeks, 52 weeks, and at the end of the study. Follow-up photographs were taken at various intervals during the treatment.

Efficacy Study (Part 1)

This portion of the investigation was a double-blind, placebo-controlled parallel study. The patients were randomly selected for treatment with mycophenolic acid or the placebo for the first 12 weeks. Neither the patients nor the grading physician was aware of which medication was being used. At the end of 12 weeks, the patients who were receiving the placebo were switched to the active mycophenolic acid, and the patients initially taking the active drug continued with it. All patients were then continued in the study as part of the safety study.

Safety Study (Part 2)

This portion of the investigation was designed to judge the long-term safety of mycophenolic acid. The protocol was identical to that outlined for part 1, except all the patients were taking the active drug. In this portion of the study both the patient and the evaluating physician knew the medication used. This part of the study included patients started as safety study patients from the beginning and those from the efficacy study after they were given the active mycophenolic acid regimen. The study was designed to last a period of two years.

STUDY POPULATION

Thirty-eight patients, 20 females and 18 males, were included in the safety study group. Of these, 25 patients were initially enrolled in the efficacy portion of the investigation. The characteristics of the entire group are listed in Table 1.

Thirty-seven patients had moderate-severe psoriasis of the plaque form. One patient had severe involvement of the palms and soles only. Three patients had moderate-severe arthritis, and in two of these the arthritis was the prominent feature of the disease. No patients with pustular psoriasis were treated.

A large percentage of patients had taken methotrexate or other antimetabolites previously. Of the 26 patients who had received methotrexate, 22 had shown definite improvement. Discontinuance of the medication was prompted by a severe side effect or inadequate control of the disease.

Twenty-four patients were judged to be in good general health. Concurrent medical problems existed in the study group, including hypertension, diabetes mellitus, arteriosclerotic heart disease, hyperlipidemia, thalassemia minor, and an inactive duodenal ulcer. One patient, a 43-year-old woman, had had a mastectomy in 1967 for carcinoma of the breast without evidence of recurrence. This same patient has had numerous basal cell carcinomas and had just completed successful Mohs' chemosurgery for a squamous cell carcinoma of the right temporal scalp. One 65-year-old woman was found to have a suspicious pigmented retinal lesion on the initial ophthalmic examination. She refused to have an enucleation and was included in the study after consultation with a panel of ophthalmologists and full understanding on her part of the risks involved.

Three patients were eliminated from the efficacy portion of the study prior to accumulating important data for inclusion in the efficacy statistics. (Two patients found that frequent visits were too inconvenient and one patient developed an anemia, leukopenia, and thrombocytopenia).

Three patients were also released from the safety portion of the investigation prior to complete evaluation of the response. Two patients developed a vaginitis and requested to be discontinued. One patient was lost to follow-up. It was

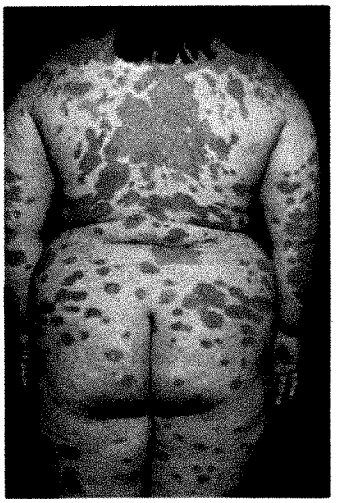

Fig 3.—Thirteen-year-old girl before treatment.

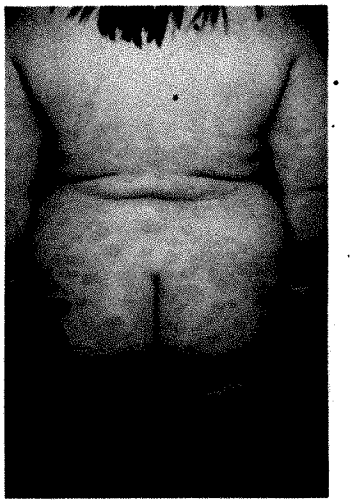

Fig 4.—Same patient seen in Fig 3 after 16 weeks of mycophenolic acid treatment (maximum dose, 4,800 mg/day).

Fig 5.—Forty-four-year-old man before treatment.

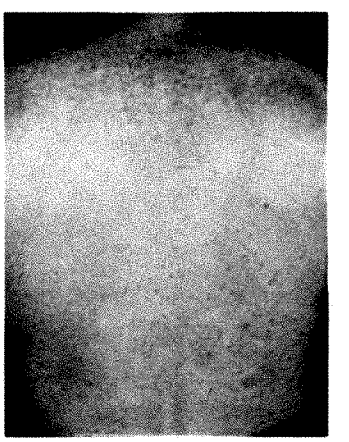

Fig 6.—Same patient seen in Fig 5 after 16 weeks of mycophenolic acid treatment (maximum dose, 600 mg/day).

Fig 7.—Fifty-four-year-old woman before treatment.

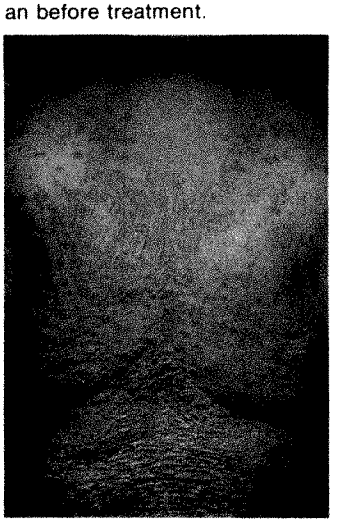

Fig 8.—Same patient seen in Fig 7 after 16 weeks of mycophenolic acid treatment (maximum dose, 4,800 mg/day).

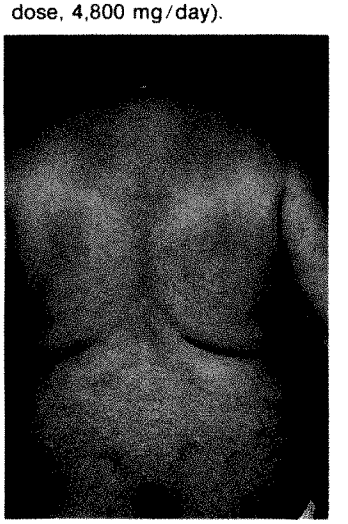

learned later that he died and an autopsy showed the presence of subdural hematoma, presumably secondary to a fall. This was five weeks after last taking the drug; at the time of his last clinic visit all laboratory test results were within normal limits.

RESULTS

In the efficacy portion of the investigation 10 patients reached at least ten weeks on the placebo regimen and 12 patients were randomly started and continued with the active medication. Figure 1 demonstrates the weekly difference in the severity scores of the two groups. Although intentional pairing of severity scores were not done for each group, the average initial severity score for the placebo and active groups was identical. The group receiving mycophenolic acid showed a statistically significant ($P < .01$) change in the severity score when compared to the group receiving the placebo. Interestingly, there were two placebo responders. These two patients continued with the placebo until the psoriasis flared (one at 26 weeks, and the other at 40 weeks), and then were given the active medication.

In the safety portion of the study, 32 patients completed at least 16 weeks with mycophenolic acid. The results are tabulated in Table 2; a total of 13/32 (41%) patients exhibited an excellent response; 11/32 (34%) had a good response; 2/32 (6%) showed a fair response; 5/32 (12.5%) had a poor response, and 1 patient's condition worsened. This patient was a 60-year-old man who took the medication for 20 weeks, with a maximum dosage of 7,200 mg/day. Mycophenolic acid was discontinued because of a lack of response and severe gastrointestinal side effects.

The average time to show maximum response was 9.1 weeks, with a range of 3 to 14 weeks. Of the three patients with psoriatic arthritis, one showed subjective improvement and no patient exhibited substantial objective improvement.

Figure 2 illustrates the improvement in severity scores compared to dosage (per ideal weight) and sex. The response appeared to be dose-related with no sex predilection. The maximal response seemed to vary between 50 mg/kg/day and 72 mg/kg/day (or 3,600 mg/day and 4,800 mg/day). There seemed to be no sex predilection to the degree of the response.

Photographs of the clinical response in three patients are shown in Fig 3 through 8.

Adverse Reactions

The adverse reactions encountered in the study of 38 patients receiving large doses of mycophenolic acid are listed below:

Side Effects Attributed To MPA	
Gastrointestinal	
Nausea	24
Abdominal cramps	23
Diarrhea	17
Melena or bloody stools	3
Soft bowel movements	13
Vomiting	12
Urinary tract symptoms	
Burning on urination	5
Urgent or frequent urination	2
Other	
Weak or tired feeling	18
Difficulty sleeping	8
Vaginal burning	2
Tender fingertips	1
Mouth ulcers	1
Events of Uncertain Association With MPA	
Carcinoma	
Adenocarcinoma of breast	1
Squamous cell carcinoma of epiglottis	1
Recurrent squamous cell carcinoma of skin	1
Infections	
Viral	
URI	5
Warts	4
Verrucae vulgaris	2
Condyloma accuminata	2
Herpes simplex	6
Herpes zoster	2
Gastroenteritis	1
Bacterial	
Urinary tract infection	4
Pharyngitis	4
Septicemia *(Staphylococcus)*	2
Otitis media	1
Furunculosis	1
Bronchitis	1
Fungal	
T. cruris (KOH [+])	2
Other	
Dizziness	2
Epistaxis	1
Angina	2
Laboratory Abnormalities	
Hematologic	
↓ Hb (> 2 gm)	4
Leukopenia (WBC, <3,500/cu mm) (2 patients with absolute neutropenia)	4
Thrombocytopenia	2
Other	
Transiently abnormal liver function tests	3
↑ Cholesterol	1
↑ Uric acid	1
Pyuria (sterile)	14

In general, the side effects appeared to be dose-related and were particularly common above a dosage of 4,800 mg/day. Usually, the reaction could be alleviated by decreasing the dosage or temporarily discontinuing the drug.

Gastrointestinal manifestations were the most frequent. Severe abdominal cramps or evidence of blood in the stools prompted cessation of the drug and the performance of a complete gastrointestinal evaluation in six cases (including proctologic examination and roentgenograms of the stomach, gallbladder, small intestine, and colon). No specific abnormality was found and the patients were able to tolerate lower doses of mycophenolic acid.

A weak or tired feeling was another common complaint. This could not be related to any specific hematologic abnormality, and seemed to be less of a problem after eight to ten weeks receiving the medication.

The occurrence of infections in the study group was quite common, with viral infections predominating. Two patients developed classic herpes zoster. One 12-year-old boy developed herpes zoster on the left thorax and painful mouth ulceration at ten weeks into the study. He had previously been taking methotrexate, 7.5 mg/week, but discontinued it two months prior to inclusion in the study. The dose of mycophenolic acid was 2,400 mg/day. The drug was discontinued for two weeks and restarted without occurrence of signs or symptoms. The zoster site healed with keloid formation. Another was a 33-year-old man who developed zoster in the left sacral area. Prior to the study he had received no systemic medication for psoriasis. His medication was discontinued for two weeks and reinstituted without difficulty after normal healing occurred. Six additional patients developed clinically obvious and/or culture-proved herpes simplex, and four patients developed warts. None of these patients had exhibited a propensity for these infections prior to taking MPA.

Three of our patients were discovered to have a neoplasm: one patient, a 43-year-old woman, discussed previously, had a recurrent squamous cell carcinoma of the scalp, which developed after having been successfully treated with Mohs chemosurgery; she also developed numerous basal cell carcinomas on her face, trunk, and extremities. The dosage of mycophenolic acid received was 3,600 mg/day during a 16-week period. She had also taken methotrexate (20 to 25 mg/week) from 1964 to 1972.

A 49-year-old woman was found to have a large mass in the right breast after 38 weeks on mycophenolic acid therapy. She had a modified radical mastectomy performed and a stage I signet ring cell carcinoma was diagnosed. She had received an average daily dosage of 4,000 mg of mycophenolic acid. Prior to inclusion in the

study she had a negative result from a breast examination at our institution, although mammograms were not done. She had taken methotrexate (20 to 25 mg/week) for five years before taking mycophenolic acid.

A 59-year-old woman was found to have a squamous cell carcinoma of the epiglottis. She had received an average daily dosage of 3,600 mg/day of mycophenolic acid for 46 weeks, and had discontinued the mycophenolic acid five months prior to detection of the tumor to try psoralen and black-light therapy. Before taking mycophenolic acid, she had taken azaribine for five months, without a substantial response. She is currently undergoing radiation therapy, and will possibly have a radical neck operation.

The laboratory abnormalities are listed in Table 3. A pertinent finding was the paucity of liver abnormalities. Although a number of our patients had been receiving other antimetabolic agents, routine liver biopsies were not done as a part of our investigation.

Hematologic abnormalities did occur: One 44-year-old woman developed anemia, leukopenia, and thrombocytopenia that recurred after stopping and restarting the drug therapy. She was released from the study and all measurements returned to normal.

Of particular interest were two siblings who developed a selective neutropenia (a 13-year-old girl and 15-year-old boy). They developed this at 16 weeks into the study, but because of the different starting dates, the onset of symptoms were separated by an interval of one month. Presenting symptoms included sore gums, fever, chills, and headache. Both patients were hospitalized and treated with parenteral antibiotics for bacteremia. Bone marrow aspirate showed a pronounced diminution in the granulocytic series. Additional normal laboratory tests included the following: immunoglobulins, chromosome analysis, leukocyte agglutinins, peripheral blood T-cell and B-cell levels, and lymphocyte transformation tests to phytohemagglutinin, pokeweed mitogen, and concanavalin A.

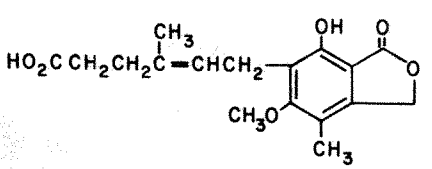

Fig 9.—Structure of mycophenolic acid.

COMMENT

Mycophenolic acid was isolated by Gosio in 1896 as a fermentation product of a penicillin mold. The finding was duplicated in 1913 by Alsberg and Black, who named the substance.[20] It was not until 1952 that the structural formula was fully elucidated (Fig 9).[21]

The compound has been shown to have antibacterial[22] and antifungal[23] activity. In vitro antiviral properties were also noted but could not be demonstrated in vivo.[24,25]

Laboratory evidence from experiments with animals indicated that mycophenolic acid may be effective against certain virally induced tumors.[26] Because of its seemingly low toxicity, the compound was utilized in clinical trials with humans in the treatment of neoplastic diseases. The results were disappointing.[27,28]

Toxicity studies in animals have implied relative safety. One study reported no clinical, laboratory, or autopsy evidence of toxic reactions in rabbits that received 320 mg/kg/day for one year.[19] There have been no reports concerning the possible carcinogenic potential of mycophenolic acid. Likewise, the studies pertaining to the effects of mycophenolic acid on the immune response are inconclusive. Another study describes the immune response to sheep red blood cells of mice treated with mycophenolic acid. With the method used it was believed that mycophenolic acid had immunosuppressive effects equipotent to 6-mercaptopurine with use of the same study format.[29]

The mechanism of action of mycophenolic acid appears to be an enzymatic inhibition of the purine precursors of RNA and DNA. Specifically, the drug blocks the enzymatic interconversion of the nucleotides inosine-5′-phosphate (IMP) to quanosine-5′-phosphate (GMP) (Fig 10). The enzymes involved are IMP dehydrogenase and GMP synthetase.[30,31] It does not appear that adenosine monophosphate synthesis is inhibited by the drug. Furthermore, it has become apparent that the enzymatic blockage can be bypassed by DNA synthesis from free guanine, the so-called guanine salvage pathway (Fig 6). This pathway can be blocked by 6-mercaptopurine, thereby potentiating the effect of mycophenolic acid.[27]

The metabolism of mycophenolic acid has been delineated by Lintrup et al.[32] After oral administration the drug is rapidly absorbed from the gastrointestinal tract and metabolized in the liver to mycophenolic acid glucuronide. In humans the peak level of free mycophenolic acid is one hour after ingestion and the glucuronide fraction reaches its highest concentration at two hours. Essentially, mycophenolic acid all is excreted as the glucuronide form, and it is predominantly found in the urine.

Mycophenolic acid glucuronide is considered inactive and it is felt that only those tissues with a high level of the enzyme β-glucuronidase can generate sufficient levels of the active drug. The epidermis and dermis had been shown to possess ample concentration of this enzyme,[33] and it is theorized that such a property may account for its specificity in certain tumors and in hyperproliferative diseases such as psoriasis.[34]

As mentioned, the initial clinical trial of mycophenolic acid in psoriasis[19] was encouraging. As the early reports of individual medical centers are published, it appears that the preliminary results are being duplicated. Twenty-seven of the 35 patients at Duke University showed clearing of more than half their lesions (written communication, W. H.

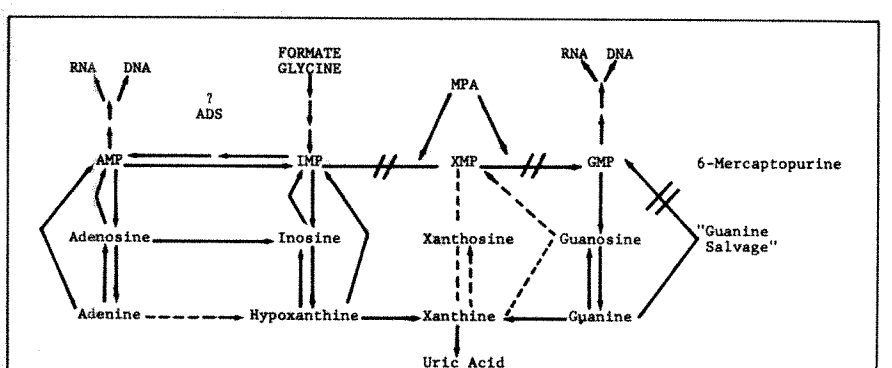

Fig 10.—Metabolic pathways affected by mycophenolic acid. Inosine-5′-phosphate indicated by IMP; guanosine-5′-phosphate, GMP; adenine monophosphate, AMP; and xanthosine-5′-phosphate, XMP.

Turner, MD, •September 1976). In patients treated at the Brown University College of Medicine, 12 of 19 patients showed greater than 50% improvement.[35] In our series, 24 of 32 patients (75%) exhibited greater than 50% improvement. Furthermore, analysis of the efficacy study showed a statistically significant response ($P < .01$) to mycophenolic acid when compared with the placebo. Undoubtedly, a higher degree of statistical significance would have been achieved had it not been for the two placebo responders. This response may help account for the close proximity in severity scores at week 9 (Fig 1).

We have not observed enough patients who have discontinued the drug for a lengthy interval before starting again to make a valid statement regarding the time it takes for the condition to relapse. Likewise, only a small group of patients have reached 52 weeks on mycophenolic acid treatment, but it appears there may be some tolerance to the drug exhibited.

The adverse reactions encountered in our series tend to temper the enthusiasm for use of mycophenolic acid in psoriasis. The majority of the problems were consistent with those being reported in other series.[19] However, the apparent increase in viral infections, the cases of neutropenia, and the associated carcinoma are of concern. The viral infections have been a problem at other institutions, and to date there have been 11 cases of herpes zoster (written communication, E. L. Jones, MD, September 1976). It is entirely possible that the two siblings who developed neutropenia may have done so secondary to a viral process. This theory is tenable, as a reinstitution of mycophenolic acid has failed to exhibit any suppressive bone marrow effects. It is also conceivable that the associated malignancies could have been a chance occurrence. Certainly, the patient with the squamous cell carcinoma of the scalp could be considered "malignancy prone."

Nonetheless, we feel that these occurrences demand additional investigative efforts. As mentioned, there is some evidence that mycophenolic acid can alter both humoral and cellular immunity.[29] Further toxicity studies should be designed to clearly elucidate the drug's effect on the immune system, and the possible carcinogenic potential. Only with such studies can the true safety of mycophenolic acid for the treatment of psoriasis be evaluated.

Nonproprietary Names and Trademarks of Drugs

Azathioprine–*Imuran.*
Levodopa–*Larodopa.*
Fenfluramine hydrochloride–*Ponderex.*
Hydroxyurea–*Hydrea.*
Azaribine–*Triazure.*
Mycophenolic acid–*Melbex.*

Figure 9 is reproduced with permission from Jones EL, McGinn TG, Silberman HR, et al.[19]

References

1. Weinstein GD, Van Scott EJ: Autoradiographic analysis of turnover times of normal and psoriatic epidermis. *J Dermatol* 45:257-262, 1965.
2. Weinstein GD, Frost P: Abnormal cell proliferation in psoriasis. *J Invest Dermatol* 50:254-259, 1968.
3. Van Scott EJ, Reinertson RP: Morphologic and physiologic effects of chemotherapeutic agents in psoriasis. *J Invest Dermatol* 33:357-369, 1959.
4. Zachariae H: Introduction and historical background of MTX in psoriasis, in Farber EM, Cox AJ (eds): *Proceedings of the International Symposium, Stanford University, 1971.* Stanford, Calif, Stanford University Press, 1971.
5. Roenigk HH Jr, Maibach HI, Weinstein GD: Use of methotrexate in psoriasis. *Arch Dermatol* 105:363-365, 1972.
6. Roenigk HH Jr, Bergfeld WF, St. Jaques R: Hepatotoxicity of methotrexate in the treatment of psoriasis. *Arch Dermatol* 103:250-261, 1971.
7. Higgins LC Jr, Thompson JG: Psoriasis with arthritis: Chemotherapy with cyclophosphamide, nitrogen mustard and 6-mercaptopurine. *South Med J* 59:1191-1193, 1966.
8. Kravetz RE, Balsam T: Treatment of psoriasis with mercaptopurine. *Arch Dermatol* 84:597-600, 1961.
9. McGinn TG, Silberman HR, Rundles RW: Response of refractory psoriasis to thioguanosine. *Clin Res* 13:230, 1965.
10. Nyfors A: Fucidin in psoriasis. A double-blind study of 20 psoriatics over two periods of four weeks each. *Dermatologica* 146:281-284, 1973.
11. Du Vivier A, Munro DD, Verbov J: Treatment of psoriasis with azathioprine. *Br Med J* 1:49-51, 1974.
12. Lewis MB: A pilot study of levodopa in psoriasis. *Am Aust J Dermatol* 14:140-142, 1973.
13. Russell T, Revter C: Fenfluramine in treatment of psoriasis. *Practiones* 214:114-117, 1975.
14. Parrish JA, Fitzpatrick TB, Tanenbaum L, et al: Photochemotherapy of psoriasis with oral methoxsalen and longwave ultraviolet light. *N Engl J Med* 291:1207-1212, 1974.
15. Leavell UW Jr, Yarbo JW: Hydroxyurea: A new treatment for psoriasis. *Arch Dermatol* 102:144-150, 1970.
16. Moschella SL, Greenwald MA: Psoriasis with hydroxyurea: An 18-month study of 60 patients. *Arch Dermatol* 107:363-370, 1973.
17. Cornell R: Current status of azaribine: A clinical and biopharmacologic review. *Derm Dig* 1974, pp 33-38.
18. Keefer R, Roenigk HH Jr, Hawk WA: Azaribine therapy for psoriasis. *Arch Dermatol* 111:853-856, 1975.
19. Jones EL, McGinn TG, Silberman HR, et al: Treatment of psoriasis with oral mycophenolic acid. *J Invest Dermatol* 65:537-542, 1975.
20. Alsberg CL, Black OF: Contribution to the study of maize deterioration. *US Dept Agr Plant Ind Bull* 270:7-28, 1913.
21. Birkinshaw JA, et al: Studies in the biochemistry of microorganisms: The molecular constitution of mycophenolic acid, a metabolic product of *penicillium brevi-compactum* dierckx: III. Further observation on the structural formula for mycophenolic acid. *Biochem J* 50:630-634, 1952.
22. Florey HW, Gilliver K, Jennings MA, et al: Mycophenolic acid: An antibiotic from penicillium brevi-compactum dierckx. *Lancet* 1:46-49, 1946.
23. Noto T, Sawada M, Ando K, et al: Some biological properties of mycophenolic acid. *J Antibiotics (Tokyo)* 22:165-169, 1969.
24. Cline JC, Nelson JD, Gerzon K, et al: In vitro antiviral activity of mycophenolic acid and its reversal by guanine-type compounds. *Appl Microbiol* 18:14-20, 1969.
25. Planterose DN: Antiviral and cytotoxic effects of mycophenolic acid. *J Gen Virol* 4:629-630, 1969.
26. Williams RH, et al: Mycophenolic acid: Antiviral and antitumor properties. *J Antibiotics (Tokyo)* 21:463-464, 1968.
27. Knudtzon S, Nissen NI: Clinical trial with mycophenolic acid (NSC 129185): A new antitumor agent. *Cancer Chemother Rep* 56:221-227, 1972.
28. Brewin TB, Cole MP, Jones CTA, et al: Mycophenolic acid (NSC-129185): Preliminary clinical trials. *Cancer Chemother Rep* 56:83-87, 1972.
29. Mitsui A, Suzuki S: Immunosuppressive effect of MPA. *J Antibiotics (Tokyo)* 22:358-363, 1969.
30. Franklin TJ, Cook JM: The inhibition of nucleic acid synthesis by mycophenolic acid. *Biochem J* 113:515-525, 1969.
31. Sweeney MJ, Hottman P, Easterman MA, et al: Metabolism and biochemistry of mycophenolic acid. *Cancer Res* 32:1803-1809, 1972.
32. Lintrup J, Hyltoft-Peterson P, Knudtzon S, et al: Metabolic studies in man with mycophenolic acid (NSC-129185): A new antitumor agent. *Cancer Chemother Rep* 56:229-235, 1972.
33. Mesirow S, Stoughton RB: Demonstration of β-glucuronidase in human skin. *J Invest Dermatol* 23:315-316, 1954.
34. Sweeney MJ, Hoffman DH, Poore GA: Possible in situ activation of mycophenolic acid by β-glucuronidase. *Cancer Res* 31:477-478, 1971.
35. McDonald CJ: Chemotherapy of psoriasis. *Int J Dermatol* 14:563-574.

Spontaneous Regression of Plane Warts After Inflammation

Clinical and Histologic Studies in 25 Cases

Hachiro Tagami, MD; Masahiro Takigawa, MD; Atsuhiko Ogino, MD; Sadao Imamura, MD; Shigeo Ofugi, MD

• Based on clinical and histological studies in 25 patients, we have confirmed that plane warts show a characteristic phenomenon of spontaneous regression totally distinct from that described in common warts.

This regression developed during various treatments in nine cases, and in 16 cases, it occurred spontaneously. In all the patients, there was a sudden and systemic onset of inflammation in every flat wart. Within two to six weeks, all the warts completely involuted.

Histologically, there were variable degrees of epidermal changes depending on the stage of inflammation. However, a mononuclear cell infiltration with epidermal invasion was demonstrated in every biopsy specimen. This evidence further supports the earlier concept that this regressive phenomenon of plane warts is mediated by cellular immunity. It represents a natural experimental model of rejection of tumors induced by papovavirus in humans.

(*Arch Dermatol* 113:1209-1213, 1977)

Plane warts or flat warts usually involve exposed parts of the skin and appear as numerous small pigmented patches or papules. Characteristically, these numerous warts will suddenly and spontaneously redden and cause severe pruritus and then within several weeks, completely disappear as inflammation subsides. Histologically, in ten such cases, we observed a dense mononuclear cell infiltration in the upper dermis and epidermis, a feature suggestive of the involvement of cellular immunity in this phenomenon.[1]

We are surprised, however, to find that there have been only a few reports about regression of plane warts from other countries,[2,3] in contrast to a number of recent studies concerning regression of common warts.[4-7] Moreover, Matthews and Shirodaria[6] and Brodersen and Genner[8] pointed out that regressing common warts associate clinically with pain and blackish discoloration and histologically with the lack of lymphohistiocytic infiltration.

In the present article, we present an additional 25 cases with clinically and histologically diagnosed flat warts that subsequently showed a characteristic regression.

MATERIAL AND METHOD

Twenty-five patients were examined. Nine of them visited us seeking treatment for their flat warts that then became inflamed during various types of treatment. Another 16 patients saw us because of the sudden and spontaneous appearance of inflammation in their flat warts. Summary of their clinical features are listed below:

Nine Patients Treated for Flat Warts

Age: 6-38 yr (mean 24.1)
Male/female: 3/6
Duration of presence of warts: 1-11 yr
Distribution of warts: face, 8; neck, 2; upper limbs, 2; dorsa of hands, 2; lower limbs, 1
Immediate preceding therapy:
- intradermal injection of purified vaccine lymph 1
- pearl barley powder (Yokuinin [Japan]; no comparable US product) orally 3
- fluorouracil ointment topically 2
- 0.05% vitamin A acid ointment topically 1
- moroxydine hydrochloride (Virustat) orally 1
- sensitization with 2% dichlorobenzene in acetone on the left upper arm 1

Duration of the preceding therapy: 3 days to 3 wk (mean 9.7 days)
Severity of pruritus: mild, 1; moderate, 7; severe, 1
Signs of inflammation:erythematous swelling, 9
Time required for resolution of warts:
2 wk, 1
3 wk, 2
4 wk, 5
6 wk, 1
(mean, 3.8 wk)

16 Patients With Spontaneously Inflamed Flat Warts

Age: 12-51 yr (mean 27.8)
Male/female: 3/13
Duration of presence of warts: unnoticed until the occurrence of sudden inflammation (2 cases)–6 yr
Distribution of warts: face, 11; dorsa of hands, 2; lower limbs, 3
Special preceding events to the occurrence of inflammation: abortion, 1; hard labor under the sun, 1; sea-bathing, 1
Severity of pruritus: mild, 3; moderate, 11; severe, 2
Signs of inflammation: erythematous swelling, 16; crusting, 3; vesiculation, 2
Time required for resolution of warts:
2 wk, 4
3 wk, 5
4 wk, 1
5 wk, 5
6 wk, 1
(mean, 3.6 wk)

Accepted for publication Jan 12, 1977.

From the Department of Dermatology, Kyoto University School of Medicine, Kyoto, Japan.

Reprint requests to Department of Dermatology, Kyoto University School of Medicine, Sakyo-ku, Kyoto 606, Japan (Dr Tagami).

Biopsies of the inflamed warts were done, but in case 7, biopsies were done both before and after the development of inflammation. Histological sections were prepared in the usual way and stained with hematoxylin-eosin. Serial sections were examined since the inflammatory changes were not uniform even in the same wart.

RESULTS

Clinical Observations

All 25 cases had similar clinical findings of erythema, swelling, and pruritus. Since inflammation occurred even in quite tiny warts on different parts of the body than had previously been noted, patients were frightened by the fact that their warts had suddenly increased in number. The pruritus ranged from mild to severe and could not be influenced either by intake of antihistamines or by topical application of steroids such as 0.1% triamcinolone acetonide and 0.025% fluocinolone acetonide. In some cases, inflammation became so severe that clearly visible vesiculation or crust formation appeared (Fig 1). After two to six weeks, the reddened warts gradually became scaly, and the inflammation subsided with complete disappearance of all the warts, occasionally leaving a slight pigmentation.

The detailed clinical courses of two representative cases follow:

CASE 7.—A 31-year-old man had suffered from numerous brownish papules on the forehead for the past two years. Diagnosis of verruca plana was made clinically and histologically (Fig 2). He was treated by provoking contact dermatitis with dichlorobenzene at the affected areas after artificial sensitization to it. Pearl barley powder, 4 gm, was also given daily. Both regimens were ineffective. Three months later, he was treated with topical application of fluorouracil ointment twice daily. Within a few days, all the warts became pruritic and prominent due to the appearance of erythema and swelling. Histological studies performed two weeks later on one of the reddened warts showed the characteristic mononuclear cell invasion in wart tissue (Fig 3). The warts gradually became scaly and flattened and disappeared within four weeks without any special treatment.

CASE 20.—A 29-year-old woman, in her fifth month of pregnancy, had been aware of an asymptomatic brownish, wart-like papular eruption over the face and dorsa of the hands for eight years. She visited us because the warts suddenly became pruritic, reddened, and enlarged in size three days before. Under the diagnosis of verruca plana with spontaneous inflammation, she was given cyanocobalamin, 500 μg subcutaneously, and oral gastric antacids. However, the pruritus continued to exacerbate and within five days, they became vesiculated (Fig 1). Similar vesicular changes also appeared in the warts on her forearms, which so far had been unnoticed by her. A biopsy of one of the vesicular lesions on the face was done that showed diffuse eosinophilic necrosis of the epidermis with subepidermal vesiculation and a dense mononuclear cell infiltration. In two days, without any further treatment, they became crusty, scaly, and less pruritic, and within two weeks, all the lesions involuted completely.

Histopathological Features

Table 1 summarizes the histopathological data from 25 patients. The characteristic feature observed in all the biopsy specimens was a dense

Table 1.—Histopathological Data From 25 Patients*

Case No.	Age (yr)/Sex	Duration of Inflammation Until Biopsy	Parakeratosis	Remaining Vacuolated Cells	Spongiosis and Exocytosis of Mononuclear Cells	Eosinophilic Necrotic Epidermal Cells	Mononuclear Cell Infiltration in the Dermis
Nine patients with sudden inflammation in flat warts during treatment							
1	8/F	2 wk	+ +	—	+ + +	+ +	+ +
2	24/F	3 days	+ +	+ +	+ +	—	+ + +
3	36/F	4 days	—	+ +	+ +	—	+ + +
4	24/F	1 wk	+ +	—	+ +	+ +	+ + +
5	28/M	3 wk	+ +	—	+ +	+ +	+ + +
6	38/M	1 wk	+ +	+	+ +	+ +	+ +
7	31/M	2 wk	+ +	+	+ +	+ +	+ +
8	22/F	1 wk	+ +	—	+ +	—	+ +
9	6/F	1 wk	+ + +	—	+ + +	—	+ +
Sixteen patients with spontaneously inflamed warts							
10	32/F	2 wk	+ +	+	+ +	+ +	+ +
11	49/F	2 wk	+ +	+	+ +	+ +	+ +
12	20/M	1 wk	+ + +	+	+ +	+ +	+ +
13	27/M	2 wk	+ +	—	+ +	+ +	+ +
14	30/M	4 days	—	—	+ +	+ +	+ +
15	28/F	1 wk	+ +	+	+ +	—	+ +
16	35/F	3 days	+ +	—	+ +	+ +	+ +
17	24/F	1 wk	+ +	—	+ +	+ +	+ +
18	19/F	1 wk	+ +	—	+ +	+ + +	+ +
19	26/F	1 wk	+ +	+	+ +	—	+ + +
20	29/F	1 wk	+ +	—	+ + +	+ + +	+ + +
21	51/F	1 wk	—	+	+ +	+ +	+ +
22	22/F	2 wk	+ +	—	+ +	+ +	+ +
23	15/F	3 days	—	+ + +	+ +	+ +	+ +
24	12/F	1 wk	+ +	—	+ + +	+	+ +
25	26/F	1 wk	+	—	+ + +	+	+ + +
Total			**22**	**11**	**25**	**19**	**25**
Percentage			88	44	100	76	100

*— indicates absent; +, few; + +, moderate; and + + +, marked.

mononuclear cell infiltration accompanied by epidermal invasion.

Epidermis.—In the lesions representing early phases of the inflammation, the upper epidermis still retained the histopathologic condition of ordinary flat warts such as the basket weave-like appearance of the stratum corneum and vacuolated cells (44%) in the stratum granulosum. However, in the lower epidermis, beginnings of mononuclear cell invasion caused basal spongiosis and histological pigmentary incontinence (Fig 4).

Fig 1.—Extreme of inflammatory changes in flat warts; vesiculation in flat warts of a 29-year-old woman (case 20) eight days after the sudden onset of spontaneous inflammation.

In specimens that appeared to represent more advanced stages, the epidermis became extensively spongiotic and diffusely invaded by mononuclear cells, being far different from the typical histological feature of plane warts (Fig 3). Occasionally, there was even focal spongiotic vesicle formation. Necrotic epidermal cells, stained strongly with eosin, were noted in 76% of the specimens. They usually scattered in the area of epidermis with spongiosis (Fig 5). In a few cases, the upper epidermis became extensively eosinophilic. Prominent upper dermal edema or subepidermal bullae were observed beneath such diffusely necrotic epidermis.

Focal parakeratotis was prominent in the portions representing fairly advanced stages, sometimes showing eosinophilic homogeneously round bodies that were perhaps remnants of those necrotic epidermal cells interspersed within the parakeratotic scales.

The epidermal changes were not uniform, however, even in the same wart. Sometimes vacuolated cells in the stratum granulosum existed beside the area where a focal parakeratotic mound was present above the spongiotic epidermis.

Dermis.—The infiltrating cells consisted of mononuclear cells or lymphohistiocytic cells. (Smear preparations of these infiltrating cells made from the content of vesicular lesions of case 10 showed approximately an equal number of small lymphocytes and

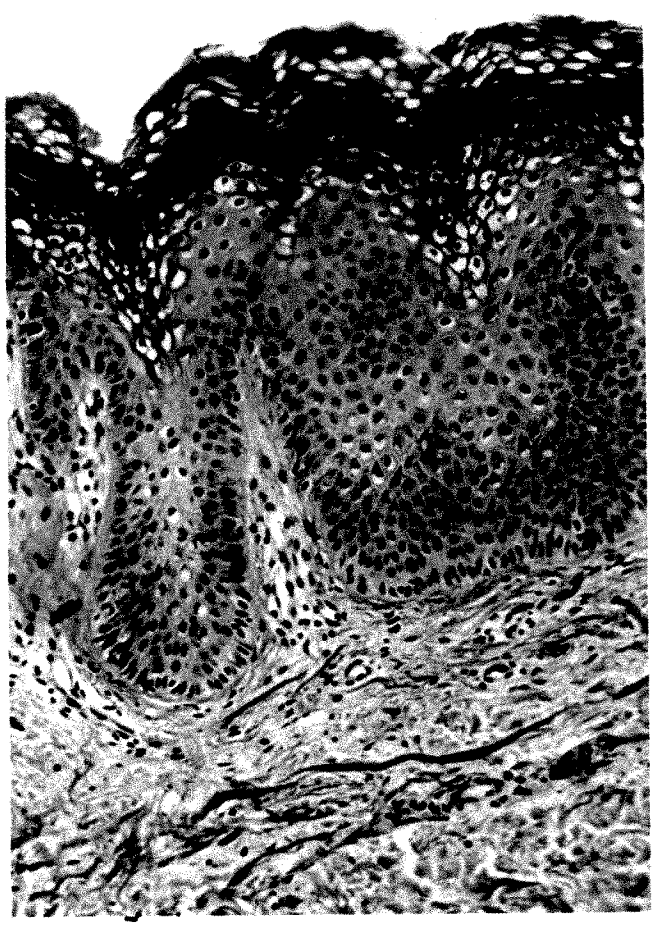

Fig 2.—Characteristic histological appearance of verruca plana, before the onset of inflammation in case 7 (hematoxylin-eosin, original magnification ×100).

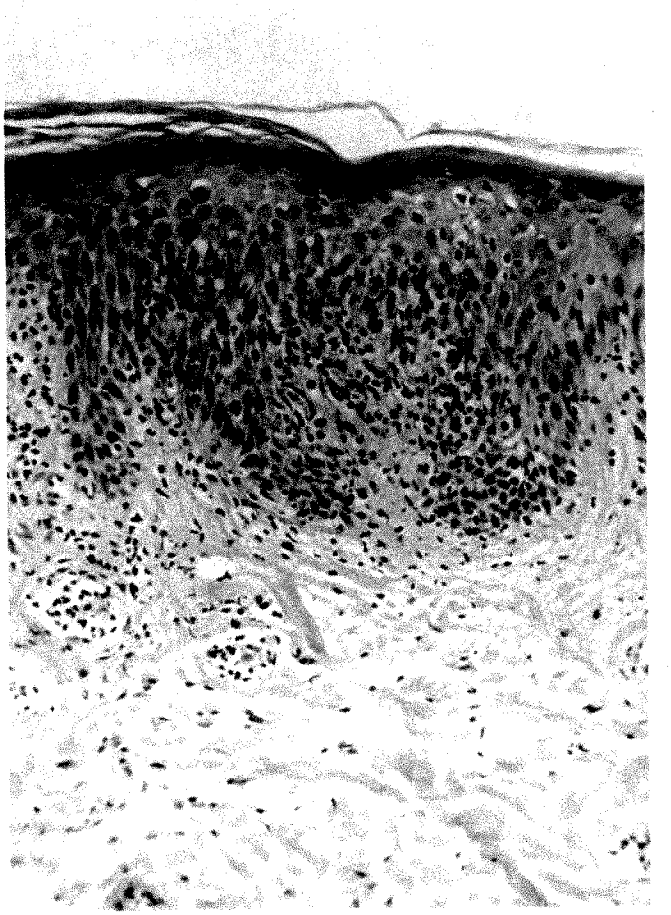

Fig 3.—Histological feature of inflamed flat wart from same patient (case 7), two weeks after onset of inflammation. Note loss of feature of verruca plana and replacement by inflammatory changes (hematoxylin-eosin, original magnification ×100).

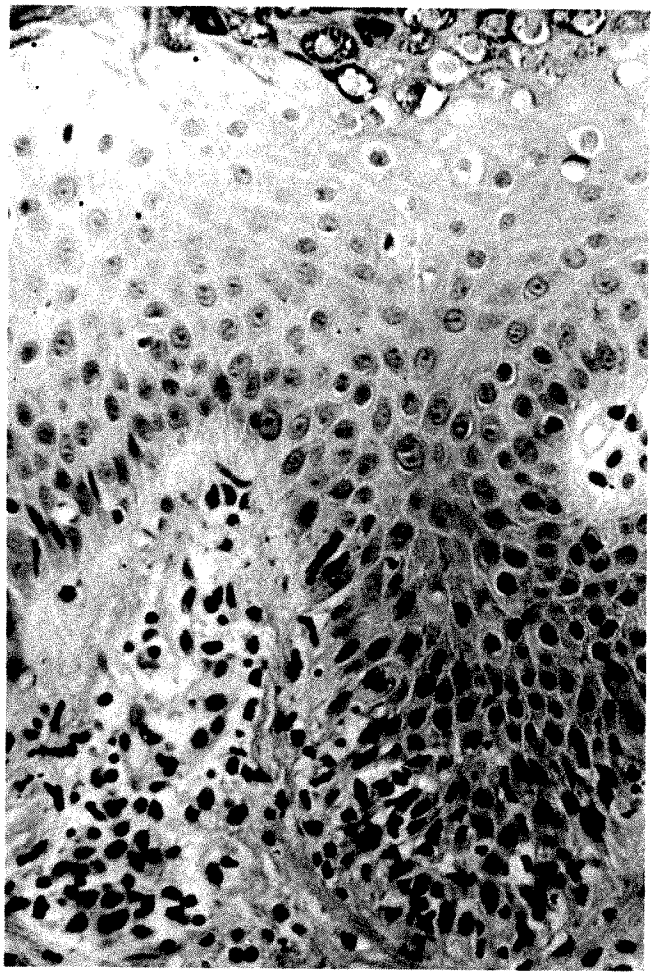

Fig 4.—Early stage of inflammation showing transitional feature from ordinary plane wart to inflamed one. Vacuolated cells are still remaining in granular cell layer, while lower epidermis is being invaded by mononuclear cells (hematoxylin-eosin, original magnification ×200).

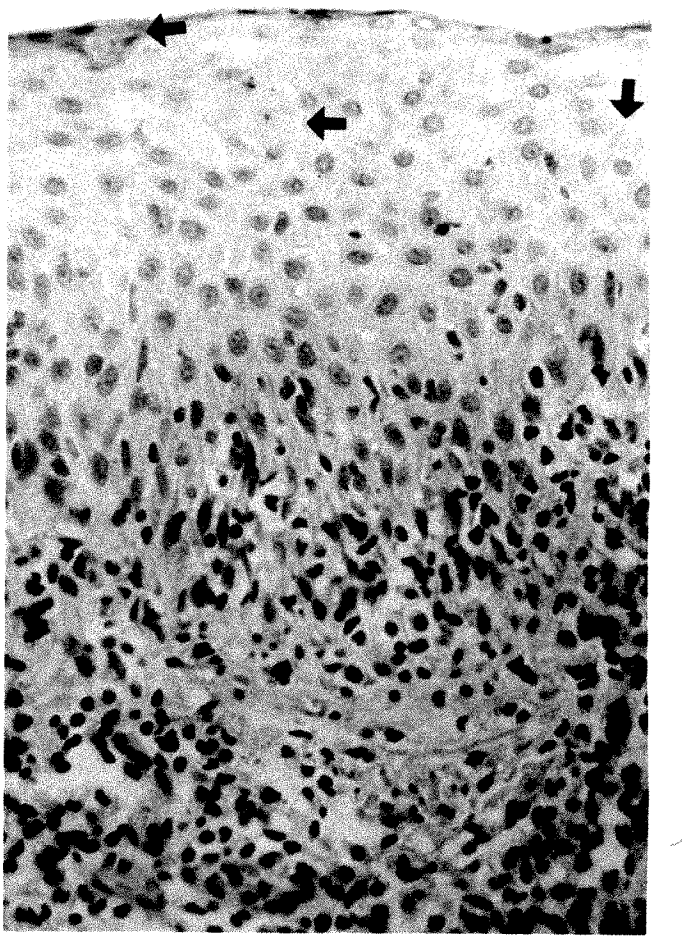

Fig 5.—Scattered eosinophilic necrotic cells (arrows) in upper epidermis. Lower epidermis is completely disorganized by spongiosis and exocytosis (hematoxylin-eosin, original magnification ×200).

Table 2.—Comparison of Clinical and Histological Features in Regressing Common Warts and Flat Warts

	Common Warts*	Flat Warts
Clinical features	Subjectively very painful and acutely tender	Subjectively pruritic
	Warts become dark or present dark spots or lines, together with redness of the surroundings	Systemically, all the warts become erythematous, swollen, scaly and occasionally vesiculated or crusted
Histopathological changes	Epidermis retains changes typical of common wart	Epidermal architecture characteristic for plane wart is almost replaced by spongiosis, exocytosis of mononuclear cells and eosinophilic necrotic cells
	No cellular infiltration in the dermis	Dense mononuclear cell infiltration in the upper dermis
	Blood vessels occluded with thrombosed blood	No thrombosed blood vessels but occasionally extravasation of erythrocytes from dilated capillaries

*Summarized from the data of Matthews and Shirodaria[4] and Brodersen and Genner[6].

medium-sized lymphocytes intermingled with several monocytes). Neutrophils or eosinophils were rarely seen. Since ordinary flat warts showed hypermelanosis in the basal cell layer, in the inflamed warts melanin-laden macrophages were sometimes found in the upper dermis due to the destruction of the lower epidermis.

COMMENT

It is a rather well-known fact among Japanese dermatologists that when flat warts become reddened and pruritic, they respond to any kind of treatment. There was no clinical and histological difference between spontaneous regression of flat warts and warts treated topically, eg, with fluorouracil ointment. Therefore, it seems to be reasonable to assume that various treatments carried out for flat warts were only effective for the induction of the same mechanisms as those that operate in the spontaneous regression of flat warts. We believe that this phenomenon would be more frequently observable in other nations if every patient with flat warts was closely observed.

In our 25 cases, biopsy was performed at various intervals after the onset of the regression phenomenon. Nevertheless, the characteristic mononuclear cell infiltration was invariably noted in every specimen. This observation confirmed our previous studies and suggests that infiltrating mononuclear cells mediate the regression of plane warts. In an early stage, the mononuclear cells accumulate in the lower epidermis, while the upper epidermal cells still retain the histological changes typical for verruca plana. The inflammatory cellular reactions may occur not against intranuclear wart virus but against the whole epidermal cell. These cells may have been antigenically altered as a result of infecting virus, ie, virus-transformed cells.

As the epidermal damage caused by invasion of mononuclear cells proceeds, there develops extensive spongiosis associated with focal vesiculation and scattered cell necrosis. Occasionally, the upper or whole epidermis becomes diffusely necrotic without any appreciable number of invading mononuclear cells. The almost absolute lack of neutrophils and eosinophils seems to mitigate against the major role played by humoral immunity. One speculative view is that some toxic factors such as lymphokines are released massively from infiltrating mononuclear cells.

Even after the damaged epidermal cells change into thick parakeratotic layers and the epidermal architecture characteristic for the plane wart is no longer observable, there still persists epidermal invasion of mononuclear cells. Inflammatory response may continue until the last single virus-transformed cell is eliminated.

The clinical and histological changes reported in regressing common warts[6,8] were not seen in our 25 cases (Table 2). Although Morrison[7] recently found spontaneous involution in patients who had a positive leukocyte migration inhibition test to human wart tissue antigen, other studies by Matthews and Shirodaria[6] and Brodersen and Genner[8] assigned only a minor role to cellular immunity in rejection of common wart because of the absence of a lymphoid cell infiltration in their histological specimens. If the same interpretation can be applied to explain the sudden and systemic involution of numerous plane warts, cellular immunity seems to play a major role in this disease. The reason why there is such a great difference in the clinical and histological features of spontaneous resolution between the common wart and flat wart is not clear. It is of interest that patients with a cell-mediated immune deficiency state appeared more prone to wart infection and that plane warts were by far the most common type in these patients.[9]

The phenomenon of spontaneous regression of plane warts resembles that noted in Shope papilloma of rabbit that is induced by a relative virus. Here, the phenomenon of regression also has the characteristic of an actively acquired immune response, ie, systemic and specific.[10] Regression of a flat wart may represent a human model of rejection of tumors induced by papovavirus.

Yohei Ito, MD, professor of the Department of Microbiology, Kyoto University School of Medicine, provided criticism and advice.

Nonproprietary Name and Trademark of Drug

Moroxydine hydrochloride—*Virustat.*

References

1. Tagami H, Ogino A, Takigawa M, et al: Regression of plane warts following spontaneous inflammation: A histopathological study. *Br J Dermatol* 90:147-154, 1974.

2. Samek J: Zum Wesen der suggestiven Warzenheiling. *Dermatol Wsch* 93:1853-1857, 1931.

3. Goihman-Yahr M, Essenfeld-Yahr E: Verrugas e immunidad. (Informe de un caso de desparicion espontanea de verrugas planas con documentacion histopatologica.) *Med Cutan* 4:137-140, 1972.

4. Pass F, Maizel JV: Wart-associated antigens: II. Human immunity to viral structural proteins. *J Invest Dermatol* 60:307-311, 1973.

5. Pyrhönen S, Penttinen K: Wart-virus antibodies and the prognosis of wart disease. *Lancet* 2:1330-1332, 1972.

6. Matthews RS, Shirodaria PV: Study of regressing warts by immunofluorescence. *Lancet* 1:689-691, 1973.

7. Morrison WL: In vitro assay of immunity to human wart antigen. *Br J Dermatol* 93:545-552, 1975.

8. Brodersen I, Genner J: Histological and immunological observation on common warts in regression. *Acta Dermatovenereol* 53:461-463, 1973.

9. Morrison WL: Viral warts, herpes simplex and herpes zoster in patients with secondary immune deficiencies and neoplasms. *Br J Dermatol* 92:625-630, 1975.

10. Evans CA, Gorman LR, Ito Y, et al: Antitumor immunity in the Shope papilloma-carcinoma complex of rabbits: I. Papilloma regression induced by homologous and autologous tissue vaccine. *J Natl Can Inst* 29:277-286, 1962.

Recovery Processes During Regression of Plane Warts

Masahiro Takigawa, MD; Hachiro Tagami, MD; Susumu Watanabe, MD; Atsuhiko Ogino, MD; Sadao Imamura, MD; Shigeo Ofugi, MD

• The regressing process of plane warts can be divided into two phases: initial changes of wart virus-infected cells that later result in degeneration of warts, and recovery phase in which degenerating warts are rejected from the level of the basal layer followed by regeneration of normal epidermal cells from the surrounding epidermis. Electron microscopic observations of recovery phase of wart regression showed (1) the epidermal lesion was clearly divided into degenerating wart possessing altered viruses and regenerating epidermis; (2) melanocytes were demonstrated in degenerating warts; and (3) a new granular layer was evident beneath regressing wart in late recovery. Throughout the recovery process, infiltration of lymphocytes and macrophages was observed only in regenerating epidermis.

(*Arch Dermatol* 113:1214-1218, 1977)

Spontaneous regression is not uncommon in plane warts.[1,2] Previous studies[2,3] demonstrated an inflammatory mononuclear cell infiltrate within epidermal lesions as a characteristic finding in regressing plane warts in contrast to the lack of lymphocytic infiltration in regressing common warts.[4] These studies,[2,3] however, did not detail the entire course of wart regression. The present study is concerned with the ultrastructure of regressing warts and regenerating epidermis to elucidate the morphological process of regression of plane warts.

Accepted for publication Jan 12, 1977.

From the Department of Dermatology, Faculty of Medicine, Kyoto University, Kyoto, Japan (Drs Takigawa, Tagami, Ogino, Imamura, and Ofugi), and the Department of Dermatology, Kurashiki Central Hospital, Kurashiki, Japan (Dr Watanabe).

Reprint requests to Department of Dermatology, Faculty of Medicine, Kyoto University, Kyoto 606, Japan (Dr Takigawa).

Fig 1.—Regressing plane warts on the face in early stage (case 3).



Fig 2.—Disappearance of all warts after two weeks of inflammatory reaction (case 3).

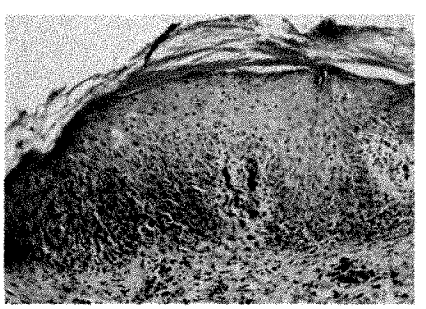

Fig 3.—Early stage of regression, showing parakeratotic area beneath horny layer, cells with eosinophilic cytoplasm and pyknotic nuclei, and dyskeratotic cells in upper epidermis. Mononuclear cell infiltrate is seen in spongiotic lower epidermis and upper dermis (hematoxylin-eosin, original magnification ×100).

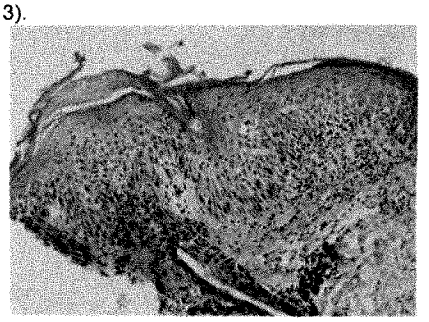

Fig 4.—Intensely inflammatory stage, showing markedly parakeratotic horny layer, appearance of granular cells, and mononuclear cell infiltrate (hematoxylin-eosin, original magnification ×100).

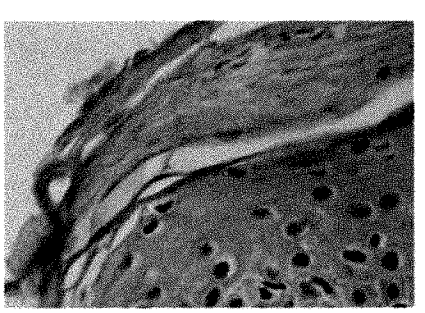

Fig 5.—Granular cells beneath parakeratotic horny layer in Fig 4 (hematoxylin-eosin, original magnification ×400).

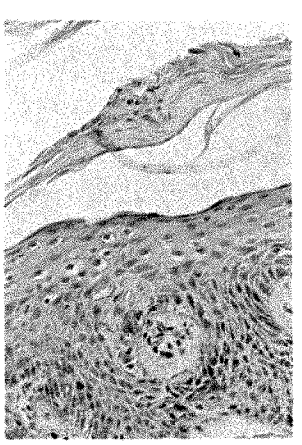

Fig 6.—Late stage showing definite granular layer beneath parakeratotic horny layer (hematoxylin-eosin, original magnification ×200).

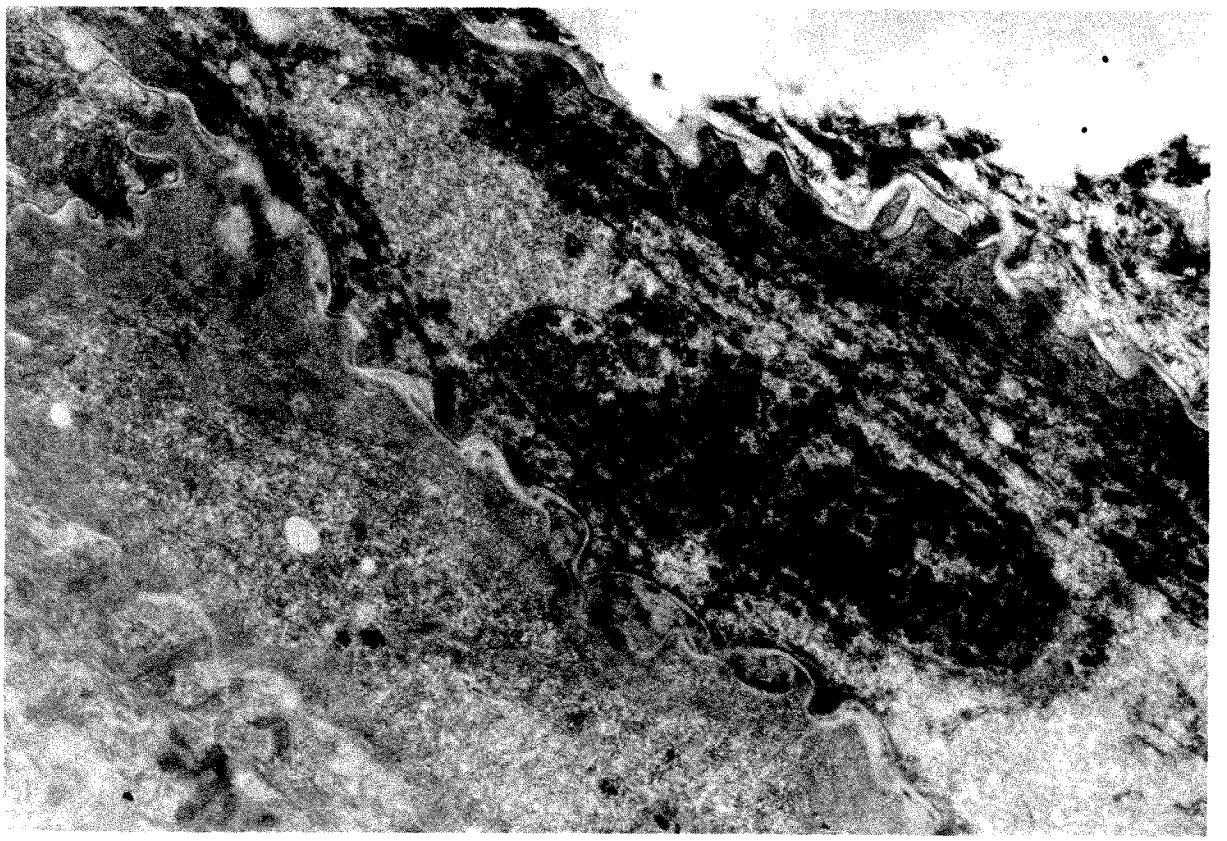

Fig 7.—Wart viral particles of ordinary plane warts (original magnification ×18,200).

MATERIALS AND METHODS

Five patients with regressing plane warts and two patients with nonregressing, persistent plane warts were studied. Clinical details are summarized in the Table. Diagnosis of plane warts before the onset of regression was based on clinical features and/or histopathological findings. The first obvious clinical signs of the regression were inflammatory reactions occurring suddenly and simultaneously in all the warts. Pruritus occurred to a variable degree. The reaction lasted a few weeks and was followed by complete disappearance of all warts (Fig 1 and 2). The course of regression was divided arbitrarily into three stages based on objective changes in the lesions, since each wart at one time during regression showed similar clinical features. In the early stage, erythema was a predominant sign. In the intensely inflammatory stage, swelling and scaling in addition to erythema were observed. In the late stage, inflammatory signs decreased, and scaling was prominent. When inflammation was severe, lesions appeared crusted.

Clinical Details of Patients With Regressing and Nonregressing Plane Warts*

Case No.	Age, yr/Sex	Duration†	Distribution	Clinical Features	Time for Resolution, wk
1	40/F	6 mo	Face	Ordinary plane warts	. . .
2	28/F	12 mo	Face	Ordinary plane warts	. . .
3	49/F	15 mo	Face, forearm	Itchy and reddish papules	2
4	8/F	2 mo	Face, forearm	Itchy, reddish and swollen papules	3
5	26/F	3 wk	Face	Itchy, reddish and swollen papules	3
6	31/M	12 mo	Face	Itchy and crusted papules	2
7	26/M	1 wk	Face	Itchy and crusted papules	3

*All patients were Japanese.
†Duration indicates time after the diagnosis was made and, in the last five cases, until the onset of regression.

Light and Electron Microscopy

The specimens were obtained from facial lesions of all patients. One half of each specimen was fixed in 10% formaldehyde solution and processed for routine histopathology. For electron microscopy, the other half was cut into pieces, fixed in cold 2.5% glutaraldehyde in 0.1M phosphate buffer, pH 7.4, for one hour, rinsed overnight at 4 C in the same buffer containing 0.2M sucrose, postfixed in cold 1% osmium tetroxide in the phosphate buffer for one hour, dehydrated in graded alcohol, and embedded in an epoxy resin. Thin sections were cut by glass knives on a microtome, mounted on grids coated with carbonized Formvar, stained with uranyl acetate and lead citrate, and examined in an electron microscope at 100 kV or 75 kV, respectively.

RESULTS

Light Microscopic Findings

The specimen from nonregressing plane warts (cases 1 and 2) showed typical changes of a viral wart.[3] In the early stage (case 3), the horny layer showed parakeratosis at the lowermost part. Cells in the upper portion of epidermis next to this parakeratotic area displayed a slightly eosinophilic cytoplasm, pyknotic nuclei, and ill-defined cellular outlines. Dyskeratotic cells were scattered. Spongiosis and exocytosis of mononuclear cells were noted in the lower portion of the epidermis. The upper dermis showed vascular dilation and a perivascular mononuclear cell infiltrate (Fig 3). In the intensely inflammatory stage (cases 4 and 5), parakeratosis was

LIBRARY



Fig 8.—Clear delineation of upper portion (UP) and lower portion (LP) of epidermis in early stage of recovery (case 3). Keratinocytes (K) with increased electron density and intranuclear particles (arrows), and dyskeratotic cell (DC) in UP are evident (original magnification, ×7,700).

more prominent throughout the entire horny layer, and mononuclear cells infiltrated a spongiotic epidermis. Cells with eosinophilic cytoplasm and dyskeratotic cells were not seen (Fig 4). Granular cells were only occasionally seen as single cells beneath the parakeratotic horny layer (Fig 5). In the late stage (cases 6 and 7), a definite, continuous granular layer had reappeared. Exocytosis of mononuclear cells was less intense than previously (Fig 6).

Electron Microscopic Findings

In control specimens (cases 1 and 2), viral particles were exclusively localized within the nuclei of cells in and adjacent to the horny layer. They were mostly spherical in shape, measured 30 to 37 mμ in diameter, and had a tendency to crystalline formation (Fig 7). Other ultrastructural findings were essentially the same as described by Lutzner[6] and Almeida et al.[7]

In the early stage (case 3), the upper portion of the epidermis had a dark appearance due to an overall high electron density of keratinocytes and could clearly be distinguished from the lower portion (Fig 8). In the dark portion, electron-dense particles giving a diameter of 22 to 44 mμ were present within the nuclei of keratinocytes (Fig 8 and 9 and inset). In their cytoplasm, mitochondria were disrupted and tonofilaments tended to clump, sometimes to form a dyskeratotic cell (Fig 8 and 9).[8] Vacuoles with and without membranes were seen commonly. Melanocytes appeared frequently within the degenerating mass of epidermal cells (Fig 10). Parakeratotic stratum corneum cells showed vacuolation and degenerative nuclei in which electron-dense particles could be recognized. No definite inflammatory cells were seen in the upper portion.

On the other hand, relatively normal-appearing keratinocytes occurred in the lower portion (Fig 8). Neither intranuclear electron-dense particles nor wart virus was observed in cells of the lower portion. In the basal and successive several layers, infiltrating lymphocytes and macrophages with lysosomes were observed in the widened intercellular spaces (Fig 11). No plasma cells or polymorphonuclear leukocytes were seen. The basement membrane and the dermal components appeared normal. These ultrastructural observations suggested that the dark, upper portion was degenerating wart while the lower portion was regenerating epidermis.

In the intensely inflammatory stage (cases 4 and 5), ultrastructural changes confirmed the light microscopic observations as follows: (1) the dead warty tissue had migrated outward into the horny layer; and (2) some high level cells contained very small keratohyalin granules (Fig 12). In addition, numerous membrane coating granules occupied the intercellular spaces of uppermost layer of regenerating epidermis.

In the late stage (cases 6 and 7), three to four layers of the granular cells were evident beneath the vacuolated horny layer (Fig 13). Infiltration of lymphocytes and macrophages in the spongiotic epidermis persisted. The appearance of many granular cells indicated that regenerating epidermal cells had resumed normal keratinization.

COMMENT

The ultrastructural observations of the early stage of wart regression showed a clear distinction between degenerating wart and regenerating epidermis. Degenerating wart contained keratinocytes with a high electron density and also many melanocytes. As the process advanced, regenerating epidermis resumed normal keratinization as indicated by the appearance of granular cells in the uppermost layer. These data imply that regression is represented by extrusion of all virus-infected cells.

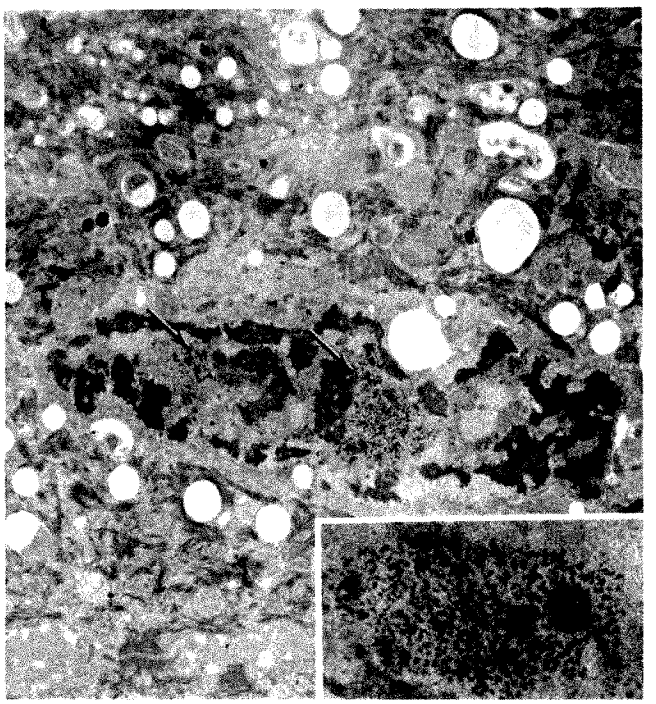

Fig 9.—Keratinocyte in upper portion, showing intranuclear electron dense particles (arrows), disintegration of nuclear membrane, mitochondrial alteration, aggregated tonofilaments, and cytoplasmic vacuoles (original magnification, ×16,000). Inset, Enlargement of intranuclear electron dense particles (original magnification, ×26,700).

Fig 10.—Melanocyte in upper portion (original magnification, ×10,300).

Fig 11.—Lymphocytes (LY) and macrophage (M) in spongiotic lower portion of early stage. Ls indicates lysosomes (original magnification, ×7,500).

Based on the finding of melanocytes in the dying tissue, we suggest that the whole lesion, including the basal layer, is rejected as the main event in wart regression. Healing would then occur by inward migration of new, uninfected basal cells from the surrounding epidermis or appendages. Alternatively, all but the basal and spinous layers are rejected, and melanocytes are drawn upward with the necrotic tissue and crowd together. The answer to this question may reflect on whether basal cells are infected with wart virus. The RNA-wart virus DNA hybridization studies of Croissant et al[9] in Shope papilloma of rabbits, the counterpart of human wart in animal experiments, suggest that the viral genome appears only in cells of the granular layer and above; but the sensitivity of their technique measured no less than 6 grains per genome. Many investigations,[10-12] on the other hand, have supported the view that proliferating cells of the basal and spinous layers contain a small number of viral genomes, probably in a provirus state.

The demonstration of regenerating epidermis in the early stage implies that recovery was already underway despite the clinical appearance. In the present study, it was not possible to detect the earliest changes of rejection, suggesting they occurred before obvious clinical signs of inflammation were noted.

Taking these observations into consideration, the regression of plane warts can be divided into two phases: (1) initial changes of wart virus-infected cells; and (2) recovery phase, although both phases might overlap. The initial changes seem to occur in almost all epidermal cells of the wart and later resulted in their degeneration. The recovery phase was composed of rejection of the degenerating wart and regeneration of normal

Fig 12.—Epidermal lesion of intensely inflammatory stage (case 4), showing flattened dead warty tissue (UP) and granular cells (GC) with small keratohyalin granules (KH) beneath UP. Arrows indicate intranuclear particles. MCG indicates membrane coating granules (original magnification, ×6,900). Inset, Enlargement of intranuclear particles (original magnification, ×27,000).

Fig 13.—Epidermal changes in late stage (case 6), showing granular layer beneath vacuolated horny layer. Keratohyalin granules are evident (original magnification, ×5,400).

epidermis. In terms of the recovery, wart regression is likely to represent a type of epidermal wound healing.[13]

Recently, regression of warts has been considered to be mediated by immune responses, and several mechanisms that possibly occur have been suggested.[14-16] Prominent infiltration of mononuclear cells in the lesions may imply that cellular immunity plays an important role in the regression of plane warts.[2] Our present electron microscopic study, however, clearly demonstrated that an infiltrate composed of lymphocytes and macrophages in the epidermal lesion was restricted to the regenerating normal epidermis and at no time were inflammatory cells observed in the degenerating wart tissue. Further electron microscopic and other studies of the initial changes of regression of plane warts are needed to elucidate the exact role of infiltrating cells in regression.

S Uchida, M Fujioka, and K Akada prepared the specimen.

References

1. Harman RRN, Nagington G, Rook A: Papovaviruses, in Rook A, Wilkinson DS, Ebling FJG (eds): *Textbook of Dermatology*, ed 2. Oxford, England, Blackwell Scientific Publications, 1972, pp 549-559.

2. Tagami H, Ogino A, Takigawa M, et al: Regression of plane warts following spontaneous inflammation: A histopathological study. *Br J Dermatol* 90:147-154, 1974.

3. Samek J: Zum Wesen der suggestiven Warzenheilung. *Dermatol Wochensch* 93:1853-1857, 1931.

4. Brodersen I, Genner J: Histological and immunological observations on common warts in regression. *Acta Dermatovener* 53:461-464, 1973.

5. Lever WF: *Histopathology of the Skin*, ed 4. Philadelphia, JB Lippincott Co, 1967, pp 397-380.

6. Lutzner MA: Virus diseases, in Zelickson AS (ed): *Ultrastructure of Normal and Abnormal Skin*. Philadelphia, Lea & Febiger, 1967, pp 365-387.

7. Almeida JD, Howatson AF, Williams MG: Electron microscope study of human warts; site of virus production and nature of the inclusion bodies. *J Invest Dermatol* 38:337-345, 1962.

8. Olson RL, Gaylor J, Everett MA: Ultraviolet-induced individual cell keratinization. *J Cut Pathol* 1:120-125, 1974.

9. Croissant MM, Dauguet C, Jeanteur P, et al: Application de la technique d'hybridation moléculaire in situ à la mise en évidence au microscope électronique, de la réplication végétative de l'ADN viral dans les papillomes provoqués par le virus de Shope chez le Lapin cottontail. *CR Acad Sci* 274:614-617, 1972.

10. Noyes WF, Mellors RC: Fluorescent antibody detection of the antigens of the Shope papilloma virus in papillomas of the wild and domestic rabbit. *J Exp Med* 106:555-562, 1957.

11. Evans CA, Gorman LR, Ito Y, et al: Antitumor immunity in the Shope papilloma-carcinoma complex rabbits: I. Papilloma regression induced by homogenous and autologous tissue vaccines. *J Nat Cancer Inst* 29:277-285, 1962.

12. Orth G, Jeanteur P, Croissant O: Evidence for an localization of vegetative viral DNA replication by autoradiographic detection of RNA • DNA hybrids in sections of tumor induced by Shope papilloma virus. *Proc Natl Acad Sci USA* 68:1876-1880, 1971.

13. Epstein WL, Fukuyama K, Cortese TA: Autoradiographic study of friction blisters: RNA, DNA, and protein synthesis. *Arch Dermatol* 99:94-106, 1969.

14. Pass F, Maizel JV: Wart-associated antigens: II. Human immunity to viral structural proteins. *J Invest Dermatol* 60:307-311, 1973.

15. Matthews RS, Shirodaria PV: Study of regressing warts by immunofluorescence. *Lancet* 1:689-691, 1973.

16. Greenberg JH, Smith TL, Katz RM: Verrucae vulgaris rejection: A preliminary study of contact dermatitis and cellular immunity response. *Arch Dermatol* 107:580-582, 1973.

Flat Warts Undergoing Involution

Histopathological Findings

Alexander Berman, MD, Richard K. Winkelmann, MD

• **Patients with multiple flat warts were observed during the period of involution, shortly before regression of the warts. The histopathological process was characterized by mononuclear cell infiltration around subpapillary blood vessels, exocytosis of mononuclear cells into the epidermis, and a spectrum of degenerative epidermal changes that culminated in focal areas of necrosis within the epidermis. Lesions near the end stage of involution did not show the histopathologic features of flat warts. The mononuclear cell-associated injury to the epidermis resembles that seen in delayed cutaneous hypersensitivity responses and suggests that regression of flat warts may be due to a cell-mediated rejection reaction.**

(*Arch Dermatol* 113:1219-1221,1977)

Tagami et al,[1] in 1974, published the first report in the English language describing the histopathologic changes in plane warts undergoing spontaneous regression. Though histologic inflammatory changes in flat warts had been described in the earlier German[2,3] and Japanese[4] literature, Tagami et al[1] correlated the development of mononuclear cell infiltration with regression of the flat warts.

We became interested in the involution of flat warts after observing three patients with typical flat warts on the extremities whose lesions disappeared in a remarkably short period of time. In each instance, mononuclear cell infiltration of the lesions, with degeneration and necrosis in the epidermis, was found on microscopic examination. It became apparent that mononuclear cell infiltration and presumably destruction of the virus-infected epidermis characterized the final stage of involution, immediately prior to regression of the warts.

To define the histopathological findings during the early phases of involution, patients with multiple flat warts were observed at regular intervals over long periods of time. We found that occasionally, the onset of involution could be recognized clinically. When the onset of involution was suspected, biopsy of the lesions was done, and the patients were then observed to establish whether the remaining flat warts would subsequently regress.

Our observations on flat warts during the stage of involution constitute the basis of this report.

REPORT OF CASES

Case 1.—A 19-year-old woman was seen on July 2, 1975, with multiple flat warts on the dorsum of the left hand, thighs, and legs. In the past two weeks, many new, extremely pruritic, lesions had developed on the thighs and legs. She decided to seek medical attention because she became alarmed at the appearance of new lesions and the sudden development of itching of the warts. A total of 60 flat warts were counted. She recalled that four years previously, she had periungual warts on her fingers that disappeared without treatment. Her two brothers have warts.

A typical lesion on her thigh was excised for microscopic examination, and she was given a 6% salicylic acid-propylene glycol gel formulation (Keralyt) to rub into the warts morning and night. She returned 13 days later. The warts had all disappeared. The skin at the sites of application of the gel showed only erythema and scaling.

Case 2.—A 27-year-old woman was seen on June 27, 1975, with multiple discrete and grouped flat warts on the left thigh and knee and both legs. A plaque of flat warts was seen also on the chin. Most lesions had been present at least two years, but in the past month, many new lesions had suddenly appeared and, "in the last two weeks all the warts started to itch constantly." She had had a plantar wart removed surgically approximately ten years ago. Her brother had a wart at the age of 12 years and her mother had recently had a wart removed from her finger. A biopsy was done on a typical lesion, and she was given the 6% salicylic acid-propylene glycol gel as patient to rub into the warts. She returned 14 days later. All the warts had disappeared. Only scaling and a few excoriations on the legs were seen.

Case 3.—A 22-year-old woman had multiple discrete flat warts on the arms, thighs, and legs. Typical flat warts were present also on the left side of the forehead. She estimated that the lesions had been present approximately 1½ years.

She was given 6% salicylic acid-propylene glycol gel to rub into the warts. After approximately three months, the flat warts became erythematous, edematous, and were surrounded by halos of depigmentation. A biopsy was done on a lesion on the left leg. Five weeks later, all the flat warts had disappeared.

Histopathological Findings:

The basic pathologic process in all cases is identical. Mononuclear cells in the upper dermis infiltrate the epidermis and produce varying degrees of degeneration and necrosis within the epidermis (Fig 1).

There is hyperkeratosis, focal parakeratosis, focal crust formation, and acanthosis. The epidermis is infiltrated by inflammatory cells. Exocytosis may be focal so that collections of exocytotic mononuclear cells resemble a Pautrier abscess (Fig 2) or may be massive, producing epidermal necrosis. Degenerative changes include intracellular and intercellular edema,

Accepted for publication Jan 12, 1977.

From the Medical College of Wisconsin, Milwaukee (Dr Berman), and the Mayo Clinic, Rochester, Minn (Dr Winkelmann).

Reprint requests to 8430 W Capitol Dr, Milwaukee, WI 53222 (Dr Berman).

Fig 1—Mononuclear cell infiltration in upper dermis, exocytosis into epidermis, and spongiosis and degeneration within epidermis. Top, Patient 1; center, patient 2; and bottom, patient 3 (hematoxylin-eosin, original magnifications ×160 [top], ×240 [center], and ×160 [bottom]).

homogenization and necrosis of groups of epidermal cells, and focal areas where epidermal architecture is lost and only fragments of cells remain. Extravasated RBCs are seen in some necrotic areas. Individually hyalinized epithelial cells are seen at all levels in areas of epidermal injury.

The upper dermis is edematous, and the subpapillary and papillary vessels are dilated and are surrounded by accumulations of mononuclear cells.

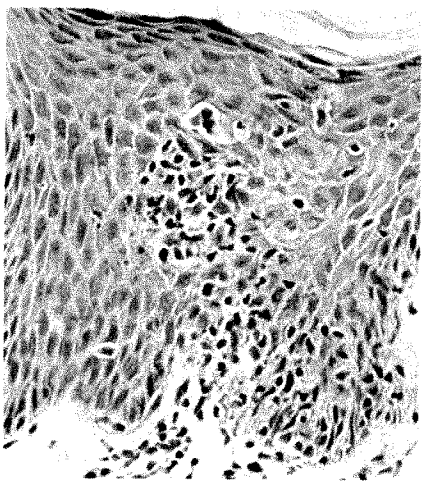

Fig 2.—Collection of exocytotic mononuclear cells and early degenerative changes in surrounding epidermis in patient 3 (hematoxylin-eosin, original magnification ×475).

These cells are remarkably uniform in size and appearance and are presumed to be lymphocytes. Larger mononuclear cells, presumably histiocytes, and plasma cells are occasionally seen. Focal areas of hemorrhage are seen around papillary blood vessels.

HISTOPATHOLOGICAL FINDINGS EARLY IN INVOLUTION

Two histologic specimen reports of flat warts were found in the files of the Mayo Clinic that showed a perivascular mononuclear cell infiltration in the upper dermis as well as characteristic histopathologic features of flat warts. The warts in these patients disappeared in a short period of time. We suspected that the mononuclear cell infiltration represented the early changes of involution.

To study the process of involution, patients with multiple flat warts were observed at regular intervals over long periods of time. Only 6% salicylic acid-propylene glycol gel was applied to the warts. We found that, occasionally, the onset of involutionary changes in the warts could be recognized clinically. When the onset of involution was suspected, lesions were excised for microscopic study, and the patients were then observed to establish whether the remaining warts would regress. In one patient studied in this manner (Fig 3), when the onset of involution was suspected by the development of an edematous appearance of the warts, five lesions were excised for microscopic study. Within one week, the warts were noted to be "getting smaller," and when she returned 25 days later, all

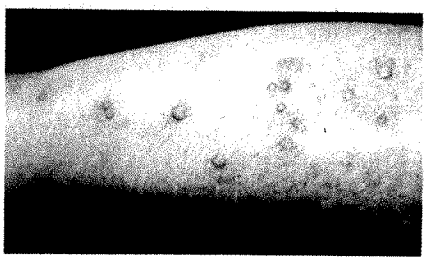

Fig 3.—Multiple flat warts on forearm. When onset of involution was suspected clinically, biopsies were done on five lesions.

Fig 4—Specimen 1. Histopathological findings early in involution. Mononuclear cell infiltration in papillary dermis; exocytosis and spongiosis in lower epidermis (hematoxylin-eosin, original magnification ×80).

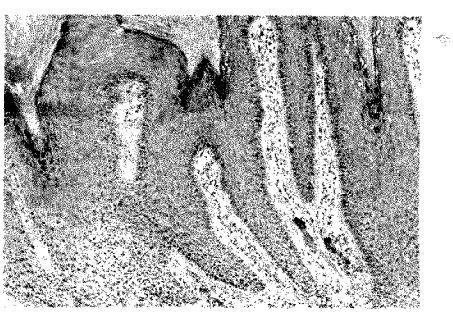

Fig 5.—Specimen 5. Mononuclear cell exocytosis and spongiosis in lower epidermis, best seen on left side. Note vacuolated virus-infected epithelial cells in granular and upper spinous layers (hematoxylin-eosin, original magnification ×80).

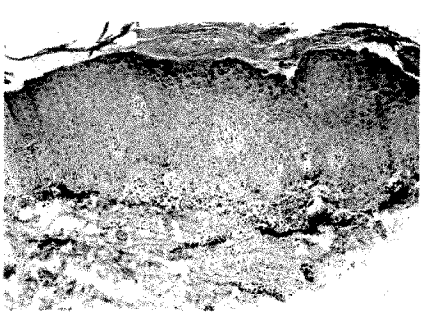

Fig 6.—Specimen 2. Intercellular edema separating epithelial cells and mild dermal mononuclear cell infiltration. This probably represents earliest changes of involution (hematoxylin-eosin, original magnification ×80)

Histologic Findings in Five Flat Warts Excised at the Time Onset of Involution Was Suspected*					
	Specimen 1	Specimen 2	Specimen 3	Specimen 4	Specimen 5
Dermal mononuclear cell infiltrate	+ +	+	o	o	+ +
Exocytosis of mononuclear cells into epidermis	+ +	+	o	o	+ +
Epidermal injury	+ +	+	o	o	+ +

*Three of the five specimens (60%) showed histologic changes sufficiently well-developed to permit recognition of stage of involution. Two specimens (40%) failed to show evidence of involution.

flat warts had disappeared.

Microscopic examination of the five specimens showed histopathologic changes characteristic of flat warts: acanthosis, basket-weave hyperkeratosis, thickening of the granular cell layer, and vacuolation of the epithelial cells in the upper spinous and granular cell layers.

Specimen 1 (Fig 4) shows early but well-developed mononuclear cell infiltration in the upper corium and focal exocytosis and spongiosis in the lower epidermis. Specimen 5 (Fig 5) shows a similar pattern of mononuclear cell infiltration and spongiosis in the lower epidermis. Specimen 2 (Fig 6) demonstrates probably the earliest changes of involution. A mild perivascular infiltration of mononuclear cells in the upper dermis, a few mononuclear cells within the epidermis, and prominent intercellular edema separating the epithelial cells is seen. Specimens 3 and 4 show only mononuclear cell cuffing around the subpapillary vessels; there is no exocytosis and no epidermal injury. Involution cannot be suspected in these specimens. Apparently, involutionary changes do not develop at the same rate in all lesions but proceed independently in individual warts (Table).

CLINICAL OBSERVATIONS ON INVOLUTING FLAT WARTS

Clinical findings that suggest the onset of involutionary changes in flat warts include the following:

1. Sudden onset of itching of the warts; two patients referred to "tenderness" of the lesions.

2. Development of erythema and edema at the base of the warts so that the lesions suddenly appear larger and more prominent than previously.

3. An effluorescence of tiny new warts preceded the disappearance of all warts by several weeks in three patients.

4. Instability of the lesions. The warts may appear more prominent at one visit and less at the next. In one patient, the surface of the warts became white and edematous shortly before regression occurred.

5. Regression of one or more of the warts is a late but dependable indicator that involution is in progress.

6. Depigmented halos marked the onset of involution in two patients. Though a number of patients have since been followed up through the period of involution and regression of their warts, depigmented halos have not been seen in any other cases.

The clinical features that suggest the onset of the process of involution need more precise delineation. Studies at an institution with a controlled population that would permit frequent observation during the critical period of involution might more precisely define the clinical characteristics of the period of involution.

COMMENT

Involution evolves over a period of several weeks: two weeks was the shortest period observed, ten weeks the longest. The histopathologic changes in the early phase are primarily in the upper dermis and consist of accumulations of mononuclear cells around the subpapillary blood vessels. Exocytosis and injury to the epidermis are minimal, and the typical histopathologic features of flat warts are present. As the process evolves, mononuclear cell infiltration of the epidermis increases, and epidermal injury becomes apparent. The earliest epidermal change appears to be intercellular edema separating the epithelial cells. In the later "epidermal" phase, exocytosis of mononuclear cells and epidermal degeneration and necrosis dominate the histopathological picture. At this stage, the usual histopathologic features of flat warts may not be present, and the lesion may not be recognizable histologically as a flat wart. Associated histopathologic findings at this stage include the following: edema in the upper dermis, dilation of the papillary and subpapillary blood vessels, focal hemorrhage in the dermal papillae, individually keratinized epithelial cells, focal parakeratosis, and focal crust formation.

The mononuclear cell-associated injury to the epidermis resembles that seen in delayed cutaneous hypersensitivity responses and suggests that regression of flat warts may be due to a cell-mediated rejection reaction.

The mononuclear cell infiltration can be utilized as a histologic "marker" of involution in physiologic studies of the process of involution of flat warts.

CONCLUSIONS

Involuting flat warts are characterized histopathologically by a perivascular infiltration of mononuclear cells in the upper dermis, exocytosis of mononuclear cells into the epidermis, and a spectrum of degenerative changes within the epidermis that result in focal areas of epidermal necrosis.

Involution evolves over a period of several weeks. The intensity of the mononuclear cell infiltration and the degree of degenerative epidermal changes will depend on the stage of development of the process at the time a biopsy is done. When mononuclear cell infiltration and epidermal degeneration are advanced, the lesions may not show the characteristic histopathologic features ordinarily seen in flat warts and, in fact, may not be recognizable histologically as flat warts.

Mononuclear cell infiltration of lesions in patients with multiple flat warts can be utilized as a histologic "marker" in physiologic studies of involution of flat warts.

The onset of involution of flat warts can occasionally be recognized on clinical grounds.

The mononuclear cell-associated injury to the epidermis resembles that seen in delayed cutaneous hypersensitivity responses and suggests that regression of flat warts may be due to a cell-mediated rejection reaction.

References

1. Tagami H, Ogino A, Takigawa M, et al: Regression of plane warts following spontaneous inflammation: An histopathological study. *Br J Dermatol* 90:147-154, 1974.

2. Samek J: Zum Wesen der suggestiven Warzenheilung. *Dermatol Wehnschr* 93:1853-1857, 1931.

3. Freudenthal W, Spitzer R: Warzen und Kondylome, in Jadassohn J (ed): *Handbook der Haut und Geschlectkr.* Berlin, Springer-Verlag, 1933, pp 33-207.

4. Minami S, Minami K: Histologic studies of verrucae planae juveniles. *Dermatol Urol* 21:390-399, 1959.

Solar Urticaria Treatment by Inducing Tolerance to Artificial Radiation and Natural Light

Colin A. Ramsay, MD, MRCP

• **Solar urticaria was treated by means of repeated exposures of the skin to fluorescent lamps or natural sunlight. Repeated exposures over a period of hours induce a state of tolerance in the skin so that urticaria fails to develop. The state of tolerance can be maintained with regular daily exposures, and treatment can lead to complete symptomatic relief. Determination of the action spectrum for urticaria is advisable in order to choose the correct fluorescent lamp for treatment.**

(*Arch Dermatol* 113:1222-1225, 1977)

Solar urticaria is an uncommon but distinctive photodermatosis, and its effect on the patient can vary from mild discomfort to a life-threatening situation should urticaria develop on large areas of skin, producing hypotension and loss of consciousness. In the great majority of patients with this disease the cause is unknown. However, erythropoietic protoporphyria should always be excluded as the sunlight-induced eruption may be urticarial in persons with this inborn error of porphyrin metabolism.[1]

The treatment of idiopathic solar urticaria is difficult and unsatisfactory, usually consisting of orally administered antihistamines and advising the patient to avoid sunshine. This article, however, presents a completely different approach to the therapy of this condition. It has been recognized for some years that in physical urticaria due to heat, cold, and solar radiation, repeated stimulation of the same skin site with the causative agent results in that area of skin becoming unresponsive to further exposures and that this lack of response may persist for hours or days.

Nine patients with solar urticaria have been treated by repeated exposure with natural sunlight or artificial ultraviolet or visible radiation, and this would seem to be a worthwhile method of treatment that can offer complete symptomatic relief. In order not to presuppose the mechanism, which is unknown, the term "induction of tolerance" will be used to describe the process.

PATIENTS AND METHODS

The patients are detailed in Table 1.

Systemic effects after exposure to sunlight had occurred in two men (patients 1 and 7), and the effects were potentially serious for both of them. The usual sequence of events was for the patient to undress on the beach and then walk toward the sea. Exposure of a large area of skin to sunlight produced massive urticaria with hypotension. This frequently occurred just as he entered the water. Both patients had been rescued from the sea semiconscious after such a reaction.

Action Spectra for Urticaria

In each patient the action spectrum was determined using a water-filled quartz prism monochromator with 2-kW xenon lamp as the radiation source.[2] Narrow wavebands were selected throughout the ultraviolet and visible spectra between 300 and 700 nm, and the back of the trunk, previously covered, was used as the test site. To minimize the effects of stray radiation from wavelengths below 320 nm, glass filters were used, Schott filters WG 345 at 340 and 360 nm and WG 360 at 380 to 700 nm. The transmission characteristics of these filters are detailed by Kobza et al.[3] The doses given at each wavelength are shown in Table 2. Multiple doses were given at wavelengths below 320 nm, and when urticaria developed at this part of the spectrum (all patients except patient 9), it was usually possible to determine the minimal urticarial dose (Table 3). At each wavelength between 340 and 700 nm, only single large doses were given, and attempts were not made to determine the minimal urticarial dose. There were several reasons for this decision. Our prime interest in this investigation was in determining the limits of the action spectrum, so that a suitable fluorescent lamp could be selected for treatment. We were especially anxious to avoid using lamps emitting in the range of 290 to 320 nm in treatment because of the problem of delayed erythema from this part of the spectrum. Thus information on whether or not patients reacted to long-wave ultraviolet radiation (320 to 400 nm) and/or visible light (400 to 700 nm) was needed to decide to use a lamp emitting in these parts of the spectrum. In addition there was usually insufficient time and not enough previously unexposed

Accepted for publication Jan 27, 1977.

From the Department of Photobiology, Institute of Dermatology, London.

Reprint requests to Toronto Western Hospital, 399 Bathurst St, Toronto, Ontario M5T 2S8 (Dr Ramsay).

Table 1.—Details of Patients and Action Spectra for Urticaria

Patient, Age (yr), Sex	Onset of Urticaria	Limits of Action Spectrum for Wealing, nm
1, 29, M	1970	300-400
2, 52, M	1961	300-400
3, 29, M	1960	300-400
4, 25, F	1972	300-400
5, 68, F	1969	300-600
6, 52, F	1970	307.5-600
7, 46, M	1958	300-700
8, 47, M	1973	300-700
9, 33, M	1967	380-500

skin on the back of the trunk to determine the minimal urticarial dose at each wavelength. In Table, 1, where the limits of the action spectra are given, the longest wavelength shown is that at which urticaria developed using the doses shown in Table 2. One patient (patient 9) developed urticaria only between 380 and 500 nm, again using doses in Table 2.

The action spectra in patients 5 through 8 were very broad, but the relatively narrow band pass of the monochromator[2] and the filters used ensured that these action spectra were real and were not the result of stray radiation.

Passive transfer experiments were not carried out.

Induction of Tolerance

When the limits of the action spectrum for urticaria had been determined in each patient, one of the following fluorescent lamps was used for further treatment:

20-W White.—This has a broad emission between approximately 400 and 600 nm. The continuum is maximal at 540 to 600 nm, and mercury vapor lines are superimposed on the continuum.

20-W "Blacklamp".—The emission is approximately 320 to 400 nm, with superimposed mercury vapor lines.

20-W Actinic.—This lamp is similar to the blacklamp, but the colored filter is absent. Thus, the emission also contains mercury vapor lines in the visible light spectrum.

20-W Blue.—The continuum is approximately 330 to 500 nm with superimposed mercury vapor lines.

It can be seen from Table 1 that in one patient (patient 9), urticaria developed only between 380 and 500 nm, and the blue fluorescent lamp was therefore used. In all other patients urticaria was induced by long-wave ultraviolet radiation, 320 to 400 nm, and in some (patients 5 through 8) also by visible light. Thus the majority of these patients (patients 1, 3, 4, 5, 6, and 8) were treated with the actinic lamp, the blacklamp being used in one patient (patient 2) and the white lamp in one (patient 7).

Exposure to the lamps was carried out at a distance from the skin that was fixed for each patient but varied among patients. The number of lamps used, their distance from the skin, and the exposure time for the development of urticaria are shown in Table 4.

It was not possible to measure absolute intensity of the lamps, and so the dose used cannot be given in absolute units. However, in any one person the number of lamps used and their distance from the skin was constant throughout the period of treatment, and the same exposure time can be assumed to deliver the same dose in that patient. The lamps were always alight for 20 minutes before exposures were given, and it is reasonable to assume that the intensity of the lamps would be constant with the short exposure times used. To avoid systemic effects, a small area of skin was chosen on which to start treatment, usually one arm. The skin was exposed to the fluorescent lamps for sufficient time for urticaria to develop (Table 4), and exposures at the same site were repeated at hourly intervals until urticaria no longer occurred. This state developed in all patients but one after two to five exposures. In one patient (patient 6), it was only possible to expose the skin at two- to three-hour intervals, and it took 16 hours for tolerance to develop. In all persons the area of skin that no longer reacted by wealing was then exposed to the same amount of radiation at increasingly longer intervals of time, namely 3, 6, and then 12 hours. As soon as tolerance was achieved in one area, it was maintained by exposures every 24 hours. Coincidentally, tolerance was induced in other areas of skin in exactly the same way so that after about one week, the whole skin was refractory and this state could be maintained by exposures every 12 or 24 hours. The refractory state persisted for 48 to 72 hours unless regular exposures at 24-hour intervals were maintained. Although these regular exposures were necessary to maintain tolerance, they did not induce urticaria once the skin was in a nonreactive state. Patients were advised to purchase the appropriate fluorescent lamp and continue the treatment at home.

RESULTS

All patients were followed up for up to two years to determine whether this form of treatment offered any practical advantage. Obviously, a patient must have a high degree of motivation for this treatment to be successful. One patient (patient 2) was unable to devote the necessary time to carry out the treatment at home, mainly because he worked irregular hours, and he must be regarded as a failure.

Table 2.—Doses Given at Different Wavelengths

Wavelength, nm	Dose Given, Joules/sq cm
300	Multiple doses between 5 and 900 millijoules/sq cm*
307.5	
320	
340	10
360	12.5
380	15
400	25
500	35
600	50
700	50

*The lowest dose given at each of these wavelengths was 5, 7.5, or 10 millijoules/sq cm.

Of the remaining eight patients, three (patients 1, 4, and 7) used the lamps regularly, the remainder found that they had to spend too much time on the treatment when only four or six lamps were available at home. Ideally, a box containing sufficient lamps to irradiate the whole body at the same time should be used, but cost limits implementation of such extensive treatment. Production of tolerance with artificial radiation effectively prevented urticaria from natural sunlight in two patients (patients 1 and 4). In another (patient 7), the protection was only partial in that when the skin failed to react to fluorescent light, he still developed some urticaria from natural sunlight. Patient 7 and the remaining five patients (3, 5, 6, 8, and 9) then turned to natural sunlight for the induction of tolerance, tailoring the treatment to their own particular needs. They usually found that the urticaria produced most trouble in the summer months or at the time of a sunny winter vacation, when they exposed large areas of skin not normally exposed. These patients would then spend the first day or two of the vacation inducing tolerance with the sun, in the same way that we had demonstrated to them with the fluorescent lamps. Thus, the remainder of the holiday could be enjoyed without problems. At times these patients were content if only part of their skin was refractory, such as the upper limbs, and they would use sunlight to induce tolerance only on these areas.

None of the nine patients described here underwent spontaneous remission during the period of observation. Even in those who maintained complete tolerance with fluorescent lamps, if treatment was stopped for 48 to 72 hours, the urticaria returned.

COMMENT

The management of patients with

Table 3.—Minimal Urticarial Doses at 300 to 320 nm

Patient	Minimal Urticarial Dose, Millijoules/sq cm		
	300 nm	307.5 nm	320 nm
1	<5*	<10	<10
2	<5	<7.5	<10
3	10	20	150
4	<5	<5	<5
5	300	230	250
6	>900†	150	150
7	150	400	400
8	200	150	400
9	>900	>900	>900

*Less than symbol indicates that this was the lowest dose given and that urticaria developed at this dose. The lowest dose given at each wavelength was 5, 7.5, or 10 millijoules/sq cm.
†Greater than symbol signifies that this was the highest dose given without urticaria developing.

Table 4.—Details of Fluorescent Lamps Used to Induce Urticaria

Patient	No. of Lamps Used	Distance From Skin, cm	Exposure Time for Urticaria, min
1	4	30	10
2	6	30	5
3	4	30	10
4	4	30	12
5	6	20	10
6	6	25	1
7	4	50	2
8	2	20	20
9	4	50	10

physical urticaria often presents problems. Treatment with repeated exposure to cold has been used in cold urticaria with varying degrees of success.[4,5] More recently one patient with severe cold urticaria[6] and another with localized heat urticaria[7] were treated by the induction of tolerance over the course of seven days with complete symptomatic relief.

The demonstration of tolerance in solar urticaria after repeated irradiation of the skin as described here is not original. It was observed by Duke in 1923[8] and has been reported on several occasions since that time.[9-11] My associates and I[12] quantitated this response in one patient at 300 nm. However, the induction of tolerance does not appear to have been used in any major way in the treatment of solar urticaria. In fact, Duke[8] stated that the tolerance gained in his patient was of no benefit. Rubin et al[9] reported one patient treated with orally administered antihistamines and repeated exposure with artificial ultraviolet radiation. Eventually the antihistamines could be discontinued, but tolerance to ultraviolet radiation could be maintained with daily exposures. These authors considered that pigmentation and/or thickening of the stratum corneum was responsible for the success of their treatment and that "densensitization" in the immunologic sense was not involved. Illig and Born[10] observed the phenomenon of what they termed "local desensitization" in two patients, but they did not apply the process in a therapeutic sense. The present report describes the use of repeated exposure to ultraviolet radiation and visible light as a form of treatment for solar urticaria in nine patients. The results varied from complete failure in one patient to partial success in six to complete success in two.

There is some evidence to support the view that at times solar urticaria is mediated by an immunologic mechanism. Harber et al[13] proposed a classification of the disease, dividing it into six types. There was evidence from passive transfer tests for an allergic mechanism in two of the types, the evidence being strong for one and less strong for the other. Sera from two patients with solar urticaria were studied by Sams[14]; in both patients there was a circulating serum factor that could be passively transferred and that behaved like a globulin although specific characterization was not possible. As Sams[14] pointed out, there are similarities and dissimilarities between IgE and the circulating factor in solar urticaria. In another type of physical urticaria—cold urticaria—it has recently been shown that a passively transferable serum factor was associated with IgE.[15] However, it should be stressed that in most persons with solar urticaria, no allergic mechanism can be demonstrated, and the cause is quite unknown.

Also unknown is the mechanism by which tolerance is induced in physical urticaria. One explanation is that specific IgE is blocked and cannot react with tissue cell receptors, thus leading to a failure of release of the mediators. No evidence exists to confirm or refute this hypothesis. True immunologic tolerance is unlikely to have occurred in these patients as the nonreactivity of the skin to the specific stimulus develops within a few hours. Another possibility is that repeated exposure produces degranulation of mast cells, so that the source of the mediators—whatever they may be—is exhausted.

Strong evidence to support this view in cold urticaria has recently been presented.[16] However, depletion of mast cells may not be the complete answer in all patients with physical urticaria in whom tolerance can be demonstrated. In one patient with localized heat urticaria,[7] an area of skin was injected at intervals with the histamine-liberator compound 48/80 until the last injection gave no response. This skin area then reacted with urticaria after exposure to heat. Conversely, in this patient an area of skin completely tolerant to heat reacted with a weal and flare to the injection of 48/80. Similar results have been obtained with ultraviolet radiation and 48/80 in patients with solar urticaria[11] (unpublished observations of the author). A patient with cold urticaria whose skin was refractory to cold reacted in a normal manner to the injection of 48/80.[6] It is possible, of course, that in these patients the cutaneous mast cells were not fully depleted by exposure to the physical agent causing the urticaria or by 48/80, and that further degranulation was produced by the other stimulus. On the other hand, there may be different receptors for the two processes.

A further possible explanation for the mechanism of action of induced tolerance is that true tachyphylaxis has occurred and that there is a lack of response of the end organ, the cutaneous blood vessels, to the mediator. Published reports do not enable any firm conclusions to be made on this point with solar urticaria, but in localized heat urticaria[7] and cold urticaria,[16] tachyphylaxis to histamine does not occur.

There are, of course, other methods of treatment of solar urticaria. If a patient reacts only to ultraviolet radiation below 320 nm, then conventional topical sunscreens might help. Many patients with solar urticaria, as in the group described here, react to long-wave ultraviolet radiation and to visible light, and topical sunscreens have limited benefit. Orally administered beta carotene was tried and failed.[17] Other systemically administered drugs have been used with apparent success, ie, chloroquine[11,18-20] and psoralen.[12] However, it is possible that in some cases the improvement that occurred while these drugs were being taken may have been due to coincidental tolerance induced by sunlight.

The results described in this article indicate that the induction of tolerance with artificial radiation or natural sunlight offers a useful treatment for solar urticaria. Highly motivated patients are able to use this form of treatment to keep themselves completely symptom-free. Others are able to maintain a level of tolerance that they themselves choose; eg, they can use the treatment just prior to a holiday in the sunshine. This variation in the degree of tolerance induced by an individual patient probably reflects the degree of interference with normal life produced by the disease. The induction of tolerance to natural sunlight probably explains the well-known clinical observation that patients with solar urticaria rarely develop problems on chronically exposed skin such as the hands and face.

References

1. Magnus IA, Jarrett A, Prankerd TAJ, et al: Erythropoietic protoporphyria: A new porphyria syndrome with solar urticaria due to protoporphyrinaemia. *Lancet* 11:448-451, 1961.
2. Magnus IA, Porter AD, McCree KJ, et al: A monochromator: An apparatus for the investigation of the responses of the skin to ultraviolet, visible and near infra-red radiation. *Br J Dermatol* 71:261-266, 1959.
3. Kobza A, Ramsay CA, Magnus IA: Photosensitivity due to the "sunburn" ultraviolet content of white fluorescent lamps. *Br J Dermatol* 89:351-359, 1973.
4. Horton BT, Brown GE, Roth GM: Hypersensitiveness to cold: With local and systemic manifestations of a histamine-like character: Its amenability to treatment. *JAMA* 107:1263-1269, 1936.
5. Blackman MS: Hypersensitivity to cold. *NY State J Med* 59:2614-2617, 1959.
6. Leigh IM, Ramsay CA, Calnan CD: Cold urticaria-"densensitization." *Trans St John's Hosp Dermatol Soc* 60:40-42, 1974.
7. Leigh IM, Ramsay CA: Localized heat urticaria treated by inducing tolerance to heat. *Br J Dermatol* 92:191-193, 1975.
8. Duke WW: Urticaria caused by light. *JAMA* 80:1835-1838, 1923.
9. Rubin L, Beal PL, Rothmans S: A method for protection of patients with solar urticaria. *J Invest Dermatol* 8:189, 1947.
10. Illig L, Born W: Untersuchungen zur Pathogenese der Lichturticaria. *Arch Klin Exp Dermatol* 220:19-37, 1964.
11. Sams WM, Epstein JH, Winkelmann RK: Solar urticaria: Investigation of pathogenetic mechanisms. *Arch Dermatol* 99:390-397, 1969.
12. Ramsay CA, Scrimenti RJ, Cripps DJ: Ultraviolet and visible action spectrum in a case of solar urticaria. *Arch Dermatol* 101:520-523, 1970.
13. Harber LC, Holloway RM, Wheatley VR, et al: Immunologic and biophysical studies in solar urticaria. *J Invest Dermatol* 41:439-443, 1963.
14. Sams WM: Solar urticaria: Studies of the active serum factor. *J Allergy* 45:295-301, 1970.
15. Houser DD, Arbesman CE, Ito K, et al: Cold urticaria: Immunologic studies. *Am J Med* 49:23-33, 1970.
16. Bentley-Philips CB, Black AK, Greaves MW: Induced tolerance in cold urticaria caused by cold-evoked histamine release. *Lancet* 2:63-66, 1976.
17. Kobza A, Ramsay CA, Magnus IA: Oral β-carotene therapy in actinic reticuloid and solar urticaria. *Br J Dermatol* 88:157-166, 1973.
18. Brunsting LA, Epstein JH: Solar urticaria. *Dermatologica* 115:171-180, 1957.
19. Epstein JH, Vandenberg JJ, Wright WL: Solar urticaria. *Arch Dermatol* 88:135-141, 1963.
20. Willis I, Epstein JH: Solar- vs heat-induced urticaria. *Arch Dermatol* 110:389-392, 1974.

CORRECTION

Missing Introductory Paragraphs.—In the article "Acne Fulminans," which appeared in the April issue of the ARCHIVES (113:444-449, 1977), the synopsis-abstract was printed twice rather than the following introductory paragraphs:

There are several severe forms of acne. An unusual acute variant with severe scarring was recognized recently. Burns and Colville[1] presented a case associated with an acute febrile reaction as "acne conglobata with septicemia (?)" in 1958. Windon (1961)[2] emphasized the combination of arthritis and severe acne in one patient as did Thyresson (1963)[3] and Moschella (1964).[4]

The most comprehensive report was published by Kelly and Burns (1971).[5] They reported three cases and described as distinctive features sudden onset with severe ulcerative lesions, fever and polyarthralgia, resistance to antibiotic therapy, and favorable response to debridement in combination with systemic therapy with corticosteroids. Ström et al[6] recently described two new cases of a similar syndrome. In addition, they reviewed 23 cases of acne conglobata admitted to the Karolinska Sjukhuset between 1962 and 1971 and found five case reports of patients with similar symptoms. The authors confirmed the findings of Kelly and Burns, with the exception of polyarthralgia, which was not present in all their patients. They stressed the importance of elevated leukocyte counts and proposed the term "acute febrile ulcerative conglobate acne with leukemoid reaction."

Atopic Dermatitis and Tuberculin Reactivity

Masami Uehara, MD

• **Transient suppression of already established tuberculin reactivity by a widespread, allergic contact dermatitis as well as by primary irritant contact dermatitis has been recently reported. Similar transient suppression of tuberculin reactivity by the eczematous inflammation of atopic dermatitis is now shown to occur. Thus, when the dermatitis is active, atopic dermatitis patients show diminished tuberculin reactivity. While they are in remission, however, a significant increase of their tuberculin reactivity occurs. Before the onset of dermatitis, their tuberculin reactivity was normal. Healed patients showed normal tuberculin reactivity. The presence of dermatitis may play an important role in the diminished cell-mediated immunity in atopic dermatitis.**

(*Arch Dermatol* 113:1226-1228, 1977)

Patients with atopic dermatitis often show diminished cell-mediated immune skin reactivity to fungal, bacterial, viral, and inorganic substances.[1-5] From a review of the literature, however, it was not clear whether the hyporeactivity is primary or whether it is secondary to whatever is causing the dermatitis.

It is known that transient impairment of cell-mediated immunity is seen in individuals with various, infectious as well as non-infectious, inflammatory processes.[6-8] Recently, Ofuji and I have shown that a widespread, allergic contact dermatitis as well as primary irritant contact dermatitis temporarily suppresses already established cell-mediated immunity in experimental animals.[9] The present study was undertaken to explore the possibility that similar temporal suppression of cell-mediated immunity might occur in patients with atopic dermatitis.

SUBJECTS AND METHODS

Patient Selection

Seventy-four patients with atopic dermatitis, ranging in age from 14 to 43 years, were the source of this study. The diagnosis was established on the basis of morphologic characteristics and distribution of skin lesions and a positive family history of respiratory atopy or eczema. All patients, on the initial visit to our clinic, had lichenified patches that involved the antecubital and popliteal fossae and other predisposed areas. Thus, according to the degree of skin involvement, they belonged to the moderately affected group (localization of the disease at four anatomical regions or more, but not generalized involvement). They were then treated for a period of two to ten years. The treatment consisted of topical application of corticosteroids and orally administered antihistamines. Internal use of corticosteroids was avoided. Clinical controls included ten adult patients with allergic contact dermatitis. Severity and extent of the dermatitis of these patients matched grossly those observed in the atopic patients. They also received topical corticosteroid and oral antihistamine therapy. Normal controls consisted of 60 adults without evidence of inflammatory skin disease.

Skin Tests

Each subject was injected intradermally with 0.1 ml of a tuberculin solution (0.5 μg of purified protein derivative per milliliter). The test solution was freshly prepared each time. The test site was normal-appearing skin on the flexor surface of the forearm. The reaction was interpreted at 48 hours. The grading was registered as positive if the diameter of the induration was 10 mm or more.

To see if the eczematous inflammation in patients with atopic dermatitis and in those with allergic contact dermatitis influenced already established tuberculin reactivity, serial examinations of their tuberculin reactivity were performed.

Patients With Atopic Dermatitis.—Thirty-two patients were tested during the exacerbation of the dermatitis and while they were in remission for a period of three weeks or more. Reexamination of tuberculin reactivity was done in 17 patients who had been almost completely free from the dermatitis for a period of one to four

Accepted for publication Jan 4, 1977.

From the Department of Dermatology, Faculty of Medicine, Kyoto (Japan) University.

Reprint requests to Department of Dermatology, Faculty of Medicine, Kyoto University, Kyoto, Japan (Dr Uehara).

years. Tuberculin reactivity before the onset of dermatitis was obtained by questioning 50 patients who had begun having the dermatitis after the age of 12 years. (In Japan, tuberculin reactivity of all school children, 6 to 12 years old, is determined and recorded by a society of health and physical education; tuberculin-negative children are inoculated with BCG vaccine.)

Patients With Allergic Contact Dermatitis.—All ten patients were tested when the dermatitis was active and during a period of two to four weeks after the subsidence of the dermatitis.

RESULTS

Patients With Atopic Dermatitis

The scattergram (Figure) demonstrates the values of tuberculin reactions found at the time of exacerbation and remission of the dermatitis in 32 atopic patients. When they had exacerbating dermatitis, the mean value of their tuberculin reactions was 3.88 ± 4.50 mm SD. If tested during a period of remission, however, the mean tuberculin reaction strength was 10.56 ± 9.24 SD. Thus, a significant increase of tuberculin reactivity occurred during the remission of the dermatitis ($P < .01$).

Fourteen of the 17 (82%) "healed" atopic patients showed a positive tuberculin reaction (the mean value was 15.00 ± 7.79 mm SD) (Table). Fifty-two of 60 (87%) normal controls were tuberculin positive (the mean value was 16.23 ± 8.12 mm SD). The tuberculin reactivity of healed atopic patients was not different from that of normal controls.

Forty-three of the 50 (86%) atopic patients who had begun having the dermatitis after the age of 12 years were found to have been tuberculin positive before the onset of dermatitis (Table). This incidence of positive reactions before the onset of dermatitis also was not different from that of normal controls.

Patients With Allergic Contact Dermatitis

Two of the ten patients showed a positive tuberculin reaction when the dermatitis was active (the mean value was 6.41 ± 4.22 mm SD). Nine of the ten patients, however, were tuberculin positive at the time of reexamination after the subsidence of the dermatitis (the mean value was 15.80 ± 2.86 mm SD). Thus, allergic contact dermatitis brought about a significant suppression of tuberculin reactivity ($P < .01$).

COMMENT

The present study demonstrated that tuberculin reactivity in patients with atopic dermatitis fluctuated with the condition of the dermatitis. When there was exacerbating dermatitis, these patients exhibited diminished skin reactivity to tuberculin. If tested during a period of remission of the dermatitis, however, they showed a significant increase of tuberculin reactivity. "Healed" atopic dermatitis patients showed normal tuberculin reactivity. In those patients who had begun having the dermatitis after the age of 12 years, the incidence of positive tuberculin reactions before the onset of the dermatitis was not different from that in normal subjects. These findings suggest that, in the evaluation of cell-mediated immunity of patients with atopic dermatitis, it is necessary to investigate them not only at the time when the dermatitis is active, but also while they are in remission or free from the dermatitis.

The present study also demon-

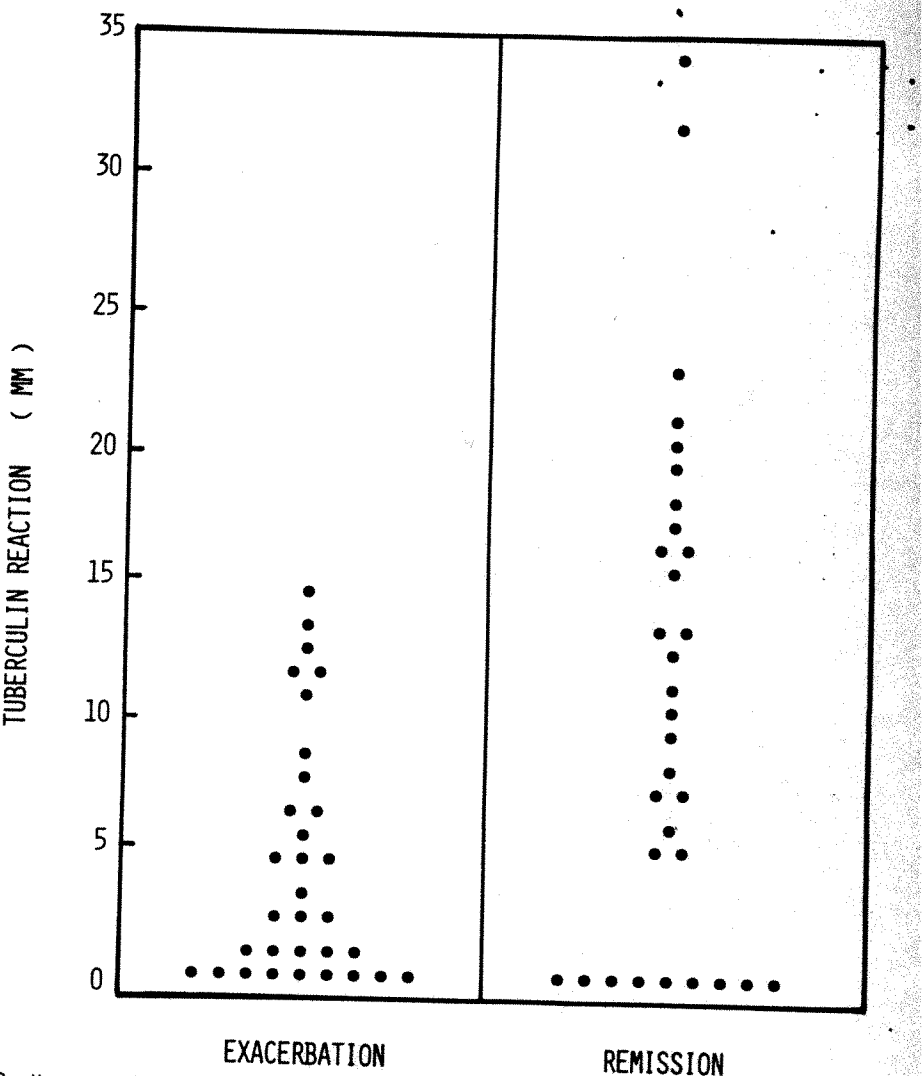

Scattergram showing values of tuberculin reactions at the time of exacerbation and remission of atopic dermatitis (32 subjects).

Comparison of Tuberculin Reactions With Course of Atopic Dermatitis

Time of Test	No. of Cases	Tuberculin Reactions		% of Positive Reactions
		Positive	Negative	
Before onset of dermatitis	50	43	7	86
At exacerbation	74	16	58	21
After healing of dermatitis	17	14	3	82

strated that transient suppression of tuberculin reactivity by eczematous inflammation occurred in patients with allergic contact dermatitis. Thus, it can be concluded that an eczematous inflammation of different cause suppresses already established tuberculin reactivity.

The mechanisms by which an eczematous inflammation leads to impaired tuberculin reactivity remain speculative. Inhibitory serum factors might be responsible for the diminished cell-mediated immunity in eczematous patients. Experimental animals sensitized with a contact allergen show increases in α-globulins that have immunosuppressive properties.[10] Macrophages of antigen-treated animals produce a low-molecular-weight substance that depresses the lymphocyte responses to phytohemagglutinin (PHA).[11,12] These serum factors may affect humans as well. Atopic serum with high IgE levels inhibits T-cell rosette formation of normal lymphocytes.[13] The IgE also decreases the lymphocyte proliferation with oxymercurisalicylic acid sodium (a T-cell mitogen).[14] Therefore, the IgE associated immunosuppression may play some role in the diminished cell-mediated immunity in patients with atopic dermatitis.

Several reports indicate that a subpopulation of immune lymphocytes (T lymphoblasts and their descendants) move nonspecifically to sites of eczematous inflammation.[15,16] It is therefore possible that a widespread eczematous lesion attracts a large number of immune cells in the circulating blood, so that these subjects fail to respond normally to skin test with tuberculin. All of these, as well as other possibilities require further study.

Lymphocytes from patients with atopic dermatitis are often less responsive to PHA compared with healthy subjects.[5,17] These patients show normal PHA reactivity, however, if tested during a period of remission of the dermatitis.[5,18] A recent report suggests that the leukocyte function defects in atopic dermatitis patients may normalize rapidly during remission of the dermatitis.[19]

On the basis of these data, it seems reasonable to consider that the presence of eczematous inflammation plays an important role in the diminished, in vivo and in vitro, cell-mediated immune reactivity in patients with atopic dermatitis.

References

1. Rajka G: Studies in hypersensitivity to molds and staphylococci in prurigo Besnier (atopic dermatitis). *Acta Derm Venereol* 43(suppl 54):1-139, 1963.
2. Gudjonsson H, Lodin A, Modee J: Besnier's prurigo in children. *Acta Derm Venereol* 46:159-166, 1966.
3. Rajka G: Delayed reactivity to bacterial and viral extract(s) in different dermatoses. *Acta Derm Venereol* 50:281-286, 1970.
4. Jones HE, Lewis CW, McMarlin SL: Allergic contact sensitivity in atopic dermatitis. *Arch Dermatol* 107:217-222, 1973.
5. Lobitz WC, Honeyman JF, Winkler NW: Suppressed cell-mediated immunity in two adults with atopic dermatitis. *Br J Dermatol* 86:317-328, 1972.
6. Hall CB, Kantor FS: Depression of established delayed hypersensitivity by mumps virus. *J Immunol* 108:81-85, 1972.
7. Heiss LI, Palmer DL: Anergy in patients with leukocytosis. *Am J Med* 56:323-353, 1974.
8. Grossman J, Baum J, Gluckman J, et al: The effect of aging and acute illness on delayed hypersensitivity. *J Allergy Clin Immunol* 55:268-275, 1975.
9. Uehara M, Ofuji S: Suppressed cell-mediated immunity associated with eczematous inflammation. *Acta Derm Venereol* 57:137-139, 1977.
10. Burger DR, Lilley DP, Vetto RM: Lymphocyte suppression associated with alpha globulin: Changes in cellular immunity. *Cell Immunol* 10:432-441, 1974.
11. Nelson DS: Production by stimulated macrophages of factors depressing lymphocyte transformation. *Nature* 246:306-307, 1973.
12. Calderon J, Unanue ER: Two biological activities regulating cell proliferation found in cultures of peritoneal exudate cells. *Nature* 253:359-361, 1975.
13. Hanifin JM, Gottlieb BR: IgE inhibits T-cell rosette formation. *Clin Res* 22:328A, 1974.
14. Schöpf E, Böhringer D: Zell-vermittelte Immunität bei Neurodermitis atopica. *Hautarzt* 25:420-426, 1974.
15. Asherson GL, Allwood GG, Mayhew B: Contact sensitivity in the mouse: XI. Movement of T blasts in the draining lymph nodes to sites of inflammation. *Immunology* 25:485-494, 1973.
16. Allwood GG: The migratory behavior of T blasts to contact sensitivity reaction in actively and passively sensitized mice. *Immunology* 28:681-692, 1975.
17. Fjelde A, Kopeczka B: Cell transformation and mitogenic effects in blood leucocyte cultures of atopic dermatitis patients. *Acta Derm Venereol* 47:168-176, 1967.
18. Cislo M. Woyton A: Das Verhalten des Lymphozyten-transformationstests bei Exacerbationen und Remissionen des endogenen Ekzems (Dermatitis atopica). *Dermatol Monatsschr* 161:108-112, 1975.
19. Rogge JL, Hanifin JM: Immunodeficiencies in severe atopic dermatitis: Depressed chemotaxis and lymphocyte transformation. *Arch Dermatol* 112:1391-1396, 1976.

Beta Carotene Therapy for Erythropoietic Protoporphyria and Other Photosensitivity Diseases

Micheline M. Mathews-Roth, MD; Madhu A. Pathak, MB, PhD; T. B. Fitzpatrick, MD, PhD; Leonard H. Harber, MD; Edward H. Kass, MD, PhD

• We treated with high doses of oral beta carotene (Solatene) (15 to 180 mg/day) 133 patients suffering from erythropoietic protoporphyria (EPP), 27 patients with polymorphous light eruption, six patients with solar urticaria, three patients with hydroa aestivale, one patient with porphyria cutanea tarda, and two patients with actinic reticuloid to relieve the photosensitivity associated with these diseases. Eighty-four percent of the patients with erythropoietic protoporphyria increased by a factor of 3 or more their ability to tolerate sunlight. On the other hand, only nine of the patients with polymorphous light eruption, and one fifth of the patients with all of the other forms of photosensitivity treated showed similar improvement.

We conclude that beta carotene is an effective treatment for EPP, but that other forms of photosensitivity will need empirical therapeutic study with beta carotene to determine the range of effectiveness, if any, of this compound in conditions other than EPP.

(Arch Dermatol **113:1229-1232, 1977**

In 1970 we reported that oral administration of beta carotene (Solatene) to three patients with erythropoietic protoporphyria (EPP) resulted in the amelioration of the photosensitivity associated with this disease.[1] In 1974, in collaboration with 16 other physicians, we reported the treatment of 50 additional patients.[2] Since that time, an additional 80 patients with EPP have been treated by us and our collaborating physicians. In addition, 39 patients with other forms of photosensitivity have been treated with high doses of beta carotene. We report herewith our data on the efficacy of beta carotene in the treatment of EPP, the lesser effectiveness of this treatment in other forms of photosensitivity, and the continued absence of evidence of toxic effects as a result of this treatment.

MATERIALS AND METHODS

Patients

The diagnostic criteria used for EPP in this study were those used previously.[2] All patients had elevated levels of protoporphyrin in blood and stool. Porphyria cutanea tarda (PCT) was defined as described by Tschudy et al,[3] including the presence of abnormal amounts of uroporphyrin and coproporphyrin in the urine. Polymorphous light eruption (PMLE), solar urticaria, and hydroa aestivale were diagnosed according to the criteria established by Pathak and Epstein.[4] Actinic reticuloid was diagnosed according to the criteria established by Ive et al.[5] The majority of the patients with these four conditions were accepted into the study because they had not obtained satisfactory photoprotection with the use of antimalarials, or the use of sunscreens had been unsatisfactory or, in the case of opaque sunscreens, cosmetically unacceptable. Porphyria was ruled out in all these patients by the finding of normal amounts of porphyrins in blood, urine, and stool.

A total of 133 patients had EPP (48 men, 36 women, 29 boys, 20 girls); 27 had PMLE (eight men, 13 women, three boys, and three girls); six patients had solar urticaria (five women and one girl); three patients had hydroa aestivale (one 7-year-old boy and two girls, 9 and 13 years old); one man had PCT, and two men had actinic reticuloid.

The patients with PMLE were classified according to lesion type as follows: 19 vesiculopapular, five erythema-edema, one eczematous, and two plaque-type. One of the six patients with solar urticaria was phototested, and was found to be sensitive to long-wavelength ultraviolet light. One of the five not phototested reported sensitivity to light through window glass. The patients with hydroa aestivale were not phototested, but all reported sensitivity to light through window glass.

Efficacy of Beta Carotene Treatment

To determine the efficacy of the beta carotene therapy, all patients visited the physician and answered detailed questionnaires.[2] All patients in all disease categories were studied two or three times over a two- to eight-week period before the beginning of therapy, to assess the variation in the patients' sensitivity to light, and at six-

Accepted for publication Jan 17, 1977.

From the Channing Laboratory and Department of Medicine, Harvard Medical School, and the Department of Medical Microbiology, Boston City Hospital (Drs Mathews-Roth and Kass), and the Photobiology Unit, Dermatology Service, Massachusetts General Hospital, and the Department of Dermatology, Harvard Medical School (Drs Pathak and Fitzpatrick), Boston, and the Department of Dermatology, College of Physicians and Surgeons, Columbia University, New York (Dr Harber).

Reprint requests to the Channing Laboratory, 180 Longwood Ave, Boston, MA 02115 (Dr Mathews-Roth).

Table 1.—Formulas Used to Calculate Protection Index (PI) Time Patient Tolerates Sun Exposure

Case	Before Treatment	During Treatment	Appropriate Formula
1	a^*	b^*	$PI = b/a$
2	$a_1 - a_2$†	b	$PI = e^u$ where $u = \left[\int_{x=a_1}^{a_2} \ln (b/x)\, dx\right] \Big/ \left[a_2 - a_1\right]$
3	a	$b_1 - b_2$†	$PI = e^u$ where $u = \left[\int_{y=b_1}^{b_2} \ln (y/a) dy\right] \Big/ \left[b_2 - b_1\right]$
4	$a_1 - a_2$	$b_1 - b_2$	$PI = e^u$ where $u = \left[\int_{y=b_1}^{b_2}\int_{x=a_1}^{a_2} \ln (y/x) dy dx\right] \Big/ \left[(a_2 - a_1)(b_2 - b_1)\right]$

*Time of symptom-free sun exposure stated by patient.
†Range of time of symptom-free sun exposure stated by patient.

Table 2.—Effect of Beta Carotene on Tolerance to Sunlight of Patients With EPP

Protection Index*	No. of Patients: This Report	No. of Patients: Previous Report[2]	No. of Patients: Total
1†	9	1	**10**
2†	9	3	**12**
3-5	15	12	**27**
6-10	20	19	**39**
11-15	7	8	**15**
16-20	2	4	**6**
> 21	18	6	**24**
Total	80	53	**133**

*Protection index is defined in the text in Materials and Methods.
†Patients showed little or no improvement despite blood carotene levels of at least 400 mg/100 ml after intake of highest dose appropriate for their ages.

to eight-week intervals during the course of therapy to assess the effect of beta carotene on the patients' tolerance to sunlight. The actual number of follow-up examinations of each patient depended on the length of time the patient was in the study. No patient had fewer than two visits, spread over a minimum of a two-month period. Fewer than 20% of the patients with EPP were seen only two times, and these were patients who did not respond to therapy or who were in the study for only six months. Eight of the patients with PMLE and half of the patients with the other photosensitivity disorders had only two visits; the remainder had three or more such visits. Similarly, 103 of the patients with EPP, 11 of the 27 patients with PMLE, and two of the 12 patients with the other forms of photosensitivity were in the study for two or more summers.

The present data from the questionnaires concern tolerance to exposure to light, and from these data we have calculated for each patient a protection index. This index is defined as the number of minutes of summer sunlight tolerated *without the development of symptoms* after therapy, divided by the number of minutes of summer sunlight tolerated without the development of symptoms before therapy. The criteria used as endpoints were itching and burning in the case of EPP and the development of characteristic skin lesions in the case of the other diseases. When patients reported a range of exposure that produced symptoms or signs of photosensitivity (the severity of photosensitivity may vary from time to time), the protection index for such patients was calculated, using appropriate statistical formulas to take these variations into account (Table 1). A protection index of 1 indicates those patients who said that beta carotene was of no benefit. To minimize the effect of small graded responses, we have considered that a protection index of less than 3 would not be held to represent appreciable improvement.

Administration of Beta Carotene

All patients underwent physical examination and a series of laboratory tests at each of their visits before and during treatment, as described previously.[2] Patients received beta carotene orally in starting doses ranging from 15 to 180 mg/day (children under 8 years, 15 to 90 mg/day; 8 to 12 years, 120 to 150 mg/day; 13 to 16 years, 150 to 180 mg/day; 16 years and above, 180 mg/day). They were instructed to increase their exposure to sunlight cautiously and gradually and to report immediately any untoward reactions (severe burning, swelling, desquamation, crusting, profuse eruptions, etc) that might occur. Dosage of the beta carotene was increased until the patient noted an amelioration of photosensitivity.[2] The serum carotene level was maintained above 400 μg/100 ml in 91% of patients. At the time therapy was begun, patients in all disease categories had few or no active skin lesions. In most cases, therapy was begun in spring or early summer before the patients experienced episodes of photosensitivity. When therapy was begun later, the patients had been avoiding exposure to sunlight.

Chemical Determinations

The hematologic and chemical analyses of blood, stool, and urine were performed as described previously.[2]

RESULTS

Table 2 shows the degree of tolerance to sunlight exposure that was achieved by the patients with EPP, as reported in the questionnaires. Eighty-four percent of the patients increased by a factor of 3 or more their stated ability to tolerate sunlight without the development of symptoms. When symptoms did develop, over three fourths of the patients reported that they were milder and of shorter duration than before treatment.

In 95% of the adult patients, the dosages of beta carotene used were those listed above. In 5% of the adults, the dose was increased to 240 mg/day before the patient experienced appreciable relief. A few children between 12 and 16 years old had to take the average adult dose (180 mg/day) to obtain relief. Those patients who did not respond to beta carotene therapy had all taken the medication for two to three months at the highest dose appropriate for their ages and had attained blood levels of beta carotene of at least 400 μg/100 ml.

Nine of the patients with PMLE and two of the patients with the other light-sensitive disorders increased their ability to tolerate exposure to sunlight by more than a factor of 3 (Table 3). Only two patients with PMLE reported marked improvement in their photosensitivity with the use of beta carotene alone. Seven patients with PMLE reported marked improvement with the use of a nonopaque topical sunscreen containing aminobenzoic acid (PreSun, Pabanol) or sulisobenzone (Uval) along with the oral beta carotene. The remaining 18 reported no improvement with the use of both oral beta carotene and the topical sunscreen. None of the 27 patients with PMLE had received any relief from the use of nonopaque sunscreens alone. One patient with solar urticaria and one patient with hydroa aestivale reported notable relief. Both stated that they obtained improvement without the use of a topical sunscreen.

In those patients who did not respond to beta carotene, therapy had been given for at least two months at the highest dose appropriate for the patient's age and blood carotene levels above 400 μg/100 ml had been attained. Of these patients who did obtain relief, two adults had to take more than 180 mg/day of beta carotene to obtain good results.

As in previous studies,[2,6-9] beta caro-

Table 3.—Effect of Beta Carotene on Tolerance to Sunlight of 39 Patients With Photosensitivity Other Than EPP

Diagnosis	Protection Index*						
	1	2	3-5	6-10	11-15	16-20	> 21
	No. of Patients						
PMLE	12	6	5†‡	2§‖	1§	0	1†‖
Solar urticaria	5	0	1‖#	0	0	0	0
Hydroa aestivale	1	1	0	0	0	0	1§
PCT	1	0	0	0	0	0	0
Actinic reticuloid	2	0	0	0	0	0	0

*Protection index is defined in Materials and Methods. Patients with protection indices of 1 and 2 showed little or no improvement despite blood carotene levels of at least 400 mg/100 ml following intake of highest dose of beta-carotene appropriate for their ages.

†One patient reporting a protection index of 4 and one patient reporting a protection index of 24 stated that they did not need to use a topical sunscreen in conjunction with beta-carotene ingestion. All other PMLE patients needed both beta-carotene and topical sunscreen to achieve the stated protection.

‡Three patients were in the study for one summer, two patients for two summers.

§One summer in study.

‖2 summers in study.

¶Seven-year-old boy.

#Forty-year-old woman.

tene was well tolerated by all of the patients; no untoward side effects were noted other than a report by one patient who complained of an episode of loose stools, which cleared spontaneously and did not necessitate stopping treatment. The vast majority of the patients were not bothered by the carotenodermia, which developed after about four to six weeks of therapy. The hematologic and chemical determinations done while the patients were receiving beta carotene did not differ markedly from the values obtained before treatment. In the case of the EPP patients, blood and stool levels of porphyrin fluctuated, but in all cases remained above normal.

COMMENT

Two general groups of patients were treated with beta carotene: those with EPP and those with other forms of photosensitivity. In the 133 patients with EPP who reported on their tolerance to sunlight, 53 had taken beta carotene for three to five years (previously reported[2]), and the remaining 80 from six months to three years.

The data on tolerance to exposure to sunlight presented in Table 2, and also in Table 2 of our previous report,[2] are compiled from each patient's answers to the question in the standard questionnaire regarding the number of minutes (or hours) the patient could stay in the sun before symptoms developed. As mentioned above, the questionnaires were given before the start of therapy and repeated at six- to eight-week intervals after the serum level of beta carotene had reached 400 μg/100 ml. Patients were considered therapeutic failures who gave no evidence of relief to symptoms after at least two months, during which time the serum level of beta carotene was greater than 400 μg/100 ml.

Beta carotene increases the amount of time that the patient can spend in the sunlight and remain symptom-free (Table 2). It is a common experience for untreated patients to spend considerable time in the sun despite the development of unpleasant symptoms. Thus, after treatment, such patients may not actually increase the time they spend in the sun, but with treatment, they often report increases in the time spent in the sun while they remain symptom-free. The latter fact makes it necessary, in evaluating the efficacy of treatment of photosensitivity, to ask the patient, before and during treatment, about the amount of time in the sun that leads to symptoms. Otherwise, the determination of time spent in the sun may be misleading and may underestimate the effect of treatment on the appearance of symptoms. In the case of beta carotene, it is important to begin assessment of benefit only after blood levels over 400 μg/100 ml and carotenemia have developed; little or no improvement is likely to occur before attainment of such levels.

In our previous report,[2] the subjective responses of the patients were confirmed by phototesting with xenon arc light those patients treated in Boston and New York. Although the data we obtained did not allow the establishment of a linear relation between tolerance to a given amount of exposure to artificial light and tolerance to a given amount of exposure to sunlight, we found that all of the patients tested who reported increased tolerance to sunlight also demonstrated some increase to tolerance to xenon arc light. Phototesting was not routinely used during the last two years of the study reported here because of the increased number of patients. However, the testing of occasional patients confirmed the validity of the earlier observations that patients are able to verify improvement by response to standardized questionnaires. Our results have now been confirmed by several different groups of investigators.[6-9]

Two reports have been published concerning the use of beta carotene in the treatment of PMLE. Wennersten and Swanbeck treated eight patients with PMLE, and found improvements in the minimal erythema dose (tested with an appropriately filtered xenon arc lamp) of all the patients after treatment.[10] Jansen treated 66 patients, 55 of whom improved, as judged by patients' questionnaires and physicians' examinations.[11] In spite of high levels of serum beta carotene, only a third of the patients with PMLE studied by us obtained relief (Table 3). Jansen divided his patients into various clinical subtypes according to the morphologic appearance of the disease and suggested that there might be some difference in the reactions to beta carotene treatment of the various types. We have found no obvious relation between a given subtype of PMLE and likelihood of improvement after treatment with beta carotene, but our numbers are small, and larger patient numbers will be needed to elucidate a biologic basis for differences in responses of patients to the treatment.

Thune[12] administered beta carotene to 17 patients with PMLE and found "a significant increase in MED for unfiltered (xenon) light at the 5% level of probability." However, only five of the 17 patients had a protection index of more than 3 with respect to sunlight exposure, a much lower rate than the above two authors and more in line with our findings. He also could not show a direct correlation between the protection index obtained for artificial light and that obtained for sunlight exposure, as we had been unable to do for EPP.[2] He also found, as we have, that some patients benefited from the combined therapy of oral beta carotene and a topical sunscreen (5% para-aminobenzoic acid).

Porphyria cutanea tarda is success-

fully treated by phlebotomy,[13] but this treatment was contraindicated in our patient. Although acute phototoxic reactions similar to those noted in EPP are not usually seen, the cutaneous changes noted in PCT are due to porphyrin-induced photoinjury. Thus we decided to administer beta carotene in the hope of decreasing the frequency of appearance of new lesions. Examination of the patient's skin and the patient's own report after two months of beta carotene therapy showed no appreciable decrease in the number of new lesions formed. Urinary porphyrin levels and the patient's exposure to skin trauma had not changed considerably over the treatment period. Wiskemann has reported some success in the treatment of PCT with beta carotene.[14]

Our poor results with solar urticaria, hydroa aestivale, and actinic reticuloid confirm those of Kobza et al.[15]

Evaluation of therapeutic success is difficult in photosensitivity disorders in which the photosensitizer is unknown. For example, spontaneous remissions are known to occur in solar urticaria, and improvement during the course of the summer in the absence of therapy may take place in PMLE. There is the possibility that such spontaneous improvement may have occurred in some of the patients with PMLE, solar urticaria, or hydroa aestivale who stated that they improved with beta carotene therapy. The only way that the possibility of spontaneous improvement can be eliminated is to conduct a larger, controlled clinical trial, lasting more than two years. It is also possible that, in some patients, we did not give beta carotene treatment an extensive enough trial; a longer, larger trial would be needed to eliminate this possibility. In the case of the patients with EPP, the facts that make the finding of therapeutic success with beta carotene more secure are (1) porphyrin levels did not markedly decrease, (2) the majority of patients were observed for more than two years, and (3) phototesting with xenon arc light correlated qualitatively with the patients' reports of improvement.

The effectiveness of beta carotene in the amelioration in patients with EPP of photosensitivity reactions caused by long-wave ultraviolet and visible light has a scientific rationale. Excitation of protoporphyrin molecules (present either in the plasma or in the extracellular fluid that bathes the epithelial cells) by ultraviolet light can result in photo-oxidative reactions deleterious to skin cells, presumably through the formation of singlet oxygen or free radicals. Beta carotene has been shown to quench such photo-oxidative reactions.[16,17] It should be understood, however, that other types of cutaneous photosensitivity reactions (eg, the vesiculopapular eruptions, the plaque type, and the eczematous eruptions in PMLE) may not have the same cause as in EPP, and since the chromophore responsible for abnormal reactions other than in EPP is not known, the mechanism responsible for the induction of abnormal responses other than in EPP may not have the same molecular basis. Thus, beta carotene may not act as an effective blocker for the biochemical reactions that lead to the clinical symptoms in these other forms of photosensitivity. Indeed, some of the reactions in PMLE appear to have an allergic nature.[4] It should be realized, therefore, that oral beta carotene may not be an effective "sunscreen" for forms of photosensitivity disorders other than EPP. Each form of photosensitivity, both to ultraviolet and to visible light, will need empirical testing to determine the range of effectiveness of beta carotene in light-induced dermatoses.

The results we report here confirm and extend our previous findings that beta carotene therapy is usually effective in the treatment of the photosensitivity associated with EPP. At present it would appear that beta carotene may be useful in some conditions other than EPP along with a topical sunscreen, and that the use of beta carotene should be limited to those conditions (other than EPP) in which other treatments have been unsuccessful or contraindicated. In EPP, beta carotene alone seems to be an effective treatment.

This investigation was supported by research grants AM 14545-06 from the National Institute of Arthritis and Metabolic Diseases; CA 05003-17 from the National Cancer Institute; ES 00288-12 from the National Institute of Environmental Health Sciences; and HD 03693-08 from the National Institute of Child Health and Development. Hoffmann-La Roche supplied the β-carotene preparation (Solatene).

In addition to the physicians previously listed,[3] the following also collaborated in this study: Robert Amon, MD, Sylvia Bottomly, MD, Daniel Bovenmeyer, MD, James Crispen, MD, Farrington Daniels, Jr, MD, Vincent DeLeo, MD, Paul Dermer, MD, Arthur Eisen, MD, Richard Ferrington, MD, Ruth Freinkel, MD, William Gentry, MD, Raymond Goldblum, MD, Lowell Goldsmith, MD, Robert Goltz, MD, Frederick Grabo, MD, Kenneth Greer, MD, Robert Haining, MD, James Herndon, MD, E. M. Hudgkins, MD, Michael Jarratt, MD, Edward Krull, MD, Beatrice Kuhn, MD, Sonia Lindo, MD, David Lockman, MD, William McCauley, MD, W. Tabb Moore, MD, Allan Moshell, MD, B. Voss Neal, MD, James Nordlund, MD, Arthur Norins, MD, Earl Rubell, MD, W. Mitchell Sams, Jr, MD, Oran Shannon, MD, Robert Stanchfield, MD, Ronald Stanley, MD, Maria Turner, MD, James Taylor, MD, Richard Torrey, MD, Hugh Tyson, MD, and Irving Wolman, MD.

Bernard Rosner and Robert Roth helped with the statistical analysis of the data.

References

1. Mathews-Roth MM, Pathak MA, Fitzpatrick TB, et al: Beta-carotene as a protective agent in erythropoietic protoporphyria. *N Engl J Med* 282:1231-1234, 1970.

2. Mathews-Roth MM, Pathak MA, Fitzpatrick TB, et al: Beta-carotene as an oral photoprotective agent in erythropoietic protoporphyria. *JAMA* 228:1004-1008, 1974.

3. Tschudy DP, Magnus IA, Kalivas J: The porphyrias, in Fitzpatrick TB (ed): *Dermatology in General Medicine*. New York, McGraw-Hill Book Co Inc, 1971, pp 1143-1166.

4. Pathak MA, Epstein JH: Normal and abnormal reactions of man to light, in Fitzpatrick TB (ed): *Dermatology in General Medicine*. New York, McGraw-Hill Book Co Inc, 1971, pp 977-1036.

5. Ive FA, Magnus IA, Warin RP, et al: Actinic reticuloid: A chronic dermatosis associated with severe photosensitivity and the histological resemblance to lymphoma. *Br J Dermatol* 81:469-485, 1969.

6. Hopsu-Havu VK, Terho PE, Hollmen T: Erythropoietic protoporphyria: The first case in Finland. *Ann Clin Res* 5:181-185, 1973.

7. Krook G, Haeger-Aronson B: Erythropoietic protoporphyria and its treatment with beta-carotene. *Acta Dermatovenereol* 54:39-44, 1974.

8. Gschnait F, Wolff K: Die erythropoetische Protoporphyrie. *Hautarzt* 25:72-80, 1974.

9. Moynahan EJ, Leppard B: Erythropoietic protoporphyria. *Proc R Soc Med* 66:1085-1086, 1973.

10. Wennersten G, Swanbeck G: Treatment of light sensitivity with carotenoids. *Acta Dermatovenereol* 54:491-499, 1974.

11. Jansen CT: Beta-carotene treatment of polymorphous light eruption. *Dermatologica* 149:363-373, 1974.

12. Thune P: Chronic polymorphic light eruption: Particular wavebands and the effect of carotene therapy. *Acta Dermatovenereol* 56:127-133, 1976.

13. Ippen H: Allgemeinsymptome der späten Hautporphyrie (Porphyria cutanea tarda) als Hinweise fur deren Behandlung. *Dtsch Med Wochenschr* 86:127-133, 1961.

14. Wiskemann A: Topical and systemic photoprotection against porphyrias, in Pathak MA, Harber LC, Seiji M, et al (eds): *Sunlight and Man*. Tokyo, University of Tokyo Press, 1974, p 669.

15. Kobza A, Ramsay CA, Magnus IA: Oral beta-carotene therapy in actinic reticuloid and solar urticaria. *Br J Dermatol* 88:157-166, 1973.

16. Foote CS, Denny RW: Chemistry of singlet oxygen: VII. Quenching by beta-carotene. *J Am Chem Soc* 90:6233-6235, 1966.

17. Mathews-Roth MM, Wilson T, Fujimori E, et al: Carotenoid chromophore length and protection against photosensitization. *Photochem Photobiol* 19:217-222, 1974.

Clotrimazole vs Haloprogin Treatment of Tinea Cruris

Maj Jules V. VanDersarl, MC, USAF, Sgt Robert H. Sheppard

• A study to compare the efficacy of clotrimazole 1% solution with that of haloprogin 1% solution for the treatment of tinea cruris was conducted among military personnel on active duty in a hot, humid climate. Eighty patients with documented dermatophyte infections were treated with the topical antifungal agents. Analysis of the response to treatment for 14 days demonstrated that clotrimazole was significantly more effective clinically and mycologically than haloprogin. With no further treatment, significantly more patients treated with clotrimazole remained free of the disease four weeks later.

(*Arch Dermatol* 113:1233-1235, 1977)

Clotrimazole is an antimycotic agent effective against yeast and fungi.[1-6] To elucidate the potency of clotrimazole's antifungal capabilities in vivo, a double-blind study was designed to compare the therapeutic efficacy of clotrimazole 1% solution with that of haloprogin 1% solution, a widely used antifungal preparation. The study was conducted during the hot, humid, summer months on the Gulf Coast of Mississippi, and the population studied was limited to military personnel on active duty who had tinea cruris. The availability of large numbers of patients afflicted with dermatophytosis of the groin offered an excellent opportunity to compare the efficacy of these two antifungal agents.

SUBJECTS AND METHODS

Young men on active duty with the US Air Force who complained of a pruritic groin rash were examined by a dermatologist for clinical evidence of tinea cruris. The degree of erythema, edema, maceration, fissuring, and scale was rated by the dermatologist according to severity on a numerical scale of 1 indicating none; 2, mild; 3, moderate; and 4, severe. To verify the presence of fungi, scrapings from the areas of skin involved were examined microscopically after preparation of potassium hydroxide (KOH) mounts and were cultured on dermatophyte test medium (DTM).

Patients were accepted as study subjects who had clinical evidence of tinea cruris and a dermatophyte infection confirmed by the presence of fungal hyphae in the KOH mount and by the growth of a dermatophyte in culture, and who had not received any topical or systemic anti-infective or anti-inflammatory treatment for at least two weeks before the initial visit. Eighty men, who volunteered after the nature of the investigation had been fully explained, were admitted to the study.

The two test preparations, clotrimazole 1% solution and haloprogin 1% solution, were assigned to the patients by a third party at random according to a predetermined code. The medications were packaged in identical containers that were numbered consecutively, but labelled identically otherwise.

The patients were instructed to apply the medication with their fingertips twice a day for 14 days to the areas involved. No other topical or systemic anti-infective or anti-inflammatory agents were to be used during the 14-day study period. No specific instructions were given regarding dress or personal hygiene. A medical corpsman dispensed the coded test preparations to each volunteer, determined how much medication was used by each patient, and collected all unused medication at the end of the 14-day treatment period.

After the initial visit, the patients returned for examination at the end of one and two weeks of treatment. A follow-up examination was scheduled for four weeks after treatment ended. At each return visit, scrapings were taken from the treated areas and examined for the presence of fungi by microscopic examination of KOH mounts and by culturing on DTM. The mycologic response for each return visit was considered negative if no

Accepted for publication Jan 5, 1977.

From the Department of Medicine, Division of Dermatology, USAF Medical Center, Keesler AFB, Miss. Maj VanDersarl is now with the Department of Medicine, Division of Dermatology, USAF Hospital, Torrejon Air Force Base, Madrid.

Reprint requests to PSC Box 1681, APO New York 09283 (Maj VanDersarl).

fungal hyphae were seen in the KOH mount and the culture was negative for dermatophyte growth after two weeks. If either of these was positive, the mycologic response at that visit was considered positive. The clinical response was determined by the objective signs of disease and the patients' subjective evaluation of the therapy, both of which were recorded numerically according to severity and averaged for each treatment group at each follow-up period.

To evaluate the overall therapeutic efficacy of each drug at the two-week visit and at the follow-up visit, the clinical and mycologic responses were combined. Patients who had a clinical cure (ie, no signs or symptoms of dermatophytosis) and a mycologic cure (ie, negative KOH mount and negative culture) were considered to have an "excellent" response. Those who were mycologically cured but only improved clinically were considered to have a "good" response. A category of "fair" was assigned to patients who showed some clinical improvement but were mycologically positive. Those who did not respond clinically or mycologically were termed "no response."

Unless otherwise indicated, the Fisher's exact test was used for the statistical analysis.

RESULTS

The 80 men admitted to the study constituted two treatment groups which were compatible in that there were no statistically significant differences in age, race, weight, and total duration or severity of the disease when the study began.

Adverse Effects

All 80 patients who entered the trial were evaluated for tolerance to the medication. Side effects consisting of burning (12 patients), stinging (one patient), and complaints of an unpleasant odor (two patients) were reported by 15 of the 40 patients (37%) treated with haloprogin, whereas none was reported by the 40 patients treated with clotrimazole. Although the side effects were not severe enough in any patient to warrant discontinuation of treatment, the lack of side effects in the clotrimazole group was highly significant ($P < .001$).

Therapeutic Efficacy

Although 80 patients entered the study, 14 were eventually omitted because of noncompliance with the protocol. Of the 66 from whom data were used for evaluation of therapeutic efficacy, 34 were treated with clotrimazole and 32 with haloprogin.

Mycologic Response.—After two weeks of treatment, the mycologic evaluation was negative (ie, conver-

Table 1.—Mycologic Response

		At End of Two-Week Treatment Period		Four Weeks After End of Treatment		
	N	Cure	Failure	Cure	Failure	No Follow-up
Clotrimazole	34	29 (85%)	5	17 (57%)	13	4
Haloprogin	32	20 (62%) ($P = .049$)	12	9 (31%) ($P = .067$)	20	3

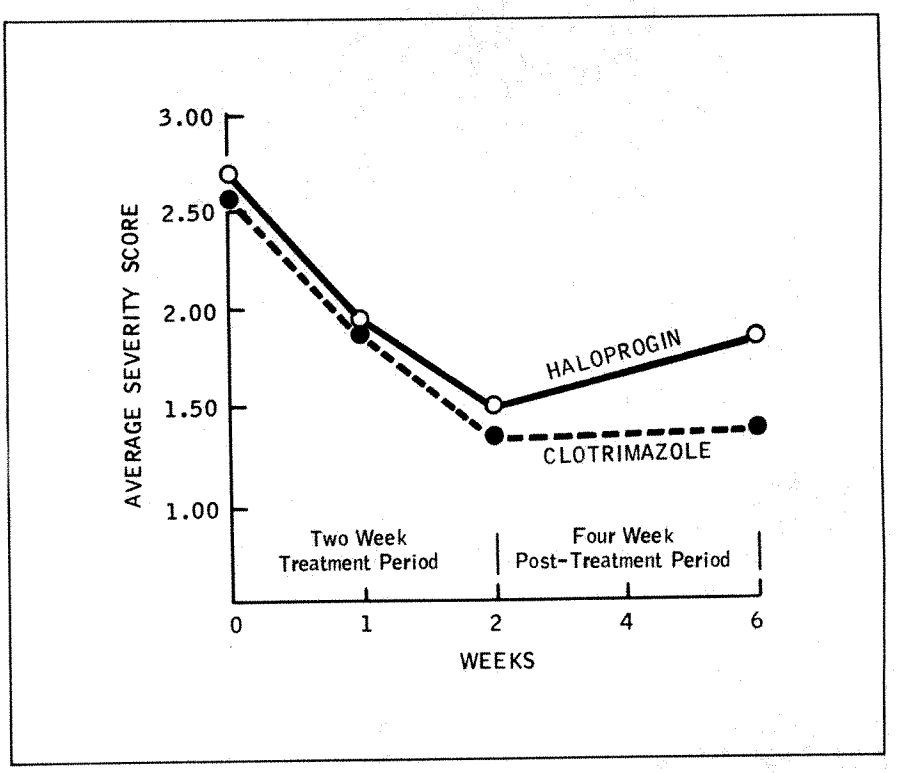

Average severity of clinical signs and symptoms of tinea cruris during and after treatment.

Table 2.—Clinical Response

		At End of Two-Week Treatment Period			Four Weeks After End of Treatment			
	N	Cured	Improved	No Change	Cured	Improved	No Change	No Follow-up
Clotrimazole	34	22 (65%)	12	0	19 (63%)	8	3	4
Haloprogin	32	18 (56%) ($P > .05$)	12	2	10 (34%) ($P = .02$)	11	8	3

Table 3.—Overall Therapeutic Response

		At End of Two-Week Treatment Period				At Four-Week Follow-up Visit			
	N	Excellent	Good	Fair	No Response	Excellent	Good	Fair	No Response
Clotrimazole	34	20 (59%)	9	5	0	16 (53%)	1	10	3
Haloprogin	32	13 (41%) ($P = .05$)	7	10	2	7 (24%) ($P = .018$)	2	12	8

sion to negative KOH mount and negative culture), and the fungal infection was considered cured in 85% (29 of 34 patients) of the group treated with clotrimazole and in 62% (20 of 32 patients) of the haloprogin-treated group (Table 1). Analysis of the mycologic response demonstrated that clotrimazole was significantly more effective ($P = .049$) than haloprogin.

Four weeks after treatment ended, mycologic evaluation was negative in 57% (17 of 30 patients) of the group treated with clotrimazole and in 31% (nine of 29 patients) of the haloprogin group. The mycologic effectiveness of clotrimazole remained greater ($P = .067$) than that of haloprogin.

The dermatophytes isolated from the 66 patients before treatment were *Trichophyton rubrum* (in 24 subjects), *T mentagrophytes* (in ten), and *Epidermophyton floccosum* (in 32). After two weeks of treatment, *T rubrum* was no longer present in 83% (ten of 12) of the infections treated with clotrimazole and in 75% (nine of 12) of those treated with haloprogin. The infection with *T mentagrophytes* was eliminated in three of four patients treated with clotrimazole and in three of six treated with haloprogin. The mycologic evaluation became negative in 88% (16 of 18) of the infections with *E floccosum* treated with clotrimazole and in 75% (eight of 14) of those treated with haloprogin.

Clinical Response.—The clinical signs and symptoms of disease were recorded numerically according to severity, and average values were calculated for each treatment group at each follow-up period. As shown in the graph (Figure), the curves of the average severity scores indicated that the rate and degree of clinical improvement were similar in each treatment group until treatment stopped. At that time, clinical evidence of dermatophytosis began to recur rapidly in the group treated with haloprogin. By four weeks after treatment ended, the average score for severity of clinical signs and symptoms was greater in the haloprogin-treated group than in the group treated with clotrimazole; this difference was shown by the Wilcoxon two-sample test on ranked data to be statistically significant ($P = .036$).

Although there was no statistically significant difference between the two groups in the number of patients clinically cured at the end of the two-week treatment period, 65% (22 of 34) of those treated with clotrimazole had no clinical signs of dermatophytosis, compared with 56% (18 of 32) of those treated with haloprogin (Table 2). Four weeks later, however, 63% (19 of 30) treated with clotrimazole remained free of the disease, whereas only 34% (ten of 29) treated with haloprogin had no clinical signs of the disease. The numerical superiority of the clotrimazole group was statistically significant ($P = .02$).

Combined Therapeutic Assessment.—Analysis of the overall therapeutic response, as determined from the combination of clinical and mycologic data, demonstrated that clotrimazole was more effective than haloprogin at the end of the two-week treatment period ($P = .05$) and at the follow-up visit four weeks later ($P = .018$). In the group treated with clotrimazole, 59% (20 of 34) of the patients were cured after two weeks of therapy, whereas 41% (13 of 32) of those treated with haloprogin were cured (Table 3). Four weeks after treatment ended, the difference between the groups in overall therapeutic response was even greater. Only 24% (seven of 29) of the patients treated with haloprogin were cured, but 53% (16 of 30) of those treated with clotrimazole had no clinical or mycologic evidence of dermatophytosis.

COMMENT

The search continues for topical antifungal agents that are more effective yet clinically acceptable. The large number of patients treated for tinea cruris at Keesler Air Force Base during the past two years who failed to respond to treatment, or who improved initially only to have the disease recur as soon as treatment stopped, prompted us to study a new topical antifungal preparation in the hope that better remission rates might be obtained. We chose to compare its effectiveness with an antifungal agent frequently prescribed by physicians in the Gulf Coast area.

A 14-day treatment period was chosen because patients with fungal disease desire a rapid response to treatment and a prolonged cure without having to use medication any longer than necessary. Perhaps more "cures" would have been effected had the treatment been continued for a longer time; however, 14 days was long enough to compare the therapeutic efficacy of the two drugs.

Clotrimazole was not only effective, but it was significantly more effective than haloprogin in both the clinical and mycologic phases of the study. In addition, clotrimazole was preferred by the patients because it had fewer side effects.

The statistical analysis was designed and interpreted by C.M. Ordille, PhD, Delbay Pharmaceuticals, Inc, Bloomfield, NJ.

Sgt Marguerite Davis provided technical assistance.

The test materials were provided by Paul Spiekermann, MD, and Roy Battye, MD, of Delbay Pharmaceuticals, Inc.

Nonproprietary Names and Trademarks of Drugs

Clotrimazole—*Lotrimin.*
Haloprogin—*Halotex.*

References

1. Fredriksson T: Topical treatment with BAY b 5097, a new broad spectrum antimycotic agent. *Br J Dermatol* 86:628-630, 1972.

2. Smith EB, David LM, Knox JM: Topical clotrimazole in dermatophytosis in a prison environment. *Postgrad Med J* 50(suppl 1):64-65, 1974.

3. Plempel M, Buchel KH, Bartmann K, et al: Antimycotic properties of clotrimazole. *Postgrad Med J* 50(suppl 1):11-12, 1974.

4. Holt RJ, Newman RL: Laboratory assessment of the antimycotic drug clotrimazole. *J Clin Pathol* 25:1089-1097, 1972.

5. Gip L: Topical treatment with clotrimazole in dermatomycosis. *Curr Ther Res* 16:27-31, 1974.

6. Spiekermann PH, Young MD: Clinical evaluation of clotrimazole. *Arch Dermatol* 112:350-352, 1976.

Immunosuppressants and Prednisone in Pemphigus Vulgaris

Therapeutic Results Obtained in 63 Patients Between 1961 and 1975

Walter F. Lever, MD, Gundula Schaumburg-Lever, MD

• **Evaluation of the treatment in 63 patients with pemphigus vulgaris showed that six patients (9.5%) died of the consequences of high-dosage prednisone treatment, while 24 patients (38.1%) were free of lesions and not receiving treatment. Immunosuppressants (methotrexate, cyclophosphamide, and azathioprine) are of value in patients with severe pemphigus vulgaris since they often reduce the maintenance dose of prednisone required after high-dosage prednisone treatment. Immunosuppressants are of even greater value in patients in the early, stable stage of pemphigus vulgaris. Of 16 such patients initially treated with a combination of an immunosuppressant and maintenance doses of prednisone not exceeding 40 mg on alternate days, 13 at no time required treatment with higher doses of prednisone. The good results obtained with this method emphasize the importance of diagnosing and treating pemphigus vulgaris in its early stage.**

(*Arch Dermatol* 113:1236-1241, 1977)

In the report from the Tufts Department of Dermatology on the treatment of pemphigus vulgaris published in 1972,[1] the role of methotrexate as a therapeutic agent was discussed. Since then two other immunosuppressants, cyclophosphamide and azathioprine, have been studied.

The purpose of the present article is (1) to record the effect of treatment on the course of pemphigus vulgaris in all 63 patients first seen between 1961 and September 1975; (2) to assess the value of the immunosuppressants in the treatment; and (3) to point out the advantage of the availability of more than one immunosuppressant.

In the previous report[1] we expressed the belief that prednisone given in maintenance doses enhanced the effectiveness of methotrexate in pemphigus vulgaris. This was confirmed in the present study, particularly in regard to the treatment of pemphigus vulgaris in its early, stable stage in which the combined use of alternate-day maintenance doses of prednisone with an immunosuppressant appears to be the treatment of choice. This treatment can be carried out usually without the need for large doses of prednisone, making the therapy of pemphigus vulgaris much safer than it was when large doses of prednisone were administered routinely.[2]

PATIENTS AND METHODS

Patients

In 63 patients with pemphigus vulgaris who were first seen between 1961 and September 1975 the diagnosis was established by multiple biopsy specimens showing suprabasal acantholysis. Furthermore, the titer for antiepithelial antibodies in the serum was determined in all patients (except in patient 7, whose death preceded the use of this test) and was positive at least once at a dilution of 1:20 or higher.

The 63 patients had the following ethnic origin: 31 were Jewish, 12 Italian, five Irish, three Anglo-Saxon, three Arab, and three French. Furthermore, one patient each was Greek, Hungarian, Iranian, Negro, Scandinavian, and South American. The age of the patients at the onset of their disease varied from 20 to 79 years, and the average was 51 years. Thirty-two were women, and 31 men.

The 63 patients comprise patients 1 through 36 who were reported in the previous paper[1] with the same numbers, and patients 37 through 63 who have been seen since. For the purpose of the present report the patients were divided into five groups.

Group A comprises patients 1 through 12 in whom treatment was started routinely with daily doses of prednisone that usually were large (at least 120 mg) and rarely were intermediate (40 to 80 mg). The patients were subsequently given daily maintenance doses of prednisone and never received immunosuppressants.

Group B comprises patients 13 through 27 who, like the patients of group A, were routinely started on usually large doses of prednisone but subsequently received methotrexate in addition to maintenance doses of prednisone.

Group C comprises patients 28 through 33 and 35 through 38 with early, stable disease who initially were treated with only an immunosuppressant.

Group D comprises patients 34 and 39 through 53 with early stable disease in whom treatment was begun with the combined treatment combining alternate-day maintenance doses of prednisone not exceeding 40 mg per dose with an immunosuppressant.

Group E comprises patients 54 through 63 with advancing or advanced pemphigus vulgaris in whom treatment was begun with large daily doses of prednisone.

Accepted for publication Feb 16, 1977.

From the Department of Dermatology, Tufts University School of Medicine and New England Medical Center, Boston.

Reprint requests to 280 Washington St, Brighton, MA 02135 (Dr Lever).

Monitoring the Immunosuppressants

A great advantage of treatment with immunosuppressants is that, in contrast with high-dosage administration of prednisone, serious side reactions are generally preventable by monitoring the treatment with blood cell counts, differential counts, platelet counts, and, in the case of methotrexate, liver function tests. Methotrexate frequently causes an elevation of the transaminases, SGPT and SGOT. It therefore can be given only to patients with normal liver function tests (SGOT, SGPT, alkaline phosphatase, and lactic dehydrogenase). Bone marrow depression, however, is induced rarely by methotrexate in the doses used. In general, liver function tests and blood cell, differential, and platelet counts were carried out every month initially, and, if the values remained normal, every two months later on. No liver biopsies were performed.

In contrast with methotrexate, cyclophosphamide and azathioprine in the doses used frequently cause a slight lowering of the WBC and occasionally a fairly pronounced lowering of either the total WBC or of the lymphocyte count, neutrophil count, RBC or platelet count. Usually, blood cell, differential, and platelet counts were carried out at first every two weeks, and later, if the values remained normal, once a month. Whenever the WBC count fell to values between 3,500 and 3,000/cu mm, the dose of cyclophosphamide or azathioprine was decreased, and when the values fell to below 3,000/cu mm, the drug was discontinued, at least temporarily.

RESULTS OF TREATMENT

Overall Results

The status of the 63 patients with pemphigus vulgaris first seen between 1961 and September 1975 was evaluated on Sept 1, 1976. Thus, all patients had been under observation for at least one year. Of the 36 patients who were included in the previous report,[1] none has been lost in the follow-up. On Sept 1, 1976, the status of the 63 patients was as follows: Six patients (9.5%) had died of the consequences of high-dosage prednisone treatment (see Causes of Death); five patients (7.9%) had died of causes unrelated to their disease or its treatment (see Causes of Death); 17 patients (27%) had a few lesions and were receiving treatment, one of them only with an immunosuppressant; 11 patients (17.5%) were free of lesions but were still being treated, three of them only with an immunosuppressant; and 24 patients (38.1%) were free of lesions and not receiving treatment.

Group A Results

Of patients 1 through 12 listed in the Table of the previous paper,[1] as of Sept 1, 1976, three (patients 7, 8, and 9) had died of the consequences of high-dosage prednisone treatment (see Causes of Death); patients 1 and 3 had died of unrelated causes (see Causes of Death); patient 4 had a few cutaneous lesions and was receiving treatment; and patients (2, 5, 6, 10, 11, and 12) were free of lesions and had received no treatment for periods of from 2 to 14 years, on the average for seven years.

Group B Results

Of patients 13 through 27 listed in the Table of the previous paper,[1] none had died of the consequences of high-dosage prednisone treatment; three (patients 13, 18, and 19) had died of unrelated causes (see Causes of Death); seven (patients 15, 20, 21, 22, 24, 25, and 26) had a few lesions and were receiving treatment; patient 27 had no lesions but was still receiving treatment; and four patients (14, 16, 17, and 23) were free of lesions and had received no treatment from two to eight years, an average of five years.

Group C Results

Of patients 28 through 33 and 35 through 38 (Figure), nine were treated initially with methotrexate alone and one patient (patient 38) with cyclophosphamide as the only drug. It soon became apparent, however, that even in patients with early, stable pemphigus vulgaris, treatment with only an immunosuppressant often was not effective; even in patients in whom it was effective, it was rather slow in taking effect. Immunosuppressant treatment alone, was abandoned, therefore, in favor of the combined treatment. Still, it is notable that four of the ten patients (patients 29, 30, 36, and 38) who initially were treated with only an immunosuppressant never had to be given any corticosteroids. They showed no worsening at any time, and even though improvement was slow, they ultimately cleared and treatment was discontinued. Patient 29 later on had a mild recurrence that responded to immunosuppressant therapy. These four patients have been without treatment for from four months to five years, on the average for two years.

The remaining six of the ten patients who had been started on immunosuppressants alone had flare-ups of their disease requiring high-dosage prednisone in patients 28, 31, 32, 33, and 37 and the addition of maintenance doses of prednisone in patient 35. Of the six patients requiring prednisone treatment, as of Sept 1, 1976, patient 28 had died of the consequences of high-dosage prednisone therapy (see Causes of Death); patients 32 and 35 had a few lesions and were receiving treatment; patients 31 and 33 had no lesions but were still being treated; and patient 37 had no lesions and had received no treatment for one year.

Group D Results

This group consisted of patients 34 and 39 through 53 in the early, stable stage of their disease. Only patient 34 described in the previous paper,[1] had received the combined treatment, but soon thereafter it became apparent that adding small doses of prednisone, initially 40 mg on alternate days, to the immunosuppressant was superior to the treatment with only an immunosuppressant. Whereas of the ten patients initially treated only with an immunosuppressant, five (50%) had a flare-up requiring high-dosage prednisone, only three of the 16 patients (18.7%) started on the combined treatment had a flare-up requiring high-dosage prednisone. Of these three patients, patient 41 required two high-dosage courses, and patients 44 and 50 required one high-dosage course. The other 13 patients at no time required prednisone doses exceeding 40 mg on alternate days. The state of the 16 patients on Sept 1, 1976, was as follows: Five patients (patients 34, 41, 43, 50, and 53) had a few lesions and were being treated; six patients (patients 40, 42, 44, 47, 48, and 52) had no lesions but were still receiving treatment; and five patients (patients 39, 45, 46, 49, and 51) were free of lesions and had been without treatment from three months to four years, for an average of one year. In the 11 patients who were still receiving treatment it consisted of maintenance doses of prednisone and methotrexate in four patients; of maintenance doses of prednisone and cyclophosphamide in four patients; of maintenance doses of prednisone only in two patients; and of cyclophosphamide only in one patient. Hospitalization was required by only patient 41 once for a week. This was for the purpose of studying her hyperglycemia.

Group E Results

Patients 54 through 63 were initially treated with large doses of prednisone because their pemphigus vulgaris was advancing or advanced. After their initial course of high-dosage prednisone, they were treated with alternate-day maintenance doses

RESULTS OF TREATMENT

Case	Treatment Period	Degree of Involvement: Start of Therapy	Degree of Involvement: Worst	Present (or time of death)	Period of Lesions during Rx	Type of Treatment	Present Treatment (or at time of death) mg	High-Dos. Prednisone: No. of Courses	High-Dos. Prednisone: No. of Weeks	High-Dos. Prednisone: Highest mg/day	Cause of Death
Group C: Initial Treatment with Only an Immunosuppressant											
28	3/68-5/72	+	++++°	(+++°)	3/68-5/72	M;M+mP;hP	(hP:400)	4	9	400	Staph. sepsis
29	2/69-7/71	+°	+°	–	2/69-9/70	M	–	–	–	–	
	12/73-12/74	+•	+•	–	12/73-5/74	M;Cyc	–	–	–	–	
30	4/69-12/71	+°	+°	–	4/69-4/71	M	–	–	–	–	
31	10/69-pres.	++•	++•	–	10/69-10/75	M;hP;mP+M	mP+M:10+5	1	2	180	
32	10/69-pres.	+°	+++°	+•	10/69-pres.	M;hP;mP+M	mP+M:30+30	1	8	240	
33	3/70-pres.	++°	++°	–	3/70-11/75	M;hP;mP+M	M:10	2	8	240	
35	12/70-pres.	+•	+°	+°	12/70-pres.	M;mP+M;mP+Cyc;mP+Aza;mP	mP:10	–	–	–	
36	12/70-5/76	+•	+•	–	12/70-12/75	M;Cyc	–	–	–	–	
37	5/71-7/76	+•	++°	–	5/71-9/75	M;hP;mP+M;M	–	1	4	180	
38	12/72-3/76	+°	+°	–	12/72-8/75	Cyc;M;Aza	–	–	–	–	
Group D: Initial Treatment With Combined Treatment											
34	8/70-pres.	++°	++°	+°	8/70-pres.	mP+M	mP+M:30+15	–	–	–	
39	11/71-12/73	+•	+•	–	11/71-9/72	mP+M;M	–	–	–	–	
40	4/72-pres.	+•	+•	–	4/72-10/75	mP+Cyc;Cyc	Cyc:50	–	–	–	
41	2/73-pres.	+•	++•	+•	2/73-pres.	mP+Cyc;mP+M;hP;mP+Aza	mP+M:20+5	2	10	200	
42	5/73-pres.	+°	+°	–	5/73-pres.	mP+M;mP+Cyc	mP+Cyc:10+50	–	–	–	
43	6/73-pres.	+°	+°	+•	6/73-pres.	mP+Cyc	mP+Cyc:15+100	–	–	–	
44	9/73-pres.	++°	+++°	–	9/73-4/75	mP+M;hP;mP+M	mP+M:7.5+5	1	6	240	
45	12/73-5/76	++•	++	–	12/73-7/74	mP+Cyc;mP+M;M	–	–	–	–	
46	4/74-5/76	+•	+•	–	4/74-4/76	mP+Cyc	–	–	–	–	
47	4/74-pres.	+•	+•	–	4/74-4/76	mP+M;mP+Cyc;mP	mP:10	–	–	–	
48	4/74-pres.	+•	+•	–	4/74-pres.	mP+Cyc;mP+M;mP+Aza;mP	mP:10	–	–	–	
49	9/74-4/76	+•	+•	–	9/74-11/75	mP+Cyc;mP+Aza	–	–	–	–	
50	3/75-pres.	+•	++•	+•	3/75-pres.	mP+Cyc;hP;mP+M	mP+M:30+20	1	5	120	
51	6/75-6/76	++°	++°	–	6/75-9/75	mP+Cyc;mP	–	–	–	–	
52	7/75-pres.	+°	+°	–	7/75-5/76	mP+Cyc	mP+Cyc:25+50	–	–	–	
53	9/75-pres.	++	++	+	9/75-pres.	mP+M;mP+Cyc	mP+Cyc:30+100	–	–	–	
Group E: Initial Treatment with Large Daily Doses of Prednisone											
54	7/71-1/76	++	++	–	7/71-6/75	hP;mP+M;mP+Cyc;Cyc	–	2	6	240	
55	1/72-pres.	++++°	++++°	+•	1/72-pres.	hP;mP+M;mP+Cyc;mP+Aza	mP+Aza:10+150	2	19	300	
56	1/72-6/73	++++°	++++°	–	1/72-9/72	hP;mP;mP+Cyc	(hP:300)	3	19	400	
	2/75-3/75	+++	+++	(++)	2/75-3/75	hP		1	6	300	E. coli sepsis
57	11/72-11/73	+++°	+++°	–	11/72-7/73	hP;mP+M;M	–	1	5	180	
58	8/73-4/76	++•	++•	–	8/73-10/75	hP;mP+M	–	1	6	240	
59	11/73-pres.	+++°	+++°	+•	11/73-pres.	hP;mP+M;mP+Cyc;mP+Aza	mP+Aza:10+50	1	6	360	
60	4/74-12/74	+++°	+++°	–	4/74-7/74	hP;mP+Cyc;mP	–	1	8	300	
61	1/75-5/75	+++°	++++°	(++)	1/75-5/75	hP	(hP:300)	1	17	500	Coccidioidomyc.
62	1/75-pres.	+++°	+++°	–	1/75-6/76	hP;mP+Cyc	mP+Cyc:20+50	1	10	300	
63	3/75-pres.	++++°	++++°	–	3/75-5/76	hP;mP+M	mP+M:15+10	1	8	400	

Results of treatment. Present and pres. refer to Sept 1, 1976. + indicates slight involvement; + +, moderate involvement; + + +, extensive involvement; + + + +, very extensive involvement; •, oral involvement exclusively; o, oral involvement in addition to cutaneous involvement; hP, high doses of prednisone (120 mg daily or higher); mP, maintenance doses of prednisone (40 mg or less) on alternate days; M, methotrexate orally once a week; Cyc, cyclophosphamide orally every day; and Aza, azathioprine orally every day.

of prednisone and an immunosuppressant. Seven of the ten patients received only one course of high-dosage prednisone; patients 54 and 55 received two high-dosage courses; and patient 56 received four high-dosage courses. Of the ten patients in group E, as of Sept 1, 1976, patients 56 and 61 had died of the consequences of high-dosage prednisone treatment (see Causes of Death); patients 55 and 59 had a few oral lesions and were receiving treatment; patients 62 and 63 were free of lesions but were still being treated; and patients 54, 57, 58, and 60 were free of lesions and had not received any treatment for from five months to three years, for an average of 1½ years. In the four patients who were still being treated, the treatment consisted of maintenance doses of prednisone and azathioprine in two patients; of maintenance doses of prednisone and methotrexate in one patient; and of maintenance doses of prednisone and cyclophosphamide in one patient.

Recurrences

Among the 63 patients seven had recurrences of their pemphigus vulgaris after a full remission (ie, no lesions and no treatment). Patients 4, 14, 21, 23, 29, and 56 had one recurrence each, and patient 13 had two recurrences. The shortest interval between a full remission and the recurrence was nine months (patient 23), and the longest interval was ten years (patient 14), with the average duration of the interval being 3½ years. Five recurrences were mild: three of them cleared (patients 14, 23, and 29) and two persisted (patients 4 and 13, second recurrence). Two recurrences were moderately severe: one of them cleared (patient 13, first recurrence) and one persisted mildly (pa-

tient 21). In one instance (patient 56), the recurrence setting in after an interval of 20 months was very severe and resulted in death from corticosteroid-induced sepsis.

Causes of Death

In six of the 63 patients with pemphigus vulgaris high-dosage treatment with prednisone was responsible for their death. The causes of death of the first three patients have already been discussed in the previous report.[1] They died of acute myocardial infarction (patient 7), of peritonitis associated with mesentary artery thrombosis (patient 8), and of a retroperitoneal abscess (patient 9). The three patients who have died since 1972 died of staphylococcal sepsis (patient 28), of *Escherichia coli* sepsis (patient 56), and of systemic coccidioidomycosis (patient 61) (Figure).

Five patients of the previously reported series have died of causes unrelated to their disease or its treatment. Patient 3 died of a myocardial infarction while having a few lesions and receiving 7.5 mg of prednisone daily. Of the other four patients (patients 1, 13, 18, and 19) who have died since 1972, patient 1 died of bronchopneumonia and the other three of cardiac failure. Patients 1 and 18 had a few lesions and were receiving maintenance doses of prednisone but no immunosuppressants, ie, 7.5 mg of prednisone daily and 10 mg of prednisone every other day, respectively; patient 13 had no lesions and was receiving 20 mg of prednisone on alternate days but no immunosuppressant; and patient 19 was free of lesions and off treatment. These five patients had not received any high-dosage prednisone treatment for from 5 to 17 years.

Comment

Two reports of large series of patients with pemphigus vulgaris, or pemphigus vegetans, have been published recently. Rosenberg et al[3] described 90 patients with pemphigus vulgaris or pemphigus vegetans treated between 1949 and 1970. The treatment consisted almost entirely of corticosteroids; methotrexate was used in only three patients in an attempt to reduce the steroid maintenance dosage. In the 90 patients the disease- or drug-related mortality was 33%. When last seen, 20% of the 90 patients had discontinued steroid therapy. A study by Krain[4] included 49 patients with pemphigus vulgaris treated between 1955 and 1973. Only 8.2% of the patients had died of the disease or its treatment; 10.2% had died of unrelated causes; 6.1% had been lost to follow-up; 63.3% were still receiving treatment; and 12.2% were free of lesions and not receiving treatment. Thus, the mortality is similar to that of our series. However, the percentage of patients who were free of lesions and not receiving treatment is less than one third of this series (12.2% vs 38.1%). Krain indicated that the use of the Lever-White regimen (high corticosteroid dosage) and adjuvant immunosuppressive therapy (where needed for recalcitrant cases of disease) dramatically decreased mortality for pemphigus vulgaris. The immunosuppressant used was cyclophosphamide.

Evaluation of Immunosuppressants in Pemphigus Vulgaris

Three immunosuppressants have been used in the treatment of pemphigus vulgaris: methotrexate, cyclophosphamide, and azathioprine. They were given either (1) after high-dosage treatment with corticosteroids in conjunction with maintenance doses of corticosteroids, in the hope of achieving a more rapid reduction in the maintenance dose of corticosteroids amounting to a "steroid-saving" effect; (2) initially with various doses of corticosteroids; or (3) initially alone. In all reports except that by Wolff in 1976,[5] the number of patients was small and usually the length of treatment was limited. No appreciable difference in the effects of the three immunosuppressive drugs is evident from previous reports, so they will be discussed together.

Immunosuppressants Given With Maintenance Doses of Corticosteroids After High-Dosage Treatment With Corticosteroids.—A steroid-saving effect, even to the point of discontinuance of the corticosteroids, was observed in some patients with methotrexate,[6,7] cyclophosphamide,[4,8-10] and azathioprine.[11-14]

Evaluation of our own results in this category of patients can be based on 12 patients in group B (patients 15 through 21 and 23 through 27), four patients in group C (patients 31, 32, 33, and 37), and eight patients in group E (patients 54 and 55, 57 through 60, and 62 and 63). Of these 24 patients, as of Sept 1, 1976, two had died of unrelated causes (patients 18 and 19); ten patients still had a few lesions and were receiving treatment; four were free of lesions but were still under treatment; and eight were free of lesions and off treatment. With half of the patients being free of lesions, the impression is gained that immunosuppressants often are steroid-saving and, in some instances, lead to an earlier discontinuance of prednisone and even of the immunosuppressant.

Immunosuppressants Initially With Various Doses of Corticosteroids.—The initial treatment of pemphigus vulgaris with 25 mg of methotrexate weekly and, in addition, with daily high doses of prednisone seems to carry some risk because the combined action of two powerful immunosuppressants may lower the patient's resistance to microorganisms to such an extent that fatal sepsis may occur within a relatively short time. Ryan[15] observed in three of four patients receiving this type of treatment the sudden onset of a fatal bacteremia within a few weeks. Similarly, Jablonska et al[16] observed nine instances of bacterial infections, four of them fatal, among 19 patients with pemphigus; they had been given, generally for only a few weeks, methotrexate, 25 mg/week, and moderate daily doses of corticosteroids. In contrast with methotrexate, azathioprine, in daily doses of 100 to 200 mg daily, did not lower resistance to infection markedly, according to Wolff,[5] even when given initially with 150 to 200 mg of prednisone daily. He treated 24 patients with pemphigus vulgaris for from two to seven years. Two patients had died of unrelated causes; four patients still had a few lesions and were receiving treatment; 17 patients were free of lesions but were still being treated, five of them only with azathioprine; and one patient was free of lesions and off therapy. Wolff pointed out that the high initial doses of prednisone could be reduced considerably faster than when corticosteroids had been given alone.

The method of initially treating early, stable pemphigus vulgaris with an immunosuppressant and, in addition, with maintenance doses of prednisone not exceeding 40 mg on alternate days, as carried out on the 16 patients of group D, has not been used so far by other investigators. All 16 patients have done well, and only three of them needed high-dosage therapy with prednisone for short periods of time.

Immunosuppressants Alone Initially.—This treatment has proved effective only occasionally in early, stable pemphigus vulgaris. Thus, Roenigk and Deodhar,[17] in treating five patients with pemphigus vulgaris with azathio-

prine alone, achieved clearing of the lesions in two patients, but both patients were still receiving treatment with azathioprine at the time of reporting; one patient experienced a breakthrough, requiring high-dosage treatment with corticosteroids; and two patients failed to respond to azathioprine. Van Dijk and van Velde[14] described one patient with pemphigus vulgaris in whom all lesions cleared on azathioprine alone.

We obtained results similar to those of Roenigk and Deodhar[17] in ten patients with early stable pemphigus vulgaris in group C; four of the ten patients not only cleared of lesions but also discontinued the immunosuppressant. However, five of the ten patients worsened to such a degree that high-dosage prednisone became necessary. Thus, the treatment with immunosuppressants alone has shown itself to be inferior to the combined treatment with an immunosuppressant plus maintenance doses of prednisone on alternate days.

Gold Compounds.—Although this treatment has not been used in the present series of patients, it deserves mentioning as an alternative treatment. In two reports Penneys et al[18,19] described treatment with gold compounds in 18 patients with pemphigus (not all patients had pemphigus vulgaris). Gold therapy was discontinued in two patients because of toxic reactions, and one patient was unavailable for follow-up. Good results were obtained in 14 of the 15 remaining patients, and eight patients (44% of the total of 18 patients) had remissions requiring no therapy. With the exception of three patients in whom involvement was limited, all had received large doses of prednisone prior to their treatment with gold compounds. Two of the three patients who had received only chrysotherapy have been in remission without therapy for 8 and 13 months. According to Penneys et al,[19] the mode of action of gold is unknown. However, certain similarities seem to exist in the effects of gold and the immunosuppressants since in both there is a lag time of six to eight weeks or longer, and also gold therapy is suitable only for mild cases or cases partially controlled by prior therapy with corticosteroids. Like the immunosuppressants, gold can produce side reactions. Whether or not the gold compounds are equal or even superior to the immunosuppressants in effectiveness can be decided only by long-range comparison studies.

Conclusion.—In assessing the results obtained with immunosuppressants in the treatment of pemphigus vulgaris, we conclude that the immunosuppressants, when given in conjunction with maintenance doses of prednisone, are of value in two respects. First, in patients with severe or advancing pemphigus vulgaris, they are of value because, after high-dosage treatment with prednisone has been given, the administration of an immunosuppressant together with maintenance doses of prednisone has made it possible in many instances to reduce the maintenance dose of prednisone more rapidly than if prednisone had been given alone. Even more important is the role of the immunosuppressants in patients with early, stable pemphigus vulgaris, as shown in the 16 patients of group D whose initial treatment consisted of an immunosuppressant plus maintenance doses of prednisone. All 16 patients have done very well, and only three of them ever needed high-dosage therapy with prednisone. Since this treatment is suitable only for patients with early, stable disease, it is of the utmost importance that pemphigus vulgaris be diagnosed early. With few exceptions, patients with pemphigus vulgaris pass through an initial stable stage during which, for several months, only a few localized lesions are present, most commonly in the mouth.

Suggested Treatment for Severe or Advancing Pemphigus Vulgaris

High-dosage treatment with prednisone is given initially. Depending on the severity of the disease, the initial daily dose should be between 180 and 360 mg. If no improvement is noted within five days, the daily dose should be increased by at leat 60 mg. High doses of prednisone should be administered until all lesions have healed and, possibly, even beyond this time. A period of at least six weeks of high-dosage treatment is recommended, because relapses may be prevented or, if they occur, are usually mild. The prolonged treatment with high daily doses is usually well tolerated by patients receiving their first course of high-dosage prednisone, provided they did not receive prior prolonged intermediate-dose treatment. Patient 57, who died of coccidioidomycosis, was the first among the more than 100 patients with pemphigus in this series and the previous series reported by Lever and White[2] who died, without prior prolonged intermediate-dose treatment, during his first course of high-dosage prednisone. The danger of side reactions greatly increases with subsequent doses of high-dosage treatment.

After completion of the high-dosage treatment, the dose of prednisone is reduced to 40 mg daily for one week, to 30 mg daily for one week, to 25 mg daily for one week, and then to 40 mg on alternate days. At this point an immunosuppressant is added (see Suggested Treatment for Early, Stable Pemphigus Vulgaris). Further reduction of alternate-day dose of prednisone is carried out very gradually over many months, and it must be individualized. Generallly, the plan is first to eliminate the prednisone and then to reduce the immunosuppressant.

In case of an acute recurrence, high doses of prednisone should be given again, at least 120 mg daily. At the same time, the immunosuppressive drug shoud be temporarily discontinued. If high-dosage treatment is instituted soon enough, four to five weeks of treatment with high doses of prednisone may be sufficient. It seems inadvisable to give intermediate doses of prednisone, between 40 mg every other day and 120 mg daily. Intermediate doses rarely suppress an exacerbation adequately, and giving them for prolonged periods of time results in serious complications when the activity of the disease makes it unavoidable to give high-dosage treatment with prednisone.

Suggested Treatment for Early, Stable Pemphigus Vulgaris

In combining maintenance doses of prednisone with an immunosuppressant, the initial dose of prednisone is 40 mg on alternate days. Orally administered immunosuppressants may be either methotrexate, 20 mg once a week; cyclophosphamide, 100 mg daily; or azathioprine, 150 mg daily. In the stated doses they are equally effective in pemphigus vulgaris. (An occasional disadvantage of methotrexate is that oral lesions may respond poorly. Also, in rare instances a burning sensation is experienced in the oral lesions for several days after its administration.) Whereas it is inadvisable to raise the dosage of prednisone above 40 mg every other day, the dose of methotrexate may be increased to 30 mg once a week, cyclophosphamide to 150 mg daily, azathioprine to 200 mg daily. Since publication of the previous study[1] it has become apparent that no greater benefit is derived from methotrexate given in doses larger than 30 mg per week or from administering it paren-

terally rather than orally.

Usually several months, and sometimes more than a year, of this combined treatment are required before improvement occurs, but the mere fact that there is no worsening, which in most instances is the natural course of the disease, is a favorable sign. If, however, the patient's condition worsens, as it did in three of our 16 patients, high-dosage treatment is indicated. After clearing or nearly full clearing has been achieved by the combined treatment with an immunosuppressant and maintenance doses of prednisone, the amount of prednisone can be very gradually lowered from 40 mg on alternate days, at first by 5 mg per month and, after the dose has been reduced to 15 mg on alternate days, by 5 mg every two months. Thus, it requires nearly a year to phase out the alternate-day dose from 40 mg, provided there is no recurrence. Even in patients who have completely cleared, a more rapid decrease in the dose of prednisone than suggested may result in a recurrence. After elimination of the prednisone, the immunosuppressant is gradually reduced over a period of approximately six months.

In some patients reactivation occurs, even with the recommended slow decrease, necessitating either a holding of the prednisone dose at the same level for several months or a slight increase in the dose. It may be impossible for several years to eliminate the prednisone, but the alternate-day dose generally is so small that it does not pose a serious risk. In any case, none of the 13 patients who received only maintenance doses of prednisone had any complications from it. If elimination of prednisone seems unlikely in the foreseeable future, gradual reduction in the amount of the immunosuppressant can be considered to be about half the recommended initial dose.

As has been pointed out, methotrexate in several patients caused an elevation of the transaminases but did not produce any lowering of the blood cell, differential, or platelet count, whereas cyclophosphamide and azathioprine not infrequently caused a lowering of the blood cell, differential, or platelet count. Thus, in many patients a continuation of immunosuppressive therapy was possible by changing from methotrexate to cyclophosphamide or azathioprine, or vice versa (see Type of Treatment in Figure). All increases in the transaminases and decreases in the blood cell, differential, and platelet counts were temporary. In several instances, side reactions, such as nausea, lassitude, or drug fever, necessitated a change in the immunosuppressants; in patients 35 and 48 these side reactions prevented the administration of all three immunosuppressants in adequate doses.

Nonproprietary Names and Trademarks of Drugs

Azathioprine—*Imuran.*
Cyclophosphamide—*Cytoxan.*
Prednisone—*Delta-Dome, Deltasone, Deltra, Meticorten, Paracort, Servisone.*

References

1. Lever WF: Methotrexate and prednisone in pemphigus vulgaris: Therapeutic results obtained in 36 patients between 1961 and 1970. *Arch Dermatol* 106:491-497, 1972.
2. Lever WF, White H: Treatment of pemphigus with corticosteroids: Results obtained in 46 patients over a period of 11 years. *Arch Dermatol* 37:12-26, 1963.
3. Rosenberg FR, Sanders S, Nelson CT: Pemphigus: A 20-year review of 107 patients treated with corticosteroids. *Arch Dermatol* 112:962-970, 1976.
4. Krain LS: Pemphigus: Epidemiologic and survival characteristics of 59 patients, 1955-1973. *Arch Dermatol* 110:862-865, 1974.
5. Wolff K: Immunosuppressive Therapie bullöser Dermatosen. *Hautarzt*, suppl 1, 1976, pp 25-27.
6. Lever WF, Goldberg HS: Treatment of pemphigus vulgaris with methotrexate. *Arch Dermatol* 100:70-78, 1969.
7. Peck SM, Osserman KE, Samuels AJ, et al: Studies in bullous diseases. *Arch Dermatol* 103:141-147, 1971.
8. Ebringer A, Mackay IR: Pemphigus vulgaris successfully treated with cyclophosphamide. *Ann Intern Med* 71:125-127, 1969.
9. McKelvey EM, Hasegawa J: Cyclophosphamide and pemphigus vulgaris. *Arch Dermatol* 103:198-200, 1971.
10. Krain LS, Landau JW, Newcomer VD: Cyclophosphamide in the treatment of pemphigus vulgaris and bullous pemphigoid. *Arch Dermatol* 106:657-661, 1972.
11. Wolff K, Schreiner E: Immunosuppressive Therapie bei Pemphigus vulgaris. *Arch Klin Exp Dermatol* 235:63-77, 1967.
12. Krakowski A, Covo J, Rozanski Z: Pemphigus vulgaris. *Arch Dermatol* 100:117, 1969.
13. Van Dijk TJA, van Velde JL: Treatment of pemphigus and pemphigoid with azathioprine. *Dermatologica* 147:179-185, 1973.
14. Burton JL, Greaves MW: Azathioprine for pemphigus and pemphigoid: A four-year follow-up. *Br J Dermatol* 91:103-109, 1974.
15. Ryan JG: Pemphigus. A 20-year survey of experience with 70 cases. *Arch Dermatol* 104:14-20, 1971.
16. Jablonska S, Chorzelski T, Blaszczyk RM: Immunosuppressants in the treatment of pemphigus. *Br J Dermatol* 83:315-323, 1970.
17. Roenigk HH Jr, Deodhar S: Pemphigus treated with azathioprine. *Arch Dermatol* 107:353-357, 1973.
18. Penneys NS, Eaglstein WH, Indgin S, et al: Gold sodium thiomalate treatment of pemphigus. *Arch Dermatol* 108:56-60, 1973.
19. Penneys NS, Eaglstein WH, Frost P: Management of pemphigus with gold compounds: A long-term follow-up report. *Arch Dermatol* 112:185-187, 1976.

Multiple Osteolytic Lesions in a Patient With Mycosis Fungoides

Kenneth E. Greer, MD; Larry L. Legum, MD; Charles E. Hess, MD

• **Skeletal lesions that were clinically significant and roentgenographically demonstrable developed in a patient with mycosis fungoides. Biopsy specimens from skin plaques and tumors and from a tibial tumor mass revealed an infiltrate of similar-appearing cells that were compatible with mycosis cells. Bone marrow involvement is not unusual in patients with mycosis fungoides with extracutaneous disease, but destruction of cortical bone in mycosis fungoides, as demonstrated by the patient in this report, is rare.**

(*Arch Dermatol* 113:1242-1244, 1977)

Mycosis fungoides is a cutaneous T cell lymphoma[1] that affects the skin primarily but that in its later stages may affect the lymph nodes and almost any visceral organ.[2] Involvement of the skeletal system is considered rare,[3] although in one recent report microscopic evidence of bone marrow involvement was demonstrated at autopsy in 12 of 31 patients with extracutaneous disease.[4] However, clinically significant or roentgenographically demonstrable bone lesions in patients with mycosis fungoides is very unusual.[5] We describe a patient with mycosis fungoides who had roentgenographic evidence of extensive bone involvement and pathological fractures.

REPORT OF A CASE

A 47-year-old man with known mycosis fungoides was admitted to the hospital in February 1975, for evaluation of polyarthralgia and a swollen right knee of three months' duration. Five years previously, annular erythematous patches developed on his chest and arms. The lesions were asymptomatic. In 1973, violaceous plaques and tumors developed in these same areas and were associated with mild burning but no pruritus. A diagnosis of mycosis fungoides was made on a biopsy specimen of an infiltrated lesion overlying the sternum, but no therapy was initiated at that time. The activity of these lesions would wax and wane without therapy. In November 1974, polyarthralgia of multiple joints developed, including the knees, ankles, wrists, and fingers. The patient was forced to quit his job, and he was begun on a regimen of oral prednisone, 15 mg/day, with only slight improvement of the joint symptoms but partial yet significant resolution of the cutaneous lesions. When the joint symptoms progressed, he was referred to the University of Virginia (Charlottesville) Hospital for admission.

Pertinent physical findings on admission were limited to the skin and the joints. Several tumors and infiltrated plaques characteristic of mycosis fungoides were noted on the chest and arms. There was erythema, swelling, and tenderness of the right knee, as well as slight swelling of several digits of the left hand. There was no lymphadenopathy and the liver and spleen were not enlarged as determined by palpation and percussion.

Laboratory investigations revealed hematocrit reading of 45%, a WBC count of 12,600/cu mm with a normal differential, an ESR of 119 mm/hr, and a platelet count of 377,000/cu mm. The lactic acid dehydrogenase level was 283 IU (normal, 120 to 230 IU); alkaline phosphatase level was 145 IU (normal, 30 to 85 IU), and protein electrophoresis revealed an albumin level of 2.2 gm/100 ml (normal, 4.2 to 5.2 gm/100 ml) with an increased alpha 2 fraction. Serum immunoelectrophoresis revealed an IgA level of 470/mg/100 ml (normal, 60 to 297/mg/100 ml). The tuberculin skin test was negative; skin tests with monilia and trichophytin were positive.

Roentgenograms of the bones revealed multiple osteolytic defects of the right tibia, with extensive destruction of the proximal tibia (Fig 1) and of the metacarpals and phalanges, with a pathological fracture of the fifth digit of the right hand (Fig 2). Similar defects were seen roentgenographically in numerous other bones, including the radius and ulna of both arms, both femurs, and the carpal bones of the right hand. In addition, pathological fractures were demonstrated in the proximal phalanx of the left third finger and the middle phalanx of the left second finger.

Aspiration of fluid from the right knee and bone marrow aspiration from the iliac crest revealed no abnormalities. Biopsy specimens from skin tumors and the right proximal tibial tumor mass revealed a dense infiltrate composed of large hyperchromic and anaplastic cells suggestive of mycosis fungoides (Fig 3). A biopsy specimen from an early and barely palpable skin plaque revealed exocytosis or penetration of the epidermis by these anaplastic cells with early Pautrier microabscess formation (Fig 4). Touch preps and electron micrographs revealed that the cells from the skin lesions and from the proximal tibia were remarkably similar and compatible with mycosis cells. The cells were mononuclear with large, hyperchromatic, and often irregularly shaped nuclei. Unfixed frozen sections of skin tumor were stained with hematoxylin-eosin and with fluorescein-labeled polyvalent goat anti-human immunoglobulins. The HE-stained sections revealed an intense infiltrate composed of mononuclear cells morphologically compatible with lymphocytes; no obvious immunofluorescence with anti-human globulins, indicative of B cells, was evident. This was consistent with the designation of these cells as T cells. Currently, no test is available for the positive identification of T cell markers in tissue.

On completion of the diagnostic workup, the patient was begun on a regimen of COP chemotherapy (oral cyclophospha-

Accepted for publication Nov 24, 1975.

From the Departments of Dermatology (Drs Greer and Legum) and Internal Medicine (Dr Hess), University of Virginia School of Medicine, Charlottesville.

Reprints not available.

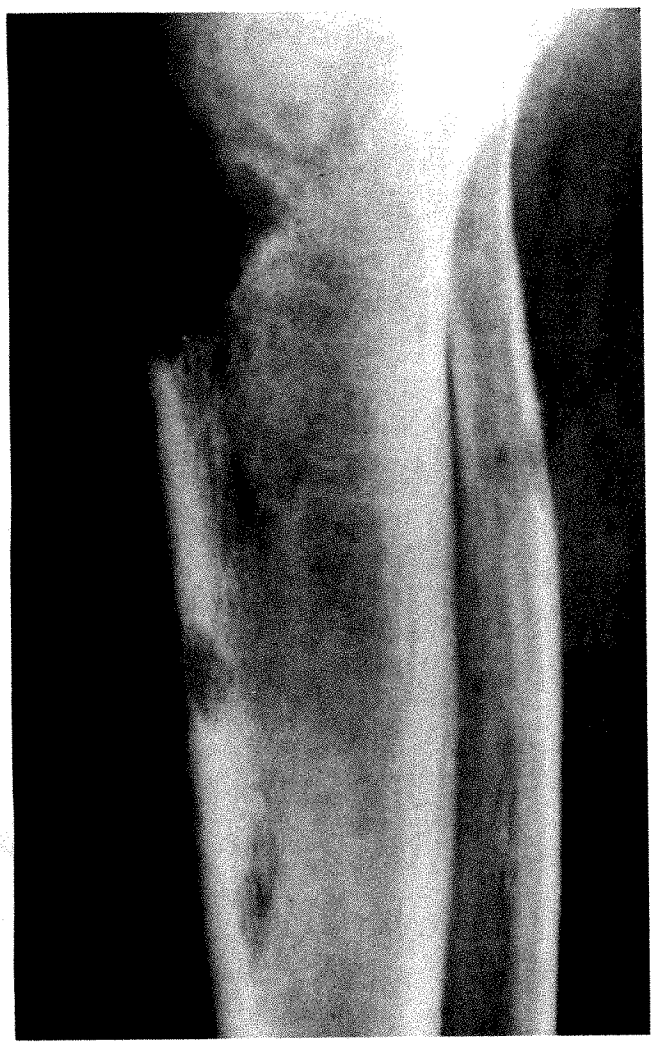

Fig 1.—Osteolytic lesions of right tibia with extensive destruction of proximal tibia.

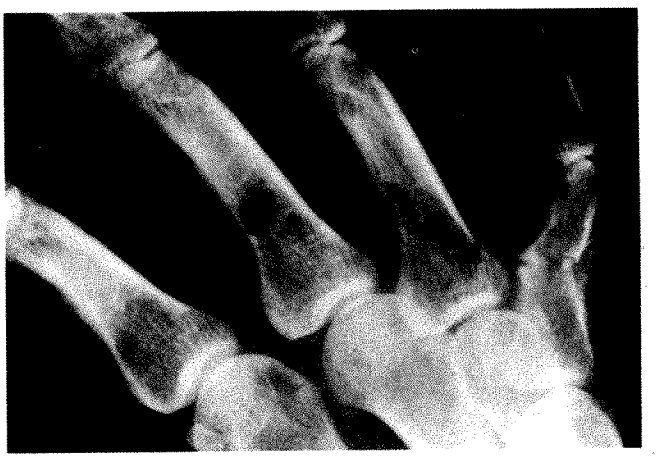

Fig 2.—Osteolytic lesions of phalanges with pathological fracture of fifth digit.

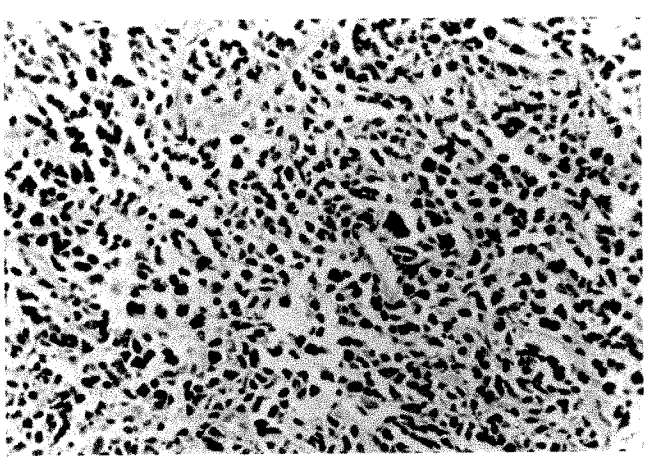

Fig 3.—Bone biopsy specimen of tibial tumor with mycosis cells similar to cells in skin lesion in Fig 4 (hematoxylin-eosin, original magnification ×150).

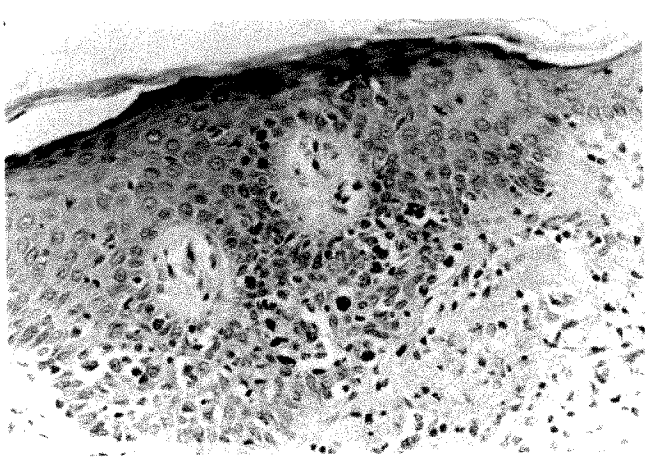

Fig 4.—Infiltrate of mycosis cells in upper dermis and epidermis (hematoxylin-eosin, original magnification ×150).

mide, 750 mg/day for five days; oral prednisone, 200 mg/day for five days, and vincristine sulfate, 2 mg intravenously for one day) and radiotherapy with a cobalt teleroentgen therapy unit (4,000 rads divided in 20 doses to the right proximal tibia). The response of the tibial tumor mass to radiotherapy was excellent, with decreased pain and swelling, and in three months new bone formation was demonstrated roentgenographically. The tumors on the chest and forearm did not improve after two courses of COP chemotherapy and these lesions were subsequently treated with 2,400 rads in 12 treatments with complete regression. In September 1975, many new small infiltrated plaques developed on the trunk and extremities, as well as severe pain in the left lower tibia. Osteolytic lesions were demonstrated roentgenographically and local radiotherapy is now in progress to the left tibia.

COMMENT

Clinical or roentgenological evidence of bone involvement in malignant lymphoma varies significantly according to the type of disease, occurring commonly in Burkitt's lymphoma of African children,[6] not infrequently in Hodgkin's disease,[5] but rarely in mycosis fungoides.[7] Rappaport and Thomas[4] found microscopic evidence of bone marrow involvement in 39% of the autopsies done on patients who had had mycosis fungoides with extracutaneous disease. The lesions were grossly visible in only two. There have been few reports with roentgenographically demonstrable bone lesions in mycosis fungoides.[7] The patient reported here not only had roentgenographic evidence of extensive osteolytic lesions involving large and small bones (tibia and phalanges, respectively), but the bone lesions were clinically significant. Because of pain on ambulation from the right tibial lesion, as well as swelling and pain of the digits of both hands, he was unable to perform his duties as a heavy equipment operator.

The exact reason for the variable involvement of bone in the different types of malignant lymphoma is unknown. One plausible reason for the small number of reports of bone involvement in mycosis fungoides is the older idea of "evolution" of mycosis fungoides to Hodgkin's disease, lymphosarcoma, and histiocytic lymphoma (reticulum cell sarcoma), especially when there is extracutaneous involvement.[8] Rappaport and Thomas[4] have convincingly demonstrated in their review of the pathology of extracutaneous mycosis fungoides that the "neoplastic cellular proliferation in both cutaneous and extracutaneous tissue is distinct and different from those of other lymphoid and histiocytic neoplasms which usually arise in extracutaneous sites, but occasionally also in the skin." They base this statement on the similar appearance microscopically of the visceral and cutaneous lesions. In the early plaque stage of mycosis fungoides, the infiltrate is frequently pleomorphic with a small percentage of the so-called mycosis cells, which are characterized by their hyperchromatic and often deeply indented nuclei[9]; visceral lesions may show similar changes microscopically. Pautrier microabscesses are characteristic of the skin lesions of the plaque stage but are not seen in visceral organs. However, in the late-tumor stage, the mycosis cells are much more numerous and more anaplastic appearing, making it difficult to differentiate this disorder from other lymphomas. This may be true for both the cutaneous and extracutaneous lesions. Our patient demonstrated this difficulty in classification until the ninth biopsy specimen of his skin lesions was examined microscopically. This specimen was taken from an early and minimally infiltrated plaque and demonstrated more clearly the considerable exocytosis or penetration of the epidermis by mycosis cells producing the microabscesses. Earlier biopsy specimens had been taken from tumors or from older and heavily infiltrated plaques and they revealed a homogenous infiltration of anaplastic cells similar to the cells in the osteolytic lesion of the proximal tibia.

Another possible reason for the infrequent occurrence of gross involvement of bone in mycosis fungoides is the fact that the disorder results from the neoplastic proliferation of T cells[1] and not B cells (bursal equivalent or bone marrow-dependent lymphocytes) characteristic of most of the other malignant lymphomas and leukemias of lymphocytic origin. In addition, bone marrow involvement, when evident microscopically, is usually small and multifocal and rarely diffuse,[5] and it infrequently involves cortical bone. Also, the proliferation and infiltration of the neoplastic cells in visceral lesions of mycosis fungoides are not generally accompanied by the destructive effects characteristic of other malignant lymphomas and carcinomas.[4] The architecture of the tissue may be preserved despite the high degree of infiltration by these cells. The patient described here is unusual in that the tumor caused severe bone destruction with pathological fractures of the proximal tibia and of the phalanges.

The treatment of skeletal lesions of mycosis fungoides does not differ significantly from the treatment of other extranodal and extracutaneous forms of the disease.[10] The good response to radiation therapy in our patient was evident clinically and roentgenographically. The eventual prognosis, however, in a patient with evidence of extensive extracutaneous involvement is guarded.

Nonproprietary Name and Trademark of Drug

Vincristine sulfate—*Oncovin*.

References

1. Edelson RL, Kirkpatrick CH, Shevack EM, et al: Preferential cutaneous infiltration by neoplastic thymus-derived lymphocytes. *Ann Intern Med* 80:685-692, 1974.
2. Epstein EH, Levin DL, Croft JD Jr, et al: Mycosis fungoides: Survival, prognostic features, response to therapy, and autopsy findings. *Medicine* 15:61-72, 1972.
3. Block JB, Edgcomb JH, Eisen A, et al: Mycosis fungoides: Natural history and aspects of its relationship to other malignant lymphomas. *Am J Med* 34:228-235, 1963.
4. Rappaport H, Thomas LB: Mycosis fungoides: The pathology of extracutaneous involvement. *Cancer* 34:1198-1229, 1974.
5. Thomas LB, Frei E III, Hilbish TF: Regional consideration of leukemia and lymphoma: The skeletal system, in Pack G, Ariel I (eds): *Treatment of Cancer and Allied Diseases*. ed 2. New York, Hoeber Medical Division, Harper & Row, Publishers, 1964, pp 206-233.
6. O'Conor GT: Malignant lymphoma in African children: II. A pathological entity. *Cancer* 14:270-283, 1961.
7. Poulson A: On mycosis fungoides. *Acta Dermatol Venereal* 21:365-400, 1940.
8. Rauschkolb RR: Mycosis fungoides: Discussion and clinical experience at Cleveland Metropolitan General Hospital *Arch Dermatol* 83:217-223, 1961.
9. Lever WF, Schaumburg-Lever G: *Histopathology of the Skin*, ed 5. Philadelphia, JB Lippincott, 1975, pp 696-703.
10. Epstein Eh Jr, Zackheim HS: Therapy of cutaneous mycosis fungoides. *Cutis* 15:245-248, 1975.

Bony Lesions in Systemic Mastocytosis.

Scintigraphic Evaluation

Maj Samuel Sostre, MC, USAF, Maj Harvey L. Handler, MC, USAF

• **Bone, bone marrow, and gallium citrate Ga 67 scans were performed on a patient with systemic mastocytosis and bony involvement to evaluate their diagnostic value in such patients. The bone scan revealed increased tracer concentration in the involved areas. These abnormalities were less prominent than those on the roentgenograms, suggesting that only a part of the roentgenographic abnormalities were associated with reactive bone formation. Bone scanning may be less sensitive than roentgenograms to detect the full extent of the bony lesions of systemic mastocytosis. The bone marrow scan revealed a normal central marrow with peripheral marrow expansion. Possibly, the central marrow infiltration by mast cells was sufficient to interfere with its hemopoietic function to a degree that made it necessary to reactivate peripheral marrow tissue. There was no significant ^{67}Ga accumulation in the bony lesions of systemic mastocytosis.**

(*Arch Dermatol* 113:1245-1247, 1977)

Systemic mastocytosis is an uncommon disease characterized by the abnormal accumulation of increased numbers of mast cells in the skin, lymph nodes, viscera, and bone marrow. Bony abnormalities in this disease were first described by Sagher et al in 1952.[1] Since then, many cases with roentgenographically demonstrable bony lesions have been reported, and the roentgenographic findings in this disease are well established.[2,3] To our knowledge, the results of radionuclide scanning of such patients have not been reported.

We will describe the results of three different radionuclide imaging procedures (bone scan, marrow scan, and gallium citrate Ga 67 total body scan) performed in a patient with proven mastocytosis and roentgenographically detectable bony lesions.

Accepted for publication June 30, 1976.

From the Departments of Nuclear Medicine and Dermatology, USAF Medical Center, Wright-Patterson Air Force Base, Ohio.

The views expressed herein are those of the authors and do not necessarily reflect the views of the US Air Force or the Department of Defense.

Reprint requests to Department of Nuclear Medicine, Buffalo General Hospital, 100 High St, Buffalo, NY 14203 (Dr Sostre).

REPORT OF A CASE

A 39-year-old woman came to the dermatology clinic at USAF Medical Center, Wright-Patterson AFB with a 20-year history of episodic facial flushing, nausea, tachypnea, blurred vision, dyspnea, and nasal congestion, as well as frequent headaches and skin lesions. These symptoms were exacerbated by a hot shower, exertion, swimming in cold water, or prolonged sun exposure. Headaches occurred daily, usually beginning in the late evening and lasting approximately one hour.

Results from physical examination were normal with the exception of the dermatologic examination that revealed hyperpigmented, brown macular lesions with surface telangiectases involving the entire body in a generalized fashion, but concentrated more on the extremities. Darier's sign was positive with the production of a wheal 30 to 45 seconds after scratching the lesions.

Skin biopsy specimen and toluidine blue stains revealed increased numbers of mast cells in the papillary dermis and surrounding the blood vessels. A chest roentgenogram was normal. Roentgenographic examination of the bones revealed diffuse

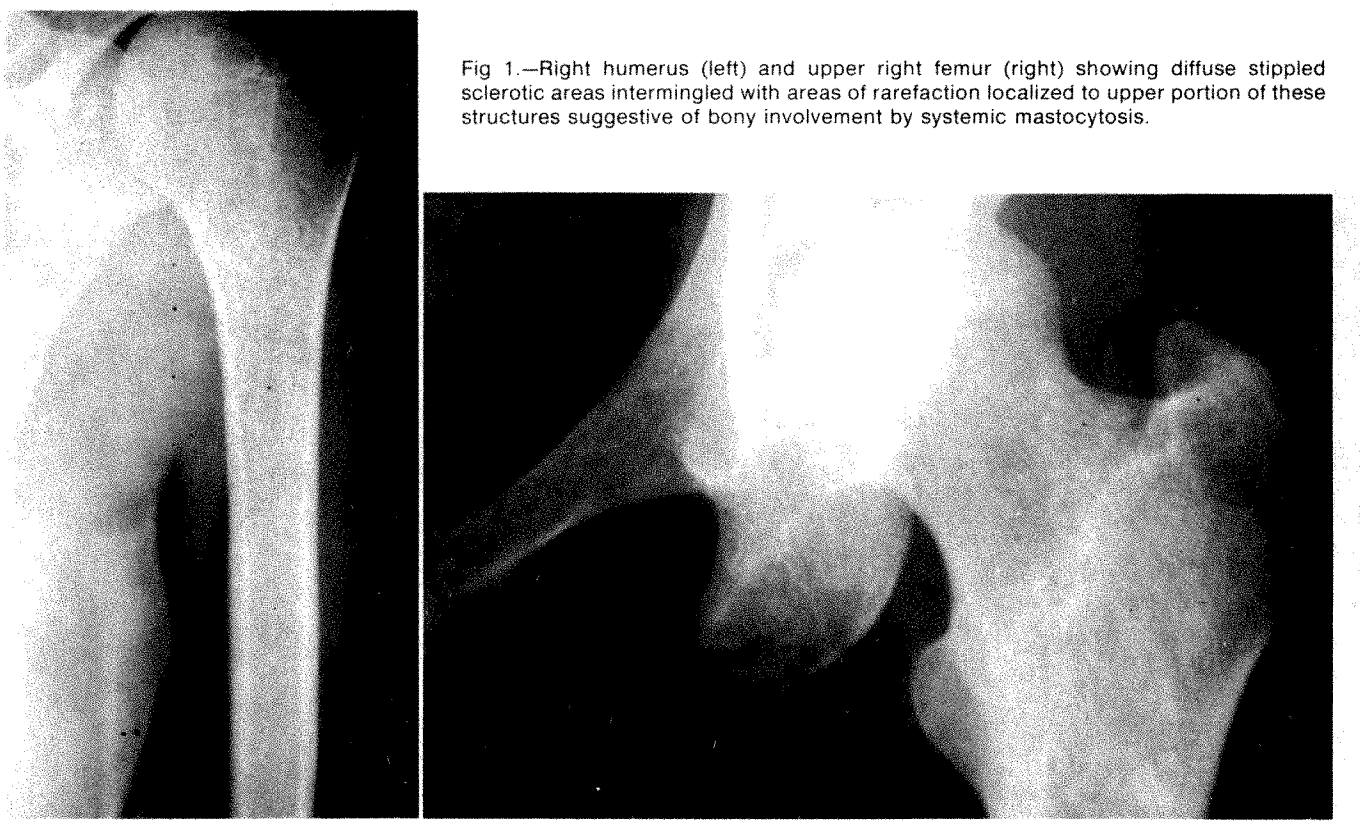

Fig 1.—Right humerus (left) and upper right femur (right) showing diffuse stippled sclerotic areas intermingled with areas of rarefaction localized to upper portion of these structures suggestive of bony involvement by systemic mastocytosis.

stippled sclerotic patches intermingled with small areas of rarefaction involving the pelvis, the proximal portion of the humeri, and the proximal portion of both femurs. No other areas were detectably involved (Fig 1).

Bone marrow aspirate from the right posterior iliac crest revealed normal myeloiderythroid ratio and orderly maturation. There was a marked increase in the number of mast cells present. Toluidine blue stains confirmed the metachromatic nature of the cytoplasmic granules. A biopsy done on bone marrow revealed impressive focal aggregates of mast cells. The complete blood cell, platelet, and reticulocyte counts were normal. Valves were within normal limits for alkaline phosphatase, SGOT, SGPT, lactic dehydrogenase, creatine phosphokinase, total protein, albumin, bilirubin, urinalysis, VDRL, sedimentation rate, and ECG.

At this time, a bone scan, a bone marrow scan, and a gallium citrate Ga 67 total body scan were obtained for further evaluation of the bony lesions.

METHODS

The bone scan was obtained two hours after the intravenous administration of 15 mCi of technetium Tc 99m-pyrophosphate. A dual probe rectilinear scanner, employing a 5:1 minification mode, was used, with the window centered on the 140-kev photon of technetium Tc 99m. The bone marrow scan was performed after the intravenous administration of 12 mCi of technetium Tc 99m sulfur colloid.

For the gallium scan, the dual probe rectilinear scanner was also used, with 5:1 minification. The study was performed 48 hours after the intravenous administration of 3 mCi of gallium citrate Ga 67. Bowel preparation was performed prior to scanning.

Fig 2.—Left, Bone scan. Areas of increased activity in humeral heads and femoral heads (arrows). Center, Bone marrow scan shows expansion of peripheral marrow (arrow) with normal central marrow distribution. Right, Gallium citrate Ga 67 scan. Essentially normal findings.

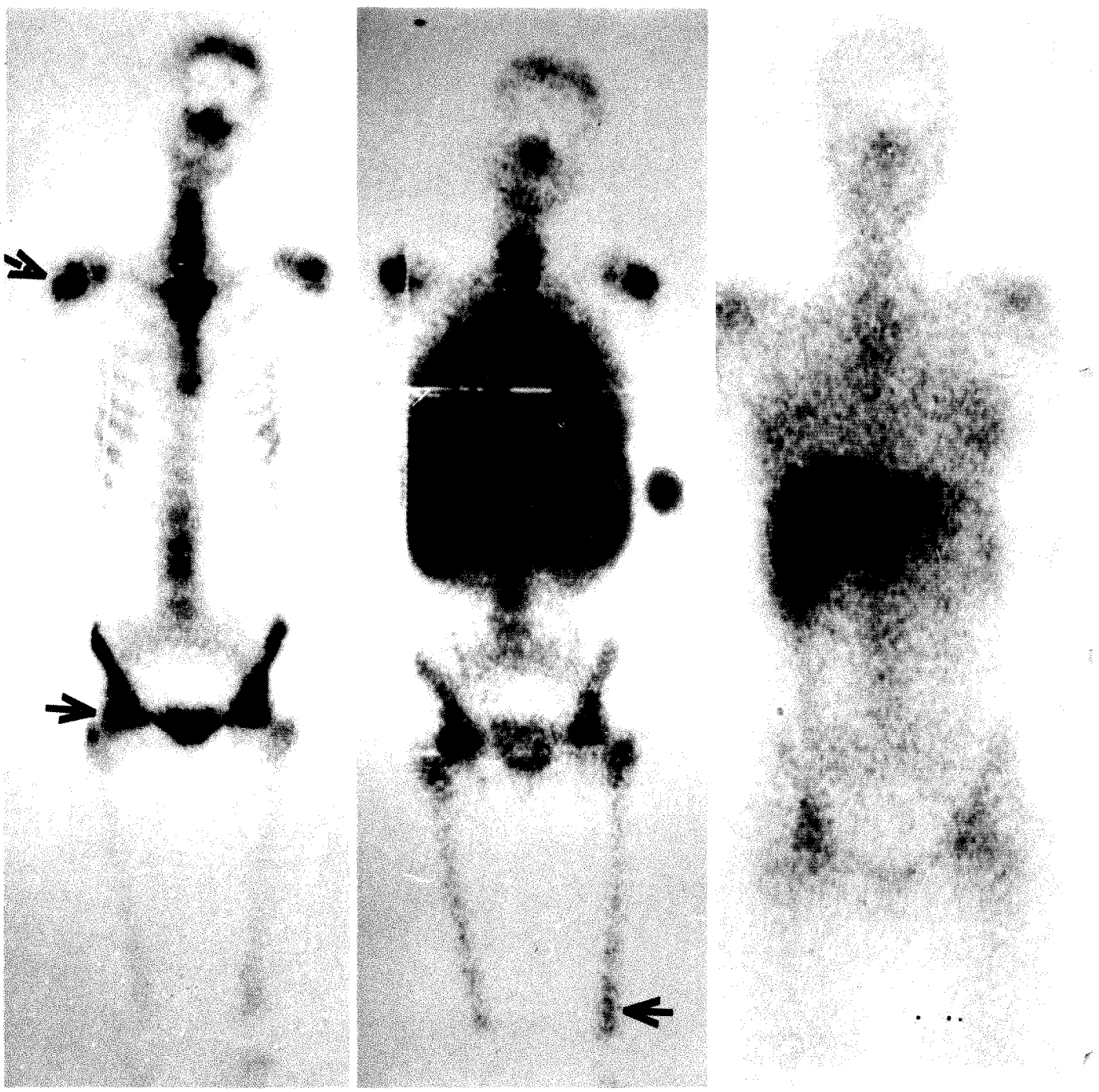

RESULTS

The bone scan revealed increased activity in both humeral and femoral heads as well as in the greater trochanters of the femurs bilaterally. It was otherwise normal. These findings correspond in location to the abnormalities seen on the roentgenograms but are less extensive (Fig 2, left). The bone marrow scan revealed a normal central marrow with no focal defects, although there was significant peripheral expansion of marrow elements into the long bones (Fig 2, center). The liver was normal in size but the tracer uptake was nonuniform. The spleen was enlarged. The gallium scan was essentially normal except for a very slight increased activity in the heads of the humeri and femurs corresponding to the abnormality seen in the bone scan. There was some tracer uptake in the breast. Notice that there is no splenic uptake in spite of the splenomegaly and possible splenic involvement (Fig 2, right).

COMMENT

Urticaria pigmentosa was first described by Nettleship in 1869.[4] Although at first believed to be a disease limited to the skin, it was later learned that multiple organs could be involved with this abnormal accumulation of mast cells.[5] Lymphadenopathy and hepatosplenomegaly are determined by the hyperplasia of tissue mast cells in these organs. Various series report an incidence of 20% to 50% in systemic mastocytosia with urticaria pigmentosa that first appears after the age of 10 to 12 years. Symtoms in these patients are believed to be due to the release of histamine and possibly other substances, eg, kinins, from the mast cells into the peripheral circulation.

Stark and co-workers[6] were the first to perform a bone biopsy in a case of urticaria pigmentosa with roentgenologically demonstrable bone lesions. They found large aggregates of tissue mast cells in the bone marrow spaces that they designated "mast cell granulomas of bone." The larger lesions showed resorption of the adjacent bony spicules. Around some of these lesions there was also evidence of new bone formation. They believed that these histologic changes consisting of bone resorption and bone production correlated with the roentgenologic findings of increased lucency and increased density of bone.

Further evidence to suggest that the bony changes observed roentgenographically are secondary to the proliferation of mast cells in the bone marrow came with the autopsy studies of Sagher and co-workers.[7]

Because our patient had bone lesions, we inferred that she had mast cell involvement of her bone marrow, which was later confirmed by marrow aspiration and biopsy. To investigate the effect marrow invasion would have on a bone marrow scan, this study was performed. Intuitively, we had expected one of two changes: (1) A hypoplastic central marrow (pelvis and spine) due to replacement by tissue mast cells and/or (2) "focal defects" in the central marrow image in the areas of mast cell proliferation. Instead we found a normal central marrow with peripheral marrow expansion. Peripheral marrow expansion into the long bones can be thought of as a "compensatory phenomenon" and is seen in diseases in which blood cell production is markedly increased (ie, hemolytic anemias) or in diseases in which infiltration or "atrophy" of the central marrow occurs.[8] It is possible that the central marrow infiltration by mast cells in this patient was sufficient to interfere with its hemopoietic function to a degree that made it necessary to reactivate peripheral marrow tissue to "compensate" for the decreased blood cell production. Being microscopic, these mast cell collections are probably not large enough to be visualized by bone marrow scanning as focal defects, with the presently available techniques. Moreover, mast cell proliferation was not enough at this time to replace sufficient marrow tissue to give a "hypoplastic central marrow" appearance on the scintigram.

Generally, areas of increased activity in a bone scan represent increased blood flow or mineral turnover such as in new bone formation.[9] Mast cell aggregates in the bone marrow give rise to local bone resorption and reactive bone formation. These active areas of reactive bone formation are visualized in the bone scan.

The roentgenographic abnormalities were more striking and extensive than the scintigraphic changes present in our patient. This is unusual as bone scanning is usually more sensitive than roentgenograms in the detection of some bony lesions.[9] It may be that only a part of the roentgenographic abnormality is associated with active reactive bone formation at the time of the bone scan and, therefore, bone scanning may be less sensitive than roentgenograms to detect the full extent of bony lesions of systemic mastocytosis.

Gallium was first introduced as a bone scanning agent.[9] By serendipity, it was later found to accumulate in some malignant neoplasms, and at present it is frequently used for the detection of neoplasia. Considering mastocytosis to be a neoplastic disease, we performed a gallium scan in our patient to determine if there would be localized accumulation of tracer in the sites of bony involvement. There was a faint increased concentration of ^{67}Ga in the same areas that were abnormal by bone scanning, namely, both humeral and femoral heads. This abnormal tracer concentration is not near the extent of accumulation we usually see in malignant lesions. The faint increase in ^{67}Ga accumulation is probably a result of the tracer's function as a bone scanning agent (concentrated in the areas of increased bone formation) and not a result of its properties for visualizing a mass of cellular proliferation or infiltration.

These scintigraphic findings lend further support to the belief that mast cell marrow invasion is the cause for bony lesions in systemic mastocytosis. However, the findings themselves are nonspecific and maybe less sensitive than bone roentgenograms in the detection of bony lesions in this disease.

Obviously, it would be desirable to have more cases of systemic mastocytosis studied with these radionuclide scintigraphic techniques before judging their applicability. For the present, roentgenograms provide the best resolution and reliability for imaging bone lesions in patients with systemic mastocytosis.

References

1. Sagher F, Cohen C, Schorr S: Concomitant bone changes in urticaria pigmentosa. *J Invest Dermatol* 18:425-432, 1952.
2. Poppel MH, Gruder WF, Silber R, et al: The roentgen manifestations of urticaria pigmentosa (mastocytosis). *Am J Roentgenol* 82:239-249, 1959.
3. Bendel WL, Race GJ: Urticaria pigmentosa with bone involvement. *J Bone Joint Surg* 45:1043-1056, 1963.
4. Nickel WR: Urticaria pigmentosa; mastocytosis: Consideration of various manifestations. *Arch Dermatol* 76:476-495, 1957.
5. Howard CWH, Scott RB: Urticaria pigmentosa with visceral and skeletal lesions. *Q J Med* 28:459-470, 1959.
6. Stark E, Van Buskirk FW, Daly JF: Radiologic and pathologic bone changes associated with urticaria pigmentosa: Report of a case. *Arch Pathol* 62:143-148, 1956.
7. Sagher F, Liban E, Ungar H, et al: Urticaria pigmentosa bone involvement: Mast cell aggregates in bones and myelosclerosis found at autopsy in a case of dying monocytic leukemia. *J Invest Dermatol* 27:355-368, 1956.
8. Wagner HH Jr (ed): *Principles of Nuclear Medicine*. Philadelphia, WB Saunders Co, 1968.
9. Blahd WH (ed): *Nuclear Medicine*, ed 2. New York, McGraw-Hill Book Co Inc, 1971.

Nodular Primary Localized Cutaneous Amyloidosis

Thomas A. Chapel, MD; Donald J. Birmingham, MD; Yolanta E. Malinowski, MD

• An 83-year-old woman had nodular primary localized cutaneous amyloidosis. Several anetodermic, bullous-appearing lesions were observed. Biopsy showed massive amyloid deposition with destruction of elastic and collagen fibers, but no bullous formation. It was concluded that the amyloid deposition induced anetodermic changes creating the clinical appearance of bullae.

(*Arch Dermatol* 113:1248-1249, 1977)

Nodular (tumefactive) primary localized cutaneous amyloidosis (NPLCA) is a rare condition. The skin-limited amyloid deposits appear as single or multiple pink to yellowish-brown nodules on the face, extremities, trunk, or genitals.

Recently we saw an elderly woman with NPLCA. Her nodular and bullous-appearing anetodermic lesions posed a perplexing diagnostic problem. The rarity of this condition and the unusual lesions noted in this patient prompted the following report.

REPORT OF A CASE

An 83-year-old woman was hospitalized because of a traumatic fracture of the right proximal humeral metaphysis, dehydration, and uremia. The patient's prior health had been good, and her medical history did not indicate chronic illnesses.

Examination showed a lethargic, dehydrated, somewhat senile woman. Her right arm was immobilized in a canvas splint. Large contusions were present on the right anterior section of her chest, and the deltoid and posterior scapular regions.

Abnormal physical findings included bronchial breath sounds and coarse rales over the left inframammary and left infra-axillary areas. Heart sounds were normal, and the cardiac point of maximal impulse was palpable 13 mm lateral to the midclavicular line in the fifth intercostal space.

Cutaneous examination revealed lesions of differing appearance. Shiny, wax-like, pinkish-tan to brownish-yellow, ovoid, firm nodules and plaques were present on the abdomen in the distribution of thoracic segmental nerves, T-9 to T-11. Purpura were noted in several lesions.

Six ovoid, brownish anetodermic plaques, ranging in size from 2 × 1.5 cm to 2 × 5 cm, were noted on the left side of the abdomen medial to the anterior superior iliac spine (Fig 1). The lesions suggested flaccid bullae, but fluid could not be aspirated. The overlying epithelium was easily lifted between the thumb and index finger. The elevated skin had a peculiar doughy feel and, upon release, was slow to return to normal contour. One of these lesions had a central ulceration covered with a hemorrhagic crust.

Determination of serum electrolytes, serum immunoglobulin electrophoresis, blood glucose level, VDRL, antinuclear antibody, rheumatoid arthritis latex fixation, creatine phosphokinase, and creatinine were within normal limits. Blood cultures were negative, and Bence-Jones protein levels were normal. Abnormal test results included a urine culture that grew appreciable numbers of *Escherichia coli*, an elevated lactic dehydrogenase level of 300 units/ml, uric acid 8.0 mg/100 ml, BUN 76 mg/100 ml, and alkaline phosphatase 22.5 units/ml. The hemoglobin level was 10.6 gm/100 ml, and WBC 11,900/cu mm.

An ECG showed evidence of a recent myocardial infarction. Roentgenographic examination of the chest showed slight cardiomegaly and a tortuous aorta with calcifications. A pneumonic infiltrate was present in the lingular segment of the left upper lobe.

Four-millimeter punch biopsies were obtained from both a nodular and a bullous-appearing anetodermic lesion. Sections of each were stained by the Congo red, hematoxylin-eosin, acid orcein-Giemsa, and crystal violet techniques. Both the tumefactive and anetodermic specimens had epidermal thinning with loss of the rete ridges (Fig 2). Bullae were not observed in either specimen. The papillary and subpapillary layers of both were disrupted by clumps of amorphous material that stained red with Congo red, light blue with orcein-Giemsa, and purple with crystal violet (Fig 3). Only remnants of elastic fibers remained and persisting collagen bundles stained purple in the crystal violet sections. The latter gave the impression that the collagen fibers were either impregnated with amyloid or transformed into amyloid without changing their morphologic characteristics. The walls of large vessels in the deep cutaneous plexus were thickened by metachromatically staining amorphous material.

The deeper dermis of the tumefactive specimen looked almost normal, although many collagen bundles appeared purple with the crystal violet stain. Most elastic fibers were preserved and sweat glands appeared normal.

Clumps of metachromatically staining material, together with metachromatically staining collagen bundles, filled the lower dermis of the anetodermic lesion. Elastic fibers were sparse, and those that remained were retracted and coiled. A few distorted sweat glands, surrounded by amorphous material, were observed in the upper half of the specimen. The diagnosis was cutaneous amyloidosis.

The patient became more alert with rehydration. The pneumonia cleared with aqueous penicillin G potassium, and her urinary infection was controlled with orally administered ampicillin sodium. She was ultimately discharged to a nursing home. A rectal biopsy for amyloid was not performed because of the patient's age and physical condition.

COMMENT

Cutaneous lesions of systemic amyloidosis and NPLCA are histologically indistinguishable. Both show amyloid infiltrating the deeper corium. Tumefactive lesions similar to NPLCA have

Accepted for publication June 14, 1976.

From the Department of Dermatology and Syphilology, Wayne State University School of Medicine, and the Detroit General Hospital, Detroit.

Reprint requests to Department of Dermatology, 540 E Canfield Ave, Detroit, MI 48201 (Dr Chapel).

Fig 1.—Bullous-appearing anetodermic lesions.

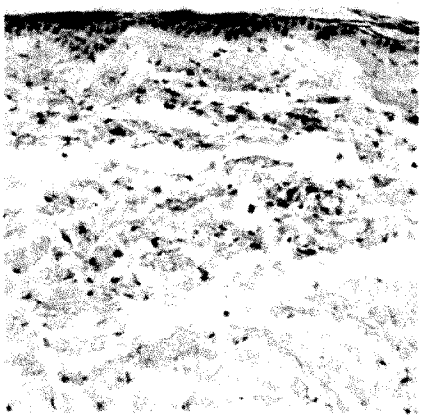

Fig 2.—Massive amyloid deposition in bullous-appearing anetodermic lesion (hematoxylin-eosin, original magnification, ×180).

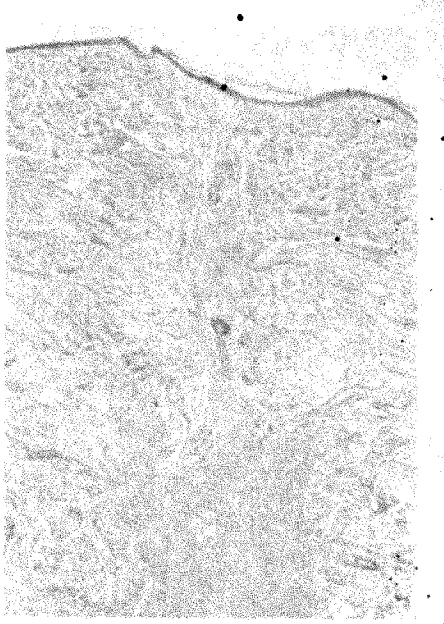

Fig 3.—Tumefactive lesion with Congo red stain (Congo red, ×20).

been described in systemic amyloidosis.[1,2] Therefore, NPLCA can be distinguished from certain types of systemic amyloidosis only after a thorough physical examination and laboratory evaluation has ruled out extracutaneous amyloid deposits. In our patient, physical and laboratory examinations showed no evidence of extracutaneous amyloid deposits or an underlying myeloma. Therefore, we believe the diagnosis is best considered NPLCA.

The case is morphologically interesting because of the prominent bullous-appearing anetodermic lesions. Blisters have been reported in association with primary systemic amyloidosis and amyloidosis associated with multiple myeloma.[3-6] Muller et al[6] removed a biopsy specimen from a frictionally produced hemorrhagic bulla in a patient with systemic amyloidosis and probable multiple myeloma. Bulla formation was due to fracture of the amyloid within the papillary dermis.

The epidermis overlying lesions of NPLCA may appear atrophic, anetodermic, or bullous. However, despite a bullous clinical appearance, histologic bullae have not been noted in patients with NPLCA.[7]

Chow and Burns[8] described a 55-year-old man with a nine-year history of flaccid bullae and waxy amyloid plaques. Neither multiple myeloma nor systemic amyloid deposits were found by extensive laboratory investigations. However, elevated gamma globulins, an elevated IgA, and a positive antinuclear factor led them to conclude that the patient had primary systemic amyloidosis. The histopathologic description reported massive amyloid deposition, but no bullous formation.

Reuter and Becker[9] reported a case of colloid degeneration of the skin in an otherwise healthy 75-year-old woman. The patient had a five-year history of pink papules and orange-colored nodules and plaques that began on the chest and spread over the trunk and onto the arms and thighs. Several anetodermic, bladder-like protuberances were observed on the arms and abdomen.

Brownstein and Helwig[7] found the clinical course and laboratory and histologic data in both these cases consistent with NPLCA. The bladder-like projections described by Reuter and Becker[9] and the flaccid bullae reported by Chow and Burns[8] are suggestive of the bullous-appearing lesions seen in our case.

The histologic sections from our patient's anetodermic lesion showed greater destruction of the deep dermal architecture than was observed in the tumefactive specimen. It appears that the severe anetodermic changes were produced by full dermal destruction of elastic and collagen fibers. This created the clinical appearance of bullae. However, the true nature of the process was suggested by the presence of purpura in adjacent plaque and nodular lesions. The association of spontaneous or traumatically induced hemorrhage in amyloid deposits is well known.

This investigation was supported by the Detroit General Hospital Research Corp. Amir H. Mehregan, MD, and Hermann Pinkus, MD, confirmed the diagnosis of cutaneous amyloidosis. Dr Mehregan also provided Fig 2.

Nonproprietary Name and Trademarks of Drug

Ampicillin sodium—*Alpen-N, Amcill-S, Omnipen-N, Penbritin-S, Polycillin-N, Principen/N.*

References

1. Potter BS, Johnson WC: Primary localized amyloidosis cutis. *Arch Dermatol* 103:448-451, 1971.

2. Brownstein MH, in discussion, Gibbs RC: Tumefactive amyloidosis. *Arch Dermatol* 104:213-214, 1971.

3. Reimann HA, Sahyoun PF, Chaglassian HT: Primary amyloidosis: Relationship to secondary amyloidosis and report of a case. *Arch Intern Med* 93:673-686, 1954.

4. Baber MD: Amyloid macroglossia: Report of a case. *Lancet* 1:210-211, 1947.

5. Moschcowitz E: The clinical aspects of amyloidosis. *Ann Intern Med* 10:73-88, 1936.

6. Muller SA, Sams M, Dobson RL: Amyloidosis masquerading as epidermolysis bullosa acquisita. *Arch Dermatol* 99:739-747, 1969.

7. Brownstein MH, Helwig EB: The cutaneous amyloidoses. *Arch Dermatol* 102:8-19, 1970.

8. Chow C, Burns RE: Bullous amyloidosis: A case report. *Arch Dermatol* 95:622-625, 1967.

9. Reuter MJ, Becker SW: Colloid degeneration (collagen degeneration) of the skin. *Arch Dermatol* 46:695-704, 1942.

Apocrine Cystadenoma of the Penile Shaft

Ralph F. Powell, MD; Charles H. Palmer, MD; Edgar B. Smith, MD

• What is to our knowledge the first apocrine cystadenoma reported on the penile shaft is described. Of 96 previously reported apocrine cystadenomas, more than 90% were located on the face, ears, or scalp; the remainder occurred on the chest, axilla, or prepuce. Apocrine cystadenoma should be considered in the differential diagnosis of solitary blue, gray, or flesh-colored cystic nodules in those areas.

(*Arch Dermatol* 113:1250-1251, 1977)

Apocrine cystadenoma (hidrocystoma) is a benign hamartoma derived from the secretory segment of apocrine sweat glands. It usually occurs singly as a smooth, dome-shaped translucent nodule that possesses a flesh colored or a gray or bluish black hue. Characteristic histologic[1] and ultrastructural features[2] have been described. This tumor is usually found on the face, and occasionally it is found on the ears or scalp, although uncommonly it is seen elsewhere. Because few of these lesions have been recorded on other parts of the skin, we are reporting an apocrine cystadenoma that occurred on the penile shaft.

REPORT OF A CASE

A 23-year-old uncircumsized man was referred to us for treatment of a penile "wart." On the ventral aspect of the penile shaft he had an asymptomatic cystic lesion that had been present for two years. The mass was flesh colored with a slight bluish hue and measured 4 × 5 mm (Fig 1). Preoperative diagnoses included apocrine cystadenoma, epidermoid inclusion cyst, and mucus retention cyst. The lesion was excised for histologic evaluation.

HISTOPATHOLOGY

The specimen consisted of a cystic soft tissue lesion measuring 1.3 × 0.3 × 0.2 cm. Examination of the microscopic section revealed a normal epidermis without follicles or other epidermal appendages. Within the dermis were several cystic spaces lined with simple to pseudostratified columnar epithelium and containing proteinaceous debris and homogeneous eosinophilic round bodies of varying size (Fig 2). Serial sectioning demonstrated that the spaces formed a single cyst. In some sections, the cyst wall consisted of a simple sheath of secretory epithelium; in other areas, papillary projections of the cyst wall were contained within the central cavity. The columnar epithelium contained focal areas of decapitation secretion, and a myoepithelial layer was seen peripheral to the secretory cells (Fig 3). With special stains, PAS-

Fig 1.—Apocrine cystadenoma of penile shaft.

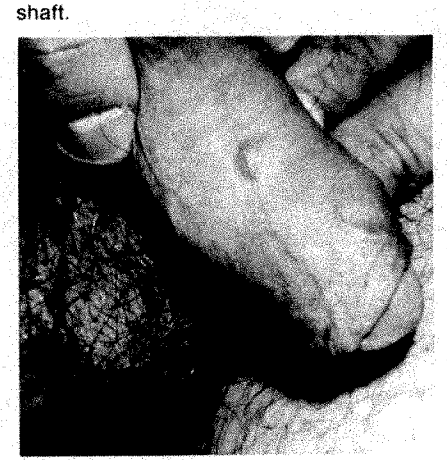

Accepted for publication Nov 24, 1975.

From the Veterans Administration Hospital (Dr Smith), and the Division of Dermatology (Drs Powell and Palmer), University of New Mexico School of Medicine, Albuquerque. Dr Powell is now in private practice in Albuquerque. Dr Palmer is now a Fellow in Pathology at the University of Minnesota School of Medicine, Minneapolis.

Reprint requests to Division of Dermatology, University of New Mexico School of Medicine, Albuquerque, NM 87131 (Dr Smith).

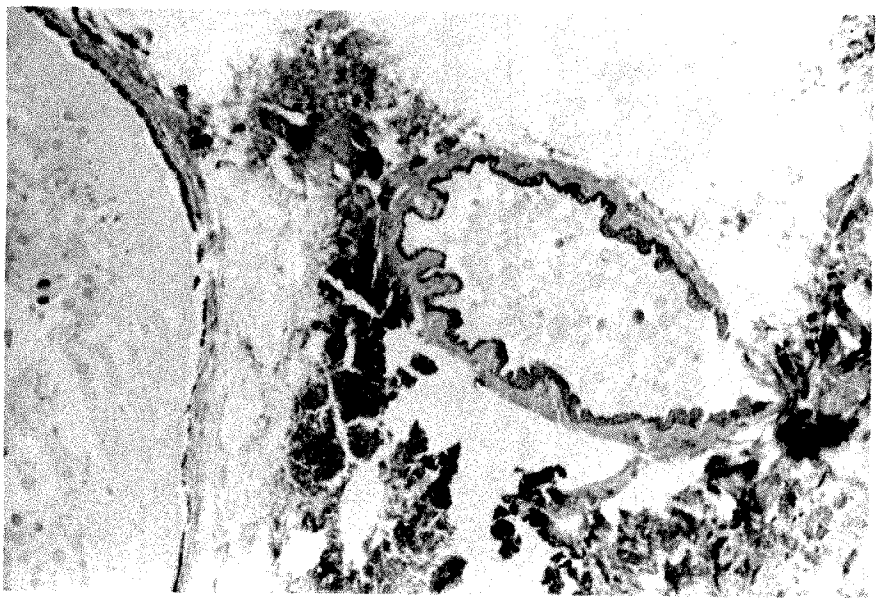

Fig 2.—Low-power magnification of lesion shown in Fig 1. Cystic spaces filled with proteinaceous material. Simple cyst wall sheath (at left) and papillomatous cyst wall (at right) (×30).

Fig 3.—Columnar epithelium with decapitation secretion (×250).

positive, diastase-resistant granules were seen in the secretory cells.

COMMENT

In our review of the literature, we found that apocrine cystadenoma was rarely reported as occurring in areas other than the head. In one study of 17 apocrine cystadenomas, all of the lesions were on the face or scalp and most of them were on the cheeks.[1] Several case reports have additionally described one or several lesions on the face[3-5] or scalp,[6] some in association with nevus sebaceous.[7,8] In their large series of 50 apocrine cystadenomas in 42 patients, Smith and Chernosky[9] found only two lesions not located on the head. Both occurred on the anterior chest. Earlier, Holder et al[10] reported the first such tumor on the trunk, a giant apocrine cystadenoma, and also on the anterior chest. One such tumor has been reported in the axilla[11] and three apocrine cystadenomas have been reported on the prepuce.[12,13] Apocrine cystadenomas of the prepuce may be less rare than these two reports would suggest. A pathologist at our institution has seen several of these tumors, heretofore unreported, on routine examination of the products of circumcision (oral communication, William C. Black, MD, January 1975). Reluctance to have an asymptomatic penile lesion examined or to have a biopsy done also may account for the lack of reports of these lesions occurring there. Notwithstanding 96 previously reported cases, we found only seven apocrine cystadenomas (less than 7%) to occur below the neck, ie, on the anterior chest, axilla, or prepuce.

The tumor's bluish hue prompted consideration of apocrine cystadenoma in our differential diagnosis. About 50% of all reported cases of these tumors were various shades of blue, often being bluish black and occasionally grayish blue. The remainder were translucent or clear, pearly, skin color, or brown.

Apocrine glands are encountered on the face, scalp, axillae, around the nipples, the anogenital region, and as modified glands in the external ear canals, eyelids, and breast.[14] It is in these regions that apocrine cystadenomas should most commonly occur and must be considered in the clinical differential diagnosis of cystic lesions, particularly if they exhibit a bluish coloration.

References

1. Mehregan AH: Apocrine cystadenoma: A clincopathologic study with special reference to the pigmented variety. *Arch Dermatol* 90:274-279, 1964.
2. Gross BG: The fine structure of apocrine hidrocystoma. *Arch Dermatol* 92:706-712, 1965.
3. Tavares A: Degeneresccence simulée d'un naevus pigmentaire par coexistence d'un hidrocystome. *Ann Anat Pathol* 7:390-392, 1930.
4. Shelley WB, Levy EJ, Weidman FD: Apocrine sweat retention in man: III. Apocrine retention cysts. *Arch Dermatol* 72:171-172, 1955.
5. Monfort J: Les hidrocystomes noirs. *Sem Hop Paris* 38:328-331, 1962.
6. Sutton RLJ: *Diseases of the Skin.* St Louis, CV Mosby Co, 1956, p 1171.
7. Mehregan AH, Pinkus H: Life history of organized nevi: Special reference to nevus sebaceous of Jadassohn. *Arch Dermatol* 91:574-588, 1965.
8. Jones EW, Hexl T: Nevus sebaceous: A report of 140 cases with special regard to the development of secondary malignant tumors. *Br J Dermatol* 82:99-117, 1970.
9. Smith JD, Chernosky ME: Apocrine hidrocystoma (cystadenoma). *Arch Dermatol* 109:700-702, 1974.
10. Holder WR, Smith JD, Mocega EE: Giant apocrine hidrocystoma. *Arch Dermatol* 104:522-523, 1971.
11. Lund HZ: *Tumors of the Skin.* Atlas of Tumor Pathology, Armed Forces Institute of Pathology, 1957, section 1, pt 2, pp F2-150-F2-151.
12. Ahmed A, Jones AW: Apocrine cystadenoma: A report of two cases occurring on the prepuce. *Br J Dermatol* 81:899-901, 1969.
13. Grinspan D, Abulafia J, Jaimovich L, et al: Hidrocystoma. *Dermatol Iber Lat Am* 10:397-408, 1968.
14. Hurley HJ, Shelley WB: *The Human Apocrine Sweat Gland in Health and Disease.* Springfield Ill, Charles C Thomas Publisher, 1960.

Allergic Contact Dermatitis From Sunscreen Preparations Complicating Photodermatitis

Greg Thompson, MD; Howard Maibach, MD; John Epstein, MD

• **Two men with known histories of photosensitivity had apparent exacerbations of their dermatoses. Patch-testing showed the presence of allergic contact sensitivity to the sunscreens that they were using. The clinical distribution patterns of adverse reactions to sunscreens naturally simulate sun-induced reactions, thus providing clinical problems that require evaluation by both patch and photo-patch tests. These findings emphasize that allergic contact or photocontact dermatitis from sunscreens that are used for prophylaxis of photodermatitis can actually complicate or aggravate the preexisting state of photodermatitis for which the sunscreens are prescribed.**
(*Arch Dermatol* 113:1252-1253, 1977)

Of the several modalities available for control of photosensitivity dermatoses, protection from sunlight is the single most important. Few patients are able to spend their lives totally avoiding solar rays. Therefore, the use of sunscreen agents is often mandatory during daylight hours.

Accepted for publication July 23, 1976.

From the Department of Dermatology, University of California School of Medicine, San Francisco.

Reprint requests to University of California Hospital, San Francisco, CA 94143 (Dr Maibach).

Although there is no cosmetically acceptable sunscreen affording complete protection, some have gained considerable acceptance in the treatment of persons with photosensitivity. Among the more popular and widely used compounds are aminobenzoic acid and its esters, and the substituted benzophenones.

We describe a photosensitive patient who developed an allergic eczematous contact dermatitis to a sunscreen containing aminobenzoic acid esters and another patient who reacted to a benzophenone sunscreen.

REPORT OF CASES

CASE 1.—A 62-year-old white man with psoriasis of ten years' duration was otherwise well until March 1974 when he developed an erythematous eruption involving the dorsa of his hands, face, and neck. He felt that sunlight was responsible for the eruption. His physician prescribed 0.1% triamcinolone acetonide cream, a lubricating lotion, and a sunscreen containing a benzophenone. The dermatitis gradually worsened during the ensuing five months. He was referred for patch, photo-patch, and photosensitivity testing. The patient was in excellent health except for his cutaneous problems and was taking no systemic medication. Pertinent physical findings at that time included an erythematous eczematous eruption of the face, V of the neck, and dorsa of the hands. In addition, he had classical psoriatic plaques on the elbows, knees, presacral area, and anterior portion of his thighs.

Laboratory examination yielded normal findings for CBC, urinalysis, and chemical analyses of the blood. An antinuclear antibody test was negative at less than 1:10 dilution.

The routine series of the International Contact Dermatitis Research Group (ICDRG), and patch tests for several sunscreens were applied to the upper back with A1 R test; phototesting was initiated. The grading of reactions was recorded according to the ICDRG system.[1] When seen for a 48-hour patch-test evaluation, a severe exacerbation of the dermatitis over the face and dorsa of the hands was noted. Forty-eight-hour patch-test examination showed a 2+ reaction with and without light exposure to the benzophenone sunscreen formulation. The active compounds,

Active compounds of benzophenone sunscreen, oxybenzone, and deoxybenzone gave 2+ reactions at 48 hours when used alone at product concentrations.



oxybenzone and deoxybenzone, at product use concentration, gave 2+ reactions (Figure). Patch-testing with these two benzophenones in ten adults produced negative results.

It was learned subsequently that the patient had applied the benzophenone-containing sunscreen to his face and hands on the same day that the initial patch tests were applied.

Final results of photosensitivity testing on normal skin by means of the repeated exposure technique to UVB radiation revealed a papular reaction at the test site that was histologically consistent with a polymorphous light eruption as described by Epstein.[2]

Case 2.—A 62-year-old white man with a history suggestive of a photosensitive dermatitis since 1960 was initially seen in 1968 when testing revealed positive patch-test reactions to Caine mix and positive photo-patch test reactions to tribromosalicylanilide (TBS) and tetrachlorosalicylanilde (TCSA). A positive photosensitivity test by means of the repeated exposure technique was consistent with polymorphous light eruption.[2] Over the ensuing six years he experienced several exacerbations of his photodermatitis that were successfully treated with topical and systemic corticosteroids; otherwise his eruption was well controlled with the use a benzophenone-containing sunscreen and topically applied corticosteroids. He was taking no other systemic medications.

In July 1974 he experienced another flare of his dermatitis after working in the sun and was given prednisone, 30 mg daily, to take orally. One week later he was changed from a benzophenone to an aminobenzoic acid ester sunscreen. Approximately ten days later, after working a full day in the bright sunlight, he developed a severe exacerbation of the dermatitis over his face and hands. At this time he was referred for further evaluation and treatment.

On examination, the patient exhibited an acute eczematous dermatitis of the face, V of the neck, and dorsa of the hands. He was treated with prednisone, 60 mg orally, daily; cool tap water compresses; and topical fluocinonide 0.05% cream. When the eruption subsided and the patient had discontinued systemic corticosteroids, therapy patch tests revealed positive reactions to Caine mix and to the aminobenzoic acid ester sunscreen. Photo patch-test and regular patch-test reactions were positive to TCSA and the octyl dimethyl and amyl dimethyl components of aminobenzoic acid sunscreen; photosensitivity testing with UVB rays produced a reaction clinically and histologically consistent with a polymorphous light eruption.

COMMENT

Although a few reports of allergic contact dermatitis from aminobenzoic acid have been published[3-6] and its potential as a sensitizing agent is well-recognized,[7] the same is not true for the benzophenones. Indeed, we could find only one report of a patient who developed contact dermatitis from a benzophenone.[8] In view of the widespread use of these agents, it is assumed that their sensitizing capacity is relatively small.

Predictive contact sensitization assays were not extensively employed when aminobenzoic acid was originally used. Kligman, using the maximization method, assayed 20% aminobenzoic acid in petrolatum and failed to sensitize any of 25 subjects[9]; however, we sensitized three of 200 men to 15% aminobenzoic acid in petrolatum, using the Draize human sensitization assay (unpublished observations). Our experience suggests that sensitization, at least in predictive assays, depends on concentration and vehicle.[10] The higher the concentration, the greater the likelihood of sensitization. Petrolatum, although an excellent vehicle for many diagnostic allergens, may not be so useful for predictive testing of aminobenzoic acid. We have no predictive assay data to demonstrate whether there is a difference in contact sensitization potential from aminobenzoic acid compared to its esters.

In the case of the first patient, we demonstrated positive patch-test responses to the finished product, and to oxybenzone and deoxybenzone. Patch-testing of the finished product in 100 control subjects revealed no positive reactions, suggesting that the formulation was appropriate for patch-testing (unpublished observations).

The second patient was tested with the final formulation and not with the aminobenzoic acid esters. It is assumed, but not documented in this patient, that sensitization was to the aminobenzoic ester and not to a vehicle ingredient. One hundred control subjects did not react to the final formulation, suggesting that it was in an appropriate concentration for patch-testing (unpublished data).

Patel et al noted that none of 50 men tested with a 10% concentration of 2-hydroxy-4-n-octoxybenzophenone developed evidence of either an irritant or allergic reaction.[11] Forbes et al found that only one in more than 1,000 individuals developed erythema after the use of a lotion containing 2-hydroxy-4-methoxybenzophenone-5-sulfonic acid.[12] Changing the patient's sunscreen to 10% benzophenone in isopropyl alcohol resulted in no recurrence of the erythema, thus suggesting that the vehicle in the initial preparation was possibly responsible.

The only documented evidence of allergic contact dermatitis to the benzophenones is that provided by Ramsey et al.[8] Their patient demonstrated both immediate urticarial and delayed contact allergic reactions.

Our first patient demonstrated only delayed contact hypersensitivity and was reactive to both of the active compounds (oxybenzone and deoxybenzone) present in the sunscreen he had been using.

Recently, in another patient clinically diagnosed as having a polymorphous light eruption, we encountered another sunscreen sensitizer, cinoxate. In this patient, testing demonstrated that photoallergic contact dermatitis only occurred (unpublished observations). Cinnamate contact dermatitis is not rare.

The clinical implication of the finding of contact dermatitis to sunscreens in these patients is obvious. Since such patients frequently experience flares of their photosensitive dermatoses, it is important that the clinician not assume automatically that any exacerbation of a light eruption is due to sun exposure. The possibility of a superimposed contact or photocontact dermatitis from the patient's sunscreen must be considered.

Nonproprietary Names and Trademarks of Drugs

Cinoxate—*Giv Tan F; Sundare.*
Fluocinonide—*Lidex; Topsyn.*

References

1. Wilkinson D, Fregert S, Magnusson B, et al: Terminology of contact dermatitis. *Acta Dermatovenereol* 50:287-292, 1970.
2. Epstein JH: Polymorphous light eruption. *Ann Allergy* 24:397-404, 1966.
3. Baer RL, Meltzer L: Sensitization to monoglycerol paraminobenzoate. *J Invest Dermatol* 11:5, 1948.
4. Baer RL, Meltzer L: Sensitization to monoglycerol paraminobenzoate. *J Invest Dermatol* 12:31, 1949.
5. Satulksky EM: Photosensitization by monoglycerol paraminobenzoate. *Arch Dermatol* 62:711-713, 1950.
6. Goldman G, Epstein E: Contact photosensitivity dermatitis from sun-protective agent. *Arch Dermatol* 100:447-449, 1969.
7. Fisher AA: *Contact Dermatitis*, ed 2. Philadelphia, Lea & Febiger, 1973.
8. Ramsey DL, Cohen HJ, Baer RL: Allergic reactions to benzophenone. *Arch Dermatol* 105:906-908, 1972.
9. Kligman AM: Allergenic aromatic amines. *Arch Dermatol* 105:459-460, 1972.
10. Marzulli F, Maibach H: Use of graded concentrations in studying skin sensitization in man. *Food Cosmet Toxicol* 12:219-227, 1974.
11. Patel VM, Levinskas G, Shaffer C: Toxicity and metabolism of 2-hydroxy-4-n-octoxybenzophenone. *Food Cosmet Toxicol* 6:199-206, 1968.
12. Forbes MA, Brannen M, King WC: Benzophenones as a sunscreen. *South Med J* 59:321-324, 1966.

Localized Mycosis Fungoides With Prominent Epidermotropism

Woringer-Kolopp Disease

Walter F. Lever, MD

• **A patient had a single, large, sharply demarcated lesion on one leg. Under the mistaken diagnosis of malignant melanoma in situ, the lesion was excised and the area grafted in 1956. There has been no recurrence in the past 20 years. Histologic reevaluation led to a diagnosis of mycosis fungoides with pronounced epidermotropism of the cellular infiltrate. This case has close clinical and histologic resemblance with three cases published in Europe and regarded as a special form of reticulosis as first described by Woringer and Kolopp. Mycosis fungoides with marked epidermotropism is not always a benign localized disease but may be widespread and lead to death.**

(*Arch Dermatol* 113:1254-1256, 1977)

Infiltration of the epidermis by mycosis cells and formation of Pautrier microabscesses is a common histologic feature of mycosis fungoides. If the epidermal infiltrate is associated with a similar infiltrate in the dermis, the histologic diagnosis of mycosis fungoides generally can be made without difficulties. In some instances, however, there is such a marked affinity of the mycosis cells for the epidermis that they permeate the epidermis, whereas the dermis shows only a mild nonspecific inflammatory infiltrate. Often, the diagnosis of mycosis fungoides has not been made in such cases. Since Woringer and Kolopp[1] were the first authors to describe the predominantly epidermal distribution of mycosis cells, subsequent cases have been referred to either as reticulosis of Woringer and Kolopp,[2] pagetoid reticulosis of Woringer and Kolopp,[3] or as Woringer and Kolopp disease.[4] In this article, localized mycosis fungoides with marked epidermotropism of the cellular infiltrate is described. The patient was observed in 1956, but the proposed diagnosis was not made until after the above cited cases had been published.

Accepted for publication July 26, 1976.

From the Department of Dermatology, Tufts University School of Medicine and New England Medical Center, Boston.

Reprint requests to 280 Washington St, Brighton, MA 02135 (Dr Lever).

REVIEW OF THE LITERATURE

In the original case, published in 1939 by Woringer and Kolopp,[1] a single asymptomatic, polycyclic, infiltrated plaque, 6 to 7 cm in diameter, was present on the left wrist of a 13-year-old boy. It had a red, scaling surface, a slightly raised margin, and areas of slight atrophy in the center. The lesion had been present for six years. After slowly increasing in size during the first four years, the lesion had remained unchanged during the fifth and sixth year.

In the second case, reported in 1970 by Gisiger,[2] a 66-year-old man had, for at least seven years on his left wrist, an asymptomatic, slightly indurated, sharply demarcated plaque, 3 by 4 cm in diameter. The lesion was bluish red and scaling, had an elevated margin, and showed central fading. It thus showed great clinical resemblance to the lesion in Woringer and Kolopp's case.

In the third case, described in 1973 by Braun-Falco et al,[3] a somewhat larger lesion than that in each of the first two cases was present. For ten years, the 58-year-old man had had a slowly enlarging lesion on his right foot. At the time of the report, the lesion occupied the dorsa of all five toes as well as the entire dorsum of the foot and extended to the inner aspect of the ankle and the instep. The lesion was dark red at its periphery and possessed a sharp, polycyclic border with considerable induration. In some areas, the center of the lesion showed hyperpigmentation with atrophy and slight redness as evidence of spontaneous healing. There was an area, 5 × 5 cm in diameter, on the dorsum of the foot where a portion of the lesion had been excised two years before and had been covered by a split-thickness graft. No recurrence had taken place within the graft.

The histologic picture was the same in all three cases. The epidermis was acanthotic and showed numerous clear spaces of varying size, which contained, depending on their size, one or several nonepidermal cells. The number of clear spaces was greatest in the lower layers of the epidermis. Both Gisiger[2] and Braun-Falco et al[3] thought that they resembled Pautrier microabscesses. The infiltrating cells in the epidermis, both within and outside the clear spaces, showed a rather scanty pale cytoplasm and fairly monomorphous nuclei that were quite large, irregularly shaped, and hyperchromatic. Many nuclei had an atypical appearance. Braun-Falco et al[3] observed numerous mitotic figures in the infiltrating cells. In all three cases, the dermis contained only a mild nonspecific cellular infiltrate. On electron microscopic examination, Baun-Falco et al[3] found that the cells infiltrating the epidermis, in contrast with the keratinocytes, possessed no desmosomes.

REPORT OF A CASE

In 1946, when he was 28 years old, a man first noticed an asymptomatic lesion, 2.5 cm in diameter, on the inner aspect of his right ankle. The lesion gradually increased in size.

Clinical Examination

When first seen in 1956, a large erythematous lesion was present on the right

Fig 1.—Left, Appearance of lesion prior to excision. Large, erythematous patch is present showing an irregular border that is slightly raised in several areas. Right, Appearance of area following skin grafting.

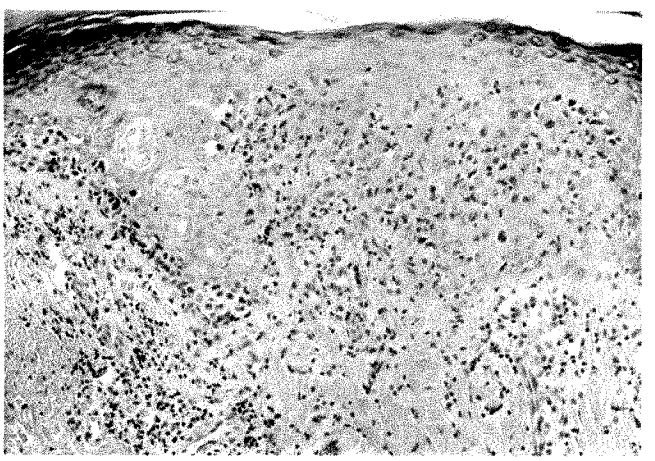

Fig 2.—Infiltrate of mononuclear cells is present in epidermis. It is densest in the lower portion of epidermis (hematoxylin-eosin, original magnification ×100).

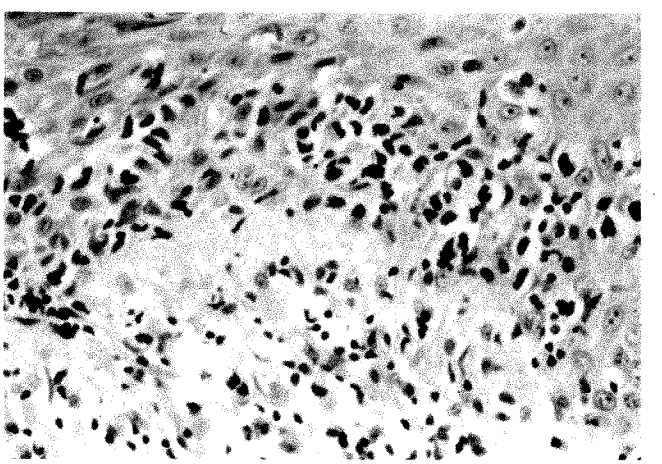

Fig 3.—Nuclei in epidermal infiltrate are deeply basophilic, irregular in shape, and variable in size and thus appear atypical. Many cells in epidermal infiltrate are surrounded by halo-like clear space. In several areas, one sees two or three nuclei lying closely together with a halo surrounding them (hematoxylin-eosin, original magnification ×200).

foot. It extended from the inner malleolus to the posterior aspect of the heel and along the medial side of the foot to the midportion of the sole. The entire lesion showed a sharp, irregular border that in several areas was slightly raised. In a few areas, especially on the medial aspect of the foot, the skin covering the lesion had an atrophic appearance. The appearance of the lesion is shown in Fig 1, left, and the appearance of the area following skin grafting is seen in Fig 1, right.

Histologic Examination

Four punch-biopsy specimens were taken. They all showed the same histologic picture. There was a moderate degree of acanthosis. An infiltrate of mononuclear cells was present in the epidermis. It was densest in the lower portion of the epidermis, especially in the basal cell layer (Fig 2). The nuclei of the infiltrating cells were deeply basophilic and irregular in shape and thus appeared atypical. Although variable in size, they were, in general, smaller than the nuclei of the keratinocytes of the epidermis (Fig 3). As a rule, the infiltrating cells had very little cytoplasm. Many of these cells were surrounded by a halo-like clear space; and, quite frequently, two or even three nuclei were arranged in nests and had a nonstaining halo at their periphery.

The dermis contained a mild to moderately severe chronic inflammatory infiltrate in which the nuclei did not show the deep basophilia and irregular shape seen in the epidermal infiltrate.

Course

After several conferences with members of the Department of Pathology at Massachusetts General Hospital, it was agreed that the histologic findings were consistent with a diagnosis of malignant melanoma in situ. The presence of halo-like clear spaces around individual cells and around nests of cells in the epidermis, and the atypical appearance of the nuclei in many of these cells seemed to support this diagnosis. It was thought advisable to excise the entire area.

The patient was referred to Bradford Cannon, MD, who on March 19, 1956, excised the entire lesion and covered the area with a split-thickness graft (Fig 1, right). The patient has been followed up at intervals until the present time. There has been no recurrence or any new lesions.

In 1973, when Braun-Falco et al[3] published their case in which there were atypical cells in the epidermis in pagetoid distribution, and also reviewed the two similar cases previously observed by Woringer and Kolopp[1] and by Gisiger,[2] it became evident that the case presented here belonged to the same category. It was thought most likely that the cells with atypical nuclei present throughout the epidermis in the three previous cases and in the present case represented mycosis cells.

COMMENT

The case just described and the cases reported by Woringer and Kolopp,[1] Gisiger,[2] and Braun-Falco et al[3] have a very similar appearance both clinically and histologically. Clinically, they were benign, showing a single cutaneous lesion that very slowly increased in size. Histologically, however, they did not appear benign but showed infiltration of the epidermis by atypical cells.

Not all cases that show the histologic picture first described by Woringer and Kolopp follow a benign course. Grosshans et al,[4] in their review of "Woringer-Kolopp disease," distinguished between a benign circumscribed form, as described by Woringer and Kolopp,[1] Gisiger,[2] and Braun-Falco et al,[3] and a disseminate form with lethal evolution, as described by Dupont et al[5,6] and by Mezzadra and Sapuppo.[7] Their own case seemed to lie between the circumscribed and the disseminate forms: their patient had had his eruption for ten years. Besides a large polycyclic, indurated plaque on his left thigh, the patient had disseminated plaques on his trunk with the same histologic appearance as the large lesion on his thigh. Grosshans et al[4] believed that the prognosis in their case was guarded.

It is of interest that the authors of the three circumscribed cases and of the three disseminate cases agreed that, histologically, the cells in the epidermis were atypical and that the disease represented a "reticulosis," ie, a lymphoma. However, none of the authors was willing to diagnose their case as mycosis fungoides. Gisiger,[2] although he found nests of infiltrating cells in the epidermis that in his opinion resembled Pautrier microabscesses, rejected the diagnosis of mycosis fungoides because of the pronounced permeation of the epidermis by the infiltrate and the absence of visceral lesions. Similarly, Braun-Falco et al,[3] in spite of the fact that he found the "pagetoid" permeation of the epidermis resembled Pautrier microabscesses, excluded the diagnosis of mycosis fungoides primarily because of the monomorphous appearance of the infiltrating cells in the epidermis, but also because of the disproportion between the severe epidermal and the very slight dermal infiltrate, and, furthermore, because of the presence of numerous mitoses in the epidermis. The term "epidermotropic reticulosis" was applied by Dupont et al[5,6] to their case.

The question arises as to why none of the above cited authors, even those describing the presence of Pautrier microabscesses, has been willing to consider mycosis fungoides as a diagnosis. The obvious reason is that in the past, the epidermotropic phenomenon, ie, diffuse epidermal invasion, has not been generally recognized as a manifestation of mycosis fungoides. This is somewhat surprising because the Pautrier microabscesses that generally are regarded as pathognomonic for mycosis fungoides are an epidermotropic phenomenon, and epidermotropic mycosis fungoides and mycosis fungoides with Pautrier microabscesses differ primarily in the degree to which epidermotropism is present. The other difference is that in epidermotropic mycosis fungoides, the dermal infiltrate is slight and nonspecific, and thus lacks the density and the presence of atypical nuclei seen in classical mycosis fungoides.

The existence of the epidermotropic phenomenon in mycosis fungoides has been emphasized recently by Ryan et al.[8] In biopsy specimens obtained from 36 patients with mycosis fungoides, they found a predominantly epidermal distribution of the mycosis cells in eight patients. They described the mycosis cell as having a large, dark-staining, irregular nucleus. Because of the relatively slight and nonspecific dermal infiltrate, Ryan et al[8] even considered the hypothesis that the mycosis cells might arise in the epidermis, possibly from Langerhans cells. This hypothesis, however, was weakened by the fact that on electron microscopic examination, they found no Langerhans granules in the mycosis cells.

In conclusion, affinity of the mycosis cells for the epidermis is a common phenomenon in mycosis fungoides. If the affinity is slight, Pautrier microabscesses are seen; but if the affinity is pronounced, epidermotropic mycosis fungoides results. Woringer-Kolopp disease either is identical with, or represents, a form of epidermotropic mycosis fungoides.

References

1. Woringer F, Kolopp P: Lésion érythémato-squameuse polycyclique de l'avant-bras évoluant depuis 6 ans chez un garçonnet de 13 ans. Histologiquement infiltrat intraépidermique d'apparence tumorale. *Ann Dermatol Syphiligr* 10:945-958, 1939.
2. Gisiger O: Zur Differentialdiagnose der von Woringer and Kolopp beschriebenen Retikulose. *Dermatologica* 140 (suppl 2):19-34, 1970.
3. Braun-Falco O, Marghescu S, Wolff HH: Pagetoide Retikulose: Morbus Woringer-Kolopp. *Hautarzt* 24:11-21, 1973.
4. Grosshans E, Hee P, Basset A, et al: La maladie de Woringer et Kolopp (réticulose cutanée épidermotropique; réticulose pagétoide). *Arch Belg Dermatol Syphiligr* 29:195-203, 1973.
5. Dupont A, Vandaele R: Réticulose cutanée épidermotrope accompagnée de lésions gastriques et vertébrales. *Arch Belg Dermatol Syphiligr* 15:267-274, 1959.
6. Smoes-Charles J, Dupont A: A propos d'une forme particulière generalisée de réticulose épidermotrope (maladie de Woringer et Kolopp). *Arch Belg Dermatol Syphiligr* 29:205-211, 1973.
7. Mezzadra G, Sapuppo A: Reticolo-istiocitosi cutanea subacutocronica con particolari aspetti clinico-istologici. *Giorn Ital Dermatol* 107:323-336, 1966.
8. Ryan EA, Sanderson KV, Bartak P, et al: Can mycosis fungoides begin in the epidermis? A hypothesis. *Br J Dermatol* 88:419-429, 1973.

CORRECTION

Name Misspelled.—In the Letter to the Editor, "Dapsone-Induced Neuropathy," published in the June ARCHIVES (113:845-846), the given name of the first author was misspelled. It should have read Louisa.

IN SKIN INFECTIONS, WHERE CLEANLINESS REQUIRES MORE THAN SOAP

BETADINE® Skin Cleanser

Degerms as it cleanses

'atients can use BETADINE Skin Cleanser to degerm and cleanse face, hands and body, gently and thoroughly—articularly when it is essential to prevent autoinoculation of new sites, as may be the case in infected acne pimples.

BETADINE Skin Cleanser, with its rich, golden lather, provides these advantages:

- Prompt, broad-spectrum microbicidal action—kills both gram-positive and gram-negative bacteria (including antibiotic-resistant strains), fungi, viruses, protozoa and yeasts.
- Maintains microbicidal activity in the presence of blood, pus and serum.
- Virtually nonirritating to skin and mucosa.*
- Nonstaining to skin and natural fabrics.

Supplied: 4 fl. oz. plastic bottles.

*In the rare instance of local irritation or sensitivity, discontinue use by the individual.

Purdue Frederick © COPYRIGHT 1976, THE PURDUE FREDERICK COMPANY

NORWALK, CONN. 06856 A8196 172076



We kept the potency and got rid of the smell.

Exsel (selenium sulfide) 2.5% lotion:

DESCRIPTION Contains: selenium sulfide 2.5%
with edetate disodium, bentonite, sodium linear alkylate sulfonate, alphaolefin sulfonate, glyceryl monoricinoleate, silicone, titanium dioxide, citric acid monohydrate, sodium phosphate monobasic, monohydrate, perfume and purified water.

ACTIONS The mechanism of action of selenium sulfide in seborrheic dermatitis is unknown.

INDICATIONS Selenium sulfide is indicated in the treatment of seborrheic dermatitis of the scalp, including dandruff.

CONTRAINDICATIONS The product should not be used by patients allergic to any of its components.

WARNINGS Safety for use in infants has not been established.

PRECAUTIONS 1. Chemical conjunctivitis may result if this preparation enters the eyes.
2. The product should be used with caution when acute inflammation or exudation is present as an increase in absorption may occur.

ADVERSE REACTIONS 1. Hair loss has been reported with the use of the product.
2. Discoloration of the hair may follow the use of selenium sulfide. This can be minimized by careful rinsing of the hair after treatment.
3. Oiliness of the hair and scalp may increase following the use of this product.

DOSAGE AND ADMINISTRATION Shake well before using.
1. Massage about 1 or 2 teaspoonfuls of the medicated shampoo into the wet scalp. Avoid contact with the eyes.
2. Allow product to remain on the scalp for 2 to 3 minutes.
3. Rinse the scalp thoroughly.
4. Repeat application and rinse thoroughly.
5. After treatment, wash hands well.
6. Repeat treatments as directed by physician.
The preparation should not be applied more frequently than required to maintain control of symptoms.

ACCIDENTAL ORAL INGESTION Selenium sulfide is highly toxic if ingested. Nausea and vomiting usually occur after oral ingestion. Treatment is to induce vomiting or if necessary perform gastric lavage, together with general supportive measures as required. Administer a purgative to hasten elimination.

HOW SUPPLIED In 4 fl. oz. plastic bottles. On prescription only.
Protect from heat. For external use only. Keep this and all medications out of the reach of children.

Herbert Laboratories/Dermatology Div. of Allergan Pharmaceuticals/Irvine, CA 92713



That's why CPT-4 can cut your claims reporting time at least 50%

Two seconds is all it takes to jot down a CPT five-digit numerical code for a medical, surgical, or diagnostic procedure.

Five seconds is the minimum time it takes to write out a description of the same procedure.

And that's the big reason **Physicians' CURRENT PROCEDURAL TERMINOLOGY** can dramatically reduce paperwork time for you or your administrative staff. Instead of having to write out descriptions of procedures on medical reports, you simply insert the CPT codes identifying the procedures. It's fast, simple, precise.

CPT provides a uniform coding system to accurately designate medical, surgical, and diagnostic services in terms that provide a uniform language among physicians, patients, and third parties. This new fourth edition of Physicians' CURRENT PROCEDURAL TERMINOLOGY is the most comprehensive and current system available and incorporates over 2,000 new and revised procedures. Each procedure is listed individually with a clear description and five-digit identifying code.

New CPT Updating Service is available at no additional cost. To insure your CPT stays up to date as new terminology is added, you can receive new and revised procedures on a regular basis. Updates are on self-adhering pages to be affixed to the pages they replace.

Order today! Buy two—one for yourself, one for your medical records clerk!

Order Department, OP-41 SJ9
American Medical Association
535 N. Dearborn St.
Chicago, Illinois 60610

Please send me _____ copy(ies) of PHYSICIANS' CURRENT PROCEDURAL TERMINOLOGY, 4th Edition. OP-41. ($12.00 per copy in U.S., U.S. Poss., Canada, and Mexico. $12.50 all other countries.)

☐ Send me information on CPT-4 magnetic computer tape versions.

Please enclose payment (payable to AMA) with order.

Please Print

Name_____

Address_____

City/State/Zip_____

what's best for the care of dry or premature aging or wrinkled skin... DUE TO EPIDERMA DEHYDRATION?

SUPPLIED: 2 OZ. TUBES

WRITE FOR SAMPLES

DOAK PHARMACAL CO., INC. WESTBURY, N.Y. 115

DISTRIBUTOR IN CANADA

Metastatic Basal Cell Carcinoma

Review, Pathogenesis, and Report of Two Cases

George R. Mikhail, MD; Linda P. Nims, MD; Alexander P. Kelly, Jr, MD; Donald M. Ditmars, Jr, MD; William R. Eyler, MD

• In 93 reported cases of metastatic basal cell carcinoma (BCC), 76 had spread through lymphatics or blood vessels. Two more cases are presented, bringing the total to 78. Metastasis to regional lymph nodes was the most frequent, followed in frequency by lungs, bones, and other organs. The size of the primary tumor, its site, its resistance to x-ray therapy, and the effects of radiation appeared to contribute to the occurrence of metastasis. However, in an appreciable number of cases, tumor dissemination was related to incomplete excision followed by immediate wound closure, particularly by grafting. It is recommended that wound grafting be delayed for at least six months after excision of large or recurrent BCC in order to assure complete removal.

(*Arch Dermatol* 113:1261-1269, 1977)

Metastasis from basal cell carcinoma (BCC) of the skin is rare. The first case was reported by Beadles in 1894.[1] By 1974, there were 91 cases on record,[2] and two more cases appeared in the 1975 literature,[3,4] bringing the total to 93.

In 1951, Lattes and Kessler[5] established the criteria for the diagnosis of metastatic BCC. These are summarized as follows: The primary tumor must be in the skin and not in a mucosa. Metastases must be demonstrated at a site that is distant from the primary lesion and should not result by direct extension. The histologic picture should be the same in both primary site and metastases. It should conform to that of BCC with no squamous cell carcinoma component. Applying these criteria, we found only 76 true examples of BCC that had spread through lymphatics or blood vessels. We excluded cases where metastasis to the lungs had resulted or could have resulted by direct implantation of tumor by aspiration. The cases are summarized in Table 1. Two more cases are described in the present report, bringing the total to date to 78. The pathogenesis, pathological findings, prognosis, and diagnostic aspects of this entity are reviewed and discussed.

Accepted for publication Oct 11, 1976.

From the Department of Dermatology (Drs Mikhail and Nims), the Division of Plastic Surgery (Drs Kelly and Ditmars), and the Department of Diagnostic Radiology (Dr Eyler), Henry Ford Hospital, Detroit.

Read before the 96th annual meeting of the American Dermatological Association, Inc, Williamsburg, Va, May 11, 1976.

Reprint requests to Department of Dermatology, Henry Ford Hospital, 2799 W Grand Blvd, Detroit, MI 48202 (Dr Mikhail).

REPORT OF CASES

CASE 1.—We first saw this 57-year-old man in January 1969. He gave a history of radiotherapy for acne in 1932 (age 19) and a "nonmalignant growth" that was excised from the left cheek in 1962. On June 8, 1964, he consulted a dermatologist because an ulcerated lesion had appeared in the same area. A biopsy obtained at that time was reported by Hermann Pinkus, MD, as follows: "Sections show basal cell epithelioma in the form of solid masses and nests surrounded by mesodermal stroma in the corium. The corium shows marked scar tissue type fibrosis." The lesion was treated electrosurgically. A hypertrophic scar developed but responded well to intralesional injections of triamcinolone acetonide (20 mg/ml). The tumor recurred and was again treated by electrosurgery on Jan 24, 1966. Histological examination was again done by Hermann Pinkus, MD, and his report read: "Sections show solid masses and elongated cords of basophilic epitheliomatous cells embedded in a cellular mesodermal stroma in the dermis." Review of the material from both biopsies led to the decision that the lesion was a sclerotic BCC. On June 5, 1967, a firm subcutaneous mass was noted over the left angle of the mandible. The patient was then advised to consult a surgeon, but he did not. He was referred to us in January, 1969. Examination showed an ulcerated, indurated lesion about 3 cm in diameter on the left cheek near the buccal commissure. A hard, cord-like mass extended posteriorly from this lesion, connecting it to a nodular mass in the parotid region (Fig 1). When admitted to the hospital on Feb 16, 1969, he weighed 58 kg, the hemoglobin value was 15%, and the serum alkaline phosphatase level was normal. Biopsy material showed sclerotic BCC identical with that found in earlier studies (Fig 2). The tumor was excised by nine microscopically controlled stages of the Mohs chemosurgery technique. The extensive postexcisional defect is shown in Fig 3. The left buccal wall, the lower part of the ear pinna, and a significant portion of the left parotid gland, including part of the facial nerve, had to be removed. The middle third of the left mandible and the mastoid bone were exposed. Nine reconstructive surgery operations were undertaken between March 6, 1969 and May 23, 1970. The result is shown in Fig 4. When seen in July 1970, the patient complained of pain that had been present in the left hip since April 1970. No clinical signs could be elicited, but radiological examination showed destruction of portions of the left iliac bone. A biopsy obtained from the bone on July 23, 1970, showed infiltration with BCC. The tumor was composed of small groups of darkly staining epithelial cells arranged in cords and irregular strands. Peripheral palisading was well marked in the tumor masses that were embedded in a fibrous and mucinous stroma that had replaced the bone marrow (Fig 5). During this hospital admission, the patient weighed 55.5 kg, the hemoglobin value was 14%, and the serum alkaline phosphatase and lactate dehydrogenase levels were elevated. Radiotherapy with high-energy ^{60}Co during August 1970, failed to relieve the pain. Lytic changes were found in the second lumbar vertebra in October 1970. In March 1971, his weight had dropped to 50 kg, and the serum

Table 1.—Proven Cases of Metastatic Basal Cell Carcinoma*

Reference	Primary Tumor Site	Interval Before Metastasis, yr	Previous Treatment: Excision No.	Previous Treatment: Excision Graft	Previous Treatment: X-ray Courses	Site of Metastasis	Metastasis Verified by	Survival After Metastasis
Beadles[1]	Face	15	1	NM	No	L nodes	Autopsy	2 yr
Costanza[2]	Thigh	10	1	Yes	No	L nodes Lungs	Biopsy	Unknown
Jimenez et al[3]	Vulva	NM	1	No	No	L nodes	Biopsy	Unknown
Curry et al[4]	Back	NM	NM	NM	NM	L nodes	Biopsy	Unknown
Lattes and Kessler[5]	Wrist	18	2	Yes	2	L nodes Lungs	Biopsy	4 yr
	Scalp	3	2	NM	No	L nodes Lungs	Biopsy	4 yr
Fordyce[6]	Nose	1	1	NM	1	L nodes	Biopsy	Unknown
Körbl[7]	Temple	1	1	Yes	1	L nodes	Biopsy	1 yr
Hazen[8]	Hand	NM	1	NM	1	L nodes	Biopsy	Unknown
	Nose	3	1	NM	1	L nodes	Biopsy	Unknown
	Axilla	4	1	NM	1	L nodes	Biopsy	Unknown
Finnerud[9]	Face	13	3	NM	2	L nodes	Biopsy	Unknown
	Face	30	1	NM	2	L nodes	Biopsy	Unknown
Spies[10]	Cheek	10	1	Yes	1	Lungs Liver Spleen Dura Bones	Autopsy	6 mo
Niles[11]	Finger	13	Mult	No	Mult	L nodes	Biopsy	4 yr
Louste et al[12]	Forehead	10	2	NM	No	L nodes	Biopsy	1 yr
De Navasquez[13]	Forehead	20	1	Yes	1	Lungs Bones	Autopsy	1 yr
Singer[14]	Face	5	No	No	No	Bones	Autopsy	2 mo
Amersback[15]	Scalp	3	3	Yes	No	L nodes	Biopsy	Unknown
Small et al[16]	Ear	8	4	NM	1	Lungs Liver Spleen	Autopsy	2 yr
	Ear	10	1	Yes	1	Lungs Liver Spleen Kidneys	Autopsy	1 yr
Eckhoff[17]	Scalp	20	3	Yes	1	L nodes	Biopsy	3 yr
	Canthus	14	4	No	1	L nodes	Biopsy	Unknown
Richter[18]	Scrotum	13	1	NM	1	Lungs	Autopsy	2 yr
Huntington and Levan[19]	Nose	23	No	No	Mult	Lungs	Autopsy	3 yr
Rank[20]	Forehead	12	2	Yes	2	L nodes	Biopsy	9 yr
Cotran[21]	Forehead	17	1	NM	1	L nodes	Biopsy	Unknown
	Preauricular	18	2	NM	Mult	L nodes Lung	Autopsy	1 yr
	Postauricular	5	1	NM	1	L nodes	Biopsy	4 yr
	Outer canthus	5	5	Yes	2	L nodes	Biopsy	Unknown
	Chin	5	7	Yes	2	L nodes	Biopsy	3 yr
	Nose	19	1	NM	2	L nodes	Biopsy	Unknown
	Scapula	45	Mult	Yes	Mult	Lungs Bone	Autopsy	1 yr
	Medial canthus	5	2	NM	1	L nodes	Biopsy	Unknown
	Scalp	1	No	No	No	L nodes	Biopsy	Unknown
Raitschev et al[22]	Scalp	20	1	Yes	No	L nodes	Biopsy	10 mo
Binkley and Rauschkolb[23]	Back	7	2	NM	No	L nodes	Biopsy	1 yr
Nelson et al[24]	Face	13	1	Yes	1	L nodes	Biopsy	10 mo
Dahlgren and Martensson[25]	Face	4	No	No	No	Liver	Autopsy	1 wk
Lewin[26]	Nose	10	1	Yes	1	L nodes	Biopsy	Unknown
Crawford and Joslin[27]	Scalp	9	No	No	No	Liver Pancreas Lungs Spleen Bone	Autopsy	2 mo

Table 1.—Continued

Reference	Primary Tumor Site	Interval Before Metastasis, yr	Previous Treatment: Excision No.	Previous Treatment: Excision Graft	Previous Treatment: X-ray Courses	Site of Metastasis	Metastasis Verified by	Survival After Metastasis
Conway and Hugo[28]	Ear	4	1	Yes	No	L nodes	Biopsy	9 yr
Jay[29]	Temple	Unknown	3	Yes	Mult	Lungs	Biopsy	Unknown
Stell et al[30]	Nasolabial	7	3	Yes	1	Lungs Bones	Autopsy	18 mo
Assor[31]	Nasolabial	6	4	NM	No	Bones	Autopsy	1 yr
	Scalp	3	3	NM	1	Bones	Biopsy	Unknown
Lakshmipathi and Hunt[32]	Scalp	10	2	Yes	1	Lungs Diaphragm Pericardium	Autopsy	3 yr
Coletta et al[33]	Leg	5	No	No	No	L nodes Bones Spleen Adrenals Liver Skin	Autopsy	2 yr
Taylor et al[34]	Scalp	33	No	No	No	Lung	Autopsy	Died during terminal surgery
Hirshowitz and Mahler[35]	Face	11	Mult	Yes	No	L nodes	Biopsy	Unknown
Rodermund and Cramer[36]	Face	Unknown	1	Yes	1	Lungs Liver	Autopsy	1 yr
Beretta and Molinari[37]	Eyelid	6	1	NM	1	Bone	Biopsy	1 yr
Wronkowski[38]	Nose	6	No	No	1	L nodes	Biopsy	9 yr
	Nose	2	No	No	1	L nodes	Biopsy	5 yr
	Chin	2	No	No	1	L nodes	Biopsy	Unknown
	Neck	7	No	No	1	L nodes	Biopsy	Unknown
	Ear	5	No	No	1	L nodes	Biopsy	2 yr
	Shoulder	1	1	NM	1	L nodes	Biopsy	3 yr
Chien[39]	Ear	7	1	Yes	2	Bones Lung	Autopsy	6 mo
Wermuth and Fajardo[40]	Nasolabial	3	Mult	Yes	1	Lung	Autopsy	11 mo
Cranmer et al[41]	Scalp	7	1	Yes	No	Femur	Biopsy	14 mo
Hall et al[42]	Chest	10	3	NM	No	Bone L nodes	Autopsy	1 yr
	Eyelid	22	Mult	NM	No	Bone Lung L nodes Dura	Autopsy	8 mo
Liu et al[43]	Arm	20	1	NM	1	Lung	Autopsy	2 mo
Mantell and Almeyda[44]	Scalp	15	3	Yes	1	Bones Lung	Biopsy	Unknown
	Shoulder	30	2	Yes	No	L nodes	Biopsy	Unknown
Mikhail et al[45]	Face	6	Mult	No	1	L nodes	Biopsy	6 yr
Harris and Libshitz[46]	Orbit & Nose	17	1	No	1	Bone	Autopsy	35 mo
	Mastoid	2	1	Yes	1	Lung	Biopsy	Unknown
Cornelius[47]	Nose	15	No	No	1	Bone	Autopsy	9 mo
Jackson and Adams[48]	Upper lip	13	1	Yes	1	Lung Bone	Biopsy	1 yr
	Neck	8	2	Yes	1	L nodes Bone	Autopsy	2 yr
	Preauricular	14	3	Yes	Mult	Lungs	Autopsy	2 yr
Hughes[49]	Cheek	21	1	Yes	1	Lungs	Biopsy	3 mo
	Scrotum	4	2	NM	2	L nodes	Biopsy	2 yr
Funkhouser and Ayuthia[50]	Cheek	19	3	Yes	1	Bone	Biopsy	6 mo
Present paper	Cheek	6	2	Yes	No	Bone	Biopsy	20 mo
	Orbit	8	1	Yes	No	Bone L nodes Skin	Biopsy	4 mo

*NM indicates not mentioned; mult, multiple; and L, lymph.

Fig 1.—Ulcerated lesion near buccal commissure with a cord-like extension into the parotid region (case 1).

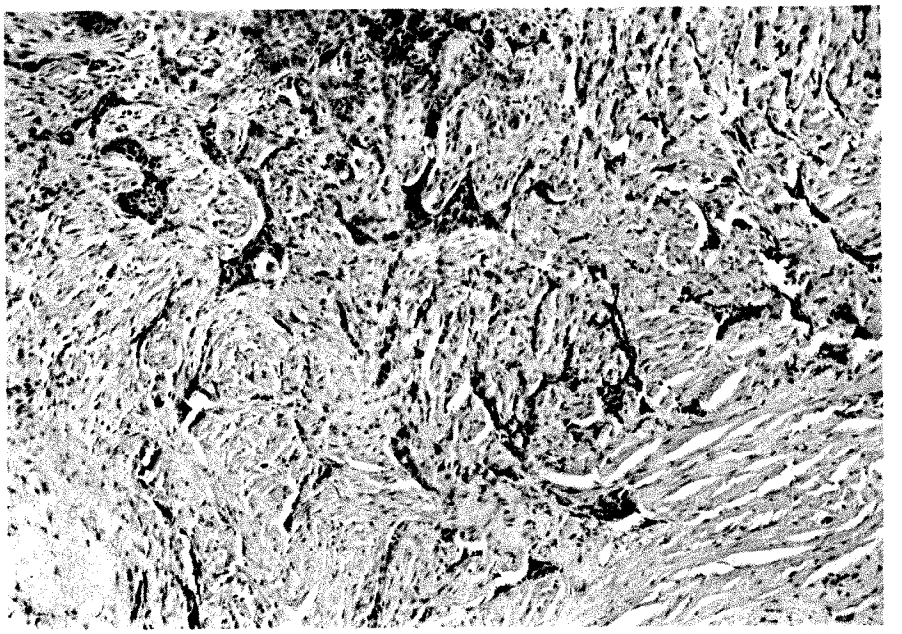

Fig 2.—Histological findings of ulcer (case 1) show sclerotic basal cell carcinoma (hematoxylin-eosin, original magnification ×150).

alkaline phosphatase level was more elevated. Bleomycin sulfate was then administered intravenously in doses of 10 mg/sq m, twice a week, for a total of 420 mg during the period from March 12 to Sept 22, 1971. The treatment had to be discontinued because of chest pains and worsening of the bone pains. Radiographs on Aug 31, 1971, showed collapse of the second lumbar vertebra. The patient's last admission to the hospital was in November 1971, because of an ulcer in the left mastoid region. This proved to be another recurrence of the BCC. This time he weighed 39.5 kg, the hemoglobin value was 11.4%, and the serum alkaline phosphate level was unusually high. The patient died at home on Dec 19, 1971, about 20 months after the onset of symptoms of bone involvement. Permission for autopsy was denied.

CASE 2.—A 59-year-old woman was referred to us by a dermatologist whom the patient had consulted about a "sore on the face" that had never been treated. The lesion apparently originated near the outer canthus of the right eye and had been present for eight years. It was extensive, ulcerated, and involved the right temporal, frontal, and zygomatic regions. The eyelids were everted, and the eye was amblyopic (Fig 6). Histological examination showed a keratinizing basal cell carcinoma (Fig 7). On April 18, 1974, the lesion was excised en masse with the contents of the orbit and a 1-cm margin of clinically free skin. The zygomatic arch was also resected, and the wound was covered with a split-thickness skin graft obtained from the right thigh. The pathology report indicated complete

Fig 3.—Defect in case 1 after nine microscopically controlled excisions (Mohs chemosurgery technique).

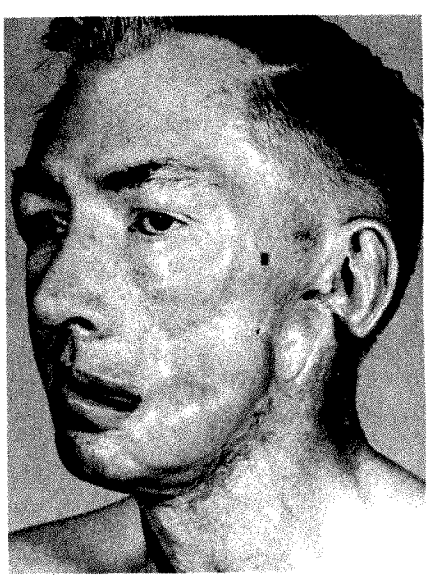

Fig 4.—Case 1 after nine reconstructive surgery operations.

removal of the tumor and absence of bone involvement. On Aug 28, 1974, two nodules were noted at the lateral margin of the orbit underneath the graft, one superiorly and the other inferiorly over the zygomatic bone. They proved to be recurrent BCC, and were excised in November 1974, by the Mohs chemosurgery technique. The lower lesion was found to extend into the maxillary bone and its antrum (Fig 8). During this hospital admission, the patient's serum alkaline phosphatase and lactate dehydrogenase levels were within normal limits. The wounds were left to heal by secondary intention, but the BCC had recurred again in the zygomatic region when the patient was seen on Jan 27, 1975. There was also another area of recurrence in the parietal scalp at the edge of the graft. Both lesions were excised by chemosurgery. In April 1975, an enlarged cervical node and a 2-cm ulcerated nodular mass of the left arm were excised. The histologic picture in both was identical with that of the primary cutaneous lesion. Subcutaneous nodular

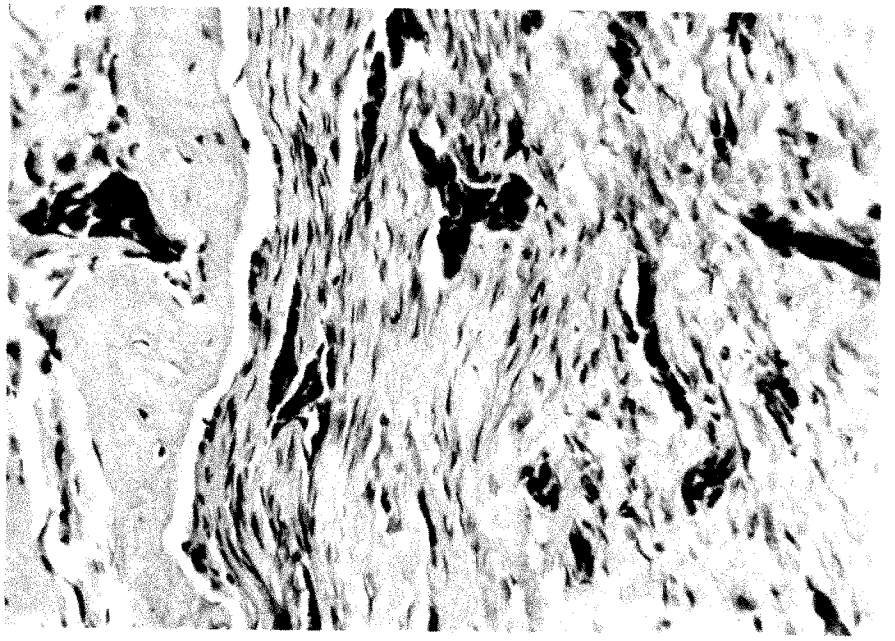

Fig 5.—Left iliac bone biopsy (case 1). Bone marrow has been replaced by mucinous, fibrous stroma that contains masses and strands of basal cell carcinoma (hematoxylin-eosin, original magnification ×420).

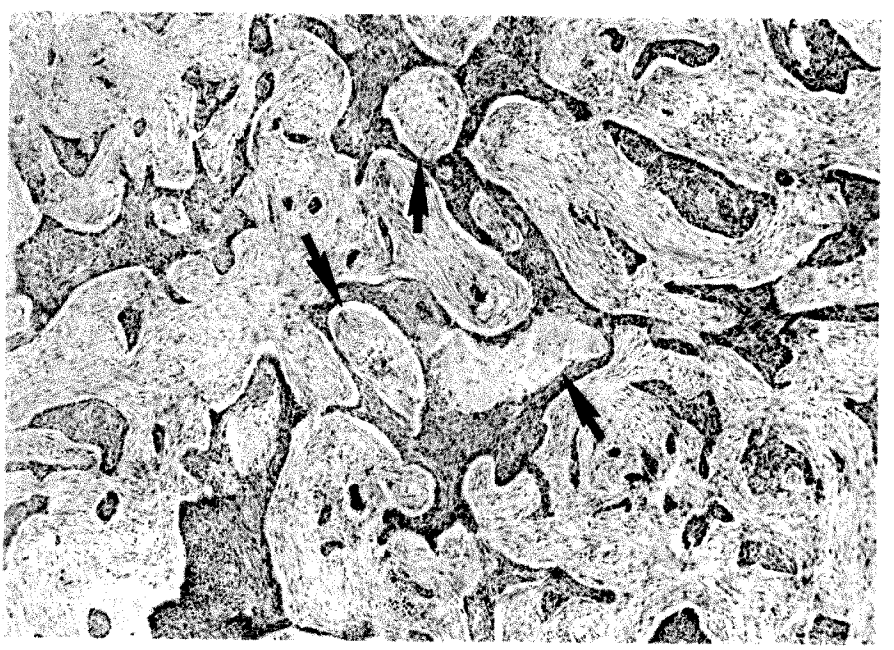

Fig 7.—Section from lesion shown in Fig 6. The histological findings were that of keratinizing basal cell carcinoma. Palisading well marked. The foci of keratinization are incompletely keratinized (arrows) (hematoxylin-eosin, original magnification ×90).

masses developed within the next month, several on the back. One on the right thigh about 2.5 cm in size (Fig 9) was excised and showed the same histological findings, but this tumor occupied the deeper dermis and the subcutis and was not connected with the epidermis. The wall of a deep subcutaneous arteriole was involved (Fig 10). By that time, the patient had lost about 8 kg, and the serum alkaline phosphatase and lactate dehydrogenase levels were markedly elevated. Because of these findings, and because of a complaint of bone pains, a radiographic bone survey was undertaken. This showed multiple compression fractures of several vertebral bodies and radiolucency of the ischium. Radionucleide examination, employing 15 mCi of technetium Tc 99m pyrophosphate, showed increased uptake of the radioactive material in the skull bones, the ribs, the sacrum, the left pubis, the left ischium, and the femurs (Fig 11). Biopsy material obtained from the right iliac bone demonstrated small masses of BCC embedded in a mucinous, fibrous tissue between the bony trabeculae (Fig 12). The cellular immune responses were found normal for the patient's age as measured by lymphocyte transformation using phytohemagglutinins and poke weed mitogens. The fluorescent antinuclear antibody test was negative, and the immunoglobulins were within normal values. Bleomycin therapy was

Fig 6.—Extensive, ulcerated basal cell carcinoma of right orbit and side of face (case 2).

Fig 8.—Basal cell carcinoma extending inside maxillary antrum (case 2).

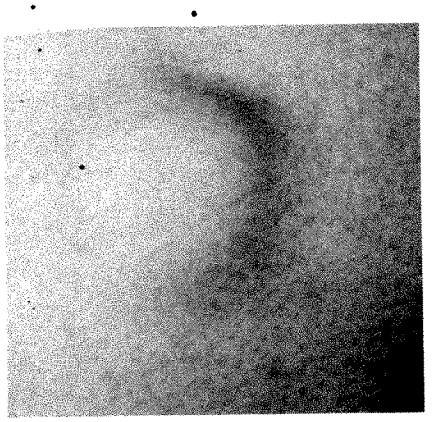

Fig 9.—Subcutaneous metastatic lesion on right thigh (case 2).

considered but was not administered because the patient failed to cooperate during the evaluation of pulmonary function. Methotrexate and leucovorin were then administered but had to be discontinued shortly afterwards because of thrombocytopenia. By June 19, 1975, there were 14 subcutaneous nodules on the back. The patient died one month later, four months after the first signs of metastasis. Autopsy was denied.

COMMENT

Cotran[21] has found nine examples of metastases among 9,050 cases of BCC seen during a 14-year period at Memorial Hospital in New York, an incidence of about 0.1%. This is probably much higher than the true incidence in the general population.[40] A survey conducted in Australia and New Zealand, where BCC is more common than elsewhere in the world, showed a metastasis rate of about 0.0028%.[51] The discrepancy between the two studies is probably due to the fact that Cotran's cases were from a hospital population while the Australian study was based on information obtained mainly from medical offices. Although metastasizing BCC is rare, it is possible that, due to the indolent nature of the disease, many cases are not seen by a physician at all or are overlooked. The diagnosis of secondary lesions has been made clinically in the majority of the reported cases, but several unsuspected metastases have been discovered at autopsy,[19,21,32,34,35,40] and one during surgery.[45]

The sites of metastases in the 78 cases are summarized in Table 2. Regional lymph node metastasis was the most frequent; metastases to the lungs and to bone were next in order of frequency. Metastases have also occurred in the liver, spleen, pancreas, peritoneum, diaphragm, pericardium, kidneys, adrenals, and skin. However, these areas were usually involved when at least one of the three major sites was also affected.[16,19,21,27,32,33,42] Metastasis to a single site occurred in 55 cases and to multiple sites in 23 patients. Metastasis to bone, possibly preceded by spread to a regional parotid lymph node, occurred in our case 1, while lymph node, bone, and skin metastases were found in case 2. Cutaneous metastasis is extremely rare with only one previously reported case.[33]

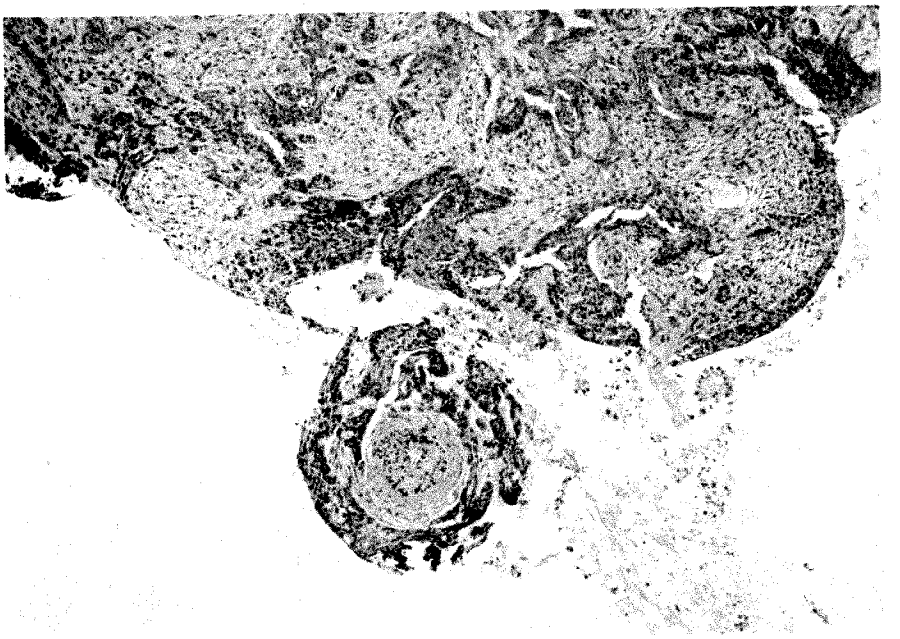

Fig 10.—Section from right thigh lesion showing metastatic basal cell carcinoma involving subcutaneous arteriole (hematoxylin-eosin, original magnification ×90).

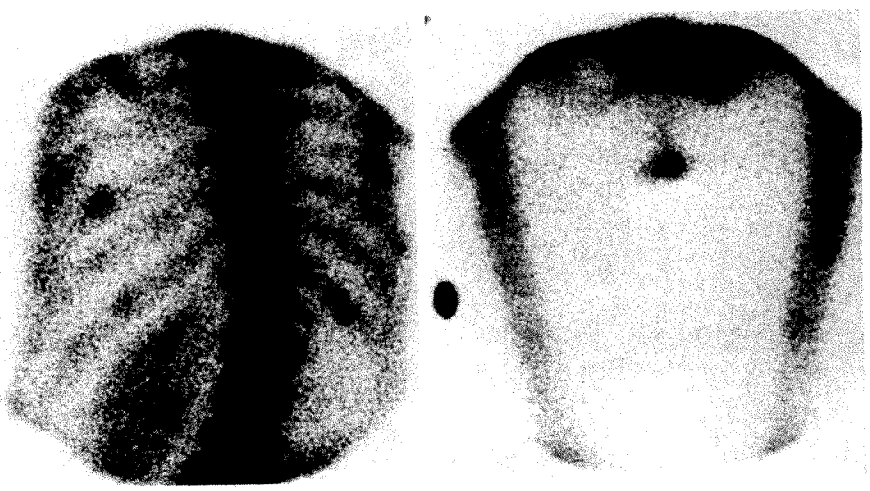

Fig 11.—Radionucleide bone scan shows increased uptake of radioactive material: left, in ribs; right, in sacrum, pubis, ischium, and femora (case 2).

In an attempt to better understand the conditions under which BCC may metastasize, certain factors have been considered, as follows: the site, size and histologic type of the primary tumor, the biologic behavior of BCC, the immune mechanism in the host, and the treatment that precedes the occurrence of metastases.

The great majority of the primary lesions (85%) have been located on the head and neck and the remainder on

Fig 12.—Section from biopsy material obtained from right iliac bone shows masses of basal cell carcinoma imbedded in mucinous fibrous tissue between bone trabeculae (case 2) (hematoxylin-eosin, original magnification ×390).

Table 2.—Sites Involved in 78 Cases of Metastatic BCC

Site of Metastasis	Single Site	Concomitant Lesions				Total Sites	Incidence %
		Nodes*	Lungs	Bone	Other†		
Nodes*	38		5	4	2	49	46
Lungs	8	5		10	7	30	28
Bone	8	4	10		4	26	25
Liver	1	0	0	0	0	1	1

*Regional lymph nodes.
†Viscera, skin.

Table 3.—Treatment Preceding Metastasis in 78 Cases of BCC

Site of Metastasis	No Treatment	Radiotherapy Only	Surgery Only	Surgery & Radiotherapy	Total
Nodes*	3	5	9	21	**38**
Remote†	5	2	8	25	**40**
Total	**8**	**7**	**17**	**46**	**78**

*Only regional lymph nodes involved.
†Lung, bone, viscera with or without node involvement.

the extremities and back.[3,4,28,40] These tumors have been characteristically large, ulcerated, of long standing, locally invasive, and resistant to radiotherapy and surgery.[8,34,48] Metastases have been noted from 1 to 45 years (average 11 years) after the appearance of the primary lesion.[21,28]

The consensus is that there is no specific histologic type of BCC that is more capable of metastasizing.[31,40] Metastases have occurred from the solid or nodular type[2,40] and from sclerotic and adenoid BCC.[4,10,19,21,31,48] Montgomery,[52] Helwig,[53] and Graham[54] believe that of all types, the metatypical BCC is the one most likely to metastasize. This tumor has been described as composed of cells that are larger than those of typical BCC, tend to be polygonal, have a more eosinophilic cytoplasm, with peripheral palisading indistinct in some areas. Cellular pleomorphism, malignant dyskeratosis, and abnormal mitotic figures have also been described.[54] According to Montgomery,[52] this type accounts for 15% to 20% of all cases of BCC, and the presence of foci of incomplete keratinization is prerequisite for the diagnosis. Other workers[13,55-57] stress that keratinization can be found in typical BCC and that there is no need for a special terminology. The presence of foci of keratin has also been interpreted as evidence of maturation of the basal cells rather than an indication of malignancy.[58] Unlike that seen in squamous cell carcinoma, keratinization is parakeratotic and is usually incomplete.[52-58] Twelve cases of metastatic BCC are on record at the Armed Forces Institute of Pathology, all of which are "metatypical".[53] Discussing the types of BCC, Lever and Schaumberg-Lever[59] conclude that it can be assumed that the controversial basal squamous cell epithelioma represents a keratotic basal cell epithelioma, and that the intermediate type is a basal cell epithelioma with differentiation into two types of cells. Case 1 was of the sclerotic type while case 2 may be designated as keratinizing or metatypical BCC.

It has been postulated that, unlike squamous cell carcinoma, the epithelial component of BCC is specifically dependent on its stroma and cannot metastasize unless part of its stroma is also taken along, and that this would account for the rarity of metastasis in BCC.[57,60] In support of this theory is the demonstration that BCC could not be transplanted autologously unless some of its stroma had been included in the transplant.[61] On the other hand, since BCC has been grown in tissue culture,[62] the possible existence of stromal independence and the emergence of highly malignant cell clones under certain conditions, eg, therapy, have been proposed.[28,29,31,47]

That immune disorders or deficiencies may play a role in enhancing metastasis in BCC has been suggested but without corroborative evidence.[11,14,18,19,40] In case 2, the lymphocyte transformation using phytohemagglutinin and poke weed mitogens was normal, the antinuclear antibody test was negative, and the immunoglobulins were within normal range.

Review of the 76 previously reported cases and the two examples of metastatic BCC presented here shows that 70 patients (90%) had undergone surgical treatment or radiotherapy prior to the occurrence of metastasis (Table 3). It has been postulated that radiation energy may transform a low-grade BCC into a highly malignant one that is capable of metastasizing.[25] It is significant evidence in support of this view that 53 patients (68%) had radiotherapy (Table 3). However, the treatment could have been inadequate, or the tumors for some as yet unknown reason were radioresistant. This is especially true in the case of sclerotic BCC. A biologically acceptable thesis may be based on possible dissemination of tumor fragments, consisting of epithelial and stromal elements, through lymphatics and veins by direct erosion of the vessels by a deeply invasive BCC or by trauma during surgery.[28,31] Masses of BCC have been demonstrated within lymphatics[21,22,48] and veins[20,48] in the vicinity of the primary growth and near metastatic lesions.[48] Involvement of a subcutaneous arteriole was noted in a cutaneous metastatic lesion in case 2 (Fig 10).

In 1971, a group of German workers succeeded in measuring the collagenase content of tissues and found a significant relationship between collagen peptidases and tumor invasion.[63] Yamanishi and co-workers[64] found that malignant melanoma had a collagenolytic activity that was 20 times that in normal skin, junction nevus, and blue nevus. We have studied collagenolytic activity in tissue extracts of squamous cell carcinoma, Broders grade 3, nodular BCC, metatypical BCC (case 2), and normal skin by the Moore and Stein photometric technique[65] and standardized by *Clostridium histolyticum* collagenase and proteinase.[66] Normal skin contained 124 units of enzymatic activity per gram, while the values for the tumors were 294 for squamous cell carcinoma, 305 for nodular BCC, and 304 for metatypical BCC. The increased collagen-degrading enzymes in BCC may facilitate the spread of tumor cells and invasion of lymphatics or blood vessels. It is also possible that this collagenolytic activity may contribute to the formation of the mucin-filled spaces that surround epithelial nests that are seen in histological sections.

It is significant that 63 of the patients (81%) had undergone extensive and repeated surgical excisions and that tumor had recurred at the primary site by the time the metastases were discovered, indicating incomplete initial eradication.[26,31] Metastases occurred in 33 patients in whom there was immediate grafting of the wounds that resulted from excision of the primary lesions. This figure by no means represents the true number of cases that were grafted, for the history was silent on this point in reports on 26 patients who were subjected to extensive surgical procedures (Table 1). The scar that anchors a graft in its place is too tough to allow the residual tumor to grow through it toward the surface. The tumor is forced to expand in the direction of least resistance, the deeper tissues. In doing so, it is conceivable that larger lymphatics and veins may become involved, leading to metastasis. Therefore, it seems advisable to defer wound grafting, whenever possible, for at least six months after excision in order to allow the residual tumor to become manifest and be extirpated before reconstructive surgery is begun.[67] The wounds in both of our patients were grafted immediately following excision of the cutaneous tumors. Metastasis was detected in case 1 at 16 months after the first reconstructive surgery operation, and the patient died six months later. It took 12 months for the metastases to become manifest in case 2, and the patient survived for only four months.

The rarity of metastatic BCC can cause diagnostic difficulties in cases with clinical evidence of a metastatic malignancy. Because of the rare incidence and its biologic behavior, it is rational to assume that BCC metastasis may be a final stage in a series of changes these carcinomas undergo. Some authors believe that BCC does not metastasize and that previously published cases could have been basaloid squamous cell carcinomata or adenocarcinomata.[57] The metastases in BCC have occurred at an average of 11 years after the original lesion had become manifest.[21,28] This is unlike squamous cell carcinoma that metastasizes within three years.[26]

The average survival time after metastasis to the lungs, bone, and internal organs has been about 10 months.[21,40] Of the 40 cases in this group, only two cases have apparently been successfully treated, one by pulmonary lobectomy,[20] and the other by cobalt therapy to metastasis in the femur.[31] Chemotherapy with bleomycin and other cytotoxic drugs has been disappointing.[2,31,39,42] Our experience agrees. The prognosis was far better when only the regional lymph nodes were involved because of accessibility to surgical removal.[2,20,28,38,45]

Definitive ablation of a recurrent or invasive BCC can be best achieved by adequate excision and the demonstration of clearance of the margins. The microscopically controlled excision by the Mohs technique is ideal for this purpose.[62] Since large and recurrent BCC are more apt to metastasize, they should be aggressively treated because they are a possible threat to life. Wound grafting and reconstructive surgery should be delayed, whenever possible, for at least six months after excision to assure complete removal and to avoid burying a residual carcinoma. The follow-up examinations should be more frequent than in the usual cases, and careful search for involved regional lymph nodes is recommended at each visit. Since the nodes are the commonest sites of spread, early detection can be life saving. Chest and bone x-ray films and determination of serum alkaline phosphatase levels are indicated when there is history of weight loss, pulmonary symptoms, or pain in bones. The serum alkaline phosphatase level was markedly elevated in our patients and in the five reported cases of bone metastasis in which it was determined.[27,31,33,45,48] Although x-ray film evidence is not conclusive, it is helpful in detecting suspected lesions in lungs and bone. Radionucleitle radiography and bone biopsies were decisive in the detection of metastases in our cases.

Although the size of the primary

tumor, its site, and the effects of radiation or resistance to radiation appear to contribute to the occurrence of metastasis in BCC, it is possible that tumor antigenic factors, tumor angiogenic factors, hormonal influences, or immunologic defects may also have roles. However, one cannot ignore the appreciable incidence of metastases reported in patients where immediate grafting followed incomplete excision of primary tumors.

This work was supported in part by the National Institutes of Health Biomedical Research Support grant 5S07 PR 05490-14 and the Ford Foundation through the Henry Ford Hospital.

The lymphocyte transformation tests were done by Sam S Yanari, PhD, of the Allergy Research Laboratory, Henry Ford Hospital. The tissue collagenase activity was assayed by Rollin H. Heinzerling, PhD, Michael G. Mikhail, and Sally Szymanski of the Dermatology Research Laboratories, Henry Ford Hospital.

Nonproprietary Name and Trademark of Drug

Bleomycin sulfate—*Blenoxane.*

References

1. Beadles CF: Rodent ulcer. *Path Soc London Trans* 45:176-181, 1894.

2. Costanza ME, Dayal Y, Binder S, et al: Metastatic basal cell carcinoma: A review, report of a case and chemotherapy. *Cancer* 34:230-235, 1974.

3. Jimenez HT, Fenoglio CM, Richart RM: Vulvar basal cell carcinoma with metastasis: A case report. *Am J Obstet Gynecol* 121:282-286, 1975.

4. Curry MC, Montgomery H, Winkelmann RK: Giant basal cell carcinoma of the back. *Arch Dermatol* 111:1663, 1975.

5. Lattes R, Kessler RW: Metastasizing basal-cell epithelioma of the skin. *Cancer* 4:886-887, 1951.

6. Fordyce JA: Cancer of the skin. *J Cutan Genito-Urin Dis* 20:147-157, 1902.

7. Körbl H: Die Röntgenbehandlung der Haut carcinome, speciell des Basalzellen/krebses, sein histologisches Verhaten vor und nach der Bestrahlung. *Arch Klin Chir* 97:752-816, 1912.

8. Hazen HH: Basal celled cancers of the skin. *South Med J* 10:241-246, 1917.

9. Finnerud CW: Metastatic basal cell carcinoma from the skin: Report of two cases. *JAMA* 82:775-778, 1924.

10. Spies JW: Adenoid cystic carcinoma: Generalized metastases in three cases of basal cell type. *Arch Surg* 21:365-404, 1930.

11. Niles HD: Metastasis of a basal-cell epithelioma. *Am J Cancer* 15:2341-2356, 1931.

12. Louste, Thibaut, Caillu, et al: Épithéliome basocellulaire du front compliqué ultérieurement d'un néoplasme de la région zygomatique. *Soc Franc Derm Syph Bull* 38:1446-1450, 1931.

13. DeNavasquez S: Metastasizing basal cell carcinoma. *J Path Bact* 53:437-439, 1941.

14. Singer A: Basal-cell carcinoma of face with remote metastases and pathological fractures. *Br J Surg* 32:537-538, 1944.

15. Amersback JC: Metastatic basal cell epithelioma. *Arch Dermatol* 56:172-178, 1947.

16. Small CS, Linda L, Hankins FD: Basal cell carcinoma with metastases: A report of two cases. *Arch Pathol* 47:196-204, 1949.

17. Eckhoff NL: Recurrent multiple and metastasizing basal-celled carcinomata. *Br J Plast Surg* 3:264-281, 1951.

18. Richter G: Subpleural lung metastases from basal cell carcinoma. *Hautarzt* 8:215-219, 1957.

19. Huntington RW Jr, Levan NE: Basal-cell carcinoma metastatic from skin. *Arch Dermatol* 75:676-677, 1957.

20. Rank BK: Metastasizing basal cell epithelioma. *Aust New Zeal J Surg* 27:279-282, 1958.

21. Cotran RS: Metastasizing basal cell carcinoma. *Cancer* 14:1036-1040, 1961.

22. Raitschev R, Andreev V, Stojanov A: Metastasierendes basocellulares carcinom. *Hautarzt* 12:320-323, 1961.

23. Binkley GW, Rauschkolb RR: Basal-cell epithelioma metastasizing to lymph nodes. *Arch Dermatol* 86:332-335, 1962.

24. Nelson WR, Kell JF, Kay ST: Temporal bone resection and radical neck dissection for basal cell carcinoma with metastases. *Surg Gynec Obstet* 115:585-592, 1962.

25. Dahlgren S, Martensson B: Metastasizing basal cell carcinoma. *Acta Pathol Microbiol Scand* 59:335-340, 1963.

26. Lewin ML: Basal cell carcinoma: Two cases with unusual features. *Plast Reconstr Surg* 32:334-347, 1963.

27. Crawford HJ, Joslin CAF: Metastasizing basal-cell carcinoma. *J Pathol* 87:437-440, 1964.

28. Conway H, Hugo NE: Metastatic basal cell carcinoma. *Am J Surg* 110:620-624, 1965.

29. Jay B: Basal cell carcinoma: Study of a carcinoma metastasizing to the lung. *Arch Dermatol* 93:354-357, 1966.

30. Stell JS, Moyer DG, Dehne E: Basal cell epithelioma metastatic to bone. *Arch Dermatol* 93:338-340, 1966.

31. Assor D: Basal cell carcinoma with metastasis to bone. *Cancer* 20:2125-2137, 1967.

32. Lakshmipathi T, Hunt KM: Metastasizing basal-cell carcinoma. *Br J Dermatol* 79:267-270, 1967.

33. Coletta DF, Haentze FE, Thomas CC: Metastasizing basal cell carcinoma of skin with myelophthisic anemia. *Cancer* 22:879-884, 1968.

34. Taylor WB, Anderson DE, Howell JB, et al: The nevoid basal cell carcinoma syndrome: Autopsy findings. *Arch Dermatol* 98:612-614, 1968.

35. Hirshowitz B, Mahler D: Unusual case of multiple basal cell carcinoma with metastasis to the parotid lymph gland. *Cancer* 22:654-657, 1968.

36. Rodermund OE, Cramer EH: Zur Frage der Metastasierung von Basaliomen. *Z Haut Geschlechtskr* 43:455-464, 1968.

37. Beretta G, Molinari R: Carcinoma basocellulare cutaneo metastasizzante con anemia mieloftisica. *Tumori* 56:175-180, 1970.

38. Wronkowski Z: Metastases in dermal basal cell carcinoma. *Nowotwory* 18:51-55, 1968.

39. Chien WL: Basal cell carcinoma with metastases to bones and lung. *Va Med Mon* 93:14-17, 1966.

40. Wermuth BM, Fajardo LF: Metastatic basal cell carcinoma: A review. *Arch Pathol* 90:458-462, 1970.

41. Cranmer L, Reingold IM, Wilson JW: Basal cell carcinoma of skin metastatic to bone. *Arch Dermatol* 102:337-339, 1970.

42. Hall TE, Tappan WM, Decker JW: Basal cell carcinoma with metastases: Report of two cases. *Rocky Mt Med J* 67:39-40, 1970.

43. Liu PI, McGregor DH, Cehak RW, et al: Basal cell carcinoma with pulmonary metastasis: A case associated with reticulum cell sarcoma and thyroid carcinoma. *Hiroshima J Med Sci* 20:281-289, 1971.

44. Mantell BS, Almeyda J: Metastasizing basal cell carcinoma. *Br J Radiol* 45:575-578, 1972.

45. Mikhail GR, Kelly AP Jr, Elmquist JG: Metastatic basal cell epithelioma discovered by chemosurgery. *Arch Dermatol* 105:103-104, 1972.

46. Harris JH Jr, Libshitz H: Basal cell carcinoma of skin metastasizing to bone. *J Can Assoc Radiol* 23:217-220, 1972.

47. Cornelius CE III: Bone—A site of metastatic basal cell carcinoma. *Arch Surg* 104:848-850, 1972.

48. Jackson R, Adams RH: Horrifying basal cell carcinoma: A study of 33 cases and comparison with 435 non-horror cases, and a report on four metastatic cases. *J Surg Oncol* 5:431-462, 1973.

49. Hughes JM: Metastatic basal cell carcinoma: A report of two cases and a review of literature. *Clin Radiol* 24:392-393, 1973.

50. Funkhouser JW, Ayuthia IN: Metastasizing basal cell carcinoma: Case report. *Ohio State Med J* 69:521-523, 1973.

51. Paver K, Poyzen K, Burry N, et al: The incidence of basal cell carcinomas and their metastases in Australia and New Zealand. *Aust J Dermatol* 14:53, 1973.

52. Montgomery H: *Dermatopathology.* New York, Harper & Row Publishers, 1967, pp 934-940.

53. Helwig O, Thomas CC: in discussion, Basal cell carcinoma of the left leg with metastesis to left inguinal lymph nodes, multiple skin metastatses and involvement of bone marrow. *Arch Dermatol* 97:597, 1968.

54. Graham JH, in discussion, Urbach F, Alkek DS: Metastatic basel cell carcinoma. *Arch Dermatol* 99:778, 1969.

55. Willis RA: *Pathology of Tumors,* ed 3. London, Butterworth Publisher, 1960, p 281.

56. Allen AC: Basal cell carcinoma, in Anderson WAD (ed): *Pathology,* ed 3. St Louis, CV Mosby Publisher, 1957, p 1162.

57. Pinkus H, Mehregan AH: *A Guide to Dermatopathology,* ed 2. New York, Appleton-Century-Crofts Inc Publishers, 1976, pp 562-567.

58. Lennos B, Wells AL: Differentiation in the rodent ulcer group of tumor. *Br J Cancer* 5:195-212, 1951.

59. Lever F, Schaumberg-Lever G: *Histopathology of the Skin,* ed 5. Philadelphia, JB Lippincott Co, 1976, pp 547-549.

60. Pinkus H: Premalignant fibroepithelioma tumors of the skin. *Arch Dermatol* 67:598-615, 1953.

61. Van Scott EJ, Reinertson RP: The modulating influence of stromal environment on epithelial cells studied in human autotransplants. *J Invest Dermatol* 36:109-131, 1961.

62. Walker DG, Goldstein N, Kopf AW, et al: Epithelial outgrowths from tissue culture of basal cell epithelioma. *J Invest Dermatol* 42:435-441, 1964.

63. New enzyme research offers "flicker of hope" in checking tumors, MEDICAL NEWS REPORT. *JAMA* 216:124-125, 1971.

64. Yamanishi Y, Maeyens E, Dabboris MK, et al: Collagenolytic activity in malignant melanoma. *Cancer Res* 33:2507-2512, 1973.

65. Moore S, Stein WH: Photometric ninhydrin method for use in the chromatography of amino acids. *J Biol Chem* 176:367-388, 1948.

66. Mandl I, MacLennan JD, Howes EL: Isolation and characterization of proteinase and collagenase from *Clostridium histolyticum. J Clin Invest* 32:1323-1329, 1953.

67. Mohs FE: Chemosurgery for skin cancer. *Arch Dermatol* 112:211-215, 1976.

Occupational Hazards From Deep Mycoses

Jan Schwarz, MD, Carol A. Kauffman, MD

The increased recognition of fungi as an important cause of disease is translated into what appears as a high incidence of mycotic disease. The increase in deep mycoses associated with occupations may be due in part to better understanding of the pathogenesis of these infections.

The fact that inhalation of spore-containing dust is the mode of infection in histoplasmosis, coccidioidomycosis, paracoccidioidomycosis, blastomycosis, and probably cryptococcosis points to any major soil digging as a potential source of such infections. Spores of *Sporothrix schenckii* have been found on timber, on the leaves of certain bushes, and in sphagnum moss; traumatic transcutaneous inoculation leading to sporotrichosis is well established. A connection exists between pigeons and the occurrence of cryptococcosis, and between bats and birds and histoplasmosis.

LABORATORY INFECTIONS

A special chapter in occupational disease caused by "deep fungi" is that associated with laboratory exposure; inhalation of culture material and traumatic transcutaneous inoculations have been observed.

Blastomycosis

Eight cases of traumatic primary transcutaneous blastomycosis after puncture or cutting wounds in laboratories (including autopsy rooms) are on record. Slow healing chancres with or without regional lymphadenitis developed, and all eight cases became arrested, with a variety of therapeutic regimens, including surgical excision and no treatment.[1] One proven case of primary pulmonary (inhalation) disease was reported after exposure to cultures of *Blastomyces dermatitidis*.[2] Denton et al[3] assume that in a laboratory worker who had an osteolytic lesion in the head of the fibula, the primary pulmonary infection was acquired three months earlier when she was removing cellophane tape from Petri dishes containing cultures of *B dermatitidis*. However, a "natural" infection cannot be ruled out in this case. In view of the generally subclinical presentation of primary pulmonary blastomycosis, the possibility of more such laboratory-acquired inhalation infections should be considered.

Histoplasmosis

Laboratory infections with *Histoplasma capsulatum* acquired by way of inhalation of culture material and by local inoculation are on record. Inhalation of material from cultures on Petri dishes resulted in the conversion of histoplasmin skin tests to positive in 17 of 26 employees in the Mycoses Laboratory of the Public Health Service in Kansas City, Kansas, with an average conversion time of 4.2 months (one month to three years).[4] Since the laboratory was located in an endemic area of histoplasmosis, "natural" infection also has to be considered. However, the authors concluded that the risk for the laboratory worker was 26 times greater than among local school children. Forty-one percent of the converters had clinical illness. Comparative values of subclinical infection were amazingly similar in this group (59%), compared with laboratory personnel exposed to *Coccidioides immitis* (59.4%).[5]

A fatal infection in a mycologist was the result of infection either from positive soil samples or from the resulting soil cultures.[6] Almost identical sources were responsible for acute disease in two fellow workers in a laboratory in Michigan, but the outcome was favorable.[7] Cultures were responsible for six infections in a Swedish laboratory with considerable clinical illness in four of the infected persons.[8] The high infectivity of cultures of *H capsulatum* led to consideration of this organism as well as *C immitis* for biological warfare.[9]

Of 17 female medical technology students transferring four-week-old cultures in a laboratory in Madison, Wisconsin,[10] one developed grippe-like symptoms and erythema nodosum two months after exposure. All 17 had a positive skin test and eight had positive complement fixation (CF) tests for *H capsulatum*. One male student representing the 18th case of the group had radiologic and serologic (CF titer 1:512) evidence of histoplasmic infection. A comparable regional control group of students had 11.5% positivity with the histoplasmin skin test.

Loosli[11] observed ten laboratory infections at the University of Chicago, four with prolonged clinical illness. Spicknall et al[12] report conjunctival inoculation in a physician exposed twice to a spray of culture suspension. Six to ten days after exposure, soreness and edema of the palpebral conjunctiva developed and subsequently an ulcer appeared with associated tenderness of preauricular and upper cervical homolateral lymph nodes. A negative histoplasmin skin test changed to positive; cultures from the conjunctiva were negative as were CF tests for *H capsulatum*. The patient recovered uneventfully.

Coccidioidomycosis

Coccidioides immitis has a well earned renown for producing high infection rates in workers handling cultures.[13]

Inhalation infection with spores in the laboratory of Ophuls represents the first of a long chain of documented cases of pulmonary coccidioidomycosis acquired from culture material.[5] An even older case of laboratory infection is controversial.[14,15] Hanel and Kruse[16] give a detailed account of infection acquired in the laboratory in students, physicians and technicians. Of 63 fungus infections uncovered by a questionnaire sent to laboratories, 49 were attributed to *C immitis*.[17] Twenty-three of the group of 49 were clerk and maintenance workers who did not personally handle culture material.

A fatal case of laboratory infection developed in one of seven persons exposed to discarded culture materi-

Accepted for publication Jan 31, 1977.

From the Clinical Laboratories, Jewish Hospital; the Division of Infectious Diseases, Department of Internal Medicine, Cincinnati Veterans Administration Hospital; and the University of Cincinnati Medical Center, Cincinnati.

Reprint requests to Clinical Laboratories, Jewish Hospital, 3200 Burnet Ave, Cincinnati, OH 45229 (Dr Schwarz).

al.[18] Other laboratory infections were reported by Nabarro[19] and by Bush.[20] An ulcer developed at the site of a thorn puncture in a technician who had been harvesting cultures of *C immitis* for four months prior to the accident.[21] Overholt and Hornick's[21] third case is quite similar in that a wrist ulcer developed in a laboratory worker with a poison ivy eruption, who was cleaning a laboratory known to be contaminated with *C immitis*. Both cases developed local lymphadenopathy strongly suggesting a primary complex. Overholt also reported an infection in a laboratory worker who had a positive coccidioidin skin test prior to the accident. Marked swelling surrounded the puncture site and the regional (axillary) lymph nodes suppurated, with *C immitis* demonstrated in the exudate. Local osteomyelitis developed, with permanent minor loss of mobility in the thumb. Another laboratory associated puncture wound in a man with a history of a positive coccidioidin skin test led to local induration, severe pruritus, and urticaria. No lymphangitis or lymphadenitis developed.[22] Accidental inoculation into the thumb of a graduate student resulted in a chancriform lesion at the point of trauma followed by a chain of nodules leading to the regional lymph nodes.[23] Injury at embalming was reported by Wilson and Smith,[24] and a traumatic infection in a physician performing an autopsy is on record.[25] Six cases of infection occurred in a German commercial microbiologic laboratory during attempts at growing *C immitis*.[26]

In 1964, Johnson et al[27] compiled 210 cases of laboratory acquired coccidioidomycosis from one institution and tabulated 96 cases from elsewhere. Of the 96 cases, the authors consider 59 proved, 28 probable, and 9 possible. Johnson's report is concerned with 2,013 workers potentially exposed to *C immitis* between 1944 and 1962 in a government installation located in Maryland far outside the endemic area. On initial coccidioidin skin testing, 118 workers were positive; they were not retested. Of the remaining 1,805 workers, 210 (10.4%) converted their skin test to positive. Only six showed significant clinical disease; three had cutaneous (primary) chancres—one after puncture of a finger with a briar thorn, one after a scratch in a hood containing *C immitis*, and the third after accidental injection of culture material into his wrist. The three other symptomatic patients had primary pulmonary coccidioidomycosis. All three had known exposure to cultures. Of the 210 converters, 76 were altogether asymptomatic, but 58 others had unexplained flu-like symptoms.

Hanel and Kruse[16] have reviewed many laboratory acquired infections up to 1967 and question the validity of the conversions reported by Johnson et al[27] because syringes used for coccidioidin skin tests had been used for other biologicals (skin test material). Disposable needles and syringes are undoubtedly preferable to avoid carryover of antigenic material.

Sporotrichosis

"Natural" sporotrichosis is, in most instances, the result of transcutaneous traumatic inoculation; small wonder that the same mechanism can be traced to handling of culture material. Fava[28] seems to have acquired the first laboratory infection when a culture suspension sprayed into his conjunctiva while injecting rabbits. Sporotrichosis after a rat bite (the animal had been inoculated with *S schenckii*) occurred in a French laboratory.[29] Aerosol from a broken capillary pipette produced conjunctival infection.[30] Meyer[31] had an inoculation ulcer on the third finger, Fielitz[32] on the forearm, and Norden[33] on a finger under a ring, after working with cultures of *S schenckii*. None of these authors were aware of trauma. Mikkelsen et al[34] reported an ulcer on the index finger of a mycologist after accidental inoculation. The ulcer took three weeks to develop and healed in three weeks under potassium iodide therapy. Carougeau[35] developed the classical picture with lymphangitis after accidentally scratching his skin after opening a subcutaneous abscess in a mule.

Cryptococcosis

Halde[36] cut her finger 5 mm deep with a knife used to open the abdominal cavity of a mouse injected intraperitoneally with a culture of *Cryptococcus neoformans;* the description of the peritoneal fluid as "viscous" suggests abundant development of cryptococci in the exudate. The wound was made to bleed and healed without further treatment. A 14-year follow-up of the patient was uneventful.

NATURAL INFECTION WITH DEEP FUNGI

Sporotrichosis

Sporothrix schenckii is a fungus of great importance in reference to occupation, since large numbers of persons have contact with and become infected by timber, sphagnum moss, marsh hay, barberry bushes, and other plant material. In fact, a person in any profession leading to contact with vegetable material is potentially at risk. An incomplete list ranges from berry pickers to bulb farmers, from miners (timber supporting the shafts) to chefs in restaurants, from pottery workers to packers in brickyards. A reasonably complete list of case reports can be found in Lurie's[37] chapter in Baker's Handbook.

Gardeners, florists and greenhouse workers, and farm hands are the most frequently affected persons. Skin tests to sporotrichin were positive in 58% of workers employed more than ten years in nurseries in Louisiana and in only 11.2% of controls from the same geographic area.[38] A glimpse into the complexities of sporotrichosis in a nursery is provided by the thorough study by McDonough et al.[39] Of 250 samples of sphagnum moss used for keeping roots of bushes covered and moist during winter in a nursery barn in Wisconsin, 15.6% were positive in culture for *S schenckii*. The sphagnum moss was the main source of subsistence for the fungus, and moisture around drainholes in the barn provided enough water for development and survival of the fungus. The authors concluded that the sphagnum moss became infected with *S schenckii* after reaching the barn since samples from only one of 34 bales of moss were positive for the fungus when received in shipping.

Clinical cases of sporotrichosis have been reported from nurseries throughout the country. In almost every instance, sphagnum moss shipped from Wisconsin has been implicated. D'Alessio et al[40] have reported 14 clinical cases that devel-

oped in a nursery in Vermont; all patients had documented contact with sphagnum moss obtained almost entirely from Wisconsin. Eight cases in two Florida nurseries were related to exposure to moss from Wisconsin.[41] Twenty-one cases in Minnesota originated from moss-packed trees.[42] A fisherman in Wisconsin developed sporotrichosis from moss used in his bait box. His three children developed CF antibody titers against *S schenckii*.[43] Recently, 13 forestry workers in Mississippi developed sporotrichosis following harvesting and packing of pine seedlings in sphagnum moss.[44]

Sphagnum moss is obviously a major reservoir of *S schenckii*, and attempts to decrease its fungal load by meticulous application of antiseptics in nursery barns would appear a reasonable prophylactic measure. A phenolic fungicide applied to the drainholes, floors, and walls has been shown to decrease the incidence of sporotrichosis dramatically.[39]

Other vocations besides those associated with gardening are at risk to develop sporotrichosis. The epidemic in gold miners in South Africa, that was traced to fungal contamination on the timbers in the mine, has been reviewed previously.[45]

Ahearn and Kaplan[46] repeatedly isolated strains of *S schenckii* from cold stored sausages (frankfurters). Although the strains differed from standard strains of *S schenckii* in their growth characteristics at 5 C and their proteolytic activity, they were pathogenic for mice. Studies such as this may have important implications for meat packers, cooks, and the general public.

Animals associated with transmission of *S schenckii* to humans include insects, fish, snakes, birds, rodents, bats, and dogs.[37] The usual type of infection is a chancre at the site of a bite.

Histoplasmosis

Numerous epidemics are on record[47] originating from spore-containing dust—how many are unpublished and remain unrecognized is anybody's guess. Bat infested caves have been associated with *H capsulatum* infection in spelunkers[48-52]; the oil bird, *Steatornis caripensis*, also has been incriminated in connection with cave disease.[53] Since bat guano is "harvested" from caves as fertilizer, the people involved in collecting, shipping, and actually mixing it into the soil are exposed to a rich source of *H capsulatum*.

Rural populations have higher skin test positivity than nearby city dwellers. Abandoned chicken houses endanger the farmer and his family especially when demolition of the chicken coop takes place.[54,55] Interestingly, only abandoned chicken houses give origin to group-infection; such buildings are often in poor repair, with broken windows, incomplete roofs, and missing doors. Bats have easy access to such places and can contaminate the floor of the buildings. Bat droppings may also be responsible for epidemics ascribed to a variety of birds, since the same shady trees invite birds and bats to roost.[56] Farmers are exposed to spore-containing dust in activities other than those connected with chicken coops—in silos,[57] when fertilizing with fecal material, and while plowing.

Scraping bridges prior to painting endangers small groups of people[58]; demolition of buildings and excavation for new construction have given origin to major outbreaks of acute (epidemic) histoplasmosis.[59,60] This and many other sources such as decaying trees, storm cellars, dust production during ballgames, spreading of topsoil,[61] and even peaceful visits to the parks create problems for those in the building trade,[62] gardeners, grave diggers, fishermen (digging for worms), and the population at large.[63]

How deceptive cultures from the environment may be was illustrated in a study of a group of bridge painters in Cincinnati; the most severely ill painter had positive CF and precipitating antibodies against *H capsulatum* and a sputum culture yielding *H capsulatum*. Several of his co-workers had elevated CF titers against *H capsulatum*. Scrapings from the bridge were injected into mice and yielded *Crypto neoformans*. Had the patient's illness not been documented beyond any doubt as being due to histoplasmosis, the incidental and additional presence of *Crypto neoformans* in scrapings from the bridge could have led to very wrong conclusions.

In view of the large number of clinically affected persons, and because these epidemics illustrate practically all aspects of the origin of "epidemic histoplasmosis," a review of the Mason City, Iowa epidemics follows.

Mason City, Iowa, Epidemics.—The epidemic outbreak of histoplasmosis in Mason City illustrates in rather unique form a gamut of coherent facts.[64-67] From July through mid-August 1962, a 200-yard long area along a creek was cleared of large trees and underbrush. Bulldozers were used to fell the trees and a power shovel dredged and widened the creek. Thousands of birds had roosted in the trees for the previous several years. Large clouds of dust were created when the trees were toppled. Twelve days after starting as a power shovel operator in this area, a 58-year-old man suddenly developed chills and fever; he died of bilateral pulmonary histoplasmosis seven weeks later. Three other men working in the area developed similar symptoms, and 24 more cases of acute histoplasmosis were recognized by a variety of diagnostic tools. Histoplasmin skin tests in 2,160 children living in the area of the earth clearing program revealed 77% positivity in subjects living within a block radius and only 20% positivity in children living one to two miles distant. Of ten soil samples taken from the undisturbed area adjacent to the "dug-up" site, nine were positive on culture for *H capsulatum*. Of 8,000 school children in Mason City, probably one third got infected during this first clearing operation, according to skin test data.[67]

Work was interrupted until January 1964, when city employees were ordered to saw up trees and underbrush accumulated in large piles from the clearing operation in 1962. The material was hauled to the city dump where it was burned. Cases of acute histoplasmosis were recognized about 12 days after work was started. Thirty persons developed erythema nodosum or erythema multiforme. School children showed skin test positivity varying from 21% to 100% depending on the distance between the area and the school site. Apparently 270 cases of clinical disease resulted from this

second epidemic in spite of attempts to limit the spread of the organism: winter had been chosen, the material was wetted down with water, and only workers with positive histoplasmin skin tests were allowed in the clearing process.[65]

1. The two epidemics show that within a city located in an area of low histoplasmosis endemicity, conditions can be created that are highly dangerous for large groups of exposed persons. Whether this condition is related to bird roosts or associated bat infestations cannot be decided,[56] but the presence of droppings from those winged animals (birds and bats) is too constant in similar epidemics to be fortuitous.

2. The closer to and the heavier the exposure, the more severe the disease and the higher the skin test conversion rate of the population in an area.

3. Clearing of trees and underbrush leads to soil-borne dust production, which is little influenced by weather conditions; simple procedures such as wetting down the spore-containing material are insufficient in preventing fungal fragments from becoming airborne.

4. Clinical disease can be severe, even lethal, in such epidemics. The large number of recognized cases, especially in women, permits correlation between erythema nodosum and erythema multiforme and primary infection with *H capsulatum*.

5. Prevention of such outbreaks by spraying the spore-containing soil with 3% formalin (in point sources)[65,66] or other methods of decontamination,[68,69] should be considered where and when practical.

As in the case of coccidioidomycosis, in individual cases of histoplasmosis within endemic areas, the decision as to whether an infection can be interpreted as "occupational" or simply represents the "natural" risk present in an endemic area is difficult. Even the fact that the infected person moved from a nonendemic area into the region of endemicity can obviously be interpreted for or against the acceptance of increased occupational hazard.

Coccidioidomycosis

A group such as archeologists may be threatened by coccidioidomycosis. Plunkett and Swatek[70,71] were the first to call attention to a small epidemic in four archeology students who became ill after a field trip near Inyokern, Calif; a fifth person cleaning the artifacts also developed coccidioidomycosis. Of 103 students excavating ruins near Chico, Calif in 1970, 61 contracted an illness consistent with the diagnosis of coccidioidomycosis.[72] Three smaller epidemics, involving a total of 79 students, occurred at archeological sites in northern California.[71,73,74] Since soil particles are brought to museums, workers in such institutions may become exposed to infection. Sterilization of the museum objects in an ethylene oxide, halogenated hydrocarbon mixture has been suggested to avoid infection.[75]

A 10-year-old boy dug up fossils 50 miles northwest of Los Angeles and subsequently cleaned them with an electric wire brush, a tool also used by his father. The boy developed severe clinical symptoms. He and the father were coccidioidin positive, three other family members were negative and so were two playmates who had been co-diggers, when searching for the shells. The difficulty of proving this case as fossil-born in persons living in the endemic area is self-evident.[76]

Since archeologists cannot be stopped from digging in the soil, it may be pertinent to emphasize that at least rodent burrows should be avoided, since they show particularly high positivity at culture.[72]

Bulldozing topsoil resulted in 34 cases of demonstrable infection at Edwards Air Force Base in 1960.[77] "Import" of topsoil for a residential garden led to a total of 24 cases of infection in San Diego.[78] Even after ten years, soil isolations were still positive at the garden site.

Coccidioidomycosis developed on the cheek and the scalp in two Filipino farm hands who scratched themselves on grapevines. The suspicion that the lesions represented primary inoculation foci was supported by the swelling of regional lymph nodes, absence of systemic disease, and in one case, by a positive precipitin reaction—suggesting recent infection.[79]

Coccidioidomycosis may be acquired from fomites.[80] Fruits, cotton, and vegetables are the most commonly postulated sources.[80,81] Dust from clothing has been implicated,[82] and cast material from a fracture site has been related to a hospital outbreak of coccidiodomycosis.[83] Two wool sorters, one from Massachusetts[84] and one from Canada[85] acquired fatal coccidioidomycosis. The first case had illness of one month duration. He supposedly had never traveled to the endemic area although the same patient described by a different author was said to have been in California many years earlier.[86] The second patient[85] also had not traveled to the area endemic for *C immitis*. An English businessman who was born in Ireland and had never left the British Isles unpacked pottery shipped from Arizona. The pottery was padded in finely shredded material, and unpacking produced a constant cloud of dust. The ensuing acute respiratory illness was diagnosed by biopsy and positive cultures as coccidioidomycosis.[87]

Although the two wool-sorters and the English businessman appear to be true fomite-transmitted infections, other cases occurring within the endemic area are much harder to prove.[80] Naturally, acquired infection is hard to rule out even if industrial exposure is demonstrated. In the endemic area, decisions are documented where infections in newcomers were accepted as pursuant to added risk (as compared with their previous habitat), and payment has been made to symptomatic members of a hospital staff, a porter traveling between Chicago and Los Angeles, a salesman, and a crane operator who came from nonendemic regions. Insurance companies do not necessarily follow the same pattern of empathy.[85]

The numerical importance and possible prevention of "occupational" coccidioidomycosis is discussed by Schmelzer and Tabershaw.[88] A point of particular importance is the need for "undusting" of earth moving equipment or any artifact that might be contaminated by fungus containing dust and would be moved from the endemic area to regions free of *C immitis*. Filtered air-conditioned cabs on earth moving equipment are likely to protect the driver as long as he stays within the cab and as long as he can do his job without opening the

windows. However, it seems rather utopic to expect major prevention of infection from the single procedure of air-conditioning cabs. Obviously, the dust accumulating on the equipment would have to be removed with utmost caution to prevent fragments of the fungus from becoming airborne. The employment of coccidioidin positive personnel in exposed occupations would seem a sensible precaution without completely eliminating the possibility of reinfection (breakthrough of the acquired immunity by heavy exposure is well documented).[89] From personal experience and statements by others, it can be accepted that wearing respirators in hot climates while performing physical work is less than pleasant and unbearable for any length of time. For a long time to come, we will have to accept any person involved in earth-digging procedures as a likely candidate for occupationally induced mycoses, especially histoplasmosis and coccidioidomycosis.

Cryptococcosis

Cryptococcus neoformans is not known as a cause of occupational disease, in spite of potential sources in infected domestic animals.[90] The well-documented cases of cryptococcosis with clinical symptoms in horses, dogs, cats, and pigs—to mention only domesticated animals—have not been associated with human infection.[91] Bovine mastitis due to *Crypto neoformans* occurs not infrequently in epidemic form,[92,93] apparently spread by contaminated milking machines or infected glucose-penicillin solutions used for injecting the breast tissue[94]; however, no infections in farm hands or veterinarians have been reported.

A high percentage of pigeon nests have been shown to contain *Crypto neoformans*.[95] Immunodiffusion antibody tests have shown positivity in the sera of pigeon fanciers: ten out of 50 asymptomatic pigeon breeders, five of six symptomatic breeders, and five of five cases of cryptococcosis showed precipitins.[96] Fink et al[96] doubt that pigeon breeders disease is caused by *Crypto neoformans*, but some exposure to *Crypto neoformans* present in pigeon excreta is apparently one source of sensitization.

In trying to explain the absence of major contagiosity in cryptococcosis, one is compelled to mention that a large number of clinical cases occur in immunosuppressed patients. Cryptococcosis is most commonly seen complicating Hodgkin disease and other lymphomas, terminal cancer, systemic lupus erythematosus, and following renal transplantation. *Cryptococcus neoformans* would therefore appear to be less invasive in the healthy population than *H capsulatum*, *C immitis*, or *B dermatitidis*. This may explain the absence of well-documented laboratory or industrial transmission of the disease even in persons handling the organism in the laboratory[36] or infected animals.[92,93]

COMMENT

A review of the literature reveals many cases of occupationally acquired mycotic infections. Prevention of those infections acquired in the laboratory should be feasible through education of laboratory workers and through the use of proper safety transfer hoods.

However, occupationally related fungal infections in persons exposed outside the laboratory may prove to be much more difficult to prevent. Soil is a large source of daily exposure to enormous numbers of workers in endemic areas. Although education of laboratory workers seems a realistic goal in preventive mycology, the education of those persons involved in digging and moving soil to practice techniques to decrease the exposure is a much more formidable task. Another approach to control of soil-borne mycotic infections is the vaccination of entire populations at risk. Although this approach may eventually prove feasible for coccidioidomycosis, no comparable vaccines have been developed for any other fungal diseases.

Soaking of soil with formalin solutions may help prevent epidemic outbreaks from point sources, but certainly the huge agricultural belts in which histoplasmosis is endemic cannot be expected to be sterilized by formalin.[65,66] Soaking with formalin those structures likely to be contaminated with *H capsulatum* such as bell towers, chicken coops, and old deserted buildings may decrease the risk of exposure during demolition.

Sporotrichosis presents a special problem since the mechanism of infection is generally traumatic-transcutaneous. Painting of timber with antiseptic material was successfully used in the South African mines to abort the ongoing epidemic.[45] In a similar fashion, it appears that soaking sphagnum moss in antiseptic solutions may also be useful in decreasing the content of *S schenkii*.[39]

References

1. Larsh HL, Schwarz J: Accidental inoculation blastomycosis. *Cutis* 19:334-337, 1977.
2. Baum GL, Lerner PI: Primary pulmonary blastomycosis: A laboratory acquired infection. *Ann Intern Med* 73:263-265, 1970.
3. Denton J, DiSalvo AF, Hirsch ML: Laboratory acquired North American blastomycosis. *JAMA* 199:935-936, 1967.
4. Furcolow ML, Guntheroth WG, Willis MJ: The frequency of laboratory infections with *Histoplasma capsulatum:* Their clinical and X-ray characteristics. *J Lab Clin Med* 40:182-187, 1952.
5. Smith CE: The hazard of acquiring mycotic infections in the laboratory. Read before the American Public Health Association Meeting, St. Louis, Nov 2, 1950.
6. Hartung M, Salfelder K: Histoplasmose mit tödlichem Ausgang als Berufserkrankung bei einem Mykologen. *Int Arch Gewerbepath Gewerbehyg* 19:270-289, 1962.
7. Vanselow NA, Davey WN, Bocobo FC: Acute pulmonary histoplasmosis in laboratory workers. *J Lab Clin Med* 59:236-243, 1962.
8. Nilzen A, Paldrok H: A laboratory infection caused by *Histoplasma capsulatum*. *Acta Derm Venereol* 33:329-341, 1953.
9. Furcolow ML: Airborne histoplasmosis. *Bacteriol Rev* 25:301-309, 1961.
10. Dickie HA, Murphy ME: Laboratory infection with *Histoplasma capsulatum*. *Am Rev Tuberc* 72:690-692, 1955.
11. Loosli CG: Histoplasmosis: Some clinical, epidemiological and laboratory aspects. *Med Clin North Am* 39:171-200, 1955.
12. Spicknall CG, Ryan WW, Cain A: Laboratory-acquired histoplasmosis. *N Engl J Med* 254:210-214, 1956.
13. Fiese MJ: Coccidioidomycosis. Springfield, Charles C Thomas Publisher, 1958.
14. Morris RT: A case of systemic blastomycosis. *JAMA* 61:2043-2044, 1913.
15. MacNeal WJ, Hjelm CE: Note on a mold *Coccidioides immitis* found in a case of generalized infection in man. *JAMA* 61:2044, 1913.
16. Hanel E, Kruse RH: Laboratory-acquired mycoses. Miscellaneous publications 28, Frederick, Md, Dept Army Fort Detrick, 1967.
17. Sulkin SE, Pike RM: Laboratory-acquired infections. *JAMA* 147:1740-1745, 1951.
18. Smith DT, Harrell ER Jr: Fatal coccidioidomycosis: A case of a laboratory infection. *Am Rev Tuberc* 57:368, 1948.
19. Nabarro JDN: Primary pulmonary coccidioidomycosis: Case of a laboratory infection in England. *Lancet* 1:982-984, 1948.
20. Bush JD: Coccidioidomycosis. *J Med Assoc State Ala* 13:159-166, 1943.
21. Overholt EL, Hornick RB: Primary cutaneous coccidioidomycosis. *Arch Intern Med* 114:149-153, 1964.
22. Sorensen RH, Cheu SH: Accidental cutaneous coccidioidal infection in an immune person. *Calif Med* 100:44-47, 1964.
23. Trimble JR, Douchette J: Primary cutaneous coccidioidomycosis: Report of a case of laboratory infection. *Arch Dermatol* 74:405-410,

1956.

24. Wilson JW, Smith CE: Primary cutaneous coccidioidomycosis: The criteria for diagnosis. *Calif Med* 79:233-239, 1953.

25. Brown PK, Cummins WT: A differential study of coccidioidal granuloma and blastomycosis. *Trans Assoc Am Physicians* 29:628-650, 1914.

26. Wegmann T, Plempel M: Das Krankheitsbild der Coccidioidomykose. *Dtsch Med Wochenschr* 99:1653-1656, 1974.

27. Johnson JE III, Perry JE, Fekety FR, et al: Laboratory-acquired coccidioidomycosis: A report of 210 cases. *Ann Intern Med* 60:941-956, 1964.

28. Fava A: Un cas de sporotrichose conjonctivale et palpebrale primitives. *Ann Ocul* 141:338-343, 1909.

29. Jeanselme E, Chevallier P: Transmission de la sporotrichose a l'homme par les morsures d'un rat blanc avec une nouvelle variete de Sporotrichum: lymphagite gommeuse ascendante. *Bull Mem Soc Med Hop* 31:287-301, 1911.

30. Wilder WH, McCullough CP: Sporotrichosis of the eye. *JAMA* 62:1156-1160, 1914.

31. Meyer KF: The relation of animal to human sporotrichosis. *JAMA* 65:579-585, 1915.

32. Fielitz H: Ueber eine Laboratoriumsinfektion mit dem Sporotrichum de Beurmann. *Centralbl Baketeriol Orig* 55:361-370, 1910.

33. Norden A: Sporotrichosis: Clinical and laboratory features and a serologic study in experimental animals and humans. *Acta Pathol Microbiol* 89(suppl):3-119, 1951.

34. Mikkelsen WM, Brandt RL, Harrell ER: Sporotrichosis: A report of 12 cases, including two with skeletal involvement. *Ann Intern Med* 47:435-459, 1957.

35. Carougeau M: Premier cas Africain de sporotrichose de de Beurmann: Transmission de la sporotrichose du mulet a l'homme. *Bull Mem Soc Med Hop* 28:507-510, 1909.

36. Halde C: Percutaneous *Cryptococcus neoformans* inoculation without infection. *Arch Dermatol* 89:545, 1964.

37. Lurie HI: Sporotrichosis, in Baker RD: *Human Infection With Fungi, Actinomycetes and Algae.* New York, Springer-Verlag, 1971, 614-675.

38. Schneidau JD, Lamar LM, Hairston MA Jr: Cutaneous hypersensitivity to sporotrichin in Louisiana. *JAMA* 188:371-373, 1964.

39. McDonough ES, Lewis AL, Meister M: Sporothrix (*Sporotrichum*) *schenckii* in a nursery barn containing sphagnum. *Public Health Rep* 85:579-586, 1970.

40. D'Alessio DJ, Leavens LJ, Strumpf GC, et al: An outbreak of sporotrichosis in Vermont associated with sphagnum moss as the source of infection. *N Engl J Med* 272:1054-1058, 1965.

41. Crevasse L, Ellner PD: An outbreak of sporotrichosis in Florida. *JAMA* 173:29-33, 1960.

42. Becker FT, Young HR: Sporotrichosis. *Minn Med* 53:851-853, 1970.

43. Evers RH, Whereatt RR: Pulmonary sporotrichosis. *Chest* 66:91-92, 1974.

44. Taylor A, Blakey D, Phillips B: Sporotrichosis. *Miss Morbid Mortal Wk* 26:227-228, 1976.

45. Raphael SS, Schwarz J: Occupational hazards from fungi causing deep mycoses. *Arch Indust Hyg Occup Med* 8:154-165, 1953.

46. Ahearn DG, Kaplan W: Occurrence of *Sporotrichum schenckii* on a cold-stored meat product. *Am J Epidemiol* 89:116-124, 1968.

47. Sarosi GA, Parker JD, Tosh FE: Histoplasmosis outbreaks: Their patterns, in: *Proceedings of the Second National Conference on Histoplasmosis.* Springfield, Ill, Charles C Thomas Publisher, 1971, pp 123-128.

48. DiSalvo AF: The role of bats in the ecology of *Histoplasma capsulatum*, in: *Proceedings of the Second National Conference on Histoplasmosis.* Springfield, Ill, Charles C Thomas Publisher, 1971, pp 149-161.

49. Gonzalez-Ochoa A: Relaciones entre el habitat del murcielago y el *Histoplasma capsulatum. Rev Inst Salubr Enferm Trop* 23:81-86, 1963.

50. Jackson D: Histoplasmosis: A "spelunker's" risk. *Am Rev Respir Dis* 83:261-263, 1961.

51. Klite PD, Diercks FH: Bats and histoplasmosis: A clinicoepidemiologic study of human cases. *Ann Intern Med* 62:1263-1271, 1965.

52. Taylor RL, Shacklette MH, Kelley HB: Isolation of *Histoplasma capsulatum* and *Microsporum gypseum* from soil and bat guano in Panama and the Canal Zone. *Am J Trop Med Hyg* 11:790-795, 1962.

53. Garcia Rosell O: La fiebre de Tingo Maria: Histoplasmosis. *Ann Fac Med Lima* 38:1083-1091, 1955.

54. Lehan PH, Furcolow ML: Epidemic histoplasmosis. *J Chronic Dis* 5:489-503, 1957.

55. Adriano SM, Schwarz J, Silverman FN: Epidemiologic studies in an outbreak of histoplasmosis. *J Lab Clin Med* 46:592-596, 1955.

56. Schwarz J, Sethi KK: Recognition of changing sources in histoplasmic infection. *Mycopathologia* 37:77-80, 1969.

57. Loosli CG, Grayston JT, Alexander ER, et al: Epidemiologic studies of pulmonary histoplasmosis in a farm family. *Am J Hyg* 55:302-401, 1952.

58. Englert E Jr, Phillips AW: Acute diffuse pulmonary granulomatosis in bridge workers. *Am J Med* 15:733-740, 1953.

59. Leznoff A, Frank H, Telner P, et al: Histoplasmosis in Montreal during the fall of 1963, with observation of erythema multiforme. *Can Med Assoc J* 91:1154-1160, 1964.

60. Wilcox KR Jr, Waisbren BA, Martin J: The Walworth Wisconsin epidemic of histoplasmosis. *Ann Intern Med* 49:388-418, 1958.

61. Kier JH, Campbell CC, Ajello L, et al: Acute bronchopneumonic histoplasmosis following exposure to infected garden soil. *JAMA* 155:1230-1232, 1954.

62. Scalia SP: An outbreak of histoplasmosis in Baltimore County. *Md State Med J* 10:614-619, 1961.

63. Brodsky AL, Gregg MB, Loewenstein MS, et al: Outbreak of histoplasmosis associated with the 1970 Earth Day activities. *Am J Med* 54:333-342, 1974.

64. Tosh FE, Doto IL, D'Alessio DJ, et al: The second of two epidemics of Histoplasmosis resulting from work on the same starling roost. *Am Rev Respir Dis* 94:406-413, 1966.

65. Tosh FE, Weeks RJ, Pfeiffer FR, et al: Chemical decontamination of soil containing *Histoplasma capsulatum. Am J Epidemiol* 83:262-270, 1966.

66. Tosh FE, Weeks RJ, Pfeiffer FR, et al: The use of formalin to kill *Histoplasma capsulatum* at an epidemic site. *Am J Epidemiol* 85:259-265, 1967.

67. D'Alessio DJ, Heeren RH, Hendricks SL, et al: A starling roost as the source of urban epidemic histoplasmosis in an area of low incidence. *Am Rev Respir Dis* 92:725-731, 1965.

68. Smith CD, Furcolow ML, Tosh FE: Attempts to eliminate *Histoplasma capsulatum* from soil. *Am J Hyg* 79:170-180, 1964.

69. Emmons CW, Piggott WR: Eradication of *Histoplasma capsulatum* from soil. *Mycologia* 55:521-527, 1963.

70. Plunkett OA, Swatek FE: Ecological studies of *Coccidioides immitis*, in *Proceedings of the Armed Forces VA Symposium on Coccidioidomycosis.* US Public Health Service Publication 575, 1957, pp 158-160.

71. Swatek FE: The epidemiology of Coccidioidomycosis, in AlDoory Y: *The Epidemiology of Human Mycotic Diseases.* Springfield, Ill, Charles C Thomas Publisher, 1975, pp 74-102.

72. Werner SB, Pappagianis D, Heindl I, et al: An epidemic of coccidioidomycosis among archeology students in Northern California. *N Engl J Med* 286:507-512, 1972.

73. Loofbourow JC, Pappagianis D, Cooper TY: Endemic coccidioidomycosis in Northern California: An outbreak in the Capay Valley of Yolow County, California. *Calif Med* 111:5-9, 1969.

74. Werner SB, Pappagianis D: Coccidioidomycosis in northern California. *Calif Med* 111:16-20, 1973.

75. Schmidt RT, Howard DH: Possibility of *C immitis* infection of museum personnel. *Pub Health Rep* 83:882-888, 1968.

76. Rothman PE, Graw RG, Harris JC, et al: Coccidioidomycosis-possible fomite transmission. *Am J Dis Child* 118:792-801, 1969.

77. Joffe B: An epidemic of coccidioidomycosis probably related to soil. *N Engl J Med* 262:720-722, 1960.

78. Walch HA, Pribnow JF, Wyborney VJ, et al: Coccidioidomycosis in San Diego County and the involvement of transported top soil in certain cases. *Am Rev Respir Dis* 84:359-363, 1961.

79. Levan NE, Huntington RW Jr: Primary cutaneous coccidioidomycosis in agricultural workers. *Arch Dermatol* 92:215-220, 1965.

80. Albert BL, Sellers TJ Jr: Coccidioidomycosis from fomites. *Arch Intern Med* 112:253-261, 1963.

81. Gelbach SH, Hamilton JD, Conant NF: Coccidioidomycosis: An occupational disease in cotton mill workers. *Arch Intern Med* 131:254-255, 1973.

82. Smith CE: Reminiscenses of the flying chlamydospore and its allies, in Ajello L (ed): *Coccidioidomycosis.* Tuscon, University of Arizona Press, 1967.

83. Eckmann BH, Schafer GL, Huppert M: Bedside interhuman transmission of coccidioidomycosis via growth on fomites: An epidemic involving 6 persons. *Am Rev Respir Dis* 89:175-185, 1964.

84. Skinner JB: Newer occupational diseases. *N Engl J Med* 243:482-486, 1950.

85. Levan NE: Occupational aspects of coccidioidomycosis. *Calif Med* 80:294-298, 1954.

86. Falkinburg LW: Disseminated coccidioidomycosis: Report of a case in the New England area. *JAMA* 150:216-217, 1952.

87. Symmers W StC: Cases of coccidioidomycosis seen in Britain, in Ajello L (ed): *Coccidioidomycosis.* Tucson, University of Arizona Press, 1967, pp 301-308.

88. Schmelzer LL, Tabershaw IR: Exposure factors in occupational coccidioidomycosis. *Am J Public Health* 58:107-113, 1968.

89. Salkin D: Clinical examples of reinfection in coccidioidomycosis, in Ajello L (ed): *Coccidioidomycosis.* Tuscon, University of Arizona Press, 1967, pp 11-18.

90. Salfelder K: Cryptococcosis, in Baker RD: *Human Infection With Fungi, Actinomycetes and Algae.* New York, Springer Verlag, 1971, pp 383-464.

91. Barron CN: Cryptococcosis in animals. *J Am Vet Med Assoc* 127:125-132, 1955.

92. Pounden WD, Amberson JM, Jaeger RF: A severe mastitis problem associated with *Cryptococcus neoformans* in a large dairy herd. *Am J Vet Res* 13:121-128, 1952.

93. Emmons CW: *Cryptococcus neoformans* strains from a severe outbreak of bovine mastitis. *Mycopathologia* 6:231-234, 1952.

94. Simon J, Nichols RE, Morse EV: An outbreak of bovine cryptococcosis. *J Am Vet Med Assoc* 122:31-35, 1953.

95. Emmons CW: Saprophytic sources of *Cryptococcus neoformans* associated with the pigeon. *Am J Hyg* 62:227-232, 1955.

96. Fink JN, Barboriak JJ, Kaufman L: Cryptococcal antibodies in pigeon breeders disease. *J Allergy* 41:297-301, 1968.

Rapid relief...

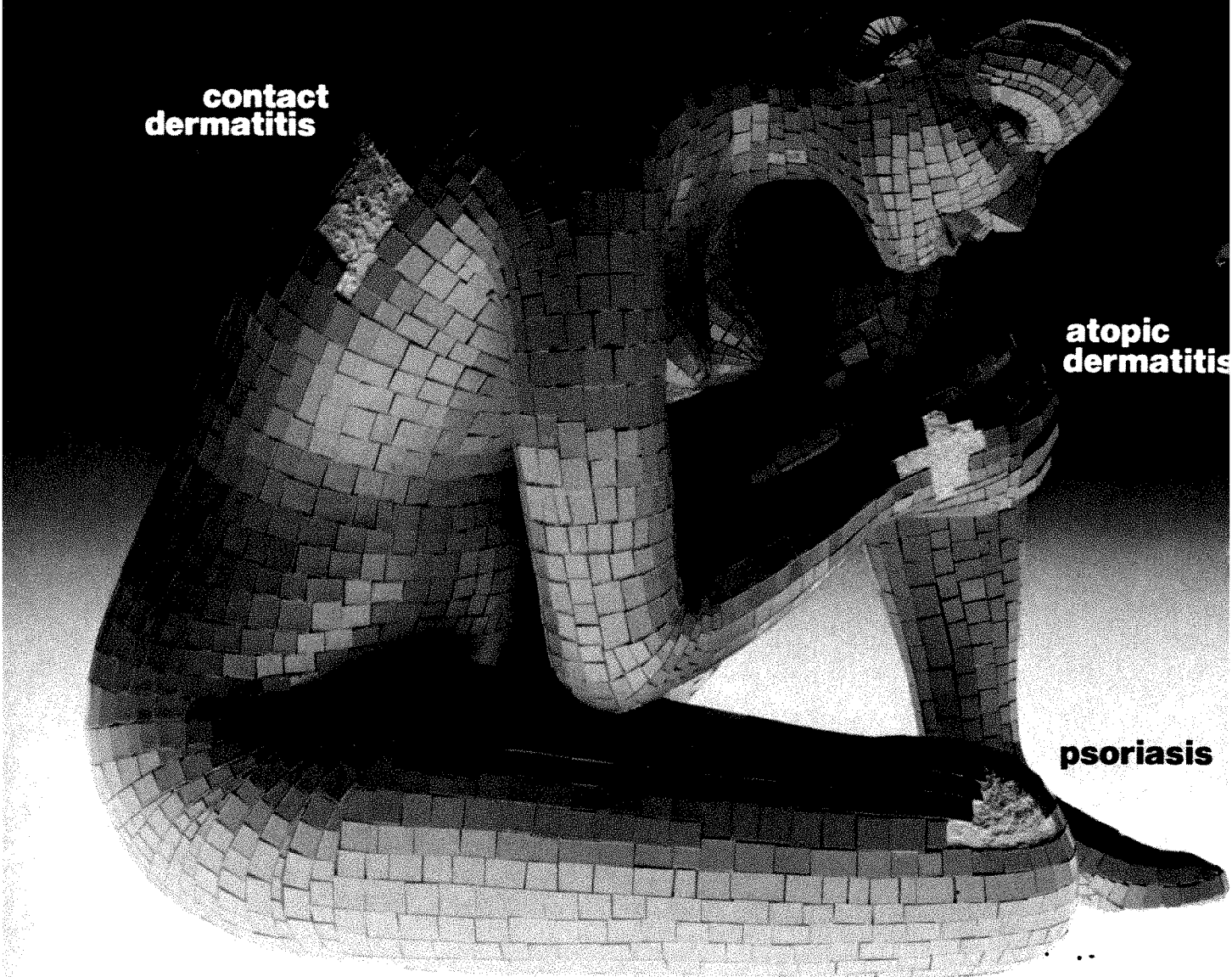

COPYRIGHT © 1977, SCHERING CORPORATION. ALL RIGHTS RESERVED.

b.i.d.
Diprosone®
brand of
betamethasone dipropionate
Cream 0.05%
(Potency expressed as betamethasone)

Twice a day for prompt relief of corticosteroid-responsive dermatoses

In contact dermatitis



90% of patients showed marked or moderate improvement in seven days*
34 of 38 contact dermatitis patients responded to therapy.

In atopic dermatitis



86% of patients showed marked or moderate improvement in seven days*
133 of 155 atopic dermatitis patients responded to therapy.

In psoriasis



62% of patients showed marked or moderate improvement in only seven days*
116 of 188 psoriasis patients responded to therapy.

Additional benefits:

- Rapid onset of response.
- Economy and convenience of b.i.d. dosage.
- Occlusive dressings infrequently needed.
- Sensitivity is rare.
- Choice of convenient package sizes—in 15 Gm. and moneysaving 45 Gm. tubes.

Diprosone® brand of betamethasone dipropionate
Cream 0.05%/Ointment 0.05%

Clinical Considerations:

DESCRIPTION DIPROSONE is betamethasone dipropionate (9-fluoro-11β, 17,21-trihydroxy-16β-methylpregna-1,4-diene-3,20-dione 17,21-dipropionate). Each gram of DIPROSONE **Cream** 0.05% contains 0.64 mg. betamethasone dipropionate (equivalent to 0.5 mg. betamethasone) in a hydrophilic, emollient cream consisting of purified water, mineral oil, white petrolatum, polyethylene glycol 1000 monocetyl ether, cetostearyl alcohol, phosphoric acid, and monobasic sodium phosphate with 4-chloro-*m*-cresol as preservative. Each gram of DIPROSONE **Ointment** 0.05% contains 0.64 mg. betamethasone dipropionate (equivalent to 0.5 mg. betamethasone) in an ointment base of mineral oil and white petrolatum. **CONTRAINDICATIONS** DIPROSONE **Cream** and **Ointment** are contraindicated in vaccinia and varicella. Topical steroids are contraindicated in those patients with a history of hypersensitivity to any of the components of such preparations. **PRECAUTIONS** If irritation develops with the use of DIPROSONE **Cream** or **Ointment,** treatment should be discontinued and appropriate therapy instituted. In the presence of an infection, the use of an appropriate antifungal or antibacterial agent should be instituted. If a favorable response does not occur promptly, the corticosteroid should be discontinued until the infection has been adequately controlled. If extensive areas are treated or if the occlusive technique is used, the possibility exists of increased systemic absorption of the corticosteroid and suitable precautions should be taken. Although topical steroids have not been reported to have an adverse effect on pregnancy, the safety of their use in pregnant females has not been absolutely established. Therefore, they should not be used extensively on pregnant patients, in large amounts or for prolonged periods of time. DIPROSONE **Cream** and **Ointment** are not for ophthalmic use. **ADVERSE REACTIONS** The following local adverse reactions have been reported with topical corticosteroids: burning; itching; irritation; dryness; folliculitis; hypertrichosis; acneiform eruptions; hypopigmentation. The following may occur more frequently with occlusive dressings than without such therapy: maceration of the skin; secondary infection; skin atrophy; striae; miliaria. **DOSAGE AND ADMINISTRATION** Apply a thin film of DIPROSONE **Cream** to the affected skin areas twice daily, in the morning and at night. Clinical studies of DIPROSONE have indicated that applications twice a day are generally adequate. Apply a small quantity of DIPROSONE **Ointment** to the affected skin areas twice daily, in the morning and at night.

APRIL 1976

For more complete details, consult package insert or Schering literature available from your Schering Representative or Professional Services Department, Schering Corporation, Kenilworth, New Jersey 07033.

*Data in files of Headquarters Medical Research Division, Schering Corporation.

Also available for prescribing flexibility

b.i.d. Diprosone® Ointment 0.05%
brand of betamethasone dipropionate

SLS-710



Bee-sting Allergy

Phadebas RAST® provides an accurate means of documenting IgE mediated allergic sensitivity to stinging insects.

Phadebas RAST®

the *in vitro* alternative

Pharmacia Diagnostics AB
Uppsala, Sweden

Pharmacia Diagnostics

Argentina Laboratorios Dr. Gador y Cia., S.A.C.I. Casilla de Correo 4041 BUENOS AIRES. **Australia** Pharmacia (South Seas) Pty. Ltd. P.O. Box 175 Cnr Talavera&Khartoum Roads NORTH RYDE N.S.W. 2113 **Austria** Pharmacia Gesellschaft m.b.H. Rathausplatz 4 A-1010 WIEN. Schoeller-Pharma G.m.b.H. Postfach 103 A-1111 WIEN. **Belgium** S.A. Pharmacia Belga N.V. Bld. Gen. Jacqueslaan 26 B-1050 BRUSSELS. **Brazil** Emprêsa Medimex Importacão e Comércio Ltda. Rua Cardoso Marinho, 40 Caixa Postal 33-ZC-00 RIO DE JANEIRO. **Canada** Pharmacia (Canada) Ltd. 2044 boul. St. Régis Blvd. DOVAL, Québec H9P 1H6. **Denmark** Pharmacia AS, Herredsvejen DK-3400 HILLERØD. **Finland** Pharmacia OY Alexandersgatan 48 A SF-HELSINGFORS 10. **France** Pharmacia France S.A. Rue de Marly Parly 2 F-78150 LE CHESNAY. **German Federal Republic** Deutsche Pharmacia GmbH Munziner Strasse 9 Postfach 5480 D-7800 FREIBURG 1. **Great Britain** Pharmacia (G.B.) Ltd. Paramount House 75 Uxbridge Road LONDON W5 5SS. **Greece** G.A. Kambanis Imports-Exports-Representations 3 Iridanou Street ATHENS 612. **Italy** Importex Chimici Farmaceutici S.p.A. P.O. Box 467 Via Flavia 122/124 I-34100 TRIESTE. **Mexico** Internacional Cientifica, S.A. Apartado 66-558 Zona 12 MEXICO 8 D.F. **The Netherlands** Gist-Brocades N.V. Diagnostics Dept. P.O. Box 324 Frijdastraat 7–9 RIJSWIJK (Z H) 2109. **Norway** Norsk Pharmacia A/S Postboks 2005 Grünerløkka OSLO 5. **Portugal** J.A. Baptista D'Almeida Lda. Apartado 1339 LISBOA 1. **South Africa** Keatings Medical Industries (Pty) Ltd. P.O. Box 256 JOHANNESBURG 2000 R.S.A. **Spain** Atom Paseo del Monte 34 BARCELONA 12. **Sweden** Pharmacia Norden AB Diagnostic Dept. Box 159 751 04 UPPSALA 1. **Switzerland** Pharmacia-pdf-(Schweiz) A.G. 214 Seefeldstrasse CH-8034 ZUERICH. **USA** Pharmacia Diagnostics Division of Pharmacia Inc. 800 Centennial Avenue PISCATAWAY, New Jersey 08854. **Other countries** Pharmacia Diagnostics AB Box 17 S-751 03 UPPSALA 1, Sweden.

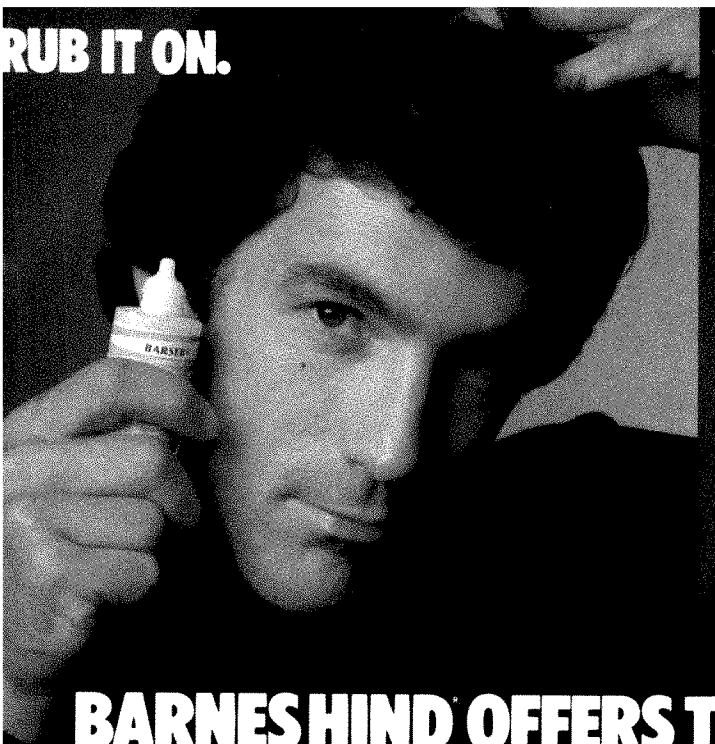

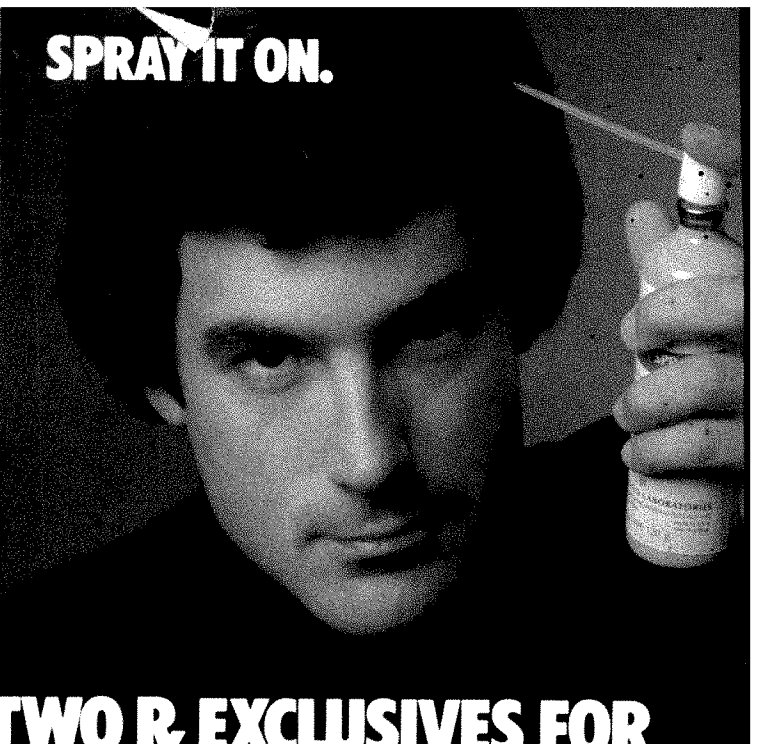

BARNES HIND OFFERS TWO Rx EXCLUSIVES FOR SEBORRHEIC DERMATITIS

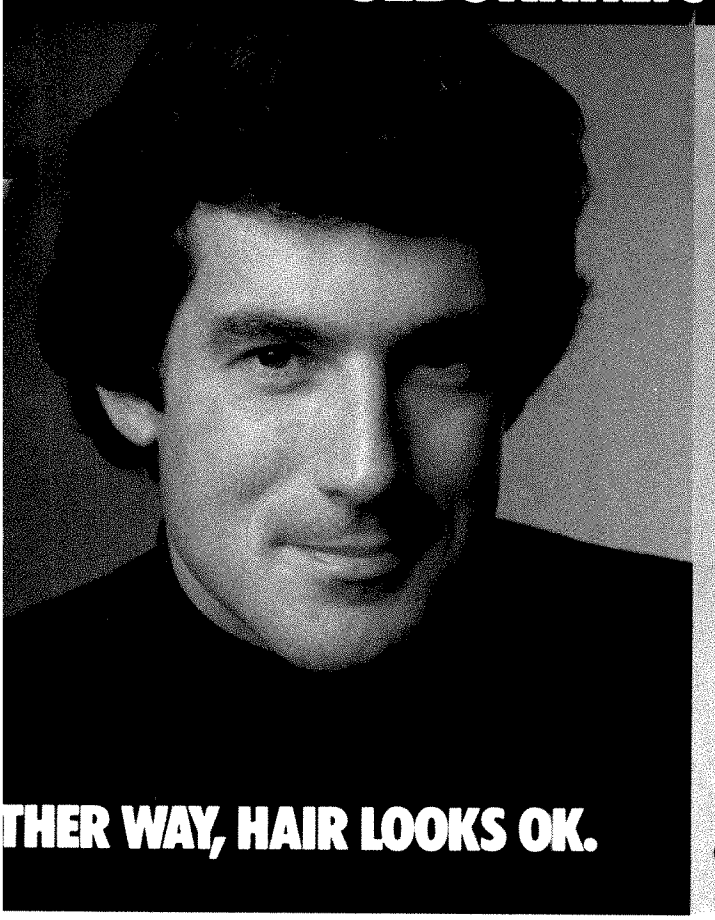

You can offer your seborrheic patients a choice of remedies that are effective yet cosmetically elegant—Barseb® Thera-Spray® and Barseb® HC Scalp Lotion.

Either way, you'll be prescribing Barnes Hind exclusive combinations of hydrocortisone and salicylic acid with their proven anti-inflammatory, antipruritic and keratolytic capabilities.

Without mussing the hair, the Thera-Spray snorkel directs the active ingredients onto the scalp in a vehicle that spreads and penetrates.

The Barseb HC base holds the active ingredients on the skin, not on the hair shafts. Barseb HC won't dry hair, or increase oiliness. And it's compatible with hair sprays, colorings, permanent waves and grooming agents.

Both Thera-Spray and Lotion are clear, non-staining, odorless.

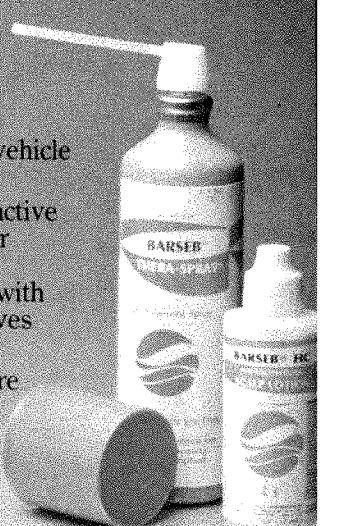

BARSEB® THERA-SPRAY®
BARSEB® HC SCALP LOTION

(hydrocortisone and salicylic acid)

For complete prescribing information, please see package insert.

ONTRAINDICATIONS
ydrocortisone is contraindicated in tuberculosis, ngal, and most viral infections of the skin (espe- ally herpes simplex, vaccina and varicella, etc).

ARNING
hile topical steroids have not been reported to ve an adverse effect on pregnancy, the safety of eir use has not been absolutely established. herefore, they should not be used extensively on egnant patients in large amounts nor for long riods of time.
oid inhalation, ingestion or contact with eyes nose.
ARSEB® THERA-SPRAY
ntents under pressure. Do not puncture or burn

PRECAUTIONS
Transient discomfort may occur when first applied to an inflamed scalp. This normally disappears with repeated use. Discontinue use if condition does not improve or if sensitivity reactions occur. The anti-inflammatory action of hydrocortisone may mask the presence of infection. If bacterial or fungal infection exists or supervenes, concomitant antimicrobial or antifungal therapy should be considered. When topical steroids are used on large areas of skin for long periods of time, there is the possibility of systemic absorption. Should adrenal suppression, electrolyte imbalance, metabolic changes, or other symptoms of systemic absorption occur, suitable counter measures

when hydrocortisone is used in the treatment of skin diseases associated with impaired circulation, such as stasis dermatitis.
Avoid spray inhalation, ingestion, or contact with eyes or nose. If medication accidentally gets into eyes, immediately flush with copious amounts of water; if irritation persists, notify your physician.
Keep out of reach of children.

CAUTION
U. S. Federal law prohibits dispensing without prescription.

Barnes Hind Pharmaceuticals, Inc.

Special Article

New Health Practitioners and Dermatology Manpower Planning

Melvin Krasner; David L. Ramsay, MD, MEd; Peyton E. Weary, MD; Marie-Louise T. Johnson, MD, PhD

• To assess the need for dermatologists in the United States, the potential role of new health practitioners in this specialty is considered. Available data on physician extenders in general and informed opinion on dermatologist extenders in particular suggest that specially trained, nonphysician personnel could substantially augment the supply of dermatological services. At present, however, widespread adoption of new staffing patterns appears unlikely. A long-run trend toward greater use of all categories of ancillary personnel in this specialty is expected, and the profession is urged to play an early and active role in this trend's development.

(*Arch Dermatol* 113:1280-1282, 1977)

A central consideration in estimating national dermatology manpower requirements is the quantity of patient care provided by a dermatologist. Many factors including the state of medical technology and the general organization of practice may affect productivity; however, a change in manpower staffing patterns, especially the introduction of new health practitioners (NHPs), eg, the physician's assistant, nurse practitioner, and MEDEX,[1] is viewed as a particularly important influence on the productivity of dermatologists.

As part of a study sponsored by the American Academy of Dermatology with the support of the Bureau of Health Manpower, Department of Health, Education, and Welfare, an effort has been made to analyze available information regarding NHPs, both in general medicine and in dermatology, to draw some broad conclusions about the potential impact of NHPs on manpower needs in the specialty.

Although using ancillary personnel in providing medical services is new neither in concept nor in practice, this subject has received considerable attention in recent years.[2,3] The substitution of auxiliary personnel for physicians whenever possible, and the development of NHPs have been proposed as methods for increasing the productivity of physicians, which would in turn alleviate the apparent problems in health care provision: (1) shortage of physicians, (2) rising cost of personal medical care, and (3) geographic inequality in the availability of such care.[4] The fact that auxiliary personnel, particularly NHPs, can have a corrective influence on these problems is generally recognized; however, the extent and magnitude of such influence remain largely unclear.

NHPs in General Medicine

Despite some reservations, patients have generally accepted NHPs.[5,6] Physicians have also expressed enthusiasm for such personnel,[7] but with important reservations and some dissent.[8-10] Both patients and physicians who have had some experience with NHPs are more likely to favor them than those who have not.[11,12] The quality of care, in terms of patients' outcomes, has been similar for traditional medical practices and those employing NHPs.[13,14] The greater personal attention, which an NHP can provide, and the additional physician time that is made available for difficult cases, are positive aspects of such care.[11,12]

A major consideration in manpower

Accepted for publication Jan 4, 1977.

From the American Academy of Dermatology Manpower Study, Department of Dermatology, New York University School of Medicine.

Reprint requests to 560 First Ave, New York, NY 10016 (Dr Ramsay).

planning is the productivity of NHPs. A wide range of productivity estimates is presented in the literature, but with the diversity of practice settings, training, experience, and other factors that are involved, this variation in productivity is to be expected.

Nelson et al report that ambulatory practices employing a MEDEX showed a 37% increase in patient visits, after three years of training and experience.[15] According to Schiff et al, the introduction of a nurse practitioner in a pediatrics practice can augment the productivity of a physician by more than one third.[16] The Burlington random trial of the nurse practitioner resulted in a 41% increase in the number of families under care.[13] In five Canadian family practices, additional training of employed personnel led to an average increase in productivity of 18%.[17] Lave et al report an instance where a physician's assistant saved 43% of a physician's time, which could have been used to expand patient care activities by 75%.[18] Steinwachs et al recently estimated that in routine adult ambulatory care, an NHP increased the productivity of a physician by 39%.[19]

Although wide variation in productivity is reported, the evidence seems to indicate that a reasonable expectation would be for an NHP to augment a physician's services by 30% to 40%. However, caution is necessary in generalizing these findings. Important determinants of the NHPs productivity include the following: (1) frequency of physician consultation, (2) time spent per patient, (3) type of care required,[20] and (4) physician and patient attitudes. These factors will necessarily differ among practices, and will undoubtedly be important considerations in extending findings in family practice and pediatrics to dermatology.

NHPs in Dermatology

Although there are formal physician's assistant training programs in many diverse specialties,[21] except for pilot or informal programs, there is no civilian program in dermatology. This fact is quite surprising, in light of the early interest shown in dermatologist extenders by the National Program for Dermatology.[22] In addition, a recent study of NHPs in general medicine revealed that diseases of the skin and subcutaneous tissue was a particularly suitable category for involvement by NHPs.[19]

Clear information upon which to assess the potential role of dermatologist extenders is rather sparse, despite a general feeling within the specialty that ancillary personnel can and often do contribute substantially to dermatological patient care. Dermatologists have been using support personnel in their practices for years, and many dermatologists delegate a large portion of their patient care to their assistants.[23-26]

Perhaps the most important consideration is the acceptance of NHPs among dermatologists. A survey of American dermatologists in 1968 found that about 60% of the respondents would be willing to delegate less than 10% of their professional office tasks to specially trained nurses or aides.[27] A more recent survey of the Chicago Dermatology Society "revealed a definite place for physician's assistants in dermatology."[26] However, the respondents felt that only about 15% of their work load could be handled by a trained assistant. A survey of the Louisiana Dermatology Society, reported by Welton,[24] seems to indicate a distinct reluctance among dermatologists to relinquish many tasks to assistants. A similar survey among California dermatologists found little interest in employing dermatologist's assistants in private practice.[22] In western New York, the recently established nurse practitioner program at the State University, Buffalo, appears not to have generated the expected enthusiasm among dermatologists in private practice, according to a letter from Richard L. Dobson, MD (March 3, 1976).

However, as experience with assistants grows and as the supply of adequately trained personnel increases, one can expect that more dermatological care will be handled by nonphysicians, particularly in institutional settings. A particularly effective experience in dermatology with a MEDEX who was the primary provider for about 40% of the patients in an institutional setting is described by Johnson.[28]

A recent survey of prepaid group practices conducted by the authors found extensive use of auxiliary personnel, although estimating their productivity was not possible. The most important group of support staff involved in direct patient care, was registered and vocational nurses; some nurses had special training and responsibility. One large group practice reported that a clinic assistant operated an acne clinic, which handled about two thirds as many patient visits annually, as ordinarily handled by one of its dermatologists.

The military has been a particularly encouraging environment for dermatologist extender training and utilization. The Dermatology Technician School of the US Navy, Philadelphia, is the only program in the country that trains large numbers of paramedical personnel in dermatology. Trainees are accepted into the program only after extensive general paramedical training and experience.[23] Hayen estimated that such personnel can augment the productivity of dermatologists by about one third,[23] which is consistent with the findings about NHPs in general, discussed earlier. Since the program's inception in 1957, more than 200 technicians were graduated; however, only 8% have been able to apply their experience and training in civilian careers, according to a letter from C. Robert Charles, MD (Feb 17, 1976). Thus, although the Navy program is a potential resource for the rest of the military and the civilian sector, there seem to be obstacles to the effective utilization of this resource.

Future Prospects

In the future, civilian academic medical centers may also play an important role in the development of NHPs in dermatology. The traditional response of medical centers to increasing demand, ie, expansion of residency positions, is largely precluded in the current austere economic environment. Compounding this situation is legislative and other pressure to expand primary care residencies at the expense of other specialty positions and to regulate the supply of residency positions to meet long-run national medical manpower requirements rather than the immediate

needs of individual health institutions. The increasing demand for care would encourage medical centers to consider implementing new staffing patterns for inpatient and outpatient services. As succeeding cohorts of physicians are trained in an environment where allied health personnel are extensively used, one would expect a corresponding increase in the acceptance and employment of such personnel in private practice.

Although this projected increase in the use of dermatologist extenders is expected to occur gradually, early planning and development of effective training programs are essential. Early experience with the use of dermatologist extenders showed great promise, but general interest was less than anticipated, perhaps because these efforts were premature or fragmented. Existing paramedical training programs, particularly the Navy Dermatology Technician School, should be considered as models for study and possible expansion or replication. A consortium of medical centers and dermatology associations should be established to provide the broad-based financial and professional support necessary to ensure the success of training programs and the effective integration of their trainees into the dermatology community.

The impact of nonphysician health care personnel on projections of national requirements for dermatologists appears limited in the near future. Dermatologist extenders have been shown to be acceptable and effective in a variety of settings, but many factors would limit the general applicability of their services at the present time.

In the long run, however, with the anticipated transformation in health services organization, the potential for change in manpower staffing patterns and physician productivity appears to be great. A farsighted, united effort by the specialty to prepare for such change can provide lasting social benefit.

This study was supported by grant 231-75-0021 from the Division of Medicine, Bureau of Health Manpower, Health Resources Administration, Department of Health, Education and Welfare.

References

1. Sadler AM, Sadler, BL, Bliss AA: *The Physician's Assistant—Today and Tomorrow.* Cambridge, Mass, Ballinger Publishing Co, 1975, pp 7-11.

2. Silver HK, Hecker JA: The pediatric nurse practitioner and the child health associate: New types of health professionals. *J Med Educ* 45:171-176, 1970.

3. Estes EH, Howard DR: Potential for newer classes of personnel: Experiences of the Duke physician's assistant program. *J Med Educ* 45:149-155, 1970.

4. Fein R: *The Doctor Shortage: An Economic Diagnosis.* Washington, DC, The Brookings Institution, 1967, pp 111-129.

5. Chenoy NC, Spitzer WO, Anderson GD: Nurse practitioners in primary care: II. Prior attitudes of a rural population. *Can Med Assoc J* 108:998-1003, 1973.

6. Patterson PK, Bergman AB, Wedgewood RJ: Parent reaction to the concept of pediatric assistants. *Pediatrics* 44:69-75, 1969.

7. Yankauer A, Tripp S, Andrews P, et al: The outcomes and service impact of a pediatric nurse practitioner training program—nurse practitioner training outcomes. *Am J Public Health* 62:347-353, 1972.

8. Lohrenz FN: The Marshfield Clinic physician-assistant concept: Critical evaluation of advantages, disadvantages, and prospects. *N Engl J Med* 284:301-304, 1971.

9. Riddick FA, Bryan JB, Gershenson MI, et al: Use of allied health professionals in internists' offices: Current practices and physicians' attitudes. *Arch Intern Med* 127:924-931, 1971.

10. Coye RD, Hansen MF: The "Doctor's assistant": A survey of physicians' expectations. *JAMA* 209:529-533, 1969.

11. Nelson EC, Jacobs AR, Johnson KG: Patients' acceptance of physician's assistants. *JAMA* 228:63-67, 1974.

12. Merenstein JH, Wolfe H, Barker KM: The use of nurse practitioners in a general practice. *Med Care* 12:445-452, 1974.

13. Spitzer WO, Sackett DL, Sibley JC, et al: The Burlington randomized trial of the nurse practitioner. *N Engl J Med* 290:251-256, 1974.

14. Levine DM, Morlock LL, Mushlin AI, et al: The role of new health practitioners in a prepaid group practice: Provider differences in process and outcomes of medical care. *Med Care* 14:326-347, 1976.

15. Nelson EC, Jacobs AR, Breer PE, et al: Impact of physician's assistants on patient visits in ambulatory care practices. *Ann Intern Med* 82:608-612, 1975.

16. Schiff DW, Fraser CH, Walters HL: The pediatric nurse practitioner in the office of pediatricians in private practice. *Pediatrics* 44:62-68, 1969.

17. Lees REM: Physician time saving by employment of expanded-role nurses in family practice. *Can Med Assoc J* 108:871-875, 1973.

18. Lave JR, Lave LB, Morton TE: The physician's assistant: Exploration of the concept. *Hospitals* 45:42-51, 1971.

19. Steinwachs DM, Shapiro S, Yaffee R, et al: The role of new health practitioners in a prepaid group practice: Changes in the distribution of ambulatory care between physician and nonphysician providers of care. *Med Care* 14:95-120, 1976.

20. Willemain TR, Moore GT: Planning a medical practice using paramedical personnel. *Health Serv Res* Spring 1974, pp 53-61.

21. Scheffler RM, Stinson OD: Characteristics of physician's assistants: A focus on specialty. *Med Care* 12:1019-1030, 1974.

22. *1972 Annual Report.* Division of Education and Communication of the National Program for Dermatology, 1972, pp 63-67.

23. Hayen DO: Socioeconomic pressure for new methods of health care delivery, letters to the editor. *Arch Dermatol* 106:421, 1972.

24. Welton DG: Physician support personnel in office practice. *Arch Dermatol* 105:42-45, 1972.

25. Epinette WW, David RG: The Navy dermatology technician. *Arch Dermatol* 107:687-688, 1973.

26. Lamberg SI: Physician's assistants in dermatology, editorial. *Arch Dermatol* 104:227-230, 1971.

27. *National Program for Dermatology.* Joint Committee on Planning for Dermatology, American Academy of Dermatology, 1969, p 26.

28. Johnson M: *Dermatology and the Physician's Assistant.* National Program for Dermatology, White River Junction, Vt, Right Press, 1974, pp 96-103.

PreSun® for proven sunscreen protection

(5% PABA LOTION/GEL)

helps protect against premature aging of skin and skin cancer caused by the sun

©1977, W.P. Inc.

WESTWOOD
PHARMACEUTICALS INC.
Buffalo, New York 14213

THE ONLY WAY TO END THE EPIDEMIC IS OVER HER DEAD BODY.

Kill the female itch mite (*sarcoptes scabiei*) and you've stopped the current scabies epidemic. Because when she burrows deep into the stratum corneum, she defies diagnosis and resists removal by surface-acting medications and cleansers. Her success has been making headlines around the country—with reports of scabies outbreaks in rural and suburban areas as well as in the cities.

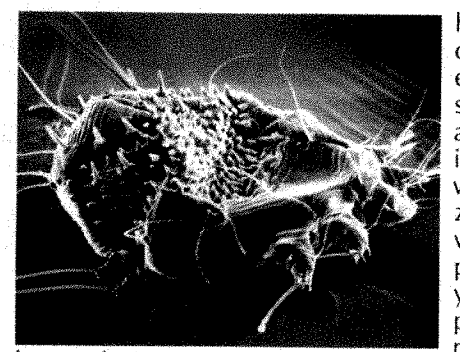

A quick and simple diagnosis. Scabies can mimic a number of dermatological conditions,[1-3] such as urticaria, furunculosis and dermatitis—as well as syphilis with which it may coexist. But there's an almost foolproof way to recognize it. Even in the absence of the fierce nocturnal itching[3] and the lesion distribution characteristic of the disease (hands, wrists and elbows in 9 out of 10 cases),[1] a quick microscopic look can confirm your scabies diagnosis.

To demonstrate the itch mite, look for an unscratched, inhabited burrow (wherever the patient says he itches at that very moment is a likely spot). Use a strong light, a magnifying glass and a surgical blade to which a drop of mineral oil is added. Scrape several sites. Transfer the material to a slide, cover and examine under low power magnification.[1,3,4] (If you don't spot any parasites in egg, larvae or adult stages, look for their red fecal compactions. They can be just as diagnostic.)

Kwell: penetrating action to kill mites, their eggs and larvae. Once you've found scabies, there's a positive way to eradicate it. Kwell (1% gamma benzene hexachloride) Lotion or Cream. It penetrates to reach the scabietic burrows, kills the female mites and, of course, the less tenacious males, as well as their eggs and any larvae that may have hatched. In fact, Kwell works so consistently and well against scabies that it has been the most widely prescribed scabicide for three decades.

Nearly 100% effective. The clinical record of Kwell has never been surpassed by any other pediculicide. It is "nearly 100% effective,"[1] and often works with a single application (a second or third application may be made at weekly intervals, if needed). Your patients will appreciate the low risk of sensitization and irritation.[5,6] And you will appreciate that Kwell works so predictably that it serves to confirm your diagnosis of scabies. Not many pharmaceutical preparations can match *that* record of dependability.

Contraindications: Kwell is contraindicated in individuals who develop hypersensitivity to the product or to any of its components.

Precautions: If accidental ingestion occurs, prompt institution of gastric lavage will rid the body of large amounts of the toxicant. However, since oils favor absorption, saline cathartics for intestinal evacuation should be given rather than oil laxatives.

Central nervous system manifestations can be antagonized by the administration of pentobarbital or phenobarbital in sufficiently large doses to the limit of their therapeutic effectiveness. It is not desirable to depress the patient to the point of hypnosis. However, persons poisoned with stimulants may tolerate large doses of barbiturate without undue depression and with great benefit. Intravenous calcium gluconate may be used in conjunction with the barbiturates. Epinephrine should not be used because ventricular fibrillation may result.

If accidental contact with eyes occurs, flush with water. If irritation or sensitization occurs, discontinue the product and consult physician.

Adverse Reactions: Eczematous eruptions due to sensitization of this product have been reported.

Available on prescription as Kwell Lotion in 2 and 16 fl. oz. bottles, and as Kwell Cream in 2 oz. and 1 lb. jars. See package insert for complete prescribing information.

References: 1. *Patient Care* 7:94, Nov. 1, 1973. 2. Stankler, L.: *Practitioner 210*:803, June 1973. 3. Domonkos, A.N. (ed.): Andrews' Diseases of the Skin: Clinical Dermatology, ed. 6, Philadelphia, W. B. Saunders Company, 1971, pp. 511-513. 4. Muller, G., *et al: Arch. Dermatol. 107*:70, Jan. 1973. 5. James, B.H.E.: *Br. Med. J. 1*:178, Jan. 15, 1972. 6. Sollman, T.: A Manual of Pharmacology, ed. 8, Philadelphia, W. B. Saunders Company, 1957, p. 178.

SEM Courtesy of J. M. Rower, M.D., Columbus, Ohio.

Reed & Carnrick / Kenilworth, New Jersey 07033

Cream/Lotion

KWELL® gamma benzene hexachloride

THE SCABICIDE OF CHOICE.

An unsurpassed standard of therapy

For effective and individualized control of acne....

Prescribe the only benzoyl peroxide acne medication available in cover-up lotions....

LOROXIDE® Acne Lotion and LOROXIDE-HC® Lotion

(benzoyl peroxide 5.5%, chlorhydroxyquinoline ¼%) (benzoyl peroxide 5.5%, chlorhydroxyquinoline ¼%, hydrocortisone ½%)

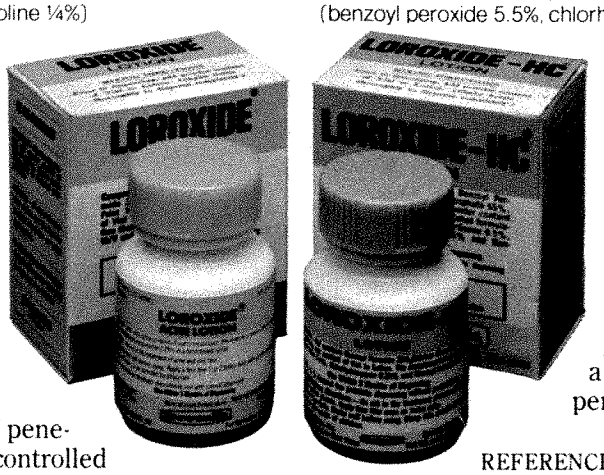

■ Contains the proved synergistic bactericidal combination of benzoyl peroxide and chlorhydroxyquinoline (300% greater antibacterial activity[1]) — which topically reduces C. Acnes *within* comedones[2]

■ LOROXIDE-HC® effectively treats papular, pustular and cystic acne[3] — a favorable response has been reported in 75% of patients in as short a period as two weeks[4]

■ Ideal therapy providing "all day," penetrating antimicrobial activity with controlled drying and desquamation — at school, work or play.

■ No sun-sensitizing properties — no need to restrict your patient's outdoor activities or eliminate the known benefits of natural UV exposure.

■ *The only* adjustable tint-intensity benzoyl peroxide lotions available.

■ Replaces and helps to prevent abuse with over-the-counter cosmetics.

■ For *day-long control* of all grades of acne vulgaris.

■ Lesion-masking base helps to eliminate the..."natural but distorted feelings that other people perceive him as 'acne with a person attached rather than as a person who happens to have acne.'"

REFERENCES: 1. Kuflik, E. G.: *Benzoyl Peroxide Gel in Acne Therapy,* Derm. Digest May, 1976, Pgs. 44-45. 2. Frank, L. and Petrou, P.: *Active Oxygen Plus Chlorhydroxyquinoline in Acne and Pyodermas,* Cutis, 3:3, Pg. 256-260, March, 1967. 3. Lubowe, I.: *Adolescent Skin Problems,* Cutis, Vol. 17, Pg. 369-374, February, 1976. 4. Frank, L.: *Active Oxygen in Acne Therapy,* Cutis 1:306, 1965. 5. Reisner, R.: *The Rational Therapy of Acne,* Cutis, Vol. 17, Pgs. 527-530, March, 1976.

Plus "Instant Social Confidence" Dermik Color Blender™

EXCLUSIVE!

Dermik

Dermik Laboratories, Inc.
Fort Washington, Pa. U.S.A. 19034

LOROXIDE® Acne Lotion and LOROXIDE-HC® Lotion

DESCRIPTION: Loroxide Acne Lotion contains (as dispensed) benzoyl peroxide 5.5%, and chlorhydroxyquinoline 0.25%, incorporated in a water washable lotion consisting of purified water, propylene glycol, hydroxyethylcellulose, caramel color, cholesterol-sterol, cetyl alcohol, propylene glycol stearate, polysorbate 20, lanolin alcohol, propylparaben, decyl oleate, purcelline oil syn., antioxidants, vegetable oil, methylparaben, tetrasodium EDTA, buffers, cyclohexanediamine tetraacetic acid, calcium phosphate, silicone emulsion, silica, kaolin, talc and titanium dioxide, with "Dermik Color Blender™" supplied separately.

Loroxide-HC Lotion contains (as dispensed) hydrocortisone 0.5%, benzoyl peroxide 5.5% and chlorhydroxyquinoline 0.25% incorporated in a lotion identical to Loroxide Lotion (see above).

Actions: Provides keratolytic, peeling and drying action.

Indications: An aid in the treatment of acne and oily skin.

Contraindications: This product is contraindicated for use by patients having known hypersensitivity to hydrocortisone, benzoyl peroxide, chlorhydroxyquinoline or any other component of this preparation. Topical steroids are contraindicated in viral diseases of the skin, such as varicella and vaccinia.

Warning — Usage in Pregnancy: Although topical steroids have not been reported to have an adverse effect on the fetus, the safety of their use during pregnancy has not been absolutely established. Therefore, they should not be used extensively, or in large amounts or for prolonged periods of time on pregnant patients.

Precautions: For external use only. Keep away from eyes. If irritation develops, the product should be discontinued and appropriate therapy instituted. In the presence of an infection, the use of appropriate antifungal or antibacterial agents should be instituted. If a favorable response does not occur promptly, the corticosteroid should be discontinued until the infection has been adequately controlled. If extensive areas are treated, or if the occlusive technique is used, the possibility exists of increased systemic absorption of the corticosteroid and suitable precautions should be taken.

Do not add any other medicaments or substances to this lotion unless specifically directed by physician to do so. Patients should be observed carefully for possible local irritation or sensitization during long-term topical therapy. Apply with caution on neck and/or other sensitive areas. There may be a slight, transitory stinging or burning sensation on initial application which invariably disappears on continued use. Ultraviolet and cold quartz light should be employed in lesser amounts, as this lotion is keratolytic and drying. Harsh, abrasive cleansers should not be used simultaneously with this lotion. Colored or dyed garments may be bleached by the oxidizing action of benzoyl peroxide. Chlorhydroxyquinoline may cause temporary light-yellowish skin staining in rare cases. Keep out of the reach of children.

Adverse Reactions: The following local adverse reactions have been reported with topical corticosteroids: burning sensations, itching, irritation, dryness, folliculitis, secondary infection, skin atrophy, striae, hypertrichosis, acneiform eruptions, and hypopigmentation. The sensitizing potential of benzoyl peroxide and chlorhydroxyquinoline are low, but they can, on occasion, produce allergic reaction. Occurrence of excessive redness or peeling indicates that the amount and frequency of application should be reduced.

Directions: Shake well before using. Apply a small quantity to affected areas with light massaging 1 to 3 times daily, or in accordance with the physician's directions.

(Important information directed to the Pharmacist: At time of dispensing, add contents of vial* to the bottle. Shake well and/or stir with a glass rod to insure a uniform dispersion. Place expiration date of three (3) months on bottle label.)

*"Benzie-Pak" vials contain a mixture of benzoyl peroxide 35% and calcium phosphate 65%.

Net weight of each vial is 3.8 grams.

How Supplied: Bottles, 25 Gm.

Caution: Federal law prohibits dispensing without prescription.

Search for a Causal Agent of Psoriasis by Seroepidemiologic Methods

Joan J. Ratner, MS, Kendall O. Smith, PhD

The cause of psoriasis is unknown, although one current hypothesis is that it is an inherited disease. Identical twin studies and clinical observations suggest that environmental factors are involved. The idea that this disease might be due to an infectious agent has been reported in the literature at various times. Zech and Lagerholm[1] reported virus-like particles in electron photomicrographs of psoriatic scales that were not present in the unaffected epidermis of psoriatic or normal skin. In 1971 Pozdnyakov[2] reported the isolation of a cytopathogenic agent for human epithelial-2 cells from the blood of patients in the progressive stage of the disease. Varelzidis and Theodoridis[3] reported an increase in serum IgA levels in patients with psoriasis, which returned to normal when the lesions were resolved by ultraviolet light therapy. In 1974 Stankler[4] found that the sera of patients who recovered from active psoriasis contained a factor that inhibited the development of lesions in these same patients during the progressive stage of the disease.

The purpose of this study was to determine whether an infectious agent plays a role in the cause of the disease, and a seroepidemiological study of psoriatic patients, with the use of a highly sensitive radioimmunoassay (RIA) was the method of approach. The plan was to determine antibody levels in patients with psoriasis and matched control patients against a select group of viral agents known to be associated with skin diseases; thus, it could be determined whether a substantial difference between the two groups exists. Psoriatic scales were cultured for the presence of unusual bacteria that were used as test antigens in the RIA. Suspensions of psoriatic scales were also used as antigens in the test.

From the Department of Microbiology, University of Texas Health Science Center, San Antonio.

Reprint requests to Department of Microbiology, University of Texas Health Science Center, 7703 Floyd Curl Dr, San Antonio, TX 78284 (Mrs Ratner).

Materials and Methods

Varicella-zoster virus and cytomegalovirus antigens were prepared from human fetal lung fibroblast cultures as previously described by Smith et al[5] and Patterson and Smith.[6] Herpes simplex virus type 1 was similarly prepared from human amnion tissue culture cells, and measles virus antigen was prepared from Vero cells. Control antigens were prepared from uninoculated tissue cultures.

Molluscum contagiosum "pearls" were minced, ground in a tissue grinder, and clarified by centrifugation at 39 g for three minutes. Phosphate-buffered saline was added to the supernatant fluid to a volume of 8 ml—a 1% (v/v) suspension.

A 1% (v/v) suspension of psoriatic scales was tested either untreated or treated with 0.02M glycine hydrochloride buffer at pH 3.2 (to dissociate antigen-antibody complexes).

Psoriatic scales were placed in tubes with sterile saline and thoroughly mixed. Suspensions were inoculated into culture media and incubated aerobically and anaerobically.

A positive control serum was tested for each of the viral antigens. Negative controls consisted of uninoculated tissue culture antigens or negative control serum.

Sera from 24 psoriatic patients and 24 controls, matched for age and sex, were used. All came from within a 24-mile radius of San Antonio, Tex.

The RIA procedure previously described by Smith et al[5] and Patterson and Smith[6] was followed. Specific counts were determined by subtracting counts that were obtained from the corresponding uninfected tissue culture antigens incubated with serum from those of virus-infected cell culture antigens incubated with the same serum.

Results

Staphylococcus aureus, *S epidermidis*, *Escherichia coli*, and an unusually large group-D *Streptococcus* were isolated from the cultures of psoriatic scales. This *Streptococcus* was used as antigen in one of the tests.

Specific counts were calculated for each serum with each antigen. Mean values were calculated for psoriatic patients and matched controls, and P values were determined by the Student's t test.

No statistically significant differences (P range, .1 to .9) between the psoriatic and control groups for antibodies to herpes simplex virus type 1, varicella-zoster virus, measles virus, molluscum contagiosum virus, cytomegalovirus, group-D *Streptococcus*, and treated and untreated psoriatic

scales were found. There was no unusual distribution or lack of antibody in either of the two groups.

Comment

There is the possibility that direct antibody determination may not be a suitable method of detection or that the causal agent was not included in the battery of tests.

Darl VanderPloeg, MD; Bob Limmer, MD; J. Lewis Pipkin, MD; and Charles Reiter, Jr, MD, assisted in obtaining specimens for this study.

References

1. Zech H, Lagerholm B: Particles resembling virus in psoriatic lesions. *Virology* 14:489-492, 1961.

2. Pozdnyakov OL: Data on the study of viral etiology of psoriasis. *Vestn Dermatol Venerol* 45:39-43, 1971.

3. Varelzidis A, Theodoridis A: Serum immunoglobulins in psoriasis before and after ultra violet light therapy. *Br J Dermatol* 85:14-17, 1971.

4. Stankler L: The effects of active and convalescent serum on the Kobner reaction in patients with active psoriasis. *Br J Dermatol* 91:15, 1974.

5. Smith KO, Gehle WG, McCracken AW: Radioimmunoassay techniques for detecting naturally occurring viral antibody in human sera. *J Immunol Methods* 5:337-344, 1974.

6. Patterson WR, Smith KO: Improvements of a radioimmunoassay for measurement of viral antibody in human sera. *J Clin Microbiol* 2:130-133, 1974.

Basal Cell Carcinoma With Bony Metastases Producing Myelofibrosis

Rama M. Jager, MD; Leonard J. Weiner, MD; Robert S. Howell, MD

Basal cell carcinoma rarely metastasizes. In more than 60% of reported patients, only lymph nodal metastases were present; bony metastases occur in fewer than 17% of patients with metastatic basal cell carcinoma.[1] In this report, we describe a patient with myelofibrosis secondary to bone marrow metastases from basal cell carcinoma.

Report of a Case

A 55-year-old man was admitted to the hospital in June 1976 with anorexia, dyspnea, weakness, and weight loss of gradual onset. He underwent chemosurgical excision of a superficial skin cancer of unknown histologic type over his right lower eyelid in 1959 and was symptom-free until 1965 when the skin ulcer recurred. It was surgically excised (Fig 1), but during the next 11 years, it recurred several times and required multiple curettages, electrodesiccations, and surgical resections. In January 1976, radical exenteration of the right eye and right radical maxillectomy and resection of the ethmoid sinus were done because of the infiltration of the inferior rectus muscle with recurrent basal cell carcinoma. The patient remained free of symptoms until the present admission.

Results of physical examination on his current admission showed a single firm, but movable, 2-cm lymph node along the anterior border of the right sternomastoid muscle and an enlarged left lobe of the liver. A biopsy specimen from the lymph node showed follicular hyperplasia, but no lymph nodal metastases.

Results of laboratory studies on the present admission disclosed some unexpected values: hemoglobin, 10.3 gm/100 ml; WBC, 5,000/μl, with 25% polymorphonuclear leukocytes, 73% lymphocytes, and 2% eosinophils; platelet count, 24,000/μl. The peripheral blood smear showed anisocytosis, poikilocytosis, polychromasia, and moderate leukoerythroblastic reaction. Liver-spleen scintiscan showed enlargement of the left hepatic lobe and moderate enlargement of the spleen, but no evidence of metastases. A chest roentgenogram was negative for metastatic disease. Bone scintiscan (^{99m}Tc) showed increased uptake of the isotope by multiple marrow-containing bones (Fig 2). Bone marrow was aspirated and had notable hypocellularity (Fig 3) and infiltration with neoplastic cells resembling basal cells, as anastomosing cords, with severe desmoplastic response around these cords (Fig 3).

The patient was treated twice weekly with vincristine sulfate (1 mg intravenously), bleomycin sulfate (15 units over 24 hours), and prednisone (40 mg by mouth per day), for six weeks. After four weeks of therapy, the pancytopenia in the peripheral blood smear regressed, with a WBC count of 6,000/μl and platelet count of 150,000/μl. The patient remained in partial remission, as evidenced by the normal peripheral blood smear, until February 1977, when he showed recurrence of basal cell carcinoma in his right orbit, requiring electrocoagulation and continuation of systemic chemotherapy.

Comment

True basal cell carcinomas lack the ability to metastasize despite chronic and extensive growth and destruction of adjacent organs. This inability may be explained by the lack of autonomy of basal cell cancers evidenced by their failure to grow as autografts unless a connective tissue stromal component is present, in contrast to squamous cell cancers.[2] Basal cell cancer xenografts also fail to grow in immunologically privileged sites, such as the anterior chamber of the eye, unlike squamous cell cancer xenografts.[3]

Carcinomatous invasion of bone marrow leading to a clinical syndrome of myelofibrosis with myeloid metaplasia has been described with various malignant tumors.[4] Basal cell carcinoma metastatic to bone marrow producing "myelophthisic" anemia, to our knowledge, has been reported in only one patient.[5] Bone marrow failure complicated the therapy of this patient by reducing the number of

From the Departments of Surgery (Drs Jager and Weiner) and Pathology (Dr Howell), University of Louisville School of Medicine.

Reprint requests to Department of Surgery, University of Louisville School of Medicine, Health Science Center, Louisville, KY 40201 (Dr Jager).

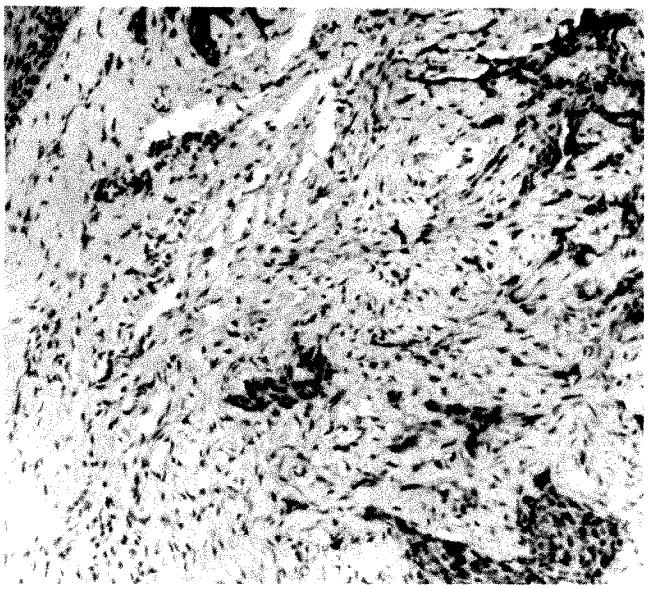

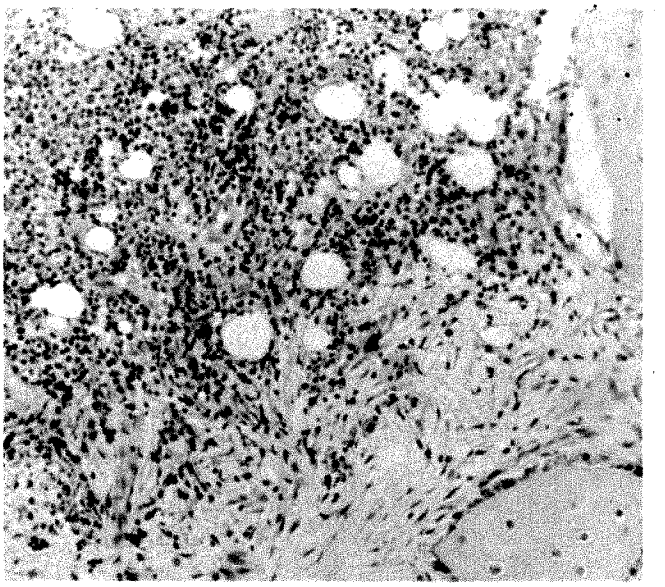

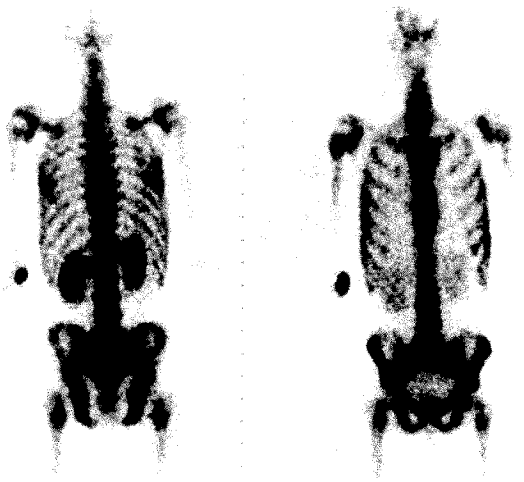

Fig 1.—Top left, Basal cell carcinoma showing characteristic uniform epithelioid cells arranged in masses.

Fig 2.—Bottom left, Bone scintiscan showing areas of increased uptake (suggestive of metastases) in multiple bones.

Fig 3.—Top right, Basal cell carcinoma metastatic to bone marrow, producing diffuse myelosclerosis. Note paucity of bone marrow cellularity and similarity between primary tumor and bone marrow metastases.

usable chemotherapeutic agents. The drugs selected should be nonmyelotoxic to avoid further suppression of bone marrow function in these patients. The choice of vincristine and bleomycin to treat this reported patient was based on the (1) selective concentration of bleomycin in epidermal cells, (2) relatively low myelotoxicity of the combination, and (3) synchronization of malignant cells in the mitotic phase by vincristine, in which phase cells are preferentially susceptible to bleomycin cytotoxicity.

The present case raises the question of the length of follow-up of patients with basal cell cancers. Patients with more than one basal cell cancer are estimated to have a 56% probability of developing a second skin cancer. Therefore, a more careful follow-up of patients with basal cell carcinoma is recommended. Basal cell carcinomas that have not recurred for six years are estimated to have less than 1% probability of recurrence.[6] This information, coupled with the observation that a majority of patients whose basal cell cancers metastasized had multiple previous recurrences, suggests that when a basal cell cancer recurs after a long latency and especially after multiple resections, chemotherapy, and radiation, the clinician should be alert to the possibility of lymph nodal or distant organ metastases.[1] Basal cell carcinomas may also become malignant during their long clinical course and acquire the ability to metastasize after multiple recurrences and multiple therapeutic maneuvers. Publication of information on use of newer chemotherapeutic agents with all the detected cases should aid in proper treatment of this rare disease.

Nonproprietary Names and Trademarks of Drugs

Bleomycin sulfate—*Blenoxane.*
Vincristine sulfate—*Oncovin.*

References

1. Costanza ME, Dayal Y, Binder S, et al: Metastatic basal cell carcinoma: Review, report of a case, and chemotherapy. *Cancer* 34:230-235, 1974.
2. Van Scott EJ, Reinertson RP: The modulating influence of stromal environment on epithelial cells studied in human autotransplants. *J Invest Dermatol* 36:109-131, 1961.
3. Gerstein W: Transplantation of basal cell epithelioma to the rabbit. *Arch Dermatol* 88:834-836, 1963.
4. Kiely JM, Silverstein MN: Metastatic carcinoma simulating agnogenic myeloid metaplasia and myelofibrosis. *Cancer* 24:1041-1044, 1969.
5. Coletta DF, Haentze FE, Thomas CC: Metastasizing basal cell carcinoma of the skin with myelophthisic anemia. *Cancer* 22:879-884, 1968.
6. Epstein E: Value of follow-up after treatment of basal cell carcinoma. *Arch Dermatol* 108:798-800, 1973.

Th seven most important reasons to prescribe a topical antifungal. Right at your fingertips.

1 It is effective against the most prevalent fungal pathogens. MicaTin brand miconazole nitrate 2% offers exceptional effectiveness against the most difficult-to-treat pathogen—*Trichophyton rubrum*, and is equally effective against *Trichophyton mentagrophytes, Epidermophyton floccosum, Candida albicans* and *Malassezia furfur.*

2 It clears the most common fungal infections. MicaTin provides outstanding clinical and mycological efficacy in tinea pedis,* tinea corporis* and tinea cruris* as well as candidiasis and tinea versicolor.

3 It relieves symptoms quickly. Within 72 hours for the majority of patients. Within 1 to 2 weeks for virtually all patients.

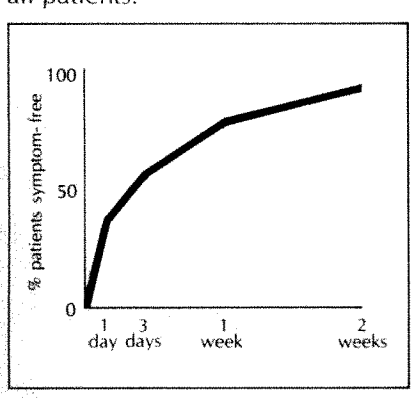

4 It demonstrates effectiveness in extensive studies. Clinical studies† demonstrate the outstanding success rate of MicaTin in the treatment of tinea pedis, tinea corporis and tinea cruris, when used with the recommended dosage of twice daily for one month. At the end of therapy, 88—94% of the patients were clinically clear.

The clinical studies of patients with candidiasis and tinea versicolor are equally impressive. Nine out of ten patients with candidiasis or tinea versicolor were clinically and mycologically clear within two weeks—the recommended duration of treatment.

Pathogen	Infection	Conversion KOH	Culture	Clinical Clearance or Improvement
Trichophyton rubrum	Tinea pedis	82%	86%	88%
Trichophyton mentagrophytes / *Epidermophyton floccosum*	Tinea corporis / Tinea cruris	93%	90%	94%
Candida albicans	Candidiasis†	92%	86%	88%
Malassezia furfur	Tinea versicolor	89%	—	92%

5 Its low relapse rate promises an outstanding chance of cure. To prove how effective MicaTin really is in keeping fungal infections clear, we evaluated these same patients one month later (median).† Of the 121 patients who were clear of tinea pedis, tinea corporis and tinea cruris at the end of treatment *and* were available for follow-up, 92% showed no clinical or mycological recurrence of the original infection.

And of the 34 patients cleared of cutaneous candidiasis *and* available for follow-up, 91% were still clear two weeks later (median).

6 It has a low incidence of side effects. Reports of "burning" sensation, irritation and maceration with MicaTin have been few and isolated. Naturally, it should not be used in patients with known hypersensitivity to any of its ingredients.

7 It is economically priced. The retail price of MicaTin is usually lower than that of other prescription antifungals.

Introducing new
MicaTin Lotion
brand miconazole nitrate 2%
12 ml. and 30 ml. bottles
MicaTin cream
brand miconazole nitrate 2%
new 85 g. (3 oz.) tube
and familiar 1 oz. and 15 g. sizes

Description: MicaTin brand miconazole nitrate cream 2% and lotion 2% each contain miconazole nitrate‡ 2%, formulated into a water miscible base consisting of pegoxol 7 stearate, peglicol 5 oleate, mineral oil, benzoic acid, and butylated hydroxyanisole.

Actions: Miconazole nitrate is a synthetic antifungal agent which inhibits the growth of the common dermatophytes, *Trichophyton rubrum, Trichophyton mentagrophytes,* and *Epidermophyton floccosum,* the yeast-like fungus, *Candida albicans,* and the organism responsible for tinea versicolor (*Malassezia furfur*).

Indications: For topical application in the treatment of tinea pedis (athlete's foot), tinea cruris, and tinea corporis caused by *Trichophyton rubrum, Trichophyton mentagrophytes,* and *Epidermophyton floccosum,* in the treatment of cutaneous candidiasis (moniliasis), and in the treatment of tinea versicolor.

Contraindications: MicaTin has no known contraindications.

Precautions: If a reaction suggesting sensitivity or chemical irritation should occur, use of the medication should be discontinued.

For external use only. Avoid introduction of MicaTin brand miconazole nitrate cream 2% and lotion 2% into the eyes.

Adverse Reactions: There have been isolated reports of irritation, burning, and maceration associated with application of MicaTin.

Dosage and Administration: Sufficient MicaTin cream should be applied to cover affected areas twice daily (morning and evening) in patients with tinea pedis, tinea cruris, tinea corporis, and cutaneous candidiasis and once daily in patients with tinea versicolor. It is preferable to use MicaTin lotion in intertriginous areas; if the cream is used, it should be applied sparingly and smoothed in well to avoid maceration effects.

Early relief of pruritus (first week) and early clinical improvement (one to two weeks) have been seen in treatment of infections caused by common dermatophytes. Even though clinical improvement may be seen fairly soon after treatment is begun, *Candida* infections should be treated for two weeks and dermatophyte infections for one month in order to reduce the possibility of recurrence. If a patient shows no clinical improvement after a month of treatment, the diagnosis should be redetermined. Patients with tinea versicolor usually exhibit clinical and mycological clearing after two weeks of treatment.

How Supplied: MicaTin brand cream 2% containing miconazole nitrate at 2% strength is supplied in 1 oz., 15 g., and 3 oz. tubes. MicaTin brand lotion 2% containing miconazole nitrate at 2% strength is supplied in polyethylene squeeze bottles in quantities of 12 and 30 ml.

*When infecting organisms are *Trichophyton rubrum, Trichophyton mentagrophytes* and *Epidermophyton floccosum.*

†Data for tinea pedis is based on 4 weeks' therapy in 138 patients; for tinea cruris and tinea corporis—4 weeks' therapy in 50 patients; for tinea versicolor—2 weeks' therapy in 38 patients; for candidiasis—2 weeks' therapy in 23 patients and 4 weeks' therapy in 20 patients. (There was no significant difference in effectiveness between the two candidiasis groups.) Data on file, Dermatological Division, Johnson & Johnson.

‡Chemical name: 1-[2,4-dichloro-β-{(2,4-dichlorobenzyl) oxy} phenethyl] imidazole mononitrate.

An ethical specific from the Dermatological Division of
Johnson & Johnson
New Brunswick, New Jersey 08903

© Johnson & Johnson 1977

Cream/
Lotion

MicaTin

BRAND

miconazole nitrate 2%

It all adds up to confidence.

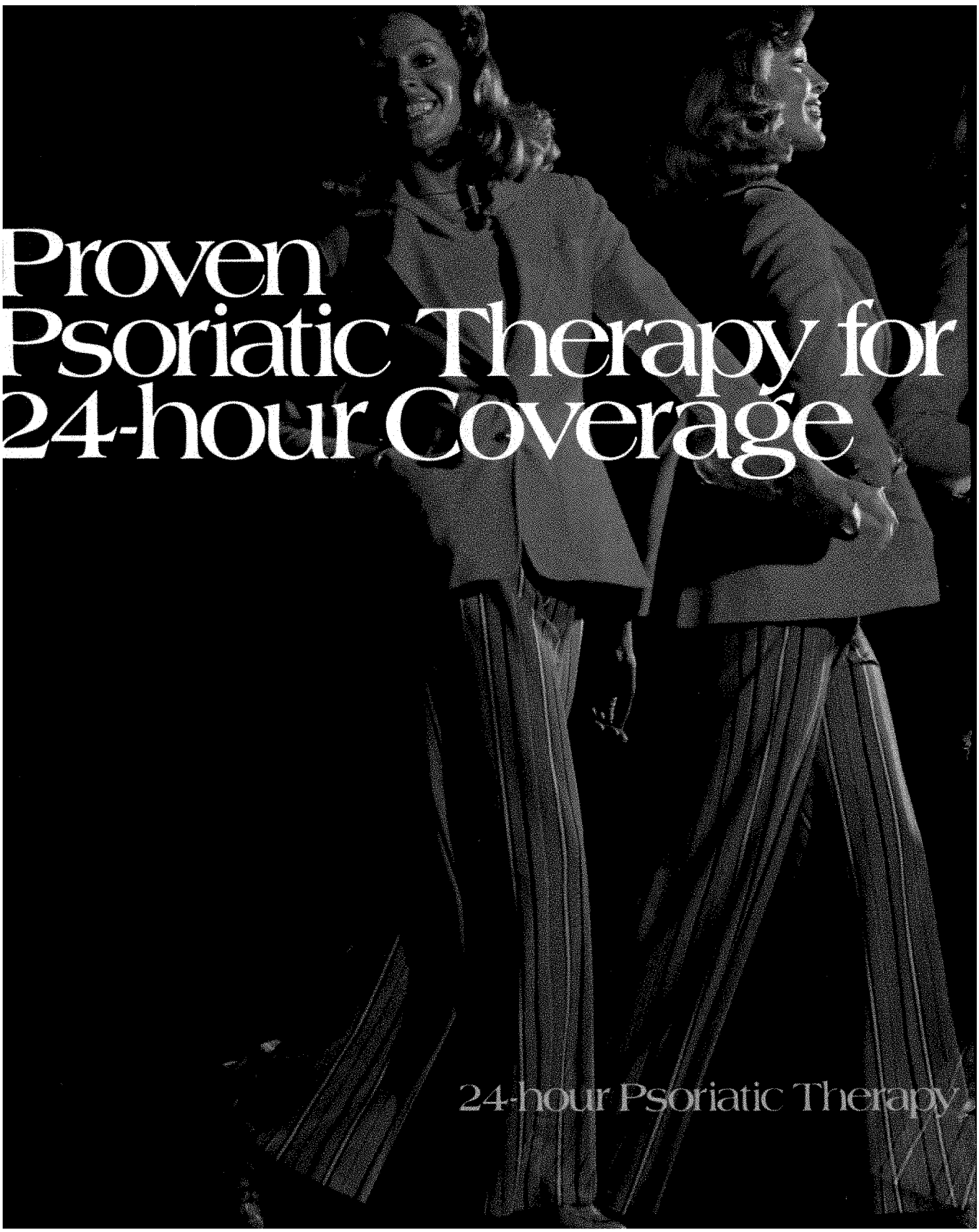
Proven
Psoriatic Therapy for
24-hour Coverage
24-hour Psoriatic Therapy

estar™

Therapeutic Tar Gel

Tar odor won't betray **estar** therapy. Proven **estar** Therapeutic Tar Gel is equivalent to 5% crude coal tar in everything but odor. No sticky, greasy residue to remain on the skin . . . proven therapy to control the formation of psoriatic scales and reduce itching with antipruritic action so that scratching is less likely.

The gel base enables the patient to apply **estar** evenly and smoothly. Tar therapy that doesn't smell like it . . . **estar** Therapeutic Tar Gel.

Balnetar®

Water-dispersible Emollient Tar

Change ordinary water into a psoriatic treatment for patients who bathe before bedtime. **Balnetar** can work through the night to provide keratoplastic, antieczematous, and antipruritic action. It lubricates and moisturizes the skin to relieve and help prevent excessive dryness while it softens and aids in the removal of scales and crusts. One to three capfuls of **Balnetar** added to a tub of warm water can extend the effect of **estar** Therapeutic Tar Gel to twenty-four hour tar therapy. The active ingredient in **Balnetar** treats the skin without staining it or the porcelain of the tub.

Sebutone®

Therapeutic Tar Shampoo

When psoriasis finds its way to the scalp, **Sebutone** can penetrate, soften, and remove scales, crusts, and excess oil with its chemically and biologically standarized tar. Microfine particles of tar remain on the scalp for up to three days (as shown with Wood's light) providing prolonged residual action. The fresh, clean fragrance and excellent cleansing properties of **Sebutone** make no other shampoo necessary when treating scalp psoriasis or any stubborn case of seborrhea or dandruff.

ith estar/Balnetar/Sebutone

Please see product information on next page.

©1977 W.P. Inc.

WESTWOO
PHARMACEUTICALS I
Buffalo, New York 142
In Canada, Belleville, Ontario K8N

estar™
Therapeutic Tar Gel

Composition: Westwood® Tar (biologically equivalent to 5% Coal Tar USP) in hydro-alcoholic gel (29% alcohol).

Actions and Uses: A therapeutic aid in the treatment of psoriasis and other tar responsive dermatoses such as eczema (atopic dermatitis, lichen simplex chronicus, nummular eczema) and seborrheic dermatitis. **estar** is suitable for use in a modified Goeckerman regimen, either in the hospital or on an outpatient basis; it also can be used in follow-up treatment to help maintain remissions.

Contraindications: estar should not be applied to acutely inflamed skin or used by individuals who are known to be sensitive to coal tar.

Dosage and Administration:

Psoriasis:
The patient should massage **estar** into affected areas, once or twice per day or as directed by physician. Rub in well, allow the gel to remain for five minutes, and then remove excess by patting with tissues.

Chronic atopic dermatitis, Lichen simplex chronicus, Nummular eczema, and Seborrheic dermatitis:

One or two applications per day, as described above, are suggested. If dryness occurs, an emollient may be applied one hour after **estar.**

Caution: AFTER USING, PROTECT TREATED AREAS FROM SUNLIGHT UNLESS DIRECTED BY PHYSICIAN. DO NOT USE ON HIGHLY INFLAMED OR BROKEN SKIN. If used on the scalp, temporary discoloration of blond, bleached, or tinted hair may occur. If undue irritation develops or increases, discontinue use and consult physician. AVOID CONTACT WITH EYES. In case of contact, flush eyes with water.

Slight staining of clothing may occur. Standard laundry procedures will usually remove stains.

For complete prescribing information, see PDR

SUPPLIED: 3 oz. plastic tube.

Balnetar®
Water-dispersible Emollient Tar

CONTAINS: WESTWOOD® TAR (Equivalent to 2.5% crude coal tar U.S.P.) mineral oil, and lanolin oil.

Balnetar is an important adjunct in the management of a wide range of dermatoses, including:

Atopic dermatitis
Psoriasis
Chronic eczematoid dermatitis
Eczematoid dermatitis
Seborrheic dermatitis

Suggested for use in modified Goeckerman regimen.

Directions:
Balnetar should always be used with water—either added to water or rubbed into wet skin.

Bath: Add 1 to 3 captuls to a tub of warm water. Do not use soap. Soak for 10 to 20 minutes. Pat dry. Frequency depends on nature and severity of condition.

Direct Application: Pat off excess with tissue or old towel to help minimize staining of clothing or linens.

Scalp Application: Mix 2 to 3 captuls with ¼ cup of water. Rub into scalp with fingertips. Apply once a day, preferably before bedtime. A therapeutic shampoo may be used the following morning.

Contraindication: Not indicated when acute inflammation is present.

CAUTION: If irritation persists, discontinue use and consult physician. In rare instances, temporary discoloration of blond, bleached, or tinted hair may occur. In rare cases, Balnetar may cause allergic irritations attributable to coal tar. Keep out of the reach of children. AVOID CONTACT WITH EYES.

PRECAUTION: After use of Balnetar, avoid exposure to sunlight unless otherwise directed by physician. GUARD AGAINST SLIPPING IN BATHTUB. TO AVOID STAINING, DO NOT USE IN FIBER GLASS BATHTUBS.

SUPPLIED: 8 fl. oz. plastic bottles.

Sebutone®
Therapeutic Tar Shampoo

CONTAINS: WESTWOOD® TAR (equivalent to 0.5% Coal Tar U.S.P.) sulfur 2% and salicylic acid 2% in SEBULYTIC® brand of unique penetrating surface-active combination of soapless cleaners and wetting agents.

CAUTION: If undue skin irritation develops or increases, discontinue use and consult physician. In rare instances, temporary discoloration of blond, bleached, or tinted hair may occur. For external use only. Keep out of the reach of children. AVOID CONTACT WITH EYES. IN CASE OF CONTACT, FLUSH EYES WITH WATER.

SUPPLIED: 4 and 8 oz. bottles and Sebutone Cream in 4 oz. tubes.

WESTWOOD
PHARMACEUTICALS INC
Buffalo, New York 14213
In Canada, Belleville, Ontario K8N 1E2

Letters to the Editor

Spread of Condyloma Acuminata to Infants and Children

To the Editor.—In their letter to the editor (ARCHIVES 112:1329, 1976), Goldman et al indicate that condyloma acuminata and digital or plantar warts may spread from family member to family member. We have had two occasions in the past year to suspect that young children with perianal condyloma acuminata had been sexually molested by family members who also had condyloma acuminata. Such an investigation might be worthwhile in the cases of Goldman and his associates.

Additionally, the work of Cook et al indicates that the mothers of children with laryngeal papillomas not uncommonly had condyloma acuminata at the time of delivery of their infected children.[1] Boyle and co-workers[2] were able to identify a papovavirus by electron microscopical examination of a laryngeal papilloma obtained from an adult and a papilloma obtained from a child. Boyle et al further commented on the transmissibility of the virus in condyloma acuminata and noted that the child in their study was born to a mother who had genital warts.

Laryngeal papillomas in children can be totally incapaciting and are associated with respiratory distress and frequent recurrences even after the lesions have been surgically removed. The treatment is surgical at the present time, although the immunotherapeutic approach to treatment with autogenous vaccine, as was first suggested by Powell et al[3] for condyloma acuminata, has been extended by Curtis and Ablin.[4] Condyloma acuminata in pregnant women should be treated with enthusiasm; possibly, some obstetricians and gynecologists may consider doing cesarean sections in the instances of women who have very extensive lesions. Perez-Figaredo and Baden[5] have recently mentioned that podophyllum probably should not be used in treating condyloma acuminata on pregnant women because of its known teratogenic effect. These authors, however, do indicate that there is no real evidence linking the topical application of podophyllum to fetal malformations, at the present time.

A prospective study designed to determine the incidence of laryngeal papillomas that occur in children born to mothers who have condyloma acuminata at the time of delivery, coupled with the information about the passage of the papovavirus across the placenta might help mold an approach to treating condyloma acuminata in pregnancy that could prevent the problem of childhood laryngeal papillomas.

FRANCES J. STORRS, MD
Portland, Ore

1. Cook TA, Brunschwig JP, Butel JS, et al: Laryngeal papilloma: Etiologic and therapeutic considerations. *Ann Otol Rhinol Laryngol* 82:649-655, 1973.
2. Boyle WF, Riggs JL, Oshiro LS, et al: Electron microscopic identification of papova virus in laryngeal papilloma. *Laryngoscope* 83:1102-1108, 1973.
3. Powell LC Jr, Pollard M, Jinkins JL: Treatment of condyloma acuminata by autogenous vaccine. *South Med J* 63:202-205, 1970.
4. Curtis WW, Ablin RJ: Immunotherapy of condyloma acuminata. *JAMA* 225:994, 1973.
5. Perez-Figaredo RA, Baden HP: The pharmacology of podophyllum. *Prog Derm* 10:1-4, 1976.

In Reply.—Dr Storrs has made some very important additional points about condylomata acuminata in children. In our discussions with the families of the patients, reported previously and recently, there was no evidence of sexual molestation by adults as far as we could determine.

We have worked with the Department of Otolaryngology of the Medical Center of the University of Cincinnati for more than 15 years on the familial incidence of laryngeal papillomas in children and on the use of autogenous wart extracts for therapy. These extracts are prepared from both small bits of excised laryngeal papillomas and from digital warts of adults and children in the family. We have found digital and plantar warts in the family and the child that were associated with the laryngeal lesions, but we found no such associations with genital warts, like those that Powell et al had reported. As with any therapy for warts without controls,

there is difficulty in evaluating the use of wart extracts for treatment. Because autogenous wart extracts often fail to prevent recurrent laryngeal papillomas, the carbon dioxide laser is now used effectively for treatment.

In cases of warts in the vaginal vault of the pregnant woman, especially when the warts are extensive, our Obstetric Service has done caesarean section. When the warts are not extensive on the labia or in the vault of the pregnant woman, the routine is now the use of the carbon dioxide laser for treatment instead of electrosurgery. Importantly, the current epidemic of condylomata acuminata involves also pregnant women. We will watch for increased incidence of laryngeal papillomas during this epidemic.

LEON GOLDMAN, MD
Cincinnati

Malignant Melanoma in a Thermal Burn Scar

To the Editor.—Last year we reported a case of malignant melanoma that arose in a thermal burn scar.[1] It was alleged by us that this was the first report of such an association in the literature. It was also the first case of an occupationally induced malignant melanoma in a burn scar. The patient was a 47-year-old San Francisco fireman who sustained burns while in the line of duty in 1964. In 1973 a malignant melanoma was excised from burn-scarred skin on the leg. The pigmented lesion was first noted in 1966. (Despite conventional and aggressive surgery and immuno- and chemotherapy, he died on Nov 30, 1975, of metastic disease).

After publication of our previous letter—as is often the case—we came upon an incidental comment about a melanoma that arose in a burn scar, published in 1965.[2] The authors presented 25 primary cancers that arose among 21 patients who were seen during a period of 20 years at Duke University. The breakdown was as follows: 18 squamous cell carcinomas, one basal cell epithelioma, one adenoacanthoma, and one melanoma. In their article, the authors did not elaborate on the latter case, nor was the uniqueness of that patient remarked upon. No details were given.

We corresponded earlier this year with the authors (Drs Pickrell and Gilbin). Unfortunately, none of the original work sheets were available to discuss the background and findings of their one case.

Recently, a monograph on malignant melanoma was published.[3] In the section on "The Relationship of Trauma to Melanoma," the author wrote: "Such a case of melanoma arising in a pigmented scar resulting from burns has been observed at Royal Prince Alfred Hospital." Whether the "burns" were thermal or chemical was not mentioned. Specific details of the case were not presented.

GERALD A. GELLIN, MD
WILLIAM L. EPSTEIN, MD
San Francisco

1. Gellin GA, Epstein WL: Malignant melanoma from thermal burn scar. *Arch Dermatol* 111:1214-1215, 1975.
2. Giblin TR, Pickrell KL, Pitts W, et al: Malignant degeneration in burn scars: Marjolin's ulcer. *Ann Surg* 162:291-297, 1965.
3. McGovern VJ: *Malignant Melanoma: Clinical and Histological Diagnosis.* New York, John Wiley & Sons, 1976, p 173.

Pruritus in Secondary Syphilis

To the Editor.—The article by Cole et al in the April ARCHIVES (113:489-490, 1977), entitled "Secondary Syphilis Presenting as a Pruritic Dermatosis," reaffirms the teachings of the late and great Dr Simeon Landy, who for decades taught his students that follicular syphilid occurring in black persons was frequently an extremely pruritic disorder. A clinical and serological two-year follow-up of 100 cases of proved secondary syphilis (to be reported in detail shortly) revealed eight patients (all black persons) with moderate to severe pruritus.

The article by Cole et al is but another step in the right direction toward updating the thinking about a disease that is so protean in its manifestations that it boggles the mind, and toward dispelling the antiquated dogmas of the past.

BURTON ALLYN, MD
New York

Photochemotherapy in Erythrodermic Seborrhoic Dermatitis

To the Editor.—Recurrences of erythrodermic seborrhoic dermatitis (SED) have often warranted the use of systemic corticosteroids.[1,2] The difficulties in tapering the corticosteroids, as well as their side effects, are well known.[3]

We report two cases of relapsing SED in long-term corticosteroid therapy, where clearing of the erythroderma and withdrawal of systemic steroids were made possible by concomitant photochemotherapy with psoralens and ultraviolet light A (PUVA).[4,5] A third case of recurrence after cessation of systemic steroid was cleared by photochemotherapy, too. Clinical findings are given in the table.

On this background, we advocate (1) that PUVA therapy is used as a therapeutic cover during withdrawal of systemic corticosteroids in patients

Clinical Findings

Finding	Patient 1	Patient 2	Patient 3
Duration of seborrhoic dermatitis, yr	12	7	3
Duration of systemic steroid therapy, mo	7	45	12
Cumulative dose of steroid, mg	11,392.5	5,383	4,160
Number of relapses after decrease of steroid dose	3	4	2
Duration of treatment with PUVA* (treatment from 0.5 to 3 joule/sq cm), mo.	7	1	2
Number of treatments with PUVA	9	18	32
Cumulative dose of 8-methoxypsoralen, mg	360	720	1,100
Side effects attributed to systemic corticosteroids	Arterial hypertension dyspnea, glucosuria	Cushingoid moon face	Arterial hypertension, elevated blood glucose
Follow-up Without relapse of seborrhoic dermatitis	9	6	...
With relapse of seborrhoic dermatitis	...	...	76. 16/2

*Psoralens plus ultraviolet light A.

with SED who are already receiving this drug and (2) that PUVA therapy is used instead of systemic corticosteroids in cases of SED as a new and better therapeutic alternative.

KARIN BIRGIT DAHL, MD
FLEMMING REYMANN, MD
Copenhagen

1. Andrews GC, Domonkos AN: *Diseases of the Skin*, ed 6. Philadelphia, WB Saunders Co, 1971, pp 221-224.
2. Rook A, Wilkinson DS, Ebling FJG: *Textbook of Dermatology*, ed 2. Oxford, Blackwell Scientific Publications, 1972, vol 2, pp 278-281.
3. Rosenberg FR, Sanders S, Nelson CT: Pemphigus: A 20-year review of 107 patients treated with corticosteroids. *Arch Dermatol* 112:962-970, 1976.
4. Parrish JA, Fitzpatrick TB, Tanenbaum L, et al: Photochemotherapy of psoriasis with oral methoxsalen and longwave ultraviolet light. *N Engl J Med* 291:1207-1211, 1974.
5. Walther JF, Vorhees JJ, Kelsey WH, et al: Psoralen plus black light inhibits epidermal DNA synthesis. *Arch Dermatol* 107:861-865, 1973.

A Simple Permanent Mount of *Sarcoptes scabiei*

To the Editor.—In the current epidemic of scabies, more extensive efforts are being made to try to demonstrate the parasites. In some dermatological centers, at least in the past, it was required that to make a diagnosis of scabies the parasites had to be demonstrated. Most of the current techniques used for microscopic studies of skin scrapings are usually moist preparations. It is difficult to preserve such preparations for detailed search or for permanent preparations for records or for teaching purposes.

A simple technique for preserving the parasite is to select what you consider the primary fresh lesion. This is scraped gently on a clean slide and immediately sprayed with hair spray such as is done for permanent preparations of Papanicolaou smears. May-Grünwald Giemsa stain may be used after this to help identify the parasites and the ova especially when scanning under low power. A coverslip is applied and the preparation is now a permanent mount. This technique may also be used for canine scabies in dogs for permanent mounts for teaching and collection, although this parasite is easy to demonstrate in dogs. This technique has probably been used before but is not well known.

Permanent hair spray mount of *Sarcoptes scabiei* (May-Grünwald Giemsa stain, original magnification ×200).

LEON GOLDMAN, MD
Cincinnati

Alopecia Areata and Vitiligo Associated With Down's Syndrome

To the Editor.—Nineteen cases of alopecia areata (AA) and four cases of vitiligo were noted in the skin of 214 patients with Down's syndrome. Patients with Down's syndrome are predisposed to immunological deficiency and thymus-dependent (T-cell) function. Drs Carter and Jegasothy suggested that immunological factors might contribute to the increased incidence of AA and vitiligo seen in patients with Down's syndrome.[1] In the May ARCHIVES (113:688, 1977), a marked depression in peripheral blood T-cell values of our patients with AA was compared with the values of 51 controls. The mean percentage of T-lymphocytes in AA was 58.9% compared with the control population of 74.9%. The number of T cells per cubic millimeter was 1,184 in patients with AA compared with the normal control of 1,461/cu mm. The T-cell percentage and T-cell number in AA patients was significantly different from the controls ($P < .001$).

Ninety-seven percent of our patients with AA had depressed (< 70%) T-cell levels in the peripheral blood. The T-cell levels in the peripheral blood in 24 patients with vitiligo were determined by the same method because of the frequent association with AA.[2] The patients ranged in age from 9 to 58 years, with a mean age of 35.9 years. The mean percentage of T-lymphocytes in patients with vitiligo was 55.2% compared with the control of 74.9%. The number of T cells per cubic millimeter in patients with vitiligo was 1,089.5 compared with the 1,460.7/cu mm value for the controls. The T-cell percentage and T-cell number in patients with vitiligo was significantly different from the controls ($P < .05$, and $P < .001$, respectively). Ninety-two percent of our patients (22/24) with vitiligo had depressed (< 70%) T-cell values in the peripheral blood. Two of these patients (11- and 18-year-old females) had Down's syndrome, Hashimoto's thyroiditis, and vitiligo. The 18-year-old patient with Down's syndrome had vitiligo and AA. Her normal brother had AA. Sixteen of our vitiligo patients were female, and eight were male; there were three black patients. There was no apparent relationship between age of the patient, and the number and the percent T cells. Duration of disease did not alter our results. The observation by Carter and Jegasothy[1] of tinea pedis (76.6%) in Down's syndrome is notable, although the identification of the dermatophyte would have been helpful. We have noted tinea corporis from *Trichophyton rubrum* in several patients with AA.[3]

Twenty-two of 24 vitiligo patients were tested for lymphocytotoxicity to our melanoma tumor cell line (M40) with an average percent toxicity of 80.8. The technique used was similar to that of Olkowski et al,[4] except that melanin-containing tissue culture cells were used and were identified as M40, melanoma tumor cell line. The lymphocytotoxicity results from 82 patients with AA against the same melanoma cell line (M40) averaged 71.2%. These percentages are not statistically different from one another.

We agree that the association of AA and vitiligo in Down's syndrome lends support to the proposition that immunological factors contribute to the development of AA and vitiligo. Our studies also indicate a decrease in the number and percentage of T cells in patients with vitiligo and AA. Lymphocytotoxicity tests of 82 AA and 22 vitiligo patients against the same melanoma tumor cell line (M40) were not statistically different.

ALGIE C. BROWN, MD
ZBIGNIEW L. OLKOWSKI, MD, ScD
JOHN R. MCLAREN, MD
MIKE H. KUTNER, PhD
Atlanta

1. Carter DM, Jegasothy BV: Alopecia areata and Down syndrome. *Arch Dermatol* 112:1397-1399, 1976.
2. Brown AC, Olkowski ZL, McLaren JR: Thymus lymphocytes of the peripheral blood in patients with alopecia areata. *Arch Dermatol* 113:688, 1977.
3. Jones HE, Reinhardt JH, Rinaldi MG: Immunologic susceptibility to chronic dermatophytosis. *Arch Dermatol* 110:213-220, 1974.
4. Olkowski ZL, McLaren JR, Mansour KA: Immunocompetence of Patients with Bronchogenic Carcinoma. *Ann Thorac Surg* 21:546-551, 1976.

Weight Loss and Psoriasis

To the Editor.—In reply to Drs Nowlin and Solomon (ARCHIVES 112:1465, 1976), I wish to draw their attention to a report[1] describing the remission of three cases of pustulosis palmaris et plantaris after intestinal shunt surgery for obesity. The relation of pustulosis palmaris et plantaris to psoriasis is still controversial; however, in case 1 the authors describe "previous rubrosquamous lesions on the elbows" that were considered "as probable psoriasis" that coexisted with the obesity and the pustulosis palmaris et plantaris.

FRANK W. ROSENBERG, MD
Toronto

1. Hallberg D, Molin L: Remission of pustulosis palmaris et plantaris after intestinal shunt operation. *Acta Derm Venereol* 54:155-156, 1974.

An Unusual Contact Photosensitizing Reaction

To the Editor.—The increase in the patch testing of materials and products by companies, individual testing laboratories, and physicians may uncover unusual reactions.

The study of the photosensitizing potential of a yet unmarketed surgical scrub was undertaken. The total product was applied to the back of volunteers as was the vehicle control. Test materials were applied daily for five days (excluding weekends) for two weeks. On Tuesday and Thursday of each week, the patch areas were left uncovered for 30 minutes after application of the test materials. The test sites were exposed then to twice the subjects' minimal erythema dose (MED) using an ultraviolet lamp (Atlas xenon arc). Patches (Parke-Davis Readi-Band Clear Plastic Patches with nonwoven Webril centers) were used.

On Wednesday of week 2 (ten days after starting the test), one subject reacted on every test and control site. Ultraviolet irradiation had been administered 24 hours earlier. After the reactions subsided, 1% isopropyl alcohol and plain tap water were applied under Elastoplast patches and the Readi-Band patches (total of four patches). Isopropyl alcohol was chosen because it was the common ingredient in both of the original test materials. After 30 minutes, the new patch test sites were exposed to 2 MED as before. Twenty-four hours later both Readi-Band sites were 2+ to 3+ positive while the Elastoplast patch test sites were normal.

Prior to the photosensitizing study, this subject participated in a Human Repeat Insult Patch Test study with the same materials and had no reactions through the entire five-week study even though the Readi-Bands were used. No photosensitization studies were done during that test.

Apparently, a photosensitizing ingredient was leached out of the Parke-Davis patches. The specific chemical responsible for the photosensitization was not isolated.

PAUL LAZAR, MD
Highland Park, Ill

Immunofluorescence Findings in Juvenile Bullous Disease

To the Editor.—We read with interest the case of Prystowsky and Gilliam (ARCHIVES 112:837-838, 1976) and their finding of a linear band of IgA and C3 immunofluorescence (IF) along the basement membrane. We have reported a similar case[1] that corresponds clinically to the IF negative benign chronic bullous disease of childhood.[2] For two years, a 6-year-old girl had recurrent crops of large, tense, nonitchy bullae predominantly about the mouth and vulva that were of decreasing severity. The condition responded only partially to acediasulfon sodium (sulfon) therapy. We found on direct IF of peribullous and normal skin "continous" IgA but not C3 along the basement membrane as described in some cases of adult dermatitis herpetiformis.[3] No circulating basement membrane or reticulin antibody was detected. A jejunal biopsy specimen did not show evidence of coeliac disease as found in true dermatitis herpetiformis.[4] It has been suggested[5] that serial sections of repeated biopsy specimens of juvenile bullous disease will always show IF. This may be so, but there would seem to be some cases in which clinical and IF findings do not match those of adult bullous diseases. Therefore, bullous disorders of childhood have yet to be completely characterized.

More recently, the finding of Esterly et al (ARCHIVES 113:42-46, 1977) of linear IgA at the basement membrane zone on direct IF in one of two cases of benign chronic bullous dermatosis of childhood would support a contention that this IF finding may be a characteristic feature of the condition.

ROGER CLAYTON, MB, MRCP
MICHAEL FEIWEL, MA, MB, FRCP
London

1. Clayton R, Feiwel M: Juvenile bullous disease. *Proc Roy Soc Med* 69:312, 1976.
2. Bean SF, Jordan RE: Chronic nonhereditary blistering disease in children. *Arch Dermatol* 110:941-944, 1974.
3. Seah PP, Fry L: Immunoglobulins in the skin in dermatitis herpetiformis and their relevance in diagnosis. *Br J Dermatol* 92:157-166, 1975.
4. Fry L, Seah PP: Dermatitis herpetiformis: An evaluation of diagnostic criteria. *Br J Dermatol* 90:137-146, 1974.
5. Chorzelski TP, Jablonska S, Beutner EE, et al: Juvenile dermatitis herpetiformis versus "Benign Chronic Dermatosis of Childhood." Are these immunologic diseases? *J Invest Dermatol* 65:447-450, 1975.

Pain With Synoviomas

To the Editor.—Ever since Kersting and Helwig[1] noted pain caused by eccrine spiradenomas, the association has been firmly established for certain nonneural lesions. For neural lesions, the solitary glomus tumor had long earned a reputation for exquisite pain. Three painful subcutaneous neurolemomas in a patient with neurofibromatosis,[2] the traumatic neuroma arising in instances of disorganized nerve repair,[3] and examples of Morton's neuroma[4] further emphasize this symptom association with nerve lesions. During the past 50 years, data have been accumulating suggesting the surprising contention that synovial sarcomas may have a place in the spectrum of nerve tumors. Although a little less than half of these cancers are painful, 18.3% have pain before emergence of other signs and symptoms,[5] indicating that the tissue giving rise to the cancer must be in especially close proximity to the nerves. Gross continuity with nerves, histologic documentation of unmyelinated nerves in the smallest and, therefore, the earliest stage of the cancer reported,[6] calcium deposits, and interstitial mucin possibly related to psammoma bodies of neural coverings and to mucin of neurofibromas are supportive of this contention. The mucin has staining characteristics of hyaluronic acid.[7,8] The relation between synoviomas and the neural system may be more than coincidental and seems to be weighing against the current belief of the synovial lining relation of the tumor.

Regardless of its histogenesis, the fact that a substantial number of synovial sarcomas cause sustained pain or tenderness in an area of skin that is clinically normal is important for the recognition of this cancer in its pretumor phase. Even though most of the lesions are periarticular in location and would more likely be seen by the orthopedic surgeon, the occasional synovial sarcoma found in the panniculus of the abdominal wall, the finger, or the fascia just deep to the subcutis in the anterior upper thigh are of immediate interest to the

dermatologist. Unexplained pain sustained for more than six weeks should encourage a biopsy inclusive of subcutis, superficial fascia, and a small stratum of underlying muscle. Since this pretumor phase of pain has a lengthy average duration of 4.7 years,[6] the tendency to delay biopsy is not only understandable but permits some leeway in timing the biopsy. The timing should be tempered with caution for another reason. In this particular group of synovial sarcomas, physician culpability has already resulted in a measurable reduction of the survival rate,[2] clearly of adverse legal interest. Nevertheless, the detection and eradication of the cancer by local excision in the pretumor stage has a reasonable prospect of a 100% cure rate as contrasted to the current five-year cure rate of 50% after more radical surgery for the usually encountered larger lesions.

VINCENT J. DERBES, MD
HERBERT ICHINOSE, MD
HARRY HOERNER, MD
New Orleans

1. Kersting DW, Helwig EH: Eccrine spiroadenoma. *Arch Dermatol* 73:199-227, 1956.
2. Izumi AK, Rosato FE, Wood MG: von Recklinghausen's disease associated with multiple neurolemomas. *Arch Dermatol* 104:172-176, 1971.
3. Haymaker W, Woodhall B: *Peripheral Nerve Injuries.* Philadelphia, WB Saunders Co, 1953, p 158.
4. Haskin JC, Reed RS: *Tumors of the Peripheral Nervous System.* Atlas of Tumor Pathology, Armed Forces Institute of Pathology second series, pt 3, 1968, pp 24-27.
5. Pack GT, Ariel JM: Synovial sarcoma (malignant synovioma): A report of 60 cases. *Surgery* 28:1047-1084, 1950.
6. Ichinose H, Derbes VJ, Hoerner HE: Cutaneous pain without tumor: A manifestation of occult synovioma. *Cutis,* to be published.
7. Roth JA, Enzinger FM, Tannerbaum M: Synovial sarcoma of the neck: A follow-up of 24 cases. *Cancer* 35:1243-1253, 1975.
8. Barr RJ, Herten RJ, Graham JH: Synovial sarcoma metastatic to skin: A case report with histochemical and electron microscopic observations, abstracted. *Arch Dermatol* 112:1782, 1976.

Cutaneous Reaction to Chlorambucil

To the Editor.—Chlorambucil is an oral alkylating agent that has been used since early 1950, particularly for the treatment of chronic lymphatic leukemia. The side effects are gastrointestinal symptoms, such as nausea and vomiting, and bone marrow depression. Allergic skin reactions are extremely rare.

This report refers to a patient with chronic lymphatic leukemia in whom a rash was produced when repeatedly challenged with a small dose of chlorambucil. The common features of the known three cases of skin reaction to chlorambucil are described.

Report of a Case.—A 69-year-old man had breathlessness on exertion and on examination was found to have a firm liver, just palpable, and an enlarged spleen extending to the left iliac fossa. There was no lymphadenopathy. The results of the investigations done at the time of admission were as follows: hemoglobin level, 78%, 11.0 gm/100 ml; WBC count, 36,000/cu mm, 88% of which were lymphocytes, platelet count, 86,000/cu mm; ESR 12 mm/hr. Bone marrow examination showed infiltration of the marrow with large numbers of mature lymphocytes consistent with a diagnosis of chronic lymphatic leukemia. He was followed up at regular intervals with no specific therapy. After a retinal hemorrhage, he was treated with 12 mg of chlorambucil daily, allopurinol 50 mg twice a day, and prednisolone 20 mg on alternate days. After eight days, an intense generalized urticarial erythema developed on the trunk, limbs, and face. There was considerable periorbital edema. All drug therapies were discontinued except for prednisolone therapy. The rash cleared within seven days. Chlorambucil and allopurinol therapies were restarted, but a similar eruption appeared within two days, including severe periorbital edema.

Although his clinical condition remained satisfactory with no treatment, within five months his WBC count rose to 70,000/cu mm and severe pressure symptoms developed on the bladder because of the enlarged spleen. Again within two days of restarting chlorambucil therapy, 6 mg daily, the eruption developed. To confirm that the reaction was caused by the chlorambucil and not by any other compound in the tablet or by any other medication, he was admitted to hospital for a challenge dose of purified chlorambucil. All other medication was discontinued and his informed consent was obtained. After a 4-mg dose of purified chlorambucil, the acute periorbital edema reappeared with a widespread urticarial erythema on the trunk that spread within 24 hours to the limbs. There was a curious pustular eruption on the mouth and chin that spread to the cheeks. These follicular lesions had no surrounding area of erythema. This faded within three days. A swab taken from these pustular lesions was sterile, with no organisms evident on Gram stain. A skin biopsy specimen from the trunk showed increased vascularity with moderate chronic inflammatory cell infiltrate around the blood vessels. The inflammatory infiltrate contained some pleomorphic cells suggestive of leukemic cells. Direct immunofluorescence of the skin was negative. The skin sensitivity was examined by patch, scratch, and intradermal tests. Patch tests to 0.01%, 0.1%, and 1% chlorambucil in soft paraffin were negative after 48, 72, and 96 hours. Scratch and intradermal tests were performed to chlorambucil in concentrations of 10^{-5}, 10^{-6}, and 10^{-4} mg/ml. These were also negative.

Comment.—Despite the widespread use of chlorambucil, rashes caused by its administration are so uncommon that only one case has been reported[1] and one other recent case was related to us by W. D. Brenckman, Jr (personal communication, 1975).

The remarkable feature of these three cases is the consistency of the clinical appearance. The rash occurred early in the therapy. The widespread urticated erythema with marked periorbital edema was a feature in all of the cases. Resolution occurred within ten days of discontinuance of the drug therapy. The patients in these cases showed an increasingly severe response after repeated challenge, and no drug tolerance was noted. The delay between taking the drug and the appearance of the eruption became shorter and the extent of the eruption became wider. The pustular eruption on the chin and cheeks in this patient was not seen in the other cases but has been reported with other drugs.[2] The patient was tested to purified chlorambucil, as it was possible that some other compound in the chlorambucil tablet, such as azo dye[3] was causing the reaction. The results of skin testing gave no indication as to the mechanism of the sensitivity reaction in our patient although it most probably is via a hapten. Interestingly, Knisley et al[1] concluded that their patient had a delayed-type hypersensitivity on the basis of late positive patch and scratch tests to pure chlorambucil. The absence of fever, arthralgia, and vasculitic lesions tends to exclude an Arthus phenomenon. Direct immunofluorescence of the skin did not show deposition of immunoglobulin, complement, or fibrin.

Although cutaneous reactions to chlorambucil seem to be extremely rare, the reported cases do show a consistent clinical picture. This may be a useful guide for patients taking chlorambucil in whom a drug eruption develops.

L. G. MILLARD, MB, MRCP
S. M. RAJAH
Leeds, England

The pure substance of chlorambucil was supplied by Burroughs Wellcome Ltd.

Nonproprietary Names and Trademarks of Drugs

Chlorambucil—*Leukeran.*
Allopurinol—*Zyloprim.*

1. Knisley RE, Settipane GA, Albala MM: Unusual reaction to chlorambucil in a patient with chronic lymphatic leukemia. *Arch Dermatol* 104:77-79, 1971.
2. Hitch JM: Acneform eruptions induced by drugs and chemicals. *JAMA* 200:879-880, 1967.
3. Michaëlsson G, Juhlin L: Urticaria induced by preservatives and dye additives in food and drugs. *Br J Dermatol* 88:525-532, 1973.

Herpes Gestationis

To the Editor.—In reference to the article by Dr Hertz et al on herpes gestationis (ARCHIVES 112:1543-1548, 1976), a broad differential diagnosis was considered. In our experience, the clinical and histological pattern described would not distinguish herpes gestationis from a bullous drug eruption. In the absence of immunologic studies, that distinction seems to me to be difficult, if not impossible. I would appreciate if the authors would elaborate on the distinctive features that they might have found helpful separating drug eruption from herpes gestationis and why they did not include it in their differential diagnosis.

KURT S. STENN, MD
New Haven, Conn

In Reply.—Reactions to drugs may clinically simulate almost every dermatitis and may elicit histological patterns similar to that of almost every inflammatory reaction in the skin. Among the most common are the lichenoid, acneiform, and urticarial. Furthermore, drugs are among the most common causes of bullous dermatitides, such as erythema multiforme and toxic epidermal necrolysis, and of allergic vasculitis. The fixed drug eruption is evoked by drugs.

In our experience, however, a drug has yet to provoke histological changes such as those of herpes gestationis and for that reason that condition was not included among our differential diagnoses. Oral contraceptives, however, may exacerbate herpes gestationis as in case 1. We think that, apart from bullous pemphigoid, the histological features of herpes gestationis are rather specific and not imitated by any drug eruption.

K. HERTZ, MD
S. KATZ, MD
J. MAIZE, MD
A. B. ACKERMAN, MD
Bethesda

Cutaneous Leishmaniasis: Inefficacity of Treatment With Metronidazole

To the Editor.—It was with great interest that we read the recent reports about successful treatment of cutaneous leishmaniasis with orally administered metronidazole.[1,2] Cutaneous leishmaniasis is endemic in our region of the world and any simple and safe form of therapy that is rapidly effective and easily administered would be of considerable value. We, therefore, decided to try this medication on some of our patients. Six consecutive patients were given oral metronidazole according to the schedule suggested by Long.[1] Three of the patients had nodular lesions, two had nodular-ulcerative lesions, and in one patient, the lesions were papular. The duration of the lesions was two months in three cases, three months in two cases, and six months in one case. The diagnosis was confirmed in all cases by positive smears and cultures. No clinical improvement was observed in any one of the patients at the end of treatment, and in one case the lesion grew larger and two small satellite lesions appeared during metronidazole therapy. Repeated smears and cultures were taken in five of the patients after the third course of the medication and in all of them they were still positive.

The lack of accordance between the results obtained in our patients and those obtained by previous authors[1-3] could be explained by possibly different sensitivities of different species or even different strains of the parasite to metronidazole. The cases of Beltran et al[3] and Long[1] were acquired in Mexico and Panama, respectively, whereas the case of Pedersen and Sawicki[2] was acquired in Afghanistan. In the later case, the duration of the lesions before initiation of therapy was seven months. It is a well-known fact that the process of spontaneous healing, which usually occurs in early leishmaniasis, begins after six months from onset.[4] Thus, the resolution of the lesions in that case could be part of the natural course of the disease and must not be obligatorily attributed to the therapeutic effect of metronidazole.

Although our experience is limited to a small number of patients, we believe that metronidazole therapy is ineffective in cutaneous leishmaniasis of Middle Eastern origin.

ASHER WAHBA, MD
CHAIM COHEN, MD
Jerusalem

Nonproprietary Name and Trademark of Drug

Metronidazole—*Flagyl.*

1. Long PI: Cutaneous leishmaniasis treated with metronidazole. *JAMA* 223:1378-1379, 1973.
2. Pedersen JK, Sawicki S: Metronidazole therapy for cutaneous leishmaniasis. *Arch Dermatol* 111:1343-1344, 1975.
3. Beltran F, Gutierrez M, Biagi F: Utilité du metronidazole dans le traitement de la leishmaniose cutanée Mexicaine. *Bull Soc Pathol Exot* 50:61-64, 1967.
4. Domonkos AN: *Diseases due to Animal Parasites in Andrew's Disease of the Skin.* Philadelphia, WB Saunders Co, 1971, pp 475-481.

The Presence of Benzocaine in Sunscreens Containing Glyceryl PABA (Escalol 106)

To the Editor.—Escalol 106 (glyceryl para-aminobenzoate) has long been used in the United States in sunburn preventative preparations. In 1949, Meltzer and Baer[1] described a patient with allergic sensitization to monoglyceryl para-aminobenzoate (glyceryl PABA) from its presence in a sunscreen. This patient showed a considerable reaction to benzocaine. Similarly, in 1951, Curtis and Crawford[2] described a patient who in addition to an allergic reaction to a sunscreen that resulted from the presence of glyceryl PABA also exhibited a strong reaction to benzocaine.

Recently, I[3] reported four cases of allergic sensitivity to glyceryl PABA in sunscreens, in all of which similar strongly positive patch test reactions to benzocaine were seen.

It is not surprising that benzocaine (ethyl aminobenzoate) and glyceryl PABA, which are both chemically related esters of para-aminobenzoic acid should show cross-reactions. However, it was thought that the phenomenon of "cross-reactions" did not entirely explain why in every single reported instance of allergic hypersensitivity to glyceryl PABA in a sunscreen, there was an equally strongly positive reaction to benzocaine. It has been my experience that cross-reaction patterns are usually not so exactly uniform.

It was suspected that in the manufacture of Escalol 106 from para-aminobenzoic acid, benzocaine is inadvertently formed. Chemical analysis has revealed that this indeed proved to be the situation. Escalol 106 (glyceryl PABA) itself, and all of the sunscreens containing Escalol 106 were shown to contain "free benzocaine" in varying amounts, from 18% to 1%.

The following sunscreens, listed as containing glyceryl PABA (Escalol 106) must thus be avoided by benzocaine-sensitive individuals: Eclipse (which also contains octyl dimethyl PABA), Expose Suntan Liquid, Negasol, Sea & Ski Dark Tanning Lotion, Sea & Ski Suntan Lotion, Tanfastic Dark Tanning Lotion, and Tanfastic Suntan Lotion with Cocoa Butter.

Padimate A (Escalol 506 [amyl paradimethyl PABA]) and padimate O (Escalol 507 [octyl dimethyl PABA]) did not cross-react with either Escalol 106 or benzocaine in my four patients. On chemical analysis, padimate A and padimate O proved to be free of

benzocaine.

In addition, it should be noted that glyceryl PABA and benzocaine may show cross-reactions with such "para" compounds as para-aminobenzoic acid, para-amino salicylic acid, paraphenylenediamine anilin, procaine, sulfaguanidine, sulfanilamide, and saccharin.

ALEXANDER A. FISHER, MD
Woodside, Long Island, NY

Nonproprietary Names and Trademarks of Drugs

Padimate A—*Block Out, Escalol 506, Pabafilm.*
Padimate O—*Escalol 507.*

1. Meltzer L, Baer RL: Sensitization to monoglycerol para-aminobenzoate. *J Invest Dermatol* 12:31-39, 1949.
2. Curtis GH, Crawford PF: Cutaneous sensitivity to monoglyceryl para-aminobenzoate. *Cleveland Clin Q* 18:35-38, 1951.
3. Fisher AA: Sunscreen dermatitis due to glyceryl PABA: Significance of cross-reactions to this PABA ester. *Cutis* 18:495-500, 1976.

Frequency of Skin Lesions in Chronic Drinkers

To the Editor.—I read Dr J. Margolis's letter on "Frequency of Skin Lesions in Chronic Drinkers" in the ARCHIVES (112:1326-1327, 1976) and was surprised to see that he was unable to find any reference in medical literature. In 1971, I published with Mr G. Oki, a paper on "Skin Diseases in Alcoholics" in the *Quarterly Journal of Studies in Alcohol* (32:1017-1024). The purpose of this study was to assess the prevalence of skin diseases in a population of alcoholics and to compare our findings with those reported by other investigators.

A total of 355 patients (307 men and 48 women) were admitted to the inpatient unit of a public hospital for the treatment of alcoholism during a period of two years. Nearly all were examined by a dermatologist within two to three days after admission; a few within a week. In addition to a complete physical examination, information was obtained on the history of previous skin diseases and their behavior during periods of heavy drinking.

As could be expected in such a fairly large group, a wide range of skin conditions was encountered; 44% of the men had one or more skin conditions compared to 33.3% of the women. A total of 34 different entities was found, most of them probably of little clinical importance or statistical significance. The following common dermatoses had an incidence of 1% or more: acne rosacea, 5.6%; acne vulgaris, 1.7%; black hairy tongue, 1.1%; dermatophytosis, 3.7%; eczema, dyshidrotic, 2.3%; eczema, intertriginous, 2.0%; leukoplakia, 1.7%; neurodermatitis, 2.5%; psoriasis, 3.4%; seborrhea capitis, 10.1%; and seborrheic dermatitis, 7.3%.

It was my belief that only a few entities showed an incidence higher than that of a normal population: acne rosacea, leukoplakia, black hairy tongue, and seborrheic dermatitis. Five of the patients with psoriasis volunteered information that their condition was aggravated by heavy drinking. Unfortunately, we were unable to compare the incidence of these conditions with that in the normal population since no data are available regarding the incidence of common dermatoses except for a few entities. No definite pattern of behavior could be established. Some patients volunteered information that their eruption was aggravated by heavy drinking. Others were unable to correlate the course of the disease with alcohol intake.

MARK ROSSET, MD FRCP(C)
Toronto

'Stockbroker's Knee'

To the Editor.—A stockbroker appeared at my office with a chief complaint of hypesthesia in a palm-sized area over the left suprapatellar area of several months' duration. Another physician had ordered roentgenograms of the lumbar spine, which were normal. Physical examination showed hypesthesia and obvious hair loss over the involved area.

Careful questioning revealed that the telephone in his office was so placed that reaching for it necessitated turning his body more than 90° to the right. This motion was always accompanied by scraping the anterior surface of his left lower thigh (the affected area) against the kneehole of the desk.

In a follow-up visit, he reported that in discussing his now famous knee with his office colleagues, another stockbroker with the same telephone-desk configuration came forward with an almost identical complaint of hypesthesia in the left suprapatellar area.

Perhaps an appropriate diagnosis in these two cases would be "stockbroker's knee."

DANIEL S. J. CHOY, MD
New York

Bone Involvement in Early Syphilis

To the Editor.—In their article "Hepatitis and Bone Destruction as Uncommon Manifestations of Early Syphilis: Report of a Case" (ARCHIVES 112:1451-1454, 1976), Drs Longstreth, Hoke, and McElroy reported uncommon manifestations of early syphilis with hepatitis and bone destruction. As they mentioned, many cases of this type presumably go unrecognized.

At the end of the primary stage, most of the treponemas leave the blood stream and invade the tissues. This intrusion of *Treponema pallidum* into the tissues of the body leads to the development of the generalized lesions that are called secondary syphilis. In the secondary eruptions on skin and mucous membranes, *T pallidum* can be demonstrated in very great numbers. Probably all tissues of the body are invaded but not all react by demonstrable changes.

The patient often complains of the following commonly named constitutional symptoms of a rather nonspecific character: general tiredness, headache, low grade fever, pains of joints and muscles that are usually most pronounced at night, hoarseness, moderate anemia, enlargement of the spleen, and a slight albuminuria. The headache is often followed by early syphilitic meningitis with increased intracranial pressure and pleocytosis. Hepatitis with jaundice and periostitis with "ostecopic pains" may also appear. Even the changes of the aorta probably start very early but do not, as a rule, manifest themselves clinically for ten to 20 years.

If one carefully examined all organs in patients with secondary syphilis and constitutional symptoms, in many cases one would, without a doubt, be able to demonstrate syphilitic changes in biopsy specimens and occasionally also *T pallidum*, as it has been shown for instance in the liver and the eye. However, we usually do not do this because these patients are seen on an outpatient basis, and, from an epidemiological point of view, we must treat the patient at once. Furthermore, it is an old clinical experience that all symptoms disappear after a few injections with penicillin or another antitreponemal drug.

This universal infection is, however, much more pronounced in early congenital syphilis. During my stay in Uganda from 1969 to 1973, as head of the Department of Dermatology at Mulago Hospital, we diagnosed 30 to 40 cases of early congenital syphilis each year. Beside the mucocutaneous

symptoms, the many cases with osteochondritis, with or without pseudoparalysis, were very impressive. Symptoms of ostitis or osteochondritis were so common that the paramedical staff in the general outpatient clinic also learned to refer infants only with osteogenic symptoms to the venereal disease clinic.

During the last six to seven months of my stay in Uganda, we made full skeletal roentgenographic examinations (except the skull) of all infants with early congenital syphilis. Among approximately 25 children, we found many with bone changes, and these changes were much more extensive and widespread than suggested from the clinical examination.

When I left Uganda for reasons outside my control, I was not able to take with me the records and the x-ray films of these cases. Therefore, I am unfortunately not able to present documentation for our findings.

PROF GUNNAR LOMHOLT
Tromsoe, Norway

Biting Insect Summary

To the Editor.—Again this year I am compiling a biting insect summary and would appreciate any case reports of unusual allergic reactions, especially systemic (sneezing, wheezing, urticaria), to bites of insects, ie, mosquitoes, fleas, gnats, kissing bugs, bedbugs, chiggers, black flies, horseflies, sandflies, deerflies, etc. I would like physicians to supply me with case reports of those patients who have had unusual reactions to such insects. Include in your reports the type of reactions (immediate and delayed symptoms), treatment, the age, sex, and race of the patient, the site of the bite(s), the season of the year, and any other associated allergies. If skin tests and hyposensitization were instituted, I would like the report of both. Please note that it is the biting (not stinging) insect in which I am interested.

If you have found any insect repellent, local treatment, or insecticides of value, I would also appreciate this information.

Please send your information to 4-C Doctors Park, Asheville, NC 28801.

CLAUDE A. FRAZIER, MD
Asheville, NC

Atopic Dermatitis Reactions to Methacholine

To the Editor.—In the May ARCHIVES, Uehara and Ofuji presented an evaluation of the abnormal vascular reactions in atopic dermatitis (113:627-629, 1977). In their discussion of the methacholine reaction, they stated that all of their patients showed normal reactions to methacholine when the tests were performed on normal skin.

I believe that this is misleading, since the test was performed with the use of a topical application of methacholine rather than with the intradermal injection that represents the standardized methacholine test.

In a study of IgE levels in atopic dermatitis (*Arch Dermatol* 108:806-811, 1973), 58 patients with a diagnosis of atopic dermatitis received a methacholine test administered in the standard fashion: 0.1 ml of methacholine chloride diluted 1:1,000 in isotonic saline solution applied to an *uninvolved* area of the back, if such an area was to be found. In 78% of the cases, a moderate to strongly positive delayed blanch reaction was found.

The disparity between these findings and the findings of Uehara and Ofuji may be attributable to the failure of methacholine, when applied to normal skin, to penetrate the stratum corneum and get to the small blood vessels. This would also explain the fact that the reaction does occur when the material is applied to eczematized or lichenified skin. Their findings do not, however, challenge the theory that the abnormality in vascular responsiveness is present throughout the atopic skin, and may simply be explained by failure of penetration of the drug when topically applied.

STEPHEN P. STONE, MD
Springfield, Ill

Azaribine, Homocystinemia, and Thrombosis

To the Editor.—Although azaribine has been shown to be an effective drug in the treatment of psoriasis, the Food and Drug Administration has recently prohibited the use of this antimetabolite because of the possibility of an associated increased incidence of thromboembolism. We present a hypothesis and some preliminary supporting data that may explain this adverse effect.

In 1969, high dosages of azaribine (400 mg/kg/day) were shown to result in the urinary excretion of various amino acids, including homocystine.[1,2] Until recently, this appeared to be a mere biochemical curiosity. However, with the report of vascular complications in patients who were on a regimen of azaribine, similar to those complications found in patients with hereditary homocystinuria, we screened our patients who were receiving azaribine for the presence of homocystine in the blood and the urine. As homocystine is normally not present in either the blood or the urine, detectable levels are considered abnormal.

Urine specimens were immediately refrigerated or frozen without preservative, and subsequently analyzed for amino acids by ion-exchange column chromatography. Plasma determinations of amino acids were performed on heparinized blood samples, which had been deproteinized immediately and frozen until they were analyzed.

Twenty-nine psoriatic patients were screened. None of these patients had a history of phlebitis, thromboembolism, cardiac disease, or diabetes. Thirteen of the patients were on a regimen of azaribine in dosages ranging from 100 to 175 mg/kg/day. The remaining sixteen control psoriatic patients had never received azaribine.

None of the sixteen control patients developed homocystinuria or vascular problems. Five of the thirteen patients receiving azaribine developed homocystinuria and homocystinemia. Of these patients, one developed a thrombotic episode. Following the appearance of homocystine in the blood and urine, this patient developed thrombophlebitis of the right calf. When treatment with azaribine was discontinued, the patient's homocystinemia disappeared, and the thrombosis resolved. Upon readministration, homocystinemia reappeared. The remaining eight patients who were treated with azaribine and did not develop homocystinemia failed to suffer any thrombotic complications.

Laboratory work supports a pathogenic role for abnormal levels of homocystine in the development of vascular disease. One investigator showed disruption of the vascular endothelium in baboons following infusion of homocystine, with subsequent development of platelet thrombi and arterial and venous occlusion.[3] These laboratory findings and the clinical observations of patients with hereditary homocystinuria suggest that elevation of plasma homocystine may cause thrombotic disease. Therefore, possibly the thrombotic vascular disease that is seen with azaribine occurs only in those patients who develop homocystinemia.

Until more information is available, urinary screening for homocystine

should be performed in all patients who are receiving azaribine. This procedure may identify those patients who are at risk of developing a thrombosis.

JEROME L. SHUPACK, MD
ANTHONY J. GRIECO, MD
ALLEN M. EPSTEIN, MD
CLAUDE SANSARICQ, MD
SELMA E. SNYDERMAN, MD
New York

Nonproprietary Name and Trademark of Drug

Azaribine—*Triazure.*

1. Hyánek J, Bremer HJ, Slavík M: Homocystinuria and urinary excretion of beta-amino acids in patients treated with 6-azauridine. *Clin Chim Acta* 25:288-290, 1969.
2. Slavík M, Hyánek J, Elis J, et al: Typical hyperaminoaciduria after high doses of 6-azauridine triacetate. *Biochem Pharmacol* 18:1782-1784, 1969.
3. McCully KS: Homocysteinemia and arteriosclerosis. *Am Heart J* 83:571-573, 1972.

Melanoma Treatment With Phenolic or Catecholic Compounds

To the Editor.—In a recent ARCHIVES editorial (113:421, 1977), Lerner and Nordlund suggested that selected cases of melanoma be treated with phenolic or catecholic compounds after resection of the primary tumor. The inference was that such a program would improve survival of patients with melanoma.

I have also been interested in this same question, and I attempted to answer it with the use of the Fortner melanotic melanoma No. 1 hamster series. I selected for study four highly active depigmenting agents—one each from the hydroquinones, the mercaptoethylamines, the catechols, and the parasubstituted phenols. These compounds were injected intralesionally into small tumor papules five days a week for four weeks. No inhibition in tumor growth or in survival was obtained.[1] Frenk and Ott had a similar result in their experiments.[2] These data do not support the concept that depigmenting compounds may be useful in the treatment of malignant melanoma.

DAVID PASLIN, MD
Daly City, Calif

1. Paslin DA: The effect of depigmenting agents on the growth of a transplantable hamster melanoma. *Acta Derm Venereol* 53:119-122, 1973.
2. Frenk E, Ott F: Evaluation of the toxicity of the monoethyl ether of hydroquinones for mammalian melanocytes and melanoma cells. *J Invest Dermatol* 56:287-293, 1971.

Minocycline and Thyroid Function

To the Editor.—I wish to call attention to an article from the *British Journal Medical* that was abstracted in the February 14 issue of the *Journal of the American Medical Association* (237:705, 1977):

A black thyroid has not been reported in man, but has been found in monkeys, dogs, and rats during trials with minocycline. A uniformly black thyroid was found in a 69-year-old man who died in respiratory failure from bronchiectasis and emphysema.... The monofluorescent pigmentation of the thyroid is attributed to the specific concentration of minocycline in the thyroid and increased lipofuscin deposition. Because previous experimental studies with minocycline have demonstrated an antithyroid effect, patients receiving prolonged minocycline therapy should have their thyroid function monitored.

Do those of us who prescribe minocycline for acne now need to monitor thyroid function?

THOMAS GRETZINGER, MD
Fresno, Calif

Zinc Sulfate and Axillary Perspiration Odor

To the Editor.—Because of the recent interest in the use of zinc for the treatment of acrodermatitis enteropathica and acne, I would like to report still another possible indication for the use of this agent.

About two years ago, I saw a patient who was being given 220 mg of oral zinc sulfate (equivalent to 50 mg of elemental zinc) three times daily by his surgeon as part of the management of recurrent leg ulcers. This observant gentleman noted that while he was taking zinc there was a marked reduction in axillary perspiration odor. This problem, which had been most distressing to him for most of his adult life, returned within days after the zinc was discontinued. When he again started taking the capsules, the odor again markedly diminished (confirmed by his wife).

Based on this observation, I have given zinc sulfate to five other persons, with uniformly good results. Most responded to daily doses as low as 20 mg of elemental zinc. All had tried a wide variety of deodorants and antiperspirants without success. This report is submitted in hope of helping other unfortunate persons who suffer from socially incapacitating perspiration odor.

MORTON D. SCRIBNER, MD
Arcadia, Calif

Isolated Familial Benign Chronic Pemphigus

To the Editor.—Familial benign chronic pemphigus (FBCP), or Hailey-Hailey disease, is a rare hereditary disorder that is characterized by recurrent vesicles and bullae in the intertriginous areas, such as the axillae and groin. The eruption is rarely confined to one area of the body.

Report of a Case.—A 29-year-old woman was examined in November 1975 for pruritus vulvae of seven months' duration. Numerous small, flat, white papules and thickened lichenified skin were found on the vulvar surface. A skin biopsy specimen of a papule showed suprabasilar clefts, villi, and acantholytic epidermal cells characteristic of FBCP. The results of the rest of the skin examination were noncontributory. Fungal and yeast cultures grew no organisms, and pelvic and breast examination results were normal. There was no family history of recurrent bullous disease. The FBCP has not responded to steroid creams, antimonilial creams and suppositories, antifungal creams, steroid antibiotic combination cream, sulfa cream, vinegar douches, or oral wide-spectrum antibiotics.

Comment.—In most patients with FBCP, the disease is found in several areas and is found only rarely in one site, such as in the case presented. Cooper reported a 21-year-old man with the disease localized to the perianal skin.[1] Lyles and associates reported a 22-year-old woman whose disease appeared during pregnancy and was localized to the vulva.[2] The eruption disappeared after successful treatment of postpartum leukorrhea.

DONALD E. HAZELRIGG, MD
LEON J. STOLLER, MD
Evansville, Ind

1. Cooper DL: Familial benign chronic pemphigus of perianal skin. *Arch Dermatol* 103:219-220, 1971.
2. Lyles TW, Knox JM, Richardson JB: Atypical features in familial benign chronic pemphigus. *Arch Dermatol* 78:446-453, 1958.

Transient Bullous Eruption

To the Editor.—We have also seen a patient with a transient bullous eruption similar to the three cases reported in the ARCHIVES by Waisman et al (112:1440-1441, 1976).

Report of a Case.—An 89-year-old man with senile dementia had a two-week history of pruritic bullae and erosions that commenced on his hands and gradually spread to involve his trunk and limbs. There were no known precipitating causes. Biopsy specimen showed a subcorneal vesicle containing some acantholytic cells. Direct

and indirect immunofluorescence were negative. The lesions resolved within six weeks with the use of only topical corticosteroids. He has been symptom-free for 18 months.

Comment.—We would prefer to emphasize the subcorneal level of vesiculation and the close clinical and pathological similarities to pemphigus foliaceus in any title used for this condition rather than regard it as a bullous variant of Grover's disease. We have seen a similar solitary subcorneal lesion occurring as an incidental finding in the skin of a mastectomy specimen. Perhaps there is a whole spectrum of subcorneal as well as suprabasal acantholytic dermatoses.

DAVID WEEDON, FRCPA
GRAEME BEARDMORE, FACD
Brisbane, Australia

Propranolol Therapy

To the Editor.—Alopecia has been caused by a number of medications, especially antineoplastic agents, anticoagulants, and certain hormones. I had occasion to see a woman in whom alopecia developed while taking propranolol hydrochloride. Since this drug is in widespread use for the treatment of cardiac disorders and hypertension, this case is presented to alert other physicians to this interesting and unusual side effect.

The patient is a 55-year-old woman. On Sept 5, 1976, she was started on a course of propranolol hydrochloride 30 mg daily because of atrial fibrillation. Approximately three weeks later, she noted hair loss that progressively became more profuse. Her only other medication was conjugated estrogens that she had taken for six years. She denied exposure to toxic chemicals of any kind. Examination on Dec 10, 1976, revealed diffuse patchy alopecia of the scalp. The eyebrows, axillary hair, pubic hair, and nails appeared normal. Numerous hairs could be plucked easily from the scalp with gentle traction by the fingers. The serum iron and thyroid profile were within normal limits, and the VDRL test was negative. Propranolol therapy was discontinued on Dec 10, 1976, and one month later the hair loss had essentially ceased. The patient refused rechallenge with the drug.

MORTON D. SCRIBNER, MD
Arcadia, Calif

Nonproprietary Name and Trademark of Drug

Propranolol hydrochloride—*Inderal.*

1. Martin CM, Southwick EG, Maibach HI: Propranolol induced alopecia. *Am Heart J* 86:236-237, 1973.
2. *Physicians' Desk Reference.* Oradell, NJ, Medical Economics Co, 1976, p 592.

Pilomatricoma

To the Editor.—"Pilomatrixoma" is just as incorrect as "appendixitis" would be, and for just the same reason, the root ends in "c", not "x". Drs Gregg and Cannon (ARCHIVES 113:232) had the example of at least one of their three references before them, but were not warned.

Perhaps it would be a good idea to have someone edit LETTERS TO THE EDITOR, for the protection of the contributors thereto and of the reputation of American physicians for writing correctly.

HARRY L. ARNOLD, JR, MD
Honolulu

In Reply.—Thank you for forwarding Dr Arnold's letter regarding the spelling of pilomatricoma. We were aware at the time of submitting our LETTER TO THE EDITOR of the correct spelling of pilomatricoma; however, because of current usage and the appearance of the word pilomatrixoma in all of the current text, we elected to perpetuate an unfortunate error. Certainly Dr Arnold is entirely correct in his spelling of the calcifying epithelioma of Malherbe.

Thanks again to Dr Arnold for again reminding us of this repeated error.

LAWRENCE J. GREGG, MD
Tulsa, Okla

Suggested Sequence of Testing for Acne Patients Receiving Long-Term Tetracycline Therapy

To the Editor.—After completion of my study on the safety of long-term tetracycline therapy for acne (*Arch Dermatol* 112:1603-1605, 1976), it seemed to me that physicians would appreciate some suggestions concerning blood testing for acne patients who are receiving long-term tetracycline therapy. The following sequence for testing is suggested, but this is not meant to be restrictive.

First, take a good history from your patient. If the patient relates unusual medical problems, take appropriate tests including a complete blood cell count (CBC) and blood chemistry studies using an automated 12-factor analysis system. Next, if the patient has been receiving long-term antibiotic therapy for one year or longer, previous to your first visit, get a 12-factor blood chemistry analysis test and a CBC. Third, if you institute antibiotic therapy, give the patient an information sheet stating in a few words the mild nonserious side effects and the fact that there appear to be no serious side effects in the great majority of patients treated with long-term tetracycline therapy. Inform the patient also that tetracycline should not be taken during pregnancy. Fourth, after two years of continuous tetracycline therapy get a 12-factor blood chemistry analysis test and a CBC. Repeat these tests at two-year intervals if the patient remains on continued therapy. Finally, do not give unlimited refills on antibiotic prescriptions. For instance, if the patient is taking 500 mg of tetracycline hydrochloride a day, then an original prescription for 100 capsules and two refills could be given to the patient.

GORDON C. SAUER, MD
Kansas City, Mo

Elastosis Perforans Serpiginosa Associated With Penicillamine

To the Editor.—The May ARCHIVES (113:630-635, 1977) contains an interesting report of a case of elastosis perforans serpiginosa (EPS) induced by penicillamine. Although there have now been a number of reports of patients with EPS who have received penicillamine therapy for Wilson's disease, it is still unclear as to whether it is the drug alone that is responsible for the eruption (or perhaps some underlying predisposition in patients with Wilson's disease to effects of penicillamine).

For the past few months I have been following up on the case of an individual with EPS who has extensive involvement of neck, arms, and thighs and who had been receiving penicillamine for nine years for cystinuria. This additional case of EPS associated with penicillamine therapy may add to the evidence for the etiologic significance of this drug.

MARK ABEL, MD
Brick Town, NJ

PSORIASIS
The Capricious Dermatosis

LIDEX® (fluocinonide) 0.05%
A Stabilizing Influence

Psoriasis. Mere mention of the word ca
make an afflicted patient cringe. And,
because of the capricious, unpredictab
nature of the disease, the patient rarely
knows where or when it will recur.

Obviously, the goal is control. And,
though varied treatment modalities are
available today, none offers universal

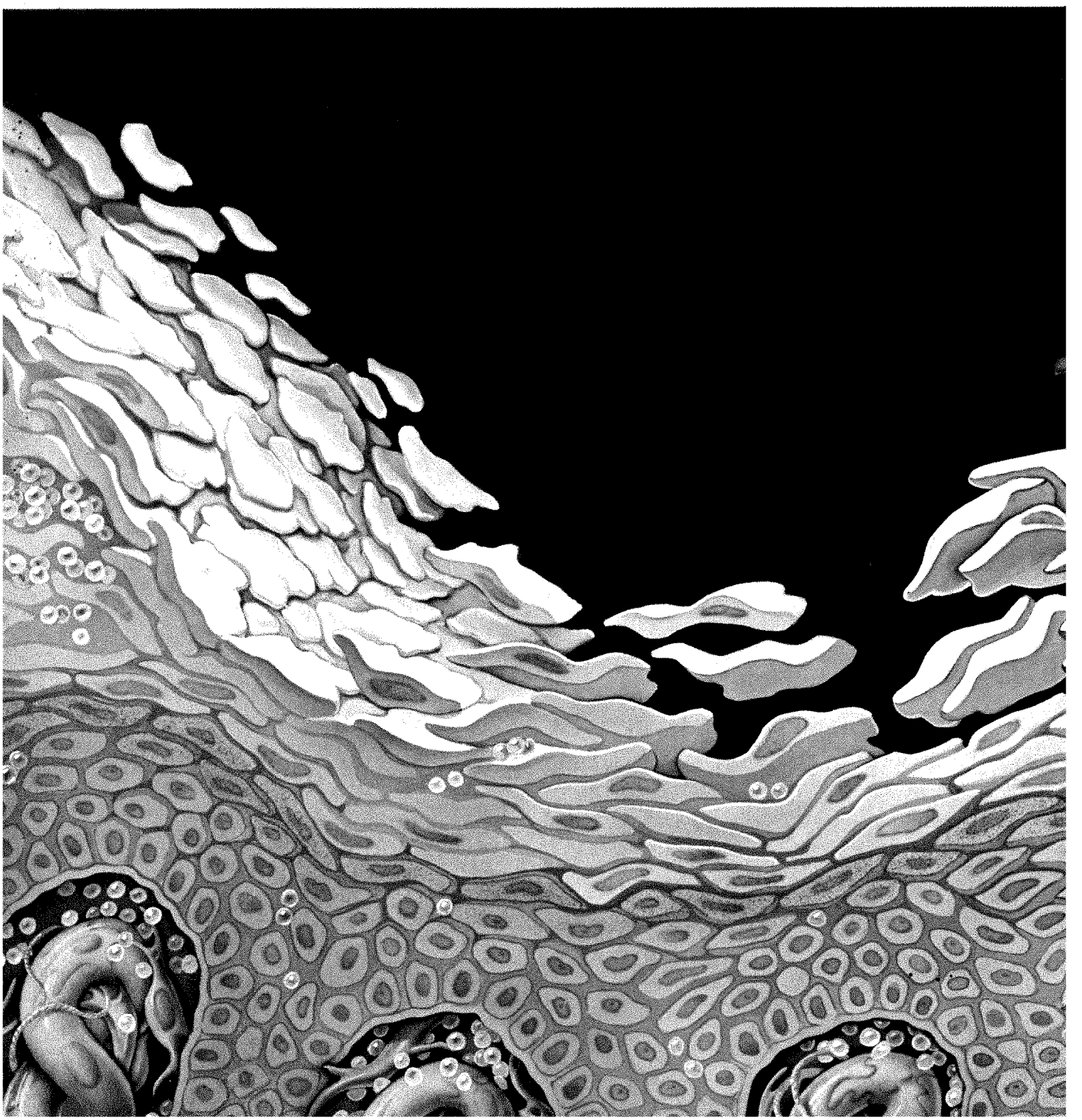

icacy for all patients, all of the time.
Yet, very often a highly effective topical
eroid, like Lidex, (fluocinonide) can
lp stabilize psoriasis.
Lidex. A highly effective topical steroid
th anti-inflammatory, vasoconstrictive,
tipruritic actions.
100% dissolved for optimal penetration,
important in stages that exhibit thickened,
scaly lesions.
Totally free of preservatives.
Available in cream, ointment, and
Topsyn® (fluocinonide) gel.

SYNTEX
SYNTEX LABORATORIES, INC.
PALO ALTO, CALIFORNIA 94304



(See following page)

LIDEX® (fluocinonide)
0.05% Cream and Ointment

TOPSYN® (fluocinonide)
0.05% Gel

Summary of prescribing information

Description

LIDEX cream 0.05%, LIDEX ointment 0.05% and TOPSYN gel 0.05% contain the active compound fluocinonide. Fluocinonide, which is the 21-acetate ester of fluocinolone acetonide, has the chemical formula 6α, 9α, -difluoro-11β, 16α, 17α, 21-tetrahydroxypregna-1,4-diene-3, 20-dione, cyclic 16, 17-acetal with acetone 21-acetate. LIDEX cream contains fluocinonide in FAPG® cream, a specially formulated cream base consisting of stearyl alcohol, polyethylene glycol 6000, propylene glycol, 1, 2, 6-hexanetriol and citric acid. This white cream vehicle is greaseless, non-staining, anhydrous and completely water miscible. The base provides emollient and hydrophilic properties. In this formulation, the active ingredient is totally in solution.

LIDEX ointment contains fluocinonide in a specially formulated ointment base consisting of Amerchol CAB (mixture of sterols and higher alcohols), white petrolatum, propylene carbonate and propylene glycol. It provides the occlusive and emollient effects desirable in an ointment. In this formulation the active ingredient is totally in solution.

TOPSYN gel contains fluocinonide in a specially formulated gel base consisting of propylene glycol, propyl gallate, disodium edetate, and Carbopol 940 (carboxypolymethylene) with NaOH and/or HCL added to adjust the pH. This clear, colorless, thixotropic vehicle is greaseless, non-staining and completely water miscible. In this formulation, the active ingredient is totally in solution.

Indications

LIDEX cream and ointment and TOPSYN gel are intended for the relief of inflammatory manifestations of corticosteroid responsive dermatoses.

Contraindications

Topical steroids are contraindicated in vaccinia and varicella. Topical steroids are contraindicated in those patients with a history of hypersensitivity to any of the components of the preparation.

Precautions

If irritation develops, the cream, ointment or gel should be discontinued and appropriate therapy instituted. In the presence of an infection the use of an appropriate antifungal or antibacterial agent should be instituted.

If a favorable response does not occur promptly, the corticosteroid cream, ointment or gel should be discontinued until the infection has been adequately controlled.

If extensive areas are treated, the possibility exists of increased systemic absorption and suitable precautions should be taken.

Although topical steroids have not been reported to have an adverse effect on pregnancy, the safety of their use in pregnant females has not absolutely been established. Therefore, they should not be used extensively on pregnant patients, in large amounts or for prolonged periods of time.

LIDEX® (fluocinonide) cream and ointment and TOPSYN® (fluocinonide) gel are not for opthalmic use.

Adverse reactions

The following local adverse reactions have been reported with topical corticosteroids:

burning	folliculitis
itching	acneform eruptions
irritation	hypopigmentation
dryness	striae
secondary infection	skin atrophy

Dosage and administration

A small amount should be gently massaged into the affected area three or four times daily, as needed.

How supplied

LIDEX 0.05% Cream—15 g 30 g and 60 g tubes.
LIDEX 0.05% Ointment—15 g 30 g and 60 g tubes.
TOPSYN Gel 0.05% 15 g and 60 g tubes.

SYNTEX
SYNTEX LABORATORIES, INC.
PALO ALTO, CALIFORNIA 94304

Society Transactions

PHILADELPHIA DERMATOLOGICAL SOCIETY

April 15, 1975

Waine C. Johnson, MD, Recorder

Psoriasis Treated With Mycophenolic Acid. Presented by RAUL FLEISCHMAJER, MD, ROSALIE K. MARINARI, MD.

A 62-year-old woman had a 44-year history of severe generalized plaques of psoriasis. She had been treated with various agents, including tars and topical steroids. For the past six years she had been treated with methotrexate with moderate control of her psoriasis, but she had adverse reactions of nausea and alopecia. Dermatological examination revealed a moderate xerosis of the upper and lower extremities, erythema and scaling of the right index finger, and a 1-cm erythematous scaly patch on the sacrum. Laboratory data including a complete blood count, blood chemistry studies using an automated multiple analysis system (SMA-12) survey, and urinalysis were within normal limits. The patient had been treated with 2,400 mg/day of mycophenolic acid.

Discussion

DR FLEISCHMAJER: We have treated a series of 35 patients. I would estimate about 300 patients with psoriasis have been treated with mycophenolic acid in the United States.

PAUL R. GROSS, MD: Is mycophenolic acid an immunosuppressive drug?

DR FLEISCHMAJER: Initially we did not think the drug was immunosuppressive. We have had a patient with herpes zoster, and several patients have had herpes simplex. Later we found out that others have observed several cases of herpes zoster and this seems to be a unique side effect of this drug. I do not think herpes zoster has been reported with treatment with methotrexate, which does have an immunosuppressive effect.

DR MARINARI: Our experience with the 35 patients treated is that about 20% show complete clearing and about 45% show almost complete clearing with only residual erythema or individual small lesions. The guidelines for results of treatment consider any erythema as activity; thus, with residual mild erythema, we consider the area as almost completely cleared. Definite improvement (at least a 50% decrease in area of involvement) was seen in 25% of the patients and two patients (8%) showed only a slight improvement. The experience of the various groups in the United States who are studying the effect of mycophenolic acid has been that most of the patients will show clearing in seven to eight weeks, though some may take up to 12 weeks. Response seems to be slower than that with methotrexate. If relapses occur after complete withdrawal of the drug, they usually occur within three to four weeks. The major side effects that we have observed are diarrhea, soft stools, and nausea, and these seem to be dose related. Some patients have burning and pain on urination, weakness, and lassitude.

JOHN W. PETROZZI, MD: Do all of the patients experience relapse three to four weeks after mycophenolic acid treatment is stopped?

DR MARINARI: No, but the lesions in most patients will gradually recur and then an individual patch will expand, but they do not recur in an explosive manner. We do not have prolonged follow-ups.

SHELDON B. GOLDSTONE, MD: Are there any hematologic complications?

DR MARINARI: Within the first 12 to 15 weeks of treatment, we have seen a gradual decline in hemoglobin level. As treatment continues, the hemoglobin level usually returns to about normal for the patient. Several patients have been reported as having leukopenia; however, the leukocyte count reverts to normal on discontinuing treatment with the drug, but we have not observed leukopenia in our patients.

DR. FLEISCHMAJER: At the present time, mycophenolic acid does not have a brand name. It is difficult to get excited about another cytotoxic drug in the treatment of psoriasis, but the thought was that this drug would not cause bone marrow depression and would not affect the liver or the kidney. The drug is slow acting and you do not get the dramatic effect sometimes seen with methotrexate. The only serious side effect in our study has been the development of a hemorrhagic diarrhea in one patient who continued taking the drug after symptoms of colitis had developed. We plan to keep the patients on treatment for two years before a final evaluation is attempted.

Nonproprietary Name and Trademark of Drug

Mycophenolic acid—*Melbex*.

Feb 21, 1975

Waine C. Johnson, MD, Recorder

Generalized Erythroderma Secondary to Atopy, R/O Sézary Syndrome. Presented by ALEXANDER EHRLICH, MD.

A 32-year-old man has had extensive atopic dermatitis since childhood. He has had frequent flares and has been hospitalized many times with a generalized erythroderma. A recent peripheral blood smear showed 9% of all lymphocytes to be abnormal and to contain PAS-positive granules. The patient has a history of amputation of the right leg following a severe burn, mild hypertension, glaucoma, bilateral cataracts, and chronic alcohol ingestion. Physical examination shows generalized lichenification with a "cobblestone" appearance on the trunk and extremities and minimal erythema. Lymph node biopsy specimens have been reported as chronic dermatopathic lymphadenitis and skin biopsy specimens as chronic dermatitis. He has been treated with

triamcinolone cream 0.1%, hydrophilic petrolatum, and bath oil.

Discussion

EUGENE J. VAN SCOTT, MD: If the abnormal cells seen on the peripheral smear have convoluted nuclei (Sézary cells), the patient should be classified as having Sézary syndrome. It is important to have a specific diagnosis and to know if the lymph nodes are involved. If the lymph nodes are involved with Sézary disease, chemotherapy for systemic effect should be instituted; whereas, if there is only skin involvement, mechlorethamine hydrochloride or electron beam therapy should be used.

WAINE C. JOHNSON, MD: I thought the histology was not entirely conclusive in that the lymph node showed changes of dermatopathic lymphadenitis and the skin biopsy specimens were consistent with, but not diagnostic of, mycosis fungoides or Sézary syndrome. I would like to know Dr Van Scott's experience regarding the concurrence of atopic dermatitis and mycosis fungoides. This patient has had severe eczema since infancy.

DR VAN SCOTT: I have seen patients with mycosis fungoides who have a long-term history of atopic dermatitis and quite a few who have had a history of nummular eczema. In some cases, we are not sure if the patients have mycosis fungoides in concurrence with atopic dermatitis. A few patients had a long history of atopic dermatitis with clinical features of Sézary disease; there was definite improvement with treatment.

March 21, 1975

Waine C. Johnson, MD, Recorder

Metastatic Squamous Cell Carcinoma. Presented by STEVEN A. GAMMER, MD, JOHN W. PETROZZI, MD.

A 56-year-old man was seen by another physician in 1969 because of a lesion on the penis that had been present for several years. Examination revealed a 1.5 × 1.7-cm red plaque at the sulcus of the penis just to the left of the frenulum. The inguinal lymph nodes were not enlarged. The patient was stated to have had a circumcision as an infant. The clinical impression was erythroplasia of Queyrat, and a punch biopsy was performed and the specimen was interpreted as erythroplasia. The lesion was treated by electrodesiccation and curettage and there was no evidence of recurrence of the penile lesion or any lymph node enlargement on examination seven months after treatment.

The patient did not return for follow-up. He apparently noted a mass in the left inguinal area in 1972 but did not seek medical evaluation until July 1974. Examination revealed metastatic squamous cell carcinoma of the left inguinal lymph nodes, an ulcerated inguinal mass, and pain and swelling of the left leg. A lymphangiogram revealed the presence of metastases in the hypogastric and left para-aortic lymph nodes. He was treated with a course of 5,500 rads of x-rays and later by a course of chemotherapy without a satisfactory response. He has been referred for further evaluation and treatment.

Metastatic squamous cell carcinoma of left inguinal area and suprapubic area.

Physical examination shows a hard, matted, foul-smelling left inguinal mass that is draining a serous exudate (Figure). A 1-cm nodule near the midline of the pubic area is also present. The penis is partially circumcised and the frenulum as well as the rest of the penis appears completely normal. The left leg shows extensive pitting edema. A chest roentgenogram, liver scan study, and bone survey did not show evidence of tumor. Pathological examinations of the left inguinal lymph node, left inguinal mass, and pubic skin nodule showed squamous cell carcinoma.

Discussion

CAPT BERNETT JOHNSON, MC, USN: The interesting aspect is whether the inguinal carcinoma represents a metastasis from the erythroplasia of Queyrat or if it is of another source.

STEVEN A. GAMMER, MD: The original biopsy specimen of the penile lesion in 1969 was interpreted as erythroplasia of Queyrat, but I have shown the sections to other dermatopathologists who do not agree with this diagnosis.

WAINE C. JOHNSON, MD: I reviewed the section presented today and I have studied sections from the initial biopsy specimen taken in 1969 and it is my opinion that the lesion of the penis was erythroplasia of Queyrat. One can raise the question as to whether there is early invasion of the underlying corium as carcinoma. I was not convinced that there was definite invasion of the corium as carcinoma, but this determination is not always clear-cut and I could understand that others might interpret the features as early invasion. It would be unusual for erythroplasia of Queyrat with such superficial invasion, if there is in fact invasion of the corium, to give rise to metastases, especially since the initial lesion was apparently cured with electrodesiccation. One has to consider the possibility of a primary squamous cell carcinoma arising in the inguinal area, or of a metastasis from an internal source not yet recognized; but the circumstantial evidence would seem to favor that the inguinal carcinoma is secondary to the lesion of the penis.

HERBERT GOLDSCHMIDT, MD: I have seen a patient with histologically confirmed Bowen's disease of the pubic area that was treated with fluorouracil with clearing of the lesion. He did not return until two years later when a new lesion had developed in the same area that was excised and histologically showed squamous cell carcinoma. Metastases to the local lymph nodes later developed. One could raise a question as to whether there is something special about the area or could it have been related to treatment with fluorouracil?

DONALD SCHETMAN, MD: The treatment of erythroplasia and Bowen's disease with fluorouracil seems to have progressed from the experimental stage to a standard procedure rather than surgery, but when you hear of recurrences and metastases, you begin to have second thoughts.

DR JOHNSON: I believe there is a distinct difference in treating erythroplasia of Queyrat, which is usually located on the glans where there are no adnexal structures, and treating Bowen's disease or extramammary Paget's disease with fluorouracil where there are adnexal structures and atypical cells extend deep into the hair follicle root sheaths and along and within the sweat ducts and sweat glands. I do not see how the atypical cells within the adnexal structures could be significantly affected by the fluorouracil. I do not see any theoretical objection to using fluorouracil on the glans or sites where there are no adnexal structures.

ALBERT M. KLIGMAN, MD: I would like to hear the opinion of the pathologists as to whether erythroplasia is identical to Bowen's disease, not just histologically but in every biological sense, or is it the same process that happens to have a special name because it is located on the glans. Since they look alike and behave similarly, it seems possible that they are not really different.

DONALD L. BAXTER, MD: The key to the answer is the biological behavior. Erythroplasia of Queyrat differs first because of the location with the absence of appendageal structures. Second, we have fairly good documentation from the work of Dr James Graham that erythroplasia of Queyrat is not associated with arsenic as is often seen in Bowen's disease, so there may be a difference in mechanisms of development. Third, erythroplasia of Queyrat has not been reported to be associated with an increased frequency of internal malignancy as is seen with Bowen's disease. The histological features of the diseases are in my opinion indistinguishable, but on the basis of the clinical and pathological correlation, I believe they are separate entities.

Nov 15, 1974

Waine C. Johnson, MD, Recorder

Kaposi's Sarcoma After Renal Transplantation. Presented by ROBERT I. RUDOLPH, MD.

A 42-year-old black man has had a long history of hypertension and deteriorating renal function. He had been treated with repeated dialysis and in February 1974 a

bilateral nephrectomy with transplantation of cadaver kidneys was performed. Initially receiving high doses of prednisone and azathioprine, he is now taking 20 mg of prednisone and 24 mg of azathioprine daily. Some weeks after the surgery, the patient noticed dark, painless, scaly lumps on his fingers, hands, feet, and soles. Skin biopsy specimens were interpreted as Kaposi's sarcoma in September 1974. A biopsy specimen from a mass in the left tonsillar area in October 1974 was also interpreted as Kaposi's sarcoma. Physical examination in September 1974 revealed multiple variable-sized purple keratotic papules and plaques on the fingers, hands, feet, and toes. Each extremity has been treated with 2,000 rads of 2 meV using 2 ports, and the neck has received 2,000 rads of cobalt 60 using 2 ports. The condition of all of the lesions has greatly improved following the treatment.

Discussion

HERBERT GOLDSCHMIDT, MD: Radiotherapy is an effective form of treatment in Kaposi's sarcoma. Relatively low doses are usually effective. Kaposi's sarcoma developed in this patient after renal transplantation and treatment with immunosuppressive drugs. Similar cases have been reported in patients with lupus erythematosus who were treated with immunosuppressive drugs. Patients receiving immunosuppressive drugs may have Kaposi's sarcoma develop in the younger age groups in contrast to the naturally occurring disease that usually appears in older patients and particularly in men. There is some indirect evidence that Kaposi's sarcoma may be a viral disease. In the lowlands of Central Africa, 9% of all malignant tumors are Kaposi's sarcoma, and this supports an infectious etiology. Patients with Kaposi's disease also have a higher incidence of other malignant neoplasms. The occurrence of Kaposi's disease in patients receiving immunosuppressive agents emphasizes that physicians should be cautious in using these drugs for benign disease.

CHARLES H. GREENBAUM, MD: Is there anything known about the person who donated the kidneys?

ROBERT RUDOLPH, MD: We have no information regarding the person who donated the kidneys. Dr Braverman has stated that in about 10% of the patients with Kaposi's sarcoma a second malignant neoplasm develops.

SAMUEL L. MOSCHELLA, MD: I recently saw a 67-year-old Italian man who had had Kaposi's disease of the extremities for eight years. Two years ago myasthenia gravis developed and a mediastinal mass was discovered. The lesion was excised and was interpreted as a spindle cell type of thymoma with two adjacent nodes showing Kaposi's sarcoma. Kaposi's sarcoma is associated not only with an increased frequency of lymphomas but also with other types of malignant neoplasms.

Nonproprietary Name and Trademark of Drug

Azathioprine—*Imuran.*

Capillary and Cavernous Hemangioma: Presented for Discussion of Therapy. Presented by HOWARD SIMONS, MD.

The patient was born on May 26, 1974, and appeared normal. Lesions of the face were first seen at 2½ weeks and they have increased in number and size. There has been no respiratory distress, bleeding, or purpura.

Physical examination at this time shows a marked deformity of the face, especially the nose and right orbit, caused by masses of hemangioma. The patient was placed on a regimen of oral steroids for two weeks without any change in appearance.

Discussion

JOHN F. WILSON, MD: This is the most disfiguring hemangioma that I have ever seen. The mother stated that when the baby was only 2 days old and had an occasional coughing spell, swollen red blotches would appear at the sites now occupied by the hemangioma. This would indicate it was probably cavernous from the very beginning. I would wait in regard to treatment and hope that the expected spontaneous involution would occur.

HERBERT GOLDSCHMIDT, MD: Radiation therapy should not be used except in very rare special circumstances. In this patient, it is not indicated because there is no life-threatening complication. Radiotherapy may rarely be considered in special locations, such as around the eyes when the eyelids cannot be opened and blindness may occur. Also, when a hemangioma involving the mouth is so severe that the patient cannot eat or drink properly, radiotherapy should be tried. I believe this patient will improve spontaneously but with considerable scarring.

PETER J. KOBLENZER, MD: In children with lesions of this type, platelet sequestration does not necessarily show itself with bleeding tendencies. Also RBCs are sequestered and the patient can get a very low hemoglobin level.

DR MOSCHELLA: In 1957, I was asked to see a 9-month-old infant on a pediatric ward who had a rapidly growing hemangioma of the face. We decided to observe the child further. A few days later, I was informed that the infant had died because of a laceration in the posterior pharynx that bled into the intestinal tract. Platelet counts had not been done, and the personnel were apparently not aware of the danger. The features were consistent with Kasabach-Merritt syndrome, hemangioma with thrombocytopenia resulting from intravascular coagulation. We have used intralesional steroid therapy in five patients with congenital hemangiomas mainly of the capillary type with satisfactory results. These were ulcerated lesions located about the genitalia that were symptomatic due to the irritating effects of excreta. The lesions were injected two to three times at three-week intervals. Involution occurred in about two months.

DONALD L. BAXTER, MD: One must know if hemangioma involves only skin and subcutaneous tissue or if it also involves underlying bony structures. If bone is involved, the prognosis is much more serious.

Tuberous Sclerosis. Presented by JAY M. HOLZWINGER, MD.

A 4-year-old girl has had a history of seizures since 7 months of age. She has psychomotor retardation, with a developmental age of 18 to 30 months when tested at 40 months. Skin lesions have been present since infancy. A maternal second cousin had seizures in childhood. A maternal third cousin has had seizures and is of normal intelligence. There are skin-colored, elevated, plaque-like lesions involving the extensor aspect of the left arm and the right midback. There are hypopigmented macular lesions of both forearm extensor surfaces. An ophthalmologic examination showed early phakoma of the inferior midline aspect of the right disc. A pneumoencephalogram showed candlegutter lesions along the floor of each lateral ventricle. Skull films and long bone x-ray films were within normal limits. A chromosome study revealed 46 XX.

Discussion

THOMAS BUTTERWORTH, MD: Ophthalmologists have always been confident that they can diagnose tuberous sclerosis on the basis of the phakomas occurring in the eyes. The questions to consider are those of what you should tell the patient's family and, later on, the patient regarding the prognosis, genetic counseling, and what studies might be done to investigate the nature of the connective tissue defect. Tuberous sclerosis is an autosomal dominant disease that has a variable penetrance and expressivity. We expect only about one half of the patients to have skin manifestations. It is important to take a good family history to know which side of the family may be transmitting the trait. This couple had four children, and by the law of averages there would be two free of tuberous sclerosis who would not transmit the disease to their offspring. Of the two carrying the trait, one might show skin lesions and the other only internal manifestations. Therefore, we tell the family there is a 50% possibility that other children may have the disease. It is also important to determine which of the parents is the carrier of the trait because members may have been asymptomatic to the age of 50 or 60 years and then a seizure or brain tumor resulting in death develops. It would be ideal, too, if a method could be devised for studying the fetus in utero to determine if the trait is present, but unfortunately we cannot do so at this time. Although tuberous sclerosis has been described as a neuroectodermal disease, it is actually a mesenchymal or connective tissue problem. In all of the involved sites, whether brain, skin, or other organs, there is an abnormal proliferation of connective tissue associated with some vascular ectasia. The question arises whether this may represent a metabolic disturbance related to a deficiency of collagenase or whether there might be an excess of a collagenase inhibitor. I would like to see collagenase studies and collagenase inhibitor studies carried out in patients with tuberous sclerosis in the hope that we can learn more about the mechanism of the formation of fibromas or angiofibromas.

...or the acne hello...

ACNAVEEN® BAR

Soothes and cleans sensitive skin, and helps bring their guards down...

Hiding their embarrassment compounds the misery. Incessant picking and rubbing of acne lesions often causes more irritation. Urge them to wash with soap-free ACNAVEEN® Bar, logical adjunctive therapy in whatever treatment you've chosen:

- 2% salicylic acid and 2% sulfur provide a peeling and drying effect.
- Aveeno Colloidal Oatmeal soothes the skin and reduces irritation.

ACNAVEEN® BAR: Special mild cleansing bar for acne.

Available in 3.5 oz. bars

Cooper Cooper Laboratories, Inc., Wayne, New Jersey 07470

New fast way with spray

for contact dermatitis control

New Diprosone® Aerosol 0.1%

brand of

betamethasone dipropionate (Potency expressed as betamethasone)

Rapid improvement of moderate to very severe contact dermatitis signs/symptoms*

	Per cent of patients improved†		
	Pruritus 129 patients	**Erythema 129 patients**	**Vesiculation 77 patients**
After 3 days	**85%**	**78%**	**82%**
After 7 days	**92%**	**93%**	**94%**

*Improvement is defined as a reduction of signs or symptoms. †Data in files of Headquarters Medical Research Division, Schering Corporation.

- Easily penetrates hairy areas...convenient for hard-to-reach sites.
- Cools and soothes hot, oozing, itching lesions.
- Cosmetically elegant...invisible, odorless, stainless.

Diprosone is also available in cream, ointment, and lotion.

COPYRIGHT © 1977. SCHERING CORPORATION. ALL RIGHTS RESERVED. SLS-846

See Clinical Considerations section on opposite page...

Schering

New Diprosone®
brand of
betamethasone dipropionate
Aerosol 0.1%

Clinical Considerations: INDICATIONS DIPROSONE Aerosol is indicated solely for the adjunctive topical management for the relief of inflammatory manifestations of acute contact dermatitis. DIPROSONE Aerosol has not been shown to be effective in any steroid-responsive dermatosis other than contact dermatitis. **CONTRAINDICATIONS** DIPROSONE Aerosol is contraindicated in vaccinia and varicella. Topical steroids are contraindicated in those patients with a history of hypersensitivity to any of the components of such preparations. DIPROSONE Aerosol is also contraindicated for use under occlusive dressings. **WARNINGS** Keep away from eyes or other mucous membranes. Use only as directed; intentional misuse by deliberately concentrating or inhaling the contents can be harmful or fatal. Avoid freezing of the tissue by not spraying for more than three seconds, at a distance of not less than six inches. Contents under pressure. Do not puncture. Do not use or store near heat or open flame. Exposure to temperatures above 120° Fahrenheit may cause bursting. Never throw container into fire or incinerator. Keep out of reach of children. **PRECAUTIONS** If irritation develops with the use of DIPROSONE Aerosol, treatment should be discontinued and appropriate therapy instituted. In the presence of an infection, the use of an appropriate antifungal or antibacterial agent should be instituted. If a favorable response does not occur promptly, the corticosteroid should be discontinued until the infection has been adequately controlled. If extensive areas are treated, the possibility exists of increased systemic absorption of the corticosteroid and suitable precautions should be taken. Although topical steroids have not been reported to have an adverse effect on pregnancy, the safety of their use in pregnant females has not been absolutely established. Therefore, they should not be used extensively on pregnant patients, in large amounts or for prolonged periods of time. DIPROSONE Aerosol is not for ophthalmic use. **ADVERSE REACTIONS** The following local adverse reactions have been reported with topical corticosteroids: burning; itching; irritation; dryness; folliculitis; hypertrichosis; acneiform eruptions; hypopigmentation; maceration of the skin; secondary infection; skin atrophy; striae; miliaria.

11079105 MARCH 1977

Aerosol Packaged by*Aerosol Techniques, Inc.
Armstrong Laboratories Division
West Roxbury, MA 02132

For more complete details, consult package insert or Schering literature available from your Schering Representative or Professional Services Department, Schering Corporation, Kenilworth, New Jersey 07033.

Books

Cryosurgical Advances in Dermatology and Tumors of the Head and Neck, edited by Setrag A. Zacarian, MD, FACP, many color and black and white illus, 272 pp, $33, Charles C Thomas Publisher, Springfield, Ill, 1977.

The field of "modern" (or advanced) cryosurgery has progressed at an impressive rate during the past decade. Zacarian has participated in this growth in many ways. He not only made and reported many of the basic clinical observations, but, he did much of the animal and other research projects that provided this field with the background that it required for acceptance. He brings his unique knowledge of his subspecialty to this publication. Zacarian has produced three books on the subject since 1969. In this, his third volume, the word "advances" seems to be the keynote. It is an attempt to bring the reader up to date on the latest advances, but it also reemphasizes the advances of the past. This may make the book of greater interest to the physician already in the field than to the potential beginner. Yet, this is not said in criticism.

It is a beautifully produced volume and credit for this must go to the publisher. Through the cooperation of many pharmaceutical firms, it contains many strikingly clear, reproduced color illustrations. The book is well written and quite readable; however, the use of anecdotal case reports although adding to the reader's interest does little to the scientific value of the treatise.

Like all multiauthored books, it has its high points and its low points, depending on the interest and the literacy of the individual contributors. In this volume, the overall effect is commendable. Most or all observers realize that cryosurgery will not replace x-radiation, surgery, microscopically controlled chemosurgery, etc, in the management of skin cancer. Nevertheless, few question that there is a place for this modality in our armamentarium against that disease. The complete dermatologist should be able to offer this form of therapy to his patients. This book can be recommended to any physician who uses or hopes to use this modality in his practice.

ERVIN EPSTEIN, MD
Oakland, Calif

Mechanisms of Topical Corticosteroid Activity, edited by Lyn C. Wilson and R. Marks, with illus, 150 pp, $22, Churchill Livingstone, New York, 1977.

There have been several pertinent reviews of corticosteroids recently. The first by D. Azarnoff (*Steroid Therapy,* Philadelphia, WB Saunders Co, 1975) covers systemic and topical applications whereas the second in *Dermatologica* (152, suppl 1, 1976) discusses topical activity. The present summary of a symposium on mechanisms of topical steroid activity supplements material presented in the previous two reviews. With these three books, the student of corticosteroids receives a broad view of the problems that have been solved and those that remain to be solved.

This volume has several new research contributions. These include a study of the effect of corticosteroids on skin fibrinolytic activity (Tebs and Cunliff), the fine points of the effect of corticoids on skin pulses (Tune), and several papers attempting to explain their effect on epidermal cell kinetics. A clear statement on the negative effect of corticosteroids on melanin pigmentation in the guinea pig (S. Bleehan) and several papers discussing the putative anti-inflammatory roles of these compounds are valuable.

Since the topical corticosteroids represent the most widely used drug in dermatology, any relevant fact (positive or negative) that might lead to an improvement in their properties is surely worthwhile. The editors (Wilson and Marks) are to be congratulated on producing this volume.

HOWARD MAIBACH, MD
San Francisco

For Skin Without Water

Neutrogena® Dry Skin products are specially formulated to supplement surface fats and aid in the retention of moisture.

- Neutrogena® Dry-Skin Soap contains humectants, lubricants, and emollients to soften and moisturize, and is nonirritating to sensitive skin.
- Neutrogena® Rainbath® Dry Skin Bath Gel is lipid-free, cleanses with a rich lather without the drying effect of ordinary soap, and leaves skin soft and smooth. Available both scented and unscented.
- Neutrogena® Hand Cream is a heavy-duty formula containing a special blend of naturally occurring oils and glycerin, and is a useful adjunct in steroid-responsive hand dermatoses.[1]

1. Data on file, Medical Dept., Neutrogena Corp.

Neutrogena®
Dedicated to Sensitive Skin Care

Neutrogena Corp.
5755 West 96th Street
Los Angeles, California 90045

Now available! The latest information on self-assessment programs.

The new edition of the AMA's DIRECTORY OF SELF-ASSESSMENT PROGRAMS FOR PHYSICIANS is now available. It lists programs sponsored by all major specialty societies, on 21 topics.

Each program is listed by topic and sponsor and includes sites and times of tests, content, format, time required, method of scoring, aids to learning, fees and whom to write.

To order your copy of the Directory, ($1 ea.) write: Order Dept. OP-414, American Medical Association, 535 N. Dearborn St., Chicago, Ill. 60610.



For Skin Plagued by Acne

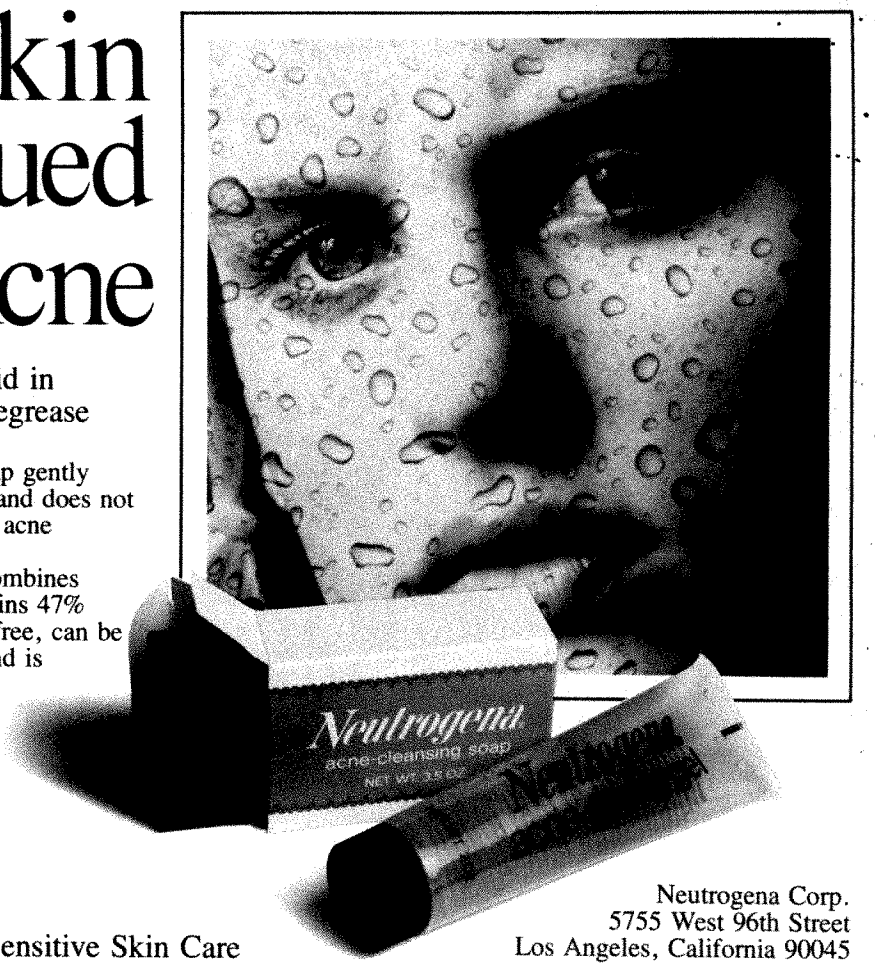

Neutrogena® Acne products aid in drying while they clean and degrease acne-plagued skin.

- Neutrogena® Acne-Cleansing Soap gently cleanses and degreases the skin, and does not interfere with topical or systemic acne treatment.
- Neutrogena® Acne-Drying Gel combines antisepsis with astringency, contains 47% active drying agents, is perfume-free, can be applied under or over makeup, and is imperceptible on the skin.

Neutrogena®
Dedicated to Sensitive Skin Care

Neutrogena Corp.
5755 West 96th Street
Los Angeles, California 90045

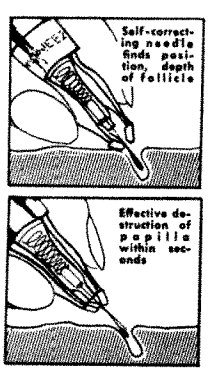

Perma Tweez®

ELECTROLYSIS FOR PERMANENT HAIR REMOVAL

Clinical study (copy on request) proves safety and efficacy of laity self-use electrolysis. Study shows chin and even axilla can be self-treated effectively through use of mirror. This permanent hair remover features the only patented self-correcting needle in existence. Battery operated instrument sterilizes itself when current flows. No-puncture safety feature also helps prevent infection.

Thousands of units sold to physicians for such varied application as removal of inverted eyelashes to cosmetic use.

PERMA TWEEZ & ATTACHMENT **$22.45**

☐ Invoice after 30 days

☐ Check enclosed

30 DAY FREE TRIAL EXAMINATION

(MAY BE RETURNED WITH NO OBLIGATION)

GENERAL MEDICAL CO., Dept. D-89
1935 Armacost Ave
West Los Angeles, CA 90025

DR _____
STREET _____
C/S _____ ZIP _____

News and Notes

Hair Transplant Symposium.—The American Society for Dermatologic Surgery and the American Academy of Facial Plastic and Reconstructive Surgery are sponsoring the Annual Hair Transplant Symposium and Workshop, Feb 2 through 4, 1978 in Lucerne, Switzerland. The course moderator will be D. Bluford Stough III, MD. For further information write to Stough Dermatology and Cutaneous Surgery Clinic, Doctor's Park, Hot Springs, AR 71901.

Flaps.—The American Society for Dermatologic Surgery announces a course entitled "Dermatologic Surgery—Flaps." The course will be held at the University of California Medical Center, San Francisco, Sept 10 and 11, 1977. The course moderator will be Theodore Tromovitch, MD. For further information write to Extended Programs in Medical Education, University of California School of Medicine, San Francisco, CA 94143.

General Meeting.—The American Society for Dermatologic Surgery will hold a general membership meeting Dec 6, 1977 in Dallas. Details will be announced in the society's newsletter, or interested parties may write to Daniel E. Gormley, MD, ASDS secretary, 210 S Grand Ave, Suite 307, Glendora, CA 91740.

ASDS Annual Meeting.—The American Society for Dermatologic Surgery will hold its fourth annual Clinical and Scientific Meeting March 29 through April 2, 1978 at Vacation Village in San Diego. The course moderator will be Theodore Tromovitch. For reservation information write to Mr Robert Brown, The Incentive Co, 2207 Chestnut St, Philadelphia, PA 19103.

Meeting.—The Western Regional Meeting of the Society for Investigative Dermatology (SID) will be held jointly with the Dermatology Subsection of the Western Section of the American Federation for Clinical Research (AFCR), the Western Society for Pediatric Research, the Western Association of Physicians, and the Western Society for Clinical Research. The meeting will be held Feb 1-3, 1978, Carmel, Calif. Inquires may be addressed to Ervin Epstein, Jr, MD, 400 30th St, Oakland, CA 94609.

Abstracts are solicited and must be received by Oct 5, 1977, and should be submitted on current AFCR or SID forms.

Following the Dermatology Subsection, the SID will present a symposium entitled "Physiologic Functions of Inflammatory Mediators."

1977-1978 American Academy of Dermatology Roster Available.—The 1977-1978 Roster of the American Academy of Dermatology, including by-laws, officers, and committees, is now available, according to Bradford W. Claxton, executive director of the Academy.

A copy has been mailed to each member of the Academy. Members may obtain additional copies for $10 each. Physicians, hospitals, libraries, and educational institutions may purchase copies for $25 each. The charge to commercial users is $75 per copy.

For details, write: Membership Services, American Academy of Dermatology, 820 Davis St, Evanston, IL 60201.

European Society for Dermatological Research (ESDR) Poster Award.—The ESDR Poster Award for the best poster presentation at the annual ESDR meeting has been kindly offered by Max Ritter, Pharmaceutical Specialities, Zurich/CH.

The 1977 winners are H. Rorsman, G. Agrup, Ch. Hansson, G. Prota, A. M. Rosengren, and E. Rosengren from the Departments of Dermatology, Organic Chemistry, Biochemistry, and Pharmacology, the University of Lund and the University of Naples, for the poster "New metabolites of the melanocytes excreted in the urine."

European Society for Dermatological Research (ESDR) Symposium.—This symposium entitled "Clinical and Experimental Approaches to Skin Carcinogenesis" is to be held in Paris, Jan 13 and 14, 1978. It is a clinically orientated symposium sponsored by the ESDR. It will consist of short papers from invited speakers, discussion periods, and a session for free communications. Anyone wishing to contribute or to attend this meeting should contact Prof M. Prunieras, Laboratoire de Recherches sur les Tumeurs de la Peau Humaine, Fondation Ophthalmologique A. de Rothschild, 29 Rue Manin, 75019 Paris, France.

SYNALAR®
(fluocinolone acetonide)
CREAM 0.025%
CREAM 0.01%
OINTMENT 0.025%
SOLUTION 0.01%

Description Synalar (fluocinolone acetonide) has the chemical name 6α, 9α-difluoro-16α-hydroxyprednisolone-16, 17-acetonide.

The cream contains fluocinolone acetonide 0.25 mg./g. or 0.1 mg./g. in a water-washable aqueous base of stearic acid, propylene glycol, sorbitan monostearate and monooleate, polysorbate 60, purified water and citric acid with methylparaben and propylparaben as preservatives.

The ointment contains fluocinolone acetonide 0.25 mg./g. in a white petrolatum U.S.P. vehicle.

The solution contains fluocinolone acetonide 0.1 mg./g. in a water-washable base of propylene glycol with citric acid.

Indications For relief of the inflammatory manifestations of corticosteroid-responsive dermatoses.

Contraindications Topical steroids are contraindicated in vaccinia and varicella.

Topical steroids are contraindicated in those patients with a history of hypersensitivity to any of the components of the preparation.

Precautions If irritation develops, the product should be discontinued and appropriate therapy instituted.

In the presence of an infection the use of an appropriate antifungal or antibacterial agent should be instituted. If a favorable response does not occur promptly, the corticosteroid should be discontinued until the infection has been adequately controlled.

If extensive areas are treated or if the occlusive technique is used, the possibility exists of increased systemic absorption of the corticosteroid and suitable precautions should be taken.

Although topical steroids have not been reported to have an adverse effect on pregnancy, the safety of their use in pregnant females has not absolutely been established. Therefore, they should not be used extensively on pregnant patients, in large amounts, or for prolonged periods of time.

Synalar products are not for ophthalmic use.

Adverse reactions The following local adverse reactions have been reported with topical corticosteroids: burning, itching, irritation, dryness, folliculitis, hypertrichosis, acneform eruptions, hypopigmentation.

The following may occur more frequently with occlusive dressings than without such therapy: maceration of the skin, secondary infection, skin atrophy, striae, miliaria.

How Supplied
Synalar (fluocinolone acetonide)
Cream 0.025% — 15 and 60g. tubes and 120 and 425g. jars.
Cream 0.01% — 15, 45 and 60g. tubes and 120 and 425g. jars.
Ointment 0.025% — 15 and 60g. tubes and 425g. jars.
Solution 0.01% — 20cc. and 60cc. plastic squeeze bottles.

Also Available
Synalar-HP® (fluocinolone acetonide) Cream 0.2% 5g. and 12g. tubes.

SYNTEX
SYNTEX LABORATORIES, INC.

AS USEFUL TODAY AS THE
DAY IT WAS INTRODUCED

SYNALAR
(FLUOCINOLONE ACETONIDE)

See preceding page for summary of prescribing information



SYNTEX

Acne illustrated by artist.

VECTRIN Capsules, 100 mg
(minocycline HCl capsules, USP)
Brief Summary of Prescribing Information

Indicated in severe acne as adjunctive therapy. Consult package insert for complete prescribing information.

Contraindication: Hypersensitivity to any tetracycline.

Warnings: When need for intensive treatment outweighs potential dangers, perform renal and liver function tests before and during therapy; also follow serum concentrations. In renal impairment, usual doses may lead to excessive accumulation and liver toxicity. Under such conditions, use lower total doses, and, in prolonged therapy, determine serum levels. The use of tetracyclines during tooth development (last half of pregnancy, infancy, and childhood to the age of 8 years) may cause permanent discoloration of the teeth (yellow-gray-brown). This is more common during long-term use but has been observed following repeated short-term courses. Enamel hypoplasia has also been reported. Tetracyclines, therefore, should not be used in this age group unless other drugs are not likely to be effective or are contraindicated. Photosensitivity manifested by an exaggerated sunburn reaction has been observed in some individuals taking tetracyclines. Advise patients apt to be exposed to direct sunlight or ultraviolet light that such reactions can occur, and discontinue treatment at first evidence of skin erythema. Studies with minocycline HCl indicated that photosensitivity did not occur. However, reports have been received in patients with significantly impaired renal function the antianabolic action of tetracycline may cause an increase in BUN leading to azotemia, hyperphosphatemia, and acidosis. **CNS side effects:** (light-headedness, dizziness, vertigo) have been reported, may disappear during therapy, and always disappear rapidly when drug is discontinued. Caution patients who experience these symptoms about driving vehicles or using hazardous machinery while taking this drug. **Pregnancy:** In animal studies, tetracyclines cross the placenta, are found in fetal tissues, and can have toxic effects on the developing fetus (often related to retardation of skeletal development). Embryotoxicity has been noted in animals treated early in pregnancy. The safety of minocycline HCl for use during pregnancy has not been established. **Newborns, infants, and children:** All tetracyclines form a stable calcium complex in any bone-forming tissue. Prematures given oral doses of 25 mg/kg every six hours, demonstrated a decrease in fibula growth rate reversible when drug was discontinued. Tetracyclines

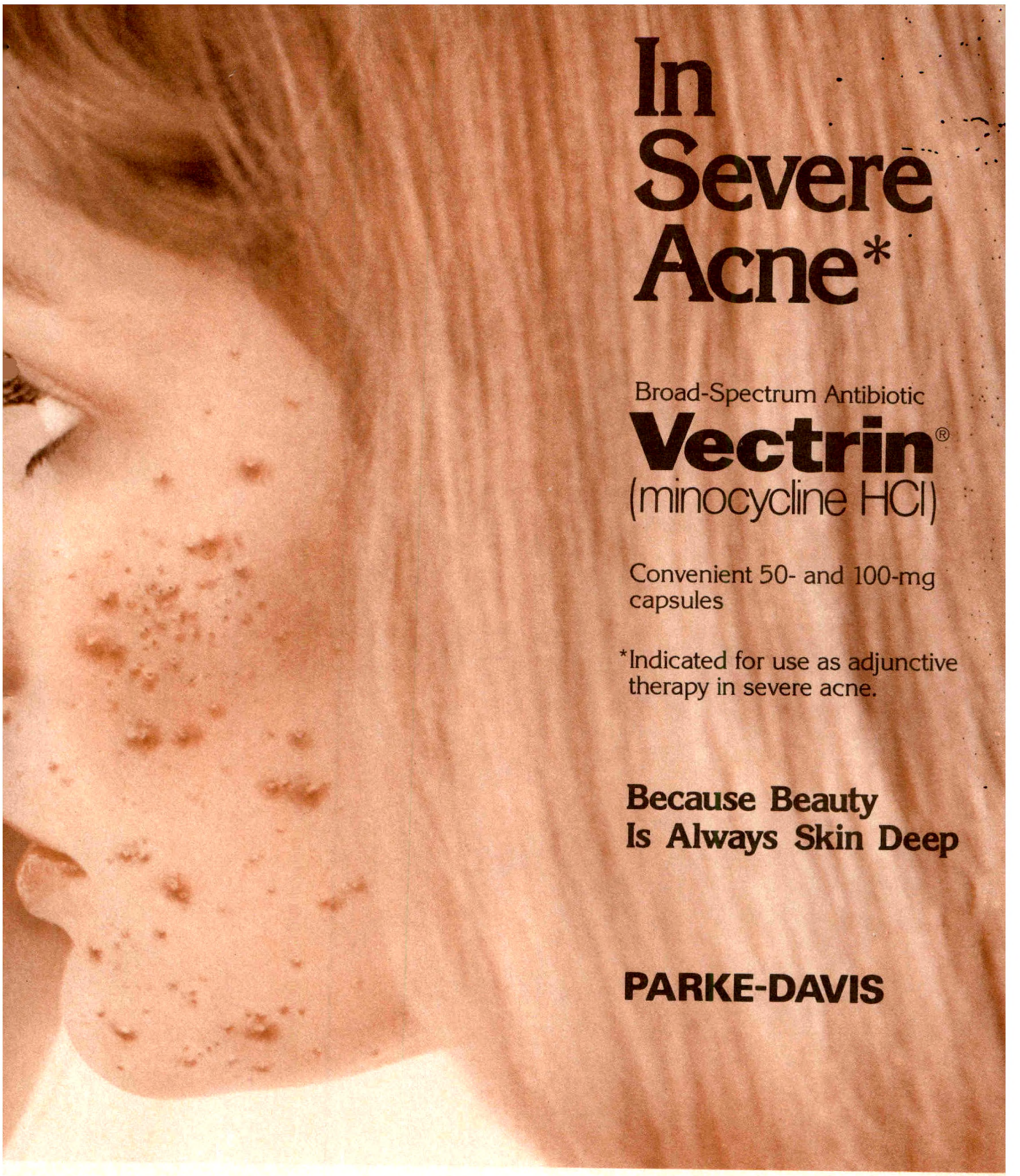

In Severe Acne*

Broad-Spectrum Antibiotic

Vectrin®
(minocycline HCl)

Convenient 50- and 100-mg capsules

*Indicated for use as adjunctive therapy in severe acne.

Because Beauty Is Always Skin Deep

PARKE-DAVIS

are present in the milk of lactating women who are taking a drug in this class.

Precautions: Use may result in overgrowth of non-susceptible organisms, including fungi. If superinfection occurs, antibiotics should be discontinued and appropriate therapy instituted. In venereal diseases when coexistent syphilis is suspected, darkfield examination should be done before treatment is started and blood serology repeated monthly for at least four months. Patients on anticoagulant therapy may require downward adjustment of such dosage. Test for organ system dysfunction (eg, renal, hepatic, and hemopoietic) in long-term use. Treat all group A beta-hemolytic streptococcal infections for at least 10 days. Avoid giving tetracycline in conjunction with penicillin.

Adverse Reactions: GI: Anorexia, nausea, vomiting, diarrhea, glossitis, dysphagia, enterocolitis, inflammatory lesions (with monilial overgrowth) in anogenital region. **Skin:** Maculopapular and erythematous rashes. Exfoliative dermatitis (uncommon). Photosensitivity is discussed above. (See Warnings.) **Renal toxicity:** Rise in BUN, dose-related. (See Warnings.) **Hypersensitivity reactions:** Urticaria, angioneurotic edema, anaphylaxis, anaphylactoid purpura, pericarditis, exacerbation of systemic lupus erythematosus. In young infants, bulging fontanels have been reported following full therapeutic dosage, disappearing rapidly when drug was discontinued. **Blood:** Hemolytic anemia, thrombocytopenia, neutropenia, eosinophilia. **CNS:** (See Warnings.) When given over prolonged periods, tetracyclines may produce brown-black microscopic discoloration of thyroid glands; no abnormalities of thyroid function studies are known to occur.

NOTE: Concomitant therapy: Antacids containing aluminum, calcium, or magnesium impair absorption; do not give to patients taking oral tetracycline. Studies to date indicate that absorption of VECTRIN (minocycline hydrochloride) is not notably influenced by foods and dairy products.

Full prescribing information available upon request.

PARKE, DAVIS & COMPANY
Detroit, Michigan 48232

anti-
inflammatory
antifungal
antipruritic
antibacterial

Clear choice

When dermatoses become infected with bacteria or fungi, plain topical steroids are generally not the recommended therapeutic choice.

A clear choice, however, is Vioform® Hydrocortisone. With its unique four-way action, it supplies the kind of comprehensive treatment many common dermatoses* require.

*This drug has been evaluated as possibly effective for these indications. See brief prescribing information.

Vioform®-Hydrocortisone (iodochlorhydroxyquin and hydrocortisone)

INDICATIONS
Based on a review of this drug by the National Academy of Sciences-National Research Council and/or other information, FDA has classified the indications as follows:
"Possibly" effective: Contact or atopic dermatitis; impetiginized eczema; nummular eczema; infantile eczema; endogenous chronic infectious dermatitis; stasis dermatitis; pyoderma; nuchal eczema and chronic eczematoid otitis externa; acne urticata; localized or disseminated neurodermatitis; lichen simplex chronicus; anogenital pruritus (vulvae, scroti, ani); folliculitis; bacterial dermatoses; mycotic dermatoses such as tinea (capitis, cruris, corporis, pedis); moniliasis; intertrigo. Final classification of the less-than-effective indications requires further investigation.

CONTRAINDICATIONS
Hypersensitivity to Vioform-Hydrocortisone, or any of its ingredients or related compounds; lesions of the eye; tuberculosis of the skin; most viral skin lesions (including herpes simplex, vaccinia, and varicella).

WARNINGS
This product is not for ophthalmic use.
In the presence of systemic infections, appropriate systemic antibiotics should be used.

Usage in Pregnancy
Although topical steroids have not been reported to have an adverse effect on pregnancy, the safety of their use in pregnant females has not been established. Therefore, they should not be used extensively on pregnant patients in large amounts or for prolonged periods of time.

PRECAUTIONS
May prove irritating to sensitized skin in rare cases. If this occurs, discontinue therapy. May stain.
If used under occlusive dressings or for a prolonged period, watch for signs of pituitary-adrenal axis suppression.
May interfere with thyroid function tests. Wait at least one month after discontinuance of therapy before performing these tests. The ferric chloride test for phenylketonuria (PKU) can yield a false-positive result if Vioform is present in the diaper or urine.
Prolonged use may result in overgrowth of nonsusceptible organisms requiring appropriate therapy.

ADVERSE REACTIONS
Few reports include: Hypersensitivity, local burning, irritation, pruritus. Discontinue if untoward reaction occurs. Rarely, topical corticosteroids may cause striae at site of application when used for long periods in intertriginous areas.

DOSAGE
Apply a thin layer to affected areas 3 or 4 times daily.

HOW SUPPLIED
Cream, 3% iodochlorhydroxyquin and 1% hydrocortisone in a water-washable base containing stearyl alcohol, cetyl alcohol, stearic acid, petrolatum, sodium lauryl sulfate, and glycerin in water; tubes of 5 and 20 Gm. *Ointment*, 3% iodochlorhydroxyquin and 1% hydrocortisone in a petrolatum base; tubes of 20 Gm. *Lotion*, 3% iodochlorhydroxyquin and 1% hydrocortisone in a water-washable base containing stearic acid, cetyl alcohol, lanolin, propylene glycol, sorbitan trioleate, polysorbate 60, triethanolamine, methylparaben, propylparaben, and perfume Flora in water; plastic squeeze bottles of 15 ml. *Mild Cream*, 3% iodochlorhydroxyquin and 0.5% hydrocortisone in a water-washable base containing stearyl alcohol, cetyl alcohol, stearic acid, petrolatum, sodium lauryl sulfate, and glycerin in water; tubes of ½ and 1 ounce. *Mild Ointment*, 3% iodochlorhydroxyquin and 0.5% hydrocortisone in a petrolatum base; tubes of 1 ounce.
C75-38 Rev. 7/75

Consult complete product literature before prescribing.

CIBA Pharmaceutical Company
Division of CIBA-GEIGY Corporation
Summit, New Jersey 07901

2/7883 17

Vioform®-Hydrocortisone (iodochlorhydroxyquin and hydrocortisone)

The most widely prescribed form... 20-Gm Cream

CIBA

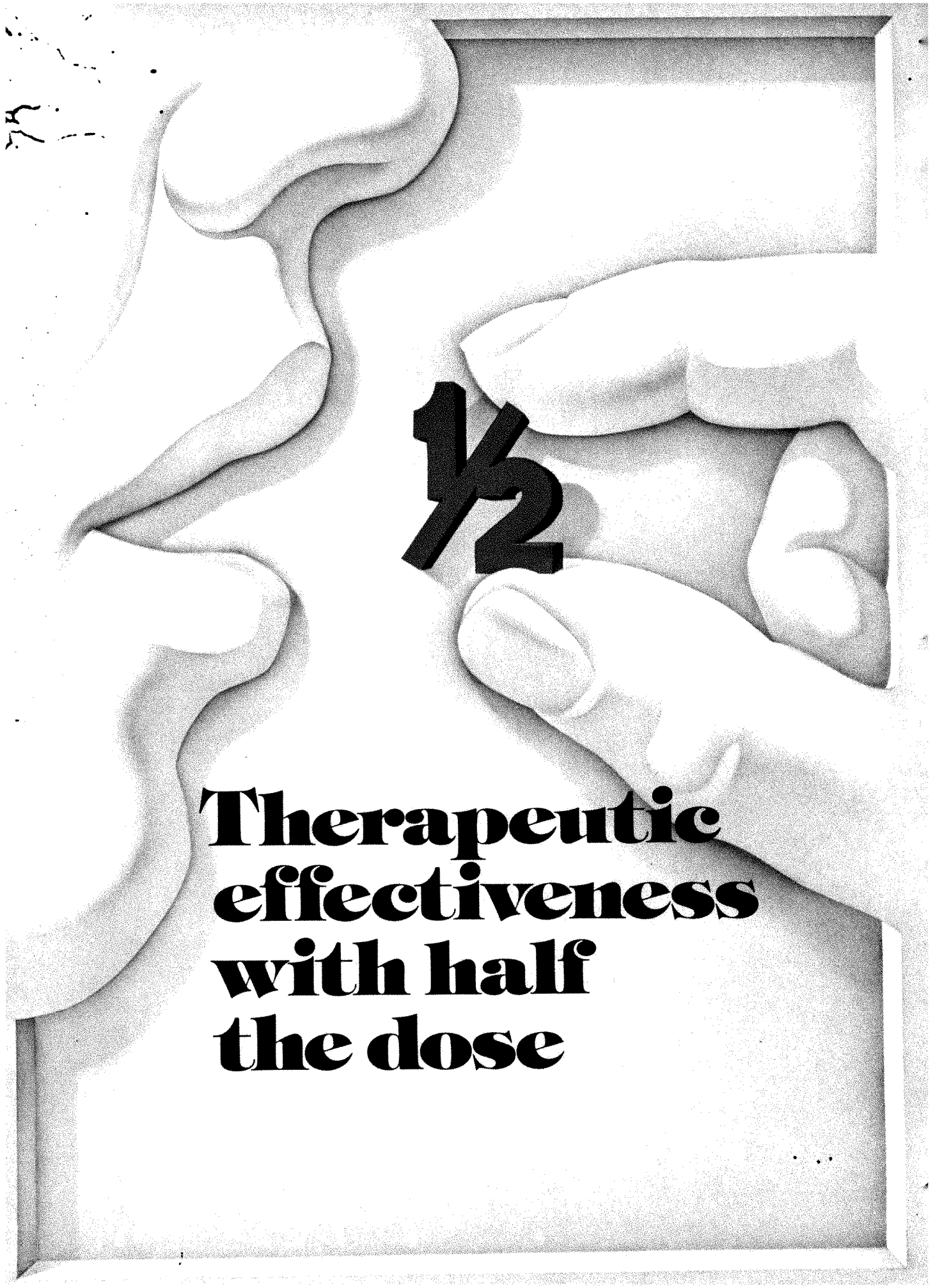
½
Therapeutic effectiveness with half the dose

Schering

Once-a-day dosage

NEW Fulvicin® P/G*

brand of griseofulvin [ultramicrosize], USP

(specially processed) **125 mg. tablets**

***"P/G" means a new polyethylene glycol system for enhanced absorption –**

A 250 mg. daily dose (two 125 mg. tablets) of new FULVICIN P/G can replace 500 mg. of griseofulvin (microsize), USP. This is made possible by a special process in which the ultramicrosize griseofulvin crystals are partly dissolved in polyethylene glycol and dispersed through the tablet matrix for enhanced absorption.

Patient convenience –

FULVICIN P/G can be prescribed as two 125 mg. tablets once a day. Compliance is further assured by the easy-to-swallow size of the tablets.

Patient savings –

FULVICIN P/G is up to 35 per cent less expensive per dose than all microsize griseofulvin formulations.**

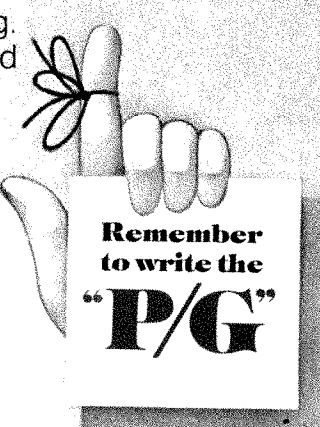

**Based on list-price comparison.

See Clinical Considerations section on following page.

COPYRIGHT © 1977, SCHERING CORPORATION. ALL RIGHTS RESERVED. SLS-703

Schering

NEW P/G Fulvicin®

griseofulvin [ultramicrosize], USP

(specially processed) **125 mg. tablets**

Clinical Considerations: INDICATIONS FULVICIN P/G Tablets are indicated for the treatment of ringworm infections of the skin, hair, and nails, namely: tinea corporis, tinea pedis, tinea cruris, tinea barbae, tinea capitis, tinea unguium (onychomycosis) when caused by one or more of the following genera of fungi: *Trichophyton rubrum, Trichophyton tonsurans, Trichophyton mentagrophytes, Trichophyton interdigitalis, Trichophyton verrucosum, Trichophyton megnini, Trichophyton gallinae, Trichophyton crateriform, Trichophyton sulphureum, Trichophyton schoenleini, Microsporum audouini, Microsporum canis, Microsporum gypseum,* and *Epidermophyton floccosum*. Note: Prior to therapy, the type of fungi responsible for the infection should be identified. The use of this drug is not justified in minor or trivial infections which will respond to topical agents alone. Griseofulvin is not effective in the following: Bacterial infections, Candidiasis (Moniliasis), Histoplasmosis, Actinomycosis, Sporotrichosis, Chromoblastomycosis, Coccidioidomycosis, North American Blastomycosis, Cryptococcosis (Torulosis), Tinea versicolor, and Nocardiosis. **CONTRAINDICATIONS** This drug is contraindicated in patients with porphyria, hepatocellular failure, and in individuals with a history of hypersensitivity to griseofulvin. **WARNINGS** *Prophylactic Usage:* Safety and efficacy of griseofulvin for prophylaxis of fungal infections have not been established. *Animal Toxicology:* Chronic feeding of griseofulvin, at levels ranging from 0.5-2.5% of the diet, resulted in the development of liver tumors in several strains of mice, particularly in males. Smaller particle sizes result in an enhanced effect. Lower oral dosage levels have not been tested. Subcutaneous administration of relatively small doses of griseofulvin once a week during the first three weeks of life has also been reported to induce hepatomata in mice. Although studies in other animal species have not yielded evidence of tumorogenicity, these studies were not of adequate design to form a basis for conclusions in this regard. In subacute toxicity studies, orally administered griseofulvin produced hepatocellular necrosis in mice, but this has not been seen in other species. Disturbances in porphyrin metabolism have been reported in griseofulvin-treated laboratory animals. Griseofulvin has been reported to have a colchicine-like effect on mitosis and cocarcinogenicity with methylcholanthrene in cutaneous tumor induction in laboratory animals. *Usage in Pregnancy:* The safety of this drug during pregnancy has not been established. *Animal Reproduction Studies:* It has been reported in the literature that griseofulvin was found to be embryotoxic and teratogenic on oral administration to pregnant rats. Pups with abnormalities have been reported in the litters of a few bitches treated with griseofulvin. Additional animal reproduction studies are in progress. Suppression of spermatogenesis has been reported to occur in rats, but investigation in man failed to confirm this. **PRECAUTIONS** Patients on prolonged therapy with any potent medication should be under close observation. Periodic monitoring of organ system function, including renal, hepatic, and hematopoietic, should be done. Since griseofulvin is derived from species of penicillin, the possibility of cross sensitivity with penicillin exists, however, known penicillin-sensitive patients have been treated without difficulty. Since a photosensitivity reaction is occasionally associated with griseofulvin therapy, patients should be warned to avoid exposure to intense natural or artificial sunlight. Should a photosensitivity reaction occur, lupus erythematosus may be aggravated. Griseofulvin decreases the activity of warfarin-type anticoagulants so that patients receiving these drugs concomitantly may require dosage adjustment of the anticoagulant during and after griseofulvin therapy. Barbiturates usually depress griseofulvin activity, and concomitant administration may require a dosage adjustment of the antifungal agent. **ADVERSE REACTIONS** When adverse reactions occur, they are most commonly of the hypersensitivity type, such as skin rashes, urticaria, and rarely, angioneurotic edema, and may necessitate withdrawal of therapy and appropriate countermeasures. Paresthesias of the hands and feet have been reported rarely after extended therapy. Other side effects reported occasionally are: oral thrush, nausea, vomiting, epigastric distress, diarrhea, headache, fatigue, dizziness, insomnia, mental confusion, and impairment of performance of routine activities. Proteinuria and leukopenia have been reported rarely. Administration of the drug should be discontinued if granulocytopenia occurs. When rare, serious reactions occur with griseofulvin, they are usually associated with high dosages, long periods of therapy, or both.

10705231 JANUARY 1977

For more complete details, consult package insert or Schering literature available from your Schering Representative or Professional Services Department, Schering Corporation, Kenilworth, New Jersey 07033.

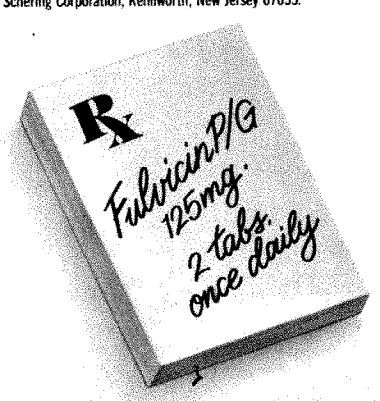

INDEX TO ADVERTISERS

A

Abbott Laboratories 1158-1159
Ayerst Laboratories 1168-1169

B

Barnes-Hind Pharmaceuticals 1165, 1279

C

Ciba Pharmaceuticals 1318-1319
Cooper Laboratories, Inc. 1309
Cryenco 1192

D

Dermik Laboratories 1155, 1286
Dista Products Company ..... 3rd Cover
Doak Pharmacal Company 1260

G

General Medical Company 1313

H

Herbert, G.S., Laboratories, Division of Allergan Pharmaceuticals 1171, 1258
Hoechst-Roussel Pharmaceuticals 1182-1184

J

Johnson & Johnson 1290-1291

L

Lederle Laboratories, Division of American Cyanamid Company 1163-1164, 1178-1180
Lenox Hill Hospital 1160

N

Neutrogena Corporation 1312-1313

O

Owen Laboratories, Inc. 1157

P

Parke-Davis & Company 1160, 1188-1189, 1316-1317
Pharmacia Diagnostics 1278
Procter & Gamble Company 1181
Purdue Frederick Company 1257

R

Reed & Carnrick 1284-1285
Roche Laboratories, Division of Hoffmann-LaRoche, Inc. 1190-1191
Roerig, J.B., Company Division of Pfizer, Inc. 1166-1167

S

Saunders, W.B., Company 1160
Schering Corporation 1177, 1276-1277, 1310-1311, 1320-1322
Squibb, E.R., & Sons, Inc. 1192-1193
Stiefel Laboratories, Inc. 1184-1186
Syntex Laboratories, Inc. 1304-1306, 1314-1315

W

Westwood Pharmaceuticals, Inc. ..... 2nd Cover, 1173-1176, 1194, 1283, 1292-1294, 4th Cover

While every precaution is taken to insure accuracy, we cannot guarantee against the possibility of an occasional change or omission in the preparation of this index.

Inflammatory manifestations of psoriasis and atopic dermatitis...

Effectiveness demonstrated in only 8 days*

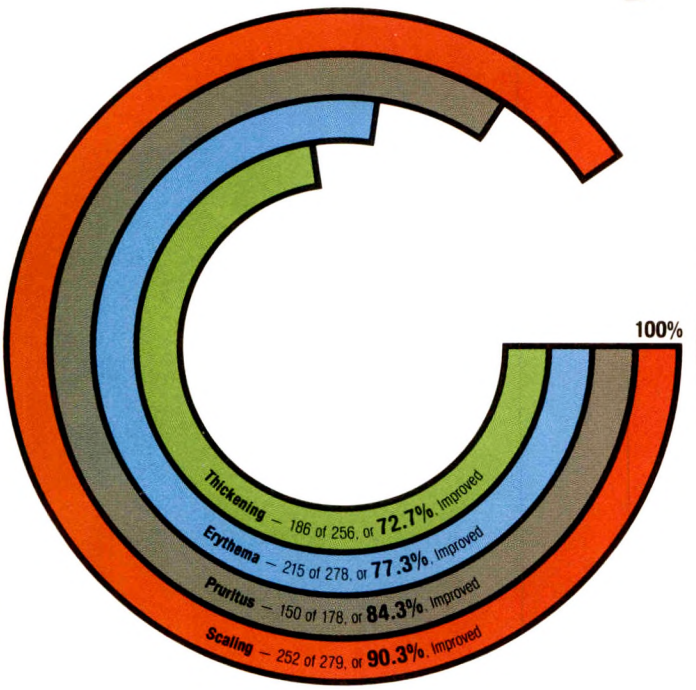

Psoriasis

In a study of 279 psoriatic patients

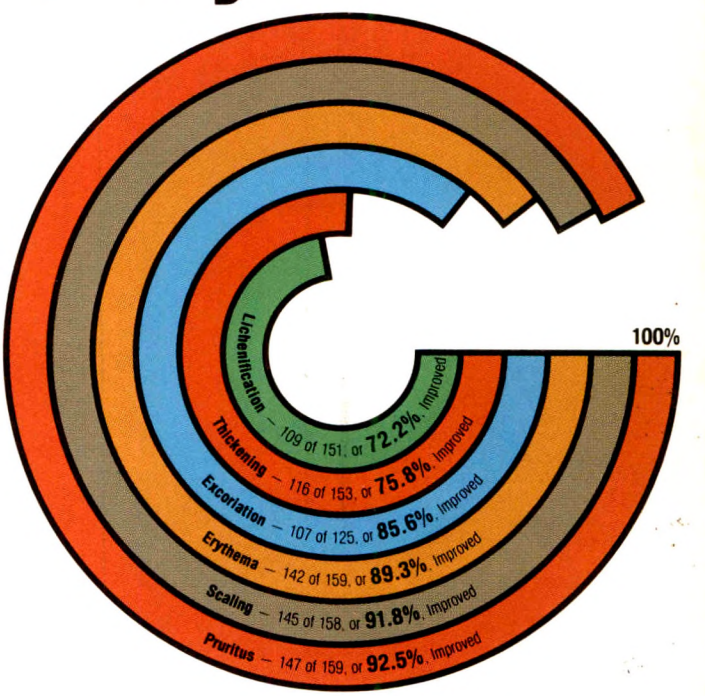

Atopic Dermatitis

In a study of 162 atopic dermatitis patients

Cordran® (Flurandrenolide)
Description: Cordran® (flurandrenolide, Dista) is a potent corticosteroid intended for topical use. **Actions:** Cordran is primarily effective because of its anti-inflammatory, antipruritic, and vasoconstrictive actions. **Indications:** For relief of the inflammatory manifestations of corticosteroid-responsive dermatoses. **Contraindications:** Topical corticosteroids are contraindicated in vaccinia and varicella and in patients with a history of hypersensitivity to any of their components. **Precautions:** If irritation develops, the product should be discontinued and appropriate therapy instituted. In the presence of an infection, an appropriate antifungal or antibacterial agent should be used. If a favorable response does not occur promptly, the corticosteroid should be discontinued until the infection has been adequately controlled. If extensive areas are treated or if the occlusive technique is used, there is a possibility of increased systemic absorption of the corticosteroid, and suitable precautions should be taken. Although topical corticosteroids have not been reported to have an adverse effect on pregnancy, the safety of their use on pregnant women has not been absolutely established. Therefore, they should not be used extensively, in large amounts, or for prolonged periods of time on pregnant patients. These products are not for ophthalmic use. **Adverse Reactions:** The following local adverse reactions have been reported with topical corticosteroid formulations: acneform eruptions, burning, dryness, folliculitis, hypertrichosis, hypopigmentation, irritation, itching. The following may occur more frequently with occlusive dressings: maceration of the skin, miliaria, secondary infection, skin atrophy, striae. **Administration and Dosage:** For moist lesions, a small quantity of the cream or lotion should be rubbed gently into the affected areas two or three times a day. For dry, scaly lesions, the ointment is applied as a thin film to affected areas two or three times daily. [111875]

Cream, Ointment, and Lotion Cordran®, 0.05%
flurandrenolide

Cream and Ointment Cordran, 0.025%

*Data on file at Dista Products Company.

DISTA
Dista Products Company
Division of Eli Lilly and Company
Indianapolis, Indiana 46206

700136
Additional information available to the profession on request.

Cream
Cordran®
Flurandrenolide

Efficacy is its strength

Desquam-X®

5 or 10% Benzoyl Peroxide 6% Polyoxyethylene Lauryl Ether

the topical side of C. acnes control

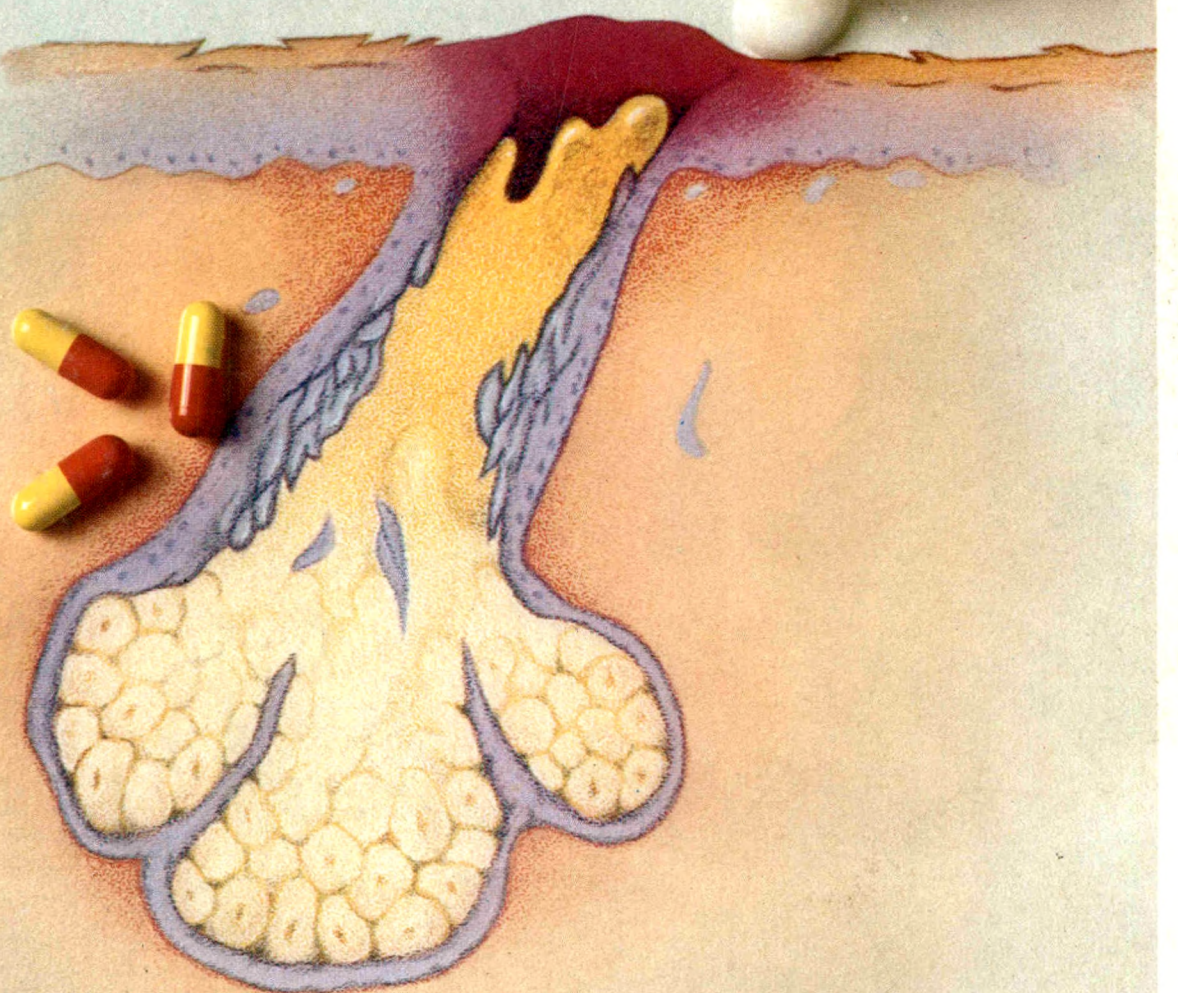

Desquam-X5®
Desquam-X10®

CONTENTS: Desquam-X 5 contains 5% Benzoyl Peroxide, 6% polyoxyethylene lauryl ether, 37% ethyl alcohol, carbomer 940, di-isopropanolamine, disodium edetate and water.

Desquam-X 10 contains 10% Benzoyl Peroxide, 6% polyoxyethylene lauryl ether, 37% ethyl alcohol, carbomer 940, di-isopropanolamine, disodium edetate and water.

INDICATION: A topical aid for the control of acne vulgaris.

ACTION: Provides the desirable drying and desquamation needed in the topical treatment of acne. Desquam-X has been demonstrated to have anti-bacterial effects, especially against Corynebacterium acnes.

DIRECTION FOR USE: After washing as instructed, rub Desquam-X into affected areas twice daily. In fair-skinned individuals or under excessively dry atmospheric conditions it is suggested that therapy be initiated with one application daily. The desired degree of drying and peeling can be obtained by modification of the dosage schedule.

CONTRAINDICATIONS: Not to be used in patients known to be sensitive to any ingredient of Desquam-X.

PRECAUTIONS: Avoid contact with eyes and mucous membranes. For external use only. Keep this and all medication out of the reach of children.

NOTE: May bleach colored fabrics.

HOW SUPPLIED: Plastic tubes 1.5 oz. (42.5 gm.)

CAUTION: Federal law prohibits dispensing without prescription.

WESTWOOD
PHARMACEUTICALS INC.
Buffalo, New York 14213
In Canada, Belleville, Ontario K8N1E2

©1975 W. P. Inc.

Published by the American Medical Association

November 1977
Volume 113, Number 11

archives of Dermatology

Vitiligo and Juvenile Diabetes Mellitus ..... *C. Macaron, R. J. Winter, H. S. Traisman, B. D. Kahan, A. E. Lasser, O. C. Green* **1515**

HLA-A10 in Pemphigus Among Japanese ..... *K. Hashimoto, Y. Miki, S. Nakata, M. Matsuyama* **1518**

Oral Pemphigus Vulgaris ..... *M. Meurer, J. L. Millns, R. S. Rogers III, R. E. Jordon* **1520**

Treatment of Psoriasis With Long-Wave Ultraviolet Light ..... *J. A. Parrish* **1525**

Photochemotherapy of Psoriasis Using Methoxsalen and Sunlight ..... *J. A. Parrish, H. A. D. White, T. Kingsbury, M. Zahar, T. B. Fitzpatrick* **1529**

Smokers' Melanosis ..... *C. A. Hedin* **1533**

Topically Applied Antifungal Agents ..... *S. M. Wallace, V. P. Shah, W. L. Epstein, J. Greenberg, S. Riegelman* **1539**

Cell Populations in Experimental Contact Dermatitis ..... *N. Hunziker, R. K. Winkelmann* **1543**

Topical Treatment of Herpes Labialis With Chloroform ..... *C. A. Taylor, J. O. Hendley, K. E. Greer, J. M. Gwaltney, Jr* **1550**

Erythropoietic Porphyria ..... *G. S. Stretcher* **1553**

Ulcers of the Leg in Thalassemia ..... *D. M. Stevens, J. L. Shupack, J. Javid, R. Silber* **1558**

DeSanctis-Cacchione Syndrome ..... *W. B. Reed, G. I. Sugarman, R. A. Mathis* **1561**

Acquired Periungual Fibrokeratoma ..... *R. L. Cahn* **1564**

Fatal Cytomegalic Inclusion Disease ..... *N. Minars, J. F. Silverman, M. R. Escobar, A. J. Martinez* **1569**

Halo Congenital Nevus ..... *M. H. Brownstein, B. B. Kazam, K. Hashimoto* **1572**

Atypical Multicentric Reticulohistiocytosis With Paraproteinemia ..... *J. R. S. Rendall, R. I. Vanhegan, A. H. T. Robb-Smith, R. E. Bowers, T. J. Ryan, H. R. Vickers* **1576**

Ulcerative Systematized Porokeratosis (Mibelli) ..... *E. M. A. Razack, M. Natarajan* **1583**

Recurrent Pyoderma Gangrenosum and Agnogenic Myeloid Metaplasia *J. P. Callen, H. V. Dubin, C. F. Gehrke* **1585**

Cobb Syndrome ..... *R. T. Jessen, S. Thompson, E. B. Smith* **1587**

Diffuse Eosinophilic Fasciitis ..... *V. M. Torres, W. M. George* **1591**

AMA AMERICAN MEDICAL ASSOCIATION

LIBRARY

Reservoir of moisture

Each bath with Alpha Keri® Therapeutic Bath Oil is a reservoir of moisture for dry skin. The addition of Alpha Keri in the bath helps skin store moisture for days. And feel soft, smooth, and supple in minutes. (Between baths, a single application of Keri® Lotion instantly restores moisture to dry skin for hours.)

Alpha Keri®

Therapeutic Bath Oil

helps skin keep in touch with moisture

See PDR for complete product information.

WESTWOOD PHARMACEUTICALS INC.
Buffalo, New York 14213

Prevent over-abrasion. Prescribe the natural cleansing control of Komex.

For patients with oily skin or acne, the natural cleansing control of Komex offers a gentle alternative to harsh abradants. Oil, sebum, make-up and surface debris are cleansed away gently by the unique Komex combination of surface active agents and naturally occurring water soluble cleansing particles. The more water your patients use the more gently Komex cleanses.

For thorough cleansing and conditioning without over-abrasion, prescribe the natural cleansing control of Komex.

Caution: Avoid contact with eyes.
Do not use on inflamed skin.

Barnes-Hind Pharmaceuticals, Inc.
895 Kifer Road
Sunnyvale, California 94086

Komex®

Archives of DERMATOLOGY

Copyright © 1977 by the AMERICAN MEDICAL ASSOCIATION

VOL 113, NO. 11 NOVEMBER 1977

ORIGINAL CONTRIBUTIONS

Vitiligo and Juvenile Diabetes Mellitus
Chamel Macaron, MD; Robert J. Winter, MD; Howard S. Traisman, MD; Barry D. Kahan, MD; Alan E. Lasser, MD; Orville C. Green, Chicago 1515

HLA-A10 in Pemphigus Among Japanese
Koji Hashimoto, MD, Osaka, Japan; Yoshiharu Miki, MD, Shigenobucho, Japan; Seizo Nakata, MD; Masamichi Matsuyama, MD, Osaka, Japan 1518

Oral Pemphigus Vulgaris
Michael Meurer, MD; John L. Millns, MD; Roy S. Rogers III, MD; Robert E. Jordon, MD, Rochester, Minn 1520

Treatment of Psoriasis With Long-Wave Ultraviolet Light
John A. Parrish, MD, Boston 1525

Photochemotherapy of Psoriasis Using Methoxsalen and Sunlight
John A. Parrish, MD, Boston; H. Anthony D. White, MB, BS, FRACP, Sydney, Australia; Timothy Kingsbury, Boston; Mahmoud Zahar, MD, Taif, Saudi Arabia; Thomas B. Fitzpatrick, MD, Boston 1529

Smokers' Melanosis
C. Anders Hedin, DDS, Centrallasarettet Eskilstuna, Sweden 1533

Topically Applied Antifungal Agents
Sylvia M. Wallace, PhD; Vinod P. Shah, PhD; William L. Epstein, MD; Joseph Greenberg, MD; Sidney Riegelman, PhD, San Francisco 1539

Cell Populations in Experimental Contact Dermatitis
Nicole Hunziker, MD, Richard K. Winkelmann, MD, PhD, Rochester, Minn 1543

Topical Treatment of Herpes Labialis With Chloroform
Cynthia A. Taylor, MD; J. Owen Hendley, MD; Kenneth E. Greer, MD; Jack M. Gwaltney, Jr, MD, Charlottesville, Va 1550

CASE REPORTS

Erythropoietic Porphyria
George S. Stretcher, MD, Augusta, Ga 1553

Ulcers of the Leg in Thalassemia
Dwight M. Stevens, MD; Jerome L. Shupack, MD; Jamshid Javid, MD; Robert Silber, MD, New York 1558

DeSanctis-Cacchione Syndrome
William B. Reed, MD, Irvine, Calif; Gerald I. Sugarman, MD, Los Angeles; Reed A. Mathis, Madison, Wis 1561

Acquired Periungual Fibrokeratoma
Ronald L. Cahn, MD, Stanford, Calif 1564

Fatal Cytomegalic Inclusion Disease
Norman Minars, MD; Jan F. Silverman, MD; Mario R. Escobar, PhD; A. Julio Martinez, MD, Richmond, Va 1569

Halo Congenital Nevus
Martin H. Brownstein, MD; Bonnie B. Kazam, MD, New York; Ken Hashimoto, MD, Memphis 1572

Atypical Multicentric Reticulohistiocytosis With Paraproteinemia
Jonathan R. S. Rendall, MRCP; Robert I. Vanhegan, BM, DPhil; Alastair H. T. Robb-Smith, MD, FRCP, Oxford, England; Robert E. Bowers, MD, FRCP, Gloucester, England; Terence J. Ryan, FRCP; Henry R. Vickers, MD, FRCP, Oxford, England 1576

(Continued on page 1484)

EDITORIAL BOARD

Chief Editor
John H. Epstein, MD
450 Sutter Street
San Francisco 94108

Assistant Chief Editor
Kimie Fukuyama, MD
San Francisco

Assistant Chief Editor
Denny L. Tuffanelli, MD
San Francisco

Donald C. Abele, MD
Augusta, Ga.

Harry L. Arnold, Jr, MD
Honolulu

Walter C. Lobitz, Jr, MD
Portland, Ore

Frederick D. Malkinson, MD
Chicago

Sigfrid A. Muller, MD
Rochester, Minn

W. Mitchell Sams, Jr, MD
Chapel Hill, NC

John S. Strauss, MD
Boston

Morris Waisman, MD
Tampa, Fla

Gerald D. Weinstein, MD
Miami

Give rough, dry skin the soft touch.

Nutraplus® restores softness to excessively rough, dry skin through enhanced absorption and moisture retention.

Nutraplus® cream or lotion with 10% urea ... stable, efficacious, economical, patient-preferred.

Owen
Owen Laboratories, Dallas, Texas 75234
Division of Alcon Laboratories, Inc.

Printed in U.S.A. ©1977

CONTENTS—Continued

Ulcerative Systematized Porokeratosis (Mibelli)
Enn M. Abdul Razack, MD, DD, Marthandam Natarajan, MD, ZDV, FDS, Madras, India 1583

Recurrent Pyoderma Gangrenosum and Agnogenic Myeloid Metaplasia
Jeffrey P. Callen, MD; Howard V. Dubin, MD; Charles F. Gehrke, MD, Ann Arbor, Mich 1585

Cobb Syndrome
R. Thomas Jessen, MD; Stephen Thompson, MD; Edgar B. Smith, MD, Albuquerque, NM 1587

Diffuse Eosinophilic Fasciitis
Victor M. Torres, MD, William M. George, MD, Miami 1591

REGULAR DEPARTMENTS

Short Reports 1598

Benign Mucous Membrane Pemphigoid Harold J. Brody, MD, Donald J. Pirozzi, MD, Atlanta . . . ***Serratia marcescens* Cellulitis** Dean E. Brenner, MD, Donald P. Lookingbill, MD, Hershey, Pa . . . **Tinea Capitis Due to *Trichophyton soudanense*** Donald R. Cox, MD, Fritz Blank, DSc Nat, Philadelphia

Books 1604

News and Notes 1605

Letters to the Editor 1610

Percutaneous Penetration Following Use of Hair Dyes Robert S. Yare, PhD; Mario Garcia, PhD, Stamford, Conn; Howard I. Maibach, MD, San Francisco; M. A. Leaffer, MS; W. A. Skinner, PhD, Menlo Park, Calif . . . **Rifampin in Leishmaniasis** F. Rolando Vásquez, MD, Guatemala City . . . **Photosensitivity Owing to Thiourea** J. C. Van der Leun, PhD; E. J. de Kreek, MD; M. Deenstra-van Leeuwen, MD, H. van Weelden, MSc, Utrecht, The Netherlands . . . **Transient Acantholytic Dermatosis** Reed R. Lockwood, MD; Peter M. Elias, MD, San Francisco; Margaret Waisman, MD, Houston . . . **Ocular Involvement in Pyoderma Gangrenosum** Rudolf Happle, MD; Hans-Peter Schiffer, MD; Peter M. Kövary, MD, Münster, West Germany . . . **Macular Anetoderma in an Appendectomy Site** André Dupré, MD, Toulouse, France . . . **Toxic Epidermal Necrolysis in Patients Who Are Allergic to Penicillin** Jata S. Ghosh, MS, Ardmore, Pa . . . **Vertical Striated Sandpaper Nails** Robert Baran, MD, Cannes, France, André Dupré, MD, Toulouse, France . . . **Paraneoplastic Acrokeratosis of Bazex** Robert Baran, MD, Cannes, France . . . **Bullous Erythema Multiforme** Howard S. Yaffee, MD, Cambridge, Mass . . . **Chronic Bullous Dermatosis of Childhood** David A. Voron, MD; Arcadia, Calif; Nancy B. Esterly, MD; Nancy L. Furey, MD, Chicago . . . **Nail Polish Remover Sensitization** Lawrence M. Field, MD, San Luis Obispo, Calif . . . **Contaminated Fungal Cultures Owing to *Tyrophagus putrescentiae*** Robert B. Amon, MD; Jon M. Hanifin, MD; Mary C. Campbell, Portland, Ore . . . **Clarification of Lichen Planus Actinicus** Sylvia Martin, MD, Vancouver, British Columbia; Mouta Dilaimy, MD, Baltimore . . . **An Unusual Variant of Darier's Disease: A Therapeutic Suggestion** Samuel Ayres, Jr, MD, Richard Mihan, MD, Los Angeles . . . **Griseofulvin Therapy in Molluscum Contagiosum** Om P. Singh, MD, DVD, Amrinder J. Kanwar, MD, New Delhi . . . **Treatment of Atopic Dermatitis With the Scholtz Regimen** Samuel Ayres, Jr, MD, Richard Mihan, MD, Los Angeles . . . **Dapsone-Induced Hepatic Changes** Lt Col D. Klaus Goette, MD, USA, Presidio of San Francisco, Calif . . . **Lymphomatoid Papulosis** Warren L. Macaulay, MD, Fargo, ND, Kristian Thomsen, MD, Copenhagen

Society Transactions 1622

Index to Advertisers 1634

Instructions for Authors 1490

SUBSCRIPTION RATES: The yearly rate of the ARCHIVES OF DERMATOLOGY is as follows: United States and US Possessions, one year, $18; two years, $28; all other countries, one year, $28; two years, $38. Special yearly price to residents, interns and medical students in the United States and US Possessions, $9.

THE ARCHIVES OF DERMATOLOGY is published monthly by the American Medical Association, 535 N Dearborn St, Chicago, IL 60610, and is an official publication of the Association. Second-class postage paid at Chicago and at additional mailing office.

SYNALAR®
(fluocinolone acetonide)
CREAM 0.025%
CREAM 0.01%
OINTMENT 0.025%
SOLUTION 0.01%

Description Synalar (fluocinolone acetonide) has the chemical name 6α, 9α-difluoro-16α-hydroxyprednisolone-16, 17-acetonide.

The cream contains fluocinolone acetonide 0.25 mg./g. or 0.1 mg./g. in a water-washable aqueous base of stearic acid, propylene glycol, sorbitan monostearate and monooleate, polysorbate 60, purified water and citric acid with methylparaben and propylparaben as preservatives.

The ointment contains fluocinolone acetonide 0.25 mg./g. in a white petrolatum U.S.P. vehicle.

The solution contains fluocinolone acetonide 0.1 mg./g. in a water-washable base of propylene glycol with citric acid.

Indications For relief of the inflammatory manifestations of corticosteroid-responsive dermatoses.

Contraindications Topical steroids are contraindicated in vaccinia and varicella.

Topical steroids are contraindicated in those patients with a history of hypersensitivity to any of the components of the preparation.

Precautions If irritation develops, the product should be discontinued and appropriate therapy instituted.

In the presence of an infection the use of an appropriate antifungal or antibacterial agent should be instituted. If a favorable response does not occur promptly, the corticosteroid should be discontinued until the infection has been adequately controlled.

If extensive areas are treated or if the occlusive technique is used, the possibility exists of increased systemic absorption of the corticosteroid and suitable precautions should be taken.

Although topical steroids have not been reported to have an adverse effect on pregnancy, the safety of their use in pregnant females has not absolutely been established. Therefore, they should not be used extensively on pregnant patients, in large amounts, or for prolonged periods of time.

Synalar products are not for ophthalmic use.

Adverse reactions The following local adverse reactions have been reported with topical corticosteroids: burning, itching, irritation, dryness, folliculitis, hypertrichosis, acneform eruptions, hypopigmentation.

The following may occur more frequently with occlusive dressings than without such therapy: maceration of the skin, secondary infection, skin atrophy, striae, miliaria.

How Supplied
Synalar (fluocinolone acetonide)
Cream 0.025% — 15 and 60g. tubes and 120 and 425g. jars.
Cream 0.01% — 15, 45 and 60g. tubes and 120 and 425g. jars.
Ointment 0.025% — 15 and 60g. tubes and 425g. jars.
Solution 0.01% — 20cc. and 60cc. plastic squeeze bottles.

Also Available
Synalar-HP® (fluocinolone acetonide) Cream 0.2% 5g. and 12g. tubes.

SYNTEX
SYNTEX LABORATORIES, INC.
PALO ALTO, CALIFORNIA 94304


AS USEFUL TODAY AS THE
DAY IT WAS INTRODUCED
SYNALAR
(FLUOCINOLONE
ACETONIDE)
See preceding page for summary
of prescribing information.
SYNTEX

Archives of Dermatology

James H. Sammons, MD
Executive Vice-President

Thomas F. Hannon
Group Vice-President,
Publishing Operations

William R. Barclay, MD
Group Vice-President,
Scientific Publications

Norman D. Richey
Director, Publication
Production Division

John T. Baker
Director, Marketing Division

Helen R. Mazur
Acting Fulfillment Manager

John T. Baker, General Sales Manager; **Robert Corcoran,** Eastern Sales Manager; **Fred Bauman, Richard M. Johnson,** Eastern Sales Representatives; **William J. Healy,** Midwest Sales Representative; **Thomas J. Carroll,** West Coast/Northern Sales Representative

PUBLICATION STAFF

Offices: 535 N Dearborn St
Chicago, IL 60610

Robert W. Mayo
Executive Editor and Director,
Scientific Publications Division

Sandra Williamson
Administrative Assistant

Marlene M. Hinsch, Production Manager

Editorial Processing Manager: Diana A. Morgan

Copy Editing: Rosanne Schulenberg (Supervisor), Paula Glitman, Patti Narret, Kathy Swartz

Proofreading: Lorraine L. Kruse (Supervisor), Patricia Coyne, Helen Grzeskiewicz, Elizabeth Petrikenas, Dorothy Troy

Production Supervisors: Julia Bero (Layout), Thomas J. Handrigan (Illustrations), Marlene M. Hinsch (Editorial), James P. Bagniewski (Advertising)

Art and Senior Production Assistants: Betty Frigerio, Linda Gilbert, Floriana Hayes, Shirley Latronica, Deborah Orent, Donna Pender, Nancy Keyes, Susan Routhier, JoAnne Weiskopf

Production Assistants: Karen Branham, E. Linda Eisenberg, Anna Goins, Dannie Kendrick, Lucille Kuznicki

Manuscript Records: Mary Paino

Indexing: Phyllis H. McLaren (Supervisor), Jane P. Mauldin, Helen F. Topel

Please address communications concerning accepted or published communications to: AMA Specialty Journals, 535 N Dearborn St, Chicago, IL 60610.

Conditions for Acceptance of Color Illustrations

Illustrations in full color are accepted for publication in ARCHIVES OF DERMATOLOGY if the editor believes that color will add significantly to the published manuscript.

When color illustrations are accepted, the American Medical Association will pay part of the expense of reproduction and printing, the remainder to be borne by the author or the institution with which he is affiliated. After deducting AMA's contribution, the author's share is $275 for up to six square finished illustrations. Additional illustrations and special effects, such as outlining, opaquing, or surprinting, will be billed to the author at cost.

Color transparencies must be submitted for evaluation. Do not send color prints unless accompanied by original transparencies. If transparencies are mounted in frames or glass, the material should be carefully packed in gauze and sent with the manuscript in a separate container or between two pieces of pressboard.

Advertising and Subscription Information

ADVERTISING OFFICES: 535 N Dearborn St, Chicago, IL 60610, Area Code 312, 751-6000; and 600 Third Ave, New York, NY 10016, Area Code 212-867-6640.

ADVERTISING PRINCIPLES: Each advertisement in this issue has been reviewed and complies with the principles governing advertising in AMA scientific publications. A copy of these principles is available on request.

CHANGE OF ADDRESS: Please notify the publisher at least six weeks in advance, including both old and new address, and a mailing label taken from the most recent copy. Include your new zip code number.

Dome

NOW... the only stable nystatin lotion available.

New Candex® (nystatin) Lotion

- ☐ for a dermatologic need
- ☐ for control of candidal infections
- ☐ for cosmetic elegance

New CANDEX Lotion offers excellent penetration around fingernails, into hairy areas and into infected tissue. It soothes inflammation and chafed or macerated skin. And it is paraben-free for the patient with that special sensitivity.

Also Available: CANDEX Creme (nystatin)

Indications: Candex (nystatin) Lotion and Creme are indicated for the treatment of cutaneous or mucocutaneous mycotic infections caused by Candida species (Monilia). A lotion is preferred on oozing intertriginous areas. **Contraindications:** Lesions caused by pathogens not susceptible to nystatin, and hypersensitivity to any of the components. **Precautions:** If irritation or sensitivity occurs and/or infection persists, discontinue use. If new infections appear, appropriate therapy should be instituted. **Caution:** Federal (USA) law prohibits dispensing without prescription. For external use only. Not for ophthalmic use. Store Candex (nystatin) Lotion below 86 F (30 C); avoid freezing; shake well. **Dosage and Administration:** Apply two or three times daily. Continue use for one week after clinical cure. **How Supplied:** Candex (nystatin) Lotion in 30 ml plastic bottles; Candex (nystatin) Creme in 15 g tubes.

Dome Laboratories

Division Miles Laboratories Inc
West Haven Connecticut 06516 U

© 1977 DOME LABORATORIES, DIVISION MILES LABORATORIES, INC. ALL RIGHTS RESERVED.

2/6/70—Before treatment a 3.0 cm lesion was present behind left ear. Biopsy revealed it to be a superficial basal cell carcinoma. Treatment with Efudex (fluorouracil) 5% Cream was begun.

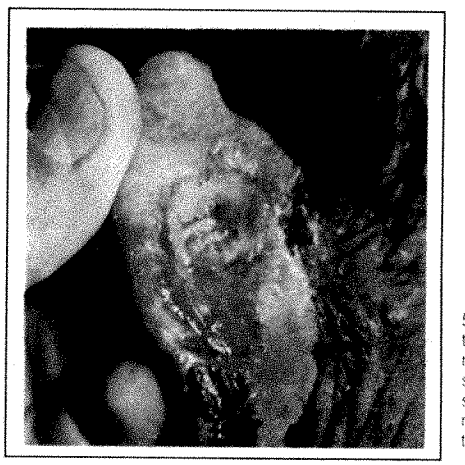

5/1/70—After 11 weeks' therapy, lesion site was necrotic and escharified; surrounding skin showed minimal inflammation. Treatment was terminated 4/24/70.

9/10/70—Area completely healed; posttreatment biopsy revealed no further carcinoma.

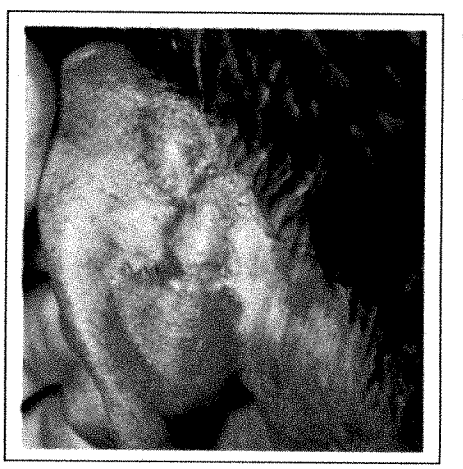

6/15/72—Patient 25 months posttreatment. No evidence of recurrence.

Management of superficial basal cell carcinoma is often complicated by multiple lesions which extend over large areas of the body. Until now, primary treatment has been surgery or radiation therapy. However, these modalities may be followed by scarring and disfigurement.

Topical chemotherapy with Efudex (fluorouracil) 5% is a valuable alternative when conventional methods are impractical. For example, it is an effective agent for the concurrent treatment of superficial lesions over large areas of the body, or for use on difficult treatment sites.

Although during treatment with Efudex the lesion and some of the surrounding skin may become inflamed and blistered temporarily, final results are cosmetically gratifying, with minimal or no scarring.

Efudex 5% Cream offers the dermatologist:

- An effective topical alternative to surgery for multiple lesions and difficult treatment sites.
- Cosmetically gratifying results, with minimal or no scarring. No systemic toxicity.
- Convenient, economical b.i.d. application. Apply with care near eyes, nose and mouth; wash hands immediately afterward if applied with fingers.

Efudex® 5% Cream
fluorouracil/Roche

An exclusive Roche formulation
Also available as 5% Efudex Solution

Before prescribing, please consult complete product information, a summary of which follows:

Indications: Multiple actinic or solar keratoses. In 5% strength, superficial basal cell carcinoma when conventional methods are impractical, such as with multiple lesions or difficult treatment sites. Establish diagnosis before treating, as this method has not been proven effective in other types of basal cell carcinomas. Conventional techniques preferred for isolated, easily accessible lesions, as success rate is nearly 100%. Success rate with Efudex is about 93%.

Contraindications: Patients with known hypersensitivity to any of its components.

Warnings: If occlusive dressing is used, may increase inflammatory reactions in adjacent normal skin. Avoid prolonged exposure to ultraviolet rays. Safe use in pregnancy not established.

Precautions: If applied with fingers, wash hands immediately. Apply with care near eyes, nose and mouth. Solar keratoses failing to respond should be biopsied. Warn patients that treated area may be unsightly during therapy and sometimes for several weeks after. Perform follow-up biopsies in superficial basal cell carcinoma.

Adverse Reactions: Local—pain, pruritus, hyperpigmentation and burning at application site most frequent; also dermatitis, scarring, soreness, tenderness, suppuration, scaling and swelling. Also reported—insomnia, stomatitis, irritability, medicinal taste, photosensitivity, lacrimation, telangiectasia, leukocytosis, thrombocytopenia, toxic granulation and eosinophilia.

Dosage and Administration: When Efudex is applied erythema occurs, then vesiculation, erosion, ulceration, necrosis, epithelization. *Actinic or solar keratosis*—apply sufficient quantity to cover lesions, twice daily. Usual length of therapy is 2 to 4 weeks. *Superficial basal cell carcinomas*—apply sufficient quantity **(only 5% strength recommended)** to cover lesions, twice daily. Continue treatment for at least 3 to 6 weeks, but possibly as long as 10 to 12.

How Supplied: Solution, 10-ml drop dispensers containing 2% or 5% fluorouracil on a weight/weight basis. Cream, 25-Gm tubes containing 5% fluorouracil in a vanishing cream base.

ROCHE

Roche Laboratories
Division of Hoffmann-La Roche Inc.
Nutley, New Jersey 07110

Instructions for Authors

Send manuscripts by first-class mail to the Chief Editor, John H. Epstein, MD, 450 Sutter St, San Francisco, CA 94108. Manuscripts are received with the understanding that they are not under simultaneous consideration by another publication. Accepted manuscripts become the permanent property of the ARCHIVES and may not be published elsewhere without permission from the publisher (AMA).

In addition, in view of *The Copyright Revision Act of 1976*, generally effective Jan 1, 1978, all transmittal letters to the editor must contain the following language before manuscripts can be reviewed for possible publication: "In consideration of AMA's taking action in reviewing and editing my (our) submission, the author(s) undersigned hereby transfers, assigns, or otherwise conveys all copyright ownership to the AMA in the event that such work is published by the AMA." We regret that transmittal letters not containing the foregoing language signed by all authors of the manuscript will necessitate return of your manuscript.

Author Responsibility.—All accepted manuscripts are subject to copy editing. The author will receive an edited typescript rather than galley proofs for approval. The author is responsible for all statements in his work, including changes made by the copy editor.

Designate one author as correspondent and provide his address and telephone number. Order reprints at the time the typescript is returned after editorial processing. Specify address to which requests for reprints should be sent.

Manuscript Preparation.—Submit an original typescript and two high-quality copies of the entire manuscript. All copy (including references, legends, and tables) must be typed double-spaced on 22 × 28-cm (8½ × 11-inch), heavy-duty white bond paper. Ample margins should be provided.

Refer to patients by number (or, in anecdotal reports, by fictitious given names). Real names or initials should not be used in the text, tables, or illustrations.

Titles.—Titles should be short, specific, and clear. They should not exceed 42 characters per line, including punctuation and spaces, and be limited to two lines, if possible. The title page should include the full names and academic affiliations of all authors, the address to which requests for reprints should be sent, and, if the manuscript was presented at a meeting, the name of the organization, place, and date on which it was read.

Style of Writing.—The style of writing should conform to acceptable English usage and syntax. Slang, medical jargon, obscure abbreviations, and abbreviated phrasing are to be avoided.

Informed Consent.—Manuscripts reporting the results of experimental investigations of human subjects must include a statement to the effect that informed consent was obtained after the nature of the procedure(s) had been fully explained.

Abstract.—Provide an abstract (135-word maximum) of the article, including statements of the problem, method of study, results, and conclusions. The abstract replaces the summary.

References.—List references in consecutive numerical order (not alphabetically). Once a reference is cited, all subsequent citations should be to the original number. All references must be cited in the text or tables. Unpublished data and personal communications should not be listed as references. References to journal articles should include (1) author(s), (2) title, (3) journal name (as abbreviated in *Index Medicus*), (4) volume number, (5) inclusive page numbers, and (6) year, in that order. References to books should include (1) author(s), (2) chapter title (if any), (3) editor (if any), (4) title of book, (5) city of publication, (6) publisher, and (7) year. Volume and edition numbers, specific pages, and name of translator should be included when appropriate. The author is responsible for the accuracy and completeness of the references and for their correct text citation.

Metrication.—All measurements must be in metric units. English units may also be given parenthetically if the measurements were originally done in English units.

Illustrations.—Use only those illustrations that clarify and augment the text. Submit illustrations in duplicate, *unmounted* and untrimmed. Do not send original artwork. Send high-contrast glossy prints (not photocopies). Figure number, name of senior author, and arrow indicating "top" should be typed on a gummed label and affixed to the back of each illustration. All lettering must be legible after reduction to column size. Artwork submitted for publication may be relettered to achieve uniformity of lettering style throughout the journal. Magnification and stain should be provided when pertinent. Illustrations should preferably be in a proportion of 12.5 × 18 cm (5 × 7 inches).

An experienced medical illustrator should be employed whenever possible for the preparation of all artwork. Template lettering or preset type is preferred to hand-lettered labels. If halftone artwork with labels is submitted, affix type and leaders to a clear acetate overlay registered to the base drawing. Labels and leaders should be applied directly to the drawing board surface if the artwork consists only of line ink technique.

Illustrations in full color are accepted for publication if the editors believe that color will add significantly to the published manuscript. The ARCHIVES will pay part of the expense of reproduction and printing color illustrations, the remainder to be borne by the author or his sponsor. After deducting the ARCHIVES contribution, the author's share is $275.00 for up to six square-finished illustrations that can be arranged on a one-page layout. Any additional illustrations or special effects will be billed to the author at cost. Positive color transparencies (35 mm preferred) must be submitted for an evaluation. Do not send color prints unless accompanied by original transparencies. All transparencies should be carefully packed and sent with the manuscript.

Legends.—Legends should be typed double-spaced, beginning on a separate sheet of paper. Length should be limited to a maximum of 40 words.

Photographic Consents.—A letter of consent must accompany all photographs of patients in which a possibility of identification exists. It is not sufficient to cover the eyes to mask identity.

Acknowledgments.—Illustrations from other publications must be acknowledged. Include the following when applicable: author(s), title of article, title of journal or book, volume number, page(s), month, and year. The publisher's permission to reprint should be submitted to the ARCHIVES after the manuscript has been formally accepted.

Statistical Review.—Manuscripts containing statistical evaluations should include the name and affiliation of the statistical reviewer.

Tables.—Each table should be typed double-spaced, including all headings, on a separate sheet of 22 × 28-cm (8½ × 11-inch) paper. Do not use larger size paper. If a table must be continued, use a second sheet and repeat all heads and stubs. Each table must have a title.

IN SKIN INFECTIONS, WHERE CLEANLINESS REQUI MORE THAN SOAP

BETADINE® Skin Cleanser

Degerms as it cleanses

'atients can use BETADINE Skin Cleanser to degerm and cleanse face, hands and body, gently an' 'articularly when it is essential to prevent autoinoculation of new sites, as may be the case in infecte

BETADINE Skin Cleanser, with its rich, golden lather, provides these advantages:

- Prompt, broad-spectrum microbicidal action—kills both gram-positive and gram-negative bacteria (including antibiotic-resistant strains), fungi, viruses, protozoa and yeasts.
- Maintains microbicidal activity in the presence of blood, pus and serum.
- Virtually nonirritating to skin and muc
- Nonstaining to skin and natural fabric

Supplied: 4 fl. oz. plastic bottles.

*In the rare instance of local irritation or sensitivity, by the individual.

Purdue Frederick © COPYRIGHT 1976, THE PURI

NORWALK, CONN. 06856



Superior to the most widely used brand of topical steroid in psoriasis and atopic dermatitis.

Based on the evidence.

In double-blind, parallel studies,* Topicort® (desoximetasone) Emollient Cream 0.25% demonstrated greater efficacy than betamethasone valerate cream 0.1% in the two most common corticosteroid-responsive dermatoses.

		NO. OF PATIENTS	Overall Evaluation: EXCELLENT & GOOD	Overall Evaluation: EXCELLENT (CLEARANCE OF DISEASE)
ATOPIC DERMATITIS	TOPICORT	39	100%	77%
	BETAMETHASONE VALERATE	41	90%	54%
PSORIASIS	TOPICORT	61	84%	43%
	BETAMETHASONE VALERATE	56	63%	21%

These recently conducted U.S. studies confirm the outstanding worldwide acceptance of Topicort in more than 30 countries for up to 4 years.

*Data on file and available upon request from Hoechst-Roussel Pharmaceuticals Inc.,

Less than 1% incidence of side effects.
Of 488 patients in the clinical trials, side effects were seen in only 4 (0.8%).* And in 2 of the 4 patients, the relationship of side effects to the drug was uncertain.

The convenience of b.i.d. dosage. And the uniqueness of a preservative-free, emollient cream base.
The specially developed, preservative-free Topicort base combines the emollience of an ointment with the cosmetic acceptability of a cream in a water-in-oil emulsion. This makes Topicort (desoximetasone) especially useful in psoriatic and

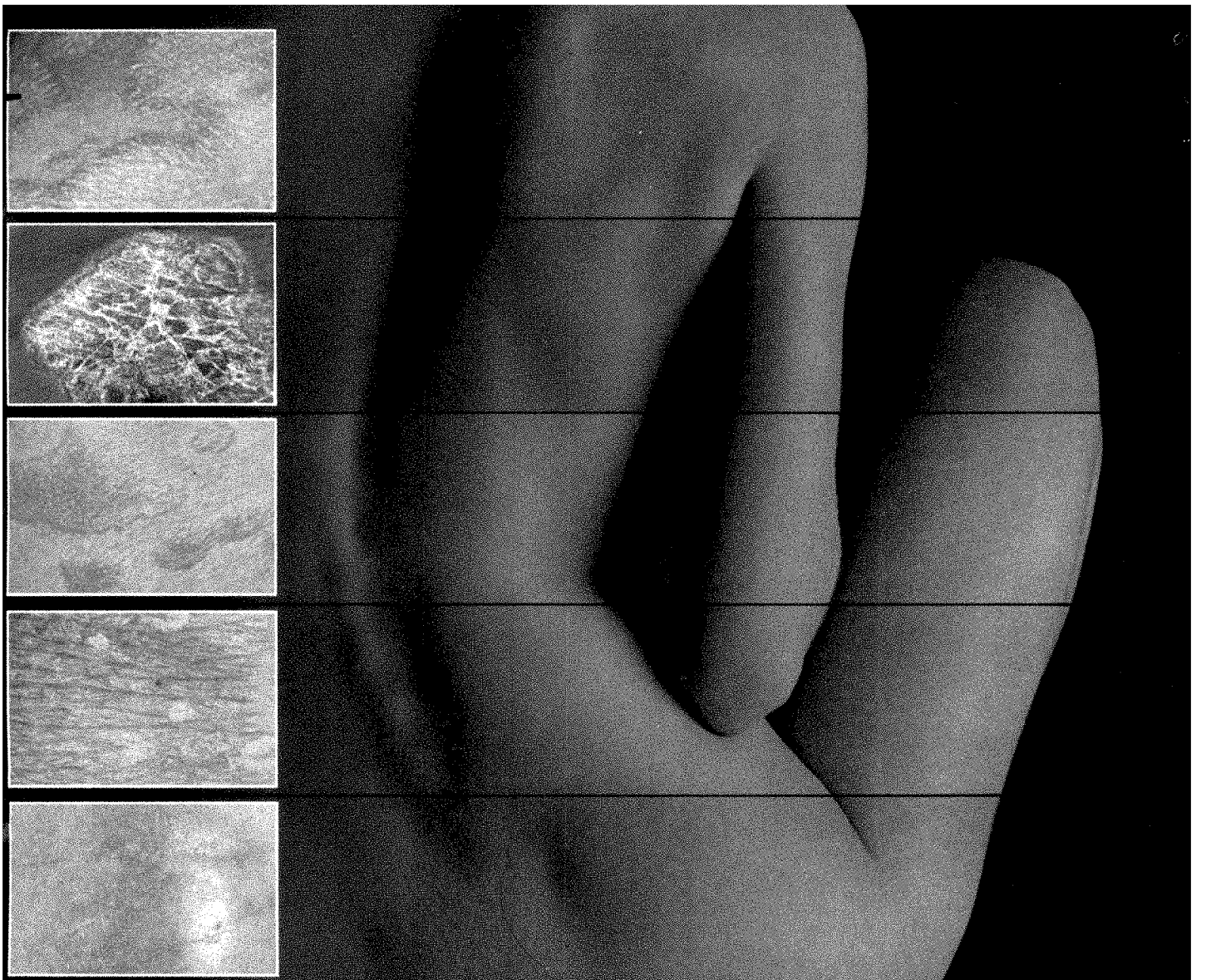

TOPICORT®
(DESOXIMETASONE)
EMOLLIENT CREAM 0.25%

An important innovation from the research laboratories of
Hoechst-Roussel Pharmaceuticals Inc.

TOPICORT® (desoximetasone) EMOLLIENT CREAM 0.25%

Description: Topicort® (desoximetasone) Emollient Cream 0.25% contains the active synthetic corticosteroid desoximetasone. The chemical name of desoximetasone is 9α - fluoro - 11β, 21 - dihydroxy - 16α - methylpregna - 1,4 - diene-3,20-dione. The chemical structure is:

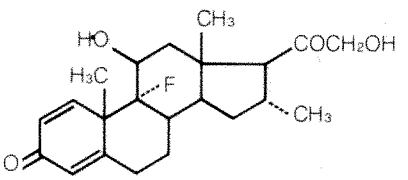

Each gram of Topicort® (desoximetasone) Emollient Cream 0.25% contains 2.5 mg desoximetasone in an emollient cream consisting of isopropyl myristate, cetylstearyl alcohol, white petrolatum, mineral oil, lanolin alcohol and purified water.

Actions: Topicort® (desoximetasone) Emollient Cream is primarily effective because of its anti-inflammatory, antipruritic and vasoconstrictive actions.

Indications: Topicort® (desoximetasone) Emollient Cream is indicated for the relief of inflammatory manifestations of corticosteroid-responsive dermatoses.

Contraindications: Topical steroids are contraindicated in vaccinia, varicella and in those patients with a history of hypersensitivity to any of the components of the preparation. This preparation is not for ophthalmic use.

Precautions: If local infection exists, suitable concomitant antimicrobial or antifungal therapy should be administered. If a favorable response does not occur promptly, application of the corticosteroid should be discontinued until the infection is adequately controlled.

Although systemic side effects associated with absorption of topical corticosteroid preparations are rare, their possible occurrence must be kept in mind when these preparations are used over large areas or for an extended period of time, or if occlusive technique is used.

If irritation or sensitization develops, the preparation should be discontinued and appropriate therapy instituted.

Although topical steroids have not been reported to have an adverse effect on pregnancy, the safety of their use during pregnancy has not been absolutely established; therefore, they should not be used extensively on pregnant patients, in large amounts, or for prolonged periods of time.

Adverse Reactions: The following local adverse reactions have been reported with topical corticosteroids: burning, itching, irritation, striae, skin atrophy, secondary infection, dryness, folliculitis, hypertrichosis, acneform eruptions and hypopigmentation. The following may occur more frequently with occlusive dressings: maceration of the skin, secondary infection, skin atrophy, striae, and miliaria.

Dosage and Administration: Apply a thin film of Topicort® (desoximetasone) Emollient Cream 0.25% to the affected skin areas twice daily. Rub in gently.

How Supplied: Topicort® (desoximetasone) Emollient Cream 0.25% is supplied in 15-gram tubes.

HOECHST-ROUSSEL

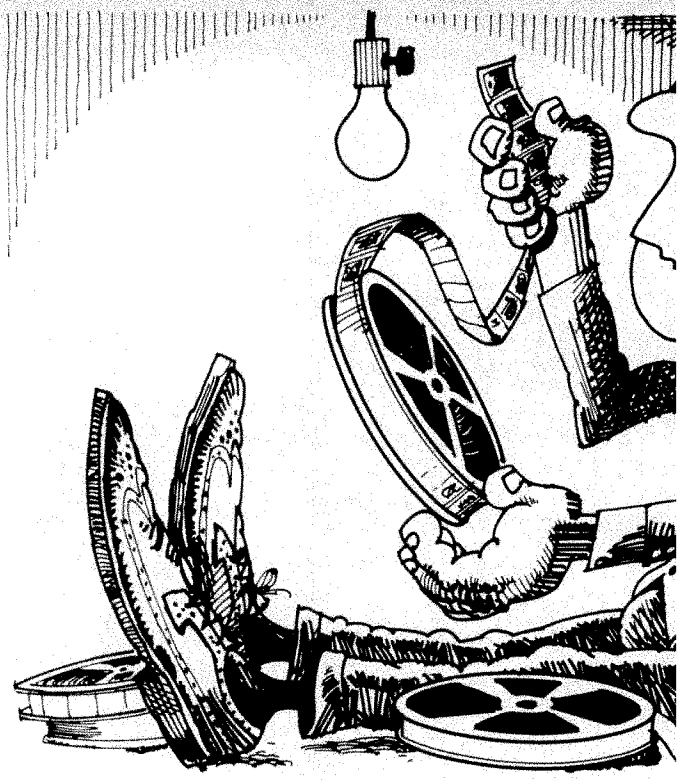

a quick reference to the AMA's large colle of medical films

and its yours free with the coupon belo

You'll find nearly 100 pages of medical motion picture titles and descriptions in this new catalog—well over 300 titles and many of them brand new! All are available on loan basis fo charge.



American Medical Asso
535 N. Dearborn St.
Chicago, Ill. 60610
ATTN: Dept. of Audio
Self Learning Programs

Please send me your c
AMA Medical Health Fi
1976

Name _____

Title _____

Organization _____

Address _____

City _____

The Corneocyte Count Down.

A high corneocyte count means scaling, flaking and an itchy scalp. Unsightly and unwanted by your dandruff patients.

Chances are they have tried the TV-promoted brands before consulting you about their problem.

Prescribe Exsel® (selenium sulfide) 2.5%. Clinically proven the most potent dandruff shampoo available. It gets rid of the unwanted corneocyte scales and retards their redevelopment for days.*

And Exsel offers one distinct advantage over other Rx anti-dandruff preparations: cosmetic elegance. Pleasing, fragrant lime-scented Exsel shampoo lathers richly, therefore assuring greater patient acceptability and better compliance with your instructions.



Exsel® (selenium sulfide) 2.5% Lotion- CONTAINS: selenium sulfide...2.5% with: edetate disodium; bentonite; sodium linear alkylate sulfonate; alphaolefin sulfonate; glyceryl monoricinoleate; silicone; titanium dioxide; citric acid monohydrate; sodium phosphate monobasic, monohydrate; perfume and purified water. ACTIONS: The mechanism of action of selenium sulfide in seborrheic dermatitis is unknown. INDICATIONS: Selenium sulfide is indicated in the treatment of seborrheic dermatitis of the scalp, including dandruff. CONTRAINDICATIONS: The product should not be used by patients allergic to any of its components. WARNINGS: Safety for use in infants has not been established. PRECAUTIONS: 1. Chemical conjunctivitis may result if this preparation enters the eyes. 2. The product should be used with caution when acute inflammation or exudation is present as an increase in absorption may occur. ADVERSE REACTIONS: 1. Hair loss has been reported with the use of the product. 2. Discoloration of the hair may follow the use of selenium sulfide. This can be minimized by careful rinsing of the hair after treatment. 3. Oiliness of the hair and scalp may increase following the use of this product.

*Kligman, A.M. et al. Dandruff: It's nature and treatment, University of Pennsylvania, Department of Dermatology, Duhring Laboratories. Paper presented at American Academy of Dermatology, San Francisco, 1975.

Herbert Laboratories
Dermatology Division of
Allergan Pharmaceuticals, Inc.
Irvine, California 92713, U.S.A.

Count on Exsel.
(selenium sulfide) 2.5%

for dry and itchy winter skin...

EMULAVE® BAR

non-alkaline, soap-free, not only cleans but helps keep moisture in.

Here's why EMULAVE satisfies patients...and you:

- More available natural emollients than any other cleansing bar. EMULAVE is enriched with 29% skin-softening emollients, which help replenish skin lipids and provide the protective coating that seals in normal skin moisture.
- Contains no soap. A special skin-tested synthetic agent provides the cleansing and sudsing action... with minimal drying effect.
- Contains 30% AVEENO Colloidal Oatmeal for soothing, anti-pruritic, anti-inflammatory action.
- EMULAVE pH approximates that of normal skin.

Available in 3-oz. bars.

Cooper Laboratories, Inc.
Wayne, N.J. 07470

322-9/Dec.,1975

When patient acceptance is half the problem

sebutone®

is the answer.

Tar is effective therapy, but it has one big drawback . . . most shampoos look like tar and, worst of all, they smell like it, too.

Sebutone® provides tar therapy with unique patient acceptance.

- Itching usually stops after the first shampoo.
- It has a clean, fresh odor patients will like.
- It is a rich, lathering shampoo with a pleasant color.
- It contains the first chemically and biologically standardized tar, developed by Westwood.
- Sebutone's tar is bioassayed to insure therapeutic activity from batch to batch.
- Available in both lotion and cream.
- In addition to 0.5% Westwood® Tar, Sebutone contains 2% sulfur and 2% salicylic acid, for increased effectiveness.
- Wood's light shows that microfine particles remain on the scalp for up to three days to provide sustained antiseborrheic action.

sebutone® Therapeutic Tar Shampoo

. . . Substantive therapy...proven by Wood's light.

Available—Sebutone in 4 and 8 oz. bottles; Sebutone Cream in 4 oz. tubes.

WESTWOOD
PHARMACEUTICALS INC.
Buffalo, New York 14213

©1977, W. P. Inc.

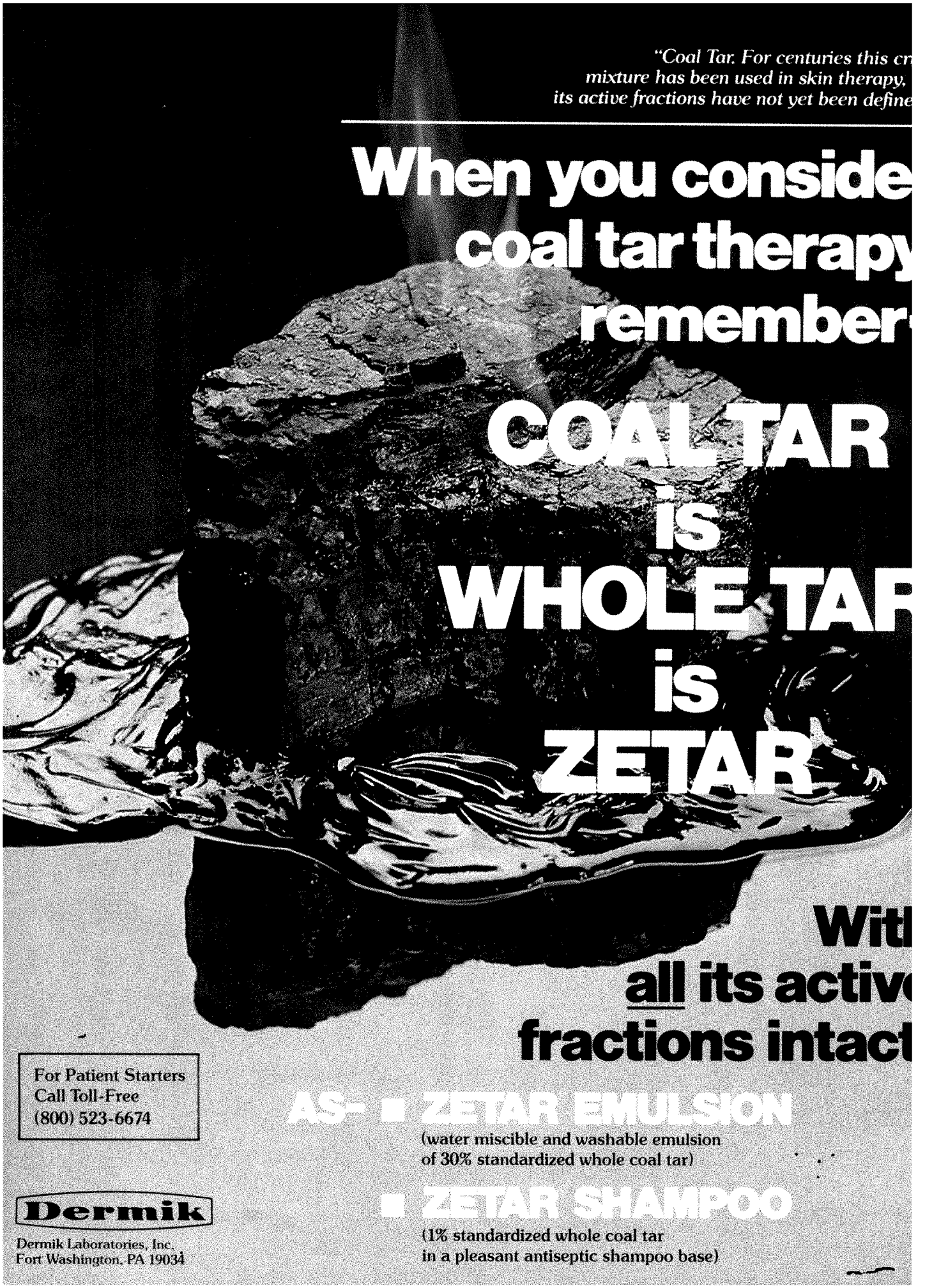
"Coal Tar. For centuries this cr
mixture has been used in skin therapy,
its active fractions have not yet been define
When you conside
coal tar therapy
remember
COAL TAR
is
WHOLE TAR
is
ZETAR
Wit
all its activ
fractions intact
For Patient Starters
Call Toll-Free
(800) 523-6674
AS-
ZETAR EMULSION
(water miscible and washable emulsion
of 30% standardized whole coal tar)
ZETAR SHAMPOO
(1% standardized whole coal tar
in a pleasant antiseptic shampoo base)
Dermik
Dermik Laboratories, Inc.
Fort Washington, PA 19034

Schering

When it's all you want, it's all they get.



pure and simple

Chlor-Trimeton® 12mg.

brand of
chlorpheniramine maleate, USP

Repetabs® Tablets, brand of repeat-action tablets

Available on prescription only.

Also available:
Chlor-Trimeton®
8 mg. Repetabs®
Injection 100 mg./ml.
and 10 mg./ml.

Copyright © 1977, Schering Corporation. All rights reserved.

SWW-9340

THE ONLY WAY TO END THE EPIDEMIC IS OVER HER DEAD BODY.

Kill the female itch mite (*sarcoptes scabiei*) and you've stopped the current scabies epidemic. Because when she burrows deep into the stratum corneum, she defies diagnosis and resists removal by surface-acting medications and cleansers. Her success has been making headlines around the country—with reports of scabies outbreaks in rural and suburban areas as well as in the cities.

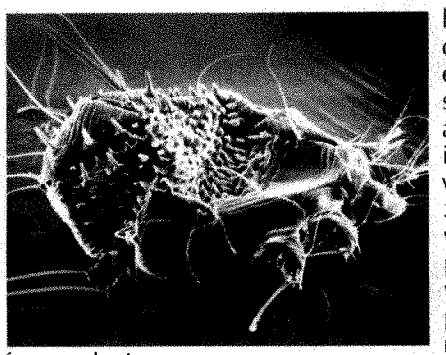

A quick and simple diagnosis. Scabies can mimic a number of dermatological conditions,[1-3] such as urticaria, furunculosis and dermatitis—as well as syphilis with which it may coexist. But there's an almost foolproof way to recognize it. Even in the absence of the fierce nocturnal itching[3] and the lesion distribution characteristic of the disease (hands, wrists and elbows in 9 out of 10 cases),[1] a quick microscopic look can confirm your scabies diagnosis.

To demonstrate the itch mite, look for an unscratched, inhabited burrow (wherever the patient says he itches at that very moment is a likely spot). Use a strong light, a magnifying glass and a surgical blade to which a drop of mineral oil is added. Scrape several sites. Transfer the material to a slide, cover and examine under low power magnification.[1,3,4] (If you don't spot any parasites in egg, larvae or adult stages, look for their red fecal compactions. They can be just as diagnostic.)

Kwell: penetrating action to kill mites, their eggs and larvae. Once you've found scabies, there's a positive way to eradicate it. Kwell (1% gamma benzene hexachloride) Lotion or Cream. It penetrates to reach the scabietic burrows, kills the female mites and, of course, the less tenacious males, as well as their eggs and any larvae that may have hatched. In fact, Kwell works so consistently and well against scabies that it has been the most widely prescribed scabicide for three decades.

Nearly 100% effective. The clinical record of Kwell has never been surpassed by any other pediculicide. It is "nearly 100% effective,"[1] and often works with a single application (a second or third application may be made at weekly intervals, if needed). Your patients will appreciate the low risk of sensitization and irritation.[5,6] And you will appreciate that Kwell works so predictably that it serves to confirm your diagnosis of scabies. Not many pharmaceutical preparations can match *that* record of dependability.

Contraindications: Kwell is contraindicated in individuals who develop hypersensitivity to the product or to any of its components.

Precautions: If accidental ingestion occurs, prompt institution of gastric lavage will rid the body of large amounts of the toxicant. However, since oils favor absorption, saline cathartics for intestinal evacuation should be given rather than oil laxatives.

Central nervous system manifestations can be antagonized by the administration of pentobarbital or phenobarbital in sufficiently large doses to the limit of their therapeutic effectiveness. It is not desirable to depress the patient to the point of hypnosis. However, persons poisoned with stimulants may tolerate large doses of barbiturate without undue depression and with great benefit. Intravenous calcium gluconate may be used in conjunction with the barbiturates. Epinephrine should not be used because ventricular fibrillation may result.

If accidental contact with eyes occurs, flush with water. If irritation or sensitization occurs, discontinue the product and consult physician.

Adverse Reactions: Eczematous eruptions due to sensitization of this product have been reported.

Available on prescription as Kwell Lotion in 2 and 16 fl. oz. bottles, and as Kwell Cream in 2 oz. and 1 lb. jars. See package insert for complete prescribing information.

References: 1. *Patient Care* 7:94, Nov. 1, 1973. 2. Stankler, L.: *Practitioner* 210:803, June 1973. 3. Domonkos, A.N. (ed.): Andrews' Diseases of the Skin: Clinical Dermatology, ed. 6, Philadelphia, W. B. Saunders Company, 1971, pp. 511-513. 4. Muller, G., *et al: Arch. Dermatol.* 107:70, Jan. 1973. 5. James, B.H.E.: *Br. Med. J.* 1:178, Jan. 15, 1972. 6. Sollman, T.: A Manual of Pharmacology, ed. 8, Philadelphia, W. B. Saunders Company, 1957, p. 178.

SEM Courtesy of J. M. Rower, M.D., Columbus, Ohio.

Reed & Carnrick / Kenilworth, New Jersey 07033

Cream/Lotion

KWELL® gamma benzene hexachloride

THE SCABICIDE OF CHOICE.

An unsurpassed standard of therapy

antifungal
antipruritic
antibacterial
anti-
inflammatory
TAXI

Clear choice

When dermatoses become infected with bacteria or fungi, plain topical steroids are generally not the recommended therapeutic choice.

A clear choice, however, is Vioform® Hydrocortisone. With its unique four-way action, it supplies the kind of comprehensive treatment many common dermatoses* require.

*This drug has been evaluated as possibly effective for these indications. See brief prescribing information.

Vioform®-Hydrocortisone (iodochlorhydroxyquin and hydrocortisone)

INDICATIONS
Based on a review of this drug by the National Academy of Sciences-National Research Council and/or other information, FDA has classified the indications as follows:
"Possibly" effective: Contact or atopic dermatitis; impetiginized eczema; nummular eczema; infantile eczema; endogenous chronic infectious dermatitis; stasis dermatitis; pyoderma; nuchal eczema and chronic eczematoid otitis externa; acne urticata; localized or disseminated neurodermatitis; lichen simplex chronicus; anogenital pruritus (vulvae, scroti, ani); folliculitis; bacterial dermatoses; mycotic dermatoses such as tinea (capitis, cruris, corporis, pedis); moniliasis; intertrigo.
Final classification of the less-than-effective indications requires further investigation.

CONTRAINDICATIONS
Hypersensitivity to Vioform-Hydrocortisone, or any of its ingredients or related compounds; lesions of the eye; tuberculosis of the skin; most viral skin lesions (including herpes simplex, vaccinia, and varicella).

WARNINGS
This product is not for ophthalmic use.
In the presence of systemic infections, appropriate systemic antibiotics should be used.

Usage in Pregnancy
Although topical steroids have not been reported to have an adverse effect on pregnancy, the safety of their use in pregnant females has not been established. Therefore, they should not be used extensively on pregnant patients in large amounts or for prolonged periods of time.

PRECAUTIONS
May prove irritating to sensitized skin in rare cases. If this occurs, discontinue therapy. May stain.
If used under occlusive dressings or for a prolonged period, watch for signs of pituitary-adrenal axis suppression.
May interfere with thyroid function tests. Wait at least one month after discontinuance of therapy before performing these tests. The ferric chloride test for phenylketonuria (PKU) can yield a false-positive result if Vioform is present in the diaper or urine.
Prolonged use may result in overgrowth of nonsusceptible organisms requiring appropriate therapy.

ADVERSE REACTIONS
Few reports include: Hypersensitivity, local burning, irritation, pruritus. Discontinue if untoward reaction occurs. Rarely, topical corticosteroids may cause striae at site of application when used for long periods in intertriginous areas.

DOSAGE
Apply a thin layer to affected areas 3 or 4 times daily.

HOW SUPPLIED
Cream, 3% iodochlorhydroxyquin and 1% hydrocortisone in a water-washable base containing stearyl alcohol, cetyl alcohol, stearic acid, petrolatum, sodium lauryl sulfate, and glycerin in water; tubes of 5 and 20 Gm. *Ointment*, 3% iodochlorhydroxyquin and 1% hydrocortisone in a petrolatum base; tubes of 20 Gm. *Lotion*, 3% iodochlorhydroxyquin and 1% hydrocortisone in a water-washable base containing stearic acid, cetyl alcohol, lanolin, propylene glycol, sorbitan trioleate, polysorbate 60, triethanolamine, methylparaben, propylparaben, and perfume Flora in water; plastic squeeze bottles of 15 ml. *Mild Cream*, 3% iodochlorhydroxyquin and 0.5% hydrocortisone in a water-washable base containing stearyl alcohol, cetyl alcohol, stearic acid, petrolatum, sodium lauryl sulfate, and glycerin in water; tubes of ½ and 1 ounce. *Mild Ointment*, 3% iodochlorhydroxyquin and 0.5% hydrocortisone in a petrolatum base; tubes of 1 ounce.

Consult complete product literature before prescribing.

CIBA Pharmaceutical Company
Division of CIBA-GEIGY Corporation
Summit, New Jersey 07901

2/6867 17

Vioform® Hydrocortisone (iodochlorhydroxyquin and hydrocortisone)

The most widely prescribed form... 20-Gm Cream

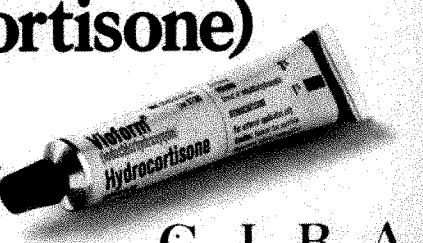

CIBA



Potency in psoriasis

Potency— A singularly important criterion in selecting a topical steroid for psoriasis, as well as all other acute inflammatory steroid-responsive conditions.

Fluocinonide — A steroid that is 100% dissolved in the Lidex base for optimal lesion penetration. Anti-inflammatory, vasoconstrictive, antipruritic actions, backed by a proven record of performance.

Available in a form that's right for the case at hand — cream, ointment, or Topsyn® (fluocinonide) Gel, 0.05%.

Lidex®
(fluocinonide) 0.05%

See following page for summary of prescribing information

Cryofractured section of psoriatic epidermis photographed en face. Epidermis (EP) is thickened and stratum corneum (SC) is both thickened and highly disorganized. Dark oval depressions are nuclei (N). Stringy adherent material is exuded serum protein (P).

Color imposed on black-and-white photomicrograph magnified 209X.

SYNTEX

SYNTEX LABORATORIES, INC.
PALO ALTO, CALIFORNIA 94304

LIDEX® (fluocinonide)
0.05% Cream and Ointment

TOPSYN® (fluocinonide)
0.05% Gel

Summary of prescribing information

Description
LIDEX cream 0.05%, LIDEX ointment 0.05% and TOPSYN gel 0.05% contain the active compound fluocinonide. Fluocinonide, which is the 21-acetate ester of fluocinolone acetonide, has the chemical formula 6α, 9α-difluoro-11β, 16α, 17α, 21-tetrahydroxypregna-1,4-diene-3, 20-dione, cyclic 16, 17-acetal with acetone 21-acetate. LIDEX cream contains fluocinonide in FAPG® cream, a specially formulated cream base consisting of stearyl alcohol, polyethylene glycol 6000, propylene glycol, 1, 2, 6-hexanetriol and citric acid. This white cream vehicle is greaseless, non-staining, anhydrous and completely water miscible. The base provides emollient and hydrophilic properties. In this formulation, the active ingredient is totally in solution.

LIDEX ointment contains fluocinonide in a specially formulated ointment base consisting of Amerchol CAB (mixture of sterols and higher alcohols), white petrolatum, propylene carbonate and propylene glycol. It provides the occlusive and emollient effects desirable in an ointment. In this formulation the active ingredient is totally in solution.

TOPSYN gel contains fluocinonide in a specially formulated gel base consisting of propylene glycol, propyl gallate, disodium edetate, and Carbopol 940 (carboxypolymethylene) with NaOH and/or HCL added to adjust the pH. This clear, colorless, thixotropic vehicle is greaseless, non-staining and completely water miscible. In this formulation, the active ingredient is totally in solution.

Indications
LIDEX cream and ointment and TOPSYN gel are intended for the relief of inflammatory manifestations of corticosteroid responsive dermatoses.

Contraindications
Topical steroids are contraindicated in vaccinia and varicella. Topical steroids are contraindicated in those patients with a history of hypersensitivity to any of the components of the preparation.

Precautions
If irritation develops, the cream, ointment or gel should be discontinued and appropriate therapy instituted. In the presence of an infection the use of an appropriate antifungal or antibacterial agent should be instituted.

If a favorable response does not occur promptly, the corticosteroid cream, ointment or gel should be discontinued until the infection has been adequately controlled.

If extensive areas are treated, the possibility exists of increased systemic absorption and suitable precautions should be taken.

Although topical steroids have not been reported to have an adverse effect on pregnancy, the safety of their use in pregnant females has not absolutely been established. Therefore, they should not be used extensively on pregnant patients, in large amounts or for prolonged periods of time.

LIDEX® (fluocinonide) cream and ointment and TOPSYN® (fluocinonide) gel are not for ophthalmic use.

Adverse reactions
The following local adverse reactions have been reported with topical corticosteroids:

burning	folliculitis
itching	acneform eruptions
irritation	hypopigmentation
dryness	striae
secondary infection	skin atrophy

Dosage and administration
A small amount should be gently massaged into the affected area three or four times daily, as needed.

How supplied
LIDEX 0.05% Cream—15 g 30 g and 60 g tubes.
LIDEX 0.05% Ointment—15 g 30 g and 60 g tubes.
TOPSYN Gel 0.05% 15 g and 60 g tubes.

SYNTEX
SYNTEX LABORATORIES, INC.
PALO ALTO, CALIFORNIA 94304

A safe, economical method of permanent hair removal— from face, legs, body

To save valuable office time, you can confidently recommend Perma Tweez to your patients for their home use.

- Battery-operated instrument self-sterilizes when current flows.
- Patented self-correcting needle.
- No-puncture safety feature helps prevent infection.
- Proved clinically safe (report on request).

FOR PHYSICIAN ORDERING

GENERAL MEDICAL CO., Dept D-91
1935 Armacost Ave.
West Los Angeles, CA 90025
30 DAY FREE TRIAL EXAMINATION.
(May be returned with no obligation.)

☐ PERMA TWEEZ $19.95
☐ ATTACHMENT $3.00
(for treating others)
☐ INVOICE AFTER 30 DAYS
☐ CHECK ENCLOSED

DR_____

STREET_____

C/S_____ ZIP_____

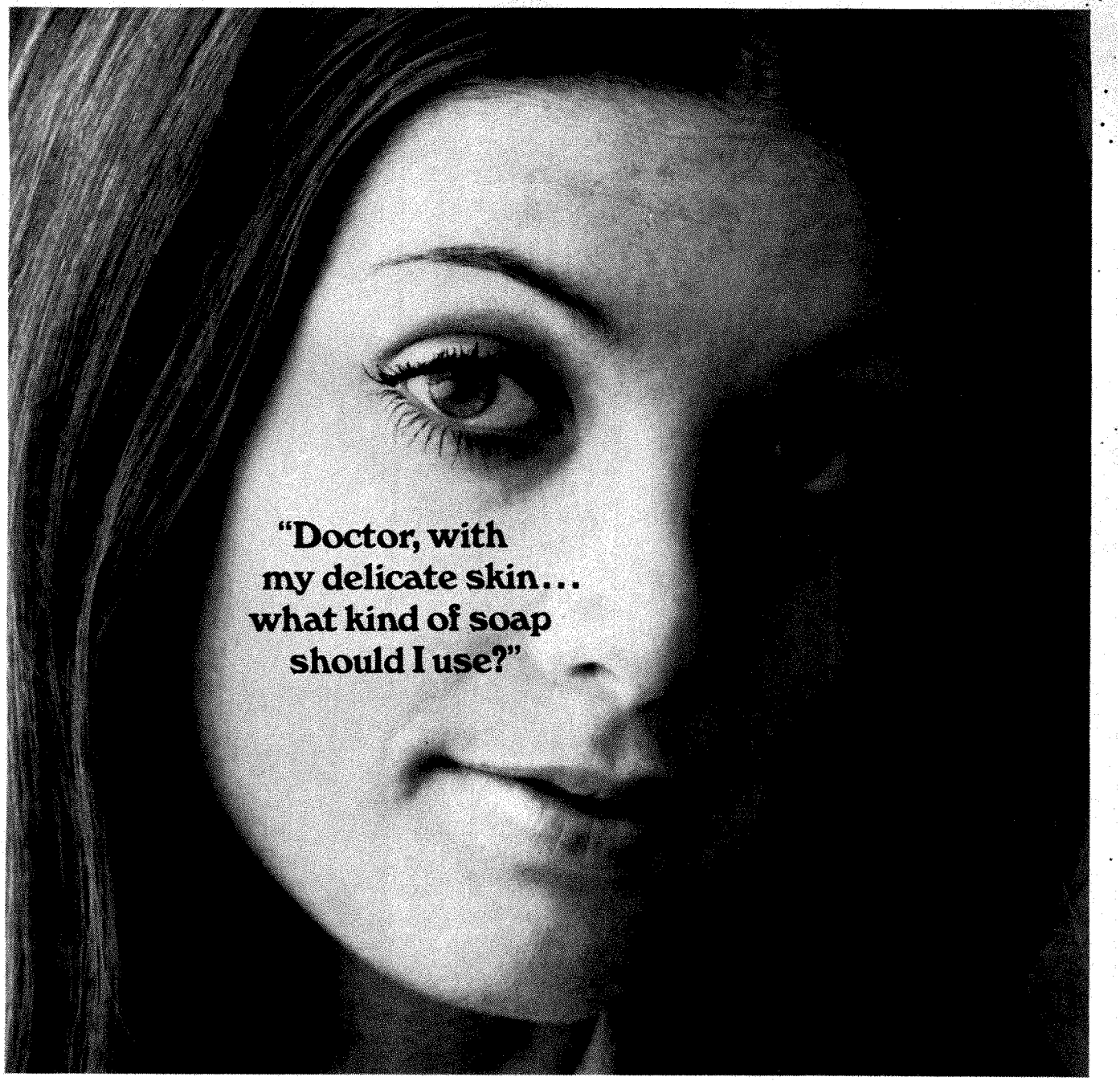

Pure mild Ivory is one of the safest possible soaps you can recommend for delicate skin. More doctors recommend Ivory than any other soap.

It makes sense. Ivory's absence of many extra ingredients helps minimize chances of irritation.

Thirty-eight years of laboratory testing—including patch tests and arm immersion experiments—confirm that Ivory is one of the mildest least irritating soaps you can recommend.

And 89 years of safe consumer use support this clinical experience.

Ivory may safely be used as an adjunct to treatment of scabies, seborrhea and impetigo.

Inflammatory manifestations of psoriasis and atopic dermatitis...

Effectiveness demonstrated in only 8 days*

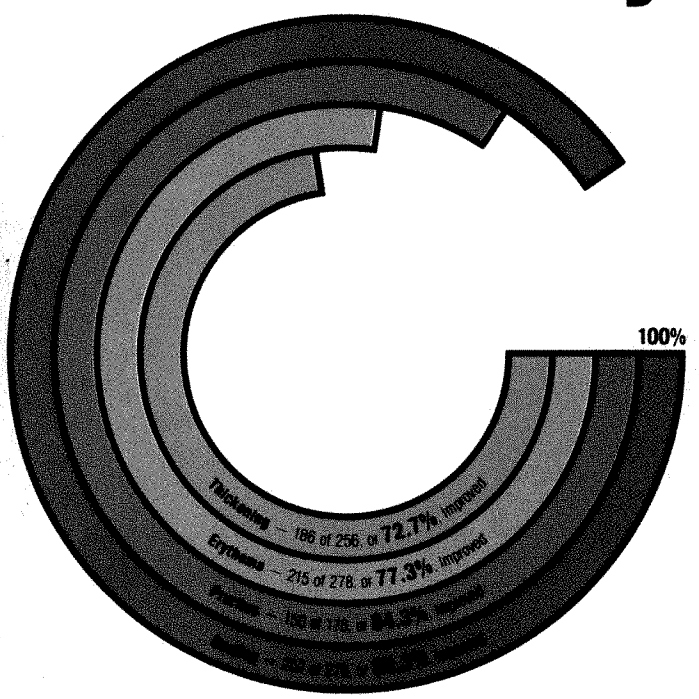

Psoriasis

In a study of 279 psoriatic patients

Atopic Dermatitis

In a study of 162 atopic dermatitis patients

Cordran® (Flurandrenolide)

Description: Cordran* (flurandrenolide, Dista) is a potent corticosteroid intended for topical use. **Actions:** Cordran is primarily effective because of its anti-inflammatory, antipruritic, and vasoconstrictive actions. **Indications:** For relief of the inflammatory manifestations of corticosteroid-responsive dermatoses. **Contraindications:** Topical corticosteroids are contraindicated in vaccinia and varicella and in patients with a history of hypersensitivity to any of their components. **Precautions:** If irritation develops, the product should be discontinued and appropriate therapy instituted. In the presence of an infection, an appropriate antifungal or antibacterial agent should be used. If a favorable response does not occur promptly, the corticosteroid should be discontinued until the infection has been adequately controlled. If extensive areas are treated or if the occlusive technique is used, there is a possibility of increased systemic absorption of the corticosteroid, and suitable precautions should be taken. Although topical corticosteroids have not been reported to have an adverse effect on pregnancy, the safety of their use on pregnant women has not been absolutely established. Therefore, they should not be used extensively, in large amounts, or for prolonged periods of time on pregnant patients. These products are not for ophthalmic use. **Adverse Reactions:** The following local adverse reactions have been reported with topical corticosteroid formulations: acneform eruptions, burning, dryness, folliculitis, hypertrichosis, hypopigmentation, irritation, itching. The following may occur more frequently with occlusive dressings: maceration of the skin, miliaria, secondary infection, skin atrophy, striae. **Administration and Dosage:** For moist lesions, a small quantity of the cream or lotion should be rubbed gently into the affected areas two or three times a day. For dry, scaly lesions, the ointment is applied as a thin film to affected areas two or three times daily. [111875]

Cream, Ointment, and Lotion Cordran®, 0.05%
flurandrenolide

Cream and Ointment Cordran, 0.025%

*Data on file at Dista Products Company.

DISTA

Dista Products Company
Division of Eli Lilly and Company
Indianapolis, Indiana 46206

700136

Additional information available to the profession on request.

Cream

Cordran®

Flurandrenolide

Efficacy is its strength

Wet dressings may need no introduction to you, but Aluwets® do because they provide

A new dimension in wet dressing therapy:

Potent Antibacterial Action

AluWets™

(aluminum chloride hexahydrate, N.F.)

Wet Dressing Crystals

In *in vivo* tests, **Aluwets** provided substantially greater antibacterial action against resident flora than a commonly-used aluminum acetate (Burow's) solution.[1]

May potentiate steroid and antibiotic activity

When used in combination with topical steroids or steroid-antibiotic combinations, **Aluwets** Wet Dressings—because of their anti-inflammatory and antibacterial effects—may enhance your therapy by reducing the dependency on topical steroids and antibiotics.

1. Kligman, A.M.: Report on file at Stiefel Research Institute.

Contains: Each packet contains 12.9 grams aluminum chloride hexahydrate, N.F.

Available: Boxes of six packets each.

Directions: Thoroughly dissolve contents of one packet in approximately 12 oz. of cool or lukewarm water to make a 2% aluminum chloride solution.

Soak clean dressing or bandage in solution and apply loosely on the inflamed skin.

Remove, re-moisten and reapply dressings every 10-15 minutes. DO NOT LET DRESSINGS DRY OUT. Continue this procedure for 4 to 8 hours or as needed.

Dressing material and used solution should be discarded *daily* and not reused.

CAUTION: FOR EXTERNAL USE ONLY. Avoid contact with the eyes. Keep this and all medications out of the reach of children. If irritation occurs or persists, discontinue use.

Another First from Stiefel

STIEFEL
Logical Dermatologicals since 1847

Stiefel Laboratories, Inc.,
Oak Hill, N.Y. 12460
Stiefel Laboratories (Canada) Ltd.,
St. Laurent, Quebec, Canada H4R 1E1

How are you keeping up with happenings in your specialty?

Keep up-to-date with an AMA Specialty Journal. Month after month, it will bring you articles on original research, news of medical significance, and comments on current events in the specialty field of your interest.

Start an AMA Specialty Journal coming today.

- ☐ American Journal of Diseases of Children
- ☐ Archives of Dermatology
- ☐ Archives of General Psychiatry
- ☐ Archives of Internal Medicine
- ☐ Archives of Neurology
- ☐ Archives of Ophthalmology
- ☐ Archives of Otolaryngology
- ☐ Archives of Pathology and Laboratory Medicine
- ☐ Archives of Surgery

	U.S. & Poss.	All Other Countries
☐ 24 issues.....	$28.00	$38.00
☐ 12 issues.....	$18.00	$28.00

Payment must accompany all orders. Make checks payable to the American Medical Association.

Name _____

Address _____

City _____ State _____ Zip _____

Return to: Subscription Department, AMA
535 North Dearborn St., Chicago, Ill. 60610

S/J

KENALOG® IN ORABASE®
Triamcinolone Acetonide Dental U.S.P.

CONTRAINDICATIONS: Fungal, vira bacterial infections of the mouth or hypersensitivity to any product component.

WARNING: Safe use of this preparat during pregnancy has not been established with respect to possible adverse reactions on fetal developn therefore, it should not be used in w of child-bearing potential and partic during early pregnancy unless the physician or dentist feels that the pc benefits outweigh the possible haza

PRECAUTIONS: Patients with tuberculosis, peptic ulcer, or diabet mellitus should not be treated with corticosteroids without the advice o patient's physician. Bear in mind tha topical corticosteroids depress the normal defensive responses of oral tissues; virulent strains of oral microorganisms may multiply witho producing the usual warning sympt oral infections. When used as recommended, systemic effects are unlikely; however, they are a possib when topical corticosteroids are use over a long period of time. If local irri or sensitization should develop, discontinue the medication and inst appropriate therapy. Additional investigation into etiology of the oral lesion is advised if no significant regeneration or repair of oral tissues occurred in 7 days.

ADVERSE REACTIONS: Prolonged administration may elicit the adverse reactions known to occur with syste steroid preparations; for example, adrenal suppression, alteration of glucose metabolism, protein catabo peptic ulcer activations, and others. These are usually reversible and disappear when the hormone is discontinued.

For full information, consult packa insert.

HOW SUPPLIED: Kenalog® in Orabas (Triamcinolone Acetonide Dental Pa U.S.P.) is available in 5 gram tubes providing 1 mg. (0.1%) triamcinolon acetonide per gram.

© 1977 E.R.Squibb & Sons, Inc. 3

SQUIBB®

"The Priceless Ingredient of every product is the honor and integrity of its maker."™

ANOTHER CASE FOR KENALOG®
TRIAMCINOLONE ACETONIDE

A CASE FOR KENALOG® IN ORABASE®
TRIAMCINOLONE ACETONIDE DENTAL PASTE U.S.P.

Aphthous Ulcer

Severely painful eruption on inner lower lip; sensitive to heat, cold and spicy foods. Patient instructed to apply area and apply Kenalog in Orabase twice daily—once after lunch and once at bedtime.

After 12 days

Patient reported relief of pain and discomfort within 48 hours after first application. Examination revealed almost total resolution of lesion. *Case history on file at Squibb Institute for Medical Research.*

The only topical steroid that clings to and protects wet, oral lesions.

See adjacent column

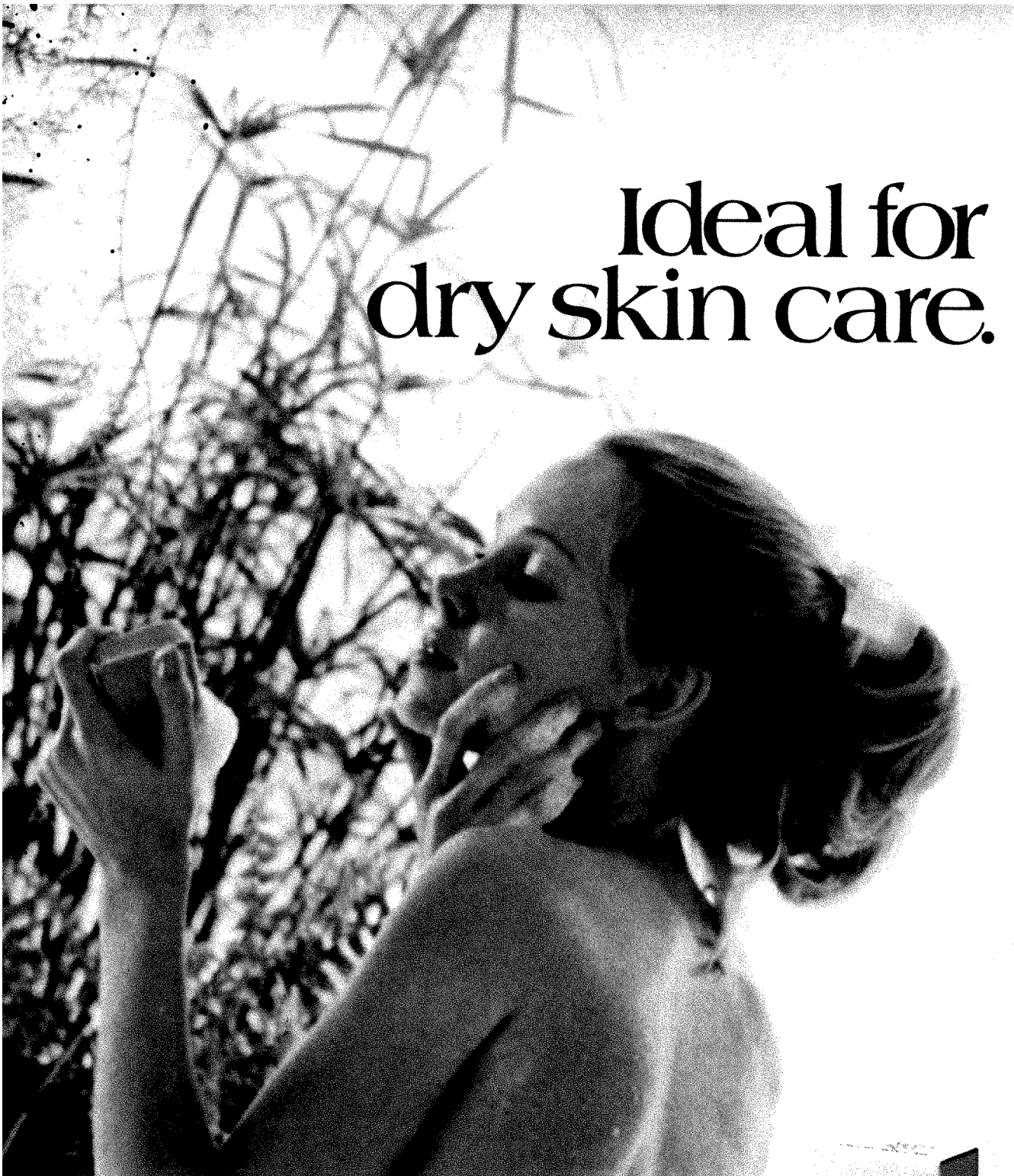

Ideal for dry skin care.

For dry skin care on a day-to-day basis, consider the soothing, softening, nondetergent cleansing properties of Alpha Keri Soap.

- Excellent cleansing properties eliminate harshness and irritation
- Contains Alpha Keri® therapeutic bath oil to soothe and soften skin
- Rich lather and delicate scent create outstanding patient acceptance



Alpha Keri® soap

The soothing, smoothing detergent-free cleanser

WESTWOOD
PHARMACEUTICALS INC.
Buffalo, New York 14213

In Canada, Belleville, Ontario K8N5E9

©1976 W.P. Inc.

Vitiligo and Juvenile Diabetes Mellitus

Chamel Macaron, MD; Robert J. Winter, MD; Howard S. Traisman, MD;
Barry D. Kahan, MD; Alan E. Lasser, MD; Orville C. Green

• Five juvenile diabetics had vitiligo. In two children, the vitiligo preceded the onset of diabetes. Four of the five patients had thyroid, adrenal, or gastric antibodies or a combination of these. In three children HLA-B8 antigens were detected, and one additional patient had HLA-Bw15. Of eight nondiabetic children with vitiligo, one had abnormal glucose tolerance. To the evidence supporting an autoimmune form of diabetes mellitus we add another observation: the association of insulin-dependent diabetes and childhood vitiligo.

(*Arch Dermatol* 113:1515-1517, 1977)

Diabetes mellitus (DM) and vitiligo have been considered autoimmune disorders by some investigators.[1,2] It is hypothesized that vitiligo results from a self-destruction of the melanocytes, and antimelanin antibodies have been detected in the serum of these patients.[1] Vitiligo has been associated with many organ-specific autoimmune diseases such as Graves' disease, pernicious anemia, adrenocortical insufficiency, and idiopathic hypoparathyroidism.[3-9] One isolated report identified selective IgA deficiency in a few patients.[10] Even in the absence of clinical manifestations of these autoimmune diseases, a markedly increased frequency of parietal cell, thyroid, and adrenal autoantibodies has been documented in patients with vitiligo.[11-13]

Diabetes mellitus is recognized as a heterogenous disorder, and the evidence for a true autoimmune form of DM is accumulating.[2] An autoimmune or a viral insult of a susceptible individual may precipitate insulin-dependent diabetes (IDD).[2,14] Susceptible individuals may be identified by HLA typing: HLA-B8 and/or HLA-Bw15 have been found in two thirds of patients with IDD.[15,16] Genes that determine specific immune response or viral-induced disease have been linked to these types.[15,16] In addition, autoimmune involvement in the pathogenesis of diabetes is supported by the following factors: (1) the autopsy finding of insulinitis with lymphocytic infiltration in the pancreata of few newly diagnosed cases of IDD[17]; (2) the detection in IDD of islet cell antibodies (AB) and cell-mediated immunity to human pancreas[18-22]; (3) the increased frequency of gastric, adrenal, and thyroid autoantibodies seen in DM[23,24]; and (4) the clinical association of diabetes with other diseases believed to be autoimmune, such as idiopathic adrenal insufficiency, Graves' disease, Hashimoto's thyroiditis, pernicious anemia, myasthenia gravis, and vitiligo.[3,4] We have recently described an increased incidence of carbohydrate intolerance in children with preexisting autoimmune thyroiditis.[30]

The association between vitiligo and DM has been described for maturity-onset diabetes.[25,26] To our knowledge, this association has not been reported in diabetic children. The purpose of this report is to describe five juvenile diabetic patients with vitiligo and compare them to eight children with vitiligo only, in regard to their HLA typing and a variety of autoantibodies.

METHODS

Subjects

Thirteen patients were studied, five juvenile diabetics with associated vitiligo and eight nondiabetic children affected with vitiligo. They ranged in age from 4 to 19 years. At the time of the study, none of the patients had evidence of an intercurrent illness by history, nor was any patient obese. All of the studies and physical examinations were performed at the Clinical Research Center of Children's Memorial Hospital. Signed informed consent was obtained from the parents and patients studied.

Oral Glucose Tolerance Testing

The eight vitiligo patients were given written and oral instructions for a 300-gm carbohydrate diet to be consumed for at least three days prior to the performance of an oral glucose tolerance test (OGTT). Trioxsalen, when prescribed, was discontinued for a week prior to the test. With the patient recumbent after an overnight fast, two baseline specimens were withdrawn; a dextrose solution was ingested in a dose of 1.75 gm/kg of body weight, to a maximum of 100 gm. Sequential blood specimens were obtained at 30 minutes, one, two, and three hours after glucose ingestion.

Criteria

The criteria used for evaluation of the OGTT have been described.[27] Glucose intolerance was defined when the sum of fasting one-, two-, and three-hour serum glucose values was greater than 600 mg/100 ml. Our results did not change when children's adjusted criteria were used.[28]

Accepted for publication June 1, 1977.

From the Department of Medicine (Drs Macaron, Winter, Traisman, and Green) and Dermatology (Dr Lasser), Northwestern University Medical School; and the Department of Dermatology, Children's Memorial Hospital (Dr Lasser). Dr Macaron is now with Edgewater Hospital and the Department of Medicine, Chicago Medical School, and Dr Kahan is now with the Department of Surgery, University of Texas Health Science Center, Houston.

Reprint requests to Edgewater Hospital-Mazel Medical Center, 5700 N Ashland Ave, Chicago, Il 60660 (Dr Macaron).

Biochemical, Hormonal, and Immunologic Determinations

Serum glucose was measured by the glucose oxidase method. Thyroxine was measured by competitive protein displacement; the plasma specimens for cortisol and insulin were stored at −20 C, then measured by a specific double-antibody radioimmunoassay in the same run to eliminate interassay variations. The immunologic profile was obtained by measuring serum immunoglobulin levels, antinuclear antibody (ANA), thyroid, gastric, and adrenal antibodies. Antithyroglobulin AB was tested by the hemagglutination technique, while the cytoplasmic, adrenal, and gastric AB were evaluated by the indirect Coons fluorescent technique.[22] Antibody titers were considered significant if positive at a dilution of 1:4 or more. We tested for HLA antigens by the lymphocyte microcytotoxic test with 112 well-characterized alloantisera to HLA.

Five Patients With Diabetes and Vitiligo

The clinical data are shown in Table 1 (patients 1 through 5). They did not have diabetic ketoacidosis. Their diabetes was in relatively good control requiring only one dose of intermediate-acting insulin. None had insulin hypertrophy or lipoatrophy at the sites of insulin injection. In two patients, the clinical recognition of the vitiligo preceded the onset of diabetes. No characteristic distribution was detected in our patients.

Table 2 (patients 1 through 5) provides the pertinent laboratory data. In four of five patients, the HLA antigens were identical to those described in the majority of insulin-dependent diabetics,[15,16] three being HLA-B8 and one HLA-Bw15.

The immunoglobulin values were within normal limits. Only one patient had no laboratory evidence of autoimmune phenomenon.

Eight Vitiligo Patients

The clinical data are presented on Table 1 (patients 6 through 13). There was a great deal of variation in the duration of the vitiligo, as well as its distribution. Only patient 6 had a first-degree diabetic relative. Seven patients (patients 6 through 12) displayed a normal OGTT by the criteria defined above. Patient 7, whose HLA type was HLA-B8, had a borderline OGTT with a one-hour value of 165 mg/100 ml and a two-hour value of 145 mg/100 ml. Patient 12 had an abnormal two-hour value of 140 mg/100 ml. Only patient 13 had an abnormal OGTT: fasting serum glucose, 103 mg/100 ml; 30 minutes, 184 mg/100 ml; one hour, 212 mg/100 ml; two hours, 162 mg/100 ml; three hours, 180 mg/100 ml. The corresponding serum insulin values are 12, 80, 85, 97, and 104 μU/ml. He was not insulin deficient, but the peak of insulin release was delayed. None of his first-degree relatives was diabetic, and his HLA type was not typical of the IDD. Thus, one vitiligo patient of eight had chemical diabetes. The remainder of the laboratory data are depicted on Table 2 (patients 6 through 13). Not included are the immunoglobulin values, which were normal.

COMMENT

Our study of 13 children with vitiligo confirms many of the reported features concerning the clinical presentation of this entity. Lerner, in his classical study, said that vitiligo is often inherited as an autosomal dominant trait, without any sex predominance and that 50% of the patients notice their skin abnormality before the age of 20.[9] This was reflected in our study by the fact that patients 2 and 7 had parents with vitiligo. In addition all of our patients had the onset of their disease before the age of 15. That seven of eight nondiabetic children were female may simply reflect pure chance or could be explained by the fact that they are more interested in the treatment this skin disfiguring disorder. Si vitiligo does not shorten life exp tancy, the males are more likely to seen when affected by a sec disease as exemplified by our f male diabetic children. On the ot hand, the family history did reveal association of vitiligo with ot organ-specific autoimmune disea such as pernicious anemia (patient and Hashimoto's thyroiditis (pati 4). A family history of DM was elici in eight patients.

None of our patients manifes clinical or biochemical evidence idiopathic adrenocortical insuffici cy, pernicious anemia, or thyr disorders. However, thyroglobu adrenal, and gastric cell autoa bodies occurred singly or in combi tion in eight patients. Irvine et detected ANA and mitochondrial in only 1% of the diabetics and in 1%

Table 1.—Clinical Data*

Patient	Age, yr/Sex/Race	Age at DM Onset, yr	Age at Vitiligo Onset, yr	Family History
1	15/M/W	7	2	DM (third generation)
2	12/M/W	2	½	Mother, vitiligo; grandmother, adult-onset DM
3	16/M/B	7½	6	Brother, IDD; maternal grandfather, pernicious anemia
4	8/M/W	3½	6	Sister, Hashimoto's thyroiditis
5	13/F/W	4	7	Father, IDD and thyroid disease
6	4/F/W	—	8 mo	Father, IDD
7	4/F/B	—	1 mo	Aunt, IDD; father, vitiligo
8	10/F/W	—	2	Negative
9	11/F/W	—	8	Maternal grandfather, IDD
10	18/F/W	—	7	Negative
11	17/F/W	—	7	Vitiligo (paternal great aunt)
12	10/F/W	—	5	Negative
13	13/M/W	—	3	Maternal grandfather, DM

*Patients 1 through 5 had diabetes and vitiligo; patients 6 through 13 had vitiligo only.

Table 2.—Laboratory Data*

Patient	HLA	AB			ANA†
		Thyroid	Adrenal	Gastric†	
1	Aw24, A28; B8, Bw 40	Neg	Neg	Neg	Neg
2	A2, Aw32; B12, Bw 15	1:25	Neg	Neg	1:160
3	A1, A3; B8	Neg	1:4(2+)	Neg	Neg
4	A1, B8	1:125	Neg	1:4(4+)	Neg
5	Aw25, Aw32; B12, B18	Neg	1:4(2+)	Neg	1:80
6	A1, A2; B8	Neg	Neg	Neg	Neg
7	A3, B8, Bw16	Neg	1:4(2+)	Neg	Neg
8	A1, A2; B5, B8	Neg	1:4(2+)	Neg	Neg
9	A2, A9; B13, Bw21	1:25	Neg	Neg	Neg
10	A2, B7, Bw21	Neg	1:4(2+)	Neg	Neg
11	A2, A28; B5, Bw15	Neg	Neg	Neg	Neg
12	Aw30, B7, Bw22	Neg	Neg	Neg	Neg
13	A2, Bw16, Bw21	Neg	Neg	Neg	Neg

*Negative in all patients.
†Patients 6 through 13 had vitiligo only.

the control subjects.[24] They concluded that the prevalence of tissue-specific AB (as compared to humoral AB) does not seem to be increased in the diabetic population. Our finding of two diabetic vitiligo patients with ANA may be a pure coincidence. Neither had signs or symptoms of systemic lupus erythematosus. In addition, none of our 13 patients had complete IgA deficiency, although minor decrements were seen.

The HLA-B8 has been associated with many diseases believed or suspected to be autoimmune, ie, Graves' disease, idiopathic Addison's disease, and IDD. Six of 13 vitiligo patients—three being diabetic—had HLA-B8 antigens. No significant association can be drawn from this small population. Nevertheless, we intend to observe the three vitiligo patients to see if they develop diabetes in the future.

The association between DM and vitiligo has been well established in the adult population.[4-6,25,26,29] The majority of these diabetics were not insulin-dependent, and some of them had other endocrine deficiencies. An increased incidence of DM in the relatives of patients with vitiligo has also been reported.[3] To our knowledge, our study is the first report of childhood vitiligo associated with juvenile diabetes. Even though the course of their diabetes has been mild, the vitiligo adds an additional burden to the adolescent diabetic. The combination of these two diseases disrupts their normal life pattern. The incidence of this association cannot be precisely ascertained; we detected these five children among 300 juvenile diabetics; the prevalence of vitiligo in our juvenile diabetics would be estimated to be 1.6%, which is higher than the prevalence of vitiligo in the general population (approximately 0.7%).[25] The finding of an abnormal OGTT in one vitiligo patient need not indicate that vitiligo patients are at a greater risk for the development of carbohydrate intolerance.

To the mounting evidence that supports the concept of a true autoimmune clinical form of DM, we hereby add another factor: the association of IDD and childhood vitiligo.

References

1. Etiology of vitiligo, editorial. *Lancet* 11:1298, 1971.
2. MacCuish AC, Irvine WJ: Autoimmune aspects of diabetes. *Clin Endocrinol Metabol* 2:435, 1975.
3. Bor S, Feiwel M, Chanarin I: Vitiligo and its etiological relationship to organ specific autoimmune disease. *Br J Dermatol* 81:83, 1969.
4. Cunliffe WJ, Hall R, Newell DJ, et al: Vitiligo, thyroid disease and autoimmunity. *Br J Dermatol* 80:135, 1968.
5. Dawber RP: Clinical association of vitiligo. *Postgrad Med J* 46:276, 1970.
6. McGregor BC, Katz HI, Doe RP: Vitiligo and multiple glandular insufficiencies. JAMA 219:724, 1972.
7. Ochi Y, DeGroot L: Vitiligo in Graves' disease. *Ann Intern Med* 71:935, 1969.
8. Doniach D, Grant D, Newns GH: Multiendocrine autoimmune disorder in mother and son. *Proc R Soc Med* 65:488, 1972.
9. Lerner AB: Vitiligo. *J Invest Dermatol* 32:285, 1959.
10. Gatti RA: Etiology of vitiligo. *Lancet* 1:91, 1972.
11. Brostoff J, Bor S, Feiwel M: Autoantibodies in patients with vitiligo. *Lancet* 2:177, 1969.
12. Hovitz J, Schwartz M: Vitiligo, achlorhydria and pernicious anemia. *Lancet* 1:1331, 1971.
13. Soter NA, Williamson DS, Fitzpatrick TB: Clinical dermatology (medical progress). *N Engl J Med* 289:242, 1973.
14. Steinke J, Taylor KW: Viruses and the etiology of diabetes. *Diabetes* 23:631, 1974.
15. Nerup J, Platz P, Andersen O, et al: HLA antigens and diabetes mellitus. *Lancet* 2:864, 1974.
16. Cudworth AG, Woodrow JC: HLA system and diabetes mellitus. *Diabetes* 24:345, 1975.
17. Doniach I, Morgan AG: Islets of Langerhans in juvenile diabetes mellitus. *Clin Endocrinol* 2:233, 1974.
18. Lemdrum R, Walker G, Gamble DR: Islet cell antibodies in juvenile diabetes mellitus of recent onset. *Lancet* 1:880, 1975.
19. Maclaren N, Huang SW, Fogh J: Antibody to cultured human insulinoma cells in insulin dependent diabetes. *Lancet* 1:997, 1975.
20. MacCuish AC, Irvine WJ, Barnes EW, et al: Antibodies to pancreatic islet cells in insulin dependent diabetics with coexistent autoimmune disease. *Lancet* 2:1529, 1974.
21. MacCuish AC, Jordan J, Campbell CJ, et al: Cell mediated immunity to human pancreas in diabetes mellitus. *Diabetes* 23:693, 1974.
22. Bottazzo GF, Florin-Christensen A, Doniach D: Islet cell antibodies in diabetes mellitus with autoimmune polyendocrine deficiencies. *Lancet* 2:1279, 1974.
23. Goldstein RE, Drash A, Gibbs J, et al: Diabetes mellitus: The incidence of circulating antibodies against thyroid, gastric, and adrenal tissue. *J Pediatr* 77:304, 1970.
24. Irvine WJ, Clarke BF, Scarth L, et al: Thyroid and gastric autoimmunity in patients with diabetes mellitus. *Lancet* 2:163, 1970.
25. Dawber RPR: Vitiligo in mature onset diabetes mellitus. *Br J Dermatol* 80:275, 1968.
26. Villaverde MM: Diabetes with vitiligo. *J Med Soc NJ* 66:218, 1969.
27. Report of the Committee on Statistics of the American Diabetes Association: Standardization of the oral glucose tolerance test. *Diabetes* 18:229, 1969.
28. Jackson RL: Insulin treatment of children with late stage chemical diabetes, in Camerini-Davalos RA, Cole HF (eds): *Early Diabetes Advances in Metabolic Disorders*. New York, Academic Press, 1970, p 401.
29. Heyman G, Lustman F: Diabete et pathologies immunitaires. *Acta Clin Belg* 26:380, 1971.
30. Winter RJ, Green OC: Carbohydrate homeostasis in chronic lymphocytic thyroiditis: Increased incidence of diabetes mellitus. *J Pediatr* 89:401, 1976.

NOTE:

NEW INSTRUCTIONS FOR AUTHORS

Congress recently passed *The Copyright Revision Act of 1976* that impacts upon our procedures for accepting manuscripts. Please refer to the "Instructions for Authors" page for details.

HLA-A10 in Pemphigus Among Japanese

Koji Hashimoto, MD; Yoshiharu Miki, MD; Seizo Nakata, MD; Masamichi Matsuyama, MD

• The frequency of the major histocompatibility antigen, HLA-A10, was significantly increased (corrected $P < .025$) in 43 unrelated patients with pemphigus vulgaris (41.9%) and in 25 patients with pemphigus foliaceus (48.0%), when compared with 60 unrelated healthy controls (16.7%).

No significant correlations with other HLA or differences between pemphigus vulgaris and pemphigus foliaceus were observed. Both forms of pemphigus were considered to link with the HLA-A10.

(*Arch Dermatol* 113:1518-1519, 1977)

In 1973, major histocompatibility antigens, HL-A10 (later designated as HLA-A10 by the World Health Organization in 1975) and HL-A13 (HLA-B13), were separately reported to be significantly increased among whites with pemphigus.[1,2] It was then postulated that a pemphigus susceptibility gene linked with these specific HLA antigens.

Between December 1974 and March 1975, 16 unrelated Japanese patients with pemphigus vulgaris were studied, and both HLA-A10 and HLA-Aw30 were shown to be significantly increased in these patients when compared with 77 unrelated healthy controls.[3]

The present study was carried out to see which of the above HLA antigens were significantly increased in a larger number of Japanese patients, and also to see the differences, if any, between pemphigus vulgaris and pemphigus foliaceus.

MATERIALS AND METHODS

A total of 43 unrelated pemphigus vulgaris (16 male and 27 female) and 25 pemphigus foliaceus (5 male and 20 female) patients were subjected to HLA typing and were compared with 60 unrelated healthy controls. This included 13 of 16 patients with pemphigus vulgaris who were studied previously,[3] though the typing was made again on these patients with a new set of antisera in the present study.

The geographic distribution of the patients is given in Table 1. All 60 controls were blood donors at the University of Osaka.

The diagnosis of the patients was based on clinical and histologic examinations. In addition, intercellular antiepithelial IgG deposits were demonstrated by indirect and/or direct immunofluorescent studies in 37 pemphigus vulgaris and 21 pemphigus foliaceus patients. Pemphigus erythematosus or Senear-Usher's syndrome was included in pemphigus foliaceus, because there was no clear-cut separation of the clinical entities from the data submitted to us.

The HLA typing was done between January and June 1976 by the modifi microdroplet lymphocyte cytotoxicity tes using 112 antisera of 25 defined specifi ties. Typing was performed immediate after the blood samples were drawn fro 22 patients with pemphigus vulgaris and patients with pemphigus foliaceus. In t remainder of the patients, it was pe formed within two to four days after t blood samples were obtained at each ins tution and mailed to us.[5]

RESULTS

Table 2 shows the result of HL frequencies in patients with pempl gus compared with healthy contro Among 25 specificities tested, HL A10 was found in 41.9% of 43 patien with pemphigus vulgaris and in 48.0 of 25 patients with pemphigus foli ceus as compared to 16.7% of controls.

The statistical significance of t antigen frequencies was tested by t χ^2 method. The increase was consi ered statistically significant $P < .001$. The corrected P value aft multiplication by 25 (number of spe ificities tested) was $< .025$.

The HLA-B16 in patients wi pemphigus vulgaris and Bw22 those with pemphigus foliaceus we also increased when compared wi

Table 1.—Geographic Distribution of Japanese Patients With Pemphigus and Frequency of HLA-A10 in Healthy Controls

Island	No. of Patients With Pemphigus Vulgaris	No. of Patients With Pemphigus Foliaceus	Frequency of HLA-A10 in Controls, %[5]
Honshu			
East	8	8	13.4-25
Middle	22	16	19.6-20.8
West	3	0	...
Skikoku	4	0	...
Kyushu	6	1	17.3

Accepted for publication April 5, 1977.

From the Departments of Dermatology (Dr Hashimoto) and First Surgery (Drs Nakata and Matsuyama), University of Osaka School of Medicine; and the Department of Dermatology (Dr Miki), University of Ehime School of Medicine, Shigenobucho, Japan.

Reprint requests to Department of Dermatology, University of Ehime School of Medicine, Shigenobucho, Ehime, 791-02, Japan (Dr Miki).

Table 2.—HLA Frequency in Patients With Pemphigus Vulgaris and Pemphigus Foliaceus

HLA Antigen	Pemphigus Vulgaris, % (n = 43)	Pemphigus Foliaceus, % (n = 25)	Controls, % (n = 60)
Locus A			
A1	0	0	1.7
A2	48.8	20.0	48.3
A3	0	0	0
A9	55.8	56.0	70.0
A10	41.9*	48.0*	16.7
A11	4.7	28.0	18.3
A28	0	0	0
Aw30	9.3	8.0	3.3
Aw31	9.3	8.0	5.0
Locus B			
B5	37.2	20.0	46.7
B7	11.6	8.0	8.3
B8	0	0	0
B12	4.7	8.0	11.7
B13	2.3	0	1.7
B14	0	0	0
B18	0	0	0
B27	0	0	1.7
Bw15	0	0	1.7
Bw16	14.0†	8.0	3.3
Bw17	0	0	0
Bw21	0	0	0
Bw22	16.3	36.0†	15.0
Bw35	16.3	16.0	15.0
Bw37	0	0	1.7
Bw40	39.5	32.0	31.7

*$P < .001$ ($P < .025$ after multiplication by 25).
†$P < .05$ ($P > .05$ after multiplication by 25).

the controls, but they were not statistically significant at $P > .05$ after multiplication by 25.

The HLA-A10 was further subclassified into Aw25 and Aw26; all patients and controls belonged to the Aw26 classification. There were no other HLA specificities that were significantly increased when compared with the controls or with the other type of pemphigus. The sexual differences were not compared because of the small size of the groups.

COMMENT

The HLA-A10 was significantly increased in the Japanese patients with pemphigus vulgaris and pemphigus foliaceus in the present study. This finding was consistent with the report by Krain et al on pemphigus vulgaris,[1] where HL-A10 (HLA-A10) was found in 60.7% of 28 Jewish patients and in 20.2% of 94 Jewish controls, while it was only in 20% of 15 non-Jewish patients and in 11% of 870 non-Jewish controls. The report by Katz et al, in which both Jewish and non-Jewish subjects were included and no clinical types were mentioned, showed that HLA-A10 was in 22.2% of 18 patients with pemphigus and in 15.5% of 251 normal controls.[2] The frequency of HL-A13 (HLA-B13) in the series of Katz et al[2] was not greater in our series.

In pemphigus vulgaris the HLA-Bw16, which was not typed in the previously published reports on pemphigus, and Bw22 in pemphigus foliaceus were increased in the present study, though the increases were not statistically significant.

The W30 (HLA-Aw30), which was significantly increased in the previous report on 16 patients with pemphigus vulgaris,[3] was not significantly increased in our larger number of patients.

The HLA frequencies among Japanese do not vary greatly by geographic location within Japan; the HLA-A10 frequency was 13.5% in Hokkaido, 13.4% in Tokyo, 20.8% in Nagoya, 16.2% in Osaka, and 17.3% in Fukuoka (Table 1).[6] Such ethnic uniformity might have contributed to the higher correlation of pemphigus with the HLA-A10 among Japanese.

Recent studies showed close correlation of specific HLA and autoimmune diseases, including ankylosing spondylitis, psoriasis, celiac disease, myasthenia gravis, and multiple sclerosis. This suggests that genes in the HLA region control immune responses critical for the disease susceptibility.[7] Both HLA antigens and the immune response gene are located in close association on chromosome 6.

Intercellular antiepithelial antibody is found both in pemphigus vulgaris and in pemphigus foliaceus, including Senear-Usher's syndrome or pemphigus erythematosus. Therefore, such autoimmune response in pemphigus may also be correlated with the HLA antigen. Katz et al demonstrated that the anti-HLA sera did not react with the pemphigus interepithelial antigen in an indirect immunofluorescent test.[2]

In the present study, patients whose conditions were diagnosed as Senear-Usher's syndrome or pemphigus erythematosus were included in the pemphigus foliaceus group because clear-cut separation was not feasible from the data submitted to us. Significantly increased HLA-A10 frequencies in both types of pemphigus found in the present study indicate a common disease susceptibility gene.

This study was supported in part by the Research Grant for Specific Disease from the Japanese Ministry of Health and Welfare.

Paul I. Terasaki, PhD, supplied the antisera and Drs Shigemi, Nagata, Sakamoto, Nishikawa, Asahi, Imamura, Ishikawa, Nakano, Masutani, Tokumaru, Sasaki, So, Arata, Ueki, Sasai, Yoshikawa, Igarashi, Sakata, Mishima, Tanabe, and Tanaka assisted in collecting blood samples of pemphigus patients.

References

1. Krain LS, Terasaki PI, Newcomer VD, et al: Increased frequency of HL-A10 in pemphigus vulgaris. *Arch Dermatol* 108:803-805, 1973.

2. Katz SI, Dahl MV, Penneys N, et al: HL-A antigens in pemphigus. *Arch Dermatol* 108:53-55, 1973.

3. Hashimoto K, Miki Y, Nakata S, et al: Pemphigus vulgaris and HL-A antigens. *Jap J Dermatol* 85:635-637, 1975.

4. Mittal KK, Mickey MR, Singal DP, et al: Serotyping for homotransplantation: XVIII. Refinement of microdroplet lymphocytotoxicity test. *Transplantation* 6:913-927, 1968.

5. Uhse HG, Terasaki PI: Transport of lymphocytes for typing. *Transplantation* 8:311-314, 1969.

6. Aizawa M: Recent progress in nomenclature and studies of HLA antigens. *Metab Disease* 13:455-461, 1976.

7. McDevitt HO, Bodmer WF: HL-A, immune-response gene, and disease. *Lancet* 1:1269-1275, 1974.

Oral Pemphigus Vulgaris

A Report of Ten Cases

Michael Meurer, MD; John L. Millns, MD; Roy S. Rogers III, MD; Robert E. Jordon, MD

• The conditions of ten patients were diagnosed as pemphigus vulgaris limited to the oral cavity. In eight patients the histopathologic findings were consistent with oral pemphigus. Direct immunofluorescence demonstrated intercellular substance (ICS) deposition of C3 either alone or in combination with IgG, IgA, IgM, C4, C1q, properdin, and factor B in all nine patients tested. Circulating ICS antibodies were detected initially in eight of the ten patients, nine of whom had positive titers at a later date, without subsequent development of cutaneous lesions.

Physicians should be alerted to a diagnosis of pemphigus in patients who have chronic erosive disease confined to the oral cavity. Prompt diagnosis by means of routine histopathologic and immunofluorescence studies followed by early initiation of treatment are warranted.

(*Arch Dermatol* 113:1520-1524, 1977)

The oral mucous membranes are involved in nearly all patients with pemphigus vulgaris, with up to two thirds of these patients developing oral lesions as the site of initial involvement.[1,2] The disease may remain localized to the oral mucosa for months before the eventual progression to extraoral sites; this usually occurs within a few weeks to a year.[1,3]

The presence of only oral lesions makes the diagnosis of pemphigus vulgaris difficult, as the transient picture of typical vesicular and bullous lesions is often obscured by repeated trauma and secondary infections, both of which can clinically and histologically result in a nonspecific picture.

The wide variety of systemic as well as localized diseases leading to bullous and ulcerative oral lesions also makes correct and early diagnosis difficult. Systemic diseases with oral involvement that can mimic pemphigus vulgaris include bullous pemphigoid, dermatitis herpetiformis, cicatricial pemphigoid, lichen planus, lupus erythematosus, erythema multiforme, systemic vasculitis, hand-foot-mouth disease, and Behcet's disease. More localized and self-limited diseases presenting a similar picture in and around the oral cavity include acute necrotizing gingivostomatitis, recurrent aphthous stomatitis, acute herpetic stomatitis, and contact stomatitis.

Within the past ten years, immunofluorescence (IF) techniques have become an important tool in the diagnosis of pemphigus vulgaris. Using indirect IF staining, Beutner and Jordon[4] demonstrated a circulating antibody in the sera of patients with active pemphigus vulgaris, which reacts with intercellular substance (ICS) of skin and mucosa at the site of the primary histopathologic lesion. In addition, direct IF staining has been used to demonstrate ICS deposition of IgG and complement components mainly of the classical pathway in the skin of patients with pemphigus vulgaris.[5-7] Bean et al[8] first reported ICS deposition of IgG in the oral mucosa of a patient with oral pemphigus vulgaris. Hasler[9] and Eversole et al[3] were the first to demonstrate circulating ICS antibodies in the sera of patients with pemphigus vulgaris localized to the oral mucosa.

This report describes a series of ten cases of pemphigus vulgaris evaluated at the Mayo Clinic between 1967 and 1975 with lesions confined to the oral mucosa. Diagnosis was confirmed by routine histopathologic examination, direct IF staining of biopsy sections of the oral mucosa, and indirect IF with use of the patients' sera. Our experience with these patients illustrates the importance of early and vigorous diagnostic measures for troublesome ulcerative and blistering lesions of the mouth.

Accepted for publication May 11, 1977.

From the Cutaneous Immunopathology Unit (Drs Meurer and Jordon) and the Departments of Dermatology (Drs Millns, Jordon, and Rogers) and Immunology (Dr Jordon), Mayo Graduate School, Mayo Clinic and Foundation, Rochester, Minn. Dr Meurer is a Deutsche Forschungsgemeinschaft fellow.

Reprint requests to Section of Dermatology, Veterans Administration Hospital, 5000 W National Ave, Wood, WI 53193 (Dr Jordon).

PATIENTS

The clinical features and previous treatment of the ten pemphigus patients are summarized in Table 1. Eight of the patients were women, two were men; the age distribution ranged from 25 to 77 years with a mean of 59 years.

All patients had a history of erosive or ulcerative lesions in the oral mucosa and adjacent areas for a duration of 2 to 15 months (mean, seven months) prior to initial evaluation at the Mayo Clinic. Distinctive blisters or bullae were reported infrequently. In most cases, the oral and pharyngeal lesions were extremely painful and bled easily; they showed little tendency to heal. Complaints of increased salivation, hoarseness, and dysphagia with resultant weight loss were also noted.

No antecedent history of oral or cutaneous, ulcerative or blistering lesions was noted in any patient prior to the onset of the presenting illness.

The oral lesions were variable in appearance. Most patients had circumscribed, denuded areas or erosions 1 to 5 cm in diameter (Fig 1 and 2). In many patients, the lesions were covered by a whitish exudate and occasionally surrounded by a collar of detached epithelium at the periphery. In three patients, intact blisters or bullae were present.

Buccal mucosal involvement was present in nine of the ten cases, the hard and soft palate in six, the dorsum of the tongue in five, the sublingual area and the gingiva in four, the lower lip in three, and the larynx in three cases. Perianal and nasal mucosal lesions were found to coexist with laryngeal ulcerations in one patient. Physical examination, both at the time of initial evaluation and during subsequent follow-up visits, failed to disclose any associated skin lesions.

REPORT OF CASES

CASE 1.—A 78-year-old woman was referred for evaluation of chronic oral and perianal ulcerations of five months' duration. Her illness began with the development of an erythematous, blistering eruption in the perianal area, which rapidly progressed to involve the mouth and oropharynx with subsequent dysphagia and bleeding. A 5.3-kg weight loss to 40 kg prompted hospitalization in her local community where a diagnosis of chronic aphthous stomatitis was made. After vigorous inpatient therapy with oral gargles of nystatin suspension, an antiseptic preparation (Chloraseptic) and hydrogen

Table 1.—Clinical Findings and Treatment

Patient	Age, yr/Sex	Duration of Disease, mo	Type of Lesion and Area of Involvement	Pretreatment Regimen
1	76/F	4	Ulcerative lesions of tongue, pharynx, tonsillar pillars, nasal and perianal mucosa	2-mo history of nystatin mouthwash, oral clindamycin
2	25/F	13	Erosions and white exudates of buccal mucosa, tongue, lower lip, tonsillar pillars	Intermittent course of tetracycline mouthwash, oral nystatin, multivitamins
3	44/M	15	Discrete blisters of buccal mucosa, gingiva, hard and soft palate	None
4	46/M	8	Ulcerative lesions less than 1 cm in diameter on tongue, gingiva, buccal mucosa	None
5	77/F	5	Erosions and blisters of tongue, buccal mucosa, gingiva	Prednisone begun at 40 mg every other day, tapered to 5 mg every other day prior to initial examination
6	75/F	2	Erythematous macular ulcerations of the buccal mucosa, tongue, soft palate, lower lip	None
7	76/F	8	Superficial erosions and purulent exudates of buccal mucosa, tongue, lower lip	None
8	58/F	5	Membranous ulcerations with white exudates on buccal mucosa, pharynx	None
9	55/F	3	Desquamative lesions of buccal mucosa, pharynx	Prednisone, 80 mg daily tapered to 60 mg daily two months prior to initial examination
10	62/F	6	Erosive ulcerations of buccal mucosa, tongue, soft palate	Several courses of prednisone, triamcinolone, corticotropin, hydroxyzine hydrochloride, diphenhydramine hydrochloride over 4-mo period

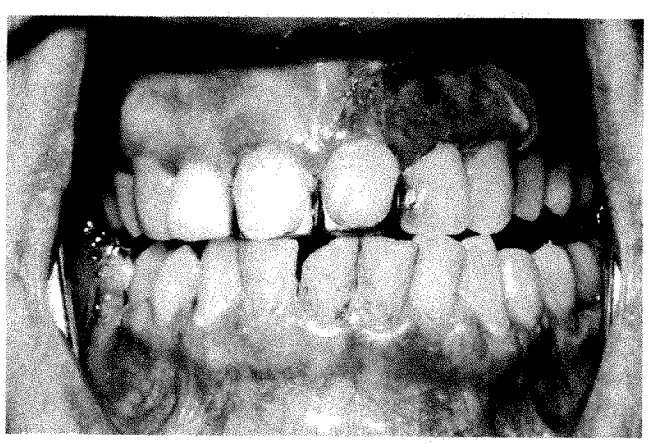

Fig 1.—Superficial, erythematous, gingival ulceration (patient 10).

Fig 2.—Irregular, superficial ulceration of soft palate (patient 3).

peroxide 50:50 in water, and a short course of orally administered clindamycin, 150 mg four times per day, the patient's condition showed little improvement and she was transferred to another hospital where her progressive debility prompted admission at Rochester Methodist Hospital for further evaluation.

Physical examination revealed multiple, superficial erosions of the nasal mucosa and several 3 to 5-mm superficial ulcerations on an erythematous base in the anal area. Oral examination showed marked erythema of the buccal mucosa and tongue with multiple 5 to 15-mm marginated, superficial ulcerations of the buccal mucosa, soft palate, lower lip, and oropharynx.

Laboratory findings included the following: hemoglobin level, 11.2 gm/100 ml; hematocrit reading, 35.3%; leukocyte count 41,000 cu mm, with a differential cell count of 54% neutrophils, 30% lymphocytes, 8% monocytes, 7.5% eosinophils, and 0.5% basophils; normal urine and electrolytes, and albumin, 2.7 gm/100 ml. Biopsy of the palate for direct IF demonstrated deposition of IgG and C3 in the ICS. Biopsy sections of the palate and anus were interpreted histologically as consistent with pemphigus vulgaris. Indirect IF studies were positive for ICS antibodies, titer of 160, and for antinuclear antibodies, titer of 80. Follow-up titers over the ensuing six weeks were 640, 320, and 640. A complete medical evaluation was noncontributory.

During hospitalization, the patient was treated with 2% viscous lidocaine and 0.1% betamethasone valerate cream four times daily to the oral lesions, 0.05% triamcinolone acetonide cream to the anal lesions, and gold sodium thiomalate, 25 mg intramuscularly on a weekly basis. High-dose steroid therapy originally planned was withheld because of impending cardiac decompensation secondary to severe aortic stenosis/insufficiency. After 22 days of hospitalization, her nasal and anal lesions had completely resolved yet she continued to have a few residual ulcerations on her soft palate. Her weight at discharge was 28 kg.

After discharge, the patient continued on the same regimen of medications outlined during her hospitalization, but she

Table 2.—Histopathologic and IF Findings

Patient	Histopathologic Findings	Direct IF (ICS)	Indirect IF (ICS)	
			Initial Titer	Subsequent Titers
1	Suprabasilar separation with superficial dermal lymphocytic infiltrate and normal salivary gland tissue	IgG, C3, C4, C1q	160	60, 320, 640
2	Suprabasilar bulla, marked acantholysis, and mixed cellular infiltrate in papillary dermis	IgG, IgM, C3, C4, C1q, fibrin	320	60, 80, twice neg
3	Suprabasilar clefting with microscopic hemorrhage and dense lymphohistiocytic and eosinophilic infiltrate	IgG, IgM, IgA, C3	Neg*	40, 80, 160, 80, 40, 80
4	Suprabasilar clefting and acantholysis with lymphohistiocytic dermal infiltrate	Not done	20	40, 20
5	Nonspecific	IgG, IgM, IgA, C3, C1q, properdin, factor B	Neg	—
6	Suprabasilar clefting minimal acantholysis, lymphohistiocytic dermal infiltrate	IgG, IgA, C3	320	60, 20, 80
7	Suprabasilar bulla formation with ulceration and mixed papillary dermal infiltrate	C3	320	—
8	Ulceration, suprabasilar clefting, dense dermal lymphohistiocytic infiltrate	C3, fibrin	20	Neg, 20, neg, 20, thrice neg, 40, neg, 20, thrice neg, 80, 160, 320, neg
9	Ulceration, suprabasilar bulla with acantholysis and dense lymphohistiocytic and plasma cell infiltrate	C3, fibrin	80	80
10	Nonspecific dermal lymphohistiocytic and plasma cell infiltrate	IgG, IgM, IgA, C3, C4	80	20, twice neg

*Negative.



Fig 3.—Suprabasilar clefting and acantholysis with dense, lymphohistiocytic dermal infiltrate (patient 4) (hematoxylin-eosin ×100).

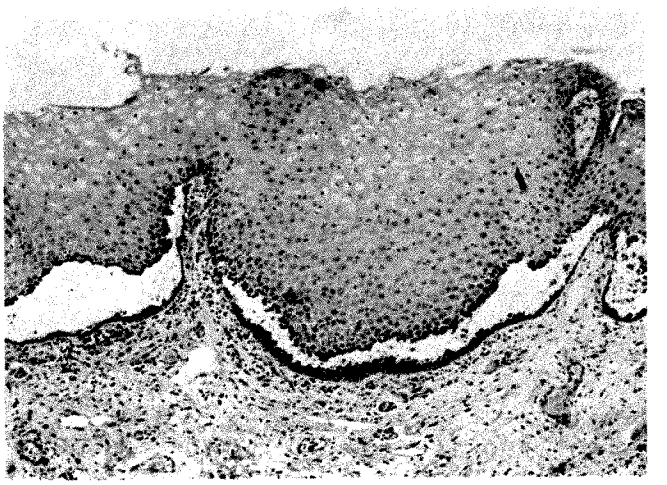

Fig 4.—Suprabasilar bulla formation with acantholysis and mixed cellular infiltrate in papillary dermis (patient 2) (hematoxylin-eosin ×100).

continued to have recurrent anal and oral lesions. Due to painful dysphagia, her weight continued to drop, and she died two months after discharge. Postmortem examination disclosed a 13-cm superficial ulceration of the pyriform sinus with microscopic sections of the dorsal tongue, pharynx, proximal esophagus and anus demonstrating suprabasilar clefting, bulla formation, acantholysis, and submucosal inflammation.

CASE 2.—A 25-year-old woman developed groups of canker sores in her mouth in April 1974, which were unresponsive to local therapy. Continued episodes of these lesions in July and August led her to consult an allergist who believed she had viral aphthae. The lesions resolved when she received a short course of systemic steroids but returned shortly after the steroids were discontinued. A two-week course on high-dose systemic prednisone tapered to 10 mg/day for two additional weeks and eventually 10 mg every other day for two months caused only a short-term remission. Adjunctive therapy with nystatin oral solution, triamcinolone acetonide in water/oil base, and tetracycline hydrochloride mouthwash gave only transient relief.

In January 1975, her oral lesions flared and vaginal ulcerations developed. An estrogen-dominant birth control pill was substituted into her regimen. By March, a severe exacerbation occurred with the development of ulcerative desquamation of her tongue and buccal mucosa and a weight loss of 6.7 kg. Indirect IF, performed in March, demonstrated the presence of ICS

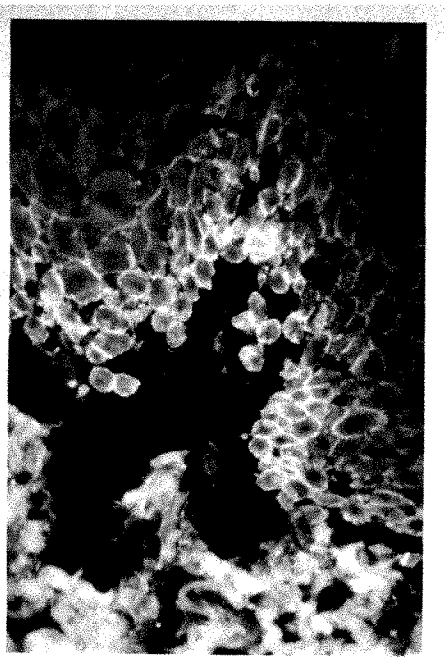

Fig 5.—Direct IF staining of pemphigus oral mucosal lesion demonstrating ICS deposition of C3 (patient 2) (×200).

Fig 6.—Direct IF staining of pemphigus oral mucosal lesion demonstrating ICS deposition of IgA (patient 6) (×200).

antibodies, titer of 320. With a tentative diagnosis of pemphigus vulgaris, the patient was referred for further evaluation.

Examination at the Mayo Clinic revealed bullae and erosions of the dorsal tongue, lower lip, buccal mucosa, and the tonsillar pillars with focal areas of white membranous exudates on the tongue.

Histopathologic examination of a fresh bulla from the oral mucosa was diagnostic of pemphigus vulgaris. A mucosal specimen studied by the direct IF examination demonstrated epidermal intercellular deposits of IgG, IgM, C3, and fibrin. Serum for indirect IF demonstrated ICS antibodies with a titer of 160. Cultures from the mouth produced normal flora. A CBC was normal with a leukocyte count of 4,900/cu mm. The differential cell count showed 11.5% eosinophils but was otherwise normal. Results of other studies, including urinalysis, chest x-ray film, serologic test for syphilis, lupus erythematosus clot test, and ESR, were within normal limits.

The patient began a regimen of prednisone, 50 mg/day, and tapered at 2.5 mg/wk until a dose of 20 mg/day was reached, whereupon the dose was increased to 50 mg every other day and tapered over the ensuing year to 10 mg every other day. As of April 1976, there have been no recurrent lesions, and her most recent test for indirect IF antibodies was negative.

CASE 3.—A 44-year-old man came to the Mayo Clinic in September 1973 with a 15-month history of recurrent oral lesions that appeared at varying intervals and tended to resolve spontaneously over periods of one to two weeks. He denied any history of cutaneous, ocular, nasal, genital, or anal lesions and volunteered that the only exacerbating factor was the ingestion of hot foods.

On examination he was found to have superficial blisters on the soft palate and buccal mucosa without evidence of other lesions.

Biopsy specimens of fresh bullae obtained from the oral mucosa were interpreted histopathologically as showing suprabasilar, acantholytic bullae consistent with pemphigus vulgaris. Sections examined by direct IF showed deposits of IgG, IgA, IgM, and C3 in the ICS. Indirect IF was negative at that time but became positive within a month. Results of other tests, including chest x-ray film, CBC, serologic test for syphilis, ESR, urinalysis, serum electrolytes, serum total thyroxine, and viral culture of the oral lesions, were normal or negative.

The patient began a regimen of prednisone, 60 mg every other day and tapered to a dose of 25 mg every other day within four weeks of the time of diagnosis. During that month he experienced a single, recurrent 3-mm ulceration of the soft palate. A second indirect IF titer to ICS was 80. By January 1974, his prednisone dose had been tapered to 15 mg every other day with a slight rise in his indirect IF titer to ICS of 80 with no notable change in his disease status. From January 1974 until January 1975, he was maintained at 10 mg prednisone every other day with the occasional occurrence of palatal ulcerations usually related to trauma. By April 1975, his prednisone was discontinued, and he has remained free of lesions in spite of persistent titers of ICS antibodies on indirect IF in the range of 80 to 160.

MATERIALS AND METHODS

Biopsy specimens from all patients were obtained from the edge of a fresh lesion and were studied after fixation and staining by routine light microscopy. Half of the specimen, however, was frozen in liquid nitrogen and stored at −70 C. Direct IF staining, performed by previously outlined methods,[5-7] was carried out using monospecific labeled goat antisera to IgG, IgM, IgA, C3, and fibrin. All conjugated antisera were checked for specificity and sensitivity by both immunoelectrophoresis and double immunodiffusion. Antibody protein assays, units of antiserum, and fluorescein to protein ratios conformed to previous standards.[5-7] The dilutions at which the various antisera were used varied depending on results of the latter tests.

Rabbit antiserum to human factor B was prepared and assayed according to the method of Götze and Müller-Eberhard.[10] Antiserum to human properdin was prepared in a goat after properdin was isolated according to the method of Pensky et al.[11] Some biopsy specimens were stained for the presence of C1q, C4, factor B, and properdin by means of modified indirect IF techniques.[12]

Venous blood for indirect IF was collected under sterile conditions, separated, aliquoted, and stored at −20 C until tested. The indirect IF staining was performed on monkey esophageal sections with use of monospecific conjugated antiserum against human IgG at a concentration of 0.25 units/ml. Details of this procedure have also been outlined elsewhere.[5-7] In nine of the ten patients, serial indirect IF studies were obtained during a follow-up period of one month to seven years.

RESULTS

Table 2 summarizes the histopathologic and IF data on the ten patients. By routine histopathologic evaluation, the biopsies of eight patients were consistent with the diagnosis of pemphigus vulgaris, as depicted in Fig 3 and 4. In two patients (5 and 10), the specimens were interpreted as nonspecific. The direct IF test performed in nine of the ten patients at the time of their initial evaluation demonstrated ICS deposition of immunoglobulins and/or complement components and fibrin in the lesional mucosal epithelium (Fig 5 and 6). In one patient, the direct IF was initially performed six years after the onset of the disease and demonstrated ICS deposition of C3 and fibrin. The immunoglobulin IgG alone or in combination with other immunoglobulins (IgA and IgM) was present in seven patients. All biopsies demonstrated ICS deposition of C3, three of which showed binding of C3 in the absence of immunoglobulins. In three patients, the binding of C1q and/or C4 and in one patient the binding of factor B and properdin was apparent, while deposition of fibrin occurred in three specimens.

At the time of the initial evaluation, circulating serum antibodies reactive with the ICS were present in eight patients. Of the two remaining patients who had negative indirect IF at that time, serum samples from one patient subsequently became positive two months later.

The initial titers of ICS antibodies ranged between 20 and 320, the majority being 80 or greater (Table 2). Also outlined are the subsequent titers of ICS antibodies of nine

patients collected throughout the course of their illness and used to monitor their disease activity and their therapeutic response.

COMMENT

Oral mucous membrane involvement is a common manifestation that affects two of three patients with pemphigus vulgaris.[1] As previously mentioned, it is the area of initial involvement of the disease in over half of the cases.[1,2] Similarly, the oral mucosa is often the site of recalcitrant lesions persisting when otherwise successful control of generalized cutaneous pemphigus is achieved by steroid or immunosuppressive therapy.[13] One common explanation for this phenomenon is the constant exposure of the oral cavity to repeated trauma. Hashimoto and Lever[14] suggested that the relative abundance of ICS in the oral mucosa as compared to the skin may enhance the binding of circulating antibodies to the ICS of this tissue. Also, specific junctions, such as gap junctions and desmosomes, are inferior in development and number in mucous membranes when compared with normal skin. Cellular adhesion in the mucosal area, therefore, may be more dependent on nonspecific junctions and more susceptible to the acantholytic process.[15]

Pemphigus of the oral mucosa and/or mucous membranes without associated or subsequent cutaneous involvement is rare.[16,17] It is unlikely that the ten patients described here comprise such a subgroup of pemphigus vulgaris. It is more probable that the absence of cutaneous lesions in these patients represents an induced dormancy in the usual relentless progression of this disease due to early diagnosis and prompt initiation of treatment. It is possible that many cases of pemphigus are not recognized by the physician in the early, mucosal stage.

The rare limitation of pemphigus vulgaris to the site of its most common initial involvement may reflect the inadequacy of the usual diagnostic tools at such an early stage of the disease. The difficulties of histologic evaluation due to secondary alterations of the histologic lesions has been mentioned.[18] The Nikolsky sign is often not present,[16] as was the case in our patients, and the cytologic examination is of rather limited value due to the transient nature of intact bullae on mucosal surfaces.

Although the clinical picture of persistent, painful erosions, ulcerations, and sometimes blisters in the oral cavity, associated with a histologic picture of intraepidermal, acantholytic clefting, certainly suggests oral pemphigus vulgaris, confirmation of this diagnosis by direct and/or indirect IF provides strong support for an aggressive therapeutic approach necessary to bring the disease under control before generalized cutaneous lesions develop.

Biopsy specimens for direct IF from perilesional mucosa were positive in all patients tested. In vivo bound C3 was present in all specimens including those from patients already treated with systemic corticosteroids as well as from lesions of untreated patients that had been present for up to 15 months.

The predominant immunoglobulin found on direct IF was IgG, once alone, three times in conjunction with IgM, and four times with IgA.

Two additional patients with oral pemphigus vulgaris not included in the study because of subsequent cutaneous involvement also demonstrated oral mucosal IgA deposition on direct IF. The much higher frequency of IgA bound to the ICS in oral mucosa in contrast to the skin might be explained by the high concentrations of locally synthesized IgA in this tissue.[19] Whether the IgA observed in oral pemphigus lesions represents ICS antibodies of the IgA type or not remains to be determined.

Indirect IF has also proved to be a valuable adjunct in the diagnosis of pemphigus vulgaris. Nine of our ten patients demonstrated positive titers on initial evaluation, seven of which remained positive on subsequent examinations. In contrast with the findings of Bean et al,[8] Tuffanelli,[20] Ryan,[21] and Nisengard et al,[22] who suggested that ICS antibodies are often not detectable in the sera of patients with early disease or minimal involvement such as oral lesions, the indirect IF data on our patients indicate that this frequency of positive values is much higher.

Several authors[20,22,23] have demonstrated the importance of serial indirect IF studies in monitoring the disease activity of pemphigus vulgaris. In our cases of pemphigus vulgaris a pronounced correlation between disease activity and indirect IF titer was noted only in those patients who were examined monthly for prolonged periods of time.

This investigation was supported in part by research grant AI 12049 from the National Institutes of Health and by a grant from the Dermatology Foundation.

Nonproprietary Names and Trademarks of Drugs

Betamethasone valerate–*Valisone.*
Clindamycin–*Cleocin.*
Corticotropin–*Acthar, Cortrophin, Cortrophin Zinc.*
Gold sodium thiomalate–*Myochrysine.*
Hydroxyzine hydrochloride–*Atarax, Vistaril IM.*

References

1. Lever WF: *Pemphigus and Pemphigoid.* Springfield, Ill, Charles C Thomas Publisher, 1965.
2. Pisanti S, Sharav Y, Kaufman E, et al: Pemphigus vulgaris: Incidence in Jews of different ethnic groups, according to age, sex, and initial lesion. *Oral Surg* 38:382-387, 1974.
3. Eversole LR, Kenney EB, Sabes WR: Oral lesions as the initial sign in pemphigus vulgaris. *Oral Surg* 33:354-361, 1972.
4. Beutner EH, Jordon RE: Demonstration of skin antibodies in sera of pemphigus vulgaris patients by indirect immunofluorescent staining. *Proc Soc Exp Biol Med* 117:505-510, 1964.
5. Beutner EH, Chorzelski TP, Jordon RE: *Autosensitization in Pemphigus and Bullous Pemphigoid.* Springfield, Ill, Charles C Thomas Publisher, 1970.
6. Jordon RE, Trifthauser CT, Schroeter AL: Direct immunofluorescent studies of pemphigus and bullous pemphigoid. *Arch Dermatol* 103:486-491, 1971.
7. Jordon RE: Immunohistopathology of the skin, in Rose NR, Friedman H (eds): *Manual of Clinical Immunology.* Washington, DC, American Society for Microbiology, 1976, pp 701-709.
8. Bean SF, Alt TH, Katz HI: Oral pemphigus and bullous pemphigoid. *JAMA* 216:673-674, 1971.
9. Hasler JF: The role of immunofluorescence in the diagnosis of oral vesiculobullous disorders. *Oral Surg* 33:362-374, 1972.
10. Götze O, Müller-Eberhard HJ: The C3-activating system: An alternate pathway of complement activation. *J Exp Med* 134:90s-108s, 1971.
11. Pensky J, Hinz CF Jr, Todd EW: Properties of highly purified human properdin. *J Immunol* 100:142-158, 1968.
12. Jordon RE, Schroeter AL, Good RA, et al: The complement system in bullous pemphigoid: II. Immunofluorescent evidence for both classical and alternate pathway activation. *Clin Immunol Immunopathol* 3:307-314, 1975.
13. Grupper MC: Pemphigus gingival. *Bull Soc Franc Dermatol Syphilol* 73:128-130, 1966.
14. Hashimoto K, Lever WF: An electron microscopic study on pemphigus vulgaris of the mouth and the skin with special reference to the intercellular cement. *J Invest Dermatol* 48:540-552, 1967.
15. Hashimoto K: Electron microscopy and histochemistry of pemphigus and pemphigoid. *Oral Surg* 33:206-219, 1972.
16. Katzenellenbogen I, Sandbank M: Beitrag zum Pemphigus vulgaris der Mundschleimhaut. *Der Hautarzt* 10:363-366, 1959.
17. Sidi E, Melki GR: Le pemphigus buccal. *Gazetta Medica Portuguesa* 10:102-112, 1957.
18. Perry HO: Skin diseases with mucocutaneous involvement. *Oral Surg* 24:800-807, 1967.
19. Tomasi TB: *The Immune System of Secretions.* Englewood Cliffs, NJ, Prentice-Hall, Inc, 1976, pp 6-12.
20. Tuffanelli DL: Cutaneous immunopathology: Recent observations. *J Invest Dermatol* 65:143-153, 1975.
21. Ryan JG: Pemphigus: A 20-year survey of experience with 70 cases. *Arch Dermatol* 104:14-20, 1971.
22. Nisengard RJ, Jablonska S, Beutner EH, et al: Diagnostic importance of immunofluorescence in oral bullous diseases and lupus erythematosus. *Oral Surg* 40:365-375, 1975.
23. Peck SM, Osserman KE, Weiner LB, et al: Studies in bullous diseases: Immunofluorescent serologic tests. *N Engl J Med* 279:951-958, 1968.

Treatment of Psoriasis With Long-Wave Ultraviolet Light

John A. Parrish, MD

• Repeated exposures of 4 by 5-cm sites to erythemogenic doses (20 to 300 joules/sq cm) of long-wave ultraviolet light (UV-A; 320 to 400 nm) led to improvement of the psoriasis vulgaris condition in nine of ten patients treated. Comparison studies showed the therapeutic responses to be similar to that of daily sunburn spectrum (UV-B; 290 to 320 nm) radiation. This finding suggests that the therapeutic response spectrum for psoriasis may parallel the action spectrum for delayed erythema of all portions of the ultraviolet spectrum that pass through psoriatic scale.

(*Arch Dermatol* 113:1525-1528, 1977)

For decades, clinicians have recognized that sun exposure often leads to improvement of psoriasis. Although the therapeutic action spectrum of sunlight was not known, it was thought to be within the ultraviolet spectrum. In order that "the response to light should be more prompt and the involution (of psoriasis) more rapid," Goeckerman[1] in 1925 tried adding various photosensitizers before deciding on crude coal tar. Since that time, the combined use of coal tar and its derivatives with ultraviolet light has been a standard treatment for psoriasis. The action spectrum for augmented delayed erythema caused by the photosensitizing tar products is within long-wave ultraviolet light (UV-A; 320 to 400 nm).[2,3] However, the spectral power distribution of most light sources used in Goeckerman's treatment[4,5] is such that the sunburn spectrum (UV-B; 290 to 320 nm) component delivers sufficient radiation to cause delayed erythema long before UV-A radiation could reach erythema-producing doses in the presence of the relatively weak photosensitizers in tar.[2] Clinical trials[6] and bilateral comparison studies[7,8] have confirmed that exposure to UV-B (290 to 320 nm) alone leads to improvement of psoriasis.

UV-A is therapeutic in treating psoriasis when given in quantities sufficient to cause erythema in skin that is previously sensitized with topical[9-11] or oral[7,8] psoralens. Preliminary observations in our laboratory suggested that much higher doses of UV-A (doses high enough to cause erythema from UV-A alone) might also improve the condition of patients with psoriasis.[12] To further test this hypothesis, we irradiated plaques of psoriasis vulgaris with large doses of UV-A alone. It is known that UV-A can cause delayed (8 to 20 hours after exposure) erythema in normal skin when given in exposure doses 1,000 times greater than erythemogenic doses of UV-B. Exposure doses of this magnitude and greater were used to treat small areas of psoriasis in ten patients.

MATERIALS AND METHODS

Five informed white adult patients with stable psoriasis vulgaris volunteered for the initial phase of this study. In each patient, each of three adjacent 4 by 5-cm areas within a single large psoriatic plaque were treated with either UV-B, UV-A, or psoralen and UV-A (PUVA). A fourth site within the plaque was identified as a control area. No other treatment was given during the study or for ten days before the onset of the study.

UV-B and UV-A exposures were given daily. Opaque tape was used to outline the exposure sites that were radiated at a distance of 4 inches from the source. Initial exposures of 20 millijoules/sq cm and 20 joules/sq cm, respectively, were increased by 40% each day as tolerated. PUVA treatments were given on alternate days. After completion of both UV-B and UV-A exposures, patients ingested 40 mg of methoxsalen (8-methoxypsoralen). Two hours after ingestion, the PUVA site was exposed to UV-A. Initial exposure was 2 joules/sq cm, which was increased by 1 joule/sq cm each day, as tolerated. Exposure doses were increased as just outlined as often as necessary to maintain a minimal to modest increase in delayed erythema in the treated sites when compared with the remainder of the lesions. High irradiance UV-A exposure can cause a prominent immediate erythema as well as the usually delayed (12 to 24 hours postexposure) "sunburn" response seen after UV-B exposure. The immediate erythema is transient (minutes to hours); it was the delayed erythema response that was used as a guide to determine subsequent UV-A and UV-B exposure doses. If tender erythema or edema was present, treatment was discontinued until these symptoms faded. When therapy was discontinued at the end of 17 days, patients had received 13 to 17 UV-B and UV-A exposures and seven to nine PUVA treatments. Final UV-B doses were 100 to 300 millijoules/sq cm and final UV-A doses were from 100 to 300 joules/sq cm. No UV-A treatments greater than 300 joules/sq cm were given because a single such exposure required 76 minutes. Four-millimeter punch biopsy specimens obtained from the control and UV-A treated sites were fixed with hematoxylin-eosin. Patient No. 5 refused biopsy.

To determine if a greater number of UV-A exposures would eventually lead to further improvement, an additional five patients were exposed daily to UV-A alone for 17 to 32 days using the same exposure doses as just outlined.

Light Sources

UV-B.—A bank of eight FS40 Westinghouse fluorescent bulbs was used; irradiance at 4 inches was 1 mW/sq cm of 320 to 380 nm, peaking at 312 nm (40% of irradiance was at wavelengths shorter than 320 nm).

UV-A.—A xenon-mercury arc, 1,000 W, was used with distilled water and a WG 335 Schott filter (2 mm). Irradiance at 4 inches was 65 mW/sq cm; the spectrum obtained was 320 to 380 nm. All measurable radiation of wavelengths shorter than 320 nm was less than 0.0001% of the UV-A radiation.

Accepted for publication April 27, 1977.

From the Department of Dermatology, Harvard Medical School, Massachusetts General Hospital, Boston.

Reprint requests to Department of Dermatology, Harvard Medical School, Massachusetts General Hospital, Boston, MA 02114 (Dr Parrish).

Table 1.—Comparison Study

Patient No.	Improvement After 14 to 17 Days			
	Control	Daily UV-B*	Daily UV-A†	PUVA‡ Every Other Day
1	0	50	50	100
2	0	50	75	100
3	0	75	50	100
4	0	95	95	95
5	0	75	75	100

*Twenty to 300 millijoules/sq cm each day.
†Twenty to 300 joules/sq cm each day.
‡Dose, 40 mg methoxsalen, 2 to 11 joules/sq cm.

Table 2.—Therapeutic Response to Daily UV-A Treatments

Patient No.	Improvement		No. of UV-A Treatments	Cumulative UV-A Treatments (Joules/sq cm)	Comments
	Control Site	UV-A-Treated Sites			
1	0	50	14	2,180	. . .
2	0	75	14	2,250	Striking response after third treatment, but no further improvement
3	0	50	13	1,930	. . .
4	0	95	13	1,870	History of clearing completely each summer without other therapy
5	0	75	13	1,800	Missed 4 days of therapy after eighth treatment
6	0	95	17	2,137	. . .
7	0	75	18	2,357	. . .
8	25	75	19	2,464	. . .
9	0	0	26	4,174	Generalized flare during treatment
10	0	50	32	6,980	Essentially clear at 10 treatments, then worsened

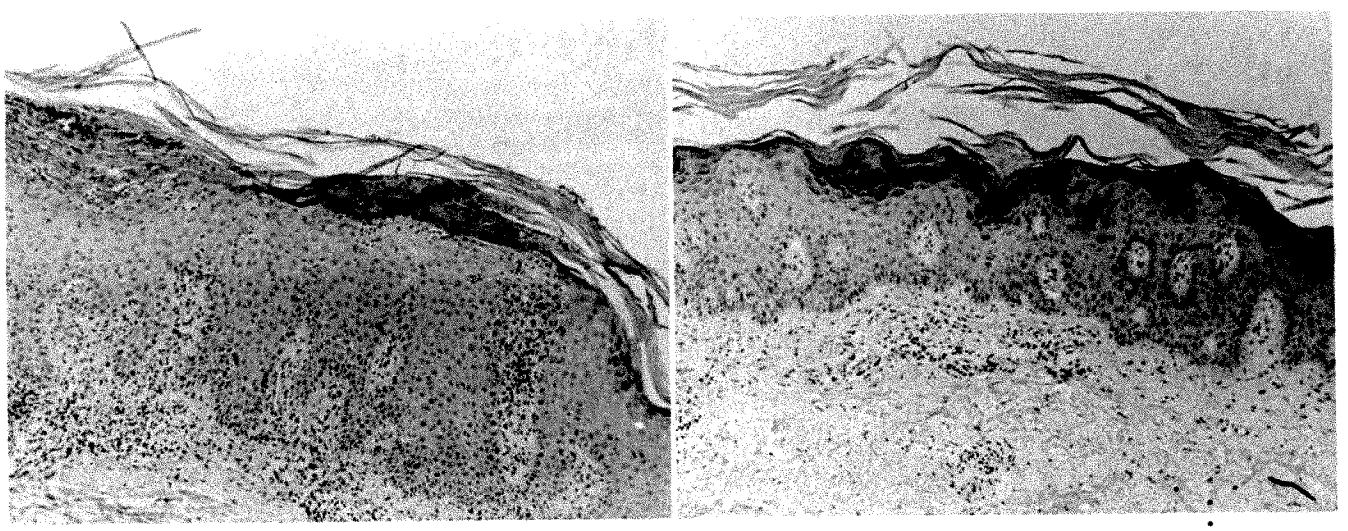

Left, Untreated site with striking parakeratosis, Monro microabscesses, and absent granular layer (hematoxylin-eosin). Right, Adjacent UV-A-treated site shows orthokeratosis, hyperkeratosis, and uniform epidermal thickening (hematoxylin-eosin).

PUVA.—A bank of eight specially designed Sylvania fluorescent PUVA lamps were used.[13] Irradiance at 4 inches was 10 mW/sq cm from 320 to 380 nm.

Instrumentation

A calibrated IL 700 research radiometer with UV-A and UV-B detectors was used to monitor the output of all ultraviolet light sources. SEE 240 (190 to 300 nm) and SEE 400 (250 to 780 nm) detectors were used with additional filters to limit spectral sensitivity. The detectors and radiometers were calibrated in mW per square centimeter traceable to the National Bureau of Standards in Washington, DC.

Improvement was graded as follows: 0 indicated not significantly improved; 50, 50% improved; moderate decrease in scaling and palpability of lesions; 75, 75% improved; significant and obvious decrease of psoriasis (the treated area has much less induration than the surrounding untreated sites); 95, only scattered 1 to 2-mm papules remain within the plaque, otherwise, the skin appears normal; 100, no clinical evidence of psoriasis.

RESULTS

Nine of ten UV-A-treated sites improved. Six sites showed 75% or greater improvement and two of these were 95% improved.

Comparison Study

The improvement noted at each treatment site is given in Table 1. In four of five patients, the sites treated with PUVA cleared completely. All of the sites treated with erythemogenic exposure doses of UV-A or UV-B improved. None cleared completely and there was no significant difference between UV-B and UV-A treatment. One patient (No. 4) was nearly clear (greater than 95% improved) in all treatment sites.

UV-A induces pigmentation within psoriatic plaques. Some of the UV-A-treated sites did not improve further after they became very tan, possibly because of the considerable screening effect of the increased melanin. As treatment progressed, UV-A-treated sites became more pigmented than PUVA-treated sites that seemed to darken only after lesions were considerably improved. UV-B-treated sites pigmented less than the other treated sites.

Continuation of Therapy

Table 2 gives the total number of treatments and final improvement grading for all patients treated with UV-A. One patient (No. 9) did not improve despite 26 treatments. He had been receiving large doses of topical steroids up until ten days before this experiment was initiated and experienced a generalized flare of his psoriasis during this experiment. The UV-A-treated site did not improve. The remaining patients improved, but the UV-A-treated sites in patients No. 6 through 10 did not improve further after the 14th treatment. In fact, the UV-A-treated site of patient 10 was nearly completely clear at ten treatments but gradually worsened during the next ten treatments and then remained unchanged. The cumulative UV-A dose for all of the patients is given in Table 2.

Histology

The histologic findings in the untreated sites were compatible with psoriasis vulgaris. Regularly elongated rete ridges separated edematous elongated papillae that bulged beneath thin suprapapular epidermis. There was loss of granular layer beneath the parakeratotic scale, and polymorphonuclear cells were seen individually and in microabscesses in the epidermis. None of the UV-A-treated sites were completely normal, but they were all substantially different from the untreated sites. In the treated sites, a prominent granular layer was present beneath a thickened orthokeratotic stratum corneum. Scattered individual cell dyskeratosis was noted. The entire epidermis was thickened but less so than in the control site and the thickening was more uniform and less psoriasiform than control sites (Figure).

COMMENT

In treating psoriasis, the beneficial effect of ultraviolet radiation is not confined to any specific portion of the ultraviolet spectrum. Ultraviolet treatment of psoriasis, with or without photosensitizers, requires exposure doses that approximate delayed erythema-producing doses. Provided adequate photons penetrate through the scale, the therapeutic response has an action spectrum similar to that of delayed erythema.

Within the range of 250 to 400 nm, the shorter wavelength end of the spectrum is more efficient at causing threshold erythema of normal, nonscaling, unpigmented skin. The higher energy associated with these photons is appropriate for absorption, photochemical alterations, and a poorly understood cascade of events resulting in altered cell metabolism and delayed erythema. Because less energy is required, light sources may be less intense, exposures of shorter duration, and less heating of skin results.

Electromagnetic radiation of wavelengths shorter than 290 nm (UV-C), however, do not sufficiently penetrate through scale, and radiation at wavelengths longer than 320 nm (UV-A) requires long exposure to high-intensity sources because much larger exposure doses are required to cause delayed erythema of normal skin. Longer wavelengths, however, penetrate more deeply through scale, pigment, and thickened epidermis. Because UV-A penetrates more deeply into the skin than does UV-B, the longer wavelengths could have more effect on blood vessels or dermal chromophores. Conventional UV-B sources offer a reasonable compromise of erythemal efficiency and penetration (absorption at depths well into the skin).

Radiation of any portion of the ultraviolet spectrum in doses well below the erythemogenic range would not be expected to have substantial, easily demonstrable cytotoxic effect on normal skin cells or to benefit patients with psoriasis. At any wavelength region, adequate exposure doses seem to be necessary. This may explain why some investigators[14,15] have found UV-B to be ineffective in treating psoriasis whereas others using larger exposure doses[6-8] have found UV-B to be beneficial. Using exposure doses of 7 to 14 joules/sq cm of UV-A, Young and van der Leun[16] found UV-A to have no effect on psoriasis in ten patients. Fischer[17] treated small areas of psoriasis with ultraviolet sources of 334- and 365-nm bands in repeated doses as high as 30 joules/sq cm without success. Using repeated doses up to 300 joules/sq cm of UV-A, we found that the psoriatic condition was improved. In our laboratory, the minimum erythema dose of the skin of white subjects to UV-A is 10 to 100 joules/sq cm.[2,18,19] Because of prolonged exposure times, the highest exposure dose of UV-A given in this study was 300 joules/sq cm. Most patients had reached this dose by the tenth to 15th treatment and were then held at this dose. It is possible that continued increase in UV-A exposure dose may have led to further improvement in the conditions of patients 6 to 10.

Most of the known cytotoxic effects of ultraviolet radiation have been documented using wavelengths shorter than 320 nm. Erythemogenic ultraviolet radiation causes a temporary reduction in the number of mitoses in epidermal basal cells and prolongation of the turnover time of the epidermis. Depression of DNA

synthesis persists for several hours after UV-B radiation in hairless mouse skin,[20] human skin,[21] microorganisms,[22,23] and cultured mammalian cells.[24,25] Inhibition of RNA and protein synthesis are also early postultraviolet irradiation effects,[20,26,27] and several enzyme activities are decreased.[28] These alterations may be related to the effect of ultraviolet irradiation on the hyperproliferative state of psoriasis.

UV-A, however, cannot be considered innocuous to cells. Relatively large exposure doses of UV-A lead to erythema and melanogenesis of normal human skin and also lead to improvement of the psoriatic condition. Many UV-A-induced cutaneous phenomena require about 1,000 times more energy than the comparable reactions by shorter ultraviolet wavelengths. At first glance this may make UV-A reactions seem less important, but it must be remembered that noonday sun on earth contains ten to 100 times more UV-A than all shorter wavelengths and this ratio may reach 1,000:1 in the early and late hours of the day. Moreover, human skin response to UV-A and UV-B may be additive[18,19] or synergistic.[29] The therapeutic effects of UV-A may also be additive or augmentative to other forms of phototherapy.

The use of UV-A alone to treat psoriasis is not presently practical. Not enough information exists about the long-term effects of repeated large exposure doses of UV-A on psoriasis or normal skin, and light sources capable of delivering total body radiation of several hundred joules per square centimeter in short time periods are not available. Thermal effects may also result from high exposure doses or high rates of delivery of ultraviolet energy given over large body areas.

Approaches that take optimum advantage of the optical properties of the more erythemogenic (and more therapeutic) shorter wavelengths and the more deeply penetrating longer wavelengths would be as follows: (1) the addition of photosensitizers that enhance the erythemogenesis and therapeutic effect of longwave ultraviolet light; (2) the development of ultraviolet treatment systems with peak emission between 310 and 330 nm as a "compromise zone;" and (3) the development of light sources that have erythemogenically balanced amounts of all wavelengths greater than 280 nm. This would require, for example, 1,000 times more energy at 365 nm than at 297 nm.

Loretta Caruso, Brian Fitzpatrick, and Timothy Kingsbury provided technical assistance.

References

1. Goeckerman WH: Treatment of psoriasis. *Northwest Med* 24:229-231, 1925.
2. Tanenbaum L, Parrish JA, Pathak MA, et al: Tar phototoxicity and phototherapy for psoriasis. *Arch Dermatol* 111:467-470, 1975.
3. Crow KD, Alexander E, Buck WHL, et al: Photosensitivity due to pitch. *Br J Dermatol* 73:220-232, 1961.
4. Zimmermann MC: Ultraviolet light therapy: Utilization of tubular fluorescent lamps in a cabinet for generalized simultaneous irradiation. *Arch Dermatol* 78:646-652, 1958.
5. Sams WM Jr: Phototherapy of psoriasis, in Pathak MA, Harber LC, Seiji M, et al (eds): *Sunlight and Man: Normal and Abnormal Photobiologic Reactions.* Tokyo, University of Tokyo Press, 1974, pp 793-798.
6. Bowers RE, Dalton D, Fudson D, et al: The treatment of psoriasis with UVB, dithranol paste and tar baths. *Br J Dermatol* 78:273-281, 1966.
7. Parrish JA, Fitzpatrick TB, Tanenbaum L, et al: Photochemotherapy of psoriasis with oral methoxsalen and longwave ultraviolet light. *N Engl J Med* 291:1207-1212, 1974.
8. Wolff K, Fitzpatrick TB, Parrish JA, et al: Photochemotherapy for psoriasis with orally administered methoxsalen. *Arch Dermatol* 112:943-950, 1976.
9. Walter JF, Voorhees JJ: Psoriasis improved by psoralen plus black light. *Acta Dermatol Venereol (Stockh)* 53:469-472, 1973.
10. Tronnier H, Schule D: First results of therapy with longwave UV after photosensitization of skin, in Schenck GO (ed): *Book of Abstracts, Symposia and Contributed Papers, Sixth International Congress of Photobiology.* Bochum, Germany, Deutsch Gesellschaft für Lichtforschung, 1972, p 340.
11. Weber G: Combined 8-methoxypsoralen and black light therapy of psoriasis: Technique and results. *Br J Dermatol* 90:317-323, 1974.
12. Parrish JA, Caruso L: The effects of UV-A on psoriasis. Presented at fourth annual meeting of the American Society for Photobiology, Feb 16-20, 1976, in *Program and Abstracts,* p 110.
13. Levin RE, Parrish JA: Phototherapy of vitiligo. *Lighting Design Application,* March 1974, pp 35-43.
14. Young E: Ultraviolet therapy of psoriasis: A critical study. *Br J Dermatol* 87:379-382, 1972.
15. Stern WK, Kihiczak G: Photobiology of psoriasis: Wavelength dependence. *Arch Dermatol* 109:502-505, 1974.
16. Young E, van der Leun JC: Treatment of psoriasis with longwave ultraviolet light. *Dermatologica* 150:352-354, 1975.
17. Fischer T: UV-light treatment of psoriasis. *Acta Dermatol Venereol (Stockh)* 56:473-479, 1976.
18. Parrish JA, Ying CY, Pathak MA, et al: Erythemogenic properties of long-wave ultraviolet light, in Pathak MA, Harber LC, Seiji M, et al (eds): *Sunlight and Man: Normal and Abnormal Photobiologic Responses.* Tokyo, University of Tokyo Press, 1974, pp 131-141.
19. Ying CY, Parrish JA, Pathak MA: Additive erythemogenic effects of middle (280-320 nm) and long-wave (320-400 nm) ultraviolet light. *J Invest Dermatol* 63:273-278, 1974.
20. Epstein JH, Fukuyama K, Fye K: Effects of ultraviolet radiation on the mitotic cycle and DNA, RNA, and protein synthesis in mammalian epidermis *in vivo. Photochem Photobiol* 12:57-65, 1970.
21. Epstein WL, Fukuyama K, Epstein JH: Early effects of ultraviolet light on DNA synthesis in human skin in vivo. *Arch Dermatol* 100:84-89, 1969.
22. Kelner A: Growth respiration and nucleic acid synthesis in ultraviolet-irradiated and photoreactivated *Escherichia coli. J Bacteriol* 65:252-262, 1953.
23. Hanawalt PS, Setlow RB: Effect of monochromatic ultraviolet light on macromolecular synthesis in *Escherichia coli. Biochim Biophys Acta* 41:283, 1960.
24. Dendy PP, Cleaver JE: An investigation of (a) variation in rate of DNA synthesis during S-phase in mouse-L cells (b) effect of ultraviolet radiation on rate of DNA synthesis. *Int J Radiat Biol* 8:301-315, 1964.
25. Klimek M, Vlasinova M: Biologically significant doses of UV light and synthesis of DNA, RNA, and protein in L-cells. *Neoplasma (Bratisl)* 14:385-392, 1967.
26. Baden HP, Pearlman C: The effect of ultraviolet light on protein and nucleic acid synthesis in the epidermis. *J Invest Dermatol* 43:71-75, 1964.
27. Fukuyama K, Epstein WL, Epstein JH: Effect of ultraviolet light on RNA and protein synthesis in differentiated epidermal cells. *Nature* 216:1031-1032, 1967.
28. Hanke W: Enzymatische Veranderungen in der Haut nach Bestrahlung mit Ultraviolett. *Strahlentherapie* 115:124-135, 1961.
29. Willis I, Kligman A, Epstein JH: Effects of long ultraviolet rays on human skin: Photoprotective or photoaugmentative? *J Invest Dermatol* 59:416-420, 1972.

Photochemotherapy of Psoriasis Using Methoxsalen and Sunlight

A Controlled Study

John A. Parrish, MD; H. Anthony D. White, MB, BS, FRACP; Timothy Kingsbury; Mahmoud Zahar, MD; Thomas B. Fitzpatrick, MD

• Fifty-one patients with psoriasis were treated with oral methoxsalen and sunlight exposure. Twelve of these patients received either methoxsalen or placebo prior to whole-body exposure. The remainder were treated with methoxsalen and sunlight to one side of the body and sunlight alone to the other. The conventional dose of methoxsalen (0.6 mg/kg) was compared with a low dose (0.3 mg/kg). Oral methoxsalen when used in the higher dose followed by sun exposure is an effective treatment for psoriasis. Accurate ultraviolet dosimetry is essential to avoid phototoxic burns. The advantages and disadvantages of solar photochemotherpy are discussed.

(*Arch Dermatol* 113:1529-1532, 1977)

Photochemotherapy using orally administered psoralens and subsequent exposure to longwave ultraviolet light (UV-A, 320 to 400 nm) has been shown to be effective in the treatment of psoriasis vulgaris.[1] This drug and light combination has been termed PUVA (psoralen and UV-A).[2] Using methoxsalen (8-methoxypsoralen) and specially designed artificial sources of UV-A,[3] comparison studies have shown PUVA to be more effective in the treatment of psoriasis than ultraviolet light alone.[1-4] This study explores the potential of using sun as the source of ultraviolet radiation for oral psoralen photochemotherapy. Because sun exposure itself is often beneficial to psoriasis, psoralen + UV-A from the sun (which we have termed PUVASOL) was compared to sun exposure alone in a placebo study and in a bilateral comparison study.

Accepted for publication April 27, 1977.

From the Department of Dermatology (Drs Parrish, White, Fitzpatrick, and Mr Kingsbury), Harvard Medical School, Massachusetts General Hospital, Boston, the Institute of Dermatology (Dr White), Royal Prince Alfred Hospital, Sydney, Australia, and the Military Hospital (Dr Zahar), Taif, Saudi Arabia.

Reprint requests to Department of Dermatology, Harvard Medical School, Massachusetts General Hospital, Boston, MA 02114 (Dr Parrish).

MATERIALS AND METHODS

Patient Selection

Fifty-one white volunteers with chronic, stable, or flaring psoriasis covering 10% to 75% of their body were treated. No patients with erythrodermic or pustular psoriasis were included in the trial. No pregnant patients or persons with known photosensitivity were permitted in the study. Although several patients had been receiving methotrexate or steroids for systemic effect in the past, patients were not permitted to use antipsoriatic medications for systemic effect, topical or oral steroids, or known photosensitizing medications during the course of this study. No topical medications except for emollients and conventional scalp applications were permitted throughout this study. When lubricants were permitted, they were used on both sides of the body in the bilateral comparison studies. Laboratory evaluation was carried out before, during, and after the study, and included hematocrit readings, hemoglobin levels, WBC count, antinuclear antibody reactions, SGOT levels, alkaline phosphatase values, bilirubin levels, and microscopic examination of urine. Informed consent was obtained.

Treatment Groups

Group 1 was a double-blind psoralen-placebo study (12 patients). Group 2 was a bilateral comparison study; a higher dose of methoxsalen was used (approximately 0.6 mg/kg). There were two subgroups within group 2: A, alternate-day PUVASOL vs alternate-day sun treatment for six patients; B, alternate-day PUVASOL vs daily sun treatment for 11 patients. Group 3 was a bilateral comparison study; a lower dose of methoxsalen was used (approximately 0.3 mg/kg). Within this group there were three subgroups: A, alternate-day PUVASOL vs alternate-day sun treatment for four patients; B, alternate-day PUVASOL vs daily sun treatment for three patients; C, daily PUVASOL vs daily sun treatment for ten patients.

Patients in the double-blind study were randomly assigned to receive methoxsalen or a placebo capsule. In this group, ingestion of medication was followed by sun exposure of the whole body every other day (or three times each week). In the bilateral comparison studies, while one side of the body was being treated, the other side was shielded with folded sheets or black cloth taped at the midline. The front and back of the same side were treated identically by having the patient first lie in a supine position and then in a prone position. On days when both PUVASOL treatment and sun treatment were to be given, the latter was given first, the exposure ending about one hour before zenith. After completion of the sun treatment, patients ingested psoralen and were kept out of the sun for two hours before they began their PUVASOL exposure about one hour after zenith. Because of the danger of cumulative phototoxic reactions, PUVASOL was never used at the higher methoxsalen dose more frequently than every alternate day. At the lower drug dose, daily PUVASOL treatments were compared to daily sun treatments (group 3, C).

Drug Dose

Ten-milligram capsules of methoxsalen were given according to the patient's weight. In groups 1 and 2, patients weighing up to 50 kg body weight received 20 mg; those weighing from 51 to 65 kg body weight received 30 mg; those weighing from 66 to 80 kg body weight received 40 mg; and those heavier than 80 kg body weight received 50 mg. In group 3, patients weighing up to 66 kg body weight received 10 mg, and those heavier than 66 kg body weight received 20 mg.

Solar Exposure Doses

The time between ingestion of methoxsalen and the initiation of sun exposure was two hours. All exposures took place under controlled, observed conditions between 10 AM and 3 PM, standard time,

during the summer months. Twenty-eight patients were treated in Boston (latitude 42° 21'N) between June and August, and 23 patients in Sydney, Australia (latitude 33° 5'S), between January and April. The duration of sun exposure was estimated for each patient according to their individual characteristics and according to the ultraviolet flux prevailing at the time of exposure. Initial exposure times were based on complexion, degree of pigmentation, individual sunburn and suntan histories, and in some patients, on actual minimal erythema dose and minimal phototoxic dose testing. At the outset, identical exposure times (based on the highest predicted safe dose of UV-A) were given for sun alone and for PUVASOL treatments. All subsequent treatments to each side of the patient were increased independently to maintain a trace erythema. The delayed erythema response was assessed 24 hours after exposure to sunlight alone and at 48 hours after PUVASOL. Exposure doses were based on clinical judgment, and ultraviolet light meters were used to determine the duration of exposures. However, the meters used in the two centers differed in principle and calibration. The radiometer (IL700 research radiometer with PT 171C detector, UV-A filter, and cosine-corrected optics full hemispheric measurement) used in the Boston study was calibrated in milliwatts per square centimeter traceable to the National Bureau of Standards, Washington, DC. It consisted of an ultraviolet-sensitive vacuum photodiode and digital read-out amplifier. The filter-detector combination was designed to pass radiation in the 320-nm to 400-nm spectral band. The response was a bell-shaped curve peaking at 365 nm. In Sydney, the Robertson meter was used, which employs a pulse-counting technique to measure UV-A and UV-B irradiance. The meter reads in relative terms, and doses were therefore calculated from day to day as the product of time of exposure and average meter reading. Dosimetry in this combined study is therefore expressed in terms of the number of treatments rather than in absolute terms (total joules per square centimeter) and this is the basis for comparing treatment groups.

Grading of Responses

Improvement was graded by an observer who did not know the patients' treatment program, but the exaggerated melanogenic response of the PUVASOL-treated sites made blind grading impossible. At the time of each treatment, patients were evaluated and responses were graded as follows. *Essentially clear* was 95% to 100% improved. Psoriatic lesions are less than 5% of original distribution (excluding scalp, nails, or unexposed areas). *Improved* was significantly (50% to 95%) improved. In this grade, definite and obvious improvement are seen but clearing is not complete. Lesions remain minimally palpable or scaly. *Not significantly improved* was minimally (0% to 50%) improved.

In addition to this grading, one side of the body was compared with the other in the paired-comparison studies. In the double-blind placebo study, patients who were not significantly improved after three to four weeks were then treated with capsules known to contain methoxsalen. Patients in groups 2 and 3 were treated until one side had been clear for three treatments, until both sides were clear, or until 40 days were reached, whichever came first.

Results

Of the 51 patients who volunteered for this experimental treatment, five patients did not finish the study. Two patients, although initially highly motivated and showing some signs of improvement, found the treatments too inconvenient. The heat, insects, long exposure times, daily travel to the medical center, and miscellaneous difficulties with being available at midday caused them to discontinue treatment. One patient broke a bone in an unrelated accident and discontinued treatment. Two patients (Australian) discontinued therapy because of single incidents of painful phototoxic erythema. Forty-six patients completed the study and summaries of their data are given in Table 1 and 2. Owing to the uncertainties of weather, the protocol schedule of treatments (daily or second-daily) was seldom attained. Treatment times ranged from four minutes per side initially to more than 60 minutes per side as tan increased and solar ultraviolet radiation decreased.

Group 1

All of the patients in the PUVASOL group (six patients) attained the "improved" grade within four to seven treatments, whereas none of the placebo group reached this grade in five to nine treatments. The difference at this stage was sufficiently clear-cut that persistence with placebo was considered unwarranted, and a switch to PUVASOL was made in all but one patient. In the latter case, improvement with sun alone was deliberately sought by continuing to 12 treatments.

Four of the six initial PUVASOL patients had complete clearing in an average of 11.5 ± 2 treatments. The two in whom clearing failed received only seven and six treatments, respectively, because of waning summer sun and declining ultraviolet intensity. After three to four weeks (7 ± 2 treatments) of placebo therapy, the five unimproved patients were changed to PUVASOL and all subsequently improved, with three patients having complete clearing in four to 16 additional treatments.

Table 1.—Methoxsalen-Placebo Comparison Study
(Highest Improvement Grading Achieved)

	No. of Patients	
	Methoxsalen + Sun	Placebo + Sun
Essentially clear	4	0
Improved	2	1
Not significantly improved	0	5

Table 2.—Bilateral Comparison Study (no. of sid

	0.6 mg/kg body wt Methoxsalen + Sun				0.3 mg/kg body wt Methoxsalen + Sun			
Group	Treatment Frequency	Essentially Clear	Improved	Not Significantly Improved	Treatment Frequency	Essentially Clear	Improved	Not Significantly Improved
2, A	AD*	5	1	0				
2, B	AD	9	2	0				
3, A					AD	1	2	1
3, B					AD	0	3	0
3, C					D	0	10	0

* AD indicates alternate days.
† D indicated daily.

Group 2, A

In five of six patients in subgroup A of group 2, the PUVASOL-treated side cleared completely in an average of seven treatments. The sun-treated side of five of six patients improved in an average of six treatments, but no sun-treated side cleared despite continuous therapy for more than one month. After completing the bilateral comparison study, four of these patients were eventually cleared with additional total body treatments with methoxsalen and sunlight. The remaining two patients were cleared with PUVA using artificial light sources (Table 2).

Group 2, B

Nine of the 11 patients in the B subgroup in group 2 were considered essentially clear (8.5 ± 3.0 treatments) on their PUVASOL-treated sides. Two of these nine patients were also essentially clear on the sun-treated side (13 treatments). However, in the remaining seven patients, three to ten additional sun treatments given after the PUVASOL side was clear failed to clear the sun-treated side. Subsequent to the bilateral comparison study, all 11 patients were made free of psoriasis bilaterally by treating with methoxsalen and total body exposure. Sunlight was used as the source of UV-A in nine patients, and artificial UV-A light sources were used in two patients (Boston).

Group 3

Three of four patients in the A subgroup in group 3 improved significantly on both sides in eight to ten treatments and the PUVASOL-treated side was considered clear in one patient (ten treatments). No patient cleared on the sun-treated side. Although no patient in the B subgroup in group 3 cleared, all PUVASOL sides and two of three sun-treated sides showed significant improvement. In each case, improvement was judged to be more marked on the PUVASOL side. All of the ten patients in the C subgroup (daily exposure) in group 3 improved. In eight of ten patients, the PUVASOL-treated side was judged to be more improved than the sun-treated side, but no patients improved enough to be judged as essentially clear (Table 2).

When lower doses of psoralens were used, the beneficial effects appeared to be similar to that seen with sun alone. Fifteen of 17 patients improved on both sides. In addition, one patient cleared on the PUVASOL side. Because no continuing improvement was observed in any patient, the group 3 bilateral comparison experiment was discontinued after 14 to 20 PUVASOL treatments. Sixteen of the 17 patients in group 3 were subsequently treated with 0.6 mg/kg of methoxsalen and artificial light and 15 had complete clearing. A total of 32 of the patients who were not clear on at least one side at the termination of the bilateral comparison (groups 2 and 3) experiment were subsequently treated with full doses of psoralen and either sun or artificial light, and 30 were thereafter judged essentially clear.

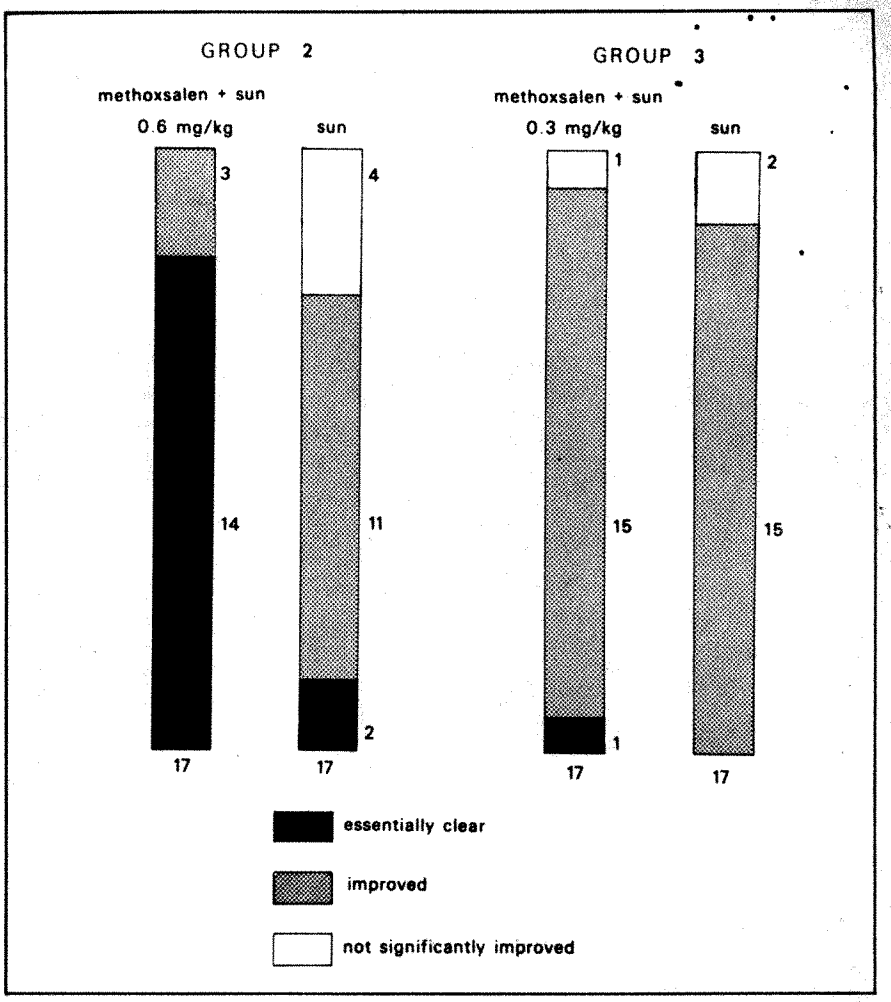

Bilateral comparison studies. Two bars on left side represent group 2 (conventional-dose (methoxsalen) patients; two bars on right represent group 3 (low-dose methoxsalen) patients. All patients, whether receiving daily or alternate-day treatments, are included in each group. Numbers refer to number of patient sides.

	Sun Alone		
Treatment Frequency	Essentially Clear	Improved	Not Significantly Improved
AD	0	5	1
D†	2	6	3
AD	0	3	1
D	0	2	1
D	0	10	0

Side Effects

Because all of the patients in the placebo study were eventually treated with methoxsalen, all 51 patients took methoxsalen at some time. Eight

patients ingesting 0.6 mg/kg of methoxsalen complained of mild nausea on at least one occasion at some point during their treatment. Severe nausea or vomiting occurred occasionally in only one patient, but this did not interrupt therapy. No patient ingesting the lower doses of methoxsalen experienced nausea. Moderate itching occurred on at least one occasion in two patients during placebo and sun therapy and in two patients receiving the lower dose of methoxsalen. Although itching occurred in five of 23 patients ingesting the higher dose of psoralen, severe itching was not a problem and never caused cessation of therapy. No ultraviolet burns occurred in the placebo group, the sun-treated sides, or the low-dose methoxsalen-treated sides. In the high-dose methoxsalen-treated sides, there were three occasions of local tender erythema and three more extensive painful erythematous responses, two of which led to patients dropping out of the study. Laboratory factors remained unchanged in all of the patients during the study.

Summary of Results

Sunlight alone is moderately good therapy for psoriasis. More than 80% of the patients' sides in the bilateral comparison studies (groups 2 and 3) improved considerably with sun therapy (Figure). Patients in group 1 (Table 1) treated with placebo and sun did not do as well as the sun-alone sides of patients in the bilateral comparison study. This difference cannot be explained by different frequencies or the total number of treatments and remains unexplained. In the bilateral study (Table 2), daily sun (83% of sides improved) was only slightly better than alternate-day sun (80% of sides improved), but two sides were considered essentially clear with daily sun therapy and no persons had complete clearing with alternate-day sun.

Low doses of methoxsalen (0.2 to 0.3 mg/kg) and subsequent sun exposure led to improvement in 94% of the patients' sides treated, with little difference in daily or alternate-day methoxsalen-sun treatment. The higher dose of methoxsalen (0.5 to 0.8 mg/kg) clearly leads to a better response to sun exposure. All of the patients treated improved substantially and 82% of the sides treated in the bilateral comparison study were judged to be essentially clear.

COMMENT

This report documents that under controlled conditions, using accurate dosimetry and adequate doses of methoxsalen, solar photochemotherapy is an effective treatment for psoriasis. The therapeutic dose of PUVA is close to the phototoxic dose. Because of this fact and because of the impossibility of accurately estimating global UV-A flux, correct dosimetry is essential. In Boston where an integrating dosimeter was used, burns were less frequent and severe than in Sydney where this type of meter was not available and where two severe burns resulted.

PUVASOL differs from artificial PUVA in that UV-B, visible light, and infrared radiation accompany the UV-A. These fractions of the electromagnetic spectrum may make a significant contribution to the erythemogenic or therapeutic effect of PUVASOL. In the present study, PUVASOL cleared four of the six (group 1) patients (whole body treated with PUVASOL placebo) in an average of 11.5 ± 2 treatments. In group 2 (split comparison, high-dose methoxsalen), 14 of the 17 patients cleared on the PUVASOL side in less than 12 treatments. These rates of clearing compare favorably with those published for artificial PUVA.

A direct comparison of PUVASOL and artificial PUVA is, however, not possible in this study in the absence of absolute ultraviolet dosimetry on all of the patients. Neither can treatment groups be compared in terms of length of exposures since solar UV-A flux varied from hour to hour. Because in all cases in the criterion for judging exposure times was the biologic response (erythema) of the subject after the previous treatment, the number of treatments remains a valid basis for comparison.

The principles of photochemotherapy are now well established.[1,2,4,5] When determining exposure doses one must consider (1) the spectral distribution of the source and how this relates to the erythema action spectrum of the skin of persons sensitized with psoralens, and (2) the intensity of the source within the erythema spectrum. This determines the duration of treatment.

In some geographic locations, the sun provides a UV-A source that requires no extra floor space, no travel to treatment centers, and no cost. However, the disadvantages are considerable and include the variability of the source due to season, or local weather factors, and time of day. In Sydney, on 26 of the 94 days, no exposures were possible due to rain or cloud. At many latitudes, exposures are feasible only during the summer. Excessive heat or cold, insects, and lack of privacy may seem to be trivial considerations, but they may result in loss of treatment days. Exposure times in the sun may be much longer than in high-intensity artificial systems. For instance, the Sylvania Phototherapy System[1,3] has more than twice the UV-A intensity of sunlight at noon in June at the equator and treats the whole body at once. Sun treatment requires that the patient receives treatments while in both prone and supine positions. Thus, the shortest possible PUVASOL treatments will be four times that of artificial sources. Exposures that are given other than at peak summer, zenith, or at the equator are lengthened further. Long treatment times extend exposures beyond the time when orally administered psoralens are most active in the skin.

Because of frequent and prolonged interruptions to the treatment schedule by weather, the investigators had opportunities of observing the response to single doses of PUVASOL. It was apparent that in many cases psoriasis would continue to clear for up to one week after one exposure. In this way, some patients had clearing in as few as five treatments. This observation has obvious therapeutic implications, and a PUVASOL trial using prolonged treatment intervals is envisioned.

Dr D. F. Robertson of the University of Queensland supplied the dosimetry equipment. Diedrich Waterman, Michael Latessa, Doffy White, Pat Lane-Brown, Beth Levin, Brian Fitzpatrick, and Loretta Caruso provided technical assistance on this project; Mr Charles Comeau, of International Light, Inc, Newburyport, Mass provided expertise; and Dr Robert Stern provided critical review and comments in the preparation of this manuscript.

References

1. Parrish JA, Fitzpatrick TB, Tanenbaum L, et al: Photochemotherapy of psoriasis with oral methoxsalen and longwave ultraviolet light. *N Engl J Med* 291:1207-1212, 1974.

2. Wolff K, Parrish JA, Fitzpatrick TB, et al: Photochemotherapy of psoriasis with oral psoralens. Read before the Society for Investigative Dermatology and the European Society for Dermatological Research, Joint Meeting, Amsterdam, Netherlands, June 9-13, 1975.

3. Levin RE, Parrish JA: Phototherapy of vitiligo. *Lighting Design Application* March 1975, pp 35-44.

4. Wolff K, Fitzpatrick TB, Parrish JA, et al: Photochemotherapy for psoriasis with orally administered methoxsalen. *Arch Dermatol* 112:943-950, 1976.

5. Swanbeck G, Thyresson-Hök M, Bredberg A, et al: Treatment of psoriasis with oral psoralens and longwave ultraviolet light: Therapeutic results and cytogenetic hazards. *Acta Dermatol Venereol (Stockh)* 55:367-376, 1975.

Smokers' Melanosis

Occurrence and Localization in the Attached Gingiva

C. Anders Hedin, DDS

• The aim was to clinically study the frequency and extension of the melanin pigmentation in the attached gingiva and its relation to tobacco smoking. The population examined consisted of patients and dental nurse students at the School of Dentistry in Umeå, Sweden. All of the patients with pigmentation proved to be tobacco smokers. The pigmentation was given the name "smokers' melanosis." Between 12.9% and 14.9% of those examined and between 25.5% and 31.0% of those who smoked had smokers' melanosis. Patients with smokers' melanosis had a significantly higher tobacco consumption than smokers without pigmentation. In 95.2%, smokers' melanosis was found in the mandible and was most common in the attached gingiva on the labial side of the canines and incisors.

Smokers' melanosis is thus considered to be caused by tobacco smoking and is expected to be found in other parts of the oral mucosa.

(*Arch Dermatol* 113:1533-1538, 1977)

Melanosis gingivae is often found in members of dark-skinned ethnic groups,[1-4] but is seldom found among white Europeans.[3,5,6] Besides melanosis gingivae caused by genetic factors, melanin pigmentation is observed in other parts of the oral mucosa. The cause can be medical drugs such as antimalarials and certain tricyclic thymoleptics.[7,8]

Several diseases are characterized by melanosis in the oral mucosa. Among them are Addison's disease, Albright's syndrome, Peutz-Jeghers syndrome, and von Recklinghausen's disease.[5] Patients suffering from periodontitis are having their oral mucosa carefully examined in connection with their periodontal treatment. To obtain a clinically correct picture of the gingival inflammation, the color differences appearing in different parts of the attached gingiva are registered. During such examinations, a brown discoloration of parts of the interdental papillae and the attached gingiva was observed in patients visiting the Department of Periodontology at the School of Dentistry in Umeå, Sweden.

Histological studies showed that the pigmentation consisted of melanin. Literature states that a maximum of 6% of the population among white Europeans have some kind of pigmentation in the oral mucosa.[4,9,10] There seemed to be a difference in frequency between the literature reports and the Umeå patient group. There also seemed to be a connection between smoking and melanosis in the attached gingiva.

Accepted for publication April 19, 1977.

From the Department of Periodontology, School of Dentistry, University of Umeå, Sweden.

Reprint requests to Department of Specialist Dentistry, Centrallasarettet Eskilstuna, S-631 88 Sweden (Dr Hedin).

AIM OF INVESTIGATION

The aim of the investigation was to clinically study the frequency and extension of the melanin pigmentation that was found to be localized to the attached gingiva and to study its relation to smoking.

MATERIALS AND METHODS
Part 1

To study the frequency of melanin pigmentation in the attached gingiva, 121 patients (53 men and 68 women) were randomly picked from the patients referred to the Department of Periodontology in 1974 (Fig 1). The periodontal diagnosis of these patients varied between gingivitis and periodontitis complicata. To study the frequency of melanin pigmentation in the attached gingiva in persons with good gingival conditions, 93 female dental nurse students were examined. They were all the students in three subsequent courses of dental nurse education in Umeå. Their average age was 21.1 years (SD = 3.5) and as a rule, the conditions of their gingivae were excellent, although minor areas of erythema and edema corresponding to the diagnosis gingivitis, were observed.

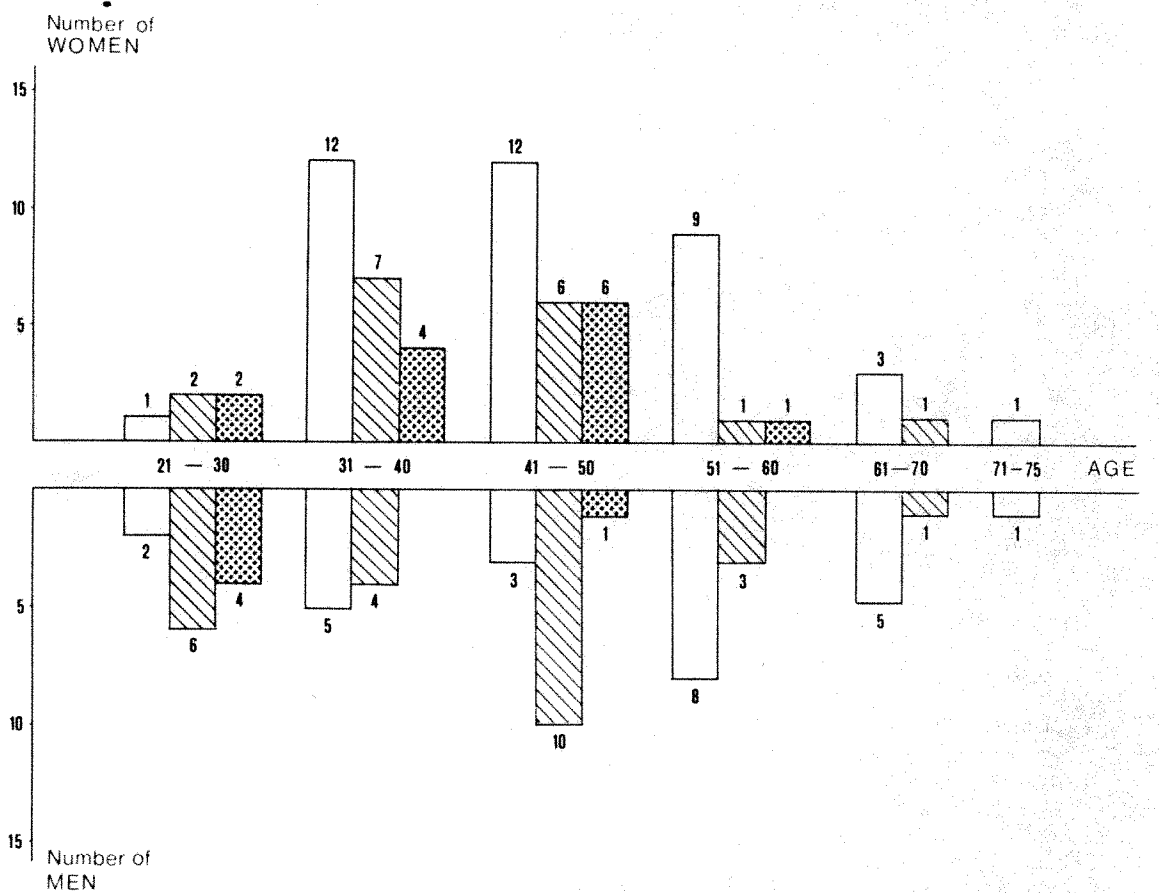

Fig 1.—Age and sex distribution among 121 patients randomly picked out from patients visiting Department of Periodontology, School of Dentistry, Umeå, Sweden. Nonsmokers without smokers' melanosis consisted of 38 women, 24 men. Smokers without smokers' melanosis consisted of 17 women, 24 men. Smokers with smokers' melanosis consisted of 13 women, 5 men. Clear bar indicates nonsmokers without pigmentation; bar with diagonal lines, smokers without pigmentation, dotted bar, smokers with pigmentation.

Part 2

To study the localization of the pigmentation and the connection with smoking in a greater number of patients with pigmentation, 71 patients (48 women and 23 men) with melanosis in the attached gingiva were picked from the patients visiting the Department of Periodontology during a one-year period (Fig 2).

State of health, medicine consumption, and smoking were noted in the case history of the patient. Color of eyes and hair was noted for the students in part 1 and for the patients in part 2. Frequency and extension of pigmentation of the attached gingiva were clinically registered in diagrams and in color photographs. Amalgam tattoos could be ruled out through their gray blue color, their position near amalgam restorations, and the fact that radiopaque substances could often be observed in the pigmentation area.[11] In connection with periodontal surgery, biopsy specimens from the attached gingiva were obtained from the patients in part 1 of the investigation.

Statistical calculations of cigarette consumption were carried out with Student's t test. The clinical extension of the pigmentation was calculated with the aid of the Sign test. The generally accepted significance levels were used.

RESULTS

Frequency of Pigmentation

Part 1.—Among the 121 patients in part 1, 18 patients (five men and 13 women [14.9%]) had melanin pigmentation in the gingiva (Fig 1). Among the 93 female students, there were 12 students (12.9%) with melanin pigmentation in the gingiva.

All of the patients and students declared that they were healthy. Their medicine consumption is given in Table 1.

Histology

The histological study of the pigmentation was performed on tissue taken from the 18 patients with pigmentation in part 1 of the investigation. In histological stains, it was evident that in the pigmented gingiva heavy silver stain (Masson-Fontana) was deposited in the basal layer of the epithelium (Fig 3) as well as in the higher cell layers (Fig 4). DOPA staining showed a high number of enzymatically active melanocytes in the basal layer (Fig 5). Electron microscopy showed premelanosomes and melanosomes in the melanocytes and compound melanosomes distributed to the keratinocytes (Fig 6). It was concluded that the clinically registered brown discoloration of the attached gingiva consisted of melanin. Studies of tissue from nonpigmented parts of the gingiva or from patients without clinical pigmentation showed minor traces of melanin in the basal cell layer.

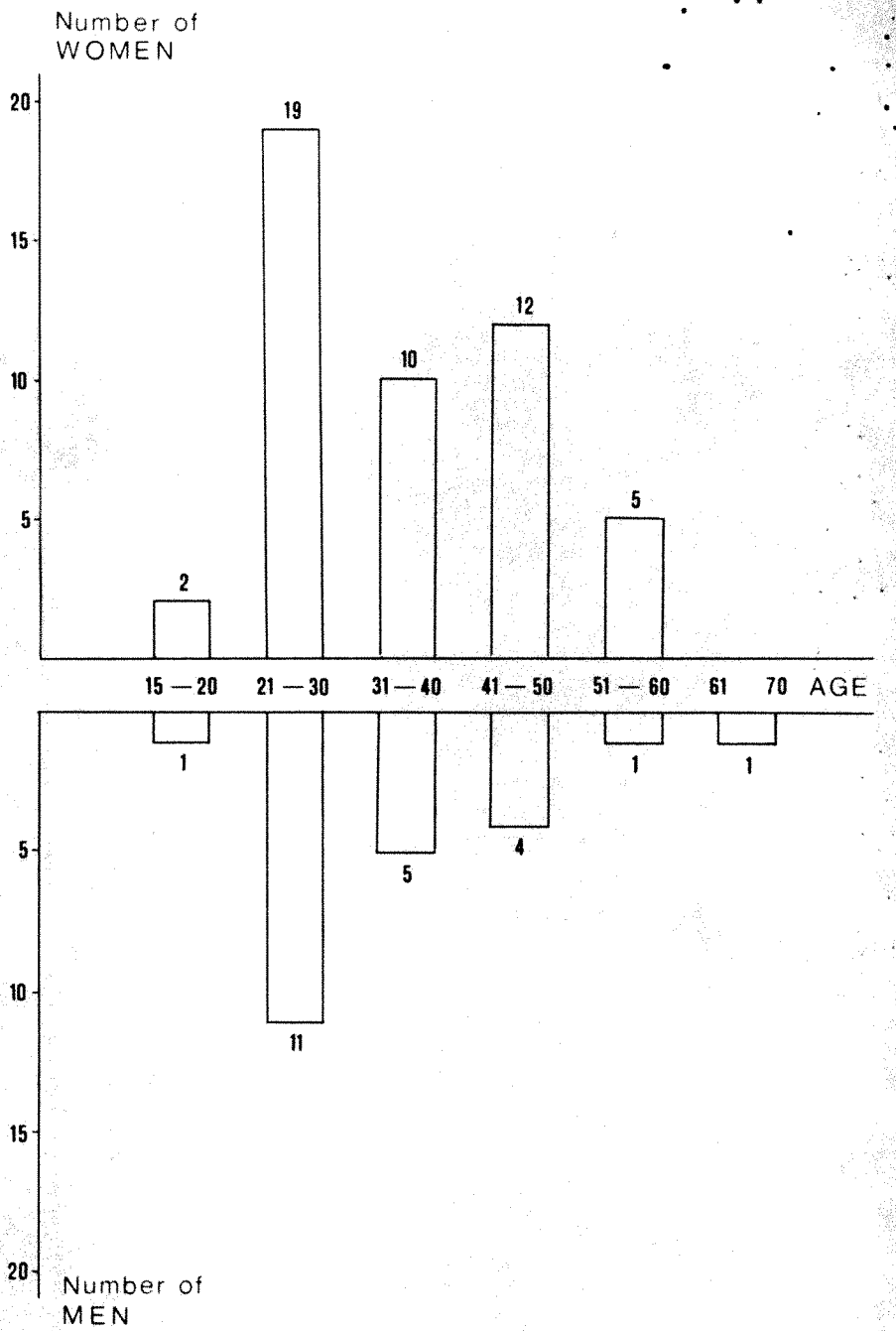

Fig 2.—Age and sex distribution among 71 patients (48 women and 23 men) with smokers' melanosis. During one year, all patients with smokers' melanosis were selected from patients visiting Department for Periodontology, School of Dentistry, Umeå, Sweden.

Localization

The least-extended pigmentation was localized to the central part of one or two solitary interdental papillae (degree I). Often it was the papillae between the canines and the nearest incisors that showed this degree of pigmentation (Fig 7). When the pigmentation was somewhat more extended, pigmentation of more numerous solitary interdental papillae was observed (degree II). At a more comprehensive extension, isolated pigmented areas had converged into short continuous ribbons (degree III) or into one long continuous ribbon that included the greater part of the gingiva in front of the canines and incisors (degree IV, Fig 8). The different degrees of pigmentation are shown graphically in Fig 9. Among 83 persons with pigmentation who were in parts 1 and 2 of the investigation, degree I was found among 21 (25.3%). Degree II was found among 25 (30.1%), degree III among 20 (24.1%), and degree IV among 17 (20.5%). The pigmentation was always localized to the attached gingiva and thus, the apical extension did not exceed the mucogingival junction (Fig 10). The free gingiva did not show pigmentation and pigmentation was not observed in the lingual or palatal part of the gingiva.

In 42 (50.6%) of the students and patients in part 2 of the investigation, pigmentation was found only in the mandible, whereas in 39 (47.0%) pigmentation was found both in the mandible and in the maxilla. In two (2.4%) pigmentation was found only in the maxilla. Thus, melanin pigmentation in the attached gingiva is most common in the mandible ($P < .001$). In 33 (84.6%) students and patients with pigmentation, the pigmentation in the maxilla was found within a sector of the attached gingiva, laterally confined by the gingiva on the labial side of the maxillary canines. In six (15.4%) of those with pigmentation, the pigmentation was also found in the premolar areas. In 68 (84.0%) of those with pigmentation in the mandible, the pigmentation was localized to the sector of the attached gingiva that is laterally confined by the gingiva on the labial side of the mandibular canines. In 12 (14.8%), the

Table 1.—Medication Used by Persons With Smokers' Melanosis in Parts 1 and 2 of the Investigation

Part	Medication*	No. of Persons
1	Tricyclic antidepressants (amitriptyline hydrochloride) + Antipsychotic drugs (perphenazine) +	1‡
	Anticholinergic drugs (Veryl†)	1
	Hormonal contraceptives female +	8
	Vitamins	1
2	Thymoleptic drugs (imipramine hydrochloride)	1
	Anticholinergic drugs (hyoscyamine sulfate [Egazil])	1
	Myalgic drugs (chlorzoxazone [Paraflex])	2
	Sulfonamides	1
	Hormonal contraceptives, female +	2
	Vitamins	1

*Drugs that according to the literature are known to give increased skin pigmentation are marked with a plus sign.
†Veryl is a Swedish trademark for a methylscopolamine nitrate and barbiturate mixture.
‡Same person used both medications.

UNIVERSITY OF MEDICINE LIBRARY

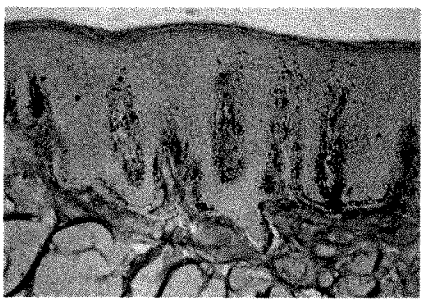

Fig 3.—Pigmented gingival tissue from patient with smokers' melanosis. Heavy accumulation of silver stain in basal cell layer of epithelium points to melanin (Masson-Fontana, van Gieson, original magnification ×175).



Fig 4.—Pigmented gingival tissue from patient with smokers' melanosis. Silver stain has deposited in keratinocytes through prickle cell layer, granular layer, and cornified layer, pointing to melanin (Masson-Fontana, van Gieson, original magnification ×450).

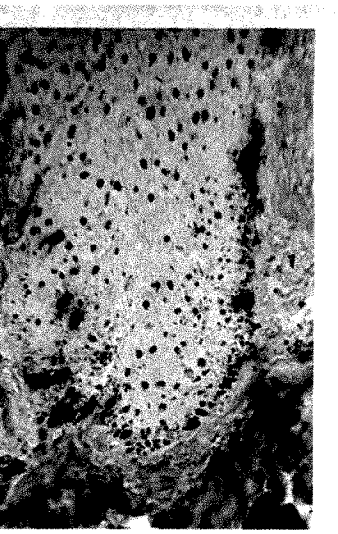

Fig 5.—Pigmented gingival tissue from patient with smokers' melanosis. DOPA stain shows enzymatically active melanocytes in basal layer of epithelial ridge (DOPA, eosin, original magnification ×250).

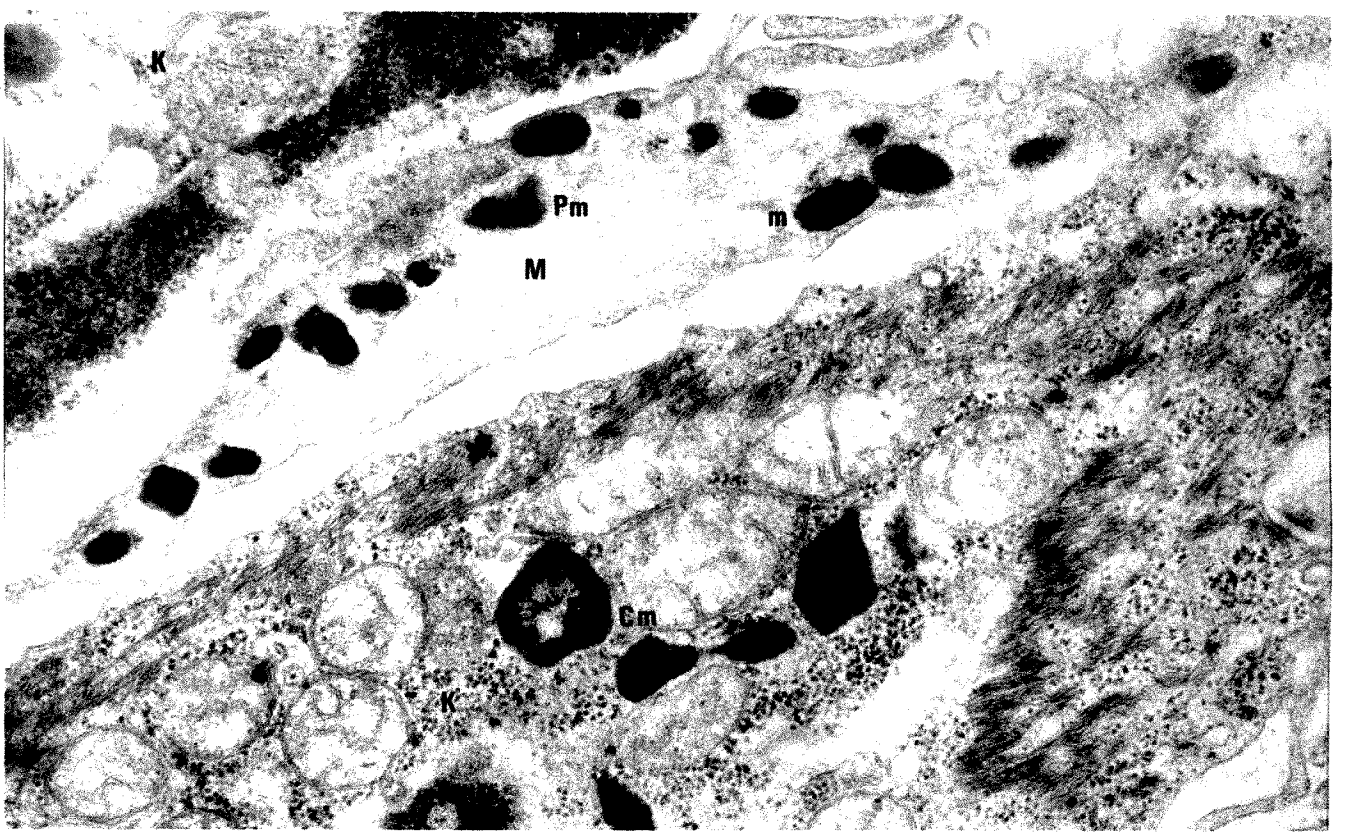

Fig 6.—Pigmented gingival tissue from patient with smokers' melanosis. Dendrite of melanocyte (M) is extending between two keratinocytes (K). Dendrite contains premelanosomes (Pm) and melanosomes (m). One keratinocyte contains compound melanosomes (Cm) (original magnification ×35,200).

Fig 7.—Degree I of smokers' melanosis. Moderately brown pigmentation can be seen in papilla medial to canines. This picture shows most common localization of smokers' melanosis.

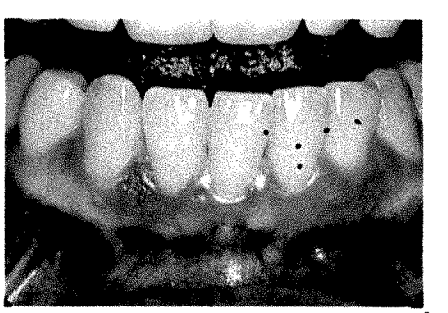

Fig 8.—Degree IV of smokers' melanosis. Moderately brown pigmentation including greater part of attached gingiva just in front of canines and incisors.

pigmentation was as well observed to the lateral side of this sector; in a single case it was also in the first molar area. Thus, melanosis in the attached gingiva is more often found in the labial part of the gingiva that is in the area of the canines and incisors than in the lingual and palatal part or in the premolar or molar areas ($P < .001$). There were no differences dependent on sex as to the localization of the melanosis.

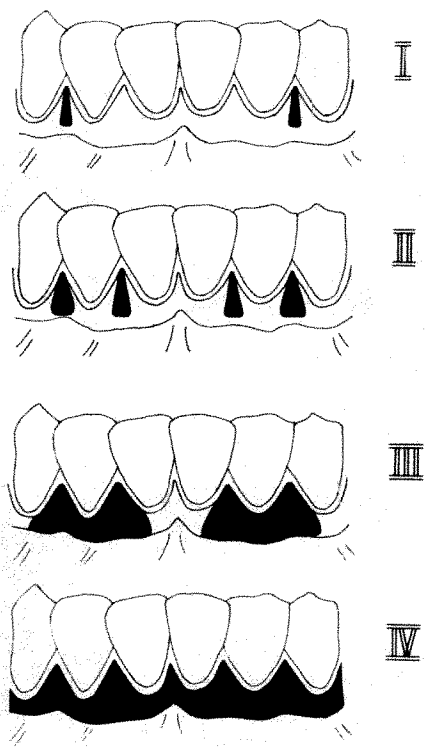

Fig 9.—Degrees of pigmentation in maxilla and mandible. Among persons with smokers' melanosis degree I occurred in 25.3%; degree II in 30.1%; degree III in 24.1%; and degree IV in 20.5%. (Black color shade in graphic does exceed in vivo brown color.)

Tobacco Consumption

All of the patients and students with melanin pigmentation in the gingiva were smokers. Patients with pigmentation had a higher cigarette consumption than smokers without pigmentation ($.01 > P > .001$). A tendency toward greater cigarette consumption among the men with melanin pigmentation than among the women could be observed in part 2 of the investigation ($.05 > P > .01$). Tobacco consumption data are given in Table 2.

Color of Eyes and Hair

No statistical correlation was found between any special iris or hair color and the occurrence of gingival melanin pigmentation.

COMMENT

The investigation shows that 18 (14.9%) of the patients and 12 (12.9%) of the students had melanin pigmentation in the gingiva. The small difference between the number of persons with pigmentation in these two groups shows that periodontitis does not increase the frequency of pigmentation significantly.

The magnitude of 18 (14.9%) and 12 (12.9%) of persons having gingival melanin pigmentation had not been reported earlier, to our knowledge, for light-skinned Europeans. This can be due either to the fact that in general, earlier investigations have had the whole oral cavity as the examination field or to the fact that the interest has been concentrated on discolorations that contrast strongly to the mucosa. At such examinations, it is probably easy to overlook a modestly pigmented interdental papilla.

The investigation shows a very strong correlation between melanin pigmentation in the gingiva and smoking, as all the persons having melanin pigmentation were smokers. No earlier investigations show this connection. Van Wyk,[3] however, suspects that smoking could be the cause for the variations in gingival pigmentation of the Bantus.

Cigarette smoking was dominant compared to pipe smoking and therefore it is not possible to show, in this investigation, any difference between cigarette smokers and pipe smokers as to pigmentation.

It has been known for a long time that melanosis gingivae is controlled by genetic factors among people with a dark complexion.[1,3] This investigation shows, however, that for a number of persons from northern Sweden where brown iris and dark hair are not predominant in frequency, it is possible to isolate tobacco smoking as a cause for melanin pigmentation of the gingiva. To distinguish the normal, genetically caused melanosis gingivae from the melanin pigmentation caused by tobacco smoking, the latter has been given the name "smokers' melanosis." Since smokers' melanosis probably can be found in all parts of the oral mucosa, the respective localization could be added. Besides the attached gingiva, other sectors of the oral mucosa are also exposed to high concentrations of tobacco smoke. At the inhalation of tobacco smoke, the mucosa in the region of the oropharynx is probably exposed. Merchant et al[12,13] have found melanin pigmentation in the soft palate in patients with serious lung diseases. They connect this with a long-time production of adrenocorticotropic hormone (ACTH) from the abnormality in the lung. All of the patients, however, are reported to be excessive smokers, and therefore it is highly probable that these changes in pigmentation are not caused by ACTH production from the lungs. They are probably smokers' melanosis in the soft palate. The connection between smoking and lung diseases has been known for a long time.

Lindquist and Ullberg[14] have shown that nicotine as a polycyclic compound has great affinity to the melanin in the inner ear. They showed that polycyclic compounds disturb the melanin-containing cells and cause a higher melanization through the development of more melanosomes and the migration of the melanosomes. The reason why smokers' melanosis arises in the oral mucosa can be due to similar disturbances in the normal

Fig 10.—Anatomic relationships of gingiva. 1 indicates canine; 2, free gingiva; 3, mucogingival junction; 4, alveolar mucosa; 5, attached gingiva; 6, interdental papilla; 7, lateral incisor.

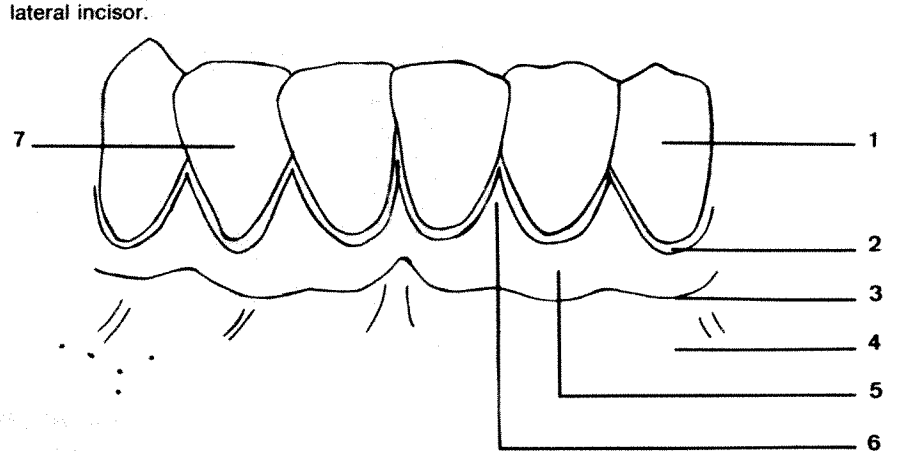

Table 2.—Tobacco Consumption

Administration	No. of Persons Using Tobacco M	F	Quantities
121 patients, part 1			
Cigarette smokers without pigmentation	24 (19.8%)	17 (14.0%)	10.0 cigarettes/day, SD = 7.0*
Cigarette smokers with pigmentation	5 (4.1%)	13 (10.7%)	14.7 cigarettes/day, SD = 4.0
Snuff users without pigmentation	6 (5.0%)	...	70.8 gm/wk, SD = 33.5
Pipe smokers without pigmentation	3 (2.5%)	...	191.7 gm/wk SD = 150.7
93 dental nurse students, part 1			
Cigarette smokers without pigmentation		36 (38.7%)	9.2 cigarettes/day, SD = 3.4
Cigarette smokers with pigmentation		12 (12.9%)	10.7 cigarettes/day, SD = 8.9
71 patients with pigmentation, part 2			
Cigarette smokers	21 (29.6%)	48 (67.6%)	Males†: 16.7 cigarettes/day, SD = 8.1* Females†: 12.6 cigarettes/day, SD = 4.6*
Pipe smokers	2 (2.8%)	...	50.0 gm/wk, SD = 0

*Patients with pigmentation had a higher cigarette consumption than patients without pigmentation who smoked ($.01 > P > .001$).
†A tendency toward greater cigarette consumption among men with pigmentation than among women with pigmentation could be observed in part 2 of the investigation ($.05 > P > .01$).

metabolism of melanosomes in the melanocytes and in the keratinocytes in the oral mucosa of smokers.

Among the patients with smokers' melanosis in part 1 of the investigation, 13 (72.2%) were women. It should then be noted that 68 of the 121 patients were women. However, the tendency is interesting when seen against the background of an almost significantly lower cigarette consumption by the women with pigmentation compared with the men with pigmentation. The cause for this could be the periodic increase in the amount of estrogen in the blood in connection with menstruation, gravidity, and/or consumption of hormonal contraceptives. Several investigations have shown an increased pigmentation tendency in women on these occasions.[15-17]

Further lines of investigation include the mechanism behind the development of smokers' melanosis and the connection with periodontitis.

Nonproprietary Names and Trademarks of Drugs

Amitriptyline hydrochloride—*Elavil.*
Chlorzoxazone—*Paraflex.*

References

1. Dummet CO: Normal and abnormal pigmentation of the oral mucosae. *Dermatol Dig* 1:41-49, 1966.
2. Becker SW: Pigmentary lesions common to the skin and oral cavity. *Oral Surg* 28:526-533, 1969.
3. Van Wyk CW: Mouth pigmentation patterns in a group of healthy South African Bantus. *Suid-Afrikaanse Tydskrift Geneeskunde* 44:177-180, 1970.
4. Brown T: Oral pigmentation in the aborigines of Kalumbura, northwest Australia. *Arch Oral Biol* 9:555-564, 1964.
5. McCarthy PL, Shklar G: Disturbances in pigmentation, in *Disease of the Oral Mucosa: Diagnosis, Management, Therapy.* New York, McGraw-Hill Book Co, Inc, 1964, pp 228-238.
6. Ainamo J: A clinical and histological study on benign gingival pigmentation. *Suom Hammasläät Toim* 64:183-189, 1968.
7. Giansanti JS, Tillery DE, Olansky S: Oral mucosal pigmentation resulting from antimalarial therapy. *Oral Surg* 31:66-69, 1971.
8. Hedstrand A-G (ed): *Farmaceutiska specialiteter i Sverige.* Uppsala, Sweden, Almqvist & Wiksell, 1976.
9. Carlson GO, Eneroth C-M, Hjertman L: Melanoma and dark, localized discolorations in the oral mucosa. *Swed Dent J* 64:601-610, 1971.
10. Fry L, Almeyda JR: The incidence of buccal pigmentation in caucasoids and negroids in Britain. *Br J Dermatol* 80:244-247, 1968.
11. Weathers DR, Fine RM: Amalgam tattoo of oral mucosa. *Arch Dermatol* 110:727-728, 1974.
12. Merchant HW: Oral pigmentation associated with bronchogenic carcinoma. *Oral Surg* 36:675-677, 1973.
13. Merchant HW, Hayes LE, Ellison LT: Soft-palate pigmentation in lung disease, including cancer. *Oral Surg* 41:726-733, 1976.
14. Lindquist NG, Ullberg S: Drug-induced damage to vision, hearing, balance and motility according to a common mechanism. *Läkartidningen* 72:1217-1221, 1975.
15. Carruthers R: Chloasma and the pill. *Br Med J* 3:307, 1967.
16. Snell RS, Bischitz PG: The melanocytes and melanin in human abdominal wall skin: A survey made at different ages in both sexes and during pregnancy. *J Anat (London)* 97:361-376, 1963.
17. Snell RS, Turner R: Skin pigmentation in relation to the menstrual cycle. *J Invest Dermatol* 47:147-155, 1966.

Topically Applied Antifungal Agents

Percutaneous Penetration and Prophylactic Activity Against *Trichophyton mentagrophytes* Infection

Sylvia M. Wallace, PhD; Vinod P. Shah, PhD; William L. Epstein, MD; Joseph Greenberg, MD; Sidney Riegelman, PhD

• **Penetration and prophylactic activity against *Trichophyton mentagrophytes* infection of topically applied antifungal agents were studied in human volunteers. The concentration and persistence of drug in the stratum corneum was determined after different treatment schedules and from different vehicles. Measurable levels of griseofulvin, clotrimazole, miconazole nitrate, and thiabendazole remained in the skin four days after discontinuation of topical applications. Griseofulvin, miconazole, and clotrimazole exhibited prophylactic activity against infection by *T mentagrophytes* spores in a standardized test. Griseofulvin was a significantly better prophylactic agent than either miconazole or clotrimazole.**

(*Arch Dermatol* 113:1539-1542, 1977)

In preliminary studies,[1] topically applied griseofulvin was shown to protect against experimental infection by *Trichophyton mentagrophytes* spores. The present study further investigates the prophylactic activity of topically applied griseofulvin and other therapeutically active antifungal agents. The drugs—thiabendazole, miconazole nitrate, and clotrimazole—were chosen from commercially available therapeutic agents used to treat superficial fungal infections.

Topical thiabendazole has been suggested[2] as a useful agent for the treatment of superficial *T mentagrophytes* infections. Miconazole is claimed[3] to be effective in the topical treatment of dermatomycosis. Studies suggest[4] that penetration of clotrimazole from topical application is sufficient to provide minimum inhibitory concentrations against most fungi.

The effect of vehicle formulation on the epidermal reservoir of the drug was also studied.

Accepted for publication May 11, 1977.

From the Departments of Pharmacy (Drs Wallace, Shah, and Riegelman) and Dermatology (Dr Epstein), University of California, and Letterman Army Institute of Research, Presidio of California (Dr Greenberg), San Francisco.

Reprint requests to College of Pharmacy, University of Saskatchewan, Saskatoon, Saskatchewan, Canada S7N OWO (Dr Wallace).

SUBJECTS AND METHODS

Subject Selection

Healthy adults between the ages of 18 and 50 were considered as suitable subjects. Medical examinations prior to initiating the study substantiated a history free of notable past illnesses and allergy to griseofulvin, clinically normal, healthy skin, and absence of chronic superficial fungal infections. Subjects who were to receive application of fungal spores were tested on the forearm with an intradermal infection of *Trichophyton* antigen. Subjects who gave an immediate response or no response after two days were excluded.

Skin Samples.—Skin samples were obtained from the palm and forearm by light scraping of the skin surface with a large, open dermal curette (level 1). In some cases a second, deeper sample (level 2) was obtained by more vigorous scraping with a curette until the glistening layer was reached.[5]

Samples were weighed and homogenized in distilled water. The homogenate was extracted with 10 ml of ether and analyzed for drug content by the appropriate method.

Assay Procedures

Griseofulvin.—Griseofulvin was determined in skin samples by the electron capture gas chromatographic procedure or fluorescence assay previously reported.[5]

Thiabendazole.—Thiabendazole was quantitated by fluorescence spectrometry. The ether extract of skin was evaporated to dryness and the residue dissolved in 0.5 ml of methyl alcohol. The solution was acidified with 1 drop of concentrated sulfuric acid. Fluorescence was measured in a spectrophotofluorometer (excitation wavelength, 300 nm; emission wavelength, 350 nm). Standard curves of fluorescence vs thiabendazole concentration were linear from 0.1 to 1 μg/0.5 ml.

Clotrimazole and Miconazole.—Both were quantitated by electron capture gas chromatography. Ether-extracted samples were chromatographed on a glass column packed with 3% phenylmethylsilicone (50% phenyl substituents) coated on a dimethyl dichlorosilane-treated diatomaceous earth (3% OV-17 on Gas Chrom Q). Griseofulvin served as the internal standard for clotrimazole assays and 8-chlorotheophylline for miconazole assays. Analytical methods were sensitive to 5 ng of drug. Details of analytical procedures are to be published.[6]

Table 1.—Average Epidermal Concentrations of Drug After Ten Days' Topical Application

Drug	Concentration in Skin, μg/mg* 24 hr After Discontinuing Drug	96 hr After Discontinuing Drug	No. of Subjects
Miconazole, 2% cream	2.59 ± 1.67	0.14 ± 0.19	5
Clotrimazole, 1% in polyethylene glycol	1.99 ± 1.12	0.40 ± 0.08	4
Griseofulvin, 0.45% in ethyl alcohol	11.7 ± 5.60	2.11 ± 0.99	5
Thiabendazole, 1% in ethyl alcohol	37.0 ± 26.1	3.06 ± 2.17	4

*Mean ± SD.

Table 2.—Comparison of Griseofulvin Levels in Stratum Corneum After 5 and 13 Days' Application in Five Vehicles

Vehicle	Site of Application	Concentration of Griseofulvin, μg/mg, in Level 1: 5 Days' Application, 6 hr After Discontinuing Drug	5 Days' Application, 24 hr After Discontinuing Drug	13 Days' Application, 6 hr After Discontinuing Drug	13 Days' Application, 24 hr After Discontinuing Drug	No. of Subjects
Experiment 2						
Propylene glycol	Palm	0.46 ± 0.20	0.06 ± 0.07			4
Water suspension in carboxymethylcellulose 2.5%	Palm	0.40 ± 0.54	0.04 ± 0.01			4
Polyethylene glycol 400 100%	Palm	0.54 ± 0.28	0.18 ± 0.09			4
Experiment 3						
Polyethylene glycol 400 85%–ethyl alcohol 15%	Forearm	0.98 ± 0.66	0.16 ± 0.25	1.64 ± 0.97	0.44 ± 0.32	4
Polyethylene glycol 400 75%–ethyl alcohol 25%	Forearm	0.85 ± 0.56	0.34 ± 0.18	1.55 ± 0.65	0.56 ± 0.38	5
Ethyl alcohol†	Forearm				11.7 ± 5.60	5

*One percent solution or suspension.
†Ten days' application.

Table 3.—Clotrimazole Concentrations in Stratum Parneum (Palm) After Five Days' Topical Application

Formulation	No. of Subjects	Skin Concentration, μg/mg: 6 hr After Discontinuing Drug, Level 1	6 hr After Discontinuing Drug, Level 2	24 hr After Discontinuing Drug, Level 1	24 hr After Discontinuing Drug, Level 2
1% Solution in propylene glycol	4	0.52 ± 0.80	0.40 ± 0.66	0.02 ± 0.03	0.05 ± 0.11
1% Suspension in carboxymethylcellulose 2.5%	4	0.13 ± 0.13	0.06 ± 0.07	0.02 ± 0.02	0.02 ± 0.02
1% Solution in polyethylene glycol 400	4	0.13 ± 0.12	0.08 ± 0.09	0.01 ± 0.01	0.002 ± 0.004

Penetration of Topically Applied Antifungals

Experiment 1 involved the following drug formulations: placebo of 95% ethyl alcohol, 0.45% griseofulvin solution in ethyl alcohol, 1% thiabendazole solution in ethyl alcohol, 1% clotrimazole solution in polyethylene glycol 400, and 2% miconazole nitrate cream. These formulations were applied to the forearm twice daily for ten days. Skin scrapings were collected 24 and 96 hours after discontinuation of topical applications.

Experiment 2 involved three formulations each of griseofulvin and clotrimazole: a 1% solution in polyethylene glycol 400, a 1% solution in propylene glycol, and a 1% suspension in 2.5% sodium carboxymethylcellulose. Subjects applied one formulation twice daily for five days on both palms. Approximately six hours after the last application, epidermal scrapings were obtained from the left palm at two levels (1 and 2) by consecutive curettage. Approximately 24 hours later, similar scrapings were obtained from the right palm.

Experiment 3 involved the following formulations: 1% griseofulvin solution in 85% polyethylene glycol 400-15% ethyl alcohol and 1% griseofulvin solution in 75% polyethylene glycol 400-25% ethyl alcohol. A formulation was applied twice daily to one arm for five days and to the other arm for 13 days. Epidermal skin scrapings were obtained from the forearm 6 and 24 hours after discontinuation of topical applications.

Prophylaxis of *T mentagrophytes* Infection

Experiment 4 involved the following formulations: placebo of 95% ethyl alcohol, 0.45% griseofulvin solution in ethyl alcohol, 1% thiabendazole solution in alcohol, 1% clotrimazole solution in polyethylene glycol 400, and 2% miconazole nitrate cream. A drug formulation was applied twice daily for ten days to one forearm. A placebo was similarly applied to the other arm. On the 11th day, 300 spores of *T mentagrophytes* were applied to a 6-sq-cm area of each forearm. The areas were covered with an occlusive plastic dressing for four days. After the patches were removed, the sites were examined weekly (for 30 days) for evidence of fungal infection.

Experiment 5 involved the following formulations: 1% griseofulvin solution in 85% polyethylene glycol 400-15% ethyl alcohol, 1% clotrimazole in polyethylene glycol 400, 2% miconazole nitrate cream, and 85% polyethylene glycol 400-15% ethyl alcohol. To maintain a double-blind study, drug formulations were letter-coded, and appli-

cation sites (on the forearms) for the four formulations were allocated according to a Latin square design. A different drug formulation was applied twice daily for ten days to each of the four areas. Each 6-sq-cm area was infected with 300 spores to *T mentagrophytes*, and the sites were occluded for four days. After removal of the dressing, gauze patches were cultured for evidence of viable fungi. Areas on the forearm were examined weekly (for 30 days) and lesions scored according to established criteria. A score of 0 represented normal skin with only slight scaling and erythema; +1, six to ten small erythematous follicular papules or small pustules with no more than one or two larger (2 to 3 mm) erythematous papules or pustules; +2, a greater number of papules or pustules, a colony formation, or coalescence of lesions. A +2 response was considered unacceptable for a prophylactic antifungal agent. For collection of data, one week was chosen (on an individual basis) when the greatest degree of response occurred. The dermatologist (W.L.E.), scoring the infections, was not aware of the treatments received. The treatment code was assigned and maintained by participants not involved in assessing the infection. Since the scoring of infections produced discontinuous data, ie, the response could only assume discrete values of 0, 1, and 2, results were analyzed by χ^2 contingency tables. Heterogeneity of treatments was further examined by multiple comparisons. For three scoring categories and two treatments, expected frequencies for the +1 response category were less than 2.5, and greater than 20% of cells were less than five. Cochran[7] suggested that in such circumstances the χ^2 calculated would be baised. Therefore, to make individual comparisons statistically valid, tables were collapsed by combining 0 and +1 responses to produce two categories—acceptable (0 and +1) and unacceptable (+2). A priori, a +1 category of infections was established as acceptable for a prophylactic agent while +2 was unacceptable. Probabilities for these individual 2 × 2 tables were calculated by the Fisher exact test.[8]

Table 4.—Prophylactic Activity of Antifungal Preparations (Response Grouped According to Drug Formulation)

Subject	Placebo	Miconazole	Clotrimazole	Griseofulvin
1	0	0	0	0
2	2	0	0	0
3	2	0	0	0
4	2	0	0	0
5	2	1	2	0
6	2	2	2	0
7	2	2	2	0
8	—	—	—	—
9	2	2	2	0
10	2	2	0	0
11	0	0	1	0
12	2	2	0	0
13	2	2	2	1
14	2	1	0	1
15	—	—	—	—
16	2	2	0	1
17	2	1	1	0
18	2	2	2	1
19	2	1	0	0
20	2	0	1	0
21	2	2	2	0
22	2	1	2	0
23	2	2	2	0
24	2	1	0	0
Totals	**40**	**26**	**21**	**4**

*Excluded from statistical analysis.

Table 5.—χ^2 Analysis of Prophylactic Activity of Antifungal Preparations*

Response Categories	Placebo	Miconazole	Clotrimazole	Griseofulvin	Total
			Observed Frequencies		
0	2	6	10	18	**36**
+1	0	6	3	3	**12**
+2	19	9	8	0	**36**
Total	**21**	**21**	**21**	**21**	**84**
			$(E-O)^2/E$		
0	5.4	1.0	0.11	9.0	**15.51**
+1	3.0	3.0	0	0	**6.0**
+2	11.1	0	0.11	9.0	**20.21**
Total	**19.5**	**4.0**	**0.22**	**18.0**	**41.72†**

*Data from Table 6.
†Significant at $P < .05$.

RESULTS AND COMMENT

Measurable levels of clotrimazole, miconazole, griseofulvin, and thiabendazole remain in skin four days after discontinuing topical application of formulations (experiment 1). Average epidermal concentrations of thiabendazole after ten days' topical application are significantly greater than miconazole, clotrimazole, or griseofulvin (Table). However, the rate of disappearance of thiabendazole and miconazole from the skin is greater than that for griseofulvin and clotrimazole. The 96-hour level is 20% of the 24-hour level for clotrimazole and 17% for griseofulvin, but only 6% for miconazole and 8% for thiabendazole. The rate of removal of drug from the skin influences the length of time the minimum inhibitory concentration against fungi is maintained and thus the efficacy of the medication.

Although the ethyl alcohol solution of griseofulvin delivered high concentration of drug to the stratum corneum, the vehicle is too irritating to be used chronically or over a widespread area. Thus, alternative vehicles were investigated. Stratum corneum concentrations six hours after discontinuation of application of griseofulvin in polyethylene glycol 400, propylene glycol and 2.5% carboxymethylcellulose (experiment 2) were not significantly different (analysis of variance, $P = .05$) (Table 2). However, the epidermal reservoir of griseofulvin 24 hours after discontinuation of topical applications was significantly larger with the polyethylene glycol 400 vehicle. Drug levels were much lower than achieved with an ethyl alcohol vehicle.

None of the three formulations of clotrimazole (experiment 2) exhibited any distinct advantage. Stratum corneum concentrations of clotrimazole were not significantly different after application in polyethylene glycol 400, propylene glycol and 2.5% carboxymethylcellulose (Table 3). Twenty-four hours after a five-day application (Table 3), clotrimazole levels in the stratum corneum were significantly less than after a ten-day application (Table 1). The difference could be due to prolonged application and/or the different permeability of palm and forearm skin.

Table 6.—Individual Comparisons (2 × 2 Tables) of Prophylactic Activity of Antifungal Agents

Comparative Treatment	No. of Subjects				
	0 and +1	+2	Total	P*	ΣP†
Griseofulvin	21	0	21	5×10^{-10}	5×10^{-10}
Placebo	2	19	21		
Total	**23**	**19**	**42**		
Clotrimazole	13	8	21	0.0004	0.0005
Placebo	2	19	21		
Total	**15**	**27**	**42**		
Miconazole	12	9	21	0.0012	0.0013
Placebo	2	19	21		
Total	**14**	**28**	**42**		
Griseofulvin	21	0	21	0.0007	0.0007
Miconazole	12	9	21		
Total	**33**	**9**	**42**		
Griseofulvin	21	0	21	0.002	0.002
Clotrimazole	13	8	21		
Total	**34**	**8**	**42**		
Miconazole	12	9	21	0.235	0.500
Clotrimazole	13	8	21		
Total	**25**	**17**	**42**		

*Probability of the observed table occurring by random chance as calculated from the following formula:

$$\frac{(a+b)!\,(c+d)!\,(a+c)!\,(b+d)!}{N!\,a!\,b!\,c!\,d!}$$

†Probability of obtaining the observed table or one even more extreme if the null hypothesis were true. The null hypothesis (there is no significant difference between treatments) is tested by examining the sum of the probabilities (as calculated from the aforementioned formula) for the observed and all more extreme tables.[9]

Multiple irritation studies of polyethylene glycol-ethyl alcohol combinations gave negative results, thus indicating a low degree of potential irritation for mixtures containing up to 50% ethyl alcohol. Mixtures of polyethylene glycol 400 and ethyl alcohol (experiment 3) were effective delivery agents for griseofulvin, but the drug did not accumulate to the extent noted when pure ethyl alcohol was used as the solvent. There was no significant difference (t-test, $P = .05$) in the epidermal concentrations of griseofulvin achieved after application in a 75% polyethylene glycol 400-25% ethyl alcohol vehicle and an 85% polyethylene glycol −15% ethyl alcohol vehicle (Table 2). Concentration of griseofulvin in epidermal skin samples obtained from the forearm was significantly greater (paired t-test, $P = .05$) after 13 days' repetitive application than after five days' application. Concentrations 24 hours after discontinuation of applications were significantly less than six hours after discontinuation.

A preliminary experiment (experiment 4) validated the infection procedure and screened topical antifungal agents for prophylactic activity. Eighteen of 22 subjects developed infections on the control forearm (ie, untreated). None of the subjects in the griseofulvin-treated group developed infections. Two of five clotrimazole, one of three miconazole, three of four thiabendazole, and five of five placebo-treated subjects developed infections on the treated arm. Results as analyzed by the Fisher exact test were statistically significant ($P < .05$) only for the placebo-griseofulvin comparison. Because of poor response, thiabendazole was not included in subsequent experiments.

Promising results of the preliminary experiment prompted further tests (experiment 5) on the prophylactic activity of griseofulvin, clotrimazole, and miconazole. Four treatments—griseofulvin, clotrimazole, miconazole, and placebo—were randomly assigned to sites on the forearms of 24 subjects according to 4 × 4 Latin squares. Two subjects did not complete the study, and one subject was excluded from statistical analysis because of departure from protocol (Table 4). The details of the statistical treatment are discussed in the Methods section. For three scoring categories (0, +1, +2) and four treatments, a χ^2 of 41.7 (Table 5) indicated a significant difference between treatments ($P < .05$, 6 df). Although the expected frequency in some cells of the χ^2 table was less than five, the significance level was still considered valid since all cells contained expected frequencies greater than 2.5.[9] Statistical comparisons between individual treatments after pooling responses into two groups (unacceptable and acceptable) are summarized in Table 6. Griseofulvin, clotrimazole and miconazole were significantly better than placebo ($P < .05$). While 91% of subjects developed +2 infections in the placebo-treated sites, 38% and 43% developed +2 infections in the clotrimazole- and miconazole-treated sites, respectively. None of the subjects developed +2 infections at the griseofulvin-treated site. Based on the above statistical analysis, it is concluded that griseofulvin showed a significantly higher prophylactic activity than either clotrimazole or miconazole. Miconazole was not significantly better ($P < .05$) than clotrimazole.

This investigation was supported by US Army contract DAMD 17-75-C-5003.

Design of the microbiological experiments and statistical analysis of the data were developed in cooperation with Lt Col A. Allen, Letterman Army Institute of Research, Presidio of California.

Clotrimazole solutions were provided by Delby Pharmaceuticals, and miconazole cream by Johnson and Johnson, Ltd.

Nonproprietary Names and Trademarks of Drugs

Clotrimazole—*Lotrimin.*
Miconazole—*Micatin, Monistat.*
Thiabendazole—*Mintezol.*

References

1. Epstein WL, Shah VP, Jones HE, et al: Topically applied griseofulvin in prevention and treatment of *Trichophyton mentagrophytes*. *Arch Dermatol* 111:1293-1297, 1975.

2. Fleischmajer R, Goldstein J, Nicholas L: Preliminary report on the antimycotic effect of topical thiabendazole in vivo. *Curr Ther Res* 7:558-561, 1965.

3. Brugmans J, Van Cutsem JM, Heykants J, et al: Systemic antifungal potential safety and transport of miconazole nitrate. *Europ J Clin Pharmacol* 5:93-99, 1972.

4. Duhm B, Maul W, Medenwald H, et al: Pharmacokinetics of topically applied bisphenyl-(2-chlorophenyl)-1-imidazolyl-methane-^{14}C. *Drugs Made in Germany* 15:99-103, 1972.

5. Epstein WL, Shah VP, Riegelman S: Griseofulvin levels in stratum corneum. *Arch Dermatol* 106:344-348, 1972.

6. Wallace SM, Shah VP, Riegelman S, et al: Electron capture gas chromatographic assay for miconazole and clotrimazole in skin samples. *J Pharm Sci*, to be published.

7. Cochran WG: Some methods for strengthening the common chi-squared tests. *Biometrics* 10:417-451, 1954.

8. Zar JH: *Biostatistical Analysis*. Englewood Cliffs, NJ, Prentice-Hall, Inc, 1974, pp 291-295.

9. Goldstein A: *Biostatistics: An Introductory Text*. New York, Macmillan Co, 1964, pp 102-117.

Cell Populations in Experimental Contact Dermatitis

Nicole Hunziker, MD, Richard K. Winkelmann, MD, PhD

• Sequential biopsy specimens from contact dermatitis induced in the guinea pig by the application of dinitrochlorobenzene were studied by histologic, histochemical, and electron microscopical methods. At 12 hours, mononuclear cells and polymorphonuclear cells reached their peak numbers. Increasing numbers of basophils were observed, and at 24 and 48 hours, the basophils reached their maximal numbers. The basophils were observed not only in the dermis but also in the epidermis, and they may have had an active role in inflammation or repair. A close relationship was noted between the macrophage and all of the successive cell populations in the dermis.

(*Arch Dermatol* 113:1543-1549, 1977)

Experiments on transfer of delayed cutaneous hypersensitivity by Landsteiner and Chase[1] in 1942 proved, for the first time, the role of the lymphocyte in allergic contact dermatitis in guinea pigs. Since then, there has been universal acceptance of the lymphocyte as the principal cell of this reaction. More recently, other authors have emphasized the presence of lymphocytes, monocytes, and macrophages.[2-5] Wolf-Jürgensen,[6] using the skin window technique, demonstrated the role of the basophil in cutaneous delayed hypersensitivity. By histologic examination, he found that the occurrence of basophil leukocytes coincided with the capacity for delayed hypersensitivity. In 1965, Hunziker and others[7] showed that the basophil count of the peripheral blood increases after primary cutaneous sensitization. Since 1970, Dvorak et al[8] have observed basophils in the Jones-Mote tissue reaction and proposed the term "cutaneous basophil hypersensitivity." Askenase et al[9] concluded that antibody cutaneous basophil reactions may be distinctive hypersensitivity responses distinguishable from classic anaphylactic Arthus and delayed hypersensitivity. Additional studies showed that basophils occur in various delayed hypersensitivity reactions, and Chase[10] questioned whether a reaction type should be characterized solely by its basophil content. In 1974, Katz et al[11] observed that, in cyclophosphamide-pretreated, sensitized guinea pigs, the cutaneous reaction is notably increased, and almost no basophils are detected. Thus, these authors stated that basophils are not necessary for the delayed hypersensitivity reaction and that they probably modulate the severity of the reaction.

We followed the time course of the basophils and other inflammatory cells in light microscopy, fluorescence, electron microscopy, and histochemistry in the cutaneous delayed hypersensitivity reaction in guinea pig skin and observed the associations of cells in the dermis and epidermis with the evolution of the inflammatory response.

MATERIALS AND METHODS

Six male albino guinea pigs, each weighing about 400 gm, were sensitized by the daily applications of 1% dinitrochlorobenzene (DNCB) dissolved in acetone to a 3-cm area on the back of the neck. Ten or more days later, the DNCB (0.1%) was applied to a 2-sq cm area of the flank skin. The degree of inflammatory activity was recorded at 2, 6, 12, 24, and 48 hours, according to a conventional scale (0 to + + +): 0, no reaction; +, mild erythema; + +, substantial erythema with induration; + + +, massive erythema with vesiculation, oozing, or crusting. Two nonsensitized guinea pigs were used as controls, with and without the application of DNCB to skin.

Biopsies were performed at each period of observation; a total of 30 biopsies were done in the sensitized guinea pig. Each biopsy specimen was immediately cut into pieces for subsequent handling.

Histology

After buffered formaldehyde fixation and paraffin embedding, sections were cut for staining with hematoxylin-eosin, Giemsa, toluidine blue, and polychrome methylene blue. Sections stained with acridine orange were examined by fluorescent microscopy with a xenon light source and an objective filter (K 530).

Histochemistry

Portions of the biopsy specimens were frozen in liquid nitrogen and were stored at −70 C until use within one week. Alkaline phosphatase,[12] acid phosphatase, and naphthol-AS-D-chloroacetate esterase (NASDCAE)[13] techniques were performed on each biopsy specimen.

Electron Microscopy

Small (1 mm) biopsy specimens were fixed in Chick's solution and were embedded in plastic.[14] Thick sections were stained with toluidine blue and Giemsa.[8] Thin sections (500 to 900 A) were triple stained with lead citrate, 3% uranyl acetate, and

Accepted for publication April 13, 1977.

From the Department of Dermatology, Mayo Clinic and Mayo Foundation, Rochester, Minn.

Reprint requests to Section of Publications, Mayo Clinic, 200 First St SW, Rochester, MN 55901 (Dr Hunziker).

Table 1.—Cells in Dermis in Experimental Contact Dermatitis

Cell	Cell Frequency*	No. of Guinea Pigs 2 hr†	6 hr	12 hr	24 hr	48 hr
Acid phosphatase-positive						
	Numerous	0	0	4	0	0
	Many	1	5	2	3	4
	Some	4	1	0	3	2
	Few	0	0	0	0	0
	None	1	0	0	0	0
Alkaline phosphatase-positive						
	Numerous	0	0	1	0	0
	Many	1	2	2	0	0
	Some	0	4	3	1	0
	Few	2	0	0	1	5
	None	4	0	0	4	1
Basophils						
	Numerous	0	0	0	0	0
	Many	0	0	0	1	4
	Some	0	0	2	5	2
	Few	2	2	4	0	0
	None	4	4	0	0	0

*Numerous, + + +; many, + +; some, +; few, ±.
†Hours after challenge with 0.1% dinitrochlorobenzene.

Table 2.—Cells in Epidermis in Experimental Contact Dermatitis

Cell	Cell Frequency*	No. of Guinea Pigs 2 hr†	6 hr	12 hr	24 hr	48 hr
Acid phosphatase-positive						
	Numerous	0	0	2	0	0
	Many	0	0	3	0	0
	Some	0	2	0	0	2
	Few	0	4	1	6	2
	None	6	0	0	0	2
Alkaline phosphatase-positive						
	Numerous	0	0	2	0	0
	Many	0	0	1	0	0
	Some	0	4	1	1	0
	Few	0	2	2	2	2
	None	6	0	0	3	4
Basophils						
	Numerous	0	0	0	0	0
	Many	0	0	0	0	0
	Some	0	0	0	2	4
	Few	0	0	4	4	2
	None	6	6	2	0	0

*Numerous, + + +; many, + +; some, +; few, ±.
†Hours after challenge with 0.1% dinitrochlorobenzene.

lead citrate. The tissue sections (copper grids 150 to 200 mesh) were examined with an electron microscope at 60 kV. Six to nine grids from each of two blocks selected by thick-section examination from those available for each guinea pig for each time of observation were used for the sensitized and for the two nonsensitized guinea pigs.

Blood Cell Counts

Total WBC counts, basophils, and differential cell counts of blood smears in 107 normal albino guinea pigs and in the six DNCB-sensitized guinea pigs were done at 1, 6, 12, 24, and 48 hours after the DNCB-challenge test.

RESULTS

Clinical and Histologic Response

The macroscopic reaction after challenge with 0.1% DNCB in saline in the skin of the sensitized guinea pigs was positive after two hours, with the redness increasing until 12 to 24 hours. The reaction was still present at 48 hours, but exudation and crust formation was apparent at this time (Tables 1 and 2 and Fig 1 and 2). The histologic results of our study of sequential skin specimens parallel those from previous classic studies of this model.[15,16]

Blood Leukocyte and Basophil Studies

The normal guinea pigs had an average of 0.6% basophils in the blood. No substantial changes in basophil numbers were noted in the six sensitized guinea pigs at the time of the biopsies 2, 6, 12, 24, and 48 hours after the challenging application of 0.1% DNCB. However, the total leukocyte count consistently increased in both the sensitized and the control guinea pigs after the test, presumably from the stress of handling and testing.

Routine Tissue Basophil Study

The Giemsa, toluidine blue, and polychrome methylene blue stains were not routinely helpful, although these have been used for confirmation of data concerning the nature of the cells in the inflammatory infiltrates. We found it necessary to individually stain sections with Giemsa to obtain good results.

Fluorescent Basophil Study

The acridine orange method using fluorescent light demonstrated an increase in the number of orange fluorescent, discrete cells in the dermis at six hours. The number of fluorescent cells increased up to the end of observation at 48 hours. At 24 and 48 hours, some discrete, yellowish, granular cells, which may have been degranulated cells, were observed.

Histochemical Basophil Study

The histochemical procedure for NASDCAE demonstrated basophil and mast cells, showing bright red-stained granules filling the cytoplasm. NASDCAE-positive cells were easily found in the dermis at two and six hours in only two of the six guinea pigs. The number of cells in the dermis increased up to 24 hours and then seemed to stabilize or to be slightly increased at 48 hours. Some scattered granules were found free in the dermis at 24 and 48 hours. Positive cells were first observed in the epidermis at 12 hours, but they were more frequently seen at 24 and 48 hours. At that time, some isolated granules also were found in the epidermis.

Electron Microscopy

The thick sections stained with toluidine blue or Giemsa for electron microscopy also showed both mast cells and basophils. The Giemsa stain showed the granules more brightly and distinctly. The number of single or grouped basophils was increased in

the dermis at 12, 24, and 48 hours, and these were also observed in the epidermis. Three to four basophils were frequently seen clustered in the epidermis of the 48-hour specimens.

Cell Populations

Two Hours.—At two hours (Table 1 and Fig 1), mononuclear cells were present between the collagen fibers and about the vessels in the reticular dermis. These mononuclear cells varied from the typical monocyte that had a round, oval, or kidney-shaped nucleus with clear cytoplasm and normal organelles to the activated macrophage, which was large and had many pseudopodia, a large irregularly shaped nucleus, and a cytoplasm rich in organelles, lysosomes, and multivesicular bodies. Observed in the dermis were lymphocytes (each with a large nucleus), peripheral chromatin, and a clear cytoplasm containing few organelles, such as mitochondria and only rare lysosomes. Most of the lymphocytes probably were activated because their cytoplasm contained many cell membrane processes. Most of the lymphocytes also were closely associated with macrophages. A few lymphocytes were observed that were elongated between the keratinocytes in the intercellular space of the epidermis. These cells contained vacuoles and multivesicular bodies in their elongated cytoplasmic processes. Indeterminate cells (Langerhans' cells without granules) or macrophages were also observed in the intercellular spaces of the epidermis. These were clear cells that had large convoluted nuclei with clear cytoplasm and no defining cytoplasmic granules. Langerhans' cells were observed in the lower epidermis, with their dendrites extending in all directions between the keratinocytes, even between the basal lamina and the keratinocytes in some instances.

In the dermis, we observed a few basophils and eosinophils with activated membrane processes that were in striking apposition to macrophages. The basophil granules were oval and electron-dense, with a crystalline structure. Scattered neutrophils were found in the dermis alone or in association with macrophages. Free leukocyte granules were observed in the dermis.

Six Hours.—At six hours, the collagen fibers were partly dissociated with fibrin deposits, RBCs, and greater numbers of infiltrating cells. Fewer typical monocytes were found, and activated macrophages were readily observed. These activated macrophages were frequently associated with other cells, such as activated lymphocytes, and occasionally with basophils or eosinophils. The basophils were active, with a vacuolated cytoplasm that showed membrane activity. The vacuoles connected with the membrane-bound basophil granules and at times with the external surface of the cell. There were some free membrane-bound granules in the dermis. The neutrophilic leukocytes were principally found associated with the macrophages.

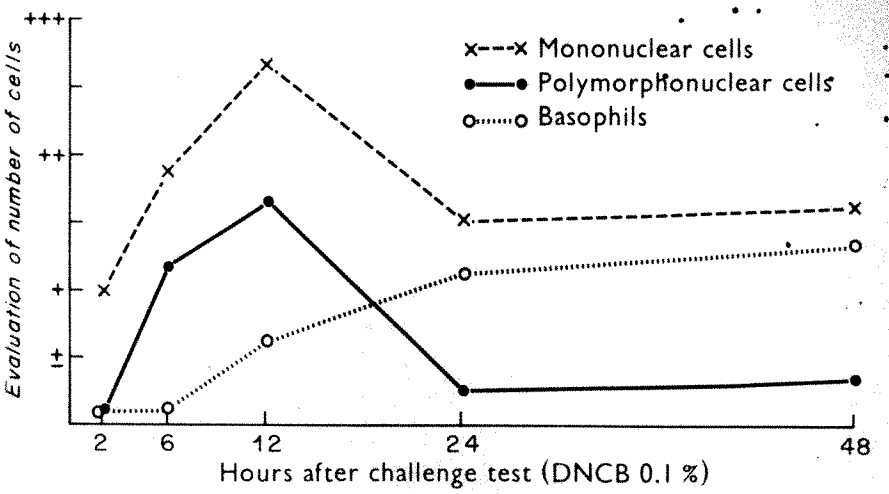

Fig 1.—Cells in dermis in experimental contact dermatitis.

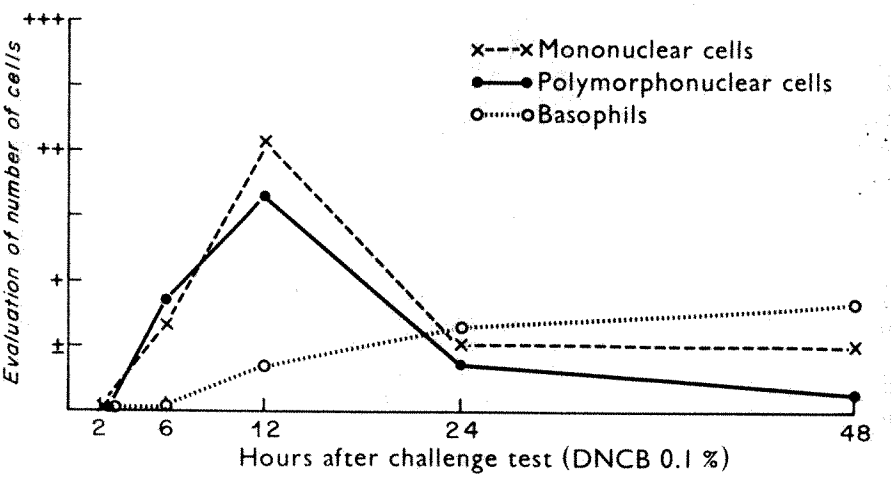

Fig 2.—Cells in epidermis in experimental contact dermatitis.

Lymphocytes were observed in the epidermis between the keratinocytes alone or in association with Langerhans' cells, as previously described by Silberberg et al[17] and by us (unpublished data). In the specimen of one guinea pig, three lymphocytes were seen closely related to a Langerhans' cell. Additional cells, each with highly indented nucleus and clear cytoplasm, were observed where the specific determination between an indeterminate cell and a mononuclear cell was difficult.

Twelve Hours.—At 12 hours, masses of infiltrating cells and RBCs separated the substantially altered collagen and fibrin masses. Most of the dermal cells were macrophages with many vacuoles, lysosomes, and myelin figures. A notable pinocytotic activity was observed, with regular dense bodies on the membrane and free in the cytoplasm. Activated lymphocytes also were observed. Neutrophil and basophil leukocytes were easily found, but eosinophils were rare. Most of the infiltrating cells occurred in closely related groups of two, three, or more cells. There were free neutrophil granules in the dermis.

While some basophils appeared to be normal, with crystalline or lamellar granules, most of the basophils contained glycogen granules, myelin structures, and dense but smudged or homogeneous granules, having lost their ordered structure but still being surrounded by a membrane. Occasionally, the cytoplasm was clear, having partly lost its granules or containing empty membrane-bound vesicles.

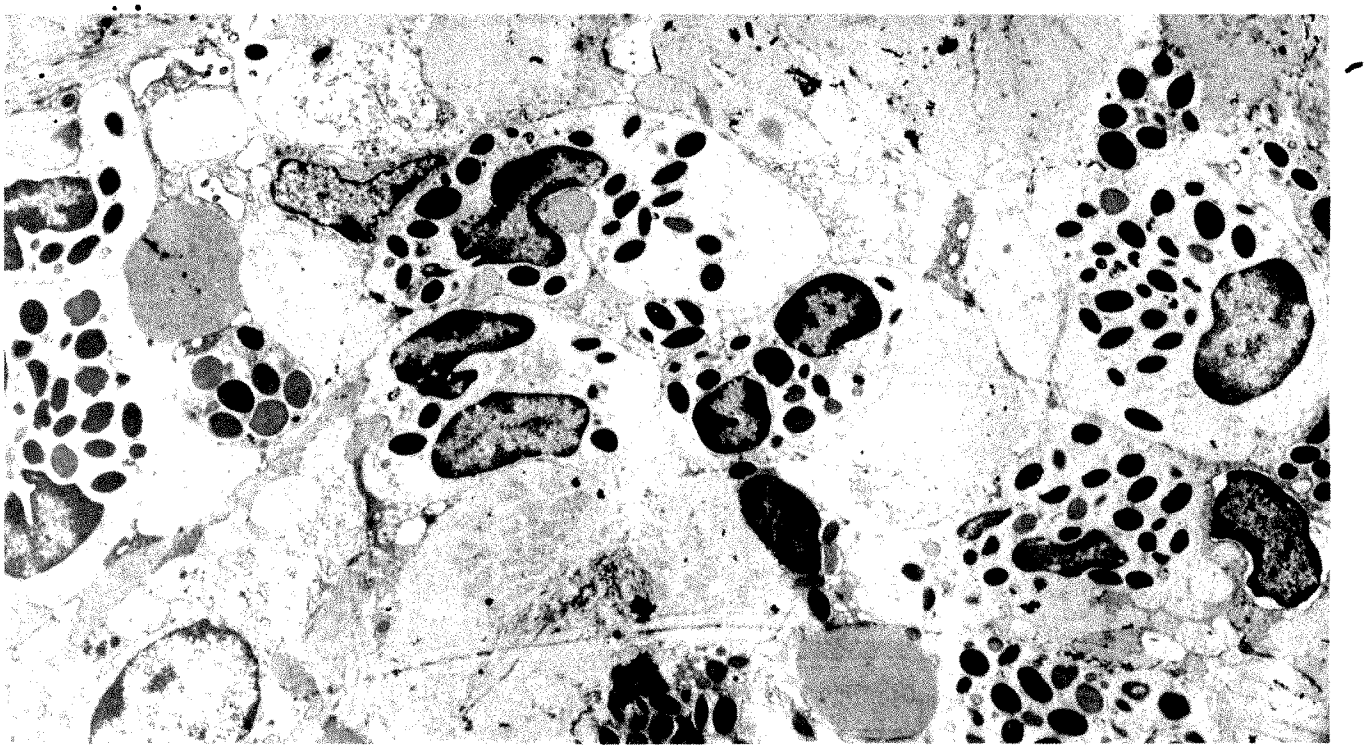

Fig 3.—Skin of sensitized guinea pig 48 hours after application of 0.1% dinitrochlorobenzene. Numerous basophils in dermis (original magnification ×7,000).

The intercellular spaces were enlarged in many areas of the epidermis, and desmosomal contacts were partially lost. Some of the intercellular space was clear and contained a uniform finely granular substance. Occasionally, free neutrophil granules were observed between the keratinocytes. The activated lymphocytes, some basophils, and a rare macrophage composed the intraepidermal cellular infiltrate.

Twenty-Four to 48 Hours.—At this time, the number of macrophages and activated lymphocytes in the tissue seemed to be reduced, particularly in comparison with the number of basophils, which was substantially increased (Fig 3). Some macrophages contained membrane-bound basophil granules. Macrophages also contained nuclei of degenerated cells. Almost all the macrophages with pinocytic activity were associated with activated lymphocytes, basophils (Fig 4), and occasionally eosinophils. Some basophil granules were observed in the interstitial space. Some basophils seemed to be nearly normal, and others contained principally clear vacuoles, myelin figures, and glycogen granules. Some basophil granules were membrane-bound, and others were partially membrane-bound, with an irregular peripheral border. Many granules did not have the consistent parallel arrangement of their lamellae, partly or wholly lacking periodicity. In other granules, the electron density was not homogeneous, and electron-lucent membrane-bound vesicles also were observed, giving a honeycomb appearance to the cells.

The epidermis in some areas was normal, and in other areas, it showed intercellular and intracellular edema, with decrease in tonofilaments in the keratinocytes. Some dark cells with dense, degenerate cytoplasm were found (dark keratinocytes). Langerhans' cells were observed in the upper epidermis, and no association with inflammatory cells could be documented. While some activated macrophages and lymphocytes could still be found in the epidermis, the number of basophils was much more striking (Fig 5). Many epidermal basophils were observed alone or in clusters. When observed in groups in the epidermis, these basophils often were associated with macrophages. Their location was in the lower epidermis near the basal lamina and in the middle and upper epidermis near the stratum corneum (Table 2 and Fig 2).

Cellular Histochemistry.—The acid phosphatase method in normal and in sensitized nontested guinea pig skin showed rare dermal round cells with a positive cytoplasm. After the challenge test, there was an infiltrate of mononuclear cells in the dermis at two hours, which was positive for acid phosphatase. The number of these cells increased until 12 hours and then diminished. At 24 and 48 hours, scattered or grouped positive cells were found. Acid phosphatase-positive cells were not found in normal epidermis or at two hours after the test, but some were observed at six hours, and many epidermal acid phosphatase-positive cells were observed at 12 hours. Subsequently, their number decreased.

Alkaline phosphatase is not found in normal guinea pig skin, except associated with hair follicle papilla and with the tactile hair disk of Pinkus. At two hours after DNCB challenge, two of six guinea pigs showed a few scattered dermal-positive cells recognized as polymorphonuclear leukocytes. The unstained polylobed appearance of the nucleus could be easily discerned in enzyme-positive cytoplasm. The number of positive cells increased until 12 hours. At 24 and 48 hours, only a few positive cells were observed in the dermis. In the epidermis, the number of positive cells reached a peak at 12 hours, and thereafter only foci of epidermal enzyme activity related to desquamated crust formation were observed. Several of the guinea pigs developed microscopic pustules of leukocytes in the upper

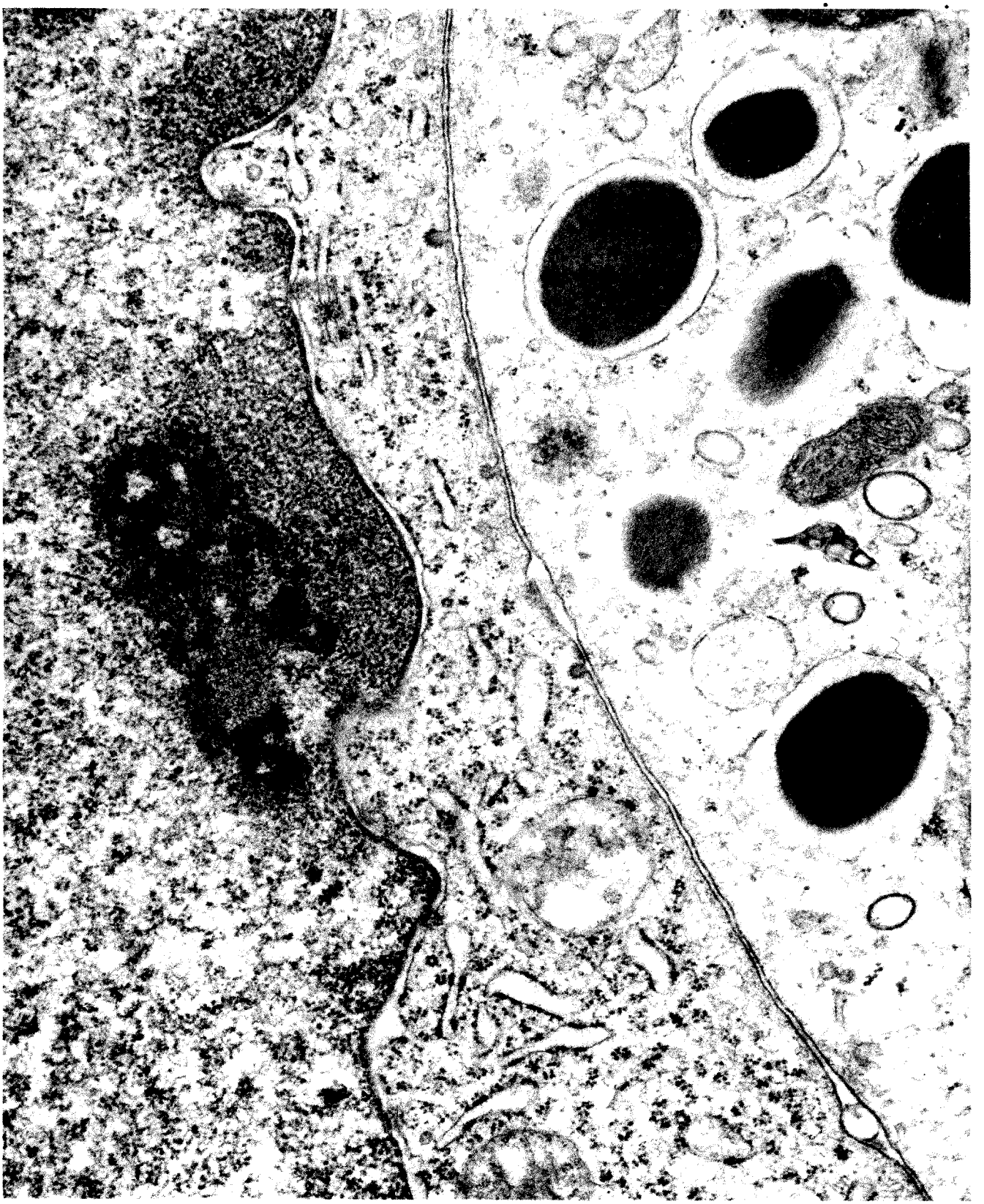

Fig 4.—Skin of sensitized guinea pig 12 hours after application of 0.1% dinitrochlorobenzene. Macrophage with endocytic activity adjacent to basophil (×17,500).

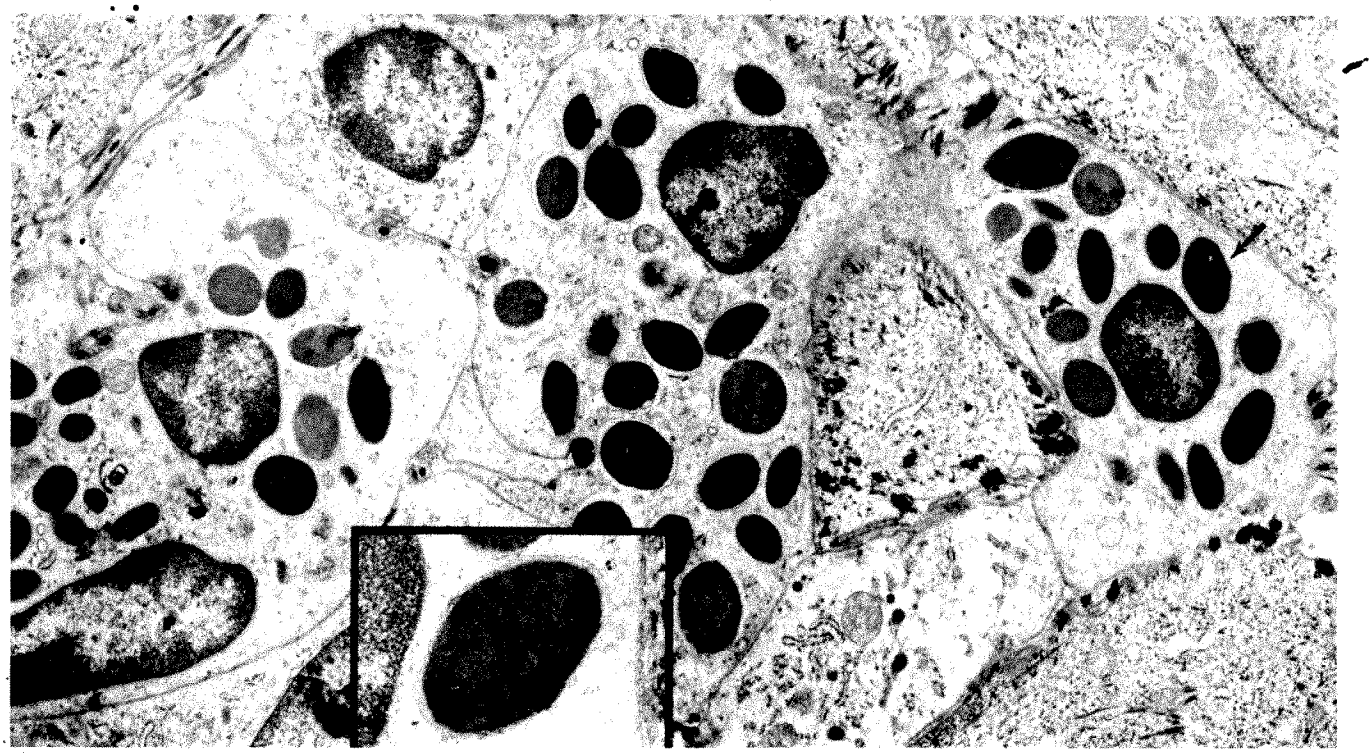

Fig 5.—Skin of sensitized guinea pig 48 hours after application of 0.1% dinitrochlorobenzene. Basophils in epidermis (×10,500). Inset, Basophil granule (original magnification ×31,500).

follicles, and these foci also were positive for alkaline phosphatase.

COMMENT

The primary role of the lymphocyte in allergic contact dermatitis is unquestioned and is confirmed again in this study. The passive transfer by lymphocytic cells and the inhibition of the reaction by antilymphocytic serum[18] indicate that the lymphocyte is the necessary cell for the reaction. Similarly, the macrophage-lymphocyte and the Langerhans' cell-lymphocyte interactions in the dermis and epidermis are an accepted part of the reaction. Although basophils may occur routinely in the dermis and epidermis as part of the reaction, in 1974, Katz et al[13] showed that, in the almost complete absence of basophils, allergic contact dermatitis occurred in cyclophosphamide-pretreated guinea pigs, with an enhanced cutaneous macroscopic reaction. In 1976, Askenase,[19] using guinea pigs sensitized with oxazolone in complete Freund's adjuvant, showed that the challenge reaction was strong, long-lasting, and devoid of basophils. Furthermore, he transferred a basophil-rich reaction to nonsensitized guinea pigs, using cells of these strongly sensitized guinea pigs. The absence of basophils may be related to such strong, long-lasting reactions. Eosinophils may occur in large numbers in special types of delayed hypersensitivity, as that induced by citraconic anhydride, but their usual few numbers is unrelated to the standard pattern of reaction.

One major finding in the present study was the close cell-to-cell contact in the dermis of the macrophage-Langerhans' cell population with the other cells of the infiltrate. Beginning with the lymphocytes, the activated macrophage formed cell-to-cell contact. Endocytosis from cell to cell was observed. Later, similar relationships were established with polymorphonuclear leukocytes and rarely with eosinophils. Most important for this study was the developing relationship of macrophages and basophils. At first, a clustering of basophils with macrophages was observed; later, with partial degranulation, the granules or portions of the cytoplasm were engulfed by macrophages. If we had used dermal injection and Freund's adjuvant for sensitization, the macrophage activity might have been greater, because this would have induced a nonspecific macrophage activation.[20]

While the basophil is not necessary to experimental epicutaneous delayed hypersensitivity reaction, it is a frequent and important part of the reaction. The marked dermal infiltration with basophils at 24 and 48 hours demonstrated the potential role of mast-cell mediators in the delayed hypersensitivity reaction. Dvorak et al[8,21] even while emphasizing the special features of cutaneous basophil hypersensitivity that was produced by soluble protein antigens in the Jones-Mote reaction, stated that basophils are an expected part of the cellular reaction of delayed hypersensitivity in animals and man. However, the basophil leukocytes may accumulate locally, so that their number in relation to other cells may become more than 20 to 30 times larger than that seen in the blood. Although the number of peripheral blood basophils increases after initial sensitization with DNCB,[7] no correlation was found in this study between peripheral WBC counts and basophil counts at the times of observation. The peripheral basophil count in the guinea pig was 0.6%/cu mm (mean of 107 normal guinea pigs); generally only a few basophils or mast cells are observed in normal guinea pig skin. Ward et al[22] have shown that the chemotactic factors for basophils include a substance (lymphokine) in culture fluid from antigen-stimulated lymphocytes and that monocytes can adsorb basophil chemotactic activity. A specific antigen also can suppress basophil chemotaxis. The mechanism is still unclear, but this could explain the behavior of basophils in delayed

hypersensitivity: (1) their large number in dermis and epidermis in the late reaction when the monocytes are less in number and the Langerhans' cells have disappeared in the epidermis, at the moment when the macroscopic reaction is fading, and (2) their absence in strong, long-lasting reactions, where antigen presumably persists.[11,19]

The basophils observed during the early phases of the reaction of guinea pig contact sensitivity do not have the dramatic features of degranulation found in anaphylaxis. The changes in the granules indicate that metabolic activity or a release of some substances may have occurred, but these changes are so different from those in anaphylaxis that a role other than anaphylaxis must be considered for the basophil. Because of the late appearance of the basophil in the tissues, we wonder whether a growth factor, such as histamine or a mediator from the basophil, might not have a role in resolving the inflammation. Also important may be the presence of mast cells or basophils in the epidermis of normal gingiva (which is rapidly dividing and renewing itself) or in chronically damaged epidermis (such as in prurigo nodularis [J. A. Doyle, S. Connolly, R. K. Winkelmann, unpublished observation], lichenification with massive IgE blood levels,[23] tuberculosis verrucosa cutis, and bromoderma).[24] In these conditions, the presence of basophils or mast cells in the epidermis might be related to the repair stimulus rather than to the primary reaction.

Our study indicates that one method of tissue examination for basophils in inflammation is not sufficient. The data could only have been obtained and checked by the use of the fluorescent acridine orange method, the histochemical NASDCAE method, and thick- and thin-section examination by electron microscopy; each technique has its individual virtues, and together they provide needed confirmation during the course of the progressive inflammation seen in experimental contact dermatitis.

References

1. Landsteiner K, Chase MW: Experiments on transfer of cutaneous sensitivity to simple compounds. *Proc Soc Exp Biol Med* 49:688-690, 1942.

2. Bandmann H-J: Monocyten bei experimentellem Kontaktekzem: I. Beitrag zur Frage der Zusammensetzung entzündlicher Infiltrate bei allergischen Reaktionen der Haut. *Hautarzt* 18:122-133, 1967.

3. Braun-Falco O, Burg G: Histochemische und cytochemische Untersuchungen bei der allergischen DNCB-Kontaktdermatitis des Meerschweinschens. *Arch Klin Exp Dermatol* 239:307-322, 1970.

4. Turk JL, Heather CJ, Diengdoh JV: A histochemical analysis of mononuclear cell infiltrates of the skin with particular reference to delayed hypersensitivity in the guinea pig. *Int Arch Allergy* 29:278-289, 1966.

5. Wolff HH, Braun-Falco O: Zur Ultrastruktur dermaler Veränderungen bei der allergischen Epicutantestreaktion des Menschen. *Arch Dermatol Forsch* 240:219-236, 1971.

6. Wolf-Jürgensen P: The role of the basophilic leucocyte in hypersensitivity. *Curr Probl Dermatol* 4:178-202, 1972.

7. Hunziker N, Brun R, Jadassohn W: Basophilia in sensitized guinea-pigs. *Experientia* 21:590, 1965.

8. Dvorak HF, Dvorak AM, Simpson BA, et al: Cutaneous basophil hypersensitivity: II. A light and electron microscopic description. *J Exp Med* 132:558-582, 1970.

9. Askenase PW, Haynes JD, Hayden BJ: Antibody-mediated basophil accumulations in cutaneous hypersensitivity reactions of guinea pigs. *J Immunol* 117:216-224, 1976.

10. Chase MW: Developments in delayed-type hypersensitivities: 1950-1975. *J Invest Dermatol* 67:136-148, 1976.

11. Katz SI, Heather CJ, Parker D, et al: Basophilic leukocytes in delayed hypersensitivity reactions. *J Immunol* 113:1073-1078, 1974.

12. Gomori G: The distribution of phosphatase in normal organs and tissues. *J Cell Comp Physiol* 17:71-83, 1941.

13. Leder L-D: *Der Blutmonocyt*. Berlin, Springer-Verlag, 1967, p 227.

14. Spurr AR: A low-viscosity epoxy resin embedding medium for electron microscopy. *J Ultrastruct Res* 26:31-43, 1969.

15. Hunziker N: *Experimental Studies on Guinea Pig's Eczema: Their Significance in Human Eczema*. Berlin, Springer-Verlag, 1969.

16. Miescher G: Ekzen: Histopathologie, Morphologie, Nosologie, in Marchionini A (ed): *Handbuch der Haut- und Geschlechtskrankheiten*. Berlin, Springer-Verlag, 1962, vol 2, part 1, pp 1-112.

17. Silberberg I, Baer RL, Rosenthal SA: The role of Langerhans cells in contact allergy: I. An ultrastructural study in actively induced contact dermatitis in guinea pigs. *Acta Derm Venereol* 54:321-331, 1974.

18. Geczy CL, Geczy AF, de Weck AL: Antibodies to guinea pig lymphokines: II. Suppression of delayed hypersensitivity reactions by a "second generation" goat antibody against guinea pig lymphokines. *J Immunol* 117:66-72, 1976.

19. Askenase PW: Cutaneous basophil hypersensitivity uncovered in cell transfer of classical tuberculin hypersensitivity. *J Immunol* 117:741-747, 1976.

20. Bruley-Rosset M, Florentin I, Khalil AM, et al: Nonspecific macrophage activation by systemic adjuvants: evaluation by lysosomal enzyme and *in vitro* tumoricidal activities. *Int Arch Allergy Appl Immunol* 51:594-607, 1976.

21. Dvorak HF, Dvorak AA: Cutaneous basophil hypersensitivity, in Brent L, Holborow J (eds): *Progress in Immunology*. Amsterdam, Elsevier Publishing Company, 1974, vol 3, pp 171-181.

22. Ward PA, Dvorak HF, Cohen S, et al: Chemotaxis of basophils by lymphocyte-dependent and lymphocyte-independent mechanisms. *J Immunol* 114:1523-1531, 1975.

23. Winkelmann RK, Gleich GJ: Chronic acral dermatitis: Association with extreme elevations of IgE. *JAMA* 225:378-381, 1973.

24. Green RM, Cordero A, Winkelmann RK: Epidermal mast cells. *Arch Dermatol* 113:166-171, 1977.

Topical Treatment of Herpes Labialis With Chloroform

Cynthia A. Taylor, MD; J. Owen Hendley, MD; Kenneth E. Greer, MD; Jack M. Gwaltney, Jr, MD

• **The efficacy of topical chloroform treatment of herpes labialis (HL) was evaluated in 50 patients with culture-verified HL. Treatment was begun within 48 hours of lesion onset, with either chloroform or camphor-in-oil placebo applied locally once a day for three days. Patients were observed daily by one investigator who also cultured and photographed the lesions. The photographs were evaluated by two other investigators. By direct observation, the time for scab formation was significantly less in the group treated with chloroform ($P < .01$). No difference in time to healing was noted. Blind evaluation of the serial photographs showed a trend for more rapid scab formation and healing in patients treated with chloroform, but the differences were not significant. The minimal benefit derived from topical chloroform therapy of HL does not appear sufficient to recommend its routine use.**

(*Arch Dermatol* 113:1550-1552, 1977)

A safe and effective treatment for herpes simplex labialis (HSL) is not available, although many remedies have been tried. Lipid solvents, specifically chloroform or ether, have been suggested for topical treatment of HSL and have been thought to be effective in uncontrolled observations.[1-3] As recently recommended by Sabin,[3] a controlled trial of this form of therapy is needed. This report describes such a study in which chloroform was used as the treatment compound because it is not explosive, as is ether.

Accepted for publication June 1, 1977.

From the Departments of Internal Medicine (Drs Taylor and Gwaltney), Pediatrics (Dr Hendley), and Dermatology (Dr Greer), University of Virginia School of Medicine, Charlottesville.

Reprints not available.

PATIENTS AND METHODS

Patients

Volunteers, both male and female, with recurrent HSL were recruited from the general population of Charlottesville, Va, during April and May 1975. They ranged in age from 19 to 60 years, with the majority being 20 to 30 years old. All volunteers were ambulatory, otherwise in good health, and gave informed consent to participate in the study.

Participants contacted an investigator at the first premonitory sign of eruption of the herpetic lesion. Seventy volunteers were seen with lesions less than 48 hours old; 45 of the 70 had lesions that were positive for herpes simplex virus (HSV) by culture. Four of the 45 virus-positive cases were lost to follow-up. The analysis of efficacy of the test compound was based on evaluation of the 41 virus-positive patients who completed the study.

Compounds

Undiluted chloroform was the test substance, and 10% camphor in mineral oil was the placebo. Previous in vitro studies verified the virucidal effect of chloroform and the absence of any measurable virucidal activity of the camphor-in-oil, with use of a standard test for virus inactivation[4] with 10^5 tissue culture ineffective dose ($TCID_{50}$) per milliliter of virus. Both compounds were in identical, coded bottles; volunteers were randomly assigned to receive chloroform or the placebo. Although it was possible to distinguish between the two compounds, participants were not told what compounds were being used and were not thought to be prejudiced in favor of either compound as being the test substance or placebo. Indeed, a few volunteers recognized the odor of the camphor-in-oil and, associating it with Camphophenique, thought it was the treatment substance. The compound was applied directly to the lesions with a cotton-tipped swab for ten minutes once a day for three consecutive days.

Clinical Observations

The lesions were cultured and photographed prior to each treatment. After the three treatment days, each patient returned on alternate days to have the lesion cultured and photographed either until it had healed or for a total of nine days. Four methods of evaluating response to treatment were utilized.

1. Direct observation: Five factors were measured daily by the investigator (C.A.T.) who applied the compounds: subjective burning, tenderness, vesicle rupture, scab formation, and healing. Although all factors were analyzed, the two that were most helpful in comparing the patients' courses were the length of time to drying or scab formation and the length of time to healing of the lesion.

2. Analysis of photographs: Two investigators who were unaware of which compound was applied reviewed serial photographs of the lesions of each patient with a lesion less than 24 hours old when first treated. One investigator was a

Table 1.—Mean Number of Days to Scab Formation and Healing With Chloroform Treatment Versus Placebo: Direct Observation

	Lesion < 24 Hours Old*			Lesion > 24 < 48 Hours Old*		
	Chloroform (15 Patients)	Placebo (11 Patients)	*P* Value†	Chloroform (9 Patients)	Placebo (6 Patients)	*P* Value†
Scab formation	1.1	2.3	0.0004	1.3	1.7	0.2
Healing	5.7	6.1	0.6	5.8	6.2	0.5

*Treatment begun either within 24 hours or between 24 and 48 hours after onset of lesion.
†*P* value determined by Student's *t* test.

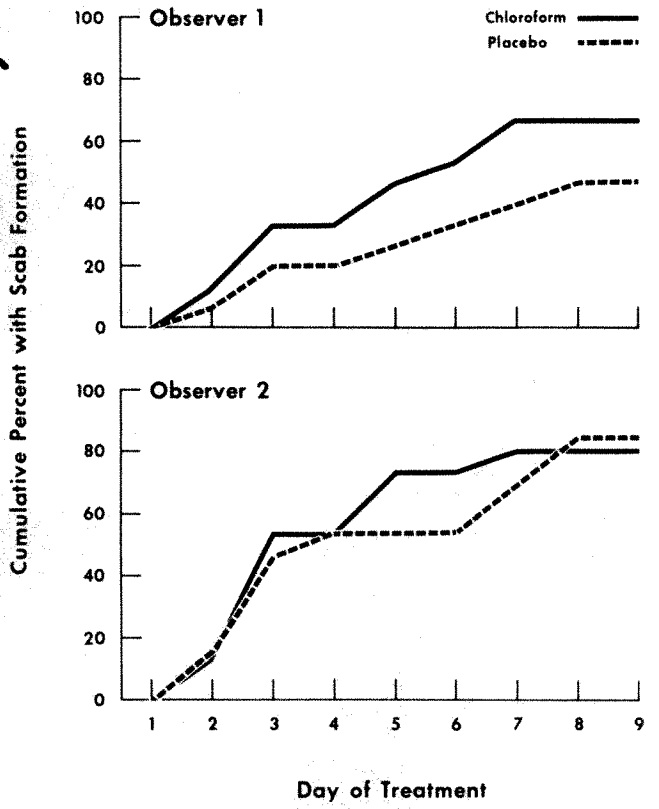

Fig 1.—Scab formation of herpes labialis in patients treated with chloroform vs placebo; evaluation by two independent observers from photographs.

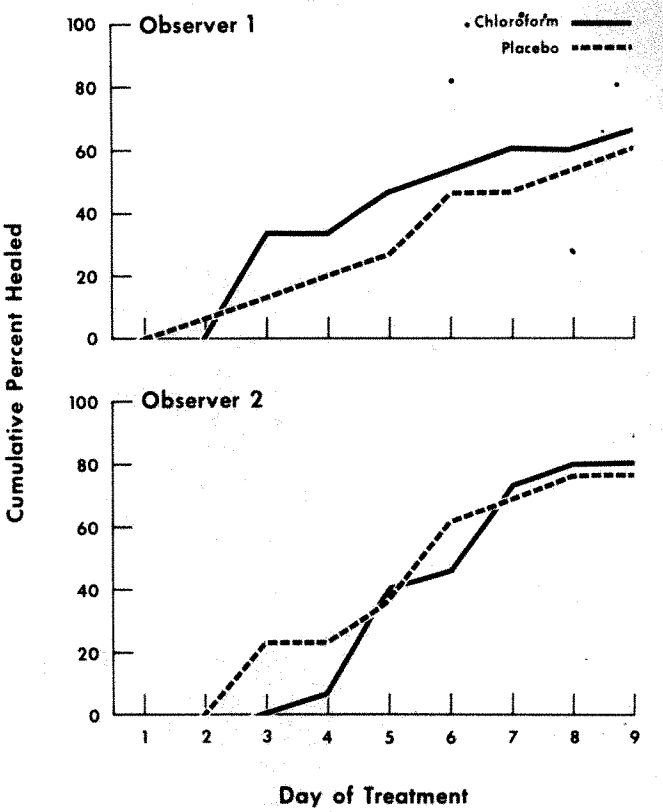

Fig 2.—Healing of herpes labialis in patients treated with chloroform vs placebo; evaluation by two independent observers from photographs.

Table 2.—Efficacy of Chloroform Therapy Versus Placebo: Subjective Evaluation by Patients

	Lesion < 24 Hours Old*			Lesion > 24 < 48 Hours Old*		
	Chloroform (15 Patients)	Placebo (15 Patients)	P Value†	Chloroform (9 Patients)	Placebo (6 Patients)	P Value†
Efficacious	12/15	7/15	0.06	2/9	2/6	0.85
Not Efficacious	0/15	3/15	0.1	3/9	2/6	0.7
Unable to determine	3/15	5/15	0.3	4/9	2/6	0.5

*Treatment begun either within 24 hours or between 24 and 48 hours after onset of lesion.
†*P* value determined by Fisher exact test.

Table 3.—Recovery of HSV in Culture From Patients With HSL

Day of Treatment	Chloroform	Placebo	Total
1	20/20*	17/20	**37/40†**
2	9/11	9/11	**18/22**
3	4/9	8/12	**12/21**
4-6	0/10	0/4	**0/14**
7-8	0/6	0/5	**0/11**

*Number of patients positive/number of patients cultured.
†One patient not cultured on day 1.

dermatologist, the other an internist specializing in infectious diseases. Factors for evaluation included lesion "active" (with subcategories, "same," "better," or "worse"), lesion "inactive" (that is, scab formation), and lesion "healed."

3. Subjective impression of efficacy by treated patient: At the end of the nine study days, each participant was asked to judge whether the treatment had facilitated healing of the lesion. Volunteers answered "yes," "no," or "unable to determine" in response to the question: "Do you feel this treatment has helped your fever blister heal?"

4. Viral shedding: Each day the patient was seen the lesion was swabbed with a dry cotton-tipped applicator, prior to application of the compound. The swab was immediately placed in 2 ml of beef heart infusion broth with 1% bovine serum albumin. Within six hours, 0.2 ml of the broth was inoculated into each of two tubes of human embryonic lung cells (WI-38). Identification of HSV was made by a standard neutralization test.[4] No attempt was made to distinguish between type 1 and type 2 HSV.

RESULTS

Direct Observation

For analysis, the patients were divided into those with a lesion that was less than 24 hours old when treatment was begun and those who were first treated when the lesion was between 24 and 48 hours old (Table 1). In the less-than-24-hour group, the mean time from initiation of treatment to scab formation on direct observation was 1.1 days in the 15 patients treated with chloroform and 2.3 days in the 11 patients treated with placebo ($P = .004$, Student's t test). The mean time for healing was 5.7 days with chloroform treatment and 6.1 days with placebo ($P = .6$, Student's t test). In the group of patients with lesions between 24 and 48 hours old, the time to scab formation was 1.3 days in nine patients

treated with chloroform vs 1.7 days in the six receiving the placebo. Mean times for healing were 5.8 and 6.2 days for the chloroform and placebo groups, respectively. These differences were not statistically significant.

Analysis of Photographs

Observer 1 noted a consistent trend on days 2 through 9 for more rapid scab formation in the patients who received chloroform (Fig 1). Observer 2 interpreted the same photographs as showing a higher proportion of patients receiving chloroform with scab formation on days 3, 5, 6, and 7, but a clear trend was not evident. Statistical analysis of the results from both observers showed no significant differences (Fisher exact test).

The time to healing of the lesion was determined from review of the same group of photographs (Fig 2). Observer 1 read the photographs as showing a trend for faster healing in the chloroform group (days 3 through 7 and 9), while interpretation by observer 2 showed no trend. Again, there were no statistically significant differences in percent of lesions healed with chloroform vs placebo treatment on any day.

Subjective Evaluation of Efficacy

Of those treated within 24 hours of onset of the lesion, 12/15 (80%) treated with chloroform vs 7/15 (47%) treated with placebo thought that the treatment was effective ($P = .06$, Fisher exact test) (Table 2). The proportion who thought treatment was ineffective or who could not tell were similar in the two groups. Patients treated more than 24 hours after the appearance of the lesions noted no difference in efficacy.

Viral Shedding

There was no difference in recovery of virus from lesions treated with chloroform compared to the camphor-in-oil placebo (Table 3). Of interest is the fact that HSV was not recovered from any lesions after three days, regardless of which compound was applied.

COMMENT

A preliminary evaluation of chloroform therapy for HSL was conducted by this laboratory in 1974, with use of a volunteer population similar to that in the current study. The time to scab formation was shortened significantly in patients treated with chloroform vs placebo as determined by the direct observations of one observer who was aware of which compound each patient was receiving.

In the current study, chloroform treatment again hastened scabbing as determined by direct observation. The experimental design of this trial was improved by including evaluation of serial photographs by two observers who were unaware of the treatment status of the volunteers. A consistent trend for more rapid scab formation and healing of the lesions of patients treated with chloroform compared to those treated with placebo was noted by one observer. However, the differences in the rate of healing and scabbing were neither very impressive nor statistically different. The second observer did not detect any appreciable difference in scabbing and healing times of the two groups from the photographs.

Each patient was questioned about the length of time HSL lesions usually lasted. Their responses correlated well with healing time observed in previous studies[5-9] with a mean of 5 to 12 days and a range of 1 to 42 days. However, the average time to scabbing noted in the current study was markedly different from that reported by Myers et al.[10] In this study scabbing times were 1.1 and 2.3 days with chloroform or placebo, respectively (values determined by direct observation). Myers et al found that the mean time to scabbing was 5.5 days in both neutral red- and placebo-treated patients. The intervals before healing were similar in the two studies. The average healing time in the current study was 5.7 and 6.1 days, chloroform and placebo treatment, respectively, and 7.5 and 7.1 days for neutral red and placebo, respectively, in the study of Myers et al. Differences in the method of evaluation and between the observer judging day-to-day changes in the lesion may explain the observed differences between the two studies.

Cultures were positive for HSV in 45 (64%) of 70 suspected HSL lesions. No virus shedding occurred after three days with lesions cultured serially, a finding also reported by Daniels and LeGoff.[11] Sixteen patients with lesions exclusively on the oral mucosa were cultured and none were positive for HSV. These latter patients were thought to have aphthosis, a condition unrelated to HSV infection.

The findings of the current study suggest that the daily topical application of chloroform may be of minimal benefit in the treatment of HSL. Efficacy might be improved by variation in the treatment regimen, such as more frequent application. Similarly, other solvents active against the lipid envelope of HSV might be more effective, though the explosive potential of ether makes that compound unsafe for casual use.

Since this study was conducted, chloroform has been implicated as a cause of liver cancer in mice and kidney cancer in rats (National Cancer Institute, March 1976). Subsequently, the Food and Drug Administration has banned the use of chloroform in any drug or domestic product, although products currently on the market will not be recalled.[12] Because of the limited treatment efficacy of topical chloroform for herpes labialis, and because of the theoretical concerns of chloroform carcinogenesis, the treatment should not be used around the mouth where oral ingestion is likely. Topical chloroform may be of some use in the treatment of herpes genitalis; however, verification would be contingent on appropriate controlled clinical trials.

The University of Virginia Student Health Service cooperated in this study; Anne Calhoun and laboratory staff provided technical assistance; and Jacqueline Grubbs and Linda Lynch provided secretarial assistance.

References

1. Nugent GR, Chou SM: Treatment of labial herpes, editorial. *JAMA* 224:132, 1973.
2. Pasricha JS, Nayyar KC, Pasucha A: A new method for treatment of herpes simplex. *Arch Dermatol* 107:775, 1973.
3. Sabin AB: Misery of recurrent herpes: What to do? editorial. *N Engl J Med* 293:986, 1975.
4. Tokumaru T: Herpesviruses, in Lennette EH, Schmidt NJ (eds): *Diagnostic Procedures for Viral and Rickettsial Infections*. New York, American Public Health Association, Inc, 1969, pp 641-700.
5. Georges JC, de Lavergne E, Foliquet JM, et al: Étude des réactions immunitaires au cours de l'infection herpétique récurrente chez l'homme. *Rev Immunol* 35:309-317, 1970.
6. Kibrick S, Katz AS: Topical idoxuridine in recurrent herpes simplex. *Ann NY Acad Sci* 173:83-89, 1970.
7. Corbet MB, Sidell CM, Zimmerman M: Idoxuridine in the treatment of cutaneous herpes simplex. *JAMA* 196:441-444, 1966.
8. Hall-Smith SP, Corrigan MJ, Gilkes MJ: Treatment of herpes simplex with 5-iodo-2-deoxyuridine. *Br Med J* 2:1515-1516, 1962.
9. Juel-Jensen BE, MacCallum FO: Treatment of herpes simplex lesions of the face with idoxuridine: Results of a double blind controlled trial. *Br Med J* 2:987-988, 1964.
10. Myers MG, Oxman MN, Clark JE, et al: Failure of neutral-red photodynamic inactivation in recurrent herpes simplex virus infections. *N Engl J Med* 293:945-949, 1975.
11. Daniels CA, LeGoff SG: Shedding of infectious virus/antibody complexes from vesicular lesions of patients with recurrent herpes labialis. *Lancet* 2:524-528, 1975.
12. Food and Drug Administration. Chloroform as an ingredient of human drug and cosmetic products. *Federal Register* 41:26842 (June 29), 1976.

Erythropoietic Porphyria

Two Cases and the Results of Metabolic Alkalinization

George S. Stretcher, MD

• **Two previously unreported cases of erythropoietic porphyria are presented. Therapeutic modalities are discussed along with the results of both short- and long-term metabolic alkalinization. Although there was a substantial increase in urinary coproporphyrin excretion during a six- to 8-day period of alkalinization, three months of alkalinization therapy resulted in no substantial depletion of porphyrin stores and both patients continued to have new skin lesions develop, indicating no clinical improvement.**

(*Arch Dermatol* 113:1553-1557, 1977)

Erythropoietic porphyria (Günther's disease), a congenital disorder of porphyrin metabolism, is quite rare, with slightly more than 70 cases reported in the literature.[1] Affected patients seem to have a relative deficiency of uroporphyrin III cosynthetase (isomerase)[2] that results in preferred production of the type I isomer of uroporphyrinogen rather than the usual synthesis of the type III porphyrin isomers. Excessive production of porphyrin, taking place mainly in the bone marrow, results in increased levels of blood, urinary, and fecal porphyrins. Recurrent vesiculobullous eruptions on sun-exposed areas of the skin eventually result in mutilating ulceration and scarring. Hypertrichosis, hyperpigmentation, brown-stained teeth that fluoresce, brownish red urine, and hemolytic anemia are the other usual clinical features.

Accepted for publication April 28, 1976.

From the Department of Dermatology, Medical College of Georgia, Augusta. Dr Stretcher is now in private practice in Spartanburg, SC.

Reprint requests to Professional Building, 711 N Church St, Spartanburg, SC 29303 (Dr Stretcher).

It is hypothesized that in erythropoietic porphyria, and also in porphyria cutanea tarda, the manifestations of increased fragility and susceptibility to blister formation in light-exposed areas of the skin are due to excessive accumulations of porphyrin (especially uroporphyrin) molecules that, when activated by radiant energy penetrating the skin, cause tissue damage. A depletion of tissue stores of porphyrin in either of these two types of porphyria could perhaps ameliorate the skin manifestations.

Wiegand et al[3] and Perry et al[4] have reported that patients with porphyria cutanea tarda will benefit from metabolic alkalinization, presumably by depletion of porphyrin tissue stores, through increased excretion of coproporphyrin. Rational for this treatment is based on the work by Bourke et al[5] that established that urinary coproporphyrin excretion is increased in the presence of an alkaline urine. This is apparently due to the pK of coproporphyrin that dictates that coproporphyrin, filtered or secreted into the alkaline media of the renal tubule, converts from an unionized, lipid-soluble, weakly acidic molecule to an ionized, relatively lipid-insoluble form that cannot back diffuse and hence is excreted.

Uroporphyrin excretion is not affected by alkalinization. Depletion of uroporphyrin by alkalinization would require a stepwise depletion of coproporphyrin, coproporphyrinogen, and through increased activity of the uroporphyrinogen decarboxylase system depletion of its immediate precursor, uroporphyrinogen. If, during the period of metabolic alkalinization, there is increased excretion of coproporphyrin (secondary to alkalinization of the urine), indirect depletion of uroporphyrin through stepwise depletion of coproporphyrin precursors, and no compensatory production of uroporphyrin and coproporphyrin, one would hope to obtain a favorable clinical improvement.

Two new cases of erythropoietic porphyria are reported with the results of a therapeutic trial of metabolic alkalinization. The effects of metabolic alkalinization were studied in two phases. To document the immediate effect on porphyrin urinary excretion, there was an initial short-term period of alkalinization during which continuous 24-hour urinary porphyrin levels were monitored. This was followed by an extended period of alkalinization to determine if there were any depletions of porphyrin stores, as reflected by lowered 24-hour urinary porphyrin levels.

REPORT OF CASES

CASE 1.—A 54-year-old woman of Irish ancestry was first admitted to Eugene Talmadge Memorial (Augusta, Ga) Hospital on Nov 11, 1968. She gave a history of blister formation on sun-exposed areas and red urine since 4 years of age. The blisters originally occurred more frequently during the summer, but in the past decade there had been no seasonal variation. Bullae, occurring spontaneously and also at sites of trauma, generally became infected and ulcerated leaving residual fibrosis and scarring. Although the patient was edentulous, both she and her relatives confirmed that her teeth had had a brownish stain. There was no history of severe anemia, abdominal pain, or neurological disorder.

On admission, the patient had multiple infected ulcerated lesions on the upper and lower extremities. No vesicles were present. There was facial hypertrichosis (Fig 1), generalized hyperpigmentation, bilateral scleral erosions, and a palpable spleen tip. The hands were considerably deformed with scarring, contractures, partial resorption of the terminal phalanges, and loss of nails (Fig 2). The diagnosis of congenital

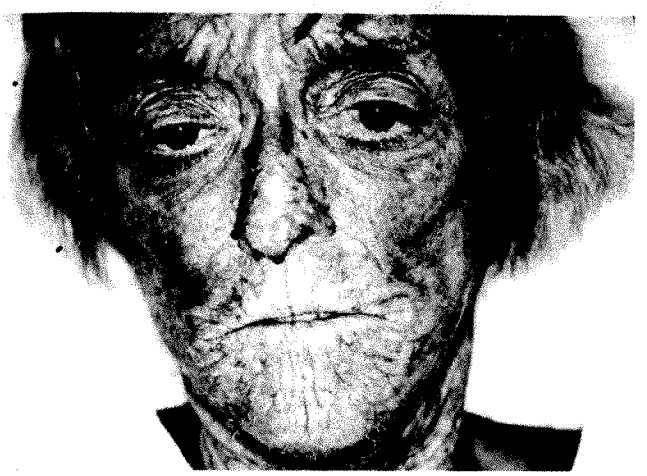

Fig 1.—Patient 1, Facial hypertrichosis, hyperpigmentation, and scarring.

Fig 2.—Patient 1, Deformed hand with ulcerations, scarring, resorption of terminal phalanges, and loss of nails.

Table 1.—Porphyrin Determinations During Initial Hospitalization*

Porphyrin	URO	COPRO	PROTO
Urine, μg/24 hr			
Patient 1	4,083	1,380	
Patient 2	2,375	1,858	
Normal	10-30	100-250	
Stool, μg/24 hr			
Patient 1	482	10,792	
Patient 2	432	20,938	
Normal	10-40	400-1,100	
RBC, μg/100 ml			
Patient 1	115	115	139
Patient 2	82	73	166
Normal	0	0.5-1.5	25-50

*URO indicates uroporphyrin; COPRO, coproporphyrin; PROTO, protoporphyrin.

erythropoietic porphyria was made on the basis of negative urinary porphobilinogen, elevated urinary uroporphyrin and coproporphyrin levels, and the presence of 4% to 5% "fluorocytes" with fluorescence of a peripheral blood preparation. Results of liver function studies were within normal limits. Hematologic studies included the following values: hematocrit, 38%; hemoglobin, 11.6 gm/100 ml; reticulocytes, 9.8%; WBCs, 11,400/cu mm; platelets 457,500/cu mm; serum iron, 27 μg/100 ml; total iron binding capacity, 210 μg/100 ml. Examination of the peripheral smear showed a mildly hypochromic, microcytic pattern with no normoblasts or bizarre RBC morphology. Roentgenologic studies revealed generalized demineralization of osseous structures, resorption of the terminal phalanges of both hands, a congenital hip dislocation on the left, and a radiodensity in the right upper abdominal quadrant interpreted as probably representing a gallstone.

After discharge, the patient continued to have intermittent development of infected ulcers on the extremities from both sites of blisters and in areas of no previous blister formation, despite avoidance of direct sunlight and conditions predisposing toward trauma to the skin. These responded to debridement and oral administration of antibiotics although healing was slow and there was residual scarring.

The patient was readmitted on Feb 19, 1970, for the purpose of evaluating the short-term effects of alkalinization for systemic effect. Physical findings were essentially unchanged except for new purulent ulcers on the right hand and both forearms. Laboratory data included the following values: WBCs, 6,600/cu mm; hematocrit, 45%; hemoglobin, 14.2 gm/100 ml; reticulocytes, 4.4%; platelets, 217,500/cu mm; and a negative direct Coombs test. Again, examination of the peripheral blood smear showed no normoblasts or bizarre morphology. Table 1 gives porphyrin determinations during the hospitalization. Stool protoporphyrin level was 422 μg/100 gm wet weight (normal range, 200 to 2,350 μg/100 gm wet weight). Red blood cell protoporphyrin levels were elevated, ranging from 139 to 201 μg/100 ml.

CASE 2.—March 9, 1970, was the first Eugene Talmadge Memorial Hospital admission for this patient, a 14-year-old boy of Irish ancestry and a distant cousin of patient 1. He also gave a history of blistering and recurrent infected ulcers on sun-exposed areas since 1 year of age. Freshly voided urine had been noted to be of a reddish brown color since infancy and the permanent teeth had always had a brownish discoloration. There was no history of anemia, abdominal pain, or neurological disorders.

Physical examination on admission showed several crusted, purulent, superficial ulcers on both lower legs. Focal areas of scar formation were present on the sun-exposed areas of the body (Fig 3). Hypertrichosis was remarkable but mainly confined to the face and areas of scar formation (Fig 4). All of his teeth had a brown discoloration and exhibited a red fluorescence with Wood's light examination. Additional physical findings were blepharitis of the right eyelid and palpable spleen on inspiration.

Laboratory data included elevated urinary, blood, and stool uroporphyrin and coproporphyrin levels (Table 1). Stool protoporphyrin level was 1,600 μg/100 gm wet weight. Red blood cell protoporphyrin levels were elevated ranging from 103 to 166 μg/100 ml. A test for urine porphobilinogen was negative. Fluorescence of a peripheral blood preparation revealed the presence of several "fluorocytes." Hematologic studies during this admission included a WBC count of 11,400/cu mm; a hematocrit reading of 41.4%; a hemoglobin value of 13.6 gm/100 ml; a platelet count of 177,500/cu mm; a reticulocyte count of 3.0%; a serum iron value of 45 μg/100 ml; a total iron binding capacity of 189 μg/100 ml; and a negative direct Coombs test. A peripheral blood smear showed no normoblasts or bizarre morphology; however, there was a slight hypochromia. *Staphylococcus aureus* coagulase-positive and group A β-hemolytic *Streptococcus* grew from cultures of the purulent ulcers. A flat plate roentgenogram of the abdomen confirmed the physical finding of splenomegaly. Immunofluorescence studies on a biopsy specimen from the dorsum of the hand obtained during an outpatient visit on Dec 21, 1973, revealed no deposition of immunoglobulin about the blood vessel walls or at the basement membrane.

METHODS

Initial Short-Term Alkalinization Therapy

For initial evaluation of systemic alkalinization, each patient was hospitalized for approximately 18 days in which there were three separate periods of study: before, during, and after alkalinization. An ad lib

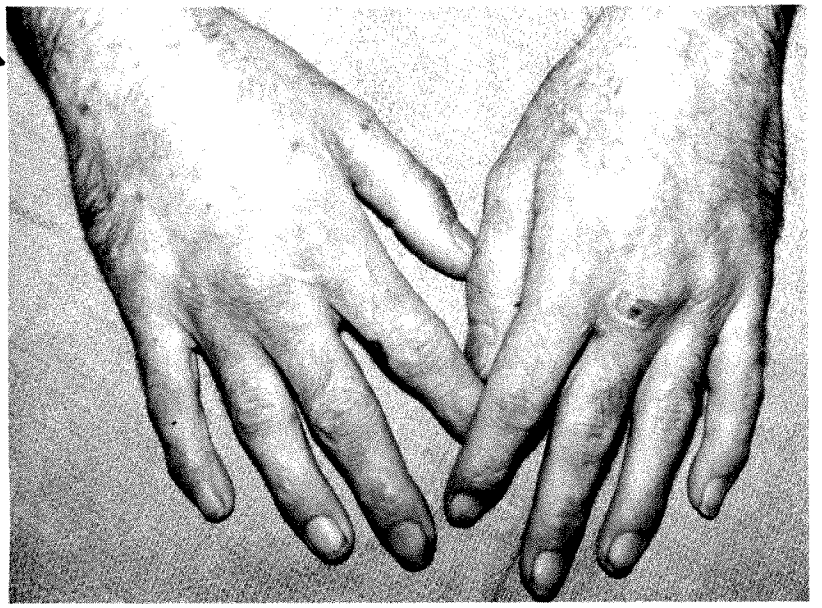

Fig 3.—Patient 2, Superficial scar formation on dorsum of hands.

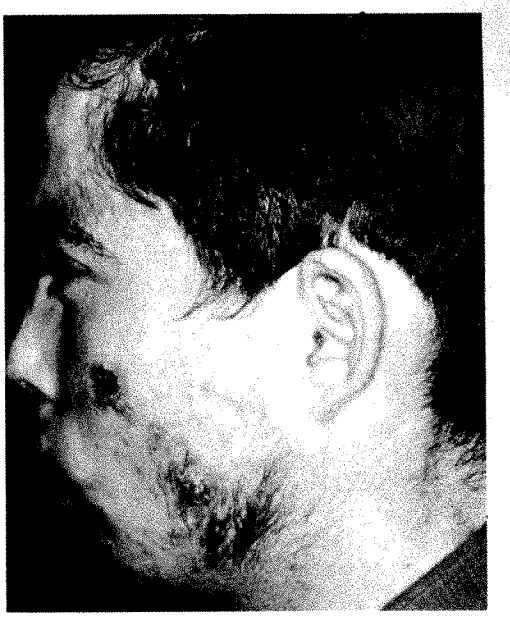

Fig 4.—Patient 2, Focal areas of superficial ulcerations, scar formation, and hypertrichosis on face.

diet and fluid intake were allowed. Approximately 40 ml of blood was drawn biweekly for routine hematologic studies and RBC porphyrins. Alkalinization for systemic effect designed to maintain a urinary pH of between 7 and 8 for the majority of each day was accomplished by daily oral doses of sodium bicarbonate amounting to 4.2 gm for patient 1 and 4.8 gm for patient 2. Continuous 24-hour urines were collected for porphyrin determinations and each 24-hour specimen was analyzed with 12 hours of collection. Sodium bicarbonate was not added to the collection bottles since coproporphyrin and uroporphyrin determinations on paired collections of acidic porphyric urines with and without added sodium bicarbonate showed no significant difference when analyses was performed on the same day of urine collection. Total creatine level was determined on each 24-hour urine specimen to ensure completeness of collection.

Porphyrin analyses were carried out by the method of Schwartz et al[6] except for the "split batch" method of uroporphyrin analysis as described by Talman.[7] Determinations were performed on the Amico spectrophotofluorometer with the Corning 7-51 and Wratten 2C as primary filters and a Wratten 23A as a secondary filter. The coproporphyrin standard was obtained from Harleco.

Long-Term Alkalinization Therapy

The second phase of the study evaluated the effects of long-term alkalinization in which both patients received systemic alkalinization therapy on an outpatient basis for a period of approximately 3½ months. Patient 1 started therapy on Nov 9, 1972, and patient 2 began therapy on Nov 19, 1972, receiving 4.2 gm and 4.8 gm of sodium bicarbonate, respectively. Porphyrin determinations on 24-hour urine collections were performed using the same methods described previously for short-term alkalinization therapy.

Table 2.—24-Hour Urinary Porphyrin Values During Initial Short-Term Alkalinization (μg/24 hr)*

	Patient 1		Patient 2	
	COPRO	URO	COPRO	URO
Before alkalinization, group 1	2,215	2,749	1,858	2,375
	1,965	2,823	1,555	1,365
	1,936	3,572	1,457	1,623
	1,953	1,819	1,296	1,390
	1,600	2,321	1,521	1,793
			1,884	1,575
	1,934 ± 98†	2,651 ± 290	1,595 ± 95	1,687 ± 152
During alkalinization, group 2	2,129	1,609	...	...
	2,319	1,898	2,223	1,550
	2,270	2,453	2,394	1,578
	2,635	2,246	2,479	1,902
	2,353	2,301	2,188	2,013
	2,596	2,646	2,037	1,668
	2,554	2,287	2,300	2,086
	2,482	2,374	...	...
	2,417 ± 63	2,227 ± 116	2,270 ± 64	1,799 ± 94
After alkalinization, group 3	2,349	4,489	1,572	1,485
	2,148	3,195	2,151	2,097
	2,016	2,957	2,071	2,109
	2,545	2,164	1,877	1,578
	2,284	3,416	...	...
	2,268 ± 90	3,245 ± 376	1,918 ± 129	1,817 ± 166

*COPRO indicates coproporphyrin; URO, uroporphyrin.
†This is the mean ± SE.

RESULTS

Table 2 gives a summary of the data for the 24-hour urinary porphyrin determinations done during the initial phase of the study. Group 1 represents the baseline collections during which there was no alkalinization. Urinary pH during this period obtained on each freshly voided specimen ranged from 4.5 to 6.5. Group 2 includes the days of sodium bicarbonate administration plus one additional day since urinary pHs remained alkaline for the majority of the 24 hours after discontinuation of medication. Group 3 includes the postalkalinization collections during the period in which there was an acidic urine. The first 24-hour urine collection in group 2 (patient 2) was deleted since urinary creatine levels indicated incomplete collection.

Table 3 gives an analysis of the results statistically. There is a consid-

Table 3.—Statistical Analysis (Student's *t*-test) of Urinary Porphyrin Levels During Initial Short-Term Alkalinization*

Patient	Group	COPRO	URO
1	1 vs 2	$P < .01$	NS
	2 vs 3	NS	$P < .05$
	1 vs 3	$P < .05$	NS
2	1 vs 2	$P < .001$	NS
	2 vs 3	$P < .005$	NS
	1 vs 3	$P < .1$	NS

*URO indicates uroporphyrin; COPRO, coproporphyrin; and NS, not significant.

erable and statistically significant difference between the coproporphyrin values obtained before (group 1) and during (group 2) alkalinization. The difference between the values obtained during (group 2) and after alkalinization (group 3) are not as marked because of an increase in coproporphyrin levels from the period before alkalinization (group 1) to the period after alkalinization (group 3). This finding of increased levels of both coproporphyrin and uroporphyrin in the period immediately following alkalinization as compared with the baseline levels before alkalinization may represent residual effects of alkalinization or perhaps a natural variation in the disease; however, the most likely explanation is that by obtaining rather sizable biweekly blood samples, we stimulated erythropoiesis, which in turn, can cause increased blood and urinary porphyrin levels.[6-8] Evidence for erythropoiesis was noted in patient 2 in that the reticulocyte count increased from 3.0% to 8.0% during the period of initial alkalinization.

The results of the second phase of the study in which there was long-term alkalinization therapy are seen in Fig 5 and 6. Patient 1 showed an increase in urinary porphyrins during the course of alkalinization and patient 2 showed a slight, but nonsignificant decrease at the end of alkalinization. The lack of a substantial decrease in the urinary excretion of porphyrins during this period indicates that alkalinization therapy was unsuccessful in depleting porphyrin stores. In addition, in both patients new skin lesions continued to develop during and at the end of the study, thus reflecting no clinical improvement.

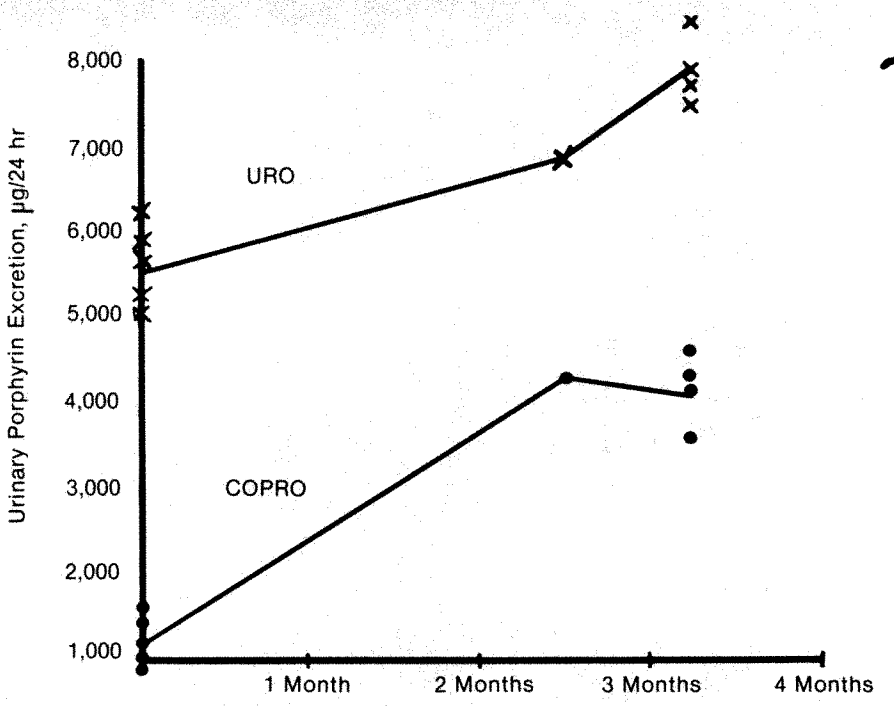

Fig 5.—Urinary porphyrin excretion during 3+ months of alkalinization in patient 1. URO indicates uroporphyrin; COPRO, coproporphyrin.

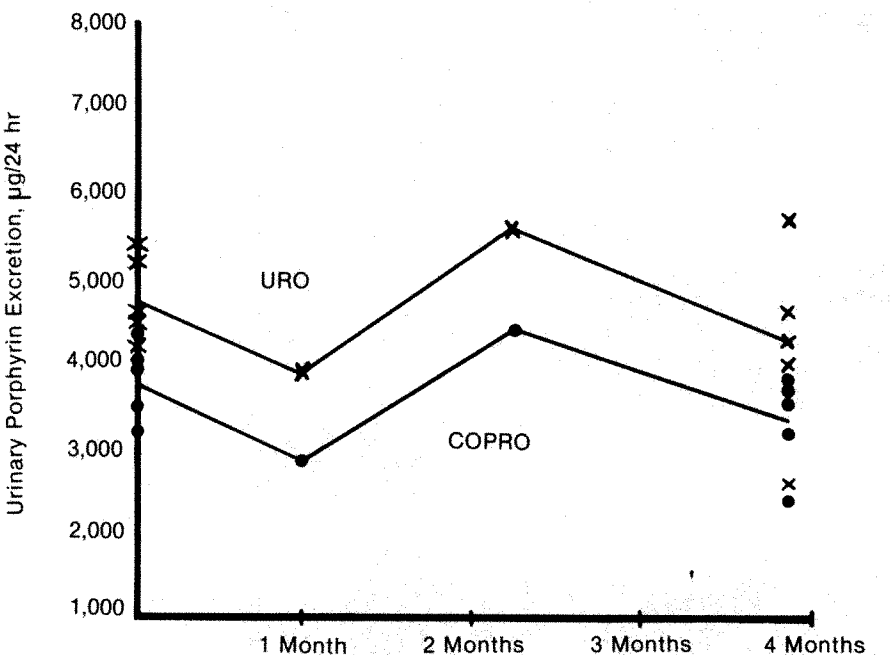

Fig 6.—Urinary porphyrin excretion during 3+ months of alkalinization in patient 2. URO indicates uroporphyrin; COPRO, coproporphyrin.

COMMENT

The following are several explanations as to the lack of effectiveness of metabolic alkalinization in congenital erythropoietic porphyria. One is porphyria cutanea tarda (PCT), which although having certain similarities to congenital erythropoietic porphyria is a different disease entity with differing metabolic defects. Therapy that proves effective for PCT is not necessarily guaranteed to also be effective for erythropoietic porphyria. That the period of alkalinization may be too short is a second explanation. The period of alkalinization used in this study was essentially the same as that used in cases of PCT.[1] Allowing for possible differences in total body stores or production rates of porphyrins, successful therapy with alkalinization in erythropoietic porphyria may require longer periods of therapy than that recommended for PCT.

Third, there are natural variations in disease activity and levels of porphyrin excretion in all of the porphyrias. There is a possibility that both patients may have been in an "up swing" of disease activity during the study, thus masking the benefits of alkalinization therapy. Finally, metabolic alkalinization may not be effective therapy for porphyria. Many of the patients with PCT were also instructed to discontinue their intake of alcohol; thus, one may question whether the improvement in disease was the result of alkalinization or the abstinence from alcohol. Of those patients with PCT who did not discontinue alcohol consumption during alkalinization, three of a total of five showed clinical and chemical improvement.[4] These numbers would not seem sufficient for any definite conclusions on the efficacy of metabolic alkalinization for porphyria cutanea tarda and certainly there was no dramatic improvement in the patients in our two cases of erythropoietic porphyria.

OTHER THERAPEUTIC MODALITIES

Attempts to prevent repeated hemolytic crises and the mutilating long-term effect of recurrent bullae followed by infected ulcerations, dramatically illustrated by patient 1, have led to the investigation of several modes of therapy for erythropoietic porphyria. Splenectomy has been performed in several patients and although there have been reports of clinical improvement,[9-11] other studies have shown only a transient or lack of response.[12-14] Chloroquine, an antimalarial, and desferrioxamine, an agent for reducing serum iron levels, were given to one patient who showed no improvement of the anemia or levels of porphyrin excretion with either form of therapy.[14] Chatterjea[15] has reported four cases, three of which showed considerable improvement of the anemia with the administration of prednisolone. In the fourth case, in which there was no anemia, there was a decrease in the urinary excretion of porphyrins. The value of prednisolone in reversing anemia was confirmed by Kramer et al[16]; however, Kaufman et al[14] obtained no clinical improvement after giving prednisolone. An initial report of beneficial effects from the administration of purines[17] led to its investigation in three other patients in whom there was no biochemical or clinical improvement.[18,19] Induced polycythemia by means of transfusions of packed RBCs does seem to inhibit erythropoiesis and to reduce the levels of excreted porphyrins,[20] but, this mode of therapy in chronic disease would seem impractical.

Recently, there have been encouraging reports of the use of beta carotene for the photoprotection in erythropoietic protoporphyria.[21] Beta carotene may also prove to be effective in cases of erythropoietic porphyria; however, this is not a foregone conclusion since the clinical and biochemical features of the two diseases are different.

There is a preliminary report suggesting the efficacy of beta carotene therapy in one case of congenital erythropoietic porphyria.[22] However, short-term therapeutic studies are difficult to evaluate due to few objective measurements of clinical response. The induction of skin lesions using monochromatic light sources is useful in evaluating therapy in cases of congenital protoporphyria; however, skin lesions in congenital erythropoietic porphyria can generally not be reproduced by this method. There have been attempts to monitor disease activity in the various porphyrias through the use of induced suction blisters[23]; unfortunately, this method was not satisfactory in our two patients because of the unreproducibility of control suction blister times (range: from 30 to 84 minutes when tested on the forearm using a 2.2-cm glass cup with continuous suction of 120 mm of Hg).

CONCLUSION

At the present, there does not seem to be a satisfactory therapy for congenital erythropoietic porphyria. The incidence of scarring from skin lesions may be reduced by minimal sun exposure to sunlight, avoidance of minor trauma to the skin, and the prompt treatment of bacterial infections occurring in ulcerated blister sites. Three months of metabolic alkalinization did not result in any substantial improvement. The effects of beta carotene administration await a critical long-term study.

References

1. Marver HS, Schmid R: The porphyrias, in Stanbury JB, Wyngaarden JB, Fredrickson DS (eds): *The Metabolic Bases of Inherited Disease*, ed 3. New York, McGraw-Hill Book Co Inc, 1972, pp 1087-1140.
2. Romeo G, Levin EY: Uroporphyrinogen III cosynthetase in human congenital erythropoietic porphyria. *Natl Acad Sci* 63:856-863, 1969.
3. Wiegand SE, Copeman PWM, Perry HO: Metabolic alkalinization in porphyria cutanea tarda. *Arch Dermatol* 100:544-549, 1969.
4. Perry HO, Mullanax MG, Wiegand SE: Metabolic alkalinization therapy in porphyria cutanea tarda. *Arch Dermatol* 102:359-367, 1970.
5. Bourke E, Monckton Copeman PW, Milne MD, et al: Effect of urinary pH on excretion or porphyrins. *Lancet* 1:1394-1396, 1966.
6. Schwartz S et al: Determination of porphyrins in biological materials, in Glick D (ed): *Methods of Biochemical Analysis*. New York, Interscience Publishers Inc, 1960, vol 8, pp 221-293.
7. Talman EL: Porphyrins in urine, in Seligson D (ed): *Standard Methods of Clinical Analysis*. New York, Academic Press Inc, vol 2, 1958, pp 137-146.
8. Wass W: Studies on bovine porphyria, PhD thesis. University of Minnesota, Minneapolis, 1961.
9. Rosenthal IM, Lipton EL, Asrow G: Effect of splenectomy on porphyria erythropoietica. *Pediatr* 15:663-673, 1955.
10. Vardi S: Haematologic aspects in a case of erythropoietic porphyria. *Br J Haematol* 4:270-280, 1958.
11. Aldrich RA, Hawkinson V, Grinstein M, et al: Photosensitive or congenital porphyria with hemolytic anemia: I. Clinical and fundamental studies before and after splenectomy. *Blood* 6:685, 1951.
12. Gray CH, Muir H, Newberger A: Studies in congenital porphyria: III. The incorporation on ^{15}N into the haem and glycine of haemoglobin. *Biochem J* 47:542, 1950.
13. Gross S: Hematologic studies on erythropoietic porphyria: A new case with severe hemolysis, chronic throbocytopenia, and folic acid deficiency. *Blood* 23:762-775, 1964.
14. Kaufman BM, Vickers HR, Rayne J, et al: Congenital erythropoietic porphyria. *Br J Dermatol* 9:210-220, 1967.
15. Chatterjea JB: Erythropoietic porphyria. *Blood* 24:806-807, 1964.
16. Kramer S, Viljoen E, Mayer AM, et al: The anemia of erythropoietic porphyria with the first description of the disease in an elderly patient. *Br J Haematol* 11:666-675, 1965.
17. Gajdos K, Gajdos-Török M: Clinical and experimental trial of adenosine-5-monophosphoric acid in porphyria. *Panminerva Med* 4:332-339, 1962.
18. Gross S: Hematologic studies on erythropoietic porphyria: A new case with severe hemolysis, chronic thrombocytopenia, and folic acid deficiency. *Blood* 24:762-775, 1964.
19. Haining RG, Cowger ML, Shurtleff DB, et al: Congenital erythropoietic porphyria: I. Case report, special studies and therapy. *Am J Med* 45:624-637, 1968.
20. Haining RG, Cowger ML, Labbe RF, et al: Congenital erythropoietic porphyria: II. The effects of induced polycythemia. *Blood* 36:297-309, 1970.
21. Mathews-Roth MM, Pathak MA, Fitzpatrick TB, et al: Beta-carotene as a photoprotective agent in erythropoietic porphyria. *N Engl J Med* 282:1231-1234, 1970.
22. Seip M, Thune PO, Eriksen L: Treatment of photosensitivity in congenital erythropoietic porphyria with beta-carotene. *Acta Derm Venereol* 54:239-240, 1974.
23. Kiistala V, Mustakallio KK: Dermo-epidermal separation with suction: electron microscopic and histochemical study of initial events of blistering on human skin. *J Invest Dermatol* 48:466-477, 1967.

Ulcers of the Leg in Thalassemia

Dwight M. Stevens, MD; Jerome L. Shupack, MD; Jamshid Javid, MD; Robert Silber, MD

• Four patients had thalassemia and leg ulcers. In three patients the hematologic diagnosis of thalassemia had not been previously made; the presenting symptom was the leg ulcer. The diagnosis of thalassemia should be considered in patients who have unexplained chronic leg ulcers; the incidence of this complication of thalassemia may be higher than previously reported.

(*Arch Dermatol* 113:1558-1560, 1977)

Leg ulcers have long been known to occur with certain blood dyscrasias. The incidence of this complication has been estimated at 5%[1] to 75%[2] in sickle cell anemia, 0[3] to 27%[4] in sickle cell-β thalassemia, and 6%[5] in hereditary spherocytosis. Only 13 cases[6-15] of leg ulcers have previously been reported in patients with thalassemia.

Over a two-year period the diagnosis of thalassemia was made in four patients referred to the New York University Medical Center for treatment of leg ulcers. This cutaneous finding, which was the presenting symptom of the disease in three of the patients, led to the hematologic diagnosis.

REPORT OF CASES

CASE 1.—A 33-year-old black woman came to the outpatient clinic with a painless ulcer overlying the right medial malleolus. The ulcer had been present for four months and had slowly increased in size without evidence of healing.

The patient had three previous leg ulcers. The first of these occurred at age 10 on the lateral side of the left leg and lasted six years before healing completely. At the age of 24, another ulcer occurred over the right pretibial area. It healed spontaneously after two years. A third ulcer appeared at age 31 on the left medial malleolus and healed after six months.

The patient had known of anemia since age 15 and had required blood transfusions on three different occasions because of severe symptoms. She had tired easily and had experienced dyspnea on exertion since the age of 16.

On physical examination the patient had pallor of the conjunctivas and mucous membranes. There was no scleral icterus. A grade 3/6 systolic murmur was heard along the left sternal border. The spleen extended to the pelvic brim. Slight pitting edema was noted over the ankles. A 2.5 × 3-cm, punched-out ulcer was present overlying the right medial malleolus (Fig 1).

Laboratory data (Table) indicated the diagnosis of thalassemia. The ulcer healed in four months with daily application of gentian violet and absorbable gelatin sponge (Gelfoam) powder.

CASE 2.—The 36-year-old brother of the first patient came to the clinic with ulcers on the medial sides of both legs. These ulcers had been present for seven years and had decreased in size on different occasions without healing completely. Skin grafts had been unsuccessful. There had been no notable improvement after the patient underwent splenectomy five months prior to our examination.

Physical examination was unremarkable except for the shallow ulcers above both medial malleoli, each measuring 5 × 9 cm (Fig 2).

Laboratory data are summarized in the Table. The leg ulcers were treated with daily application of gentian violet and absorbable gelatin sponge powder with marked improvement. The patient moved from the area and was lost to further follow-up.

The family of these first two patients had been previously studied,[16] and both parents were found to have elevated hemoglobin A_2 levels and normal fetal hemoglobin (Hb F). Another brother also had a history of leg ulcers, and he was found to have a markedly elevated Hb F value of 26%.

CASE 3.—A 37-year-old Chinese man had a leg ulcer that had gradually enlarged over 14 months. The patient had known of anemia since age 12. A splenectomy had been performed in 1957 in Hong Kong. At that time he was told he had "Cooley's anemia." He subsequently has been in good health.

On physical examination the patient was found to have icteric scleras. A grade 3/6 systolic ejection murmur was heard along the lower left sternal border. A well-healed splenectomy scar was noted. The liver was palpated 7 cm below the right costal margin. A 6 × 6-cm necrotic ulcer was noted over the right medial malleolus.

Laboratory data are shown in the Table. The patient was treated with complete bed rest, soaks, and topical antibiotics, but the ulcer showed no evidence of healing. Skin grafts were then successfully performed.

The patient had two children, aged 3 and 5. Both were healthy without notable medical problems, and both had Hb F values of 5%.

CASE 4.—A 24-year-old man of Iranian parentage was referred for evaluation of indolent leg ulcers. The patient had been anemic since childhood but had not required blood transfusions or hospitalization.

Three years before admission he sustained minor trauma to the skin over his left medial malleolus. The abrasions failed to heal, and a gradually enlarging ulcer developed that did not respond to conservative treatment.

On physical examination, a grade 2/6 systolic murmur was heard at the apex. The spleen was palpated 6 cm below the left costal margin. Darkly pigmented skin was noted over both ankles, and a 2.5 × 6-cm ulcer was present over the left medial malleolus.

Laboratory findings are given in the Table. The patient's older brother was clinically well; he had a hemoglobin level of 13.9 gm/100 ml with mean corpuscular volume (MCV), 73 cu μ; mean corpuscular hemoglobin (MCHb), 23 pg; Hb A_2, 5.2%; and Hb F, 5.1%. On the basis of the clinical and laboratory findings, it is likely that our patient is homozygous for the variety of thalassemia described by Schokker et al.[17]

On a regimen of complete bed rest, soaks, and topically applied antibiotics, the ulcer diminished in size to 1 × 5 cm, but it failed to heal completely. After discharge, it again increased in size. Multiple skin grafts were attempted but were unsuccessful.

COMMENT

A number of similarities between our patients and the 13 previously reported patients should alert the physician to the diagnosis of thalassemia. Most of the patients are young adults with few other symptoms when they first develop their leg ulcers, which are usually recurrent, bilateral, and tend to be located over the malleoli. In half of the cases, other members of the family have had ulcers and presumably had thalassemia. The racial background of the patient (Mediterranean, African, Middle Eastern, or Eastern Asiatic) should also alert the physician to this possibility.

Three different hemoglobins may be detected within the RBC of the normal child and adult. Each one is composed of one pair of identical α chains and a second pair that is unique to each hemoglobin. Hemoglobin A (α_2

Accepted for publication Sept 10, 1976.

From the Departments of Dermatology (Drs Stevens and Shupack) and Medicine, Division of Hematology (Drs Javid and Silber), New York University Medical Center.

Read in part before the New York Academy of Science, New York, May 7, 1974.

Reprints not available.

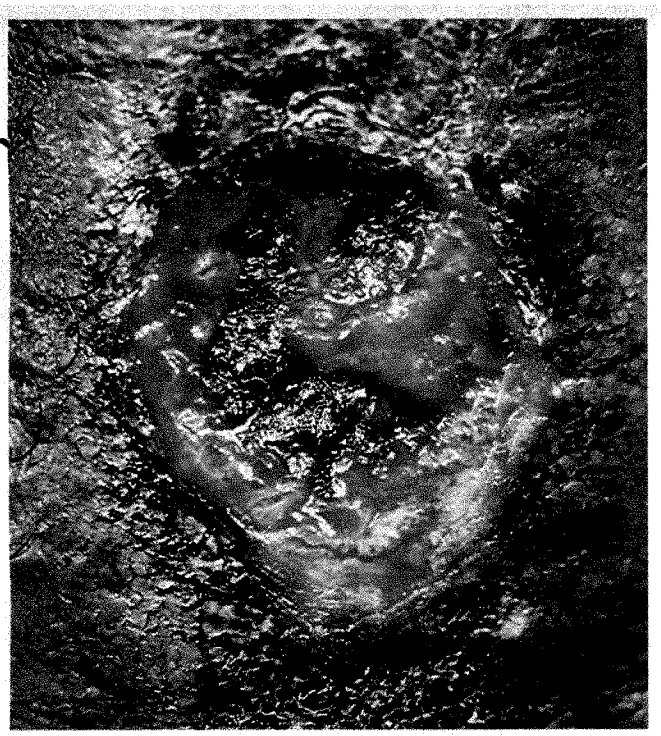

Fig 1.—2.5 × 3-cm punched-out purulent ulcer overlying right medial malleolus.

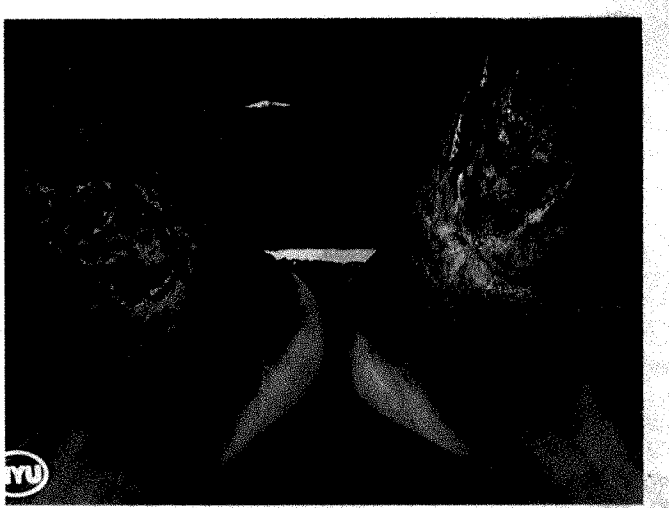

Fig 2.—Shallow ulcers, each measuring 5 × 9 cm, above both medial malleoli.

Hematologic Data										
Case	Hb, gm /100 ml	Hct, %	RBCs, Million/cu mm	MCV, cuμ	MCHb, pg	MCHC,* %	Hb F,† %	Hb A_2,‡ %	Hb S	Smear
1	7.9	23	4.1	56	19.7	34.3	58	4.8	0	Hypochromia, microcytosis, some anisocytosis and poikilocytosis, 28 nucleated RBC/100 WBCs
2	8.8	27	4.2	64	20.9	32.6	54	5.3	0	Hypochromia, microcytosis, marked poikilocytosis and leptocytosis, many nucleated RBC/high-power field (HPF)
3	9.3	31.4	3.9	80	23.8	29.6	39	5.4	0	Hypochromia, many target cells and occasional stomatocytes, minimal anisocytosis and polychromasia, many Howell-Jolly bodies, 350 nucleated RBC/100 WBC
4	10.7	31.8	4.0	79	26.7	33.6	98.5§	1.5	0	Hypochromia, marked anisocytosis and poikilocytosis, occasional nucleated RBC/HPF

*MCHC, mean corpuscular hemoglobin concentration.
†By one-minute alkali denaturation.
‡By column chromatography.[38]
§By column chromatography.[36] No Hb A could be detected in the sample by electrophoresis, chromatography, or radioimmunoassay.[37]

β_2) accounts for 96.5% to 98% of the total; Hb A_2 (α_2 δ_2) is present in small amounts (2% to 3.5% of total hemoglobin); and Hb F (fetal hemoglobin, α_2 γ_2) accounts for less than 1% of the total. The level of fetal hemoglobin at birth is 60% to 70%, but declines to the adult level by the first year of life.

Normally, the sum of β, δ, and γ chain synthesis is equal to α chain production. The thalassemia syndromes may be defined as conditions in which the synthesis of a specific hemoglobin polypeptide chain is reduced, which results in an unbalanced amount of polypeptide chains. The excess subunits are unstable and precipitate in the normoblasts as Heinz bodies; these in turn contribute to the hemolysis and ineffective erythropoiesis that characterize this disease.

The most common variety in the United States is β thalassemia, in which β chain synthesis is deficient. There are at least two, and probably more, varieties of β thalassemia genes. The one encountered more commonly among the people of Mediterranean origin is associated with total or nearly total lack of synthesis of the β chain, designated β^0. The variety encountered among the black population, β^+, allows the synthesis of reduced but measurable amounts of β chain. The wide range of clinical severity represents the occurrence of the β^0, β^+, and the normal β gene in various combinations.

The homozygotes for β^0 have severe limitation in β chain synthesis. These are the cases first described by Cooley and Lee in 1925.[18] They manifest a chronic anemia from early childhood, hepatosplenomegaly, and bone changes secondary to extramedullary hematopoiesis. Frequent transfusions are the rule, and most affected patients die before reaching adulthood. These patients have very high Hb F values, and are considered to

have thalassemia major.

A number of individuals with intermediate symptomatology of the disease fall somewhere between the clinical extremes. These patients have a notable but not severe anemia and elevated Hb F values. Their genotype is usually β^0 combined with β^+, or another less common type of thalassemia gene. These are termed thalassemia intermedia, and three of our patients (cases 1, 2, and 3) fall into this clinical category. The presentation in this group is quite variable. One manifestation that has not been often reported is ulceration of the leg. This is a well-known complication of sickle cell anemia,[19-31] most commonly in homozygous sickle cell disease (SS disease) and least commonly in the heterozygous variants (SC disease).[32] However, an awareness of leg ulcers as a manifestation of thalassemia is important since the diagnosis of thalassemia may not be initially suspected. Such was the case in three of our four patients where the leg ulcer was the initial manifestation of the disease.

Whereas the sickle cell anemia vaso-occlusive phenomena play a considerable role in the pathogenesis of leg ulcers, its cause in thalassemia is not clear. Several factors may be involved. The tissue over the bony prominences of the malleoli is subject to repeated physical trauma, and clinical experience has shown that injuries in this area have a tendency to heal poorly. Superimposed on this anatomic feature, some abnormalities in thalassemia may contribute toward the development of ulcers. Two possible factors may be the rheologic properties of the RBCs and their high content of fetal hemoglobin as observed in our four patients. The abnormal shape of the RBCs and the presence in them of inclusions[33] may limit their deformability and thus hinder the normal flow of blood in the capillaries. In patients with increased levels of Hb F the high affinity of this hemoglobin for oxygen[34] may also contribute to tissue hypoxia. It may be a combination of these factors that makes the skin of the ankles susceptible to ulceration in thalassemic patients.

Stamatoyannopoulos et al[35] and Braverman et al[16] have shown that there are many thalassemic patients with very high fetal hemoglobin levels and only mild symptoms of their disease. This has been especially noted in American blacks of no apparent Greek or Italian heritage. If the elevated fetal hemoglobin does play a notable role in the pathogenesis of the leg ulcers, more such cases of leg ulcers in relatively asymptomatic patients may be expected.

There is a remarkable similarity in the clinical presentation of the leg ulcers in patients with thalassemia or sickle cell anemia. The ulcers in both diseases occur in young adults, most commonly are bilateral, appear punched-out with a well-defined margin, heal slowly with scarring, and tend to overlie or be near the malleoli.

When the diagnosis of a hemoglobinopathy is suspected in a patient who has leg ulcers, a routine blood cell count with RBC indices and a reticulocyte count should be performed. The finding of a microcytic and hypochromic anemia, in the absence of iron deficiency, suggests the diagnosis of thalassemia. The finding of sickled cells on the blood smear should prompt further studies. These include a sickle cell preparation and hemoglobin electrophoresis. Further tests to characterize the qualitative and quantitative defect in hemoglobin synthesis, as indicated in the Table, should then be performed to make a diagnosis of thalassemia, sickle cell anemia, or sickle cell-β thalassemia disease. In doubtful cases, family study is indicated.

Conservative therapy with absorbable gelatin sponge and gentian violet resulted in healing of the ulcer in one patient and in marked improvement in another until he was lost to follow-up. One patient was successfully treated with a skin graft, while in another patient grafting was unsuccessful. Splenectomy or blood transfusions did not appear to be of any benefit in the healing of the ulcers.

References

1. River GL, Robbins AB, Schwartz SO: SC hemoglobin: A clinical study. *Blood* 18:385-416, 1961.
2. Diggs LW, Ching RE: Pathology of sickle cell anemia. *South Med J* 27:839-845, 1934.
3. Monti A, Feldhake C, Schwartz SO: The S-thalassemia syndrome. *Ann NY Acad Sci* 119:474-484, 1964.
4. Serjeant GR, Ashcroft MT, Serjeant BE, et al: The clinical features of sickle cell B thalassemia in Jamaica. *Br J Haematol* 24:19-30, 1973.
5. Gendel BR: Chronic leg ulcer in disease of the blood. *Blood* 3:1283-1289, 1948.
6. Estes JE, Farber E, Stickney JM: Ulcers of the leg in Mediterranean disease. *Blood* 3:302-306, 1948.
7. March HW, Schlyen SM, Schwartz SO: Mediterranean hemopathic syndromes (Cooley's anemia) in adults. *Am J Med* 13:46-57, 1952.
8. Pascher F, Keen R: Chronic ulcers of the leg associated with blood dyscrasias. *Arch Dermatol* 66:478-487, 1952.
9. Pascher F, Keen R: Leg ulcers associated with Cooley's anemia. *Arch Dermatol* 72:201-202, 1955.
10. Cooper CD, Wacker WEC: The successful therapy with streptokinase-streptodornase of ankle ulcers associated with Mediterranean anemia. *Blood* 9:241-243, 1954.
11. Pascher F, Keen R: Ulcers of the leg in Cooley's anemia. *N Engl J Med* 256:1220-1222, 1957.
12. Zelickson AS: Leg ulcers associated with Mediterranean anemia (thalassemia major and minor). *Arch Dermatol* 76:351-356, 1957.
13. Samitz MH, Waldorf DS, Sharager J: Leg ulcers in Mediterranean anemia. *Arch Dermatol* 90:567-571, 1964.
14. Pope FM: Leg ulceration and thalassemia. *Br J Dermatol* 80:840, 1968.
15. Berge G, Brehmer-Anderson E, Rorsman H: Thalassemia minor and painful ulcers of lower extremities. *Acta Dermatol Venereol* 50:125-128, 1970.
16. Braverman AS, McCurdy PR, Manos O, et al: Homozygous beta thalassemia in American blacks: The problem of mild thalassemia. *J Lab Clin Med* 81:857-866, 1973.
17. Schokker RC, Went LN, Bok J: A new genetic variant of beta thalassemia. *Nature* 209:44-46, 1966.
18. Cooley TB, Lee OD: A series of cases of splenomegaly in children with anemia and peculiar bone changes. *Trans Am Pediatr Soc* 37:29-30, 1925.
19. McGavack TH, Nussbaum CC: Skin manifestations of sickle cell anemia. *Urol Cutan Rev* 46:194-200, 1942.
20. King AD: Sickle cell anemia. *Arch Dermatol* 33:756-757, 1936.
21. Netherton EW: Sickle cell anemia with ulcer of the leg. *Arch Dermatol* 34:158-159, 1936.
22. Schwartz WF: Sickle cell anemia associated with ulcers of the legs. *Arch Dermatol* 37:866-867, 1938.
23. Cummer CL, LaRocco CG: Ulcers on the legs in sickle cell anemia. *Arch Dermatol* 40:459-460, 1939.
24. Krugh FJ: Sickle cell anemia: Ulcer on the leg. *Arch Dermatol* 40:656, 1939.
25. Ebert MH: Sickle cell anemia with ulcer of the left leg. *Arch Dermatol* 44:948-949, 1941.
26. Smith EM, Lewe AI: Sickle cell anemia associated with chronic ulcers of the leg and hyperkeratotic plaques. *Arch Dermatol* 44:946-947, 1941.
27. Chargin L: Ulcer of the leg in a patient with sickle cell anemia. *Arch Dermatol* 44:725-726, 1941.
28. Cummer CL, LaRocco CG: Ulcers on the legs in sickle cell anemia. *Arch Dermatol* 42:1015-1039, 1940.
29. Stewart JW, MacIver JE: Sickle-cell/haemoglobin-D disease. *Lancet* 1:23-25, 1956.
30. Smith EW, Conley CL: Sickle-cell hemoglobin D disease. *Ann Intern Med* 50:94-105, 1959.
31. Milner PF, Miller C, Grey R, et al: Hemoglobin O Arab in four Negro families and its interaction with hemoglobin S and hemoglobin C. *N Engl J Med* 283:1417-1425, 1970.
32. Serjeant GR: Leg ulceration in sickle cell anemia. *Arch Intern Med* 133:690-694, 1974.
33. Fessas P: Inclusions of hemoglobin in erythroblasts and erythrocytes in thalassemia. *Blood* 21:21-32, 1963.
34. The thalassemias and related disorders: Quantitative disorders of hemoglobin synthesis, in Wintrobe M, Lee GR, Boggs DR, et al (eds): *Clinical Hematology*. Philadelphia, Lea and Febiger, 1974, p 875.
35. Stamatoyannopoulos B, Fessas P, Papayannopoulou TF: Thalassemia. *Am J Med* 47:194-208, 1969.
36. Huisman TJJ, Doze AM: Studies on the heterogeneity of hemoglobin: IX. The use of tris (hydroxymethyl) aminomethane-HCl buffers in the anion exchange chromatography of hemoglobin. *J Chromat* 19:160-169, 1965.
37. Javid J, Pettis P: The immunologic identification of abnormal hemoglobins. *J Lab Clin Med* 88:621-626, 1976.

DeSanctis-Cacchione Syndrome

A Case Report With Autopsy Findings

William B. Reed, MD†; Gerald I. Sugarman, MD; Reed A. Mathis

• One of the first patients studied by Cleaver on the DNA repair defect to ultraviolet light damage in xeroderma pigmentosum has been subjected to autopsy examination. This patient had the DeSanctis-Cacchione syndrome (microcephaly, dwarfism, mental deficiency, and choreoathetosis). Her autopsy findings were similar to those of the other three patients with this syndrome, emphasizing olivopontocerebellar atrophy, who underwent autopsy. The patient apparently could not tolerate psoralens because of increased incidence of carcinoma formation.

(*Arch Dermatol* 113:1561-1563, 1977)

The subject of this report and her brother were among the original patients with the DeSanctis-Cacchione variant of xeroderma pigmentosum (XP) studied by Cleaver[1] and later by Epstein and associates.[2]

Xeroderma pigmentosum is characterized by freckle-like lesions in areas exposed to sunlight with the subsequent development of carcinomas. These symptoms usually have their onset at an early age. The DeSanctis-Cacchione syndrome is the most severe form of XP. In addition to the skin lesions, the syndrome includes microcephaly with mental deficiency, premature closure of the sutures, retarded growth and sexual development, choreoathetosis, cerebellar ataxia, eventual quadriparesis with shortening of the achilles tendons, and sometimes sensorineural deafness.

This patient has been pictured many times in various medical texts and films[3-8] (Fig 1). Her epidermal cells have been kept alive in liquid nitrogen for further studies of XP.[4-11] Her brother died of lymphatic leukemia and has been described elsewhere.[4] We describe the fifth reported autopsy findings in a patient with DeSanctis-Cacchione syndrome.

REPORT OF A CASE

A girl was one of two severely affected siblings.[3] Her gestation was uneventful, and at birth she weighed 2,524 gm. There were no abnormalities apparent at birth, but mental retardation was evident at 8 months of age. Inspection of the skin revealed no pigmentary disturbances.

Pneumoencephalographic studies showed closure of the cranial sutures before 3 years of age. The ventricles and the basal cisterns all appeared somewhat dilated and larger than usual. These radiographic findings were consistent with cerebral atrophy. The occipital area of the skull was asymmetrical, with the left side slightly flattened and the left petrous bone projecting lower than the right. Posteroanterior films of both hands and wrists at 3½ years of age showed the bony development to be consistent with the age level of 4 years 2 months, according to the Greulich-Pyle standard.

At 3 years of age the patient could walk only short distances with a spastic gait and athetoid movements of her head and arms.

At 5 years of age she had frequent infections: adenotonsillitis, otitis media, mastoiditis, sinusitis, pneumonitis, multi-

Accepted for publication April 12, 1976.

From the Department of Dermatology, University of California School of Medicine, Irvine (Dr Reed); Department of Neurology, University of Southern California School of Medicine, Los Angeles (Dr Sugarman); and University of Wisconsin School of Pharmacy, Madison (Dr Mathis).

†Deceased.

Reprint requests to 3325 Division St, Los Angeles, CA 90065 (Dr Sugarman).

Fig 1.—Patient, age 7, and her brother, age 3, who died of lymphatic leukemia. Both underwent autopsies.

Fig 2.—Patient at age 14 years, one month before death, showing early signs of puberty.

ple carious teeth, and numerous bleeding episodes from her nose and ears.

She suffered three severe sunburn reactions when 9 months of age, and then developed freckling of the sun-exposed skin when 1 year of age. Thereafter, the skin condition grew progressively worse for the next five years. She was seen almost on a monthly basis for removal of skin lesions. These usually were histopathologically confirmed keratoacanthomas, much less frequently basal cell carcinomas, usually pigmented, and only rarely squamous cell carcinomas. At 6 years of age she was treated with 1% to 5% fluorouracil in a propylene glycol base for application to her skin. For 1½ years the skin lesions improved, but later resistance to this therapy developed and more lesions appeared. She was treated with trioxsalen with very poor results, apparently leading to a greater number of skin lesions. This therapy was stopped after a month because of this apparent adverse effect. Sun screens were ineffectual in preventing new carcinomas.

In January 1970, she was studied by a team of immunologists under the supervision of Robert Good, MD. She had normal IgA, IgM, and IgG levels but an extremely elevated IgE level (1,685 units; normal, less than 300 units). Associated with her increasingly frequent infections, she became severely deficient in IgA, so much so (119 mg/100 ml at 14 years of age) that she developed a secondary immunologic deficiency.

Two weeks before death she had the onset of seizures, vomiting, and anorexia, with increasing loss of ambulation; she became bedridden. She developed severe dyspnea and was hospitalized at Children's Hospital of Los Angeles and was given intensive pulmonary therapy, but died at home a few days later (Fig 2).

Autopsy Findings

Autopsy examination showed severe microcephaly (the brain size was that of a child 8 weeks of age, although the patient was 14 years old). There was diffuse loss of cortical neurons in the cerebrum with no evidence of a storage disease or injury, nor gliosis or perivascular inflammation. Neurons of the thalamus, putamen, and pallidum were sparse. Loss of Purkinje cells were noted in the cerebellum. The inferior olive and pons were also atrophic.

The thymus showed chronic involution, and Hassal's corpuscles were present with slight fibrosis. The thymus weighed 8 gm (normal weight, 30 gm).

In addition, the autopsy showed bilateral acute and subacute pneumonia with aspiration of food and superimposed abscesses. The midmesenteric, retroperitoneal, and paratracheal lymph nodes were hyperplastic. The ovaries were atrophied, with the outer cortex fibrotic and the follicle cells scanty. The tunica albuginea was thick and fibrotic.

COMMENT

Before Cleaver's discovery of the inability of fibroblasts from XP patients to repair ultraviolet (UV)-inflicted DNA damage, XP was considered first to have just two manifestations: XP alone or XP with neurologic complications (the DeSanctis-Cacchione syndrome). The fibroblasts initially given to Dr Cleaver came from three patients with the DeSanctis-Cacchione syndrome and one patient with XP.[1-4] The DNA repair rate was at only 20% normal efficiency in fibroblasts of the XP patient and was nonexistent in fibroblasts of the DeSanctis-Cacchione patients. Thereafter, Epstein and coworkers reported that epithelial cells from XP and DeSanctis-Cacchione patients showed defective DNA repair in vivo.[2]

A study in Holland in 1972 shed more light on the genetic heterogeneity of the XP clinical entities. De Weerd-Kastelein and others[12,13] devised an intergenic complementation test to study the complexity of the enzyme system involved in the repair of UV-damaged DNA. Xeroderma pigmentosum cell strains were caused to form binuclear fusions by the fibroblast membrane activity of UV-inactivated Sendai virus, after a technique by Harris and Watkins.[14] After this treatment, certain combinations of XP cell strains resulted in heterokaryons with increased repair levels as shown by higher incorporation of tritiated thymidine. Fusion of cells of the same strain or from the same patient produced heterokaryons with unchanged repair levels. In one study,[12] heterokaryons were produced by fusion of fibroblasts from one of two male patients with severe XP and from a female patient with severe XP combined with those of a male patient who had the DeSanctis-Cacchione variant. The three groups of heterokaryons all displayed higher repair levels following controlled UV exposure.

This result indicated that the DNA

repair system enzymes were defective in XP cells and were different from the DeSanctis-Cacchione variant. Hybrid cells containing genes from XP and DeSanctis-Cacchione cells may synthesize the full complement of normal enzymes, as evidenced by the enhanced repair levels. Further use of this technique has led to the discovery of five subclasses of XP, each caused by a mutation at a different locus, indicating the complexity of the enzyme system involved in the repair of UV-damaged DNA.[9]

Of the five types of XP, not all are clinically distinct entities. More types may be detected, since there is heterogeneity in genetic disorders. Our patient had genetic subtype A, which is one of the three subtypes with neurologic abnormalities.[10]

Cleaver et al,[15] studying the human diseases with altered DNA repair processes, found that the damage inflicted on fibroblasts by many "chemical carcinogens" could be classified as either x-ray-like (that is, damage that XP cells can repair) or UV-like (that is, damage that XP cells cannot repair). One of the substances causing UV-like damage is methoxypsoralen, which attaches to the DNA of the fibroblasts and to the epidermal cells in vivo after UV irradiation.[16,17] Such an injury might have been responsible for the apparent acceleration of tumor formation that was associated with tripsoralen therapy in our patient.

Olivopentocerebellar atrophy is a major part of the CNS in the DeSanctis-Cacchione syndrome, as noted in the autopsy findings of our three patients. In all but one patient (the brother) all organ weights examined have been small. The previous patients with small organ weights have all been Japanese (two described by Yano[11] and two by Reed and associates[4]). This is the first white to be described as having small organ weights. At death she was only 108 cm in length. This neuropathologic study was similar to the other cases reported. Three of the previously reported patients with this syndrome died of chronic infections of the respiratory tract, perhaps due to immunologic deficiencies as suggested by the immunological findings in our patient. The relationship of chronic infection to poor DNA repair, if any, is not clear at this time.

At the NIH conference on XP and its associated symptoms,[10] Festoff discussed the associated neurologic abnormalities. He stated that a relatively common finding was microcephaly, defined as a head circumference more than 2 SD below the mean. Mental deficiency is also a common neurologic abnormality. He also mentioned loss of neurons, since the number of large pyramidal cells of the cortex and the Purkinje cells of the cerebellum were greatly reduced in XP patients. Some of the NIH patients had some of the abnormalities of the DeSanctis-Cacchione syndrome, but all three of our DeSanctis-Cacchione patients showed the same neurologic, somatic, and sexual characteristics.[3,4] Festoff assumed that all presumably neurologically healthy individuals are losing neurons from the CNS at a given rate. Our autopsy reports on DeSanctis-Cacchione patients confirm that there is neuronal loss. Because the brain probably developed poorly before birth, the neurons may never have been formed. The subject of this report died at 14 years of age with a brain size equivalent to that of an 8-week-old child.

Benjamin Landing, MD, performed the autopsy at Children's Hospital of Los Angeles; Richard Breathnack, assisted with the preparation of the manuscript.

References

1. Cleaver JE: Defective repair replication of DNA in xeroderma pigmentosum. *Nature* 218:652-656, 1968.

2. Epstein JH, Fukuyana K, Reed WB, et al: Defect in DNA synthesis in skin of patients with xeroderma pigmentosum demonstrated in vivo. *Science* 168:1477-1478, 1970.

3. Reed WB, May SB, Nickel WR: Xeroderma pigmentosum with neurological complications: The DeSanctis-Cacchione syndrome. *Arch Dermatol* 91:224-226, 1965.

4. Reed WB, Landing B, Sugarman GI, et al: Xeroderma pigmentosum: Clinical and laboratory investigation of its basic defect. *JAMA* 207:2073-2079, 1969.

5. Holmes LB, Moser HW, Halldorssen S, et al: *Mental Retardation: An Atlas of Diseases With Associated Physical Abnormalities.* New York, MacMillan, 1972, pp 382-383.

6. Reed WB, Epstein WH: *The Genetics of the Photodermatoses.* 1974.

7. Goodman RM, Gorlin J: *The Face in Genetic Disorders.* St Louis, CV Mosby Co, 1970, pp 166-167.

8. Fitzpatrick TB, et al: *Dermatology in General Medicine.* New York, McGraw-Hill Book Co Inc, 1971, p 1414.

9. Cleaver JE: DNA repair and radiation sensitivity in human (xeroderma pigmentosum) cells. *Int J Radiat Biol* 18:557-565, 1970.

10. Robbins JH, Kraemer KH, Lutzner MA, et al: Xeroderma pigmentosum: An inherited disease with sun sensitivity, multiple cutaneous neoplasms and abnormal DNA repair. *Ann Intern Med* 80:221-248, 1974.

11. Yano K: Xeroderma pigmentosum mit Storungen des Zentralnervensystems: Eine Histopathologische Untersuchung. *Folia Psychiatr Neurol Jap* 4:143, 1950.

12. De Weerd-Kastelein EA, Keijzer W, Bootsma D: Genetic heterogeneity of xeroderma pigmentosum demonstrated by somatic cell hydridization. *Nature (New Biol)* 238:80-83, 1972.

13. De Weerd-Kastelein EA, Keijzer WJ, Sluyter ML, et al: Repair replication of heterokaryons derived from different repair-deficient xeroderma pigmentosum strains. *Mutat Res* 19:237-243, 1973.

14. Harris H, Watkins JF: Hybrid cells derived from mouse and man: Artificial keterokaryons of mammalian cells from different species. *Nature* 205:640-642, 1965.

15. Cleaver JD, Bootsma D, Freidberg F: Human diseases with genetically altered DNA repair processes. Read before the Genetics Congress, Berkeley, Calif, August 1973.

16. Pathak MA, Kramer DM: Photosensitization of skin in vivo by furocoumarins (psoralens). *Biochem Biophys Acta* 195:197-206, 1969.

17. Epstein, JH, Fukuyama K: Effects of methoxypsoralen-induced phototoxic effects on mammalian epidermal macromolecule synthesis in vivo. *Photochem Photobiol* 21:325-330, 1975.

Acquired Periungual Fibrokeratoma

A Rare Benign Tumor Previously Described as the Garlic-Clove Fibroma

Ronald L. Cahn, MD

• A rare periungual tumor, clinically and histologically identical to the acquired digital fibrokeratoma, is discussed in association with the differential diagnosis of acral digital nodules. It is believed that this is the first report that conclusively links the previously described garlic-clove fibroma with the acquired digital fibrokeratoma.

(*Arch Dermatol* 113:1564-1568, 1977)

In 1965, Steel[1] described a previously unknown isolated periungual fibrous tumor surrounded by a hyperkeratotic epidermal capsule. Little attention was given to more precise nomenclature for this lesion until 1968, when Bart et al[2] described ten cases of an acral tumor that they termed acquired digital fibrokeratoma. It was suggested that Steel's three garlic-clove fibroma cases may actually have been acquired periungual fibrokeratomas, but this point remained mere speculation until the present patient was carefully studied. This report documents a tumor identical to the originally reported garlic-clove fibroma and further demonstrates its historical and histopathologic relationship to the acquired digital fibrokeratoma.

REPORT OF A CASE

A 44-year-old woman was seen in May 1975 because of an asymptomatic flesh-colored mass overlying the dorsal aspect of the nail on the left middle finger (Fig 1). The patient indicated that the distal interphalangeal joint of that digit had sustained moderate blunt trauma approximately seven years previously in which no laceration or fracture occurred. Within a year after the injury, she first noted a firm pink hyperkeratotic tongue of tissue protruding over the nail plate from beneath the cuticle of the proximal nail fold. The lesion progressively enlarged, deforming the proximal nail fold and eventually thinning and depressing the central portion of the nail plate ventral and distal to the lesion. Two prominent ridges on the nail plate paralleled the lateral margins of the tumor and extended to the free margin of the nail. There was no other history of notable concomitant cutaneous or systemic illness.

The lesion was approached surgically under digital block using 1% lidocaine with 1:200,000 epinephrine. On the dorsal distal phalanx two parallel longitudinal incisions were created to allow reflection of the entire proximal nail fold back to the distal interphalangeal joint with subsequent visualization of the tumor overlying the nail and matrix. Without appreciable difficulty or hemorrhage, the mass was bluntly dissected free from adjacent structures and its proximal attachment exposed and extirpated while care was exercised to avoid trauma to the nail matrix (Fig 2). Closure was effected by reapproximation of the nail fold margins to the surrounding skin with 5-0 nylon sutures. A nonadherent compression dressing was applied, and healing was uneventful with restoration of a normal nail configuration by the 12th postoperative week (Fig 3).

Histopathologic Findings

The surgical specimen was preserved in 10% formalin solution after which paraffin-embedded sections were prepared by standard techniques. An irregularly acanthotic hyperkeratotic epidermal envelope surrounded the entire tumor with the exception of the proximal basal attachment. The basal and Malpighian cell layers were normal with maturation to an exaggerated stratum granulosum. No parakeratosis was evident in any of the sections. The core of the tumor was composed of thickened interlacing sclerotic collagen bundles primarily oriented longitudinally (Fig 4). Fibroblasts were generally sparse throughout the tumor, and in none of the sections could stellate fibroblasts be observed. Occasional endothelial channels coursed through the collagenous matrix, their number being relatively greater in the superficial papillary dermis than deeper in the more sclerotic reticular dermis. Conspicuously absent was evidence of any inflammatory infiltrate.

Staining with the Verhoeff-van Geison technique demonstrated only widely scattered fragments of elastic tissue that could have been easily missed without careful scrutiny (Fig 5). The more specific aldehyde-fuchsin stain showed slightly greater quantities of elastic fibers that were thin and frequently clumped in granules deposited irregularly throughout the tumor (Fig 6). There was no predilection for increased elastic tissue in or near vessels.

Serial sections failed to demonstrate any evidence of foreign material. Polariscopic examination revealed no doubly refractory bodies. Appropriate stains for histochemically detectable glycogen, acid and neutral mucopolysaccharides, and fibrin were uniformly negative. Phosphotungstic acid-hematoxylin stains of multiple sections revealed no intracytoplasmic granules.

There was no evidence of cutaneous adnexal structures within the tumor, and no nerve fibers could be found in either the dermal core or at the basal point of attachment. Thus, this tumor is microscopically a hyperplastic fibroepithelial neoplasm devoid of neural elements and lacking any evidence of epidermal appendages.

COMMENT

The differential diagnosis of acral digital tumors includes a wide variety of lesions of diverse causation (Table). The majority are mesodermal in origin, thereby necessitating an extensive classification to facilitate their study. An attempt is made to bring some order to this multitude of lesions in general and the fibrous tumors in particular. Confused reporting has fostered inappropriate nomenclature of some of these tumors, a situation that may be clarified in part by the ensuing discussion. Basic to the diagnosis of many of these lesions is

Accepted for publication Aug 20, 1976.

From the Department of Dermatology, Stanford (Calif) University Medical Center.

Reprint requests to 15215 National Ave, Los Gatos, CA 95030.

the fact that not only are the histopathologic findings important, but the clinical history, gross appearance, and genetic background provide tangible clues to the correct diagnosis.

The neural tumors are readily differentiated histologically and in some cases by clinical inspection. Neurofibromas usually occur in association with other signs of von Recklinghausen's disease, ie, café-au-lait spots, axillary freckling, and multiple soft cutaneous tumors, the onset of which dates to childhood or early adolescence. A familial incidence with autosomal dominant inheritance further clarifies the diagnosis. Isolated neurilemomas are distinctly uncommon, may follow trauma, and frequently are painful on compression. They arise from the Schwann cell sheaths of peripheral nerves, usually situated within the subcutaneous layer. The neuroma is a tangled mass of neural tissue arising from the proximal end of a severed peripheral nerve. They usually are deep in the subcutaneous layer and cause considerable pain. The clinical history and histopathologic characteristics easily elucidate these diagnoses.

The tumors of vascular origin are clinically distinct from one another. Their histopathologic characteristics are definitive enough to obviate confusion with other mesodermal neoplasms. The situation is similar for cartilaginous and osseous lesions; the histopathologic findings are diagnostic, and in the case of exostoses, a routine roentgenogram substantiates the clinical impression.

The gross appearance, geographic location, and histologic characteristics of verrucas, mucous cysts, traumatic epidermal inclusion cysts, cutaneous horns, and foreign body granulomas facilitate these diagnoses, and little chance for error exists if adequate history and/or tissue is available for study. The eccrine poroma is the only cutaneous adnexal tumor that may be encountered on the hands or feet with any frequency. It appears as an erythematous nodule or pedunculated mass that has a distinctive microscopic appearance.

The remaining tumors in the classification are of fibroblastic origin and require greater effort for adequate differentiation. The frankly malignant fibrous neoplasms include the dermatofibrosarcoma protuberans and the fibrosarcoma, but these lesions are rare in acral locations. The former tumor is most frequently encountered on the trunk, but other locations have been reported. It is a slowly growing multinodular flesh-colored or red dermal mass that may eventuate with a bluish or brownish color as it enlarges, and secondary painful ulceration may follow. Dermatofibrosarcoma protuberans usually is a solitary lesion that may begin as early as the second or third decade and may be preceded by trauma. The histopathologic findings are sufficiently characteristic to be diagnostic. Fibrosarcomas are also readily identified by their microscopic appearance. They may arise at any age, but frequently the lesion develops many years after intense therapeutic radiation exposure thereby appearing on poikilodermatous skin. The most common location is the trunk where it appears as a slowly enlarging reddish or violaceous smooth nodule that eventually ulcerates. These two tumors are unlikely to be misinterpreted and therefore provide little confusion with regard to the other benign fibromatoses.

The recurring digital fibrous tumor of childhood is a histologically benign, but biologically aggressive lesion that frequently recurs after the most exhaustive attempts at local extirpation. The characteristic location of this smooth flesh-colored nodular dermal mass is on the distal phalanx; therefore the nail matrix and/or the nail plate may be secondarily involved resulting in dystrophy. The histopathologic hallmark of this tumor is the finding of intracytoplasmic inclusion bodies that stain positively with phosphotungstic acid-hematoxylin, or red with methylgreen pyronine.[3]

Keloids pose little difficulty in the differential diagnosis of acral digital lesions. A prior history of trauma is to be expected, and the keloid generally conforms to the area of cutaneous insult. The histologic appearance varies with the age of the lesion, but little chance of confusion exists once the clinical history is appreciated.

True benign fibromas occur uncommonly on the digits. Grossly they may resemble acquired digital fibrokeratomas, Koenen's tumors, or rudimentary supernumerary digits by virtue of their location, consistency, color, and contour. However, microscopically they are usually more cellular in terms of fibroblasts and endothelial elements, and a collarette of hyperplastic acanthotic epidermis distinctly separates the thickened collagen bundles of the neoplasm from the underlying normal dermis.[2] Additionally, elastic fibers are consistently lacking within the matrix of true fibromas.[4]

Koenen's tumors are the acral digital fibrous lesions associated with tuberous sclerosis. Generally, multiple, symptomless, subungual and periungual fibroepithelial excrescences develop on the fingers and toes at, or after, puberty. The other neurocutaneous signs of tuberous sclerosis are readily discernible, thereby narrowing the diagnostic possibilities. Histologically these tumors are angiofibromas that occasionally show stellate fibroblasts with the collagen matrix.

Rudimentary supernumerary digits and acquired digital fibrokeratomas are the most difficult of the fibrous lesions to separate histopathologically. Both appear as fibroepithelial nodules, but the rudimentary supernumerary digit is distinguished by the finding of multiple nerve bundles within the dermal core and especially at the proximal base of the nodule.[5] Such neuroid structures were not described in any of the 53 acquired digital fibrokeratomas examined by Bart et al[2] and Verallo.[5] Additionally, rudimentary polydactyly almost always occurs at the base of the metacarpophalangeal joint, tend to be familial, and are present at, or soon after, birth. The most important clinical feature of rudimentary polydactyly is its propensity to be bilaterally symmetric, a phenomenon never reported with acquired digital fibrokeratomas, although on two occasions the latter lesion has occurred multiply, but not simultaneously.[2,5]

In 1965, Steel described three cases of a peculiar periungual hyperkeratotic fibrous tumor that overgrew the dorsal nail plate from beneath the proximal nail fold and designated it the garlic-clove fibroma. There was no history of trauma, and the lesions were asymptomatic. No comment was made regarding the resultant nail dystrophy, but a clear illustration of a channel-like depression was provided in the original report. Steel indicated that the lesion arose from the nail bed. This seems unlikely in his cases, since the tumor would then have to herniate through the nail matrix or plate to reach the dorsal nail surface, the location described for each of the original lesions. This would necessarily produce a much greater nail dystrophy than the longitudinal depression herein described and illustrated in the original report. After careful dissection of the tumor in the present case, it was obvious that the lesion arose in the dermis proximal to the nail matrix and merely expanded distally, in the direction of least physical resistance. After resection, the matrix was depressed in the center, but intact distal to the basal attachment of the

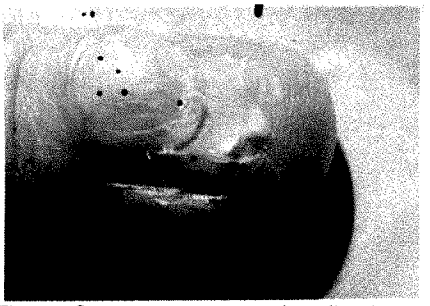

Fig 1.—Gross appearance of garlic-clove fibroma and channel-like dystrophy of nail.

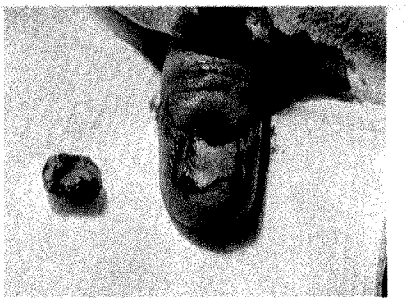

Fig 2.—Intraoperative view showing excised tumor and mechanical distortion of underlying nail.

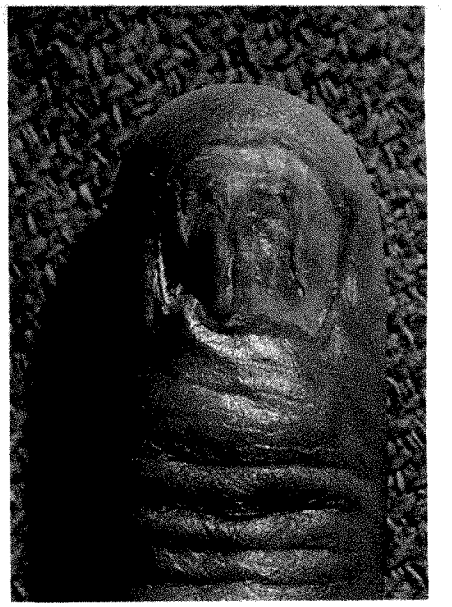

Fig 3.—Postoperative view of distal finger and nail at 12 weeks.

Fig 4.—Top, Scanning magnification of the entire tumor showing the surrounding hyperplastic epidermis and stratum corneum (hematoxylin-eosin, original magnification, ×4). Center, Low magnification of dorsal aspect of tumor showing uniformly thick epidermis, accentuated granular layer, and overlying dense hyperkeratosis (hematoxylin-eosin, original magnification ×60). Bottom, High-power view of thick collagen bundles without evidence of inflammatory infiltrate (hematoxylin-eosin, original magnification ×200).

Fig 5.—Sparse elastic fibers within a representative field (Verhoeff-van Geison stain, ×50).

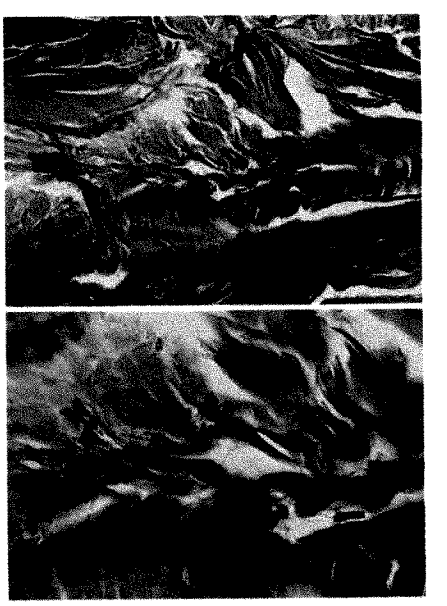

Fig 6.—Top, Representative field showing sparse elastic fibers (aldehyde-fuchsin stain, ×50). Bottom, Abnormal elastic tissue deposited in granular clumps (aldehyde-fuchsin stain, ×128).

Fig 7.—Case 2. Gross appearance.

Fig 8.—Case 2. Operative view showing extent of tumor and site of origin proximal to nail matrix.

Fig 9.—Case 3. Gross appearance.

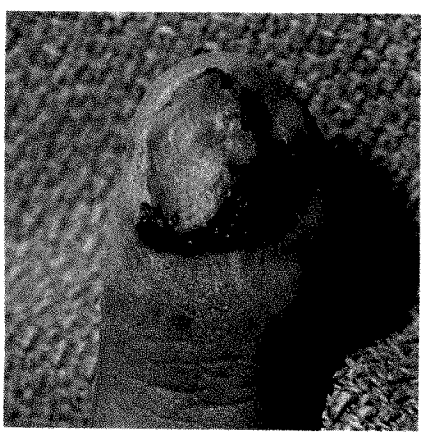

Fig 10.—Case 3. Appearance after avulsion of nail.

Fig 11.—Case 3. Appearance after blunt dissection of tumor from nail bed.

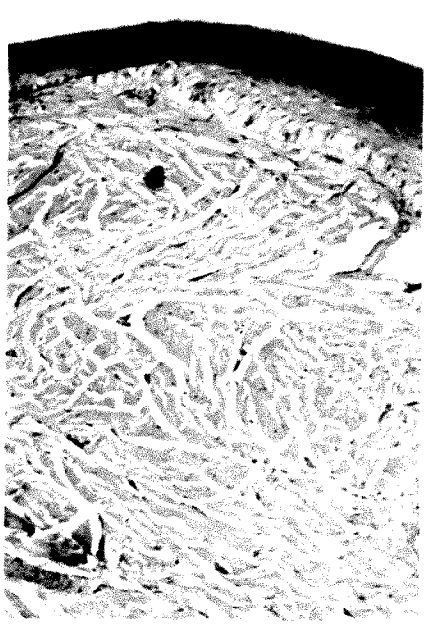

Fig 12.—Case 2. Low-power view showing irregularly distributed elastic tissue within tumor (aldehyde fuchsin stain, original magnification ×60).



Fig 13.—Case 2. High-power view showing abnormally distributed irregular elastic tissue (aldehyde fuchsin stain, original magnification ×240).

Differential Diagnosis of Acral Digital Nodules

- I. **Primarily fibrous**
  - A. Neoplastic
    - 1. Fibroma
    - 2. Keloid
    - 3. Koenen's tumor (tuberous sclerosis)
    - 4. Recurring digital fibrous tumor of childhood
    - 5. Acquired fibrokeratoma
    - 6. Dermatofibrosarcoma protuberans
    - 7. Fibrosarcoma
  - B. Genetic
    - 1. Rudimentary supernumerary digits
- II. **Primarily neural**
  - A. Neurofibroma
  - B. Neuroma
  - C. Neurilemoma
  - D. Neurofibrosarcoma
- III. **Primarily vascular**
  - A. Pyogenic granuloma
  - B. Hemangioma
  - C. Glomus tumor
- IV. **Primarily cartilaginous**
  - A. Cutaneous cartilaginous tumor
- V. **Primarily osseous**
  - A. Exostosis of phalanx
- VI. **Other nodular lesions**
  - A. Verruca vulgaris
  - B. Mucous cyst
  - C. Foreign body granuloma
  - D. Epidermal cyst (implantation type)
  - E. Eccrine poroma
  - F. Cutaneous horn

tumor. The site of origin is further substantiated by the fact that a normal nail plate eventuated subsequent to successful surgery, an event unlikely to occur if the tumor primarily involved the matrix area. It is not inconceivable that this lesion actually could arise from the nail bed and protrude from beneath the nail plate. Such a lesion is pictured in one of the major dermatology texts,[7] albeit without further clinical or histopathologic explanation.

Steel indicated that the garlic-clove fibroma is composed of a core of dense interlacing collagen bundles with associated capillaries within a hyperkeratotic thickened epidermal capsule. He noted normal basal and prickle cell layers as well as a markedly thickened granular layer. As previously noted, there are the same general findings described for the acquired digital fibrokeratoma. The one notable histologic feature that has eluded firm definition is the quantitative and qualitative characterization of the elastic tissue within the tumor. Steel did not comment on the presence of elastin in his case. Bart et al examined two tumors for the presence of elastic fibers and found them to be very sparse in one specimen and thin straight fibers reduced in quantity in the second. Verallo found variable quantities of elastic fibers present in all lesions, some of which were noted to be coarse and others fragmented. In the present case, elastic tissue was almost undetectable with the Verhoeff-van Geison technique, but the more specific aldehyde-fuchsin stain demonstrated sparse abnormal clumped granules of elastin and less conspicuous, thin fragmented elastic fibers. It seems apparent, therefore, that this tumor is characterized by the presence of variable quantities of distinctly abnormal elastic tissue.

The tumor that is the subject of this report is histologically identical to the garlic-clove fibroma, but more importantly, such lesions appear congruent with the ten cases first described by Bart et al as acquired digital fibrokeratomas. Indeed, these authors speculated that the tumors described by Steel may have been acquired periungual fibrokeratomas, but at that time conclusive histopathologic proof was lacking. Current evidence now substantiates this association. Verallo reviewed 43 similar cases of acquired digital fibrokeratomas and generally corroborated the above clinical and pathologic findings. In doing so he noted that some lesions occurred on the dorsum of the hand, palm, sole, ankle, and patella, therefore agreeing with Bart et al that the broad designation, acquired digital fibrokeratoma, is less desirable than the specific term acquired fibrokeratoma, especially when the latter is further clarified by the exact anatomic location of the lesion.

The cause of this tumor is unclear. The initial report included three cases with no history of trauma. Bart et al reported one of ten cases that was preceded by trauma; Verallo noted direct predisposing major trauma or repeated minor insults in five of his 43 cases; and the present case followed within a year of direct blunt injury. These statistics suggest that trauma plays more than an incidental role in the genesis of this tumor, but the exact link remains elusive.

It now seems apparent that the term garlic-clove fibroma should be discarded and replaced by the more useful, and appropriate designation, acquired periungual fibrokeratoma, a term that encompasses both the salient clinical and histopathologic features of this unusual benign tumor.

Since the completion of this article, two additional cases of acquired periungual fibrokeratoma have been diagnosed and underwent operation.

A 16-year-old boy sustained moderate blunt trauma to the distal right hallux when he "stubbed" his toe on Dec 6, 1973. Pain was considerable, and roentgenograms taken then showed a chip fracture of the epiphyseal plate of the distal phalanx. The toe was splinted and healing was uneventful. Approximately one year later, the patient noted a bulging firm soft tissue mass emerging from beneath the proximal nail fold and lying dorsal to the nail plate. The lesion progressively enlarged until it deformed the nail plate, producing a shallow depressed groove. A tongue of thick keratin protruded from the distal margin to the tumor (Fig 7). Under local anesthesia, the lesion was resected in a fashion identical to that of case 1 (Fig 8). The site healed without incident, and a normal nail contour was restored.

A 17-year-old, severely retarded teenager sustained a direct dorsal blow to the distal right index finger in October 1974. This resulted in a laceration that necessitated the removal of the partially avulsed nail plate and suture reconstruction of the distal fingertip. Healing was uneventful, with the exception of slight radial deviation of the extreme distal fingertip. Approximately 11 months later the nail was noted to be deformed by a subungual hyperkeratotic mass that produced distal onycholysis (Fig 9). No attempt was made to rectify the deformity until the patient was seen in the dermatology clinic for an unrelated problem. Subsequently, the lesion was approached surgically by removing the nail plate (Fig 10) and bluntly dissecting free the tumor (Fig 11). Its point of origin was on the nail bed exactly at the previous suture line. Healing progressed without difficulty.

Histopathologic Findings

The histopathologic features of the latter two cases were very similar to those of the first lesion described in detail within the body of this article. The latter tumors had a very thick epidermis with an exaggerated granular cell layer. Massive orthokeratotic hyperkeratosis was uniformly present surrounding the lesions. The connective tissue core in both cases was composed of thick collagen bundles with little vasculature. What few vessels were encountered maintained an unusually straight course for extended lengths. These straight vessels were most prominent in case 2 where the lesion had been on the hallux. There did not appear to be any predisposition for their orientation either horizontal or vertical to the axis of anatomical tumor orientation.

The remaining features differed little from those presented previously. There were sparse fragments of abnormal elastic tissue widely scattered through the collagen bundles. The hallux lesion in case 2 showed the greatest total amount of elastin of any of the three cases. No inflammatory infiltrate was noted in any of the cases and, again, no neural elements were identified in any of the multiple sections examined from each tumor.

COMMENT

These three cases and those of Steele clearly indicate that the acquired periungual fibrokeratoma is induced by trauma. Their anatomic location and varying age of onset strongly favor a hyperplastic growth rather than any type of congenital malformation such as a supernumerary digit. The histologic picture also substantiates this differentiation. No evidence of neural elements was found in any of the present lesions, and elastic tissue was sparse and definitely abnormal. The latter findings would not be expected in congenital malformations, namely, supernumerary digits.

Ultimately, the cellular mechanisms responsible for the acquired periungual fibrokeratoma and the acquired digital fibrokeratoma may be elucidated. However, the present state of knowledge would indicate that these tumors are distinct clinical and histopathologic entities representing a reactive hyperplasia initiated by tissue trauma.

Barnes-Hind Pharmaceutical Co sponsored the color photographic reproductions.

References

1. Steel HH: Garlic-clove fibroma. *JAMA* 191:1082-1083, 1965.
2. Bart RS, Andrade R, Kopf AW, et al: Acquired digital fibrokeratomas. *Arch Dermatol* 97:120-129, 1968.
3. Raye RDK: Recurring digital fibrous tumors of childhood. *Arch Pathol* 80:228-231, 1965.
4. Pinkus H, in discussion, Bart RS, Andrade R, Kopf AW, et al: Acquired digital fibrokeratomas. *Arch Dermatol* 97:120-129, 1968.
5. Verallo VVM: Acquired digital fibrokeratomas. *Br J Dermatol* 80:730-736, 1968.
6. Zaias N, Baden HP: in Fitzpatrick TB (ed): *Dermatology in General Medicine*. New York, McGraw-Hill Book Co Inc, 1971, p 350.

Fatal Cytomegalic Inclusion Disease

Associated Skin Manifestations in a Renal Transplant Patient

Norman Minars, MD; Jan F. Silverman, MD; Mario R. Escobar, PhD; A. Julio Martinez, MD

• A case of cytomegalovirus-induced vasculitis led to skin ulcerations in a renal transplant patient. Light and electron microscopy revealed inclusion bodies and viral particles, respectively, characteristic of cytomegalovirus. To our knowledge, this is the first report of cytomegalovirus-induced vasculitis producing skin ulcerations, and it illustrates another of the protean manifestations of cytomegalovirus inclusion disease that may have important clinical implications.

(*Arch Dermatol* 113:1569-1571, 1977)

Cytomegalovirus (CMV) is now considered as a member of the herpesvirus family that includes agents that are remarkable for their capacity to persist in a latent state, possibly from the time of conception to the time of death. In the general population, from 0.5% to 2.0% of newborn infants may be infected with CMV, depending on the socioeconomic level.[1] On the other hand, cytomegalic inclusion disease (CMID) in adults often becomes manifest in chronic debilitating conditions and frequently in immunosuppressed individuals, such as cancer patients and recipients of organ transplants. Of these, up to 91% may show evidence of CMV infection.[2]

The clinical manifestations of CMID in the adult are often nonspecific and vary depending on the organ involved. In the localized form of infection, the lungs (pneumonia) and the gastrointestinal tract (ulcers) are commonly affected, whereas in the disseminated form, most of the tissues may be compromised. Except for maculopapular or purpuric rash,[3] specific dermatological signs of CMID and the presence of the virus in the skin have not been documented in the literature. To our knowledge, this is the first report of CMV-induced vasculitis leading to skin ulcerations. This finding represents another manifestation of CMID that may have important clinical implications.

Accepted for publication Aug 23, 1976.

From the Medical College of Virginia, Health Sciences Division of Virginia Commonwealth University, Richmond.

Reprint requests to Medical College of Virginia, Box 106, Richmond, VA 23298 (Dr Escobar).

REPORT OF A CASE

A 24-year-old woman transplant patient was last admitted to the Medical College of Virginia with complaints of skin ulcers, fever of unknown origin, and decreased visual acuity. Her condition was first diagnosed as nephritis at the age of 7 years, which was well controlled by medical therapy. However, at the age of 21, she developed chronic uremia and renal tubular acidosis secondary to chronic pyelonephritis for which she was admitted to the Staten Island Hospital and treated by peritoneal dialysis. Subsequently, she had many hospital admissions there for hemodialysis. In August 1972, she was first admitted to the Medical College of Virginia, and in September of that year, she underwent renal transplantation two weeks after bilateral nephrectomy, ureterectomy, splenectomy, and appendectomy. Her mother served as a kidney donor. Subsequently, she underwent immunosuppressive therapy with azathioprine (Imuran) and prednisone. Hepatitis B surface (HB_s) antigen was first detected in her serum by complement fixation approximately a month after transplantation, but a peak titer of 1:2,000,000 was detected at 2½ months. The patient had two episodes of rejection at 37 and 104 days after the transplant for which alternate therapy with cyclophosphamide (Cytoxan), azathioprine, and prednisone, as well as irradiation was instituted. Her subsequent course was complicated by anemia; febrile urinary tract infections treated with gentamicin sulfate, nafcillin sodium, and sulfisoxazole (Gantrisin); and hypertension followed by a seizure and hemiplegia of unknown cause. She recovered from these problems and was discharged from the hospital 192 days after the transplant to remain under the care of her private physician.

The patient's condition was well under control until July 24, 1973, when she was readmitted to the Staten Island Hospital with a history of fever ranging from 38.3 to 41.1 C. At this time, she had a WBC count of 3,400/cu mm; platelets, 100,000/cu mm; hemoglobin level, 8 gm/100 ml; and hematocrit, 27%. *Escherichia coli* was isolated from a blood culture, and she was then treated with ampicillin sodium and chloromycetin. Two necrotic skin ulcers, one on her left elbow and the other on her right thigh, were noted for the first time but no biopsy was done. She was discharged on Sept 8, 1973, with continuation of immunosuppressive therapy and sutilains (Travase) ointment for her skin lesions.

Despite intensive therapy, the patient continued to have symptoms, and she was readmitted to the Medical College of Virginia Hospital on Sept 24, for the last time with complaints of necrotic skin ulcers (Fig 1), a chronic dry cough, fever of unknown origin, decreased visual acuity, and dysphagia. Physical findings on admission included oral candidiasis, skin ulcers, one on her left elbow and the other on her right thigh, Cushing's type of habitus, poor visualization of fundi with narrowed vessels and scarring with waxy exudates in the left eye and failure to see the discs. Punch biopsies from the skin ulcers were performed shortly after admission. She progressively deteriorated during her hospitalization that was complicated by gastrointestinal bleeding for which she received multiple transfusions. During this admission her condition was diagnosed as chorioidoretinitis of presumed viral origin, which progressed to blindness. Terminally, she developed diffuse pulmonary infiltrates bilaterally and her fever persisted despite broad-spectrum antibiotic therapy. She died approximately seven weeks following this admission.

MATERIALS AND METHODS

For light microscopy, punch biopsies from ulcers on the right elbow and the right leg and from nearby uninvolved skin

Fig 1.—Three-inch punched out ulcer of skin with a clear base and subcutaneous tissue with slight erythema of surrounding epidermis on anterior lateral upper thigh.

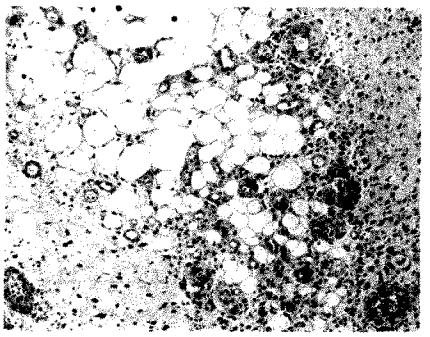

Fig 2.—Cytomegalic inclusion disease involving dermis and subcutaneous tissue. Dermal vessels markedly narrowed by the affected enlarged endothelial and perithelial cells with surrounding perivascular and interstitial inflammatory infiltrate (hematoxylin-eosin, original magnification ×120).

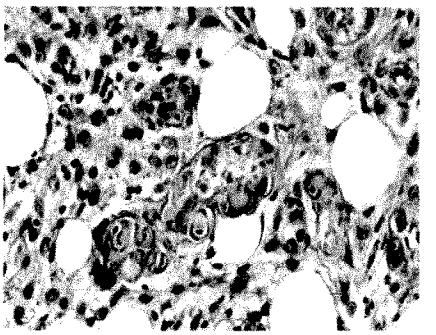

Fig 3.—Affected vessels revealing characteristically enlarged cells with large purplish intranuclear inclusion surrounded by clear halo and occasional eosinophilic intracytoplasmic inclusions (hematoxylin-eosin, original magnification ×375).

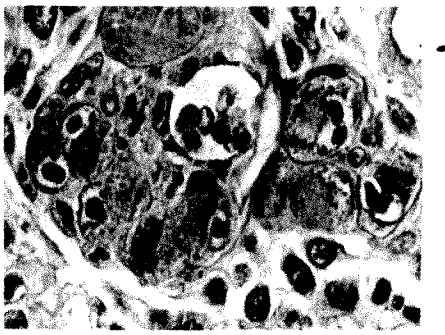

Fig 4.—Dermal arteriole markedly narrowed by swollen cells having characteristic large purplish intranuclear inclusion with surrounding halo (hematoxylin-eosin, original magnification ×920).

Fig 5.—Low power view of clinically uninvolved skin revealing no cytomegalic inclusion disease (hematoxylin-eosin, original magnification ×52).

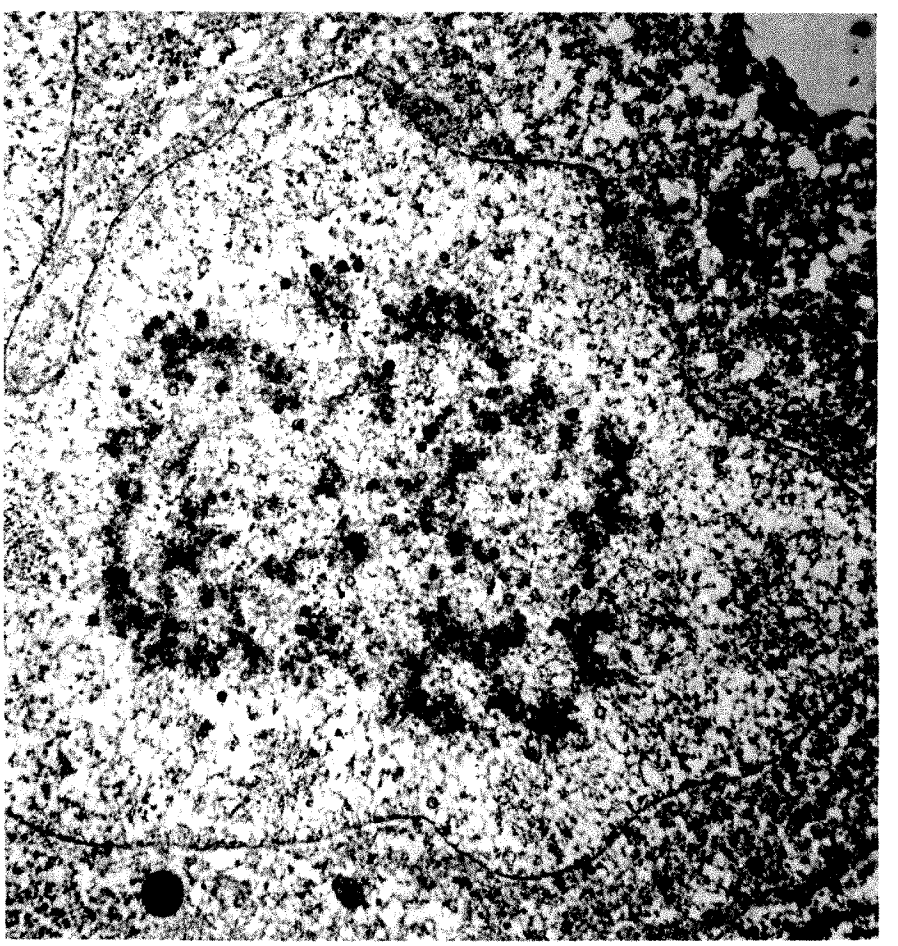

Fig 6.—Intranuclear spherical viral particles measuring 110 nm in average diameter containing either empty or dense cores (original magnification ×20,000).

were fixed in Zenker's solution and embedded in paraffin. Sections 6 μm in thickness were cut and stained with hematoxylin-eosin. At postmortem, specimens were submitted from the skin, lung, liver, kidney, breast, ovaries, adrenal, parathyroid, and eye tissues. Frozen sections from skin, kidney, liver, and lung tissues were prepared for indirect immunofluorescence, using isothiocyanate-conjugated rabbit antihuman γ-globulin and human antiserum to CMV (prepared at the Medical College of Virginia Virology Laboratory) free of antibody to herpes hominis and varicella-zoster viruses according to complement fixation and immunofluorescence tests. Cell cultures of human embryonic lung uninfected and infected with CMV were employed as negative and positive controls, respectively. Negative control serum (tested at the Medical College of Virginia Virology Laboratory) was also included. The technique used was originally described by Hanshaw.[1]

For electron microscopy, blocks of skin and subcutaneous tissue fixed in Zenker's solution and embedded in paraffin were used. Depending on previous histological examination, the blocks containing more inclusion bodies were selected. The paraffin was removed and the tissue rehydrated; then the cubes were placed in 4% glutaraldehyde in cacodylate buffer, postfixed in 2% osmium tetroxide dissolved in cacodylate buffer, dehydrated, and embedded in an epoxy resin. One-micron sections were cut with glass knives and stained with paragon PS-1301 for a general survey. Thin sections were cut with a diamond knife, double-stained with uranyl acetate and lead citrate, and observed with an electron microscope.

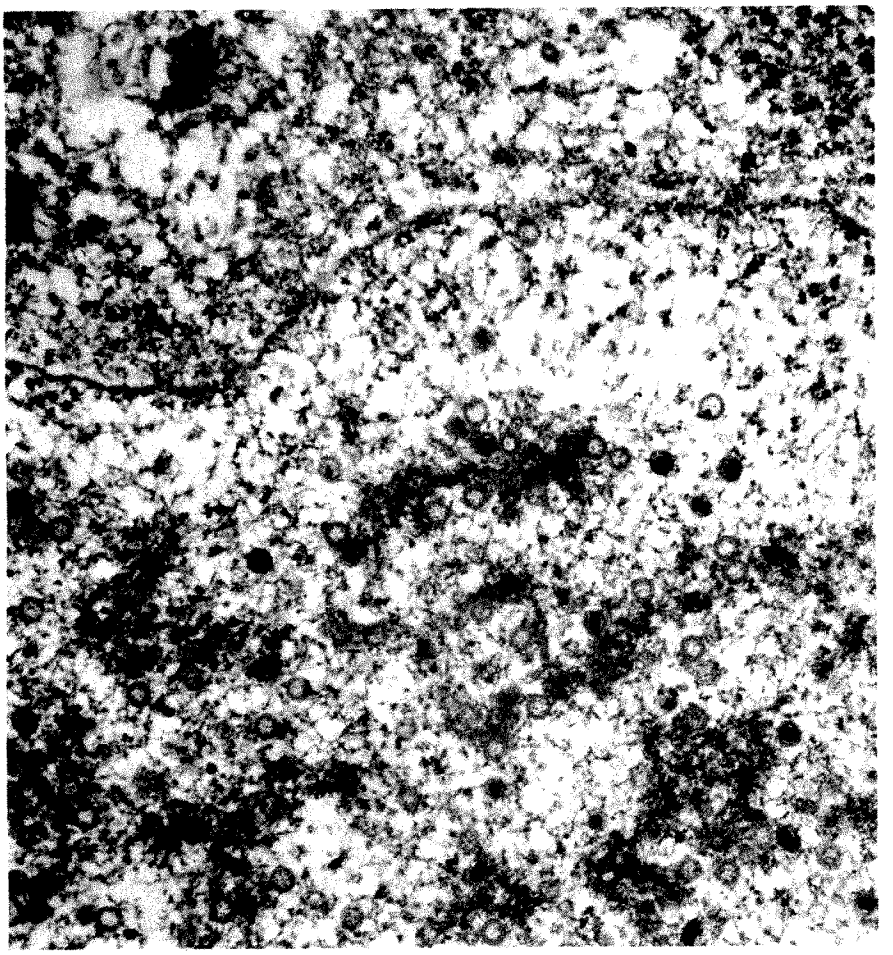

Fig 7.—Collection of mature and immature viral particles within nucleoplasm; some of them reveal dense cores while others are immature forms with single or double rings (original magnification ×45,000).

RESULTS

Microscopic examination from both skin ulcers demonstrated that the main pathologic change involved the small dermal vessels (Fig 2). The CMV inclusions were present in the endothelial and perithelial cells of the small arterioles, venules, and capillaries. The affected cells were characteristically enlarged and showed large purplish intranuclear inclusions surrounded by a clear halo. Occasional cells had circumscribed granular pale eosinophilic intracytoplasmic inclusions (Fig 3). Rarely, large cells with two nuclei containing inclusions were seen. The lumen of the involved vessels was markedly narrowed by the swollen cells (Fig 4). There was a severe perivascular and interstitial infiltrate composed of polymorphonuclear neutrophils, histiocytes, and lymphocytes. The biopsy specimen from the uninvolved skin revealed no CMID or inflammation (Fig 5).

At autopsy, disseminated CMID was present with involvement of the skin, lungs, liver, kidneys, breasts, ovaries, adrenal and parathyroid glands, and eyes. The kidney, liver, and lung sections showed areas of specific immunofluorescence with anti-CMV rabbit antiserum. The ulcerated skin sections were unsatisfactory for immunofluorescence.

Electron microscopic study revealed numerous degenerating cells within the dermis containing intranuclear viral particles approximately 110 nm in diameter. Some of these particles were devoid of dense cores while others represented immature intranuclear forms of the virus (Fig 6 and 7).

COMMENT

Cytomegalovirus inclusion disease may have protean clinical manifestations ranging from inapparent infection to widely disseminated disease with a fatal outcome, as in this case. The development of CMID in patients with underlying debilitating conditions is well documented, but whether CMV infection in organ-transplant or immunosuppressed individuals is primary or represents reactivation of a latent infection is unclear.[5] Approximately one year following renal transplantation and while she was receiving immunosuppressive therapy, this patient was readmitted to the hospital with complaints of skin ulcers, fever of unknown origin, and decreased visual acuity. To our knowledge, this is the first report of CMV-induced vasculitis presenting with skin ulcerations in a fatal case. The histologic changes in this case are similar to the ones described by Goodman and Porter[6] and Nakoneczna and Kay.[7] Both of these patients had gastrointestinal tract ulceration secondary to CMV-induced vasculitis. We believe that the striking CMID vasculitis in the dermal vessel caused the skin ulceration in our case.

The pathologic and histologic findings described in this case, as well as the demonstration by electron microscopy of intranuclear herpes-like viral particles in the ulcerated skin lesions of this patient, confirm that CMV was associated with the pathogenesis of the skin lesions in this patient. We suggest that biopsy should be done if immunosuppressed patients have skin ulcers. This case is another example of the protean manifestations of CMID and should alert the clinician of the possible occurrence of skin ulceration induced by CMV.

Nonproprietary Names and Trademarks of Drugs

Gentamicin sulfate—*Garamycin.*
Nafcillin sodium—*Unipen.*
Ampicillin sodium—*Alpen-N, Amcill-S, Omnipen-N, Penbritin-S, Polycillin-N, Principen/N.*

References

1. Marx JL: Cytomegalovirus: A major cause of birth defects. *Science* 190:1184-1186, 1975.
2. Merigan TC, Stevens DA: Viral infections in man associated with acquired immunological deficiency states. *Fed Proc* 30:1858-1863, 1971.
3. Mintz L: Herpesvirus infections in the postneonatal period, in Drew WL (ed): *Viral Infections—A Clinical Approach.* Philadelphia, FA Davis Co, 1976, pp 135-187.
4. Hanshaw JB: Congenital cytomegalovirus infections: Laboratory methods of detection. *J Pediatr* 75:1179-1185, 1969.
5. Weller TH: The cytomegaloviruses: Ubiquitous agents with protean clinical manifestations. *N Engl J Med* 285:203-214; 267-274, 1971.
6. Goodman MD, Porter DD: Cytomegalovirus vasculitis with fatal colonic hemorrhage. *Arch Pathol* 96:281-284, 1973.
7. Nakoneczna I, Kay S: Fatal disseminated cytomegalic inclusion disease in an adult presenting with a lesion of the gastrointestinal tract. *Am J Clin Pathol* 47:124-128, 1967.

Halo Congenital Nevus

Martin H. Brownstein, MD; Bonnie B. Kazam, MD; Ken Hashimoto, MD

• A 24-year-old woman noted a depigmented halo around a pigmented lesion that had been present on her abdomen since birth. The halo and the central pigmented zone showed no change during the following year. Light and electron microscopic studies disclosed an uninflamed nevus extending to the deep reticular dermis; peripherally, the basal layer of the epidermis was depigmented. These findings indicate that a halo may develop about an *uninflamed* nevus that does not involute, and that the nevus may show the specific histopathology of *congenital* nevus.

(*Arch Dermatol* 113:1572-1575, 1977)

Depigmented zones may form about a variety of *acquired* melanocytic lesions,[1] including intradermal, compound, and blue nevi, and benign juvenile melanoma (spindle and epithelioid cell nevus), as well as primary and metastatic malignant melanoma. Histologic examination of the central lesion[1,2] classically shows a well-circumscribed, dense infiltrate of lymphoid cells and some melanophages admixed with nevus cells, enabling the pathologist to make the diagnosis of halo nevus without even examining the peripheral area of depigmentation. Our purpose here is to describe an example of a depigmented halo occurring around a *congenital* nevus in which inflammatory infiltrate was *absent* from the central area.

REPORT OF A CASE

A 24-year-old woman had had a 2.3 by 1.2-cm pigmented lesion on her abdomen since birth. The growth was dark brown and contained coarse black hairs. An irregularly shaped depigmented halo varying in width from 0.2 to 1.8 cm developed around it (Fig 1). Simultaneously, she noted several hypopigmented areas on her face, neck (Fig 2), and back. During the following year, there was no change in the central pigmented area or of the halo. Her general health was excellent.

One year after the appearance of the halo, a fusiform excision of the pigmented lesion, together with most of the halo and a small amount of normal skin, was performed under local anesthesia. A biopsy of a vitiliginous area on the neck was also carried out. Part of each specimen was fixed in 10% buffered formaldehyde and processed for light microscopy; another portion of each specimen was placed in 5% glutaraldehyde buffered to pH 7.2 with a 0.1M solution of cacodylate for electron microscopic examination.

Light microscopy showed benign nevus cells, with no inflammatory infiltrate, extending deeply into the reticular dermis (Fig 3). Staining with the Masson-Fontana silver technique disclosed heavy melanin pigmentation of the basal layer of the epidermis overlying the nevus (Fig 4, top left), a zone of depigmentation of the basal layer of the epidermis (Fig 4, top right), and an area of normally pigmented skin peripherally (Fig 4, bottom right). When examined by the silver technique, the hypopigmented macule on the neck showed a marked decrease, to absence of epidermal melanin.

When examined with the electron microscope, nevus cells in the dermis were slightly vacuolated (Fig 5); many of those in the upper cutis produced melanosomes. There was neither lymphocytic nor histiocytic infiltration into the lesion, except for occasional small monocytes; the nevus cell nests were practically free of inflammatory cells. In the epidermis overlying the intradermal lesion, melanocytes were shrunken but still produced melanosomes (Fig 6). Transfer of these melanosomes to the surrounding basal cells was accomplished normally. In the vitiliginous lesion apart from the halo nevus, epidermal melanocytes were still present, though shrunken and often vacuolated. Very small melanosomes were occasionally seen. The basal cells surrounding these atrophic melanocytes contained a small number of melanosomes. Similar findings have previously been described in vitiligo.[3]

COMMENT

For some time, it had been thought that nevi present at birth are huge and show the distribution of bathing trunks or other garments. Recently, it has been reported[4] that congenital nevi are almost always larger than 1.5 cm in greatest surface dimension, but are not always gigantic, whereas acquired nevi are usually smaller than 1.5 cm. Histologically, congenital nevi feature a distinctive pattern with nevus cells extending into the deep reticular dermis and even into the subcutaneous tissue. The nevocytes in congenital nevi may also involve, surround, and appear to invade the various adnexal structures of skin. The cells may be arranged in single file or in dense sheets, and at times show a neuroid configuration. Involvement of the deeper cutis is extremely unusual in acquired nevi. Congenital nevi have a higher incidence of associated malignant melanoma than the smaller acquired nevi; the melanoma may develop during childhood or later.[4] Prophylactic surgical removal has been advocated if feasible.

In our patient, a depigmented halo developed around a lesion that clinically, anamnestically, and histologically fulfilled the criteria for congenital nevus. It is well known that a halo can form around a variety of acquired melanocytic lesions,[1] including intradermal, compound, blue nevi, and benign juvenile melanoma (spindle and epithelioid cell nevus), as well as primary and metastatic melanoma, but very few cases of halo congenital nevus have been reported.[5,6] This is the first time, to our knowledge, the specific histopathologic picture of congenital nevus has been demonstrated in a halo nevus.

Halo nevi are often multiple, usually occur on the trunk, and appear most commonly in children and young adults. The condition is not inherited, nor does it show any sex predilection. In many patients, vitiligo develops at

Fig 1.—Pigmented growth surrounded by depigmented halo.



Fig 2.—Vitiliginous lesion on neck.

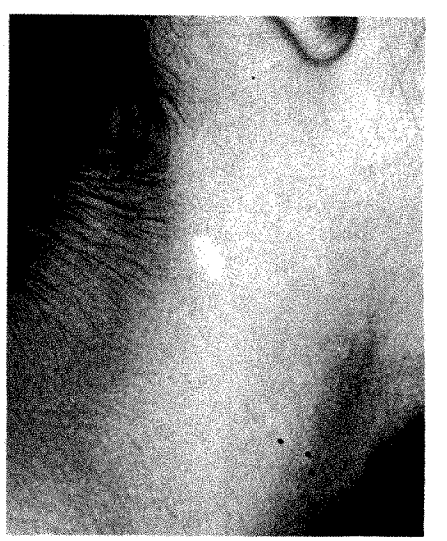

Accepted for publication Aug 23, 1976.

From the Departments of Dermatology (Drs Brownstein and Kazam) and Pathology (Dr Brownstein), New York Medical College-Metropolitan Hospital Center; and the Memphis Veterans Administration Hospital and the Division of Dermatology, Department of Medicine, University of Tennessee, Memphis (Dr Hashimoto).

Reprint requests to Laboratory of Dermatopathology, PO Box 400, Great Neck, NY 11022 (Dr Brownstein).

Fig 3.—Nevus cells extending into deep dermis and lack of inflammatory infiltrate (hematoxylin-eosin, ×2.4).

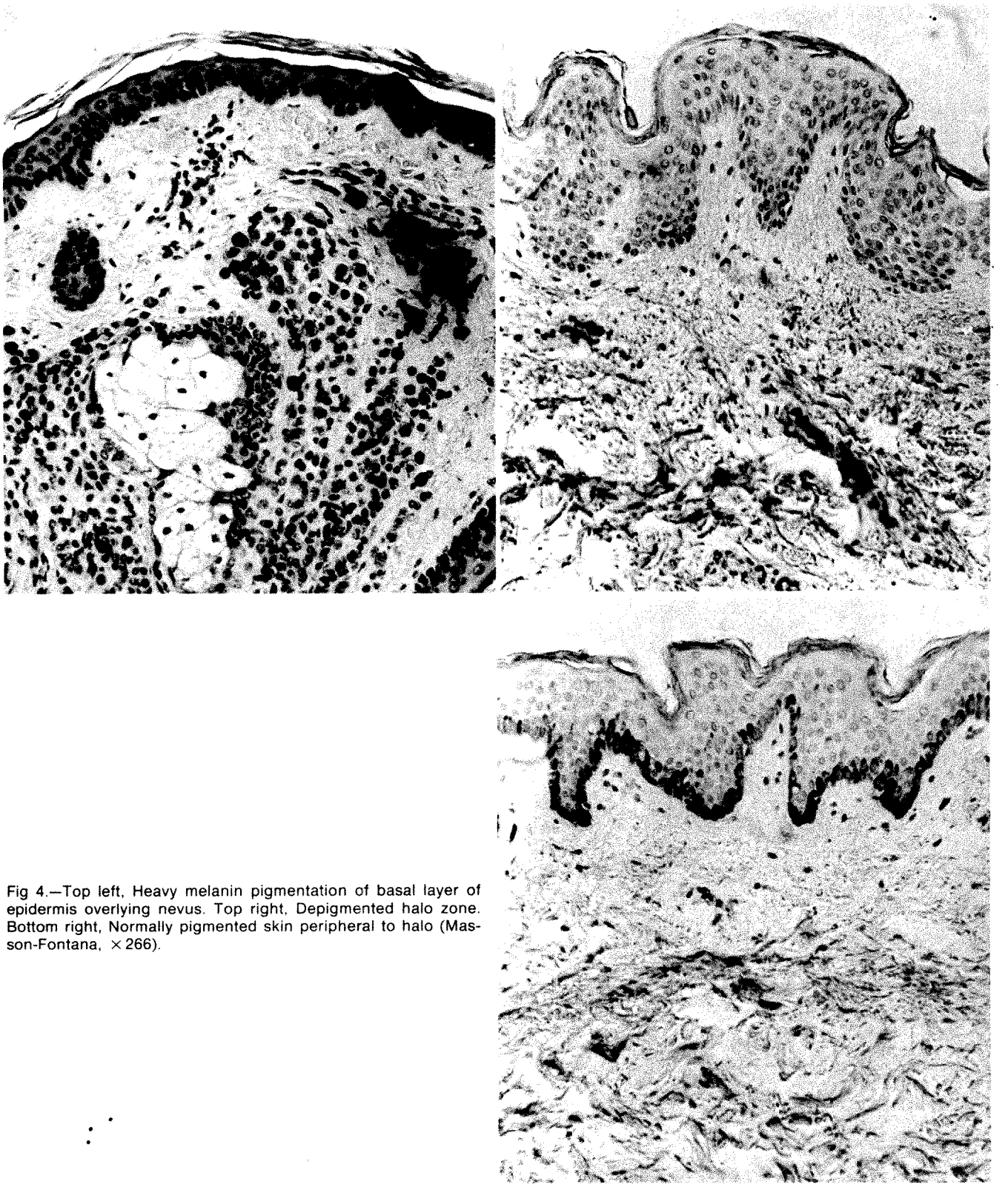

Fig 4.—Top left, Heavy melanin pigmentation of basal layer of epidermis overlying nevus. Top right, Depigmented halo zone. Bottom right, Normally pigmented skin peripheral to halo (Masson-Fontana, ×266).

Fig 5.—Nevus cells in dermis are slightly vacuolated (V). Melanosome (m) production is active. Morphology of some of these cells is similar to that of epidermal melanocytes, particularly when they possessed long dendrites (asterisks). Note lack of lymphocytic infiltration; every cell shown here is a nevus cell (×10,000).

distant and random sites.

Histologically,[1,2] the central lesion shows a dense, sharply demarcated infiltrate of lymphocytes and melanophages admixed with nevus cells that may be slightly atypical. When examined with the electron microscope,[7-10] the nevus cells have cytoplasmic vacuoles with evidence of autophagocytosis, and macrophages are found to contain phagocytosed portions of nevus cells. The epidermis over the pigmented lesion shows variable melanin pigmentation; the peripheral halo area progresses to complete absence of melanin. Clear epidermal cells in the halo are found to be Langerhans' cells on electron microscopic examination; melanocytes are not present.

Although early reports of halo nevi[11] mentioned nonregressing central pigmented lesions and central nevi without inflammation, most recent stud-

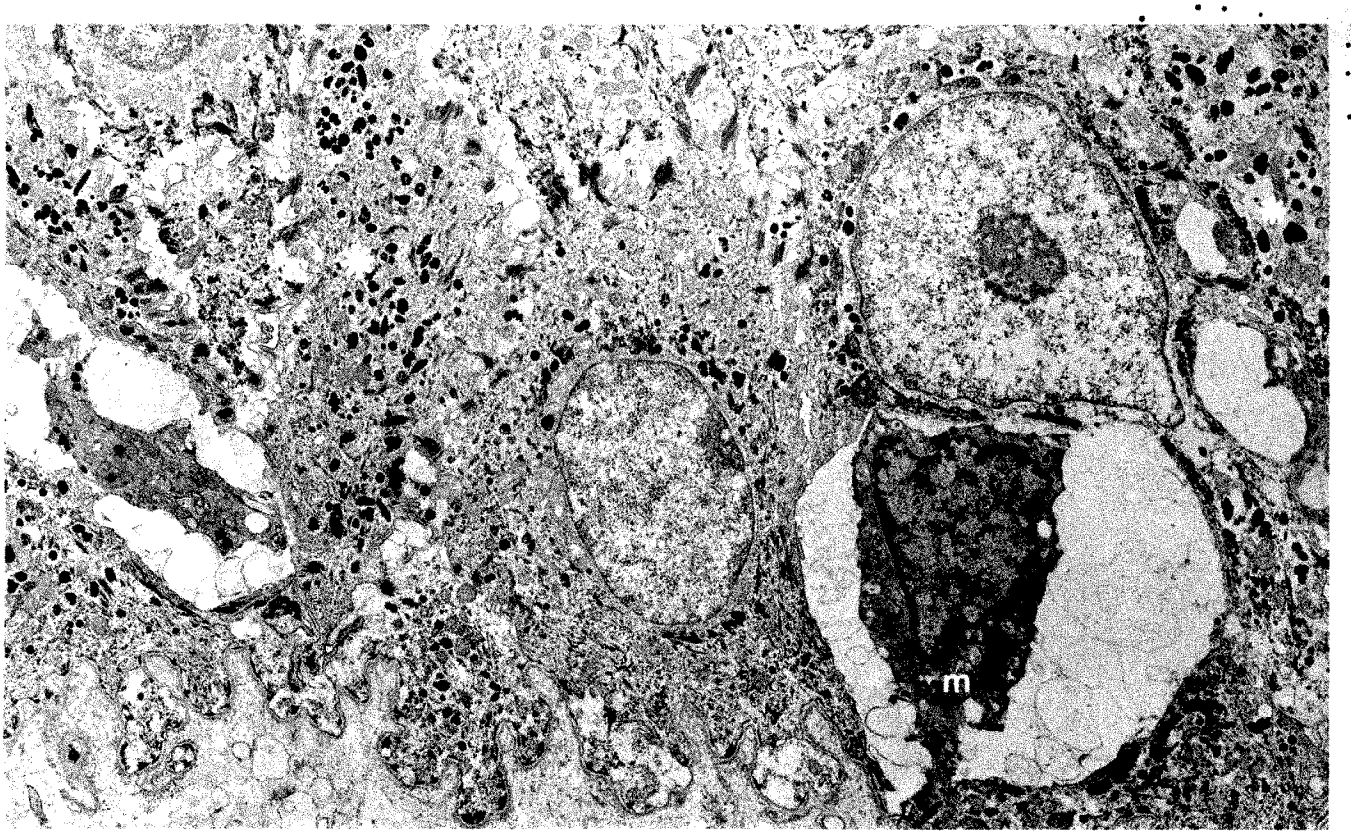

Fig 6.—Melanocytes in epidermis covering lesion are shrunken but still producing melanosomes (m). Surrounding basal cells received large number of melanosomes (asterisks) from these cells (×15,000).

ies[1,2] emphasize the progression to total destruction of the central nevus cells, with clinical disappearance of the pigmented lesion and of the histologic inflammatory infiltrate and, at times, repigmentation of the skin. This seems likely in one of the reported cases of congenital halo nevus.[6] It is clear, however, that some halo nevi do not follow this course, nor do they have the characteristic dense inflammation. The nevus in our patient showed no evidence of regression clinically and no signs of inflammation histologically after one year. The depigmented halo thus can not simply be attributed to an inflammatory process that destroys the central nevus. In one study,[11] half of 18 halo nevi did not spontaneously disappear. Biopsy specimens of five of 14 lesions showed intradermal nevi. In a previously reported case of halo congenital nevus,[3] the patient was followed up for 20 years with no involution of the lesions and no inflammation on biopsy. The fact that a halo nevus can remain unchanged clinically and have no inflammation histologically deserves emphasis. In at least some instances, there is a correlation between inflammation and involution.

The mechanism of halo nevus formation is still obscure. It was previously thought[12] that the halo represented the fortuitous appearance of vitiligo around a pigmented nevus. Recently, circulating antibodies (IgG) against the cytoplasm of melanoma cells have been demonstrated in patients with primary malignant melanoma and in resolving halo nevi.[13] It has also been shown[14] that lymphocytes from patients with halo nevi exhibit increased cytotoxicity against melanoma cells in vitro. There has even been speculation[13] that halo nevus represents rejection of a mole developing malignant changes, though this seems unlikely.[15] An alternative hypothesis to immune mechanisms is that depigmentation is related to a disturbance of the melanocyte-nerve relationships. Recently, it has been suggested that such mechanisms operate in other noninflammatory depigmentary disorders, including vitiligo, incontinentia pigmenti achromians, and the Vogt-Koyanagi syndrome.[3]

References

1. Kopf AW, Morrill SD, Silberberg I: Broad spectrum of leukoderma acquisitum centrifugum. *Arch Dermatol* 92:14-35, 1965.
2. Wayte DM, Helwig EB: Halo nevi. *Cancer* 22:69-90, 1968.
3. Morohashi M, Hashimoto K, Goodman TF, et al: Ultrastructural studies of vitiligo, Vogt-Koyanagi syndrome and incontinentia pigmenti achromians. *Arch Dermatol* 113:755-766, 1977.
4. Mark GJ, Mihm MC, Liteplo MG, et al: Congenital melanocytic nevi of the small and garment type: Clinical, histologic, and ultrastructural studies. *Hum Pathol* 4:395-418, 1973.
5. Berger RS, Voorhees JJ: Multiple congenital giant nevocellular nevi with halos: Clinical and electron microscopic study. *Arch Dermatol* 104:515-521, 1971.
6. Ridley CM: Giant halo naevus with spontaneous resolution. *Trans St Johns Hosp Dermatol Soc* 60:54-58, 1974.
7. Hashimoto K: Ultrastructural studies of halo nevus. *Cancer* 34:1653-1666, 1974.
8. Gauthier Y, Surleve-Bazeille JE, Gauthier O, et al: Ultrastructure of halo nevi. *J Cutan Pathol* 2:71-81, 1975.
9. Jacobs JB, Edelstein LM, Snyder LM, et al: Ultrastructural evidence for destruction in the halo nevus. *Cancer Res* 35:352-357, 1975.
10. Swanson JL, Wayte DM, Helwig EB: Ultrastructure of halo nevi. *J Invest Dermatol* 50:434-437, 1968.
11. Frank SB, Cohen HJ: The halo nevus. *Arch Dermatol* 89:367-373, 1964.
12. Leider M, Cohen TM: Leukoderma acquisitum centrifugum. *Arch Dermatol* 57:380-386, 1948.
13. Copeman PWM, Lewis MG, Phillips TM, et al: Immunological associations of the halo naevus with cutaneous malignant melanoma. *Br J Dermatol* 88:127-137, 1973.
14. Roenigk HH, Deodhar SD, Krebs JA, et al: Microcytotoxicity and serum blocking factors in malignant melanoma and halo nevus. *Arch Dermatol* 111:720-725, 1975.
15. Whimster IW: The halo naevus and cutaneous malignant melanoma. *Br J Dermatol* 89:111-113, 1974.

Atypical Multicentric Reticulohistiocytosis With Paraproteinemia

Jonathan R. S. Rendall, MRCP; Robert I. Vanhegan, BM, DPhil; Alastair H. T. Robb-Smith, MD, FRCP; Robert E. Bowers, MD, FRCP; Terence J. Ryan, FRCP; Henry R. Vickers, MD, FRCP

• Two women had multiple subcutaneous nodules that showed features of multicentric reticulohistiocytosis (MR). Neither had joint symptoms. Both had a raised erythrocyte sedimentation rate, an immunoglobulin G paraproteinemia, and raised levels of nonhepatic serum alkaline phosphatase. The skin lesions have been followed up, using light and electron microscopy, immunoperoxidase, and histochemical methods. The material in the giant cells stained positively for γ heavy chain determinants: the light chain type in each case was that of the paraprotein. An attempt to reproduce the skin lesions in one patient by intradermal injection of her paraprotein failed.

(*Arch Dermatol* 113:1576-1582, 1977)

The narrative defining multicentric reticulohistiocytosis (MR) has been confusing. In the differentiation from rheumatoid arthritis, lipid disorders, histiocytosis X, and other granulomatous disorders, the condition has been described under 14 titles. The first case has been attributed to Weber and Freudenthal.[1] Goltz and Laymon[2] introduced the term "multicentric reticulohistiocytosis." Davis and Wood[3] emphasized the separation of MR from the single reticulohistiocytoma of Zak.[4] More recently, Barrow and Holubar[5] fully reviewed the literature, history, and clinical criteria. They suggested the definition:

MR is a systemic disease of unknown cause manifested by the gradual development of nodules in the skin, mucosa, subcutaneous tissues, synovia, and, at times, periosteum and bone resulting in destructive arthritis and disfigurement of the facies. On biopsy of a nodule, whether from skin, mucosa or synovia, multi-nucleated giant cells and histiocytes with a ground glass appearance of the cytoplasm secondary to lipid inclusions are invariably seen.

Mihm et al,[6] in their survey of the histiocytic infiltrates of the skin, describe the distinctions between the histiocytosis X group, juvenile xanthogranuloma, giant cell reticulohistiocytosis, and MR. Flam et al,[7] and later Ehrlich et al,[8] used electron microscopy in their examination of the lesions. Characteristically, numerous small membrane-bound, electron-dense particles are seen within the giant cells.

Two female patients with many of the characteristics of MR, in addition to paraproteins demonstrable in serum and within their skin lesions, have been studied.

Accepted for publication Sept 3, 1976.

From the Department of Dermatology, Slade Hospital, Headington (Drs Vickers, Ryan, and Rendall), and the Department of Pathology, Radcliffe Infirmary (Drs Robb-Smith and Vanhegan), Oxford, England; and the Department of Dermatology, Gloucester Royal Hospital, Gloucester, England (Dr Bowers).

Reprints not available.

REPORT OF CASES

The two patients have been shown individually to the section of dermatology of the Royal Society of Medicine.[9,10]

CASE 1.—A 65-year-old woman first noticed a painless lump beneath her right eye one year before an initial examination. Subsequently, two others developed on her face, another on the left side of the neck, and several more on the upper part of the trunk. During this year, she experienced nasal irritation, occasionally associated with mucoid, sometimes blood-stained discharge. For ten years, she had recurrent episodes of episcleritis affecting both eyes.

Twelve mobile, nontender subcutaneous lumps were palpable. The skin over each was normal save for the lesion below the right eye that showed a yellow discoloration. The majority of the lumps were distributed over the face, neck, and upper part of the trunk. None were found below the level of the umbilicus. She had bilateral episcleritis and crystals were seen in the cornea by slit-lamp examination. The nasal mucosa was atrophic in appearance. For the last nine months, she has developed a typical parkinsonian tremor and gait.

CASE 2.—A 55-year-old woman first noticed a lump beneath the left eye 18 months before initial examination. Subsequently, she developed further lesions around each orbit that coalesced into indurated yellow plaques (Fig 1). The eyelids themselves were spared. At the same time, similar lesions evolved on each breast and at the site of an appendectomy. The lesion below the left eye became slightly ulcerated for a period, then healed. Nasal irrita-

Fig 1.—Periorbital lesions in case 2. Indurated yellow-colored plaques surround both eyes; eyelids themselves are spared.

Fig 2.—Subcutaneous nodule in skin in upper back of subject 2 showing deep dermal infiltration with unaffected upper dermis (hematoxylin-eosin, original magnification ×15).

tion with discharge has become a feature.

In addition to the lumps, the spleen was palpable and bilateral conjunctival plaques near the inner canthus were seen. Most recently, thin red plaques have developed over the dorsal surfaces of several fingers, particularly at the joints.

LABORATORY DATA

The results of laboratory tests from these two patients are compared (Table 1). In addition, the following were found to be negative: Mantoux test (1 in 100 old tuberculin), Wassermann reaction, Reiter protein complement fixation test, routine plasma reagin tests, rheumatoid factor (latex screening test), antinuclear factor, and lupus erythematosus cell preparation. Patient 1 received an intradermal injection of 0.1 ml Kveim antigen; no nodule appeared at this site, and biopsy was refused. Patient 2 had a negative result after Kveim biopsy. Sternal marrow aspirates were obtained from both and were within normal limits. No excess of plasmacytoid cells was detected nor was any abnormality detected in the monocytic series. Patient 2 received an intradermal injection of her paraprotein in parallel with normal saline as a control. Erythema was detected at the site at 48 hours but not at the control site. A biopsy done on the test site at six weeks revealed no abnormality.

Table 1.—Laboratory Data

Test	Case 1	Case 2	Normal Range
Hemoglobin, complete blood cell count, platelets, ESR (Westergren)	Normal, 40-60 mm/hr	Normal, 41 mm/hr	
Sequential multichannel analysis (Ca, Pi, urea, uric acid, cholesterol)	Normal	Normal	
Triglycerides, lipoprotein electrophoresis	Normal	Normal	
Glucose tolerance test, oral	Normal	Normal	
Serum alkaline phosphatase	160	168	80 ImU/100 ml
Nucleotidase	14	16	3-17 ImU/100 ml
Lactic dehydrogenase	372	269	50-225 ImU/100 ml
SGOT	59	109	4-40 units/ml
Albumin	2.3	3.0	3.5-5.2 gm/100 ml
Globulin	5.1	3.9	1.4-3.1 gm/100 ml
Paraprotein	IgG,κ	IgGλ	
Concentration	1.4	1.1	gm/100 ml
Immunoglobulins			
IgG	3,135	2,996	720-1,920 mg/100 ml
IgA	143	265	80-480 mg/100 ml
IgM	255	203	50-200 mg/100 ml
C3 level	160	192	80-140 mg/100 ml
X-ray examination: chest, skull, pelvis, long bones, hands	Normal	Normal	

HISTOPATHOLOGICAL FINDINGS

The biopsy specimens received for histopathological diagnosis were fixed either in formol-saline or Bouin's fixative. Nodules were seen to arise in the lower dermis at the border of the subcutaneous fat and were moderately well circumscribed although not encapsulated (Fig 2). A narrow free zone of normal dermis between epidermis and nodule was evident. Mast

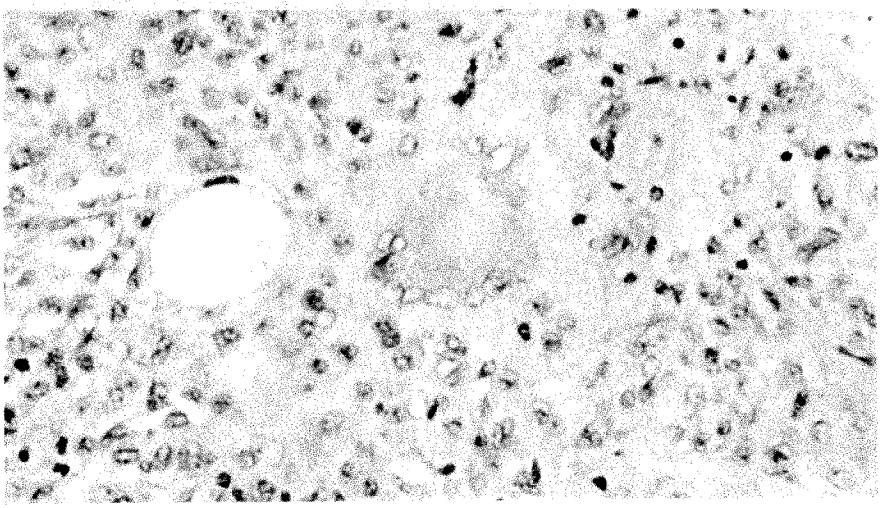

Fig 3.—Case 1. An area of subcutaneous adipose tissue infiltrated and replaced by monomorphic cells and multinucleate giant cells. Mature fat cell remains (clear space) with typical multinucleate giant cell near by (Diastase, PAS, and hematoxylin-eosin, original magnification ×500).



Fig 4.—Case 1. Reticulin around individual cells in infiltrate. Adipose tissue, collagen, and striated muscle have been replaced by newly formed reticulin around infiltrating cells and two giant cells shown (silver impregnation, original magnification ×500).

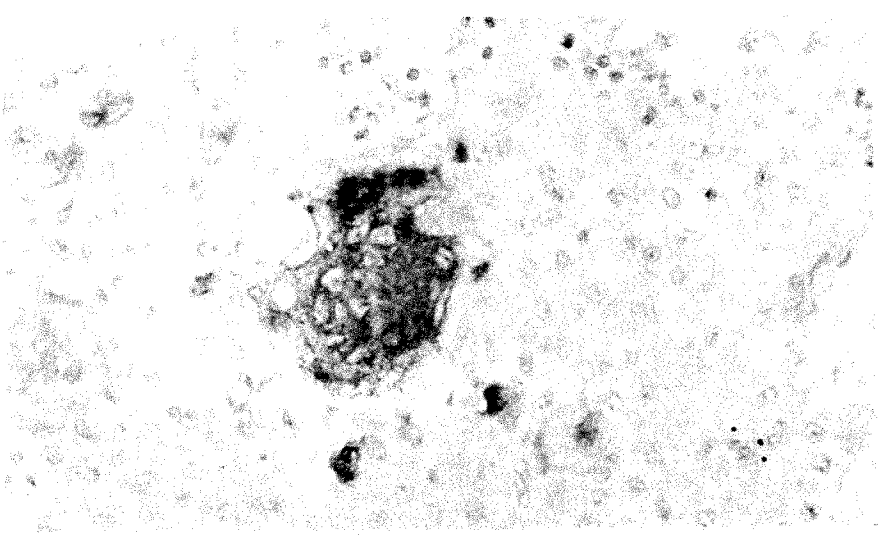

Fig 5.—Case 2. Immunoperoxidase staining for λ light chain determinants. Central giant cell is strongly positive as are five mononuclear cells in vicinity. Staining for κ determinants negative in this case (hematoxylin counter stain, original magnification ×500).

Table 2.—Multicentric Reticulohistiocytosis: Histiochemistry of Lesions

Technique	Single Cells	Multinucleate Cells
Diastase digestion followed by PAS for nonglycogen—CH (OH). CH (OH)—groups	Granular	Granular staining central to rim of nuclei
Oil red O for lipids on formalin fixed frozen sections	Small droplets	Larger droplets arranged peripherally, external to ring of nuclei
Alkaline phosphatase	Variable; slight to moderate activity	Very faint to negative in some cells
Acid phosphatase	Moderate activity	Heavy reaction product in peripheral lipid containing areas
Muramidase (by immunoperoxidase staining of antigen)	Negative	Negative
Paraprotein specific for each case (by immunoperoxidase)	Positive in only a few cells near multinucleate cells	Positive (Fig 4)
Amyloid (methyl violet, thioflavine T, Congo red and electron microscopy	None detected	
Reticulin (silver impregnation)	Normal dermal tissue (fat, collagen, and muscle) infiltrated and replaced by reticulin around single cells and multinucleate cells (Fig 7)	

Fig 6.—Case 2. Portion of cytoplasm of multinucleate cell. Numerous membrane bound electron dense granules are present in addition to mitochondria, smooth endoplasmic reticulum, and glycogen. Portion of one nucleus is visible at one corner (original magnification, ×25,200).

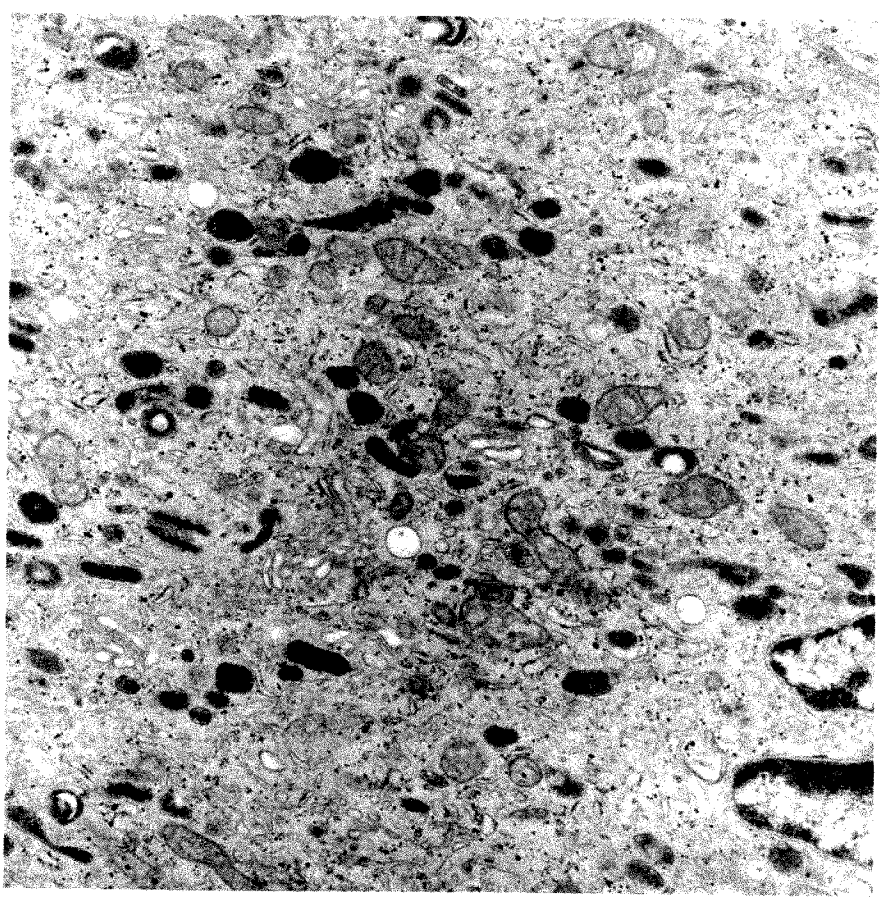

cells, when present, appeared "caught up" in the lesion, were granulated, and showed a normal morphological condition down to the electron microscopic level. Acute inflammatory cells, fibrinoid necrosis, and eosinophils were absent (Fig 3).

The nodules frequently abutted on normal collagen at the lateral margin. Sometimes the junction region was quite sharp, the collagen bundles giving way rapidly to split and swollen fibrillar forms that failed to stain altogether. The reticulin stain, however, was positive for fine fibers around individual cells and clumps of cells within the nodule (Fig 4). In the deeper aspect, the infiltrate was spreading between mature adipose cells. While the younger histiocytes showed an open nucleus and eosinophilic cytoplasm, clumps of older cells with condensed nuclei and foamy cytoplasm were often found in relation to adipose tissue.

A prominent feature in all the biopsy specimens was the presence of a considerable number of large multinucleated giant cells. These were both of the Touton type with a peripheral rim of foamy cytoplasm, an intermediate ring of nuclei, and a central island of eosinophilic cytoplasm, and also of the foreign-body type. The cytoplasm was eosinophilic, finely granular, and ground glass-like in appearance. These features form the hallmark of MR. No caseation or acid-fast bacilli were demonstrable.

The histochemical techniques were applied to Bouin's fixed, paraffin-embedded material when possible, and fresh-frozen sections where necessary. The histochemical reactions of the histiocytes were paralleled by both types of giant cells and are summarized in Table 2.

The immunoperoxidase studies followed the schedule of Burns.[11] Endogenous peroxidase activity in RBCs and leukocytes was destroyed by incubation in hydrogen peroxide in methyl alcohol after the sections were dewaxed: background staining was reduced by prior incubation of the sections in nonimmune swine serum. The location of bound rabbit antihuman antibody was demonstrated by using swine antirabbit serum to link it to a soluble complex of peroxidase/rabbit antiperoxidase. The specific peroxidase activity was demonstrated using diaminobenzidine and hydrogen peroxide. Antigens present in the dewaxed histological sections were then demonstrated by the binding of specific rabbit antihuman antibody (κ, λ, α, γ, μ determinants).

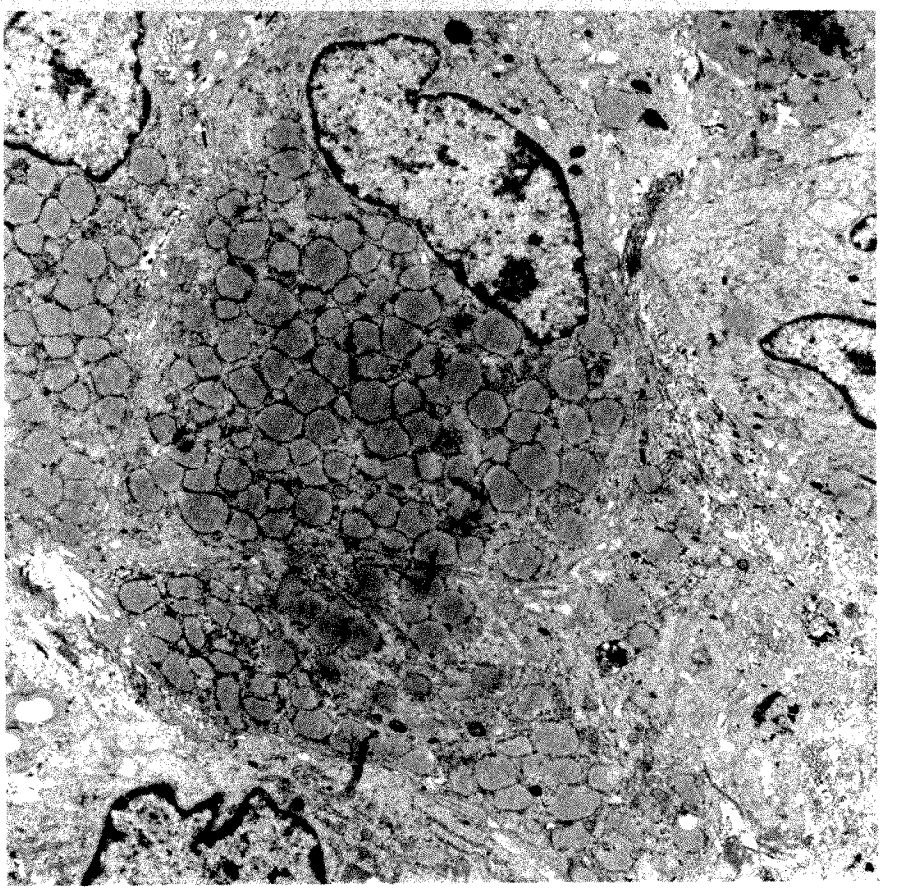

Fig 7.—Case 2. Mononuclear infiltrating cell showing cisternae bound by rough endoplasmic reticulum. Secretory protein has not been identified. Few such cells are found characteristically in the vicinity of the giant cells (original magnification, ×6,000).

The brown diaminobenzidine reaction product was well-localized and readily visualized in the light microscope. Sections may subsequently be stained with hematoxylin or the PAS techniques. The procedure has the advantage over immunofluorescence in that nuclear, cytoplasmic, and morphological detail may be visualized permanently in addition to the specific antigen.

No intracytoplasmic staining was observed, using antisera to the heavy chain determinants μ or α. The multinucleated giant cells and a number of surrounding mononuclears stained positively with the anti γ serum, indicating the presence of IgG. Those cells staining positively for γ heavy chains also stained positively for κ light chains in patient 1 and λ light chains in patient 2 (Fig 5). This corresponded to the paraprotein IgG, and no staining was seen with use of sera to the alternative light chain in either case.

The biopsy specimens intended for electron microscopy were immersed as rapidly as possible in phosphate-buffered 4% glutaraldehyde at pH 7.4. The tissues were immediately trimmed to approximately 1-mm cubes and fixed for six hours. They were then washed in two changes of cold phosphate buffer for two hours, after which they were postfixed in 1% osmium tetroxide in phosphate buffer at 4%. Dehydration was achieved with graduations of alcohol before passing the blocks into propylene oxide (1, 2 epoxypropane) and embedding in an epoxy resin. Sections were cut on an ultratome at 60 to 80 nm, mounted on bare copper grids, double-stained with 2% aqueous uranyl acetate and Reynolds lead citrate, and examined with an electron microscope.

The giant cell contained clear vacuoles, usually arranged around the periphery and corresponding in position with the oil red O positively in the fresh-frozen sections. In addition, they contained numerous small membrane-bound, electron-dense particles (Fig 6). A number of the single histiocytes showed cytoplasmic cisternae bound by a rough endoplasmic reticulum and contained uniform, moderately electron dense "secretion material for export" (Fig 7). Although this

Table 3.—Synopsis of Criteria for Diagnosis of MR

Criteria	Case 1	Case 2
1. Geographical distribution, most patients from United States or United Kingdom	+	+
2. Age of onset, mean 43 years	64	54
3. Sex, F to M ratio 3:1	F	F
4. Race, white 88%	+	+
5. Family history, usually negative	—	—
6. Initial manifestations, 2/3 joints and 1/3 skin	Skin	Skin
7. Clinical cause, mean time from onset to quiescence eight years	Progressing	Progressing
8. Skin nodules		
Color yellow—red/brown	Yellow	Yellow/brown
Distribution on body:		
Face, 94%	+	+
Hands, 91%	—	+
Cephalo caudal distribution	+	+
Ears, 76%	—	—
Scalp, 39%	+	+
Neck, trunk, and shoulders, 27%	+	+
Chest and abdomen, 21%	+	+
Nail folds, 39%	—	—
9. Other features:		
Fever	—	—
Weight loss	—	—
Malaise	+	—
10. Pathological findings:		
A. Light microscopy:		
Moderately well circumscribed nodules	+	+
Subepidermal free zone	+	+
Histiocytic lesion	+	+
Histiocytic multinucleated giant cells with eosinophilic, ground glass-like cytoplasm	+	+
Vacuoles in giant cell cytoplasm	+	+
B. Histochemistry:		
PAS reactive material	+	+
C. Electron microscopy:		
Vacuoles in giant cell cytoplasm	+	+
Electron dense membrane bound bodies in giant cell cytoplasm	+	+

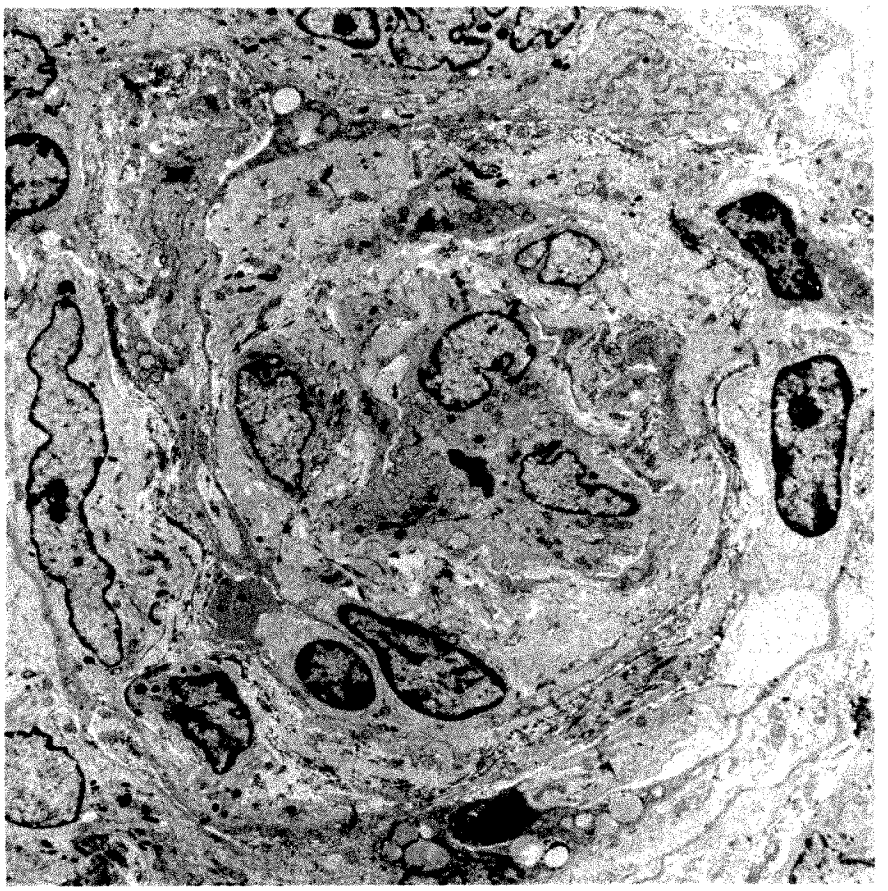

Fig 8.—Case 1. Capillary endothelial proliferation. Mononuclear cells in vessel lumen have cytological features similar to those in infiltrate (original magnification, ×4,320).

cytoplasmic appearance bore some resemblance to that of a plasma cell, the nuclear structure was more that of a histiocyte, and the Golgi apparatus did not figure so prominently. The material within the cisternae has not been characterized.

COMMENT

The criteria for the diagnosis of MR have been fully reviewed. The two cases described are compared with a synopsis of these criteria (Table 3). They conform well in showing most of the described features in so far as geographical distribution, age of onset, sex, race, clinical course, and pathological findings are concerned. However, there has been a striking absence of joint involvement, neither subject had ear nodules, and only one subject had slight changes over the back of the hands. Both patients may be in a relatively early stage of evolution of the process; alternatively, they may represent a rather benign variant of the disease. The differential diagnosis of MR has been exhaustively considered in the past.[7] A number of diseases are of special interest. Because the histological condition of the skin nodules in the two patients under discussion was reminiscent of that seen in a group of patients at the dermatology department with necrobiosis lipoidica, serum from six of these was investigated for the presence of a paraprotein. Three of the group had clinical diabetes, while three did not. In none was a paraprotein detected. Both the patients described in this report have normal glucose tolerance curves. Patient 2, however, has a cousin who suffered from maturity onset diabetes mellitus.

Capillary endothelial proliferation with narrowing of the lumen was occasionally seen (Fig 8) and bore a close resemblance to that described by Gray et al[12] in their histopathological study of diabetic and nondiabetic necrobiosis lipoidica. Such capillary changes are known to occur in the skin and other organs in patients with diabetes. Alteration in the composition of the serum proteins has been thought to play a role in the development of the vascular changes in this situation.

An immunoglobulin G λ serum paraprotein is invariably found in patients with papular mucinosis (lichen myxodermatosus). Five patients with the condition were reviewed by James et al.[13] In their series, the range for total immunoglobulin G was 610 to 1,220 mg/100 ml. In their cases and our own, the quantity of paraprotein was too small to give an increased total serum γ-globulin level. The clinical and histopathological appearances of papular mucinosis are, however, quite distinct from MR. The absence of osteolytic lesions and proteins in the urine, together with the normal bone marrow appearance, works against a diagnosis of multiple myeloma. It is possible that we have observed the coincidental occurrence of a benign monoclonal essential hypergammaglobulinemia and MR. The rarity of the latter makes this a very unlikely explanation.

The cause of MR is unknown. The two patients under discussion had three additional features, the significance of which is quite unknown, namely, a high serum alkaline phosphatase activity, a raised erythrocyte sedimentation rate (ESR), and paraproteinemia.

The "hepatic" 5-nucleotidase level in both was normal. Isoenzyme electrophoresis in agar showed the raised activity to be in a diffuse "bone" type distribution. The patients neither had symptoms nor radiological evidence of bone disease. There was no clinical evidence in either woman to suggest alternative sources of the enzyme such as the presence of placental tissue or a disorder of the gastrointestinal tract or kidney. An interpretation of the possible role of the enzyme in the disease will probably not be forthcoming until the heterogeneous enzymes contributing to serum alkaline phosphatase activity can be better defined. Reticulin is actively laid down around the cells in the dermal nodules, and it is conceivable that the enzyme from this process finds its way into the serum: the enzyme could be expected to display the same electrophoretic features as the mesodermal enzyme from bone.

The ESR is higher than would be predicted from the serum concentration of immunoglobulin. In case 2, the serum viscosity was measured and found to be raised at 2.29 centipoise (normal, 1.75 cp). The Coomb's test was negative in both patients, and immunoperoxidase staining on washed RBCs did not reveal surface binding of the paraprotein. Whatever causes the raised ESR may lead to sludging of RBCs and damage to small vessel walls favoring the deposition of

immune complexes. The side of the lesions may reflect differences in local blood flow or vascular reactivity.

By using sandwich immunofluorescence methods, it was not possible to demonstrate that the paraprotein from either patient would bind to uninvolved areas of their own skin or to skin biopsy specimens from patients with other conditions. Fluorescence was observed in the giant cells and a number of single cells, which, in so far as the technique permits, was in agreement with the immunoperoxidase results. Purified paraprotein from one patient injected intradermally into her own skin failed to elicit a nodule or cellular response.

The presence of the immunoglobulin within the older giant cells may be of significance. It appears to be specifically the paraprotein that is involved and not any of the other circulating immunoglobulins. Mature macrophages have receptors for the Fc portion of immunoglobulin G and can bind immune complexes. The impression gained from following up the two cases is that the earliest lesions consist of fairly large mononuclear cells around small vessels, and the fully developed dermal lesion, so well described in the literature, represents a late stage.

The hypothesis is advanced that the paraprotein might be an antibody produced following chronic exposure to an unidentified, possibly autologous antigen and that the proliferation of well differentiated histiocytes is a reactive process. The infiltrate may thus be viewed as having more in common with, for example, sarcoid than a neoplastic process in keeping with the fact that lesions show none of the features of malignancy. The improbability of a chance association of a paraprotein in two patients with MR suggests that an intensive search for an immunological basis could be rewarding in other cases.

Alfred J. Gunning, FRCS, referred case 1 for further study, and Anthony J. Bron, FRCS, gave an ophthalmological opinion in each case.

References

1. Weber FP, Freudenthal W: Nodular non-diabetic cutaneous xanthomatosis with hypercholestrolaemia and typical histiological features. *Proc R Soc Med* 30:522-526, 1937.

2. Goltz RW, Laymon CW: Multicentric reticulohistiocytosis of the skin and synovia. *Arch Dermatol Syphil* 69:717-731, 1954.

3. Davis BT, Wood SR: The so-called reticulohistiocytosis of the skin. *Br J Dermatol* 67:205-211, 1955.

4. Zak FG: Reticulohistiocytoma (Ganglioneuroma) of the skin. *Br J Dermatol* 62:351-355, 1950.

5. Barrow MV, Holubar K: Multicentric reticulo histiocytosis: A review of 33 patients. *Medicine* 48:287-305, 1969.

6. Mihm MC Jr, Clarke WH, Reed RJ: The histiocytic infiltration of the skin. *Hum Pathol* 5:45-54, 1974.

7. Flam M, Ryan SC, Mah-Poy GL, et al: Multicentric reticulo histiocytosis with electron microscopic study of skin lesions. *Am J Med* 52:841-847, 1972.

8. Ehrlich GE, Young I, Nosheny SZ, et al: Multicentric reticulohistiocytosis (lipoid dermato arthritis): A multicentric disorder. *Am J Med* 52:830-840, 1972.

9. Rendall JRS: Subcutaneous granulomata. *Proc R Soc Med* 68:449-450, 1975.

10. Bowers RE: Sclerosing lipogranuloma: Necrobiosis lipoidica. *Proc R Soc Med* 68:450-451, 1975.

11. Burns J: Background staining and sensitivity of the unlabelled antibody enzyme method (PAP): Comparison with the peroxidase labelled antibody sandwich methods using formalin fixed paraffin embedded material. *Histochemistry* 43:291-294, 1975.

12. Gray R, Graham JH, Johnson WC: Necrobiosis lipoidica: A histopathological and histochemical study. *J Invest Dermatol* 44:369-380, 1965.

13. James K, Fudenberg H, Epstein WL, et al: Studies on a unique diagnostic serum globulin in papular mucinosis. *Clin Exp Immunol* 2:153-166, 1967.

New Requirement for Authors

Congress recently passed *The Copyright Revision Act of 1976*, effective January 1, 1978, which impacts upon the American Medical Association's scientific publications procedure for acceptance of manuscripts submitted for publication.

In view of this new law, all transmittal letters to the editor accompanying manuscripts submitted for publication should contain the following language before manuscripts can be reviewed for possible publication: "In consideration of the AMA taking action in reviewing and editing my (our) submission, the author(s) undersigned hereby transfers, assigns, or otherwise conveys all copyright ownership to AMA in the event that such work is published by the AMA."

Ulcerative Systematized Porokeratosis (Mibelli)

Enthi M. Abdul Razack, MD, DD, Marthandam Natarajan, MD, ZDV, FDS

• **An unusual clinical variant of porokeratosis (Mibelli's disease) appeared in a patient soon after birth; the lesions were widely distributed mostly on the right half of the body. Spontaneous recurrent ulcerations occurred over certain sites. The right foot was grossly deformed as a result of atrophic scarring after ulcerations. Biopsy specimens of the classical lesion showed cornoid lamella. It is suggested that the term "ulcerative systematized porokeratosis" be used to describe this clinical variant of porokeratosis.**

(*Arch Dermatol* 113:1583-1584, 1977)

Porokeratosis (Mibelli), a rare disorder of keratinization, transmitted usually as autosomal dominant, affecting males twice as often as females, begins at birth, childhood, or later.[1,2] A second type of porokeratosis, disseminated superficial actinic porokeratosis (DSAP), was described by Chernosky and co-workers[3-6] as occurring in an older population and in sun-exposed parts of the body. The following clinical variants of porokeratosis have so far been described: the hyperkeratotic verrucous type, the hyperplastic type, Freund's forma minima[7] porokeratosis plantaris palmaris et disseminata,[2] Zosteriform porokeratosis of Mibelli[8] and linear porokeratosis of Mibelli.[9]

We recently had the opportunity of treating an adult man who had classical lesions of porokeratosis occurring with ulcerated ones that were confined mostly to the right half of the body and that did not conform to any one of the previously documented variants.

Accepted for publication Sept 21, 1976.

From the Department of Dermatology, Government Stanley Hospital, Madras, India.

Reprint requests to 24, Subadral St, Triplicane, Madras-600 005 (India) (Dr Razack).

REPORT OF A CASE

A 52-year-old man was admitted to the Skin Ward, Government Stanley Hospital for foul-smelling ulcerative skin lesions that were all over the body. His parents had first noticed a coin-shaped "lesion" on the right groin soon after birth. Over the years, the patient noticed more of these lesions; many of them enlarged centrifugally and became rough and ulcerated, especially during the summer months.

In 1951 the patient, born of consanguinous parents, married his first cousin. His only son aged 20 years, his mother, and two younger brothers are doing well; his father died at the age of 72. There was no family history of similar eruption.

Examination of the skin revealed hundreds of pigmented, annular, and gyrate plaques limited by keratotic ridges and seen more on the right half of the chest, back, forearm, palm, right thigh, and leg. The lesions on the neck and groin were ulcerated, discharging a serosanguinous fluid that emitted a 'musty' odor. In about six weeks' time, the ulcerated lesions started healing, leaving atrophic areas (Fig 1 and 2). The eruptions on the forehead and back of the forearm were annular with central atrophy surrounded by keratotic walls. The right foot was deformed with hallux valgus and syndactyly of the lateral two toes (Fig 3). The foot was smaller in size than its normal counterpart and showed atrophic scarring on its outer half and a painful ulcerated lesion on its arch. All the modalities of sensations were intact, with the lateral popliteal nerve being normal in thickness. The maximum circumference of the right and left legs at corresponding points were 23 and 31 cm, respectively. There was no substantial regional adenopathy and the mucous membranes were spared. Systemic examination showed no abnormalities.

FINDINGS

The routine laboratory investigations were within normal limits. Erythrocyte sedimentation rate was 27 mm/hr for the first hour (Westergren). The VDRL tests of both blood and CSF were nonreactive. X-ray film of the chest was normal and that of the right foot showed demineralization of the metatarsal bones and pha-

Fig 1.—Unilateral distribution of lesions with atrophy and scarring.

Fig 2.—Typical porokeratosis lesions on forearm, with atrophic scarring.

Fig 3.—Deformed foot with atrophy and scarring.

Fig 4.—Section from keratotic wall showing typical parakeratotic tier (hematoxylin-eosin, original magnification ×120).

langes, with gross deformity of the bones.

Histologic examination of the classical lesion of porokeratosis revealed hyperkeratosis, acanthosis, and the typical cornoid lamella. There was pigment incontinence and a chronic inflammatory infiltrate in the dermis (Fig 4). Histologic section from the ulcerated area showed the following features. The surface was ulcerated, the margin of the ulcer showing epidermal downgrowths with no evidence of subjacent infiltrate penetrating the epidermis. The dermis showed pigment incontinence and an infiltrate mostly consisting of round cells with occasional plasma cells. Basophilic changes were noticed in the adjacent subepidermal collagen.

COMMENT

Porokeratosis is a familial disorder of the skin that is characterized by localized areas of faulty keratinization that result in the cornoid lamella that is the hallmark of the disease process.[10,11] The initial lesion is a crateriform horny papule that gradually enlarges in a centrifugal fashion to form a plaque of circinate or irregular contour.[1] Though Mibelli assumed that the peripheral extension of the lesion was effected by the progressive involvement of new sweat pores, there is not much convincing documentation to substantiate this view. Hence, the term porokeratosis is a definite, if not a total, misnomer. The disease may be related to the appearance of abnormal clones of cells in the epidermis.[10]

The appearance of the earliest lesion at birth, the preponderance of the eruption on the right half of the body, and the presence of classic lesions of porokeratosis over the forehead and the back of the forearm would classify the case as being one of the Mibelli types in a systematized form; yet, the ulcerations limited by keratotic ridges and recurring at summer months might well justify an addition to the list of erstwhile clinical variants. To our knowledge, such an occurrence has not been reported.

The extreme atrophy after the ulceration deserves special attention. Even though no malignant neoplasm was observed either clinically or histologically in the case being reported, a few cases in which squamous carcinoma and Bowen's disease developed in such lesions have been reported.[12-14] The atrophic scarring had caused the deformity of the right foot that resulted in the limp and the consequent dimunition in the circumference of the leg. Atrophy of the epidermis in combination with fibrosis of the dermis might give one the impression of a resolving granulomatous process or a localized scleroderma; yet, such possibilities have been ruled out clinically and histopathologically in this patient.

A. S. Thambiah, MB, FRCP, FAMS, DV, interpreted the histopathological sections.

References

1. Ebling FJ, Rook A: Porokeratosis of Mibelli, in Rook A, Wilkinson DS, Ebling FJG (eds): *Textbook of Dermatology*. Oxford, England, Blackwell Scientific Publications, 1968, vol 2, pp 1062-1064.

2. Guss SB, Osbourn RA, Lutzner MA: Porokeratosis plantaris, palmaris et disseminate: A third type of porokeratosis. *Arch Dermatol* 104:366-373, 1971.

3. Chernosky ME: Report of 12 patients with multiple superficial lesions. *South Med J* 59:289-294, 1966.

4. Chernosky ME, Freeman RG: Disseminated superficial actinic porokeratosis (DSAP). *Arch Dermatol* 96:611-624, 1967.

5. Chernosky ME, Anderson DE: Disseminated superficial actinic porokeratosis: Clinical studies and experimental production of lesions. *Arch Dermatol* 99:401-407, 1969.

6. Anderson DE, Chernosky ME: Disseminated superficial actinic porokeratosis: Genetic aspects. *Arch Dermatol* 99:408-412, 1969.

7. Mikhail GR, Wertheimer FW: Clinical variants of porokeratosis (Mibelli). *Arch Dermatol* 98:124-131, 1968.

8. Goldner R: Zosteriform porokeratosis of Mibelli. *Arch Dermatol* 104:425-426, 1971.

9. Eyre WG, Carson WE: Linear porokeratosis of Mibelli. *Arch Dermatol* 105:426-429, 1972.

10. Reed RJ, Leone P: Porokeratosis—A mutant clonal keratosis of the epidermis: I. Histogenesis. *Arch Dermatol* 101:340-347, 1970.

11. Pinkus H, Mehregan AH: *A Guide to Dermato-histopathology*. New York, Appleton-Century-Crofts, 1969, pp 391-393.

12. Johnston ENM: Porokeratosis of Mibelli with squamous cell carcinoma. *Br J Dermatol* 70:381, 1958.

13. Savage J: Porokeratosis (Mibelli) and carcinoma. *Br J Dermatol* 76:489, 1964.

14. Coskey R, Mehregan A: Bowen disease associated with porokeratosis of Mibelli. *Arch Dermatol* 111:1480-1481, 1975.

Recurrent Pyoderma Gangrenosum and Agnogenic Myeloid Metaplasia

Jeffrey P. Callen, MD; Howard V. Dubin, MD; Charles F. Gehrke, MD

• Pyoderma gangrenosum has been associated with myelogenous leukemia and plasma cell dyscrasia. When associated with leukemia, pyoderma gangrenosum often has a distinctive clinical presentation with an advancing bullous margin. The pathogenesis of this disorder is unknown, although defective immune mechanisms may be operative. The occurrence of pyoderma gangrenosum and agnogenic myeloid metaplasia in the same patient has now been reported sufficiently to make it a recognized association.

(*Arch Dermatol* 113:1585-1586, 1977)

Pyoderma gangrenosum is an uncommon cutaneous condition often associated with internal diseases.[1] The diagnosis of pyoderma gangrenosum is a clinical one, made by exclusion of other entities. The typical appearance is that of an ulcerated lesion with violaceous necrotic borders. Often the lesion rapidly expands. Other causes of necrosis and ulceration must be ruled out prior to a diagnosis of pyoderma gangrenosum. The condition is most frequently associated with bowel disease (ulcerative colitis); however, it has also been associated with rheumatoid arthritis,[2] monoclonal gammopathy,[3-5] and leukemia.[1,6-10] We report a case of pyoderma gangrenosum in a woman with agnogenic myeloid metaplasia and review the literature of the association of pyoderma gangrenosum with myeloproliferative disorders and malignancies.

Accepted for publication Sept 27, 1976.

From the Departments of Dermatology (Drs Callen and Dubin) and Internal Medicine (Simpson Memorial Institute) (Dr Gehrke), University of Michigan Medical School, Ann Arbor.

Reprint requests to Department of Dermatology, University of Louisville School of Medicine, Louisville, KY 40202 (Dr Callen).

REPORT OF A CASE

A 62-year-old woman was in good health until June 1974 when she noticed a lump in her abdomen. In August 1974, an enlarged spleen was found. Her WBC count was 64,000/cu mm. Results of hemoglobin, platelet count, and blood volume studies were normal. Findings on a bone marrow biopsy were consistent with agnogenic myeloid metaplasia. Since that time, she has been treated with busulfan in varying dosages.

In October 1974, the patient noted development of a pustule on her right hand that spread and ulcerated and covered a large part of her hand. She had an associated lesion on her face (Fig 1). She was thought to have sporotrichosis and was therefore treated with potassium iodide. She developed a severe allergic reaction to the iodide, however, with fever, chills, abdominal pain, and was admitted to a hospital. The skin lesions spontaneously resolved after her iodides had been stopped. Cultures taken at that time from the skin lesions for atypical mycobacteria, fungi, and aerobic and anaerobic bacteria were all negative. She had no other skin diseases until October 1975, when she noted a pustule on her right hand that spread to cover the dorsum of her hand. No trauma was noted to her hand prior to the development of these lesions. In addition, within the week prior to admission, she noted the development of a small erythematous lesion on her face below her left eye. Cultures for atypical mycobacteria and deep and superficial fungi were negative. She was treated with dicloxacillin sodium monohydrate with no improvement. She was subsequently admitted to the University of Michigan Medical Center. Family history indicated one sister with leukemia (type unknown) and a daughter with ankylosing spondylitis. No similar skin problems, ulcerative colitis, or rheumatoid arthritis were noted in any family members. There has been no industrial exposure to halides or halogens. The patient denied fever, chills, or weight loss.

The physical examination revealed a blood pressure of 140/80 mm Hg, respirations of 16 per minute, pulse rate of 100 beats per minute, and a temperature of 36.6 C. She was a thin woman in no acute distress. Examination of her skin showed a tender ulcerated area with an advancing necrotic blue-gray margin that was approximately 7 × 6 cm on the dorsum of her right hand. The border was bullous. An erythematous plaque was present under her left eye. Examination of her neck revealed unremarkable cervical adenopathy. The liver span was 10 cm in the right midclavicular line. The spleen was palpated 7.5 cm below the left costal margin; it was firm and not tender. The width of the spleen was approximately 6 cm at its largest diameter. Other physical findings were normal.

Fig 1.—Facial ulcerated and crusted lesions of pyoderma gangrenosum.

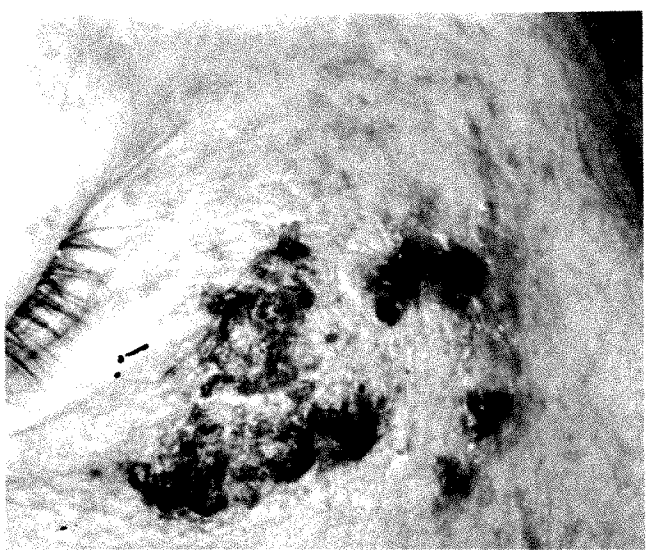

Fig 2.—Biopsy specimen of hand lesion demonstrating dense polymorphous inflammatory infiltrate with granulation tissue and purulent exudate (hematoxylin-eosin, × 40).

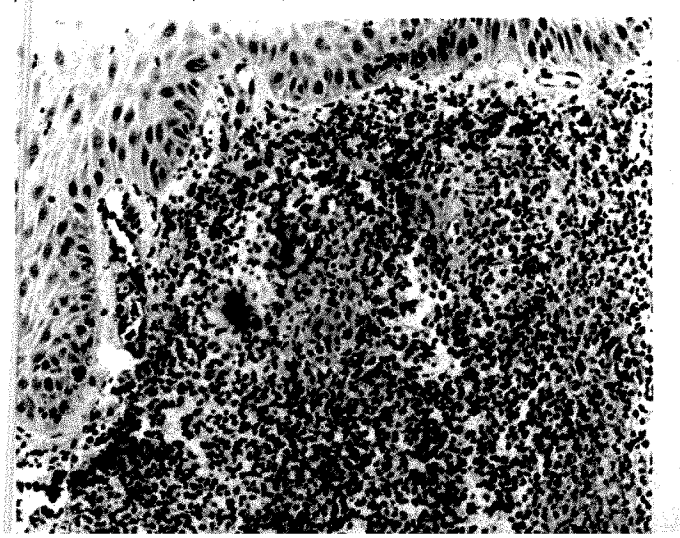

Laboratory findings included the following: WBC count of 45,000/cu mm, with a differential of 16 segmented polymorphonuclear cells, 48 band forms, seven lymphocytes, no mononuclear cells, 11 eosinophils, seven basophils, five metamyelocytes, five myelocytes, and five progranulocytes. Platelet count was 290,000/cu mm. Hemoglobin level was 16.6 gm/100 ml. Findings on a bone marrow biopsy were consistent with the diagnosis of agnogenic myeloid metaplasia. Cultures for fungi and acid-fast bacilli (AFB) were negative. The leukocyte alkaline phosphatase level was 294 units/100 ml (normal, 50 to 200 units/100 ml); complement fixation tests for fungi were negative; the lactic acid dehydrogenase (LDH) was 692 units/100 ml (normal < 205 units/100 ml); the alkaline phosphatase level was 290 units/100 ml (normal < 110 units/100 ml); the serum leucine aminopeptidase level was 180 units/100 ml (normal < 180 units/100 ml). The LDH isoenzyme pattern was normal. Protein electrophoresis and immunodiffusion were within normal limits. The VDRL test for syphilis was negative. X-ray films of chest, skull, and right hand and wrist, intravenous pyelogram, barium enema examination, and bone scan were normal. Cultures of her hand lesion and bone marrow were taken and were negative for fungi, AFB, and aerobic and anaerobic bacteria. A skin biopsy specimen of her hand lesion showed a hyperplastic epidermis that covered a dense polymorphous inflammatory infiltrate with granulation tissue and purulent exudate. No granulomatous inflammation was present (Fig 2). A biopsy specimen of the lesion on her face showed a circumscribed zone of necrosis with a purulent exudate in the reticular dermis. No organisms were seen on routine stains or special stains for fungi. The histologic findings in both lesions were compatible with the diagnosis of pyoderma gangrenosum. The patient was seen in consultation with hematologists, who agreed with our diagnosis of myeloid metaplasia. She was treated with soaks, wound debridement, and topically applied corticosteroid (fluocinonide gel). She was continued on busulfan (4 mg/day). Skin tests were done for dermatophytin, which was positive, and purified protein derivative, which was negative. She was started on a regimen of prednisone, 30 mg/day because of continued progression of the cutaneous ulceration. This therapy resulted in a marked improvement of her cutaneous disease.

COMMENT

Pyoderma gangrenosum is a clinically diagnosed condition that has no specific histologic or laboratory features. The clinical diagnosis depends on a typical clinical presentation and a careful evaluation to rule out other diseases, including bacterial pyoderma, fungal pyoderma, necrotizing vasculitis, bites, factitial ulceration, and iododerma. These were ruled out in our patient.

The cause of pyoderma gangrenosum is unknown. Reports of altered immunity have frequently appeared in the literature. Multiple case reports of the association of pyoderma gangrenosum with paraproteinemias have appeared.[3-5] To date, 16 cases of paraproteinemia and pyoderma gangrenosum have been reported (12 with IgA, five with IgG, and one with IgM).[3] Although some of these patients developed or had multiple myeloma, this was not always the case. It has been suggested that alteration of the serum immunoglobulins may in some way predispose to pyoderma gangrenosum.[4,5]

Association of pyoderma gangrenosum with rheumatoid arthritis has also suggested varying alterations in immunity. In a recent report, two patients with rheumatoid arthritis and pyoderma gangrenosum were studied.[2] The serum IgA was slightly elevated in each case. However, complement levels, lymphocyte counts, T rosettes, lymphocyte blastogenesis, and delayed type hypersensitivity in vivo were normal. Immunoglobulins could not be demonstrated by direct immunofluorescence of the skin. Their skin biopsies, however, were not noted to be taken from an early lesion, and therefore negative immunofluorescence was not meaningful. Positive immunofluorescence with immunoglobulins and complement has been demonstrated in a previous study of pyoderma gangrenosum in a lesion induced by injection of potassium iodide.[5] Although immunoglobulins have been found periodically in skin lesions of pyoderma gangernosum, serum complement has been normal or elevated,[11] and no circulating complexes have been demonstrated. It appears unlikely that pyoderma gangrenosum represents a Arthus reaction (type III hypersensitivity).

Alteration of cellular immunity has been discussed in the literature. Depressed phytohemagglutinin induced lymphocyte blastogenesis, and failure to sensitize to dinitrochlorobenzene has been noted.[12,13] Lazarus and his co-workers demonstrated dissociation of lymphocyte blastogenesis and macrophage inhibition factor production in vitro in pyoderma gangrenosum.[12]

Clinically, pyoderma gangrenosum associated with myeloproliferative disorders and leukemia has displayed characteristic features.[7] The ulcers are superficial, they spread concentrically with a blue-gray bullous margin, and they are associated with severe pain. These features were present in our patient's hand lesion during both of her episodes of pyoderma gangrenosum. However, the recent facial lesion was merely a superficial erythematous plaque. Two of the patients described by Perry and Winkelmann[7] were diagnosed as having agnogenic myeloid metaplasia. One case in the earlier review by Perry[1] and a subsequent case[10] suggest a specific association of pyoderma gangrenosum with agnogenic myeloid metaplasia. In addition, the cases of pyoderma gangrenosum associated with malignancy have been those associated with chronic myelogenous leukemia,[9] acute myelogenous leukemia,[7] and one case of acute lymphocytic leukemia.[8] The explanation for these associations and the lack of association with other lymphoproliferative disorders or solid tumors is unknown.

Nonproprietary Names and Trademarks of Drugs

Dicloxacillin sodium monohydrate—*Dynapen, Pathocil, Veracillin.*
Fluocinonide gel—*Lidex, Topsyn.*

References

1. Perry HO: Pyoderma gangrenosum. *South Med J* 62:899-908, 1969.
2. Stolman LP, Rosenthal D, Yaworsky R, et al: Pyoderma gangrenosum and rheumatoid arthritis. *Arch Dermatol* 111:1020-1023, 1975.
3. Jablonska S, Stachow A, Dabrowska H: Rapports entre la pyodermite gangreneuse et le myelone. *Ann Dermatol* 94:121-132, 1967.
4. Imhof JW, Vlengels Schutter GJN, Hart HC, et al: Monoclonal gammopathy (IgG) and chronic ulcerative dermatitis (phagedenic pyoderma). *Acta Med Scand* 186:289-292, 1969.
5. Thompson DM, Main RA, Beck JS, et al: Studies on a patient with leukocytoclastic vasculitis, pyoderma gangrenosum and paraproteinemia. *Br J Dermatol* 88:117-125, 1973.
6. Maldonado N, Torres VM, Mednez-Cashion D, et al: Pyoderma gangrenosum treated with 6-mercaptopurine and followed by acute leukemia. *J Pediatr* 72:409-414, 1968.
7. Perry HO, Winkelmann RK: Bullous pyoderma gangrenosum and leukemia. *Arch Dermatol* 106:901-905, 1972.
8. Tay CH: Pyoderma gangrenosum and leukemia. *Arch Dermatol* 108:580-581, 1973.
9. Goldin D: Pyoderma gangrenosum with chronic myeloid leukemia. *Proc R Soc Med* 67:1239-1240, 1974.
10. Gopinath DK, Wolfe RD, Sabharwal K: Pyoderma gangrenosum with myelofibrosis. *J Ky Med Assoc* 72:548-566, 1974.
11. Michel B, Haserick JR, Naff GB: Elevated levels of serum complement in patients with pyoderma gangrenosum. *Br J Dermatol* 82 (suppl 5):24-25, 1970.
12. Lazarus GS, Goldsmith LA, Rocklin RE, et al: Pyoderma gangrenosum, altered delayed hypersensitivity and polyarthritis. *Arch Dermatol* 105:46-51, 1972.
13. Delescluse J, deBast Cl, Achten G: Pyoderma gangrenosum with altered cellular immunity and dermonecrotic factor. *Br J Dermatol* 87:529-532, 1972.

Cobb Syndrome

R. Thomas Jessen, MD; Stephen Thompson, MD; Edgar B. Smith, MD

• Cobb syndrome consists of a vascular skin nevus associated with an angioma in the spinal cord. We describe a young man with this condition. To our knowledge, this is the 28th case reported. Cobb syndrome must be differentiated from other syndromes characterized by vascular cutaneous lesions associated with central nervous system abnormalities, such as Sturge-Weber, Osler-Weber-Rendu, Fabry-Anderson, von Hippel-Lindau, and ataxia telangiectasia.

(*Arch Dermatol* 113:1587-1590, 1977)

Cobb syndrome, or cutaneomeningospinal angiomatosis, is the combination of a vascular skin nevus and an angioma in the spinal cord corresponding within a segment or two to the dermatome involved.[1] The first case was reported by Berenbruch in 1890.[2] The syndrome did not receive recognition until Cobb's description in 1915, however.[3] As of 1972, only 27 cases had been reported in the world literature, none in English language dermatologic periodicals.[2-24] We discuss the 28th case of cutaneomeningospinal angiomatosis.

REPORT OF A CASE

Our patient was 15 years old when he first came to Bernalillo County Medical Center in August 1972. Multiple hemangiomas over the right side of his trunk, buttocks, and right leg had been present since birth without evidence of involution. He sought care because of bleeding, superficial infection, and pain in the skin lesions that interfered with his activities. A hemangioma had been excised from the right knee in 1968. No other family members had similar lesions, and the patient was otherwise healthy. No neurologic abnormalities were detected on examination at that time. During that hospitalization, four ulcerated hemangiomas were excised from the right leg with the patient under general anesthesia. The histologic appearance of the tumors was that of a combined cavernous and capillary hemangioma with the cavernous pattern predominating.

At age 19 the patient returned to Bernalillo Country Medical Center requesting further excision of his cutaneous hemangiomas. He also complained of weakness of the right leg of two months' duration associated with a limp and difficulty emptying his bladder.

Physical examination showed no abnormalities except those relating to the dermatologic and neurologic findings on the right side of his trunk and lower right extremity. The right leg was noticeably smaller than the left, both in length and circumference. His gait was asymmetric and somewhat halting, with a shorter period of weight-bearing on the right leg than on the left and a tendency to advance the right leg with the knee extended. The right hip flexors and ankle dorsiflexors were weak. Knee and ankle jerks were brisk bilaterally with the right greater than the left, and Babinski's sign was present bilaterally. Sensitivity to pin, cotton, and vibration was diminished bilaterally from the upper level of the cutaneous lesions downward. Position sense was decreased bilaterally in the toes. Multiple skin tumors were present varying from 3 to 6 cm in diameter on the right side of the body (Fig 1). The lesions were vascular-looking and purple and had sharply demarcated irregular borders.

The surfaces of the lesions were rough, and many were crusted. These vascular lesions were present from the level of the umbilicus downward to the inguinal region and approximately followed the distribution of the fourth and fifth lumbar dermatomes on the right leg. The lesions were dense proximally and became sparse as they progressed distally down the leg.

Results of laboratory studies including hemogram, platelet count, urinalysis, and VDRL for syphilis were normal. The spinal fluid was clear and colorless with no increase in cells or protein, and no organisms were found on culture. Thoracic and lumbosacral spine x-ray films were unremarkable. A lumbar and thoracic myelogram showed partial obstruction at T-8 to T-9 by a fusiform widening of the spinal cord. Spinal angiography was performed by catheter in the right femoral artery with selective injection of the thoracic and lumbar spinal arteries. Angiograms failed to demonstrate any arteriovenous malformation. Biopsy of the skin lesions showed mild hyperkeratosis and thinning of the epidermis with focal acanthosis (Fig 2). Focal epidermal areas contained dilated and trapped vascular channels with single endothelial cell linings. These dilated vascular channels were also present in the papillary and deeper dermal layers (Fig 3). In the deeper dermis they interdigitated between glandular structures. There were scattered foci of extravasated erythrocytes and occasional perivascular inflammatory cells, mononuclear in type, in the upper dermis.

In August 1975, a thoracic laminectomy was performed. The spinal cord was found to be widened from the level of the eighth to the tenth thoracic vertebrae. The cord was nodular, and two bluish, mulberry-shaped hemangiomas were present on the right side. No attempt at surgical correction was made. Postoperatively the patient had a slow recovery with no change in his neurologic status. A cystometrogram performed after surgery showed a normal curve. Nine days postoperatively the patient was transferred to a special facility for rehabilitative therapy.

COMMENT

In 1915, Cobb described an 8-year-old boy who was suddenly stricken while playing ball with a sharp pain in his lower back that radiated to the lower abdomen. The first episode of pain resolved, but three days later a similar attack occurred, which, in 14 hours, progressed from numbness of the left leg to flaccid paraplegia

Fig 1.—Angiokeratomas of Cobb syndrome.

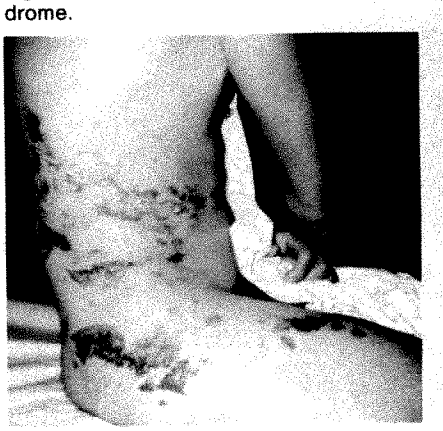

Accepted for publication Sept 23, 1976.

From the Veterans Administration Hospital (Drs Jessen and Smith), and the Division of Dermatology, Department of Medicine (Drs Jessen and Smith) and the Department of Neurology (Dr Thompson), University of New Mexico School of Medicine, Albuquerque.

Read before the Section on Dermatology at the annual convention of the American Medical Association, Dallas, June 30, 1976.

Reprint requests to Division of Dermatology, University of New Mexico School of Medicine, 2701 Frontier NE, Albuquerque, NM 87131 (Dr Smith).

Fig 2.—Biopsy specimen of right leg lesion in 1972. Epidermis is mildly hyperkeratotic and thinned with focal acanthosis. Focal epidermal areas contain dilated entrapped vascular channels with single endothelial cell linings. These dilated vascular channels are also present in papillar and deeper dermal layers (hematoxylin-eosin, ×25).

accompanied by analgesia to about the ninth thoracic dermatome. On examination the patient was found to have a "birthmark of the 'port wine' variety on the left back" at the level of the upper limit of the analgesia. Over a period of 10½ weeks the paraplegia became spastic. Subsequently, "a swelling along the right side of the vertebral column from the 4th to the 8th dorsal vertabrae was noted. The patient was seen by Dr Cushing who ventured a diagnosis of congenital dermoid haemangioma." On laminectomy, the patient was found to have an "extraordinary tangle of large pulsating vessels" involving the spinal cord at the level of the sixth through the tenth thoracic vertebrae.[3]

Since Cobb's original discussion, only 25 additional cases have been reported. Seventeen of these were well reviewed by Kissel and Dureux in 1972.[4] These authors believed that Cobb syndrome may not be as rare as the small number of case reports implies. They suggested that improved radiographic techniques may increase the ease of diagnosis. Arteriography has been performed on nine of the reported cases of Cobb syndrome.[20-22,24] Despite the contention of Kissel and Dureux, this technique was not helpful in demonstrat-

	Cobb[2-24]	Sturge-Weber[1, 25, 27-30]
Synonym	Cutaneomeningospinal angiomatosis	Encephalotrigeminal angiomatosis
Inheritance	Not familial	Dominant partial trisomy or not familial
Sex distribution	More in males	Equal
Age of onset	Childhood or adolescence	Two thirds with hemangioma at birth
Skin lesion	Port wine stain or angiokeratomas in dermatomal distribution corresponding within segment or two of area of spinal cord involvement*	1. Ipsilateral capillary angioma or port wine stain in distribution of the superior and middle branches of the trigeminal nerve*; associated cavernous changes may occur 2. No consistent relationship between extent of skin lesion and degree of meningeal involvement
CNS findings	1. Arteriovenous or venous angioma of the spinal cord* 2. Neurologic signs of cord compression or anoxia	1. Angioma of meninges* 2. Intracranial gyriform calcifications 3. Mental retardation (60%)* 4. Epilepsy (usually focal)* 5. Hemiparesis contralateral to skin lesions* 6. Visual impairment (50% have one or more of variety of eye abnormalities)*
Associated findings	1. Angioma of vertebrae 2. Renal angioma 3. Kyphoscoliosis	1. Renal angioma 2. Coarctation of aorta 3. High arched palate 4. Abnormally developed ears
Diagnostic aids	1. Lateral spine x-ray 2. Myelography 3. Selective spinal angiography	1. EEG 2. Skull x-ray 3. Cerebral angiography
Treatment	Surgical removal of spinal cord angioma if possible	1. Anticonvulsants 2. Surgical removal of intracranial lesion if possible 3. Cosmetic procedures for skin lesions

* Major components of the syndrome.

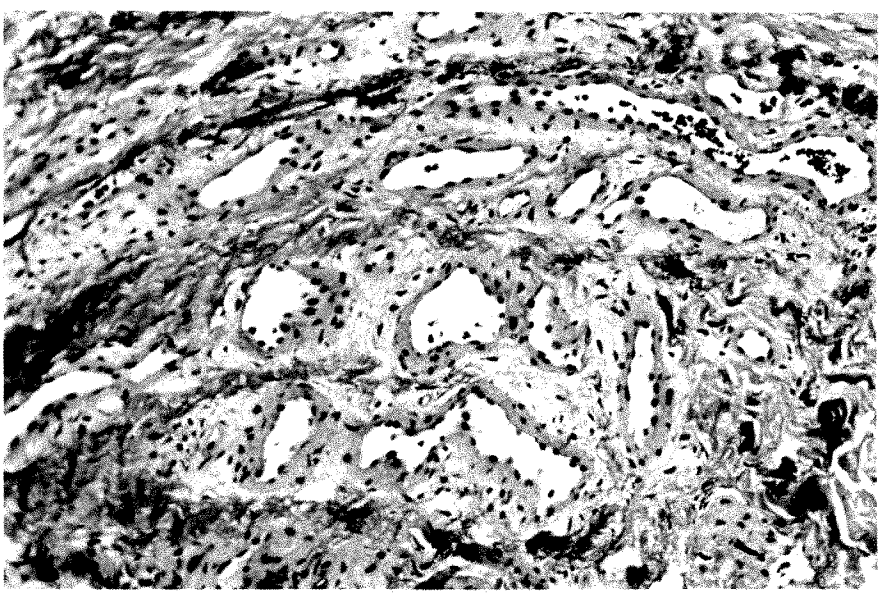

Fig 3.—Biopsy specimen of right leg lesion in 1975. Vascular channels with single endothelial cell lining found in papillary dermis (hematoxylin-eosin, ×100).

Neurocutaneous Syndromes

Osler-Weber-Rendu[1, 28, 31]	Fabry-Anderson[1, 32]	Ataxia Telangiectasia[33-35]	Von Hippel-Lindau[1, 25, 36, 37]
Hereditary hemorrhagic telangiectasia	Angiokeratoma corporis diffusum	Cephalo-oculocutaneous-telangiectasia syndrome	Angiomatosis retinae et cerebelli syndrome
Autosomal dominant	Recessive trait (X chromosome)	Autosomal recessive	Autosomal dominant
Equal	Males tend to full syndrome: (1) angiokeratomas (2) extremity pain, (3) high blood pressure, (4) cardiomegaly, (5) albuminuria, (6) hypohidrosis	Equal	Equal
Childhood	Childhood	Childhood	Adult
Telangiectasia (skin and mucous membranes)*	1. Small clustered angiokeratomas (symmetric, mucosal, increased over bony prominences) 2. Palmar mottling	1. Telangiectasia (increased in sun-exposed areas)* 2. Inelasticity	1. Port wine stains in some; Most with no cutaneous lesions* 2. Café-au-lait spots
Angiomas in the brain or spinal cord with signs of localized tumor	1. Cerebral vascular accidents 2. Neuronal glycolipid deposition (peripheral neuritis)	1. Progressive cerebellar ataxia (voluntary movements)* 2. Ocular telangiectasia (spread from canthal fold)* 3. Peculiar eye movements (nystagmus, poor control)* 4. Retarded 5. Slow dysarthric speech 6. Decreased tendon reflexes	1. Cerebellar hemangioblastoma and cyst* 2. Spinal hemangioblastoma (rarely) 3. Retinal hemangiomas (tangle of vessels away from disk)*
1. Pulmonary arteriovenous anastomoses 2. Hemorrhage from lesions in the mouth, GI tract, GU tract, and associated anemia	1. Stooped posture 2. Slender limbs, thin, weak muscles 3. Dilated, tortuous conjunctival and retinal vessels 4. Varicose veins and stasis edema 5. Scant facial hair 6. Hypogonadism	1. Sinopulmonary infections* 2. Hypoplastic or absent thymus 3. Small spleen 4. Retarded growth 5. Malignancies (reticulum cell sarcoma, Hodgkin's disease, lymphosarcoma, gastric, carcinoma	1. Pheochromocytoma 2. Pancreatic cysts 3. Hepatic angiomas 4. Renal hypernephromas (20%) 5. Polycythema (erythropoietic substance from tumor)
None	1. Urinary glycolipids (ceramide trihexoside) 2. Slit lamp 3. Biopsy, renal or marrow (lipid deposits)	1. Diminished or absent IgA 2. Increased serum α-fetoprotein	1. Hemogram (polycythemia) 2. Urinalysis, excretory urograms 3. Skull x-ray, angiogram 4. Myelogram
Cautery of bleeding lesions	Symptomatic	1. Control infections 2. Plasma infusions (IgA) 3. Thymus transplant 4. Transfer factor	Supportive

ing the vascular malformation in our patient. Males slightly outnumber females in the cases reported. In most patients the neurologic problems occurred during childhood or adolescence. No inciting event except exercise has been reported. Although neurolgic problems in our patient did not begin suddenly after strenuous exercise, our patient was active in sports, and exercise may have played a role in the onset of his symptoms. Three modes of onset of the syndrome have been described: (1) a series of episodes of neurologic deficit separated by weeks or years, (2) the sudden onset of symptoms progressing to paralysis within hours, and (3) gradual onset of a progressive deficit such as occurred in our patient. The quiescent period is usually terminated by pain involving the area supplied by the involved segment of the spinal cord. Paraplegia and monoplegia are also frequent initial symptoms. Involvement of rectal and urethral sphincters is not common early, but it is usually present in the fully developed syndrome. The neurologic picture is that of an intraspinal tumor with a sharp sensory level, spastic paralysis, and decreased sensation to all stimuli. The results of a lumbar puncture are usually normal, but occasionally there will be evidence of spinal block, hemorrhage, and increased protein and cell counts. The vascular lesion is predominantly arteriovenous and intradural, with the alternate being a venous angioma. The skin lesions occur along the appropriate dermatome at the site of the spinal cord lesion and may be either flat lesions of the port wine stain type or papular and nodular angiomas. These angiomas do not tend to resolve spontaneously as do the usual capillary and cavernous hemangiomas of childhood. The angiomas are either asymptomatic or result in mechanical problems because of size or susceptibility to trauma. In those cases in which the vascular lesion is an arteriovenous malformation, limb hypertrophy may occur. Familial cases of Cobb syndrome have not been reported.[4]

The combination of cutaneous angiomas with neurologic disease results in a variety of unusual syndromes. Among these are the Sturge-Weber syndrome, Osler-Weber-Rendu disease, Fabry-Anderson disease, von Hippel-Lindau syndrome, and ataxia telangiectasia. The clinical features of these are summarized in the Table. Two additional rare neurocutaneous syndromes are the Bonnet-Dechaume-Blanc syndrome, characterized by a

telangiectatic facial nevus and retinal and intracranial angiomatosis predominantly around the thalamus and mesencephalon, and the Wyburn-Mason syndrome, consisting of an arteriovenous aneurysm of the midbrain, congenital anomalies of the retinal vessels of one side, and a telangiectatic nevus in the skin in the region of the affected eye.[2,25]

Cobb syndrome has much in common with Sturge-Weber syndrome. Kissel and Dureux point out, however, that the venous angioma of Sturge-Weber syndrome is characterized by a dense pial matting of small vessels and a peculiar calcification in the corresponding part of the brain. There is no counterpart in cutaneomeningospinal angiomatosis.[4] The pathogenesis of the neural deficit in Cobb syndrome is believed to be ischemia secondary to diversion of blood into the malformation. Intraspinal arteriovenous malformations without associated skin lesions are themselves somewhat rare. This lesion occurs in men four times as frequently as in women, and symptoms of spinal cord disease tend to appear in middle age or later. Inasmuch as there is no apparent difference between the spinal lesions in patients with or without associated skin nevi, it seems that these differences are more apparent than real. Too few cases of Cobb syndrome have been reported for accurate comparison.

Treatment as well as diagnosis may be aided by the selective spinal angiography.[4,24,26] Angiomas fed by the posterior spinal artery often are juxtamedullary and can be extirpated surgically without appreciable damage to the spinal cord. Those fed by the anterior spinal artery are often intramedullary. This artery supplies critical motor pathways and neurons, which makes its removal impossible with current techniques.

On reviewing the reported cases of Cobb syndrome, we found various cutaneous vascular tumors described, ranging from angiolipomas to cavernous hemangiomas. Many of the earlier reports do not describe the skin lesions well and most lack histologic confirmation. However, a majority of patients appear to have had lesions of the port wine type; some had associated angiokeratomas. A characteristic feature of all types of lesions was a dermatomal distribution on the trunk or the extremities. If a port wine stain or multiple angiomas are found in this distribution, the diagnosis of Cobb syndrome should be seriously considered. Unfortunately, laboratory aids are limited in predicting the development of neurologic problems. Lateral thoracic and lumbar spine radiograms may show early bony erosion by the angioma.[7] Arteriography at present has too many risks to be a useful predictive tool and should be used for confirmation of diagnosis and evaluation before treatment.

The combination of a cutaneous angioma in a dermatomal distribution and spinal cord angioma comprises a rare, potentially crippling or fatal syndrome. We describe this young man with Cobb syndrome in the hope that increased awareness will result in more frequent recognition by dermatologists and other physicians. Perhaps early diagnosis and counseling regarding the adverse affect of strenuous exercise might prevent or delay the tragic neurologic effects.

References

1. Butterworth T: *Manual of Dermatologic Syndrome*, ed 2. Philadelphia, JB Lippincott Co, Second Edition, 1972.
2. Berenbruch K: *Ein Fall von multiplen Angio-lipomen kombiniert mit einem Angiom des Rückenmarkes*, inaugural dissertation, Tübingen, West Germany, 1890, p 24.
3. Cobb S: Haemangioma of the spinal cord associated with skin naevi of the same metamere. *Ann Surg* 62:641-649, 1915.
4. Kissel P, Dureux JB: Cobb syndrome: Cutaneomeningospinal angiomatosis, in Bruyn GW, Vinken PJ (eds): *Handbook of Clinical Neurology*. New York, North Holland Publishing Co, 1972, vol 14, pp 429-445.
5. Jackimowicz W, Sterling W: Venous dilation of spinal pia mater with intramedullary angiomatosis. *Neurol Pol* 19:391-408, 1936.
6. Johnston LM: Epidural hemangioma with compression of spinal cord. *JAMA* 110:119-122, 1938.
7. Karshner RG, Rand CW, Reeves DL: Epidural hemangioma associated with hemangioma of the vertebrae. *Arch Surg* 39:942-951, 1939.
8. Turner OA, Kernohan JW: Vascular malformations and vascular tumors involving the spinal cord. *Arch Neurol Psychiatr* 46:444-463, 1941.
9. Wyburn-Mason R: *The Vascular Abnormalities and Tumours of the Spinal Cord and Its Membranes*. London, H Kimpton, 1961.
10. Silverman S: Vascular tumours of the spinal cord associated with skin haemangiomata. *Br J Surg* 33:307-311, 1945.
11. Cross GO: Subarachnoid cervical angioma with cutaneous hemangioma of a corresponding metamere: Report of a case and review of the literature. *Arch Neurol Psychiatr* 58:359-366, 1947.
12. Francasso L: L'angiomatosi del midollo spinale. *Cervello* 23:81-112, 1947.
13. Trupp M, Sachs E: Vascular tumors of the brain and spinal cord and their treatment. *J Neurosurg* 5:354-371, 1948.
14. Louis-Bar D: Les rapports entre les angiomatoses du type Sturge-Weber et les autres dysplasies (formes de passage). *Acta Neurol Belg* 50:680-710, 1950.
15. Van Bogaert L: Pathologie des angiomatoses. *Acta Neurol Belg* 50:525-610, 1950.
16. Henson RA, Croft PB: Spontaneous spinal subarachnoid hemorrhage. *Quart J Med* 25:53-66, 1956.
17. Nielsen JM, Marvin SL, Seletz E: Telangiectasis of skin and spinal cord. *Bull Los Angeles Neurol Soc* 23:97-101, 1958.
18. Ginsbourg M, cited by Kissel P, Dureux JB: Cobb syndrome: Cutaneomeningospinal angiomatosis, in Bruyn GW, Vinken PJ (eds): *Handbook of Clinical Neurology*. New York, North Holland Publishing Co, 1972, vol 14, pp 429-445.
19. Fine RD: Angioma racemosum venosum of spinal cord with segmentally related angiomatous lesions of skin and forearm. *J Neurosurg* 18:546-550, 1961.
20. Hurth M, cited by Kissel P, Dureux JB: Cobb syndrome: Cutaneomeningospinal angiomatosis, in Bruyn GW, Vinken PJ (eds): *Handbook of Clinical Neurology*. New York, North Holland Publishing Co, 1972, vol 14, pp 429-445.
21. De Seze S, Hurth M, Djindjian R, et al: A propos d'un cas d'angiomatose metamerique cutaneo-vertebro-medulaire. *Rev Rhum* 33:455-460, 1966.
22. Hurth M, Djindjian R, Houdart R: L'exerese complète des anevrysmes arterioveineux de la moelle epiniere: Intérêt de l'artériographie medullaire selective: A propos de 11 cas. *Neurochirurgie* 14:499-514, 1968.
23. Szojchet A: Metameric spinal cord and skin hemangiomas: Case report. *J Neurosurg* 29:199-201, 1968.
24. Doppman JL, Wirth FP, Di Chiro G, et al: Value of cutaneous angiomas in the arteriographic localization of spinal-cord arteriovenous malformations. *N Engl J Med* 281:1440-1444, 1969.
25. Rook A: Naevi and other developmental defects, in Rook A, Wilkinson DS, Ebling FJG (eds): *Textbook of Dermatology*. ed 2. Oxford, England, Blackwell Scientific Publications, 1972, pp 144-147.
26. Dilenge D, Heon M, Metzger J: Selective spinal angiography in multiple CNS lesions. *J Assoc Can Radiol* 24:178-183, 1973.
27. Allen HB, Parlette HL: Coats disease. *Arch Dermatol* 108:413-415, 1973.
28. Archard HO: Stomatologic manifestations of internal and integumental disorders, in Fitzpatrick TB, Arndt KA, Clark WH, et al (eds): *Dermatology in General Medicine*. New York, McGraw-Hill Book Co, Inc, 1970.
29. Shah SS, Doshi HV, Shah DP, et al: Sturge-Weber syndrome. *J Indian Med* 62:352-354, 1974.
30. Rasmussen T, Mathieson G, Le Blanc F: Surgical therapy of typical and a forme fruste variety of the Sturge-Weber syndrome. *Arch Suisse Neurochir Psychiatr* 3(pt 2):393-409, 1972.
31. Masters R, Herskovic T: Cutaneous manifestations of disorders of the alimentary tract, in Fitzpatrick TB, Arndt KA, Clark WH, et al (eds): *Dermatology in General Medicine*. New York, McGraw-Hill Book Co, Inc, 1970, pp 1368-1369.
32. Frost P, Spaeth G: Glycolipid lipidosis: Fabry's disease (angiokeratoma corporis diffusum universale), in Fitzpatrick TB, Arndt KA, Clark WH, et al (eds): *Dermatology in General Medicine*. New York, McGraw-Hill Book Co, Inc, 1970, pp 1193-1202.
33. McFarlin DE, Strober W, Waldmann TA: Ataxia-telangiectasia. *Medicine* 51:281-314, 1972.
34. Tadjoedin MK, Fraser FC: Heredity of ataxia-telangiectasia (Louis-Bar syndrome). *Am J Dis Child* 110:64-68, 1965.
35. Truman JT, Richardson EP, Dvorak HF: Young man with telangiectasia, glaucoma, and peripheral lymphadenopathy. *N Engl J Med* 292:1231-1237, 1975.
36. Melmon KL, Rosen SW: Lindau's disease: Review of the literature and study of a large kindred. *Am J Med* 36:595-617, 1964.
37. Christoferson LA, Gustafson MA, Petersen AG: Von Hippel-Lindau's disease. *JAMA* 178:280-282, 1961.

Diffuse Eosinophilic Fasciitis

A New Syndrome or Variant of Scleroderma?

Victor M. Torres, MD, William M. George, MD

• Recently, attention has been drawn to a scleroderma-like illness, characterized by transient eosinophilia, which is commonly antedated by unusual physical exertion, is apparently free from significant systemic changes, and in which the primary pathological alterations, consisting of intense inflammation and thickening with or without eosinophils, occur initially in the fascia, not the skin. These patients are said to respond well to oral corticosteroids and an occasional one may undergo spontaneous resolution. Clinicopathologic study of a patient with this syndrome, suggests an even deeper tissue genesis than that recently proposed for some of the cutaneoindurative disorders. Eosinophilic fasciitis probably represents an impressive, but perhaps relatively benign variant of diffuse scleroderma, according to reported cases.

(*Arch Dermatol* 113:1591-1593, 1977)

A middle-aged muscular man had a baffling indurative process and was presented at the March 1975 monthly conference of the Department of Dermatology, University of Miami School of Medicine. The clinical picture did not conform to the usual manifestations of cutaneous hardening, such as seen in scleroderma, scleredema, and other known connective tissue disorders. The histologic picture of the initial skin biopsy did not show notable pathologic changes in the dermis or subcutaneous tissue, but a fragment of fascia revealed inflammatory changes almost identical to those described by Shulman[1] in a strikingly similar disorder affecting two male patients. Other patients apparently suffering from the same condition have been reported by rheumatologists.[2,3] The distinctive clinicopathologic picture presented by this patient, which, though differing from diffuse scleroderma, shares with it certain important, probably basic, features, prompts this report.

REPORT OF A CASE

A 57-year-old man, who had always been in good general health and had not suffered antecedent trauma, saw his physician in March 1975, because of "hives" for one month, hardness of the skin, and "stiffening of his muscles," mostly those of the extremities, of six weeks' duration. The stiffness was fairly persistent but became more noticeable when playing tennis. Aside from this, there had not been any unaccustomed exertion. There was no suggestion of Raynaud's phenomenon, muscle weakness, or visceral symptomatological condition. His family history disclosed that one brother died at the age of 12 of diabetic complications. The patient was originally treated with small doses of prednisone daily for a few weeks, which made the hives disappear, but the stiffness and skin hardening persisted.

The examination on March 27, 1975, showed a muscular, dark-complexioned man with visible irregularities in skin contour, characterized by depressions and ridges most apparent on the anteromedial aspects of the arms and thighs (Fig 1). The integument in these areas, although smooth and unaccompanied by significant color changes, felt firm and irregularly nodular, and the tissues appeared tight and bound down. Tightness was also felt all around the arms and thighs, down to and including the knees, and almost throughout the trunk, but the latter presented a smooth, regular surface. The distal portion of the extremities was practically uninvolved, and the face appeared normal. There was limitation of motion of the shoulder girdles with notable wincing on abduction.

The laboratory tests revealed the following values: hemoglobin, 13.5 gm/100 ml; hematocrit, of 39.3%; RBC 4,620,000/cu mm; 2nd WBC, 8,400/cu mm, with a differential cell count of 63% neutrophils, 34% lymphocytes, 2% eosinophils, and 1% monocytes. Values for urinalysis, VDRL, tetratriiodothyronine, latex fixation, roentgenogram of the chest, ECG, and 12-factor automated blood chemical analysis were within normal limits or nonreactive, with a nonfasting glucose level of 55 mg/100 ml. The serum protein electrophoresis showed the following values in gm/100 ml: albumin, 3.4 (normal 3.5 to 5.0); α 1, 0.5 (normal 0.1 to 0.4); α 2, 1.0 (normal 0.5 to 1.1); β, 1.3 (normal 0.6 to 1.2); and γ globulin, 1.7 (normal 0.5 to 1.5); the sedimentation rate (Westergren) was 48 mm/hr (normal 15 to 20); and fluorescent antinuclear factor was positive 1:16 (homogeneous pattern).

HISTOPATHOLOGICAL FINDINGS

The following is a composite picture of two biopsies done on the left biceps area. In the hematoxylin-eosin stained sections, the epidermis showed no significant changes aside from slight effacement of the rete

Fig 1.—Surface irregularities of skin that was nodular and tight (right arm).

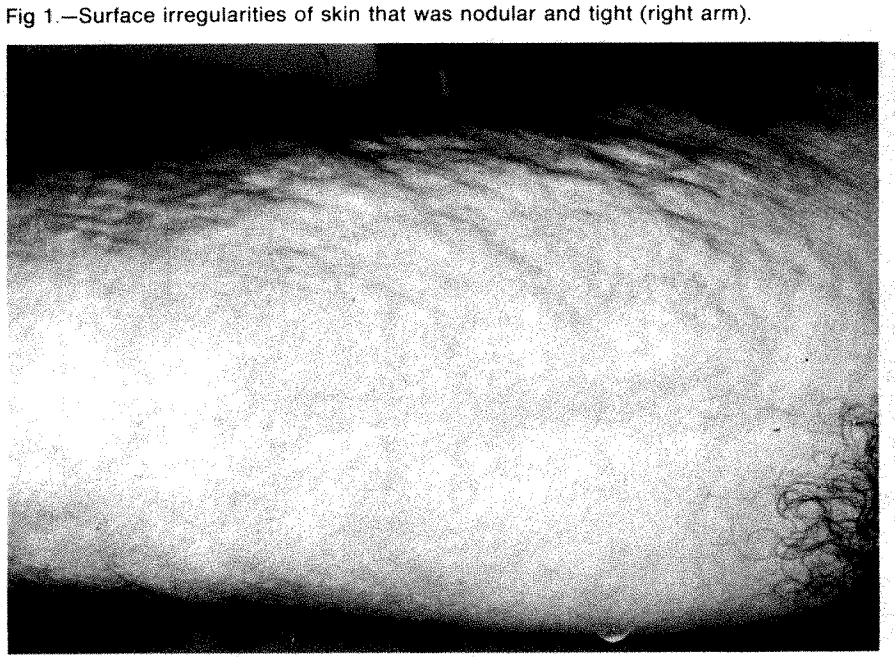

Accepted for publication Sept 10, 1976.

From the Departments of Dermatology (Drs Torres and George) and Pathology (Dr Torres), University of Miami (Fla) School of Medicine. Dr Torres is now with the University Hospital, Rio Piedras, Puerto Rico.

Reprint requests to Department of Dermatology, University (District) Hospital, Caparra Heights Station, Rio Piedras, Puerto Rico 00935 (Dr Torres).

ridges. The pilosebaceous structures, sweat glands, and dermal connective tissue appeared normal. Minimal collections of lymphocytes with an admixture of histiocytes were seen around occasional deep dermal vessels. The adipose tissue did not show appreciable changes but a fibrous septum separating deeply located fat lobules was thicker and appeared paler staining and more homogeneous and "hyaline" than the dermal connective tissue (Fig 2). Its collagen showed practically no birefringence in polarized light as compared to that of the dermis. The alcian blue stain revealed an increase in positive-staining mucopolysaccharide material and the elastic stain (Verhoeff-van Gieson) diminished, thin, delicately wavy and curled elastic fibrils (Fig 3) in this hyalinized area, both stains showing normal changes in the dermis. The stain for elastic also showed some delicate wavy fibrils and finely fragmented, almost granular, clumped material in the deeper fascial region. A scattering of small mononuclear cells and a few histiocytes and fibroblasts were present in the less compact stroma of the deep hypodermis and around one or two neighboring vessels, but inflammatory cells became more abundant in the loose connective tissue stroma of the fascia among markedly thickened collagen bundles. Lymphocytes and eosinophils were predominant, accompanied by lesser numbers of histiocytes and rare neutrophils. In some areas, the infiltrate was almost exclusively lymphocytic, but in most, eosinophils were found (Fig 4). This became more apparent with the Giemsa-Wright stain. The cellular collections were not dense and showed no tendency to form lymphoid follicular aggregates. A fragment of muscle included in the biopsy appeared normal. The vessels did not show any significant changes. Masson's trichrome, PAS, and reticulum (Gordon and Sweet) stains did not depict any appreciable abnormalities.

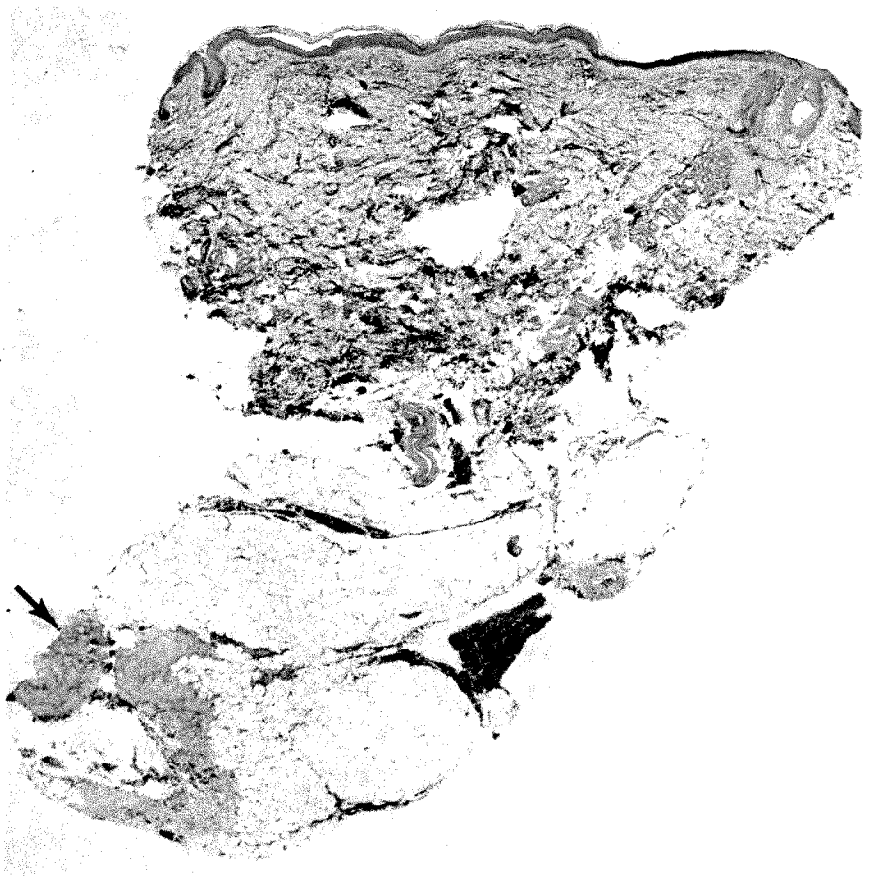

Fig 2.—Skin biopsy specimen, left arm. Thick, pale-staining, deep hyalinized interlobular septum (arrow); relatively normal skin otherwise (hematoxylin-eosin, original magnification ×11).

COURSE

The patient was treated with prednisone, 10 mg twice daily, and after nearly five months (last seen on Aug 28, 1975), he felt considerably happier and could move his arms with hardly any difficulty, but the objective findings of his skin had not undergone notable change.

COMMENT

When observed originally, it was

Fig 3.—Elastic fibers in deep hyalinized septum are diminished, thin, delicately wavy, and curled (Verhoeff-van Gieson, original magnification ×290).

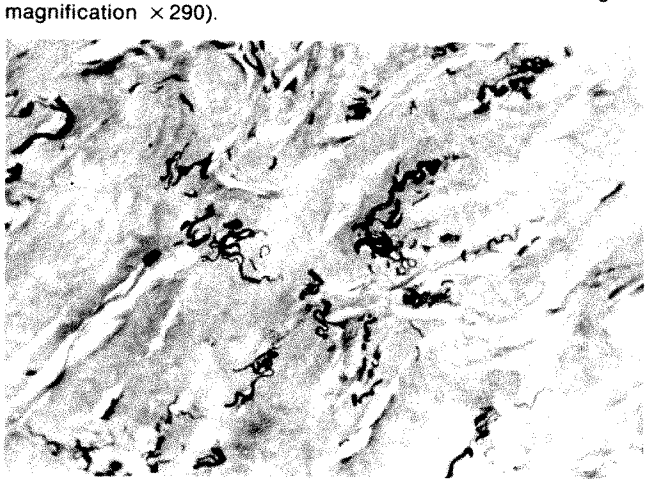

Fig 4.—Cellular infiltrate in loose stroma of fascia. Lymphocytes predominate, but eosinophils are also present (hematoxylin-eosin, original magnification ×267).

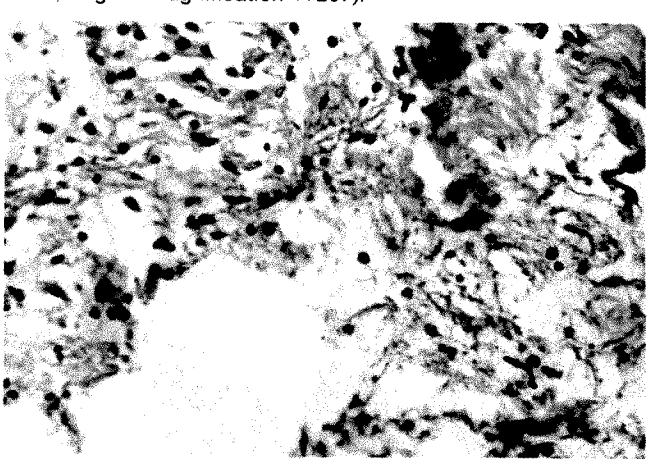

apparent that this patient's clinical manifestations did not conform to any of the known connective tissue disorders, mucinoses, or panniculitides. The symmetrical, irregular, firm nodularities of the proximal aspect of the extremities and the lack of involvement of the face, hands, and feet in an otherwise relatively asymptomatic patient did not resemble any of the usual expressions of generalized morphea, acrosclerosis, or progressive systemic sclerosis.[4-8] The superficially smooth but hard and bound down skin of the trunk suggested scleredema, but this, as well as scleromyxedema, which on clinical grounds was not strongly entertained, was eliminated by the normal acid mucopolysaccharide content of the dermis.[4] A faint clinical resemblance to an involuting, but surely atypical panniculitis was discarded by the paucity of findings in the patient's adipose tissue. The deep septal thickening, vaguely reminiscent of an erythema nodosum-like resolving septitis, could certainly not support that diagnosis in view of the bizarre clinical picture. The hyalinized septum, however, was the clue to the problem. The patient's changes, surmised clinically, pointed to diffuse involvement of the connective tissue that bound the skin and panniculus adiposus to the underlying muscles, ie, the fascia. This was confirmed by the study of the deeper tissues obtained during the first biopsy: the fascia showed a definite inflammatory process and thickening.

Shulman[1] recently described two male patients, one 53, another 19 years old, without myositis or the visceral manifestations of systemic sclerosis, who had "a diffuse scleroderma-like illness with firm, taut skin bound down to the underlying structures (sparing the face in both patients and hands and feet in one) the onset of which was antedated by unusual physical exertion." These patients had flexion contractures of elbows and knees and limitation of abduction at the shoulders, blood eosinophilia, elevated sedimentation rate, and hypergammaglobulinemia. The bone marrow showed plasmacytosis and eosinophilia, and the biopsies revealed striking thickening of the fascia between the subcutis and muscle, with intense infiltration with plasma cells and lymphocytes, but eosinophils were absent. There was no histologic evidence of scleroderma or myositis. One of the patients underwent a full remission after prednisone therapy for 15 months, but in the other, more severely involved, the clinical improvement had been minimal, even though reversal of laboratory abnormalities had occurred. Shulman's name for the condition was "diffuse fasciitis with hypergammaglobulinemia and eosinophilia" but this has already been simplified to "diffuse eosinophilic fasciitis."[3] It has also been stated that other patients have responded well to prednisone, and one who received no medication recovered spontaneously.[3]

Our patient fulfills the criteria for Shulman's concepts. The minor deviations, also noted in subsequent reports,[2,3] fall within the variations expected in a complex process, and rather than clouding it, probably serve to place it in its proper perspective. This patient, for example, showed tissue rather than blood eosinophilia and a slight instead of a marked increased in γ-globulins, suggesting a different, perhaps earlier, transitory stage of development.

There is no doubt that inflammation of subhypodermal connective tissue is fundamental in Shulman's and similar cases. Therefore, the distinctive pathologic alterations in a portion of interlobular connective tissue in the hypodermis of our case acquires great significance in understanding the pathogenesis of the process. This hyalinized tissue exhibits almost identically, the changes found by Fleischmajer et al[7,8] in the subcutaneous areas in cases of systemic scleroderma and generalized morphea, viz, hyalinized, pale-staining connective tissue with diminished, newly synthesized elastic fibrils. Since their studies indicated that dermal connective tissue was initially relatively unaffected, these authors conclude that the replacement of the panniculus by connective tissue is most likely the primary factor responsible for the skin induration in scleroderma and that it is likely that panniculitis may be a prominent feature during the early stages of this disease. This patient (and possibly Shulman's and other similar ones) indicates that, indeed, an even deeper inflammatory reaction, ie, a fasciitis, could be the earliest observable event in at least some members of the group of cutaneoindurative disorders.

Immunoglobulin abnormalities and antinuclear antibodies, whether significant or not, as well as possibly latent diabetes and hyperinsulinism, all seen in this patient to a minor degree, have also been reported in systemic scleroderma.[6,9,10,11]

Rodnan has been quoted as saying, "Although newly recognized, the condition is not new... patients with eosinophilic fasciitis have probably been thought to have scleroderma, or scleredema, in the past" (*Skin and Allergy News*, Aug 1975). Perhaps, eosinophilic fasciitis is a relatively benign, albeit impressive, variant of diffuse sclerosis. It has been emphasized that the condition does not progress to systemic sclerosis and that the patients' outlook for recovery is very good. This alone, added to the realization that deep biopsy specimens are essential, marks Shulman's contribution as a significant advance in our understanding and evaluation of these processes. Our patient's euphoric response when told that he was not suffering from progressive scleroderma reminded the senior author of another patient seen almost 20 years ago, a similarly labelled 31-year-old woman, who was "born again" when told that her diagnosis was, instead, atrophoderma of Pasini and Pierini, an entirely benign process.[12]

References

1. Shulman L: Diffuse fasciitis with hypergammaglobulinemia and eosinophilia: A new syndrome? *J Rheum* 1:46, 1974.
2. Caperton EM, Hathaway DE: Scleroderma with eosinophilia and hypergammaglobulinemia: The Shulman syndrome. *Arthritis Rheum* 18:391, 1975.
3. Rodnan GP, Di Bartolomeo AG, Medsger, TA et al: Eosinophilic fasciitis: Report of seven cases of a newly recognized scleroderma-like syndrome. *Arthritis Rheum* 18:422-423, 1975.
4. Jablonska S: *Scleroderma and Pseudoscleroderma.* Department of Commerce Clearing House for Federal Scientific and Technical Information, Springfield, Va, 1965.
5. Talbott JH: *Collagen-Vascular Diseases.* New York, Grune & Stratton, 1974.
6. Sackner MA: *Scleroderma.* New York, Grune & Stratton, 1966.
7. Fleischmajer R, Damiano V, Nedwich A: The alteration of the subcutaneous tissue in systemic scleroderma. *Arch Dermatol* 105:59-66, 1972.
8. Fleischmajer R, Nedwich A: Generalized morphea: I. Histology of the dermis and subcutaneous tissue. *Arch Dermatol* 106:509-514, 1972.
9. Rothfield NR, Rodnan GP: Serum antinuclear antibodies in progressive systemic sclerosis (scleroderma). *Arthritis Rheum* 11:607-617, 1968.
10. Jordan RE, Deheer D, Schroeter A, et al: Antinuclear antibodies: Their significance in scleroderma. *Mayo Clin Proc* 46:111-113, 1971.
11. Fleischmajer R, Faludi G: A study of carbohydrate metabolism in scleroderma. *J Invest Dermatol* 52:326-328, 1969.
12. Canizares O, Sachs PM, Jaimovich L, et al: Idiopathic atrophoderma of Pasini and Pierini. *Arch Dermatol* 77:42-60, 1958.

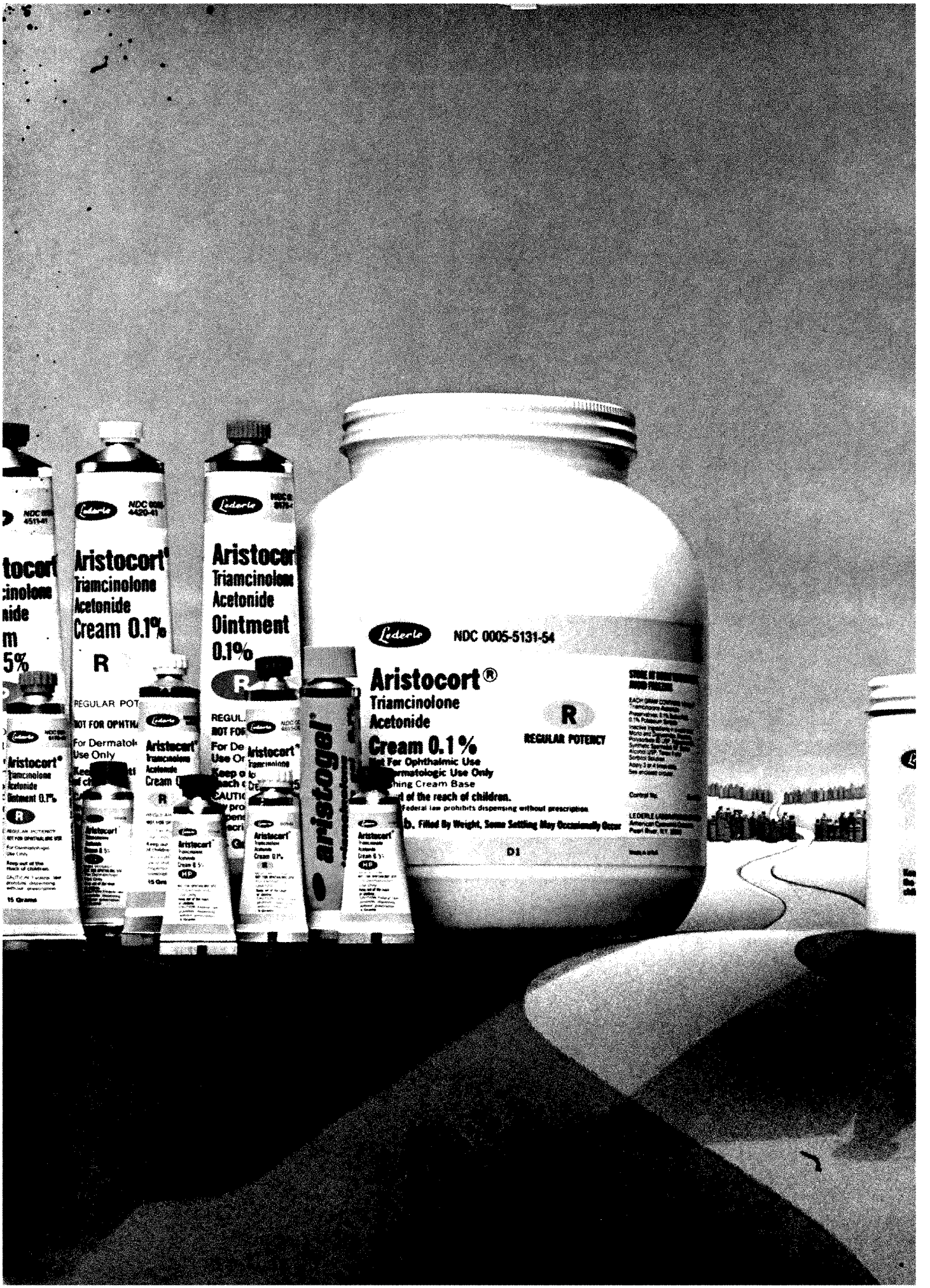
Lederle
NDC 0005-5131-54
Aristocort®
Triamcinolone
Acetonide
Cream 0.1%
R
REGULAR POTENCY
Aristocort
Triamcinolone
Acetonide
Cream 0.1%
R
Aristocort
Triamcinolone
Acetonide
Ointment
0.1%
R
Aristocort
Triamcinolone
Acetonide
Cream 0.1%
R
aristogel

Stop at our place

before you go to more expensive topical steroids

Aristocort®

Triamcinolone Acetonide

Effective initial therapy in a wide range of steroid-responsive dermatoses.

Clinical efficacy proven again and again over almost 20 years of clinical use—a standard among fluorinated topicals.

One of the most *economical* topical steroids available—in forms, strengths and sizes for every susceptible steroid-responsive problem (large-size tubes and jars lower treatment costs even more for patients with chronic or widespread conditions...free trial samples available, too).

The *first* triamcinolone preparation to remove common sensitizers—contains no parabens, phenol preservatives, lanolin.

Indications: For relief of inflammatory manifestations of corticosteroid-responsive dermatoses.

Contraindications: Viral skin diseases, such as varicella and vaccinia; hypersensitivity to any component (not for ophthalmic use); when circulation is markedly impaired.

Warnings: Safety of use in pregnancy has not been absolutely established. Do not use extensively, in large amounts, or for prolonged periods of time in pregnant patients.

Precautions: If irritation develops, discontinue use and institute appropriate therapy. In infections, use appropriate antifungal or antibacterial agents; if a favorable response does not occur promptly, discontinue the corticosteroid until the infection is adequately controlled. If extensive areas are treated or the occlusive technique is used, increased systemic absorption of the corticosteroid may occur; take suitable precautions.

Adverse Reactions: (local) Burning sensations, itching, irritation, dryness, folliculitis, secondary infection, skin atrophy, striae, hypertrichosis, acneform eruption and hypopigmentation.

Supplied: Cream 0.5%—Per Gm.: triamcinolone acetonide 5 mg., sorbic acid 0.1% and potassium sorbate 0.1% as preservatives; *Cream 0.1%*—Per Gm.: triamcinolone acetonide 1 mg., sorbic acid 0.1% and potassium sorbate 0.1% as preservatives; *Cream 0.25%*—Per Gm.: triamcinolone acetonide 0.25 mg., sorbic acid 0.1% and potassium sorbate 0.1% as preservatives; all potencies are in a water base of mono and diglycerides, squalane, polysorbate 80 USP, polysorbate 60, cetyl esters wax NF, stearyl alcohol USP, Tenox II, and sorbitol solution USP. *Ointment 0.5%*—Per Gm.: triamcinolone acetonide 5 mg.; inactive ingredient: white petrolatum; *Ointment 0.1%*—Per Gm.: triamcinolone acetonide 1 mg.; inactive ingredient: white petrolatum. *ARISTOGEL® Gel 0.1%*—Per Gm.: triamcinolone acetonide 1 mg., 1.8% benzyl alcohol as preservative, inactive ingredients in a water base: polysorbate 80 USP, polyoxyethylene (20) cetyl ether, glycerin USP, and citric acid USP. 004-7

Lederle

Lederle Laboratories
A Division of American Cyanamid Company, Pearl River, New York 10965

Obviously, efficacy is foremost in your mind when you recommend a therapeutic shampoo. And efficacy, coupled with cosmetic acceptability, usually guarantees a successful therapeutic course.

That's why Head & Shoulders is so highly regarded in the treatment of dandruff.

Clinically effective

For years, Head & Shoulders has proved effective in the treatment of dandruff—whether for initial therapy or long-term control. And now, research shows that Head & Shoulders is effective in the treatment of seborrheic dermatitis.*

Cosmetically pleasing

Head & Shoulders lathers well, has a pleasant odor and appearance, and need not be left on the scalp for an extended period of time. Also, it leaves hair clean, manageable, and attractive.

Head & Shoulders®

You'll like it for its therapeutic benefits. Your patients will like it for its cosmetic appeal.

*Orentreich, N.: A clinical evaluation of two shampoos in the treatment of seborrheic dermatitis, J. Soc. Cosmet. Chem. 23:189 (March 3) 1972.

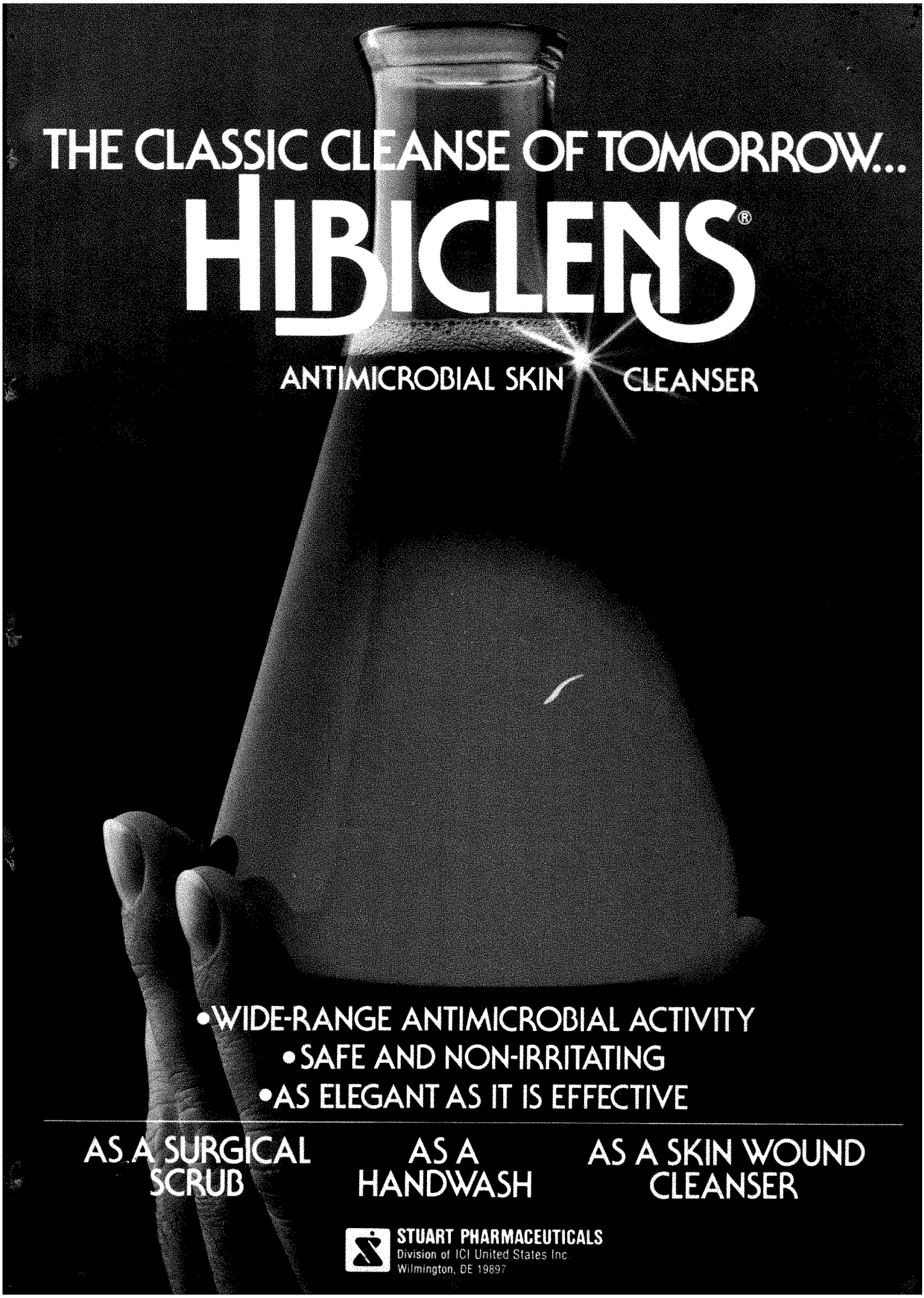
THE CLASSIC CLEANSE OF TOMORROW...
HIBICLENS®
ANTIMICROBIAL SKIN CLEANSER
•WIDE-RANGE ANTIMICROBIAL ACTIVITY
•SAFE AND NON-IRRITATING
•AS ELEGANT AS IT IS EFFECTIVE
AS A SURGICAL SCRUB
AS A HANDWASH
AS A SKIN WOUND CLEANSER
STUART PHARMACEUTICALS
Division of ICI United States Inc
Wilmington, DE 19897

Benign Mucous Membrane Pemphigoid

Response to Therapy With Cyclophosphamide

Harold J. Brody, MD, Donald J. Pirozzi, MD

Benign mucous membrane pemphigoid, also called cicatricial pemphigoid, is a chronic vesiculobullous disease of the mucosa and skin that results in permanent scarring of the affected areas, often causing blindness. Reports of treatment for this disorder have been scanty and quite variable in presentation. To our knowledge, this is the first case report of an initially recalcitrant patient treated successfully with cyclophosphamide.

Report of a Case

A 49-year-old man was in good health until June 1975 when he noted injection of the right conjunctiva accompanied by photophobia. The diagnosis was staphylococcal keratoconjunctivitis, and he was treated accordingly with antibiotics and topical steroid combinations with minimal response and progression to the left eye in September of 1975. Several months later an ulcer developed involving the right buccal mucosa. His vision was 20/20 in both eyes with correction, and examination OD revealed hyperemia of the lid margins and collarette formation. There was almost a pseudomembrane involving the inferior and superior tarsal conjunctiva with subepithelial cicatricial band formation inferiorly. Biopsy of a fleshy pedunculated vascularized mass at the limbus had been done in the past and pyogenic granuloma was the diagnosis. Examination OS showed similar conjunctival changes with early symblepharon (Fig 1). The patient was treated intensively with corticosteroid mixture (Predneferin) and gentamicin sulfate ophthalmic drops, his condition was diagnosed as probable benign mucous membrane pemphigoid, and he was admitted to the Dermatology Service of Emory (Atlanta) University Hospital.

On admission in January 1976, the patient was complaining of difficulty with swallowing secondary to ulcerations in his mouth. He noted increased photophobia and blurring of vision with considerably increased lacrimation. He denied anorexia, weight loss, or complaints relating to systemic illness. Physical examination revealed a well-nourished and anxious afebrile man in no acute distress. Scattered 2- to 3-mm ulcerations were present in the mouth, nasopharynx, hypopharynx, pharynx, larynx, and nose (Fig 2). Eye examination was unchanged. Results from the remainder of the physical examination were within normal limits.

Esophagoscopy revealed the entire upper half of the esophagus to be studded with small ulcerations. Proctoscopy to 22 cm revealed no mucosal disease. Findings for chest roentgenogram, complete blood cell count, urinalysis, anti-nuclear antibody, ECG, VDRL, SGOT, lactic dehydrogenase, bilirubin, cholesterol, uric acid, total protein, albumin, calcium, and phosphorus were all within normal limits. A slightly elevated alkaline phosphatase level of 114 mU/ml (normal, 20 to 85 mU/ml) was present.

Conjunctival biopsy was performed that revealed hyperemic tissue with superficial nonspecific inflammation and almost total erosion of the surface epithelium. A biopsy specimen of buccal mucosal ulceration was consistent with mucosal pemphigoid. Cultures of the conjunctiva and lid margin grew *Staphylococcus aureus* and *epidermidis*. Serum was negative for circulating antibodies to the skin by indirect immunofluorescence, and a conjunctiva specimen was negative for direct immunofluorescence.

The patient was begun on a regimen of triamcinolone acetonide 60 mg daily, with marginal improvement in visual blurring after one week. Therapy was changed to prednisone 80 mg daily and he was discharged. One month later, his eyes seemed to be worse, with persistent oral lesions; azathioprine 100 mg daily was added to his treatment plan and triamcinolone in orobase was used symptomatically for oral ulcerations. The following month, betamethazone 7.2 mg daily was substituted for prednisone without success. The patient now had a 9-kg weight gain, was noticeably cushingoid, was still incurring new oral ulcerations, and was bilaterally losing his vision. His azathioprine therapy was discontinued and he was begun on a regimen of cyclophosphamide 50 mg twice daily. This dosage was gradually raised to 200 mg daily during the next month, with healing of oral ulcerations and improvement in visual acuity. His corticosteroid therapy was changed again to prednisone and tapered to a dose of 20 mg every other day over the next six months with considerable resolution of his disease. Eight months after the onset of therapy with cyclophosphamide, the patient was largely clear of lesions and corticosteroid therapy was tapered off, with a maintenance

From the Department of Dermatology, Emory University School of Medicine, Atlanta.

Presented in part at the Gross and Microscopic Section, American Academy of Dermatology, 1976.

Reprint requests to Department of Medicine (Dermatology), Emory University School of Medicine, Grady Memorial Hospital, Atlanta, GA 30303 (Dr Brody).

Fig 1.—Initial presentation showing severe bilateral conjunctivitis.

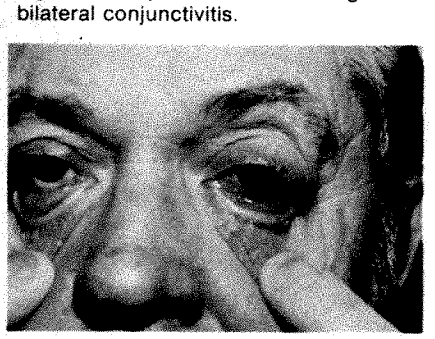

Fig 2.—Initial presentation of oral mucosa showing 2- to 3-mm ulcerations.

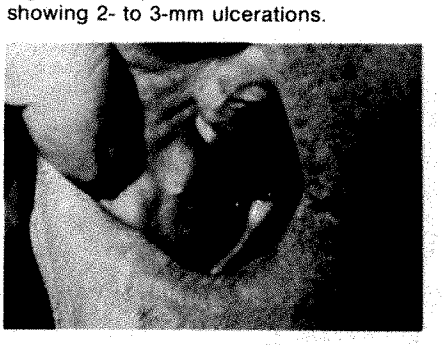

Fig 3.—Improvement of both eyes after treatment.

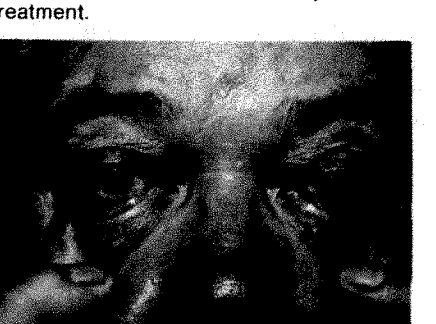

therapy of only 200 mg of cyclophosphamide daily (Fig 3).

COMMENT

Therapy in mucosal pemphigoid has been erratic in the past from the standpoint of consistency in improvement. Unfortunately, the steroids that are often helpful in bullous pemphigoid of the skin are not necessarily the drug of choice in cicatricial pemphigoid. Hardy et al[1] found that the equivalent of 40 mg of prednisone per day was necessary to retard or arrest the disease, triamcinolone being the most effective drug. The fluorinated corticosteroids are known to have a more rapid anti-inflammatory effect and also are associated with a greater degree of adrenal suppression. In the 81 patients in their series, 21 became blind, 17 in both eyes, and one patient died from the side effects of corticosteroid therapy. Though triamcinolone was more effective in this series, there were only five patients in the series treated with this steroid, and the impression of superiority was derived from improvement in four of these five patients. Herron[2] encountered success in his study using 80 mg of triamcinolone daily and tapering to 40 mg every other day during a two-month interval. It seems generally accepted that topical steroids do little to prevent shrinkage and symblepharon formation.

Immunosuppressive therapy in the form of azathioprine has been successful, especially in combination with prednisone.[3] Greatest benefit is reported with doses of 100 to 200 mg/day of azathioprine with steroids in a series of four patients. Visual impairment was arrested and oral ulceration minimized, thus improving the prognosis.

Cyclophosphamide[4] is a synthetic drug related to the nitrogen mustards that has been used chiefly for its immunosuppressive action by interfering with the cross-linking of DNA. Presumably metabolized in the liver, it may be associated with alopecia, mucosal loss, hemorrhagic cystitis, and myelosuppression. Used in much higher doses for lymphoma, multiple myeloma, leukemia, mycosis fungoides, and certain solid malignant neoplasms, WBC counts and serum hemoglobins are indicated on a regular basis during therapy with the drug.

To our knowledge, this is the first report of a successful trial of cyclophosphamide in controlling benign mucous membrane pemphigoid. Since its action is immunosuppressive and not anti-inflammatory, it supports an autoimmune etiology of the disease. Our patient did not have autoantibodies on immunofluorescence, although they have been reported inconsistently in the past.[5,6] It is significant that the addition of this agent enabled tapering of the corticosteroid dosage and elimination of the side effects of hypercortisolism.

Schering Pharmaceuticals provided funds for color reproductions.

Nonproprietary Names and Trademarks of Drugs

Cyclophosphamide—*Cytoxan.*
Azathioprine—*Imuran.*

References

1. Hardy KM, Perry HO, Pingree GC, et al: Benign mucous membrane pemphigoid. *Arch Dermatol* 104:467-475, 1971.
2. Herron BE: Immunologic aspects of cicatricial pemphigoid. *Am J Ophthalmol* 79:271-278, 1975.
3. Dave VK, Vickers CFH: Azathioprine in the treatment of mucocutaneous pemphigoid. *Br J Dermatol* 90:183, 1974.
4. Dantzig PI: Immunosuppressive and cytotoxic drugs in dermatology. *Arch Dermatol* 110:393-406, 1974.
5. Tagami H, Imamura S: Benign mucous membrane pemphigoid: Demonstration of circulating and tissue-bound membrane antibodies. *Arch Dermatol* 109:711-713, 1974.
6. Cooperative Study: Uses for immunofluorescence tests of skin and sera: Utilization of immunofluorescence in the diagnosis of bullous diseases, lupus erythematosus, and certain other dermatoses. *Arch Dermatol* 111:371-381, 1975.

Serratia marcescens Cellulitis

Dean E. Brenner, MD, Donald P. Lookingbill, MD

During the last decade, *Serratia marcescens* has become an important bacterial pathogen in the debilitated patient. This organism has been shown to cause infections in most organ systems.[1] It has not, to our knowledge, been found as a cause of cellulitis in unbroken skin. We report a unique case of cellulitis developing in areas of unbroken skin in a patient with *S marcescens* bacteremia.

Report of a Case

A 51-year-old nondiabetic man was admitted for the third time to the Hershey (Penn) Medical Center with increasing dyspnea. He was admitted initially in 1970 with dyspnea, and in 1972 after cardiac catheterization, idiopathic cardiomyopathy was diagnosed. He was readmitted in July 1975 for increasingly severe congestive heart failure. Two days after heart catheterization a deep vein thrombophlebitis of the left calf developed. Following treatment with continuous infusion heparin sodium, continuous warm soaks, and leg elevation, the calf improved but purulent drainage from the left arm intravenous catheter site was noted. Initial blood and urine cultures proved negative.

Four days after catheterization, the patient became lethargic. At that time, a warm, indurated, erythematous, extremely tender lesion was noted to be advancing rapidly on the left lateral thigh at a rate of 6 mm/hr. The skin of the thigh was intact. A 4-mm punch biopsy specimen of the skin lesion was taken and then was homogenized, Gram stained, and cultured. No organisms were seen on Gram stain. Gram stain of the drainage from catheter sites revealed scattered Gram-negative rods that were interpreted as contaminants. Treatment with intravenous nafcillin sodium was begun; however, because of spiking temperatures, and a rising WBC count, gentamicin sulfate was added to the treatment regimen later the same night.

A gentamicin-sensitive, non-pigmented strain of *S marcescens* grew from cultures of the skin biopsy specimen, catheter site drainage, and blood. Despite vigorous, high-dose antibiotic treatment, the hip cellulitis slowly progressed to cover the entire leg, buttock, thigh, and scrotum. The patient became increasingly lethargic, hepatic and renal failure developed and he died on the ninth postcatheterization day. Permission for autopsy was denied.

Comment

This report presents a case of *Serratia* cellulitis arising in unbroken skin, at a site that is remote from the presumed portal of entry. In this case, the appearance of the cellulitis also served as the initial manifestation of an underlying *Serratia* bacteremia. We surmise that the infection, originating at the left arm catheter site, was blood borne to an ecchymosis in the left thigh of this anticoagulated patient. The infection then spread by continguity in the neighboring skin and subcutaneous tissues.

Patients with chronic congestive heart failure may be predisposed to having Gram-negative cellulitis devel-

From the Division of Dermatology, Department of Medicine, the Milton S. Hershey Medical Center of the Pennsylvania State University, Hershey.

Reprints not available.

op as a result of the chronic edema present in their skin and subcutaneous tissues.[3] Once infection is established, endotoxin produced from the Gram-negative bacilli causes thrombosis of the nutrient small vessels, with resultant ischemia and edema. This environment enhances bacterial pathogenicity and the spread of the cellulitis.[2,3]

Diagnosis of Gram-negative cellulitis may be difficult and it requires a high index of suspicion. Initially, it may occur as a relatively benign lesion of warmth, induration, and discoloration. The border is usually poorly defined and there may be minimal erythema. The cellulitis then spreads rapidly and can be associated with local erythema, induration, necrosis, and sometimes crepitance.[3] Systemically, initial elevation of the WBC count and indolent fever may be the only clues of the process. Later, signs and symptoms of septicemia can be expected to supervene.

To identify the causative organism, culture material is required. Blood cultures, of course, should always be drawn, but diagnosis from the skin is often a difficult task. Although bacteria have, in some instances, been recovered with saline injection and needle aspiration,[4] in our hands this procedure is often unrewarding. Tronca et al[5] showed that for septic gonococcemia pustules, homogenized skin punch biopsy material yielded positive cultures more often than did aspirated material. Likewise, culture of a skin biopsy specimen in suspected cellulitis infection, as was successfully done in this case, may prove to be a productive diagnostic maneuver.

Nonproprietary Name and Trademark of Drug

Gentamicin sulfate–*Garamycin.*

References

1. Wilfert JN, Bartlett FF, Kass EH: Bacteremia due to *Serratia marcescens*. *N Engl J Med* 279:286-289, 1968.
2. Weinberg AN, Swartz MN: Gram-negative coccal and bacillary infections, in Fitzpatrick TB (ed): *Dermatology in General Medicine*. New York, McGraw-Hill Book Co Inc, 1971, pp 1713-1727.
3. Culbertson WR: Acute nonclostridial crepitant cellulitis. *Arch Surg* 77:462-468, 1958.
4. Goetz JP, Tafari N, Boxerbaum B: Needle aspiration in *Hemophilus influenzae* type b cellulitis. *Pediatrics* 54:504-506, 1974.
5. Tronca E, Handsfield HH, Wiesner PJ, et al: Demonstration of *Neisseria* gonorrhea with fluorescent antibody in patients with disseminated gonococcal infection. *J Infect Dis* 129:583-586, 1974.

Tinea Capitis Due to *Trichophyton soudanense*

Donald R. Cox, MD, Fritz Blank, DSc Nat†

Trichophyton soudanense (Joyeux,[1] 1912) is a frequent cause of tinea capitis in certain regions of Africa. Infections of skin and nails are less frequent.[2] To our knowledge, this is the first published report of a scalp infection by this dermatophyte in the United States; however, two reports of tinea corporis have been published.[2,3]

Report of a Case

A 6-year-old, American girl who had never left the Philadelphia area developed four pruritic, round areas of alopecia in the occipital area of her scalp. The plaques were slightly elevated, scaly, dull red, and 1- to 4-cm in diameter. The follicles contained black dots that were broken hairs containing spores 6 to 7 μ in diameter. There were enlarged lymph nodes in the posterior cervical and postauricular areas. Inoculation of broken hairs on Sabouraud's glucose agar yielded a folded, yellow to dried apricot colony surrounded by submerged mycelium. Results of microscopical examination of this growth showed septate hyphae with reflexive branching and chains of arthrospores. The culture was therefore identified as *T soudanense.*

From the Skin and Cancer Hospital, Temple University Health Sciences Center, Philadelphia.

Reprint requests to 416 Balboa Ave, Stuart, FL 33494 (Dr Cox).

†Deceased.

The patient was treated with 250 mg of griseofulvin (Fulvicin U/F), microsize, twice daily with meals. The lesions were treated topically with clotrimazole (Lotrimin) cream (1%) twice daily. Her mother was asked to shampoo the scalp daily. After two months of therapy, inoculation of epidermal scalp scrapings yielded no growth on Sabouraud's glucose agar. Inflammation and scaling regressed, and there was a gradual regrowth of hair during the next nine months.

The patient's mother had two scaly red patches on her back. Epidermal scrapings from these lesions did not show any hyphae when examined microscopically, and there was no growth after inoculation of Sabouraud's glucose agar.

The patient had a friend born in Africa who had lived in the United States for four years. Unfortunately, permission was not granted to examine the friend and her family.

Comment

Travel has been responsible for the spread of *T soudanense* infections to countries outside of Africa. Cases have been reported in Europe.[4] Additional unreported cases have been found in the New York area. A Jamaican girl who had been living in New York for 4½ years had two lesions on the left thigh that had been present several months (personal communication with M. Silva-Hutner). Unpublished cases of scalp infections include a 4-year-old child born in New York (personal communication with I. Waitzman) and two American children who most probably had contact with African children (personal communication with S. A. Rosenthal).

The number of African visitors to the United States has doubled between 1967 and 1974.[5] It may be surprising that more infections have not been discovered since the last reported isolation by Johnson and Rosenthal in 1968.[3] The sometimes chronic and nearly asymptomatic clinical manifestations of *T soudanense* infection,[4] which can easily be confused with other dermatologic diseases, and the lack of proper facilities for identification of this dermatophyte[6] may explain the relatively small number of infections reported.

Nonproprietary Name and Trademark of Drug

Clotrimazole–*Lotrimin.*

References

1. Joyeux C: Sur le *Trichophyton soudanense*, n. sp., note préliminaire. *Compt rend Soc Biol* 73:15-16, 1912.
2. Rippon JW, Medenica M: Isolation of *Trichophyton soudanense* in the United States. *Sabouraudia* 3:301-302, 1964.
3. Johnson JA, Rosenthal SA: Superficial cutaneous infection with *Trichophyton soudanense*. *Arch Dermatol* 97:428-431, 1968.
4. Vanbreuseghem R: *Trichophyton soudanense* in and outside Africa. *Br J Dermatol* 80:140-148, 1968.
5. *1974 Annual Report: Immigration and Naturalization Service.* Washington, DC, US Dept of Justice, 1974.
6. Vanbreuseghem R: Contribution à l identification du *Trichophyton (Langeronia) soudanense*, et du *Trichophyton ferrugineum*. *Ann Soc Belg Med Trop* 43:259-269, 1963.

When either Benzoyl Peroxide or Retinoic Acid can't solve the puzzle of pustular acne...

Sulfacet-R®

(10% sodium sulfacetamide,
5% microsize sulfur)

PENETRATES into the skin to exert its antibacterial activity.

CONTROLS pustular stages of acne and seborrhea quickly, safely... without unsightly desquamation.

SAFETY RECORD..."in thousands of patients during the past two decades, not a single instance of sensitivity has been observed."*

PROVIDES instant **"Social Confidence"** with the exclusive Dermik Color Blender,™ customized tinting to match individual patient skin tones.

*Olansky S: Old drug in a new system revisited. Cutis 19:852-854, June, 1977

Dermik

Dermik Laboratories, Inc.
Fort Washington, Pa., U.S.A. 19034

SULFACET-R® LOTION

DESCRIPTION—Sulfacet-R® Acne Lotion contains (as dispensed) sodium sulfacetamide 10% and microsize sulfur 5% in a flesh-tinted lotion of purified water, alkyl aryl sulfonic acid salts, hydroxyethylcellulose, propylene glycol, xanthan gum, lauric myristic diethanolamide, polyoxyethylene laurate, cyclohexanediamine tetraacetic acid, butylparaben, methylparaben, silicone emulsion, talc, zinc oxide, titanium dioxide, attapulgite, iron oxides, pH buffers and 2-bromo-2-nitropropane-1, 3-diol.

ACTIONS—Provides keratolytic, peeling, drying and antiseborrheic action.

INDICATIONS—An aid in the treatment of acne vulgaris, acne rosacea and seborrheic dermatitis.

CONTRAINDICATIONS—This product is contraindicated for use by patients having known hypersensitivity to sulfonamides, sulfur or any other component of this preparation. Not to be used by patients with kidney disease.

PRECAUTIONS—For external use only. Keep away from eyes. If irritation develops, discontinue use and consult physician. Sensitivity to sodium sulfacetamide may occur. Therefore, caution and careful supervision should be observed when prescribing this drug for patients who may be prone to hypersensitivity to topical sulfonamides. Particular caution should be employed if areas of denuded or abraded skin are involved. Patients should be carefully observed for possible local irritation or sensitization during long term therapy. Occasionally, certain individuals may be sensitive to one or more components of this preparation. The object of this therapy is to achieve desquamation without irritation, but sodium sulfacetamide and sulfur can cause reddening and scaling of the epidermis. These side effects are not unusual in the treatment of acne vulgaris, but patients should be cautioned about the possibility. Keep out of the reach of children.

ADVERSE REACTIONS—Previous toxic reactions such as agranulocytosis, acute hemolytic anemia, purpura hemorrhagica, drug fever, jaundice and contact dermatitis indicates hypersensitivity to sulfonamides.

DIRECTIONS—Shake well before using. Apply a thin film 1 to 3 times daily with light massaging to blend in each application in accordance with the physician's directions. Each package contains a "Dermik Color Blender" which enables the patient to alter the basic shade of the lotion so that it matches the skin color exactly.

[Important to the Pharmacist—At the time of dispensing, add contents of vial* to the bottle. Shake well and/or stir with a glass rod to insure a uniform dispersion. Place expiration date of four (4) months on bottle label.]

*"Sulfa-Pak" vial contains 2.4 grams of sodium sulfacetamide.

HOW SUPPLIED—Bottle, 1 oz.

CAUTION—Federal law prohibits dispensing without prescription.

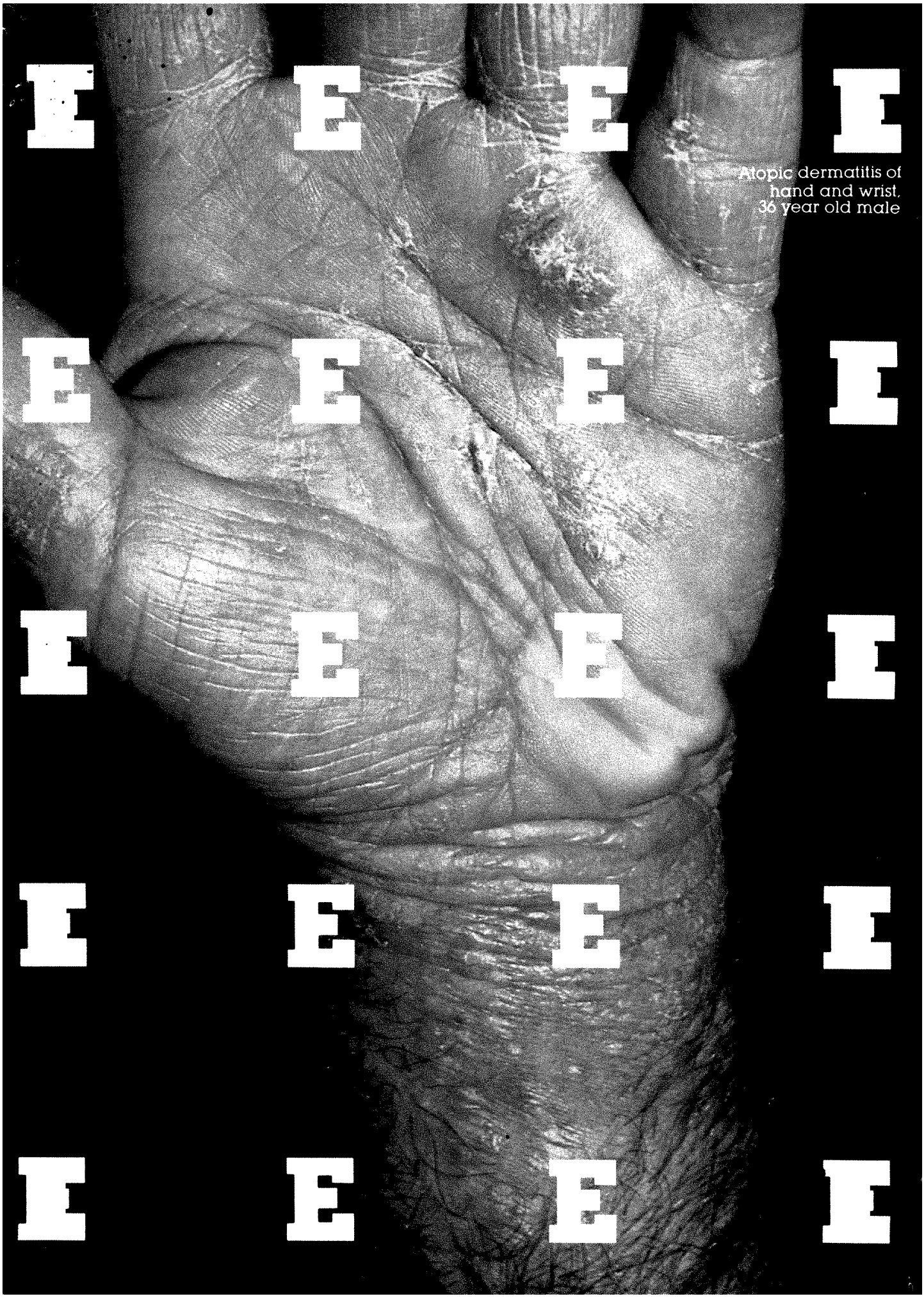
E E E E
E E E E
E E E E
E E E E
E E E E
Atopic dermatitis of
hand and wrist,
36 year old male

Added versatility in dermatology

new Lidex®-E (fluocinonide) 0.05%

The established potency of fluocinonide, in a soothing emollient base.

Less drying than a cream, with the lubricating qualities of an ointment–cosmetically acceptable to patients.

Especially useful wherever a soothing topical steroid is indicated, as in atopic dermatitis.

Available in 15g and 60g tubes.

SYNTEX

Please see following page for summary of prescribing information

new
Lide® E
(fluocinonide)
Cream 0.05%

Prescribing Information

Description LIDEX-E cream 0.05% contains the active compound fluocinonide. Fluocinonide, which is the 21-acetate ester of fluocinolone acetonide, has the chemical formula 6α, 9-difluoro-11β, 16α, 17, 21-tetrahydroxypregna-1, 4-diene-3, 20-dione, cyclic 16, 17-acetal with acetone, 21-acetate.

The cream contains fluocinonide 0.5 mg./g. in a water-washable aqueous emollient base of stearyl alcohol, cetyl alcohol, mineral oil, propylene glycol, sorbitan monostearate, polysorbate 60, citric acid and purified water.

Actions Topical steroids are primarily effective because of their anti-inflammatory, antipruritic and vasoconstrictive actions.

Indications For relief of the inflammatory manifestations of corticosteroid-responsive dermatoses.

Contraindications Topical steroids are contraindicated in vaccinia and varicella.

Topical steroids are contraindicated in those patients with a history of hypersensitivity to any of the components of the preparation.

Precautions If irritation develops, the cream should be discontinued and appropriate therapy instituted.

In the presence of an infection, the use of an appropriate antifungal or antibacterial agent should be instituted. If a favorable response does not occur promptly, the corticosteroid cream should be discontinued until the infection has been adequately controlled.

If extensive areas are treated, the possibility exists of increased systemic absorption and suitable precautions should be taken.

Although topical steroids have not been reported to have an adverse effect on pregnancy, the safety of their use in pregnant females has not absolutely been established. Therefore, they should not be used extensively on pregnant patients, in large amounts or for prolonged periods of time.

This product is not for ophthalmic use.

Adverse reactions The following local adverse reactions have been reported with topical corticosteroids: burning sensations, itching, irritation, dryness, secondary infection, folliculitis, acneform eruptions, hypopigmentation, striae, skin atrophy.

Dosage and Administration A small amount should be gently massaged into the affected area three or four times daily, as needed.

How Supplied LIDEX®-E (fluocinonide) cream 0.05% — 15g. and 60g. tubes.

SYNTEX
SYNTEX LABORATORIES, INC.
PALO ALTO, CALIFORNIA 94304

Books

Psoriasis: Proceedings of the Second International Symposium, edited by Eugene M. Farber, MD, and Alvin J. Cox, MD, 487 pp. 225 + illus, $35, New York, Yorke Medical Books, 1977.

The proceedings of the Second International Symposium on Psoriasis, which was held at Stanford University from July 12 through 15, 1976, have been published in a handsome volume that is a great improvement over that of the 1971 symposium. The type is clear and can be read easily, and the many graphs and photographs consistently are reproduced well. There are few errors, and the editors are to be congratulated.

The opening remarks of the symposium by Dr G. Donald Whedon, director of the National Institute of Arthritis, Metabolism, and Digestive Diseases, are of particular interest. In essence, Dr Whedon acknowledged the effects of lobbying by institutions and individuals to obtain money for research on psoriasis. Of particular note was the urging of the National Institute for Arthritis, Metabolism, and Digestive Diseases by the Senate Appropriations Subcommittee for Health, Education, and Welfare to increase its efforts in funding research on psoriasis; the Institute was directed also to analyze the needs and priorities for dermatologic research. It is this kind of direct plotting that will be needed to obtain more funds for dermatologic research.

The papers are presented uniformly. Some of the chapters are especially outstanding, such as the chapter by Van Scott and Yu, "Pharmacobiologic Leads in Psoriasis," and the chapter by Stoughton, "A Perspective of Topical Corticosteroid Therapy." The bibliographic references were carefully selected and up-to-date and will add to the reference value of this volume.

My only criticism of the book is the absence of an index—an addition that would make the book more useful.

This book will bring the reader reasonably up-to-date with the old and the new ideas in the treatment and research in psoriasis. It would be an excellent addition to the library of every dermatologist, as well as research workers in the field, and certainly should be available to all residents in dermatology.

SIGFRID A. MULLER, MD
Rochester, Minn

Atlas of the Face in Genetic Disorders, ed 2, by Richard M. Goodman, MD, and Robert J. Gorlin, DDS, MS, 586 pp, 1,181 illus, $57.50, St Louis, CV Mosby Co, 1977.

The purpose of this atlas is to aid the clinician in making a diagnosis of a genetic disorder on the basis of certain distinguishing facial features. The number of syndromes recorded in the second edition is almost triple that in the first edition. A tremendous amount of information is presented to assist the reader in the quest for a specific diagnosis.

An introductory section on genetic inheritance and counseling details the importance of the family history, the modes of genetic transmission, and, most importantly, an integral part of the treatment both to the patient and to his family—genetic counseling. The embryology of the face and precise methods of head and facial measurements are presented briefly. Guidelines and definitions on the classification, nomenclature, and naming of morphologic defects are proposed.

Genetic disorders of the face are recorded either alphabetically or by an increasing chromosomal number and according to the various modes of inheritance—autosomal dominant, autosomal recessive, X-linked, chromosomal, or uncertain genetics. Abundant clinical photographs and radiographs of excellent quality illustrate the distinguishing features of each genetic disorder presented. In addition, a large summary table, an appendix with extensive tables, and medical and genetic glossaries are included to further aid in pursuit of a diagnosis.

The authors acknowledge that some genetic syndromes with unusual facial features are omitted; however, these omissions do not detract from the value of the text. This atlas effectively achieves the goal of assisting the clinician in making a diagnosis of a genetic disorder. This outstanding contribution should be of interest to medical personnel of all disciplines, particularly those working in human genetics, dermatology, oral pathology, otolaryngology, ophthalmology, and plastic and reconstructive surgery. Since receiving this atlas, I have referred to it on numerous occasions and value it immensely in my reference library.

LTC RICHARD B. ODOM, MC, USA
Presidio of San Francisco

News and Notes

Postgraduate Course and Workshop in Dermatomycology.—The course in dermatomycology will be offered from Aug 25-27, 1978, for dermatologists, clinical pathologists, medical mycologists, and other persons interested in the current status of medical mycology. This program will be limited and is acceptable for category I credit toward the American Medical Association Physician's Recognition Award and the Certificate in Continuing Education of the California Medical Association. For further information please contact Extended Programs in Medical Education, University of California, Room 569-U, San Francisco, CA 94143, or call (415) 666-4251.

Pediatric Dermatology Seminar.—A three-day pediatric dermatology seminar will begin Thursday evening, Feb 23, 1978, at the Konover Hotel on the ocean front of Miami Beach. The program will conclude on Sunday afternoon, Feb 26, to be followed by a one-week postseminar flight and cruise to the Caribbean and South America. Dr R. Winkelmann, of the Mayo Clinic (Rochester, Minn), will conduct daily lectures and discussions at Curacao, Caracas, Grenada, Guadeloupe, St Thomas, and San Juan.

The course is designed to review the most recent advances about skin diseases of children. The format will be two 45-minute lectures followed by a 30-minute question and discussion period in which the audience can quiz an internationally renowned faculty. Continuing medical education credit will be awarded.

The faculty and their subjects include as follows: Albert Kligman, "Contact and Irritancy Dermatitis, Myths About Acne and Diaper Rashes;" Richard Winkelmann, "Bullous Diseases of Children, Review of Pediatrics Dermatological Literature;" Gerald Weissman, "Inflammation and Infection—New Views and Therapy;" Heinz Eichenwald, "Neonatal Skin Abnormalities and Infectious Diseases of Children's Skin;" Loren Golitz, "Difficult and Practical Diagnostic Problems of Pediatric Dermatology Reviewed and Updated;" William Awad, "Internal Abnormalities of Children With Skin Disease;" Guinter Kahn, "New Thoughts, Types and Therapies—Hemangiomas."

The tuition is $150 for physicians and $100 for physicians in training. For further details write to Guinter Kahn, MD, 16800 NW Second Ave, Suite 401, N Miami Beach, FL 33169.

Seminar.—A postgraduate seminar in dermatology will be held March 3-5, 1978 at the Carillon Hotel, Miami Beach. Registration fee is $180. For further information, contact William Eaglstein, MD, 3900 NW 79th Ave, Suite 469, Miami FL 33166, or call (305) 592-9298.

American Society for Dermatologic Surgery.—The Fifth Annual Clinical and Scientific Meeting, will be held March 28 to April 1, 1979, at the Princess Hotel, Grand Bahama Island. For information contact Daniel E. Gormley, MD, Society Secretary, 210 S Grand Ave, Suite 307, Glendora, CA 91740.

University of Cambridge School of Clinical Medicine.—The fifth five-year course "Progress in Biological Sciences in Relation to Dermatology" will be held in Cambridge, England, Sept 25-29, 1978.

Details may be obtained in due course from the Secretary, Cambridge University School of Clinical Medicine, Addenbrooke's Hospital, Hills Road, Cambridge CB2.2QQ, England.

"Your Consultant Speaks".—The Stanford University Department of Dermatology will offer the postgraduate symposium, "Your Consultant Speaks," on Feb 7-10, 1978, at Del Webb's Sahara Tahoe Hotel and Casino, Lake Tahoe, Nev. This multidisciplinary course is designed for the dermatologist. Objectives are to encourage dermatologist-consultant cooperation in diagnosing and treating skin diseases, and to update and broaden the dermatologist's knowledge of chemotherapy, DNA, endocrinology, hematology, immunology, infectious diseases, internal medicine, and psychiatry. Sessions will be held at Lake Tahoe from 7:00 to 9:00 AM and from 5:00 to 7:00 PM. This is an American Medical Association accredited postgraduate seminar. For information contact Paul H. Jacobs, MD, Department of Dermatology, Stanford University Medical Center, Stanford, CA 94305; (415) 497-6101.

University of California, San Francisco-Cleveland Clinic—Northwestern University Dermatology Seminar in Hawaii.—This seminar sponsored by the University of California Medical Center, San Francisco, Cleveland Clinic, and Northwestern University, will be held at the Hotel Inter-Continental, Maui, Hawaii, from Jan 20-25, 1978. In addition to the faculty of these three institutions, guest speakers include Drs John Strauss and Harry Arnold.

Registration is limited in number. For a program, please write the Department of Dermatology at the University of California Medical Center, San Francisco, CA 94143 or the Department of Dermatology, Northwestern University Medical School, Chicago, IL 60611.

Dermatopathology Club Meeting.—The Dermatopathology Club will meet with the International Academy of Pathology in Atlanta on March 5, 1978 at 1:30 PM in the Hilton Hotel. The program will include clinicopathologic correlations, basic research, and experimental pathology. Any person interested in diseases of skin is encouraged to attend. Submit proposed titles of material to Richard J. Reed, MD, 234 Loyola Ave, suite 603, New Orleans, LA 70112, or to David L. Page, MD, Department of Pathology, Vanderbilt University Hospital, Nashville, TN 37232. The last hour of this afternoon session is jointly sponsored by the American Society of Dermatopathology and the Dermatopathology Club.

Advanced Dermatology Course.—The Institute of Dermatology, St John's Hospital for Diseases of the Skin, as an organization accredited for 30 hours in category I of the American Academy of Dermatology of their continuing medical education award, and of the PRA of the American Medical Association, is holding an advanced dermatology course in London, Sept 11-15, 1978, assuming a minimum of 100 participants. The speakers will be authorities in their field from different British Centers. The course consists of clinicopathological conferences, color slide presentations, and lectures and laboratory demonstrations, and is suitable for hospital and office dermatologists and for residents in training. For further information please write to Dr A. Kobza Black, Institute of Dermatology, St John's Hospital for Diseases of the Skin, Lisle St, London WC2H 7BN, England.

IS AQUACARE®/HP TOO MUCH FOR EVERYDAY DRY SKIN?

IF IT WEREN'T SO SAFE AND COSMETICALLY ELEGANT THE ANSWER MIGHT BE YES.

AQUACARE®/HP HYDRATES, SOFTENS AND SOOTHES CHRONIC, SCALING, PRURITIC CONDITIONS . . . WHETHER MILD OR SEVERE.

HERBERT LABORATORIES/DERMATOLOGY DIVISION OF ALLERGAN PHARMACEUTICALS, IRVINE, CA 92713, U.S.A.

wash it. dry it. peel it.

Fostex,® the flexible therapeutic acne wash that degreases, dries, and peels. Easily integrated with all topical or systemic therapy for acne Grades I, II, and III. Convenient and economical Fostex Liquid and Cream are also effective anti-seborrheic shampoos for oily scalps associated with acne. Available as Fostex Cream in 4½ oz. jars, Fostex Cake in 3¾ oz. bars, and Fostex Liquid in 5 oz. plastic bottles.

Fostril,® the flesh-tinted drying and peeling lotion that conceals as it heals. Adaptable to Grades I, II, or III acne, Fostril is available in 1 oz. plastic tubes.

Transact,® the transparent medicated acne gel. A thin film of Transact will dry the oiliest of skin and is ideal for acne on chest, shoulders, and back. Greaseless, nonstaining, with a fresh clean fragrance. In 1 oz. plastic tubes.

WESTWOOD
PHARMACEUTICALS INC.
Buffalo, New York 14213
In Canada, Belleville, Ontario K8N 1E2

Rapid relief...

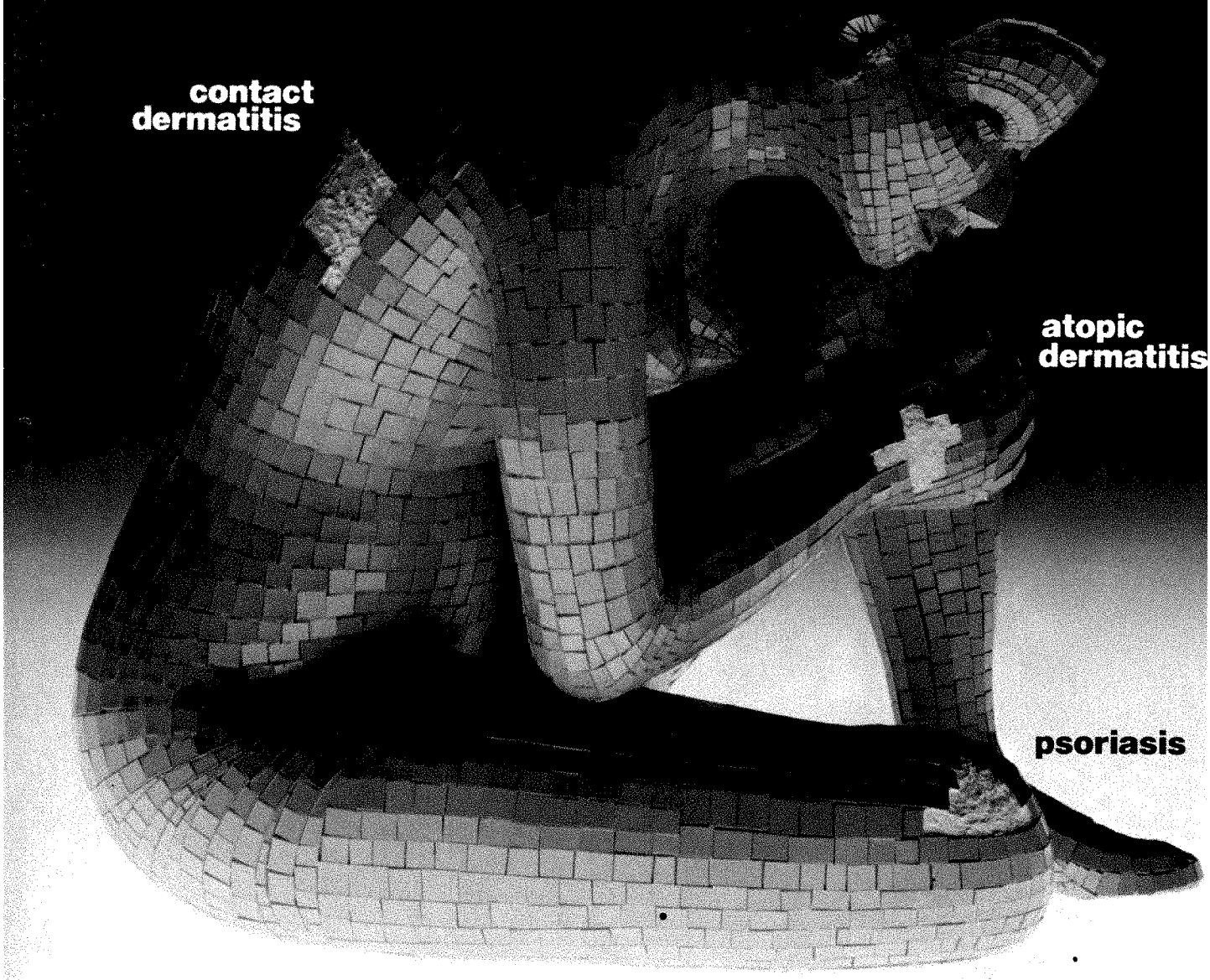

COPYRIGHT © 1977, SCHERING CORPORATION. ALL RIGHTS RESERVED.

Schering

b.i.d. Diprosone®

brand of

betamethasone dipropionate Cream 0.05%

(Potency expressed as betamethasone)

Twice a day for prompt relief of corticosteroid-responsive dermatoses

In contact dermatitis

90% **of patients showed marked or moderate improvement in seven days***

34 of 38 contact dermatitis patients responded to therapy.

In atopic dermatitis

86% **of patients showed marked or moderate improvement in seven days***

133 of 155 atopic dermatitis patients responded to therapy.

In psoriasis

62% **of patients showed marked or moderate improvement in only seven days***

116 of 188 psoriasis patients responded to therapy.

Additional benefits:

- Rapid onset of response.
- Economy and convenience of b.i.d. dosage.
- Occlusive dressings infrequently needed.
- Sensitivity is rare.
- Choice of convenient package sizes—in 15 Gm. and moneysaving 45 Gm. tubes.

Diprosone® brand of betamethasone dipropionate

Cream 0.05%/Ointment 0.05%

Clinical Considerations:

DESCRIPTION DIPROSONE is betamethasone dipropionate (9-fluoro-11β, 17,21-trihydroxy-16β-methylpregna-1,4-diene-3,20-dione 17,21-dipropionate). Each gram of DIPROSONE **Cream** 0.05% contains 0.64 mg. betamethasone dipropionate (equivalent to 0.5 mg. betamethasone) in a hydrophilic, emollient cream consisting of purified water, mineral oil, white petrolatum, polyethylene glycol 1000 monocetyl ether, cetostearyl alcohol, phosphoric acid, and monobasic sodium phosphate with 4-chloro-*m*-cresol as preservative. Each gram of DIPROSONE **Ointment** 0.05% contains 0.64 mg. betamethasone dipropionate (equivalent to 0.5 mg. betamethasone) in an ointment base of mineral oil and white petrolatum. **CONTRAINDICATIONS** DIPROSONE **Cream** and **Ointment** are contraindicated in vaccinia and varicella. Topical steroids are contraindicated in those patients with a history of hypersensitivity to any of the components of such preparations. **PRECAUTIONS** If irritation develops with the use of DIPROSONE **Cream** or **Ointment,** treatment should be discontinued and appropriate therapy instituted. In the presence of an infection, the use of an appropriate antifungal or antibacterial agent should be instituted. If a favorable response does not occur promptly, the corticosteroid should be discontinued until the infection has been adequately controlled. If extensive areas are treated or if the occlusive technique is used, the possibility exists of increased systemic absorption of the corticosteroid and suitable precautions should be taken. Although topical steroids have not been reported to have an adverse effect on pregnancy, the safety of their use in pregnant females has not been absolutely established. Therefore, they should not be used extensively on pregnant patients, in large amounts or for prolonged periods of time. DIPROSONE **Cream** and **Ointment** are not for ophthalmic use. **ADVERSE REACTIONS** The following local adverse reactions have been reported with topical corticosteroids: burning; itching; irritation; dryness; folliculitis; hypertrichosis; acneiform eruptions; hypopigmentation. The following may occur more frequently with occlusive dressings than without such therapy: maceration of the skin; secondary infection; skin atrophy; striae; miliaria. **DOSAGE AND ADMINISTRATION** Apply a thin film of DIPROSONE **Cream** to the affected skin areas twice daily, in the morning and at night. Clinical studies of DIPROSONE have indicated that applications twice a day are generally adequate. Apply a small quantity of DIPROSONE **Ointment** to the affected skin areas twice daily, in the morning and at night.

APRIL 1976

For more complete details, consult package insert or Schering literature available from your Schering Representative or Professional Services Department, Schering Corporation, Kenilworth, New Jersey 07033.

*Data in files of Headquarters Medical Research Division, Schering Corporation.

Also available for prescribing flexibility

b.i.d. Diprosone® ointment 0.05%

brand of betamethasone dipropionate

SLS-710

Letters to the Editor

Percutaneous Penetration Following Use of Hair Dyes

To the Editor.—Maibach et al[1] reported in the ARCHIVES that thin-layer chromatography (TLC) of urine samples from four of eight subjects, which were taken one to four days after they had dyed their hair with one of two commercially distributed, semipermanent hair dyes, disclosed a purple spot. The spot, which was unidentified, was the same with both dye preparations and was neither detected in control TLC of urine samples from the subjects nor in TLC of either hair dye. The authors concluded that "It is likely that these hair dyes not uncommonly penetrate the skin," and that the purple spot was most likely a metabolite.

We found the same purple spot in urine specimens from 13 of 14 subjects who had been treated according to the procedure of Maibach et al, ie, ether extraction of concentrates that were adjusted to pH 1, followed by ether extraction of the concentrates adjusted to pH 11; the extracts were then subjected to TLC on silica gel in either of Maibach's solvent systems C or D. Eight of the urine specimens were obtained from persons who had used a black shade of hair color lotion. Since the purple spot was detected in the urine specimens from this group either before or after the application of the dye to their hair, as well as in urine from nonusers, we suspected that the purple urinary metabolite was an artifact produced from a normal urinary constituent by the conditions used for the extraction.

An artifact was confirmed by the following:

1. The spot was detected only when the extraction at pH 11 followed the extraction at pH 1. The spot was not detected when the sequence was reversed.

2. The spot was detected in the pH 11 extract when the residue from the extraction at pH 1 was heated for one hour on a steam bath. When the residue from the extraction at pH 1 was adjusted immediately to pH 11 without heating, the spot was not detected.

3. The spot was detected in the extracts at pH 11 when the residue from the extraction at pH 1 was held at room temperature for six to 24 hours prior to the extraction. When the residue was held for one hour or less following the extractions at pH 1, the spot was not detected. The intensity of the colored spot at 24 hours indicated a higher concentration of the purple substance than at six hours.

Consequently, we believe that we have demonstrated that the purple metabolite reported by Maibach et al is an artifact produced by the extraction procedure used. The reason Maibach et al did not detect the spot in extracts of all the urine specimens that were examined might be because the specimens stood at pH 1 for varying lengths of time before being extracted at pH 11, and/or the amount of artifact present in various urine specimens was not sufficient to be visible on all of the TLC plates.

ROBERT S. YARE, PHD
MARIO GARCIA, PHD
Stamford, Conn

1. Maibach HI, Leaffer MA, Skinner WA: Percutaneous penetration following use of hair dyes. *Arch Dermatol* 111:1444-1445, 1975.

In Reply.—We observed in our laboratories and in others that when urine is heated at 100 C for periods of one to two hours at pH 1 and is extracted by ethyl acetate or other solvents at pH 11 and is followed by TLC, a variety of colored spots can be observed owing to hydrolysis of conjugated blood pigments. When this procedure is followed without heating at pH 1, no colored spots are observed on TLC.

In our previous study, we were careful to avoid heating the urine at pH 1 or allowing the urine to stand longer than two to three hours at 20 C before extraction. In our control urine samples, taken from persons prior to hair dyeing, we never observed colored spots on TLC (eight subjects). Furthermore, a total of thirty-seven 24-hour urine samples that were taken from the subjects after they had dyed their hair were processed in the same manner and yielded no evidence of coloration on TLC.

In view of the recent publication by Ames et al,[1] wherein hair coloring dye components have been shown to be mutagenic in his microbial systems, evaluation of whether dye components contained mutagens, in the urine of persons who have been treated with the dyes, is desirable.

HOWARD I. MAIBACH, MD
San Francisco
M. A. LEAFFER, MS
W. A. SKINNER, PHD
Menlo Park, Calif

1. Ames BN, Kammen HO, Yamasaki E: Hair dyes are mutagenic: Identification of a variety of mutagenic ingredients. *Proc Natl Acad Sci* 72:2423-2427, 1975.

In Reply.—Urine specimens from the eight individuals included in our study, who had used color lotion (natural black), were evaluated for mutagens by using the liver microsome activation method described by Durston and Ames.[1] Urine specimens that were collected prior to the use of the hair colorant were tested also. Neither the control nor the experimental urine showed mutagenic activity. In addition, urine specimens from 75 regular users of hair-coloring products have been evaluated by the same technique. All evaluations were negative.

ROBERT S. YARE, PHD
MARIO GARCIA, PHD
Stamford, Conn

1. Durston WE, Ames BN: A simple method for the detection of mutagens in urine: Studies with the carcinogen 2-acetylaminofluorine. *Proc Nat Acad Sci USA* 71:737-741, 1974.

Rifampin in Leishmaniasis

To the Editor.—I was very interested in the letter by Griffiths and Sodeify (*Arch Dermatol* 112:1791, 1976) in which rifampin is mentioned as a valuable drug for the treatment of cutaneous leishmaniasis.

I would like to report the case of a 19-year-old woman who had a 4 × 4-cm ulcer of eight months' duration on the right forearm. On October 1976, a Giemsa stain revealed Leishman-Donovan bodies on a smear obtained from the base of the ulcer. The patient was started on a pentavalent antimonial compound, methylglucamine antimoniate (Glucantime [France]; no comparable US product); she received two courses, (ten injections of 1.5 gm each) during a period of four weeks, without any signs of improvement. After reading the above-mentioned letter, I decided to start her on a regimen of rifampin, 600 mg twice a day for ten days; complete healing of the lesion with this treatment was observed. If further experiences show efficacy in the treatment of leishmaniasis with Rifampin, we will have a safe, easily obtainable and easy to manage drug, for this kind of problem.

Like Griffiths and Sodeify, I have not had good results with the use of metronidazole (Flagyl) in previous cases.

F. ROLANDO VÁSQUEZ, MD
Guatemala City

Photosensitivity Owing to Thiourea

To the Editor.—In two of our patients who were suffering from photosensitivity, thiourea could be identified as the sensitizer.

Report of Cases.—CASE 1.—A 51-year-old white man developed photosensitivity three weeks after having started work with a photocopying machine. Fiery redness and swelling developed on the skin that was exposed to light, accompanied by burning sensations; even indoor light caused complaints.

In light tests, the skin showed an increased sensitivity mainly to ultraviolet-A light (UV-A). Photopatch tests showed that the photocopy paper that was used by the patient in his work made his skin strongly reactive to light. The manufacturer of the paper kindly supplied us with data on the chemical composition of the paper and with samples of the 12 compounds involved. In photopatch tests with the separate compounds, thiourea turned out to be the cause of the severe reactions of the skin to light. Thiourea is used in almost all kinds of photocopy paper as an antioxidant, serving to prevent yellow discoloration of the paper.

After the patient's contact with the photocopying process was ended, the photosensitivity persisted for several years. However, at this writing three years have elapsed, and the patient's problem has become noticeably less severe.

CASE 2.—A 40-year-old black man was recently admitted to our clinic with an itching dermatosis. The areas most affected were the hands, including the palms and nailbeds, and the face. The patient complained of reactions of his skin to sunlight. Light tests showed that the skin reacted abnormally to ultraviolet-B light (UV-B); swelling could be produced anywhere on the skin with UV-B in doses corresponding to less than one minimal erythema dose (MED) for white skin. Repeated irradiation caused papules and vesicles on the patient's skin. A blister was elicited in the palm of the hand with UV-B administered in a dose insufficient to cause any visible reaction on the corresponding site in a white normal person. Patch tests showed strongly positive reactions to thiourea, even without intentional exposure to light. Such reactions could be avoided by decreasing the concentration of the aqueous thiourea solution used in the test to 0.0001 N; the total amount of thiourea applied per square centimeter of skin in this way was estimated to be only 0.01% of that present in 1 sq cm of a typical photocopy paper. Even then, papular reactions could be elicited in the contact area with either UV-B or UV-A.

Since avoiding any contact with photocopy paper was not compatible with the patient's job as an architect, we looked for a combination of photocopy paper and developer that did not contain thiourea or related compounds; we found such a combination in paper and developer that is marketed by a company in Great Britain.

Comment.—Contact sensitivity to photocopy paper has been described before,[1,2] but in these reports there is no indication that either thiourea or light were involved. Thiourea is toxic; amounts that penetrate through the skin may cause symptoms of poisoning.[3] The use of this agent as an antithyroid drug was discontinued because of the severe reactions it caused.[4] Thiourea is not only used in photocopying processes but also, for instance, as a rubber additive.

Photosensitivity owing to thiourea is rare, judging from the lack of reports to this effect, and especially considering that the compound is so widely used. Nevertheless, other investigators and physicians should be alerted to this possibility, now that two cases were found in one center in just a few years' time.

Dr H. G. J. de Boer of GAF-Nederland, Delft, and Dr H. Mustacchi of GAF-Great Britain, Colnbrook, gave us information on the composition of photocopy papers; they also supplied the paper and developer that did not contain thiourea.

J. C. VAN DER LEUN, PHD
E. J. DE KREEK, MD
M. DEENSTRA-VAN LEEUWEN, MD
H. VAN WEELDEN, MSC
Utrecht, The Netherlands

1. Harman RRM, Sarkany I: Studies in contact paper dermatitis. XI: Copy paper dermatitis. *Trans St Johns Hosp Dermatol Soc* 44:37-47, 1960.

2. Gertler H, Laubstein H: Ueber berufsbedingte Erkrankungen bei Lichtpausern. *Berufsdermatosen* 11:125-140, 1963.

3. Kosova LV: The skin-resorptive action of thiourea and its dioxide. *Gig Sanit* 35:31-34, 1970.

4. Goth A: *Medical Pharmacology*, ed 3. St Louis, CV Mosby Co Publishers, 1966, p 468.

Transient Acantholytic Dermatosis

To the Editor.—We are concerned about the report of a so-called variant of transient acantholytic dermatosis (TAD) by Waisman et al.[1] Their three patients all exhibit the clinical, histologic, and therapeutic picture of bullous impetigo (BI), but test data to exclude this more common entity, eg, skin lesion culture and Gram's stain, coagulase and phage typing, and injection of organisms into neonatal mice,[2] were not presented.

Clinically, the crusted, bullous lesions (some of which became purulent) with a + Nikolsky's sign, which originate periorificially, are typical of BI. Therapeutically, the partial response or nonresponse to penicillinase-sensitive or bacteriostatic antibiotics is consistent with BI. Incidentally, the observation of new bullae possibly precipitated by sunlight or suction trauma is interesting but may be coincident since BI prefers exposed surfaces too.

Histologically, the appearance of acantholysis[3] with negative immunofluorescence, and, particularly, a high cleavage plane (sub- or intragranular layer) is almost pathognomonic in these three patients of the so-called localized variant[4] (BI) of scalded skin syndrome. The more typical findings of TAD, ie, suprabasilar clefts, dyskeratotic cells, corps ronds, and grains,[5] were not described in any of these patients.

Perhaps the reason TAD was considered was because of (unstated) negative skin cultures. We would suggest that in the setting described, BI (missed by technical error) would still be a more appropriate diagnosis than TAD and that appropriate antibiotic therapy should have been administered. Perhaps the protracted course and the risks of potent topical corticosteroids and corticosteroid therapy that produces systemic effects, which were administered, could thus have been avoided.

REED R. LOCKWOOD, MD
PETER M. ELIAS, MD
San Francisco

1. Waisman M, Stewart JJ, Walker AE: Bullous transient acantholytic dermatosis. *Arch Dermatol* 112:1440-1441, 1976.

2. Melish ME, Glasgow LE: Staphylococcal scalded skin syndrome: The expanded clinical syndrome. *J Pediatr* 78:958-967, 1971.

3. Steigleder GK: Zur Differentialdiagnose des pemphigus vulgaris aus dem Blasengrundausstrich. *Arch Klin Exp Dermatol* 202:1-9, 1955.

4. Elias PM, Levy SW: Bullous impetigo: Occurrence of localized scalded skin syndrome in an adult. *Arch Dermatol* 112:856-858, 1976.

5. Grover RW: Transient acantholytic dermatosis. *Arch Dermatol* 101:426-434, 1970.

In Reply.—Drs Lockwood and Elias strive mightily to establish a case for bullous impetigo. They minimize the evidence that points to transient acantholytic dermatosis and deprecate the credibility of two experienced clinicians (my coauthors) who observed the cases reported. In rebuttal, let me point out that the degree of acantholysis was far in excess of that in impetigo and simulated pemphigus foliaceus, and no microorganisms were present in the many histologic sections. Incidentally, Ralph W. Grover, MD (ARCHIVES 101:426-434, 1970) reviewed our material prior to

submission for publication and concurred in the diagnosis.

Practicing dermatologists do not usually perform the extensive and costly laboratory work demanded by Drs Lockwood and Elias for bullous impetigo. In the office in which we practiced, there were no neonatal mice that we were aware of.

MARGARET WAISMAN, MD
Houston

Ocular Involvement in Pyoderma Gangrenosum

To the Editor.—Pyoderma gangrenosum (PG) is an inflammatory disease of unknown origin that may be associated with ulcerative colitis and polyarthritis.[1-3] Ocular involvement, however, has not been reported to our knowledge. We observed a patient with PG of the left temporal region and ipsilateral ulcerative scleritis.

Report of a Case.—A 64-year-old man had had seronegative asymmetrical arthritis of the distal finger joints, the knees, and the sacroiliacal joints for many years. There was no evidence of rheumatic nodules, bowel disease, or a hematological disorder. In 1971, several inflammatory papules appeared on his left temple. Ulceration of these lesions resulted in a 6 × 10-cm defect with a highly inflamed margin (Fig 1). Simultaneously, severe scleral conjunctivitis of the left eye occurred and was followed by a scleral ulcer, anterior uveitis, and corneal opacity (Fig 2). Histological examination of biopsy specimens from both ocular and cutaneous lesions revealed a nonspecific inflammation. Laboratory test results were normal, with the exception of an increased ESR.

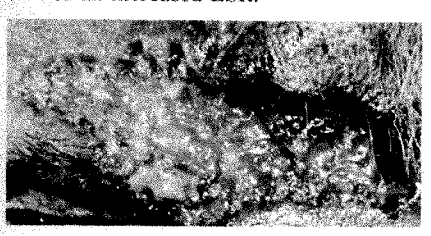

Fig 1.—Pyoderma gangrenosum of four months' duration.

Fig 2.—Ulcerative scleritis with corneal opacity in pyoderma gangrenosum.

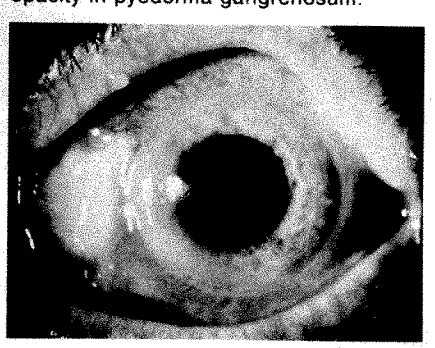

Local and systemic treatment with antibiotics was without effect. Cryotherapy of the scleral ulcer and treatment with cortisone for systemic effects (12 mg/day) was followed by improvement of the ocular lesions. The skin ulcer, however, persisted. Therefore, a combined therapy with prednisone and azathioprine was initiated, and prompt improvement was achieved. Reductions of the dosage led to recurrences on repeated occasions. With 50 mg of azathioprine and 5 mg of prednisone twice a week, the patient has been free of symptoms for three years.

Comment.—In PG, ocular manifestations have not been reported. Our patient's ipsilateral involvement and clinical course may indicate that both ocular and cutaneous lesions are owing to a common pathogenetic trait. Ulcerative scleritis may be an extracutaneous manifestation of PG. On the other hand, the ulcerative scleritis of our patient may be merely incidental. To make this point clear, all patients with PG should be examined for ocular involvement.

RUDOLF HAPPLE, MD
HANS-PETER SCHIFFER, MD
PETER M. KÖVARY, MD
Münster, West Germany

1. Perry HO, Brunsting LA: Pyoderma gangrenosum: A clinical study of 19 cases. *Arch Dermatol* 75:380-386, 1957.

2. vdSluis I: Two cases of pyoderma gangraenosum associated with the presence of an abnormal serum protein (β_2A-paraprotein): With a review of the literature. *Dermatologica* 132:409-424, 1966.

3. Basler RSW, Dubin HV: Ulcerative colitis and the skin. *Arch Dermatol* 112:531-534, 1976.

Macular Anetoderma in an Appendectomy Site

To the Editor.—The macular anetodermas are idiopathic atrophies of the skin characterized by multiple, discrete, oval lesions of loose, wrinkled, skin that may be depressed or bulge loosely. I report a particular case, in which a classical eruption was associated with the very elective occurrence of several lesions of anetoderma in an appendectomy site.

Report of a Case.—A 12-year-old girl had an eruption of macular anetoderma that appeared at the age of 8 years and developed gradually. When the patient was first seen, lesions were in the atrophic stage and had the characteristic bulging appearance. Pressure with the tip of the finger readily depressed the bulge, and a defect in the dermis was felt. The bulge reappeared when the finger was released, much like an umbilical hernia. The lesions were distributed over the shoulders, interscapular area, upper arms, and trunk. Subjective symptoms were absent. About 40 typical lesions were irregularly scattered over the body. A string of four typical macules of anetoderma was present in a small, appendectomy scar (Figure). The patient had undergone a classical appendectomy at the age of 5 years. According to her mother, the scar remained unchanged until the age of 10 years, when it became looser, bulging, and atrophic because of the development of lesions of anetoderma in this site. Histopathologic study showed the destruction and loss of elastic fibers, without perivascular infiltration.

Anetoderma in appendectomy site.

Comment.—The two following types of macular anetoderma are classically distinguished[1-4]: (1) secondary macular anetodermas that arise directly from inflammatory lesions (syphilids, tuberculids, urticarial lesions, purpuric lesions) and (2) primary macular anetodermas that arise from apparently normal skin. The case herein reported undoubtedly falls under the group of primary macular anetodermas. In this group, the localization of the eruption in old scars is exceptional, since in the literature, I have found only a case reported by Degos and Larregue,[2] in which some lesions had developed electively in chickenpox scars.

Therefore, it is possible to distinguish a new type of primary macular anetoderma, in which lesions electively occur in old scars. These findings might be compared with a recent report of lichen sclerosus et atrophicans in vaccination scars.[1]

ANDRÉ DUPRÉ, MD
Toulouse, France

1. Anderton RL, Abele DC: Lichen sclerosus et atrophicus in a vaccination site. *Arch Dermatol* 112:1787, 1976.

2. Degos R, Larregue M: Anétodermie de type Schwenninger-Buzzi ayant débuté après une varicelle. *Bull Soc Fr Dermatol Syphiligr* 78:218, 1971.

3. Demis DJ, Crounse RG, Dobson RL: *Clinical Dermatology*. Hagerstown, Md, Harper & Row Publishers Inc, 1976, vol 7, pp 4-19.

4. Deluzenne R: Les anétodermies maculeuses. *Ann Dermatol Syphiligr* 83:618-630, 1956.

Toxic Epidermal Necrolysis in Patients Who Are Allergic to Penicillin

To the Editor.—I congratulate Dr Elias and his associates for the excel-

lent review of staphylococcal scalded skin syndrome.[1] However, on page 212, in the "Treatment" section, the authors state that they are not aware of any study documenting the effectiveness of alternate drugs in treating patients with toxic epidermal necrolysis (TEN), who are allergic to penicillin. I would like to invite their attention to a report by Rudolph et al[2] (reference 84 cited in the article by Elias et al), where a 2-year-old boy (patient 9) who was suffering from *Staphylococcus aureus*-induced TEN and allergic to penicillin, was treated with erythromycin (150 mg/day) orally for eight days. His lesions cleared with desquamation in six days. This case clearly supports Dr Elias and colleagues' presumptive choice of using erythromycin as one of the alternates in treating patients with TEN, who are allergic to penicillin.

JATA S. GHOSH, MS
Ardmore, Pa

1. Elias PM, Fritsch P, Epstein EH Jr: Staphylococcal scalded skin syndrome: Clinical features, pathogenesis, and recent microbiological and biochemical developments. *Arch Dermatol* 113:207-219, 1977.

2. Rudolph RI, Schwartz W, Leyden JJ: Treatment of staphylococcal toxic epidermal necrolysis. *Arch Dermatol* 110:559-562, 1974.

Vertical Striated Sandpaper Nails

To the Editor.—In a general sense, 25 years ago Alkiewicz[1] and, recently, Achten and Wanet-Rouard[2] described rough nails under the title "Trachyonychie."

In a study soon to be published in the *Annales de Dermatologie et Syphiligraphie*, we report on a number of cases of rough nails that are suggestive of an expression of alopecia areata and bear a clinical similarity to the cases reported by Drs Hazelrigg, Duncan, and Jarratt in their article "Twenty-Nail Dystrophy of Childhood" (ARCHIVES 113:73-75, 1977). The descriptive term *l'ongle grésé peladique* (vertical striated sandpaper nails) is offered (Figure). This entity, observed in both children and adults, may involve all 20 nails.

Vertical striated sandpaper nails.

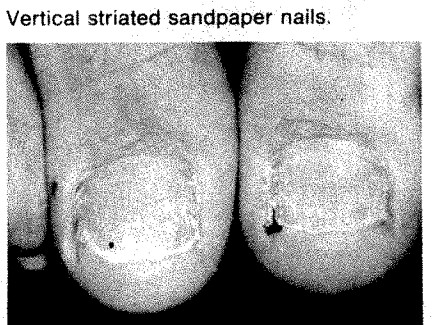

When the vertical striated sandpaper effect is not uniformly distributed over the full expanse of the nail plates, the disorder may be caused by lichen planus or even psoriasis. Historical evidence of keratolytic degeneration supports this thesis.

ROBERT BARAN, MD
Cannes, France
ANDRÉ DUPRÉ, MD
Toulouse, France

1. Alkiewicz J: Trachyonychie. *Ann Dermatol Syphiligr* 10:136-140, 1950.

2. Achten G, Wanet-Rouard J: Atrophie ungueale et trachyonychie. *Arch Belg Dermatol* 30:201-207, 1974.

Paraneoplastic Acrokeratosis of Bazex

To the Editor.—The entity paraneoplastic acrokeratosis of Bazex[1,2] has to be regarded as a true paraneoplastic syndrome affecting middle-aged men. The sudden clinical dermatological manifestations are related to the existence of a cancer; they may disappear if the malignant growth is removed, but appear again if there is a recurrence of tumor.[3] The cutaneous changes must alert the physician to search the upper respiratory and digestive tract for a malignant tumor, always a carcinoma, before it begins to produce it's own signs and symptoms.

The lesions are symmetrically located on the extremities, involving hands, feet, ears, and, rarely, the nose (Figure). Ungual involvement is constant and also the earliest manifestation. The nails are deformed by subungal hyperkeratosis that lifts their free edge. Their surface is irregular, flaky, and whitish. When the lesions are severe, their appearance is similar to a major psoriatic onychopathy, including even total nail loss.[4]

In some instances there is total or nearly total onychopathy, mostly of the toenails. The nail bed is replaced by a smooth, soft epidermis, and debris (remnants of the nail plate) are adherent to this epidermis by means of irregular, horny, ridged, and fissured formations. When ungual involvement is mild, only soft, thinned, crumbling, and cracking nails are seen.

Sometimes, both degrees of severity corresponding to two stages of the affection are shown in some observations in which the proximal third of the nail is atrophic, while in contrast the distal two thirds are hypertrophic.[5]

The dorsal aspects of the distal portions of toes and fingers are more or less sheathed by erythematous and

Foot showing symmetrical lesions of paraneoplastic acrokeratosis of Bazex. Nails are deformed, surface irregular, flaky, and whitish.

scaly patches. Perionyxis with intermittent suppuration is frequently seen. The tips of fingers and toes are covered with rough, fissured, and keratotic patches.

The pathological changes described by Bazex are not always present. There is allergic vasculitis in the dermis and the epidermal cells show a cytoplasm rapidly becoming eosinophilic and then disappearing and leading to vacuolated cells.

ROBERT BARAN, MD
Cannes, France

1. Bazex A, Salvador R, Dupre A, et al: Syndrome paraneoplasique a type d'hyperkeratose des extremites: Guerison après traitement de l'epithelioma larynge. *Bull Soc Fr Dermatol Syphiligr* 72:182, 1965.

2. Bazex A, Dupré A, Christol B: Dermatose psoriasiforme d'etiologie cancereuse: Acrokeratose paraneoplasique, in: *Report of the 13th Congress of the Association of French-speaking Dermatologists* (Turin, June 7-9, 1969). Paris, Masson & Cie, 1971, p 368.

3. Degos R, Civatte J, Audebert G, et al: Acrokeratose paraneoplasique (syndrome de Bazex). *Bull Soc Fr Dermatol Syphiligr* 75:539-540, 1968.

4. Bureau Y, Barriere H, Litoux P, et al: Acrokeratose paraneoplasique de Bazex: Importance des lesions ungueales: A propos de deux observations. *Bull Soc Fr Dermatol Syphiligr* 78:79-82, 1971.

5. Thiers H, Moulin G, Haguenauer JP, et al: Acrokeratose paraneoplasique. *Bull Soc Fr Dermatol Syphiligr* 80:129-130, 1973.

Bullous Erythema Multiforme

To the Editor.—In the December 1976 issue of the ARCHIVES (112:1757-1760), Drs Robinson and Samorodin presented a case report entitled "Thiabendazole-Induced Toxic Epidermal Necrolysis." The clinical presentation began initially with typical bullous erythema multiforme. This progressed to the picture of toxic epidermal necrolysis. The authors raised the issue of this conjunction. Moreover, they raised the interesting point that the immunologically changed lymphocyte may release a pharmacologically active agent that damages the epidermis.

Years ago at the US Naval Hospital, Chelsea, Mass, we saw a similar patient whose bullous erythema multiforme was initially treated with penicillin ointment followed by penicillin, given for systemic effects, that was administered on shipboard when the original, allergic nature of his disease was not appreciated by his paramedical attendants. His disease progressed to a point where he shed broad areas of skin. The mucous membrane involvement, high fever, and systemic deterioration continued as he received intramuscular penicillin for ten days.

Although he was desperately ill when seen at Chelsea, Mass, and he was thought to have smallpox, he recovered with massive amounts of intravenous adrenocorticotropic hormone that was available at that time.

I pondered with astonishment over the fact that he endured what we would call "delayed hypersensitivity" albeit severe, rather than go on to an acute anaphylactic course in the presence of continued antigen administration systemically. The development of modern immunologic theory has begun to clarify such issues.

However, I do not think that we have sufficient information to separate the drug type of toxic epidermal necrolysis from erythema multiforme until we have isolated the agent responsible for the epidermal necrosis, as is seemingly the case with the staphylococcal variety.

HOWARD S. YAFFEE, MD
Cambridge, Mass

1. Yaffee HS: Erythema multiforme (Stevens-Johnson syndrome) caused by penicillin. *Arch Dermatol* 79:591, 1959.

Chronic Bullous Dermatosis of Childhood

To the Editor.—Contrary to the comments of Esterly et al (ARCHIVES 113:42-46, 1977), linear deposition of IgA at the dermoepidermal junction may be found in 12% of cases of dermatitis herpetiformis (*Br J Dermatol* 92:157-166, 1975), as well as in "chronic bullous dermatosis of childhood."

Although this pattern appears to be more frequent in "chronic bullous dermatosis of childhood," than in dermatitis herpetiformis, it cannot be used as a reliable criterion for differentiating these two entities.

DAVID A. VORON, MD
Arcadia, Calif

In Reply.—We did not intend to imply that the finding of linear IgA at the dermoepidermal junction on direct immunofluorescence is diagnostic of chronic bullous dermatosis of childhood. In bullous pemphigoid, IgA can be found in a similar pattern, but IgG is the predominant immunoglobulin present, and the morphologic characteristic of the band is distinctive. In dermatitis herpetiformis, IgA can also be found along the dermoepidermal junction but is uncommon; such a patient was described recently by Yaoita et al.[1] The characteristic immunofluorescent finding in dermatitis herpetiformis is deposition of IgA in the dermal papillae and/or discrete granular deposits at the dermoepidermal junction, especially prominent in the dermal papillae.

It is becoming apparent that children who have a chronic eruption of large blisters with rosette formation and figurate erythematous plaques can have deposition of IgA along the dermoepidermal junction. All of the cases with positive immunofluorescent findings reported to date[2-5] have had this finding, including an additional case reported recently.[6]

Whether one calls this entity the large blistering type of juvenile dermatitis herpetiformis, mixed bullous pemphigoid-dermatitis herpetiformis, juvenile pemphigoid, or the "chronic bullous dermatosis of childhood,"[7] the disorder is a distinct clinical entity with characteristic immunologic abnormalities.

NANCY B. ESTERLY, MD
NANCY L. FUREY, MD
Chicago

1. Yaoita H, Hertz KC, Katz SI: Dermatitis herpetiformis: Immunoelectronmicroscopic and ultrastructural studies of a patient with linear deposition of IgA. *J Invest Dermatol* 67:691-695, 1976.

2. McGuire J, Nordlund J: Bullous disease of childhood. *Arch Dermatol* 108:284, 1973.

3. Feuerman GJ, Metzker A, Varsano J: Dermatitis herpetiformis in childhood. *J Isr Med Assoc* 88:114-118, 1975.

4. Faber WR, Van Joost TH: Juvenile pemphigoid. *Br J Dermatol* 89:519-522, 1973.

5. Esterly NB, Furey NL, Kirschner BS, et al: Chronic bullous dermatosis of childhood. *Arch Dermatol* 113:42-46, 1977.

6. Prystowsky S, Gilliam JN: Benign chronic bullous dermatosis of childhood: Linear IgA and C3 deposition on the basement membrane. *Arch Dermatol* 112:837-838, 1976.

7. Bean SF, Jordan RE: Chronic nonhereditary blistering disease in children. *Arch Dermatol* 110:941-944, 1974.

Nail Polish Remover Sensitization

To the Editor.—While one of my patients was using topical tretinoin on her face, she noticed that her nail polish came off. I hurriedly confirmed that tretinoin indeed removes nail polish (the liquid and swabs work much better than the cream or the gel), and I would consider this property worthy of note for patients who have become sensitized to nail polish remover.

LAWRENCE M. FIELD, MD
San Luis Obispo, Calif

Contaminated Fungal Cultures Owing to *Tyrophagus putrescentiae*

To the Editor.—Acarodermatitis is an occupational disorder caused by the stored-food mites of the families Tyroglyphidae and Pyemotidae. These normally nonpathogenic mites do occasionally cause skin irritations (cheese mite dermatitis, fig mite dermatitis, copra itch, grain itch, grocer's itch), which may become extremely severe, but are self-limited and never transmitted from person to person.[1-4]

Recently, one of these mites, *Tyrophagus putrescentiae*, was identified as the cause of our continuing failure to successfully culture dermatophytes from several of our private patients. Fungal cultures that originally appeared normal, rapidly and at an early stage, changed their appearance to that of gross bacterial contamination. Microscopic examination of these contaminated specimens demonstrated myriads of mites, which were subsequently identified as *T putrescentiae*. All existing cultures within our offices and all old cultures within the clinical laboratory's teaching collection were discarded. Working areas were decontaminated with gamma-benzene hexachloride spray. Lindane crystals were added to the stock teaching collection, and subcultures of this collection were made on Sabouraud's agar slants to which two drops of concentrated lindane in 95% alcohol were added. The lindane was added after autoclaving but before agar cooling (B. Russel, personal communication, 1977). Other, but equally successful, approaches to the control of these mites have been suggested.

These mites live not only on stored foods, such as cheeses and cereals, but also in molds and pathogenic fungii. Therefore, they should be suspected and looked for in those cultures whose early appearance is that of gross bacterial contamination.

ROBERT B. AMON, MD
JON M. HANIFIN, MD
MARY C. CAMPBELL
Portland, Ore

1. O'Donovan WJ: Dermatitis due to *Carpoglyphus passularum*. *Br J Dermatol* 32:297-298, 1920.

2. Prosser-Thomas EW: Dermatitis due to *Tyroglyphus longior* Gerv, var *Castellanii* Hirst, in cheese dust. *Br J Dermatol* 54:313-319, 1942.

3. Booth BH, Jones RW: Epidemiological and clinical study of grain itch. *JAMA* 150:1575-1579, 1952.
4. Mumcuoglu Y: Acaro-dermatitis. *Praxis* 65:101-104, 1976.
5. Emmons CW, Binford CH, Utz JP, et al: *Medical Mycology*. Philadelphia, Lea & Febiger Publishers, 1977, pp 544-545.
6. Rebell G, Taplin D: *Dermatophytes: Their Recognition and Identification*. Coral Gables, Fla, University of Miami Press, 1970, p 115.

Clarification of Lichen Planus Actinicus

To the Editor.—In the recent article by Dilaimy in the ARCHIVES (112:1251-1253, 1976), the author describes an annular lichen planus that is unique and clinically distinct in the Middle East countries and that he has named "lichen planus subtropicus."

However, I wish to refer to an article by Katzenellenbogen[1] in which the author describes similar features, ie, pigmented patches, with a slightly elevated border, on sun-exposed areas of the skin that are worsened by sun exposure and that occur in a younger age-group of persons than that in cases of classical lichen planus. In addition, this author describes a dyschromic and granular annulare variety of lichen planus in these patients.

Dilaimy does not mention these varieties dyschromic granuloma annulare) in his patients, but the similarity of the pigmented, annular, actinic lichen planus in these two articles should warrant the retention of the original name, lichen planus actinicus, rather than the renaming of the disease.

SYLVIA MARTIN, MD
Vancouver, British Columbia, Canada

1. Katzenellenbogen I: Lichen planus actinicus (lichen planus in subtropical countries). *Dermatologica* 124:10-20, 1962.

In Reply.—When we call a lesion "actinic," as in actinic keratotis, we imply that the lesion is caused by the sun. If the sun was one of many factors that caused a condition, we cannot call that condition actinic.

In lichen planus subtropicus, there are other factors that play a role in its origin besides the sun. These factors include heat, nutritional deficiencies, and genetic predisposition. Lichen planus actinicus is an existing clinical variety of lichen planus that usually follows a sunburn and is considered as a Koebner's reaction; the name "lichen planus actinicus" should be restricted to this variety of the disorder only.

MOUTA DILAIMY, MD
Baltimore

An Unusual Variant of Darier's Disease: A Therapeutic Suggestion

To the Editor.—In the March 1977 issue of the ARCHIVES (113:374), Dr Dolezal describes a severe case of the cornifying variant of Darier's disease that was widespread distribution, with painful, malodorous, and secondarily infected vegetations on the lower legs and feet. The article is illustrated with four color photographs that emphasize the patient's tragic plight. The patient was lost to follow-up for 11 years, but when seen again, the patient's condition had not changed. There was no mention of therapy on either occasion, except that the secondary infection had been cleared up with "tetracycline and acetic acid compresses" during his initial visits. When seen 11 years later, the malodorous infection was again present.

We reported the successful control of keratosis follicularis (Darier's disease) with the use of a combination of vitamins A and E (*Arch Dermatol* 106:909-910, 1972). Our patient was a 26-year-old man who had had a severe, widespread eruption of classical Darier's disease with notable photosensitivity for 13 years. He had failed to respond to vitamin A in a dosage of 200,000 IU daily, during a five-year period, but he became much worse if the dose was reduced.

A synergism between vitamin A and vitamin E was demonstrated by Ames,[1] who showed that the serum vitamin A level of rats that are on a vitamin E-deficient diet remained low, no matter how much vitamin A was given, either by mouth or by injection; however, the serum vitamin A level returned to normal when vitamin E was added to the diet.

On the basis of these experiments, our patient was instructed to continue a regimen of 200,000 IU vitamin A daily. This course was later reduced to 150,000 IU of vitamin A, and vitamin E was also given in the form of *d*-α-tocopheryl acetate, 1,200 IU daily. The patient was also instructed to avoid ingesting inorganic iron, either as a dietary supplement or in white bread or cereals that are reinforced with iron, since inorganic iron combines with and inactivates vitamin E. During the ensuing 15 months of observation, the eruption almost completely cleared.

We have observed two additional patients with Darier's disease, in a milder form, whose conditions cleared completely, and we are aware of 11 additional cases of Darier's disease or of pityriasis rubra pilaris that were successfully controlled with a combination of vitamins A and E. The fact that large doses of vitamin E appear to be the key to treatment of this condition does not necessarily mean that there was a deficiency in vitamin E intake, although a relative deficiency that is due to an abnormally high requirement from congenital or acquired causes, or a defect in absorption or utilization of the vitamin may be indicated.

In any event, we would strongly recommend a therapeutic trial of the combined vitamins for treatment of this spectacular occurrence of cornifying Darier's disease.

SAMUEL AYRES, JR, MD
RICHARD MIHAN, MD
Los Angeles

1. Ames SR: Factors affecting absorption, transport, and storage of vitamin A. *Am J Clin Nutr* 22:934-935, 1969.

Griseofulvin Therapy in Molluscum Contagiosum

To the Editor.—Griseofulvin has recently been found useful in the treatment of viral warts (unpublished data) and molluscum contagiosum.[1] Keeping this in mind, we treated five cases of extensive molluscum contagiosum with griseofulvin fine particles, giving dosages of 500 mg a day, orally, for patients above 14 years of age, and half this dosage for younger patients. The treatment was continued for four to six weeks. The patients ranged in age from 4 to 17 years and had had lesions for 15 to 30 days. In each patient, the lesions started to regress within two weeks after treatment was begun, and the lesions completely disappeared in four to six weeks. There had been no recurrence of the condition in any of these patients after six to eight months of follow-up.

Although further studies are required to attribute antiviral activity to griseofulvin, disappearance of the lesions in every case within a few weeks of therapy is notable. Without treatment, the lesions are known to persist for six to nine months, or even as long as three to four years.[2]

OM P. SINGH, MD, DVD
AMRINDER J. KANWAR, MD
New Delhi

1. Kapur TR: Griseofulvin therapy in molluscum contagiosum: A case report. *Indian J Dermatol Venerol Leprol* 42:90, 1976.
2. Harmann RR, Naginton J, Rook A: Virus infections, in Rook A, Wilkinson DS, Ebling DS (eds): *Text Book of Dermatology*, ed 2. Oxford, England, Blackwell Scientific Publications, 1972, p 587.

Treatment of Atopic Dermatitis With the Scholtz Regimen

To the Editor.—Atopic dermatitis continues to present a challenge to the dermatologist, in spite of much research on the theoretical aspects of the immunological process. We would like to call attention again to an important contribution by Dr Jud R. Scholtz in two papers on the management of atopic dermatitis that were published in 1964 and 1965.[1,2] We have designated Scholtz's technique as the "Scholtz regimen," and we have used this method during the ensuing 14 years for the successful control of this recalcitrant disease.

We feel that the dramatic response of atopic dermatitis to the Scholtz regimen is comparable to the advancement in the therapy of infections by the introduction of antibiotics, and of inflammatory diseases by corticosteroids; the Scholtz regimen has not received the attention that it merits.

Our introduction to this new technic for the management of atopic dermatitis occurred at the October 1963 meeting of the Los Angeles Dermatological Society, when Scholtz reported on two lifelong victims of this harassing disease. Both individuals, in their middle years, appeared to have perfectly normal skin with no trace of inflammation. Only after reading the protocols and examining pretreatment color transparencies, did one become aware of the fact that this treatment had transformed these two sufferers from chronic dermatologic invalids into normal and happy members of society. As might be expected, several highly critical skeptics expressed their disbelief.

The rationale of the Scholtz regimen is based on the concept of an impaired functioning of the skin with especial reference to a defective sweating mechanism, associated with dryness, as reported by Sulzberger and his colleagues.[3,4] Food sensitivities, emotional disturbances, and contact irritants may be important secondary factors, but without correction of the long overlooked primary defect of skin function, treatment will be unsatisfactory.

The Scholtz regimen is divided in two main categories: things to avoid, and things to do; the factors in these categories must be scrupulously observed indefinitely if satisfactory results are to be achieved. We have made several minor modifications in Scholtz's original program that we feel have improved patient cooperation.[5] The regimen is summarized following:

Prohibitions.—No soap on affected areas; no contact with water except for brief, one-minute showers; no topical applications containing oil or grease, which might occlude sweat ducts; no heavy exercise (such as tennis), which would tend to promote perspiration; no wool, rough, or occlusive clothing; no exposure to occupational or household irritants; no oral steroids.

Topical Therapy.—Cetaphil lotion, a nonlipid, softening and cleansing lotion, followed immediately by .01% fluocinolone acetonide lotion (Synalar solution) twice daily, or oftener as needed. If secondary infection is present, .5% Neomycin sulfate with .025% fluocinolone acetonide (Neo-Synalar cream) may be used temporarily.

Systemic Therapy.—Scholtz recommended small doses of thyroid, once or twice daily if there is evidence of hypothyroidism or if the pulse is slow; and vitamin A, 10,000 IU to 100,000 IU daily (depending on age) if the skin is excessively dry. Oral antibiotics may be given for a short time if there is pronounced secondary infection. Foods that have been observed to aggravate the condition should be avoided.

We have treated all of our atopic dermatitis patients with this regimen since Scholtz first reported it in 1963. During these 14 years, we have had uniformly excellent results, sometimes with a 75% or 80% improvement within two or three weeks. There have been a few instances of relapse, but usually these occurred when the patient had gotten "off the beam," and had resumed frequent and prolonged bathing or other prohibited activities. We have seldom found it necessary to restrict the patient's diet or to administer thyroid, vitamin A, or antibiotics.[5,6]

The effectiveness of the regimen was dramatically emphasized in the case of a 26-year-old man who was seen in our office within the past month. The patient had suffered from atopic dermatitis at intervals since infancy, and he had suffered continuously during the past year and severely during the preceding three weeks. At the time of his second visit, two weeks after beginning the Scholtz regimen, the patient's eruption was 90% clear.

SAMUEL AYRES, JR, MD
RICHARD MIHAN, MD
Los Angeles

1. Scholtz JR: Management of atopic dermatitis: A preliminary report. *Calif Med* 100:103, 1964.
2. Scholtz JR: Management of atopic dermatitis. *Calif Med* 102:210-216, 1965.
3. Sulzberger MB: Atopic dermatitis: Its clinical and histologic picture, in Baer RL (ed): *Atopic Dermatitis*. New York, NY University Press, 1955, chap 2.
4. Sulzberger MD, Wolf J, Witten VH, et al: Atopic dermatitis, clinical appearance and course, in *Dermatology: Diagnosis and Treatment*, ed 2. Chicago, Yearbook Publishers Inc, 1961, p 201.
5. Ayres S Jr, Mihan R: Atopic dermatitis: Success or failure with the Scholtz Regimen. *Australas J Dermatol* 9:16-22, 1967.
6. Ayres S Jr, Mihan R: Letter to the editor. *Cutis* 15:445-451, 1975.

Dapsone-Induced Hepatic Changes

To the Editor.—Dapsone is a sulfone commonly used in the treatment of dermatological diseases, eg, leprosy and dermatitis herpetiformis and, on occasion, in the treatment of acne conglobata, erythema elevatum diutinum, relapsing polychondritis, and actinomycetoma. The side effects of dapsone, including hemolytic anemia and methemoglobinemia, agranulocytosis, diverse dermatoses, neuropathy, and upper gastrointestinal disturbances are generally well appreciated. Recently, I noted three patients who were on dapsone regimens (one patient for Hailey-Hailey disease, and two patients for dermatitis herpetiformis) who developed abnormalities in the results of their liver function tests.

Report of Cases.—All three patients were healthy aside from their dermatological conditions; they had normal glucose-6-phosphate dehydrogenase levels, had regularly screened normal blood counts and methemoglobin levels, and normal BUN, serum phosphorus, calcium, glucose, cholesterol, total protein, albumin, and alkaline phosphatase levels. Abnormal levels of lactic dehydrogenase, SGOT, and total bilirubin were observed consistently (Table).

Patient 1 began taking dapsone, 600 mg daily because of a pharmacy error. This error was discovered, and the medication was discontinued four days later after the patient had complained of malaise, fatigue, weakness, and gastrointestinal upset. Three weeks later, a regimen of dapsone was started at a dosage of 150 mg/day. In late April 1976, dapsone was discontinued because of recurring malaise and gastrointestinal problems and because of persistently abnormal results of liver function studies. Results of liver function studies returned to normal in May 1976, and remained normal until July 1976. In February 1977, the patient resumed the use of dapsone for treatment, at 150 mg daily, and again the results of his liver function studies became abnormal (Table); malaise, fatigue, and gastric symptoms prevailed and necessitated discontinuation of the use of dapsone. The results of liver function studies normalized within four weeks.

Patients 2 and 3 have been on continued regimens of dapsone (150 mg/day) and are

Dapsone-Induced Hepatic Changes

Patient/Age, yr/ Sex/Disorder	Date, Drug Dosage (mg/day)	Liver Function Test Results* Lactic Dehydrogenase (mU/ml)	SGOT (mU/ml)	Total Bilirubin (mg/100 ml)
1/60/M/Hailey-Hailey disease	8/75, none	143	45	1.3
	10/75, 600	152	44	1.8
	4/11/75, . . .	157	41	1.8
	23/11/75, 150	211	36	2.2
	2/76, 200	249	52	1.5
	5/76, none	212	36	0.7
	7/76, none	123	33	0.5
	2/77, 150	182	48	1.1
	4/77, 150	225	67	1.8
	5/77, 150	246	50	1.4
2/63/M/Dermatitis herpetiformis	1/70, 150	280	55	1.4
	2/71, 150	310	50	1.4
	2/76, 150	347	71	2.7
	3/76, 150	345	65	2.5
	5/76, 150	280	. . .	2.3
	11/76, 150	320	114	1.7
	2/77, 150	350	95	1.3
3/61/M/Dermatitis herpetiformis	6/74, none	238	50	0.6
	4/75, 100	170	52	0.9
	10/76, 100	267	. . .	1.0
	12/76, 100	259	74	1.2
	3/77, 100	245	72	0.9
	6/77, 100	263	107	0.9

*Normal results for lactic dehydrogenase, 90 to 200 mU/ml; SGOT, 15 to 50 mU/ml; total bilirubin, 0.2 to 1.0 mg/100 ml.

taking dapsone regularly despite the abnormalities of test results.

Patients 1 and 2 had gastroenterology consultations. Despite extensive workup, excluding liver biopsies, no reason for the abnormal results of liver function studies was uncovered. Dapsone was tentatively deemed the culpable agent.

Comment.—The purpose of this letter is threefold:

1. To alert colleagues to the potential of dapsone to cause abnormalities of hepatic function. Despite careful screening of several review articles on the side effects of dapsone, I have not found any mention of such hepatic changes. Neither have pharmacology texts been helpful on this subject.
2. To solicit confirmatory reports or literature references on this subject.
3. To stimulate investigations of the cause of these liver function changes and to determine the long-range effects of continued dapsone therapy.

LT COL D. KLAUS GOETTE, MC, USA
Presidio of San Francisco, Calif

Nonproprietary Name and Trademark of Drug

Dapsone—*Avlosulfon.*

Lymphomatoid Papulosis

To the Editor.—I wish to correct a misunderstanding introduced by the phrase, "lymphomatoid papulosis, or as he has named it, 'Rhythmic Paradoxical Eruptions,'" which refers to my use of nomenclature and appears in the first paragraph of Drs Thomsen and Schmidt's letter to the editor (ARCHIVES 113:232-233, 1977). The term "lymphomatoid papulosis" is not exactly synonymous with the term "rhythmic paradoxical eruption." Rather, lymphomatoid papulosis is one band in the spectrum of the rhythmic paradoxical eruptions.

In collecting data on lymphomatoid papulosis, it became apparent to me that there are a number of conditions, as yet unnamed and unclassified, that fit the description of "a continuing, self-healing eruption, clinically benign—histologically malignant."[1] Although they have many features in common, such as lesions coming and going for protracted periods of time, and they follow an apparent benign course while having histopathologic characteristics of a malignant lymphoma, these conditions differ in certain clinical features, histologic patterns, and prognosis. In short, there seems to exist a whole spectrum of continuing, self-healing eruptions that have the histopathologic characteristics of a malignant lymphoma of one type or another. To encompass this constellation of similar yet different disorders, I proposed the term "rhythmic paradoxical eruptions"[2] and assigned lymphomatoid papulosis as one band in this unusual spectrum of eruptions.

The foregoing concept is expounded in more detail with case histories and bibliographic review in a communication entitled "Lymphomatoid Papulosis and Some Other Rhythmic Paradoxical Eruptions," scheduled to appear in a forthcoming issue of the *International Journal of Dermatology.*

WARREN L. MACAULAY, MD
Fargo, ND

1. Macaulay WL: Lymphomatoid papulosis: A continuing, self-healing eruption, clinically benign—histologically malignant. *Arch Dermatol* 97:23-30, 1968.

2. Macaulay WL: Lymphomatoid papulosis and rhythmic paradoxical eruptions. Read before the Clinicopathologic Conference of the American Academy of Dermatology, San Francisco, December 1975.

In Reply.—Firstly, I want to thank Dr Macaulay, the father of the term "lymphomatoid papulosis," for his remarks on nomenclature. Secondly, allow me to make use of the opportunity to report yet another case of lymphomatoid papulosis that coexisted with parapsoriasis en plaque.

Report of a Case.—A 64-year-old man was referred to us two months ago with parapsoriasis en plaque since 1974, which was clinically characteristic and without poikiloderma. Histologic findings did not show evidence of mycosis fungoides. The eruption was localized to the lower back, the buttocks, hips, and thighs. Since the summer of 1975, he also had a recurring eruption of 3- to 5-mm, dark red papules on the buttocks, thighs, and legs, which left small, depigmented scars. Histologic findings showed a dermal infiltrate of abnormal lymphoreticular cells, some of which resembled Reed-Sternberg's cells. Pautrier's abscesses were not seen. The rest of the results of physical examination were normal, with no enlargement of lymph nodes, liver, or spleen. Results of routine blood tests and a roentgenogram of the lungs were all normal.

KRISTIAN THOMSEN, MD
Copenhagen

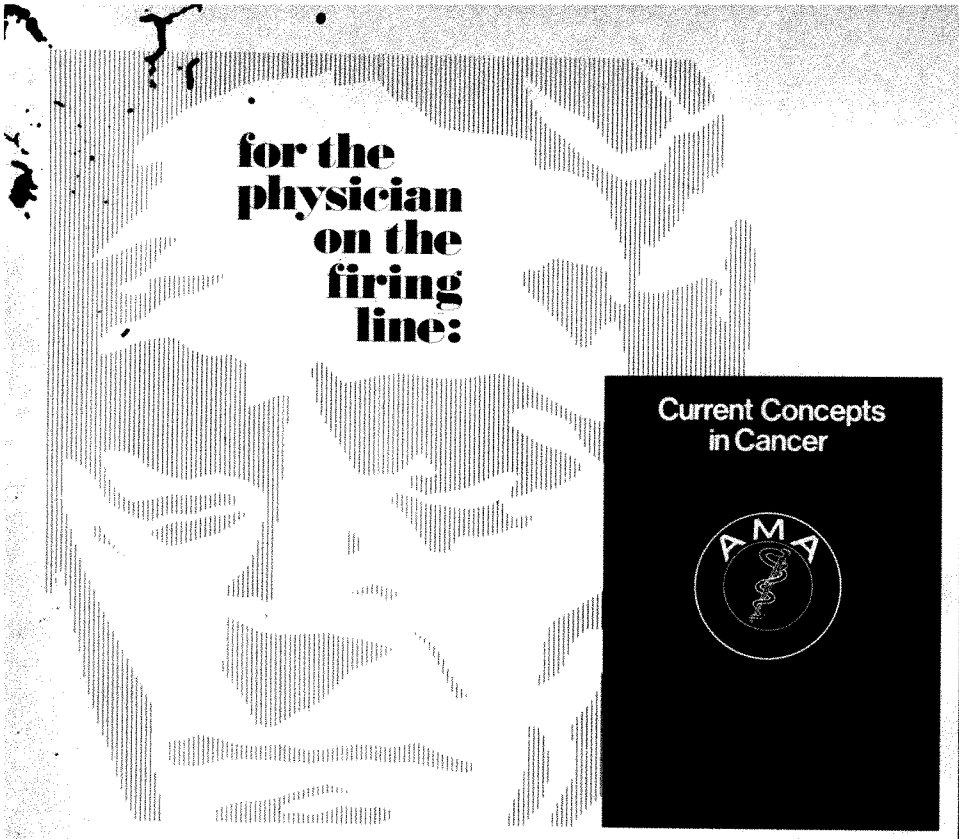

A valuable guide to diagnostic and therapeutic procedures for the cancer patient

Current Concepts in Cancer

While national attention focuses on cancer through specialized cancer centers, physicians are aware that the majority of cancer patients are treated in office practices. For most practicing physicians, cancer treatment is not a research objective, but a very practical problem in patient management.

Current Concepts in Cancer, a compilation of articles originally published in the *Journal of the American Medical Association,* is designed to be a guide for the practitioner in the choice of diagnostic and therapeutic procedures for many types of malignancies. It presents an objective interdisciplinary view by MDs outstanding in their respective fields, emphasizing principles of diagnosis and surgical, radiotherapeutic, and chemotherapeutic treatment.

Make this important resource a part of your reference file. Order your copy today.

American Medical Association S/J
535 North Dearborn Street
Chicago, Illinois 60610

Please send me _____ copy(ies) of **Current Concepts in Cancer** (OP-281). Price is $10 per copy. Please enclose your remittance with order.

Please Print

Name _____

Address _____

City _____ State _____ Zip _____

Selsun®

(SELENIUM SULFIDE LOTION, U.S.P.) ℞

Brief Summary

Contains:

Selenium sulfide, 2½%, w/v; bentonite; lauric diethanolamide; ethylene glycol monostearate; titanium dioxide; amphoteric—2; sodium lauryl sulfate; sodium phosphate (monobasic); glyceryl monoricinoleate; citric acid; captan; perfume; and water.

Indications:

For the treatment of dandruff and seborrheic dermatitis of the scalp.

Contraindications:

Should not be used by patients allergic to any of its components.

Warnings:

Safety for use on infants has not been established.

Precautions:

Cutaneous sensitization of the scalp or adjacent areas has been reported; if sensitivity reactions should occur, discontinue use. Chemical conjunctivitis may result if product enters the eyes. Do not use when acute inflammation or exudation is present as an increase in absorption may occur.

Adverse Reactions:

As with other shampoos, oiliness or dryness of the hair and scalp may occur following use; there have been occasional reports of an increase in the amount of normal hair loss. Hair discoloration may occur; can be avoided or minimized by thorough rinsing.

ABBOTT

7093197

For the benefit of your patients

TRADITIONAL THERAPY

FOR DANDRUFF AND SEBORRHEIC DERMATITIS OF THE SCALP

HAS BEEN IMPROVED

NEW FRAGRANCE
(much milder)

NEW COLOR
(much lighter)

NEW SUDSING
(much better)

SAME EFFICACY AND SAFETY

IMPROVED
Selsun® ℞
SELENIUM SULFIDE, LOTION, U.S.P.

Please see opposite page for Brief Summary.

7665197

For Skin Without Water

Neutrogena® Dry Skin products are specially formulated to supplement surface fats and aid in the retention of moisture.

- Neutrogena® Dry-Skin Soap contains humectants, lubricants, and emollients to soften and moisturize, and is nonirritating to sensitive skin.
- Neutrogena® Rainbath® Dry Skin Bath Gel is lipid-free, cleanses with a rich lather without the drying effect of ordinary soap, and leaves skin soft and smooth. Available both scented and unscented.
- Neutrogena® Hand Cream is a heavy-duty formula containing a special blend of naturally occurring oils and glycerin, and is a useful adjunct in steroid-responsive hand dermatoses.[1]

1. Data on file Medical Dept Neutrogena Corp

Neutrogena®

Dedicated to Sensitive Skin Care

Neutrogena Corp.
5755 West 96th Street
Los Angeles, California 90045

Now available! The latest information on self-assessment programs.

The new edition of the AMA's DIRECTORY OF SELF-ASSESSMENT PROGRAMS FOR PHYSICIANS is now available. It lists programs sponsored by all major specialty societies, on 21 topics.

Each program is listed by topic and sponsor and includes sites and times of tests, content, format, time required, method of scoring, aids to learning, fees and whom to write.

To order your copy of the Directory, ($1 ea.) write: Order Dept. OP-414, American Medical Association, 535 N. Dearborn St., Chicago, Ill. 60610.



For Skin Plagued by Acne

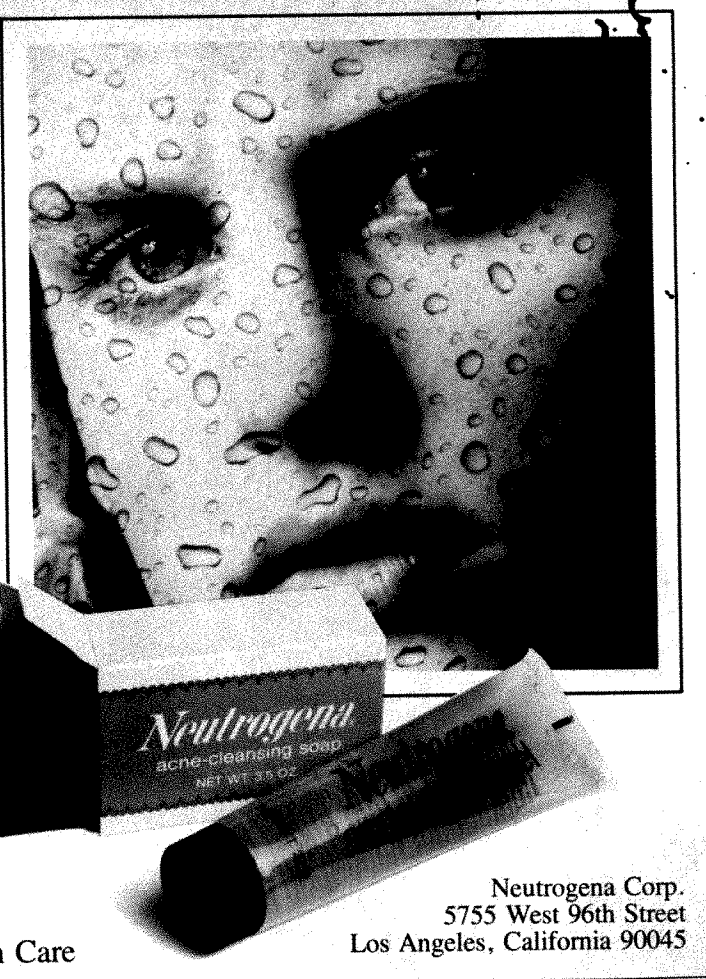

Neutrogena® Acne products aid in drying while they clean and degrease acne-plagued skin.

- Neutrogena® Acne-Cleansing Soap gently cleanses and degreases the skin, and does not interfere with topical or systemic acne treatment.
- Neutrogena® Acne-Drying Gel combines antisepsis with astringency, contains 47% active drying agents, is perfume-free, can be applied under or over makeup, and is imperceptible on the skin.

Neutrogena®
Dedicated to Sensitive Skin Care

Neutrogena Corp.
5755 West 96th Street
Los Angeles, California 90045



PUSH BUTTON PHOTOGRAPHY

No experience necessary to get professional results in your first twenty exposures.
NO FOCUSING. The automatic focusing mechanism included in our unit will permit you to be in focus at all times without the necessity of changing lenses, bellows, filters, batteries, etc. Unit is completely assembled and ready to take picture.

Only change frames. (sizes in inches.) 1⅜ × 1"- (1 to 1 photography) 2 × 3"- 4 × 6"- 6 × 9"- 9 × 13"- ⅓ body rod.

DELUXE MACRO . . . Photoeaze single unit reflex camera consists of 35 mm reflex camera back with double extention bellow, 50 mm- 2.8 lens, cable release, Pistol grip handle, Super power pack (strobe) that serves as base of unit, 2 strobe lights, full set of frames as shown above and automatic focusing mechanism.
Price . . . $399.00 FOB N. Y.

MINI MACRO . . . Same as above, with one strobe light and three frames (sizes in inches). 2 × 3"- 4 × 6"- 9 × 13"- . . . Price . . . $299.00 FOB N. Y.

Critically sharp pictures at all times in 35 mm color slides (2 × 2) or black and white film.
Copy x-ray negatives or books with any size frame.
We repair or remodel Coreco (Coret) cameras.
To order or for information:
PHOTOEAZE MFG INC.
241 East 10 STREET
NEW YORK, N. Y. 10003 tel 212-982-0660

Position:	**Faculty Appointment Department of Dermatology**
Responsibilities to be fulfilled:	**Teach Basic Science in Dermatology and participate in all Dermatology functions except patient care. Will do research in Lipid Biochemistry related to skin and be Research Leader**
Qualifications Desired:	**PhD. or equivalent, and a demonstrated scholar and leader in Lipid Biochemistry**
Salary:	**Appropriate for qualifications and responsibilities. Excellent fringe benefits.**
Employer:	**The University of Iowa, Iowa City, Iowa 52242, is an Equal Opportunity Employer.**
Application:	**Interested persons are invited to direct inquires and submit vitae to:**

Dr. John S. Strauss, Professor & Head
Department of Dermatology
College of Medicine
University of Iowa
Iowa City, Iowa 52242

Society Transactions Editor: Harry L. Arnold, Jr, MD, Straub Clinic, 888 S King St, Honolulu, HI 96813. Transactions and photographs should be submitted, in duplicate, to him.*

**Effective Jan 1, 1978, address correspondence to 1380 Lusitana St, Honolulu, HI 96813.*

LOS ANGELES DERMATOLOGICAL SOCIETY
May 11, 1977

Arnold W. Gurevitch, MD, Recorder

Atrophoderma (Type Unknown). Presented by ARNOLD W. GUREVITCH, MD, DORE J. GILBERT, MD.

This 20-year-old woman has had an asymptomatic eruption on her legs for 3½ years, with recent spread to her trunk and right upper arm. She also complains of tender, red areas on her buttocks that she believes are secondary to being bathed in chlorine bleach as a child.

Various topical creams have produced no beneficial results.

Multiple macular, erythematous lesions are seen on both thighs, within which are regions of circumscribed atrophy. The right upper arm, as well as the trunk, reveals small pink papules. The buttocks show extensive bilateral and symmetrical atrophic, tender, and very erythematous areas, with marked wrinkling of the skin.

Four punch biopsy specimens were taken from normal skin, a small erythematous papule, an atrophic macule, and from the atrophic buttock lesion. They were stained with hematoxylin-eosin and for elastic tissue.

Discussion

LEO INDIANER, MD: Histologically, the lesions show atrophy of the epidermis, basilar vacuolopathy, exocytosis of lymphocytes and monocytes, and a tremendous upper dermal inflammatory infiltrate of lymphocytes and histiocytes. Of interest is that the elastic tissue is greatly decreased. In some areas, it is almost completely lost. In other areas, the elastic fibers are thin, almost whittled down. This change is quite characteristic of what has been called "elastolytic," in which there is a tapering of the long ends of the elastic fibers, and the elastic fibers appear longer than usual. These changes alternate with areas in which the elastic fibers are fairly normal, or minimally altered. In this case, it represents an inflammatory process.

The question is: how should this lesion be classified? It could be classified as macular atrophy of Jadassohn, which is the inflammatory type of macular atrophy, except that those lesions are small, generally 0.5 to 1 cm in size. Most of the lesions of macular atrophy of the inflammatory type that I am accustomed to seeing are no larger than a thumbprint. However, the type of process we are seeing here has been described in the literature as "postinflammatory elastolysis." The lesions are characteristically 10 to 20 cm in size, and they have a tremendous inflammatory infiltrate and elastolysis. They occur in young individuals and particularly involve the buttocks, but they can involve other areas of the body. There may be smaller areas of the 1-cm size but more characteristic are the large lesions.

We have not been able to pinpoint the origin of this problem. Is it secondary to a collagen vascular disease? Is it a variant of poikiloderma vasculare atrophicans? Will it respond to penicillin, as some cases of elastolysis do? We cannot tell. May this be a precursor to mycosis fungoides, which will develop in lesions that show elastolysis, inflammation, and atrophy of the epidermis? The only thing we have been able to do, I believe, is to classify it as other than a simple macular atrophy. Its proper classification is postinflammatory elastolysis.

IRWIN LINDEN, MD: Were the biopsy specimens from the other lesions the same histologically as the biopsy specimen from the hip?

DR INDIANER: Three of the biopsy specimens show a tremendous inflammatory infiltrate. Two of the three show epidermal atrophy. All three did show foci of elastolysis, varying in degree from minimal to extensive, and the control, from normal skin, showed just some mild perivascular inflammatory infiltrate without elastic alteration.

LOUIS WINER, MD: I agree wholeheartedly with Dr Indianer's histologic description. Clinically, if this lesion were on the legs or arms, you would call it acrodermatitis chronica atrophicans. Histologically, it is just what was described: loss of elastic, elastolysis, an infiltrate hugging the epidermis, and atrophy of the epidermis. Clinically, there is a cigarette-paper wrinkling on the surface. Prior to the penicillin era, we used to see this eruption in Minneapolis, and even here I have seen cases of it. It has been shown that some cases respond to penicillin. I believe the clinician in this case should treat this patient with penicillin, and not do anything else, to see if the lesions respond.

DR GUREVITCH: I remain very puzzled as to what is going on in this woman. It is of interest that these lesions are progressing, and some of them are progressing rather rapidly. She has newly developing lesions on her abdomen. The new ones are small papules, whereas slightly older lesions, as on her arm, are small, macular areas of atrophy with a cigarette-paper type of wrinkling on the surface. Some of those individual lesions on her arm and on her leg look like the macular atrophy of Jadassohn's type. However, as Dr Indianer pointed out, there are just too many alterations, both clinically and histologically, for that diagnosis. And finally, the buttock eruption looks quite different. These changes on her buttocks have been there since infancy. Unfortunately, she was adopted by her aunt and uncle, and we do not have an adequate history of these lesions. She was told that she was dipped in chlorine bleach as an infant, and her current family blames the buttock eruption on that. Her buttocks are not only very soft and atrophic; they are also very tender. This combination is puzzling. We also considered acrodermatitis chronica atrophicans, but this is not only exceedingly rare in the United States, occurring mostly in people of European origin, but it also tends to begin distally, down around the ankles and feet, the lower legs, and may progress up to the thighs. Occasionally, it involves other areas but usually after progression from the legs. Many cases will, after several years, show evidence of fibrosis with banding. She has no evidence

of these fibrotic bands. So, she does not fit very well into that category either. I am not yet sure exactly how to categorize her unusual problem.

Feb 9, 1977

Arnold W. Gurevitch, MD, Recorder

Congenital Linear Porokeratosis. Presented by MORTON D. SCRIBNER, MD.

A 13-month-old girl was noted at birth to have an eruption on the left leg. The lesions have enlarged only in proportion to her growth, have not spread, and have not been pruritic. Family history is negative for similar skin disorders, consanguinity, diabetes, or psoriasis.

Physical examination reveals a healthy-appearing infant with numerous lesions that extend down the left thigh and leg in a band-like pattern. The patches are round and reddish-brown, and have sharp, slightly elevated margins.

A biopsy specimen was interpreted by Dr Bernard Gottlieb as follows:

"There is marked focal epidermal acanthosis associated with columns of parakeratotic material and loss of the stratum granulosum. There is benign dyskeratosis within the epidermis beneath the parakeratotic masses, but there is no mitotic activity or atypia and the change is not malignant in character. The marked parakeratosis and hypogranulosis virtually exclude simple ichthyosis and rule against ichthyosis hystrix of the usual type. Although the designation epithelial hamartoma is preferred, the pattern is that of linear porokeratosis. Although other types of linear epithelial nevi can be parakeratotic and psoriasiform in character, the sharp definition of the parakeratotic columns is somewhat against this possibility."

Flurandrenolide cream, applied four times daily for two months gave no improvement. One month ago, nightly application of tretinoin (retinoic acid; 0.05% Retin-A cream) was begun. Because of irritation, flurandrenolide cream is now being used two or three times during the day in addition to the tretinoin cream. There has been some improvement during the past few weeks.

Discussion

LEO INDIANER, MD: The histological features of this case bring up many points about porokeratosis. The biopsy specimen reveals thick columns of parakeratotic cells that alternate with areas of massive hyperkeratosis. Beneath the parakeratotic columns is a zone with absence of the granular layer and notable acanthosis, in which there are large dyskeratotic cells, proliferating smaller epithelial keratinocytes, and multiple small basaloid cells all intermingled. Also of interest, within the stratum corneum are large colonies of bacteria that are seen as basophilic granular material. In the differential diagnosis of linear lesions, the only diagnosis that would seem to fit in this case is porokeratosis. Lichen striatus, linear epidermal nevi of the usual type, linear psoriasis, and linear lichen planus do not fit in this histological pattern. However, in other entities, such as inflammatory linear verrucous epidermal nevus, there can be an inflammatory disorder occurring within the epidermis and resembling psoriasis. This inflammation may be associated with parakeratosis and even microabscesses within the stratum corneum. However, the parakeratosis is either spotty or diffuse, rather than in columns as occurred in the case presented.

Could this be an epithelial hamartoma? The linear hamartoma is of follicular origin, so that a tremendous amount of verrucous acanthosis with dyskeratotic cells, proliferating basaloid cells, and keratinocytes, resembling an inverted follicular keratosis, could be a part of the linear hamartoma syndrome. Yet, the parakeratotic columns seen in this case would be unusual for that entity. My own feeling is that much of the peculiar epidermal reaction in this case is due to the bacterial proliferation. I think a biopsy specimen from another lesion that had been treated with a topical antibiotic beforehand might give a purer picture of porokeratosis.

This case would have to be classified as a linear form of porokeratosis. The correlation between this form of porokeratosis and other variants is often discussed. Persons with linear lesions before the age of 5 years may develop the Chernosky type of disseminated superficial actinic porokeratosis later in life. In some patients with porokeratosis, squamous cell carcinoma has developed, even though the histopathology, aside from the presence of dyskeratotic cells, does not suggest cancer. I believe that this patient does have linear porokeratosis, but I think that biopsies of noninfected areas might reveal a clearer histology.

REID BINDER, MD: Is it the current feeling that porokeratosis is an accurate name?

DR INDIANER: The parakeratotic process in porokeratosis follows the periphery of the entire lesion. There is no way that we can postulate a sweat duct going all the way around a single lesion and enveloping it. The parakeratotic cornoid lamella involves epithelium in areas other than sweat pores and can also occur on buccal mucous membrane and on penile areas in which there are no duct openings. Therefore, porokeratosis is not an accurate term.

SAMUEL AYRES, JR, MD: We do not see cases of this condition very often. In the last case of porokeratosis of Mibelli that I had occasion to see, there were scattered lesions, some of which were linear and some patchy. My patient made good progress on a regimen of tretinoin, but this progress eventually came to a standstill. Ultimately, the patient achieved almost complete resolution after treatment with liquid nitrogen. The patient presented here, according to the mother, has made some progress with topical tretinoin. I would say that if this patient does not continue to respond to the tretinoin, I would certainly try liquid nitrogen in the hope of getting a complete response.

MORTON SCRIBNER, MD: In France, there has been one published report of clearing with 5% tretinoin. So far, this patient has had difficulty tolerating .05% tretinoin.

VICTOR NEWCOMER, MD: A similar case of porokeratosis at the UCLA School of Medicine exhibited striking improvement with tretinoin after a very brisk inflammatory response.



FOR THE

ZONES OF DERMATOSES

For dry areas/lesions

A **New Halog® Ointment 0.1%**

Halcinonide Ointment 0.1%

For scalp lesions

B **New Halog® Solution 0.1%**

Halcinonide Solution 0.1%

For moist areas/lesions

Full-strength

C **Halog® Cream 0.1%**

Halcinonide Cream 0.1%

'Maintenance formula'

Quarter-strength

New Halog® Cream 0.025%

Halcinonide Cream 0.025%

Clinical experience

A total of 984 psoriatic patients in US clinical studies were treated with either the Solution, the Creams, or the Ointment. After 2 weeks' therapy,* 151 (78%) of 194 patients improved with Halog Solution, 407 (92.5%) of 440 patients improved with full-strength (0.1%) Halog Cream, 132 (72%) of 184 patients improved with quarter-strength (0.025%) Halog Cream, and 145 (87%) of 166 patients improved with Halog Ointment.

In general, the preferred topical formulations for lesions in specific areas are: solutions for scalp lesions, creams for moist areas/lesions, and ointments for dry areas/lesions. The studies cited above, however, were not limited to lesions in these specific areas.

*Majority of patients evaluated after 2 weeks' therapy. Data on file at Squibb Institute for Medical Research.

See next page for brief summary.

HALOG®

HALCINONIDE

SQUIBB®

©1977 E.R. Squibb & Sons, Inc. 357-508

HALOG® (Halcinonide) Cream/Ointment/Solution

Halog Cream 0.025% (Halcinonide Cream 0.025%) and Halog Cream 0.1% (Halcinonide Cream 0.1%) contain 0.25 mg. and 1 mg. halcinonide per gram, respectively, in a specially formulated cream base. Halog Ointment (Halcinonide Ointment 0.1%) contains 1 mg. halcinonide (0.1%) per gram in Plastibase® (Plasticized Hydrocarbon Gel), a polyethylene and mineral oil gel base. Halog Solution (Halcinonide Solution 0.1%) contains 1 mg. halcinonide (0.1%) per ml.

CONTRAINDICATIONS: Topical steroids are contraindicated in vaccinia, varicella, and in those patients with a history of hypersensitivity to any of the components of the preparations. These preparations are not for ophthalmic use.

PRECAUTIONS: *General*—If local infection exists, suitable concomitant antimicrobial or antifungal therapy should be administered. If a favorable response does not occur promptly, application of the corticosteroid should be discontinued until the infection is adequately controlled. If extensive areas are treated or if the occlusive technique is used, the possibility exists of increased systemic absorption of the corticosteroid and suitable precautions should be taken. If irritation or sensitization develops, the preparation should be discontinued and appropriate therapy instituted. Although topical steroids have not been reported to have an adverse effect on pregnancy, the safety of their use during pregnancy has not been absolutely established; therefore, they should not be used extensively on pregnant patients, in large amounts, or for prolonged periods of time.

Occlusive Dressing Technique—The use of occlusive dressing increases the percutaneous absorption of corticosteroids; their extensive use increases the possibility of systemic effects. For patients with extensive lesions it may be preferable to use a sequential approach, occluding one portion of the body at a time. The patient should be kept under close observation if treated with the occlusive technique over large areas and over a considerable period of time. Occasionally, a patient who has been on prolonged therapy, especially occlusive therapy, may develop symptoms of steroid withdrawal when the medication is stopped. Thermal homeostasis may be impaired if large areas of the body are covered. Use of the occlusive dressing should be discontinued if elevation of the body temperature occurs. Occasionally, a patient may develop a sensitivity reaction to a particular occlusive dressing material or adhesive and a substitute material may be necessary. If infection develops, discontinue the use of the occlusive dressing and institute appropriate antimicrobial therapy.

ADVERSE REACTIONS: The following local adverse reactions have been reported with topical corticosteroids: burning, itching, irritation, striae, skin atrophy, secondary infection, dryness, folliculitis, hypertrichosis, acneform eruptions, and hypopigmentation. The following may occur more frequently with occlusive dressings: maceration of the skin, secondary infection, skin atrophy, striae, and miliaria. Contact sensitivity to a particular dressing material or adhesive may occur occasionally (see PRECAUTIONS).

For full prescribing information, consult package insert.

HOW SUPPLIED: The 0.025% and 0.1% Cream and the 0.1% Ointment are supplied in tubes of 15 g. and 60 g., and in jars of 240 g. (8 oz.). The 0.1% Solution is supplied in plastic squeeze bottles of 20 ml. and 60 ml.

SQUIBB®

JAMA

for the developments your specialty journal doesn't cover.

JAMA is one of the world's most respected medical journals.

Each weekly issue contains authoritative original contributions featuring the latest clinical developments in research, diagnosis, and treatment.

In addition, JAMA brings you editorials, question and answer columns, news of medical meetings, abstracts of key articles from other journals in the U.S. and abroad, plus letters and reviews of books and films.

Start your JAMA subscription coming today!

	U.S. & Poss.	All Other Countries
☐ 104 issues	$50	$75
☐ 52 issues	$30	$50

(Payment must accompany order. Make check or money order payable to JAMA.)

Name _____

Address _____

City _____ State _____ Zip _____

Return to: Circulation and Records Department
American Medical Association
S/J 535 North Dearborn Street, Chicago, Ill. 60610

what's best for the care of dry, or premature aging or wrinkled skin... DUE TO EPIDERMA DEHYDRATION?

SUPPLIED: 2 OZ. TUBES

WRITE FOR SAMPLES

DOAK PHARMACAL CO., INC. WESTBURY, N.Y. 115

DISTRIBUTOR IN CANADA

The best way to treat allergic patients is to properly identify the offending allergen.

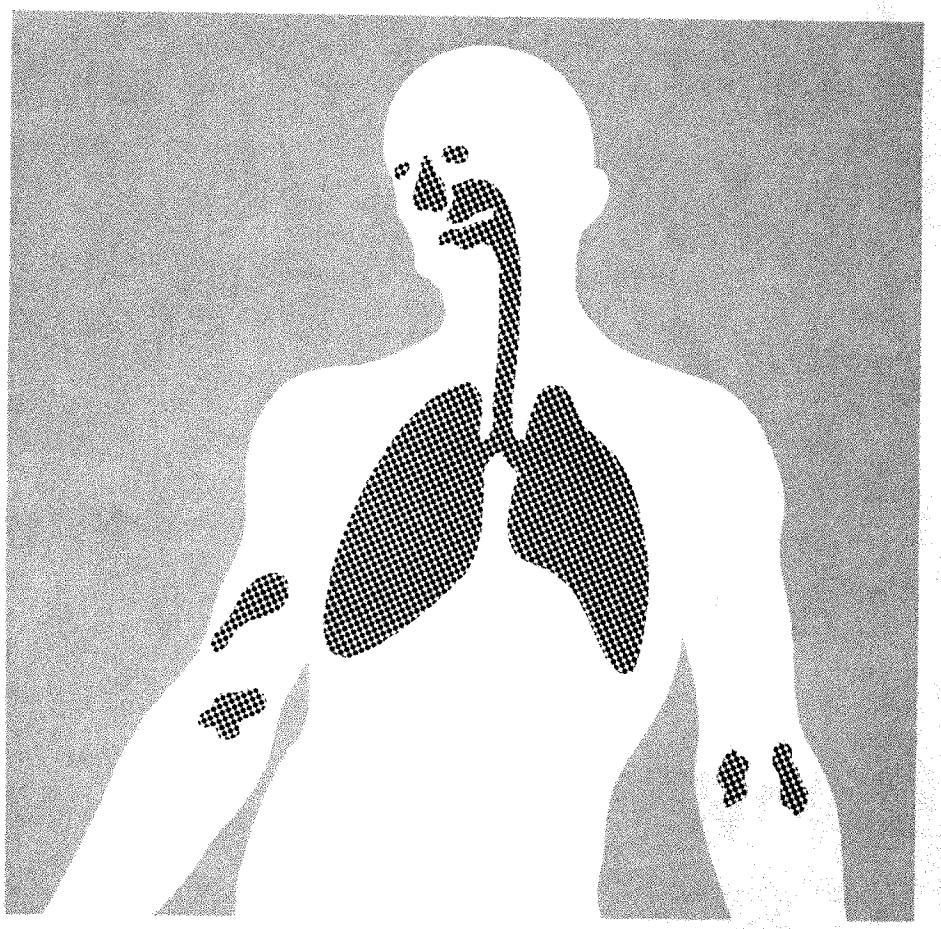

Phadebas RAST®

the *in vitro* alternative

Pharmacia Diagnostics AB
Uppsala, Sweden

Pharmacia Diagnostics

Argentina Laboratories Dr. Gador y Cia., S.A.C.I. Casilla de Correo 4041 1006 BUENOS AIRES. **Australia** Pharmacia (South Seas) Pty. Ltd. P.O. Box 175 Cnr Talavera&Khartoum Roads NORTH RYDE N.S.W. 2113. **Austria** Pharmacia Gesellschaft m.b.H. Rathausplatz 4 A-1010 WIEN. Schoeller-Pharma G.m.b.H. Postfach 103 A-1111 WIEN. **Belgium** N.V. Pharmacia Belga S.A. Bld. Gen. Jacqueslaan 26 B-1050 BRUSSELS. **Brazil** Emprêsa Medimex Importação e Comércio Ltda. Rua Cardoso Marinho, 40 Caixa Postal 33-ZC-00 RIO DE JANEIRO. **Canada** Pharmacia (Canada) Ltd. 2044 boul. St. Régis Blvd. DORVAL, Québec H9P 1H6. **Denmark** Pharmacia AS, Herredsvejen DK-3400 HILLERÖD. **Finland** Pharmacia OY Norrskensvägen 6, SF-02100 ESBO. **France** Pharmacia France S.A. Rue de Marly, Parly 2, F-78150 LE CHESNAY. **German Federal Republic** Deutsche Pharmacia GmbH Munzinger Strasse 9 Postfach 5480 D-7800 FREIBURG. **Great Britain** Pharmacia (G.B.) Ltd. Paramount House 75 Uxbridge Road LONDON W5 5SS. **Greece** G.A. Kambanis Imports-Exports-Representations 3 Iridanou Street ATHENS 615. **Italy** Importex Chimici Farmaceutici S.p.A. P.O. Box 467 Via Flavia 122/124 I-34100 TRIESTE. **Mexico** Internacional Cientifica, S.A. Apartado Postal 2-807 Angel del Campo 17-A MEXICO 12 D.F. **The Netherlands** Gist-Brocades N.V. Diagnostics Dept. P.O. Box 1 DELFT. **Norway** Norsk Pharmacia A/S Postboks 2005 Grünerlokka OSLO 5. **Portugal** J.A. Baptista D'Almeida Lda. Apartado 1339 LISBOA 1. **South Africa** Keatings Medical Industries (Pty) Ltd. P.O. Box 256 JOHANNESBURG 2000 R.S.A. **Spain** Atom, Paseo del Monte 34, BARCELONA 12. **Sweden** Pharmacia Norden AB Diagnostics Dept. Box 159 751 04 UPPSALA 1. **Switzerland** Pharmacia -pdf- (Schweiz) A.G. 214 Seefeldstrasse CH-8034 ZUERICH. **USA** Pharmacia Diagnostics Division of Pharmacia Inc. 800 Centennial Avenue PISCATAWAY, New Jersey 08854. **Other countries** Pharmacia Diagnostics AB Box 17 S-751 03 UPPSALA 1, Sweden.

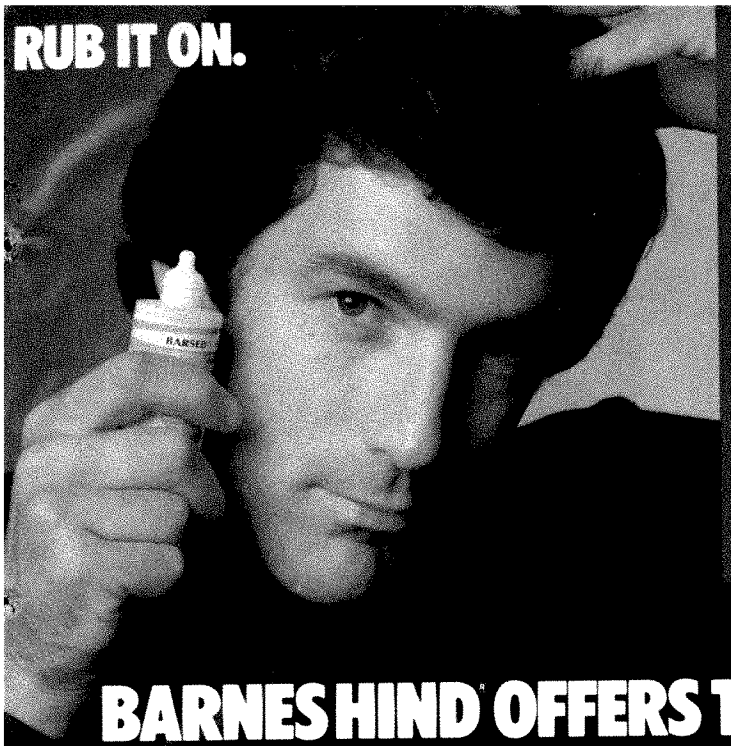

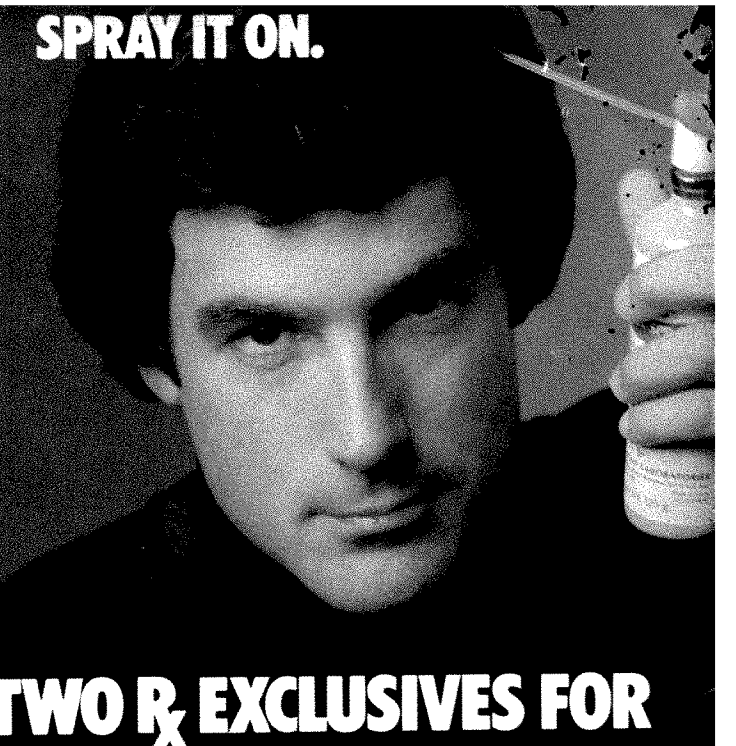

BARNES HIND OFFERS TWO Rx EXCLUSIVES FOR SEBORRHEIC DERMATITIS

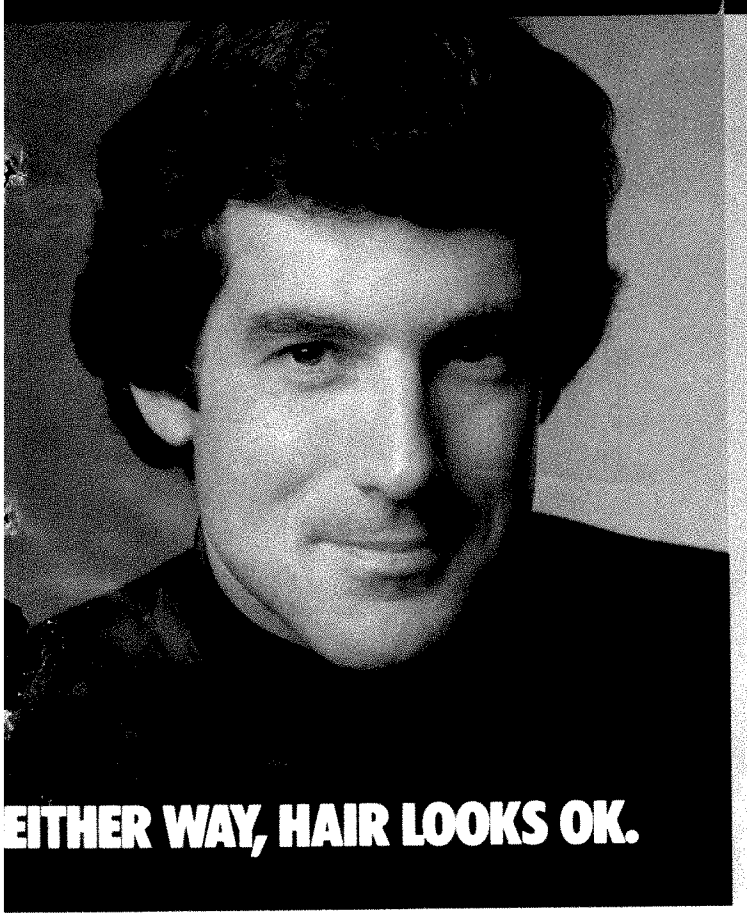

You can offer your seborrheic patients a choice of remedie that are effective yet cosmetically elegant—Barseb® Thera-Spray® and Barseb® HC Scalp Lotion.

Either way, you'll be prescribing Barnes Hind exclusive combinations of hydrocortisone and salicylic acid with their proven anti-inflammatory, antipruritic and keratolytic capabilities.

Without mussing the hair, the Thera-Spray snorkel directs the active ingredients onto the scalp in a vehicle that spreads and penetrates.

The Barseb HC base holds the active ingredients on the skin, not on the hair shafts. Barseb HC won't dry hair, or increase oiliness. And it's compatible with hair sprays, colorings, permanent waves and grooming agents.

Both Thera-Spray and Lotion are clear, non-staining, odorless.

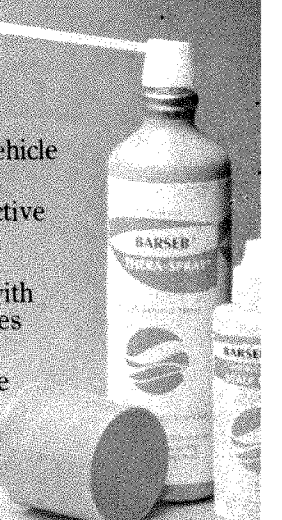

BARSEB® THERA-SPRAY®
BARSEB® HC SCALP LOTION

(hydrocortisone and salicylic acid)

For complete prescribing information, please see package insert.

CONTRAINDICATIONS
Hydrocortisone is contraindicated in tuberculosis, fungal, and most viral infections of the skin (especially herpes simplex, vaccina and varicella, etc).

WARNING
While topical steroids have not been reported to have an adverse effect on pregnancy, the safety of their use has not been absolutely established. Therefore, they should not be used extensively on pregnant patients in large amounts nor for long periods of time.
Avoid inhalation, ingestion or contact with eyes or nose.
BARSEB® THERA-SPRAY
Contents under pressure. Do not puncture, burn or

PRECAUTIONS
Transient discomfort may occur when first applied to an inflamed scalp. This normally disappears with repeated use. Discontinue use if condition does not improve or if sensitivity reactions occur. The anti-inflammatory action of hydrocortisone may mask the presence of infection. If bacterial or fungal infection exists or supervenes, concomitant antimicrobial or antifungal therapy should be considered. When topical steroids are used on large areas of skin for long periods of time, there is the possibility of systemic absorption. Should adrenal suppression, electrolyte imbalance, metabolic changes, or other symptoms of systemic absorption occur, suitable counter measures should be taken. Precautions should be taken when hydrocortisone is used in the treatment of skin diseases associated with impaired circulation such as stasis dermatitis.
Avoid spray inhalation, ingestion, or contact with eyes or nose. If medication accidentally gets into eyes, immediately flush with copious amounts of water; if irritation persists, notify your physician.
Keep out of reach of children.

CAUTION
U. S. Federal law prohibits dispensing without prescription.

Barnes Hind Pharmaceuticals, Inc
895 Kifer Road
Sunnyvale, California 94086

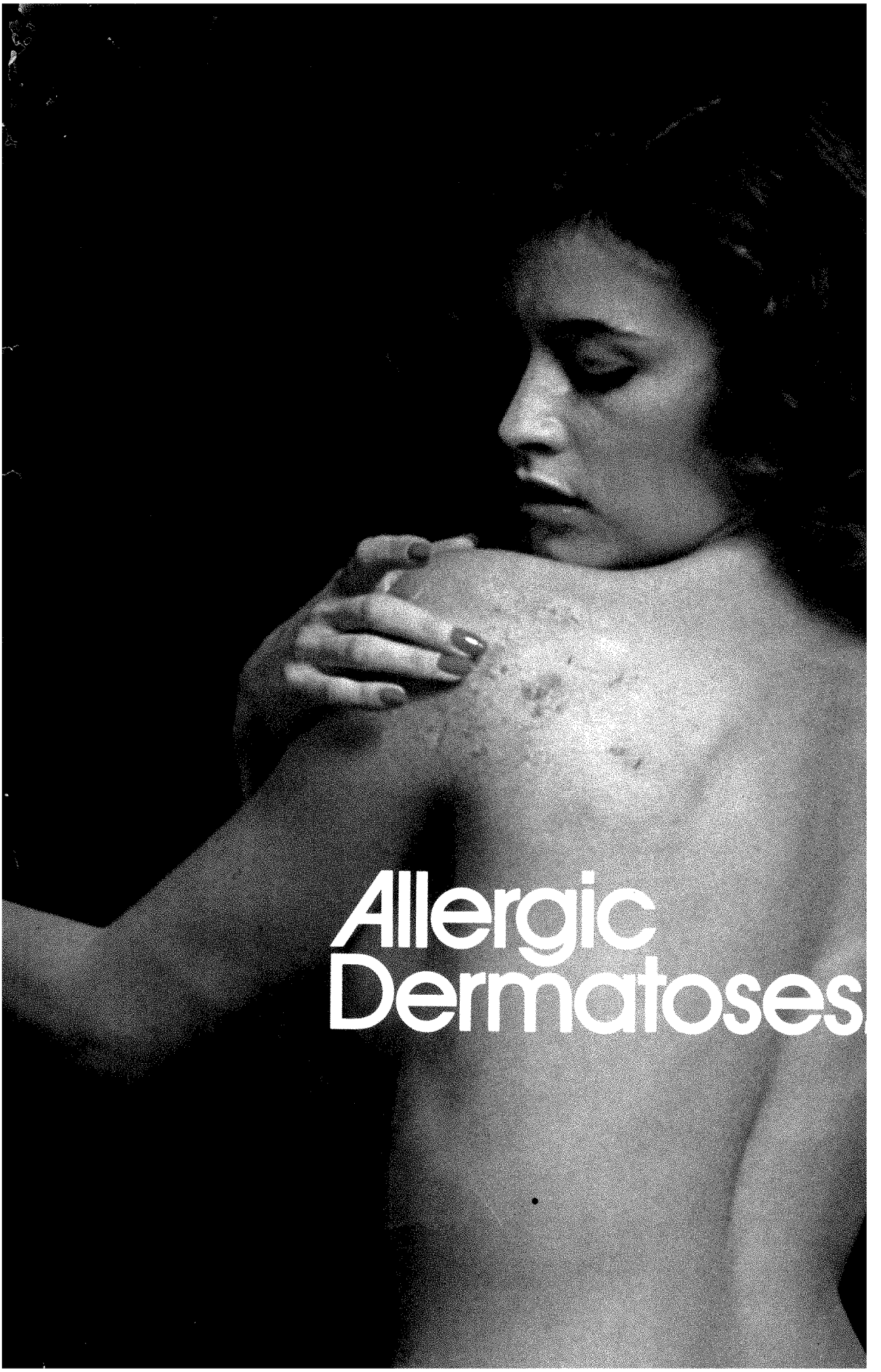
Allergic
Dermatoses

Contraindications: Hypersensitivity to hydroxyzine. Hydroxyzine, when administered to the pregnant mouse, rat, and rabbit, induced fetal abnormalities in the rat at doses substantially above the human therapeutic range. Clinical data in human beings are inadequate to establish safety in early pregnancy. Until such data are available, hydroxyzine is contraindicated in early pregnancy.

Precautions: Hydroxyzine may potentiate the action of central nervous system depressants such as meperidine and barbiturates. In conjunctive use, dosage for these drugs should be reduced. Because drowsiness may occur, patients should be cautioned against driving a car or operating dangerous machinery.

Adverse Reactions: Drowsiness may occur; if so, it is usually transitory and may disappear in a few days of continued therapy or upon dosage reduction. Dryness of the mouth may occur with higher doses. Involuntary motor activity, including rare instances of tremor and convulsions, has been reported, usually with higher than recommended dosage.

Supply: Tablets, containing 10 mg, 25 mg, or 50 mg hydroxyzine hydrochloride, 100's and 500's; Tablets, containing 100 mg, 100's; Syrup, containing 10 mg per teaspoonful (5 ml) and ethyl alcohol 0.5% v/v, pint bottles.

Before prescribing or administering, see package circular.

with strong emotional overlay

the cause can be obscure

Factors precipitating allergic dermatoses with strong emotional overlay, which can range from allergens to anxiety, can be difficult to identify.

successful treatment often includes

Atarax®
(hydroxyzine HCl)

TABLETS: 10 mg, 25 mg, 50 mg, and 100 mg

- rapid antianxiety action
- demonstrated antihistaminic activity

ROERIG Pfizer
A division of Pfizer Pharmaceuticals
New York, New York 10017

½
Therapeutic effectiveness with half the dose

Schering

Once-a-day dosage DD

Fulvicin® P/G*

brand of griseofulvin [ultramicrosize], USP

(specially processed) **125 mg. tablets**

*"P/G" means a new polyethylene glycol system for enhanced absorption –

A 250 mg. daily dose (two 125 mg. tablets) of new FULVICIN P/G can replace 500 mg. of griseofulvin (microsize), USP. This is made possible by a special process in which the ultramicrosize griseofulvin crystals are partly dissolved in polyethylene glycol and dispersed through the tablet matrix for enhanced absorption.

Patient convenience –

FULVICIN P/G can be prescribed as two 125 mg. tablets once a day. Compliance is further assured by the easy-to-swallow size of the tablets.

Patient savings –

FULVICIN P/G is up to 35 per cent less expensive per dose than all microsize griseofulvin formulations.**

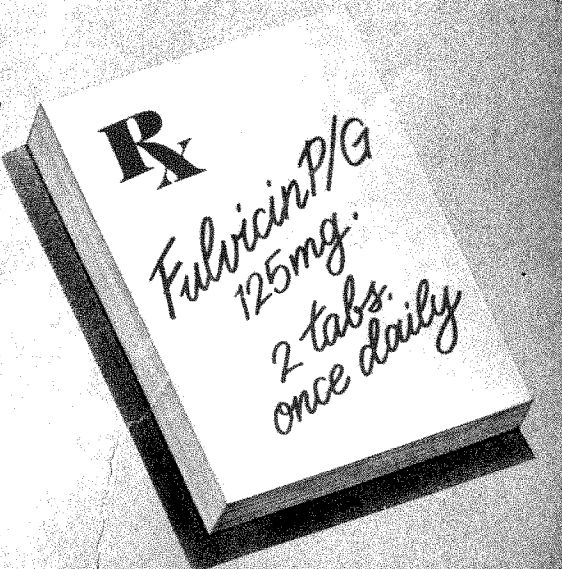

**Based on list-price comparison.

See Clinical Considerations section on following page...

COPYRIGHT © 1977, SCHERING CORPORATION. ALL RIGHTS RESERVED. SLS-945

Schering

Fulvicin P/G

griseofulvin [ultramicrosize], USP

(specially processed) **125 mg. tablets**

Clinical Considerations: INDICATIONS FULVICIN P/G Tablets are indicated for the treatment of ringworm infections of the skin, hair, and nails, namely: tinea corporis, tinea pedis, tinea cruris, tinea barbae, tinea capitis, tinea unguium (onychomycosis) when caused by one or more of the following genera of fungi: *Trichophyton rubrum, Trichophyton tonsurans, Trichophyton mentagrophytes, Trichophyton interdigitalis, Trichophyton verrucosum, Trichophyton megnini, Trichophyton gallinae, Trichophyton crateriform, Trichophyton sulphureum, Trichophyton schoenleini, Microsporum audouini, Microsporum canis, Microsporum gypseum,* and *Epidermophyton floccosum.* Note: Prior to therapy, the type of fungi responsible for the infection should be identified. The use of this drug is not justified in minor or trivial infections which will respond to topical agents alone. Griseofulvin is not effective in the following: Bacterial infections, Candidiasis (Moniliasis), Histoplasmosis, Actinomycosis, Sporotrichosis, Chromoblastomycosis, Coccidioidomycosis, North American Blastomycosis, Cryptococcosis (Torulosis), Tinea versicolor, and Nocardiosis. **CONTRAINDICATIONS** This drug is contraindicated in patients with porphyria, hepatocellular failure, and in individuals with a history of hypersensitivity to griseofulvin. **WARNINGS** *Prophylactic Usage:* Safety and efficacy of griseofulvin for prophylaxis of fungal infections have not been established. *Animal Toxicology:* Chronic feeding of griseofulvin, at levels ranging from 0.5-2.5% of the diet, resulted in the development of liver tumors in several strains of mice, particularly in males. Smaller particle sizes result in an enhanced effect. Lower oral dosage levels have not been tested. Subcutaneous administration of relatively small doses of griseofulvin once a week during the first three weeks of life has also been reported to induce hepatomata in mice. Although studies in other animal species have not yielded evidence of tumorogenicity, these studies were not of adequate design to form a basis for conclusions in this regard. In subacute toxicity studies, orally administered griseofulvin produced hepatocellular necrosis in mice, but this has not been seen in other species. Disturbances in porphyrin metabolism have been reported in griseofulvin-treated laboratory animals. Griseofulvin has been reported to have a colchicine-like effect on mitosis and cocarcinogenicity with methylcholanthrene in cutaneous tumor induction in laboratory animals. *Usage in Pregnancy:* The safety of this drug during pregnancy has not been established. *Animal Reproduction Studies:* It has been reported in the literature that griseofulvin was found to be embryotoxic and teratogenic on oral administration to pregnant rats. Pups with abnormalities have been reported in the litters of a few bitches treated with griseofulvin. Additional animal reproduction studies are in progress. Suppression of spermatogenesis has been reported to occur in rats, but investigation in man failed to confirm this. **PRECAUTIONS** Patients on prolonged therapy with any potent medication should be under close observation. Periodic monitoring of organ system function, including renal, hepatic, and hematopoietic, should be done. Since griseofulvin is derived from species of penicillin, the possibility of cross sensitivity with penicillin exists; however, known penicillin-sensitive patients have been treated without difficulty. Since a photosensitivity reaction is occasionally associated with griseofulvin therapy, patients should be warned to avoid exposure to intense natural or artificial sunlight. Should a photosensitivity reaction occur, lupus erythematosus may be aggravated. Griseofulvin decreases the activity of warfarin-type anticoagulants so that patients receiving these drugs concomitantly may require dosage adjustment of the anticoagulant during and after griseofulvin therapy. Barbiturates usually depress griseofulvin activity, and concomitant administration may require a dosage adjustment of the antifungal agent. **ADVERSE REACTIONS** When adverse reactions occur, they are most commonly of the hypersensitivity type, such as skin rashes, urticaria, and rarely, angioneurotic edema, and may necessitate withdrawal of therapy and appropriate countermeasures. Paresthesias of the hands and feet have been reported rarely after extended therapy. Other side effects reported occasionally are oral thrush, nausea, vomiting, epigastric distress, diarrhea, headache, fatigue, dizziness, insomnia, mental confusion, and impairment of performance of routine activities. Proteinuria and leukopenia have been reported rarely. Administration of the drug should be discontinued if granulocytopenia occurs. When rare, serious reactions occur with griseofulvin, they are usually associated with high dosages, long periods of therapy, or both.

10705231 JANUARY 1977

For more complete details, consult package insert or Schering literature available from your Schering Representative or Professional Services Department, Schering Corporation, Kenilworth, New Jersey 07033.



Remember to write the "P/G"

INDEX TO ADVERTISERS

A

Abbott Laboratories 1618-1619

B

Barnes-Hind Pharmaceuticals 1481, 1629

C

Ciba Pharmaceuticals 1504-1505
Cooper Laboratories, Inc. 1496

D

Dermik Laboratories 1500, 1601
Dista Products Company 1510
Doak Pharmacal Company 1627
Dome Laboratories 1487

G

General Medical Company 1508

H

Herbert, G.S., Laboratories, Division of Allergan Pharmaceuticals 1495, 1606
Hoechst-Roussel Pharmaceuticals 1492-1494

L

Lederle Laboratories, Division of American Cyanamid Company ..... 1594-1595, 3rd Cover

N

Neutrogena Corporation 1620-1621

O

Owen Laboratories, Inc. 1483

P

Pharmacia Diagnostics 1628
Photoeaze Manufacturing Inc. 1621
Procter & Gamble Company 1509, 1596
Purdue Frederick Company 1491

R

Reed & Carnrick 1502-1503
Roche Laboratories, Division of Hoffmann-LaRoche, Inc. 1488-1489
Roerig, J.B., Company Division of Pfizer, Inc. 1630-1631

S

Schering Corporation 1501, 1608-1609, 1632-1634
Squibb, E.R., & Sons, Inc. 1512-1513, 1624-1626
Stiefel Laboratories, Inc. 1511
Stuart Pharmaceuticals Div. of ICI United States Inc. 1597
Syntex Laboratories, Inc. 1484-1485, 1506-1508, 1602-1604

U

University of Iowa 1621

W

Westwood Pharmaceuticals, Inc. ..... 2nd Cover, 1499, 1514, 1607, 4th Cover

While every precaution is taken to insure accuracy, we cannot guarantee against the possibility of an occasional change or omission in the preparation of this index.

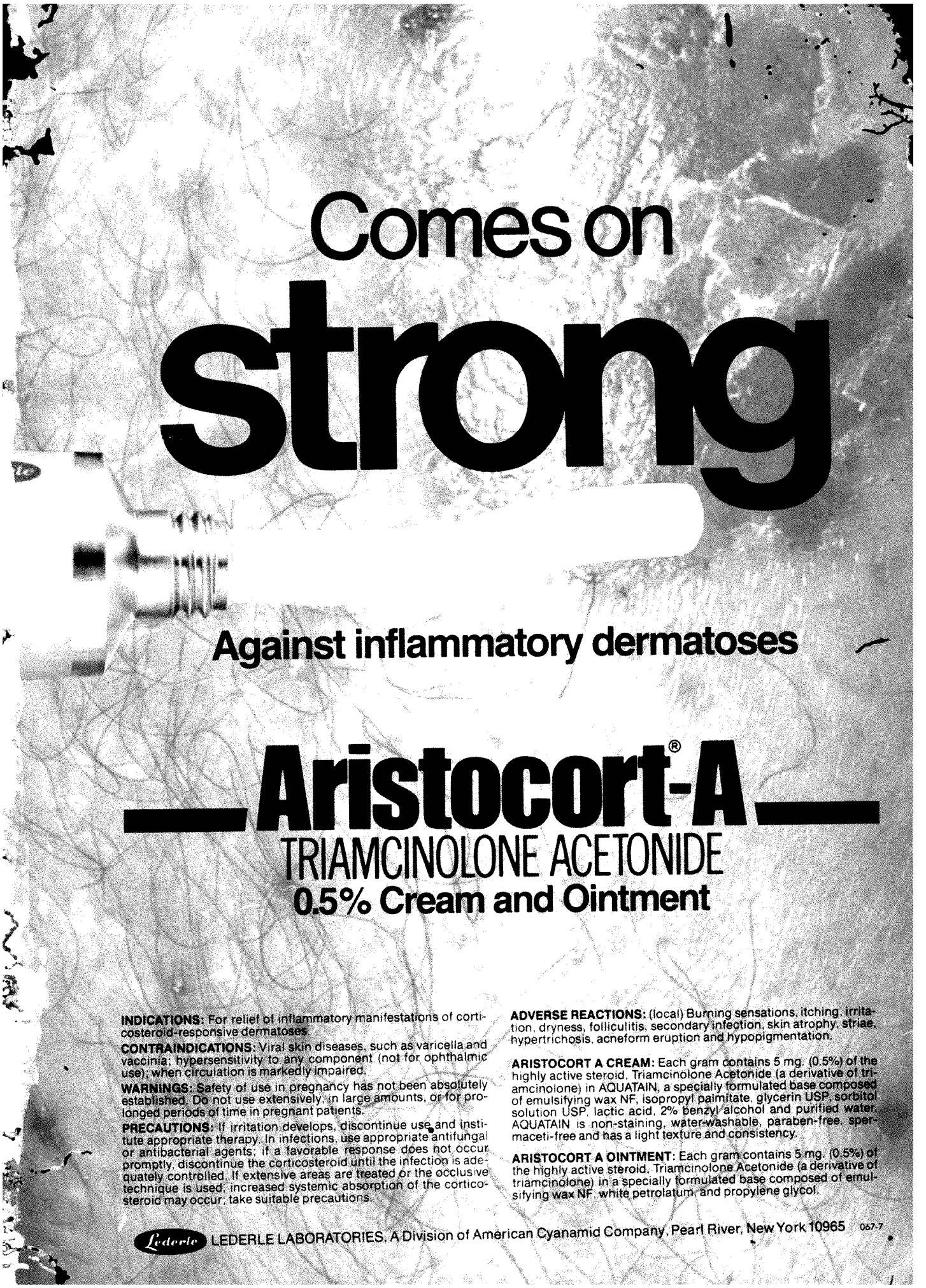

INDICATIONS: For relief of inflammatory manifestations of corticosteroid-responsive dermatoses.

CONTRAINDICATIONS: Viral skin diseases, such as varicella and vaccinia; hypersensitivity to any component (not for ophthalmic use); when circulation is markedly impaired.

WARNINGS: Safety of use in pregnancy has not been absolutely established. Do not use extensively, in large amounts, or for prolonged periods of time in pregnant patients.

PRECAUTIONS: If irritation develops, discontinue use and institute appropriate therapy. In infections, use appropriate antifungal or antibacterial agents; if a favorable response does not occur promptly, discontinue the corticosteroid until the infection is adequately controlled. If extensive areas are treated or the occlusive technique is used, increased systemic absorption of the corticosteroid may occur; take suitable precautions.

ADVERSE REACTIONS: (local) Burning sensations, itching, irritation, dryness, folliculitis, secondary infection, skin atrophy, striae, hypertrichosis, acneform eruption and hypopigmentation.

ARISTOCORT A CREAM: Each gram contains 5 mg. (0.5%) of the highly active steroid, Triamcinolone Acetonide (a derivative of triamcinolone) in AQUATAIN, a specially formulated base composed of emulsifying wax NF, isopropyl palmitate, glycerin USP, sorbitol solution USP, lactic acid, 2% benzyl alcohol and purified water. AQUATAIN is non-staining, water-washable, paraben-free, spermaceti-free and has a light texture and consistency.

ARISTOCORT A OINTMENT: Each gram contains 5 mg. (0.5%) of the highly active steroid, Triamcinolone Acetonide (a derivative of triamcinolone) in a specially formulated base composed of emulsifying wax NF, white petrolatum, and propylene glycol.

Lederle LEDERLE LABORATORIES, A Division of American Cyanamid Company, Pearl River, New York 10965 067-7

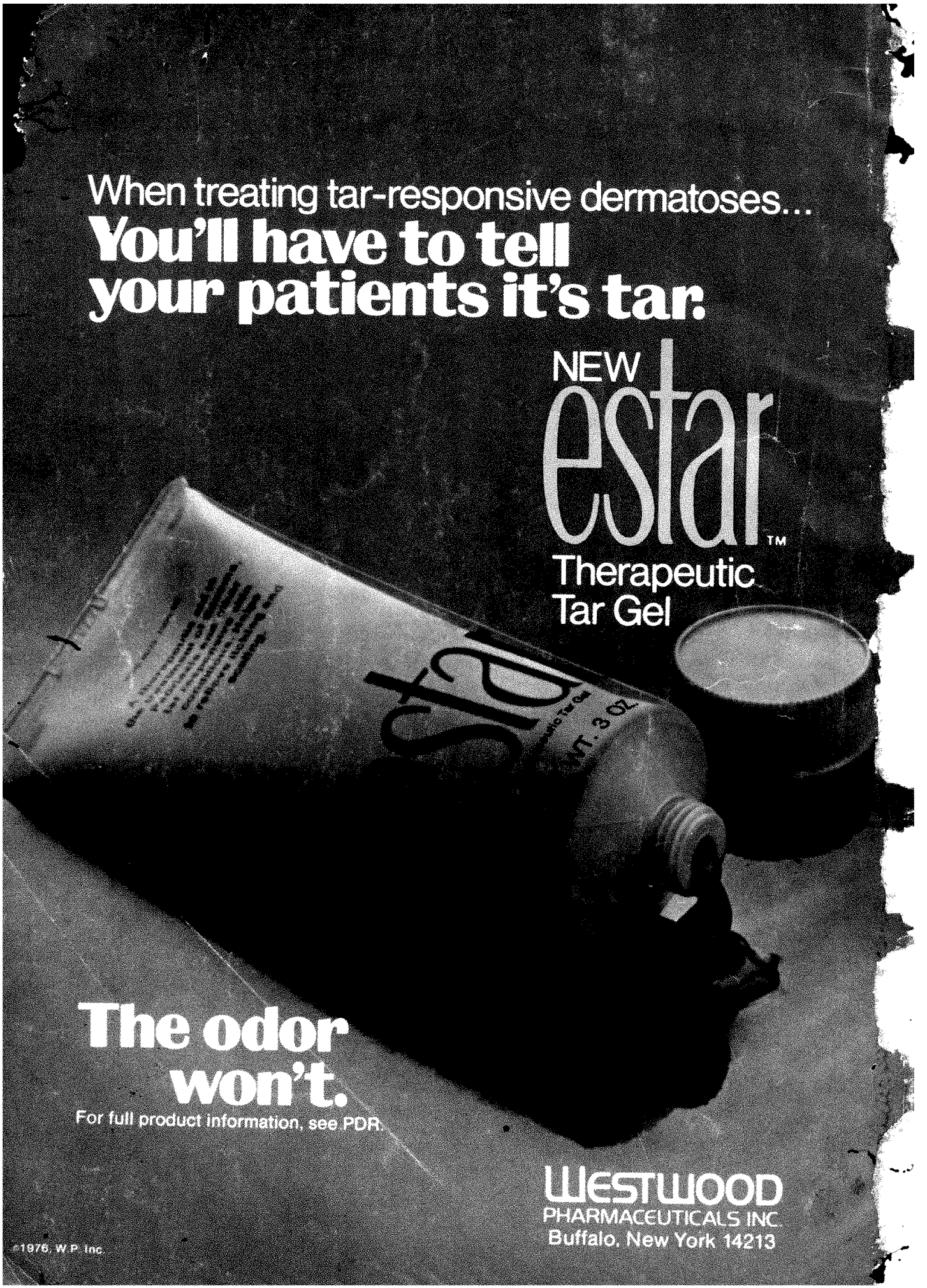
When treating tar-responsive dermatoses...
You'll have to tell your patients it's tar.
NEW
estar™
Therapeutic Tar Gel
The odor won't.
For full product information, see PDR.
WESTWOOD PHARMACEUTICALS INC.
Buffalo, New York 14213
©1976, W.P. Inc.